



LUND UNIVERSITY

Radiography, tomosynthesis, CT and MRI in the evaluation of pulmonary cystic fibrosis: an untangling review of the multitude of scoring systems.

Vult von Steyern, Kristina; Björkman-Burtscher, Isabella; Geijer, Mats

Published in:
Insight Into Imaging

DOI:
[10.1007/s13244-013-0288-y](https://doi.org/10.1007/s13244-013-0288-y)

2013

[Link to publication](#)

Citation for published version (APA):

Vult von Steyern, K., Björkman-Burtscher, I., & Geijer, M. (2013). Radiography, tomosynthesis, CT and MRI in the evaluation of pulmonary cystic fibrosis: an untangling review of the multitude of scoring systems. *Insight Into Imaging*, 4(6), 787-798. <https://doi.org/10.1007/s13244-013-0288-y>

Total number of authors:
3

General rights

Unless other specific re-use rights are stated the following general rights apply:
Copyright and moral rights for the publications made accessible in the public portal are retained by the authors and/or other copyright owners and it is a condition of accessing publications that users recognise and abide by the legal requirements associated with these rights.

- Users may download and print one copy of any publication from the public portal for the purpose of private study or research.
- You may not further distribute the material or use it for any profit-making activity or commercial gain
- You may freely distribute the URL identifying the publication in the public portal

Read more about Creative commons licenses: <https://creativecommons.org/licenses/>

Take down policy

If you believe that this document breaches copyright please contact us providing details, and we will remove access to the work immediately and investigate your claim.

LUND UNIVERSITY

PO Box 117
221 00 Lund
+46 46-222 00 00

Radiography, tomosynthesis, CT and MRI in the evaluation of pulmonary cystic fibrosis: an untangling review of the multitude of scoring systems

Kristina Vult von Steyern · Isabella M. Björkman-Burtscher · Mats Geijer

Received: 26 May 2013 / Revised: 4 July 2013 / Accepted: 2 September 2013 / Published online: 25 September 2013
© The Author(s) 2013. This article is published with open access at Springerlink.com

Abstract

Objective The first radiographic scoring system for pulmonary cystic fibrosis was presented in 1958. Since then a multitude of scoring systems for radiography and computed tomography (CT) have been presented, recently also for tomosynthesis and magnetic resonance imaging (MRI). The aim of the current review was to analyse and compare the plethora of scoring systems for cystic fibrosis, especially regarding which scoring components are considered most important.

Methods Four scoring systems for chest radiography, one for tomosynthesis, eight for CT and one for MRI were compared regarding components evaluated and their terminology; the areas scored; scoring levels; the weighting of each component in percentage of the total score; and the calculations for the final score.

Results In most radiological scoring systems the lungs are evaluated for increased volume, bronchial wall thickening, bronchiectasis, mucus plugging, atelectasis and consolidation. In addition, for instance abscesses, bullae, septal thickening, mosaic perfusion, ground glass opacities and air trapping are evaluated in some CT scoring systems. Pleural affection and perfusion defects are scored on MRI.

Conclusions Bronchiectasis alone, or in combination with mucus plugging, is given the highest weighting in most scoring

systems and is thus commonly considered to be the most significant finding when evaluating cystic fibrosis lung disease.

Teaching points

- Scoring of examinations is used for comparison of outcome in studies.
- Scoring of examinations can also be used for monitoring disease progression.
- Cystic fibrosis can be scored on radiography, tomosynthesis, CT or MRI.
- The typical imaging findings of cystic fibrosis depend on the imaging modality used.
- Bronchiectasis is commonly considered the most significant finding when scoring cystic fibrosis.

Keywords Cystic fibrosis · Magnetic resonance imaging · Radiography · Tomography, X-ray · Tomography, X-ray computed

Introduction

Radiological scoring systems for pulmonary cystic fibrosis have been introduced to allow for a standardised and robust comparison of radiological scoring to clinical scoring and for comparison of outcomes within patient groups in different studies. The evaluation of radiological studies is more objective when using a scoring system than simply describing the abnormal imaging findings.

Typical imaging features of cystic fibrosis are overinflation, bronchial wall thickening, bronchiectasis, mucus plugging, atelectasis and consolidation. In addition, abscesses, cysts, bullae, thickened inter- or intra-lobular septa, mosaic perfusion, ground glass opacities and air-trapping can be evaluated with

K. Vult von Steyern (✉) · I. M. Björkman-Burtscher · M. Geijer
Center for Medical Imaging and Physiology, Skåne University
Hospital, Lund, Lund University, 221 85 Lund, Sweden
e-mail: kristina.vult_von_steyern@med.lu.se

I. M. Björkman-Burtscher
Lund University Bioimaging Centre, Lund University, Lund,
Sweden

computed tomography (CT). Radiography is often used to follow the development of pulmonary changes in cystic fibrosis, and to detect complications of the disease. CT is the modality which offers the best combination of high contrast resolution and detailed spatial resolution about the morphological findings in cystic fibrosis, but the role of CT is under investigation. It has up to now mainly been used for research purposes, due to the comparatively high radiation dose [1–3]. Recently tomosynthesis [4–6] and magnetic resonance imaging (MRI) [7–9] have appeared as alternatives to CT for more detailed evaluation of the pulmonary changes compared with radiography.

The first radiographic scoring system for pulmonary cystic fibrosis was presented by Shwachman and Kulczycki in 1958 [10]. Since then a multitude of scoring systems for radiography [11–21] and CT [22–35], and recently also scoring systems for tomosynthesis (digital tomography) [5] and MRI [9] have been presented. The aim of the current review was to analyse and compare the plethora of scoring systems for cystic fibrosis, with focus on the differences of the imaging modalities used and scoring components considered most important.

Materials and methods

Selection of scoring systems

From a survey of the literature and a search in PubMed (search terms: cystic fibrosis, scoring, system, radiography, computed tomography, tomosynthesis and MRI) followed by a manual perusal of references in the selected articles to locate all published scoring systems totally 28 scoring systems were found, 12 for radiography [10–21], one for tomosynthesis [5], 14 for CT [22–35] and one for MRI [9]. To select the most widely used scoring systems for the current review, scoring systems for radiography and CT with 25 or more citations in the Citation Index of the Web of Science database were selected for analysis. The scoring systems for tomosynthesis and MRI were published in 2012; consequently both systems yet have fewer citations in the Web of Science database.

Seven cystic fibrosis scoring systems for chest radiography with 25 or more citations were found in the Web of Science database, but the Shwachman-Kulczycki scoring system from 1958 [10], the National Institutes of Health (NIH) clinical score from 1973 [12] and the Royal Children's Hospital (RCH) pulmonary score from 1981 [14] were excluded since the scores are a part of clinical scores not included in this review and other authors have shown that the Brasfield score [11] is superior to those scoring systems [36, 37]. Thus four radiography scoring systems remained for analysis: the Chrispin-Norman scoring system from 1974 [13] (with modifications 1982 [15] and 2005 [21]), the Brasfield scoring system from 1979 [11], the Wisconsin scoring system from 1993 [18] (with validation in 2000 [20]) and the Northern scoring system from 1994 [19].

Nine chest CT cystic fibrosis scoring systems with 25 or more citations were found in the Web of Science database, but the Brody I scoring system [29] was excluded from the comparison due to the development of the Brody II scoring system [34]. Thus, eight CT scoring systems remained for analysis: Bhalla [22] and Nathanson [23] from 1991, Maffessanti from 1996 [25], Shah from 1997 [27], Santamaria from 1998 [28], Helbich from 1999 [30, 38], Robinson from 2001 [32], and Brody II from 2004 [34] (Table 3). The scoring systems by Shah [27], Santamaria [28], Helbich [30], and Robinson [32] are developed from the Bhalla scoring system [22].

Evaluated components

The analysis of the scoring systems included an evaluation of: (1) The abnormalities scored such as increased lung volume, bronchial wall thickening, mucus plugging, bronchiectasis and parenchymal changes (e.g. atelectasis, consolidation, cysts and bullae) as well as the terminology used to describe these components; (2) the area scored for the components in each system (a general overview, evaluation per quadrant, per lobe, or per bronchopulmonary segment); (3) the number of scoring levels used for each component; (4) the weighting applied to each component as a percentage of the total score; (5) the calculations needed to reach the final score.

Results

The pulmonary abnormalities associated with cystic fibrosis have different appearances depending on the modality chosen to evaluate them (Fig. 1), and certain abnormalities can only be evaluated with CT or MRI, since CT has a higher contrast resolution than radiography and tomosynthesis and MRI is performed with intravenous contrast, enabling detection of perfusion defects (Table 1).

Radiography

Tables 2 and 3 give an overview of the four evaluated radiographic scoring systems. As the systems use two different scoring approaches, Table 2 shows one system based on integrated scores for lung areas and Table 3 shows three systems based on separate scoring components. In the modified Chrispin-Norman scoring system from 2005 [21], as well as in the Northern scoring system [19], only the frontal radiograph is needed for scoring.

Scored abnormalities

In all reviewed scoring systems for radiography (Tables 2 and 3), increased lung volume is scored separately, except in the Northern score [19] where it is included in the overall impression

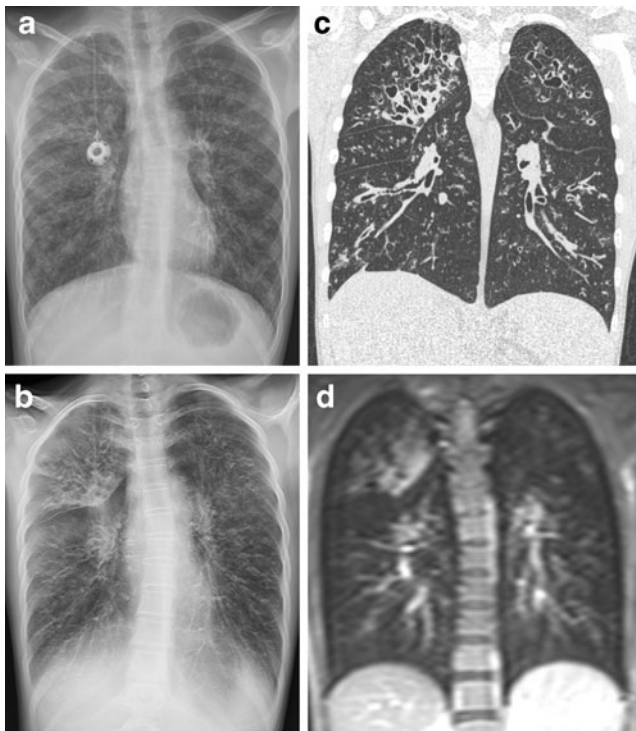


Fig. 1 A 15-year-old girl with cystic fibrosis examined with the four different imaging modalities within 4 months. A frontal radiograph (a) acquired on the same occasion as the tomosynthesis examination (b). CT (c) performed four months earlier and MRI (d) performed 2 weeks earlier (T1-weighted sequence, with intravenous contrast). Tomosynthesis, CT and MRI sections were selected to represent approximately the same imaging plane, to simplify the comparison between the modalities. Overinflation, bronchial wall thickening, bronchiectasis and mucus plugging were present in both lungs, with the most severe changes in the right upper lobe

score. Increased lung volume is described as altered chest configuration [13], air trapping [11], hyperinflation [15, 18, 20] or overinflation [21]. Bronchial wall thickening, evaluated in all scoring systems, is described as bronchial line shadows [13, 15], linear markings [11, 19] or peribronchial thickening [18, 20]. Bronchiectasis and mucus plugging are described as ring shadows and mottled shadows [13], as bronchiectasis and nodular-branching opacities [18], or scored together as nodular-cystic lesions [11, 19]. The parenchyma, evaluated in all scoring systems, is scored for large shadows [13], large lesions [11], large soft shadows [21], large round or ill-defined opacities [18], or collapse or consolidation [19]. In the Northern and the Brasfield scoring systems the overall [19] or general [11] severity is also scored, giving more flexibility according to the authors of the Northern scoring system as well as others [36].

Scoring areas

The Northern [19] scoring system (Table 2) gives an integrated score for all pulmonary abnormalities for each of the four lung quadrants. The other three systems [11, 13, 18] (Table 2) give separate scores for both lungs, central versus peripheral lung, lung zones, quadrants or lobes to each of the different pulmonary

abnormalities such as increased lung volume, bronchial wall thickening, mucus plugging, bronchiectasis and large lesions.

Scoring levels

The Chrispin-Norman score [13] has three scoring levels (not present, present but not marked and marked) which are comparable to the Wisconsin scores [18] (none, mild, and severe) for bronchiectasis and nodular-branching opacities. In the Wisconsin score, large opacities are scored as absent or present, and then the numbers of affected lobes are rated. The other scoring systems predominately use five scoring levels.

Weighting of components

In the Chrispin-Norman [13] and the Wisconsin [18] scoring systems, the combination of bronchiectasis and mucus plugging is given the highest weighting in percentage of the total score (Table 7, Fig. 2). In the Wisconsin score, parenchymal changes are also given a high weighting. In the Brasfield score [11], large lesions and general severity are given the highest weightings, while bronchiectasis and mucus plugging are given comparatively low weightings.

Calculations for final score

The possible total scores for the evaluated scoring systems differ (Tables 2 and 3), as do the ways used to reach the final score; from simple addition to a complicated multiplicative [18] or additive [20] model.

Tomosynthesis

There is currently only one published scoring system for tomosynthesis, developed by Vult von Steyern et al. [5] (Table 4).

Scored abnormalities and scoring areas

Both lungs are scored for the degree of overinflation on the frontal and lateral radiographs, in comparison with reference images available on the publisher's web site. Each lung quadrant is scored for bronchial wall thickening, parenchymal lesions (atelectasis or consolidation), number and appearance of bronchiectatic bronchi and large (>5 mm) or small (<5 mm) mucus plugs, using all tomosynthesis sections covering the quadrant in question.

Scoring levels

The scoring components overinflation, parenchymal lesions, bronchiectasis and mucus plugging have five scoring levels (0–4). Bronchial wall thickening has three scoring levels (0–2–4).

Table 1 A comparison of the four different radiological modalities regarding the ability to depict cystic fibrosis changes of the lungs (yes or no), as well as for cost; need for anaesthesia in young children; detail of information provided by the imaging modality; simplicity of the

examination procedure; and radiation dose [6, 46, 47]. The approximate cost for each modality (derived from the price list of Skåne Regional Council, Sweden) was compared with the cost of a frontal and lateral radiograph, which was given the factor 1

		Radiography	Tomosynthesis	CT	MRI
<i>Evaluated abnormalities:</i>					
Lung volume	Increased lung volume	Yes	Yes	Yes	No
	Emphysema	No	No	Yes	No
	Air trapping (expiratory images)	No	No	Yes	No
Bronchial wall thickening		(Yes) ^a	Yes	Yes	(Yes) ^b
Bronchiectasis	Mucus plugging/ radiography	(Yes) ^a	Yes	Yes	(Yes) ^b
Mucus plugging			Yes	Yes	Yes
Parenchyma	Consolidation	Yes	Yes	Yes	Yes
	Atelectasis	Yes	Yes	Yes	Yes
	Cysts/Bullae	(Yes) ^a	Yes	Yes	(Yes) ^a
	Abscesses	(Yes) ^a	Yes	Yes	Yes
	Thickened intra-/inter-lobular septa	No	No	Yes	No
	Mosaic perfusion	No	No	Yes	No
	Ground glass opacities	No	No	Yes	No
Pulmonary perfusion		No	No	No	Yes
Pleural affection		Yes	Yes	Yes	Yes
Cost, compared with radiography		1	1.1	5.5	10.7
Anaesthesia required for young children		No	Yes	(Yes) ^c	Yes
Detail of information		Low	Medium	High	Medium
Quick and easy to perform		Yes	Yes	(Yes) ^c	No
Mean radiation dose (mSv)		0.09–0.1	0.12–0.13	7–8	0

^a Using radiography and MRI these changes are inferiorly discerned, compared with tomosynthesis and CT

^b MRI cannot differentiate between bronchial wall thickening and bronchiectasis, especially in the lung periphery [9]

^c Depending on the CT system used

The most severe score is 4 for all scoring components and subcomponents.

Weighting of components

The highest weighting is given bronchiectasis and mucus plugging, with 32% each of the maximum score (Table 7).

Calculations for final score

The maximum score is calculated by summation of the subscores, with a maximum total score of 100.

Computed tomography

Scored abnormalities

Combined radiographic pathology, such as nodular-cystic lesions [11] and mottled and ring shadows [13], is resolved into more detail on chest CT and scored separately as mucus plugging and bronchiectasis in the CT scoring systems (Table 4).

Bronchial wall thickening is also seen more clearly on CT, corresponding to radiographic scoring terms such as bronchial line shadows [13] and linear markings [11]. Increased lung volume is scored as emphysema [22, 30] or overinflation [25]. Three of the CT scoring systems score air trapping on expiratory images [28, 32, 34] (in the current review this scoring component has been included in the score for increased lung volume). The Nathanson CT scoring system [23] scores only bronchiectasis and mucus plugging. The other chest CT scoring systems all evaluate bronchial wall thickening, bronchiectasis, mucus plugging and parenchymal lesions, with the exception of the Maffessanti system [25], where mucus plugging is regarded as a transient phenomenon and recorded separately from the total score. Sacculations and abscesses are scored in the Bhalla [22] and the Helbich [30] scoring systems. In the Shah scoring system [27], air-fluid levels and centrilobular nodules are scored. In the Santamaria [28] and the Brody II [34] systems, ground glass opacities are scored either separately or as a part of the parenchyma score. In the Santamaria scoring system [28], thickening of intra- and interlobular septa as well as acinar nodules or consolidations are

Table 2 An overview of the Northern scoring system [19], adapted from the original publication

Radiography scoring system	Northern (1994) [19]	
	Comment	Score (points)
Scoring area	4 lung quadrants	0–4
	Both lungs (overall severity)	0–4
Scoring	No cystic fibrosis lung disease evident	Normal (0)
	Minimal increase in linear markings and/or nodular cystic lesions up to 0.5 cm diameter	Mild (1)
	More pronounced linear markings and/or more widespread nodular cystic lesions	Moderate (2)
	Prominent increase in linear markings, profuse nodular cystic lesions, large areas of collapse/consolidation	Severe (3)
	Little or no area of normal lung seen, dense infiltration	Very severe (4)
Overall severity		Range 0–4
Total score		Maximum 20

scored. The Helbich system [30] scores mosaic perfusion (Table 5).

Scoring areas

The chest CT scoring systems score the abnormalities per bronchopulmonary segment [22, 27, 28, 30], 12 zones [23], six lobes [27, 32, 34] or four regions [25]. In the Bhalla [22], the Santamaria [28] and the Helbich [30] scoring systems, bronchiectasis is scored both for severity, extent (number of bronchopulmonary segments involved) and for number of generations of bronchial divisions involved (this score component also includes mucus plugging). In the Maffessanti scoring system [25], bronchiectasis and bronchial wall thickening are scored for severity and extent (central, intermediate, to peripheral lung), and then the percentage of regional involvement is assessed both for the bronchial score and for the parenchyma score. In the Brody II scoring system [34], bronchiectasis and peribronchial thickening are scored for severity and extent (central to peripheral lung).

Scoring levels

In the scoring systems for CT most components are scored using four grades (0–3). In the Nathanson [23] scoring system, six grades are used for scoring bronchiectasis, and mucus plugging is scored as absent or present. In the Robinson [32] scoring system, five grades are used for all components.

Weighting of components

In the majority of the CT scoring systems the highest weighting in percentage of the total score is given bronchiectasis, except in the Robinson [32] and Santamaria [28] scoring

systems. In the Robinson scoring system [32], all scoring components are given the same weighting (20%), and in the Santamaria system [28] parenchymal changes are given the highest weighting (43%). Bronchiectasis together with mucus plugging is given the highest weighting in all scoring systems, except in the Santamaria system, and the parenchymal abnormalities are given a relatively high weighting in many scoring systems (Table 7, Fig. 2). However, the range of the weighting of components in the scoring systems is wide (Table 7).

Calculations for final score

As for radiography, the final scores for CT are also arrived at by means of varying degrees of complicated mathematics, ranging from simple additive scores to the Brody II score [34], where a theoretical maximum of 243 points cannot be greater than 207, and the resultant score is normalised to a grading from 0 to 100.

MRI

As for tomosynthesis, there is currently only one published scoring system for MRI, developed by Eichinger et al. [9] (Table 6).

Scored abnormalities and scoring areas

Six lung lobes (the lingula is considered a single lobe) are scored for bronchiectasis/wall thickening, mucus plugging, abscess/sacculation, consolidation, special findings and perfusion defect size (after intravenous contrast). Bronchiectasis and bronchial wall thickening are scored as a single entity since the spatial resolution of MRI does not allow for differentiation between them. Special findings relate to pleural affection, reflecting for example pleural effusion, pleural reaction/pleurisy or pneumothorax [9].

Table 3 An overview of three scoring systems for chest radiography in cystic fibrosis, adapted from the original publications. The modification of the Chrispin-Norman score from 1982 [19] also included enlarged hilar lymph nodes in the score, in this table included in the parenchyma score.

In the Wisconsin scoring system [18] each scoring component is weighted, the range for each component score was calculated by using the formula given in the publication

Radiography scoring systems	Chrispin-Norman (1974) [13] Modified 1982 [15] Modified 2005 [21]	Brasfield (1979) [11]	Wisconsin (1993) [18] Validated 2000 [20]
Scoring area	4 zones	Both lungs	- central/peripheral (peribronchial thickening) - 4 quadrants (bronchiectasis, nodules) - 5 lobes (opacities, atelectasis)
Scoring components/scoring levels, scoring range			
Increased lung volume	Chest configuration [13] - Sternal bowing - Diaphragm depression - Spinal kyphosis Overinflation [21] - Diaphragm depression - Chest wall shape - Lung fields <i>Each finding is scored 0–2</i> Range 0–6	Air trapping - sternal bowing - depression of diaphragm - and/or thoracic kyphosis 0–4 Range 0–4	Hyperinflation - diaphragm contour - retrosternal lucency - heart position - sternal bowing - kyphosis 0–1 (Range 0–12.5)
Bronchial wall thickening	Bronchial line shadows <i>Each zone 0–2</i> Range 0–8	Linear markings 0–4 Range 0–4	Peribronchial thickening 0–1 (Range 0–12.5)
Bronchiectasis and mucus plugging	- Ring shadows 0–2 - Mottled shadows 0–2 Range 0–16	Nodular cystic lesions 0–4 Range 0–4	- Bronchiectasis 0–1 (Range 0–31) - Nodular branching opacities 0–1 (Range 0–12.5)
Parenchyma	Large shadows <i>Each zone 0–2</i> Range 0–8 (Enlarged hilar shadows [15]) 0–2 × 2 Range 0–4	Large lesions 0–5 Range 0–5	- Large opacities 0–1 (Range 0–12.5) - Atelectasis 0–1 (Range 0–19)
Overall severity		0–5 Range 0–5	
Total score	Maximum 38 [13, 21] Maximum 42 [15]	Maximum 22	Maximum 100 p - Multiplicative model [18] - Additive model [20]

Scoring levels

The scoring levels 0–1–2 are used for all parameters, where 1 implies involvement of less than 50% of the lobe and 2 implies involvement of more than 50% of the lobe.

Weighting of components

All components of the score are given the same weighting, 17% of the maximum score (Table 7).

Calculations for final score

The maximum score is calculated by summation of the subscores, with a maximum score of 12 per lobe and a maximum total score of 72.

Discussion

The evolution of radiological scoring systems for pulmonary cystic fibrosis reflects a desire to translate the pathological

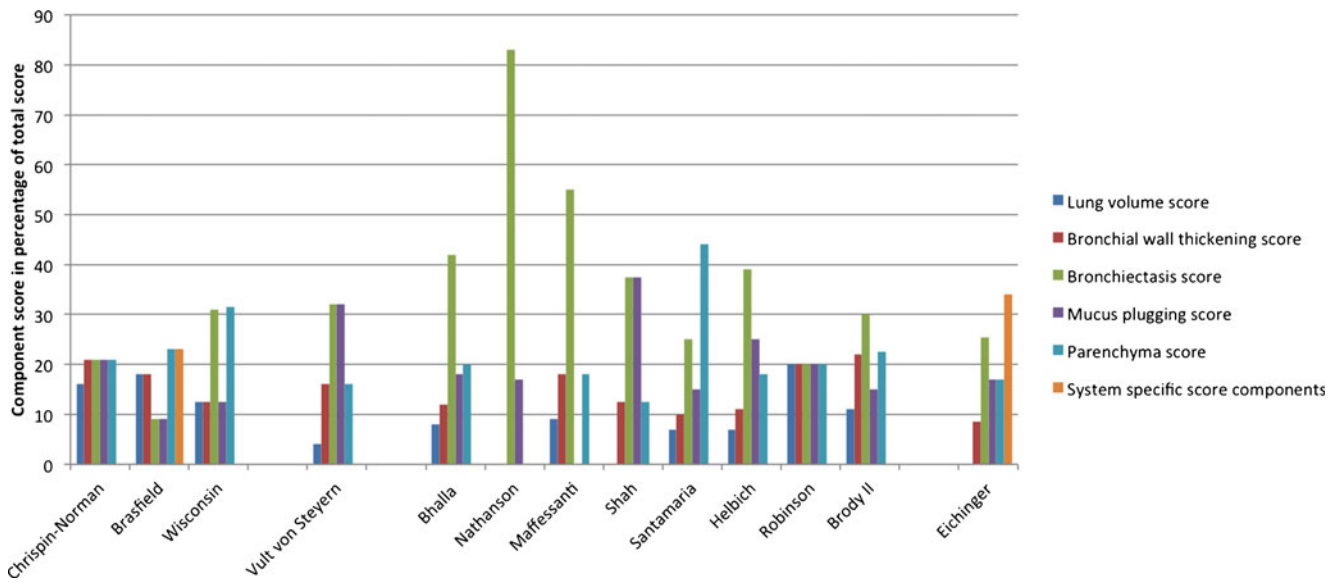


Fig. 2 A comparison of the weighting of scoring components (percentage of total score) in three radiographic scoring systems [11, 13, 18], one tomosynthesis scoring system [5], eight CT scoring systems [22, 23, 25, 27, 28, 30, 32, 34], and one MRI scoring system [9]. The Brasfield system [11] scores bronchiectasis and mucus plugging together as “nodular cystic

lesions”, and in the MRI score bronchiectasis and bronchial wall thickening are scored together. In this table these scores are divided between the two entities. “System specific score components” refer to general severity in the Brasfield score [11], and special findings and perfusion size in the MRI score [9]

findings in the images into numbers, in a reproducible and objective way. Clinicians are of course interested in the general disease progression, but also in the progression of a separate component, such as mucus plugging, atelectasis or

consolidation since treatment then can be focused on a specific pathology with a specific therapy. Chest radiography is the most widely used imaging modality to track the progression of cystic fibrosis lung disease, since it is easy to perform and the radiation dose and cost are low. Scoring systems for tomosynthesis, CT and MRI are still mainly used for research purposes. The different modalities obviously have different abilities to detect cystic fibrosis changes, but when deciding which modality to choose in the follow-up of patients with cystic fibrosis other aspects are of course also important, such as radiation dose, cost and the possibility to perform the examination on young children without anaesthesia (Fig. 1, Table 1).

Table 4 An overview of the scoring system for tomosynthesis presented by Vult von Steyern et al. [5], adapted from the original publication

Tomosynthesis scoring system	Vult von Steyern [5] (2012)
Scoring area	Overinflation: both lungs Other components: 4 quadrants
Scoring components/scoring levels, scoring range	
Increased lung volume	Overinflation, overall impression 0–4, Range 0–4
Bronchial wall thickening	Each quadrant 0–2–4, Range 0–16
Bronchiectasis	-Number of bronchiectasis Each quadrant 0–4, Range 0–16 -Appearance of widest bronchiectasis Each quadrant 0–4, Range 0–16
Mucus plugging	-Large mucus plugs Each quadrant 0–4, Range 0–16 -Small mucus plugs Each quadrant 0–4, Range 0–16
Parenchyma	Atelectasis or consolidation Each quadrant 0–4, Range 0–16
Total score	Maximum 100 (sum of subscores)

Figures from studies using different radiological scoring systems are difficult to compare, due to the different scoring components and scoring areas used by the scoring systems, and also from divergences in weighting and terminology. For example, “bronchial wall thickening” [25, 29] may also be called “bronchial line shadows” [13], “linear markings” [11, 19] or “peribronchial thickening” [18, 34]. Chest CT and tomosynthesis obviously have a greater ability to detect early abnormalities that may have similar appearances on radiography, there reflected in radiographic scoring terms such as “nodular cystic lesions” [11, 19], whereas CT and tomosynthesis scoring systems may differentiate these lesions into “mucus plugging” and “bronchiectasis”. MRI, on the other hand, is more sensitive to mucus plugging compared with CT [8], but cannot evaluate air trapping or differentiate

Table 5 An overview of eight scoring systems for CT in cystic fibrosis, adapted from the original publications. In the Bhalla [22], Santamaria [28] and Helbich [30] scores, the generations of bronchial divisions involved for bronchiectasis and mucus plugging are scored separately, in this table this entity is divided between the scores for bronchiectasis and mucus plugging. In the Brody II score [34], air trapping is scored both for extent and appearance (subsegmental or larger). The maximum scores for the Maffessanti [25] and the Robinson [32] scoring systems were calculated from the data in the original publications, since they were not reported there

CT scoring systems	Bhalla [22] (1991)	Nathanson [23] (1991)	Maffessanti [25] (1996)	Shah [27] (1997)	Santamaria [28] (1998)	Helbich [30] (1999)	Robinson [32] (2001)	Brody II [34] (2004)
Scoring area	BPS	12 zones	4 regions	6 zones + BPS (modified Bhalla)	BPS (modified Bhalla)	BPS (modified Bhalla)	6 lobes (modified Bhalla)	6 lobes (modified Brody I)
Scoring components/scoring levels, scoring range								
Increased lung volume	Emphysema 0–2 Range 0–2		Overinflation 0–1 Range 0–1	Air trapping 0–2 (expiratory scans if regional reduced density) Range 0–2	Air trapping on expiratory scans if regional reduced density Range 0–2	Emphysema 0–2 Range 0–2	Air trapping on expiratory image 0–4 Range 0–4	Air trapping on expiratory image Extent 0–3 × appearance 1–1.5 Range: 0–4.5
Bronchial wall thickening	0–3 Range 0–3		0–2 Range 0–2	0–3 Range 0–3	0–3 Range 0–3	0–3 Range 0–3	0–4 Range 0–4	(Extent central 0–3 + peripheral lung 0–3) × severity 1–1.5 Range 0–9
Bronchiectasis	Severity 0–3 Extent 0–3 Sacculations or abscesses 0–3 Generations bronchial divisions involved 0–3 × 0.5 Range 0–10.5	0–5 Range 0–5	Diameter 0–3 Axial extent 0–3 Range 0–6	Severity 0–3 Extent 0–3 Air-fluid levels 0–3 Range 0–9	Severity 0–3 Extent 0–3 Generations bronchial divisions involved 0–3 × 0.5 Range 0–7.5	Severity 0–3 Extent 0–3 Sacculations or abscesses 0–3 Generations bronchial divisions involved 0–3 × 0.5 Range 0–10.5	0–4 Range 0–4	(Extent central 0–3 + peripheral lung 0–3) × average bronchiectasis size 0–2 Range 0–12
Mucus plugging	0–1 Range 0–1		Recorded separately	Extent: 0–3 Centrilobular nodules, 0–6 Range 0–9	Extent: 0–3 Generations bronchial divisions involved 0–3 × 0.5 Range 0–4.5	Extent: 0–3 Generations bronchial divisions involved 0–3 × 0.5 Range 0–4.5	0–4 Range 0–4	Extent central lung 0–3 + peripheral lung 0–3 Range 0–6
Parenchyma	0–2 No. of bullae 0–3 Range 0–5		Alveolar consolidations 0–1 Atelectasis, bullae and cysts 0–1 Range 0–2	Atelectasis or consolidation 0–3 Range 0–3	0–2 No. of bullae 0–3 Acinar nodules/consolidations 0–2 Thickened intra or inter lobular septa 0–3 Ground glass opacities 0–3 Range 0–13 Maximum 30	0–2 No. of bullae 0–3 Acinar nodules/consolidations 0–2 Thickened intra or inter lobular septa 0–3 Ground glass opacities 0–3 Range 0–7	0–4 Range 0–4	Extent of dense opacity, ground glass opacity, and cysts or bullae. Each 0–3 Range 0–9
Total score	Maximum 25	Per zone max. 6 p (dement points) Score = 72-max. 72 = Minimum 0	% of regional involvement (thirds of lung on axial slices). Each region × 0–3 Maximum 132	Maximum 24	Maximum 30	Maximum 27	Per lobe max. 20 Maximum 120	Per lobe max. 40.5, but max. possible score is 207. Score then normalised 0–100 Maximum 100

Table 6 An overview of the scoring system for MRI presented by Eichinger et al. [9], adapted from the original publication

MRI scoring system	Eichinger [9] (2012)
Scoring area	6 lobes
Scoring components/ <i>scoring levels</i> , scoring range	
Bronchiectasis/ wall thickening	Each lobe 0–1–2, range 0–12
Mucus plugging	Each lobe 0–1–2, range 0–12
Abscesses/sacculations	Each lobe 0–1–2, range 0–12
Consolidation	Each lobe 0–1–2, range 0–12
Perfusion size	Each lobe 0–1–2, range 0–12
Total score	Maximum 72 (sum of subscores)

between bronchial wall thickening and bronchiectasis [9] (Table 1).

In most scoring systems, increased lung volume, bronchial wall thickening, bronchiectasis, mucus plugging and parenchymal changes are scored (Fig. 2). In some CT scoring systems, air trapping on expiratory images and mosaic perfusion are evaluated. Sacculations and abscesses are scored together in two CT scoring systems as well as on MRI, as the image resolution often does not often allow for differentiation between these entities (sacculations are dilated bronchi and abscesses are located in the lung parenchyma). In addition, some CT scoring systems score for cysts/bullae, ground glass opacities and thickened intra- or inter-lobular septa. In the MRI score, pleural affection is scored as a special finding and a functional scoring component has been introduced, as first-pass perfusion images are assessed, making it possible to evaluate perfusion defects (which is an unique scoring component for the MRI) scoring system), which according to preliminary results from on-going studies may allow differentiation between reversible and irreversible lung changes [7].

For all scoring systems, a defined total score which should represent the total structural lung damage has been reported in the articles, except for the scoring systems of Maffessanti [25] and Robinson [32]. It has been shown that inter-observer reproducibility is higher for the total score than for the component scores for most CT scoring systems [39] as well as for the tomosynthesis scoring system [5].

The range of the weightings, expressed as the component score in percentage of the total score, is wide (Table 7, Fig. 2), indicating disagreement between research groups on which abnormalities are the most indicative of changes in disease status. Bronchiectasis and mucus plugging are the most specific pulmonary abnormalities for cystic fibrosis [15, 40] and some authors have even suggested that selective scoring of mucus plugging and bronchiectasis might be as sensitive as more complicated CT scoring systems in observing the course of disease in patients with cystic fibrosis [23, 35, 40, 41]. It is

therefore logical to give them a high score compared with other findings, and most scoring systems give bronchiectasis alone, or in combination with mucus plugging, the highest weightings. Bronchiectasis is generally given higher weightings in CT and MRI scoring systems (when combined with scores for abscess and sacculations), as well as in the tomosynthesis scoring system, compared with radiographic scoring systems (Table 7, Fig. 2), probably due to the fact that bronchiectasis is more clearly visualised. The mean scores for mucus plugging (17%) are the same for radiography, CT and MRI scoring systems, even though CT and MRI depict these changes better than radiography, but is higher in the tomosynthesis scoring system (32%), where the sum of the scores for mucus plugging together with bronchiectasis contribute to 64% of the total score.

In the current review, the term “increased lung volume” has been used in place of the not exactly interchangeable terms “overinflation” and “air trapping”. Air trapping can only be evaluated on expiratory CT scans, and overinflation would in most cases be the more appropriate term, when expiratory images are not used. Bronchial wall thickening and increased lung volume are commonly seen in cystic fibrosis but are non-specific abnormalities that can often be seen in, for example, children with asthma and bronchiolitis, and in most scoring systems these components are consequently given quite low weightings in percentage of the total score (Table 7, Fig. 2). Consolidations and atelectasis of the parenchyma are also non-specific and are in most scoring systems given a weighting of about 20% of the total score. However, in the CT scoring systems of Santamaria [28], Robinson [32] and Brody [34] expiratory images are included, as air trapping in these scoring systems is thought to reflect small airway disease in early cystic fibrosis [40, 42].

In a comparison of six radiography scoring systems with correlation to clinical parameters by Terheggen-Lagro et al. [43], the authors concluded that all six scoring systems correlated well with lung function tests and infectious exacerbation rate, showed low inter-observer variation and that a simple scoring system like the Chrispin-Norman system was preferable. In a European consensus paper on standards of care for patients with cystic fibrosis in 2005 [44] the authors recommended the use of the Northern scoring system for radiography, since it only requires the frontal projection for scoring. Five CT scoring systems have been validated in a previous study [39] and, despite differences in scoring and weighting, the authors found no differences in the scoring systems’ ability to track disease progression in 48 children [40, 41]. In a study by Puderbach et al. [45], 31 patients with cystic fibrosis were examined with MRI, radiography and CT, and using a modified Chrispin-Norman score [13] for radiography and a modified Helbich score [30] for CT and MRI the authors found comparable results for all modalities.

Table 7 The weighting, i.e. the component score in percentage of the total score, given to the different scoring components in each radiological scoring system. The Northern [19] scoring system for radiography could not be compared with the above given systems due to large differences in the scoring procedures

	Radiography			Tomosynthesis			CT			MRI			
	Christin-Norman 1974 [13]	Brasfield 1979 [11]	Wisconsin 1993 [18]	Vult von Stevern 2012 [5]	Bhalla 1991 [22]	Nathanson 1991 [23]	Maffessanti 1996 [25]	Shah 1997 [27]	Santamaria 1998 [28]	Helbich 1999 [30]	Robinson 2001 [32]	Brody II 2004 [34]	Eichinger 2012 [9]
Scoring systems													
Reference number													
Scoring components/component score in percentage of total score													
Lung volume	16%	18%	12.5%	4%			9%	7%		7%			
Emphysema					8%								
Air trapping (expiratory images)													
Bronchial wall thickening	18%	12.5%	16%	12%		18%	12.5%	10%		11%	20%	11%	7%
Bronchiectasis	21%	9%	31%	32%	30%	83%	55%	25%	25%	17%	20%	30%	7%
Air-fluid levels							12.5%						
Sacculations or abscesses					12%					11%			17%
Bronchiectasis/wall thickening													(17%) ^a
Bronchiectasis/mucus plugging													
Mucus plugging	21%	9%	12.5%	32%	18%	17%		37.5% ^b	15%	17%	20%	15%	17%
Parenchyma	21%	23%	16%					12.5%	7%	7%	20%	7.5%	17%
Consolidation and atelectasis									7%				
Consolidation			12.5%						7%				
Atelectasis			19%		8%								
Cysts/Bullae					12%				10%	11%		7.5%	
Atelectasis, cysts and bullae													
Thickened intra-/inter-lobular septa							9%		10%				
Mosaic perfusion										7%			
Ground glass opacities									10%			7.5%	
General severity			23%										
Special findings (pleural affection)													17%
Perfusion defect size													17%
Maximum score	38	22	100	100	25	72	132	24	30	27	120	100	72

^a In the Brasfield score [11], bronchiectasis and mucus plugging are scored together as “nodular cystic lesions”, and in the MRI [9] score bronchiectasis and bronchial wall thickening are scored together. In this table these scores are divided between the two entities

^b In the Shah score [27], centrilobular nodules are scored separately; in this table this entity is included in the mucus plugging score

Radiography is an easily accessible modality, with low cost and radiation dose [46, 47], but the diagnostic detail is low (Table 1). Tomosynthesis is superior to radiography in the detection of cystic fibrosis changes [4, 5], and also has the advantages of low cost and radiation dose [6], but cannot be performed in young children without anaesthesia (since a breath-hold of 10 s is required). MRI is an interesting alternative in the follow-up and monitoring of cystic fibrosis, since it is performed without radiation and offers the possibility of scoring perfusion [7–9], but is expensive and also requires anaesthesia for young children. CT remains the “gold standard”, but has the disadvantage of a high radiation dose [46, 47]. Alternative CT imaging protocols are under development, with lower dose than conventional settings [48], but the reported effective dose still is higher than for radiography and tomosynthesis [6, 46, 47].

In conclusion, to try to objectify the progression of cystic fibrosis lung disease different imaging modalities can be used, with specific advantages and disadvantages. A multitude of scoring systems have been proposed for radiography and CT, and recently scoring systems for tomosynthesis and MRI also have been presented. There are large divergences in the radiological scoring systems. Most scoring systems, however, consider bronchiectasis alone, or in combination with mucus plugging, to be the most important component of the score. Bronchiectasis, with or without mucus plugging, is thus the most significant finding when evaluating pulmonary cystic fibrosis.

Conflicts of interest The authors declare no conflicts of interest.

No funding was received for this work.

Open Access This article is distributed under the terms of the Creative Commons Attribution License which permits any use, distribution, and reproduction in any medium, provided the original author(s) and the source are credited.

References

1. Aziz ZA, Davies JC, Alton EW, Geddes DM, Hansell DM (2007) Computed tomography and cystic fibrosis: promises and problems. *Thorax* 62:181–186
2. Cooper P, MacLean J (2006) High-resolution computed tomography (HRCT) should not be considered as a routine assessment method in cystic fibrosis lung disease. *Paediatr Respir Rev* 7:197–201
3. Tiddens H (2006) Chest computed tomography scans should be considered as a routine investigation in cystic fibrosis. *Paediatr Respir Rev* 7:202–208
4. Vult von Steyern K, Björkman-Burtscher I, Geijer M (2012) Tomosynthesis in pulmonary cystic fibrosis with comparison to radiography and computed tomography: a pictorial review. *Insights Imaging* 3:81–89
5. Vult von Steyern K, Björkman-Burtscher IM, Höglund P, Bozovic G, Wiklund M, Geijer M (2012) Description and validation of a scoring system for tomosynthesis in pulmonary cystic fibrosis. *Eur Radiol* 22: 2718–2728
6. Båth M, Svåkvist A, von Wrangel A, Rismyhr-Olsson H, Cederblad Å (2010) Effective dose to patients from chest examinations with tomosynthesis. *Radiat Prot Dosim* 139:153–158
7. Eichinger M, Puderbach M, Fink C et al (2006) Contrast-enhanced 3D MRI of lung perfusion in children with cystic fibrosis-initial results. *Eur Radiol* 16:2147–2152
8. Puderbach M, Eichinger M, Gahr J et al (2007) Proton MRI appearance of cystic fibrosis: comparison to CT. *Eur Radiol* 17:716–724
9. Eichinger M, Optazait D-E, Kopp-Schneider A et al (2012) Morphologic and functional scoring of cystic fibrosis lung disease using MRI. *Eur J Radiol* 81:1321–1329
10. Shwachman H, Kulczycki L (1958) Long-term study of one hundred five patients with cystic fibrosis: studies made over a five-to fourteen-year period. *AMA J Dis Child* 96:6–15
11. Brasfield D, Hicks G, Soong S, Tiller RE (1979) The chest roentgenogram in cystic fibrosis: a new scoring system. *Pediatrics* 63:24–29
12. Taussig L, Kattwinkel J, Friedewald W, Di Sant’Agnese PA (1973) A new prognostic score and clinical evaluation system for cystic fibrosis. *J Pediatr* 82:380–390
13. Chrispin A, Norman A (1974) The systematic evaluation of the chest radiograph in cystic fibrosis. *Pediatr Radiol* 2:101–105
14. Holzer F, Olinsky A, Phelan P (1981) Variability of airways hyper-reactivity and allergy in cystic fibrosis. *Arch Dis Child* 56:455–459
15. Van der Put J, Meradji M, Danoesastro D, Kerrebijn KF (1982) Chest radiographs in cystic fibrosis. A follow-up study with application of a quantitative system. *Pediatr Radiol* 12:57–61
16. Carty H (1987) The chest radiograph in cystic fibrosis in children and the role of other radiological techniques. *J R Soc Med* 80:38–46
17. O’Laoide R, Fahy J, Coffey M et al (1991) A chest radiograph scoring system in adult cystic fibrosis: Correlation with pulmonary function. *Clin Radiol* 43:308–310
18. Weatherly M, Palmer C, Peters M et al (1993) Wisconsin cystic fibrosis chest radiograph scoring system. *Pediatrics* 91:488–495
19. Conway S, Pond M, Bowler I et al (1994) The chest radiograph in cystic fibrosis: a new scoring system compared with the Chrispin-Norman and Brasfield scores. *Thorax* 49:860–862
20. Kosciak R, Kosorok M, Farrell P et al (2000) Wisconsin cystic fibrosis chest radiograph scoring system: validation and standardization for application to longitudinal studies. *Pediatr Pulmonol* 29:457–467
21. Benden C, Wallis C, Owens C, Ridout DA, Dinwiddie R (2005) The Chrispin-Norman score in cystic fibrosis: doing away with the lateral view. *Eur Respir J* 26:894–897
22. Bhalla M, Turcios N, Aponte V et al (1991) Cystic fibrosis: scoring system with thin-section CT. *Radiology* 179:783–788
23. Nathanson I, Conboy K, Murphy S, Afshani E, Kuhn JP (1991) Ultrafast computerized tomography of the chest in cystic fibrosis: a new scoring system. *Pediatr Pulmonol* 11:81–86
24. Stiglbauer R, Schurawitzki H, Eichler I, Vergesslich KA, Götz M (1992) High resolution CT in children with cystic fibrosis. *Acta Radiol* 33:548–553
25. Maffessanti M, Candusso M, Brizzi F, Piovesana F (1996) Cystic fibrosis in children: HRCT findings and distribution of disease. *J Thorac Imaging* 11:27–38
26. Donnelly L, Gelfand MJ, Brody AS, Wilmott RW (1997) Comparison between morphologic changes seen on high-resolution CT and regional pulmonary perfusion seen on SPECT in patients with cystic fibrosis. *Pediatr Radiol* 27:920–925
27. Shah R, Sexauer W, Ostrum B, Fiel SB, Friedman AC (1997) High-resolution CT in the acute exacerbation of cystic fibrosis: evaluation of acute findings, reversibility of those findings, and clinical correlation. *AJR Am J Roentgenol* 169:375–380
28. Santamaria F, Grillo G, Guidi G et al (1998) Cystic fibrosis: when should high-resolution computed tomography of the chest be obtained? *Pediatrics* 101:908–913
29. Brody A, Molina P, Klein J, Rothman BS, Ramagopal M, Swartz DR (1999) High-resolution computed tomography of the chest in

- children with cystic fibrosis: support for use as an outcome surrogate. *Pediatr Radiol* 29:731–735
30. Helbich T, Heinz-Peer G, Eichler I et al (1999) Cystic fibrosis: CT assessment of lung involvement in children and adults. *Radiology* 213:537–544
 31. Castile R, Hayes J, Flucke R, McCoy KS (2000) Correlation of structural and functional abnormalities in the lungs of infants with cystic fibrosis (Abstract). *Pediatr Pulmonol* 20:A427
 32. Robinson T, Leung A, Northway W et al (2001) Spirometer-triggered high-resolution computed tomography and pulmonary function measurements during an acute exacerbation in patients with cystic fibrosis. *J Pediatr* 138:553–559
 33. Oikonomou A, Manavis J, Karagianni P et al (2002) Loss of FEV1 in cystic fibrosis: correlation with HRCT features. *Eur Radiol* 12:2229–2235
 34. Brody A, Klein J, Molina P, Quan J, Bean JA, Wilmott RW (2004) High-resolution computed tomography in young patients with cystic fibrosis: distribution of abnormalities and correlation with pulmonary function tests. *J Pediatr* 145:32–38
 35. Oikonomou A, Tsanakas J, Hatzigorou E et al (2008) High resolution computed tomography of the chest in cystic fibrosis (CF): is simplification of scoring systems feasible? *Eur Radiol* 18:538–547
 36. Wong E, Regnis J, Shnier R, Bye PT, Stewart ME (1993) The relationship between tests of lung function and three chest radiological scoring systems in patients with cystic fibrosis. *Australas Radiol* 37:265–269
 37. Sawyer S, Carlin J, DeCampo M, Bowes G (1994) Critical evaluation of three chest radiograph scores in cystic fibrosis. *Thorax* 49:863–866
 38. Helbich T, Heinz-Peer G, Fleischmann D et al (1999) Evolution of CT findings in patients with cystic fibrosis. *AJR Am J Roentgenol* 173:81–88
 39. de Jong P, Ottink M, Robben S et al (2004) Pulmonary disease assessment in cystic fibrosis: comparison of CT scoring systems and value of bronchial and arterial dimension measurements. *Radiology* 231:434–439
 40. de Jong P, Tiddens H (2007) Cystic fibrosis specific computed tomography scoring. *Proc Am Thorac Soc* 4:338–342
 41. De Jong P, Nakano Y, Lequin M et al (2004) Progressive damage on high resolution computed tomography despite stable lung function in cystic fibrosis. *Eur Respir J* 23:93–97
 42. Bonnel AS, Song SM, Kesavaraju K et al (2004) Quantitative air-trapping analysis in children with mild cystic fibrosis lung disease. *Pediatr Pulmonol* 38:396–405
 43. Terheggen-Lagro S, Truijens N, van Poppel N, Gulmans V, van der Laag J, van der Ent C (2003) Correlation of six different cystic fibrosis chest radiograph scoring systems with clinical parameters. *Pediatr Pulmonol* 35:441–445
 44. Kerem E, Conway S, Elborn S, Heijerman H (2005) Standards of care for patients with cystic fibrosis: a European consensus. *J Cyst Fibros* 4:7–26
 45. Puderbach M, Eichinger M, Haeselbarth J et al (2007) Assessment of morphological MRI for pulmonary changes in cystic fibrosis (CF) patients: comparison to thin-section CT and chest X-ray. *Invest Radiol* 42:715–724
 46. Smith-Bindman R, Lipson J, Marcus R et al (2009) Radiation dose associated with common computed tomography examinations and the associated lifetime attributable risk of cancer. *Arch Intern Med* 169:2078–2086
 47. Mettler FA, Huda W, Yoshizumi TT, Mahesh M (2008) Effective doses in radiology and diagnostic nuclear medicine: a catalog. *Radiology* 24:254–263
 48. Loeve M, Lequin MH, de Bruijne M et al (2009) Cystic fibrosis: are volumetric ultra-low-dose expiratory CT scans sufficient for monitoring related lung disease? *Radiology* 253:223–229