LUND UNIVERSITY

New aspects of tissue mast cells in inflammatory airway diseases

Andersson, Cecilia

2011

Link to publication

Citation for published version (APA):
Andersson, C. (2011). *New aspects of tissue mast cells in inflammatory airway diseases*. [Doctoral Thesis (compilation), Airway Inflammation and Immunology]. Lund University.

Total number of authors:
1

General rights
Unless other specific re-use rights are stated the following general rights apply:
Copyright and moral rights for the publications made accessible in the public portal are retained by the authors and/or other copyright owners and it is a condition of accessing publications that users recognise and abide by the legal requirements associated with these rights.
• Users may download and print one copy of any publication from the public portal for the purpose of private study or research.
• You may not further distribute the material or use it for any profit-making activity or commercial gain
• You may freely distribute the URL identifying the publication in the public portal

Read more about Creative commons licenses: https://creativecommons.org/licenses/

Take down policy
If you believe that this document breaches copyright please contact us providing details, and we will remove access to the work immediately and investigate your claim.

LUND UNIVERSITY

PO Box 117
221 00 Lund
+46 46-222 00 00

LUND UNIVERSITY
Faculty of Medicine

ISBN 978-91-86671-60-0
ISSN 1652-8220
Lund University, Faculty of Medicine Doctoral Dissertation Series 2011:11

Cecilia Andersson

New Aspects of Tissue Mast Cells in Inflammatory Airway Diseases

2011:11

New Aspects of Tissue Mast Cells in Inflammatory Airway Diseases



Cecilia Andersson

Respiratory Medicine & Allergology
Department of Clinical Sciences
Lund University

New Aspects of Tissue Mast Cells in Inflammatory Airway Diseases

Cecilia Andersson

LUND UNIVERSITY
Faculty of Medicine

AKADEMISK AVHANDLING

som för avläggande av doktorsexamen i medicinsk vetenskap
vid Medicinska Fakulteten, Lunds universitet,
kommer att offentligen försvaras i Belfragesalen BMC D15, Lund,
fredagen den 11 februari 2011, kl. 9.00.

Fakultetsopponent:
Prof essor Sally Wenzel
University of Pittsburgh

Organization
LUND UNIVERSITY

Department of Clinical Sciences, Lund
Department of Experimental Medical Sciences

Document name
DOCTORAL DISSERTATION

Date of issue
2011-01-02

Sponsoring organization

Author(s) Cecilia Andersson

Title and subtitle New Aspects of Tissue Mast Cells in Inflammatory Airway Diseases

Abstract

Mast cell are found throughout the body, but are especially prominent in tissues that have direct contact with the external milieu such as the skin, gastrointestinal tract and lungs. Mast cells are commonly recognized for their detrimental role in allergic reactions and can, upon activation through the high-affinity receptor for IgE (FcεRI), rapidly produce and secrete many of the mediators responsible for the typical symptoms in urticaria, asthma and rhinitis. However, increasing amount of data show that mast cells have important, even vital, roles in host defence against bacteria, viruses, parasites and venoms. Mast cells exist as two different subtypes, MCT (mucosal mast cells) and MCTC (connective tissue mast cells). These two subtypes differ in their molecular expression and distribution in the body. MCT are for example the dominating subtype in the lungs, while MCTC are most common in the skin and the gastrointestinal tract. Since mast cells (unlike the majority of other immune cells) only mature inside the tissue, their final phenotype is highly dependent on the local tissue milieu. This gives rise to a pronounced heterogeneity within the populations. The mast cell populations differ between human and rodents. In this thesis mast cells were, henceforth, studied in human tissue from patients suffering from allergic and non-allergic inflammatory airway diseases. A variety of histological methods are used to study the balance between MCT and MCTC, mast cell morphology and mediator and receptor expression patterns in different lung compartments.

Under healthy baseline conditions, mast cells were abundant at all airway levels with a gradually increasing numbers towards the alveolar parenchyma. The MCT and MCTC populations could be further divided into site-specific subpopulations with regard to expression of mediators and morphology. A main finding was that the alveolar mast cell population had low expression of FcεRI in the healthy human lung. In COPD, CF and IPF, a significant increase in the proportion and density of MCTC with increased expression of CD88, IL-6 and TGF-β were found. Several mast cell alterations correlated to patient lung function and to the degree of remodelling compared to healthy controls. Mast cell numbers did not differ in healthy controls, patients with mild asthma or rhinitis with or without bronchial hyperreactivity. In patients with uncontrolled asthma despite treatment with inhaled corticosteroids, an increase of MCTC was found in the bronchi and alveolar parenchyma. In mild and uncontrolled asthma a significant increase of the expression of FcεRI was found in the alveolar parenchyma

In conclusion, the prevailing MCT and MCTC populations could be further divided into site-specific subpopulations dependent on the local microenvironment already at healthy conditions. Mast cell alterations are present in patients with COPD, CF and IPF, diseases characterised by increases in the density of MCTC with increased expression of pro-inflammatory and pro-fibrotic molecules. Uncontrolled atopic asthma patients have expanded MCT and MCTC populations in the alveolar parenchyma. The increase in alveolar mast cell expression of FcεRI might be specific to atopic asthma since we could detect similar changes in mild asthma, but not in patients with allergic rhinitis, CF and COPD.

Key words: Mast cell, heterogeneity, inflammation, lung, tissue, alveolar parenchyma, high-affinity receptor for IgE, asthma, rhinitis, chronic obstructive pulmonary disease, cystic fibrosis, idiopathic pulmonary fibrosis.

Classification system and/or index termes (if any):

Supplementary bibliographical information:

Language
English

ISSN and key title:
1652-8220

ISBN
978-91-86671-60-0

Recipient's notes

Number of pages
188

Price

Security classification

Distribution by (name and address)
I, the undersigned, being the copyright owner of the abstract of the above-mentioned dissertation, hereby grant to all reference sources permission to publish and disseminate the abstract of the above-mentioned dissertation.

Signature _____ Date 2011-01-02

New Aspects of Tissue Mast Cells in Inflammatory Airway Diseases

Doctoral Thesis

by

Cecilia Andersson

LUND UNIVERSITY
Faculty of Medicine

Department of Respiratory Medicine and Allergology
Unit of Airway Inflammation
Clinical Sciences, Lund
2011

Cover image: High magnification (600x) micrograph of lung tissue double stained for mast cell sub-populations: MC_T (red) and MC_{TC} (brown).

Lund University 2011
Faculty of Medicine, Department of Respiratory Medicine and Allergology,
Unit of Airway Inflammation
Copyright © Cecilia Andersson (Cecilia.Andersson@med.lu.se)
Printed by MediaTryck, Lund University, Sweden

ISBN 978-91-86671-60-0
ISSN 1652-8220
Lund University, Faculty of Medicine Doctoral Dissertation Series 2011:11

Till Mamma och Pappa
för er villkorslösa kärlek

Dum Spiro Spero

Så länge jag andas, hoppas jag
While I breathe, I hope

Cicero

Contents

List of Papers 11

Additional peer-reviewed papers, not included in the thesis 12

Abbreviations 13

Introduction 15
- Inflammatory Airway Diseases 15
- Monitoring Airway Inflammation 23
- The Mast Cell 25

Aims and Hypotheses 33

Methodology 35
- Subjects and Patient Characterisation 35
- Tissue Acquisition and Processing 37
- Histology and Immunohistochemistry 39
- Measurements 41

Results 45
- Novel Site-Specific Mast Cell Subpopulations in the Human Lung (Paper I) 45
- Marked Alterations of Lung Mast Cell Populations in Patients with COPD (Paper II) 46
- Activated Connective Tissue Mast Cells Infiltrate Diseased Lung Areas in Cystic Fibrosis and Idiopathic Pulmonary Fibrosis (Paper III) 49
- Mast cell-Associated Alveolar Inflammation in Patients with Atopic Uncontrolled Asthma (Paper IV) 50
- Alveolar Mast Cell Expression of FcεRI Differs between Allergic Asthma and Rhinitis (Paper V) 52

Discussion 55

Conclusions and Summary 61

Future Perspective 63

Populärvetenskaplig sammanfattning på svenska 65

Acknowledgements 67

References 69

List of Papers

This thesis is based on the following papers, which will be referred to in the text by their Roman numerals.

I. *Novel Site-Specific Mast Cell Subpopulations in the Human Lung.* Andersson CK, Mori M, Bjermer L, Löfdahl CG and Erjefält JS. **Thorax**, 2009 64:297-305.

II. *Patients with COPD have Altered Lung Mast Cell Populations.* Andersson CK, Mori M, Bjermer L, Löfdahl CG and Erjefält JS. **Am Respir J Crit Care Med**, 2010 181:206-17.

III. *Activated Connective Tissue Mast Cells Infiltrate Diseased Areas in Cystic Fibrosis and Idiopathic Pulmonary Fibrosis.* Andersson CK, Andersson-Sjöland A, Mori M, Hallgren O, Pardo A, Eriksson L, Bjermer L, Löfdahl CG, Selman M, Westergren-Thorsson G and Erjefält JS. **Thorax**, submitted 2010.

IV. *Mast Cell-Associated Alveolar Inflammation in Atopic Uncontrolled Asthma.* Andersson CK, Bergqvist A, Mori M, Mauad T, Bjermer L, and Erjefält JS. **J Allergy Clinical Immunol**. Accepted for publication 2011.

V. *Alveolar Mast Cell Expression of FcεRI Differs between Allergic Asthma and Rhinitis.* Andersson CK, Tufvesson E, Aronsson D, Mori M, Bergqvist A, Bjermer L, and Erjefält JS. **Allergy,** submitted 2011.

Papers are reproduced with permission from the publisher

Additional peer-reviewed papers, not included in the thesis

- *Mice lacking 12/15 Lipoxygenase have an Augmented Sensitization to Allergens but are Protected from Airway Allergic Inflammation and Remodeling.* Andersson CK, Rydell-Törmänen K, Claesson H-E, Svedmark S, and Erjefält JS. **Am J Respir Cell Mol Biol**. 2008, 39:648-56.

- *MEDI-563, a Humanized Anti-IL-5Rα Monoclonal Antibody With Enhanced Effector Function, Mediates Reversible Peripheral Blood Eosinophil Depletion in Patients With Mild Asthma.* Kolbeck R, Kozhich A, Koike A, Peng L, Busse W, Andersson CK, Damschroder M, Reed J, Woods R, Dall'Acqua W, Stephens G, Erjefalt JS, Humbles A, Kiener P, Spitalny G, Mackay C, Molfino N and Coyle AJ. **J Allergy Clin Immunol**. 2010, 125:1344-1353.

- *A Central Role for IL-9 in Mediating Mast Cell Progenitor Mobilization to the Lung and Chronic Remodeling of the Airways.* Kearley J, Erjefalt JS, Andersson CK, Burwell TJ, Jones T, BenjaminE, Brewah Y, Robinchaud A, Pegorier S, Kolbeck R, Kiener P, Gurish M, Lloyd C, Coyle A and Humbles AA. **Am J Respir Crit Care Med**. 2010 Oct 22. [Epub ahead of print]

Abbreviations

ACT	asthma control test
AP	alkaline phosphatase
AR	allergic rhinitis
CF	cystic fibrosis
COPD	chronic obstructive pulmonary disease
DAB	3,3' diaminobenzidine
FcεRI	high affinity receptor for IgE
FEV_1	forced expiratory volume in 1 second
FVC	forced vital capacity
GINA	global initiative for asthma
GOLD	global initiative for chronic obstructive lung disease
HRP	horseradish peroxidase
ICS	inhaled glucocorticosteroids
IOS	impulse oscillometry
IgE	immunoglobulin E
IPF	idiopathic pulmonary fibrosis
MC_T	tryptase positive mast cells (mucosal mast cells)
MC_{TC}	tryptase and chymase positive mast cells (connective tissue mast cells)
NO	nitric oxide
PD_{20}	cumulative dose of bronchoconstrictor where FEV_1 fell by 20% or more
PEF	peak expiratory flow
p.r.n	*pro re nata*, as needed
RV	residual volume
SCF	stem cell factor
TLR	toll-like receptor

Introduction

Inflammatory Airway Diseases

The respiratory tract has an estimated surface area of 70 m^2 that is in direct contact with the external milieu: from the mucosal tissue in the conducting airways to the alveoli in the peripheral lung parenchyma. The main function of the lung is to maintain gas exchange and thus host survival. This, however, leads to increased risk of exposing the host to various harmful agents. As defence, each lung compartment has its specific population of immune cells that participate in inflammatory responses. The distinct cell populations are a reflection of the diverse properties of local tissue and of different deposition of pathogens, toxins and allergens throughout the lung.

Airway inflammation is initiated by stimuli at the epithelial surface and cells already present in the tissue mediate the acute inflammation. The stimuli cause activation of resident leucocytes and structural cells to produce various cytokines, chemokines and growth factors that cause inflammatory symptoms. Vasodilation and increased blood flow causes redness (*rubor*) and increased heat (*calor*). Increased blood vessel permeability results in exudation of fluid and plasma proteins into the tissue, which causes oedema (*tumor*) and some of the released mediators increase the sensitivity to pain (*dolor*). Released mediators cause migration of leukocytes into the tissue and act in parallel with other factors, such as the complement system, fibrin cascades and immunoglobulins in the inflammatory response[1].

The cellular inflammatory responses involve increased endothelial expression of adhesion molecules and transmigration of cells (monocytes/macrophages, T-lymphocytes, neutrophils, eosinophils and B-lymphocytes) into the extravascular space[2]. In the tissue, immune cells secrete factors that stimulate extracellular matrix production[3]. Resolution of the chronic inflammatory response is an active process that involves elimination of harmful agents (phagocytosis), removal of leucocytes (necrosis, apoptosis and luminal entry), and termination of wound healing. A persistent chronic inflammation might lead to formation of fibrosis and to the development of autoimmune diseases[1]. Lung diseases characterised by chronic inflammation affect a substantial part of the human population. Some of the most common are asthma, chronic obstructive pulmonary diseases (COPD) and cystic fibrosis (CF).

Allergic Airway Diseases

Asthma

Approximately 300 million people are currently suffering from asthma, and asthma causes almost 300 000 deaths globally each year[4]. Asthma is the most common chronic disease among children, and one of the strongest determinants is parental history of asthma and atopy[3]. Airflow obstruction, inflammation and bronchial hyperresponsiveness induced by a variety of exogenous and endogenous stimuli are hallmarks of the disease, although asthma is considered to be a heterogeneous disease. International committees have been formed with the goal to produce recommendations for the management, diagnosis and awareness of asthma (Global Initiative for Asthma – GINA). Today, asthma is divided into different categories based on phenotypic characteristics[5]:

- *Clinical and physiological phenotypes:* severity, exacerbation frequency, resistance to treatment, age onset e.g.
- *Phenotype related to triggers:* drugs, environmental allergens, occupational allergens, exercise e.g.
- *Inflammatory phenotypes:* eosinophilic, neutrophilic or pauci-granulocytic

Asthma is traditionally considered to be a large airway disease (Figure 1), characterised by an increase in density of inflammatory cells (eosinophils, CD4+ T-lymphocytes, macrophages and mast cells) in the submucosa and adventitia of the bronchial wall, which produce Th2 cytokines (IL-3, IL-4, IL-5, IL-9, IL-13 and GM-CSF)[6 7]. In more severe forms of asthma, CD8+ T-lymphocytes and neutrophils infiltrate the tissue[8]. Damage to the airway epithelium in the asthmatic lung results in thickening of the true basement membrane. This is due to proliferation of myofibroblasts that produce collagens, laminin and tenascin. The epithelium undergoes damage-repair processes with metaplasia and increased number of goblet cells as a consequence. Increase in deposition of extra cellular matrix and hyperplasia of vessels, neurons and smooth muscle are typical pathological features of asthma[6 9 10].

Not only the central airways, but also small airways are involved in the inflammatory response in the asthmatic lung. Inflammation in the small airways has, however, remained largely unexamined because of the relative inaccessibility of these structures[11]. Most of the information of tissue inflammation in small airways comes from autopsy studies of fatal asthma. Due to the possibility of obtaining transbronchial biopsies under more controlled conditions, it has been shown that the inflammation evident in the large airways, occurs in the distal airways as well[11]. In large and small airways, the number of lymphocytes and eosinophils were found to be increased in asthmatics compared to healthy controls[12]. Structural changes and remodelling, similar to that seen in large airways seem to be present also in the small airways[13]. Furthermore, Balzar *et al.*[14], showed that inflammatory cell density even seems to be increased towards the periphery of the airway.

Inflammation in the alveolar parenchyma has been shown in different asthma phenotypes[14-16]. Kraft *et al.*[16], found an increase in alveolar parenchymal eosinophil numbers in patients with nocturnal asthma compared to patients with non-nocturnal asthma, and this increase correlated to the night time fall in FEV_1. However, much is still unknown regarding the involvement of peripheral lung inflammation in asthma.

Treatment of asthma patients with inhaled β2 agonists (short- and long-acting), that cause smooth muscle relaxation is common. By the introduction of inhaled glucocorticosteroids (ICS), due to their broad anti-inflammatory effect, an improvement for many, but not all, asthma and rhinitis patients are achieved[7 17]. Anti-IgE therapy has been shown to down-regulate both IgE and FcεRI-bearing cells in asthmatic bronchi[18 19].

Rhinitis

The term rhinitis refers to an inflammatory disease of the nasal mucosa. Rhinitis is classified as seasonal allergic rhinitis (AR, hay fever), perennial AR and perennial non-allergic rhinitis (vasomotor rhinitis). In the studies included in the present thesis the rhinitis patients are characterised as seasonal AR and perennial AR. In hay fever and perennial AR the inflammation is induced by allergen stimulated, IgE-mediated, mast cell release of mediators like histamine, leukotrienes, prostaglandins and kinines. Increased numbers of eosinophils are seen in the mucosa of patients with hay fever and perennial AR. In clinical practice, diagnosis is based on the presence of secretion, itching, sneezing and blockage. Sneezing is considered to be induced by mediator stimulation of sensory nerve endings in the mucosa and hyper-secretion from nasal glands has been proposed to be mediated via a parasympathic reflex. The nasal blockage seems to be mediated via an effect of mediators on blood vessels causing both edema and increased blood accumulation in the mucosa[20-22].

Most atopic asthmatics have concurrent AR whereas clinical manifestation of asthma in rhinitis patients is more rare[23]. Reports show that AR patients often present symptoms such as unspecific bronchial hyper responsiveness (BHR), shortness of breath, wheezing and cough, all typical symptoms in asthma[24]. The similarities in induction and development of inflammation in the nasal and bronchial mucosa have lead to on going discussions suggesting that allergic asthma and AR appear to be organ specific variants of the same disease with a gradual development of respiratory allergy from the upper airways (rhinitis) towards involvement of the lower airways (asthma)[25]. In allergen-induced inflammation in AR and asthma the same inflammatory cells (eosinophils, CD4+ T-lymphocytes and mast cells) and mechanisms appears to be present[26-29]. Much is, however, unknown regarding the relevance of distal lung inflammation and its possible involvement in the transition of rhinitis into asthma.

As histamine and leukotrienes have been shown to play important roles in the pathology of allergic rhinitis, treatment with anti-histamines (H_1-blockers) and leukotriene-antagonists is commonly used. Sodium cromoglycate, described as a "mast cell stabilizer", and treatment with intranasal glucocorticosteroids has been proven useful[7 17].

Chronic Obstructive Pulmonary Disease (COPD)

According to WHO, 80 million people are suffering of moderate to severe COPD, and more than 3 million people died as a consequence of COPD in 2005. This corresponds to 5 % of all deaths globally, and estimates show that by 2020, COPD will be the third leading cause of death worldwide. The major risk factor for developing COPD is cigarette smoking, although only approximately 15% of all smokers develop the disease[30]. COPD is characterised by an irreversible and progressive airflow limitation combined with non-pulmonary conditions (lung cancer, skeletal muscle dysfunction, osteoporosis and cardiac/vascular disease) that contribute to the mortality of the disease. The *Global initiative for chronic Obstructive Lung Disease* (GOLD) was formed to improve prevention and management of COPD, as well as to increase the awareness of the disease. The diagnosis of COPD is confirmed by spirometry, and the presence of a postbronchodilator $FEV_1 < 80\%$ of the predicted value in combination with a $FEV_1/FVC < 70\%$ confirms airflow limitations that is not fully reversible. A classification of COPD severity into 4 stages is commonly applied (GOLD I-IV). COPD, in contrast to asthma, is considered to be a peripheral airway disease, although the chronic inflammation is present in the whole lung, from the bronchi (central airways) and bronchioles (small airways) to the alveolar parenchyma (Figure 2C, D)[31 32]. Additionally, the pulmonary circulation gets affected as the disease progresses in severity[31 33]. The increased airway resistance observed in COPD is ascribed to two major pathological features: small airway abnormalities and parenchymal destructions (emphysema)[31].

The main histopathological changes found in small airways are: increased number of goblet cells in the airway epithelium, increased occurrence of mucus plugging in the airway lumen, increased number of lymphoid follicles and enlarged smooth muscle mass and fibrosis formation in and around the small airway wall[7 34]. The inflammatory infiltrate in the small airway wall is characterised by elevated number of T-lymphocytes (in particular CD8+ cells, in contrast to CD4+ cells in asthma), neutrophils, macrophages and B-lymphocytes[32 34 35]. The other hallmark of COPD, emphysema, is defined as a permanent destruction of the alveolar septa that causes enlargement of airspaces and entailed imbalance in the gas-exchange (Figure 1)[7 36]. These lesions lead to decreased elastic recoil of the lung and, to some extent, collapse of the small airways and terminal bronchioles[37]. Scattered areas of fibrosis can also occur in the COPD affected alveolar parenchyma.

The inflammatory response in COPD is caused by inhalation of cigarette smoke (or other noxious particles) that activates the airway epithelium and alveolar macrophages to secrete cytokines like IL-8, LTB_4 and TNF-α. Many of these mediators are important in the innate immunity and cause neutrophil recruitment. Exposure to tobacco increases the oxidative metabolism in macrophages and can direct destroy epithelial integrity[38 39 40].

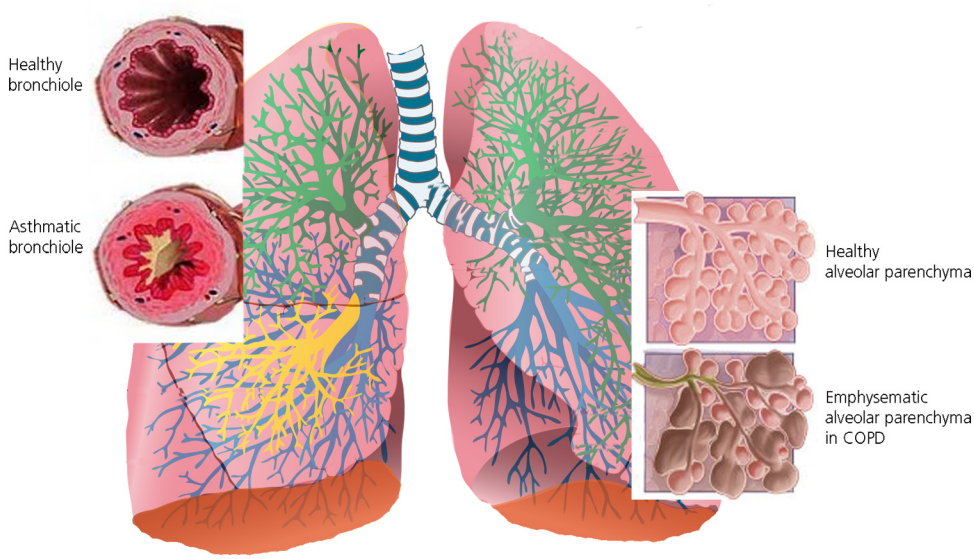

Figure 1. Key features of asthma and COPD pathology. Adapted from A.D.A.M.

There are two major mechanisms proposed for the cause of tissue damage in COPD: protease-antiprotease imbalance and oxidant-antioxidant imbalance. Recruited neutrophils release proteolytic enzymes like elastase, cathepsin G and matrix metalloproteases (MMPs). The oxidative effect of cigarette smoke impairs the body's normal anti-protease activity (e.g. α_1-antitrypsin), which usually should neutralise the released proteases. The activity of the proteases causes destruction of the alveolar walls and release of IL-8 and TGF-β from airway proteoglycans, further enhancing neutrophil recruitment and collagen deposition[7].

Today, no effective treatment of COPD exists. The most effective way of preventing the progression of the disease is to stop smoking. The current therapy used, is mainly long acting β2 agonists and anti-cholinergic drugs (decreased air trapping). ICS (suppression of the inflammatory response) is a common therapy, although COPD is considered to be steroid-resistant[7 17]. The main focus for future therapy should be to target peripheral inflammation, which is poorly assessed by today's therapy.

Cystic Fibrosis

Cystic fibrosis (CF) is one of the most common hereditary (autosomal recessive) diseases in Europe and the United States and affects approximately 1 in 3000 births. In 1959 the mean age of survival of a child born with CF was 6 months, today the mean life expectancy has increased to 38 years. CF is caused by a mutation, the most common is a deletion (ΔF 508) in the gene for the protein CFTR (Cystic Fibrosis Transmembrane conductance Regulator) located in a chloride channel expressed by e.g. epithelial cells. The mutation causes dehydrated and hyperviscous secretion that leads

to mucus plugging, impaired mucociliary clearance and airway obstruction. The consequence is airway infections by pathogens such as *Staphylococcus aureus*, *Haemophilus influenzae* and *Pseudomonas aeruginosa*, which induce chronic inflammation and in the end, respiratory failure[41 42 43 44].

The damaged airway epithelium in CF secretes IL-8, which attracts neutrophils into the lung. Once there, neutrophils trigger the release of proinflammatory mediators and chemoattractants, which maintain the inflammatory response. Mediators such as IL-6, TNF-α, and LTB_4, are found to be elevated in CF and cause recruitment of other inflammatory cells, such as macrophages. Cytokines from macrophages in turn mediates further neutrophil attraction. Upon activation, neutrophils release proteases (e.g. MMP9 and elastase) important in the defence against pathogens. However, the release of large amounts of these mediators during neutrophil activation, phagocytosis and apoptosis cause airway destruction, bronchiectasis and formation of fibrotic lesions (Figure 2E, F). The CF airway is exposed to oxygen radicals derived not only from environmental oxygen and bacterial products, but also from the strong host response. Furthermore, toll like receptors (TLRs), which recognise pathogen and inflammatory products, mediate the inflammation[45-48].

Given that chronic bacterial infections lead to chronic inflammation, CF patients are commonly treated with antibiotics. Inhaled and oral glucocorticosteroids and anti-inflammatory drugs are given with the aim to suppress the inflammatory response, although only modest effects are observed[45 49]. Chest physiotherapy is commonly used to improve airway clearance. Today, there is no effective treatment of the disease and in severe cases the patient is in need of lung transplantation.

Idiopathic Pulmonary Fibrosis

Generally, acute injury to the lung is followed by an inflammatory response with infiltration of inflammatory cells and release of mediators that eliminate the harmful agents. Normally the inflammation is resolved and the damaged tissue repaired by processes like apoptosis and phagocytosis of immune cells, healing and regeneration of the tissue through actions of structural cells. Fibrosis results from chronic inflammation, in which persistent stimuli such as infectious agents, chemicals, toxins or radiation, cause inflammation, tissue remodelling and repair processes to occur simultaneously. In this uncontrolled wound healing response, in which important checkpoints for regulation of the response is lost, a milieu rich in various cytokines, chemokines, growth factors and tissue destructive enzymes causes accumulation of extra cellular matrix proteins and formation of fibrotic lesions[1].

Idiopathic pulmonary fibrosis (IPF) is a progressive interstitial lung disease with unknown cause. IPF affects approximately 5 million people worldwide and is more common in men than women (ratio 1.4:1.0). The majority of patients are over 50 years old and the mean age of survival after diagnosis is 4 years. Diagnosis is set with regard to high-resolution computed tomography (HRCT; peripheral opacity, honeycombing and bronchiectasis), lung function values (decreased FVC and FEV_1) and impaired gas ex-

change and oxygenation during exercise[50-52]. Due to the unspecific pattern of leucocytes in BAL fluids, surgical lung biopsies are important for diagnosis of IPF. The histopathological abnormality associated with IPF is called *usual interstitial pneumonia* (UIP) and is characterised by normal lung structures alternating with patchy areas of parenchymal fibrosis. The fibrotic lesions are defined by thickening of the alveolar septa in mildly affected areas to complete distortion of the parenchyma with connective tissue replacing normal lung tissue and occurrence of cystic structures (honeycombing) (Figure 2G, H). Another hallmark of the disease is manifestation of structures called fibroblast foci: loose extracellular matrix, scattered with fibroblast-like cells[51 53 54]. Traditionally, IPF was thought to be caused by a primary injury that initiates an inflammatory response, resulting in formation of fibrosis[55]. However, animal models have shown that pulmonary fibrosis can arise without inflammatory cells. Furthermore, anti-inflammatory and inflammatory-suppressive drugs do not seem to be effective in the treatment of the disease[55]. New data have shown that a rapid (or even absent) inflammatory phase might precede the uncontrolled wound-healing response. Recent research has shown that damage epithelium might be an important source of fibrinogenic cytokines, such as TGF-β, that increase fibroblast proliferation and migration and production of connective tissue proteins[56]. These fibroblasts seem to be abnormally responsive to TGF-β and more resistant to apoptosis. For unknown reasons, the repair process never terminates and formation of fibrosis continues[57 58].

Airway Infections

Pathogens are aggravating factors in the development of the obstructive airway diseases described above. Knowledge of how the host's immune response to pathogens affects the susceptibility to develop chronic inflammatory airway diseases remains poorly understood. Longitudinal studies have shown that having a respiratory syncytial virus (RSV) infection as a child increases the risk of developing asthma later in life. Acute exacerbations are related to great health care costs, health status, quality of life and morbidity and are a feature of both asthma and COPD. In the majority of cases the exacerbations are caused by airway infections. Acute exacerbations are characterised by a decrease of the patient lung function compared to baseline values, shortness of breath and/or wheezing, cough and increased production of purulent sputum. Viral infections are thought to increase production of chemokines and cytokines from the airway epithelium, initiating host defence and inflammatory responses[59 60].

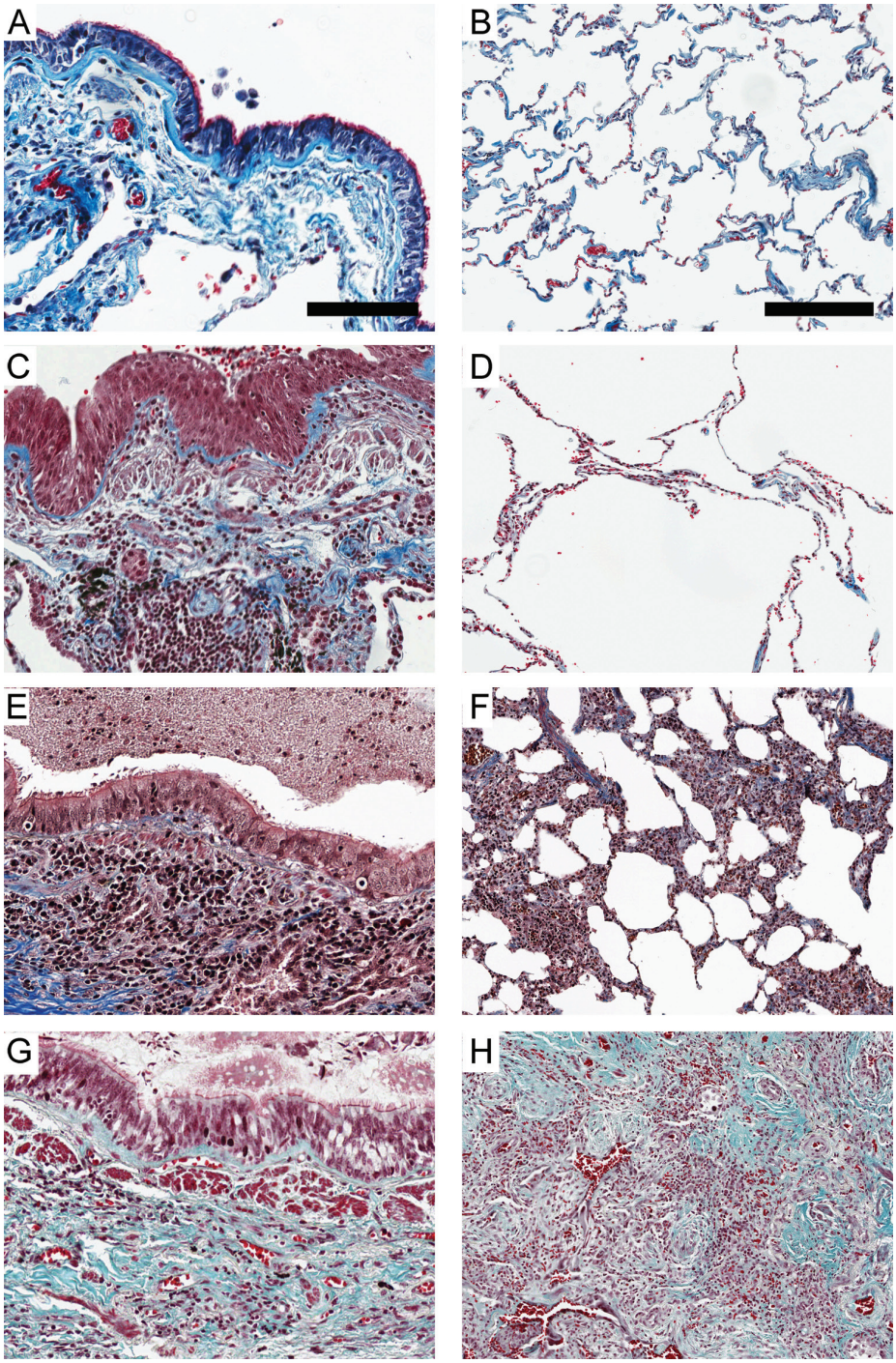

Figure 2. Trichrome stained sections of small airways (A, C, E, G; scale bar = 100µm) and alveolar parenchyma (B, D, F, H: scale bar = 200µm) from healthy controls (A, B), patients with COPD (C, D), CF (E, F) and IPF (G, H). Pictures A-F are stained with Masson's trichrome and G-H with Gomori's trichrome.

Monitoring Airway Inflammation

Pathological alterations are present throughout the human lung and several techniques for assessment of cellular, biochemical and molecular markers of inflammation are available. The technique used, should be selected depending on the aim of the study and evaluated for patient safety, reproducibility and repeatability.

Spirometry

The most widely used approach to study obstructive pulmonary diseases is through pulmonary function tests. Measurements of forced expiratory volume in 1 second (FEV_1), peak expiratory flow (PEF), forced vital capacity (FVC) and residual volume (RV) can show signs of air trapping and obstruction in both large and small airways. Difficulties with the mentioned lung function tests include weak correlations to the inflammatory status of the airways and poor representation of alterations in peripheral lung[61].

Impulse Oscillometry

In impulse oscillometry (IOS), pressure impulses are superimposed on the tidal breathing of the patient at different frequency and measure tissue resistance and reactance. Although not widely used, IOS is particularly useful since the resistance of peripheral airways can be calculated[61 62].

Exhaled Nitric Oxide

Exhaled nitric oxide (NO) is one of the most established biomarkers of airway inflammation and has for example been shown to correlate with eosinophilic activity in allergic patients[63]. NO is thought to mainly be produced by epithelial cells in the central airways and by alveolar macrophages in the parenchyma. By measurements of exhaled NO concentrations at different flows, inflammation in central and distal airways can be assessed[64].

Sputum

Spontaneous or induced (by hypertonic saline) sputum samples are commonly collected and used for measurements of airway inflammation. Samples can be used for cell counts, immunohistochemical staining as well as for measurements of mediators. Analysis of sputum samples have been proven useful in both asthma and COPD since it can predict patient's response to ICS, as high numbers of eosinophils in sputum are associated to a presumptive favourable response. Elevated eosinophil numbers are found in asthma and COPD patients prior to exacerbations, and early intervention

with therapy has decreased the number of exacerbations and hospitalizations in these groups of patients. Due to the safety of the procedure, induced sputum can be used in patients with severe lung disease[65]. However, one disadvantage with the procedure is that sputum mainly reflects the inflammation in large airways. Samples also primarily reflect changes in cell populations that are prone to go into the airway lumen, which result in an underrepresentation of tissue-dwelling cells.

Bronchoalveolar Lavage

Bronchoalveolar lavage (BAL) is an invasive technique where sterile saline is injected and flushed throughout the lung and fluid is sampled in aliquots, reflecting different parts of the lung. Lung compartments that are difficult to reach (small airways and alveolar parenchyma) are assessed with this technique and cell counts and mediators can be measured, mostly reflecting features of the airway epithelium[66]. As for sputum, tissue-dwelling cells are difficult to study by the use of this technique.

Direct Analysis of Diseased Tissue

Since not all cells are equally represented in luminal sampling, direct analysis of tissue is important when studying inflammatory airway disease. The first bronchoscopy was performed in 1897, and was then used to remove foreign bodies from the airways. Rigid bronchoscopy later became an important method for visual inspection of the airways. The first flexible bronchoscope was invented in 1966 and improved the procedure with regard to accessibility of more distal bronchi and patient comfort[67 68]. However, until 30 years ago histological assessment of living patients under controlled circumstances was rare. Histological studies on asthma used autopsy tissue material from fatal cases but little was known regarding the inflammatory response in the airway wall in patients with milder disease[69]. The development of techniques to obtain lung biopsies have made a great progress in this field. Tissue acquisition in connection with lung resections, lobectomies and transplantations are common ways of studying tissue inflammation in for example patients with COPD, CF and lung fibrosis. These techniques are also commonly used for obtaining control tissue[70 71]. An advantage with the techniques is the possibility to get large tissue blocks from several regions of the lung (also from the peripheral part of the lung). One drawback is however, that the patients commonly have other diagnoses that are the primary cause of surgery, such as lung cancer. The possibility of obtaining transbronchial biopsies has improved studies on inflammatory and structural changes in the distal airways[69]. However, biopsy procedures are invasive methods and can be associated with bleeding, increased risk of infections and pneumothorax. Sample size of biopsies is small and to avoid bias sampling due to the heterogeneity of the disease, several biopsies (from different lung regions) from numerous patients are needed. Tissue analyses have many advantages. Direct *in vivo* studies of structural changes and cell densities in the airway wall using immunohistochemical

methods, electron microscopy and *in situ* hybridisation are achievable. Furthermore, after processing of the tissue, cell cultures with measurements of cell activation, migration and mediator release can be performed.

The Mast Cell

The German scientist Paul Erlich discovered the mast cell in 1878, and until recent times, mast cell activation has been mainly associated with harmful effects in allergic responses[72]. Mast cells originate in the bone marrow as haematopoietic stem cells, but circulate in the blood as immature precursors. Mast cells mature first when recruited into the tissue and are therefore particularly dependent on the local tissue milieu for the development of their final phenotype[73 74]. They are located in normal tissue throughout the body, but are especially prominent in tissue that face the external environment, e.g. skin, lung and gastro-intestinal tract[75-77]. Consequently, mast cells are among the first cells that can react on various harmful agents and initiate an immune response, and are believed to have significant roles in host defence against pathogens, regulation of homeostasis and wound healing[78]. As an example of the essential role of the mast cell, the urochordate *Ciona intestinalis*, which is regarded as an ancestor of vertebrates 550 million years ago, have a cell population that stain metachromatically with toluidine blue and by the use of electron microscopy analysis have been shown to resemble connective tissue mast cells. These cells can also release histamine and prostaglandins upon activation. Thus, mast cells evolved and participated in host defence long before the development of other cells in the adaptive immune system[79]. Humans deficient in mast cells are not known, which is another indication of a fundamental role. However, excessive numbers of mast cells and concomitant release of mediators give rise to harmful reactions, exemplified by mastocytosis[80]. Mast cells are long-lived cells, which can survive for month or even years. Furthermore, the persistent and rapid response to harmful stimuli is unique for the cell. They react within seconds with release of active mediators, and unlike other cells participating in the early innate immunity, such as neutrophils, mast cells are not destroyed in the process and within days new granules have been formed[81].

Mast Cell Heterogeneity

In humans, mast cells are found throughout the entire respiratory system, from upper airways, to the bronchi, bronchioles and alveolar parenchyma in the lower airways[76]. Large differences in mast cell distribution are found between rodents and humans[72]. Rodents have mast cells in the bronchial airway wall, but unlike humans, lack mast cells in the small airways and alveolar parenchyma. Indeed, in humans, mast cell density increases from the central airways to the peripheral lung[32 76]. Since mast cells mature in the tissue, the local milieu is important in the development of their final pheno-

type. While mast cells share many characteristics, they do not represent a homogenous population. Based on anatomic location in rodents, mast cells were already in 1960's divided into two subtypes: connective tissue mast cells (CTMC) and mucosal mast cells (MMC)[72]. The CTMC and MMC differ not only in their tissue distribution, but also in morphology, granule content and function[82]. The knowledge of human mast cell heterogeneity is more limited, although like in rodents, human mast cells display subpopulations that differ in protease content, distribution, mediator expression and granule ultrastructure[72 77 83-86].

One distinct mast cell population in humans shows measurable levels of the proteases tryptase, chymase, cathepsin G and carboxypeptidase and are called MC_{TC} since they express both tryptase and chymase (Figure 3A). These cells largely correspond to the CTMC population in rodents. The other mast cell subpopulation contains only tryptase and is known as MC_T (Figure 3A), and corresponds to the MMC in rodents[72]. A few studies have reported a mast cell subpopulation only positive for chymase, though these cells seem extremely rare and only comprise 1 % of all mast cells in the lung[77]. To properly study mast cells, it is not only important to consider the density of total mast cells, but also the density of the two major subtypes. This can be achieved by immunohistochemical double staining for tryptase and chymase[86] (Figure 3A). The two subtypes can also be separated using transmission electron microscopy, since only MC_T cells display a scroll-like granule ultrastructure, and lattice or grating structures are found in MC_{TC} cells[87 88] (Figure 3B). Little is known regarding the plasticity of the subtypes, although reports have suggested that one subtype can change into the other[89]. In the healthy human lung, the dominating subtype is the MC_T, comprising approximately 90 % of all mast cells[72]. In humans the proportion of the two subtypes has been shown to change in pathological conditions[14], a phenomenon that is likely to have functional consequences in the immune system.

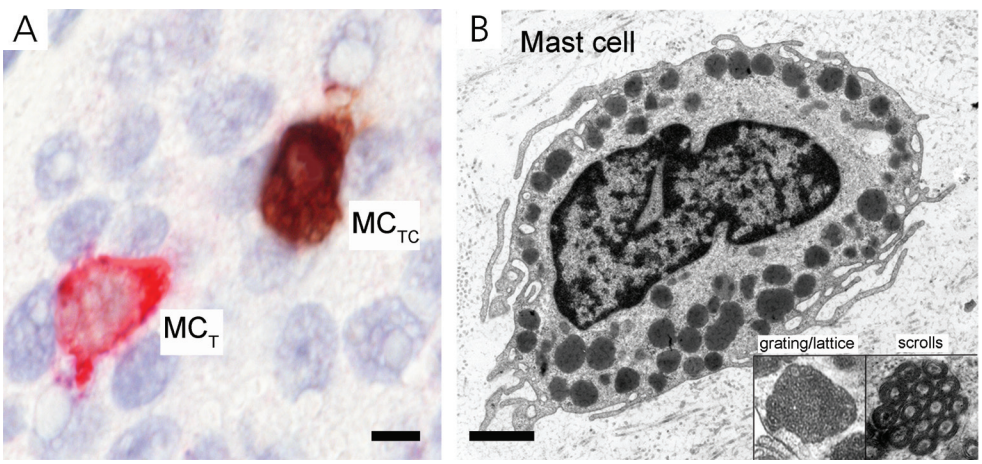

Figure 3. High-magnification micrograph (600x) of immunohistochemical double staining of MC_T (red) and MC_{TC} (brown) (A). Transmission electron micrograph showing a non-degranulated mast cell (B). High-power images of intact granules (lattice/grating and scrolls) are shown as insets. Scale bars = 5µm (A) and 1µm (B).

Not only the density of mast cells have been shown to change in disease, but also the distribution (microlocalisation) of mast cells within the airway wall[90]. An increased number of mast cells have been shown in the airway epithelium in asthmatics which is likely to be important for the epithelial function[91]. Increased numbers of total and degranulated mast cells have been reported in the airway mucosal glands in patients with fatal and non-fatal asthma compared to non-asthmatic subjects. These densities correlated significantly to the degree of mucus obstruction in the airway[76]. In the smooth muscle bundles of asthmatics, elevated numbers of mast cells of the MC_{TC} subtype were reported[92]. This correlated positively to the airway hyperreactivity. Other studies have shown that smooth muscle associated mast cells have increased expression of Th2 cytokines (IL-4 and IL-13)[93] and show increased degranulation in both large and small airways[76]. Bradding *et al.*[84], reported mast cell heterogeneity, not only in protease composition, but also with respect to cytokine expression where IL-4 was expressed preferentially by the MC_{TC}, and IL-5 and IL-6 by the MC_T subtype. When considering these findings, mast cell heterogeneity is likely to go beyond the division into MC_T and MC_{TC} subsets, and to be of importance when considering the role of mast cells in health and disease.

Origin and Maturation of Mast Cells

Mast cells develop from the bone marrow as $CD34^+$, c-kit^+ (CD117: receptor for stem cell factor) stem cells, although very little is known regarding mast cell progenitors in humans. Mast cells do not complete their maturation in the bone marrow but mature in the tissue, influenced by the local tissue milieu. Therefore, unlike other immune cells, mature mast cells are not found in the circulation. Studies of murine mast cell progenitors in the blood have shown that the progenitors express c-kit and contain few cytoplasmic granules but lack the FcεRI. Mast cells, unlike other haematopoietic stem cells, continue to express c-kit also when they are mature cells. An explanation for this is the great plasticity of these cells, i.e. the ability to change phenotype depending on the local environment. The most important growth factor for mast cell development is stem cell factor (SCF) that bind c-kit on the mast cell surface. SCF promotes mast cell development and survival as well as adhesion to the extra cellular matrix[73 74 94] and has been shown to enhance IgE-dependent mediator release[95]. Cytokines, like IL-4 in humans, regulate the development of mast cell subtypes[96 97]. IL-4 can work synergistically together with SCF to promote mast cell survival and proliferation, as well as direct mast cell cytokine release towards a Th2 response. Another cytokine that regulate mast cell function is IL-9, which is also named mast cell growth factor[98]. Mast cell progenitors have recently been identified to express integrins, such as β_7, and mast cell homing into the lung require expression of both $\alpha_4\beta_7$ and $\alpha_4\beta_1$ binding to VCAM-1 and MAdCAM-1 in the endothelium as well as expression of the α chemokine receptor 2[74 99].

Mast Cell Activation

FcεRI

The hallmark of an immediate hypersensitivity reaction is crosslinking of a multivalent allergen to IgE bound to the IgE receptor (FcεRI) on the mast cell surface (Figure 4). This causes activation of the mast cell through a signal transduction pathway that terminates in fusion and exocytosis of granules with preformed mediators (e.g. proteases, TNF-α, histamine), and *de novo* production of lipid mediators (eicosanoids, prostaglandins, leukotrienes) and various cytokines. Consequently, the result of IgE-mediated mast cell activation includes bronchoconstriction, plasma extravasation leading to tissue oedema, recruitment of leucocytes and persistent inflammation. These actions contribute to the pathogenesis of anaphylaxis, urticaria, angioedema and exacerbations of asthma[94 100 101].

The FcεRI is highly expressed on the surface of mast cells (about 500,000 copies per cell), and the regulation of expression is dependent on the concentration of circulating IgE. IgE binds to the FcεRI with high affinity (dissociation constant 10^{-10} M) and the binding is highly specific (isotype specific and not inhibited by excess of other immunoglobulins)[102 103]. *In vitro* studies have shown that IgE have the ability to prevent mast cell apoptosis, and can induce mast cell release of cytokines without degranulation[104].

Besides the role in allergic reactions, other biological roles of FcεRI activation of mast cells are under investigation. IgE-deficient mice are shown to have delayed elimination of intestinal parasites as well as increased numbers of larvae in the skeletal muscles compared to wild type controls[105]. Parasite infection is characterised by high numbers of CD4+ T-lymphocytes and Th2 cytokines (IL-4, IL-5, IL-9 and IL-13) and high concentrations of IgE in serum. Most of the IgE produced upon parasite infections is polyclonal and thereby not specific and, anaphylaxis seldom occurs in infected patients[106].

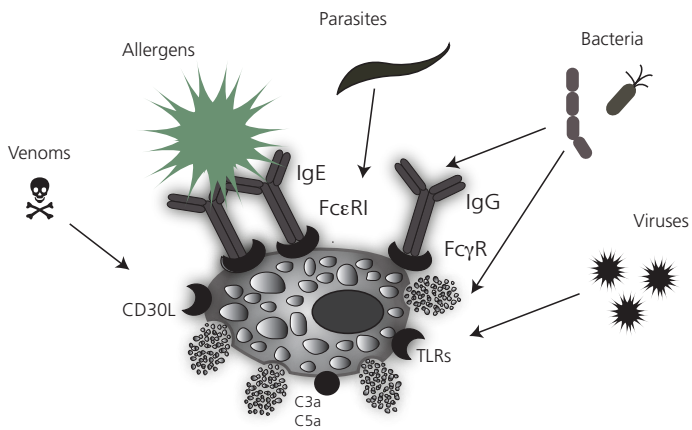

Figure 4. Schematic illustration of different stimuli that cause mast cell activation, with degranulation or degranulation-independent release of mediators as a consequence.

FcεRI independent activation

Mast cells can be activated by other immunoglobulins such as IgG through binding to FcγRs (Figure 4). This is likely to have implications not only in recognition of specific antigens in allergic reactions, but also in the recognition of bacteria and elimination of parasites (pathogen specific antibodies)[81 107]. Bacterial superantigens, such as *S. aureus* protein A, which bind certain antibodies can similarly activate mast cells, independently of antigen specificity[108].

Mast cells can also be activated directly by viruses and bacteria through their expression of toll-like receptors (TLRs) that recognise pathogen-associated molecular patterns (PAMPs) (Figure 4). Mast cells have been shown to express TLR1, TLR2, TLR3, TLR4, TLR6, TLR7 and TLR9. *In vitro* studies in rodents and humans have shown that TLRs can activate mast cells, and that the response is specific for each PAMP. Activation through different TLRs leads to individual patterns of cytokine production (e.g. TNF-α, IL-6, IL-13, IL-1β) with or without degranulation[78 109-112].

The anaphylatoxins, C3a and C5a of the complement system, act as potent chemoattractants as well as activate mast cells and cause histamine release (Figure 4)[113 114]. Furthermore, other host endogenous peptides such as neurotensin, substance P[115 116] and endothelin 1[117] activate mast cells and cause mediator release. Binding of the CD30 ligand to CD30 on mast cells causes degranulation-independent secretion of chemokines, such as IL-8 and macrophage inflammatory protein-1 α and β[118].

Mast Cells in Health and Disease

As described above, the role of mast cells in disease is most commonly exemplified by effector functions in allergic rhinitis and asthma (Figure 5). Several pathophysiological events important for development of allergic asthma follow upon IgE activation. Mast cells rapidly release histamine (vascular leak, hypotension, bronchoconstriction), leukotrienes and prostaglandins (vascular leak, bronchoconstriction)[75]. Evidence for their role in anaphylaxis and asthma is the localisation in or near structures involved in asthma pathophysiology such as smooth muscle, glands and epithelium[90]. Increased numbers of degranulated mast cells are found in post-mortem bronchial biopsies from patients who died of asthma, and increased levels of mast cell mediators are found in BAL fluid in asthmatic patients compared to healthy subjects, even without allergen provocation. Mast cells are also in part responsible for the late phase reactions observed in allergy 4-24 h after allergen provocation. This is due to the release of *de novo* synthesis and release of various cytokines[119]. However, murine models of allergic inflamation in the lung have shown that in mast cell or IgE deficient mice a similar degree of airway inflammation exists[120]. Taking into account that mice do not naturally develop asthma, and the large differences in mast cell distribution in the airways between mice and humans might give an explanation to this phenomenon. Indeed, in other sensitization protocols, mast cells were shown to be essential for the induction of an allergic inflammation.

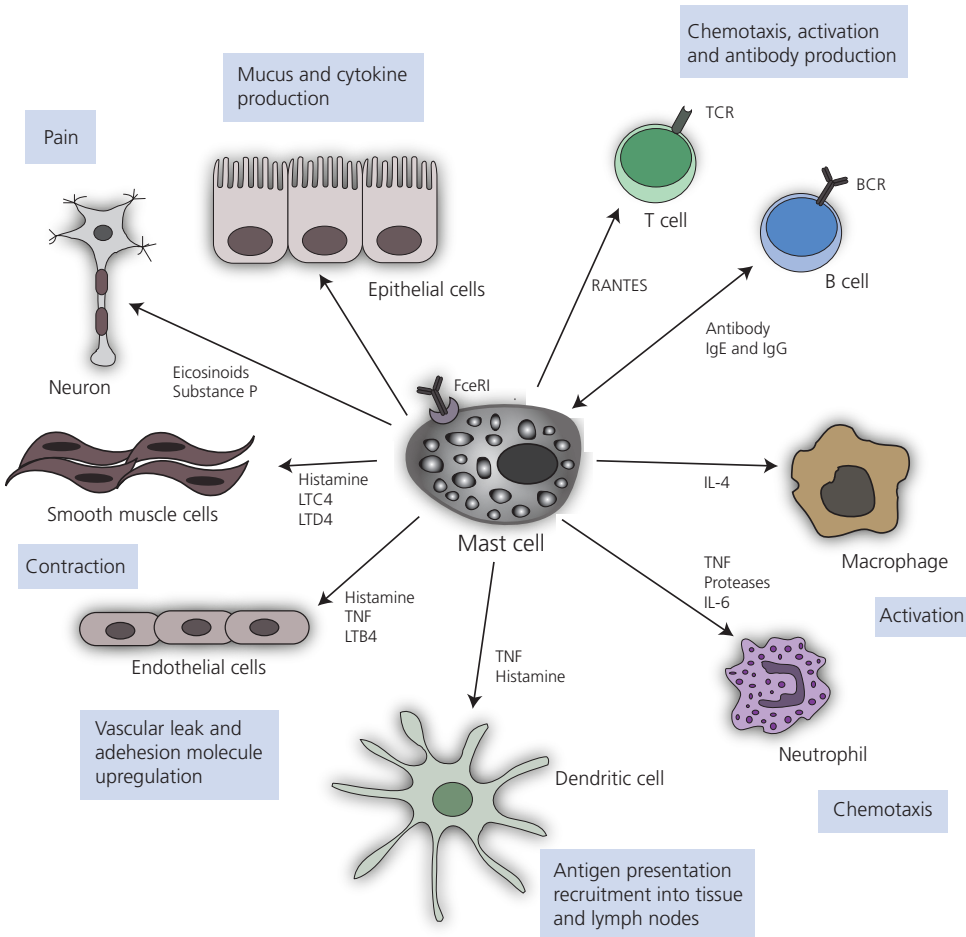

Figure 5. The interaction of mast cells with various structural and immunological cells, which results in different pathological processes.

Mast cells have been proven central for host survival. Mast cell deficient mice were found to be more likely to die in *Mycoplasma pulmonis* infection and in a model of acute septic peritonitis than their wild type counterparts[121]. In other infection models, recruitment of neutrophils by rapid release of mast cell derived TNF-α is essential for host survival and clearance of pathogens[122]. Mast cells also express receptors for direct recognition of bacteria (CD48)[123], bacterial products (TLRs)[78] and mediators like proteins of the complement system[124] and endothelin-1[117] are upregulated during a bacterial infection. Mast cells can also directly kill bacteria by the release of cathelicidins[125] and chymase[126]. Some bacteria have developed protective mechanisms against mast cells, for example exotoxin A from *Psuedomonas aeruginosa* can induce mast cell apoptosis.

Exacerbations in asthma and COPD are often associated with viral infections. Several respiratory viral infections change mast cell numbers and function[127 128], where

they upon activation via for example TLR3 secrete cytokines and mediators that can activate the endothelium to recruit immune cells to the site of infection[78 129-133].

Little is known about the possible contribution of the mast cell in fibrotic disorders of the lung[134]. Mast cells release a vast range of cytokines, proteases and proteoglycans that can modify and direct the inflammatory response towards resolution or formation of fibrosis[134]. Mast cell-derived molecules can both modify the production and destruction of extracellular matrix as well as promote migration and proliferation of fibroblasts *in vitro*[135-137]. Despite that mast cells have been shown to promote fibrosis in several organs[138 139], little is known regarding their role in formation of lung fibrosis. Previous studies have shown increased numbers of mast cells in bleomycin-induced pulmonary fibrosis in rats[136] and in sarcoidosis[135], as well as presence of mast cells in the airways of patients with CF[140 141] and increased mast cell numbers in the airways of patients with IPF[142-144]. Increased chymase expression has been reported in human idiopathic interstitial pneumonia [145]. Furthermore, Tchougounova *et al.*[146] demonstrated a possible role for chymase in mMCP-4 knockout mice, where chymase-deficient mice developed an imbalance in extracellular matrix production.

Upon parasite infection, IgE activates mast cells and in a mouse model, mast cells cause expulsion of the parasite from the intestinal mucosa by destroying the tight junction protein, occludin, by the activity of mast cell protease 1[147]. The mast cell involvement in the adaptive immune system is currently under investigation, but has been shown in murine models to include roles as antigen presenting cells or indirectly by potentiation of lymph nodes[148 149]. Mast cell activation (through IgE/FceRI or PAMPs/TLRs) promotes maturation and migration of dendritic cells to the lymph nodes, recruitment of dendritic cells from the circulation and can induce lymphnode hypertrophy. Several mast cell mediators, such as TNF-α and IL-6 can activate B- and T-lymphocytes in the lymph node. Finally, various venoms from snake, honeybee, mosquito (mastoparan, MCDP and sarafotoxins) cause mast cell activation and release of proteases that can degrade and reduce the concentration of the toxic peptides[78 81 133]. It is important to consider that mast cell-pathogen interactions have been predominantly studied in *in vitro* settings, and that differences are found depending on cell source and culture condition. More *in vivo* studies exploring the role of mast cells in non-allergic immune responses seem warranted.

Aims and Hypotheses

The general aim of this thesis was to study the distribution, heterogeneity and molecular expression pattern of human mast cells, as they appear in tissue from patients with inflammatory airway disease.

The main hypothesises of the five studies are as follows:

- The first study (paper I) tests the hypothesis that the prevailing MC_T and MC_{TC} mast cell subtypes can be further divided into site-specific populations created by the microenvironment within each anatomical compartment in the healthy human lung.

- Following studies aimed to investigate how non-allergic inflammatory responses affect the mast cell populations in the lung with regard to mast cell heterogeneity of the MC_T and MC_{TC} populations, morphology, distribution and molecular expression. This is studied in detail in different severities of COPD (paper II), and in idiopathic pulmonary fibrosis and cystic fibrosis (paper III).

- We hypothesised that the alveolar parenchyma is subjected to a mast cell-associated inflammation in patients with uncontrolled asthma (paper IV). A significant proportion of patients with asthma have persistent symptoms despite treatment and little is known regarding the inflammation and role of mast cells in the alveolar parenchyma in these patients.

- We hypothesised (paper V) that allergic rhinitis patients with concurrent asthma (but not patients with rhinitis alone) have increased mast cell expression of the high affinity IgE receptor in the alveolar parenchyma. Many patients with allergic rhinitis develop asthma over time but little is known regarding the differences in alveolar inflammation between the two diseases.

Methodology

The aim of this chapter is to give an overview of the different techniques and methodological approaches used in this thesis. Information about specific material and methods is given in detail in paper I-V. For all included papers, human lung tissue was studied with different histological techniques.

Subjects and Patient Characterisation

All subjects analysed in this thesis gave their written informed consent and the local ethics committee approved the studies. For patient details see Table 1.

Healthy Controls and Smoking Controls (Paper I-V)

In all papers, control tissues were collected from healthy non-atopic non-smoking subjects (n=16). Also smoking controls (ex- or current smokers without COPD, n = 7) were included. All control subjects had normal lung function according to criteria for each corresponding disease, negative metacholine challenge test (PD20 > 2000 μg) and negative skin prick test. Control tissues were obtained through two different methods: lung resections and bronchial- and transbronchial biopsies (see below).

Patients with COPD (Paper II)

Twenty-five subjects were included in the study and were divided into 3 COPD patient groups: patients with mild COPD (GOLD I, n = 6), moderate to severe COPD (GOLD II–III, n = 9), and very severe COPD (GOLD IV, n = 10). The patient grouping was based on GOLD classifications[31]. Lung tissue from mild, moderate, and severe COPD was obtained in association with lung lobectomy due to suspected lung cancer, a procedure that has been used repeatedly to collect tissue from COPD patients[70 71 150 151]. In patients with very severe COPD (GOLD IV), matching lung tissue was collected in association with lung transplantation.

Patients with Cystic Fibrosis (Paper III)

CF was diagnosed on the basis of clinical manifestations from the lung and gastro-intestinal tract and a positive sweat test[42 152]. In 5 patients with end-stage CF, lung tissue (20 large tissue blocks) was collected in association with lung transplantation.

Patients with Idiopathic Pulmonary Fibrosis (Paper III)

Twenty-one large lung tissue blocks from 7 IPF patients, diagnosed based on established criteria[50] and confirmed by open lung biopsy was collected. Characterisation was further established after lung function tests, oxygen saturation test during exercise, blood sampling and cell profile in BAL fluid. As patients were diagnosed in relation to their inclusion in the study, they were not on treatment with any medication. The research protocol for IPF patients was approved by the Ethics Committee of the National Institute of Respiratory Diseases, Mexico City, Mexico.

Patients with Atopic Asthma and Rhinitis (Paper IV-V)

Thirty-eight non-smoking patients with confirmed allergic rhinitis (AR)[153] were studied. Of the AR patients, 8 had a concomitant diagnosis of mild atopic asthma and 14 had a concomitant diagnosis of mild to moderate uncontrolled asthma. Diagnosis were based according to GINA guidelines and asthma control test (ACT)[154]. Among the 16 AR patients with no concomitant asthma, 8 were hyper-responsive to metacholine defined by spirometric testing (PD20 < 2000 μg). Central airway biopsies and transbronchial biopsies were collected at the Department of Respiratory Medicine, Lund University Hospital (see below).

Skin Prick Test

Skin prick test (SPT) (Alk Abello, Copenhagen, Denmark) was used to screen for sensitization for 10 aeroallergens (birch, timothy, mugwort, cat, dog, horse, *D. pteronyssinus*, *D. farinae*, *Aspergillus fumigatus* and *Cladosporium herbarum*). Patients with positive SPT to pollens without any other sensitivity were classified as seasonal, whereas patients with multiple sensitivities (pollen, animal, mould and/or mite) were classified as perennial. For all subjects with positive SPT to pollen, bronchoscopy procedures were performed outside pollen season.

Spirometry and Metacholine Inhalation Challenge Test

For measurements of lung function a MasterScope spirometer (v. 4.5, Erich Jaeger GmbH, Wurzburg, Germany) was used, and reference values were obtained from

Crapo[155]. Two values of FEV_1, with less than 4 % variation, were obtained and the better was recorded as baseline. If the baseline value was less than 70 % of predicted, the metacholine inhalation challenge test was aborted and patients were excluded from the study. Presence of bronchial hyper-responsiveness was measured with a metacholine inhalation challenge test, which was performed with a tidal volume triggered equipment (Aerosol Provocation System, APS; Erich Jaeger GmbH). The APS delivered a cumulative dose of 2000 µg metacholine in five increments (50, 150, 300, 600 and 900 µg) following an initial dose of 0.9% NaCl. If the FEV_1 declined more than 20% during the test the challenge was aborted. A positive test was defined as the cumulative dose that caused a decline in FEV_1 by 20% or more from baseline. When FEV_1 fell below 80% of the baseline value or when the total amount of 2000 µg metacholine was delivered, 400 µg of salbutamol was given to the subject. After 10 min a new flow-volume spirometry was carried out, to ensure that the subjects were recovering accurately.

NO measurement

Measurements were performed as previously described[156]. Briefly, FeNO measurements were done prior to bronchial challenge test at a flow rate of 50, 100, 200 and 400 ml/s using a NIOX nitric oxide analyser (Aerocrine AB, Stockholm, Sweden) and the results were expressed as parts per billion (ppb). Alveolar NO concentration and bronchial flux of NO were calculated with a two-compartment linear model using a flow rate of 100–400 ml/s.

Impulse Oscillometry

A Jaeger MasterScreen Impulse Oscillometry System, Erich Jaeger GmbH, was used 90 s after each step of the challenge, prior to FEV_1 (as previously described[157]). Resistance was reported as R5 (total respiratory resistance of the airways) and R20 (resistance of the proximal airways). The ΔR5-R20 parameter is an indicator of peripheral resistance of the respiratory tract. Resonant frequency (Fres) is a good index of changes of the degree of peripheral involvement[157]. The IOS parameters were plotted against the metacholine dose at each challenge step and linear regression analysis was used to calculate a slope value.

Tissue Acquisition and Processing

When possible, care was taken to immerse the tissues from patients and controls in fixative immediately after surgical excision and multiple large tissue blocks were prepared for histological analysis.

Lung resections

Tissue was obtained from lung lobectomy samples resected from patients undergoing surgery due to suspected lung cancer. Only patients with solid, well-delineated tumours were included, and tissue samples were obtained as far as possible from the tumour. This procedure has commonly been used to collect human tissue from never-smoking and smoking controls as well as from COPD patients[70 71].

Bronchial and Transbronchial Biopsies

Bronchoscopy was performed after local anaesthesia with a flexible bronchoscope (Olympus IT160, Tokyo, Japan) and transbronchial biopsies were taken with biopsy forceps (Olympus FB211D) under fluoroscopic guidance in the peripheral right lower lobe, not closer than 2 cm from the chest wall. Before bronchoscopy, the subjects received oral Midazolam (1mg per 10kg) and i.v. Glykopyrron (0.4 mg). Local anaesthesia was given as Xylocain spray; local and through spray catheter. Just before the procedure, alphentanyl 0.1-0.2mg / 10kg bodyweight was given intravenously and extra Midazolam i.v. was given as needed. Central airway biopsies (n=5) were taken from the segmental or sub segmental carina in right lower and upper lobe, followed by transbronchial (n=5) in right lower lobe. Oxygen was given as needed under and after the procedure. Fluoroscopy of the right lung was done immediately after and 2 hours after the procedure in order to rule out significant bleeding or pneumothorax. 3-4 mg betamethasone was given to prevent eventual fever reactions and the subject was discharged after 2 hours observation.

Formalin Fixated and Paraffin-Embedded Tissue

Samples (paper I-IV) were placed in 4% buffered formaldehyde, dehydrated, and embedded in paraffin. From each block, a large number of sequential sections 3 µm in thickness were generated.

Periodate Lysine Paraformaldehyde Fixated Tissue

Samples (paper IV and V) were fixed in periodate-lysine containing 1% paraformaldehyde (1% PLP) for 4 h at 4°C. Specimens were embedded in OCT (Tissue-Tek, Miles Laboratories, IN), and stored at -80°C. Cryosections were cut serially at 8 µm and enwrapped in aluminium foil, and stored at -80°C until used.

Tissue Processing for Electron Microscopy

After tissue fixation (paper I-II) in buffer supplemented with 1% glutaraldehyde and 3% formaldehyde overnight, samples were rinsed in buffer, post-fixed in 1% osmium tetroxide for 1 h, and dehydrated in graded acetone solutions and embedded in Polarbed 812. One-µm thick toluidine blue stained plastic sections were examined by bright field microscopy and areas with a well-preserved morphology were selected for electron microscopic analysis. Ultrathin sections (90 nm) were cut and placed on 200-mesh, thin bar copper grids before staining with uranyl acetate and lead citrate [158].

Histology and Immunohistochemistry

Mayer's Haematoxylin and Masson's Trichrome-Staining

Mayer's haematoxylin (HTX) staining was used both as counterstain in immunohistochemistry procedures and as complete HTX and eosin staining used for morphological evaluation. HTX-Eosin stains cell nuclei blue and cell cytoplasm red. Masson's trichrome-staining visualise collagen fibres bright blue, muscle, cytoplasm and keratin red and cell nuclei black and was used for morphological evaluation in tissue from patients with fibrotic lesions. The trichrome staining was also used to measure the degree of fibrosis in the lungs of patients with CF and IPF in paper III. A scoring system[159] as well as measuring of the density of collagen (based on the blue staining using a image analysis program) were applied to the sections.

Double Immunohistochemical Staining of MC_T and MC_{TC}

A modified double-staining technique was developed to stain for mast cell subtypes, mucosal mast cells (MC_T, positive for tryptase) and connective tissue mast cells (MC_{TC}, positive for chymase and tryptase), in the same section. Paraffin sections were pretreated with a high-temperature antigen unmasking technique (pressure cooking, DIVA buffer, pH 6, for 20 min; Biocare Medical, Concord, CA or PT Link, target retrieval solution low pH, Dako, Glostrup, Denmark). The immunohistochemical staining was performed with an automated immunohistochemistry robot (Autostainer; DakoCytomation) with EnVision™ G|2 Doublestain System (K5361; Dako). Sections were blocked with dual endogenous enzyme block for 10 minutes, then incubated with primary antibody (mouse monoclonal anti-mast cell chymase) for 1 hour, incubated with an HRP-conjugated polymer for 30 min and developed using the HRP substrate DAB as chromogen. By saturating all chymase-positive mast cells with a dark brown DAB (3,3'-diaminobenzidine) precipitation staining, they become inert to further mast cell tryptase staining due to that the precipitated DAB complex constitutes a steric hindrance for any further antibody binding. Next, sections were blocked using double

stain block reagent (making the first antibody inert to further staining by chemically destroying the antigenicity) and were incubated with mouse monoclonal anti-mast cell tryptase for 1 hour at room temperature. This was followed by Rabbit/Mouse link and incubation with an AP-polymer and visualisation with Permanent Red or New Fuchsine chromogen. Background was visualised with HTX staining and sections were mounted in Pertex mounting medium (Histolab, Gothenburg, Sweden). The resulting staining showed MC_{TC} cells as dark brown and the MC_T population appeared bright red.

Immunohistochemical Triple-Staining

Slides were pre-treated using a high-temperature antigen unmasking technique with appropriate target retrieval solution. Paraffin sections were blocked for unspecific binding in normal serum from the species in which the secondary antibody was produced, mixed with or without dry milk (Vector Laboratories, Burlingame, CA) at ambient temperature. Sections were blocked for endogenous streptavidin and biotin with avidin/biotin blocking kit (Vector Laboratories, Burlingame, CA) and incubated with primary antibodies against the molecules of interest. After a rinsing step, sections were incubated for 1 hour at ambient temperature with the biotinylated secondary antibody and fluorescence conjugated streptavidin (1:200, 10 µg/ml, S21381; Molecular Probes, Eugene, OR) for 30 minutes at ambient temperature. To stain the same sections for mast cell subtypes (MC_T and MC_{TC}), the mouse monoclonal antibodies used in the double staining described above, anti-mast cell tryptase and anti-mast cell chymase, were directly labelled with Alexa Fluor 488 and Alexa Fluor 350, respectively, using Zenon® Mouse IgG labelling kit (Invitrogen, Molecular Probes). Sections were incubated with the mixed solutions for 1 hour at ambient temperature and mounted in TBS/glycerol mounting medium. All rinse steps were in TBS buffer (pH 7.6).

Detection of Apoptotic Mast Cells in Lung Tissues with the TUNEL Technique

Paraffin-embedded sections (3 µm) were deparaffinised and pre-treated with proteinase K (20 µg/ml; Sigma, Stockholm, Sweden) for 15 min at room temperature. Apoptotic cells were visualised using the TUNEL technique according to the manufacturer's instructions (ApopTag Fluorescein In Situ Apoptosis Detection Kit, S7110; Chemicon/Millipore, Billerica, MA)[160]. Apoptotic cells were visualised with a sheep anti-digoxigenin fluorescein (FITC) antibody. No staining was evident in negative controls when the terminal deoxynucleotidyl transferase (TdT) enzyme was omitted. Mast cells were detected using primary antibody to tryptase (1 h at ambient temperature) and visualised with an Alexa-555 conjugated secondary goat anti-mouse antibody (Invitrogen, Molecular probes, Eugene, OR). Slides were counterstained with the DNA-binding

stain Hoechst 33342 (Sigma) to show the total number of cell nuclei. As positive control, dexamethasone-treated thymus was used.

Antibody Specificity Controls

The antibodies used in this thesis have been used extensively in research and routine pathological examinations of human formalin-fixed, paraffin-embedded material and most antibodies have also been validated and certified for pathology-based diagnosis. All antibodies showed relevant biological staining in accordance with previous literature. Staining was absent in sections omitting the primary antibody. For all immunohistochemical procedures, markers and tissues, staining were also absent in sections using isotype-matched control antibodies (Dako) that were used instead of, and in the same concentration as, the primary antibody. The mouse monoclonal isotype IgG1 and IgG2 controls are antibodies against Aspergillus niger glucose oxidase, an enzyme which is neither present nor inducible in mammalian tissues. The rabbit negative control immunoglobulin fraction was isolated from serum of healthy non-immunised rabbits.

Measurements

Quantification of Mast Cell Densities in Lung Compartments

From each section double stained for MC_T and MC_{TC}, the density of each population was quantified manually in blinded images and related to the tissue area. Ultra-high resolution digital images (> 4 GB) were generated by an automated slide scanner robot equipped with an x20 microscope lens (Image Scope, v10.0.36.1805, and ScanScope FL, Aperio, Vista, CA). After manual delineation of each analysed compartment (i.e. large airway walls, small airway walls, pulmonary vessel walls and alveolar tissue), the analysed tissue area was calculated through computerised image analysis using virtual microscopy software. The image analysis program automatically excluded any air spaces, so that only true tissue was measured. For lung resections and transplantation tissue, each tissue section comprised > 4 cm^2 lung tissue and contained several small airways, pulmonary vessels as well as differentially altered alveolar parenchyma, allowing for comparisons between the following key compartments: *Large airways:* bronchi, defined by a diameter > 2 mm and regular or intermittent occurrence of cartilage, *Small airways:* bronchioles, defined by absence of cartilage and diameter < 2 mm. When appropriate, mast cells were evaluated in large and small airway epithelium, lamina propria, smooth muscle and adventitia. *Pulmonary vessels*: mid-size pulmonary arteries in the broncho/bronchiovascular axis or with an intra-acinar localisation. Mast cells were counted in intima, media and adventitia. *Alveolar parenchyma:* Four randomly selected 0.5 mm^2 alveolar regions were analysed in each lung section. Due to the heterogeneity of diseased alveolar parenchyma (paper III), each slide was assessed for mast cells in the

following category of parenchyma: normal, or nearly normal parenchyma (defined as absent or minimal fibrous thickening of alveolar walls and only few scattered inflammatory cells); inflammatory parenchyma (areas with significant leukocyte infiltration, often accompanied by some alteration of alveolar structure); and fibrotic parenchyma (fibrotic lesions and regions with excessive collagen deposition, as revealed by Masson's trichrome staining in consecutive sections). For bronchial and transbronchial biopsies (paper I, IV and V), all mast cells of each subpopulation per biopsy were quantified manually in randomised, blinded images of central airways and alveolar parenchyma. In bronchial biopsies the densities of MC_T and MC_{TC} were also calculated in sub-anatomical compartments: *epithelium, subepithelial tissue (excluding smooth muscle and glands), smooth muscle tissue and subepithelial glands*. The proportion of the MC_{TC} subtype in each compartment was calculated according to $(MC_{TC} / [MC_{TC} + MC_T]) \times 100$.

Expression of Mast Cell-Related Molecules

The markers in paper I-V were selected to reflect activation status and possible roles for mast cells in normal conditions, chronic inflammation and in the formation of fibrosis. Sections were analysed using NIS-elements AR 3.0 system (Nikon, Tokyo, Japan), a Nikon Eclipse 80i microscope, and a Nikon DS-Qi1Mc camera. After triple immunofluorescence staining, filter setting was adjusted to reveal the tryptase-positive mast cells at 488 nm. By alternating the filter settings each tryptase-positive cell was examined for presence of chymase as well as expression of mast cell-related molecules. By dividing the number of $tryptase^+/chymase^-$ and $tryptase^+/chymase^+$ cells that were co-positive for the molecule of interest, the proportion of co positive mast cells of total number of mast cells, MC_{TC} and MC_T was calculated. In papers IV and V also the density of mast cells expressing FcεRI and IgE was calculated by multiply the percentage of $MC^{Fc\varepsilon RI+}$ or MC^{IgE+} with the total mast cell density in the same tissue region.

Size and Shape Analysis

In paper I and II, the average cross section size was calculated for both MC_T and MC_{TC} in each major compartment of the lung. Cell size was measured with manual cursor tracing at high resolution digital images using software Image J (version 1.34s, National Institutes of Health, USA). MC_T and MC_{TC} were visualised in the same section by double staining (see above). The size measurements used in the main study were performed on foremost cross-sectioned airways and pulmonary vessels. To exclude any misleading results from an uneven or biased sectional plane we analysed cell sizes in a large numbers of longitudinally sectioned airways and vessels. To further improve our quantification of mast cell sizes we employed a stereological approach using volume fraction measurements from a fixed cell number quantification [161]. In short, using a point grid overlaid onto randomly orientated tissue sections point counting was performed until a fixed numbers of mast cells (240 /patient) were hit by one or more points. With similar cell

numbers analysed differences in volume fraction will equate differences in mean cell size. The volume fraction for each mast cell subtype and compartment was calculated using the equation:

$$V_{V\,(MC,\,compartment)} = \frac{\sum P\,(MCT,\,MCTC)}{\sum P\,(SA,\,PV)}$$

Where P is points counted, SA denotes the small airways compartment and PV is pulmonary vessels. The cell shape was calculated using the formula: circularity=4π (area/perimeter^2).

Transmission Electron Microscopy

In each lung compartment samples were processed and analysed by routine transmission electron microscopy using a standard protocol[162]. Mast cell subtypes and the degranulation status of each individual mast cell were analysed according to established ultra structural characteristics[88] and the results were scored according to the following categories: no degranulation (completely filled granules with characteristic scroll or crystalline pattern), mild piecemeal degranulation (presence of granules with loss of structural organization and electron density and absence of granule fusions to the plasma membrane[88]), advanced piecemeal degranulation (the majority of granules partially or completely empty and abundant secretory vesicles) and classical anaphylactic degranulation (granule swelling, fusion, or degranulation channel formation and occurrence of extracellular granules[163]).

Statistical Analyses

Data were analysed statistically using Kruskal-Wallis test with Bonferroni's multiple comparisons test for comparison between three groups or more and Mann-Whitney rank sum test for comparison between two groups, using GraphPad Prism v. 5 (GraphPad Software, Inc., La Jolla, CA). For correlation between lung function values and mast cell parameters, Spearman rank correlation test (two-tailed) was used. To compensate for multiple testing, the false discovery rate procedure was applied to the correlation analysis, which guaranties that less than 5% of all positive results are false positive[164]. Results were considered significant at $p \leq 0.05$.

Table 1. Study design and characteristics of patients with COPD, CF, IPF, asthma, rhinitis and healthy control subjects

	Healthy controls	**Healthy smokers**	**COPD** (GOLD I-IV)	**CF**	**IPF**	**Uncontrolled asthma**	**Mild asthma**	**Allergic rhinitis** (without/with BHR)
Number of patients (n)	16 (8+8)	7	25	5	7	14	8	16 (8+8)
Age (years)	63 (33-76)[b] 23 (21–39)[c]	56 (47-68)	64 (52-76)	30 (23-38)	64 (57-70)	40 (22-59)	28 (22-37)	26 (22-58)[d] 27 (22-28)[e]
Male/Female	2/6[b] 5/3[c]	3/4	16/9	2/3	0/7	9/5	5/3	5/3[d] 5/3[e]
Tissue acquisition (n=number of tissue blocks)	Lung resections (n=28) EBBX (n=40/16[a]) TBBX (n=40/16[a])	Lung resections (n=21)	Lung resections Lung transplantation (n=75)	Lung transplantation (n=20)	Open lung biopsy (n=21)	EBBX (n=70/28[a]) TBBX (n=70/28[a])	EBBX (n=40/16[a]) TBBX (n=40/16[a])	EBBX (n=40/16[a]) TBBX (n=40/16[a])
Medication								
Inhaled GCS (yes)	No	No	10	5	No	14	No	No
Oral GCS (yes)	No	No	1	3	No	No	No	No
β2 agonist (yes)	No	No	12	5	No	14	5	1
Anticholinergics (yes)	No	No	9	1	No	No	No	No
Mucolytic (yes)	No	No	8	5	No	No	No	No
Lung function								
FEV_1 % pred.	110 (82–141)[b] 98 (72-116)[c]	97.4 (82–120)	56.5 (13-95)	31 (22-45)	82 (66-93)	81.2 (63-108)	96.4 (88-124)	107 (96-138)
FEV_1 / FVC	86 (66–121)[b]	78.1 (71–88)	49.7 (17-70)	50 (33-84)	90 (82-99)	-	-	-
Histology								
MC_T/MC_{TC}	Yes	Yes	Yes	Yes	Yes	Yes	Yes	Yes
Expression pattern	Yes	Yes	Yes	Yes	Yes	Yes (FcεRI/IgE)	Yes (FcεRI/IgE)	Yes (FcεRI/IgE)
Microlocalisation	Yes	Yes	Yes			Yes		
Apoptosis	Yes		Yes					
Morphology (size/shape)	Yes		Yes					
TEM (degranulation)	Yes		Yes					
Correlation study	Yes	Yes	Yes	Yes	Yes	Yes	Yes	Yes

BHR = bronchial hyperreactivity. GCS = glucocorticosteroids. [a] number of specimens selected for the mast cell analyses, [b] healthy control (tissue acquisition: lung resection), [c] healthy control (tissue acquisition: bronchoscopy), [d] allergic rhinitis without BHR, [e] allergic rhinitis with BHR.

Results

Novel Site-Specific Mast Cell Subpopulations in the Human Lung (Paper I)

In vivo data on human lung mast cells, particularly in peripheral regions, have remained scarce. There are indications that division into MC_T and MC_{TC} does not adequately explain the complexity of lung mast cell heterogeneity. Based on these notions we hypothesised that among the anatomical compartments of the lung there is a site-specific heterogeneity that is present already under non-inflamed healthy conditions and goes beyond the MC_T and MC_{TC} classification. The present study explores this possibility through detailed assessments of morphometric and molecular characteristics of lung tissue mast cell populations under base-line conditions. These parameters were investigated in multiple lung structures by immunohistochemistry and electron microscopy. Fifteen non-smoking subjects with normal lung function were investigated.

MC_T and MC_{TC} are abundant at all airway levels with a gradual increase towards peripheral regions

Mast cells were abundant at all airway levels with a gradual and statistically increased density towards the alveolar parenchyma. In all major anatomical compartments, except in the adventitia of pulmonary vessels and the pleural wall, MC_T was the predominant subtype (Figure 6A).

MC_T and MC_{TC} may be divided into site-specific subgroups

By measuring cell cross-section areas it was revealed that the size within each of the MC_T and MC_{TC} populations differed dramatically between anatomical regions. Large MC_T cells were found in bronchi, small airways and alveolar parenchyma and significantly smaller MC_T were present in pulmonary vessels. For MC_{TC} a reversed pattern was found, i.e. large MC_{TC} in pulmonary vessel walls, and a significantly smaller MC_{TC} population in bronchial and small airway walls and alveolar parenchyma. Distinct size changes were further corroborated by stereology where distinct volume fractions were present after analysis of equal mast cell numbers. Calculation of the circularity showed that MC_{TC} cells were significantly more circular in all compartments compared to neighbouring MC_T cells in the bronchial wall, small airways, and pulmonary vessels. Ultrastructural examinations of MC_{TC} and MC_T subtypes, identified by their distinct

granule morphology, revealed that in all examined compartments mast cells were of a non-degranulated phenotype.

Distinct expression of mast cell-related molecules in site-specific MC_T and MC_{TC} populations

When different lung compartments were examined, a significant difference in mast cell FcεRI expression was found, from an extensive expression in bronchi, moderate in small airways, and a virtually absent expression on alveolar mast cells. A similar pattern was seen in bronchial and transbronchial biopsies from the young control population. The expression of HDC followed the same pattern as the FcεRI. Renin, just recently discovered as an airway mast cell mediator, showed significantly elevated expression in the pulmonary vessels and the distal airways compared to the other compartments of the lung. Differences in mast cell expression of 5-LO, LTC_4-S, IL-9R, FGF-2 and VEGF were found, not only between the MC_T and MC_{TC} subpopulation, but also between each compartment (Figure 6B).

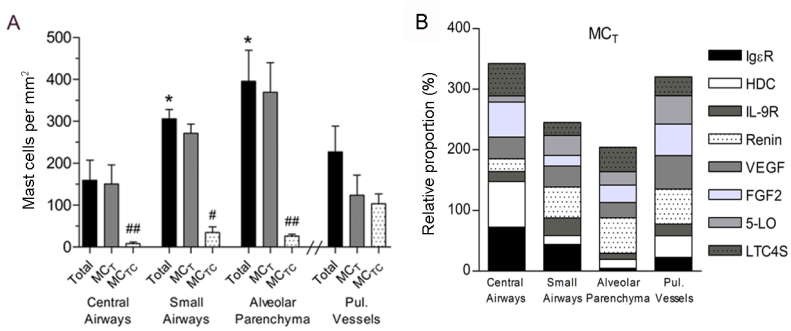

Figure 6. Mast cell densities (A) and a summary of the molecular expression pattern in MC_T (B) in different compartment of the healthy human lung.

Marked Alterations of Lung Mast Cell Populations in Patients with COPD (Paper II)

Mast cells have been asserted roles in innate immunity, immune orchestration, and tissue remodelling. Since mast cells are present in high numbers throughout the human lung, this suggests potential involvement in non-allergic inflammatory diseases like COPD.

Alteration of mast cell numbers in COPD

In both control and COPD subjects, mast cells were present at all anatomical compartments of the lung. A decrease in total mast cell numbers was found in small airways in patients with COPD (GOLD IV) compared to non-smoking and smoking controls. The total density of mast cells in pulmonary vessel walls also decreased significantly in very severe COPD when compared to non-smokers, smokers and GOLD I-III. No difference in total numbers were found in the alveolar septa of the parenchyma as the different groups were compared.

COPD lungs have increased proportion of MC_{TC}

Division into MC_T and MC_{TC} populations revealed that in all compartments of the lung there was a gradual and significant decrease in MC_T density as the severity of COPD increases (Figure 7B-D). In contrast, in small airway walls and alveolar parenchyma the density of MC_{TC} increased significantly in COPD (GOLD IV). In pulmonary vessels the density of both subpopulations dropped significantly in COPD (GOLD IV). In very severe COPD scattered submucosal glands were present in association with airways in the peripheral lung. Notably in these structures, MC_{TC} comprised 95 % of the total mast cell density. Bronchial mast cell densities in large airway tissue were analysed in separate biopsies and lung resections of non-smoking controls and COPD (GOLD IV). In central airways in COPD (GOLD IV) a decreased total number of mast cells, and an increased MC_{TC} proportion, were shown compared to controls.

MC_T and MC_{TC} cells have altered distributions in small airways and pulmonary vessels

The distribution of mast cells was analysed in more detail in sub-anatomical compartments within the small airways and pulmonary vessels. In summary, in small airways from COPD patients there was a shift in relative mast cell densities from the outer to the inner wall layers (epithelium and lamina propria). For both MC_T and MC_{TC} the percentage of intraepithelial mast cells increased significantly in very severe COPD while the proportion of both subtypes decreased in the smooth muscle and adventitia layers.

Mechanisms for clearance of lung mast cells

In light of the decreased numbers of total mast cells in COPD possible mechanisms for mast cell elimination were investigated. Screening of >5000 mast cells / patient and large numbers of TUNEL-positive nuclei (mostly neutrophils) revealed that co-localization in mast cells was exceedingly rare. In patients with COPD (GOLD IV), luminal MC_T cells mast cells were readily observed and significantly increased in numbers compared to control groups and COPD groups with milder disease, which might indicate elimination of mast cells through luminal entry or epithelial shedding.

Altered MC_T and MC_{TC} phenotypes in COPD

Ultrastructural examination of lung mast cells by transmission electron microscopy was performed on very severe COPD lungs and non-smoking controls. Mast cells in non-smoking subjects were of a non-degranulating phenotype i.e. displayed filled granules lacking morphological signs of anaphylactic or piecemeal degranulation. Although most of the mast cells in COPD were of a non-degranulating phenotype, cells displaying signs of mild to moderate piecemeal degranulation were readily found. In small airways the cross-section MC_{TC} area in controls was significantly lower than in patients with very severe COPD. The expression of the mast cell related molecules CD88, TGF-β and renin were changed in patients with COPD compared to controls. The percentage of mast cells expressing the C5a receptor (CD88) and TGF-β increased significantly in all COPD groups compared to non-smoking and smoking controls. In patients with COPD the most pronounced increase was observed for the MC_{TC} subclass. The expression of mast cell renin was high at baseline conditions. COPD lungs, particularly those affected by more severe disease (GOLD II-IV), were associated with a significant decrease in renin expression.

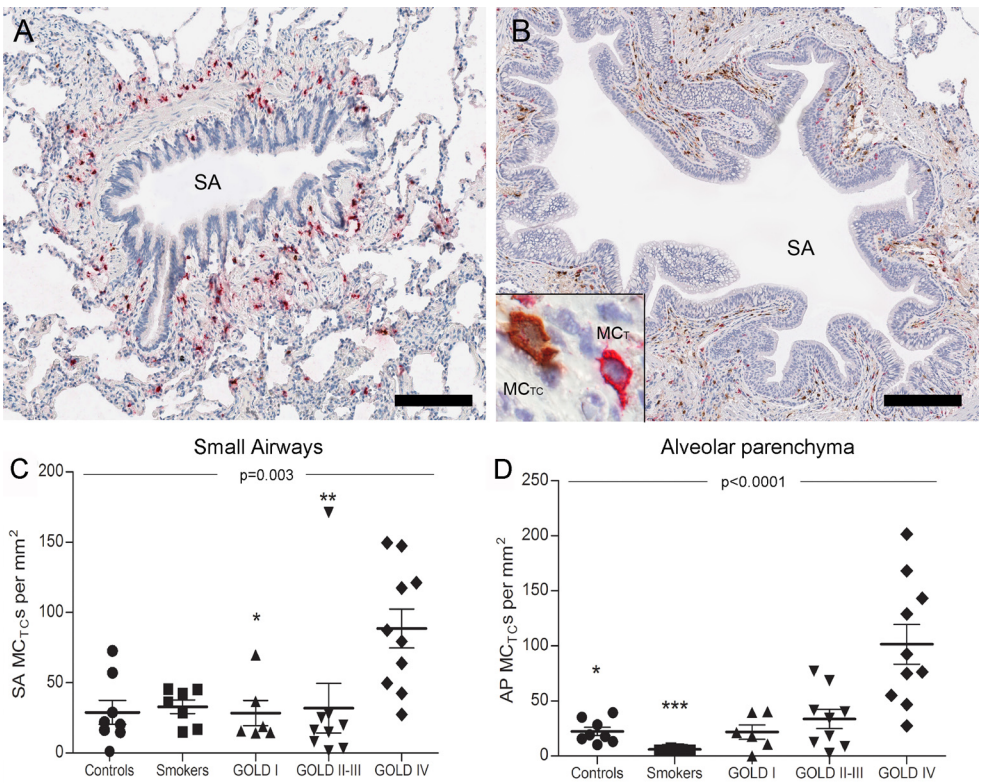

Figure 7. Representative micrographs of immunohistochemical double staining of MC_T (red) and MC_{TC} (brown) in small airways from a healthy subject (A) and a patient with COPD GOLD IV (B). Scale bars: A = 100µm, B = 200µm. The density of MC_{TC} in small airways (C) and alveolar parenchyma (D) in smoking and never-smoking controls and COPD GOLD I-IV.

Correlations

For the COPD patient groups several highly statistical correlations were found between mast cell and lung-function parameters (FEV_1/VC and FEV_1 % predicted). In all anatomical compartments there was a positive correlation between decreased densities of total or MC_T mast cells and reduced lung function. For MC_{TC} increased densities within small airways and the lung parenchyma correlated with reduced lung function.

Activated Connective Tissue Mast Cells Infiltrate Diseased Lung Areas in Cystic Fibrosis and Idiopathic Pulmonary Fibrosis (Paper III)

Although mast cells are regarded as important regulators of inflammation and tissue remodelling, their role in cystic fibrosis (CF) and idiopathic pulmonary fibrosis (IPF) has remained poorly studied. The present study compares the densities and phenotypes of mast cell populations in multiple compartments in lungs from patients with CF, IPF and never smoking controls. Sections stained with Masson's trichrome revealed extensive alterations of lung structures in all CF and IPF patients.

Change in densities of MC_T and MC_{TC} populations in key anatomical compartments in CF and IPF compared to controls

In patients with CF, a significant decrease in total mast cell density was observed in small airways and pulmonary vessels. The total number of mast cells were increased in fibrotic and inflamed areas of the alveolar parenchyma in CF patients. In the inflamed parenchyma this was due to increased numbers of MC_T and MC_{TC} whereas only the density of the MC_{TC} population increased in fibrotic parenchyma. The preserved total mast cell numbers observed in small airways of IPF patients were a result of a decrease in MC_T and a parallel increase in MC_{TC} numbers. A significant decrease in total mast cell numbers was observed in pulmonary vessels in IPF. Furthermore, an increase in the density of the MC_{TC} population was found in the inflammatory parenchyma of IPF patients (Figure 8).

Calculation of the MC_{TC} percentage of the total mast cell population revealed that there was a shift towards a MC_{TC} phenotype in lungs from patients with CF and IPF. In CF, the increase in the proportion of MC_{TC} cells was found in small airways, and in normal as well as fibrotic areas of parenchyma. In IPF affected lungs, an increase in the proportion of MC_{TC} was found in small airways, pulmonary vessels as well as in normal, inflammatory and fibrotic areas of the parenchyma (Figure 8).

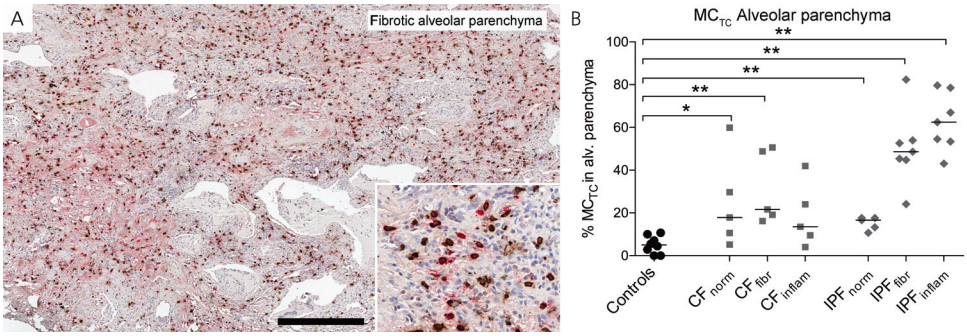

Figure 8. Micrographs of alveolar parenchyma with interstitial fibrosis from a patient with IPF stained for MC_T (red) and MC_{TC} (brown) (A). Scale bar = 300 µm. The proportion of MC_{TC} in alveolar parenchyma from patients with CF, IPF and healthy controls.

Increased mast cell expression of IL-6 and TGF-β in CF and IPF

In lungs from CF patients, the total mast cell expression of IL-6 was increased in small airways, pulmonary vessels and alveolar parenchyma compared to controls. No difference in mast cell expression of IL-6 was observed in the IPF lungs compared to control subjects. A significantly increased MC_{TC} expression of TGF-β was observed in all compartments analysed in both CF and IPF.

Correlation of mast cell parameters with lung function and degree of fibrosis

The percentage of MC_{TC} in small airways and the density of MC_{TC} per mm^2 in fibrotic alveolar parenchyma correlated negatively with lung function values in the CF and IPF patients. Both the density as well as the percentage of MC_{TC} correlated positively with the degree of fibrosis and the density of collagen.

Mast cell-Associated Alveolar Inflammation in Patients with Atopic Uncontrolled Asthma (Paper IV)

A significant proportion of patients with asthma have persistent symptoms despite treatment with ICS. We hypothesised that in these patients the alveolar parenchyma is subjected to a mast cell-associated inflammation.

Characterisation of mast cell phenotypes in uncontrolled asthma and healthy controls

In central airways, the total tissue density of mast cells did not differ between patients with uncontrolled asthma and healthy control subjects. In contrast, the alveolar parenchyma displayed increased numbers of mast cells in patients with uncontrolled asthma compared to healthy controls. The unaltered total mast cell numbers in central airways

in uncontrolled asthma were a result of decreased MC_T and increased MC_{TC} numbers compared to healthy controls. The significant increase in total alveolar mast cell numbers in uncontrolled asthmatics was due to an increase in both MC_T and MC_{TC} numbers compared to healthy controls. The densities of MC_T and MC_{TC} were also calculated in sub-anatomical regions within bronchial biopsies. The highest density of mast cells was found in the lamina propria for both control subjects and asthmatics. The MC_{TC} density increased in the smooth muscle layer in asthmatics compared to controls. No difference in the distribution of the MC_T subclass was found in asthmatics compared to controls.

Expression of FcεRI and IgE on bronchial and alveolar mast cells

The proportion of mast cells expressing FcεRIα was high in central airways in healthy subjects, and no significant difference was found in uncontrolled asthmatics. In the alveolar parenchyma, the mast cell expression of FcεRIα was low in healthy controls and significantly higher in uncontrolled asthma. To further confirm the increased FcεRIα expression in uncontrolled asthma, a computerized image analysis approach was used to calculate the area of FcεRIα immunoreactivity on individual mast cells. This analysis showed an increase in FcεRIα expression in central airways of asthmatics compared to controls. A similar increase was found in the alveolar parenchyma in asthmatics compared to controls. In the alveolar parenchyma, the proportion of IgE^+ mast cells was low in controls and significantly increased in the alveolar parenchyma of asthmatics. Similar results were found in the bronchi. In alveolar parenchyma, the tissue density of FcεRIα and IgE positive mast cells was increased in uncontrolled asthmatics compared to controls (Figure 9).

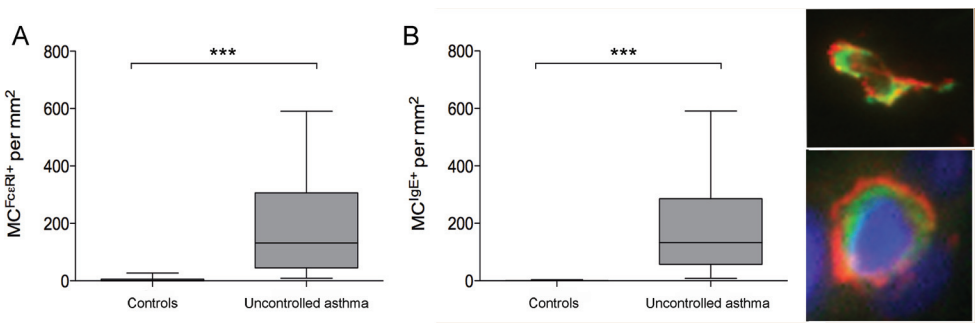

Figure 9. Density of mast cells expressing FcεRIα (A) and mast cell bound IgE (B) in alveolar parenchyma in uncontrolled asthma compared to healthy controls. Insets represents images (600×) of mast cells double positive for tryptase (green) and FcεRIα or IgE (red).

FcεRI and IgE expression on alveolar mast cells in AR and non-allergic inflammatory diseases

No significant change in total mast cell numbers or density of MC_T and MC_{TC} was found in central airways or alveolar parenchyma in patients with AR compared to healthy controls. Furthermore, no increase in the proportion of mast cells expressing FcεRIα or IgE could be found in central airways or alveolar parenchyma. However, an increase in the proportion of mast cells expressing surface bound IgE was found in alveolar parenchyma in patients with AR compared to controls.

The FcεRIα expression was high in central airways in controls compared to the same compartment in COPD and CF. In alveolar parenchyma, the mast cell FcεRIα expression was low in controls; no significant change was found in COPD and CF patients.

Alveolar Mast Cell Expression of FcεRI Differs between Allergic Asthma and Rhinitis (Paper V)

A significant proportion of patients with AR develop asthma over time. We hypothesised that AR patients with concurrent asthma (but not patients with AR alone) have increased mast cell expression of the high affinity IgE receptor (FcεRI) in the alveolar parenchyma.

Mast cell densities in central airways and alveolar parenchyma

No significant difference in total mast cell numbers or in the density of the two subtypes, MC_T and MC_{TC}, was found between the healthy controls, AR with and without BHR and AR with concomitant asthma.

Mast cell expression of FcεRI and mast cell-bound IgE in central airways and alveolar parenchyma

In healthy controls mast cells positive for FcεRIα were present in high numbers in central airways. No significant change was observed in patients with AR with or without BHR or in AR patients with concurrent asthma compared to non-atopic controls. In alveolar parenchyma, the mast cell expression of FcεRIα was low in non-atopic controls and in AR with or without BHR. A significant increase in both proportion and density of FcεRIα expressing mast cells was found in AR patients with concomitant asthma compared to healthy non-atopic controls and patients with AR alone (Figure 10).

In central airways, the proportion of mast cells positive for surface bound IgE was low in healthy controls. A significant increase in mast cells with positive staining for IgE was observed in AR with concurrent asthma. In the alveolar parenchyma, the proportion of mast cells with IgE was low in controls and AR without and with BHR. A significant increase in the proportion and the density of mast cells with IgE was observed

in the alveoli in patients with AR with concurrent asthma compared to non-atopic controls.

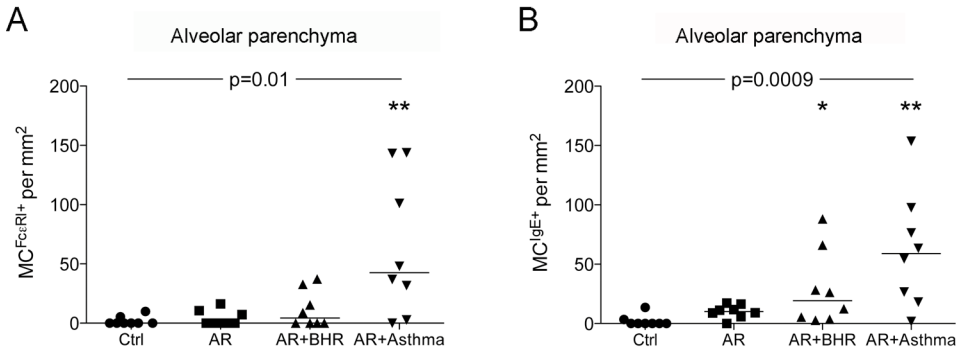

Figure 10. Density of mast cells expressing FcεRIα (A) and mast cell bound IgE (B) in alveolar parenchyma in healthy non-atopic controls, AR patients and asthma patients with and without BHR.

Correlation analyses

Significant negative correlations were found between PD_{20} and bronchial mast cell expression of FcεRIα and IgE. The bronchial NO flux and FeNO50 correlated positively with mast cell bound IgE in the bronchi. The alveolar mast cell expression of FcεRIα correlated positively with Slope-$Fres^{MCh}$. No correlations between mast cell parameters and R5, R20 and R5-R20 were found.

Discussion

The phenomenon of mast cell heterogeneity has been known for decades and studied in several species [72 165 166]. Apart from the prevailing classification into MC_T and MC_{TC}, this phenomenon has remained poorly investigated, especially under human *in vivo* conditions. Paper I in this thesis describes an expansion of the heterogeneity concept by showing that already under base-line conditions each anatomical compartment of the lung contains distinct MC_T and MC_{TC} populations with regard to morphology and mediator expression. How this heterogeneity changes under diseased conditions were studied in paper II-V.

Altered balance of MC_T and MC_{TC} in diseased lung

As previously described[77 167], mast cells in our studies were abundant in all lung regions and the MC_T subtype was by far the most common in the healthy human lung (paper I). MC_{TC} are the predominating subtype in several non-respiratory compartments like the dermis of the skin whereas there is a strong domination of MC_T in mucosa-lined organs like the respiratory tract. In COPD affected lungs (paper II), the MC_T population decreased markedly and there was an actual expansion of the MC_{TC} population. MC_{TC} cells increased in absolute numbers in both small airways and the alveolar parenchyma resulting in a shift in the MC_{TC}/MC_T balance. Balzar *et al.*, showed that in lungs with severe asthma there was a similar increase in MC_{TC} but these changes, unlike our results, correlated to improved lung function values[14]. A study by Gosman *et al.*[168], did not report any increase in MC_{TC} density but this may be explained by the fact that the COPD group in this study consisted of mixed disease severities and the present data suggest that the shift may only be evident in advanced disease. A marked expansion of the MC_{TC} population was also found in the small airways in IPF and remodelled parenchyma in CF and IPF (paper III). The expansion of the MC_{TC} population in CF and IPF may have several consequences in lung remodelling processes. Hirata *et al.*[145] showed that increased chymase expression in human idiopathic interstitial pneumonia, correlated with increased numbers of IL-4 expressing cells, smooth muscle cells and myofibroblasts. Furthermore, Tchougounova *et al.* [146] demonstrated a possible role for chymase in mMCP-4 knockout mice, where chymase-deficient mice developed an imbalance in extracellular matrix production. The previous research on mast cells in association with remodelling and fibrosis is limited, but increased numbers of mast cells have been found in animal models of fibrosis[169] and mast cells have been shown to affect biochemical properties of lung fibroblast function *in vitro*[135 137]. Pesci *et al.*[144]

found increased numbers of mast cells in patients with fibrotic lung disorders, which correlated significantly with the degree of fibrosis. We found increased density of MC_{TC} in the lungs of patients with atopic uncontrolled asthma (paper IV). This phenomenon was not seen in patients with mild asthma (paper V), and might hence be connected to more heavy inflammatory conditions of the lung, giving rise to symptoms like altered lung function and respiratory symptoms. A shift in the MC_{TC}/MC_T balance suggests that the microenvironment promote growth of the MC_{TC} population while the normally prevailing MC_T cells are reduced. More work is now needed to further explore the potential processes involved in the shift in the proportion of mast cell populations in asthma, COPD, CF and IPF. Irrespective of underlying mechanism, a change in the MC_{TC}/MC_T proportion is likely to have functional consequences and indeed, several correlations between multiple disease-related changes in density, balance of mast cell subtypes and lung function data were found. The expanded density of MC_{TC} also correlated to the degree of fibrosis as well as density of collagen in the lungs of patients with CF and IPF.

Effect of medication on mast cell subpopulations

The on-going medication of the patients included in this thesis could have contributed to the shift in MC_T/MC_{TC} balance. ICS have been demonstrated to reduce mast cell numbers in central airways [170], and have been shown to mainly affect mucosal mast cells in various compartments of the respiratory system[171-173]. However, the baseline density of MC_{TC} in some of these studies[171 173] was low and it is difficult to draw any conclusion if ICS selectively affected only the MC_T population. The results from the study of uncontrolled atopic asthma (paper IV) might indicate that ICS have an effect on mast cell subtype balance as a reduction of MC_T but not MC_{TC} was found in central airways. The fact that both subtypes expand in the alveolar parenchyma may show that the on-going ICS therapy did not reach this compartment. No changes in mast cell densities were observed in cases of mild asthma compared to healthy controls, and non of these patients were treated with ICS. The change in MC_T/MC_{TC} balance seen in the COPD study might depend on ICS therapy, although decreased numbers of mast cells were observed already in moderate to severe COPD of which only one patient had ICS treatment (paper II). As one part of the changed mast cell subtype balance in the various investigated diseases depends on expansion in actual numbers of MC_{TC}, the altered balance is unlikely to solely be a ICS effect and should therefore be regarded as an important feature of COPD, CF and IPF pathology. When discussing potential drug effects on mast cells in non-allergic and allergic disease it should be noted that it is not entirely obvious whether anti-mast cell effects is solely beneficial. The potential effects of current and emerging drugs on lung mast cells should thus be explored with regard to both the destructive and pro-inflammatory capacity of mast cells as well as their potential beneficial role in innate immunity and host defence mechanisms.

Microenvironment and mast cell heterogeneity

Our discovery of site-specific mast cell subtypes under healthy conditions (paper I) supports the idea of microlocalisation as a determinant in creating differential phenotypes of infiltrating cells [90]. Indeed, both the airways and pulmonary vessels contain sub-anatomical compartments such as smooth muscle bundles and epithelial/endothelial regions that may differentially attract mast cells and/or alter mast cell behaviour [76 89 92 174 175]. Hence, the fact that pulmonary vessels, conducting airways and alveoli contain different proportions and types of structural cells may in part explain the present novel site-specific mast cell populations. Alterations in mast cell distribution in the airway wall have been described in asthma, with increases in mast cell numbers in the epithelial and smooth muscle layer[91 92]. Infiltration of mast cells in specific airway layers in smokers with and without chronic bronchitis, and COPD [35 176-178] has also been reported. This is likely to have several functional consequences. In our study we describe an increased proportion of both MC_T and MC_{TC} in the inner layers (epithelium and lamina propria) of small airways in very severe COPD, a compartment where the mast cells are most likely to interact with for example pathogens and regulate an immune response as a response to an increased inflammatory process in these airway layers (paper II). In uncontrolled atopic asthma, we found an increase of MC_{TC} in the smooth muscle layer compared to controls. This goes in line with previous studies, and further indicates that mast cell alterations are present in structures important for the disease pathology.

Mast cell expression patterns in health and disease

Apart from the classical staining for tryptase and chymase, the mast cells in paper I was assessed for expression of a variety of other mast cell-related molecules. By this approach we could demonstrate several statistically significant differences within each of the MC_T and MC_{TC} subtypes, but also between the different compartments of the lung. The most interesting observation was the reduced expression of FcεRI and increased renin expression in the alveolar region, which will be further discussed below. Mast cells express numerous pro-inflammatory molecules and are traditionally considered to be part of harmful inflammatory processes. In paper II, the MC_{TC} population in COPD displayed an increase in expression of the pro-fibrotic molecule TGF-β. As in COPD, the expanded MC_{TC} population showed high expression of TGF-β in all compartments in lungs from patients with CF and IPF (paper III). The expression also correlated to the degree of fibrosis and patients lung function. The importance of TGF-β as a fibrotic agent in the lung has been widely demonstrated[179 180] and an increased expression of TGF-β has been shown in tissue remodelling in CF[181] and IPF[53]. In mice and rat lungs a severe fibrotic response develops in the lung after induction of active TGF-β[182 183], when expressed in the airways stimulates fibroblasts to produce extracellular matrix proteins[180 184]. This suggests important interactions between mast cells and fibroblasts, leading to remodelling and fibrosis and implicates that MC_{TC} derived TGF-β plays an important role in this process. The anaphylatoxin receptor C5aR (CD88) was signifi-

cantly increased in all lung compartments in COPD (paper II). CD88 was used as a general marker of mast cell activation, and the increase indicates that the mast cells in COPD have acquired a more pro-inflammatory phenotype. IL-6 is a multifunctional regulator of immune and inflammatory processes[185] and is a potent chemo-attractant for neutrophils. The pro-inflammatory cytokine IL-6 was selected as an indicator of an "inflammatory" mast cell phenotype in paper III. In CF lungs, both MC_T and MC_{TC} populations show elevated expression of IL-6 in all compartments investigated. The lower expression of IL-6 in IPF could indicate less active inflammation and lack of bacterial infections. Similarly, in CF the elevated IL-6 expression in less affected regions suggests that mast cell activation in this disease may take place early in the pathogenesis. In support of this, based on findings of increased lung mast cell numbers already in CF foetuses, it has been speculated that mast cells may participate even in the initiation of the inflammation and the lung histopathology changes seen in CF[186]. However, the role of mast cells can be both pro- and anti-inflammatory[187]. The MC_{TC} population had particularly high levels of renin in healthy conditions, a key hormone in vascular homeostasis recently identified in mast cells[188]. Together with the capacity of chymase to act as an angiotensin converting enzyme and angiotensin II activator, this suggests a role for MC_{TC} in lung vascular regulation with potential implications in disease. Also histamine and serotonin have blood flow modulating capacities[189 190] and this further underscores the potential of mast cells in vascular regulation of the lungs.

The role of alveolar mast cells in diseased lung

Previous studies have shown an increase in mast cell density in small airways compared to bronchi[32 76]. Much less is known regarding mast cells in the alveolar compartment. Interestingly, in the studies in this thesis, the alveolar lung parenchyma was the most mast cell-rich compartment. Balzar *et al.* reported low levels of IgE-bearing mast cells in the alveolar tissue of asthmatics and healthy controls[191] which suggests a reduced capacity for classical anaphylactic degranulation and IgE mediated activation among alveolar mast cells. It seems rational to have mechanisms for local down regulation of FcεRI[192] and thus prevent an anaphylactic degranulation in the sensitive alveolar regions. Effects of classical degranulation like plasma extravasation would be a catastrophic event in the alveoli. The finding of low FcεRI expression on alveolar mast cells in healthy conditions is in agreement with previous reports. Alveolar mast cells might therefore under normal conditions be regulated by non-IgE mast cell triggers such as C5aR, CD30L etc.[118 193]. The finding of increased expression of FcεRI in the alveolar parenchyma in patients with mild and uncontrolled asthmatics (paper IV and V) was therefore surprising and intriguing. Since this phenomenon could not be found in non-allergic diseases (COPD, CF and IPF) as well as in AR, the FcεRI high expressing mast cell phenotype in alveolar parenchyma might be specific for asthma. Highly statistical increases of surface-bound IgE on mast cells in both central airways and the alveolar parenchyma were also demonstrated in mild and uncontrolled asthmatics. The consequences of IgE-mediated mast cell activation in the alveoli are however unknown, but from the known

range of pro-inflammatory effects caused by mast cell-derived mediators[194-196], these effects should be expected to be significant and multifaceted. Irrespective of activation mechanism, alveolar mast cells are likely to have a variety of roles ranging from regulation of blood flow, a notion supported by the present high renin content in alveolar mast cells, to participation in the many new functions recently ascribed to mast cells, ranging from immune modulators, effector cells in innate immunity to pro-fibrotic cells[129 133 197 198] (see above).

A major prerequisite for induction of IgE-mediated alveolar mast cell activation is the possibility for allergens to reach the alveolar parenchyma. Although most of the inhaled allergens are deposited in the conducting airways, common allergens may well be transported by respirable particles all the way to the alveolar region[199-201]. If high FcεRI and IgE-expressing alveolar mast cells are present in additional asthma cohorts needs to be further investigated. Anti-IgE therapy, Omalizumab (Xolair®), was developed on the basis of the proposed IgE-driven allergic inflammation in the conducting airways[202-204]. As expected, Omalizumab down-regulate both IgE and FcεRI-bearing mast cells in asthmatic bronchi[18 19]. Future studies are now needed to investigate if anti-IgE therapy yields similar effects in the alveolar compartment.

Study design: advantages and disadvantages

The novel mast cell heterogeneity presented in this thesis has several practical implications. In agreement with previous studies[14 76 92] this report shows that quantification of lung mast cells in disease without proper information of anatomical location or subtype may be misleading; a certain subtype in one location may display increased numbers and/or activation whereas the situation may be reversed in neighbouring areas. An additional aspect is the complexity in assessing lung-derived mast cells *ex vivo.* From our data it can be expected that purification of mast cells from lung homogenates yield a mixture of several populations with potentially different propensity to survive and get activated *ex viv*o. This type of heterogeneity may account for the many previously reported discrepancies in functionality among lung-derived mast cells. In this context knowledge about the present site-specific heterogeneity may be helpful if lung mast cells were instead purified from dissected well-defined compartments of the lung[193]. In the majority of the studies included in this thesis we used large and multiple sections that contained all anatomical compartments from large patient groups (transplantation material and surgical resections). This made it possible to perform comparisons of mast cells, not only between health and disease, but also between compartments within each section. This also guaranteed that our comparison of mast cell parameters and molecular expression in the different anatomical regions was subjected to exactly the same immunohistochemical conditions. Lung tissue samples obtained during surgery for lung cancer are commonly used to assess lung diseases like COPD as well as collecting tissue from control subjects. Nevertheless this approach call for some cautiousness since the influence of cancer tumours on the neighbouring mast cells is hard to rule out. To minimize the risk of any influence of the cancer we only included patients with well-

delineated tumours and our samples were collected as far as possible from the tumour. To compensate for this uncertainty we also used a very unique tissue material, bronchial as well as transbronchial biopsies, from healthy young subjects without cancer diagnosis. This method was also used to study patients with mild and uncontrolled asthma and AR. To compensate for the small tissue volume obtained by this method multiple biopsies (>10 per patients) were taken.

Conclusions and Summary

The following conclusions can be drawn based on the results in this thesis:

- Extensive mast cell heterogeneity in the human lung is evident even at healthy baseline conditions. We conclude that the prevailing MC_T and MC_{TC} populations can be further divided into site-specific subpopulations dependent on the local microenvironment. Especially the alveolar mast cell population, with low expression of the high affinity receptor for IgE, stands out as a new hitherto unknown mast cell phenotype.

- Mast cell alterations are prominent features of non-allergic chronic inflammatory disorders of the lung. For example, in COPD, an increased proportion of MC_{TC} with increased expression of pro-inflammatory mediators were found. Several mast cell alterations in COPD correlated to patient lung function values.

- In fibrotic lung diseases, such as CF and IPF, the density of MC_{TC} was increased. This alteration, as well as mast cell expression of pro-fibrotic molecules, was particularly prominent in the remodelled alveolar parenchyma and correlated to patient lung function and to the degree of tissue fibrosis.

- Atopic asthma patients with persistent symptoms despite ICS therapy show expanded MC_T and MC_{TC} populations in the alveolar parenchyma. These populations have a significantly increased expression of FcεRI and surface-bound IgE. Apart from advancing the concept of a distal airway inflammation in asthma, this observation provides important indications regarding how to improve treatment strategies for uncontrolled asthma. The phenomenon of increased FcεRI expression on alveolar mast cells might be specific to atopic asthma since we could detect similar changes in mild asthma, but not in patients with allergic rhinitis, CF and COPD.

Table 2. Disease alterations in mast cell parameters relative to control subjects

Inflammatory respiratory disease	COPD n = 25	CF n = 5	IPF n = 7	Uncrtl. asthma n= 14	Mild asthma n = 8	Allergic rhinitis n = 8+8
Bronchi						
MC_T	↓			↓	→	→
MC_{TC}	↑			↑	→	→
Expression pattern	FcεRI →	FcεRI →		FcεRI → IgE ↑	FcεRI → IgE ↑	FcεRI → IgE →
Bronchioles						
MC_T	↓	↓	↓			
MC_{TC}	↑	→	↑			
Expression pattern	TGF-β ↑ CD88 ↑ Renin ↓	TGF-β ↑ IL-6 ↑	TGF-β ↑ IL-6 →			
Alveolar parenchyma						
MC_T	↓	↑	↑	↑	→	→
MC_{TC}	↑	↑	↑	↑	→	→
Expression pattern	FcεRI → TGF-β ↑ CD88 ↑ Renin ↓	FcεRI → TGF-β ↑ IL-6 ↑	FcεRI → TGF-β ↑ IL-6 →	FcεRI ↑ IgE ↑	FcεRI ↑ IgE ↑	FcεRI → IgE →
Pulmonary vessels						
MC_T	↓	↓	↓			
MC_{TC}	↓	↓	→			
Expression pattern	TGF-β ↑ CD88 ↑ Renin ↓	TGF-β ↑ IL-6 ↑	TGF-β ↑ IL-6 →			

n = number of patients. Unctrl = uncontrolled according to ACT score.

Future Perspective

The present thesis shed light upon new roles for mast cells in inflammatory airway diseases as well as the importance of studying mast cells directly in human diseased lung tissue. The present work also underscores the fact that more research is needed to understand the true nature of human lung mast cell populations under disease-relevant *in vivo* conditions. Indeed, the present thesis has identified some remaining fundamental questions that now await further investigations.

Biological and pathological roles of alveolar mast cells in health and disease

Today very little is known regarding the role of alveolar mast cells, in healthy conditions or in disease. Further characterisation of these cells is necessary, concerning heterogeneity, molecular expression patterns and function. Research needs to be done in finding the role and activation mechanisms for alveolar mast cells in healthy conditions. Means of studying alveolar mast cell function need to be investigated and evaluated in *in vitro*, explant and animal models. Very little knowledge exists about the peripheral inflammation in asthma and the role of mast cells. Although the present thesis shows an altered alveolar mast cell phenotype, possibly activated by IgE, these mast cells need to be further characterised by their expression pattern of leukotrienes, prostaglandins and cytokines. Also analyses of the activation status of these cells (whole mount studies of activation and degranulation status on and of season) seem warranted. More knowledge about how to target the alveolar mast cell population with today's available (or future) therapy is necessary. How anti-IgE treatment affects alveolar mast cells and the expression of FcεRI seems to be an important future research area.

The role of mast cells in airway infections

Chronic colonisation of bacteria and viruses are part of the pathological picture in both asthma, COPD and CF. To study how mast cell populations are affected by viruses in the human lung are important for understanding the role of mast cells in the above mentioned conditions. Through collaborations, we have access to tissue material from 22 children who have died from respiratory syncytial-, adeno- and influenza viral infections. The phenotype of these mast cells, with regard to expression of pro- and anti-inflammatory mediators as well as expression of toll-like receptors will be examined.

Translating *in vitro* findings into *in vivo* contexts

The finding of extensive mast cell heterogeneity in this thesis raises important questions regarding the possible translation of *in vitro* findings into *in vivo* settings. A future challenge is to find equivalents of mast cell lines in different human lung compartments in both healthy and diseased conditions.

Populärvetenskaplig sammanfattning på svenska

Mastcellen är en cell som ingår i immunförsvaret och finns i hela kroppen men är speciellt många i organ som har kontakt med den yttre miljön, så som lungor, hud och mag-tarmkanal. Mastceller har länge varit förknippade med de skadliga effekter som observerats i allergiska överkänslighetsreaktioner, och mastceller kan producera och utsöndra ämnen som ger upphov till typiska allergisymptom vid luftvägsallergi så som andnöd, hosta, nysningar, klåda, svullnad och rinnsnuva. Mindre kunskap finns om vilken roll mastceller har i andra, icke-allergiska sjukdomar. Många av mastcellens ämnen ligger lagrade i ett stort antal kapslar inuti cellen och kan snabbt utsöndras när mastcellen aktiveras. Det finns, traditionellt sett, två olika subtyper av mastceller; slemhinnemastceller (MC_T) och bindvävsmastceller (MC_{TC}). Dessa subtyper skiljer sig åt i vilka ämnen de innehåller och i sin distribution i kroppen. Mastcellen är en evolutionärt sett en mycket gammal cell och eftersom de inte förändrats mycket genom evolutionen och finns i stort antal även hos friska människor tyder detta på en viktig roll i immunförsvaret. Mastceller av bindvävstypen har, exempelvis, påvisats hos sjöpung, ett djur som är 500 miljoner år äldre än människan, långt innan det specifika immunförsvaret utvecklades. Eftersom mastceller, till skillnad från många andra celler i immunförsvaret, endast mognar i vävnaden bestäms deras slutgiltiga egenskap (fenotyp) av den lokala vävnadsmiljön. Detta leder till att mastceller är mycket heterogena, vilket gör det svårt att studera dem. Mastcellspopulationerna skiljer sig också åt mellan djur och människa, bland annat saknar möss och råttor mastceller långt ut i lungan, ett område med mycket högt antal mastceller i människa.

I denna avhandling studeras därför mastcellernas lokalisering, heterogenitet och uttryck av ämnen enbart i vävnad från människor som lider av olika allergiska och icke-allergiska lungsjukdomar. För att studera detta användes flera olika histologiska och immunohistokemiska metoder som utnyttjar cellens kemiska egenskaper eller antikroppar som känner igen specifika proteiner för att på tunna vävnadssnitt färga in mastceller. Bland annat studerades deras utseende (morfologi), vad de uttrycker för ämnen och receptorer samt den sjuka vävnaden i vilken de befinner sig i.

Eftersom mycket lite är känt om mastcellernas heterogenitet i friska lungor, studerades detta i delarbete I. Vi fann bland annat att mastcellspopulationen kan ytterligare delas in fler subtyper än MC_T och MC_{TC}, beroende på deras förekomst i små och stora luftvägar, lungans kärl samt lungblåsorna (alveolärt parenkym). Ett huvudfynd i denna studie var att den alveolära mastcellspopulationen skiljer sig markant från de övriga. Bland annat saknar denna typ av mastcell receptorn för IgE, en antikropp som aktiverar

mastcellen i allergiska reaktioner. Det innebär att i alveolärt parenkym kan mastcellen inte aktiveras av allergen, och måste således ha en annan funktion. I delarbete II studerades hur dessa nya mastcellspopulationer förändrades i samband med den inflammation som ses vid olika svårighetsgrader av kroniskt obstruktiv lungsjukdom (KOL) som orsakas av rökning. Vi fann att andelen bindvävsmastceller, som normalt är mycket få, ökar med ökad svårighetsgrad av KOL. Också mastcellernas uttryck av inflammatoriska ämnen ökade. I delarbete III studerades mastceller i två olika lungsjukdomar, som karakteriseras av massiv inlagring av bindväv i lungan. Också här ökade antalet bindvävsmastceller dramatiskt. Denna ökning sammanföll med graden av fibros i lungan, patienternas lungfunktion samt mastcellernas uttryck av ämnen viktiga för fibrosutvecklingen. Trots att allergisk astma är en av de vanligaste kroniska sjukdomarna vet man mycket lite om vad som händer i de perifera delarna av lungan samt vad som gör att en stor andel av patienterna inte svarar på dagens behandling. I delarbeten IV och V studerades därför de alveolära mastcellerna i patienter med mild och svårbehandlad astma och patienter med hösnuva. Huvudfyndet i dessa studier var att de alveolära mastcellerna, som normalt inte uttrycker IgE receptorn, uppvisar ett markant ökat uttryck av IgE receptorn hos patienter med mild och svårbehandlad astma, men inte hos patienter med allergisk hösnuva. Detta innebär att mastceller, som hos friska personer inte kan reagera ”allergiskt”, nu har den förmågan hos patienter med astma och det i ett område som normalt inte nås av dagens allergibehandling.

Slutsatserna i denna avhandling är att mastcellernas heterogenitet är utbredd redan hos friska människor. Denna heterogenitet är viktig att studera för att kunna förstå vad som händer i sjuka tillstånd. Mastcellerna är förändrade i icke-allergiska lungsjukdomar som KOL och lungfibros. Ett kännetecken för allergiska astmatiker, men inte allergiska patienter med hösnuva, är ett ökat uttryck av IgE receptorn i alveolärt parenkym, något som är potentiellt viktigt för behandlingen av denna patient grupp. Sammantaget har denna avhandling identifierat en rad nya aspekter kring mastcellernas potentiella roll i friska lungor och i lungor från patienter med våra vanligaste luftvägssjukdomar. Denna nya kunskap kan förhoppningsvis stimulera till ny viktig forskning och i förlängningen bidra till förbättrad behandling vid alla de sjukdomar där mastcellerna tycks ha en betydande roll.

Acknowledgements

I wish to express my sincere gratitude to all who have contributed and supported me during my PhD studies. This thesis would not exist without the encouragement from numerous people, both inside and outside the lab. I would especially like to thank:

My main supervisor, **Jonas Erjefält**, for introducing and guiding me in the complex field of airway inflammation. For sharing your great scientific and practical knowledge and for your ability to look at things with fresh eyes, and for teaching me to see beyond what is known. Thank you for your invaluable support, and kindness, which have contributed to interesting and enjoyable years in your group. My co-supervisor, **Leif Bjermer**, for sharing your great clinical and pre-clinical knowledge. Thank you for your unlimited generosity and enthusiasm and for stimulating conversations and discussions. Thanks for letting me take part in the clinical research at the Dept. of Respiratory Medicine.

Karin Jansner, who has, from the very beginning, supported me with endless kindness and generosity. For patiently sharing your immense knowledge and experience in the field of histology. Karin, you have taught me everything I know in the lab, this thesis would not exist without you! **Britt-Marie Nilsson**, for your skilful experience in the field of electron microscopy and histology and for always being helpful, supportive and generous!

Present and former members of the Unit of Airway Inflammation: **Michiko Mori**, **Beata Olejnicka**, **Anders Bergqvist**, **Gediminas Smailys** and **Chris van Hove** for creating a good scientific environment and for interesting discussions. **Kristina Rydell-Törmänen** and **Lena Uller**, my colleagues and friends, for invaluable support and encouragement. **Katarina Danielson** for administrative support.

Ellen Tufvesson, my colleague and friend, for your endless scientific and personal support. Thanks for sharing your great clinical and pre-clinical knowledge, your honesty and for always finding the time to discuss and finding solutions. **Claes-Göran Löfdahl**, for sharing your excellent knowledge, and for your enthusiasm and encouragement. **Gunilla Westergren-Thorsson** and **Anders Malmström** for your passion for research, your kindness and for creating a good, stimulating scientific environment. **Oskar Hermansson**, for your support and for making every day in the lab enjoyable. **Annika Andersson-Sjöland** and **Oskar Hallgren** for your infinite encouragement and fun discussions. **David Aronsson**, for fun and stimulating discussions about science and life.

A sincere thanks to all who have been involved in the clinical studies. **Louise Qvist**, **Anna Sikesjö**, **Mette Solum**, **Johan Olsson**, **Jonas Olsson** in the ARINI study.

Magnus Dahlbäck, **Leif Eriksson** with collaborators in the transplantation team at AstraZeneca.

All collaborators at **MedImmune** for fruitful discussions regarding mast cell biology. Thanks to **Thais Mauad**, São Paulo University and **Moises Selman** and **Annie Pardo**, Mexico, for productive collaborations.

Present and former members at BMC D12: Maria, Kristian, Lizbet, Anna, Calle, Lena T, Marie, Anna-Karin, Sara, Emil, AnnKatrin, Angelica, Jenny, Irma, Yulie, Linnea, Yulia, Karl Swärd and group members, Bengt Olof Nilsson and group members, Per Hellstrand and group members, David Erlinge and group members, Roland Andersson and group members, Lo Persson, Ingemar Carlstedt, the veterinaries and everyone else at D12! Thank you for your support and for making my PhD studies enjoyable!

Former members at BMC F10: Eva Ekblad and group members, Frank Sundler and group members, Anna Themner-Persson and Doris Persson: Thank you for your support. **Martin Nyström** and **LRI** for making computers and technique function! Big thanks to **Elin Sand**, my ex-roomie for all your encouragement, being my only mast cell buddy in Lund, for taking good care of me when I was new and confused and for all late nights in the lab with the stereo at top volume!

Members of the LURN Journal Club: Thank you for all the scientific and perhaps less scientific discussions! Thanks to Pernilla Glader, Amelie Plymouth and Lisa Alenmyr.

All members and participants at LURN: Thanks for interesting meetings with excellent scientific presentations and discussions and for creating a cheerful atmosphere.

Sincere thanks to all participants and members of **MaCNet** and it's organiser **Gunnar Nilsson**, for creating excellent mast cell meetings with an enjoyable atmosphere.

All my friends for your support outside the lab. Without you I would have perished! To **Katrin**, **Emma** and **Helena** for your encouragement and all the funny moments, dinners and shopping sprees in Copenhagen. **Emy** for your endless support and for always making me laugh. **Caroline**, it has been invaluable to have someone who understands and to share this experience with. **Catharina** and **Carolina,** for making the University studies much more fun. **Linn,** who has been my close friend literally all my life.

My relatives for your love and encouragement. Till Clara och Ella för att ni alltid får mig att bli glad och till min morfar, Arvid, som är den klokaste person jag känner.

My family for your endless support and unfailing love. You have given me the confidence to start this journey and the strength to finish it. To my father, Per, for inspiring me to choose this path and for your guidance and support in difficult scientific situations. To my mother, Brita, for guiding and supporting me in everything that is not science and for always being there for me. To my brother, Mikael for constantly making me realise what is important in life.

This study was supported by grants from the Heart and Lung Foundation, Sweden, the Swedish Medical Research Council, Swedish Asthma and Allergy Association's Research Foundation, the Crafoord Foundation and the Royal Physiographic Society in Lund.

References

1. Ward PA, Gilroy DW, Karp CL. Part I. The inflammatory response - an overview. In: Serhan CN, Ward PA, Gilroy DW, editors. *Fundamentals of inflammation*. New York: Cambridge University press, 2010:1-37.
2. Medzhitov R. Origin and physiological roles of inflammation. *Nature* 2008;454(7203):428-35.
3. O'Byrne P M, Postma DS. The many faces of airway inflammation. Asthma and chronic obstructive pulmonary disease. Asthma Research Group. *Am J Respir Crit Care Med* 1999;159(5 Pt 2):S41-63.
4. Wold Health Organization, www.who.int (retrieved at 2010-11-21).
5. Wenzel SE. Asthma: defining of the persistent adult phenotypes. *Lancet* 2006;368(9537):804-13.
6. Holgate ST. Airway inflammation and remodeling in asthma: current concepts. *Mol Biotechnol* 2002;22(2):179-89.
7. O'Byrne P, M., Postma DS. The many faces of airway inflammation. Asthma and chronic obstructive pulmonary disease. Asthma Research Group. *Am J Respir Crit Care Med* 1999;159(5 Pt 2):S41-63.
8. Tillie-Leblond I, Gosset P, Tonnel AB. Inflammatory events in severe acute asthma. *Allergy* 2005;60(1):23-9.
9. Bosse Y, Pare PD, Seow CY. Airway wall remodeling in asthma: from the epithelial layer to the adventitia. *Curr Allergy Asthma Rep* 2008;8(4):357-66.
10. James AL, Maxwell PS, Pearce-Pinto G, Elliot JG, Carroll NG. The relationship of reticular basement membrane thickness to airway wall remodeling in asthma. *Am J Respir Crit Care Med* 2002;166(12 Pt 1):1590-5.
11. Tashkin DP. The role of small airway inflammation in asthma. *Allergy Asthma Proc* 2002;23(4):233-42.
12. Carroll N, Cooke C, James A. The distribution of eosinophils and lymphocytes in the large and small airways of asthmatics. *Eur Respir J* 1997;10(2):292-300.
13. Carroll N, Elliot J, Morton A, James A. The structure of large and small airways in nonfatal and fatal asthma. *Am Rev Respir Dis* 1993;147(2):405-10.
14. Balzar S, Chu HW, Strand M, Wenzel S. Relationship of small airway chymase-positive mast cells and lung function in severe asthma. *Am J Respir Crit Care Med* 2005;171(5):431-9.
15. Hamid Q, Song Y, Kotsimbos TC, Minshall E, Bai TR, Hegele RG, et al. Inflammation of small airways in asthma. *J Allergy Clin Immunol* 1997;100(1):44-51.
16. Kraft M, Djukanovic R, Wilson S, Holgate ST, Martin RJ. Alveolar tissue inflammation in asthma. *Am J Respir Crit Care Med* 1996;154(5):1505-10.
17. Fabbri L, Peters SP, Pavord I, Wenzel SE, Lazarus SC, Macnee W, et al. Allergic rhinitis, asthma, airway biology, and chronic obstructive pulmonary disease in AJRCCM in 2004. *Am J Respir Crit Care Med* 2005;171(7):686-98.
18. Bousquet J, Cabrera P, Berkman N, Buhl R, Holgate S, Wenzel S, et al. The effect of treatment with omalizumab, an anti-IgE antibody, on asthma exacerbations and emergency medical visits in patients with severe persistent asthma. *Allergy* 2005;60(3):302-8.
19. Holgate S, Casale T, Wenzel S, Bousquet J, Deniz Y, Reisner C. The anti-inflammatory effects of omalizumab confirm the central role of IgE in allergic inflammation. *J Allergy Clin Immunol* 2005;115(3):459-65.
20. Konno A, Togawa K. Role of the vidian nerve in nasal allergy. *Ann Otol Rhinol Laryngol* 1979;88(2 Pt 1):258-66.
21. Konno A, Togawa K, Nishihira S. Participation of vascular reflex in mucosal swelling in nasal allergy. *Acta Otolaryngol* 1982;94(1-2):131-40.
22. Okuda M, Mygind N. *Pathophysiological basis for topical steroid treatment in the nose. In Topical steroid treatment for Asthma and Rhinitis.* London: Ballie're Tindall, 1980.

23. Leynaert B, Neukirch C, Kony S, Guenegou A, Bousquet J, Aubier M, et al. Association between asthma and rhinitis according to atopic sensitization in a population-based study. *J Allergy Clin Immunol* 2004;113(1):86-93.
24. Alvarez MJ, Olaguibel JM, Garcia BE, Rodriquez A, Tabar AI, Urbiola E. Airway inflammation in asthma and perennial allergic rhinitis. Relationship with nonspecific bronchial responsiveness and maximal airway narrowing. *Allergy* 2000;55(4):355-62.
25. Bachert C, Vignola AM, Gevaert P, Leynaert B, Van Cauwenberge P, Bousquet J. Allergic rhinitis, rhinosinusitis, and asthma: one airway disease. *Immunol Allergy Clin North Am* 2004;24(1):19-43.
26. Brown JL, Behndig AF, Sekerel BE, Pourazar J, Blomberg A, Kelly FJ, et al. Lower airways inflammation in allergic rhinitics: a comparison with asthmatics and normal controls. *Clin Exp Allergy* 2007;37(5):688-95.
27. Djukanovic R, Wilson JW, Britten KM, Wilson SJ, Walls AF, Roche WR, et al. Quantitation of mast cells and eosinophils in the bronchial mucosa of symptomatic atopic asthmatics and healthy control subjects using immunohistochemistry. *Am Rev Respir Dis* 1990;142(4):863-71.
28. Kirby JG, Hargreave FE, Gleich GJ, O'Byrne PM. Bronchoalveolar cell profiles of asthmatic and nonasthmatic subjects. *Am Rev Respir Dis* 1987;136(2):379-83.
29. Beasley R, Roche WR, Roberts JA, Holgate ST. Cellular events in the bronchi in mild asthma and after bronchial provocation. *Am Rev Respir Dis* 1989;139(3):806-17.
30. Sommerhoff CP, Caughey GH, Finkbeiner WE, Lazarus SC, Basbaum CB, Nadel JA. Mast cell chymase. A potent secretagogue for airway gland serous cells. *J Immunol* 1989;142(7):2450-6.
31. Pauwels RA, Buist AS, Calverley PM, Jenkins CR, Hurd SS. Global strategy for the diagnosis, management, and prevention of chronic obstructive pulmonary disease. NHLBI/WHO Global Initiative for Chronic Obstructive Lung Disease (GOLD) Workshop summary. *Am J Respir Crit Care Med* 2001;163(5):1256-76.
32. Battaglia S, Mauad T, van Schadewijk AM, Vignola AM, Rabe KF, Bellia V, et al. Differential distribution of inflammatory cells in large and small airways in smokers. *J Clin Pathol* 2007;60(8):907-11.
33. Peinado VI, Barbera JA, Abate P, Ramirez J, Roca J, Santos S, et al. Inflammatory reaction in pulmonary muscular arteries of patients with mild chronic obstructive pulmonary disease. *Am J Respir Crit Care Med* 1999;159(5 Pt 1):1605-11.
34. Hogg JC, Chu F, Utokaparch S, Woods R, Elliott WM, Buzatu L, et al. The nature of small-airway obstruction in chronic obstructive pulmonary disease. *N Engl J Med* 2004;350(26):2645-53.
35. Saetta M. Airway inflammation in chronic obstructive pulmonary disease. *Am J Respir Crit Care Med* 1999;160(5 Pt 2):S17-20.
36. Mc Lean KH. The pathogenesis of pulmonary emphysema. *Am J Med* 1958;25(1):62-74.
37. Sturton G, Persson C, Barnes PJ. Small airways: an important but neglected target in the treatment of obstructive airway diseases. *Trends Pharmacol Sci* 2008;29(7):340-5.
38. Barnes PJ. Immunology of asthma and chronic obstructive pulmonary disease. *Nat Rev Immunol* 2008;8(3):183-92.
39. Sutherland ER, Martin RJ. Airway inflammation in chronic obstructive pulmonary disease: comparisons with asthma. *J Allergy Clin Immunol* 2003;112(5):819-27; quiz 28.
40. Cosio MG, Guerassimov A. Chronic obstructive pulmonary disease. Inflammation of small airways and lung parenchyma. *Am J Respir Crit Care Med* 1999;160(5 Pt 2):S21-5.
41. Davis PB, Drumm M, Konstan MW. Cystic fibrosis. *Am J Respir Crit Care Med* 1996;154(5):1229-56.
42. De Boeck K, Wilschanski M, Castellani C, Taylor C, Cuppens H, Dodge J, et al. Cystic fibrosis: terminology and diagnostic algorithms. *Thorax* 2006;61(7):627-35.
43. Ratjen FA. Cystic fibrosis: pathogenesis and future treatment strategies. *Respir Care* 2009;54(5):595-605.
44. Heijerman H. Infection and inflammation in cystic fibrosis: a short review. *J Cyst Fibros* 2005;4 Suppl 2:3-5.
45. Elizur A, Cannon CL, Ferkol TW. Airway inflammation in cystic fibrosis. *Chest* 2008;133(2):489-95.
46. Rowe SM, Miller S, Sorscher EJ. Cystic fibrosis. *N Engl J Med* 2005;352(19):1992-2001.
47. Hilliard TN, Regamey N, Shute JK, Nicholson AG, Alton EW, Bush A, et al. Airway remodelling in children with cystic fibrosis. *Thorax* 2007;62(12):1074-80.

48. Bals R, Weiner DJ, Wilson JM. The innate immune system in cystic fibrosis lung disease. *J Clin Invest* 1999;103(3):303-7.
49. Ratjen F. Update in cystic fibrosis 2008. *Am J Respir Crit Care Med* 2009;179(6):445-8.
50. American Thoracic Society/European Respiratory Society International Multidisciplinary Consensus Classification of the Idiopathic Interstitial Pneumonias. This joint statement of the American Thoracic Society (ATS), and the European Respiratory Society (ERS) was adopted by the ATS board of directors, June 2001 and by the ERS Executive Committee, June 2001. *Am J Respir Crit Care Med* 2002;165(2):277-304.
51. Meltzer EB, Noble PW. Idiopathic pulmonary fibrosis. *Orphanet J Rare Dis* 2008;3:8.
52. du Bois RM. Idiopathic pulmonary fibrosis. *Annu Rev Med* 1993;44:441-50.
53. Khalil N, O'Connor R. Idiopathic pulmonary fibrosis: current understanding of the pathogenesis and the status of treatment. *CMAJ* 2004;171(2):153-60.
54. Katzenstein AL, Myers JL. Idiopathic pulmonary fibrosis: clinical relevance of pathologic classification. *Am J Respir Crit Care Med* 1998;157(4 Pt 1):1301-15.
55. Selman M, King TE, Pardo A. Idiopathic pulmonary fibrosis: prevailing and evolving hypotheses about its pathogenesis and implications for therapy. *Ann Intern Med* 2001;134(2):136-51.
56. Selman M, Pardo A. Role of epithelial cells in idiopathic pulmonary fibrosis: from innocent targets to serial killers. *Proc Am Thorac Soc* 2006;3(4):364-72.
57. Noble PW, Homer RJ. Idiopathic pulmonary fibrosis: new insights into pathogenesis. *Clin Chest Med* 2004;25(4):749-58, vii.
58. Selman M. Idiopathic pulmonary fibrosis challenges for the future. *Chest* 2001;120(1):8-10.
59. Busse WW, Lemanske RF, Jr., Gern JE. Role of viral respiratory infections in asthma and asthma exacerbations. *Lancet* 2010;376(9743):826-34.
60. See H, Wark P. Innate immune response to viral infection of the lungs. *Paediatr Respir Rev* 2008;9(4):243-50.
61. Contoli M, Bousquet J, Fabbri LM, Magnussen H, Rabe KF, Siafakas NM, et al. The small airways and distal lung compartment in asthma and COPD: a time for reappraisal. *Allergy* 2010;65(2):141-51.
62. Oostveen E, MacLeod D, Lorino H, Farre R, Hantos Z, Desager K, et al. The forced oscillation technique in clinical practice: methodology, recommendations and future developments. *Eur Respir J* 2003;22(6):1026-41.
63. Strunk RC, Szefler SJ, Phillips BR, Zeiger RS, Chinchilli VM, Larsen G, et al. Relationship of exhaled nitric oxide to clinical and inflammatory markers of persistent asthma in children. *J Allergy Clin Immunol* 2003;112(5):883-92.
64. Tsoukias NM, George SC. A two-compartment model of pulmonary nitric oxide exchange dynamics. *J Appl Physiol* 1998;85(2):653-66.
65. Brightling CE. Clinical applications of induced sputum. *Chest* 2006;129(5):1344-8.
66. Walters EH, Gardiner PV. Bronchoalveolar lavage as a research tool. *Thorax* 1991;46(9):613-8.
67. Kraft M. Approach to the patient with respiratory disease. In: Goldman L, Ausiello D, editors. *Cecil Medicine*. Philadelphia: Saunders Elsevier, 2007.
68. Reynolds H. Respiratory structure and function: mechanisms and testing. In: Goldman L, Ausiello D, editors. *Cecil Medicine*. Philadelphia: Saunders Elsevier, 2007.
69. Vignola AM, Bousquet J, Chanez P, Gagliardo R, Merendino AM, Chiappara G, et al. Assessment of airway inflammation in asthma. *Am J Respir Crit Care Med* 1998;157(5 Pt 2):S184-7.
70. Baraldo S, Turato G, Badin C, Bazzan E, Beghe B, Zuin R, et al. Neutrophilic infiltration within the airway smooth muscle in patients with COPD. *Thorax* 2004;59(4):308-12.
71. Grashoff WF, Sont JK, Sterk PJ, Hiemstra PS, de Boer WI, Stolk J, et al. Chronic obstructive pulmonary disease: role of bronchiolar mast cells and macrophages. *Am J Pathol* 1997;151(6):1785-90.
72. Metcalfe DD, Baram D, Mekori YA. Mast cells. *Physiol Rev* 1997;77(4):1033-79.
73. Okayama Y, Kawakami T. Development, migration, and survival of mast cells. *Immunol Res* 2006;34(2):97-115.
74. Gurish MF, Boyce JA. Mast cell growth, differentiation, and death. *Clin Rev Allergy Immunol* 2002;22(2):107-18.
75. Bradding P, Walls AF, Holgate ST. The role of the mast cell in the pathophysiology of asthma. *J Allergy Clin Immunol* 2006;117(6):1277-84.

76. Carroll NG, Mutavdzic S, James AL. Distribution and degranulation of airway mast cells in normal and asthmatic subjects. *Eur Respir J* 2002;19(5):879-85.
77. Weidner N, Austen KF. Heterogeneity of mast cells at multiple body sites. Fluorescent determination of avidin binding and immunofluorescent determination of chymase, tryptase, and carboxypeptidase content. *Pathol Res Pract* 1993;189(2):156-62.
78. Marshall JS. Mast-cell responses to pathogens. *Nat Rev Immunol* 2004;4(10):787-99.
79. Stevens RL, Adachi R. Protease-proteoglycan complexes of mouse and human mast cells and importance of their beta-tryptase-heparin complexes in inflammation and innate immunity. *Immunol Rev* 2007;217:155-67.
80. Brockow K, Metcalfe DD. Mastocytosis. *Chem Immunol Allergy* 2010;95:110-24.
81. Abraham SN, St John AL. Mast cell-orchestrated immunity to pathogens. *Nat Rev Immunol* 2010;10(6):440-52.
82. Enerback L, Norrby K. The mast cells. *Curr Top Pathol* 1989;79:169-204.
83. Bradding P. Human lung mast cell heterogeneity. *Thorax* 2009;64(4):278-80.
84. Bradding P, Okayama Y, Howarth PH, Church MK, Holgate ST. Heterogeneity of human mast cells based on cytokine content. *J Immunol* 1995;155(1):297-307.
85. Okuda M. Functional heterogeneity of airway mast cells. *Allergy* 1999;54 Suppl 57:50-62.
86. Weidner N, Austen KF. Ultrastructural and immunohistochemical characterization of normal mast cells at multiple body sites. *J Invest Dermatol* 1991;96(3 Suppl):26S-30S; discussion 30S-31S, 60S-65S.
87. Dvorak AM. Human mast cells. *Adv Anat Embryol Cell Biol* 1989;114:1-107.
88. Dvorak AM. Ultrastructural studies of human basophils and mast cells. *J Histochem Cytochem* 2005;53(9):1043-70.
89. Hsieh FH, Sharma P, Gibbons A, Goggans T, Erzurum SC, Haque SJ. Human airway epithelial cell determinants of survival and functional phenotype for primary human mast cells. *Proc Natl Acad Sci U S A* 2005;102(40):14380-5.
90. Siddiqui S, Hollins F, Saha S, Brightling CE. Inflammatory cell microlocalisation and airway dysfunction: cause and effect? *Eur Respir J* 2007;30(6):1043-56.
91. Sanmugalingam D, Wardlaw AJ, Bradding P. Adhesion of human lung mast cells to bronchial epithelium: evidence for a novel carbohydrate-mediated mechanism. *J Leukoc Biol* 2000;68(1):38-46.
92. Brightling CE, Bradding P, Symon FA, Holgate ST, Wardlaw AJ, Pavord ID. Mast-cell infiltration of airway smooth muscle in asthma. *N Engl J Med* 2002;346(22):1699-705.
93. Brightling CE, Symon FA, Holgate ST, Wardlaw AJ, Pavord ID, Bradding P. Interleukin-4 and -13 expression is co-localized to mast cells within the airway smooth muscle in asthma. *Clin Exp Allergy* 2003;33(12):1711-6.
94. Bischoff SC. Role of mast cells in allergic and non-allergic immune responses: comparison of human and murine data. *Nat Rev Immunol* 2007;7(2):93-104.
95. Bischoff SC, Dahinden CA. c-kit ligand: a unique potentiator of mediator release by human lung mast cells. *J Exp Med* 1992;175(1):237-44.
96. Kirshenbaum AS, Kessler SW, Goff JP, Metcalfe DD. Demonstration of the origin of human mast cells from CD34+ bone marrow progenitor cells. *J Immunol* 1991;146(5):1410-5.
97. Toru H, Eguchi M, Matsumoto R, Yanagida M, Yata J, Nakahata T. Interleukin-4 promotes the development of tryptase and chymase double-positive human mast cells accompanied by cell maturation. *Blood* 1998;91(1):187-95.
98. Kearley J, Erjefalt JS, Andersson C, Benjamin E, Jones CP, Robichaud A, et al. IL-9 Governs Allergen-induced Mast Cell Numbers in the Lung and Chronic Remodeling of the Airways. *Am J Respir Crit Care Med* 2010.
99. Hallgren J, Gurish MF. Pathways of murine mast cell development and trafficking: tracking the roots and routes of the mast cell. *Immunol Rev* 2007;217:8-18.
100. Brightling CE, Bradding P, Pavord ID, Wardlaw AJ. New insights into the role of the mast cell in asthma. *Clin Exp Allergy* 2003;33(5):550-6.
101. Gould HJ, Sutton BJ. IgE in allergy and asthma today. *Nat Rev Immunol* 2008;8(3):205-17.
102. MacGlashan D, Jr. IgE and FcepsilonRI regulation. *Clin Rev Allergy Immunol* 2005;29(1):49-60.
103. Kraft S, Kinet JP. New developments in FcepsilonRI regulation, function and inhibition. *Nat Rev Immunol* 2007;7(5):365-78.

104. Kalesnikoff J, Huber M, Lam V, Damen JE, Zhang J, Siraganian RP, et al. Monomeric IgE stimulates signaling pathways in mast cells that lead to cytokine production and cell survival. *Immunity* 2001;14(6):801-11.
105. Gurish MF, Bryce PJ, Tao H, Kisselgof AB, Thornton EM, Miller HR, et al. IgE enhances parasite clearance and regulates mast cell responses in mice infected with Trichinella spiralis. *J Immunol* 2004;172(2):1139-45.
106. Henz BM, Maurer M, Lippert U, Worm M, Babina M. Mast cells as initiators of immunity and host defense. *Exp Dermatol* 2001;10(1):1-10.
107. Woolhiser MR, Okayama Y, Gilfillan AM, Metcalfe DD. IgG-dependent activation of human mast cells following up-regulation of FcgammaRI by IFN-gamma. *Eur J Immunol* 2001;31(11):3298-307.
108. Genovese A, Bouvet JP, Florio G, Lamparter-Schummert B, Bjorck L, Marone G. Bacterial immunoglobulin superantigen proteins A and L activate human heart mast cells by interacting with immunoglobulin E. *Infect Immun* 2000;68(10):5517-24.
109. Supajatura V, Ushio H, Nakao A, Akira S, Okumura K, Ra C, et al. Differential responses of mast cell Toll-like receptors 2 and 4 in allergy and innate immunity. *J Clin Invest* 2002;109(10):1351-9.
110. Supajatura V, Ushio H, Nakao A, Okumura K, Ra C, Ogawa H. Protective roles of mast cells against enterobacterial infection are mediated by Toll-like receptor 4. *J Immunol* 2001;167(4):2250-6.
111. McCurdy JD, Olynych TJ, Maher LH, Marshall JS. Cutting edge: distinct Toll-like receptor 2 activators selectively induce different classes of mediator production from human mast cells. *J Immunol* 2003;170(4):1625-9.
112. Varadaradjalou S, Feger F, Thieblemont N, Hamouda NB, Pleau JM, Dy M, et al. Toll-like receptor 2 (TLR2) and TLR4 differentially activate human mast cells. *Eur J Immunol* 2003;33(4):899-906.
113. Nilsson G, Johnell M, Hammer CH, Tiffany HL, Nilsson K, Metcalfe DD, et al. C3a and C5a are chemotaxins for human mast cells and act through distinct receptors via a pertussis toxin-sensitive signal transduction pathway. *J Immunol* 1996;157(4):1693-8.
114. el-Lati SG, Dahinden CA, Church MK. Complement peptides C3a- and C5a-induced mediator release from dissociated human skin mast cells. *J Invest Dermatol* 1994;102(5):803-6.
115. Johnson D, Krenger W. Interactions of mast cells with the nervous system--recent advances. *Neurochem Res* 1992;17(9):939-51.
116. Guhl S, Lee HH, Babina M, Henz BM, Zuberbier T. Evidence for a restricted rather than generalized stimulatory response of skin-derived human mast cells to substance P. *J Neuroimmunol* 2005;163(1-2):92-101.
117. Maurer M, Wedemeyer J, Metz M, Piliponsky AM, Weller K, Chatterjea D, et al. Mast cells promote homeostasis by limiting endothelin-1-induced toxicity. *Nature* 2004;432(7016):512-6.
118. Fischer M, Harvima IT, Carvalho RF, Moller C, Naukkarinen A, Enblad G, et al. Mast cell CD30 ligand is upregulated in cutaneous inflammation and mediates degranulation-independent chemokine secretion. *J Clin Invest* 2006;116(10):2748-56.
119. Boyce JA. Mast cells as sentinels of inflammation In: Serhan CN, Ward C, Gilroy DW, editors. *Fundamentals of inflammation*. New York: Cambridge University press, 2010:65-73.
120. Taube C, Wei X, Swasey CH, Joetham A, Zarini S, Lively T, et al. Mast cells, Fc epsilon RI, and IL-13 are required for development of airway hyperresponsiveness after aerosolized allergen exposure in the absence of adjuvant. *J Immunol* 2004;172(10):6398-406.
121. Echtenacher B, Mannel DN, Hultner L. Critical protective role of mast cells in a model of acute septic peritonitis. *Nature* 1996;381(6577):75-7.
122. Malaviya R, Ikeda T, Ross E, Abraham SN. Mast cell modulation of neutrophil influx and bacterial clearance at sites of infection through TNF-alpha. *Nature* 1996;381(6577):77-80.
123. Malaviya R, Gao Z, Thankavel K, van der Merwe PA, Abraham SN. The mast cell tumor necrosis factor alpha response to FimH-expressing Escherichia coli is mediated by the glycosylphosphatidylinositol-anchored molecule CD48. *Proc Natl Acad Sci U S A* 1999;96(14):8110-5.
124. Gommerman JL, Oh DY, Zhou X, Tedder TF, Maurer M, Galli SJ, et al. A role for CD21/CD35 and CD19 in responses to acute septic peritonitis: a potential mechanism for mast cell activation. *J Immunol* 2000;165(12):6915-21.

125. Di Nardo A, Vitiello A, Gallo RL. Cutting edge: mast cell antimicrobial activity is mediated by expression of cathelicidin antimicrobial peptide. *J Immunol* 2003;170(5):2274-8.
126. Orinska Z, Maurer M, Mirghomizadeh F, Bulanova E, Metz M, Nashkevich N, et al. IL-15 constrains mast cell-dependent antibacterial defenses by suppressing chymase activities. *Nat Med* 2007;13(8):927-34.
127. Castleman WL, Sorkness RL, Lemanske RF, Jr., McAllister PK. Viral bronchiolitis during early life induces increased numbers of bronchiolar mast cells and airway hyperresponsiveness. *Am J Pathol* 1990;137(4):821-31.
128. van Schaik SM, Tristram DA, Nagpal IS, Hintz KM, Welliver RC, 2nd, Welliver RC. Increased production of IFN-gamma and cysteinyl leukotrienes in virus-induced wheezing. *J Allergy Clin Immunol* 1999;103(4):630-6.
129. Metz M, Maurer M. Mast cells--key effector cells in immune responses. *Trends Immunol* 2007;28(5):234-41.
130. Orinska Z, Bulanova E, Budagian V, Metz M, Maurer M, Bulfone-Paus S. TLR3-induced activation of mast cells modulates CD8+ T-cell recruitment. *Blood* 2005;106(3):978-87.
131. Bannert N, Farzan M, Friend DS, Ochi H, Price KS, Sodroski J, et al. Human Mast cell progenitors can be infected by macrophagetropic human immunodeficiency virus type 1 and retain virus with maturation in vitro. *J Virol* 2001;75(22):10808-14.
132. Wedde-Beer K, Hu C, Rodriguez MM, Piedimonte G. Leukotrienes mediate neurogenic inflammation in lungs of young rats infected with respiratory syncytial virus. *Am J Physiol Lung Cell Mol Physiol* 2002;282(5):L1143-50.
133. Dawicki W, Marshall JS. New and emerging roles for mast cells in host defence. *Curr Opin Immunol* 2007;19(1):31-8.
134. Nilsson G, Costa J, Metcalfe D. *Mast cells and basophils*. 3rd edition ed. Philadelphia: Lippincott Williams and Wilkins, 1999.
135. Garbuzenko E, Berkman N, Puxeddu I, Kramer M, Nagler A, Levi-Schaffer F. Mast cells induce activation of human lung fibroblasts in vitro. *Exp Lung Res* 2004;30(8):705-21.
136. Levi-Schaffer F, Rubinchik E. Mast cell/fibroblast interactions. *Clin Exp Allergy* 1994;24(11):1016-21.
137. Rubinchik E, Levi-Schaffer F. Mast cells and fibroblasts: two interacting cells. *Int J Clin Lab Res* 1994;24(3):139-42.
138. Batlle M, Perez-Villa F, Lazaro A, Garcia-Pras E, Ramirez J, Ortiz J, et al. Correlation between mast cell density and myocardial fibrosis in congestive heart failure patients. *Transplant Proc* 2007;39(7):2347-9.
139. Ozbilgin MK, Inan S. The roles of transforming growth factor type beta3 (TGF-beta3) and mast cells in the pathogenesis of scleroderma. *Clin Rheumatol* 2003;22(3):189-95.
140. Henderson WR, Jr., Chi EY. Degranulation of cystic fibrosis nasal polyp mast cells. *J Pathol* 1992;166(4):395-404.
141. Hubeau C, Lorenzato M, Couetil JP, Hubert D, Dusser D, Puchelle E, et al. Quantitative analysis of inflammatory cells infiltrating the cystic fibrosis airway mucosa. *Clin Exp Immunol* 2001;124(1):69-76.
142. Fortoul TI, Barrios R. Mast cells and idiopathic lung fibrosis. *Arch Invest Med (Mex)* 1990;21(1):5-10.
143. Hunt LW, Colby TV, Weiler DA, Sur S, Butterfield JH. Immunofluorescent staining for mast cells in idiopathic pulmonary fibrosis: quantification and evidence for extracellular release of mast cell tryptase. *Mayo Clin Proc* 1992;67(10):941-8.
144. Pesci A, Bertorelli G, Gabrielli M, Olivieri D. Mast cells in fibrotic lung disorders. *Chest* 1993;103(4):989-96.
145. Hirata K, Sugama Y, Ikura Y, Ohsawa M, Inoue Y, Yamamoto S, et al. Enhanced mast cell chymase expression in human idiopathic interstitial pneumonia. *Int J Mol Med* 2007;19(4):565-70.
146. Tchougounova E, Lundequist A, Fajardo I, Winberg JO, Abrink M, Pejler G. A key role for mast cell chymase in the activation of pro-matrix metalloprotease-9 and pro-matrix metalloprotease-2. *J Biol Chem* 2005;280(10):9291-6.
147. McDermott JR, Bartram RE, Knight PA, Miller HR, Garrod DR, Grencis RK. Mast cells disrupt epithelial barrier function during enteric nematode infection. *Proc Natl Acad Sci U S A* 2003;100(13):7761-6.

148. Jawdat DM, Rowden G, Marshall JS. Mast cells have a pivotal role in TNF-independent lymph node hypertrophy and the mobilization of Langerhans cells in response to bacterial peptidoglycan. *J Immunol* 2006;177(3):1755-62.
149. Suto H, Nakae S, Kakurai M, Sedgwick JD, Tsai M, Galli SJ. Mast cell-associated TNF promotes dendritic cell migration. *J Immunol* 2006;176(7):4102-12.
150. Finkelstein R, Fraser RS, Ghezzo H, Cosio MG. Alveolar inflammation and its relation to emphysema in smokers. *Am J Respir Crit Care Med* 1995;152(5 Pt 1):1666-72.
151. Saetta M, Mariani M, Panina-Bordignon P, Turato G, Buonsanti C, Baraldo S, et al. Increased expression of the chemokine receptor CXCR3 and its ligand CXCL10 in peripheral airways of smokers with chronic obstructive pulmonary disease. *Am J Respir Crit Care Med* 2002;165(10):1404-9.
152. Farrell PM, Rosenstein BJ, White TB, Accurso FJ, Castellani C, Cutting GR, et al. Guidelines for diagnosis of cystic fibrosis in newborns through older adults: Cystic Fibrosis Foundation consensus report. *J Pediatr* 2008;153(2):S4-S14.
153. Bousquet J, Khaltaev N, Cruz AA, Denburg J, Fokkens WJ, Togias A, et al. Allergic Rhinitis and its Impact on Asthma (ARIA) 2008 update (in collaboration with the World Health Organization, GA(2)LEN and AllerGen). *Allergy* 2008;63 Suppl 86:8-160.
154. Global Initiative for asthma. GINA Report, Global Strategy for Asthma Management and Prevention. www.ginasthma.com, 2006.
155. Crapo RO, Morris AH, Gardner RM. Reference spirometric values using techniques and equipment that meet ATS recommendations. *Am Rev Respir Dis* 1981;123(6):659-64.
156. Tufvesson E, Aronsson D, Ankerst J, George SC, Bjermer L. Peripheral nitric oxide is increased in rhinitic patients with asthma compared to bronchial hyperresponsiveness. *Respir Med* 2007;101(11):2321-6.
157. Aronsson D, Tufvesson E, Ankerst J, Bjermer L. Allergic rhinitis with hyper-responsiveness differ from asthma in degree of peripheral obstruction during metacholine challenge test. *Clin Physiol Funct Imaging* 2008;28(2):81-5.
158. Erjefalt JS, Sundler F, Persson CG. Eosinophils, neutrophils, and venular gaps in the airway mucosa at epithelial removal-restitution. *Am J Respir Crit Care Med* 1996;153(5):1666-74.
159. Ashcroft T, Simpson JM, Timbrell V. Simple method of estimating severity of pulmonary fibrosis on a numerical scale. *J Clin Pathol* 1988;41(4):467-70.
160. Gavrieli Y, Sherman Y, Ben-Sasson SA. Identification of programmed cell death in situ via specific labeling of nuclear DNA fragmentation. *J Cell Biol* 1992;119(3):493-501.
161. Howard C, Reed M. Unbiased Stereology. *Advanced methods, Garland Science/BIOS Scientific Publishers, Second edition* 2005.
162. Forssell J, Sideras P, Eriksson C, Malm-Erjefalt M, Rydell-Tormanen K, Ericsson PO, et al. Interleukin-2-inducible T cell kinase regulates mast cell degranulation and acute allergic responses. *Am J Respir Cell Mol Biol* 2005;32(6):511-20.
163. Dvorak AM, Hammel I, Schulman ES, Peters SP, MacGlashan DW, Jr., Schleimer RP, et al. Differences in the behavior of cytoplasmic granules and lipid bodies during human lung mast cell degranulation. *J Cell Biol* 1984;99(5):1678-87.
164. Benjamini Y, Hochberg Y. Controlling the False Discovery Rate: A Practical and Powerful Approach to Multiple Testing. *Journal of the Royal Statistical Society. Series B (Methodological)* 1995;57(1):289-300.
165. Bienstock J. An update on mast cell heterogeniety*. *The journal of Allergy and Clinical Immunology* 1987;81(5):763-69.
166. Kitamura Y. Heterogeneity of mast cells and phenotypic change between subpopulations. *Annu Rev Immunol* 1989;7:59-76.
167. Irani AM, Schwartz LB. Human mast cell heterogeneity. *Allergy Proc* 1994;15(6):303-8.
168. Gosman MM, Postma DS, Vonk JM, Rutgers B, Lodewijk M, Smith M, et al. Association of mast cells with lung function in chronic obstructive pulmonary disease. *Respir Res* 2008;9(1):64.
169. Goto T, Befus D, Low R, Bienenstock J. Mast cell heterogeneity and hyperplasia in bleomycin-induced pulmonary fibrosis of rats. *Am Rev Respir Dis* 1984;130(5):797-802.
170. Hattotuwa KL, Gizycki MJ, Ansari TW, Jeffery PK, Barnes NC. The effects of inhaled fluticasone on airway inflammation in chronic obstructive pulmonary disease: a double-blind, placebo-controlled biopsy study. *Am J Respir Crit Care Med* 2002;165(12):1592-6.

171. Bentley AM, Hamid Q, Robinson DS, Schotman E, Meng Q, Assoufi B, et al. Prednisolone treatment in asthma. Reduction in the numbers of eosinophils, T cells, tryptase-only positive mast cells, and modulation of IL-4, IL-5, and interferon-gamma cytokine gene expression within the bronchial mucosa. *Am J Respir Crit Care Med* 1996;153(2):551-6.
172. Zanini A, Chetta A, Saetta M, Baraldo S, D'Ippolito R, Castagnaro A, et al. Chymase-positive mast cells play a role in the vascular component of airway remodeling in asthma. *J Allergy Clin Immunol* 2007;120(2):329-33.
173. Juliusson S, Aldenborg F, Enerback L. Proteinase content of mast cells of nasal mucosa; effects of natural allergen exposure and of local corticosteroid treatment. *Allergy* 1995;50(1):15-22.
174. Ammit AJ BS, Johnson PR, Hughes JM, Armour CL, Black JL. Mast cell numbers are increased in the smooth muscle of human sensitized isolated bronchi. *Am J Respir Crit Care Med* 1997;155:1123–29.
175. Ekberg-Jansson A, Amin K, Bake B, Rosengren A, Tylen U, Venge P, et al. Bronchial mucosal mast cells in asymptomatic smokers relation to structure, lung function and emphysema. *Respir Med* 2005;99(1):75-83.
176. Berger P, Laurent F, Begueret H, Perot V, Rouiller R, Raherison C, et al. Structure and function of small airways in smokers: relationship between air trapping at CT and airway inflammation. *Radiology* 2003;228(1):85-94.
177. Liesker JJ, Ten Hacken NH, Rutgers SR, Zeinstra-Smith M, Postma DS, Timens W. Mast cell numbers in airway smooth muscle and PC20AMP in asthma and COPD. *Respir Med* 2007;101(5):882-7.
178. Pesci A, Rossi GA, Bertorelli G, Aufiero A, Zanon P, Olivieri D. Mast cells in the airway lumen and bronchial mucosa of patients with chronic bronchitis. *Am J Respir Crit Care Med* 1994;149(5):1311-6.
179. Bartram U, Speer CP. The role of transforming growth factor beta in lung development and disease. *Chest* 2004;125(2):754-65.
180. Camoretti-Mercado B, Solway J. Transforming growth factor-beta1 and disorders of the lung. *Cell Biochem Biophys* 2005;43(1):131-48.
181. Wojnarowski C, Frischer T, Hofbauer E, Grabner C, Mosgoeller W, Eichler I, et al. Cytokine expression in bronchial biopsies of cystic fibrosis patients with and without acute exacerbation. *Eur Respir J* 1999;14(5):1136-44.
182. Ask K, Bonniaud P, Maass K, Eickelberg O, Margetts PJ, Warburton D, et al. Progressive pulmonary fibrosis is mediated by TGF-beta isoform 1 but not TGF-beta3. *Int J Biochem Cell Biol* 2008;40(3):484-95.
183. Sime PJ, Marr RA, Gauldie D, Xing Z, Hewlett BR, Graham FL, et al. Transfer of tumor necrosis factor-alpha to rat lung induces severe pulmonary inflammation and patchy interstitial fibrogenesis with induction of transforming growth factor-beta1 and myofibroblasts. *Am J Pathol* 1998;153(3):825-32.
184. Sheppard D. Transforming growth factor beta: a central modulator of pulmonary and airway inflammation and fibrosis. *Proc Am Thorac Soc* 2006;3(5):413-7.
185. Gabay C. Interleukin-6 and chronic inflammation. *Arthritis Res Ther* 2006;8 Suppl 2:S3.
186. Hubeau C, Puchelle E, Gaillard D. Distinct pattern of immune cell population in the lung of human fetuses with cystic fibrosis. *J Allergy Clin Immunol* 2001;108(4):524-9.
187. Caughey GH. Mast cell tryptases and chymases in inflammation and host defense. *Immunol Rev* 2007;217:141-54.
188. Veerappan A, Reid AC, Estephan R, O'Connor N, Thadani-Mulero M, Salazar-Rodriguez M, et al. Mast cell renin and a local renin-angiotensin system in the airway: role in bronchoconstriction. *Proc Natl Acad Sci U S A* 2008;105(4):1315-20.
189. Chetta A, Zanini A, Foresi A, D'Ippolito R, Tipa A, Castagnaro A, et al. Vascular endothelial growth factor up-regulation and bronchial wall remodelling in asthma. *Clin Exp Allergy* 2005;35(11):1437-42.
190. Ryan JJ, Kashyap M, Bailey D, Kennedy S, Speiran K, Brenzovich J, et al. Mast cell homeostasis: a fundamental aspect of allergic disease. *Crit Rev Immunol* 2007;27(1):15-32.
191. Balzar S, Strand M, Rhodes D, Wenzel SE. IgE expression pattern in lung: relation to systemic IgE and asthma phenotypes. *J Allergy Clin Immunol* 2007;119(4):855-62.

192. Kennedy Norton S, Barnstein B, Brenzovich J, Bailey DP, Kashyap M, Speiran K, et al. IL-10 Suppresses Mast Cell IgE Receptor Expression and Signaling In Vitro and In Vivo. *J Immunol* 2008;180(5):2848-54.
193. Oskeritzian CA, Zhao W, Min HK, Xia HZ, Pozez A, Kiev J, et al. Surface CD88 functionally distinguishes the MCTC from the MCT type of human lung mast cell. *J Allergy Clin Immunol* 2005;115(6):1162-8.
194. Hakim-Rad K, Metz M, Maurer M. Mast cells: makers and breakers of allergic inflammation. *Curr Opin Allergy Clin Immunol* 2009;9(5):427-30.
195. Kalesnikoff J, Galli SJ. New developments in mast cell biology. *Nat Immunol* 2008;9(11):1215-23.
196. Galli SJ, Tsai M, Piliponsky AM. The development of allergic inflammation. *Nature* 2008;454(7203):445-54.
197. Feger F, Varadaradjalou S, Gao Z, Abraham SN, Arock M. The role of mast cells in host defense and their subversion by bacterial pathogens. *Trends Immunol* 2002;23(3):151-8.
198. Liebler JM, Qu Z, Buckner B, Powers MR, Rosenbaum JT. Fibroproliferation and mast cells in the acute respiratory distress syndrome. *Thorax* 1998;53(10):823-9.
199. Custovic A, Woodcock H, Craven M, Hassall R, Hadley E, Simpson A, et al. Dust mite allergens are carried on not only large particles. *Pediatr Allergy Immunol* 1999;10(4):258-60.
200. Taylor PE, Flagan RC, Miguel AG, Valenta R, Glovsky MM. Birch pollen rupture and the release of aerosols of respirable allergens. *Clin Exp Allergy* 2004;34(10):1591-6.
201. Taylor PE, Flagan RC, Valenta R, Glovsky MM. Release of allergens as respirable aerosols: A link between grass pollen and asthma. *J Allergy Clin Immunol* 2002;109(1):51-6.
202. Holgate S, Smith N, Massanari M, Jimenez P. Effects of omalizumab on markers of inflammation in patients with allergic asthma. *Allergy* 2009;64(12):1728-36.
203. Busse WW. Anti-immunoglobulin E (omalizumab) therapy in allergic asthma. *Am J Respir Crit Care Med* 2001;164(8 Pt 2):S12-7.
204. Strunk RC, Bloomberg GR. Omalizumab for asthma. *N Engl J Med* 2006;354(25):2689-95.

It is a capital mistake to theorise before one has data.
Insensibly one begins to twist facts to suit theories,
instead of theories to suit facts.

Sherlock Holmes
(Sir Arthur Conan Doyle)