



# LUND UNIVERSITY

## Retinal function in deaf-blind syndromes

Malm, Eva

2011

[Link to publication](#)

*Citation for published version (APA):*

Malm, E. (2011). *Retinal function in deaf-blind syndromes*. [Doctoral Thesis (compilation), Ophthalmology, Lund]. Department of Clinical Sciences, Lund University.

*Total number of authors:*

1

### General rights

Unless other specific re-use rights are stated the following general rights apply:

Copyright and moral rights for the publications made accessible in the public portal are retained by the authors and/or other copyright owners and it is a condition of accessing publications that users recognise and abide by the legal requirements associated with these rights.

- Users may download and print one copy of any publication from the public portal for the purpose of private study or research.
- You may not further distribute the material or use it for any profit-making activity or commercial gain
- You may freely distribute the URL identifying the publication in the public portal

Read more about Creative commons licenses: <https://creativecommons.org/licenses/>

### Take down policy

If you believe that this document breaches copyright please contact us providing details, and we will remove access to the work immediately and investigate your claim.

LUND UNIVERSITY

PO Box 117  
221 00 Lund  
+46 46-222 00 00

# Retinal function in deaf-blind syndromes

Eva Malm

M.D.



LUND UNIVERSITY

Faculty of Medicine

Doctorial thesis

With the permission from the Faculty of Medicine, Lund University Hospital, the public defense of this thesis for the degree of Doctor of Philosophy in Medicine will take place in Segerfalksalen, BMC house A, Sölvegatan 19, University Hospital Lund, Friday the 7th of October 2011 at 2.00 PM.

Faculty opponent:

Professor Günter Niemeyer

Department of Ophthalmology, University Hospital Zurich

Zurich, Switzerland



# Retinal function in deaf-blind syndromes

Eva Malm



LUND UNIVERSITY  
Faculty of Medicine

Department of Clinical Sciences, Lund  
Ophthalmology  
Faculty of Medicine  
Lund University, Sweden  
2011

© Eva Malm  
Doctoral Dissertation 2011  
Department of Clinical Sciences, Lund  
Ophthalmology  
Faculty of Medicine  
Lund University, Sweden

ISSN 1652-8220  
ISBN 978-91-86871-29-1  
Lund University,  
Faculty of Medicine Doctoral Dissertation Series 2011:79

Printed by Media-Tryck, Lund University, 2011

Front page:  
Drawings by courtesy of Josefin Ohlin (hands) and Ida Gullberg (eye).

*Möjligheter*

*Till Peter  
och  
alla våra barn*



# Contents

<b>List of papers</b>	<b>9</b>
<b>Abbreviations</b>	<b>11</b>
<b>Introduction</b>	<b>13</b>
Personal reflection	13
General background	13
Deaf-blind syndromes included in this thesis	14
The retina	19
Electrophysiological examinations	22
Other examinations	25
<b>Aims of the study</b>	<b>27</b>
<b>Methods</b>	<b>29</b>
Ophthalmological examinations	29
Electrophysiological examinations	29
Other examinations	30
<b>Results</b>	<b>33</b>
Alström syndrome – paper I	33
Usher syndrome – paper II and III	33
Rare syndrome-related disorders – paper IV	35
<b>Discussion</b>	<b>37</b>
<b>Major conclusions</b>	<b>41</b>
<b>Svensk sammanfattning</b>	<b>43</b>
<b>Acknowledgements</b>	<b>49</b>
<b>References</b>	<b>51</b>





# List of papers

- I. Malm E, Ponjavic V, Nishina PM, Naggert JK, Hinman EG, Andréasson S, Marshall JD, Möller C.  
Full-field electroretinography demonstrates a marked variability in clinical phenotype of Alström syndrome.  
*Archives of Ophthalmology* 2008;126(1):51-57.
- II. Malm E, Ponjavic V, Möller C, Kimberling WJ, Stone ES, Andréasson S.  
Alteration of rod and cone function in children with Usher syndrome.  
*European Journal of Ophthalmology* 2011 Jan-Feb;21(1):30-38.
- III. Malm E, Ponjavic V, Möller C, Kimberling WJ, Andréasson S. Phenotypes in defined genotypes including siblings with Usher syndrome.  
*Ophthalmic Genetics* 2011;32(2):65-74.
- IV. Malm E.  
Full-field electroretinography in rare disorders including hearing and visual impairment.  
*Submitted.*

I. Permission granted for publication.

Copyright © (2008) American Medical Association. All rights reserved.

II. Permission granted for publication. Copyright EJO. All rights reserved.

III. Permission requested for.



# Abbreviations

<i>3D</i>	Three-dimensional
<i>ADL</i>	Activities of daily living
<i>BBS</i>	Bardet-Biedl syndrome
<i>CRS</i>	Congenital rubella syndrome
<i>CS</i>	Cockayne syndrome
<i>DNA</i>	Deoxyribonucleic acid
<i>ERG</i>	Electroretinography
<i>Ff-ERG</i>	Full-field electroretinography
<i>GCL</i>	Ganglion cell layer
<i>INL</i>	Inner nuclear layer
<i>IPL</i>	Inner plexiform layer
<i>Mf-ERG</i>	Multifocal electroretinography
<i>MPS</i>	Mucopolysaccharidosis
<i>NFL</i>	Nerve fiber layer
<i>OCT</i>	Optical coherence tomography
<i>OMIM</i>	Online Mendelian Inheritance in Man®
<i>ONL</i>	Outer nuclear layer
<i>OPL</i>	Outer plexiform layer
<i>OS</i>	Outer segment (of the photoreceptor)
<i>PCR</i>	Polymerase chain reaction
<i>RP</i>	Retinitis pigmentosa
<i>RPE</i>	Retinal pigment epithelium
<i>USH</i>	Usher syndrome



# Introduction

## Personal reflection

Why am I doing this? Why have I chosen to do clinical research? My meeting with one of the girls in this thesis illustrates the purpose of clinical research to me.

This girl was in her middle teens. She did not know that she had a disorder that could affect the eyes. She had noticed that she was not aware of things in her visual fields as before. For example, she missed balls thrown to her during gymnastics. This made her sad, as she had been very good at all kinds of sports. She had started to stumble over things. She had not told her parents; she did not want to bother them. She really thought that something was wrong in her head – that she was going mad. After our examinations, we could explain to her that she had retinitis pigmentosa. When we said goodbye she hugged me with tears in her eyes and thanked us all for what we had done for her; she now had an explanation for all her visual symptoms and she understood that she was not going mad.

This thesis is for all children and adults who have not-so-common disorders involving visual impairment, and who all too often find it difficult to be understood in our society.

I hope you will enjoy reading my thesis.

## General background

Hereditary retinal disorders is said to be the most common cause of acquired severe visual impairment in Sweden (Andréasson 2006). Many of these patients have associated handicaps, and in the literature it has been estimated that 10-30 % of patients with retinitis pigmentosa also have some form of hearing impairment (Keats 2002; Bayazit et al 2006; Goode et al 1967; Ahmed et al 2003). There are many different causes of combined visual and hearing impairment – for example, rubella virus infection, Alström syndrome, Usher syndrome, or Cockayne syndrome. For these patients, and especially if they are children, it is of great value to have an early diagnosis since there is a large variation in phenotype and prognosis.

The last two-three decades have seen great progress for patients with visual and hearing impairment. The development of the cochlear implant during the 1980s and 1990s has brought a revolutionary change regarding hearing impairment. Studies have revealed the genetic background in for example many of the subtypes in Usher's syndrome (OMIM). Our knowledge about the pathophysiological mechanisms involved has improved, and molecular genetic studies give hope of gene therapy in the future (Williams 2008).

The Swedish Retinal Degeneration (RD) Registry is linked to the Department of Ophthalmology at Lund University and covers more than 2,900 patients, including about 100 patients with hereditary retinal disorders combined with hearing impairment. Research on hereditary retinal disorders has been carried out at the Eye Clinic, Lund University Hospital since the 1980s. Regarding deaf-blind syndromes, several research projects have been run together with Prof. Claes Möller (Department of Audiology, Swedish Institute of Disability Research, Örebro University Hospital, Sweden). In this thesis, the term "deaf-blind syndromes" refers to disorders that include both visual and hearing impairment, which can either be the main and only feature of the disorder or part of a disorder with multiple manifestations.

In presented papers we have collaborated with Prof. Claes Möller and researchers in molecular genetics: Prof. William Kimberling (Department of Ophthalmology and Visual Science, Iowa University Carver School of Medicine, Iowa City, Iowa, USA and Usher Syndrome Center, Boys Town National Research Hospital, Omaha, Nebraska, USA) and Prof. Jan Marshall (Jackson Laboratory, Bar Harbor, Maine, USA).

## Deaf-blind syndromes included in this thesis

### *Alström syndrome*

Alström syndrome is an autosomal recessive inherited disorder that was first described in 1959 by Alström (Alström et al 1959). Alström syndrome is caused by a mutation in the *ALMS 1* gene (OMIM 203800). The exact prevalence is not known, but approximately 450 cases have been identified in the world since the condition was first described in 1959 (Marshall et al 2007).

Cardinal clinical features of this disorder are early-onset cardiomyopathy, progressive retinal degeneration, progressive sensorineural hearing loss, and childhood obesity. Respiratory failure with recurring infections and asthma is often observed in infancy. Most affected individuals develop severe insulin resistance, hyperinsulinemia, or type 2 diabetes mellitus in early adulthood. Other metabolic disturbances such as hypothyroidism, hyperuricemia, and hypertriglyceridemia and also dermatological conditions such as acanthosis nigricans and alopecia may be present. Dilated cardiomyopathy with infant or adolescent onset and subsequent congestive heart

failure occur in approximately 70% of individuals with Alström syndrome. Hepatic and urological dysfunction is often observed, and progressive chronic nephropathy with eventual renal failure is a late finding. Accelerated skeletal maturity and low growth hormone levels result in short stature, scoliosis, and kyphosis in some patients (Tremblay et al 1993; Marshall et al 2010).

In early childhood, ophthalmic manifestations include nystagmus and photophobia with diminished visual acuity. Posterior subcapsular cataracts may be present. There is a variation in fundus appearance with narrowing of retinal vessels, chorioretinal atrophy, bone spiculae pigmentary changes, and optic atrophy. Electrophysiologically, the retinal degeneration is characterized by early cone dysfunction followed by rapid deterioration of the rod responses and early loss of vision in the second decade of life (Marshall et al 2010).

The *ALMS 1* gene has been mapped to chromosome 2p13 and several disease-causing mutations have been identified (OMIM). The *ALMS 1* gene encodes a protein found primarily in centrosomes and basal bodies of ciliated cells, suggesting a function in cilia formation, maintenance, and function. This places Alström syndrome among a growing number of ciliopathies that include Bardet-Biedl syndrome (BBS), Senior-Loken syndrome, and polycystic kidney disease (Badano et al 2006). In Alström syndrome, considerable phenotypic interfamilial and intrafamilial variability exists, with differences in clinical expression and rate of progression of nearly all the features (Marshall et al 2010).

### *Usher syndrome*

Usher syndrome is a group of autosomal recessively inherited disorders characterized by retinitis pigmentosa (RP) and sensory hearing loss with or without vestibular dysfunction. The first to describe combined deafness and RP were Albrecht von Graefe in 1858 and Liebreich a few years later. In 1914, Charles Usher described the transmission of congenital deafness and RP as a hereditary condition, and in 1922 Julia Bell was the first to describe a difference in phenotype. The original classification by Davenport and Omenn was presented in 1977. Bertil Hallgren was the first to report on the prevalence of Usher syndrome in 1959. Today, the prevalence is estimated to range from 3.5–6.2 per 100,000 (Hope et al 1997; Rosenberg et al 1997; Keats et al 1999; Saihan et al 2009; Millán et al 2011). Usher syndrome accounts for more than 50% of all deaf-blind patients (Vernon 1969), about 18% of pigmentary retinopathies (Boughman et al 1983), and 3–6% of cases of congenital deafness (Vernon 1969).

Usher syndrome is classified into three clinical phenotypes: Usher types 1, 2, and 3. The clinical classification is based on the three characteristics RP, sensory hearing loss, and vestibular dysfunction. As different genes and loci have been identified, these three clinical phenotypes have been divided into several genetic subtypes described below. The sensory hearing loss is congenital and stable in Usher types 1 and 2, with



severe to profound hearing loss in type 1 and moderate to severe hearing loss in type 2. This contrasts with Usher type 3, where the onset may be later and the severity of the hearing loss is variable. The vestibular dysfunction is profound in Usher type 1 (bilateral vestibular areflexia), absent in type 2, and progressive in type 3.

The ophthalmological manifestation is rod-cone degeneration (retinitis pigmentosa) and cataract. Nyctalopia is often the first symptom, followed by constricted visual fields and reduced visual acuity. The onset of RP has previously been stated to be prepubertal in Usher type 1, pubertal in Usher type 2, and variable in Usher type 3. This is open to debate, however, since most cases show retinal pathology at a very young age (Young et al 1996; Mets et al 2000; Pennings et al 2004; Sandberg et al 2008; Flores-Guevara et al 2009). The classical retinal changes of spicular pigmentation and narrow arterioles are often recognized late in life, and as the rod-cone degeneration progresses there is a general atrophy of the retina and development of optic atrophy.

During the past two decades, several genes involved in Usher syndrome have been identified and the syndrome has been found to be a more heterogeneous group of inherited disorders than originally thought. In 1990, the first locus – associated with Usher type 2 – was mapped to chromosome 1q (Kimberling et al 1990). Mutations in genes at a minimum of twelve different loci can cause Usher syndrome. At least nine genes of these loci have been identified (OMIM; Friedman et al 2011; Millán et al 2011).

To date, eleven genetic subtypes and nine proteins encoded by the Usher genes are known: USH 1B (myosin VIIa), USH 1C (harmonin), USH 1D (cadherin-23), USH 1E (unknown protein), USH 1F (protocadherin-15), USH 1G (SANS), USH 1H (unknown protein), USH 2A (usherin), USH 2C (G-protein coupled receptor 98 (GPR98)), USH 2D (whirlin), and USH 3A (clarin-1) (OMIM; Friedman et al 2011; Millán et al 2011).

The proteins encoded by the known Usher syndrome genes are also involved in non-syndromic types of hearing loss and RP (Weil et al 1997; Rivolta et al 2000; Tamagawa et al 2002). The identification of genes involved in both syndromic and non-syndromic hearing loss has made it possible to study the proteins, their function in the inner ear, and the associated phenotype. In the inner ear the proteins myosin VIIa, harmonin, cadherin-23, SANS, protocadherin-15, usherin, GPR98 (previously Vlgr-1b), whirlin, and clarin-1 are involved in the normal structure and function of the hair cells and their stereocilia, and some of these proteins (myosin VIIa, harmonin, and cadherin-23) are also expressed in the vestibular hair cells. Analogously, different proteins in the photoreceptors are affected and a theory of a protein interactome involving the Usher proteins in both the inner ear and the retina has been presented in recent studies (Petit 2001; Reiners et al 2006; Kremer et al 2006; Saihan et al 2009; Friedman et al 2011).

### *Cockayne syndrome*

Cockayne syndrome (CS) is an autosomal recessive inherited disorder. In 75% of the patients, CS is caused by a mutation in the *ERCC6* gene and in 25% of the patients it is caused by a mutation in the *ERCC8* gene (OMIM 216400 and OMIM 133540). The prevalence is about 2 per million newborns in the United States and Europe (Neilan et al 2006).

Cockayne syndrome is characterized by short stature and an appearance of premature aging. Other features are postnatal growth failure, abnormally small head size (microcephaly), and impaired development of the nervous system with progressive neurological dysfunction. Other symptoms include hearing loss, tooth decay, and bone abnormalities (Nance et al 1992; Cleaver et al 1999; Rapin et al 2000; Neilan et al 2006).

There is a wide variation in ophthalmic pathology in Cockayne syndrome. Congenital structural anomalies such as enophthalmos, microphthalmia, and cataract may be present and the child may have nystagmus, photophobia, and strabismus. Variable ocular features include cataract of various types, iris and ciliar body atrophy, narrowing of retinal vessels, retinal atrophy, retinal pigmentary atrophy, and optic nerve atrophy (Dollfus et al 2003).

Cockayne syndrome is divided into three phenotypes: CS type I (also called CS type A), CS type II (also called CS type B), and CS type III. In CS type I, the classical form, the major features become apparent in early childhood (at 1–2 years of age) and death typically occurs in the first or second decade. In CS type II, the symptoms are much more severe and are apparent at birth (congenital); expected length of life does rarely exceed seven years. CS type III is the mildest form and appears later in childhood (Rapin et al 2000; Neilan et al 2006).

The *ERCC6* gene, which has been mapped to chromosome 10q11 and is also known as the *CSB* gene, and the *ERCC8* gene, which has been mapped to chromosome 5q12 and is also known as the *CSA* gene, code for proteins involved in repair of damaged DNA. DNA can be damaged by ultraviolet (UV) rays from the sun and by toxic chemicals, radiation, and unstable molecules called free radicals. In CS, defective DNA repair leads to cellular malfunction and increased cell death, both of which contribute to the features of CS (van Oosterwijk et al 1996; Cleaver et al 1999; Tuo et al 2003; Cramers et al 2011).

### *Mucopolysaccharidosis*

Mucopolysaccharidosis (MPS) is group of autosomal recessively inherited disorders. MPS 1 is caused by a mutation in the *IDUA* gene (OMIM 252800). The precise figures

for MPS 1 incidence are not known, but they have been estimated to be approximately 1 per 100,000 births (Clarke et al 2011).

The clinical manifestations of MPS 1 are highly heterogeneous and multi-systemic, and have a progressive course. Symptoms common to the different types include facial dysmorphism, hepatomegaly, valvular heart disease, obstructive pulmonary disease, mental retardation, hearing loss, hernias, skeletal deformities, and joint stiffness (Wraith et al 1987; Neufeld et al 2001; Clarke et al 2011).

Common ophthalmological manifestations in MPS 1 are corneal clouding and retinal degeneration. Optic nerve head swelling and glaucoma may be observed (Caruso et al 1986; Collins et al 1990; Ashworth et al 2006; Ferrari et al 2010).

Three major phenotypes have been recognized: Hurler syndrome (MPS 1H, OMIM 607014), Hurler-Scheie syndrome (MPS 1H/S, OMIM 607015), and Scheie syndrome (MPS 1S, OMIM 607016). Children with Hurler syndrome, the most severe phenotype, appear normal at birth and develop the characteristic appearance over the first years of life. Their lifespan is less than ten years. Scheie syndrome is the mildest phenotype with onset of symptoms commonly occurring after five years of age and diagnosis being made between ten and twenty years of age. Individuals with Scheie syndrome can have the same physical symptoms, but generally with little impairment of intellect, and they may have a normal lifespan. Hurler-Scheie syndrome has an intermediate phenotype (Wraith et al 1987; Neufeld et al 2001; Moore et al 2008; Clarke et al 2011).

The *IDUA* gene has been mapped to chromosome 4p16.3 and codes for alpha-L-iduronidase. This is a specific lysosomal enzyme involved in the degradation of glycosaminoglycans (GAGs), or mucopolysaccharides. Deficiency of alpha-L-iduronidase results in accumulation of partially degraded GAGs, causing interference with cell, tissue, and organ function (Pastores et al 2005; Pastores 2008).

### *Congenital rubella syndrome*

Rubella is a common childhood infection caused by rubella virus. Rubella is commonly known as German measles since it was first described by two German physicians, De Bergen and Orlow in 1752 and 1758, respectively. The name rubella (latin: little red) was given to the disease by the Scottish physician Veale in 1866 (Duszak 2009). An Australian ophthalmologist N. McAlister Gregg observed in 1941 that pregnant women who develop rubella can give birth to children with congenital defects (Gregg 1941). This was the first description of the teratogenic effects of a viral infection.

Rubella epidemics occur at six- to nine-year intervals, and major pandemics have occurred every ten to thirty years. After the last pandemic in the 1960s, extensive studies were initiated and in 1969 the rubella virus was isolated and identified. The first vaccine was licensed in the same year, and since then congenital infection from rubella

has been dramatically reduced. Today, the incidence of congenital rubella syndrome has been reduced to a minimum in countries with immunization programs, but just a few decades ago it was the most frequent cause of congenital deaf-blindness (Duszak 2009).

Rubella infection at any stage of pregnancy can cause infection of the fetus. The highest infection rates are in the early stages of pregnancy and it may cause miscarriage, stillbirth, or health problems for the affected fetus. The term congenital rubella syndrome (CRS) is used for any combination of the manifestations that usually result from gestational rubella (Freij et al 1988). The main defects in CRS are sensorineural hearing loss, mental retardation, cardiovascular defects, and ocular defects. There is a wide spectrum of other manifestations including thrombocytopenia, hepatitis, myocarditis, and dental defects. Not all effects of CRS are seen at birth; in addition, delayed manifestations may occur – including diabetes, thyroid diseases, hypertension, and neurological and psychosocial problems (Duszak 2009; Dammeyer 2010).

Ocular involvement may be either congenital or manifested later in life. Cataract is the most common ocular complication, followed by microphthalmia and pigmentary retinopathy. The retinopathy is characterized by a salt-and-pepper appearance in fundus and may be unilateral or bilateral. Pigmentary changes have been reported to be due to focal atrophy and pigment alterations of the retinal pigment epithelium. The retina and the choroid appear normal. Glaucoma can either be congenital or acquired in CRS. Corneal haze may occur (Gregg 1941; Arnold et al 1994).

## The retina

The retina is a light-sensitive tissue lining the inner surface of the eye. It has much the same function as the film in an old camera. Light entering the eye projects an image of the visual world on the retina (Fig. I).

The retina is a complex structure, in section approximately 0.5 mm thick, with three layers of nerve cells and two layers of synapses (Fig. II). It is the photoreceptors in the outer part of the retina that absorb the light. When the light is absorbed, the visual pigment is activated and in turn initiates a cascade of chemical reactions, called the phototransduction cascade. The photoreceptor is hyperpolarized and the light is transformed to an electrical signal. This neural signal undergoes complex processing by other neurons of the retina (see below). The output signal is conducted through the retinal ganglion cells, in the inner part of the retina, the axons of which form the optic nerve. The nerve impulse reaches the brain, where we experience an impression of the world around us.

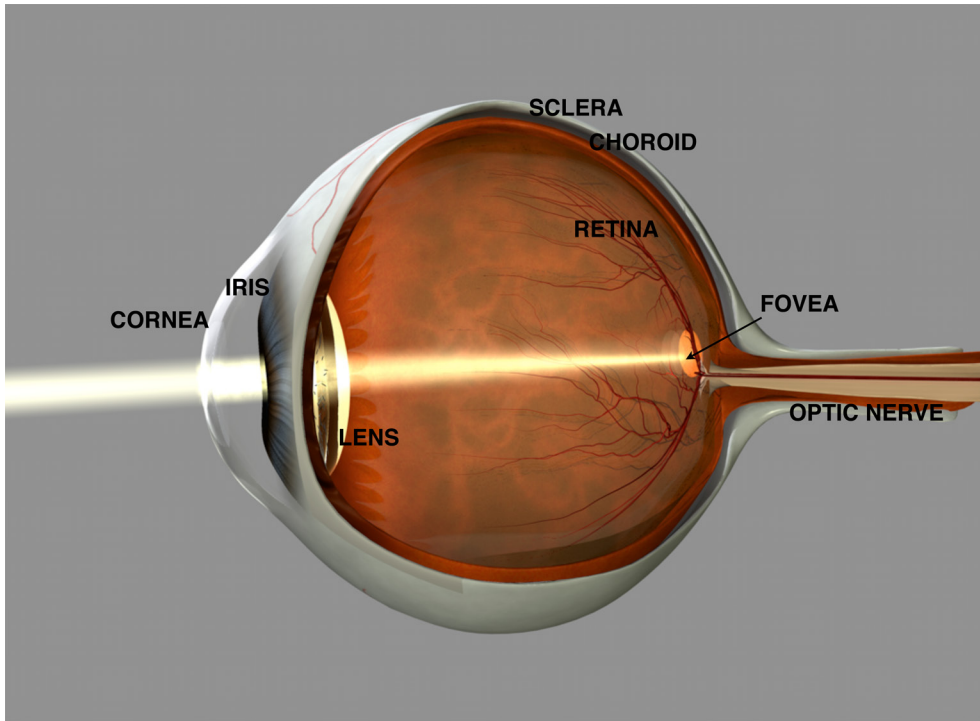


Fig. I. Anatomy of the eye. (Copyright Fredrik Ghosh)

The photoreceptors are of two types, the rods and the cones; these have different visual pigments that are sensitive to different wavelengths of light. The rods contain a very photosensitive visual pigment called rhodopsin and function mainly in dim light, providing black-and-white eyesight, which is important for night vision (scotopic vision). The cones express visual pigments with different absorption maxima; these are divided into three subgroups: blue (short wavelength), green (middle wavelength), and red (long wavelength) cones. The cones respond to bright light and mediate color vision during daylight illumination (photopic vision). The illumination is often at a level at which both cones and rods are active (mesopic vision) (Österberg 1935; Dacheux 2000; Blanks 2001).

The retina contains approximately 7 million cones and 100 million rods (Österberg 1935; Blanks 2001). The cones are most frequent in the macula and in its center is the fovea, which is responsible for our sharp vision. In the foveal pit, the cones are smallest and in a hexagonal mosaic – the most efficient and of the highest density. The rods are found throughout the retina except in the foveola, the center of the fovea, where they are absent. The macula has a yellow pigmentation and is known as the macula lutea.

The other cells in the retina apart from the photoreceptors and the ganglion cells are the bipolar cells, the horizontal cells, the amacrine cells, the Müller cells, the interplexiform cells, and the pigment epithelium cells (Fig. II) (Dacheux 2000; Blanks 2001). The bipolar cells transmit the electrical signal from the photoreceptor to the ganglion cells. The receptors are “cross-linked” by horizontal cells and amacrine cells, which modify the synaptic signal before the ganglion cells. The Müller cells regulate levels of extracellular ions, are structural and metabolic support of neurons and provide neuronal guidance during retinal development. The interplexiform cells contain dopamine and participate in information processing in the retina. The retinal pigment epithelium (RPE) is located between the photoreceptors and the choroid. The RPE transports ions, metabolites, and water between the retina and the choroid, and is important in the transport and storage of the retinoids (components of the visual pigments).

The two layers of synapses in the retina are called the outer plexiform layer and the inner plexiform layer. In the outer plexiform layer, the rods and cones connect to the vertically running bipolar cells and the horizontally oriented horizontal cells. In the inner plexiform layer, the bipolar cells connect to the ganglion cells and the amacrine cells (Fig. II) (Dacheux 2000).

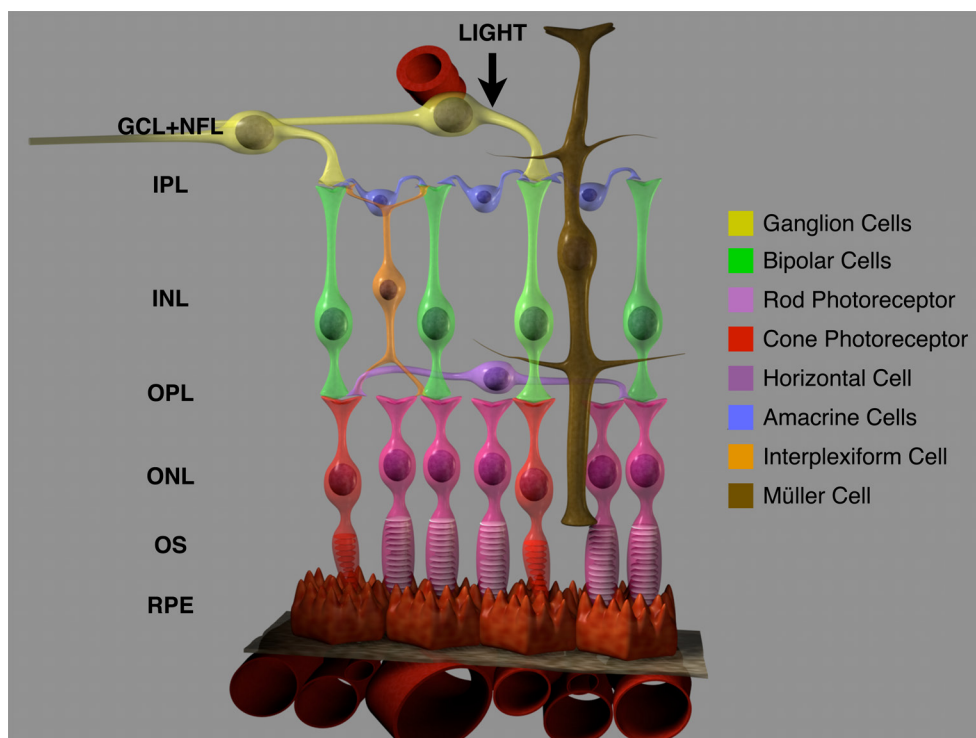


Fig. II. The retina. (Copyright Fredrik Ghosh)

# Electrophysiological examinations

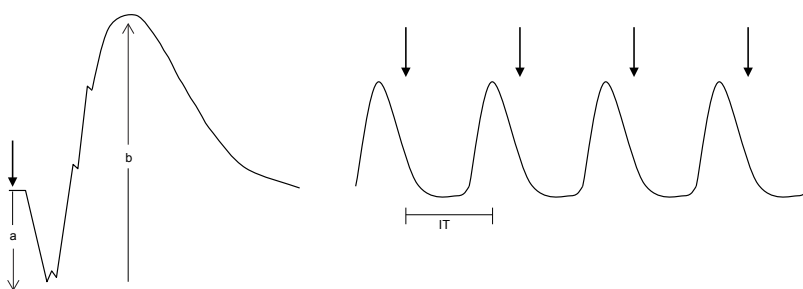
Visual function is complex and it is really a combination of many different variables representing different functions from the optics of the eye to the central nervous system (the brain). The total visual ability of an individual can be difficult to evaluate and visual impairment may be difficult to define, especially in children with another handicap or a multiple handicap in addition to the visual disturbance. In order to determine retinal function, we have used two objective electrophysiological methods: full-field electroretinography and multifocal electroretinography.

## *Full-field electroretinography (ff-ERG)*

Ff-ERG is an electrophysiological method for objective measurement of the total retinal function, the isolated total cone function, and the isolated total rod function. The first electroretinographic recordings were made on the frog by Holmgren in 1865. The technique is based on registration of the summation of the action potentials generated by the retinal cells after stimulation with light. To obtain the best sensitivity of the photoreceptors, the retina is dark-adapted for 30–45 min before stimulation with light. This is the time it takes for the chemical process to replace the bleached photopigment. The whole retina is illuminated by light produced by a Ganzfeld sphere and a bipolar contact lens electrode, applied to the corneal surface, registers the electric activity generated by the retina. The response is dealt with by a computer-based analysis system (Marmor et al 2009).

By illumination with different wavelengths, intensities, and frequencies of light in combination with different background illumination, responses from different cells in the retina can be evaluated. Stimulation with dim blue light in the dark-adapted eye mainly reflects the rod function. Stimulation with a single flash of white light in the dark-adapted eye allows us to measure the combined rod and cone response, i.e. the total retinal function. To evaluate the isolated cone response, the retina is stimulated with 30-Hz flickering white light, either in the dark-adapted or the light-adapted eye. The implicit time of the 30-Hz flickering light is evaluated, since it is believed to predict the progression of retinal degeneration. The implicit time is considered to be normal in stationary forms of retinal disorders and prolonged in progressive forms (Berson 1993).

The major components of the electrical response in ff-ERG are the a-wave, the b-wave, and the c-wave (Fig. III). The origin of the different components is complex, but on evaluation looked at in a simplified way. The a-wave is negative in relation to the cornea and is thought to originate from the photoreceptors. The b-wave is positive in relation to the cornea and is believed to originate from the bipolar cells and perhaps also partially from the Müller cells. The b-wave reflects the activity of the photoreceptors since the bipolar cells depend on normal neural signaling from the photoreceptors. The c-wave originates from the RPE and is not measured routinely in clinical practice. By definition, the implicit time of the 30-Hz flickering light is the time from the stimulus to the maximum response. The amplitudes of the responses are measured in microvolts ( $\mu\text{V}$ ) and the implicit time in microseconds ( $\mu\text{s}$ ) (Robson 1998).



**Fig. III.** The major components of the electrical response in ff-ERG. Arrow indicates stimulus with light. The waveform at the left illustrates the a-wave (a) and the b-wave (b), registered after stimulation with single flashes of white light under dark-adapted conditions, corresponding to the combined rod-cone function. The waveform at the right is registered after stimulation with 30-Hz flickering white light, corresponding to isolated cone function. The implicit time (IT) of the 30-Hz flickering light is the time from the stimulus to the maximum response.



### *Multifocal electroretinography (mf-ERG)*

Mf-ERG was introduced by Sutter and Tran in 1992. The technique allows local ERG responses to be recorded simultaneously from many regions of the retina. A screen projects a stimulus pattern of 103 hexagons onto the central retina. The pattern stimulates the retina 20–30 degrees on both sides of fixation and the hexagons alternate between black and white on stimulation. A bipolar contact lens electrode applied to the cornea receives the retinal response and the fixation is monitored with an infrared fundus camera. The signals are processed by a mathematical system that can analyze each hexagon separately. The results are displayed as an array of the mf-ERG traces. From the mf-ERG trace arrays the mathematical program allows averaging of groups of responses, for example successive rings from center to periphery, presented as group averages. The third way to present the results are in a topographic (3D) response density plot that show the overall signal strength per unit area of retina (Fig. IV) (Marmor et al 2003; Holder et al 2007; Hood et al 2008).

The responses in mf-ERG are thought to originate from the cones, since it has been shown that there is a close relationship in signal generation and shape between the first-order kernel responses of the mf-ERG on the one hand and the ff-ERG cone response on the other (Hood 1998). Thus, it is the first-order response components of the mf-ERG that are analyzed, and as in ff-ERG, the amplitudes of the responses are measured in  $\mu\text{V}$  and the implicit time in ms.

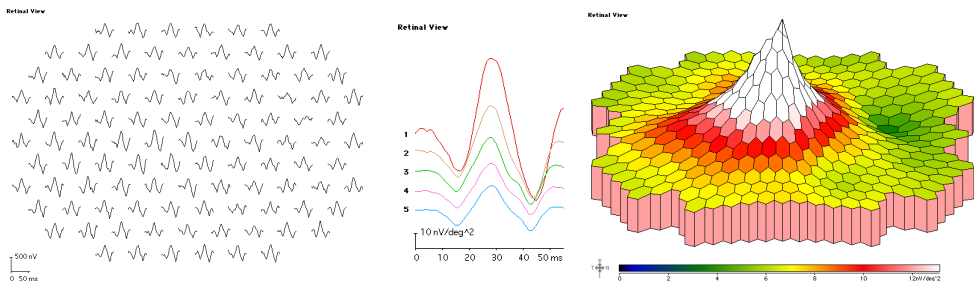


Fig IV. Mf-ERG recordings with normal amplitudes. At the left the mf-ERG trace arrays, in the middle group averages, and at the right the 3D response density plot. The central peak in the 3D plot corresponds to the cone function in the fovea.

## Other examinations

### *Optical coherence tomography (OCT)*

OCT is a non-invasive imaging method that captures micrometer-resolution, cross-sectional and three-dimensional images of biological tissues. The mechanism is analogous to ultrasound B-mode imaging, but uses light instead of sound. The use of light makes the resolution about ten times greater (in the 10–20- $\mu\text{m}$  range) and in addition it allows an image to be obtained without contact with the globe. The signals from the OCT scans are usually presented in a false color scale.

Optical coherence tomography is an interferometric technique, a technique in which electromagnetic waves are superimposed in order to extract information about the waves, using near-infrared light. The use of relatively long-wavelength light allows it to penetrate into the scattering medium. A relatively recent implementation of optical coherence tomography, frequency-domain optical coherence tomography, provides advantages in signal-to-noise ratio, thus permitting faster signal acquisition. The optical coherence tomography systems are employed in diverse applications. In ophthalmology OCT produces detailed images of the retinal layers, allowing analysis of structural changes within the retina (Paunescu et al 2004; Chan et al 2006; Leung et al 2008).



# Aims of the study

The general aim of this thesis was to characterize the retinal function, to describe the phenotype, and – where appropriate – to relate the phenotype to genotype in patients with combined visual and hearing impairment. This was with a view to improving our understanding of the visual handicap in this group of patients.

The specific aims for each paper were:

Paper I: To characterize the clinical phenotype and to study the course of disease in patients with Alström syndrome, with emphasis on retinal function assessed with ff-ERG.

Paper II: To evaluate the retinal function, with emphasis on phenotype and rate of progression, in infants and children with different genotypes of Usher syndrome.

Paper III: To characterize visual function in defined genotypes including siblings with Usher syndrome.

Paper IV: To characterize the retinal function in children with rare syndrome-related disorders involving visual and hearing impairment.



# Methods

## Ophthalmological examinations

### *Ophthalmological examination and visual acuity – papers I, II, III, and IV*

Clinical ophthalmological examination with slit-lamp inspection of the anterior segment and ophthalmoscopic examination of the posterior segment were performed in all patients included in the studies.

Best-corrected visual acuity was measured with preferential looking, KM letter chart (Moutakis et al 2004), or Snellen letter chart.

### *Visual fields – papers I and III*

Visual fields were examined with Goldmann kinetic perimetry using two standardized objects, V:4e and I:4e, with white light stimulus.

## Electrophysiological examinations

### *Full-field electroretinography (ff-ERG) – papers I, II, III, and IV*

Ff-ERG is an electrophysiological examination that reflects the total function of the retina. Isolated total cone and isolated total rod responses can be measured together with total retinal function.

Ff-ERG was recorded in a Nicolet Viking analysis system (Nicolet Biomedical Instruments, Madison, WI) using the standard protocol presented by the International Society for Clinical Electrophysiology of Vision (ISCEV) (Marmor et al 2009), with a few minor modifications. Recordings of isolated cone responses were obtained without background illumination on the full-field screen. When responses measuring less than 10  $\mu$ V were recorded with single white flashes, recordings were also obtained with computer averaging (30 flashes) and a bipolar artifact rejecter. To obtain small cone responses, stimulation also included 200 flashes of flickering white light (30 Hz), with a line frequency notch filter (50 Hz) and a digital narrow-band pass filter added to the Nicolet instrument. The narrow-band filter was tuned at 30 Hz (12 dB at 29 Hz and

31 Hz) to enable measurements of signals down to 0.1  $\mu$ V (Andréasson et al 1988; Andréasson et al 1993; Andréasson et al 1996).

### *Multifocal electroretinography (mf-ERG) – papers II, and III*

Mf-ERG is an electrophysiological examination that reflects the function in the central retina, the function of the cones in the macula.

Mf-ERG was performed using a visual evoked response imaging system (VERIS 4; EDI, San Mateo, CA). After dilatation of the pupils and topical anesthesia, a Burian Allen bipolar lens with infrared light was applied on the cornea. 103 hexagonal stimulus elements were used. Fixation was controlled using a fundus camera and illumination with infrared light from the recording electrode, with visualization of the hexagonal elements over the retina. The amplitudes of the peak wave and the peak time were calculated according to the guidelines for basic mf-ERG (Marmor et al 2003; Holder et al 2007; Hood et al 2008).

## Other examinations

### *Optical coherence tomography (OCT) – papers II and III*

Both OCT-3 and 3D OCT have been used to visualize the structure and thickness of the central retina.

In OCT-3 (Zeiss Humphrey Instruments, Dublin, CA), the macular thickness map scan protocol was used to obtain 6 consecutive radial macular scans, 6 mm in length, centered on the fovea, with 30 degrees displacement between them. Internal fixation was used and visualized with a video camera. The scanning and video images were displayed simultaneously to further verify fixation. The retinal map analysis protocol on the OCT instrument was used to calculate the retinal thickness in the fovea, measuring from the surface of the retinal pigment epithelium to the retinal nerve fiber layer. Foveal thickness was defined as the average thickness in the central 1,000- $\mu$ m diameter area of the macula (Paunescu et al 2004; Chan et al 2006).

In the spectral domain 3D OCT-1000 (version 3.00 software; Topcon, Tokyo, Japan), the 3D macula scan option was used for all scans, centered on the fovea (covering 6  $\times$  6 mm, resolution 512  $\times$  128), imaging the complete macular area. The instrument uses a Fourier domain spectrometer producing cross-sectional B-scans and 3D volumetric images at a speed of 25,000 A-scans/sec (Leung et al 2008).

### *Genetic examinations – papers I, II, and III*

For genetic analysis, blood samples were collected in tubes containing EDTA as an anticoagulant. DNA was prepared according to standard procedures.

In paper I, *ALMS1* primers were designed to amplify exon and splice-site sequences from genomic DNA. PCR amplification was performed in a PTC-100 (MJ Research, Waltham, MA). PCR-amplified products were electrophoresed on a 1.5% agarose gel to ensure that they were of the predicted size, and they were purified further using AMPure (Agencourt, Beverly, MA) and sequenced on an ABI Prism 3730xl sequencer (Applied Biosystems, Inc., Foster City, CA). The sequenced products were then compared to the *ALMS1* transcript (GenBank Assession no. NM\_015120). Numbering of both nucleotide position and amino acid position was started at the open reading frame (ATG, Met).

In most of the patients with Usher syndrome (paper II), genetic testing was performed at Asper Ophthalmics (Asper Biotech, Tartu, Estonia).

In all the patients in paper III and in two patients in paper II, genetic testing was performed using the USHplex test developed using the SNPlex platform (Applied Biosystems), which screens for 96 of the most common pathogenic Usher alleles across 8 of the known Usher genes. Mutations found using the USHplex test were confirmed using standard ABI sequencing.

The genetic examinations in paper IV were initiated at other clinics as part of the general investigation of the children, and were not a part of this study.

### *Activities of daily living (ADL) – paper III*

The patients in paper III answered a questionnaire containing eight questions related to their activities of daily living (ADL). The questions were constructed to reflect the patients' subjective assessment of nyctalopia, photosensitivity, narrowing of visual fields, and reduced visual acuity (Damen et al 2005).





# Results

## Alström syndrome – paper I

Three age- and gender-matched patients with Alström syndrome were examined. Repeated ff-ERG was done between the ages of four months and twelve years. Ff-ERG showed cone-rod degeneration in all three patients, and concomitant impairment in color vision and visual fields. The results showed a marked variation in retinal function and in disease severity. Ophthalmological variability was observed in the appearance of the fundus, in color vision, in visual fields, in refraction, and in visual acuity of the patients.

At four months of age, one patient (patient 3) had reduced cone function and essentially normal rod function. Repeated ff-ERG at six years of age showed no measurable cone or rod function, in accordance with a more aggressive disease course. Another patient (patient 1) had some remaining cone function and markedly reduced rod function at the age of five. The third patient (patient 2) had slightly reduced cone function and minor loss of rod function at ten years of age. This patient had a more benign clinical phenotype with normal fundus appearance, stable visual acuity, and preserved visual fields up to ten years of age.

Mutations in the *ALMS 1* gene were identified in all three patients.

## Usher syndrome – paper II and III

In paper II, fourteen children (2–10 years of age) with retinitis pigmentosa and hearing impairment phenotypical of Usher syndrome were examined under general anesthesia. Repeated examinations were performed under local anesthesia in five children. Ophthalmoscopy at the first examination under general anesthesia revealed only minor alterations, including narrow arteriolae and retinal pigmentary changes in the mid-periphery. All but one child had a normal macular appearance.

Six children were genotyped as having Usher 1B (four children), 2A (one child), and 3A (one child).

Ff-ERG demonstrated early alterations corresponding to a rod-cone dystrophy in all children. Up to four years of age, a remaining rod function could be verified in the majority of the children. After four years, there was a severe progression in deterioration of the rod function in Usher types 1 and 2, and a moderate progression in Usher type 3. In all children the cone function was moderately reduced, and in a few cases it was almost normal. The child genotyped as having Usher 3A underwent repeated ff-ERG up to the age of eighteen years of age; there was slowly progressing retinal degeneration with moderately reduced rod function and almost normal cone function. In two children, mf-ERG confirmed that there was preserved central cone function. OCT showed discrete structural alterations in their early teens.

Ff-ERG under general anesthesia in fifty-eight children with no diagnosed retinal disorder showed normal values in three age groups: 5–12 months, 1–4 years, and 5–10 years. In children who were less than one year old, there were slightly reduced amplitudes regarding both cones and rods. The results confirm that ff-ERG is reliable under general anesthesia.

In paper III, we examined thirteen patients (12–66 years of age) with phenotypically different subtypes of Usher syndrome, including three families with affected siblings. Ff-ERG revealed remaining cone function in twelve of them. In three of the patients with Usher type 1, mf-ERG showed a specific pattern with a sharp distinction between the area with reduced function and the central area with remaining macular function and normal peak time. In OCT, loss of foveal depression with distortion of the foveal architecture in the macula was seen in all patients. There was a wide range of foveal thickness (159–384  $\mu\text{m}$ ), which was not correlated with retinal function.

The patients' degree of visual handicap was evaluated with a questionnaire (activities of daily living, ADL). The siblings with Usher 2A were most impeded by their visual handicap. Within each family, the subjective character of the visual handicap was quite homogenous – except in the Usher 2C family, where there was a distinct intrafamilial correlation between the objectively measured phenotype and the subjective assessment of their visual ability.

Twelve of thirteen patients were genotyped and this included siblings from three families genotyped as having Usher 2A, 2C, and 3A. One unrelated patient was genotyped as Usher 2A and three unrelated patients as Usher 1B, 1D, and 1F. In one patient with Usher type 1 phenotype, no mutation was found.

All three siblings with Usher 2A had a similar phenotype demonstrating a severe form of retinal degeneration with more than 98% reduction according to ff-ERG, and no residual function in central areas according to mf-ERG. The three siblings with Usher 2C shared the same genotype with a marked phenotypic variation in retinal function including the macular area. Two siblings had severe rod-cone degeneration, while the

third sibling had moderately reduced rod and cone function according to ff-ERG, remaining function in the macular region according to mf-ERG, visual acuity of 20/20, and almost normal macular structure according to OCT. The two siblings with Usher 3A had severe rod-cone degeneration with severely reduced function in the macular region.

## Rare syndrome-related disorders – paper IV

We examined four children (3–11 years of age) with rare disorders including Alström syndrome, Cockayne syndrome, MPS 1H/S, and rubella retinopathy. The fundus appearance and the retinal dysfunction showed a wide variation in the phenotype associated with the syndrome-related disorder in each child.

Ff-ERG under general anesthesia in the child with Alström syndrome showed almost no cone response and only slightly reduced rod function at three years of age. At this time, the child had slight degenerative changes on fundus examination and an ERG phenotype that could have been classified as achromatopsia, but which later on more resembled progressive cone-rod degeneration.

On fundus examination, the child with Cockayne syndrome had narrow arterioles and degenerative changes in the mid-periphery and periphery. Ff-ERG under general anesthesia at seven years of age showed no residual rod response but there was remaining cone function and a delayed implicit time for 30-Hz flicker, corresponding to progressive rod-cone degeneration.

The child genotyped as having MPS 1H/S had peripheral corneal clouding and discrete, paramacular degenerative changes on fundus examination. Ff-ERG showed moderately reduced responses for both rods and cones with a moderately delayed implicit time for 30-Hz flicker, a response that would correspond to a progressive generalized degeneration of the photoreceptors.

The patient with congenital rubella syndrome had the classical salt-and-pepper appearance in the macula, and ff-ERG at both eleven and twenty-seven years of age showed normal retinal function.



# Discussion

Impairment of vision and hearing affects communication, and therefore the development of children. A variety of disorders can cause retinal degeneration and hearing impairment, which is referred to as deaf-blindness in this thesis. Deaf-blindness may be the main feature of a syndrome or may be part of a syndrome with other clinical characteristics. The visual impairment may be the first presenting symptom of the disorder, and is often difficult to evaluate in children – especially when combined with other psychomotor and physiological handicap.

Alström syndrome is a rare autosomal recessive disease with approximately 450 patients identified world-wide (Marshall et al 2007). Diagnosis of Alström syndrome is difficult because of the range of clinical phenotypes observed and because of similarities to other syndromes such as Bardet-Biedl syndrome (BBS), achromatopsia, and cone-rod degeneration (Dyer et al 1994). Although different clinical phenotypes with a wide range of onset and progression have been reported (Marshall et al 1997; Titomanlio et al 2004; Marshall et al 2005; Marshall et al 2007), the general opinion has been that the visual impairment progresses to blindness in the teens. We found variability in the retinal function with different age of onset and rate of progression of the cone-rod degeneration in Alström syndrome, in which the final visual outcome could vary considerably. At the age of ten, the child with the most benign phenotype (patient 2) had normal fundus appearance, slightly reduced cone function, minor loss of rod function, stable visual acuity, and preserved visual fields.

Usher syndrome is a group of autosomal recessively inherited disorders with a prevalence of 3.5–6.2 per 100,000 (Saihan et al 2009; Millán et al 2010). This syndrome accounts for more than 50% of all deaf-blind patients (Vernon 1969). The three clinical phenotypes (Usher types 1, 2, and 3) have variability in onset, progression, and severity of the three characteristics: RP, sensory neural hearing loss, and vestibular dysfunction (Kimberling 2003). The hearing impairment is often the earliest symptom, and even if there is early retinal degeneration it is often not until school age, or later in life, that the visual handicap becomes evident and diagnosis is confirmed (Pennings et al 2004; Sandberg et al 2008). Screening with ff-ERG in children with severe to profound preverbal hearing impairment can verify retinal dysfunction and establish the diagnosis of Usher syndrome even before the onset of funduscopy and visual abnormalities (Flores-Guevara et al 2009).

In Usher syndrome we were able to confirm that a normal clinical retinal appearance does not exclude the possibility of a retinal degenerative disorder. Ff-ERG under general anesthesia verified rod-cone degeneration with remaining rod function in all children examined up to at least four years of age, which indicates that they still have night vision early in life. All the children had remaining cone responses to some extent, which was confirmed by the finding of retained central cone function by mf-ERG even in the early teens. Between and within the subtypes of Usher syndrome, the phenotypes and degree of progression of the retinal degeneration were variable. The progress was most rapid in patients with Usher type 1, who had no detectable rod function later in life. In contrast, repeated examinations up to eighteen years of age in one child with Usher 3A showed less severe and slowly progressing rod-cone degeneration.

Phenotypic heterogeneity in Usher syndrome was further confirmed in examination of teenagers and adults with Usher syndrome. We established that there was phenotypic heterogeneity in siblings and between different genotypes of Usher syndrome regarding both the severity of the rod-cone degeneration and the function in the macular region. The retinal degeneration in Usher type 1 would be expected to be more severe and to have a more rapid progression than the other Usher types. Three of the unrelated Usher type 1 patients illustrated the phenotypic variability, with central visual function remaining until thirty-five years of age in one patient (Usher 1D). In these three unrelated patients with Usher type 1, mf-ERG showed a sharp distinction between areas with reduced function and preserved function, and OCT showed retained retinal layers. The siblings with Usher 2A (aged 48, 63, and 66) had a similar phenotype with widespread degeneration, including central areas. The Usher 2C siblings (aged 48, 51, and 52) had a marked phenotypic variation in retinal function. Two of the Usher 2C siblings had severe rod-cone degeneration, while the third sibling had moderately reduced rod and cone function with a well-preserved macular function. The two siblings with Usher 3A had more severe rod-cone degeneration than expected (including macular function), which is in accordance with the known variability in phenotype for Usher type 3.

In Usher syndrome we have not been able to find a correlation between foveal thickness in OCT and visual acuity, but there appears to be a correlation between normal definable retinal layers in the parafoveal retina and visual acuity. Visual field defects assessed with Goldmann perimetry in Usher syndrome have been found to show gradually decreasing visual fields, frequently following a particular course: a result that we could confirm.

Our results illustrate the complexity of the relationship between phenotype and genotype in Usher syndrome, with both interfamilial and intrafamilial differences, knowledge that will be essential in clinical diagnosis of both children and adults.

A variety of rare syndrome-related disorders can cause retinal degeneration and hearing impairment, together with other psychomotor or physiological characteristics (Goode et al 1967; Keats 2002; Ahmed et al 2003; Bayazit et al 2006; Neilan et al 2006; Duszak

2009; Clarke et al 2011). In this group of patients, the degree of visual impairment can be difficult to evaluate. In these children, as in most children with retinal degeneration, the appearance of the fundus often shows no or minor changes. Of four children examined who had Alström syndrome, Cockayne syndrome, MPS 1H/S, or rubella retinopathy, classical bone corpuscular retinal formations were not seen in any child and only the child with Cockayne syndrome had narrow arterioles. In these four children, different types and degrees of retinal degeneration were seen in ff-ERG. The degree of retinal degeneration was found to be correlated with the degree of visual impairment, but not always with the appearance of the fundus. Alström syndrome was associated with cone-rod degeneration, Cockayne syndrome with rod-cone degeneration, MPS 1H/S with generalized degeneration of the photoreceptors, and rubella retinopathy with normal retinal function.

We have examined a control group of children with no retinal disorder. Ff-ERG under general anesthesia in these children showed normal values for each age group, confirming previous results with slightly lower amplitudes for both rods and cones before one year of age. Taking slightly lower amplitudes into consideration, the results establish ff-ERG under general anesthesia as a reliable method.

Diagnosis is essential for all patients with deaf-blind syndromes, especially children. Early examination with ff-ERG establishes the type of retinal degeneration, which is valuable both in diagnosis of and habituation to the visual handicap. In combination with genetic screening, ff-ERG constitutes a valuable diagnostic tool in establishing diagnosis and prognosis for patients with deaf-blind syndromes.





# Major conclusions

- Normal clinical ophthalmological examination does not exclude the possibility of a retinal degenerative disorder.
- Ff-ERG under general anesthesia in children is a reliable method for the assessment of retinal function.
- Alström syndrome is associated with a cone-rod type of retinal degeneration with a striking variability in retinal function, and in disease onset and severity.
- Ff-ERG under general anesthesia in children with Usher syndrome shows variable phenotypes and different degrees of rate of progression of the rod-cone degeneration under childhood.
- In Usher syndrome there is phenotypic heterogeneity of visual function between siblings and between different genotypes, concerning both the severity of the rod-cone degeneration and the function in the macular region.
- In rare syndrome-related disorders including visual and hearing impairment, ff-ERG establishes the type of retinal degeneration, and is valuable in diagnosis.
- Ff-ERG improves our understanding of the visual handicap. Important in all ages and for all patients with deaf-blindness, either the visual impairment is the main feature or part of a multiple handicap.



# Svensk sammanfattning

Ett kombinerat syn- och hörselhandikapp påverkar vår möjlighet att kommunicera med omvärlden och det påverkar barnets möjlighet att utvecklas. De senaste decennierna har det skett stora framsteg för patienter med syn- och hörsel handikapp. Utvecklingen av cochlea-implantat under 80- och 90-talen har inneburit en revolutionerande förändring för barn födda med ett hörselhandikapp. Från att bli döv med dåligt utvecklat tal, dövstum, har dessa barn idag möjlighet att med ett cochlea-implantat utveckla normal hörsel och ett normalt tal. Genetiska studier har kunnat klarlägga den genetiska bakgrunden till många syndrom, däribland Ushers syndrom, och tillsammans med den ökade kunskapen om patofysiologiska mekanismer finns det hopp om framtida genterapi.

Ärftlig retinal sjukdom är den vanligaste orsaken till förvärvad svår synnedättning i Sverige. Många patienter har andra associerade handikapp och i litteraturen har uppskattningsvis 10-30% av patienterna med retinitis pigmentosa även en hörselnedsättning. Det finns många orsaker till kombinerat syn- och hörselhandikapp, till exempel Alströms syndrom, Ushers syndrom och röda hund (rubella). Många av de döv-blinda syndromen är ovanliga tillstånd och för de drabbade individerna kan det ibland vara svårt att bli förstådd, både i mötet med människor i vardagen, men också i mötet med vården och samhället i stort.

Målet med våra projekt är att beskriva och definiera näthinnans funktion vid olika döv-blinda syndrom. I begreppet döv-blinda syndrom har vi innefattat sjukdomar som leder till både syn- och hörselnedsättning, där syn- och hörselhandikappet kan vara det enda symtomet eller en del av en komplex sjukdomsbild. De sjukdomar som finns med i våra arbeten är Alströms syndrom, Ushers syndrom, Cockaynes syndrom, mucopolysackaridos och rubella.

## *Alströms syndrom*

Alströms syndrom är en sjukdom som ärvs autosomalt recessivt och som orsakas av en mutation i *ALMS1* genen. Den exakta förekomsten är osäker, men det finns något mer än 450 beskrivna fall i världen sedan syndromet beskrevs första gången 1959 av Alström och hans medarbetare. Kännetecknande för syndromet är tidigt debuterande hjärtmuskelsjukdom (kardiomyopati), tilltagande synnedättning, tilltagande hörselnedsättning, och övervikt. Andra symtom som är vanliga är astma, återkommande luftvägsinfektioner, leversvikt, njursvikt, och flertalet metabola störningar såsom

diabetes och nedsatt funktion i sköldkörteln. Bland annat låga nivåer av tillväxthormon leder till kortväxthet och skolios. Hudåkommor kan förekomma, tex fläckvis hårfall (alopeci). De flesta utvecklar med ökad ålder en tilltagande hjärtsvikt och njursvikt.

Synnedstättningen vid Alströms syndrom beror på en retinal degeneration (degeneration av näthinna) där tapparna drabbas före stavarna (tapp-stav dystrofi). Ibland förekommer grå starr. De första kliniska symtomen är ofta ögondarr (nystagmus), ljuskänslighet (fotofobi) och nedsatt synskärpa. Degenerationen av näthinna progredierar snabbt och de flesta blir blinda i tonåren.

### *Ushers syndrom*

Ushers syndrom är en grupp av sjukdomar som ärvs autosomalt recessivt. Förekomsten av Ushers syndrom är mellan 3.5-6.2 per 100 000. Ushers syndrom är orsaken till mer än 50% av all dövblindhet och 3-6% av medfödd dövhet. Charles Usher, som syndromet är uppkallat efter, beskrev medfödd dövhet i kombination med retinitis pigmentosa som ett ärftligt tillstånd 1914. Idag känner man till flera olika mutationer som kan orsaka Ushers syndrom. Molekylärgenetiska studier har kunnat identifiera flertalet av de proteiner som är defekta vid Ushers syndrom, och flera av dessa proteiner uttrycks bland annat i innerörat, i balansorganet och i näthinna. Ushers syndrom kännetecknas av synnedstättning, hörselnedsättning och i vissa typer av balansstörning.

Ushers syndrom är uppdelat i tre typer baserade på den kliniska bilden. Ushers syndrom typ 1 karakteriseras av en djup medfödd hörselnedsättning, en snabbt progredierande synnedstättningen som debuterar i barndomen, och uttalade balanssvårigheter. Vid Ushers typ 2 är hörselnedsättningen medfödd men måttlig, synnedstättningen debuterar vanligen i tonåren och det förekommer inga balanssvårigheter. Vid Ushers typ 3 förekommer alla tre kardinalsymtomen, med varierande debut och progress.

Efterhand som gendefekterna kopplade till Ushers syndrom har klarlagts, har de tre kliniska typerna delats upp i flertalet genetiska subtyper (Usher 1B, 2A, 3A etc). Idag är elva genetiska subtyper klassificerade.

Synnedstättningen vid Ushers syndrom beror på en retinal degeneration där stavarna drabbas före tapparna (stav-tapp dystrofi) och grå starr. Första symtomet på en synpåverkan är ofta nedsatt mörkerseende som hos barnen kan yttra sig som mörkerrädsla. Efterhand som den retinala degenerationen progredierar utvecklas en inskränkning av synfälten och en nedsatt synskärpa.

### *Cockaynes syndrom*

Cockaynes syndrom är en sjukdom som ärvs autosomalt recessivt och som orsakas av en mutation i *ERCC6* genen (75% av fallen) eller en mutation i *ERCC8* genen (25% av fallen). Ungefär 2 av 1 000 000 nyfödda i USA och Europa föds med Cockaynes

syndrom. Karakteristika vid Cockaynes syndrom är kortväxthet och utseende av för tidigt åldrande. Andra utmärkande drag är tillväxtsvårigheter, litet huvud (microcefali), hörselnedsättning, synnedsättning, karies, skelettdeformiteter och försämrad utveckling av nervsystemet med progredierande neurologiska symtom.

Patologin bakom synnedsättningen vid Cockaynes syndrom varierar. Orsakerna kan vara medfödda såsom till exempel anläggningsrubbningar med djupt indragna ögon (enoftalmus), små ögon (microftalmus) eller medfödd grå starr. Andra orsaker är till exempel en successiv förtvining (atrofiering) av regnbågshinnan, synnerven och näthinnan (retinal degeneration). Symtomen varierar med den bakomliggande patologin, men vanligt är ljuskänslighet, ögondarr och skelning.

Cockaynes syndrom (CS) är indelat i tre kliniska typer. CS typ I är den klassiska formen med symtom vid ett till två års ålder och förväntad livslängd cirka tio till tjugio år. Vid CS typ II är symtomen mer uttalade och uppenbara redan vid födseln, dessa barn blir sällan mer än sju år gamla. CS typ III är den mildaste formen med debut senare i barndomen.

### *Mucopolysackaridos*

Mucopolysackaridos är en grupp av sjukdomar som ärvs autosomt recessivt och som orsakas av en mutation in *IDUA* genen. Förekomsten av mucopolysackaridos uppskattas till 1 på 100 000 nyfödda. Den kliniska bilden har stor variation, flera organ drabbas och sjukdomen har ett progressivt förlopp. Symtomen omfattar anläggningsrubbning av ansiktet med deformerad ansiktsform, andra skelettdeformiteter, förstörd lever, hjärklaffssjukdom, obstruktiv lungsjukdom, mental retardation, bråck, hörselnedsättning och synnedsättning. Synen påverkas dels av disigheter i hornhinnan, och dels av retinal degeneration. Svullnad av synnerven kan förekomma.

Mucopolysackaridos (MPS) är uppdelad i tre huvudtyper: Hurlers syndrom (MPS 1H), Hurler-Scheies syndrom (MPS 1H/S), och Scheies syndrom (MPS 1S). Vid Hurlers syndrom har barnen inga symtom vid födseln, de utvecklas under de första levnadsåren och barnen blir sällan över tio år gamla. Scheies syndrom är den mildaste typen med symptomutveckling efter fem års ålder och ibland normal förväntad livslängd. Hurler-Scheies syndrom har en klinisk bild mitt emellan de båda andra typerna.

### *Rubella*

Rubella infektion (röda hund) orsakas av rubella viruset. Rubella viruset identifierades 1969 och samma år tillverkades det första vaccinet. För ett par decennier sedan var rubella infektion den vanligaste orsaken till medfödd dövblindhet, men incidensen har idag minskats till ett minimum i länder med vaccinationsprogram. Rubella viruset kan överföras från moder till barn under hela graviditeten. En infektion tidigt i graviditeten kan leda till missfall eller grava skador hos fostret.

Termen medfött rubella syndrom (congenital rubella syndrome, CRS) används för de symtom som en infektion med rubella virus under fosterstadiet kan leda till. De vanligaste följderna är medfödd hörselnedsättning, skador på ögonen, mental retardation och hjärtproblem. Det finns en mängd andra symtom såsom tandskador, leverinflammation och hjärtmuskelinflammation. En del symtom uppkommer senare i livet, till exempel diabetes, ämnesomsättningsrubbing, neurologiska och psykosociala problem.

Förändringarna i ögonen kan vara antingen medfödda eller manifesteras sig senare i livet. Vanligast är utvecklande av grå starr, därefter anläggningsrubbing med för små ögon (microftalmus) och pigmentförändringar i näthinnan (pigment retinopati). Pigment retinopatin kan finnas i ena eller båda ögonen och karakteriseras av ett salt-och-peppar utseende i gula fläcken. Man tror att pigmentförändringarna ligger i det retinala pigment epitelet. Näthinnan och åderhinnan har inga förändringar och näthinnans funktion är normal. Mer ovanliga förändringar i ögonen till följd av rubella infektion är grön starr och grumlingar i hornhinnan.

### *Metoder*

Synfunktionen är mångfacetterad och påverkas av förändringar i allt från optiken i ögat (framför allt lins och hornhinna) till högre visuella centra i hjärnan. Den totala synfunktionen kan vara svår att värdera och synhandikappet kan vara svårt att definiera, framför allt hos barn med andra handikapp. För att kunna beskriva och definiera näthinnans funktion har vi provat synskärpan och gjort synfältsundersökning när så varit möjligt, dessa undersökningar är subjektiva undersökningsmetoder som kräver patientens medverkan. Vidare har samtliga patienter undersökts med ff-ERG och i förekommande fall med mf-ERG och OCT, dessa undersökningar är objektiva och kräver inte medverkan av patienten. Ff-ERG mäter näthinnans totala funktion, i hela dess utbredning. Genom att använda olika former av ljusstimulering kan tapparnas totala funktion, stavarnas totala funktion och deras gemensamma totala funktion värderas med ff-ERG. Mf-ERG är en mätmetod där enbart näthinnans centrala delar stimuleras och det elektrofysiologiska svaret motsvarar tapparnas funktion i gula fläcken. OCT är en undersökning som lättast kan beskrivas som en ultraljudsundersökning, fast istället för ljud sändes ljus in i ögat och av det reflekterade ljuset skapas en två eller tre dimensionell bild av näthinnans lager. Med hjälp av OCT kan näthinnans struktur och tjocklek värderas.

### *Resultat*

Ff-ERG på barn i narkos är omdebatterat. Som kontrollgrupp undersökte vi femtioått barn utan retinal sjukdom, och ff-ERG i narkos visade normala värden i tre åldersgrupper: 5-12 månader, 1-4 år och 5-10 år. Hos barn yngre än ett år kan man se lätt reducerade amplituder för både tappar och stavar. Resultaten bekräftar att ff-ERG i narkos är en tillförlitlig metod.

Tre patienter med Alströms syndrom (paper I), undersöktes upprepade gånger mellan fyra månader och tolv års ålder, och ff-ERG visade en tapp-stav degeneration hos samtliga. De tre patienterna uppvisade överraskande skillnader i ålder vid symtomdebut, grad av funktionsnedsättning och i hur snabbt den retinala degenerationen försämrades. Skillnaden förelåg även, och var överensstämmande med ff-ERG, i synskärpa, synfält, färgseende och i näthinnans makroskopiska utseende. Patienten (patient 2), med den bäst bevarade synfunktionen, hade vid tio års ålder ett normalt makroskopiskt utseende av näthinnan, lätt nedsatt tappfunktion, lätt försämrad stavfunktion, stabil synskärpa och bevarade synfält.

Liksom vid Alströms syndrom kunde vi se vid undersökning av fjorton barn (2-10 år gamla) med Ushers syndrom (paper II) att ett normalt makroskopiskt utseende av näthinnan inte utesluter en retinal degenerativ sjukdom. Ff-ERG i narkos bekräftade en bevarad stavfunktion hos barn med Ushers syndrom upp till fyra års ålder. Alla barnen hade i olika grad en bevarad tappfunktion, varav ett par barn hade nästan normal tappfunktion. Upprepade undersökningar visade att tappfunktionen kunde vara bevarad ändå upp i tonåren, både vid undersökning med ff-ERG och med mf-ERG. Progressen varierade mellan de olika Usher-typerna. Den retinala funktionen försämrades snabbast hos barnen med Usher typ 1. Bästa bevarad retinal funktion hade barnet med Usher 3A där upprepade undersökningar upp till arton års ålder påvisade en mindre uttalad och en långsamt progredierande stav-tapp degeneration.

Skillnaden i fenotyp (hur en sjukdom uttrycks kliniskt) mellan olika Usher-typer förelåg även vid undersökning av tretton patienter mellan tolv och sextiosex års ålder med Ushers syndrom (paper III). Vi kunde fastställa en skillnad i graden av stav-tapp degenerationen totalt sett och en skillnad i gula fläckens funktion både mellan olika genotyper av Ushers syndrom och mellan syskon med samma genotyp. Bland Usher typ 1 patienterna, som inte var släkt med varandra, fann vi bevarad central synfunktion i gula fläcken upp till trettiofem års ålder hos en patient med Usher 1D, vilket var något oväntat. Bland syskonparen utmärkte sig syskonen med Usher 2C. Två av dem hade en uttalad stav-tapp degeneration, medan det tredje syskonet hade en måttligt sänkt stav- och tappfunktion med en väl bevarad funktion i gula fläcken.

Resultaten från undersökningarna av Usher patienterna illustrerar väl komplexiteten i den fenotypiska och genotypiska variabiliteten och relationen dem emellan.

Det finns en mängd olika sjukdomar och syndrom som kan orsaka kombinerad syn- och hörselnedsättning. Flera av syndromen omfattar även andra handikapp, både mentala och fysiska, och hos dessa patienter kan det vara mycket svårt att värdera synfunktionen. Vi har undersökt fyra barn med ovanliga sjukdomar. Barnen hade Alströms syndrom, Cockaynes syndrom, MPS 1H/S, eller medfött rubella syndrom och ff-ERG påvisade olika typer av retinal degeneration vid de olika syndromen (paper IV). Barnet med Alströms syndrom hade en tapp-stav degeneration, barnet med Cockaynes syndrom en



stav-tapp degeneration och barnet med MPS 1H/S en generaliserad degeneration av både stavar och tappar. Barnet med rubella retinopati hade en normal retinal funktion. Vid ögonbottenundersökning hade dessa fyra barn inga eller smärre förändringar i näthinnans utseende. Ingen uppvisade de klassiska pigmentförändringar som kan ses vid retinitis pigmentosa. Barnet med rubella retinopati hade det klassiska ”salt och peppar” utseendet i gula fläcken.

Genomförda studier visar att en normal ögonbottenbild inte utesluter retinal degenerativ sjukdom. Ff-ERG i narkos på små barn är en tillförlitlig metod. Med ff-ERG kan vi särskilja olika typer av retinal degeneration. Vid tapp-stav degeneration, som förekommer vid till exempel Alströms syndrom, är barnet vanligen ljuskänsligt, synskärpan försämras tidigt i sjukdomsförloppet medan synfälten kan vara bevarade under lång tid. Vid stav-tapp degeneration, som förekommer vid till exempel Ushers syndrom, drabbas patienten tidigt av nedsatt mörkerseende och inskränkning av synfälten medan synskärpan kan vara bra under lång tid, även vid utbredd retinal degeneration.

För patienten innebär typen av retinal degeneration olika symtom och olika svårigheter i vardagen. Oavsett om syn- och hörselnedsättningen är enda symtomen eller del av en komplex sjukdomsbild är diagnostisering och karaktärisering av den retinala degenerationen med ff-ERG väsentlig – för habilitering av synhandikappet och som hjälp i diagnosticering och särskiljande mellan olika döv-blinda syndrom. Ff-ERG i kombination med genetisk screening utgör värdefulla undersökningsmetoder för säkerställande av diagnos och värdering av prognos hos barn och vuxna med döv-blinda syndrom.

# Acknowledgements

I would like to thank:

All the patients who have been willing to participate, despite the inconvenience it has meant for them to travel far, sometimes with an attendant, and taking a day off from work.

My supervisor, Professor Sten Andréasson, for having so much patience with me, for being available every hour of the day, and for good advice in all matters.

My co-supervisor, Vesna Ponjavic M.D., Ph.D., for being a brilliant scientist, always contributing with methodical and structural thinking. And for “always being there” when needed.

Professor Claes Möller, co-author, for support, cooperation, and providing essential information and contact with patients included in this thesis.

Professor William Kimberling, co-author, for cooperation and help with genetic analysis regarding patients with Usher syndrome.

Professor Jan Marshall and co-workers at the Jackson laboratory, co-authors, for help with genetic analysis regarding patients with Alström syndrome.

Boel Nilsson and Ing-Marie Holst of the Department of Ophthalmology, Lund University Hospital, for skillful technical assistance in examination of the patients and for help with all kinds of practical things.

Lena Mitkiewicz, secretary at the Department of Ophthalmology, Lund University Hospital, for assistance and for never complaining about work that needed to be done.

Fredrik Ghosh M.D., Ph.D., for introducing me to “the world of science”, and for providing excellent illustrations.

Björn Hammar M.D., Ph.D., for being a good colleague and friend.

Staff, colleagues and friends at the Department of Ophthalmology, Lund University Hospital, for putting up with me through the years.

Louise Walther, my friend.

Hedda, Hanny, and Hampus, my “cream-children”, for brighten up my day.

Ida and Olof, my children, for making the sun rise every morning.

Most important, Peter, for bringing me back to life, and for making it worthwhile to get up in the morning.

# References

- Ahmed ZM, Riazuddin S, Riazuddin S, et al. The molecular genetics of Usher syndrome. *Clin Genet* 2003; 63:431-444.
- Alström CH, Hallgren B, Nilsson LB, et al. Retinal degeneration combined with obesity, diabetes mellitus and neurogenous deafness: a specific syndrome (not hitherto described) distinct from the Laurence-Moon-Bardet-Biedl syndrome: a clinical, endocrinological and genetic examination based on a large pedigree. *Acta Psychiatr Neurol Scand*. 1959;34(1)(suppl 129):1-35.
- Andréasson S, Sandberg MA, Berson EL. Narrow-band filtering for monitoring low-amplitude cone electroretinograms in retinitis pigmentosa. *Am J Ophthalmol*. 1988;105(5):500-503.
- Andréasson S, Tornqvist K, Ehinger B. Full-field electroretinograms during general anesthesia in normal children compared to examination with topical anesthesia. *Acta Ophthalmol (Copenh)*. 1993;71(4):491-495.
- Andréasson S, Ponjavic V. Full-field electroretinograms in infants with hereditary tapetoretinal degeneration. *Acta Ophthalmol Scand Suppl*. 1996; 219:19-21.
- Andréasson S. Developments in molecular genetics and electrophysiology in inherited retinal disorders. *Acta Ophthalmol Scand*. 2006;84:161-168.
- Arnold JJ, McIntosh EG, Martin FJ, et al. A fifty year follow up of ocular defects in congenital rubella: Late ocular manifestations. *Aust NZ J Ophthalmol*. 1994;22:1-6.
- Ashworth JL, Biswas S, Wraith E, et al. The ocular features of the mucopolysaccharidoses. *Eye (Lond)*. 2006 May;20(5):553-563.
- Badano JL, Mitsuma N, Beales P, et al. The ciliopathies: an emerging class of human genetic disorders. *Annu Rev Genomics Hum Genet*. 2006;22(7):125-148.
- Bayazit YA, Yilmaz M. An overview of hereditary hearing loss. *ORL J Otorhinolaryngol Relat Spec*. 2006; 68:57-63.
- Bell J. Retinitis pigmentosa and allied diseases. In: Pearson K, ed. *The Treasury of Human Inheritance*. London: Cambridge Press; 1922:2:1-29.
- Berson EL. Retinitis pigmentosa. The Friedenwald lecture. *Invest Ophthalmol Vis Sci*. 1993;5:1659-1676.
- Blanks JC. Morphology and topography of the retina. In *Retina*. Ryan SJ, editor 2001, Mosby Inc.:St Louis:32-50.
- Boughman JA, Vernon M, Shaver KA. Usher syndrome: definition and estimate of prevalence from two high-risk populations. *J of Chronic Dis*. 1983;36(8):595-603.
- Caruso RC, Kaiser-Kupfer MI, Muenzer J, et al. Electroretinographic findings in the mucopolysaccharidoses. *Ophthalmology*. 1986 Dec;93(12):1612-1616.
- Chan A, Duker JS, Ko TH, et al. Normal macular thickness measurements in healthy eyes using Stratus Optical Coherence Tomography. *Arch Ophthalmol*. 2006;124:193-198.
- Clarke LA. Mucopolysaccharidosis Type I. *Gene Reviews*. <http://www.ncbi.nlm.nih.gov/books/NBK1162/>. Oct 31, 2002. Updated July 21, 2011.
- Cleaver JE, Thompson LH, Richardson AS, et al. A summary of mutations in the UV-sensitive disorders: xeroderma pigmentosum, Cockayne syndrome, and trichothiodystrophy. *Hum Mutat*. 1999;14(1):9-22. Review.
- Collins ML, Traboulsi EI, Maumenee IH. Optic nerve head swelling and optic atrophy in the systemic mucopolysaccharidoses. *Ophthalmology*. 90 Nov;97(11):1445-1449.
- Cramers P, Verhoeven EE, Filon AR, et al. Impaired Repair of Ionizing Radiation-Induced DNA Damage in Cockayne Syndrome Cells. *Radiat Res*. 2011 Apr;175(4):432-443.
- Dacheux RF, Raviola E. Functional anatomy of the neural retina. In *Principles and practice of ophthalmology*. Albert & Jakobiec's, editor 2000, Sanders Co:Philadelphia:1601-1624.

- Damen GW, Krabbe PF, Kilsby M, et al. The Usher lifestyle survey: maintaining independence: a multi-centre study. *Int J Rehabil Res.* 2005;28(4):309–320.
- Dammeyer J. Congenital rubella syndrome and delayed manifestations. *Int J Pediatr Otorhinolaryngol.* 2010 Sep;74(9):1067-1070.
- Davenport SLH, Omenn GS. The heterogeneity of Usher syndrome [abstract]. In: Littenfield JW, Ebbing FJG, Henderson JW, eds. *Fifth International Conference on Birth Defects.* Amsterdam: Excerpta Medica; 1977: 87-88.
- Dollfus H, Porto F, Caussade P et al. Ocular Manifestations in the Inherited DNA Repair Disorders. *Surv Ophthalmol.* 2003 Jan-Feb;48(1):107-122.
- Duszak RS. Congenital rubella syndrome – major review. *Optometry.* 2009;80:36-43.
- Dyer DS, Wilson ME, Small KW, et al. Alström syndrome: a case misdiagnosed as Bardet-Biedl syndrome. *J Pediatr Ophthalmol Strabismus.* 1994;31(4):272-274.
- Ferrari S, Ponzin D, Ashworth JL, et al. Diagnosis and management of ophthalmological features in patients with mucopolysaccharidosis. *Br J Ophthalmol.* 2011 May;95(5):613-619.
- Flores-Guevara R, Renault F, Loundon N, et al. Usher syndrome type 1: early detection of electroretinographic changes. *Eur J Paediatr Neurol.* 2009;13(6):505–507.
- Freij BJ, South MA, Sever JL. Maternal rubella and the congenital rubella syndrome. *Clin Perinatol.* 1988 Jun;15(2):247-257.
- Friedman TB, Schultz JM, Ahmed ZM, et al. Usher syndrome: hearing loss with vision loss. *Adv Otorhinolaryngol.* 2011;70:56-65.
- Gregg NM. Congenital cataract following German measles in the mother. *Transactions of the Ophthalmological Society of Australia.* 1941:35-46.
- Goode RL, Rafaty FM, Simmons B. Hearing loss in retinitis pigmentosa. *Pediatrics.* 1967;40(5):875-880.
- Hallgren B. Retinitis pigmentosa combined with congenital deafness; with vestibulo-cerebellar ataxia and mental abnormality in a proportion of cases: a clinical and genetical study. *Acta Psychiatr Scand Suppl.* 1959;34:5-101.
- Holder GE, Brigell M, Hawlina M, et al. Standard for pattern electroretinography. *Doc Ophthalmol.* 2007;114:111–116.
- Holmgren F. Metod att objectivera effecten af ljusintyck på retina. *Uppsala Läkaref. Förh.* 1865;1:184-198.
- Hood DC, Graham N. Threshold fluctuations on temporally modulated backgrounds: A possible physiological explanation based upon a recent computational model. *Vis Neurosci.* 1998;15(5):957-967.
- Hood DC, Bach M, Brigell M, et al. ISCEV guidelines for clinical multifocal electroretinography (2007 edition). *Doc Ophthalmol.* 2008;116:1–11.
- Hope CI, Bunday S, Proops D, et al. Usher syndrome in the city of Birmingham: prevalence and clinical classification. *Br J Ophthalmol.* 1997; 81:46-53.
- Keats BJ, Corey DP. The Usher syndromes. *Am J Med Genet.* 1999;89:158-166.
- Keats BJ. Genes and syndromic hearing loss. *J Commun Dis.* 2002;35:355-366.
- Kimberling WJ, Weston MD, Möller C, et al. Localization of Usher syndrome type II to chromosome 1q. *Genomics.* 1990;7:245-249.
- Kimberling WJ. Clinical and genetic heterogeneity of Usher syndrome. *Audiol Med.* 2003; 1: 67-70.
- Kremer H, van Wijk E, Märker T, et al. Usher syndrome: molecular links of pathogenesis, proteins and pathways. *Hum Mol Genet.* 2006;15:15SpecNo2:R262–270.
- Leung CK, Cheung CY, Weinreb RN, et al. Comparison of macular thickness measurements between time domain and spectral domain optical coherence tomography. *Invest Ophthalmol Vis Sci.* 2008;49(11):4893–4897.
- Liebreich R. Abkunft aus Ehen unter Blutverwandten als Grund von Retinitis Pigmentosa. *Dtsch Arch Klin Med.* 1861;13:53-55.
- Marmor MF, Hood DC, Keating D, et al. International Society for Clinical Electrophysiology of Vision: Guidelines for basic multifocal electroretinography (mfERG). *Doc Ophthalmol* 2003;106:105-115.
- Marmor MF, Fulton AB, Holder GE, et al. International Society for Clinical Electrophysiology of Vision. ISCEV Standard for full-field clinical electroretinography (2008 update). *Doc Ophthalmol.* 2009 Feb;118(1):69-77.

- Marshall JD, Ludman MD, Shea SE, et al. Genealogy, natural history, and phenotype of Alström syndrome in a large Acadian kindred and three additional families. *Am J Med Genet.* 1997;73(2):150-161.
- Marshall JD, Bronson RT, Collin GB, et al. New Alström syndrome phenotypes based on the evaluation of 182 cases. *Arch Intern Med.* 2005;165(6):675-683.
- Marshall JD, Hinman EG, Collin GB, et al. Spectrum of ALMS1 variants and evaluation of genotype-phenotype correlations in Alström syndrome. *Hum Mutat.* 2007;28(11):1114-1123.
- Marshall JD, Beck S, Maffei P, et al. Alström syndrome. *Eur J Hum Genet.* 2007 Dec;15(12):1193-1202.
- Marshall JD, Paisey RB, Carey C, et al. Alström syndrome. *Gene Reviews.* <http://www.ncbi.nlm.nih.gov/books/NBK1267/>. Feb 7, 2003. Updated June 8, 2010.
- Mets MB, Young NM, Pass A, et al. Early diagnosis of Usher syndrome in children. *Trans Am Ophthalmol Soc.* 2000; 98: 237-245.
- Millán JM, Aller E, Jaijo T, et al. An Update on the Genetics of Usher Syndrome. *J Ophthalmol.* 2011;2011:417217.
- Moore D, Connock MJ, Wraith E, et al.. The prevalence of and survival in Mucopolysaccharidosis I: Hurler, Hurler-Scheie and Scheie syndromes in the UK. *Orphanet J Rare Dis.* Sep 16 2008;3:24.
- Moutakis K, Stigmar G, Hall-Lindberg J. Using the KM visual acuity chart for more reliable evaluation of amblyopia compared to the HVOT method. *Acta Ophthalmol Scand.* 2004 Oct;82(5):547-551.
- Nance MA, Berry SA. Cockayne syndrome: review of 140 cases. *Am J Med Genet.* 1992 Jan 1;42(1):68-84.
- Neilan EG. Cockayne Syndrome. *Gene Reviews.* <http://www.ncbi.nlm.nih.gov/books/NBK1342/>. Dec 28, 2000. Updated March 7, 2006.
- Neufeld EF, Muenzer J. The mucopolysaccharidoses. In: Scriver, C. R., Beaudet, A. L., Sly, W. S., Valle, D. (eds.) *The Metabolic & Molecular Bases of Inherited Disease.* Vol. III. (8th ed.) New York: McGraw-Hill 2001.
- Online Mendelian Inheritance in Man. OMIM™. Available at: <http://www.ncbi.nlm.nih.gov/omim/>.
- Pastores GM, Meere PA. Musculoskeletal complications associated with lysosomal storage disorders: Gaucher disease and Hurler-Scheie syndrome (mucopolysaccharidosis type I). *Curr Opin Rheumatol.* 2005 Jan;17(1):70-78.
- Pastores GM. Musculoskeletal complications encountered in the lysosomal storage disorders. *Best Pract Res Clin Rheumatol.* Oct 2008;22(5):937-947.
- Paunescu LA, Schuman JS, Price LL, et al. Reproducibility of nerve fiber thickness, macular thickness, and optic nerve head measurements using Stratus OCT. *Invest Ophthalmol Vis Sci.* 2004;45:1716-1724.
- Pennings RJ, Huygen PL, Orten DJ, et al. Evaluation of visual impairment in Usher syndrome 1b and Usher syndrome 2a. *Acta Ophthalmol Scand.* 2004;82(2):131-139.
- Petit C. Usher syndrome: from genetics to pathogenesis. *Annu Rev Genomics Hum Genet.* 2001; 2: 271-297.
- Rapin I, Lindenbaum Y, Dickson DW, et al. Cockayne syndrome and xeroderma pigmentosum. *Neurology.* 2000 Nov 28;55(10):1442-1449.
- Reiners J, Nagel-Wolfrum K, Jürgens K, et al. Molecular basis of human Usher syndrome: deciphering the meshes of the Usher protein network provides insights into the pathomechanisms of the Usher disease. *Exp Eye Res.* 2006;83:97-119.
- Rivolta C, Sweklo EA, Berson EL, et al. Missense mutation in the USH2A gene: association with recessive retinitis pigmentosa without hearing loss. *Am J Hum Genet.* 2000;66:1975-1978.
- Robson JG, Frishman LJ. Dissecting the dark-adapted electroretinogram. *Doc Ophthalmol.* 1998;95(3-4):187-215.
- Rosenberg T, Haim M, Hauch AM, et al. The prevalence of Usher syndrome and other retinal dystrophy-hearing impairment associations. *Clin Genet.* 1997;51:314-321.
- Saihan Z, Webster AR, Luxon L, et al. Update on Usher syndrome. *Curr Opin Neurol.* 2009;22:19-27. Review.
- Sandberg MA, Rosner B, Weigel-DiFranco C, et al. Disease course in patients with autosomal recessive retinitis pigmentosa due to the USH2A gene. *Invest Ophthalmol Vis Sci.* 2008;49(12):5532-5539.

- Sutter EE, Tran D. The field topography of ERG components in man—I. The photopic luminance response. *Vision Res.* 1992;32(3):433-446.
- Tamagawa Y, Ishikawa K, Ishida T, et al. Phenotype of DFNA11: a nonsyndromic hearing loss caused by a myosin VIIA mutation. *Laryngoscope.* 2002;112:292-297.
- Titomanlio L, De Brasi D, Buoninconti A, et al. Alström syndrome: intrafamilial phenotypic variability in sibs with a novel nonsense mutation of the ALMS1 gene. *Clin Genet.* 2004;65(2):156-157.
- Tremblay F, LaRoche RG, Shea SE, et al. Longitudinal study of the early electroretinographic changes in Alström syndrome. *Am J Ophthalmol.* 1993;115(5):657-665.
- Tuo J, Jaruga P, Rodriguez H, et al. Primary fibroblasts of Cockayne syndrome patients are defective in cellular repair of 8-hydroxyguanine and 8-hydroxyadenine resulting from oxidative stress. *Faseb J.* 2003 Apr;17(6):668-674.
- Tzetzis D, Hamilton R, Robinson PH, et al. Negative ERGs in mucopolysaccharidoses (MPS) Hurler-Scheie (I-H/S) and Hurler (I-H)-syndromes. *Doc Ophthalmol.* 2007 May;114(3):153-158.
- Usher C. On the inheritance of retinitis pigmentosa, with notes of cases. *R Lond Ophthalmol Hosp Rep.* 1914; 19:130-236.
- van Oosterwijk MF, Versteeg A, Filon R, et al. The sensitivity of Cockayne's syndrome cells to DNA-damaging agents is not due to defective transcription-coupled repair of active genes. *Mol Cell Biol.* 1996 Aug;16(8):4436-4444.
- Vernon M. Sociological and psychological factors associated with hearing loss. *J of Speech and Hearing Res.* 1969;12(3):541-563.
- Von Graefe A. Vereinzelt Beobachtungen und Bemerkungen: Exzeptionelles Verhalten des Gesichtsfeldes bei Pigmentenartung der Netzhaut. *Von Graefes Arch Ophthalmol.* 1858; 4: 250-253.
- Weil D, Kussel P, Blanchard S, et al. The autosomal recessive isolated deafness, DFNB2, and the Usher 1B syndrome are allelic defects of the myosin VIIA gene. *Nat Genet.* 1997;16:191-193.
- Williams DS. Usher syndrome: animal models, retinal function of Usher proteins, and prospects for gene therapy. *Vision Res.* 2008;48:433-441.
- Wraith JE, Rogers JG, Danks DM. The mucopolysaccharidoses. *Aust Paediatr J.* 1987 Dec;23(6):329-334.
- Young NM, Mets MB, Hain TC. Early diagnosis of Usher syndrome in infants and children. *Am J Otol.* 1996;17:30-34.
- Österberg G. Topography of the layer of cones and rods in the human retina. *Acta Ophthalmol (Copenh).* 1935;13(S6):1-103.

