



LUND UNIVERSITY

Dementia with Lewy bodies - a clinical and neurological approach

Londos, Elisabet

2001

[Link to publication](#)

Citation for published version (APA):

Londos, E. (2001). *Dementia with Lewy bodies - a clinical and neurological approach*. [Doctoral Thesis (compilation), Psychiatry (Lund)]. Psychiatry.

Total number of authors:

1

General rights

Unless other specific re-use rights are stated the following general rights apply:

Copyright and moral rights for the publications made accessible in the public portal are retained by the authors and/or other copyright owners and it is a condition of accessing publications that users recognise and abide by the legal requirements associated with these rights.

- Users may download and print one copy of any publication from the public portal for the purpose of private study or research.
- You may not further distribute the material or use it for any profit-making activity or commercial gain
- You may freely distribute the URL identifying the publication in the public portal

Read more about Creative commons licenses: <https://creativecommons.org/licenses/>

Take down policy

If you believe that this document breaches copyright please contact us providing details, and we will remove access to the work immediately and investigate your claim.

LUND UNIVERSITY

PO Box 117
221 00 Lund
+46 46-222 00 00

**DEMENTIA WITH LEWY BODIES –
A CLINICAL AND NEUROPATHOLOGICAL APPROACH**

From the Department of Psychogeriatrics,
University Hospital, Lund, Sweden

Dementia with Lewy bodies –
a clinical and neuropathological approach

Elisabet Londos



Lund 2001

Elisabet Londos
Printed by Bloms i Lund Tryckeri AB
Lund, Sweden, 2001

“At vide,
hvad man ikke véd,
er dog en Slags
Alvidenhed”

Piet Hein

List of original publications

The thesis is based on the following five papers, referred to in the text by their Roman numerals.

I

Londos E, Passant U, Brun A, Gustafson L.

Clinical Lewy body dementia – the impact of vascular components.

International Journal of Geriatric Psychiatry, 2000;15:49-49

II

Londos E, Passant U, Gustafson L.

Blood pressure and drug treatment in clinically diagnosed Lewy body dementia and Alzheimer's disease.

Archives of Gerontology and Geriatrics, 2000;30:35-46.

III

Londos E, Passant U, Gustafson L, Brun A.

Neuropathological correlates to clinically defined dementia with Lewy bodies

(Accepted for publication in International Journal of Geriatric Psychiatry).

IV

Londos E, Passant U, Brun A, Rosén I, Risberg J, Gustafson L.

Regional cerebral blood flow and EEG in clinically diagnosed dementia with Lewy bodies and Alzheimer's disease

(Manuscript).

V

Londos E, Passant U, Risberg J, Gustafson L, Brun A.

Contribution of other brain pathologies in dementia with Lewy bodies

(Submitted for publication).

Contents

Abbreviations	9
Introduction	
Organic dementias	11
The Lund longitudinal dementia study	12
Epidemiology of dementia	14
Alzheimer´s disease	15
Vascular dementias	18
Frontotemporal dementia	22
Dementia in Parkinson´s disease	24
Dementia with Lewy bodies	26
Diagnostic reflections	44
Aims of the thesis	46
Materials and methods	
Patient sample	47
Representativity of the material	47
Data collection procedure	49
The process of data analysis	50
Clinical criteria	50
Differential diagnostic rating scales	50
Ratings of ADL and dementia - the Katz and Berger indices	51
Regional cerebral blood flow	52
Electroencefalogram	54
Neuropathology	54
Main features of paper I	56
Main features of paper II	57
Main features of paper III	59
Main features of paper IV	60
Main features of paper V	62
Conclusion	64
General summary in Swedish	66
Acknowledgements	69
References	71
Paper I	105
Paper II	117
Paper III	131
Paper IV	151
Paper V	167

Abbreviations

AD	Alzheimer's disease
ADL	Activity of daily living
CT	Computerized tomography
DLB	Dementia with Lewy bodies
DLBD	Diffuse Lewy body disease
EEG	Electroencephalogram
FLD	Frontal lobe degeneration
FTD	Frontotemporal dementia
IS	Ischemic score
LB(s)	Lewy body(ies)
LBD	Lewy body dementia
LBV	The Lewy body variant of Alzheimer's disease
LC	Locus coeruleus
MABP	Mean arterial blood pressure
MID	Multi infarct dementia
MRI	Magnetic resonance imaging
nbM	Nucleus basalis Meynert
NFT	Neurofibrillary tangles
PaD	Parkinson's disease
PSVE	Progressive subcortical vascular encephalopathy
rCBF	Regional cerebral blood flow
SDLT	Senile dementia of Lewy body type
SIWI	Selective incomplete white matter infarction
SPECT	Single photon emission computerized tomography
SN	Substantia nigra
VaD	Vascular dementia

Introduction

Organic dementias

Dementia is a descriptive term derived from the latin “de mens” -without mind- indicating a decline in mental abilities. Dementia is characterized as a “global deterioration of mental functioning in its intellectual, emotional and cognitive aspects” (Mayer-Gross et al., 1969). In ICD-10, dementia is defined as a chronic or progressive syndrome lasting at least 6 months and based on brain disease. Higher mental functions such as memory, learning, judgement, thinking, awareness of the environment, emotional control and motivation are impaired but this impairment occurs in the absence of clouding of consciousness. The diagnosis is further supported by evidence of damage to other higher cortical functions such as dysphasia, dyspraxia and dysgnosia (ICD-10). This deterioration was earlier considered progressive and irreversible. However, clinical experience has changed our views so that it is now accepted that different types of dementia have different clinical courses and prognoses. Dementing disorders may be stationary as well as progressive. It may be possible to prevent, arrest and even to cure some forms (Gustafson, 1985).

However, no mental symptoms are in themselves pathognomonic of any type of dementia. It is the symptom constellation, the timing of their appearance and the clinical course that are important (Gustafson and Passant, 2000). There is usually a mixture of symptoms of which some can be interpreted as primary, related to the organic brain damage and dysfunction, while some may be regarded as secondary, adaptive or insufficiency reactions to the brain disease (Gustafson and Hagberg, 1975). Therefore, a symptom may be interpreted differently in different contexts and the diagnosis of dementia should rely on a broad assessment of both psychiatric and neurological features.

Dementia syndromes may be classified on the basis of the predominant distribution of pathology in the brain, that will also be reflected in the symptomatology. Some disorders mainly involve cortical structures in predominantly one or the other region, some have a more subcortical predominance while others affect both cortical and subcortical structures. Alzheimer’s disease (AD) and fronto temporal dementia (FTD) are the major cortical dementias while progressive supranuclear palsy, Huntington’s disease, Parkinson’s disease (PaD) and Binswanger’s disease are mainly subcortical (Gustafson, 1992).

Several authors have suggested that there is an association between dementia and Lewy bodies as a pathological marker (see below) and the term Dementia with Lewy bodies (DLB) was recommended by a consensus group (McKeith et

al.) in 1996. DLB has been classified as a mixed cortical-subcortical degenerative dementia (Hansen et al., 1990, Neary, 1999).

Dementia diagnosis is traditionally based on cognitive, conative and neurological deficits. The DLB consensus presents a different approach where psychotic symptoms, neurologic disturbances and pharmacological reactions are taken into account and regarded as clinical characteristics. The clinical picture is complex and offers differential diagnostic difficulties. The neuropathological diagnosis has also been debated since different pathological entities overlap.

The Lund longitudinal dementia study

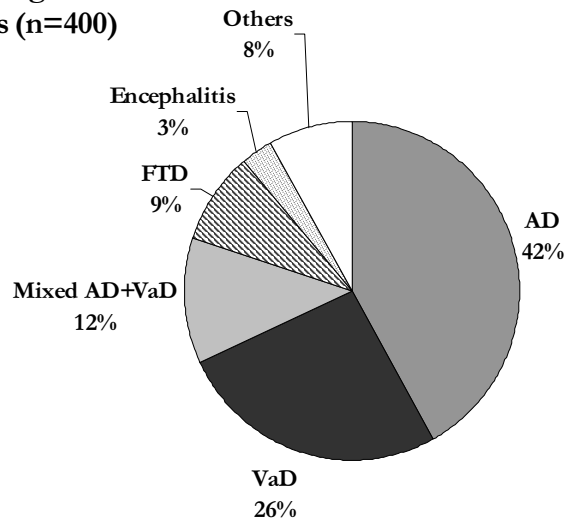
The department of Psychogeriatrics at Lund University Hospital has a long tradition of research in dementia. More than 30 years ago a prospective and longitudinal dementia study started in Lund (Gustafson and Hagberg, 1975, Brun and Gustafson, 1993). The project, still in progress, is based on multi and interdisciplinary co-operation between departments with an interest in different aspects of the neuroscientific field such as old age psychiatry, neuropsychology, neurophysiology, neurochemistry and neuropathology. The initial aim of the longitudinal dementia study was to select patients at an early stage of a dementing illness, to follow these patients prospectively and finally to perform post mortem neuropathological examinations. The purpose was to develop clinical criteria for early recognition and differential diagnosis of specific types of dementia. Over the years the longitudinal project has led to the recognition of the importance of different types of dementia such as frontal lobe degeneration of non Alzheimer type (FLD) (Brun, 1987, Gustafson, 1987), the role of ischemic white matter lesions (Brun and Englund, 1986, Englund et al., 1989) and hemodynamic factors in both degenerative and vascular dementias (VaD) (Passant et al., 1996). The results of the project have contributed to the description of the degenerative and clinical pattern in dementia of Alzheimer type (Brun and Gustafson, 1976, Brun and Gustafson, 1978, Brun and Englund, 1981) and new classifications for degenerative and vascular dementias (Brun and Gustafson, 1988, Gustafson et al., 1990) have been put forward. The longitudinal dementia study has contributed greatly to the development and availability of diagnostic techniques such as regional cerebral blood flow (rCBF) measurements and neuropsychological testing in dementia. It has also shown the importance of clinical diagnosis for the design of treatment and care of patients with dementia (Gustafson et al., 1995).

The neuropathological panorama of the first 400 dementia cases in the project which came to autopsy is depicted below (Brun and Gustafson, 1993) (Fig 1). AD was found in 42%, VaD in 26%, Mixed VaD and AD in 12%, FTD in 9%,

encephalitis in 3% and other more or less specified diseases including brain tumours in 8%.

Fig 1. Neuropathological diagnoses in consecutive dementia cases (n=400)

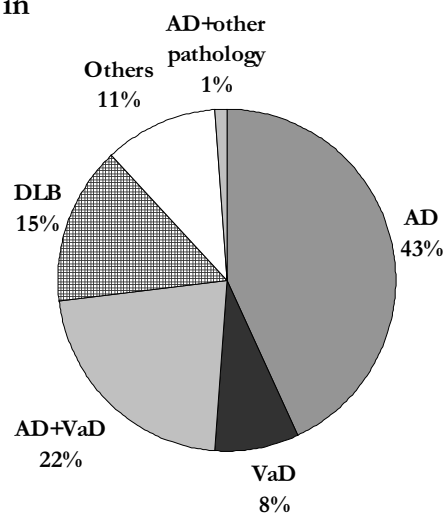
Brun et al., 1993



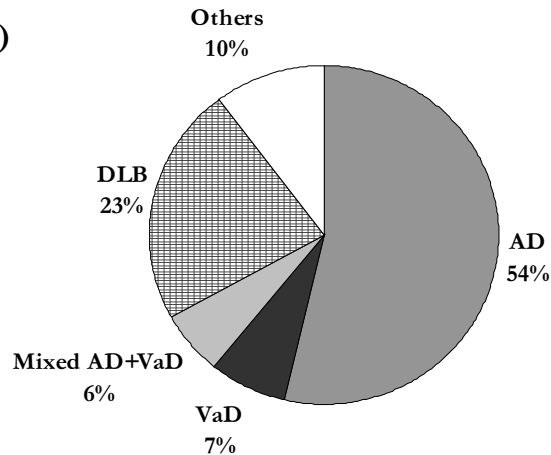
Compared to neuropathological findings in consecutive dementia cases from Jellinger et al., 1996 (Fig 2) and Perry et al., 1991 (Fig 3), the prevalence of AD and other pathologies are similar while FTD and VaD are more prevalent in our study. DLB is not specified in the Lund study. The differences may depend on the varied selection of patients, the age of the patients, the neuropathological technique or genetic factors.

Fig 2. Neuropathological diagnoses in dementia (n=540)

Jellinger, 1997 (modified)



**Fig 3. Neuropathological diagnoses
in dementia (n=89)
Perry et al., 1991 (modified)**



Epidemiology of dementia

The prevalence of dementia increases exponentially with age doubling every 5 years from 1% at 65 years to over 20% at 85 (Jorm et al., 1987). The prevalence of AD is 1-2% in persons aged 65-74 years, 4-5 % in persons aged 75-84 years, and 10-13% in persons over the age of 85 (Fratiglioni, 1996). The prevalence of VaD rises less sharply with age than that of AD. The proportion of VaD among demented varies in different studies between 11 and 45% (Skoog and Aevarsson, 2000). VaD seems to be more prevalent and even more common than AD in Asia and Eastern Europe than in Western countries (Jorm, 2000, Homma and Hasegawa, 2000). The prevalence of FTD is not known. The ratio of FTD compared to AD thus ranges from 1:5 to 1:30 in neuropathological materials (Brun, 1987, Jellinger et al., 1990). In a prospective population based study of FTD, the incidence rates were 1.2/10⁶ (age group 30-40 years), 3.4/10⁶ (age group 40-50 years), 10.7/10⁶ (age group 50-60 years) and 28.0/10⁶ (age group 60-70 years) (Stevens et al., 1995).

PaD affects about 1 in 1000 individuals and the prevalence increases with age (Mutch et al., 1986). Metaanalyses have shown a 35-40% prevalence of dementia in PaD (Brown and Marsden, 1984, Cummings, 1988).

In a community based population in England and Wales the prevalence of DLB, or rather Lewy bodies in demented individuals, was 12% (Esiri, 2001).

The following description of different dementia disorders is aimed at enlightening the various aspects of these diseases that share features with DLB.

Alzheimer's disease

In a lecture in 1906, Alois Alzheimer described a form of dementia which was later to bear his name, Alzheimer's disease. He described a 51-year-old patient, Auguste D, who had shown progressive cognitive impairment with memory disturbance, aphasia, apraxia, disorientation and unpredictable behaviour, hallucinations, delusions and psychosocial incompetence. At necropsy there was cortical atrophy with senile plaques and neurofibrillary tangles (NFT) (Alzheimer, 1907, Maurer et al., 1997).

Historically there has been a distinction between this presenile dementia (onset before 65 years) and late onset, senile dementia of Alzheimer type (SDAT), starting after 65. Today the two forms are mostly grouped together since the important pathological features are the same. There are, however, some pathological (Terry et al., 1981, Hansen et al., 1988) and neurochemical differences (Rossor et al., 1984) as well as differences in symptomatology (Lauter, 1970, Gustafson, 1985, Blennow and Wallin, 1992) between early and late onset AD. The clinical heterogeneity of AD is also reflected in the classification systems DSM and ICD. It has been suggested that a Lewy body variant of AD is to be found among other subgroups (Hansen et al., 1990, Förstl et al., 1993).

Clinical findings

AD is the most common of dementias occurring in 50-60% of all dementing disorders (Tomlinson et al., 1970). This often stated figure must, however, be considered with caution since mixed pathologies are common and the proportion of pathologically confirmed AD is unknown in representative community dwelling samples (Lovestone, 2000). Studies on the symptomatology of AD agree upon a common pattern of cognitive, emotional and neurological symptoms (Sjögren, 1952, Delay and Brion, 1962, Lauter, 1970, Brun and Gustafson, 1976) although this does not exclude an important individual variation concerning both symptoms and the course of the disease. The onset is insidious with a gradual progression of the disease. The characteristic clinical features are cognitive deterioration of temporoparietal type such as memory impairment for recent and remote events, expressive and impulsive dysphasia, dyspraxia, dysgnosia and spatial disorientation. Under optimal conditions the personality and social competence are, comparatively spared. As the disease progresses epi-

sodic confusion, psychotic symptoms (Wragg et al., 1989, Cummings and Victoroff, 1990, Burns et al., 1990a,b, Gustafson and Risberg, 1993) extrapyramidal symptoms (EPS) such as increased muscular tension and bradykinesia (Perusini, 1910, Pearce, 1974, Mölsä et al., 1984, Michell, 1995) and neurological signs such as myoclonia and tonic-clonic epileptic seizures (Perusini, 1910, Sourander and Sjögren 1970, Gustafson, 1987) also appear.

For the clinical diagnosis there are several sets of criteria that can be used depending on tradition and purpose (Gustafson and Nilsson, 1982, NINCDS-ADRDA McKhann, 1984, ICD 10, 1993, DSM IV, 1994). In the diagnostic process, neuropsychological testing and brain imaging techniques support the clinical criteria. EEG shows general slowing with increased delta and theta activity (Johánnesson et al., 1977, Petit et al., 1996). The typical rCBF pattern is temporoparietal blood flow decrease (Ingvar and Gustafson, 1970, Gustafson and Risberg, 1979, Friedland et al., 1983, Jagust et al., 1995) especially early in the course and sometimes structural brain imaging, computerized tomography (CT) and magnetic resonance tomography (MRI), may show general atrophy and atrophy of the hippocampus and the medial temporal lobe (Wilson et al., 1982, Soininen et al., 1982, LeMay et al., 1986, Jobst et al., 1992). White matter changes on MRI are common in AD probably indicating white matter changes of ischemic vascular origin (Englund et al., 1987).

Neuropathology

Macroscopically the brain is atrophic with reduced brain weight and secondary enlargement of the ventricles. The classical Alzheimer changes associated with the dementia are a degeneration of neurones and especially synapses and dendrites, NFT, neuritic plaques, neuronal loss and granulovacuolar degeneration. A topographic pattern of NFT accumulation has been identified (Hirano and Zimmerman, 1962, Brun and Gustafson, 1976, Brun and Englund, 1981, Braak and Braak, 1991). Pathological changes are most severe in the temporal and parietal cortices and in later stages also in the frontal cortex (Lauter, 1970, Brun and Gustafson, 1976, Brun and Englund, 1981, Brun, 1985).

Amyloid angiopathy is often seen in the cerebral vessel walls (Scholz, 1938) and consists of the same protein as that in the senile plaques, β A4-protein (Glenner and Wong, 1986).

On a light microscopical level diffuse white matter changes of the hypoperfusive type, called selective incomplete white matter infarctions (SIWI) are found in over 50% of Alzheimer cases (Brun and Englund, 1986). The white matter pathology is more common in late onset compared to early onset AD. This has been demonstrated both post mortem (Brun and Gustafson, 1976) and in vivo

with CT (Wallin et al., 1989, Blennow et al., 1991). These subcortical white matter lesions have been suggested to relate to hemodynamic factors (Englund et al., 1989).

The neuropathological diagnosis of AD can be based on different diagnostic systems using different basic neuropathological approaches. The grading system described by Brun and Englund (1981), using the semiserial whole brain sectioning technique, is based on the combined effects of semiquantitative grading of plaques, tangles and other histological variables such as gliosis, microvacuolation, and cortical atrophy. The Khachaturian criteria (1985) emphasize the number of neocortical plaques per unit area and CERAD (Mirra et al., 1991) is based on semiquantitative plaque counts. Neither of the last two approaches requires the presence of NFT for the diagnosis of AD. According to the grading system by Braak and Braak (1991), 6 different topographic stages are discernable. In stages I-II, NFT involve the entorhinal-perirhinal cortex, in III-IV the hippocampus and other limbic areas, in stage V the association cortices and in stage VI NFT also occur in the primary sensory cortex. The NIA-Reagan guidelines (1997) combine a semiquantitative assessment of both neuritic plaques and NFT using CERAD and topographic staging and assess the likelihood that the dementia is due to AD as “high, intermediate and low”. An assessment of major coexisting lesions to Alzheimer changes is recommended. According to Newell et al., (1999) the NIA-Reagan criteria “provides a nomenclature framework to begin to understand overlap syndromes and differentiate these from pure AD” since “the relative degree to which Alzheimer neuropathological changes and other present pathologies each contribute to dementia cannot be determined with certainty”.

Several neurotransmitters are reduced in AD. One consistent finding is the failure of cholinergic function (Bowen et al., 1976) both in the cortex (Davies and Maloney, 1976, Perry et al., 1977) and in the nucleus basalis Meynert (nbM) (Davies, 1979, Rossor et al., 1982). The cholinergic neurotransmission is strongly dependent on the function of nbM. Cholinergic neurons from nbM project to the cortex and hippocampus, suggesting an important role of this system in memory, learning (Barthus et al., 1982) and attention (Muir et al., 1992, Levy et al., 2000). Cell numbers are reduced in nbM in AD (Whitehouse et al., 1981). The noradrenergic system in part originating in the locus ceruleus (LC) and located in the dorsolateral pontine tegmentum, seems to play a role in behavioural symptoms and depression in AD (Zweig et al., 1988, Zubenko et al., 1990). Cell loss and pathological changes of LC (Ishii, 1966, Forno, 1978, Bondareff et al., 1982, Mann et al., 1983) are common in AD. The loss of cells

and presence of NFT in serotonergic nuclei have also been reported in AD (Yamamoto and Hirano, 1985, Zweig et al., 1988) with lowered brain serotonin content (D'Amato et al., 1987). The serotonergic neurons originate in nucleus raphe and adjacent nuclear groups and have been linked to emotional disturbances, increased frequency of depressive symptoms and psychosis in AD (Zweig et al., 1988). The substantia nigra (SN) is the principal source of dopaminergic neurons projecting primarily to the striatum. The SN is abnormal in 44-86% of AD cases, (Ditter and Mirra, 1987, Gibb et al., 1989a, Kazee et al., 1995a) with cell loss (Rinne et al., 1986), NFT (Liu et al., 1997) and Lewy bodies (Reyes et al., 1996). Metabolites and other markers of dopamine are reduced in AD, both in postmortem material and living humans (Bowen et al., 1974, Gottfries et al., 1983, Allard et al., 1990). In the cerebrospinal fluid in living AD patients, HVA concentrations were related to the impairment of motor performance and to intellectual disturbances (Bråne et al., 1989). It is generally suggested that dopamine deficiency in different locations correlates to bradyphrenia and bradykinesia (Gaspar et al., 1991) and to cognitive decline (Decker and McGaugh, 1991).

Vascular dementias (VaD)

At the end of the 19th century Alzheimer and Binswanger studied the clinical and pathological heterogeneity of vascular dementia. Kraepelin, in his textbook of 1910, considered cerebral arteriosclerosis to be the major cause of organic dementia. Binswanger (1894) pointed out the relationship between a slowly progressive, subcortical vascular encephalopathy (PSVE), with focal neurological deficits and vascular white matter lesions and Alzheimer further developed the subclassification of VaD into arteriosclerotic brain atrophy, PSVE, dementia apoplectica and perivascular gliosis (Gustafson, 2000). In 1975, Hachinski et al., introduced the term “multi-infarct dementia” (MID) to emphasize the relationship between dementia and multiple cerebral infarcts.

Clinical picture

Dementia is caused by several different cerebrovascular disorders but is currently grouped under the term VaD.

The clinical manifestations of VaD relate to different vascular mechanisms and changes in the brain and have different causes. The patient often has a medical history of cardio-vascular disease and vascular risk factors such as hypertension, diabetes, hyperlipidemia and smoking are common. Focal lesions may

often be confirmed by CT/MRI (Román et al., 1993). Even more prevalent in the elderly patients is diffuse white matter pathology on CT/MRI, which when widespread or focal, although sometimes discrete, speaks in favour of a vascular origin (Englund, 2000). However, this can also be found in non-demented cases (Scheltens et al., 1995), possibly indicating a subclinical condition since the longer the patients are followed the more cerebrovascular lesions are likely to be found (Skoog and Aevarsson, 2000). When several areas of the brain are affected the interpretation of and interplay between symptoms and their relation to brain damage becomes more complex. The clinical features in MID are classically lateralized sensimotor impairment, cognitive impairment and aphasia. The disease onset is often abrupt with a stepwise progression (Hachinski et al., 1975). Small vessel disease, such as Binswanger's disease and lacunar states, on the other hand, often has a slowly progressive clinical picture dominated by motor and cognitive bradykinesia, bulbar signs, incontinence, dysarthria, depression and emotional lability (Babikian and Ropper, 1987, Fischer, 1989, Fredriksson et al., 1992). Often there is also mental slowing, impaired attention, impaired executive functions and memory failure. Neurological status may reveal gait problems with a shuffling small stepped gait and primitive reflexes (Babikian and Ropper, 1987, Fischer, 1989, Wallin et al., 1993, Gustafson and Passant, 2000).

Cerebrovascular diseases in general may also give rise to a wide spectrum of psychiatric manifestations such as delirium (Lipowski, 1990, Gustafson Y et al., 1991, Hénon et al., 1999), dementia, personality change (Bogousslavsky et al., 1988), mood disorders, vascular depression- with greater overall cognitive disability and impairment- (Alexopoulos et al., 1997) and paranoid reactions. Fluctuations with confusional episodes and clouding of consciousness are often seen in VaD and other types of cerebrovascular disease (Mayer-Gross Slater and Roth, 1969, Roth, 1981). Agitated delirium accompanied by visual hallucinosis has been reported in patients with right sided or bilateral temporal vascular lesions and basilar infarcts (Mesulam et al., 1976, Caplan, 1980). The symptoms are related to the localisation and severity of the ischemic lesions but are also dependent on the age of the patient. The parietal lobe symptoms typical for AD, such as dyspraxia, dyscalculia, and dysgraphia may also result from vascular lesions (Benson et al., 1982).

The frontal and fronto-subcortical syndromes may be caused by frontal cortical infarcts, bithalamic infarcts, bilateral caudate infarcts, Binswangers disease and incomplete white matter infarcts in the frontal lobes (Brun, 1987, Pasquier et al., 1995, Riechfield et al., 1987, Jellinger et al., 1964, Brun and Gustafson, 1991a). The fronto-subcortical syndrome is characterized by mental slowness,

which is difficult to differentiate from hypokinesia. In addition it is also characterized by apathy, basal neurological signs such as bilaterally increased reflex activity, pseudobulbar signs and EPS (Wallin et al., 1996).

Clinical PaD may also be due to vascular lesions, “vascular pseudoparkinsonism” or “arterosclerotic parkinsonism”, which is seen in 4-5% of PaD cases (Chang et al., 1992, Jellinger., 1997). Common features in vascular parkinsonism are gait disturbances, absence of tremor and impaired balance with falling tendency. CT and MRI frequently show white matter lesions in these patients (Trenkwalder et al., 1995).

The prevalence of neuropathological white matter pathology in VaD is high (Brun, 1992, Román et al., 1993). Englund et al., (1989) compared the clinical symptoms in neuropathologically defined cases of AD with and without white matter pathology (SIWI). They found that the cases with combined AD and SIWI had a higher prevalence of fluctuations, confusion, vertigo and fainting as well as hallucinosis and frontal signs in general, while temporo-parietal symptoms and tonus increase were less prevalent, compared to what was found in pure AD. Cases with SIWI, alone or in combination with AD also had more cardiovascular signs such as atrial fibrillation, myocardial infarcts, angina pectoris and previous hypertension (Englund et al., 1989) that later in the course of the illness turned into hypotension (Passant, 1996).

Several clinical criteria for VaD have been developed. The most commonly used are the DSM-IV (which do not specify subtypes), the ICD-10 (which presents six subtypes: “acute onset, multi infarct, subcortical, mixed cortical and subcortical, other and unspecified”) and the NINCDS-AIREN criteria (which include cortical VaD, subcortical VaD, Binswanger’s disease and thalamic dementia). The DSM-IV criteria are less restrictive compared to the others (Erkinjuntti, 2000). The commonly used ischemic score (IS) (Hachinski et al., 1975) was originally developed to differentiate between MID and AD.

Neuropathophysiologic classification

The classification of VaD may have different approaches and can be based on the primary vascular aetiology (large, small artery disease, haemorrhages etc), the type of ischemic brain lesion (complete, incomplete, lacunar infarcts etc), the location of brain lesions (cortical, subcortical, both, strategic) or the clinical syndrome (cortical, subcortical, prefrontal-subcortical etc) (Erkinjuntti, 2000).

The subdivision of vascular dementia diseases below was developed in the Lund longitudinal project (Brun and Gustafson, 1988, Brun, 1994a) and forms the basis for the Swedish consensus of dementia diseases (Wallin et al., 1994). The subforms may be pure but are more often mixed (Brun, 1994b).

MID (large vessel dementia) is caused mainly by thromboembolism originating from atherosclerotic lesions in the large vessels resulting in large infarcts involving the cortex, the white matter and central grey and brainstem structures. Complete infarcts are surrounded by wide areas of white matter incomplete infarcts. Tomlinson and colleagues (1970) considered a total infarct volume of about 100 ml as the limit beyond which dementia is a regular sequel. However, much smaller volumes have been reported in VaD, especially when the lesions are bilateral or strategically positioned (strategic infarct dementia, Brun and Gustafson, 1988). Dementia is also more common when infarcts are leftsided, bilateral and involving temporoparietal regions (Ladurner et al., 1982). Small vessel dementia results from obstruction or rather occlusion of vessels of arteriolar size, sometimes due to microembolies from the heart and large vessels but more often due to hypertensive angiopathy. A purely subcortical type is called Binswanger's disease of which lacunar state is a milder variant. It is characterized neuropathologically by lacunar infarcts located in the brain stem and central grey nuclei but also in the frontal white matter, which may give rise to an extensive cortical undermining. To a large extent the white matter change has the character of an incomplete white matter infarct, which can be assumed to evolve due to repeated episodes of ischemia in a penumbra zone around the lacunes. According to Englund et al., (1988) the incomplete white matter infarcts, surround the complete white matter infarcts. This white matter pathology generally covers an area several times larger than the complete infarct. These changes are found in large vessel as well as in small vessel diseases.

Ischaemic-hypoxic dementia is a variant of the same disease as subcortical small vessel dementia. It is caused by disturbances of the systemic circulation eg arrhythmias and hypotension, or hypoxia, often combined with arteriolar narrowing rather than occlusion, and it sometimes emerges in the borderzone between the major cerebral arteries in the cortex (Brun, 1994b).

White matter disease is common in both vascular and degenerative dementias. Sixty per cent of all AD cases (Brun and Englund, 1986) also show white matter ischemic lesions often as selective incomplete white matter infarctions (SIWI). SIWI consist of diffuse white matter attenuation, but not cavitation, with a reduction of both myelin and oligodendroglial cells. It is thought to be due to stenosing small vessel disease confined to the white matter in combination with episodic systemic hypotension.

In the vascular dementias several types of neurotransmitter failure are reported. Gottfries et al., (1994) showed severely reduced serotonin metabolism and activity of cholinacetyltransferase. Dopamine levels are decreased and the number of dopamine uptake sites is reduced in the caudate nucleus in VaD with an increased risk of EPS side effects of dopamine blocking agents (Allard et al., 1999).

Frontotemporal dementia

Arnold Pick described dementia in frontal and frontotemporal atrophy in 1892, later called Pick's disease (Onari and Spatz., 1926). Far more common however, is the frontal lobe degeneration of non-Alzheimer type (FLD) described much later by Brun (1987), Gustafson (1987) and Neary et al., (1988). It is defined pathoanatomically as a presenile cortical, frontal, and often anterior temporal lobe disease of a progressive degenerative nature. Frontotemporal dementia (FTD) is an overriding concept for a group of disorders with a basic degenerative pattern in the frontal lobes such as FLD, progressive aphasia and motor neuron disease with dementia. Pick's disease is also included in the FTD complex although it has additional neuropathological changes of a partly different distribution (Brun et al., 1994). The cause is unknown but a genetic aetiology has been suggested, with a linkage to chromosome 17 and parkinsonism (Wilhelmsen et al., 1994, Lynch et al., 1994, Foster et al., 1997).

Clinical features

FTD constitutes about 9% of organic dementia cases of all ages (Brun and Gustafson, 1993). Males and females are equally affected. Passant et al., (2000) describe FLD as follows: FLD, the most common form, has an insidious onset and a slow progressive course. Deterioration in personality with behavioural affective symptoms such as levelling of emotions, social neglect, apathy, lack of concentration and lack of judgement are typical findings. Speech disturbances, described as a progressive reduction of verbal output ending in late mutism are typical. Memory impairment appears later in the disease and is usually less prominent than in AD. Psychotic features are rather prevalent in FLD and hallucinations and delusions have been reported in 20% (Brun et al., 1994, Brun and Gustafson, 1999). The neurological status examination could reveal primitive reflexes and late in the disease EPS such as akinesia, rigidity and tremor. Hypomimia is common. When a connection to motor neuron diseases exists, symptoms like fasciculation, muscular wasting, dysarthria and dysphagia

could appear (Mitsuyama and Takamiya, 1979, Mitsuyama, 1993).

For a clinical diagnosis of FTD the guidelines for clinical and neuropathological diagnosis developed by the Lund and Manchester groups should be used (Brun et al., 1994).

EEG is usually normal. However with a longer duration of the disease and increased severity patients may develop moderately abnormal EEG (Johánnesson et al., 1977). Structural brain imaging may reveal atrophy in the frontal regions (Gustafson and Brun, 1989, Larsson et al., 2000). The rCBF pathology is localized in frontal or frontotemporal cortex bilaterally with better preserved perfusion in posterior areas (Neary et al., 1987, Risberg et al., 1993). Neuropsychology is a useful tool for early recognition of FTD with a test profile characterized by slow verbal production and relatively intact reasoning and memory, while intellectual and motor speed are reduced (Johanson and Hagberg, 1989, Elfgrén et al., 1993). Picks disease, part of the FTD group, cannot be clinically distinguished from FLD although the neuropathological findings are more severe. The clinical differences between FTD and AD are usually more obvious at an early and especially at a mid stage of the disease compared to later stages where both diseases tend to extend to a more global involvement of the brain. However, in 5-7% of AD cases, the frontal lobes become prominently involved at an early stage (Brun and Gustafson, 1991b). Vascular brain damage may also sometimes mimic FTD. Patients with frontal SIWI or PSVE often display psychiatric features of frontal lobe type (Brun and Gustafson, 1999).

Neuropathology

According to the description of FLD by Brun (1987), the brain may appear normal macroscopically although some cases show frontal atrophy with widening of the sulci and of the frontal horns of the lateral ventricles. Under the microscope the degenerative process is usually expressed as gliosis in the molecular layer and microvacuolation and reduction of neurons and synapse loss in the cortical lamina II and III (Liu et al., 1999). The areas involved are the frontal convexity cortex anterior to the prefrontal fissure, the anterior gyrus cingulum, the anterior insular cortex and in one third of the cases also the anterior one-third of the temporal lobe. In advanced cases postcentral parietal areas could also be involved. The white matter adjacent to the involved cortical areas shows attenuation of myelin density and gliosis. There is often a mild to moderate affection of the SN (Brun and Gustafson, 1999).

Little is known about the neurochemistry and transmitter pathology in FTD. Normal cholinacetyltransferase activities have been reported (Francis et al., 1993). Nigrostriatal dopamine decrease has been described in Pick's disease and decreased monoamine metabolites in FTD (Kanazawa et al., 1988, Sjögren et al., 1998). There are however differences between FTD and AD in peptide expressions (Minthon et al., 1991, Edvinsson et al., 1993).

Dementia in Parkinson's disease

In 1817, James Parkinson, published a monography "An essay on the shaking palsy". He stated that the patients showed "involuntary tremulous motion with lessened muscular power, in parts not in action and even when supported: with a propensity to bend the trunk forward and to pass from a walking to a running pace: the senses and intellects being uninjured". However, in 1923, Lewy stated that, "the psyche is seldom spared in the course of the shaking palsy" (Förstl, 1999).

Clinical features

The diagnosis PaD, is clinical and based on the presence of two of the three major clinical features: bradykinesia, rigidity and resting tremor. Postural instability is sometimes included as a fourth major manifestation (Rajput, 1994). A positive L-Dopa response supports the PaD diagnosis. In one metaanalysis of 2530 Parkinson patients the prevalence of dementia was 35.1% although the range was wide (0% to 81%) (Brown and Marsden, 1984), and in another metaanalysis of 27 studies representing 4336 PaD patients, the prevalence of dementia was 39.9% (4-93%) (Cummings, 1988). Neuropsychological investigations reveal that PaD patients manifest impairment of memory, visuospatial skills, and changes suggestive of frontal lobe dysfunction (Gotham et al., 1988). The language function is largely spared (Cummings, 1988). With the passage of time inertia and bradyphrenia appear and may further progress into a more pronounced frontal lobe syndrome. Mild mental changes are most commonly seen and a severe dementia syndrome occurs in 7-15% of PaD patients (Lees, 1985, Oyeboode et al., 1986). For a clinical diagnosis of Dementia in PaD one criterion in the DSM is that the decline in occupational or social functioning should be caused by the cognitive deficits, even though it may be difficult to determine to what extent the functional impairment in PaD reflects motor disability or a cognitive decline (Tröster et al., 2000).

rCBF studies in PaD with dementia, have shown reduced perfusion in the

temporoparietal lobes (Pizzolato et al., 1988, Spampinato et al., 1991, Liu et al., 1992) and in additional areas, like the frontal and occipital cortices (Miller et al., 1996).

Neuropathology

The neuropathological hallmark of PaD is the Lewy body (Duvoisin and Golbe, 1989), invariably found in pigmented brain stem nuclei including SN, and in the nbM, the dorsal vagal nucleus, autonomic ganglia and hypothalamus. Neuronal loss has been seen in most of the locations in which Lewy bodies are found (Gibb, 1989b). Cortical Lewy bodies of differing density have been described in 100% of parkinsonian patients (Hughes et al., 1993, De Vos et al., 1996) and in almost 100% of AD combined with PaD and AD with incidental Lewy bodies (Joachim et al., 1988).

The dementias of PaD are a heterogenous group of disorders and could be caused by a variety of central nervous system lesions. The molecular and pathogenic causes are poorly understood but probably include: (I) degeneration of subcortical ascending systems with neuronal losses in dopaminergic, noradrenergic, serotonergic, cholinergic systems, (II) limbic and neocortical Alzheimer and Lewy body pathologies, (III) combinations of these lesions or (IV) additional CNS pathologies (eg infarcts in basal ganglia and in the white matter) (Jellinger, 1997, de Vos, 1996). In a consecutive autopsy series of 610 patients with parkinsonism, 34.6% had dementia (Jellinger, 1997). In that study dementia was seen in 30.2% in PaD of the Lewy body type. This was, however, mostly associated with other brain lesions, mainly Alzheimer pathology. Only 3.5% of the “pure” PaD cases (without additional brain pathologies) were demented. In the 100 Parkinson patients described by Hughes et al., (1993), 17% had coexisting Alzheimer pathology and 34% had vascular striatal abnormalities. Dementia was present in 44 cases of which 29% had Alzheimer pathology, 6% had vascular pathology and 10% had increased amounts of cortical Lewy bodies. In 55% no obvious pathological cause of the dementia was found.

The incidence of neuropathological Alzheimer changes is higher than the mere coincidence of two common degenerative diseases. This has been interpreted as AD being a risk factor for PaD (Kazee et al., 1995a)

“The intellectual decline in PaD is based on both pathologic and neurochemical changes. The subcortical dementia syndrome may be related to the dopaminergic deficit. Loss of dopaminergic projections from the ventral tegmental area to the mesocortical regions and disruption of fronto-striatal interactions may account for similarities between PaD and frontal lobe syndromes“

(Cummings, 1988). The majority of patients with marked dementia have evidence of cholinergic as well as dopaminergic deficits although alterations in norepinephrine, serotonin, and a variety of neuropeptides and neuromodulators may contribute to the intellectual dysfunction in some patients (Cummings, 1988).

The most well known neurotransmitter deficit of PaD involves dopamine or its metabolites which are reduced in putamen, caudate nuclei, SN, lateral hypothalamus, nucleus accumbens, hippocampus, the frontal lobe, cingulate gyrus, entorhinal cortex and para olfactory gyrus (Price et al., 1978, Scatton et al., 1982). Both the nigro-striatal and ventral segmental mesolimbic and mesocortical dopamine systems are affected in PaD (Cummings, 1988). Estimated with [^{18}F] dopa PET technique clinical signs of PaD seem to appear when 75% of the dopamine content in putamen is lost (Morrish et al., 1998). A correlation between decreased cerebral dopamine and dementia is supported by observations in parkinsonism induced by 1-methyl-4-phenyl-1,2,3,6-tetrahydropyridine (MPTP) where a SN lesion produces neuropsychological dysfunction similar to that observed in PaD (Stern and Langston, 1985). Norepinephrine is also decreased in PaD with the involvement of several subcortical nuclei, including LC, as well as the cortex (Riederer et al., 1977). A metabolite of norepinephrine has been related to MMSE scores and frontal functions (Stern et al., 1984) and also in combination with dopamine related to memory function (Mann et al., 1983).

Markers of acetylcholine, such as choline acetyltransferase are decreased in PaD with dementia even when neuropathological Alzheimer changes are not present (Perry et al., 1983).

A decrease in other neurotransmitters such as serotonin (Perry et al., 1984) and somatostatin has also been found in PaD patients with dementia (Stern et al., 1984).

Dementia with Lewy bodies

Historical note

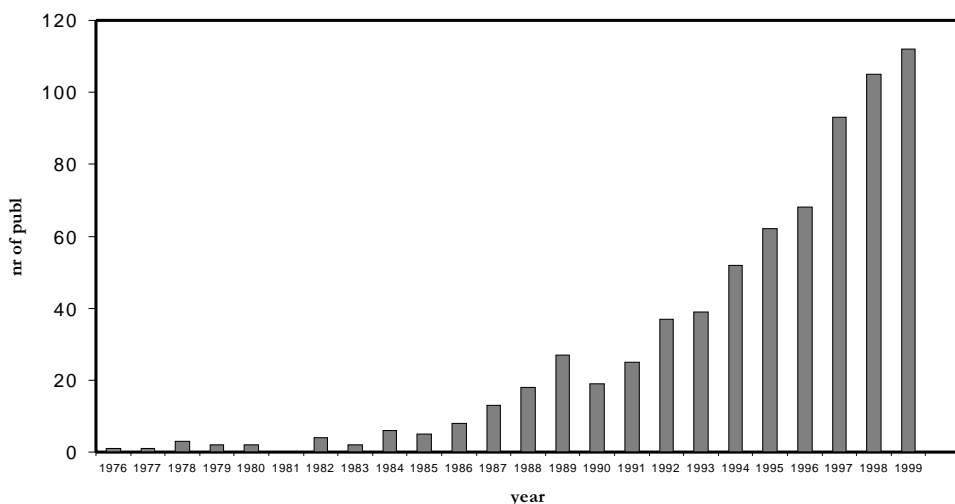
Friedrich Heinrich Lewy (1885-1950) was a German neuroscientist whose career extended over the entire neurological, neuropathological, neurophysiological and neurosurgery field. He made major contributions to the description of PaD both neuropathologically and clinically. In 1912, he described the neural inclusion in the dorsal vagal nucleus and nbM of parkinsonian patients that

was later to bear his name “Lewy body” (Trétiakoff, 1919). In ”die Lehre vom tonus und der bewegung“ 1923, Lewy described paralytis agitans and made solid clinico-pathological interpretations. In the clinical description of the psychiatric features of his parkinsonian patients, Lewy concluded: ”Die Psyche ist im weiteren Verlauf der Erkrankung nur selten ganz frei. Je nach dem Zeitpunkt der ersten psychischen Symptome haben sie eine unterschiedliche Färbung, gehören aber alle dem Formenkreis der senilen Demenz an. In den frühen Fällen überwiegen die Affektanomalien teils euphorischer, teils depressiver Natur, vielfach verknüpft mit Halluzinationen und daraus abgeleiteten paranoiden Wahnideen. In den späteren Jahren tritt die Störung der Merkfähigkeit und des Gedächtnisschatzes mehr in den Vordergrund, um bei einer kleinen Anzahl von Kranken zu schwersten Verblödungszuständen zu führen“.

“The psyche is seldom totally spared during the further course of the disease. Depending on the time of the debut of psychiatric symptoms they have a different colouring, all, however, belonging to the type seen in the senile dementia. In the early cases, emotional disturbances dominate, sometimes euphoric, sometimes depressive affects, often associated with hallucinations and secondary to these paranoid delusions. Later in the course disturbances of attention and memory predominate and in a small proportion of cases leads to severe cognitive deterioration.”

The number of publications on DLB has increased exponentially since the first reports in the 1970s (Fig 4).

Fig 4. Number of publications on “dementia with Lewy bodies” or Lewy body disease” on MEDLINE 1976-2000

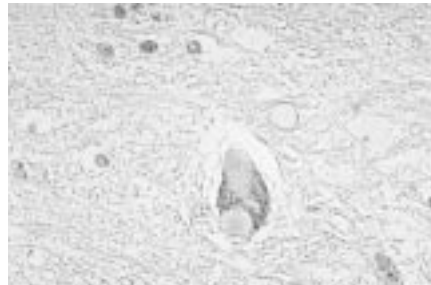

In a MEDLINE search (1976-1999) 703 papers on “Dementia with Lewy bodies” or “Diffuse Lewy body disease” was found. A substantial part of the early work came from Japan. Initially single-case studies were reported and later larger studies presented mainly a neuropathological perspective. Thirty-one studies in the search comprised more than 200 cases (the size of the present study) and only 10 studies included more than 50 DLB cases diagnosed either clinically or neuropathologically. From the late 80s an increasing number of immunohistochemical studies have been performed, their goals being to define and understand the Lewy body as a pathological phenomenon and to establish its relations to other pathological structures in the brain. Neurochemical studies although fewer have also increased since the early 1990s. Before 1995 only 39 clinical studies were found but after 1995 the number increased to 145.

What is a Lewy body?

A Lewy body is a rounded pathological structure, an inclusion body, which lies within the cytoplasm of nerve cells or in nerve cell processes (Fig 5).

Fig 5. Microscopical picture of Lewy body in Hematoxylin Eosin staining



It is recognised by its characteristic eosinophilic staining and surrounding halo (Gibb, 1989c). This classical description is typical of a Lewy body located in the brainstem. Cortical Lewy bodies are more variable at light microscopical level (Kosaka, 1978) and biochemically (Fukuda et al., 1993). Cortical Lewy bodies are found in pyramidal cells (Wakabayashi et al., 1995).

Lewy bodies in the SN, LC and nbM are, together with the degeneration of SN, the pathological hallmarks of PaD (Greenfield and Bosanquet, 1953, Bethlem and Den Hartog Jager, 1960).

The Lewy body consists of neurofilaments (Duffy and Tennyson, 1965) and proteins such as ubiquitin, crystallin and α -synuclein (Pollanen et al., 1993). Cortical Lewy bodies are shown either with ubiquitin immunocytochemistry

(Lennox et al., 1989a), or lately also with α -synuclein antibodies (Spillantini et al., 1997). α -synuclein has gained increasing interest lately partly as a possible link between common neurological disorders (Higuchi et al., 1998). α -synuclein is a presynaptic protein, identical with the precursor of the non A β component of amyloid in AD (Jakes et al., 1994). It also forms the major component of the abnormal filaments that form Lewy bodies and Lewy neuritis in PaD and DLB (Jakes et al., 1999). A mutation in the α -synuclein gene in early onset familial PaD has been discovered (Polymeropoulos et al., 1997) and a genetic association between AD and the α -synuclein gene have recently been proposed (Matsubara et al., 2001). There is hope that the efforts to clarify the composition of Lewy bodies will yield insight in the role of the Lewy bodies for the degeneration of affected neurons (Galvin et al., 1997).

What is the role of Lewy bodies in the nervous system?

Although the precise role of Lewy bodies in the brain is still unknown the appearance of Lewy bodies seems to be associated with neuronal injury and death (Pollanen et al., 1992, Kremeer and Bots, 1993). The involvement of the ubiquitin system and enzymes associated with cytosolic proteolysis suggests that the Lewy body phenomenon may be a reflection of the cell becoming reorganized to remove abnormal or unwanted proteins (Lowe, 1994). The inability of the SN to handle damaged or mutant (eg, α -synuclein) proteins may lead to their aggregation and deposition and to the formation of Lewy bodies (Jenner and Olanow, 1998).

It has also been suggested that Lewy bodies are a morphological sign of a more widespread underlying disease process (Woodard, 1962, Perry et al., 1997). The synucleins (α -, β - and γ -) may play a role by transformation into insoluble pathological proteins, forming aggregates (e.g. Lewy bodies), which compromise the function of synaptic transmission and viability of neurones (Galvin et al., 1999). The role of α -synuclein is unknown although involvement in synaptic function, integration of presynaptic signalling, plasticity and protection of or restoration of surviving neurons have been hypothesised (Clayton and George, 1998, Clayton and George, 1999, Kholodilov et al., 1999). It has been suggested that oxidative stress and impairment of mitochondrial function as well as apoptosis play a role in the degenerative processes (Jenner et al., 1992, Dexter et al., 1994, Tompkins et al., 1997).

An aged nervous system seems to be required for the appearance of Lewy body like inclusions in animal models with MPTP-induced parkinsonism (Forno et al., 1988).

Where are Lewy bodies located?

Lewy bodies have a specific and consistent distribution in the nervous system with the principal locations being SN, LC, raphé nuclei, thalamus, nbM, cerebral cortex and the entire autonomic system including the hypothalamus, dorsal vagal nucleus, intermediolateral columns, sympathetic ganglia and parasympathetic myenteric plexi (Gibb, 1989c). The distribution of cortical Lewy bodies correlates with the site of cortical monoaminergic neurons and in the cortical neurons that express a key enzyme in the catecholamine biosynthesis, suggesting that monoaminergic neurons may be selectively vulnerable to the stimulus causing Lewy body formation (Wakabayashi et al., 1989, Kuljis et al., 1989, Lowe, 1994). A regular periodicity of Lewy body clusters in the cortex and hippocampus also suggests that Lewy bodies develop in relation to the cells of origin of specific cortico-cortical and cortico-hippocampal projections (Armstrong et al., 1997). Lewy body density is highest in SN > entorhinal cortex > cingulate gyrus > insula > frontal cortex > hippocampus > occipital cortex (Gomez-Tortosa et al., 1999). The predilection areas of Lewy bodies are brainstem, subcortical nuclei, limbic structures, amygdala, and neocortex (temporal > frontal = parietal) (McKeith et al., 1996), which are the sites recommended for sampling.

Who has Lewy bodies?

By definition patients with idiopathic PaD have Lewy bodies while patients with postencephalitic parkinsonism (Greenfield and Bosanquet, 1953, Rövétí, 1956) and MPTP induced parkinsonism do not exhibit Lewy bodies (Langston et al., 1999). It is also a common phenomenon in AD which can be seen in Table 1.

Table 1. Frequency of cases with Lewy bodies in confirmed post mortem Alzheimer's disease (AD)

Study	Neuropathologically verified AD cases (n)	Cases with concomitant Lewy bodies
Joachim et al., 1988	131	18%
Gibb and Lees., 1989	121	14%
Bergeron and Pollanen, 1989	150	25%
Hansen et al., 1990	36	33%
Hansen et al., 1993	147	28%
Förstl et al., 1993	65	12%
Galasko et al., 1994a	123	24%
Hulette et al., 1995	78	20%
Victoroff et al., 1995	108	7%
Kazee and Han, 1995	48	71%
Ince et al., 1995	62	21%
Reyes et al., 1996	17	35%
Mirra, 1997	176	23%
Present study	99	15%

Lewy bodies have also been identified in a variety of more rare diseases such as Hallervorden-Spatz disease (Helfand, 1935), idiopathic cerebellar atrophy (Sigwald et al., 1964), amyotrophic lateral sclerosis (Hirano et al., 1967), ataxia-telangiectasia (Agamanolis et al., 1979), pure autonomic failure (van Ingelghem et al., 1994, Hishikawa et al., 2000) and multisystem atrophy (Pakiam et al., 1999). Lewy bodies are also detected in 50% of cases with Down's syndrome with AD (Lippa et al., 1999a).

Lewy bodies in non-demented

The prevalence of Lewy bodies in the brainstem has been found to increase with age and appears most commonly after the age of 65 when also substantial loss and reduction of neuronal volume of the SN also appears (Mann et al., 1984). By combining data from different reported series the prevalence of incidental Lewy body disease was 1.8% among persons <60, 10.7% in 60-69, 12.5% in 70-79, 18.2% in 80-89 and 16.7% in >90 years (Gibb and Lees., 1988). Of 92 neuropathologically investigated elderly in Norway, 69 were demented and 23 non-demented. Four of the non-demented (17%) had Lewy bodies (their mean age was 88 years) (Ince et al., 1995) confirming the higher prevalence with increased age. Lindboe et al., (1998), investigated 248 cases (50-94 years), in an autopsy series to determine the frequency of Lewy bodies. In 22 (7.7%) cases Lewy bodies were found and 9 (3.6%) of the cases had cortical Lewy bodies. None of these 9 cases were demented. Cases with Lewy bodies were significantly older than those without.

In a recent large unselected community-based multicenter study of pathological correlates to late-onset dementia, Lewy bodies were equally common in demented and non-demented individuals, 12 respectively 9% (Esiri et al., 2001).

Lewy bodies in psychiatric disorders

It is often claimed that Lewy bodies are more prevalent in psychiatric patients. Woodard (1962), investigated 400 consecutive neuropathological cases with mental disease, and found that 6.7% cases exhibited Lewy body formation. In another study the Lewy body prevalence was 2.3% in an aged population and increased to 9% in cases with psychiatric illness (Perry et al., 1990a). Birkett et al., (1992) found Lewy bodies in 7% of 212 autopsied mental hospital patients (their mean age at death was, however, 86 years). When the psychiatric histories were compared between cases with and without Lewy bodies, a clinical diagnosis of PaD and admission with a paranoid diagnosis was most commonly associated with Lewy bodies.

Clinical picture in neuropathological cases with Lewy bodies

In 1961 Okazaki presented 2 remarkable cases with a rapid disease progression including dementia and a clinical picture of paraplegia in flexion. The autopsy revealed widely spread Lewy bodies in the brain. The characteristic clinical features of 400 neuropathologically investigated consecutive cases with mental disease and Lewy body formation were paranoid delusions, episodes of physically violent behaviour and delirious episodes, affective disturbances and often only mild and late intellectual deterioration (Woodard, 1962). Many of these cases could however, not be differentiated from AD on clinical grounds and one third showed superimposed Alzheimer pathology. In a review of the clinical presentations of 30 reported neuropathological DLB cases, Burkhardt et al., (1988), found that symptoms such as dementia, psychosis, parkinsonism (rigidity), involuntary movements, myoclonus, quadriparesis in flexion, orthostatic hypotension and dysphagia were common.

In 43 of Lewy's original PaD patients, reanalysed by Förstl and Levy in 1991, the complex picture with parkinsonism, dementia and psychosis was already recognised, although no connection between Lewy bodies and the psyche was described. Twenty-one (49%) of Lewy's patients were demented and 6 (14%) had psychotic features such as paranoid ideas and hallucinations. Only 12 (28%) cases were judged to be mentally healthy.

Nomenclature

Many different diagnostic labels have been applied to clinico pathological entities involving Lewy bodies and dementia.

From a neuropathological standpoint Kosaka (1984) divided the Lewy body diseases into 4 groups depending on the presentation of the lesions in the brain. Type A, the brainstem type, is equivalent to classical PaD. Type B is called transitional or limbic type. Type C is diffuse Lewy body disease (DLBD), which consists of a common form, mostly affecting older individuals and pathologically characterized by the coexistence of AD, and a pure form preferentially affecting younger individuals and where no Alzheimer changes are seen neuropathologically. Type D is called the cortical form.

In England, Perry et al., (1989) described "senile dementia of Lewy body type" (SDLT) a disease entity on its own, constituting about 20% of all organic dementias. SDLT was equivalent to Kosaka's DLBD common form, in other words Alzheimer pathological changes were also present. In San Diego, USA, Hansen and co-workers described a high frequency (33%) of Lewy body pathology in cases with pathological AD (1990) and therefore called this as a "Lewy body variant of AD (LBV)". Förstl in Germany also used the name Lewy body

variant of AD (1993).

Criteria for Dementia with Lewy bodies (DLB)

The dementia cases with Lewy bodies seem to share several clinical features. In 1991 and 1992 two different sets of clinical criteria were published. The Nottingham research group (Byrne et al., 1991) emphasised the presence of EPS (“Dementia associated with cortical Lewy bodies”) while the group in Newcastle (McKeith et al., 1992a) pointed out the fluctuating course in this type of dementia (SDLT). In 1995 a consensus agreed on the clinical criteria of DLB (Fig 6).

Fig 6. Consensus criteria for the clinical diagnosis of dementia with Lewy bodies (DLB)

1. The central feature required for a diagnosis of DLB is progressive cognitive decline of sufficient magnitude to interfere with normal social or occupational function. Prominent or persistent memory impairment may not necessarily occur in the early stages, but is usually evident with progression. Deficits on tests of attention and of fronto-subcortical skills and visuospatial ability may be especially prominent.
2. **Two** of the following core features are **essential** for a diagnosis of *probable* DLB, **one** is **essential** for *possible* DLB.
 - (a) Fluctuating cognition with pronounced variations in attention and alertness.
 - (b) Recurrent visual hallucinations which are typically well formed and detailed.
 - (c) Spontaneous motor features of parkinsonism.
3. Features **supportive** for the diagnosis
 - (a) Repeated falls
 - (b) Syncope
 - (c) Transient loss of consciousness
 - (d) Neuroleptic sensitivity
 - (e) Systematised delusions
 - (f) Hallucinations in other modalities
4. A diagnosis of DLB is **less likely** in the presence of
 - (a) Stroke disease evident as focal neurological signs or on brain imaging
 - (b) Evidence on physical examination and investigation of any clinical illness, or other brain disorder, sufficient to account for the clinical picture

(McKeith et al., 1996)

The first criterion comprises a dementia syndrome with progressive decline in cognition. Deficiencies in neuropsychological tests of attention, fronto-subcortical skills (such as measured by verbal fluency test, the Wisconsin Card Sorting Test, the Trail Making Test) and visuospatial ability may be prominent. Core features are EPS, cognitive fluctuations and visual hallucinations and supporting features are repeated falls, syncope, transient loss of consciousness, delusions and hallucinations of other modalities. Dementia caused by stroke or underlying physical illness or brain disorder, should be excluded.

In 1999, in a report from the second DLB workshop (McKeith et al., 1999) two additional clinical features were discussed: depressive symptoms, reported in 33-50% of DLB cases (Klatka et al., 1996, Ballard et al., 1999a), and REM sleep disorder (Uchiyama et al., 1995, Negro and Farber, 1996).

How common is DLB?

It has been claimed that DLB represents 10-20% of all organic dementias in the elderly (Lennox et al., 1989a, Hansen et al., 1990, Perry et al., 1990c). In a study by Ala et al., (1997), 90 of 426 (21%) dementia cases had cortical Lewy bodies with or without other pathology and an additional 4 had Lewy bodies in SN without cortical Lewy bodies. These figures are, however, based on the occurrence of Lewy bodies in dementia cases from a neuropathological perspective. The clinical prevalence of DLB among patients referred to a district general hospital, with a diagnosis of dementia, varied depending on the set of clinical criteria used: 26% with the Newcastle SDLT criteria and 7-17% with the Nottingham (Byrne) criteria (Shergill et al., 1994). The actual occurrence of Lewy bodies was, however, not investigated here.

Neuropathological features of DLB

According to the consensus guidelines the pathological features associated with DLB are Lewy bodies, both cortical and subcortical, Lewy-related neurites, Alzheimer pathology, spongiform change (Hansen et al., 1989, Iseki et al., 1997) and synapse loss (Brown et al., 1998, Hansen et al., 1998). The spongiform changes in DLB were not related to prion disease (Hansen et al., 1989) and in an investigation of different movement disorders, including DLBD, no prion proteins were found (Jendroska et al., 1994).

Lesions in basal forebrain cholinergic system have been most consistent and severe in DLB (Clark et al., 1986) with loss of neurons in nbM and also in SN (Förstl et al., 1993, Perry et al., 1993).

Prominent frontal atrophy has been associated with DLB (Förstl et al., 1993, Cordato et al., 2000). Others, however, interpret the patterns of atrophy to be

similar in AD and in cases with AD/cortical Lewy bodies (Mann and Snowden, 1995). The tissue loss paralleled the AD pathological changes and the Lewy bodies in the cortex or subcortical sites were considered to contribute little if anything to the degree of atrophy.

The Alzheimer pathology in DLB cases has been discussed and debated. Researchers agree that cases with Lewy bodies have less intense or a lower degree of AD changes (Förstl et al., 1993, Hansen et al., 1993, Hulette et al., 1995). The tangles and plaques counts are reported to be lower in the hippocampus, temporal and frontal cortices in Lewy body cases with AD compared to pure AD (Gibb et al., 1989b) but higher than in PaD and controls (Ince et al., 1991). The NFT are few and sometimes absent giving the appearance of a "plaque-only AD" (Dickson et al., 1987, Hansen et al., 1993). Depending on the pathological definition of AD these cases are categorized differently. With pathological criteria demanding NFT for a diagnosis of AD, fewer DLB cases are categorized as mixed AD/Lewy body while the cases with Lewy bodies stand out as more of a disease on its own. When pathological AD criteria are wider, and include plaques, a majority of the DLB cases will also have pathological Alzheimer and could therefore be viewed as a variant within the AD spectrum (Hansen and Samuel, 1997).

The medial temporal lobe, which is commonly affected in AD, is less affected in DLB (Lewy body/AD) cases and normal in pure Lewy body disease (Lippa et al., 1998) and is an expression of the AD degree in this location.

The nosological debate in dementia and Lewy bodies also includes different immunohistochemical and genetic aspects of similarities and differences between AD, PaD and DLB. These include APOE epsilon 4 allele frequency which is elevated in AD and in cases with AD/Lewy bodies (LBV) (Galasko et al., 1994b, Betard et al., 1994, Gearing et al., 1995, Martolini et al., 1995) but not in cases with Lewy bodies without Alzheimer changes (=DLBD, pure). APOE is known to be a major risk factor for AD, alone or in conjunction with other pathologies (Betard et al., 1994). The CYP2D6B allele is overrepresented in PaD and LBV but not in AD (Saitoh et al., 1995).

The precise significance of vascular lesions is not discussed in the DLB consensus guidelines, except for signs of infarcts, which are believed to make the DLB diagnosis less likely. Recognition of a potential overlap between other conditions causing dementia such as AD and VaD is thus noted. In a prospective study 31% of the DLB cases also had significant vascular pathology (McKeith et al., 2000a).

The consensus group recommended the term DLB as a generic term for cases fulfilling the criteria to "acknowledge the presence of Lewy bodies without

specifying their relative importance in symptom formation with respect to other degenerative or vascular pathology that is simultaneously present". As pointed out by Samuels et al., (1997), the consensus does not separate the larger group of patients with Lewy bodies and AD pathology from the smaller group with Lewy bodies without AD pathology.

Clinical diagnosis

There are as yet, no reliable diagnostic tools apart from the clinical diagnostic criteria for DLB. The morphologic brain imaging adds no significant features although it has been suggested that medial temporal lobe atrophy on MRI is less pronounced in DLB compared to AD (Barber et al., 1999). EEG does not distinguish DLB from AD (Briel et al., 1999). rCBF in DLB is, in some studies, identical with the temporoparietal flow pattern seen in AD (Donnemiller et al., 1997, Turjanski et al., 1997, Varma et al., 1997) while other studies report an additional occipital blood flow decrease (Albin et al., 1996, Ishii et al., 1999). CSF-tau levels do not distinguish DLB from AD (Arai et al., 1997).

Neurochemistry and DLB

There are many articles focusing on the neurochemical deficits in relation to DLB. Both dopaminergic and cholinergic abnormalities in DLB are described and correlated to neuronal loss in SN and nbM (Eggertson and Sima, 1986, Dickson et al., 1987, Lippa et al., 1999b). Perry et al., (1994) stated that the cerebral cholinergic defect in DLB is even more consistent than in AD. The cholineacetyltransferase activity parallels the nbM pathology (Lippa et al., 1999b). The dopaminergic degeneration in DLB has also been demonstrated in vivo (Walker et al., 1999a) where clinically diagnosed DLB cases have shown changes in striatal postsynaptic D2 receptors in single photon emission tomography (SPET) (Walker et al., 1997).

The core symptoms of DLB have also been correlated to the neurochemical deficiencies. The EPS are related to striatal levels of dopamine. Cognitive impairment is associated with cholinergic deficits in the temporal cortex. Hallucinations are related to extensive cholinergic deficits in the temporal cortex and the resulting imbalance between acetylcholine and serotonin (Perry et al., 1991).

Validation of the clinical DLB criteria

Twelve studies investigating the accuracy of clinical DLB criteria are shown in Table 2. In 9 studies the consensus criteria for probable DLB were used. In 4 studies the Newcastle and/or Nottingham criteria alone or combined with the consensus criteria were used. The present study has been added for comparison.

The sample selection, the investigated population and the diagnosis is also shown. The specificity and sensitivity of the investigated criteria are denoted. Sensitivity refers to the probability of receiving a clinical diagnosis of a disease given its neuropathological evidence (proportion of true cases identified). Specificity refers to the probability of not obtaining the clinical diagnosis of a disease given its neuropathological absence (proportion of true “non-cases” identified as such).

Table 2. Validations studies in Dementia with Lewy bodies

Study	Population	Sample selection	Diagnoses	DLB Criteria	Spec	Sens
1 (McKeith et al., 1994a)	Psychogeriatric patients	NP	SDLT 20 AD 21 MID 9	Newcastle Nottingham	97% 90-100%	75-85% 35-50%
2 (McKeith et al., 1994b)	Psychogeriatric patients	NP	20 SDLT 21 AD 9 MID	Newcastle	90-97%	74%
3 (Mega et al., 1996)	Neurobehaviour clinic patients	Clin	24 AD 5 PaD 1 PSP	Consensus	79%	75%
4 (Papka et al., 1998)	Neuropath database	NP	18 LBD 21 AD	Newcastle Consensus	95% 29%	17% 89%
5 (Litvan et al., 1998)	Movement disorder clinic	NP	14 DLB 15 PaD 76 others	6 neurologists diagnoses	99% DLB 86% PaD	18% DLB 73% PaD
6 (Holmes et al., 1999)	Dementia register, referrals from psychiat, medical and soc services	Clin	80 cases: 2DLB 38 AD 7 VaD	Consensus	100%	22%
7 (Lopez et al., 1999)	Prospective longitudinal dementia	NP	10 AD 8 DLB 22 others	Consensus	94%	34%
8 (McRitchie et al., 1999)	Longitudinal dementia study	Prospect clin	3 DLB	Consensus		100%
9 (Verghese et al., 1999)	Dementia in nursinghome	NP	18 DLB 76others	Consensus (possible) (probable)	28% 84%	89% 61%
10 (Luis et al., 1999)	Brain Bank	NP	23 DLBD 12AD+DLBD 21AD	Newcastle Consensus	100% 90%	49% 57%
11 (Hohl et al., 2000)	Dementia study	Prospect clin	10 DLB 32 DLB	Consensus		50%
12 (McKeith et al., 2000b)	Prospective dementia study	Prospect clin	50 cases: 26DLB, 19AD, 5VaD	Consensus	95%	83%
Present study	Prospective longitudinal dementia	clin	200 cases: 48 DLB 45 AD	Consensus	(60%)	38%

The author's comments on the studies:

Study (1): Many SDLT patients "erroneously" met the criteria for MID or AD. (2): The specificity of the diagnosis was greater when evaluated by experienced raters. (3): Reformulated criteria that require EPS signs increased specificity to 100%. (4): There was a high false negative rate, in that 15 of 18 cases with Lewy bodies did not meet the clinical criteria. The specificity was low because many AD cases met the DLB criteria. (5): Features separating DLB from PaD were presence of hallucinations, absence of tremor, bradykinesia and dystonia. Differences in the seniority of the raters were not significant. (6): Mixed pathologies were common. (7): There was low interrater reliability in DLB. (8): Two cases exhibited cortical Lewy bodies and 1 case had AD/limbic Lewy bodies. The pathology was heterogeneous with a variety of neuropathologies in addition to Lewy bodies. (9): Criteria that excluded almost three-fourths of cases with DLB were needed to define a group with high rates of DLB. (10): Sensitivity improved when mixed AD/DLBD cases were eliminated. (11) Greater emphasis on hallucinations may improve the distinction between DLB and AD. (12): Thirty one percent of the DLB cases had additional vascular pathology.

The sensitivity for DLB varied in the studies, while the specificity was generally high. There was no consistency in the diagnostic accuracy that could be explained by the selection procedure based on clinical or neuropathological parameters. The prevalence of mixed pathologies was commented on in studies 6, 8 and 12. Some studies commented on the difficulties in reaching agreeable sensitivity and specificity, others suggested modifications of the criteria to improve diagnostic precision.

Explanations of symptomatology by location of LB pathology

Even if "subjective judgements are almost unavoidable in assessing the cause of organic dementia" (Ulrich et al., 1986) attempts to explain symptoms in DLB by the location of Lewy bodies have been made.

EPS have been attributed to the presence of Lewy bodies in SN (Perry et al., 1991), dysphagia to Lewy bodies in the dorsal vagus nucleus and myenteric plexus involvement (Qualman et al., 1984) and weight loss to Lewy bodies in the lateral hypothalamus (Langston and Forno, 1978). Autonomic dysfunction may be the result of Lewy bodies in the lateral hypothalamus or in the intermediolateral nucleus of the thoracic spinal cord and sympathetic ganglia (Rajput and Rozdilsky, 1976, Goetz et al., 1986, Wakabayashi et al., 1997). Hallucinations have indirectly, through reduction of cortical choline acetyltransferase been associated to SDLT and Lewy bodies (Perry et al., 1990). Förstl et al.,

(1994) however, did not find any association between psychotic phenomena and the presence of Lewy bodies in the brainstem and neocortex.

Depending on whether the neuropathological picture is of a pure Lewy body disease type or of a mixed Lewy body/AD type the dementia has been attributed to different correlates. In DLBD the cortical lesions were considered to be responsible for the cognitive deterioration and in brainstem DLB cases the cognitive decline was attributed to the Alzheimer changes or to degeneration of the subcortical nuclei eg nbM (Kosaka et al., 1988). Cholinergic neurons in the nbM, projecting to the cortex, might be directly affected by Lewy bodies (Gaspar and Gray, 1984) or the cortical Lewy body burden itself could result in dementia (Lennox et al., 1989b, Samuel et al., 1996). According to Perry et al., (1990b) “low densities or occasional Lewy bodies in the cortex are unlikely to correlate directly with dementia in SDLT, since cortical Lewy bodies are found in many elderly, non-demented PaD cases”. However, Lewy body density correlated only weakly with the clinical symptoms and duration of disease correlated with neocortical global Lewy body burden (Gomez-Tortosa et al., 1999). It has also been proposed that other subcortical lesions (except in nbM) such as in SN and LC contribute (Ulrich et al., 1986).

Explanations of DLB symptomatology by other pathologies

Psychotic symptoms

Hallucinations are mental phenomena with many different factors contributing to their release such as organic brain disease, sensory impairment and the premorbid personality traits. Visual hallucinations are overrepresented among patients with reduced vision (Cooper and Porter, 1976) while deafness has proved to be an important factor in late life psychosis (Cooper et al., 1974). In patients with AD poor eyesight contributed to the severity of the hallucinations (McShane, 1995). Hallucinations may also be caused by drug treatment.

Structural brain abnormalities were common (42%) in a group of patients with late life psychosis (Miller et al., 1991). Silent vascular disease (cortical and white matter infarctions, especially located temporally) was present in 25% of these patients. Cognitive impairment and psychosis have also been attributed to cell loss in the ventral tegmental area causing altered mesocortical dopaminergic innervation (Burkhardt et al., 1988, Eggertson and Sima, 1986). Diminution of the volume of periventricular, limbic structures, hippocampal and parahippocampal gyrus have been reported in psychotic patients (Bogerts, 1989). The findings of tumours in cases suffering from visual hallucinations were located in the temporal, occipital and frontal lobes as well as mesen-

diencephalon and subtentorially (Ey, 1973).

Vascular thalamic lesions (De Morsier, 1969) and high rostral basilar infarcts (Caplan, 1980) may also cause visual hallucinations. Hallucinations might on the other hand, depend on the presence of intact cerebral tissue (Cummings, 1985, Förstl et al., 1993) or may be related to the combination of impaired visuoperception and fluctuating attention (Calderon et al., 2001).

Systematised delusions in dementia seem to require a relatively intact cerebral cortex as shown by rCBF and CT (Gustafson and Risberg, 1974, Jacoby and Levy, 1980) but have also been associated with basal ganglia calcification (Burns et al., 1990c, Förstl et al., 1994). In the study by Förstl et al., (1994) delusions and hallucinations were also observed in patients with less severe cell loss in the parahippocampal gyrus and with lower cell counts in the dorsal raphe nucleus. Misidentifications were associated with lower neurone counts in the area CA1 of the hippocampus.

Neuroleptic sensitivity

Neuroleptic sensitivity is common in the elderly population and parkinsonism is a well-known and common side effect of antipsychotic drugs. These side-effects occur in 75% of elderly patients (Dubovsky and Buzan., 2000). Patients with severe neuroleptic sensitivity had significantly reduced SN neurone density (Piggott et al., 1994). It has also been proposed that a critical factor responsible for neuroleptic sensitivity is the failure to up regulate D2 receptors in response to neuroleptic blockade and reduced DA innervation (Piggott et al., 1998).

Cognitive fluctuations

Fluctuations of the clinical state, including cognition and especially motor performance, are a part of PaD where the autonomic dysfunction also contributes to alterations in consciousness and, thereby, cognition. The neurochemical basis for variability in attention and alertness is related to deficits in both noradrenaline, acetylcholine and dopamine (Downes et al., 1989, Perry et al., 1999, Reikkinen et al., 1999). Traditionally fluctuations have been regarded as a part of vascular diseases (Mayer-Gross et al., 1969, Roth, 1981) with episodically compromised blood circulation as a physiological basis. Several commonly used drugs such as antihypertensives, diuretics, antidepressants, antianginal, neuroleptics and antiparkinson agents are known to yield hypotension and orthostatic hypotension as a primary therapeutic effect or as an adverse effect (Schoenberger, 1991, McCarthy and Cameron, 1992, Mets, 1995), which may

also contribute to the fluctuating state.

There are substantial difficulties in defining and quantifying fluctuations of cognition and differential diagnosis may include conditions such as delirium due to medication toxicity or intercurrent illness (McKeith et al., 1996).

Falling

Falling has multifactorial reasons and does not depend on specific brain lesions. Falls are common in the elderly (Tinetti et al., 1988, Downton and Andrews, 1991). Factors associated with falls are female sex, older age, drugs, poor postural control, and cognitive function. Patients with frequent falls have in general been found to have a higher prevalence of cognitive impairment compared to those that do not fall (Prudham and Evans, 1981). Subjects with AD are as much as three times more likely to fall (36%) than non-demented controls (11%) (Morris et al., 1987). Diseases associated with falls are orthostatic hypotension, epilepsy, PaD, cerebrovascular disease and dementia. Patients with PaD often experience falls depending on the extent of their gait disturbance. Other important factors are the impairment of postural reflexes and orthostatic hypotension, reported in 58% of PaD patients (Senard, 1997). Older patients with disequilibrium of unknown cause had more subcortical white matter lesions on MRI (Baloh et al., 1995) compared to controls.

Syncope

Syncope is defined as a sudden, brief loss of consciousness due to the transient global impairment of cerebral circulation, usually occurring in the absence of organic brain disease or cerebrovascular disease (Ormerod, 1984). It has a number of synonyms including “fainting”, loss of consciousness, seizure, collapse, black-out, unresponsiveness, passing out etc. These terms might not mean the same to different doctors or to their patients a fact, which makes investigations difficult. The frequency of syncope and loss of consciousness increases with age (Hale et al., 1986). There are limited “final common pathways” by which loss of consciousness can be produced: impaired circulation of blood to the brain, impaired cerebral metabolism and alteration in electric activity within the brain (Downton, 1993). There is also a clear overlap of factors such as hypotension and other cardiovascular factors, hypoglycemia and epilepsy, which give rise to syncope/loss of consciousness, especially in the elderly.

Treatment in Dementia with Lewy bodies (DLB)

Treatment in DLB starts with a tentative diagnosis and identification of the problem symptoms – cognitive, motor and/or psychiatric. Non-pharmacologi-

cal treatment involves information, optimisation of vision and hearing, blood pressure control and assistance at a proper care level. The only drug treatment of DLB patients is so far symptomatic and may often be complicated since disease symptoms and adverse reactions to medications are sometimes identical. (Table 3). (Liberini et al., 1996).

Table 3. Drug treatment in Dementia with Lewy bodies, benefits, adverse reactions and management.

Drug actions	Drug classes	Potential benefits	Adverse reactions	Management
Enhancement of the cholinergic system	Acetylcholine agonists and cholinesterase inhibitors	Memory improvement	Worsening of EPS	L-dopa or dopamine agonists at low doses
Agonism of the cholinergic system	Tricyclic antidepressants	Mood elevation	Worsening of attention and memory deficit	Atypical antidepressants or SSRI
Enhancement of the dopaminergic system	L-dopa and ergot alkaloids	Relief from EPS	Induction or worsening of hallucinations	Low/fractionated doses
Antagonism of the dopaminergic system	Neuroleptics	Relief from hallucinations	Worsening of EPS	Preferably atypical neuroleptics

(Liberini et al., 1996)

The studies of DLB and neuroleptics indicate that neuroleptic sensitivity is an important feature in this group. Table 4 shows 7 studies of neuroleptic treatment in DLB found in a MEDLINE search; the number of patients treated, the diagnostic methods, substance and comments on the primary outcome are outlined.

Table 4. Studies of neuroleptic (NL) treatment of DLB

Study	N	DLB Diagnosis	Substance	Outcome
McKeith et al., 1992b	AD 21 LBD 20	NP	Traditional NL	NL sens: 13 (81%) LBD, 4 (29%) AD
Chacko et al., 1993	1	Clinical	Clozapine	Improvement of psychotic symptoms.
Allen et al., 1995	3	Clinical	Risperidone	Improvement of psychotic and behavioural symptoms
McKeith et al., 1995	3	Clinical	Risperidone	Worsening of EPS and cognition
Ballard et al., 1998	40 (21NL treated)	NP	NL: (haloperidol, risperidone, sulpiride, thioridazine)	Severe NL sensitivity only occurred in DLB and was seen in 6 (29%). All reactions occurred within 2 weeks
Burke et al., 1998	2	NP 1 Clinical 1	Clozapine	"unequivocal decrement in the patients well-being"
Walker et al., 1999b	8	Clinical	Olanzapine	3/8 showed increases in confusion and hallucinations and worsening of parkinsonian symptoms.

The studies performed so far are few (Table 4) and most lack neuropathological confirmation. Single cases show a positive effect on psychotic symptoms while others report a worsening of parkinsonism, confusion and cognition.

There is an increased interest in the possibilities of the cholinesterase inhibitors regarding treatment and their effects in DLB. Table 5 shows studies of treatment with cholinesteraseinhibitors in DLB; the number of patients treated, the diagnostic methods, substance and comments on the primary outcome are outlined.

Table 5. Studies of treatment with cholinesteraseinhibitors of DLB

Study	N	DLB Diagnose	Substance	Outcome
Levy et al., 1994	3	NP: cortical LB+AD	Tacrine	"possible association between presence of LB and a favourable response to the drug".
Wilcock and Scott, 1994	2	NP: cortical LB (2) AD (8)	Tacrine	Responders: 1 cortical LB and 3 AD.
Lebert et al., 1998	19	Clinical: DLB 19 AD 20	Tacrine	11/19 DLB and 11/20 AD were responders. DLB cases improved in digit span and verbal initiation, AD cases improved conceptualisation.
Shea et al., 1998	9	Clinical	Donepezil	Improved/maintained hallucinations (sometimes cognition) in 6/9, worsening of EPS in 3/9.
Geizer and Ancill, 1998	1	Clinical	Donepezil (and Risperidone)	Free from psychosis, improvement of sleep, expressive aphasia and constructal apraxia. Avoidance of nursing home placement.
Aarsland et al., 1999	1	Clinical	Donepezil	Improvements of orientation, hallucinations, personal ADL.
Lancot and Herrmann, 2000	7	Clinical	Donepezil	5/7 showed at least minimally improved in behaviour. Adverse effects/non response in 3/7.
McKeith et al., 2000c	11	Clinical	Rivastigmine	Reduction in delusions, hallucinations, agitation, apathy. Carers reporting: more alert and responsive. Reduced EPS.
Fergusson, 2000	2	Clinical	Donepezil	"Improvement in behaviour and cognitive function and disappearance of psychotic symptoms".
Querfurth et al., 2000	6	Clinical: DLB 6 AD 6	Tacrine	"The data support a beneficial effect in a subset of DLB responders (n=3) who have baseline mild-moderate disease. Improvement in memory and fluency. Acceleration of parkinsonism occurred in all DLB subjects".
McKeith et al., 2000d	120	Clinical DLB	Rivastigmine	Randomised, double-blind, placebo-controlled international study. Patients on active substance were less apathetic and anxious, suffered fewer delusions and hallucinations, and were better on tests of attention.

As can be seen in Table 5, the investigated cases are rather few, except in the study by Lebert et al., (1998), the McKeith et al., (2000c) (preliminary results of the McKeith et al 2000d study) and the McKeith et al., (2000d) study. The lack of neuropathological confirmation is obvious. Several studies show an improvement of psychotic symptoms, apathy, ADL and frontal functions, which in turn could relate to improved attention.

Cholinesteraseinhibitors are theoretically attractive for the amelioration of symptoms caused by the deficiency and imbalance in the neurochemical systems involved in DLB, regardless of pathogenesis.

Diagnostic reflections

A diagnosis of dementia assumes organic factors behind the symptomatology. The term “dementia with Lewy bodies” implies a strong connection to an underlying pathology and not just an important symptom constellation. A similar diagnostic dilemma concerns Picks disease where the core pathological structures, Pick bodies and Pick cells, are present only in a minority of cases with the clinical syndrome of frontotemporal dementia.

Essen-Möller & Wohlfahrt in 1947, however, first suggested a dual system of diagnostic nomenclature where a descriptive term, the psychopathological syndrome, should be separated from the known or tentative aetiology. Martin Roth (1971) also emphasized that “clinical descriptive terms should, at any rate, be kept apart from statements of organic, psychogenic or genetic factors whose association may be fortuitous or aetiologically important to a greater or lesser degree”. The principle of a combined clinico-aetiological classification has also been further recommended by Gustafson (1996) and Mathuranath et al., (2000). The rationale behind such reasoning is apparent in several of our common dementia diagnoses where eg AD clinically depicts a certain symptom constellation but the neuropathological picture might differ and sometimes even show vascular changes in strategic locations. Another example is PaD meaning a clinical syndrome, which in only 75% of the cases has the assumed neuropathological basis of brainstem Lewy bodies (Rajput et al., 1991, Hughes et al., 1992). It would be an advantage to find a more descriptive clinical term without an immediate link to a specific aetiopathogenesis for the combination of symptoms in clinical DLB; a fronto-subcortical dementia profile with EPS, cognitive fluctuations and psychotic symptoms. A tentative aetiology could be added to the clinical diagnosis; degenerative; AD or Lewy body based, vascular or other.

The complexity of the functional systems involved contributes to the fact that a clinico-morphological relationship is not always conclusive. Therefore, another suggested approach is to think of neurodegenerative disease as the consequences of sequential biochemical processes, and that some of these processes appear to operate in more than one disease entity (Hardy and Gwinn-Hardy, 1999). The aetiology could in that perspective be described as a eg “cholinergic/dopaminergic” syndrome.

Symptoms and signs in a case of dementia may not necessarily relate to the disease process per se, but also to the setting, the situation, the demands, the drug treatment or rather provocation, motivational state or secondary disease. Brain lesions, depending on site, may also unmask inherent weaknesses, not related to the disease itself. The interpretation of symptoms also depends on the clinicians' theoretical background, training, speciality and interest. A clinical diagnosis could therefore be looked upon as a good theory. In psychosocial sciences theories are regarded as "tools for orientation". Most formations of theory try to overcome dualistic positions by specifying ways of understanding connections and their mutual interference. In DLB this (1) dualistic position could be the question of whether DLB is a variant of AD or a disease on its own, their (2) connection; the Alzheimer pathology and the (3) mutual interference; the cholinergic deficiency. It is therefore essential to pay respect to different approaches (neurochemical, immunohistochemical, clinical, neuropathological).

Martin Stevens (1998) stated "once revealed, no more to be concealed" which makes it our duty to try to understand the suggested clinical criteria without misinterpretations.

This study could be an example of an attempt to find different perspectives on DLB and recognize the "larger complex situation" in which nature has put us.

Aims of the thesis

Paper I

To study the prevalence of patients fulfilling the clinical consensus criteria of Dementia with Lewy bodies in a dementia population followed up with post mortem examination. To compare the clinical and neuropathological findings in the clinical Lewy body dementia group with findings in a clinically defined group with Alzheimer's disease.

Paper II

To investigate arterial blood pressure and the use of pharmacological treatment in patients with Lewy body dementia and Alzheimer's disease diagnosed on clinical grounds.

Paper III

To analyse the neuropathological changes behind clinically defined dementia with Lewy bodies compared with clinically diagnosed Alzheimer's disease and to investigate how the use of α -synuclein staining could improve the neuropathological detection of Lewy bodies.

Paper IV

To compare regional cerebral blood flow and EEG findings in patients with clinically diagnosed dementia with Lewy bodies and Alzheimer's disease Furthermore, within the clinical DLB group compare cases with and without neuropathologically verified Lewy bodies.

Paper V

To describe and critically compare the clinical and neuropathological data in clinically diagnosed DLB cases with (n=6) and without (n=10) Lewy bodies and to evaluate the clinical expression of the different brain pathologies in these cases.

Material and methods

Patient sample

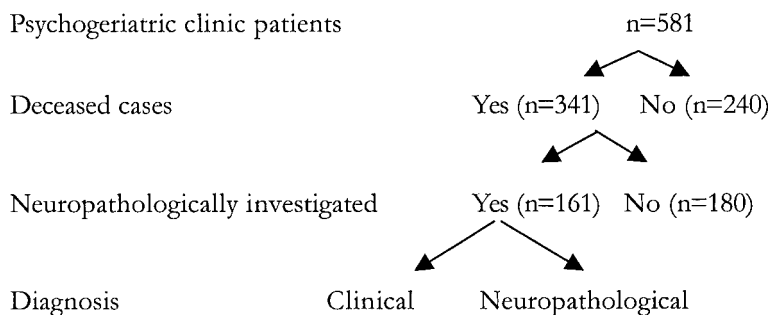
The patients were all part of the Lund longitudinal dementia study. The material in the longitudinal study was designed for early differential diagnosis, the evaluation of diagnostic tools and finally to make the clinico-pathological comparisons rather than finding specific diseases. This implies a broad diagnostic base. In the present study 200 consecutive neuropathologically investigated cases were selected. The patients died between 1985 and 1994. They had all been investigated as suspected dementia cases. About 90% were examined and cared for at the Psychogeriatric or Psychiatric departments at Lund University hospital. The remaining cases came from other departments in Lund (medicine and neurology) or psychiatric departments and nursing homes, mostly in the nearby region.

The patients went through a diagnostic procedure with neuropsychiatric and neuropsychological assessment, neurological status evaluation, laboratory testing, CT, EEG, rCBF and an investigation of ECG and blood pressure. The patients were followed clinically with fairly regular visits and were finally investigated post mortem. The observational time ranged from less than 1 month to 107 months.

Representativity of the material

A schedule of the compared groups is shown in Fig 7.

Fig 7.



During the time period 1985-1992, 341 patients died. Of these 161 (47%) were neuropathologically investigated. Comparisons of the clinical diagnoses of those with and without autopsy are shown in Fig 8a and b.

Fig 8a. Clinical diagnoses in 161 autopsied patients within Lund longitudinal dementia study 1985-1992

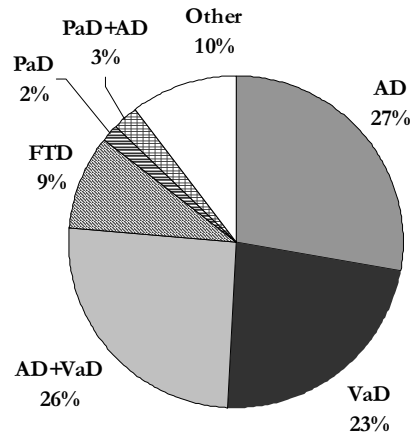
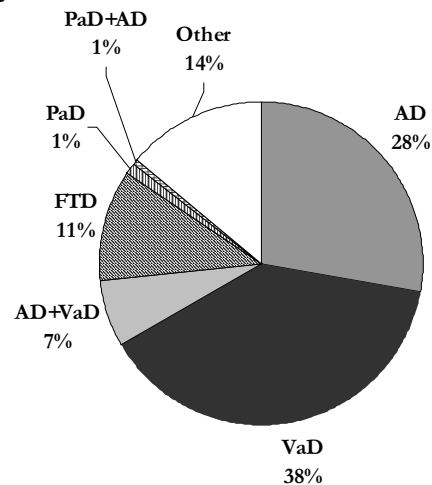


Fig 8b. Clinical diagnoses in 180 not autopsied patients 1985-1992



We can conclude that a higher number of cases with a clinical diagnosis of mixed dementia and fewer cases with a clinical diagnosis of VaD went to autopsy. The cases that were neuropathologically investigated (and partly included in this study) (Fig 9), were considered to be fairly representative of the total number of patients (n=581) cared for at the Psychogeriatric clinic and investigated for any psychogeriatric disturbance during the actual time period (Fig 10). However, mixed cases were overrepresented in the autopsy group while cases belonging to the “other” category (eg non-dementia cases) were more common in the non-autopsied group. The difference in the prevalence of the neuropathological diagnoses of the autopsied cases in this study, compared to

the 400 cases in Brun et al., (1993) (see introduction), is explained by the AD-SIWI cases. In the present study these were classified separately as a combined type (in accordance with Englund, 2000) while in the Brun study they were contained within the AD group.

Fig 9. Neuropathological diagnoses in 161 cases 1985-1992

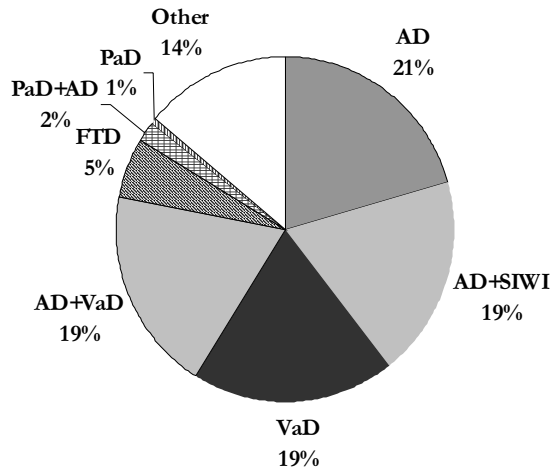
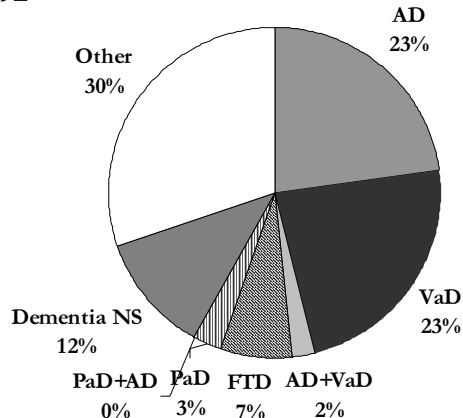


Fig 10. Clinical diagnoses in 581 psychogeriatric patients 1985-1992



Data collection procedure

Initially a protocol was set up with the clinical variables of interest, covering issues such as heredity, social situation, medical history, symptoms, medication, laboratory results, blood pressure measurements, results of dementia investigation, physical examination including neurological findings and clinical rating scales. All available information contained in the patients' medical records was studied, including the often detailed observations noted by the different

staff. If information was too sparse, the cases were excluded (n=12). To test if there was a difference in the collected data over time, information from 5 of the first analysed cases were gathered a second time. The number of items that differed from the first to the second time was less than 1% of the total and in no cases did the dementia classification differ.

The detailed neuropathological data were derived from the autopsy reports.

The process of data analysis

The presence of clinical features was registered dichotomously. Knowing that different clinicians describe and interpret the same phenomenon differently (eg loss of consciousness) we however decided that a symptom was to be considered present only when explicitly noted in the records. The interpretation of the items in the different dementia classification systems was thoroughly discussed before use. Furthermore, available explanatory literature was used in the interpretation of the DLB criteria.

Clinical criteria

188 cases were diagnosed according to three sets of clinical criteria for DLB (McKeith et al., 1992, Byrne et al., 1991, McKeith et al., 1996) although the consensus criteria were used in the present papers. The criteria differ somewhat with a stronger emphasis on parkinsonism in the Nottingham criteria (Byrne) and on the fluctuating course in the Newcastle criteria. Of our 48 cases identified as probable DLB by the consensus criteria, only 15 fulfilled the Newcastle criteria while 27 fulfilled the Nottingham probable and 4 the Nottingham possible criteria.

Furthermore clinical criteria for AD (DSM IV and NINCDS-ADRDA; McKann et al., 1984), The Lund- Manchester criteria (Brun et al., 1994) for the diagnosis of frontotemporal dementia and the DSM IV criteria for vascular dementia were applied.

Differential diagnostic rating scales

Differential diagnostic rating scales “AD-score”(Gustafson and Nilsson, 1982, Brun and Gustafson, 1993), “FTD-score”(Gustafson and Nilsson, 1982) and “Ischemic score” (Hachinski et al., 1975) were also applied to improve the clinical differentiation (Fig 11). The clinical usefulness of the scoring profile of these diagnostic rating scales has been validated against neuropathology and brain imaging (Brun and Gustafson, 1993, Risberg and Gustafson, 1983, Moroney et al., 1997).

Fig 11. Rating Scales for Differential Diagnosis of Dementia

AD score (Gustafson, Nilsson, 1982; Brun, Gustafson, 1993)		FTD score (Gustafson, Nilsson, 1982; Brun, Gustafson, 1993)		Ischemic score (IS) (Hachinski et al., 1975)	
Symptom	Score	Symptom	Score	Symptom	Score
Slow progression	1	Slow progression	1	Abrupt onset	2
Early loss of insight	1	Early loss of insight	1	Stepwise progression	1
Early amnesia for remote events	2	Early signs of disinhibition	2	Fluctuating course	2
Early spatial disorientation (<i>impaired sense of locality</i>)	2	Irritability, dysphoria	1	Nocturnal confusion	1
Dyspraxia, dysphasia, dysgnosia (<i>all symptoms present to some extent</i>)	2	Confabulation, (<i>spontaneous</i>)	1	Relative preservation of person	1
Logoclonia, (<i>stuttering-like speech disturbance</i>)	2	Logorrhoea, (<i>voluble speech</i>)	1	Depression	1
Logorrhoea, (<i>voluble speech</i>)	1	Progressive reduction (<i>and stereotypy</i>) of speech	1 (2)	Somatic complaints	1
Progressive reduction of speech	1	Echolalia, late mutism, amimia (<i>2 or more symptoms present during the course of the disease</i>)	2	Emotional incontinence	1
Epileptic seizure of late onset	1	Klüver-Bucy syndrome: (<i>hyperorality, utilization behaviour</i>)	1	History of hypertension	1
Increased muscular tension	2			History of strokes	2
Myoclonic twitches	1			Evidence of associated atherosclerosis	1
Klüver-Bucy syndrome: (<i>hyperorality, utilization behaviour</i>)	1			Focal neurological symptoms	2
				Focal neurological signs	2
Total score		Total score		Total score	
Max scores 17		Max score 12 (13)		Max score 18	

INSTRUCTIONS: The diagnostic scoring requires reliable information and a detailed clinical examination. The diagnosis is based on the scoring profile.
AD-score $\geq 5-6$ indicates dementia of Alzheimer type. FTD-score ≥ 5 indicates frontal lobe dysfunction. Ischemic-score $\geq 7-8$ indicates vascular etiology.
Mixed AD and vascular dementia is common with increasing age.

Ratings of ADL and dementia - The Katz and Berger indices

The Berger scale (Berger, 1980) was used as a global measurement of the severity of dementia and the Katz index of independence in ADL (Katz et al., 1963) was chosen as a complementary measure of the severity of impairment (Fig 12).

Fig 12.

The Katz Index of ADL (Katz et al., 1963)

A= Independent in feeding, continence, transferring, going to the toilet, dressing and bathing.

B= Independent in all but one of these functions.

C= Independent in all but bathing and one additional function.

D= Independent in all but bathing, dressing and one additional function.

E= Independent in all but bathing, dressing, going to the toilet and one additional function.

F= Independent in all but bathing, dressing, going to the toilet, transferring and one additional function.

G= Dependent in all six functions.

Other= Dependent in at least two functions, but not classifiable as C, D, E or F.

The Berger's scale – a system for rating the severity of dementia (Berger, 1980)

Class I: Can function in any surroundings, but forgetfulness is often disruptive of daily activities.

Class II: Can function without direction only in familiar surroundings.

Class III: Needs direction to function even in familiar surroundings but can respond appropriately to instruction.

Class IV: Needs assistance to function, cannot respond to direction only.

Class V: Remains ambulatory, needs assistance to function, but cannot communicate verbally in a meaningful fashion.

Class VI: Bedridden or confined to chair and responds only to tactile stimuli.

These rating scales have proved to be clinically useful and easy to apply in our care system (Annerstedt et al., 1996). The ratings were based on standardised assessments including reports from social workers and staff responsible for the care of the patients. Each patient was assessed 1-3 times. The first and the last assessment for each patient were chosen to describe the progress of the dementia.

The patient characteristics in study I-V are shown in table 6.

Table 6. Patient characteristics in paper I-V

Paper	Clinical diagnosis	Number	Sex m/f	Mean age (y)	Range
I	Consecutive dementia cases	188	82/106	77	39-97
	DLB	48	20/28	78	58-94
	AD	45	18/27	79	61-97
	VaD	20	10/10	78	66-91
	AD+VaD	13	9/4	77	68-91
	FTD	12	6/6	60	40-85
	other	50	19/31	77	39-94
II	DLB	47-45			
	AD	45-36			
III	DLB	48 (α -sy:16)	20/28 (7/9)	78 (79)	58-94 (60-94)
	AD	45 (α -sy:10)	18/27 (4/6)	79 (78)	61-97 (62-88)
IV	DLB	34 (EEG)	15/19	77	60-94
		26 (rCBF)	14/11	77	60-94
	AD	28 (EEG)	11/17	81	61-91
		25 (rCBF)	9/16	79	73-88
		16 (α -sy:16)	8/8	79	60-94
V	DLB	16 (α -sy:16)	8/8	79	60-94

α -sy= α -synuclein

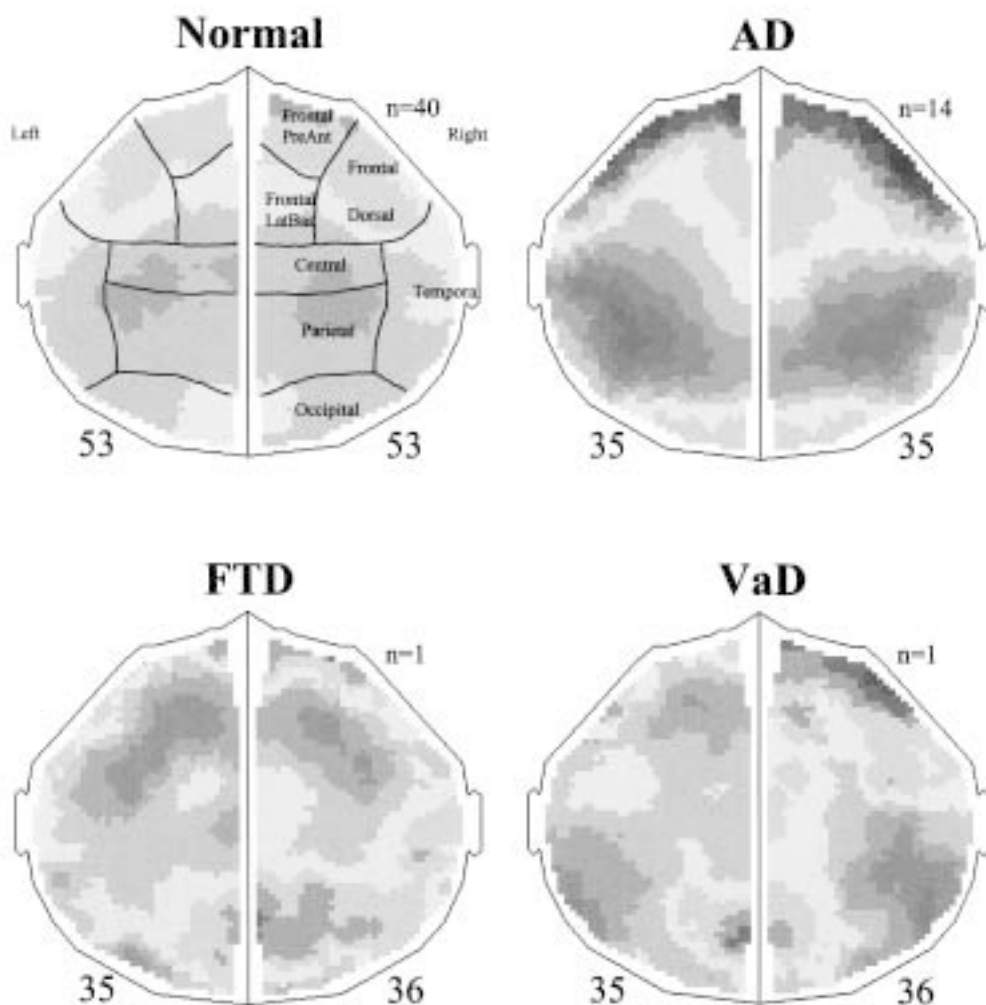
Regional cerebral blood flow

The regional cerebral blood flow (rCBF) was assessed with the xenon-133 inhalation method, developed by Obrist et al., (1975) and modified by Risberg (Risberg et al., 1975, Risberg, 1980), using the Initial Slope Index (ISI) as an indicator of cortical blood flow. rCBF was measured without premedication, in a resting situation with the eyes closed. The inert γ -radiating tracer xenon-133 (90 MBq/l) was inhaled for 1 min through a facemask, followed by 10 min breathing of ordinary air. Up to 1986 the rCBF was assessed with 32-detector equipment, which was then replaced by a high-resolution recording device with 254 scintillation detectors (Cortexplorer 256 HR; Ceretronix Inc, Randers, Denmark), which gave a spatial resolution of about one cm for the superficial cortex. Absolute values of the blood flow were obtained for each region. For

technical reasons only group results based on rCBF registrations with 254 channels will be presented here (IV). The individual rCBF results (IV, V) are displayed as interpolated flow maps with a colour coding of the regional values as a percentage of the individual mean flow (Risberg, 1986).

Examples of rCBF findings in normals, AD, FTD and VaD are shown in Fig 13.

Fig 13. Regional cerebral blood flow in normals, Alzheimer's disease, Frontotemporal dementia and Vascular dementia. Regions of interest are shown on the normals.



Electroencephalogram

Electroencephalogram (EEG) was recorded with 16 or 24 channel electroencephalographs (Siemens Elema or Nihon Kodhen, time constant 0.3 s; low pass filter 70 Hz) with electrode positions according to the 10-20 system. Bipolar and common reference montages were used. Periods of drowsiness were counteracted by sound stimuli.

The EEG records were reanalysed visually regarding dominant activity frequency, presence of focal abnormalities, side asymmetry, epileptiform activity and degree of abnormality. This was done without any knowledge of the clinical diagnosis. The degree of EEG background abnormality was classified in four categories:

1. Normal EEG.
2. Slightly pathologic. Posterior-dominant frequency within normal range ($>8\text{Hz}$). Increase of diffuse and/or episodic theta.
3. Moderately pathologic. Posterior-dominant frequency $<8\text{Hz}$. Moderate increase of delta waves.
4. Highly pathologic. Posterior dominant frequency $\leq 6\text{Hz}$. Marked increase of delta waves.

Neuropathology

The neuropathological procedures included laboratory standard measures of whole brain immersion fixation in 4% formaline and in addition intraventricular injection of formaline, for a more rapid central white matter fixation. Fixation times averaged 2-3 weeks. The entire brain was then cut in $\frac{1}{2}$ -1 cm thick coronal slices, and every other slice was paraffin-embedded and cut in five micra thick sections. The semi-serial section technique with subsequent extensive microscopical analysis was used as a prerequisite for a safe neuropathological mapping of type, severity and distribution of changes and also for the detection or exclusion of other types of clinically significant brain pathology. Staining routines included Hematoxylin/Eosin for overall detail assessment and Luxol Fast Blue with cresyl violet counter staining for myelin and appreciation of cell numbers. Congo red for amyloid and Van Gieson-elastica staining for meningeal, vascular fibrosis and degeneration were used in selected sections.

Campbell and Gallyas methods were used for the detection of neuritic plaques, dystrophic neurites and NFT while ubiquitin staining was used for protein degradation and Lewy bodies. The regional distribution and severity of white matter changes were mapped and quantitated according to a grading system with three main degrees, used previously for correlation with quantitative neu-

rochemical measures (Englund et al., 1988). This assessment was combined with a similar mapping of the grey matter Alzheimer pathology using a grading system, which combines a number of histological variables (Brun and Englund, 1981). AD was defined as a combination of pathological changes such as neuronal loss, gliosis, microvacuolation, NFT, neuritic plaques and dystrophic neurites. In terms of severity it ranges from a basal encephalopathy consistent with normal ageing (grade 0) to a level of severity recognised as AD grade I=mild, II=moderate and III=severe. The large and small vessel pathology was mapped including carotid arteriosclerosis, amyloid angiopathy and central white matter arteriolosclerosis as well as other, specific vascular changes. Incomplete infarcts restricted to the white matter are named selective incomplete white matter infarcts (SIWI). These are characterized by a reduction of both myelin and oligodendroglial cells with mild reactive changes, suggestedly appearing as a result of regionally reduced cerebral perfusion due to subcortical small vessel disease combined with systemic hypotension (Englund et al., 1988). To amplify the detection of Lewy bodies, cases were reinvestigated with α -synuclein, tau, ubiquitin and GFAP antibodies. Lewy bodies were defined as rounded, non-fibrillary intensely immunoreactive inclusions. Complementary tissue sections for this purpose were taken from the mesencephalon, cingulate gyrus, hypothalamus, basal temporal cortex including the hippocampus, parietal cortex and the frontal pole cortex.

Main features of paper I

Clinical Lewy body dementia and the impact of vascular components

Dementia with Lewy bodies have gained increasing attention during the last 15 years. A number of studies have identified a clinical symptom constellation overrepresented in these cases, summarized in the clinical consensus criteria from 1996 (McKeith et al.,). The clinical diagnosis DLB has not previously been used in a systematic way within the framework of the Lund longitudinal dementia study. We therefore addressed the question whether cases with signs of DLB were identifiable in this study and how they could be described clinically and neuropathologically compared to clinically identified AD cases. Clinical criteria of DLB, AD and other dementias were applied retrospectively on the medical records from 200 consecutively post mortem investigated cases all of whom participated in the prospective longitudinal dementia study when they were alive. The results of clinical differential rating scales, ADL measurements, dementia ratings and brief neuropathological findings were compared between clinically diagnosed DLB and AD cases.

Results

1. 48 cases, 20 men and 28 women (age range 58-94 years) fulfilled the clinical criteria of probable DLB.
2. In comparison with clinically diagnosed AD, the clinical DLB cases showed a higher prevalence of frontal clinical signs such as disinhibition, personality change and vocally disruptive behaviour.
3. In the differential diagnostic rating, the clinical DLB cases showed an AD score equal to the clinical AD cases and a significantly higher ischemic score. There was also a trend towards more signs of frontal lobe damage in FTD score in comparison to clinical AD.
4. The clinical DLB cases were more deteriorated in ADL capacity at an earlier stage of dementia compared to clinical AD cases and 83.3% of DLB had deteriorated to the most severe level at the last measurement.
5. Neuropathology revealed a high degree of Alzheimer pathology in both clinical groups. Vascular pathology in the shape of frontal white matter changes was more common in clinical DLB cases in which also the degeneration of SN was also more advanced.

Comments

Many studies have investigated the prevalence of DLB both from neuropathological (Lennox et al., 1989ab; Hansen et al., 1990; Perry et al., 1990b) and clinical (Shergill et al., 1994) standpoints although relatively few studies have addressed consecutive dementia cases.

The prevalence of DLB symptoms in our clinically defined cases were in accordance with what has been reported in earlier neuropathologically identified cases (Byrne et al., 1989, Perry et al., 1990b, McKeith et al., 1994a, Lennox, 1992). The finding of more frontal signs in DLB is in accordance with results of studies showing frontal atrophy (Förstl et al., 1993) and frontal signs in EEG (Burkhardt et al., 1988), neuropsychology (Hansen et al., 1990) and neuropathology- synapses (Hansen et al., 1998).

An increased ischemic score in neuropathologically defined DLB cases was considered to be a contributory factor to the misdiagnosis of vascular dementia (McKeith et al., 1994a). In a substantial number of our clinical DLB cases, however, cerebrovascular pathology was diagnosed.

Main features of paper II

Blood pressure and drug treatment in clinically diagnosed Lewy body dementia and Alzheimer's disease.

At least two types of biochemical deficiencies in DLB have been seen: cholinergic (Perry et al., 1994) and dopaminergic (Eggertson and Sima, 1986). These deficiencies have created a clinical situation with a complicated interplay of symptoms and reactions to pharmacological treatment. Patients with Lewy bodies often show neuroleptic sensitivity which sometimes lead to fatal consequences (McKeith et al., 1992b). EPS are common adverse effects of neuroleptics in the same way as hallucinations could be to antiparkinson agents. In DLB both psychotic symptoms and parkinsonism are contained within the consensus criteria. Several of the separate clinical symptoms within DLB such as syncope, falls, fluctuations and transient loss of consciousness could also be consequences of failure in the autonomic blood pressure regulation (Bradshaw and Edward, 1986, Rubenstein and Robbins, 1984, Tinetti, 1986). Several papers have recognized orthostatic hypotension in DLB (Kuzuhara et al., 1996, Ballard et al., 1999b).

In the present study we investigated the blood pressure, both during the course of the dementia and in orthostatic tests, as well as the pharmacological treatment in clinically diagnosed DLB compared to AD cases.

In 48 clinically diagnosed DLB and 45 clinical AD cases results of blood pressure measurements and pharmacological treatment were analysed. Drugs considered potentially hypotensive were antihypertensive agents, diuretics, neuroleptics, benzodiazepins and antiparkinson agents.

Results

1. During the course of dementia there was a similar blood pressure decrease in the clinical DLB and AD cases.
2. A higher number of cases in the clinical DLB group developed arterial hypotension (systolic blood pressure <120 mmHg) during the course of dementia compared to the cases with clinical AD.
3. There was a trend towards a more pronounced drop in systolic blood pressure at orthostatic testing in clinical DLB compared to AD.
4. Compared to clinical AD, the clinical DLB cases had a higher pharmacological load with a higher prevalence of antiparkinsonian treatment, a higher number of neuroleptics and other medication potentially associated with hypotension.

Comments

Blood pressure has in several studies been shown to decrease during dementia (Burke et al., 1994, Guo et al., 1996, Passant et al., 1996, Hogan et al., 1997, Fredriksson et al., 1992) in contrast to the normal situation with a continuous increase with age (Landahl et al., 1986, Bots et al., 1991). This has been investigated with a longitudinal perspective in both AD and vascular dementia but not in DLB. Orthostatic blood pressure has been described in many DLB cases but has not been compared with AD in terms of actual levels. The blood pressure reactions may be explained in at least two ways; either as caused by the brain damage (analogous to Lewy bodies located in sympathetic ganglia) or in itself causing the brain damage (analogous to selective white matter infarcts caused by hypoperfusion of arteriolosclerotic brain vessels). Part of the last theory is the possible contribution of hypotensive medication or medication with hypotensive side effects.

Our DLB cases had a higher pharmacological load during dementia with more potentially hypotensive medication.

Main features of paper III

The neuropathological correlates to clinically defined dementia with Lewy bodies

The role of the Lewy body per se is not yet known. A common hypothesis is that there is an association between Lewy bodies and neuronal stress (Pollanen et al., 1992, Kremeer and Bots, 1993). The Lewy body is however, the neuropathological hallmark of PaD (Greenfield and Bosanquet, 1953, Bethlem and Den Hartog Jager, 1960) even though it is not specific for this disease (Helfand, 1935, Sigwald et al., 1964, Hirano et al., 1967, Hishikawa et al., 2000). Within the DLB concept several neuropathological pictures, ranging from a rare pure Lewy body disease to a more common Lewy body variant of Alzheimer's disease exist. The clinical criteria of DLB have in several studies been found to be highly sensitive (Mega et al., 1996, McKeith et al., 2000a,b). It was therefore of interest to investigate the accuracy of the clinical DLB criteria in our patient population, using the most sensitive staining technique available, α -synuclein antibodies. It was also considered important to analyse in detail the previous results of the neuropathology. These were done routinely as whole brain semiserial sections, a prerequisite for a safe neuropathological mapping of type, severity and distribution of changes and also for the exclusion of other types of clinically significant brain pathology.

All cases in our previously investigated clinical DLB (n=48) and AD (n=45) groups were investigated neuropathologically. 16 clinical DLB and 10 clinical AD cases were reassessed using α -synuclein staining.

Results

1. The degree of AD pathology, present in >80% of clinical DLB and clinical AD cases, was the same. Clinical AD cases had more temporal and hippocampal pathology and a higher degree of NFT than the clinical DLB cases.
2. The degeneration of the SN was more pronounced in clinical DLB.
3. Lewy bodies were found in 14% of clinical DLB and 9% of clinical AD cases. With α -synuclein staining these percentages increased to 38% and 40% respectively.
4. Frontal white matter pathology was significantly more common in clinical DLB compared to clinical AD.
5. There was a greater difference in the concomitant pathology in the clinical DLB group than in the clinical AD group.

6. Within the clinical DLB group; cases with actual Lewy bodies had a lower degree of Alzheimer pathology and frontal white matter pathology but a higher degree of SN degeneration.
7. 50% of the cases with Lewy bodies had significant vascular pathology.
8. The main pathological diagnoses in the cases with Lewy bodies were strongly divergent.

Comments

Several main neuropathological features in the clinical DLB cases, such as a lower degree of AD changes in the temporal lobes and in the hippocampus and a higher degree of NFT, were in accordance with results from studies performed on neuropathologically defined cases (Gibb, 1989b, Hansen et al., 1993, Förstl et al., 1993). In contrast to other studies we did not find a high prevalence of Lewy bodies. This could be due to: lower specificity of the clinical criteria when applied to consecutive dementia cases which often exhibit mixed pathologies (Holmes et al., 1999), a systematic error within the retrospective approach or that combinations of other pathologies may produce the same clinical picture. In our clinically diagnosed DLB group the pathological combination of AD with frontal white matter pathology, mostly of the SIWI type, seemed to “mimic” true DLB verified by neuropathology.

The neuropathological technique with whole brain semiserial sections probably contributed to the finding of additive pathologies, which could be overlooked with a small sample method.

Main features of paper IV

Regional cerebral blood flow and EEG in clinically diagnosed dementia with Lewy bodies and Alzheimer’s disease

EEG and rCBF are highly valuable tools in the differential diagnosis of dementia. These two methods mirror mainly cortical function, which is of special interest considering that it has been claimed that cortical Lewy body density correlates with dementia (Lennox et al., 1989b, Samuel et al., 1997). In the fourth paper we addressed the question of whether EEG and rCBF findings would be helpful in the differentiation between clinical DLB and clinical AD. Furthermore, with neuropathological data at hand, were there any differences between the cases with and without Lewy bodies among the clinically defined DLB cases?

Available EEGs in our diagnostic groups (DLB n=34 and AD n=24) were analysed by visual inspection while cases with rCBF measured by the 254-detector technique (DLB n=26 and AD n=25) were compared according to a statistical mapping system.

Results

1. EEG and rCBF were very similar in the clinical DLB and clinical AD groups.
2. EEG showed a general slowing with increased theta activity in both clinical groups.
3. rCBF showed temporoparietal blood flow decrease in both clinical groups.
4. Within the clinical DLB group EEG did not differ between cases with and without Lewy bodies at neuropathological examination.
5. There was no consistent feature in the rCBF patterns in cases with Lewy bodies within the clinical DLB group.

Comments

Our findings of a temporoparietal blood flow decrease in both clinical AD and DLB are in accordance with results from previous studies (Donnemiller et al., 1997, Turjanski et al., 1997, Varma et al., 1997). We could not however, confirm studies showing an additional occipital flow component in DLB cases (Albin et al., 1996, Ishii et al., 1999). Both EEG and rCBF patterns in the clinically defined groups were in accordance with that seen in AD, and subsequently indistinguishable from findings in PaD with dementia (Pizzolato et al., 1988, Spampinato et al., 1991, Liu et al., 1992). The different components from these pathologies could therefore not be singled out.

The rCBF patterns of the cases within the clinical DLB group with Lewy bodies verified neuropathologically, differed highly from each other, possibly reflecting the varying additional pathologies found in these cases.

Main features of paper V

Contributions of other brain pathologies in Dementia with Lewy bodies

Our earlier studies have shown that cases fulfilling clinical criteria of DLB had a prevalence of Lewy bodies in 38% when α -synuclein staining was used. These cases also had other pathologies at neuropathological examination. Since it has been claimed that the prevalence of Lewy bodies in different locations of the brain form a probable neuropathological basis of the specific symptomatology of DLB (Lennox et al., 1989b, Perry et al., 1990b, Perry et al., 1991), we analysed the cases with a clinico-pathological correlative approach.

From our clinical dementia cohort of 200 cases, 48 were found to fulfil the clinical consensus criteria of DLB. Sixteen of these were reassessed with α -synuclein staining. The medical history, clinical findings and neuropathology were analysed individually in these cases and interpreted clinico-pathologically. Six of the cases exhibited Lewy bodies located in mainly subcortical but in 3 cases also in cortical regions, while 10 cases had no Lewy bodies.

Results

1. There were no obvious clinical differences between the cases with and without Lewy bodies.
2. All cases had other neuropathological findings besides Lewy bodies.
3. The originally given neuropathological diagnoses in the six cases with Lewy bodies were diverse; AD alone or in combination with cortical or subcortical VaD and Parkinsonian changes, as well as frontal lobe degeneration of non Alzheimer type, while the original neuropathological diagnoses in the ten cases without Lewy bodies were similar showing AD in all cases, combined with vascular pathology in 7 cases.
4. The rCBF of the cases with Lewy bodies were different from each other and in accordance with the neuropathological diagnoses in 4 of these cases while the rCBF of the cases without Lewy bodies showed temporo-parietal blood flow decrease combined with a frontal decrease in most cases.
5. Cases with Lewy bodies had a generally lower degree of Alzheimer pathology in all but one case compared to cases without Lewy bodies. In these cases all had Alzheimer pathology, generally combined with vascular pathology, especially white matter changes with a frontal location.

6. SN degeneration was seen in the majority of cases with Lewy bodies while those without Lewy bodies had no or only mild degeneration.
7. Among the cases with Lewy bodies a higher number of EPS were seen when SN showed degeneration while in the majority of the cases without Lewy bodies EPS were seen in all but one case with frontal white matter pathology.
8. Cases with hallucinations with or without Lewy bodies, had combinations of sensory deprivation and neuropathological lesions in the temporal and frontal lobes.
9. The mean blood pressure decreased during dementia in all cases with Lewy bodies and in almost all cases without Lewy bodies.
10. Symptoms such as fluctuations, episodes of confusion and falls seemed to be related in time to blood pressure decreases in both groups.
11. Pharmacological treatment probably enhanced the blood pressure decrease in several of the cases.
12. In 5 of the 6 cases with Lewy bodies other neuropathological changes (except the Lewy bodies) could have accounted for the clinical picture.

Comments

In all cases the complicated interplay between previous medical conditions, such as arterial hypertension, the timing of the appearance of clinical symptoms, pharmacological treatment and finally neuropathological lesions was obvious. Evaluating the influence of different neuropathological lesions is delicate and not only a statistical procedure since the intensity, location, volume and extent have to be taken into account. The case-study approach might therefore be complementary to studies of larger group data. Smaller lesions such as Lewy bodies may serve as markers of more widespread biochemical pathology, (Woodard et al., 1962, Perry et al., 1997) and in that way add to the total burden of neuropathology. A Lewy body might also be a coexisting phenomenon to other neuropathological lesions indicating neuronal stress.

Conclusions

In societies with an increasing number of elderly inhabitants the issue of dementia, its recognition, treatment and care is of essential importance. DLB has been increasingly recognized as a clinical syndrome with important pharmacological considerations.

The present study has shown that:

1. During their course of illness, 24% of consecutively selected dementia cases developed symptoms contained within the clinical consensus criteria for DLB.
2. The clinical DLB patients were more demented and impaired in ADL at an early stage of dementia compared to cases with clinically diagnosed AD and 83% of the clinical DLB patients were totally reliant on assistance after 5 years of dementia.
3. Arterial blood pressure decreased during dementia in both the clinical DLB and AD cases, although more individuals with clinical DLB developed hypotension.
4. The pharmacological burden during the illness was higher in the clinical DLB cases with more neuroleptics, antiparkinson medication and other potentially hypotensive drugs.
5. The clinical consensus criteria of DLB identified cases with Lewy bodies at neuropathological assessment in 38% using α -synuclein antibodies.
6. Lewy bodies were also found in 40% of clinical AD cases using α -synuclein antibodies.
7. Alzheimer pathology was the most prevalent type of neuropathological change seen in 81% of the clinical DLB and 93% of the clinical AD cases.

8. The cases without Lewy bodies, still fulfilling the clinical DLB criteria, were characterized as having a higher degree of Alzheimer pathology combined with frontal white matter changes, mainly of the SIWI type.
9. Clinical DLB cases had more diverse and more often combinations of different pathologies, compared to clinical AD cases.
10. Vascular pathology was recognised in 50% of all cases (both the clinical DLB and AD) exhibiting Lewy bodies.
11. Neuroimaging, EEG and rCBF, was not helpful in discriminating clinical groups of DLB and AD. Neither were there any discriminating, specific patterns characterizing cases with or without Lewy bodies.
12. In individual clinical-pathological analysis of the cases fulfilling both clinical and neuropathological criteria of DLB it was obvious that combinations of different pathological lesions could be explanatory for the symptoms within the DLB criteria in the majority of the cases.

This study still leaves several questions about the functions of Lewy bodies in dementia unanswered. The role of other brain lesions, especially of vascular origin, has to be further investigated since this might have therapeutic potentials of possible prevention. There is a need for a continuation of longitudinal studies with broad assessment of symptom development, neuroimaging and neuropathological examination to refine the clinical criteria of dementia with Lewy bodies. Furthermore, possibly pharmacological studies in clinical DLB will be able to contribute to answering the question of whether the Lewy bodies per se are the main interest or the clinical symptom constellation, indicating a certain mixture of neurochemical disturbances, is the target.

With advances in imaging techniques, genetics and immunocytochemistry the differential diagnosis in dementia remains a perpetual field of challenge.

General summary in Swedish (populärvetenskaplig sammanfattning på svenska)

Demens med Lewy bodies - en ny demenssjukdom

Vid sidan av de klassiska demensformerna Alzheimers sjukdom, blodkärlsdemens och frontallobsdemens har forskargrupper från flera håll i världen på senare år funnit tecken på en ny demensform som man kallar ”demens med Lewy bodies (DLB)”. Sjukdomen bär drag av både Alzheimers och Parkinsons sjukdom och därför är forskare oeniga om huruvida den är en egen sjukdom, en blandning av dessa eller en variant av Alzheimers sjukdom. På grund av lovande resultat av behandling med läkemedel mot Alzheimers sjukdom har DLB blivit allt mer uppmärksammasad.

Vad är Lewy bodies?

Lewy bodies är små proteinansamlingar i nervcellerna som endast kan ses vid en neuropatologisk undersökning. Lewy bodies kan finnas i olika delar av hjärnan men är vanligast i hjärnstammen, särskilt i den svarta substansen (substantia nigra). Lewy bodies är typiska för Parkinsons sjukdom men finns även vid andra sjukdomstillstånd och hos icke-dementa i ökad andel med ökande ålder. Ingen vet med säkerhet vilken funktion Lewy Bodies har i hjärnan även om en vanlig uppfattning är att de associeras med cellstress och nervcellsöd.

Vad är demens med Lewy bodies?

Forskare i England, Japan och USA fann att patienter med Lewy bodies tycktes ha flera gemensamma kliniska drag: synhallucinationer, parkinsonliknande rörelsemönster och variationer i uppmärksamhet och vakenhet. Ibland sågs även överkänslighet för antipsykosläkemedel (neuroleptika), vanföreställningar, svimning och fall. Vid ett forskarmöte 1996, där målsättningen var att enas i definitioner av DLB, formulerades kliniska kriterier för att känna igen patienter med Lewy bodies.

Undersökningar av avlidna patienter med DLB har visat brist på de båda neurotransmittorerna dopamin och acetykolin.

Svårigheter

Diagnosen kan endast ställas med säkerhet efter döden. Det finns alltså inga diagnostiska hjälpmedel i form av labprover, datortomografi/magnetrontgen, hjärnblodflödesmätning eller EEG att förlita sig på. Symptomen i DLB är inte

entydigt typiska för sjukdomen utan ingår även i andra demensdiagnoser. De enskilda symptomen i DLB är svåra att behandla med läkemedel då behandlingen i sig ger bieffekter som är identiska med symptom i kriterierna för DLB.

Syftet med avhandlingen

Syftet med denna avhandling var att:

- undersöka om det inom Lunds longitudinella demensprojekt fanns patienter som uppfyllde de kliniska kriterierna för DLB

- beskriva och jämföra en klinisk DLB grupp med en klinisk Alzheimer grupp avseende

symptom och funktions nivå i dagliga aktiviteter (ADL), blodtryck och läkemedelsbehandling, hjärnfunktion i EEG och hjärnblodflöde samt slutligen neuropatologisk bild.

Resultat

Arbete I: Vi fann att en knapp fjärdedel av 200 patienter, som alla utretts för misstänkt demenssjukdom, uppfyllde de kliniska kriterierna på DLB. Symptomen fördelade sig helt i enlighet med vad andra studier visat trots att man då valt ut patienter med neuropatologisk DLB.

Arbete II: DLB patienternas blodtryck var inte stabilt utan sjönk över demensförloppet. Det sjönk också påtagligt vid uppresning från liggande till stående. DLB patienterna behandlades också med fler läkemedel mot Parkinsons sjukdom, psykotiska symptom och med läkemedel som sänker blodtrycket. Detta gör att en bedömning av vad som är symptom i sig respektive bieffekter av medicin eller lågt blodtryck försvåras.

Arbete III: Den neuropatologiska bilden hos de kliniskt definierade DLB patienterna var till många delar lik den som beskrivits hos patienter med Lewy bodies. Dock var andelen med Lewy bodies förvånansvärt låg (38%) även då vi använt de mest känsliga neuropatologiska färgningsteknikerna. Hälften av DLB patienterna hade kärlförändringar som lett till betydande skador i hjärnan. Detta är ett fynd som inte tidigare beskrivits i så hög omfattning vid DLB. Många DLB patienter hade kombinationer av olika sjukliga förändringar i hjärnan vilka tillsammans kan ha gett upphov till symptombilden.

Arbete IV: Resultaten av hjärnavbildande tekniker som EEG och hjärnblodflödesmätning visade sig inte vara till hjälp för att särskilja DLB patienter från Alzheimerpatienter eller för att inom den kliniska DLB gruppen

urskilja patienter med Lewy bodies. Hos patienterna med Lewy bodies var dessutom blodflödesbilderna sinsemellan mycket olika och hade under patientens levnad tolkats som uttryck för olika sjukdomar.

Arbete V: Ingående individuella granskningar av 16 fall med klinisk DLB (6 med och 10 utan Lewy bodies) gjordes för att försöka värdera olika hjärnförändringars betydelse för de gemensamma kliniska symptomen. Det visade sig att majoriteten av patienterna hade förändringar i hjärnan, förutom Lewy bodies, som i sig skulle kunna förklara eller bidra till DLB symptomen. Alla patienterna hade dessutom ett blodtryck som uppenbart sjönk under demensförloppet vilket i sin tur ytterligare kunde bidra till flera av symptomen.

Sammanfattning

Resultaten visar att det bland patienter som utretts på misstanke om demenssjukdom fanns många som uppfyller de kliniska kriterierna för DLB. Mer än hälften av dessa hade inga Lewy bodies utan andra patologiska förändringar i hjärnan. Dessutom hade även de flesta patienter med Lewy bodies ett flertal andra neuropatologiska orsaker till utvecklingen av sina symptom. En möjlig orsak till våra neuropatologiska fynd kan vara att våra neuropatologer använder en teknik där de kan titta på hjärnan i storsnitt och därför kunnat värdera utbredningen av skadorna i sin helhet. Det vanligaste sättet annars är att undersöka små bestämda bitar av hjärnan. Våra kliniska DLB patienter hade dock bl a skador i hjärnområden som är viktiga för produktion av neurotransmittorerna acetylcolin och dopamin oavsett förekomst av Lewy bodies. Dessa skador bidrar till att symptomkombinationen parkinsonism, psykotiska symptom, överkänslighet för neuroleptika kombinerat med variationer i uppmärksamhet och vakenhet kan uppstå. Eftersom patienter med dessa kemiska brister är särskilt svåra att behandla med läkemedel är det en viktig grupp att känna igen. Det kan även vara viktigt att avstå från viss behandling som neuroleptika och läkemedel som ogynnsamt påverkar blodtrycket. Det är därför viktigt att undersöka blodtrycket på patienterna i både liggande och stående samt vara lyhörd för olika symptom på otillräcklig blodcirkulation i hjärnan.

Acknowledgements

Life is full of possibilities. I am so happy that I followed my intuition and heart on that day in May 1997 when I was asked to join the research group at the Department of Psychogeriatrics, University Hospital, Lund.

I want to express my special and sincere thanks to:

My three tutors who have complemented each other in this role in the most excellent way.

Lars Gustafson, professor of Old Age Psychiatry and head of the department, for creating a unique scientific surrounding, for his patience, inexhaustible knowledge and encouragement,

Arne Brun, professor of Neuropathology, for sharing his neuropathological wisdom and always being prepared for a new manuscript,

Ulla Passant, head of the clinic at the time, for supervision in large and small matters, her concern and skilled guidance and for generously introducing me to everybody in the field, nationally and internationally and

to all three for very, very good times (the best of my working years), with life lengthening laughter and for so generously offering me their friendship.

Ingemar Rosén and **Jarl Risberg**, professors of Neurophysiology and Neuropsychology for co-authorship (read tutoring), deep knowledge and fast thinking.

Maria Sjöström for enthusiastic and professional help far beyond working hours with manuscripts and writing the thesis.

Siv Börjesson and **Helena Andersson** for help with figures and design.

Rose Reddy for patiently helping me with my English writing.

Christina Elfgren for sharp scientific comments and great fun.

Sonja, Gunilla, Irene and **Hans** for making my clinical work run smoothly.

The **hospital library** for unusual servicemindedness.

My neighbours and friends, **Anders** and **Kristina Lind** for help with my Swedish and with computer service.

Martin Bäckström for explaining statistics.

The research group, **Ann, Aki, Elisabet (Bitte), Karin, Susanna**, and **Ulla** for their kindness and support.

Bengt for technical support whenever needed.

Finally I want to thank **Mikael** for putting up with everything: listening to monologues about Lewy bodies, taking care of our home and children and never giving up the hope of a time for us to come (it will) and to my dear children, **Ludvig, Andreas** and **Isabella** who have paid the highest price for the last few years but constantly give me reasons to smile.

International Journal of Geriatric Psychiatry is thanked for kindly letting me reprint Paper I and print Paper III.

Archives of Geriatrics and Gerontology is thanked for kindly letting me reprint Paper II.

The Swedish Alzheimer foundation and the Sjöbring foundation have throughout the project been most supportive.

References

- Aarsland D, Bronnick K, Karlsen K. Donezepil for dementia with Lewy bodies: a case study. *Int J Geriatr Psychiatry*. 1999;14:69-72.
- Agamanolis DP, Greenstein JI. Ataxia-telangiectasia. Report of a case Lewy bodies and vascular abnormalities in the cerebral tissue. *J Neuropathol Exp Neurol*. 1979;38:475-489.
- Ala TA, Yang K-H, Sung JH, Frey II WH. Hallucinations and signs of parkinsonism help distinguish patients with dementia and cortical Lewy bodies from patients with Alzheimer's disease at presentation: a clinicopathological study. *J Neurol Neurosurg Psychiatry*. 1997;62:16-21.
- Albin RL, Minoshima S, D'Amato CJ, Frey KA, Kuhl DA, Sima AAF. Fluorodeoxyglucose positron emission tomography in diffuse Lewy body disease. *Neurology*. 1996;47:462-466.
- Alexopoulos GS, Meyers BS, Young RC, Kakuma T, Silbersweig D, Charlson M. Clinically defined 'vascular depression'. *Am J Psychiatry*. 1997;154:562-565.
- Allard P, Englund E, Marcusson J. Reduced number of caudate nucleus dopamine uptake sites in vascular dementia. *Dement Geriatr Cogn Disord*. 1999;10:77-80.
- Allard P, Alafuzoff I, Carlsson A, Eriksson K, Gottfries CG, Marcusson JO. Loss of dopamine uptake sites labelled with [3 H] GBR-12935 in Alzheimer's disease. *Eur Neurol*. 1990;30:181-185.
- Allen RL, Walker Z, D'At PJ, Katona CLE. Risperidone for psychotic and behavioural symptoms in Lewy body dementia. *Lancet*. 1995;346:185.
- Alzheimer A. Über eine eigenartige erkrankung der hirnrinde. *Allg. Z. Psychiat*. 1907;64:146-148.
- Annerstedt L, Sanada J, Gustafson L. A dynamic long-term care system for the demented elderly. *Int J Psychogeriatr*. 1996;8:561-573.
- Arai H, Morikawa Y, Higuchi M, Matsui T, Clark CM, Miura M, Machida N, Lee VM, Trojanowski JQ, Sasaki H. Cerebrospinal fluid tau levels in neurodegenerative diseases with distinct tau-related pathology. *Biochem Biophys Res Commun*. 1997;236:262-264.
- Armstrong RA, Cairns NJ, Lantos PL. Dementia with Lewy bodies: clustering of Lewy bodies in human patients. *Neurosci Lett*. 1997;224:41-44.
- Babikian V, Ropper AH. Binswanger's disease: A review. *Stroke*. 1987;18:2-12.

- Bahloh RW, Yue Q, Socotch TM, Jacobson KM. White matter lesions and disequilibrium in older people. I. Case-control comparison. *Arch Neurol.* 1995;52:970-974.
- Ballard C, Grace J, McKeith IG, Holmes C. Neuroleptic sensitivity in dementia with Lewy bodies and Alzheimer's disease. *Lancet.* 1998;351:1032-33.
- Ballard CD, Holmes C, McKeith IG, Niell D, O'Brien J, Cairns N, Lantos P, Perry E, Ince P, Perry R. Psychiatric morbidity in dementia with Lewy bodies: a prospective clinical and pathological comparative study with AD. *Am J Psychiatry.* 1999a;156:1039-1045.
- Ballard CG, Shaw F, Lowery K, McKeith I, Kenny R. The prevalence, assessment and associations of falls in dementia with Lewy bodies and Alzheimer's disease. *Dement. Geriatr. Cogn. Disord.* 1999b ;10:97-103.
- Barber R, Gholkar A, Scheltens P, Ballard C, McKeith IG, O'Brien JT. Medial temporal lobe atrophy on MRI in dementia with Lewy bodies. *Neurology.* 1999;56:1153-1158.
- Barthus RT, Dean RL, Beer B, Lippa AS. The cholinergic hypothesis of geriatric memory dysfunction. *Science.* 1982;217:408-417.
- Benson DF, Cummings JL, Tsai SY. Angular gyrus syndrome simulating Alzheimer's disease. *Arch Neurol.* 1982;39:616-620.
- Berger EY. A system for rating the severity of senility. *J Am Geriatr Assoc.* 1980;38:234-236.
- Bergeron C, Pollanen M. Lewy bodies in Alzheimer's disease – one or two diseases? *Alz Dis Assoc Disord.* 1989;3:197-204.
- Betard C, Robitaille Y, Gee M, Tiberghien D, Larrivee D, Roy P, Mortimer JA, Gauvreau D. Apo E allele frequencies in Alzheimer's disease, Lewy body dementia, Alzheimer's disease with cerebrovascular disease and vascular dementia. *Neuroreport.* 1994;5:1893-1896.
- Bethlem J, DenHartog Jager WA. The incidence and characteristics of Lewy bodies in idiopathic paralysis agitans (Parkinson's disease). *J Neurol Neurosurg Psychiatr.* 1960;23:74-80.
- Binswanger O. Die Abgrenzung der allgemeinen progressiven Paralyse. *Berl Klein Wochenschr.* 1894;31:1103-1105, 1137-1139, 1180-1186.
- Birkett P, Desouky A, Han L, Kaufman M. Lewy bodies in psychiatric patients. *Int J Geriatr Psychiatry.* 1992;7:235-240.
- Blennow K, Wallin A, Uhlemann C, Gottfries CG. White matter lesions on CT in Alzheimer patients: relation to clinical symptomatology and vascular factors. *Acta Neurol Scand.* 1991;83:187-193.
- Blennow K, Wallin A. Clinical heterogeneity of probable Alzheimer's disease. *J Geriatr Psychiatr Neurol.* 1992;5:106-113.

- Bogerts B. The role of limbic and paralimbic pathology in the etiology of schizophrenia. *Psychiatry Res.* 1989;29:255-256.
- Bogousslavsky J, Ferrazzini M, Regli F, Assal G, Tanabe H, Deleloye-Bischof A. Maniac delirium and frontal-like syndrome with paramedian infarction of the right thalamus. *J Neurol Neurosurg psychiatry.* 1988;51:116-119.
- Bondareff W, Mountjoy CQ, Roth M. Loss of neurons of origin of the adrenergic projection to cerebral cortex (nucleus locus ceruleus) in senile dementia. *Neurology.* 1982;32:164-168.
- Bots M, Grobbee E, Hofman A. High blood pressure in the elderly. *Epidem Rev.* 1991;13:294-314.
- Bowen DM, White P, Flack RH, Smith CB, Davison AN. Brain-decarboxylase activities as indices of pathological change in senile dementia. *Lancet.* 1974;I:1247-1249.
- Bowen DM, Smith CB, White P, Davison AN. Neurotransmitter-related enzymes and indices of hypoxia in senile dementia and other abiotrophies. *Brain.* 1976;99: 459-496.
- Braak H, Braak E. Neuropathological staging of Alzheimer-related changes. *Acta Neuropathol.* 1991;82:239-259.
- Bradshaw MJ, Edwards RTM. Postural hypotension – pathophysiology and management. *Quarterly J Med.* 1986;231:643-657.
- Briel RC, McKeith IG, Barker WA, Hewitt Y, Perry RH, Ince PG, Fairbairn AF. EEG findings in dementia with Lewy bodies and Alzheimer's disease. *J Neurol Neurosurg Psychiatry.* 1999;66:401-403.
- Brown DF, Risser RC, Bigio EH, Tripp P, Stiegler A, Welch E, Eagan KP, Hladik CL, White CL3rd. Neocortical synapse density and Braak stage in the Lewy body variant of Alzheimer's disease: a comparison with classic Alzheimer's disease and normal aging. *J Neuropathol Exp Neurol.* 1998;57:955-960.
- Brown RG, Marsden CD. How common is dementia in Parkinson's disease? *Lancet.* 1984;1262-1265.
- Brun A, Gustafson L. Distribution of cerebral degeneration in Alzheimer's disease. A clinico-pathological study. *Arch Psychiatr Nerenkr.* 1976;223:15-33.
- Brun A, Gustafson L. Limbic lobe involvement in presenile dementia. *Arch Psychiat Nervenkr.* 1978;226:79-93.
- Brun A, Englund E. The pattern of degeneration in Alzheimer's disease. Neuronal loss and histopathological grading. *Histopathology.* 1981;5:549-64.
- Brun A. The structural development of Alzheimer's disease. *Dan Med Bull.* 1985;32:25-27.

- Brun A, Englund E. A white matter disorder in dementia of the Alzheimer type. A patho-anatomical study. *Ann Neurol*. 1986;19:253-262.
- Brun A. Frontal lobe degeneration of non-Alzheimer type, I. *Neuropathology. Arch Geront Geriatr*. 1987;6:193-208.
- Brun A, Gustafson L. Zerebrovaskuläre Erkrankungen. In: *Psychiatrie der Gegenwart*. Band 6; Organische Psychosen. Disker DP, Lander A, Meyer J-E, Muller C, Strömberg E (eds). Springer: Berlin, Heidelberg, 1988. pp 253-294.
- Brun A, Gustafson L. Incomplete infarction is an important component in cerebrovascular dementia. In: *Cerebral Ischemia and Dementia*. Hartmann A, Kuschinsky W, Hoyer S (eds). Springer-Verlag, Berlin, Heidelberg. 1991a. pp 54-59.
- Brun A, Gustafson L. Psychopathology and frontal lobe involvement in organic dementia. In: *Alzheimer's disease: Basic Mechanisms, Diagnosis and Therapeutic Strategies* Iqbal K, McLachlan DRC, Winblad B, Wisniewski HM (eds). John Wiley & Sons Ltd, England. 1991b. pp 27-33.
- Brun A. Dementia with white matter lesions. In: *Vascular dementia*. Román GC (ed), *New Issues in Neuroscience*. 1992;4:169-171.
- Brun A, Gustafson L. The Lund longitudinal dementia study: A 25-year perspective on neuropathology, differential diagnosis and treatment. *Alzheimer's Disease: Advances in clinical and basic research*. Corrain B, Iqbal K, Nicolini M, Winblad B, Wisniewski H, Zatta P (eds). John Wiley&Sons Ltd. 1993. pp 3-18.
- Brun A. Vascular dementia: Pathological findings; in Burns A, Levy R (eds): *Dementia*. London, Chapman and Hall. 1994a. pp 653-663.
- Brun A. Pathology and pathophysiology of cerebrovascular dementia: pure subgroups of obstructive and hypoperfusive etiology. *Dementia*. 1994b;5:145-147.
- Brun A, Englund E, Gustafson L, Passant U, Mann DMA, Neary D, Snowden J. Clinical and neuropathological criteria for frontotemporal dementia. *J Neurol Neurosurg Psychiatry*. 1994;57:416-418.
- Brun A, Gustafson L. Clinical and Pathological aspects of frontotemporal dementia. In: *The Human Frontal lobes: Functions and Disorders*. Miller BL, Cummings JL (eds). Guilford Publications, Inc., Spring Street, New York, NY 10012. 1999.
- Bråne G, Gottfries CG, Blennow K, Karlsson I, Lekman A, Parnetti L, Svennerholm L, Wallin A. Monoamine metabolites in cerebrospinal fluid and behavioural ratings in patients with early and late onset of Alzheimer dementia. *Alzheimer Dis Assoc Disord*. 1989;3:148-156.

- Burke WJ, Coronado PG, Schmitt CA, Gillespie KM, Chung HD. Blood pressure regulation in Alzheimer's disease. *J Auton Nerv Syst.* 1994;48:65-71.
- Burke WJ, Pfeiffer RF, McComb RD. Neuroleptic sensitivity to clozapine in dementia with Lewy bodies. *J Neuropsychiatry Clin Neurosci.* 1998;10:227-229.
- Burkhardt CR, Filley CM, Kleinschidt-DeMasters BK, de la Monte S, Norenberg MD, Schneck SA. Diffuse Lewy body disease and progressive dementia. *Neurology.* 1988;38:1520-1528.
- Burns A, Jacoby R, Levy R. Psychiatric phenomena in Alzheimer's disease. II: Disorders of perception. *Br J Psychiatry.* 1990a;157:76-81.
- Burns A, Jacoby R, Levy R. Psychiatric phenomena in Alzheimer's disease. IV: Disorders of behaviour. *Br J Psychiatry.* 1990b;157:86-94.
- Burns A, Jacoby R, Levy R. 1990c. Psychiatric phenomena in Alzheimer's disease. *Br J Psychiatry* 257:72-94
- Byrne EJ, Lennox G, Lowe J, Godwin-Austen RB. Diffuse Lewy body disease: clinical features in 15 cases. *J Neurol Neurosurg Psychiatry.* 1989;52:709-17.
- Byrne EJ, Lennox GG, Godwin-Austen RB, Jefferson D, Lowe J, Mayer RJ, Landon M, Doherty FJ. Dementia associated with cortical Lewy bodies: proposed clinical diagnostic criteria. *Dementia.* 1991;2:283-284.
- Calderon J, Perry RJ, Erzincliglu SW, Berrios GE, Denning TR, Hodges JR. Perception, attention, and working memory are disproportionately impaired in dementia with Lewy bodies compared with Alzheimer's disease. *Eurosurg Psychiatry.* 2001;70:157-164.
- Caplan LR. 'Top of the basilar' syndrome. *Neurology.* 1980;30:72-79.
- Chacko RC, Hurley RA, Jankovic J. Clozapine use in diffuse Lewy body disease. *J Neuropsychiatry Clin Neurosci.* 1993;5:206-208.
- Chang CM, Yu YL, Hg HK, Leung SY, Fong KY. Vascular pseudoparkinsonism. *Acta Neurol Scand.* 1992;86:588-592.
- Clark AW, White CL 3d, Manz HJ, Parhad IM, Curry B, Whitehouse PJ, Lehmann J, Coyle IT. Primary degenerative dementia without Alzheimer pathology. *Can J Neurol Sci.* 1986;13:462-470.
- Clayton DF, George JM. The synucleins: a family of proteins involved in synaptic plasticity, neurodegeneration and disease. *Trends Neurosci.* 1998;6:249-254.
- Clayton DF, George JM. Synucleins in synaptic plasticity and neurodegenerative disorders. *J Neurosci Res.* 1999;58:120-129.
- Cooper AF, Kay DWK, Curry AR, Garside RF. Hearing loss in paranoid and affective psychoses of the elderly. *Lancet.* 1974;2:851-861.

- Cooper AF, Porter R. Visual acuity and ocular pathology in the paranoid and affective psychoses of later life. *J Psychosom Res.* 1986;20:107-114.
- Cordato NJ, Halliday GM, Harding AJ, Hely MA, Morris JG. Regional brain atrophy in progressive supranuclear palsy and Lewy body disease. *Ann Neurol.* 2000;47:718-728.
- Cummings JL. Organic delusions: phenomenology, anatomic correlations, and review. *Br J Psychiatry.* 1985;146:184-197.
- Cummings JL Intellectual impairment in Parkinson's disease: clinical, pathologic, and biochemical correlates. *J Ger Psychiat Neurol.* 1988;2:24-36.
- Cummings JL, Victoroff JI. Noncognitive neuropsychiatric syndromes in Alzheimer's disease. *Neuropsychiatr Neuropsychol Behav Neurol.* 1990;3:140-158.
- D'Amato RJ, Zweig RM, Whitehouse PJ, Wenk GL, Singer HS, Mayeux R, Price DL, Snyder SN. Aminergic system in Alzheimer's disease and Parkinson's disease. *Ann Neurol.* 1987;22:229-236.
- Davies P, Maloney AJ. Selective loss of cholinergic neurons in Alzheimer's disease. *Lancet.* 1976:1403.
- Davies P. Neurotransmitter-related enzymes in senile dementia of the Alzheimer type. *Brain Res.* 1979;171:319-327.
- Decker MW, McGaugh JL. The role of interactions between the cholinergic system and other neuromodulatory systems in learning and memory. *Synapse.* 1991;7:151-168.
- Delay J, Brion S. *Les demences tardives.* 1962. Masson, Paris
- De Morsier G. Les hallucination visuelles d'encéphaliques. *Psychiatria Clinica.* 1969;2:167-184, 232-251.
- De Vos RA, Jansen EN, Stam FC, Ravid R, Swzb DF. 'Lewy body disease': clinico-pathological correlations in 18 consecutive cases of Parkinson's disease with or without dementia. *Clin Neurol Neurosurg* 1995;97:13-22.
- De Vos RAI, Jansen ENH, Yilmazer D, Braak H, Braak E. Pathological and clinical features of Parkinson's disease with and without dementia. In: *Dementia with Lewy bodies – clinical, pathological and treatment issues.* Perry R, McKeith I, Perry E (eds). Cambridge University Press. 1996.
- Dexter DT, Sian J, Rose S, Hindmarsh JG, Mann VM, Cooper JM, Wells FR, Daniels SE, Lees AJ, Schapira AH, Jenner P, Marsden CD. Indices of oxidative stress and mitochondrial function in individuals with incidental Lewy body disease. *Ann Neurol.* 1994;35:38-44.

- Dickson DW, Davies P, Mayeux R, Crystal H, Horoupian DS, Thompson A, Goldman JE. Diffuse Lewy body disease. Neuropathological and biochemical studies of 6 patients. *Acta Neuropathol (Berl)*. 1987;75:8-15.
- Ditter SM, Mirra SS. Neuropathologic and clinical features of Parkinson's disease in Alzheimer's disease patients. *Neurology*. 1987;37:754-760.
- Donnemiller E, Heilmann J, Wenning GK, Berger W, Decristoforo C, Moncayo R, Poewe W, Ransmayr G. Brain perfusion scintigraphy with ^{99m}Tc -HMPAO or ^{99m}Tc -ECD and ^{123}I - β -CIT single-photon emission tomography in dementia of the Alzheimer-type and diffuse Lewy body disease. *Eur J Nuc Med*. 1997;24:320-325.
- Downes JJ, Roberts AC, Sahakian BJ, Evenden JL, Morris RG, Robbins TW. Impaired extra-dimensional shift performance in medicated and unmedicated Parkinson's disease: evidence for a specific attentional dysfunction. *Neuropsychologia*. 1989;27:1329-1343.
- Downton JH, Andrews K. Prevalence, characteristics and factors associated with falls among the elderly living at home. *Aging*. 1991;3:219-228.
- Downton JH. Falls in the elderly. 1993. Edward Arnold. London, Melbourne Auckland.
- American Psychiatric Association. DSMIV: diagnostic and statistical manual of mental disorders. 4th ed. Washington DC: American Psychiatric Association, 1994.
- Dubrovsky SL and Buzan R. Psychopharmacology. In: Textbook of geriatric neuropsychiatry. Coffey CE, Cummings JL (eds). American Psychiatric Press, Inc. Washington, DC, London, England. 2000. pp 779-827.
- Duffy PE, Tennyson VM. Phase and electron microscopic observations of Lewy bodies and melanin granules in the substantia nigra and locus caeruleus in Parkinson's disease. *J Neuropath Exper Neurol*. 1965;24:389-414.
- Duvoisin RC, Golbe LI. Toward a definition of Parkinson's disease. *Neurology*. 1989;39:746.
- Edvinsson L, Minthon L, Ekman R, Gustafson L. Neuropeptides in cerebrospinal fluid of patients with Alzheimer's disease and dementia with fronto temporal lobe degeneration. *Dementia*. 1993;4:167-171.
- Eggertson DE, Sima AAF. Dementia with cerebral Lewy bodies. A mesocortical dopaminergic defect? *Arch Neurol*. 1986;43:524-527.
- Elfgrén C, Passant U, Risberg. Neuropsychological findings in frontal lobe dementia. *Dementia*. 1993;4:214-219.

- Englund E, Brun A, Persson B. Correlations between histopathologic white matter changes and proton MR relaxation times in dementia. *Alz Dis Ass Disord.* 1987;1:156-170.
- Englund E, Brun A, Alling C. White matter changes in dementia of Alzheimer type – Biochemical and neuropathological correlates. *Brain.* 1988;111:1425-39.
- Englund E, Brun A, Gustafson L. A white-matter disease in dementia of Alzheimer's type – clinical and neuropathological correlates. *Int J Geriatr Psychiat.* 1989. 4:87-102.
- Englund E. White matter pathology of vascular dementia. In: *Cerebrovascular disease and dementia. Pathology, Neuropsychiatry and management.* Chiu E, Gustafson L, Ames D, Folstein MF (eds). Martin Dunitz Ltd, London. 2000. pp 77-84
- Erkinjuntti T. Classification and criteria. In *Cerebrovascular disease and dementia – pathology, neuropsychology and management.* Chiu E, Gustafson L, Ames D, Folstein ME (eds). Martin Dunitz Ltd, London. 2000. pp 99-113.
- Esiri M, Matthews F, Brayne C, Ince PG. Neuropathology group of the medical research council cognitive function and ageing study (MRC CFAS). Pathological correlates of late-onset dementia in a multicentre, community-based population in England and Wales. *Lancet.* 2001;357:169-175.
- Essen-Möller E, Wohlfahrt S. Suggestions for the amendment of the official Swedish classification of mental disorders. *Acta Psychiatr Scand.* 1947;47:551-555.
- Ey, H. *Traité des Hallucination.* Paris, Masson. 1973.
- Fergusson E. Donezepil for treatment of psychosis in dementia with Lewy bodies. *Int J Geriatr Psychiatry.* 2000;15:280-281.
- Fisher CM. Binswanger's encephalopathy: A review. *J Neurol.* 1989; 236:65-79.
- Forno LS. The locus ceruleus in Alzheimer's disease. *J Neuropathol Exp Neurol.* 1978;27:614.
- Forno LS, Langston J, DeLanney L, Irwin I. An electron microscopic study of MPTP-induced inclusion bodies in an old monkey. *Brin Res.* 1988;448:150-157.
- Foster NL, Wilhelmsen KC, Sima AAF, Jones MZ, D'Amato C, Gilman S. Frontotemporal dementia and parkinsonism linked to chromosome 17: A consensus statement. *Ann Neurol.* 1997;41:706-715.
- Förstl H, Levy R. F.H.Lewy on Lewy bodies, parkinsonism and dementia. *Int J Geriatr Psychiatry.* 1991;6:757-766.

- Förstl H, Burns A, Luthert P, Cairns N, Levy R. The Lewy body variant of Alzheimer's disease. Clinical and pathological findings. *Br J Psychiatry*. 1993;162:385-392.
- Förstl H, Burns A, Levy R, Cairns N. Neuropathological correlates of psychotic phenomena in confirmed Alzheimer's disease. *Br J Psychiatry*. 1994;165:53-59.
- Förstl H. The Lewy body variant of Alzheimer's disease: clinical, pathophysiological and conceptual issues. *Eur Arch Psychiatry Clin Neurosci*. 1999;249:suppl.3 III/64-III/67.
- Francis PT, Holms C, Webster MT, Stratman GC, Procter AW, Bowen DM. Preliminary neurochemical findings in non-Alzheimer dementia due to lobar atrophy. *Dementia*. 1993;4:172-177.
- Fratiglioni L. Epidemiology of Alzheimer's disease and current possibilities for prevention. *Acta Neurol Scand*. 1996;(suppl) 165:33-40.
- Fredriksson K, Brun A, Gustafson L. Pure subcortical arteriosclerotic encephalopathy (Binswanger's disease): A clinicopathologic study. *Cerebrovasc Dis*. 1992;2:82-86.
- Friedland RP, Budinger TF, Ganz E, Yano Y, Mathis CA, Koss B, Ober BA, Huesman RH, Derenzo SE. Regional cerebral metabolic alterations in dementia of the Alzheimer type: Positron emission tomography with [^{18}F] Fluorodeoxyglucose. *J Comp Ass Tomography*. 1983;7:590-598.
- Fukuda T, Tanaka J, Watabe K, Numoto RT, Minamitani M. Immunohistochemistry of neuronal inclusions in the cerebral cortex and brainstem in Lewy body disease. *Acta Pathol Jpn*. 1993;43:545-51.
- Galasko D, Hansen, LA, Katzman R, Wiederholt W, Masliah E, Terry R, Hill LR, Lessin P, Thal LJ. Clinical-neuropathological correlations in Alzheimer's disease and related dementias. *Arch Neurol*. 1994a;51:888-895.
- Galasko D, Saitoh T, Xia Y, Thal LJ, Katzman R, Hill LR, Hansen L. The apolipoprotein E allele epsilon 4 is overrepresented in patients with the Lewy body variant of Alzheimer's disease. *Neurology*. 1994b;44:1950-1951.
- Galvin JE, Lee VM, Baba M, Mann DM, Dickson DW, Yamaguchi H, Schmidt ML, Iwatsubo T, Trojanowski JQ. Monoclonal antibodies to purified cortical Lewy bodies recognize the mid-size neurofilament subunit. *Ann Neurol*. 1997;42:595-603.
- Galvin JE, Uryu K, Lee V M-Y, Trojanowski JQ. Axon pathology in Parkinson's disease and Lewy body dementia hippocampus contains α -, β -, and γ -synuclein. *Proc Nat Acad Sci US*. 1999;96:450-455.

- Gaspar P, Gray F. Dementia in idiopathic Parkinson's disease. A neuropathological study of 32 cases. *Acta Neuropathol (Berl)*. 1984;64:43-52.
- Gaspar P, Duyckaerts C, Alvarez, Javoy-Agid F, Berger B. Alterations of dopaminergic and dopaminergic innervations in motor cortex in Parkinson's disease. *Ann Neurol*. 1991;30:365-374.
- Gearing M, Schneider JA, Rebeck GW, Hyman BT, Mirra SS. Alzheimer's disease with and without coexisting Parkinson's disease changes: apolipoprotein E genotype and neuropathological correlates. *Neurology*. 1995;45:1985-1990.
- Geizer M, Ancill RJ. Combination of Risperidone and Donepezil in Lewy body dementia. *Can J Psychiatry*. 1998;43:421-422.
- Gibb WRG, Lees AJ. The relevance of the Lewy body to the pathogenesis of idiopathic Parkinson's disease. *J Neurol Neurosurg Psychiatry*. 1988;51:745-752.
- Gibb WRG, Mountjoy CQ, Mann DMA, Lees AJ. The substantia nigra and ventral segmental area in Alzheimer's disease and Down's syndrome. *J Neurol Neurosurg Psychiatry*. 1989a;52:193-200.
- Gibb WR, Mountjoy CQ, Mann DM, Lees AJ. A pathological study of the association between Lewy body disease and Alzheimer's disease. *J Neurol Neurosurg Psychiatry*. 1989b;52:709-717.
- Gibb WRG. Dementia and Parkinson's disease. *Br J Psychiat*. 1989c;154:596-614.
- Gibb WR, Lees AJ. Prevalence of Lewy bodies in Alzheimer's disease. *Ann Neurol*. 1989;5:691-693.
- Glenner GG, Wong CW. Alzheimer's disease and Down's syndrome: sharing a unique cerebrovascular amyloid fibril protein. *Biochem Biophys Res Com*. 1984;122:1131-1135.
- Goetz CG, Lütge W, Tanner CM. Autonomic dysfunction in Parkinson's disease. *Neurology*. 1986;36:73-75.
- Gomez-Tortosa E, Newell K, Irizarry MC, Albert M, Growdon JH, Hyman BT. Clinical and quantitative pathologic correlates of dementia with Lewy bodies. *Neurology*. 1999;53:1284-1291.
- Gotham AM, Brown RG, Marsden CD. "Frontal" cognitive function in patients with Parkinson's disease "on" and "off" levodopa. *Brain*. 1988;111:299-321.
- Gottfries CG. Biochemical changes in blood and cerebrospinal fluid. In: Reisberg B (ed). *Alzheimer's disease. The standard reference*. London: The Free Press. Collier MacMillan. 1983. pp 122-130.

- Gottfries CG, Blennow K, Karlsson I, Wallin A. The neurochemistry of vascular dementia. *Dementia*. 1994;5:163-167.
- Greenfield JG, Bosanquet FD. The brainstem lesions in parkinsonism. *J Neurol Neurosurg Psychiatr*. 1953;16:213-226.
- Guo Z, Viitanen M, Fratiglioni L, Winblad B. Low blood pressure and dementia in elderly people: the Kungsholmen project. *Br Med J*. 1996;312:805-808.
- Gustafson L, Risberg J. Regional cerebral blood flow related to psychiatric symptoms in dementia with onset in the presenile period. *Acta Psychiatr Scand*. 1974;257:9-71.
- Gustafson L, Hagberg B. Dementia with onset in the presenile period. *Acta Psychiatr Scand*. 1975;Suppl 257.
- Gustafson L, Risberg J. Regional cerebral blood measurements by the ^{133}Xe inhalation technique in differential diagnosis of dementia. *Acta Neurol Scand*. 1979; (suppl 72) 60:546-547.
- Gustafson L, Nilsson L. Differential diagnosis of presenile dementia on clinical grounds. *Acta Psychiatr Scand*. 1982;65:194-209.
- Gustafson L. Differential diagnosis with special reference to treatable dementia and pseudodementia conditions. *Dan Med Bull*. 1985;32:55-59.
- Gustafson L. Frontal lobe degeneration of non-Alzheimer type, II. Clinical picture and differential diagnosis. *Arch Geront Geriatr*. 1987;6:209-223.
- Gustafson L, Brun A. The Scandinavian View. In: *The Classification and Diagnosis of Alzheimer Disease, An International Perspective*. Hovaguimian T, Henderson S, Khachaturian Z, Orley J (eds). Toronto, Lewiston NY, Bern, Stuttgart, Göttingen. Hogrefe and Huber Publishers. 1989. pp 17-23.
- Gustafson L, Brun A, Johanson A, Risberg J. Diagnostic criteria of Alzheimer's disease. In: Maurer K, Riederer P, Beckman H (eds). *Wien: Springer Verlag*, 1990. pp 357-364.
- Gustafson L. Clinical classification of dementia conditions. *Acta Neurol Scand*. 1992;suppl 139:16-20.
- Gustafson L, Risberg J. Deceptions and delusions in AD and FLD. In: *Delusions and Hallucinations in Old Age*. Katona C, Levy R (eds). Gaskell, London. 1993. pp 216-227.
- Gustafson L, Brun A, Johanson A, Passant U, Risberg J. Early clinical manifestations and the course of Alzheimer's disease related to regional cerebral blood flow and neuropathology. In: *Research Advances in Alzheimer's disease and related disorders*. Iqbal K, Mortimer JA, Winblad B, Wisniewski HM (eds) John Wiley & Sons Ltd. 1995. pp 209-218.
- Gustafson L. What is dementia? *Acta Neurol Scand*. 1996;suppl.168:22-24.

- Gustafson L, Passant U. Clinical pathological correlates. In: Cerebrovascular disease and dementia. Pathology, Neuropsychiatry and management. Chiu E, Gustafson L, Ames D, Folstein MF (eds). Martin Dunitz Ltd, London. 2000. pp 85-97.
- Gustafson L. Historical overview. In: Cerebrovascular disease and dementia – pathology, neuropsychology and management. Chiu E, Gustafson L, Ames D, Folstein ME (eds). Martin Dunitz Ltd, London. 2000. pp 3-14.
- Gustafson Y, Olsson T, Eriksson S, Asplund K, Bucht G. Acute confusional states (delirium) in stroke patients. *Cerebrovasc Dis.* 1991;1:257-264.
- Hachinski VC, Iliff LD, Zilkha E, Du Boulay GH, McAllister VC, Marshall J, Russell RW, Symon L. Cerebral blood flow in dementia. *Arch Neurol.* 1975;32: 632-637.
- Hale WE, Perkins LL, May FE, Marks RG, Stewart RB. Symptom prevalence in the elderly. An evaluation of age, sex, disease and medication use. *J Am Geriatr Sci.* 1986;34:333-340.
- Hansen LA, De Teresa R, Davies P, Terry RD. Neocortical morphometry, lesion counts and choline acetyl transferase levels in the age spectrum of Alzheimer's disease. *Neurology.* 1988;38:48-54.
- Hansen LA, Masliah E, Terry RD, Mirra SS. A neuropathological subset of Alzheimer's disease with concomitant Lewy body disease and spongiform change. *Acta Neuropathol (Berlin).* 1989;15:27-44.
- Hansen LA, Salmon D, Galasko D, Masliah E, Katzman R, De Teresa R. The Lewy body variant of Alzheimer's disease: a clinical and pathological entity. *Neurology.* 1990;40:1-8.
- Hansen LA, Masliah E, Galasko D, Terry RD. Plaque-only Alzheimer disease is usually the Lewy body variant and vice versa. *J Neuropathol Exp Neurol.* 1993;52:648-654.
- Hansen LA, Samuel W. Criteria for Alzheimer's disease and the nosology of dementia with Lewy bodies. *Neurology.* 1997;48:126-132.
- Hansen LA, Daniel SE, Wilcock GK, Love S. Frontal cortical synaptophysin in Lewy body disease: relation to Alzheimer's disease and dementia. *J Neurol Neurosurg Psychiatry.* 1998;64:653-656.
- Hardy J, Gwinn-Hardy K. Neurodegenerative disease: a different view of diagnosis. *Mol Med Today.* 1999;5:514-517.
- Helfand M. Status pigmentatus: its pathology and its relation to Hallervorden-Spatz disease. *J Nerv Ment Dis.* 1935;81:662-675.

- Hénon H, Lebert F, Durieu I, Godefroy O, Lucas C, Pasquier F, Leys D. Confusional states in stroke. Relation to preexisting dementia, patient characteristics, and outcome. *Stroke*. 1999;30:773-779.
- Higuchi S, Arai H, Matsushita S, Matsui T, Kimpara T, Takeda A, Shirakura K. Mutation in the alpha-synuclein gene and sporadic Parkinson's disease, Alzheimer's disease, and dementia with Lewy bodies. *Exp Neurol*. 1998;153:164-166.
- Hirano A, Zimmerman HM. Alzheimer's neurofibrillary changes, a topographic study. *Arch Neurol*. 1962;7:227-242.
- Hirano A, Kurtland LT, Sayre GP. Familial amyotrophic lateral sclerosis. A subgroup characterised by posterior and spinocerebellar tract involvement and hyaline inclusions in the anterior horn cells. *Arch Neurol*. 1967;16:232-243.
- Hishikawa N, Hashizume Y, Hirayama M, Imamura K, Washimi Y, Koike Y, Mabuchi C, Yoshida M, Sobue G. Brainstem-type Lewy body disease presenting with progressive autonomic failure and lethargy. *Clin Auton Res*. 2000;10:139-143.
- Hogan DB, Ebly EM, Rockwood K. Weight, blood pressure, osmolarity, and glucose levels across various stages of Alzheimer's disease and vascular dementia. *Dement Geriatr Cogn Disord*. 1997;8:147-151.
- Hohl U, Tiraboschi P, Hansen LA, Thal LJ, Corey-Bloom J. Diagnostic accuracy of dementia with Lewy bodies. *Arch Neurol*. 2000;57:347-351.
- Holmes C, Cairns N, Lantos, Mann A. Validity of current clinical criteria for Alzheimer's diseases, vascular dementia and dementia with Lewy bodies. *Br J Psychiatry*. 1999;174:45-50.
- Homma A, Hasegawa K. Epidemiology of vascular dementia in Japan. In: Cerebrovascular disease and dementia. Pathology, Neuropsychiatry and management. Chiu E, Gustafson L, Ames D, Folstein MF (eds). Martin Dunitz Ltd, London. 2000. pp33-46.
- Hughes AJ, Daniel SE, Kilford L, Lees AJ. The accuracy of clinical diagnosis of idiopathic Parkinson's disease a clinicopathological study. *J Neurol Neurosurg Psychiatry*. 1992;55:181-184.
- Hughes AJ, Daniel SE, Blankson S, Lees AJ. A clinicopathological study of 100 cases of Parkinson's disease. *Arch Neurol*. 1993;50:140-148.
- Hulette C, Mirra S, Wilkinson W, Heyman A, Fillenbaum G, Clark C. The Consortium to Establish a Registry for Alzheimer's disease (CERAD). Part IX. A prospective cliniconeuropathologic study of Parkinson's features in Alzheimer's disease. *Neurology*. 1995;45:1991-1995.

- The ICD-10 Classification of Mental and Behavioural Disorders: Diagnostic criteria for research. World Health Organization, Geneva, 1993.
- Ince P, Irving D, MacArthur F, Perry RH. Quantitative neuropathological study of Alzheimer-type pathology in the hippocampus: comparison of senile dementia of Alzheimer type, senile dementia of Lewy body type, Parkinson's disease and non-demented elderly control patients. *J Neurol Sci.* 1991;106:142-152.
- Ince PG, McArthur FK, Bjertness E, Torvik A, Candy JM, Edwardson JA. Neuropathological diagnoses in elderly patients in Oslo: Alzheimer's disease, Lewy body disease, vascular lesions. *Dementia.* 1995;6:162-168.
- Ingvar DH, Gustafson L. Regional cerebral blood flow in organic dementia with early onset. *Acta Neurol Scand.* 1970;46:42-73.
- Ishii K, Yamaji S, Kitagaki H, Imamura T, Hirono N, Mori E. Regional cerebral blood flow difference between dementia with Lewy bodies and AD. *Neurology.* 1999;53:413-416.
- Ishii T. Distribution of Alzheimer's neurofibrillary changes in the brain stem and hypothalamus of senile dementia. *Acta Neuropathol.* 1966;6:181-187.
- Izeki E, Li F, Kosaka K. Close relationship between spongiform change and ubiquitin-positive granular structures in diffuse Lewy body disease. *J Neurol Sci.* 1997;146:53-57.
- Jacoby, RJ, Levy R. Computed tomography in the elderly. II Senile dementia: diagnosis and functional impairment. *Br J Psychiatry.* 1980;136:256-269.
- Jagust WJ, Hohmann KA, Holman BL. SPECT perfusion imaging in the diagnosis of dementia. *J Neuroimag.* 1995;5: S45-S52.
- Jakes R, Spillantini MG, Goedert M. Identification of two distinct synucleins from human brain. *FEBS Lett.* 1994;345:27-32.
- Jakes R, Crowther RA, Lee VM, Trojanowski JQ, Iwatsubo T, Goedert M. Epitope mapping of LB509, a monoclonal antibody directed against human alpha-synuclein. *Neurosc Lett.* 1999;269:13-16.
- Jellinger K, Neumayer E. Progressive subcortical vasculäre Encephalopathie Binswanger. *Arch Psychiatr Nervenkr.* 1964;205:523-554.
- Jellinger K, Danielczyk W, Fischer P, Gabriel E. Clinicopathological analysis of dementia disorders in the elderly. *J Neurol Sci.* 1990;95:239-258.
- Jellinger KA. Structural basis of dementia in neurodegenerative disorders. *J Neural Transm.* 1996 (suppl) 47:1-29.
- Jellinger KA. Morphological substrates of dementia in parkinsonism. A critical update. *J Neural Transm.* 1997;51:57-82.

- Jendroska D, Hoffmann O, Schelosky L, Lees AJ, Poewe W, Daniel SE. Absence of disease related prion protein in neurodegenerative disorders presenting with Parkinson's syndrome. *J Neurol Neurosurg Psychiatry*. 1994;57:1249-1251.
- Jenner P, Dexter DT, Sian J, Schapira AH, Marsden CD. Oxidative stress as a cause of nigral cell death in Parkinson's disease and incidental Lewy body disease. The Royal Kings and queens Parkinson's Research Group. *Ann Neurol*. 1992;32 suppl:S82-87.
- Jenner P, Olanow CW. Understanding cell death in Parkinson's disease. *Ann Neurol*. 1998; 44: S72-S84.
- Joachim CL, Morris JH, Selkoe DJ. Clinically diagnosed Alzheimer's disease: autopsy results in 150 cases. *Ann Neurol*. 1988;24:50-56.
- Jobst KA, Smith AD, Barker CS, Wear A, King EM, Smith A, Anslow PA, Molyneue AJ, Shepstone BJ, Snoper N, Holmes KA, Robinson JR, Hope RA, Oppenheimer C, Brockbank K, McDonald B. Association of atrophy of the medial temporal lobe with reduced blood flow in the posterior parietotemporal cortex in patients with a clinical and pathological diagnosis of Alzheimer's disease. *J Neurol Neurosurg Psychiatry*. 1992;55:190-194.
- Johánneson G, Brun A, Gustafson L, Ingvar DH. EEG in presenile dementia related to cerebral blood flow and autopsy findings. *Acta Neurol Scand*. 1977;56:89-103.
- Johanson A, Hagberg B. Psychometric characteristics in patients with frontal lobe degeneration of non-Alzheimer type. *Arch Gerontol Geriatr*. 1989;8:129-137.
- Jorm AF, Korten AE, Henderson AS. The prevalence of dementia: a quantitative integration of the literature. *Acta Psychiatr Scand*. 1987;76:464-479.
- Jorm AF. Epidemiology: metaanalysis. In: *Cerebrovascular disease and dementia. Pathology, Neuropsychiatry and management*. Chiu E, Gustafson L, Ames D, Folstein MF (eds). Martin Dunitz Ltd, London. 2000. pp 55-61.
- Kanazawa I, Kwak S, Sasaki H, Muramoto O, Mizutani T, Hori A, Nukina N. Studies of neurotransmitter markers of the basal ganglia in Pick's disease, with special reference to dopamine reduction. *J Neurol Sci*. 1988;83:63-74.
- Katz S, Ford AB, Moscovitz RW. Studies of illness in the aged. The index of ADL: A standardised measure of biological and psychosocial function. *J Am Med Ass*. 1963;185:914-919.
- Kazee AM, Cox C, Richfield EK. Substantia nigra lesions in Alzheimer's disease and normal aging. *Alzheimer Dis Assoc Disord*. 1995a;9:61-67.

- Kazee AM, Han LY. Cortical Lewy bodies in Alzheimer's disease. *Arch Pathol Lab Med.* 1995;151:448-453.
- Khachaturian ZS. Diagnosis of Alzheimer's disease. *Arch Neurol.* 1985;42:1097-1105.
- Klatka L, Louis E, Schiffer RB. Psychiatric features in diffuse Lewy body disease; a clinicopathological study using Alzheimer's disease and Parkinson's disease control groups. *Neurology.* 1996;47:1148-1152.
- Kholodilov NG, Oo TF, Burke RE. Synuclein expression is decreased in rat substantia nigra following inductions of apoptosis by intrastriatal 6-hydroxydopamine. *Neurosci Lett.* 1999;275:105-108.
- Kosaka K. Lewy bodies in cerebral cortex, report of three cases. *Acta Neuropathol (Berl).* 1978;42:127-134.
- Kosaka K, Yoshimura M, Ikeda K, Budka H. Diffuse type of Lewy body disease: progressive dementia with abundant Lewy bodies and senile changes of varying degree - a new disease? *Clin Neuropathol.* 1984;3:185-192.
- Kosaka K, Tsuchiya K, Yoshimura M. Lewy body disease with and without dementia: a clinicopathological study of 35 cases. *Clin Neuropathol.* 1988;7:299-305.
- Kremer HP, Bots GT. Lewy bodies in the lateral hypothalamus: do they imply neuronal loss? *Mov Disord.* 1993;8:315-320.
- Kraepelin E. *Psychiatrie: Ein lehrbuch für Studierende und Ärzte.* Leipzig: Verlag von Johann Ambrosius Barth.
- KuljisR, Martin-Vasallo P, Peress N. Lewy bodies in tyrosin hydroxylase-synthesising neurons of the human cerebral cortex. *Neurosci Lett.* 1989;106:49-54.
- Kuzuhara S, Yoshimura M, Mizutani T, Yamanouchi H. Clinical features of diffuse Lewy body disease in the elderly: analysis of 12 cases. In: Perry R, McKeith I, Perry E (eds.). *Dementia with Lewy Bodies – Clinical, Pathological and Treatment Issues.* Cambridge University Press. 1996. pp 153-160.
- Ladurner G, Illiff LD, Sager WD, Lechner H. A clinical approach to vascular multiinfarct dementia. *Exp Brain Res.* 1982;5(suppl): 243-250.
- Lancotot KL, Herrmann N. Donezepil for behavioural disorders associated with Lewy bodies: a case series. *Int J Geriatr Psychiatry.* 2000;15:338-345.
- Landahl S, Bengtsson C, Sigurdsson J, Svanborg A, Svärdsudd K. Age-related changes in blood pressure. *Hypertens.* 1986;8:1044-1049.
- Langston JW, Forno LS. The hypothalamus in Parkinson's disease. *Ann Neurol.* 1978;3:129-133.

- Langston JW, Forno LS, Tetrud J, Reeves AG, Kaplan JA, Karluk D. Evidence of active nerve cell degeneration in the substantia nigra of humans years after 1-methyl-4-phenyl-1,2,3,6-tetrahydropyridine exposure. *Ann Neurol*. 1999;46:598-605.
- Larsson EM, Passant U, Sundgren PC, Englund E, Brun A, Lindgren A, Gustafson L. Magnetic resonance imaging and histopathology in dementia, clinically of frontotemporal type. *Dement Geriatr Cogn*. 2000;11:123-134.
- Lauter H. Über spätfornen der Alzheimerschen Krankheit und ihre Beziehung sur senilen Demenz. *Psychiat Clin*. 1970;3:169-189.
- Lebert F, Pasquier F, Souliez L, Petit H. Tacrine efficacy in Lewy body dementia. *Int J Geriatr Psychiatry*. 1998;13:516-519.
- Lees AJ. Parkinson's disease and dementia. *Lancet*. 1985;1:43-44.
- LeMay M, Stafford JL, Sandor T, Albert M, Haykal H, Samani A. Statistical assessment of perceptual CT scan ratings in patients with Alzheimer type dementia. *J Comput Assist Tomogr*. 1986;10:802-809.
- Lennox G, Lowe J, Morell K, Landon M, Mayer RJ. Anti-ubiquitin immunocytochemistry is more sensitive than conventional techniques in the detection of diffuse Lewy body disease. *J Neurol Neurosurg Psychiatry*. 1989a;52:67-71.
- Lennox G, Lowe JS, Godwin-Austen RB, Landon M, Mayer RJ. Diffuse Lewy body disease: an important differential diagnosis in dementia with extrapyramidal features. *Prog Clin Biol Res*. 1989b;317:121-130.
- Lennox, G. Lewy body dementia. In: Baillière's Clinical neurology – unusual dementias. Byres C (ed) Baillière Tindall, 24-28 Oval Road, London NW1 7DX, 1992. vol 1/no3 nov. pp 661-662.
- Levy JA, Parasuraman R, Greenwood PM, Dukoff R, Sunderland T. Acetylcholine affects the spatial scale of attention: evidence from Alzheimer's disease. *Neuropsychology*. 2000;14:288-298.
- Levy R, Eagger S, Griffiths M, Perry E, Honavar M, Dean A, Lantos P. Lewy bodies and response to tacrine in Alzheimer's disease. *Lancet*. 1994;343:176.
- Lewy FH. Paralysis agitans. I. Patologische anatomie. In: Handbuch der Neurologie. Lewandowsky M (ed). Springer, Berlin. 1912;3:920-33.
- Lewy FH. Die Lehre vom tonus und der Bewegung. Zugleich systematische untersuchungen zur klinik, physiologie, pathologie and patogenese der paralytis agitans. Berlin: Julius Springer. 1923.
- Liberini P, Valerio A, Memo M, Spano P. Lewy-body dementia and responsiveness to cholinesterase inhibitors: a paradigm for heterogeneity of Alzheimer's disease? *TIPS*. 1996;17:55-160.

- Lindboe CF, Hansen HB. The frequency of Lewy bodies in a consecutive autopsy series. *Clinical Neuropathol.* 1998;4:204-209.
- Lipowski ZJ. Vascular diseases. In: *Delirium: Acute confusional states.* Oxford University Press. 1990. pp 375-398.
- Lippa CF, Johnson R, Smith TW. The medial temporal lobe in dementia with Lewy bodies: a comparative study with Alzheimer's disease. *Ann Neurol.* 1998;43:102-106.
- Lippa CF, Schmidt ML, Lee VM, Trojanowski JQ. Antibodies to alpha synuclein detect Lewy bodies in many Down's syndrome brains with Alzheimer's disease. *Ann Neurol.* 1999a;45:353-357.
- Lippa CF, Smith TW, Perry E. Dementia with Lewy bodies: choline acetyltransferase parallels nucleus basalis pathology. *J Neural Transm.* 1999b;106:525-535.
- Litvan I, MacIntyre A, Goetz CG, Wenning GK, Jellinger K, Verny M, Bartdo JJ, Jankovic J, McKee A, Brandel JP, Chaudhuri KR, Lai EC, D'Olhaberriague L, Pearce RK, Agid Y. Accuracy of the clinical diagnoses of Lewy body disease, Parkinson disease and dementia with Lewy bodies: a clinicopathologic study. *Arch Neurol.* 1998;55:969-978.
- Liu RS, Lin KN, Wang SJ, Shan DE, Fuh JL, Yeh SH, Liu HC. Cognition and 99Tcm-HMPAO SPECT in Parkinson's disease. *Nuclear Medicine Communications.* 1992;13:774-748.
- Liu Y, Stern Y, Chun MR, Jacobs DM, Yau P, Goldman JE. Pathological correlates of extrapyramidal signs in Alzheimer's disease. *Ann Neurol.* 1997;41:368-374.
- Liu, X, Passant U, Risberg J, Warkentin S, Brun A. Synapse density related to cerebral blood flow and symptomatology in frontal lobe degeneration and Alzheimer's disease. *Dement Geriatr Cogn Disord.* 1999;10(suppl 1):64-70.
- Lopez OL, Litvan I, Catt KE, Stowe R, Klunk W, Kaufer DI, Becker JT, DeKosky ST. Accuracy of four clinical diagnostic criteria for the diagnosis of neurodegenerative dementias. *Neurology.* 1999;53:1292-1299.
- Lovestone S. Dementia: Alzheimer's disease. In: *New Oxford Textbook of Psychiatry*, vol 1. Gelder MG, López-Ibor Jr JJ, Andreasen NC (eds). Oxford University Press. 2000. pp 387-397.
- Lowe J. Lewy bodies. In: *Neurodegenerative disease.* Calne DB (ed). WB Saunders company, USA. 1994. pp 51-69.
- Luis CA, Barker WW, Gajraj K, Harwood D, Petersen R, Kashuba A, Waters C, Jimison P, Petito C, Dickson D, Duara R. Sensitivity and specificity of three clinical criteria for dementia with Lewy bodies in an autopsy-verified sample. *Int J Geriatr Psychiatry.* 1999;14:526-533.

- Lynch TS, Sano M, Marder KS. Clinical characteristics of a family with chromosome 17-linked disinhibition-dementia-parkinsonism-amyotrophy complex. *Neurology*. 1994;44:1878-1884.
- Mann DMA, Yates PO, Hawkes J. The pathology of human locus ceruleus. *Clin Neuropathol*. 1983;2:1-7.
- Mann DMA, Yates PO, Marcyniuk B. Monoaminergic neurotransmitter systems in presenile Alzheimer's disease and in senile dementia of Alzheimer type. *Clin Neuropathol*. 1984;3:199-205.
- Mann DM, Snowden JS. The topographic distribution of brain atrophy in cortical Lewy body disease in comparison with Alzheimer's disease. *Acta Neuropathol (Berl)*. 1995;89:178-183.
- Mann JJ, Stanley M, Kaplan RD, Sweeney J, Neophytides A. Central catecholaminergic metabolism in vivo and the cognitive and motor deficits in Parkinson's disease. *J Neurol Neurosurg Psychiatry*. 1983;46:905-910.
- Marsden CD. Parkinson's disease. *J Neurol Neurosurg Psychiatry*. 1994;57:672-681.
- Martolini MG, Trojanowski JQ, Schmidt ML, Arnold SE, Fujiwara TM, Lee VM, Hurtig H, Julien JP, Clark C. Association of apolipoprotein epsilon 4 allele and neuropathologic findings in patients with dementia. *Acta Neuropathol (Berl)*. 1995;90:239-243.
- Mathuranath PS, Xuereb JH, Bak T, Hodges JR. Corticobasal ganglionic degeneration and/or frontotemporal dementia? A report of two overlap cases and review of literature. *J Neurol Neurosurg Psychiatry*. 2000;68:304-312.
- Matsubara M, Yamagata H, Kamino K, Nomura T, Kohara K, Kondo I, Miki T. Genetic association between Alzheimer disease and the alpha-synuclein gen. *Demet Geriatr Cogn Disord*. 2001;12:106-109.
- Maurer K, Volk S, Gerbaldo H, Auguste D and Alzheimer's disease. *Lancet*. 1997;349:1546-49.
- Mayer-Gross W, Slater E, Roth M. *Clinical Psychiatry* 3rd. Baillere, Tindall, Cassell (ed). London 1969.
- McCarthy, P., Cameron Snyder, J. Orthostatic hypotension: A potential side effects of psychiatric medications. *J Psychosoc Nurs*. 1992;30:3-5.
- McKeith IG, Perry RH, Fairbairn AF, Jabeen S, Perry EK. Operational criteria for senile dementia of Lewy body type (SDLT). *Psychol Med* 1992a;22:911-922.

- McKeith IG, Fairbairn A, Perry R, Thompson P, Perry E. Neuroleptic sensitivity in patients with senile dementia of Lewy body type. *BMJ*. 1992b;305:673-678.
- McKeith IG, Fairbairn AF, Perry RH, Thompson P. The clinical diagnosis and misdiagnosis of senile dementia of Lewy body type (SDLT). *Br J Psychiatry* 1994a;165:324-332.
- McKeith IG, Fairbairn AF, Bothwell RA, Moore PB, Ferrier IN, Thompson P, Perry RH. An evaluation of the predictive validity and interrater reliability of clinical diagnostic criteria for senile dementia of Lewy body type. *Neurology*. 1994b;44:872-77.
- McKeith IG, Ballard CG, Harrison RW. Neuroleptic sensitivity to risperidone in Lewy body dementia. *Lancet*. 1995;346:699.
- McKeith IG, Galasko D, Kosaka K, Perry EK, Dickson DW, Hansen LA, Salmon DP, Lowe J, Mirra SS, Byrne EJ, Lennox G, Quinn NP, Edwardson JA, Ince PG, Bergeron C, Burns A, Miller BL, Lovestone S, Collerton D, Jansen ENH, Ballard D, de Vos RAI, Wilcock GK, Jellinger KA, Perry RH. Consensus guidelines for the clinical and pathological diagnosis of dementia with Lewy bodies (DLB). *Neurology*. 1996;47:113-124.
- McKeith IG, Perry EK, Perry RH. Report of the second dementia with Lewy body international workshop: diagnosis and treatment. Consortium on Dementia with Lewy bodies. *Neurology*. 1999;53:902-905.
- McKeith IG, Ballard CG, Perry RH, Ince PJ, Jaros E, Neill D, O'Brien JT, Neill D, Lowery K, Jaros E, Barber R, Thompson P, Swann A, Fairbairn AF, Perry EK. Predictive validation of consensus criteria for the diagnosis of dementia with Lewy bodies. *Neurology*. 2000a;54:1050-1058.
- McKeith IG, Ballard CG, Perry RH, Ince PG, O'Brien JT, Neill D, Lowery K, Jaros E, Barber R, Thompson P, Swann A, Fairbairn AF, Perry EK. Prospective validation of consensus criteria for the diagnosis of dementia with Lewy bodies. *Neurology*. 2000b;54:1050-1058.
- McKeith IG, Grace JB, Walker Z, Byrne EJ, Wilkinson D, Stevens T, Perry EK. Rivastigmine in the treatment of dementia with Lewy bodies: preliminary findings from an open trial. *Int J Geriatr Psychiatry*. 2000c;15:387-392.
- McKeith A, Del Ser T, Spano P, Emre M, Wesnes K, Anand R, Cicin-Sain A, Ferrara R, Spiegel R. Efficacy of rivastigmine in dementia with Lewy bodies: a randomised, double-blind, placebo-controlled international study. *Lancet*. 2000d;356:2031-2036.

- McKhann G, Drachman D, Folstein M, Karzman R, Pride D, Stadlan E. Clinical diagnosis of Alzheimer's disease: Report from the NINCDS-ADRDA work group under the auspices of department of Health and Human Service Task Force on Alzheimer's disease. *Neurology*. 1984;34:939-943.
- McRitchie DA, Reid WGJ, Halliday GM, Hely MA, Brooks WS, Morris JGL. Neuropathology of three clinical cases prospectively diagnosed as dementia with Lewy bodies. *J Clin Neurosci*. 1999;6:149-154
- McShane R, Gedling K, Reading M, McDonald B, Esiri MM, Hope T. Prospective study of relations between cortical Lewy bodies, poor eyesight and hallucinations in Alzheimer's disease. *J Neurol Neurosurg Psychiatry*. 1995;59:185-188.
- Mega MS, Masterman DL, Benson DF, Vinters HV, Tomiyasu U, Craig AH, Foti DJ, Kaufer D, Scharre DW, Fairbans L, Cummings JL. Dementia with Lewy bodies: reliability and validity of clinical and pathological criteria. *Neurology*. 1996;47:1403-1409.
- Mesulam M, Waxman SG, Geschwind N, Sabin TD. Acute confusional states with right middle cerebral territory infarctions. *J Neurol Neurosurg Psychiatry*. 1976;39:84-89.
- Mets TF. Drug-induced orthostatic hypotension in older patients. *Drugs Aging*. 1995;6:219-228.
- Michell SL. Extrapyrarnidal features in Alzheimer 's disease. *Age Ageing*. 1995;28:401-409.
- Miller BL, Lesser IM, Boone KB, Hill E, Mehninger CM, Wong K. Brain lesions and cognitive function in late-life psychosis. *Br J Psychiatry*. 1991;158:76-82.
- Miller BL, Urrutia LE, Cornford M, Mena I. The clinical and functional imaging characteristics of Parkinsonian dementia. In: Perry R, McKeith I, Perry E (eds). *Dementia with Lewy bodies – clinical, pathological and treatment issues*. Cambridge: Cambridge University press. 1996:132-144.
- Minthon L, Edvinsson L, Ekman R, Gustafson L. Reduced lumbar cerebrospinal fluid somatostatin levels in Alzheimer's disease and dementia with frontotemporal degeneration. *Dementia*. 1991;2:273-277.
- Mirra SS, Heyman A, McKeel D, Sumi SM, Crain BJ, Brownlee LM, Vogel FS, Hughes JP, van Belle G, Berg L. The consortium to establish a registry for Alzheimer's disease (CERAD). Part II. Standardization of the neuropathologic assessment of Alzheimer's disease. *Neurology*. 1991;42:479-486.
- Mirra SS. Neuropathological assessment of Alzheimer's disease: the experience of the Consortium to Establish a Registry for Alzheimer's disease. *Int Psychogeriatr*. 1997;9 suppl 1:263-272.

- Mitsuyama Y, Takamiya S. Presenile dementia with motor neuron disease. *Arch Neurol*. 1979;36:592-593.
- Mitsuyama Y. Presenile dementia with motor neuron disease. *Dementia*. 1993;4:137-142.
- Moroney JT, Bagiella E, Desmond DW, Hachinski VC, Mölsä PK, Gustafson L, Brun A, Fischer P, Erkinjuntti T, Rosen W, Paik MC, Tatemichi TK. Meta-analysis of the Hachinski ischemic score in pathologically verified dementias. *Neurology*. 1997;49:1096-1105.
- Morris JC, Rubin EH, Morris EJ, Mandel SA. Senile dementia of the Alzheimer type: an important risk factor for serious falls. *J Gerontol*. 1987;42:412-417.
- Morrish PK, Rakshi JS, Bailey DL, Sawle GV, Brooks DJ. Measuring the rate of progression and estimating the preclinical period of Parkinson's disease with [¹⁸F]dopa PET. *J Neurol Neurosurg Psychiatry*. 1998;64:314-419.
- Muir JL, Dunnett SB, Robbins TW, Everitt BJ. Attentional functions of the forebrain cholinergic systems: effects of intraventricular himicholinum, physostigmine, basal forebrain lesions and intracortical grafts on a multiple-choice serial reaction time task. *Exp Brain Res*. 1992;89:611-622.
- MutchWJ, Dingwall-Fordyce I, Downie AW, Paterson JG, Roy SK. Parkinson's disease in a Scottish city. *Br Med J (Clin res ed)*. 1986;292:534-536.
- Mölsä PK, Marttila RJ, Rinne UK. Extrapyrarnidal signs in Alzheimer's disease. *Neurology Cleveland*. 1984;34:1114-1116.
- Neary D, Snowden JS, Shields RA. Single photon emission tomography using 99mTC-HP-MAO in the investigation of dementia. *J Neurol Neurosurg Psychiatry*. 1987;50:1101-1109.
- Neary D, Snowden JS, Northen B, Goulding PJ. Dementia of frontal type. *J Neurol Neurosurg Psychiatry*. 1988;51:353-361.
- Neary D. Classification of dementias. *Rev Clin Gerontol*. 1999;9:55-64.
- Negro PJ Jr, Farber R. Lewy body disease in a patient with REM sleep disorder. *Neurology*. 1996;46:1493-1494.
- Newell KL, Hyman BT, Growdon JH, Hedley-Whyte ET. Application of the National Institute on Aging (NIA)-Reagan Institute criteria for the neuropathological diagnosis of Alzheimer's disease. *J Neuropathol Exp Neurol*. 1999;58:1147-1155.
- Obrist WD, Thompson HK, Wang HS, Wilkinson WE. Regional cerebral blood flow by 133-xenon inhalation. *Stroke*. 1975;6:245-256.

- Okazaki H, Lipkin LE, Aronson SM. Diffuse intracytoplasmatic ganglionic inclusions (Lewy type) associated with progressive dementia and quadriparesis in flexion. *J Neuropathol Exp Neurol.* 1961;20:237-244.
- Onari K, Spatz H. Anatomische Beiträge zur Lehre von der Pickschen umschriebenen Großhirnrinden-Atrophie ('Picksche Krankheit'). *Z Neurol.* 1926;101:470-511.
- Ormerod AD. Syncope. (Clinical Algorithms). *Br Med J.* 1984;288:1219-1222.
- Oyeboode JR, Barker WA, Blessed G, Dick DJ, Britton PG. Cognitive functioning in Parkinson's disease: In relation to prevalence of dementia and psychiatric diagnosis. *Br J Psychiatry.* 1986;149:720-725.
- Pakiam AS, Bergeron C, Lang AE. Diffuse Lewy body disease presenting as multiple system atrophy. *Can J Neurol Sci.* 1999;26:127-131.
- Papka M, Rubio A, Schiffer RB, Cox C. Lewy body disease: can we diagnose it? *J Neuropsychiatry Clin Neurosci.* 1998;10:405-412.
- Parkinson JD. *The Shaking Palsy.* London, Sherwood, Neely & Jones, 1817.
- Passant U. Blood pressure changes and white matter pathology in Alzheimer's disease. A clinical and neuropathological study of brain disease and cardiovascular risk factors. In: *Posture and brain function in dementia – a study with special reference to orthostatic hypotension (Thesis).* Lund, 1996.
- Passant U, Warkentin S, Karlsson S, Nilsson K, Edvinsson L, Gustafson L. Orthostatic hypotension in organic dementia: Relationship between blood pressure, cortical blood flow and symptoms. *Clin Auton Res.* 1996;6:29-36.
- Passant U, Elfgren C, Risberg J, Rosén I, Gustafson L. Brain imaging in frontotemporal dementia. *Int J Geriatr Psychopharmacol.* 2000;2:90-96.
- Pasquier F, Lebert F, Petit H. Dementia, apathy, and thalamic infarcts. *Neuropsychiatry Neuropsychol Behav Neurol.* 1995;8:208-214.
- Pearce J. The extrapyramidal disorder of Alzheimer's disease. *Eur Neurol.* 1974;12:94-103.
- Perry EK, Perry RH, Blessed G, Tomlinson BE. Necropsy evidence of central cholinergic deficits in senile dementia. *Lancet.* 1977:189.
- Perry EK, Perry RH, Candy JM, Fairbairn AF, Blessed G, Dick DJ, Tomlinson BF. Cortical serotonin S2 receptor binding abnormalities in patient with Alzheimer's disease: Comparisons with Parkinson's disease. *Neurosci Lett.* 1984;51:353-357.

- Perry EK, McKeith I, Thompson P, Marshall E, Kerwin J, Jabeen S, Edwardson JA, Ince P, Blessed G, Irving D, Perry RH. Topography, extent, and clinical relevance of neurochemical deficits in dementia of Lewy body type, Parkinson's disease and Alzheimer's disease. *Ann N Y Acad Sci.* 1991;640:197-202.
- Perry EK, Irving D, Kerwin JM, McKeith IG, Thompson P, Collerton D, Fairbairn AF, Ince PG, Morris CM, Cheng AV, Perry RH. Cholinergic transmitter and neurotrophic activities in Lewy body dementia similarity to Parkinson's disease and distinction from Alzheimer disease. *Alzheimer Dis Assoc Disord* 1993b;7:69-79.
- Perry EK, Haroutunian V, Davis DL, Levy R, Lantos P, Eagger S, Honavar M, Dean A, Griffith M, McKeith IG, Perry R. Neocortical cholinergic activities differentiate Lewy body dementia from classical Alzheimer's disease. *Neuroreport.* 1994;5:747-749.
- Perry E, Walker M, Grace J, Perry R. Acetylcholine in mind: A neurotransmitter correlate of consciousness? *Trends Neurosci.* 1999;22:273-280.
- Perry RH, Tomlinson BE, Candy JM, Blessed G, Foster JF, Bloxham CA, Perry EK. Cortical cholinergic deficit in mentally impaired parkinsonian patients. *Lancet.* 1983;2:789-790.
- Perry RH, Irving D, Blessed G, Perry EK, Fairbairn AF. Clinically and neuropathologically distinct form of dementia in the elderly. *Lancet.* 1989;166.
- Perry RH, Irving D, Tomlinson BE. Lewy body prevalence in the aging brain: relationship to neuropsychiatric disorders, Alzheimer-type pathology and catecholaminergic nuclei. *J Neurol Sci.* 1990a;100:223-233.
- Perry RH, Irving D, Blessed G, Fairbairn A, Perry EK. Senile dementia of Lewy body type – a clinically and neuropathologically distinct form of Lewy body dementia in the elderly. *J Neurological Sci.* 1990b;95:119-139.
- Perry R, McKeith I, Perry E. Lewy body dementia – clinical, pathological and neurochemical interconnections. *J Neural Transm.* 1997;suppl 51: 95-109.
- Perusini G. Überklinisch und histologisch eigenartige psychische erkrankungen des späteren lebensalters. *Histol U Histopath.* 1910;3:297-351.
- Petit D, Montplaisir J, Reikkinen PJ Sr, Soininen H, Reikkinen P Jr: Electrophysiological test. In: Gauthier S, (ed). *Clinical Diagnosis and Management of Alzheimer's Disease.* London: Dunitz, 1996:107-127.
- Piggott MA, Perry EK, McKeith IG, Marshall E, Perry RH. Dopamine D2 receptors in demented patients with severe neuroleptic sensitivity. *Lancet.* 1994;343:1044-1045.

- Pigott MA, Perry EK, Marshall EF, McKeith IG, Johnson M, Melrose HL, Court JA, Lloyd S, Fairbairn A, Brown A, Thompson P, Perry RH. Nigrostriatal dopaminergic activities in dementia with Lewy bodies in relation to neuroleptic sensitivity: comparisons with Parkinson's disease. *Biol Psychiatry*. 1998;44:765-774.
- Pizzolato G, Dam M, Borsato N, Saitta B, DaCol C, Perlotto N, Zanco P, Ferlin G, Battistin L. 99m Tc-HM-PAO-SPECT in Parkinson's disease. *J Cereb Blood Flow Metab*. 1988;8:S101-S108.
- Pollanen MS, Bergeron C, Weyer L. Detergent-soluble cortical Lewy body fibrils share epitopes with neurofilament and tau. *J Neurochem*. 1992;58:1953-1956.
- Pollanen MS, Dickson DW, Bergeron C. Pathology and biology of the Lewy body. *J Neuropath Exp Neurol*. 1993;52:183-191.
- Polymeropoulos MH, Lavedan C, Leroy E, Ide SE, Dehejia A, Dutra A, Pike B, Root H, Rubenstein J, Boyer R, Stenroos ES, Chandrasekharappa S, Athanassiadou A, Papapetropoulos T, Johnson WG, Lazzarini Am, Duvoisin RC, Di Iorio G, Golbe LI, Nussbaum RL. Mutation in the alpha-synuclein gene identified in families with Parkinson's disease. *Science*. 1997;276:2045-2047.
- Price KS, Farley I, Hornykiewicz O. Neurochemistry of Parkinson's disease: Relations between striatal and limbic dopamine. *Adv Biochem Psychopharmacol*. 1978;19:293-300.
- Prudham D, Evans JG. Factors associated with falls in the elderly: a community study. *Age Ageing*. 1981;10:141-146.
- Qualman SJ, Haupt HM, Yang P, Hamilton SR. Esophageal Lewy bodies associated with ganglion cell loss in achalasia. *Gastroenterology*. 1984;87:848-856.
- Querfurth HW, Allam GJ, Geffroy MA, Schiff HB, Kaplan RF. Acetylcholinesterase inhibition in dementia with Lewy bodies: Results of a prospective pilot trial. *Dement Geriatr Cogn Disord*. 2000;11:314-321.
- Rajput AH, Rozdilsky. Dysautonomia in parkinsonism: a clinicopathological study. *J Neurol Neurosurg Psychiatry*. 1976;39:1092-1100.
- Rajput AH, Rozdilsky B, Rajput A. Accuracy of clinical diagnosis in parkinsonism – a prospective study. *Can J Neurol Sci*. 1991;18:275-278.
- Rajput AH. Clinical features and natural history of Parkinson's disease (special consideration of aging). In: *Neurodegenerative diseases*. Calne DB (ed). WB Saunders Company, USA. 1994. pp 555-571.

- Reikkinen M, Laakso MP, Jäkälä P, Reikkinen P Jr: Clonidin impairs sustained attention in Alzheimer's disease; in Iqbal K, Swaab B, Wisniewski HM (eds): Alzheimer's disease and related disorders. John Wiley&Sons Ltd. 1999. pp 641-647.
- Reyes MG, Faraldi F, Chandran R, Verano A, Levi AC. Histopathology of the substantia nigra in Alzheimer's disease. *Panminerva Med.* 1996;38:8-14.
- Riechfield EK, Twyman R, Berent S. Neurological syndrome following bilateral damage to the head of the caudate nuclei. *Ann Neurol.* 1987;22:767-771.
- Riederer P, Birkmayer W, Seemann D, Wuketich ST. Brainnoradrenalin and 3-methoxy-4-hydroxyphenylglucol in Parkinson's syndrome. *J Neurol Transm.* 1977;41:241-251.
- Rinne JO, Säkö E, Paljärvi L, Mölsä PK, Rinne UK. Brain dopamine D-2 receptors in senile dementia. *J Neural Transm.* 1986;65:51-62.
- Risberg J, Ali Z, Wilson EM, Wills EL, Halsey JH. Regional cerebral blood flow by ¹³³-xenon inhalation. *Stroke.* 1975;6:142-148.
- Risberg J. Regional cerebral blood flow measurements by ¹³³ Xe-inhalation: methodology and applications in neuropsychology and psychiatry. *Brain and Language.* 1980;9:9-34.
- Risberg J, Gustafson L. ¹³³Xe cerebral blood flow in dementia and in neuropsychiatry research. In: Functional radionuclide imaging of the brain. Phillippe Magistretti, C (ed.) Raven Press, New York. 1983. pp 151-159.
- Risberg J. Regional cerebral blood flow. In: Experimental Techniques in Human Neuropsychology. Hannay JH (ed). New York, Oxford Press. 1986. pp 514-543.
- Risberg J, Passant U, Warkentin S, Gustafson L. Regional cerebral blood flow in frontal lobe dementia of non-Alzheimer type. *Dementia.* 1993;3-4:186-187.
- Román GC, Tatemichi TK, Erkinjuntti T, Cummings JL, Marsden JC, Garcia JH, Amaducci L, Ororozo JM, Brun A, Hofman A, Moody DM, O'Brien MD, Yamaguchi T, Grafman J, Drayer BP, Bennett DA, Fisher M, Ogata J, Kokmen E, Bermejo F, Wolf PA, Gorelick PB, Bock KL, Pajean AK, Bell MA, DeCarli C, Culebras A, Korczyn AD, Bogousslavsky J, Hartmann A, Scheinberg P. Vascular dementia: diagnostic criteria for research studies. Report of the NINCDS-AIREN International Work group. *Neurology.* 1993;43:250-260.

- Rossor MN, Svendsen C, Hunt SP, Mountjoy CO, Roth M, Iversen LL. The substantia innominata in Alzheimer's disease: a histochemical and biochemical study of cholinergic marker enzymes. *Neurosci Lett*. 1982;28:217-222.
- Rossor MN, Iversen LL, Reynolds GP, Mountjoy CQ, Roth M. Neurochemical characteristics of early and late onset types of Alzheimer's disease. *BMJ*. 1984;288:961-964.
- Roth M. Classification and aetiology in mental disorders of old age: some recent developments. In: *Recent developments in Psychogeriatrics – A Symposium*. Kay DWK, Walk A (eds). *Br J Psychiatry*, spec publ no 6. 1971. pp 1-18.
- Roth M. The diagnosis of dementia in late and middle life. In: *The Epidemiology of Dementia*. Mortimer JA, Schuman LM (eds). Oxford University Press. New York, Oxford. 1981. pp 24-61.
- Rubenstein LZ, Robbins AS. Falls in the elderly. A clinical approach. *Geriatr*. 1984;39:67-78.
- Rövéti G. Über Zelleinschlüsse in Substantia nigra und Locus coeruleus bei Fällen ohne Parkinsonsyndrom, zugleich ein Beitrag zur Kenntnis der senilen Veränderungen dieser Gebiete. *Msschr Psychiat Neurol*. 1956;132:347-363.
- Saitoh T, Xia Y, Chen X, Thal LJ, Hansen LA, Katzman R. The CYP2D6B mutant allele is overrepresented in the Lewy body variant of Alzheimer's disease. *Ann Neurol*. 1995;37:110-112.
- Samuel W, Galasko D, Masliah E, Hansen LA. Neocortical Lewy body counts correlate with dementia in the Lewy body variant of Alzheimer's disease. *J Neuropathol Exp Neurol*. 1996;55:44-52.
- Samuel W, Alford M, Hofstetter CR, Hansen L. Dementia with Lewy bodies versus pure Alzheimer disease: differences in cognition, neuropathology, cholinergic dysfunction, and synapse density. *J Neuropathol Exp Neurol*. 1997;56:499-508.
- Scatton B, Rouquier L, Javoy-Agid F, Agid Y. Dopamine deficiency in the cerebral cortex in Parkinson disease. *Neurology*. 1982;32:1039-1040.
- Scheltens P, Barkhof F, Leys D, Wolters EC, Ravid R, Kamphorst W. Histopathologic correlates of white matter changes on MRI in Alzheimer's disease and normal aging. *Neurology*. 1995;45:883-888.
- Scholz W. Studien zur Pathologie der Hirngefäße; die druzige entartung der Hirnarterien und Capillaren (Eine Form seniler Gefässerkrankung). *Z Gesamte Neurol Psychiatry*. 1938;162:694-715.

- Schoenberger JA. Drug-induced orthostatic hypotension. *Drug safety*. 1991;6:402-407.
- Senard JM, Rai S, Lapeyre-Mestre M, Brefel C, Rascol O, Rascol A, Montastruc JL. Prevalence of orthostatic hypotension in Parkinson's disease. *J Neurol Neurosurg Psychiatry*. 1997;63:584-589.
- Shea C, MacKnight C, Rockwood K. Donepezil for treatment of dementia with Lewy bodies: a case series of nine patients. *Int Psychogeriatr*. 1998;10:229-238.
- Shergill S, Mullan E, D'At P, Katona C. What is the clinical prevalence of Lewy body dementia? *Int J Geriatr Psychiatry*. 1994;9:907-912.
- Sigwald J, Lapresle J, Raverdy P, Recondo HJ. Atrophie cérébelleuse familiale avec association de lésions nigériennes et spinales. *Presse Med*. 1964;72:557-62.
- Sjögren H. Clinical analysis of morbus Alzheimer and morbus pick. *Acta Psychiat et Neurol*. 1952;suppl 82:69-139.
- Sjögren M, Minthon L, Passant U, Blennow K, Wallin A. Decreased monoamine metabolites in frontotemporal dementia and Alzheimer's disease. *Neurobiol Aging*. 1998;19:379-384.
- Skoog I, Aevarsson O. Epidemiology of vascular dementia in Europe. In: *Cerebrovascular disease and dementia. Pathology, Neuropsychiatry and management*. Chiu E, Gustafson L, Ames D, Folstein MF (eds). Martin Dunitz Ltd, London. 2000. pp 15-24.
- Spampinato U, Habert O, Mas JL, Bourdel MC, Ziegler M, de Recondo J, Askienazy S, Rondot P. (99m Tc)-HM-PAO-SPECT and cognitive impairment in Parkinson's disease: a comparison with dementia of the Alzheimer type. *J Neurol Neurosurg Psychiatry*. 1991;54:787-792.
- Spillantini MG, Schmidt ML, Lee VMY, Trojanowski JQ, Jakes R, Goedert M. α -Synuclein in Lewy bodies. *Nature*. 1997;338:839-340.
- Soininen H, Puranen M, Riekkinen PJ. Computed tomography findings in senile dementia and normal aging. *J Neurol Neurosurg Psychiatry*. 1982;45:50-54.
- Sourander P, Sjögren H. The concept of Alzheimer's disease and its clinical implications. In: *Alzheimer's Disease and Related Conditions*. Wolstenholme GEW, O'Connor M, Churchill J and A (eds). London. 1970. pp 11-36.
- Stern Y, Mayeux R, Cote L. Reaction time and vigilance in Parkinson's disease. *Arch Neurol*. 1984;41:1086-1089.
- Stern Y, Langston JW. Intellectual changes in patients with MPTP induced parkinsonism. *Neurology*. 1985;35:1506-1509.

- Stevens M, Van Sweiten JC, Van Duijn CM, Tibben A, Niermeijer MF. Familiäre vormen van frontotemporale dementia. *Nederlands Tijdschrift voor Geneeskunde*. 1995;139:871-875.
- Stevens M. Fronto temporal dementia – a clinical and genetic-epidemiological study. Thesis. 1998, p 115.
- Terry RD, Peck A, DeTeresa R, Schechter R, Horoupian DS. Some morphometric aspects of the brain in senile dementia of Alzheimer type. *Ann Neurol*. 1981;10:184-192.
- The National Institute on Aging, and Reagan Institute Working Group on diagnostic criteria fro the neuropathological assessment of Alzheimer's disease. *Neurobiol Aging*. 1997; 18(S4):S1-S2.
- Tinetti ME, Williams TF, Mayewski R. Fallrisk index for elderly patients based on the number of chronic disabilities. *Am J Med*. 1986;80:429-434.
- Tinetti ME, Speechley M, Ginter SF. Risk factors for falling in elderly persons living in the community. *N Engl J Med*. 1988;319:1701-1707.
- Tomlinson BE, Blessed G, Roth M. Observations on the brains of demented old people. *J Neurol Sci*. 1970;11:205-242.
- Tompkins MM, Basgall EJ, Zamrini E, Hill WD. Apoptotic-like changes in Lewy-body-associated disorders and normal aging in substantia nigral neurons. *Am J Pathol*. 1997;150:119-131.
- Trenkwalder C, Paulus W, Krafczyk S, Hawken M, Oertel WH, Brandt Th. Postural stability differentiates "lower body" from idiopathic parkinsonism. *Acta Neurol Scand*. 1995;91:444-452.
- Trétiakoff C. Contribution l'étude de l'anatomie patologique du locus niger de Soemmering. Thèse de Paris. 1919.
- Tröster AI, Fields JA, Koller WC. Parkinson's disease and parkinsonism. In: *Textbook of geriatric neuropsychiatry*. Coffey CE, Cummings JL (eds). American Psychiatric Press, Inc. Washington, DC, London, England. 2000. pp 559-589.
- Turjanski N, Brooks DJ. PET and the investigation of dementia in the parkinsonian patient. *J Neural Transm*. 1997(suppl);51:37-48.
- Uchiyama M, Isse K, Tanaka K, Yokota N, Hamamoto M, Aida S, Ito Y, Yoshimura M, Okawa M. Incidental Lewy body disease in a patient with REM sleep behavior disorder. *Neurology*. 1995;45:709-712.
- Ulrich J, Probst A, Wuest M. The brain diseases causing senile dementia. A morphological study on 54 consecutive autopsy cases. *J Neurol*. 1986;233:118-122.

- Wakabayashi K, Takahashi, H, Takeda S, Ohama E, Ikuta F. Lewy bodies in the enteric nervous system in Parkinson's disease. *Arch Histol Cytol.* 1989;52(suppl):191-194.
- Wakabayashi K, Hansen LA, Masliah E. Cortical Lewy body containing neurons are pyramidal cells: laser confocal imaging of double-immunolabeled sections with anti-ubiquitin and SMI3. *Acta Neuropathol (Berlin).* 1995;89:404-408.
- Wakabayashi K, Takahashi H. Neuropathology of autonomic nervous system in Parkinson's disease. *Eur Neurol.* 1997;38:2-7.
- Walker Z, Costa DC, Janssen AG, Walker RW, Livingstone G, Katona CL. Dementia with Lewy bodies: a study of post-synaptic dopaminergic receptors with iodine-123 iodobenzamide single-photon emission tomography. *Eur J Nucl Med.* 1997;24:609-614.
- Walker Z, Costa DC, Ince P, McKeith IG, Katona CL. In-vivo demonstration of dopaminergic degeneration in dementia with Lewy bodies. *Lancet.* 1999a;354:646-647.
- Walker Z, Grace J, Overshot R, Satarasinghe S, Swan A, Katona CL, McKeith IG. Olanzapine in dementia with Lewy bodies: a clinical study. *Int J Geriatr Psychiatry.* 1999b;14:459-466.
- Wallin A, Blennow K, Gottfries CG, Långström G, Uhlemann C. White matter low attenuation on computed tomography in Alzheimer's disease and vascular dementia. *Acta Neurol Scand.* 1989;80:518-523.
- Wallin A, Blennow K. Heterogeneity of vascular dementia: Mechanisms and subgroups. *J Geriatr Psychiat Neurol* 1993;6:177-188.
- Wallin A, Brun A, Gustafson L (eds) Swedish consensus on dementia diseases. *Acta Neurol Scand.* 1994;90:3-31.
- Wallin A, Edman Å, Blennow K, Gottfries C-G, Karlsson I, Regland B, Sjögren M. Stepwise comparative status analysis (STEP): A tool for identification of regional brain syndromes in dementia. *J Geriatr Psychiatr Neurol.* 1996;9:185-199.
- van Ingelghem E, van Zandijcke M, Lammens M. Pure autonomic failure: a new case with clinical, biochemical, and necropsy data. *J Neurol Neurosurg Psychiatry.* 1994;57:745-747.
- Varma AR, Talbot PR, Snowden JS, Lloyd JJ, Testa HJ, Neary D. A ^{99m}Tc -HMPAO single-photon emission computed tomography study of Lewy body disease. *J Neurol.* 1997;244:349-359.
- Vergheze J, Crystal HA, Dickson DW, Lipton RB. Validity of clinical criteria for the diagnosis of dementia with Lewy bodies. *Neurology.* 1999;53:1974-1982.

- Whitehouse PJ, Price DL, Clark AW, Coyle JT, DeLong MR. Alzheimer's disease: evidence for selective loss of cholinergic neurons in the nucleus basalis. *Ann Neurol*. 1981;10:122-126.
- Victoroff J, Mack WJ, Lyness SA, Chui HC. Multicenter clinicopathological correlation in dementia. *Am J Psychiatry*. 1995;152:1476-1484.
- Wilcock GK, Scott MI. Tacrine for senile dementia of Alzheimer's or Lewy body type. *Lancet*. 1994;344:544.
- Wilhelmsen KC, Lynch T, Pavlou E, Higgins M, Nygaard TG. Localization of disinhibition-dementia-parkinsonism-amyotrophy complex to 17q21-22. *Am J Hum Genet*. 1994;55:1159-1165.
- Wilson RS, Fox JH, Huckman MS, Bacon LD, Lobick JJ. Computed tomography in dementia. *Neurology*. 1982;32:1054-1057.
- Woodard JS. Concentric hyaline inclusion body formation in mental disease: Analysis of twenty-seven cases. *J Neuropath Exper Neurol*. 1962;21:442-449.
- Wragg RE, Jeste DV. Overview of depression and psychosis in Alzheimer's disease. *Am J Psychiatry*. 1989;145:577-587.
- Yamamoto T, Hirano A. Nucleus raphé dorsalis in Alzheimer's disease: neurofibrillary tangles and loss of large neurons. *Ann Neurol*. 1985;22:17-32.
- Zweig RM, Ross CA, Hedreen JC, Steele C, Cardillo JE, Whitehouse PJ, Folstein MF, Price DL. The neuropathology of aminergic nuclei in Alzheimer's disease. *Ann Neurol*. 1988;24:233-242.
- Zubenko GS, Moosy J, Koop U. Neurochemical correlates of depression in primary dementia. *Arch Neurol*. 1990;47:209-214.

CLINICAL LEWY BODY DEMENTIA AND THE IMPACT OF VASCULAR COMPONENTS

ELISABET LONDOS,^{1*} ULLA PASSANT,¹ ARNE BRUN² AND LARS GUSTAFSON³

¹*Department of Psychogeriatrics, University Hospital, Lund, Sweden*

²*Professor, Department of Pathology, University Hospital, Lund, Sweden*

³*Professor, Department of Psychogeriatrics, University Hospital, Lund, Sweden*

ABSTRACT

Objective. To study the prevalence of patients fulfilling the clinical consensus criteria for dementia with Lewy bodies (DLB) in a dementia population followed up with postmortem examination. To compare the clinical and neuropathological findings in the clinical Lewy body dementia (LBD) group with findings in a clinically defined group with Alzheimer's disease (AD).

Design. Medical records from 200 patients were studied retrospectively. Clinical consensus criteria for DLB and clinical criteria for other dementias were applied.

Setting. The majority of the cases were examined and cared for in psychogeriatric and psychiatric departments.

Patients. The patients, who died between 1985 and 1994, were part of a longitudinal dementia project. Each case was neuropathologically examined.

Main outcome measures. Prevalence of clinical signs and neuropathology was compared between the clinical groups.

Results. Forty-eight (24%) patients fulfilled the clinical criteria for DLB while 45 (22%) fulfilled the clinical criteria for Alzheimer's disease. The clinical LBD group had a higher Hachinski score compared to the clinical AD group. They also showed a tendency towards a 'frontal profile' with disinhibition, confusion, personality change and vocally disruptive behaviour. More than 80% of the AD and LBD groups respectively exhibited Alzheimer pathology. The LBD group had frontal white matter pathology and degeneration of the substantia nigra more often than the clinical AD group. Both LBD and AD groups showed a progressive and marked increase in severity of dementia and decrease in ADL capacity according to an evaluation based on the Berger scale and Katz index. The condition of the LBD group was significantly worse earlier in dementia.

Conclusion. The results of this study indicate that patients fulfilling the clinical criteria for DLB also exhibit clinical features of possible vascular origin and a frontal profile. Subcortical vascular pathology, nigral degeneration and AD pathology in this group could partly explain the clinical features used to define DLB. Copyright © 2000 John Wiley & Sons, Ltd.

KEY WORDS—Lewy body dementia; Alzheimer's disease; white matter disease; differential diagnosis; ischaemic score; Parkinsonism; ADL function

In recent decades the clinicopathological entity of Lewy body dementia (LBD) or dementia with Lewy bodies (DLB) has become a field of great interest and lively debate among dementia researchers. LBD has been proposed to be the second most common organic dementia after

Alzheimer's disease. In different pathological materials, the prevalence rates of SDLT were 12–27% (Dickson *et al.*, 1989; Lennox *et al.*, 1989).

In 1995 a consensus agreed on the clinical criteria for DLB (Appendix 1). The first criterion comprises a dementing syndrome with progressive decline in cognition. Core features are extra-pyramidal symptoms, fluctuations and visual hallucinations, while supporting features are repeated falls, syncope, transient loss of consciousness, delusions and hallucinations in other modalities. Dementia caused by stroke or underlying physical illness or brain disorder should be excluded.

*Correspondence to: Dr E. Londos, Department of Psychogeriatrics, University Hospital, S-221 85 Lund, Sweden. Tel: +46 4617 7463. Fax: +46 4617 7456. e-mail: elisabet.londos@psykiatr.lu.se

Contract grant sponsor: Alzheimerfoundation, Sweden.

These clinical criteria, however, proved to have variable sensitivity and specificity (McKeith *et al.*, 1994; Mega *et al.*, 1996; Papka *et al.*, 1998; Holmes *et al.*, 1998).

In the context of this study, the term 'DLB' is used for neuropathologically diagnosed cases and 'LBD' for clinically diagnosed cases.

AIM OF THE INVESTIGATION

The aim of this study was to see if LBD could be identified clinically in our dementia population through the application of the clinical consensus criteria for DLB.

Clinical and neuropathological comparisons with other clinically defined dementia groups could then be made, particularly in regard to Alzheimer's disease (AD).

MATERIAL AND METHODS

The patients were selected from a large population of patients with dementia—the Lund Longitudinal Dementia Study, which is an ongoing project with a prospective design (Gustafson and Hagberg, 1975). This project started 30 years ago and the neuropathological panorama of the first 400 deceased before 1991 has been presented (Brun and Gustafson, 1993). In this project, most patients have undergone an extensive investigation with neuropsychiatric evaluation including neurological examination, neuropsychological testing, brain imaging such as computerized tomography (CT) and measurement of regional cerebral blood flow (rCBF), neurophysiological examination including EEG, and finally a detailed neuropathological examination. These interdisciplinary collaborators developed clinical criteria for early recognition and differential diagnosis of specific types of dementia. LBD has not previously been diagnosed in this material.

In the present study, clinical records from 200 deceased patients who had undergone neuropathological postmortem examination were studied retrospectively. The cases were selected in order of date of death. They were all part of the longitudinal dementia project involving patients who had died between 1985 and 1994. Twelve cases were excluded (see Results). One hundred and eighty-eight cases were diagnosed according to three sets of clinical criteria for LBD (McKeith *et al.*, 1992, 1996; Byrne *et al.*, 1991). Furthermore,

clinical criteria for AD (DSM-IV and NINCDS–ADRDA; McKhann *et al.*, 1984), the Lund–Manchester criteria (Burns *et al.*, 1994) for diagnosis of frontotemporal dementia (FTD) and the DSM-IV criteria for vascular dementia (VaD) were applied. Differential diagnostic rating scales 'AD score' (Gustafson and Nilsson, 1982; Brun and Gustafson, 1993), 'FTD score' (Gustafson and Nilsson, 1982) and 'ischaemic score' (Hachinski *et al.*, 1975) were also applied to improve the clinical differentiation.

The Berger scale (Berger, 1980) was used as a global measure of severity of dementia and the Katz index of independence in ADL (Katz *et al.*, 1963) was chosen as a complementary measure of severity of impairment (see Appendix 2). These ratings were based on standardized assessments including reports from social workers and staff responsible for the care of the patients. Each patient was assessed 1–3 times. The first and the last assessment for each patient were chosen to describe the progress of the dementia.

The rater (EL) had not previously clinically tested these patients and all ratings were performed regardless of neuropathological results. The majority of cases (>90%) were examined and/or cared for at psychogeriatric and psychiatric departments. The remaining group of patients was mainly cared for at nursing homes.

The data were collected from medical records kept by psychiatrists, consultant doctors of different specialities, nurses and other staff members. They included neuropsychiatric and somatic investigations, psychometric testing, measurement of regional cerebral blood flow (rCBF), EEG and in many cases CT. No personal assessments were made except for laboratory and blood pressure values (for example, vitamin B12 deficiency, hypothyreosis and arterial hypotension).

The patients' clinical status was assessed from the clinical records, in which a symptom not regarded as present is not recorded.

The average total observation time at the psychogeriatric ward was 10.3 months/patient. The long and often well-documented period of observation explains the high prevalence of symptoms.

For a clinical diagnosis of LBD the criteria of 'probable DLB', according to consensus guidelines 1996 (McKeith *et al.*, 1996), were used.

The group with 'clinical LBD' originally had other clinical diagnoses and several patients also fulfilled criteria for AD. When this occurred, the LBD diagnosis was given preference.

The consensus criteria for DLB are presented in Appendix 1. Some items will be easily understood, while the interpretation of other items needs further explanation.

The first criterion was considered fulfilled when the patient had 'a progressive cognitive decline ...', and 'prominent and persistent memory disturbances ...' and failed on frontosubcortical and visuospatial tasks based on either neuropsychological tests or information obtained from the neuropsychiatrist or neurologist.

Criterion 2(c), Parkinsonism, was diagnosed when tremor, muscular rigidity, bradykinesia, Parkinsonian gait and/or flexed body position were present. The fourth criteria on exclusion here are based on brain imaging and physical examination. However, the rCBF findings were not taken into account for the recognition of cerebrovascular disease in this study, since rCBF results will be analysed in a forthcoming paper.

Patients who suffered stroke only at a terminal stage (1–3 months before death) and otherwise fulfilled DLB criteria were not excluded.

Somatic diseases like vitamin B12 deficiency, folate deficiency, hypothyreosis, hyperparathyroidism and orthostatic hypotension which were diagnosed and treated were not considered 'sufficient to account' for the dementing disorder *per se*.

Statistical analysis

All statistical work was conducted in SPSS. The χ^2 -test (with continuity correction) was used for comparison of proportions in supportive diagnostic features, neurological features and neuropathology. Fischer's exact test was applied for comparisons in Table 6, as well as for comparison of fluctuations measured by the Katz and Berger scales. Multiple comparisons of variables in Tables 3 and 5 were achieved using logistic regression analyses. The Student's *t*-test was used for comparison of scores between the LBD and the AD groups in the diagnostic rating scales and onset

of urinary incontinence. An application of the Mann-Whitney U-test resulted in an assessment of the significance of the differences in number of symptoms between the AD and LBD groups. Spearman's rank correlation coefficient was used in order to measure the relation between the degree of substantia nigra degeneration and the number of extrapyramidal symptoms. All analyses were carried out against a two-tailed alternative.

RESULTS

Material

Two hundred patients were included in the study. Seven patients were excluded since their medical records were not available and in five additional cases the clinical information was considered insufficiently complete for the present purpose and they were therefore excluded from the study.

The remaining 188 medical records were studied by collecting clinical data referring to prior medical history, symptoms, findings on physical examination, laboratory test results, medication, EEG, CT results, etc. The patients were diagnosed according to criteria for AD, VaD and DLB. The basic characteristics of the patient groups are shown in Table 1.

Fifty patients did not fulfil any of these clinical dementia criteria. The tentative clinical diagnoses in these patients were VaD ($N = 15$, did not fulfil DSM-IV), AD ($N = 6$, did not fulfil DSM-IV and NINCDS-ADRDA criteria), Creutzfeldt Jacob disease ($N = 3$), Huntington's disease ($N = 2$), post-traumatic dementia ($N = 2$), non-organic psychosis ($N = 13$) and single cases of several other diseases such as Gerstmann Streussler Schinkel, leucencephalopathy, brain tumour, amyotrophic lateral sclerosis and Parkinson's disease, etc.

The antemortem clinical diagnoses in 48 LBD and 45 AD patients diagnosed retrospectively,

Table 1. Demographic data

	LBD	AD	VaD	AD + VaD	FTD
<i>N</i>	48	45	20	13	12
Male/female	20/28	18/27	10/10	9/4	6/6
Age at death	78 (58–94)	79 (61–97)	78 (66–91)	77 (68–91)	60 (40–85)
Age of onset	71 (52–82)	72 (50–87)	75 (61–88)	70 (59–87)	55 (34–83)
Dementia duration	7.1 (1–16)	7.7 (2–19)	3.5 (0–9)	6.8 (3–12)	5.9 (2–14)

Table 2. Antemortem clinical diagnoses in 48 LBD and 45 AD patients diagnosed retrospectively according to clinical consensus criteria

Antemortem diagnosis	Consensus diagnoses	
	LBD* (N = 48)	AD† (N = 45)
AD	21 (43.8%)	34 (75.6%)
VaD	16 (33.3%)	6 (13.3%)
AD + VaD	5 (10.4%)	4 (8.9%)
FTD	2 (4.2%)	1 (2.1%)
PaD	2 (4.2%)	0
Non-organic psychosis	2 (4.2%)	0

* DSM-IV, NINCDS-ADRDA.

† McKeith *et al.* (1996).

according to clinical consensus criteria, are presented in Table 2.

Morbidity

There were no significant differences in vascular morbidity or head trauma between the clinical AD and LBD groups: cardiovascular disorder (29% vs 29%), hypertension (22% vs 31%), orthostatic hypotension (37.5% vs 40%) and diabetes (7% vs 2%). Cardiovascular disease included clinical findings of congestive heart failure, angina pectoris and myocardial infarction. Furthermore, vascular risk factors such as smoking (20% vs 25%), alcohol abuse (18% vs 15%) and increased body-weight did not differ between the clinical LBD and AD groups.

Heredity

There were no statistical differences between clinical AD and LBD concerning heredity for dementia or psychiatric illness (depression, schizophrenia, alcoholism or suicide). Heredity for dementia was noted in 35% of clinical AD and 23% of clinical LBD. Furthermore, there was no difference in heredity for somatic illness (heart/vascular (13% vs 17%) cancer, neurological or endocrine disease).

Clinical criteria for DLB

When the clinical AD and LBD groups were compared, there were significant differences in the core criteria (Table 3). Logistic regression analyses covering all consensus criteria yielded three significant variables for clinical LBD: fluctuations, visual

Table 3. Presence of clinical DLB consensus (%) features in patients with Alzheimer's disease and dementia with Lewy bodies diagnosed clinically

Consensus criteria	AD (N = 45) %	LBD (N = 48) %
'Progressive cognitive decline'	98	100
Fluctuations in general	31.1%	85.4% ^a
Visual hallucinations	24.2%	47.9% ^b
Two or more Parkinsonian symptoms	48.9%	75.0% ^c
Auditory hallucinations	8.9%	31.3%
Delusions	31.1%	35.4%
Repeated falls	57.8%	72.9%
Syncope	15.6%	16.7%
Transient loss of consciousness	37.8%	43.8%
Neuroleptic sensitivity	35.6%	48.0%

Note: Logistic regression analysis with AD and LBD as dependent variables. ^a $p < 0.001$; ^b $p = 0.0095$; ^c $p = 0.017$.

hallucinations and presence of more than two EPS. 'Fluctuations in general' included fluctuations in memory, orientation and activity of daily living (ADL), as well as fluctuations in consciousness. Fluctuation in cognition was present in 35.4% of the LBD and 6.7% of the AD patients; 41.7% of the LBD patients exhibited two or more psychotic symptoms compared to 15.6% of the AD. Furthermore, there were strong intercorrelations between visual and auditory hallucinations ($p < 0.01$), auditory hallucinations and delusions ($p < 0.01$) and visual hallucinations and delusions ($p < 0.05$) in the whole material ($N = 188$).

The number of EPS was significantly higher ($p < 0.001$) in the LBD group compared to the AD group (median 4 vs 1).

Supportive diagnostic features

Falls were more likely to occur in patients with two or more EPS compared to patients with less prevalent EPS ($p = 0.036$). Parkinsonian gait was not connected statistically with repeated falls.

The types of neuroleptic sensitivity reactions noted were worsening of EPS, sedation, salivation and mental deterioration. There were no differences between the different types of neuroleptic sensitivity reactions in the LBD and AD groups, but a trend ($p = 0.08$) towards more EPS in the LBD group.

Table 4. Comparison of prevalence of extrapyramidal symptoms in clinical LBD and neuropathological DLB (%)

Feature	Clinical diagnoses	Neuropathological diagnoses
	Present study (<i>N</i> = 48)	Meta-analysis, Lennox (1992) (<i>N</i> = 75)
Increased muscle tension	85.4%	77.0%
Tremor	45.8%	49.0%
Bradykinesia	41.5%	40.0%
Parkinsonian gait	50.0%	48.0%
Flexed body position	18.8%	28.0%

Neurological features

There were no significant differences in reported neurological signs in clinical AD and LBD except for dyspraxia, which was more common in the AD group ($p = 0.046$, 64.4% vs 41.7%).

Visual impairment or hearing disability was reported to the same extent in the different clinical groups. Faecal incontinence was more common in the LBD group compared to the AD group (41.7% vs 22.2%), although this finding was not statistically significant.

Behavioural disturbances

Confusional episodes and personality change were more prevalent in the clinical LBD than in the AD group when logistic regression analyses were applied. Disinhibition and vocally disruptive behaviour (Hallberg *et al.*, 1993) were more prevalent in the LBD group, although the difference from the AD group was non-significant with the statistical method used (Table 5).

Diagnostic rating scales

Rating scales for recognition of AD (Gustafson and Nilsson, 1982; Brun and Gustafson, 1993), VaD (Hachinski *et al.*, 1975) and FTD (Gustafson and Nilsson, 1982; Brun and Gustafson, 1993) were applied on the medical records. The clinical usefulness of the scoring profile of these diagnostic rating scales has been validated against neuropathology and brain imaging (Brun and Gustafson, 1993; Risberg and Gustafson, 1983; Moroney *et al.*, 1997).

Table 5. Clinical features of frontal type in clinically diagnosed Lewy body dementia (LBD), Alzheimer's disease (AD), vascular dementia (VaD), mixed dementia (AD + VaD) and frontotemporal dementia (FTD) (%)

	LBD	AD	VaD	AD + VaD	FTD
<i>N</i>	48	45	20	13	12
Aggression	60.4	55.6	55.0	69.2	33.3
Spontaneity in speech	47.9	42.2	20.0	53.8	83.3
Confusion	50.0	24.4 ^a	55.0	61.5	41.7
Disinhibition	37.5	17.8	35.0	15.4	50.0
Irritability/dysphoria	45.8	37.8	50.0	53.8	25.0
Lack of insight	47.9	48.9	35.0	46.2	83.3
Personality change	18.8	4.4 ^b	40.0	53.8	75.0
Vocally disruptive behaviour	35.4	13.3	25.0	46.2	8.3

Note: Logistic regression analysis with AD and LBD as dependent variables. ^a $p = 0.007$; ^b $p = 0.026$.

The AD scores, based on 12 items with a maximum score of 17 and a score of 5 or above indicating AD, were very similar in the clinical AD (7.5 ± 2.4) and LBD (7.4 ± 2.8) groups.

The ischaemic score, based on 13 items with a maximum score of 18 and a score of 7 or above indicating vascular aetiology, was significantly higher ($p < 0.001$) in the clinical LBD (5.3 ± 2.6) compared to the clinical AD (2.9 ± 1.8) group. The FTD score, based on nine items with a maximum score of 13 and a score of 5 or above indicating frontal lobe dysfunction, was slightly higher ($p = 0.06$) in the LBD (4.3 ± 2.4) than in the AD (3.5 ± 1.5) group.

Neuropathology and clinical symptoms of dementia with Lewy bodies

Mild to severe Alzheimer pathology was found in 90.3% of the clinical AD cases and in 81.3% of clinical LBD cases.

Frontal white matter pathology, defined as complete or incomplete white matter infarcts, traumatic white matter damage or unspecified white matter degeneration, was significantly ($p = 0.011$) more prevalent in the clinical LBD group (47.9%) compared to the clinical AD group (20.5%).

The degree of substantia nigra degeneration, arbitrarily graded as none (median 2), mild (median 3), moderate (median 3) or severe (median 4), was highly correlated ($p < 0.01$, $r = 0.315$).

with the number of extrapyramidal symptoms ($N = 128$).

LBs were identified mainly in subcortical regions. The implication of these findings is further analysed in an ongoing neuropathological study of these cases using additional immunostaining techniques with focus on identification of LBs.

Grading of dementia with the Berger scale and Katz ADL index

The progression of dementia as measured by Berger and Katz indices is presented in Table 6. The first and last measurements in both clinical groups were performed approximately between the third and fifth year of dementia. However, the first measurement was 1 year earlier in LBD than in AD. Thus, the deterioration was already more marked in the LBD group (Katz E–G, Berger IV–VI) at the first measurement (38.9% vs 18.2%, $p = 0.036$, Fischer's exact test).

At the last measurement, 63.6% of AD and 83.3% of LBD had deteriorated to the most severe level, indicating a great need for care. Urinary incontinence, which is of critical importance in this grading, started earlier ($p = 0.059$) in the clinical LBD (at 73.2 ± 10.2 years) compared to the clinical AD group (at $78.2\% \pm 8.5$ years). Twenty-five individuals in total were measured on three occasions. A fluctuating score was noted over time in either Katz, Berger or both rating scales in 7/17 in the clinical LBD and 0/8 in the clinical AD group ($p = 0.04$, Fischer's exact test).

DISCUSSION

The clinical consensus criteria for DLB developed by McKeith *et al.* (1996) were based on neuropathologically verified cases. When we used these consensus criteria for clinical DLB it was possible on clinical grounds to identify a group of LBD patients *retrospectively* in a dementia project *with a prospective design*. The prevalence of LBD thus defined in this group, 24.7%, was very similar to earlier findings using different sets of clinical criteria for dementia associated with Lewy bodies, 24% (Ballard *et al.*, 1993) and 26% (Shergill *et al.*, 1994). Based on this, we have analysed the clinical features in this LBD group and compared them to other clinically diagnosed dementia groups, mainly AD.

It should be pointed out that the neuropathological analysis of our deceased cases is based on semi-serial coronal sectioning of the whole brain (Brun and Gustafson, 1993). The previous neuropathological diagnosis in the majority of cases, now diagnosed clinically as LBD, was AD with or without vascular brain lesions. Up to this point LBD was not diagnosed neuropathologically. The limited numbers of LBs observed were found almost exclusively in subcortical regions.

The prevalence of the LBD core symptoms (Tables 3 and 4) in our clinical LBD group was similar to results from other materials diagnosed neuropathologically. Fluctuations were seen in 85.4%, which is in agreement with earlier studies (Byrne *et al.*, 1989; Perry *et al.*, 1990). Visual hallucinations were abundant in 47.9%. Earlier

Table 6. Grading of dementia with the Berger scale and Katz ADL index

LBD ($N = 36$)					AD ($N = 33$)				
First measurement (%)					First measurement (%)				
Berger (3.4 yr)	Katz (2.8 yr)				Berger (4.4 yr)	Katz (3.9 yr)			
	A	B–D	E–G	Other		A	B–D	E–G	O
I–III	16.7	11.1	5.6	2.8	I–III	30.3	15.1	0	0
IV–VI	5.6	19.4	38.9	0	IV–VI	9.1	27.3	18.2	0
Last measurement (%)					Last measurement (%)				
Berger (5.2 yr)	Katz (5.2 yr)				Berger (5.7 yr)	Katz (5.6 yr)			
	A	B–D	E–G	Other		A	B–D	E–G	O
I–III	2.8	0	2.8	2.8	I–III	12.1	3.0	3.0	6.1
IV–VI	0	5.6	83.3	2.8	IV–VI	0	12.1	63.6	0

Note: Time of rating: mean years after onset of dementia in parentheses.

reported prevalence rates have been more variable, from 13.3% (Byrne *et al.*, 1989) to 80% (McKeith *et al.*, 1994), probably reflecting different selection criteria. There was particularly good agreement on prevalence of the individual EPS in our clinical material and Lennox meta-analysis of 75 post-mortem verified cases in 1992.

The majority of our patients diagnosed as LBD were recruited from antemortem clinical AD 43.8%, VaD 33.3% and mixed AD + VaD 10.4% (Table 2). It should be pointed out that the antemortem clinical diagnosis took into account the rCBF results.

It has been claimed that diagnostic difficulties are mainly caused by the use of different sets of clinical criteria for AD. Perry *et al.* (1997) found that 15–50% of the SDLT patients were misdiagnosed as having AD. This is probably not the case in our material, where all the patients were studied prospectively, with the diagnoses supported by rCBF findings, neuropsychological test results and diagnostic scoring, and the diagnoses were in agreement with the NINCDS ADRDA criteria for AD and DSM-III-R criteria for different types of dementia.

This study shows several significant differences as well as similarities between AD, LBD and VaD. These differences were not related to differences in age at the onset of dementia, dementia duration, gender, hereditary factors, previous morbidity or pharmacological treatment. The differences between LBD and AD diagnosed clinically were most pronounced in the core symptoms of DLB, a consequence of the selection criteria. However, no significant differences were found in any of the supportive features (see Appendix 1). The distinction between syncope and transient loss of consciousness as well as TIA without obvious neurological focal signs is not very clear, probably due to observers using a different vocabulary. Differentiation of fluctuations through loss of consciousness could be problematic, as the latter could be an extreme of fluctuation. This might weaken the validity of these supportive features.

The presence of EPS was common in all clinical dementia groups, especially in the vascular groups.

There was a tendency clinically to a 'frontal profile', with personality change, episodic confusions and vocally disruptive behaviour being more common in the clinical LBD group compared to the clinical AD group. A frontal profile has been discussed earlier in DLB in several aspects, such as frontal atrophy (Förstl *et al.*, 1993), frontal bursts

KEYPOINTS

- Clinical criteria for Alzheimer's disease, AD, dementia with Lewy bodies (LBD), vascular dementia (VaD) and frontotemporal dementia were applied for 200 deceased and neuropathologically examined patients in a prospective longitudinal study of dementia
- Prevalence of consensus clinical features in the clinically defined group of Lewy body dementia were in accordance with earlier neuropathologically defined dementia with Lewy bodies. In addition, the clinically defined LBD group exhibited marked vascular and frontal lobe features, both clinically and neuropathologically
- The clinical course of dementia expressed as abilities in daily living showed fluctuations and a faster deterioration in the Lewy body group compared to the Alzheimer group diagnosed clinically
- Further neuropathological data will be presented in a forthcoming paper

in EEG (Burkhardt *et al.*, 1988) and frontal deficiencies in neuropsychological testing (Hansen *et al.*, 1990).

Subcortical vascular dementia such as lacunar state and Binswanger's disease often have characteristics such as rapid or insidious onset, clinical fluctuations and a frontal-subcortical symptom pattern with bradykinesia, muscular rigidity, small stepped gait and memory disturbance, even if they do not always dominate (Wallin and Blennow, 1993). These are all symptoms shared with LBD. In this study, this was confirmed regarding fluctuations, bradykinesia, increased muscle tone, the prevalence of 'two or more EPS' and frontal features such as disinhibition, personality change and vocally disruptive behaviour. LBD and the clinical vascular dementia groups share all these symptoms. Confusional episodes were also observed in high percentages of the vascular dementias.

The separation into five clinical groups (LBD, AD, VaD, AD + VaD and FTD) was strongly supported by the scores of the differential diagnostic rating scales. When the clinical diagnostic rating scales were used, there were obvious differences in Hachinski score, indicating a possible vascular component in the clinical LBD compared

to the AD group. The significant differences remained ($p = 0.002$) even when Hachinski score was compensated for the item 'fluctuations'. The Hachinski score in our clinical LBD group (5.3 ± 2.6) was equal to what Perry *et al.* (1990) found (5.57 ± 2.20) in their 14 neuropathologically verified SDLT patients. This finding was not discussed further.

The diagnostic rating scales placed the clinical LBD group as basically AD but with vascular features and a certain frontal profile. This picture was supported neuropathologically by the consistent finding of AD and frontal white matter pathology in our clinical LBD group.

There were indications of higher proportions of a more disabling dementia in LBD compared to AD. Already at the first measurement after 2.8–3.4 years of dementia, 38.9% of the LBD group were classified as belonging to the most severe rating (Katz E–G and Berger IV–VI). The differences could not be explained by the duration of dementia, since the LBD group was evaluated even earlier (1 year) in dementia than the AD group. Urinary incontinence with onset at an earlier age, and a more pronounced frontal clinical pattern might contribute to the more severe dementia and could also indicate a frontal affection. The Katz and Berger instruments could in this study identify fluctuations in ADL capacity and degree of dementia in 41% of the LBD cases. It could therefore be suggested as one way of measuring the otherwise difficult concept of fluctuations. The high proportion of patients with the most severe degree of dementia (63.6% of AD and 83.3% of LBD) indicates the need for greater care. Furthermore, the last measurement was performed after 5.6–5.7 years of dementia and these patients have a mean dementia duration of 7.1–7.7 years, which means that they have to spend the remainder of their lives disabled, dependent and suffering. With regard to these clinical problems, an early recognition of the LBD symptom profile is important, since LBD patients might respond particularly well to cholinesterase inhibitors (Shea *et al.*, 1998).

CONCLUSIONS

The results of this study show that DLB could be identified retrospectively in our dementia population by applying the clinical consensus criteria of DLB. Clinically, our LBD group also exhibited behavioural disturbances of frontal type as well as

signs of vascular origin. Neuropathological examination revealed Alzheimer pathology, frontal subcortical vascular components and substantia nigra degeneration, which may offer an important explanation for the clinical picture of DLB. There is a need for further studies addressing possible vascular components and their significance.

As the clinical LBD group seems to have a more pronounced and earlier deterioration of dementia than the clinical AD, it is important to recognize the LBD symptomology because of the ameliorating effects of cholinesterase inhibitors. Another important factor is the choice of appropriate care, since there is such a rapid deterioration.

ACKNOWLEDGEMENTS

The Alzheimerfoundation, Sweden supported this study.

REFERENCES

- Ballard, C. G., Mohan, R. N. C. and Patel, A. *et al.* (1993) Idiopathic clouding of consciousness—do the patients have cortical Lewy body disease? *Int. J. Geriatr. Psychiat.* **8**, 571–576.
- Berger, E. Y. (1980) A system for rating the severity of senility. *J. Am. Geriatr. Assoc.* **38**, 234–236.
- Brun, A., Englund, E. and Gustafson, L. *et al.* (1994) Clinical and neuropathological criteria for frontotemporal dementia. *J. Neurol. Neurosurg. Psychiat.* **57**, 416–418.
- Brun, A. and Gustafson, L. (1993) The Lund Longitudinal Dementia Study: A 25-year perspective on neuropathology, differential diagnoses and treatment. In *Alzheimer's Disease: Advances in Clinical and Basic Research* (B. Corain, M. Nicolini, B. Winblad, H. Wisniewski and P. Zatta, Eds). Wiley, Chichester, 4–18.
- Burkhardt, C. R., Filley, C. M., Kleinschmidt-DeMasters, B. K., De la Monte, S., Norenberg, M. D. and Schneck, S. A. (1988) Diffuse Lewy body disease and progressive dementia. *Neurology* **38**, 1520–1528.
- Byrne, E. J., Lennox, G., Lowe, J. and Godwin-Austen, R. B. (1989) Diffuse Lewy body disease: Clinical features in 15 cases. *J. Neurol. Neurosurg. Psychiat.* **52**, 709–717.
- Byrne, E. J., Lennox, G. G., Godwin-Austen, R. B., Jefferson, D., Lowe, J., Mayer RJ, Landon, M. and Doherty, R. J. (1991) Dementia associated with cortical Lewy bodies: Proposed clinical diagnostic criteria. *Dementia* **2**, 283–284.

- Dickson, D. W., Crystal, H., Mattiace, L. A., Kress, Y., Schwagerl, A., Ksiezak-Reding, H., Davies, P. and Yen, S.-H. (1989) Diffuse Lewy body disease: Light and electron microscopic immunocytochemistry of senile plaques. *Acta Neuropathol.* **78**, 572–584.
- Förstl, H., Burns, A., Luthert, P., Cairns, N. and Levy, R. (1993) The Lewy body variant of Alzheimer's disease: Clinical and pathological findings. *Brit. J. Psychiat.* **162**, 385–392.
- Gustafson, L. and Hagberg, B. (1975) Dementia with onset in the presenile period. *Acta Psychiatr. Scand.* Suppl. 257.
- Gustafson, L. and Nilsson, L. (1982) Differential diagnosis of presenile dementia on clinical grounds. *Acta Psychiatr. Scand.* **65**, 194–209.
- Hachinski, V. C., Iliff, L. D., Zilkha, E., Du Boulay, G. H., Mcallister, V. C., Marshall, J., Russell, R. W. and Symon, L. (1975) Cerebral blood flow in dementia. *Arch. Neurol.* **32**, 632–637.
- Hallberg, I. R., Edberg, A.-K., Nordmark, Å and Johnsson, K. (1993) Daytime vocal activity in institutionalized severely demented patients identified as vocally disruptive by nurses. *Int. J. Geriatr. Psychiat.* **8**, 155–164.
- Hansen, L. A., Salmon, D., Galasko, D., Masliah, E., Katzman, R. and De Teresa, R. (1990) The Lewy body variant of Alzheimer's disease: A clinical and pathological entity. *Neurology* **40**, 1–8.
- Holmes, C., Cairns, N., Lantos, P. and Mann, A. (1998) Validity of current clinical criteria for Alzheimer's disease, vascular dementia and dementia with Lewy bodies. *Brit. J. Psychiat.* **174**, 45–50.
- Katz, S., Ford, A. B. and Moscovitz, R. W. (1963) Studies of illness in the aged. The index of ADL: A standardised measure of biological and psychosocial function. *J. Am. Med. Assoc.* **185**, 914–919.
- Lennox, G. (1992) Lewy body dementia. In *Baillière's Clinical Neurology—Unusual Dementias* (C. Byres, Ed.). Baillière Tindall, London, 661–662.
- Lennox, G., Lowe, J., Landon, M., Byrne, F. J., Mayer, R. J., Godwin-Austen, R. B. (1989) Diffuse Lewy body disease: Correlative neuropathology using anti-ubiquitin immunocytochemistry. *J. Neurol. Neurosurg. Psychiatr.* **52**, 1236–1247.
- McKeith, I. G., Perry, R. H., Fairbairn, A. F., Jabeen, S. and Perry, E. K. (1992) Operational criteria for senile dementia of Lewy body type (SDLT). *Psychol. Med.* **22**, 911–922.
- McKeith, I. G., Fairbairn, A. F., Bothwell, R. A., Moore, P. B., Ferrier, I. N., Thompson, P. and Perry, R. H. (1994) An evaluation of the predictive validity and interrater reliability of clinical diagnostic criteria for SDLT. *Neurology* **44**, 872–877.
- McKeith, I. G., Galasko, D., Kosaka, K., Perry, E. K., Dickson, D. W., Hansen, L. A., Salmon, D. P., Lowe, J., Mirra, S. S., Byrne, E. J., Lennox, G., Quinn, N. P., Edwardson, J. A., Ince, P. G. and Bergeron, C., Burns, A., Miller, B. L., Lovestone, S., Collerton, D., Jansen, E. N. H., Ballard, D., de Vos, R. A. J., Wilcock, G. K., Jellinger, K. A., and Perry, R. H., (1996) Consensus guidelines for the clinical and pathological diagnosis of dementia with Lewy bodies (DLB). *Neurology* **47**, 113–124.
- McKhann, G., Drachman, D., Folstein, M., Karzman, R., Pride, D. and Stadlan, E. (1984) Clinical diagnosis of Alzheimer's disease: Report from the NINCDS-ADRDA Work Group under the auspices of Department of Health and Human Services Task Force on Alzheimer's Disease. *Neurology* **34**, 939–943.
- Mega, M. S., Masterman, D. L., Benson, D. F., Vinters, H. V., Tomiyasu, U., Craig, A. H., Foti, D. J., Kanfer, D., Scharre, D. W., Fairbanks, L. and Cummings, J. L. (1996) Dementia with Lewy bodies; reliability and validity of clinical and pathological criteria. *Neurology* **47**, 1403–1409.
- Moroney, J. T., Bagiella, E., Desmond, D. W., Hachinski, V. C., Mölsä, P. K., Gustafson, L., Brun, A., Fischer, P., Erkinjuntti, T., Rosen, W., Paik, M. C. and Tatemichi, T. K. (1997) Meta-analysis of the Hachinski ischemic score in pathologically verified dementias. *Neurology* **49**, 1096–1105.
- Papka, M., Rubio, A., Schiffer, R. B. and Cox, C. (1998) Lewy body disease: Can we diagnose it? *J. Neuropsych. Clin. Neurosci.* **10**(4), 405–412.
- Perry, R., McKeith, I. G. and Perry, E. (1997) Lewy body dementia—clinical, pathological and neurochemical interconnections. *J. Neural Transm. Suppl.* **51**, 95–109.
- Perry, R. H., Irving, D., Blessed, G., Perry, E. K. and Fairbairn, A. F. (1990) Senile dementia of Lewy body type. A clinically and neuropathologically distinct type of Lewy body dementia in the elderly. *J. Neurol. Sci.* **95**, 119–139.
- Risberg, J. and Gustafson, L. (1983) 133xe cerebral blood flow in dementia and in neuropsychiatry research. In *Functional Radionuclide Imaging of the Brain* (C. Magistretti, Ed.). Raven Press, New York, 151–159.
- Shea, C., MacKnight, C. and Rockwood, K. (1998) Donepezil for treatment of dementia with Lewy bodies: A case series of nine patients. *Int. Psychogeriatr.* **10**(3), 229–238.
- Shergill, S., Mullan, E., D'At, P. and Katona, C. (1994) What is the clinical prevalence of Lewy body dementia? *Int. J. Psychogeriatr.* **9**, 907–912.
- Wallin, A. and Blennow, K. (1993) Heterogeneity of vascular dementia: Mechanisms and subgroups. *J. Geriatr. Psychiatr. Neurol.* **6**, 177–188.

APPENDIX 1

Consensus criteria for the clinical diagnosis of dementia with Lewy bodies (DLB)

1. The central feature required for a diagnosis of DLB is progressive cognitive decline of sufficient magnitude to interfere with normal social or occupational function. Prominent or persistent memory impairment may not necessarily occur in the early stages, but is usually evident with progression. Deficits on tests of attention and of frontosubcortical skills and visuospatial ability may be especially prominent.
2. Two of the following core features are *essential* for a diagnosis of probable DLB; *one* is *essential* for possible DLB:
 - (a) Fluctuating cognition with pronounced variations in attention and alertness
 - (b) Recurrent visual hallucinations which are typically well formed and detailed
 - (c) Spontaneous motor features of Parkinsonism
3. Features *supportive* for the diagnosis:
 - (a) Repeated falls
 - (b) Syncope
 - (c) Transient loss of consciousness
 - (d) Neuroleptic sensitivity
 - (e) Systematized delusions
 - (f) Hallucinations in other modalities
4. A diagnosis of DLB is *less likely* in the presence of:
 - (a) Stroke disease evident as focal neurological signs or on brain imaging
 - (b) Evidence on physical examination and investigation of any clinical illness, or other brain disorder, sufficient to account for the clinical picture

APPENDIX 2

The Katz index of ADL

- A = Independent in feeding, continence, transferring, going to the toilet, dressing and bathing
- B = Independent in all but one of these functions
- C = Independent in all but bathing and one additional function
- D = Independent in all but bathing, dressing and one additional function
- E = Independent in all but bathing, dressing, going to the toilet and one additional function
- F = Independent in all but bathing, dressing, going to the toilet, transferring and one additional function
- G = Dependent in all six functions
- Other = Dependent in at least two functions, but not classifiable as C, D, E or F

The Berger scale—a system for rating the severity of dementia

Class I: Can function in any surroundings, but forgetfulness is often disruptive of daily activities

Class II: Can function without direction only in familiar surroundings

Class III: Needs direction to function even in familiar surroundings but can respond appropriately to instruction

Class IV: Needs assistance to function, cannot respond to direction only

Class V: Remains ambulatory, needs assistance to function, but cannot communicate verbally in a meaningful fashion

Class VI: Bedridden or confined to chair and responds only to tactile stimuli

Blood pressure and drug treatment in clinically diagnosed Lewy body dementia and Alzheimer's disease

Elisabet Londos *, Ulla Passant, Lars Gustafson

Department of Psychogeriatrics, Lund University Hospital, S-221 85 Lund, Sweden

Received 28 August 1999; received in revised form 18 October 1999; accepted 20 October 1999

Abstract

The aim of the study was to investigate arterial blood pressure (BP) and the use of pharmacological treatment in patients with Lewy body dementia (cLBD) and Alzheimer's disease (cAD) diagnosed on clinical grounds. BP and pharmacological treatment was analysed based on the medical records of 200 deceased dementia patients. Forty-eight cases with LBD and 45 AD were diagnosed using clinical criteria. The patients, who died between 1985 and 1994, were part of a prospective longitudinal dementia project. The majority of the cases were examined and cared for at the psychogeriatric and psychiatric departments. BP levels were very similar at an early stage of dementia but there was a marked decrease during the course of dementia in cAD and cLBD. The cLBD cases became hypotensive during the course of dementia to a significantly greater extent and also had a more pronounced drop in systolic BP at orthostatic testing compared to the cAD cases. cLBD and cAD were prescribed neuroleptics and medication potentially associated with hypotension to the same extent. The total number of these drugs was however higher in cLBD than in cAD. Antiparkinsonian treatment was, as expected, more common in cLBD compared to cAD. The findings suggest that insufficient BP regulation and drug treatment could affect the clinical picture of dementia, particularly in cLBD patients. © 2000 Elsevier Science Ireland Ltd. All rights reserved.

Keywords: Alzheimer's disease; Arterial blood pressure; Lewy body dementia; Orthostatic blood pressure; Pharmacological treatment

* Corresponding author. Tel.: +46-4617-7463; fax: +46-4617-7457.

E-mail address: elisabet.londos@psykiatr.lu.se (E. Londos)

1. Introduction

Dementia with Lewy bodies (DLB) is considered to be the second most common dementia in the elderly after Alzheimer's disease (AD). It represents about 20% of all organic dementias in clinical settings (Lennox et al., 1989; Hansen et al., 1990; Perry et al., 1990; Shergill et al., 1994). It was initially recognised neuropathologically and later also with clinical criteria (McKeith et al., 1996). The consensus criteria for clinical diagnosis of DLB comprise a dementing disorder with clinical fluctuations, extrapyramidal symptoms and visual hallucinations. Supporting features are frequent falls, loss of consciousness, syncope, neuroleptic sensitivity, auditory hallucinations and delusions. Many of these characteristics feature in other dementias especially vascular dementias.

A previous study (Londos et al., 1999) analyzed the medical records of 200 deceased dementia cases, all neuropathologically examined. Forty-eight cases fulfilled the clinical consensus criteria of DLB and 45 the clinical diagnosis of AD. The neuropathological investigation showed Alzheimer pathology in more than 80% of both clinical groups. The clinically defined LBD group (cLBD) had significantly more prevalent frontal white matter pathology and more severe degeneration of the substantia nigra compared to the clinical AD group (cAD). The cLBD cases showed more vascular signs expressed as a significantly higher Hachinski ischemic score (5.3 ± 2.8 versus 2.9 ± 1.8) (Hachinski et al., 1975).

Blood pressure (BP) abnormalities, both arterial hyper- and hypotension, as well as postural hypotension, have been reported in dementia both in clinical and neuropathological materials (Brun and Englund, 1985, 1986; Sulkava and Erkinjuntti, 1987; Erkinjuntti and Hachinski, 1993; Wallin and Blennow, 1993; Passant et al., 1997). Neuropathological studies by Englund and co-workers have demonstrated that 50–60% of patients with AD also have selective incomplete white matter infarcts (SIWI) of a presumed ischemic aetiology (Englund et al., 1989). Hypotension and orthostatic hypotension (OH) were significantly more prevalent in AD + SIWI cases compared to the AD without SIWI. The AD patients with SIWI also showed more symptoms such as hallucinations, fluctuations, confusion and syncope compared to the AD without SIWI. This symptom constellation is in part similar the clinical picture of DLB.

Hypotension and OH have previously also been recognised in about 40–50% of DLB cases and in a mixed DLB and AD population (Kuzuhara et al., 1996; Ballard et al., 1999).

Arterial hypotension may give rise to symptoms such as dizziness, loss of consciousness and syncope (Bradshaw and Edwards, 1986) as well as unsteady gait, falls and fractures (Rubenstein and Robbins, 1984; Tinetti et al., 1986). Several commonly used drugs such as antihypertensives, diuretics, antidepressants, antianginal, neuroleptics and antiparkinson agents are known to yield hypotension and OH as a primary therapeutic effect or as an adverse effect (Schoenberger, 1991; McCarthy and Cameron, 1992; Mets, 1995).

The aim of this study was to describe and compare cLBD and cAD with respect to

- arterial BP variation throughout the clinical course of dementia,
- the orthostatic BP reaction and
- pharmacological treatment.

2. Material and methods

In the present study, medical records from 200 deceased patients were studied. The patients were all part of a prospective longitudinal dementia project (Gustafson and Hagberg, 1975; Brun and Gustafson, 1993). In this project most patients had undergone an extensive investigation with neuropsychiatric evaluation including neurological status examination, neuropsychological testing, measurements of regional cerebral blood flow (rCBF), EEG, neuroradiology, laboratory testing and finally neuropathological post mortem examination. The aim of this project was to study the course of dementia and the clinico-pathological correlates. The present patient sample represents consecutive cases of clinically and neuropathologically investigated patients with dementia who died between 1985 and 1994. The clinical criteria for probable DLB (McKeith et al., 1996) and AD (DSM IV and NINCDS-ADRDA; McKhann et al., 1984) were applied retrospectively. The clinical diagnoses were made without any previous knowledge of the neuropathological results (EL).

The majority of cases (> 90%) were examined and/or cared for at psychogeriatric and psychiatric departments at Lund University hospital.

The prevalence of any pharmacological treatment during the course of dementia was registered dichotomously as present or not. In this study, it was not always possible to calculate the exact treatment time of each drug. Drugs which were used for less than a week were not included in the analysis.

Systolic (SBP) and diastolic BP (DBP) values were chosen from assessments made as early as possible in the course of dementia and at a late stage in dementia (not the last month of life). The mean arterial BP (MABP) was calculated at corresponding timepoints.

The orthostatic test was performed with repeated measurements in the standing position since a considerable amount of dementia patients at orthostatic testing have their BP decrease after 3–5 min or later during standing (Passant et al., 1996). At orthostatic testing, the lowest systolic and diastolic values were measured. At the same time, the difference between supine systolic BP and lowest systolic value in standing position, named the maximal systolic difference, was calculated.

Orthostatic hypotension (OH) was defined as a systolic drop of 20 mmHg or more from supine to standing position (Mathias and Bannister, 1992). Hypotension was considered present when the systolic BP was 120 mmHg or below.

2.1. Statistical analysis

All statistical work was conducted in SPSS. McNemars test was used to compare

the differences in the number of cases with BP ≤ 120 or > 160 early and late in dementia in the cAD and cLBD groups in Table 2. For the comparison of proportions between the clinical cAD and cLBD groups in Table 3 the Fisher's exact test and χ^2 test (with continuity correction) was applied. The Mann Whitney U test was used for the comparison of number of medications in clinical cAD and cLBD groups in Table 4, while the Students *t*-test was applied to compare the differences in maximal systolic drop during orthostatic testing between the cAD and cLBD groups. In order to compare the BP levels between the cAD and the cLBD groups during the course of dementia the paired *t*-test was used (Fig. 1).

3. Results

Two hundred patients were included in the study. Seven patients were excluded since their medical records were not available and in five additional cases the clinical information was considered insufficient for the present purpose. Clinical information was obtained from the remaining 188 medical records. Forty-eight

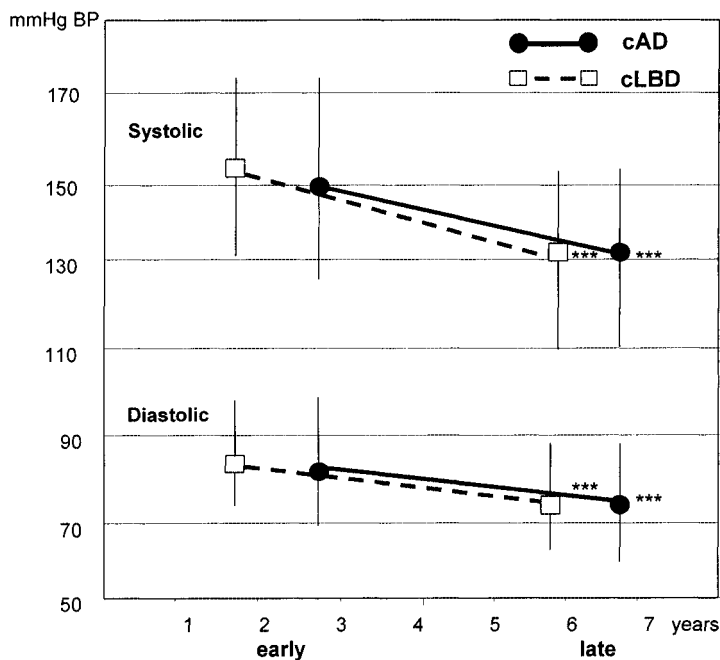


Fig. 1. Mean blood pressure (mmHg) early and late in Alzheimer's disease and Lewy body dementia diagnosed clinically.

the differences in the number of cases with BP ≤ 120 or > 160 early and late in dementia in the cAD and cLBD groups in Table 2. For the comparison of proportions between the clinical cAD and cLBD groups in Table 3 the Fisher's exact test and χ^2 test (with continuity correction) was applied. The Mann Whitney U test was used for the comparison of number of medications in clinical cAD and cLBD groups in Table 4, while the Students *t*-test was applied to compare the differences in maximal systolic drop during orthostatic testing between the cAD and cLBD groups. In order to compare the BP levels between the cAD and the cLBD groups during the course of dementia the paired *t*-test was used (Fig. 1).

3. Results

Two hundred patients were included in the study. Seven patients were excluded since their medical records were not available and in five additional cases the clinical information was considered insufficient for the present purpose. Clinical information was obtained from the remaining 188 medical records. Forty-eight

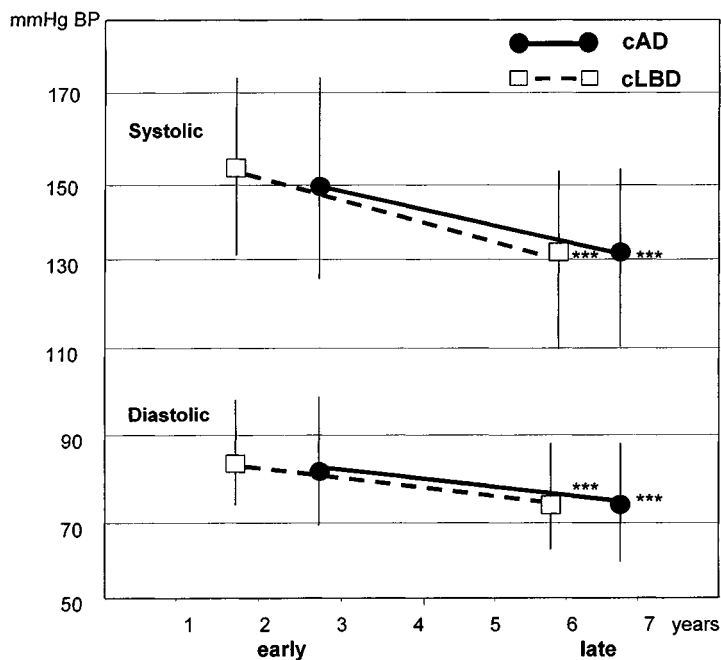


Fig. 1. Mean blood pressure (mmHg) early and late in Alzheimer's disease and Lewy body dementia diagnosed clinically.

There was a marked variation in BP levels within each clinical group (Table 2). Hypertension (SBP > 160) was significantly ($P = 0.001$) more prevalent at an early stage of dementia in both cLBD and cAD compared to late in dementia. A significantly ($P = 0.001$) larger number of cLBD patients thus exhibited hypotension (SBP ≤ 120 mmHg) late in dementia, compared to the cAD patients.

The average maximal drop in systolic BP at orthostatic testing tended ($P = 0.053$) to be more marked in the cLBD, 32.4 ± 12.6 mmHg, median 30 (range 15–60, $n = 17$) than in the cAD, 24.2 ± 11.5 mmHg, median 20 (range 0–50, $n = 18$). The orthostatic tests were performed after a median interval of 2.5 years (range 0–8) of dementia in cLBD and 2 years (range 3–12) in cAD.

Treatment with antiparkinsonian agents was, not surprisingly, significantly ($P = 0.006$) more prevalent in cLBD (31.3%) than in cAD (6.7%). There was however no major difference in the prescription of other drugs (antipsychotics, antidepressants, sedatives — mainly benzodiazepines, hypnotics, anticonvulsants, antihypertensives, antianginal agents and steroids) between the two clinical groups (Table 3).

The cLBD group had been treated with a significantly ($P = 0.007$) larger number of different neuroleptics during the course of dementia than the patients in the cAD group (2.73 vs. 2.0). The number of drugs that might have contributed to hypotension (antihypertensives, diuretics, antiparkinsonian agents and sedatives) was also significantly ($P = 0.015$) higher in the cLBD (1.4) compared to the cAD (0.9) (Table 4).

Table 3

Pharmacological treatment during dementia in Alzheimer's disease (cAD) and Lewy body dementia (cLBD) diagnosed clinically (in %)^a

	cAD <i>n</i> = 45	cLBD <i>n</i> = 48	<i>P</i>
Antiparkinsonian agents	6.7	31.3	0.006
Haloperidol	68.9	81.3	0.127
Thioridazine	35.6	50.0	0.209
Zuclopenthixol	24.4	45.8	0.053
Melperone	35.6	29.2	0.658
Levopromazine	8.9	16.7	0.358
Pimozide	4.4	12.5	0.269
Propiomazin	13.3	12.5	1.000
Clorpromazin	8.9	8.3	1.000
SSRI	0	6.2	0.243
Tricyclic antidepressants	26.7	31.2	0.655
Benzodiazepine	33.3	37.5	0.829
Benzodiazepine–night	46.7	41.7	0.679
Antiepileptics	11.1	14.6	0.760
Diuretics	28.6	39.6	0.386
Other antihypertensives	6.7	8.3	1.000
Digitalis	20.0	20.8	1.000
Steroids	2.2	2.1	1.00

^a Statistical analysis: Fisher's exact test and χ^2 .

Table 4

Mean number of neuroleptics and medication with potential hypotensive side effects in clinically defined Lewy body dementia (cLBD) and Alzheimer's disease (cAD)^a

Number of	cAD	cLBD	<i>P</i>
<i>N</i>	45	48	
Neuroleptics	2.0	2.73	0.007
Potentially hypotensive drugs	1.9	2.3	0.024
Potentially hypotensive drugs exl antipsychotics	0.9	1.4	0.015

^a Statistical analysis: Mann Whitney U-test.

There was a trend ($P = 0.057$) towards a higher prevalence of treatment with any kind of neuroleptic medication in cLBD (47.9%) before the onset of parkinsonism compared to cAD (26.7%).

The dosages of neuroleptics did not differ in the clinical groups. 84.9% of cAD and 73.8% of cLBD were treated with low doses according to established Swedish treatment recommendations. Only a few patients, one in each group, were treated with a dosage of neuroleptics within the higher recommended range.

4. Discussion

The patients in this study were part of a longitudinal dementia project. A vast majority of the patients were not only examined and diagnosed but also treated at the psychiatric or psychogeriatric wards, often with long observational times (median 6 months, range 1–107). DLB was not an antemortem clinical diagnosis in use at the time of the clinical evaluations in any of these cases and therefore the doctors were not biased to this diagnosis when describing the symptoms.

The patients in our study fulfilling the clinical criteria of DLB and AD did not differ in demographic data and prevalence of DLB symptoms from populations in other studies (Byrne et al., 1989; Perry et al., 1990; Lennox, 1992; McKeith et al., 1994) based on post mortem verified cases.

The average SBP and DBP, early in the course of dementia (Fig. 1) were similar and within normal range in both clinical groups. One third of our cAD and cLBD cases were hypertensive (> 160 mmHg) at an early stage of dementia (Table 2) and an additional one cAD patient and five cLBD patients were previously diagnosed as hypertensive although there was no information on BP values. There are few longitudinal reports on BP in degenerative dementia with post mortem confirmation. Previously increased BP may increase the risk for both AD and vascular dementia as shown by Skoog et al., 1996 in a clinical longitudinal study. Some studies have shown lower SBP and DBP levels in AD than in controls (Bucht et al., 1984; Elmståhl et al., 1992). The measurements of BP in these studies were, however, performed later (after 3.2 ± 1.0 and 7.2 ± 3.6 years) in the course of dementia than the early measurements in our study. There are few if any longitudinal studies comparing BP in AD and DLB. It was therefore interesting that SBP

was within the normal range at an early stage of dementia and decreased significantly at a late stage of dementia in both clinical groups. The development of a hypotensive profile late in dementia was more marked in cLBD than in cAD. The increase of individuals with hypotension (SBP < 120 mmHg) from 3 to 18 individuals in the cLBD group was significantly greater than in the cAD group where the corresponding prevalence were 8 early and 11 late in dementia (Table 2). The decrease in BP was independent of age since there were no differences in SBP levels between subjects younger or older than 75 years of age late in dementia. In contrast, several large epidemiological studies have shown that arterial BP in the general population consistently rises with age up to about the age of 75 and thereafter decreases (Landahl et al., 1986; Bots et al., 1991). In AD, BP has been shown to decline during the course of dementia (Burke et al., 1994; Guo et al., 1996; Passant et al., 1996; Hogan et al., 1997). It should be noted that this tendency is also reported in post-mortem verified vascular dementia of Binswanger type (Fredriksson et al., 1992) and multi-infarct dementia (Gustafson et al., 1999). Thus the hypotensive profile in our cLBD patients, largely independent of age, indicates a connection with the dementing disease.

Orthostatic BP tests were performed in 17 cAD and 18 cLBD cases in our study. The missing cases in each clinical group did not differ from the examined cases concerning arterial BP, age or medication. Among those who had gone through the orthostatic test male patients were, however, significantly more prevalent in the cLBD group compared with those who had not. The cases investigated were, however, considered to be representative of the two diagnostic groups, in all aspects except for the described gender difference.

Low BP and OH, which are common in organic dementia of all types (Passant et al., 1997) are suggested as an etiologic or as a complicating factor in dementia, particularly of the AD type (Englund et al., 1989; Guo et al., 1996). Previous hypertension that develops into hypotension, as well as other types of cardiac and vascular insufficiencies, have been suggested as contributing factors in dementia through the development of SIWIs (Englund et al., 1989; Skoog et al., 1996; Englund, 1999). It is suggested that episodes of hypoperfusion of a brain area due to BP falls, usually in combination with small vessel stenosis, results in complete and mainly incomplete white matter infarctions (Brun and Englund, 1986), particularly prevalent in the frontal lobes (Englund et al., 1989). It was therefore especially interesting that a consistent neuropathological finding in our cLBD group was AD pathology combined with frontal white matter pathology, mainly of the SIWI type. White matter pathology was also found in the cAD group but the frontal location was the predominant feature of the cLBD cases. Accounting neuropathological findings will be presented in a forthcoming paper after renewed staining techniques have been applied to the material to assess more specifically the prevalence of Lewy bodies.

The more pronounced orthostatic BP reaction in the cLBD groups could place this group in the same clinico-pathological spectrum as Parkinson's disease where OH has been proposed to be highly prevalent (58%) (Senard et al., 1997). Thirty-eight percent of cLBD and 40% of cAD had OH in our material (Londos et al., 1999).

In a previous study we showed that 83% of the cLBD and 64% of the cAD patients late in the course of dementia (5 ± 3 years after clinical onset) had a poor ability in ADL capacities, including mobility (Londos et al., 1999). The decreased activity may further increase the orthostatic BP reactions (Mets, 1995).

The regulation of the cerebrovascular system in dementia is a complex interplay between metabolic, chemical and neurogenic factors with the involvement of several neurotransmitters. The physiological basis of BP regulation involves both parasympathetic and sympathetic autonomic activity via the central cholinergic system (Ewing et al., 1980). It is a well-established fact that cerebral blood vessels are endowed with acetylcholinesterase positive fibers (Edvinson, 1993). A speculative biochemical correlate to the insufficient BP regulation in cLBD in this study could be a hypothetical cholinergic deficiency. It has been suggested that patients with impaired cholinergic function have a greater postural drop on standing and may also be the patients who will respond to cholinergic therapy (Eagger and Harvey, 1995). There is strong evidence of a cerebral cholinergic defect in AD (Bowen et al., 1976) and there may be even more pronounced defects in DLB (Perry et al., 1994). DLB patients have also been reported to respond particularly well to cholinesterase inhibitors (Shea et al., 1998). The importance of the dopaminergic system has been more emphasised in relation to neuropharmacological issues than to cerebrovascular physiology. However, a recent study (Faucheux et al., 1999) found that blood vessels in the mesencephalon change in patients with Parkinson's disease and the authors suggested that modifications in the microenvironment of dopaminergic neurones may be important in the pathogenesis of brain diseases.

The larger number of neuroleptics prescribed per person in the cLBD group compared to the cAD group is probably due to a more severe state of illness and more psychotic symptoms in this group. It could also be a result of a different sensitivity to neuroleptics in this group, and therefore more changes of medications. The trend towards a higher frequency of 'previous treatment with neuroleptics before onset of EPS' in the cLBD group could lead to the interpretation that the medication per se induced the EPS. The cLBD patients were also treated with a significantly higher number of medications possibly associated with hypotension (antihypertensives, diuretics, antiparkinsonian agents and sedatives).

In summary, this study showed that BP levels decreased significantly during the symptomatic phase of degenerative dementia in both cLBD and cAD although with a more marked hypotensive profile late in dementia in cLBD. The orthostatic reaction was also more pronounced in cLBD compared to cAD. The cLBD was treated with a higher number of antipsychotics and other drugs associated with hypotension compared to the cAD, which may contribute to the unstable BP reaction. Hypotension and OH could also be due to the brain dysfunction per se. The analysis of BP and medication in relation to symptoms is however difficult since the clinical profile of DLB and side effects of medications are similar.

A clinical implication that could be drawn from this study is the importance of repeated BP measurements, in a supine as well as a standing position, and caution with polypharmacy in the elderly population, in particular in patients with clinical Lewy body dementia.

Acknowledgements

This study was supported by the Alzheimer foundation, Sweden, the Sjöbring foundation and the Swedish Medical Research Council, project no. 3950.

References

- Ballard, C.G., Shaw, F., Lowery, K., McKeith, I., Kenny, R., 1999. The prevalence, assessment and associations of falls in dementia with Lewy bodies and Alzheimer's disease. *Dement. Geriatr. Cogn. Disord.* 10, 97–103.
- Bots, M., Grobbee, E., Hofman, A., 1991. High blood pressure in the elderly. *Epidemiol. Rev.* 13, 294–314.
- Bowen, D.M., Smith, C.B., White, P., Davison, A.N., 1976. Neurotransmitter-related enzymes and indices of hypoxia in senile dementia and other abiotrophies. *Brain* 99, 459–496.
- Bradshaw, M.J., Edwards, R.T.M., 1986. Postural hypotension—pathophysiology and management. *Q. J. Med.* 231, 643–657.
- Brun, A., Englund, E., 1985. White matter changes in Alzheimer's presenile and senile dementia. In: Gottfries, C.G. (Ed.), *Normal Aging, Alzheimer's disease and Senile Dementia*. Editions de l'Université de Bruxelles, Bruxelles, pp. 47–50.
- Brun, A., Englund, E., 1986. A white matter disorder in dementia of the Alzheimer type: a pathoanatomical study. *Ann. Neurol.* 19, 253–262.
- Brun, A., Gustafson, L., 1993. The longitudinal dementia study: a 25-year perspective on neuropathology, differential diagnoses and treatment. In: Corain, B., Iqbal, K., Nicolini, M., Winblad, B., Wiesniewski, H., Zatta, P. (Eds.), *Alzheimer's Disease Advances in Clinical and Basic Research*. Wiley, New York, pp. 3–18.
- Bucht, G., Adofsson, R., Winblad, B., 1984. Dementia of the Alzheimer type and multi-infarct dementia: a clinical description and diagnostic problems. *J. Am. Geriatr. Soc.* 32, 491–498.
- Burke, W.J., Coronado, P.G., Schmitt, C.A., Gillespie, K.M., Chung, H.D., 1994. Blood pressure regulation in Alzheimer's disease. *J. Auton. Nerv. Syst.* 48, 65–71.
- Byrne, E.J., Lennox, G., Lowe, J., Godwin-Austen, R.B., 1989. Diffuse Lewy body disease: clinical features in 15 cases. *J. Neurol. Neurosurg. Psychiatry* 52, 709–717.
- Eagger, S.A., Harvey, R.J., 1995. Clinical heterogeneity in dementia responders to cholinergic therapy. *Alzheimer Dis. Assoc. Disord.* 9 (Suppl. 2), 37–42.
- Edvinson, L., 1993. In: Edvinson, L., MacKenzie E.T., McCulloch, J. (Eds.), *Cerebral Blood Flow and Metabolism*, Raven Press, New York, pp. 231–252, 285–312.
- Elmståhl, S., Petersson, M., Lilja, B., Samuelsson, S.M., Rosén, I., Bjunö, L., 1992. Autonomic cardiovascular responses to tilting in patients with Alzheimer's disease and in healthy elderly women. *Age Ageing* 21, 301–307.
- Englund, E., Brun, A., Gustafson, L., 1989. A white matter disease in dementia of Alzheimer's type—clinical and neuropathological correlates. *Int. J. Geriatr. Psychiatry* 4, 87–102.
- Englund, E., 1999. Neuropathology of white matter disease: parenchymal changes. In: Pantoni, L., Inzitari, D., Wallin A. (Eds.), *Clinical and Pathophysiological Aspects of White Matter Disease Related to Cognitive Decline and Vascular Dementia*, ICG Publications, Dordrecht, The Netherlands, in press.
- Erkinjuntti, T., Hachinski, V.C., 1993. Rethinking vascular dementia. *Cerebrovasc. Disord.* 3, 3–23.
- Ewing, D.J., Hume, L., Campbell, I.W., Murray, A., 1980. Autonomic mechanisms in the initial heart rate response to standing. *J. Appl. Physiol.* 49, 809–814.
- Faucheux, B.A., Bonnet, A.-M., Agid, Y., Hirsch, E.C., 1999. Blood vessels change in the mesencephalon of patients with Parkinson's disease. *Lancet* 353, 981–982.
- Fredriksson, K., Brun, A., Gustafson, L., 1992. Pure subcortical arteriosclerotic encephalopathy (Binswanger's disease): a clinicopathologic study. *Cerebrovasc. Disord.* 2, 82–86.

- Guo, Z., Viitanen, M., Fratiglioni, L., Winblad, B., 1996. Low blood pressure and dementia in elderly people: the Kungsholmen project. *Br. Med. J.* 312, 805–808.
- Gustafson, L., Hagberg, B., 1975. Dementia with onset in the presenile period. *Acta Psychiatr. Scand. Suppl.* 257, 1–77.
- Gustafson, L., Brun, A., Johansson, A., 1999. Vascular dementia clinical and classification aspects. Beijing Joint Meeting Plenary Lectures. *Chin. Ment. Health J. Institute of Mental Health Beijing Medical University*, pp. 73–87.
- Hachinski, V.C., Iliff, L.D., Zilkha, E., Du Boulay, G.H., Mcallister, V.C., Marshall, J., Russell, R.W., Symon, L., 1975. Cerebral blood flow in dementia. *Arch. Neurol.* 32, 632–637.
- Hansen, L., Salmon, P., Galasko, D., Masliah, E., Katzman, E., DeTeresa, R., 1990. The Lewy body variant of Alzheimer's disease: a clinical and pathological entity. *Neurology* 40, 1–8.
- Hogan, D.B., Ebly, E.M., Rockwood, K., 1997. Weight, blood pressure, osmolarity, and glucose levels across various stages of Alzheimer's disease and vascular dementia. *Dement. Geriatr. Cogn. Disord.* 8, 147–151.
- Kuzuhara, S., Yoshimura, M., Mizutani, T., Yamanouchi, H., 1996. Clinical features of diffuse Lewy body disease in the elderly: analysis of 12 cases. In: Perry, R., McKeith, I., Perry, E. (Eds.), *Dementia with Lewy Bodies — Clinical, Pathological and Treatment Issues*. Cambridge University Press, UK, pp. 153–160.
- Landahl, S., Bengtsson, C., Sigurdsson, J., Svanborg, A., Svärdsudd, K., 1986. Age-related changes in blood pressure. *Hypertension* 8, 1044–1049.
- Lennox, G., 1992. Lewy body dementia. In: Rossor, M.N. (Ed.), *Baillière's Clinical Neurology—Unusual Dementias*. Baillière Tindall, pp. 661–662.
- Lennox, G., Lowe, J., Landon, M., Byrne, E.J., Mayer, R.J., Godwin-Austen, R.B., 1989. Diffuse Lewy body disease: correlative neuropathology using anti-ubiquitin immunocytochemistry. *J. Neurol. Neurosurg. Psychiatry* 52, 1236–1247.
- Londos, E., Passant, U., Brun, A., Gustafson, L. 1999. Clinical Lewy body dementia and the impact of vascular components. *Int. J. Geriatr. Psychiatry*, in press.
- Mathias, C.J., Bannister, R., 1992. Investigation of autonomic disorders. In: Bannister, R., Mathias, C.J. (Eds.), *Autonomic failure. A Textbook of Clinical Disorders of the Autonomic Nervous System*, 3rd ed. Oxford University Press, Oxford, pp. 255–290.
- McCarthy, P., Cameron, Snyder, 1992. Orthostatic hypotension: a potential side effects of psychiatric medications. *J. Psychosoc. Nurs.* 30, 3–5.
- McKeith, I.G., Fairbairn, A.F., Bothwell, R.A., Moore, P.B., Ferrier, I.N., Thompson, P., Perry, R.H., 1994. An evaluation of the predictive validity and interrater reliability of clinical diagnostic criteria for SDLT. *Neurology* 44, 872–877.
- McKeith, I.G., Galasko, D., Kosaka, K., Perry, E.K., Dickson, D.W., Hansen, L.A., Salmon, D.P., Lowe, J., Mirra, S.S., Byrne, E.J., Lennox, G., Quinn, N.P., Edwardson Ince, P.G., Bergeron, C., Burns, A., Miller, B.L., Lovestone, S., Collerton, D., Jansen, E.N.H., Ballard, D., de Vos, R.A.I., Wilcock, G.K., Jellinger, K.A., Perry, R.H., 1996. Consensus guidelines for the clinical and pathological diagnosis of dementia with Lewy bodies (DLB). *Neurology* 47, 113–124.
- McKhann, G., Drachman, D., Folstein, M., Karzman, R., Pride, D., Stadlan, E., 1984. Clinical diagnosis of Alzheimer's disease: report from the NINCDS-ADRDA work group under the auspices of department of health and human service Task Force on Alzheimer's disease. *Neurology* 34, 939–943.
- Mets, T.F., 1995. Drug-induced orthostatic hypotension in older patients. *Drugs Aging* 6, 219–228.
- Passant, U., Warkentin, S., Karlsson, S., Nilsson, K., Edvinsson, L., Gustafson, L., 1996. Orthostatic hypotension in organic dementia: Relationship between blood pressure, cortical blood flow and symptoms. *Clin. Auton. Res.* 6, 29–36.
- Passant, U., Warkentin, S., Gustafson, L., 1997. Orthostatic hypotension and low blood pressure in organic dementia: a study of prevalence and related clinical characteristics. *Int. J. Geriatr. Psychiatry* 12, 395–403.
- Perry, R.H., Irving, D., Blessed, G., Perry, E.K., Fairbairn, A.F., 1990. Senile dementia of Lewy body type. A clinically and neuropathologically distinct type of Lewy body dementia in the elderly. *J. Neurol. Sci.* 95, 119–139.

- Perry, E.K., Haroutunian, V., Davis, K.L., Levy, R., Lantos, P., Egger, S., Honavar, M., Dean, A., Griffith, M., McKeith, I.G., Perry, R., 1994. Neocortical cholinergic activities differentiate Lewy body dementia from classical Alzheimer's disease. *Neuroreport* 5, 747–749.
- Rubenstein, L.Z., Robbins, A.S., 1984. Falls in the elderly a clinical approach. *Geriatrics* 39, 67–78.
- Schoenberger, J.A., 1991. Drug-induced orthostatic hypotension. *Drug Saf.* 6, 402–407.
- Senard, J.M., Rai, S., Lapeyre-Mestre, M., Brefel, C., Rascol, O., Rascol, A., Montastruc, J.L., 1997. Prevalence of orthostatic hypotension in Parkinson's disease. *J. Neurol. Neurosurg. Psychiatry* 63, 584–589.
- Shea, C., MacKnight, C., Rockwood, K., 1998. Donepezil for treatment of dementia with Lewy bodies: a case series of nine patients. *Int. Psychogeriatr.* 10, 229–238.
- Shergill, S., Mullan, E., D'Át, P., Katma, C., 1994. What is the clinical prevalence of Lewy body dementia? *Int. J. Geriatr. Psychiatry* 9, 907–912.
- Skoog, I., Lernfeldt, B., Landahl, S., Palmertz, B., Andreasson, L.-A., Nilsson, L., Persson, G., Odén, A., Svanborg, A., 1996. 15-Year longitudinal study of blood pressure and dementia. *Lancet* 347, 1141–1145.
- Sulkava, R., Erkinjuntti, T., 1987. Vascular dementia due to cardiac arrhythmias and systemic hypotension. *Acta Neurol. Scand.* 76, 123–128.
- Tinetti, M.E., Williams, T.F., Mayewski, R., 1986. Fallrisk index for elderly patients based on the number of chronic disabilities. *Am. J. Med.* 80, 429–434.
- Wallin, A., Blennow, K., 1993. Heterogeneity of vascular dementia. Mechanisms and subgroups. *J. Geriatr. Psychiatry* 6, 137–145.

III

Neuropathological correlates to clinically defined dementia with Lewy bodies

E. Londos^{1*}, U. Passant¹, L. Gustafson², A. Brun³

¹MD, Department of Psychogeriatrics, University hospital, Lund, Sweden

²Professor, Department of Psychogeriatrics, University hospital, Lund, Sweden

³Professor, Department of Pathology, University hospital, Lund, Sweden

Running title: Clinical DLB and neuropathology

Corresponding address:

Elisabet Londos, MD

Department of Psychogeriatrics

Lund University Hospital

SE-221 85 Lund, Sweden

Tel no: +46 – 46 17 74 63

Fax no: +46 – 46 – 17 74 57

E-mail: elisabet.londos@psykiatr.lu.se

Abstract

Objectives. To analyse the neuropathological changes behind clinically defined dementia with Lewy bodies (clinDLB) compared with clinically diagnosed Alzheimer's disease (clinAD).

Methods. The prevalence of neuropathological findings in 48 clinDLB and 45 clinAD cases was compared. 16 clinDLB and 10 clinAD cases were reassessed with α -synuclein staining for Lewy bodies (LB).

Results. Alzheimer pathology was found in 81% of the clinDLB and 93% of the clinAD cases. The clinDLB group had a higher prevalence of frontal white matter pathology, mostly of ischemic type, and a more severe degeneration of the substantia nigra compared to the clinAD group. In Hematoxylin/Eosin staining LBs were identified in 7 (15%) of the clinDLB and in 4 (9%) of the clinAD group. In α -synuclein staining 38% of the clinDLB and 40% of the clinAD cases exhibited LBs. The cases without LBs, in the clinDLB group, had AD pathology in combination with frontal white matter disease. Vascular pathology of significant degree was prevalent in almost 50 % of all the cases with verified LBs regardless of clinical diagnosis.

Conclusion. Consecutive dementia cases, fulfilling the clinical consensus criteria for DLB may exhibit combinations of neuropathological changes which in themselves can explain the clinical picture of DLB even when LBs are absent.

Key words: Lewy body dementia, Alzheimer pathology, white matter disease, Alzheimer's disease, substantia nigra, vascular pathology, neuropathology

Key points:

- Lewy bodies were seen in equal prevalence, about 40%, of cases fulfilling clinical criteria for DLB and clinical criteria of AD.

- Cases fulfilling the clinical consensus criteria of DLB show combinations of neuropathological changes which in themselves may explain the clinical picture of DLB even when LBs are absent.

- Vascular pathology was seen in 50% of cases with Lewy bodies.

- Cases with clinical DLB without Lewy bodies neuropathologically, often have Alzheimer pathology combined with frontal white matter pathology of ischemic type.

Introduction

Lewy bodies (LB) are pathological structures visualised as cytoplasmatic eosinophilic, concentric neural inclusion bodies with a characteristic halo when located in the brainstem. The structure was first described by Lewy in 1912 and the occurrence of LBs in SN, locus coeruleus and nbM were later considered to be characteristic phenomena Parkinson's disease (PaD) (Greenfield and Bosanquet, 1953, Bethlem and Den Hartog Jager, 1960).

LBs have however, been identified in a variety of diseases of different origin (Helfand 1935, Sigwald et al., 1964, Hirano et al., 1967, Agamanolis et al., 1979), although degenerative diseases and psychiatric disorders dominate (Rövéti 1956, Woodard 1962, Birkett et al 1992).

LBs have also been described as an incidental finding at autopsy in 4-5% (Forno 1969, Bergeron and Pollanen 1989). The prevalence has been found to increase with age (Hamada et al., 1963, Hirai 1968) and was 12,8% in the ninth decade (Gibb et al., 1988).

In 1960 Okazaki presented 2 remarkable cases with rapid disease progression, dementia and the clinical picture of paraplegia in flexion, who at autopsy were found to have widely spread LBs in the brain. These cases represent an unusual form of pure diffuse Lewy body disease (Kosaka, 1990).

Presence of LBs in dementia as revealed with modern staining techniques have been reported in about 20% of all organic dementia conditions, however most often in combination with Alzheimer pathology (Lennox et al., 1989; Hansen et al., 1990; Perry et al., 1990b; Shergill et al., 1994). The terminology adapted over the years such as combined AD and PaD, AD with PaD-related changes, AD with incidental Lewy bodies, AD with concomitant Lewy body disease, senile dementia of Lewy body type (SDLT), diffuse Lewy body disease (DLBD) and the Lewy body variant of Alzheimer's disease, has reflected the ongoing debate whether the condition is part of a disease spectrum between PaD and AD or a separate neurodegenerative disease entity but with clinical, neuropathological, and neurochemical features of both (Samuel et al., 1996).

In 1996 the first consensus guidelines for the clinical and pathological diagnosis of dementia with Lewy bodies (DLB) were published (McKeith et al., 1996). DLB was described as a dementia disorder with three clinical core features: cognitive fluctuations, extrapyramidal symptoms and visual hallucinations.

Several of the clinical DLB characteristics also appear in other dementia's: extrapyramidal symptoms (EPS) in AD (Pearce, 1974, Mölsä et al., 1984, Michell, 1995), dementia in PaD (Marttila and Rinne, 1976) and fluctuations in vascular dementias (Mayer-Gross, Slater, Roth, 1969, Gustafson et al., 1990, Moroney et al., 1997), especially of the small vessel type (Englund et al., 1989).

The pathological significance and clinical implications of the LB itself have not been established even though an association to cellular stress and neuronal degeneration are often suggested (De la Fuente-Fernández and Calne, 1996). The presence of LBs in the SN are classically correlated to EPS (Trétiakoff, 1919), in neocortex to the dementia syndrome (Lennox et al., 1989, Samuel et al., 1996) and through cholinergic deficits also to visual hallucinations (Perry et al., 1990a, Cummings, 2000). Other studies have however found that tangles in the SN may also produce EPS (Liu et al., 1997). Förstl et al., (1994) found no statistical evidence for a relation between hallucinations or delusions and the presence of LBs in the brainstem or neocortex. Hughes et al (1993) found cortical LBs in 100% of histologically confirmed PaD cases regardless of whether dementia was present or not. Against this complex background it is understandable that the diagnostic process involves differential diagnostic dilemmas.

The aim of this study was to describe the neuropathological findings in cases with clinically defined DLB to compare these findings with the neuropathology of a group of clinically defined AD patients and to investigate how the use of α -synuclein staining could improve the neuropathological detection of LB.

Patients and methods

The patients in this study were all part of a prospective longitudinal dementia project (Gustafson and Hagberg, 1975; Brun and Gustafson, 1993). The majority (>90%) of the patients were referred to the Psychogeriatric department, Lund University hospital. The catchment area is the most southern county (Skane) of Sweden with a population of about 1.1 million. The remaining 10% were referred to the neuropsychiatric consultant from the medical, neurology and psychiatry departments or nursing homes in Lund and nearby communities. The patients were investigated with neuropsychiatric evaluation including neurological status examination, neuropsychological testing, measurements of regional cerebral blood flow (rCBF), EEG, CT, laboratory screening and finally neuropathological post mortem examination. The primary aim of the dementia project was to study the course of dementia and clinico-pathological correlates. The present patient sample represents 200 consecutive cases investigated for dementia. These patients died between 1985-1994.

The clinical consensus criteria for probable DLB (McKeith et al., 1996), the DSM IV and NINCDS-ADRDA for probable AD (McKhann et al., 1984), The Lund- Manchester criteria (Brun et al., 1994) for diagnosis of frontotemporal dementia (FTD) and the DSM IV criteria for vascular dementia (VaD) were applied retrospectively.

The clinical diagnosis of DLB is based on recognition of a dementia syndrome with three major clinical criteria: fluctuations of cognition, extrapyramidal symptoms and visual hallucinations. Supporting criteria are: frequent falls, loss of consciousness, syncope, neuroleptic sensitivity, auditory hallucinations and delusions. The neuropathological guidelines offer a pathological subclassification according to topographical distribution of LBs: predominantly brainstem, limbic or transitional, and neocortical localisation. Associated neuropathological features are Lewy-related neurites, plaques, neurofibrillary tangles, regional neuronal loss in SN, LC and nbM and spongiform changes (McKeith et al., 1996).

The clinical diagnoses in this study were made without any previous knowledge of the neuropathological results (EL) and were based on clinical signs and brain imaging (CT/MR) when available. The regional cerebral blood flow (rCBF) findings were not taken into account in this study since they are analysed in a separate study (Londos et al 2000b).

Among the diagnostic groups that emerged, the groups fulfilling the clinical criteria for AD (clinAD) and DLB (clinDLB) were chosen for further comparisons. 67% of the cases in the clinDLB group also fulfilled clinical AD criteria.

The prevalence of symptoms in the clinDLB group have been described in Londos et al 2000 and was in accordance with the prevalence described in primarily neuropathologically diagnosed DLB cases (Lennox, 1992). In accordance with the clinical consensus criteria none of the clinDLB patients had clinical signs or a history of stroke.

The same neuropathologist (AB) examined all the cases. The procedures included laboratory standard measures of whole brain immersion fixation in 4% formaline and in addition intraventricular injection of formaline, for a more rapid central white matter fixation. Fixation times

averaged 2-3 weeks. The entire brain was then cut in 1/2-1 cm thick coronal sections, which were paraffin-embedded and cut in five micra thick sections. The semi-serial section technique with subsequent extensive microscopical analysis is a prerequisite for a safe neuropathological mapping of type, severity and distribution of changes and also for the exclusion of other types of clinically significant brain pathology. Staining routines included H/E for overall detail assessment and Luxol Fast Blue with cresyl violet counter staining for myelin and appreciation of cell numbers. Congo red for amyloid and Van Gieson-elastica staining for meningeal, vascular fibrosis and degeneration were used in selected sections.

Campbell and Gallyas methods were used for the detection of neuritic plaques, dystrophic neurites and neurofibrillary tangles and ubiquitin staining. The regional distribution and severity of white matter changes were mapped and quantitated according to a grading system with three main degrees, used previously for correlation with quantitative neurochemical measures (Englund et al., 1988). This assessment was combined with a similar mapping of the grey matter Alzheimer pathology using a grading system, which combines a number of histological variables (Brun and Englund, 1981). AD was defined as a combination of pathological changes such as neuronal loss, gliosis, microvacuolization, neurofibrillary tangles, senile plaques and dystrophic neurites. In terms of severity it ranges from a basal encephalopathy consistent with normal ageing (grade 0) to a level of severity recognised as AD grade I=mild, II=moderate and III=severe. The vascular pathology was mapped with regard to large and small vessels including carotid atherosclerosis, amyloid angiopathy and central white matter arteriolosclerosis as well as other, specific vascular changes. Incomplete infarcts restricted to the white matter are named selective white matter infarcts (SIWI) characterized by a reduction of both myelin and glial cells, appearing as a result of regionally reduced cerebral perfusion due to subcortical small vessel disease combined with systemic hypotension (Englund et al., 1988).

To amplify the detection of LBs 16 cases from the clinDLB group and the 10 cases from the clinAD group were reinvestigated with α -synuclein, tau, ubiquitin and GFAP antibodies. LBs were defined as rounded, non-fibrillary intensely immunoreactive inclusions. Tissue sections were taken from the mesencephalon, cingulate gyrus, hypothalamus, basal temporal cortex including hippocampus, parietal cortex and the frontal pole cortex. The groups were age and sex matched to be representative of the clinDLB (n=48) and clinAD (n=45) groups. Other variables that were accounted for were age of onset of dementia and duration of dementia.

Statistical methods

All statistical work was conducted in SPSS. For the comparison of the prevalence of different pathologies in the clinDLB and clinAD groups in table 2 the χ^2 test with continuity correction was used. The Mann Whitney U test was applied for the comparison of degrees of pathological change in the clinDLB and clinAD groups in table 3. The Kruskal-Wallis test was used when numbers of EPS (0-5) was correlated to the degree of SN degeneration.

Results

Demographic data are shown in table 1. Prevalence of separate pathological results is presented descriptively in table 2 and 3. As can be seen, Alzheimer pathology of any degree (mild-severe) was seen in 93% of the clinAD and in 81% of clinDLB. The overall degree of the Alzheimer degeneration was not significantly different in the clinDLB and clinAD groups. There was however, a significantly ($p<0.001$) more pronounced hippocampal degeneration, a higher de-

gree of temporal Alzheimer pathology ($p=0.007$) and a higher degree of neurofibrillary tangles ($p=0.047$) in the clinAD compared to the clinDLB group.

The degeneration of SN was significantly ($p=0.013$) more severe in clinDLB than in clinAD (table 3) and a larger number of EPS was reported when the degeneration of SN was more advanced ($p=0.001$ Kruskal-Wallis).

LBs, identified with the basal H/E and ubiquitin staining, were almost exclusively found in the brainstem. When found in the cortex the numbers were small. Table 4.

The prevalence of cases with LBs was 14,6% in the clinDLB and 9,1% in the clinAD group. Frontal white matter pathology defined as complete or selective incomplete white matter infarcts (SIWI) and traumatic white matter damage was seen in 47,9% of the clinDLB group compared to 20,5% of the clinAD group ($p=0.011$). SIWI was the dominating white matter pathology in these cases.

Among the cases with clinAD and clinDLB who exhibited a combination of AD and frontal white matter pathology ($n=32$), 24 (75%) belonged to the clinDLB and 8 (25%) to the clinAD group.

The prevalence of vascular pathology defined as small, single or multiple large infarcts did not differ between the two clinically defined groups, 67% of clinDLB and in 68% of clinAD.

Combinations of AD and vascular pathology, either SIWI, complete infarct or both, were the most common pathological findings in both clinical dementia groups (table 5 and 6). The general impression was that the clinDLB group had a larger variety of mixed pathological diagnoses compared to the clinAD cases and the combination Alzheimer pathology and degeneration of the SN was present in most cases.

The 16 clinDLB and 10 clinAD cases in the extended investigation with α -synuclein staining showed no significant differences compared to the original clinDLB ($n=48$) and clinAD ($n=45$) cases in demographic data, frequencies of symptoms of DLB, vascular symptoms, behavioural disturbances, risk factors or medication.

Hansen and Samuel (1997) suggested that descriptive profiling of the studied cases should be presented to reduce nosologic confusion. Therefore individual data of the α -synuclein assessed cases is presented in table 4. All cases with AD pathology exhibited diffuse and neuritic plaques. Tau positive neurites were also present in all of these cases. As can be seen here, LBs were found in 6 of 16 α -synuclein investigated clinDLB cases. Two of these previously exhibited LB in H/E and ubiquitin stainings. Four cases showed LBs in subcortical regions. Cortical LBs were seen in 4 cases. LBs were most frequently located in the SN 4/6, the nbM/hypothalamus 4/6 and the cingulate cortex 2/6. The density of cortical LBs was generally low, ranging from 1-7 LBs per case. Five of six cases with LBs exhibited Alzheimer pathology, 4 of mild and 1 of severe degree in contrast to the 10 clinDLB cases without LBs, where 9 had a moderate or severe AD degree. Three of the 6 clinDLB cases with LBs were of the “no-tangle” type. Four of the 6 clinDLB cases with LBs had a concomitant moderate SN degeneration in contrast to the clinDLB cases without LBs where only 3 of 9 cases showed mild and 1 of 9 showed moderate SN degeneration.

Among the 6 clinDLB cases with LBs, only 1 had AD and frontal white matter pathology in contrast to the clinDLB cases without LBs, where 7 of 10 cases exhibited this combined pathology ($p=0.059$, Fischer’s exact test).

The original pathological diagnoses of the six cases with clinical DLB and LBs are presented in table 7.

LBs were found in 4 of the 10 α -synuclein reassessed AD cases. In one of these cases, LBs were

found previously in the H/E and ubiquitin stainings.

The location of the LBs was in the hypothalamus in all 4 cases and in 2 of these also in mesencephalon and the cingulate cortex. The numbers of LBs varied between 5 and 10. Original pathological diagnoses of these 4 clinAD cases were AD (n=2), AD+MID and AD+SIWL.

The predictive validity of clinical diagnosis against the criterion of neuropathological identification of LBs among the 26 α -synuclein assessed cases was expressed in terms of sensitivity and specificity. The specificity for DLB was $6/16=38\%$ and the sensitivity was $6/10=60\%$.

Discussion

The results of this study are based on the comparison between two clinically defined patient groups, fulfilling generally accepted clinical dementia criteria. The cases were selected as consecutive cases within a prospective longitudinal dementia project. The investigated cases had all been referred to the psychogeriatric clinic as suspected dementia cases and followed up clinically and with post mortem neuropathological examination. The patient sample was selected as consecutively neuropathologically investigated cases in a demented population as an attempt to mirror the clinical spectrum of the psychogeriatrician's everyday practice. The age and sex distributions were in accordance with other neuropathologically studied DLB and AD populations. The retrospective collection of data and the clinical diagnostic process have been described in previous publications (Londos et al., 2000a and b). Since clinical consensus criteria for DLB were not available during the patient's lifetime these clinical criteria were applied retrospectively.

The primary aim of this study was to investigate the neuropathological picture of cases fulfilling clinical DLB criteria. The neuropathological staining techniques used in the study mirror the evolution of increasing sensitivity in detection of LBs. The original results from the whole brain semi serial sections and stored blocks of neuropathological material for reassessment with α -synuclein staining allowed the retrospective analysis of representative cases in the two clinical groups spanning an investigation period between 1985 and 1994.

All our cases could have been designated, according to earlier terminologies, as the Lewy body variant of AD (Hansen et al., 1990) or Senile dementia of Lewy body type (Perry et al., 1989) or DLBD common type (Kosaka, 1990), since the AD pathology in most cases was combined with small amounts of LBs. However it was considered that the density of LBs per se had not contributed to the cortical dementia syndrome and none of our cases showed the wide spread LBs of high densities throughout the cortex named cortical Lewy body disease or diffuse Lewy body disease, pure type.

In our study the LB prevalence rate in clinDLB was low and identical to that in the clinAD. Although not designed to be a validity study this indicates that the diagnostic specificity and the sensitivity of the clinical criteria of DLB are rather poor. There are several possible explanations for this.

The retrospective approach might have resulted in a systematic error in the application of the clinical criteria of DLB. There was however a very similar prevalence of the clinical features down to details, such as the distribution of separate EPS, compared to what has been described in neuropathologically defined DLB cases (see further, Londos et al., 2000). Even some non-LB neuropathological characteristics such as AD pathology of less degree, SN degeneration, spongiform changes resembled earlier described neuropathological DLB cases (Dickson et al.,

1987, Hansen et al., 1989).

The clinical criteria of DLB might not be sufficiently specific, when applied on consecutive dementia cases. Studies designed and aimed to investigate validity of the criteria of DLB have mostly been performed on cases with neuropathologically established, more pure diagnoses (Litvan et al., 1998, McShane et al., 1998, Papka et al., 1998, Luis et al., 1999). This might have contributed to high specificity (0.87-0.91) and sensitivity rates (0.43-0.89). However, in a community-based study by Holmes et al., 1999, where the cases were representative of a geographic catchment area, the pathologies appeared to be more mixed yielding a sensitivity of 1.0 and specificity of 0.22. In a pure prospective study by McKeith et al 2000 the sensitivity was 0.83 and specificity 0.95, although 31% of the DLB cases also had significant vascular pathology and the distribution of Lewy bodies was not found to correlate to the clinical features. However in another prospective study (Hohl et al., 2000), the diagnostic accuracy of DLB was found to be rather limited, 50%.

Combinations of other pathologies may produce the same clinical picture that is described as DLB. This is one of the main findings in this study. Even cases with various other pathologies, such as MID, Binswanger's disease, AD combined with SIWI, PaD combined with AD and frontotemporal dementia did, in our study, fulfil the clinical criteria of DLB and exhibit LBs at postmortem.

The relative impact on the clinical picture of different pathological findings is complex since the location, extension and addition of lesions have to be evaluated. The semiserial coronal sectioning technique may be advantageous here as it offers an overview of the brain and possibilities to evaluate the interplay between the regional lesions. The detection of SIWI lesions is dependent on this sectioning technique and probably underestimated when the small block technique is used (Brun et al., 1990).

Lewy bodies may have a different significance with more impact on the symptomatology in cases with higher densities and a more widespread distribution.

The consensus group recommended the term DLB as a generic term to "acknowledge the presence of LB without specifying their relative importance in symptom formation with respect to other degenerative or vascular pathology that is simultaneously present". With this broad definition DLB becomes a pathological descriptive diagnosis not indicating in which cases the LB pathology possibly or substantially contributes to the clinical picture.

As pointed out by Samuels et al., 1997, the consensus does not separate the larger group of patients with LBs in combination with AD pathology from the smaller group with LB without any AD pathology.

More recently great attention has been paid to the synucleins (α -, β - and γ -) that may play a role in synaptic transmission by transformation into insoluble pathological proteins and form aggregates (e.g. LB) which compromise the function and viability of neurones. Pre synaptic axon terminal pathology in hippocampus have been shown in PaD and DLB using α -, β - and γ -synuclein antibodies (Galvin et al., 1999). α -synuclein antibodies have also been traced in the extensive fine thread-like Lewy neurites in connection with peripheral nerves (Braak et al., 1999). It is suggested that the neurites formed abnormal aggregations which interfere with normal axon function. These studies are examples of the efforts to increase the understanding of the synucleins and LBs extended effect on the brain. However it is important to bear in mind that a pathological or molecular classification of dementia as for example synucleinopathies, is most useful when there are relevant and reliable clinical correlates (Mann et al., 2000). As pointed out by Hansen et al., 1993, almost identical neuropathologies (for example AD combined with PaD) could be designated differently depending on different clinical presentation or different timing of clinical manifestations (LBV or PaD combined with AD).

Our observation of a more severe hippocampal and temporal degenerative AD process in clinAD cases compared to clinDLB cases, is in accordance with other studies (Gibb et al., 1990a, Hansen et al., 1990, Ince et al., 1991) and is in this study, interpreted as an expression of the severity of the AD component. The LBs were most frequent in the SN and nbM, forming a basis for dopaminergic and cholinergic deficiencies, and in accordance with most neuropathological studies of DLB (Perry et al., 1989, Kosaka 1990, Hansen et al., 1990). Perry (1997) suggested that the presence of LBs in the cortex could be indicative of more widespread pathology particularly by affecting key subcortical areas such as nbM and that a key morphologic correlate of dementia may be de-afferentiation of the cortex related to degeneration of cortically projecting subcortical nuclei.

Other pathological differences between our clinically defined DLB and AD groups were the more severe SN pathology and the prevalence of white matter pathology mostly of ischemic type (SIWI) with a frontal location in the clinDLB group. The clinical features theoretically associated with these pathologies in combination with a basal AD pathology might explain why these patients fulfilled the clinical DLB criteria. Englund et al., 1989 investigated the clinical symptoms of neuropathologically defined cases of AD with and without SIWI. They found that the AD/SIWI cases exhibited more fluctuations, confusion, vertigo, fainting, hallucinations and frontal signs compared to the AD cases. There was also a difference in age at onset of dementia, with a higher prevalence of SIWI in the senile cases. SIWI is present in up to 50-60% of patients with AD. These pathological white matter lesions also correlate to the frequent finding of white matter changes on CT and MRI in elderly patients (Brun and Englund 1986; Englund et al., 1988). Both AD and DLB cases exhibit white matter lesions on MRI to a larger extent than controls (Barber et al., 1999). AD patients with leucoaraiosis on MRI showed significantly more EPS, more apathy and more deficiencies in demanding attentional tasks than AD patients without leucoaraiosis (Starkstein et al., 1997). Several of the DLB symptoms are thus encountered in cases with AD and white matter lesions visualised with different techniques.

The predominant pathology in the majority of our clinDLB cases was the Alzheimer pathology. The cases with LBs in α -synuclein showed a consistent pattern of less severe AD pathology and more advanced SN degeneration compared to the cases without LBs, still fulfilling the clinical DLB criteria. The more severe AD pathology in combination with frontal white matter pathology of ischemic type in the cases without LBs seemed to generate a strikingly similar clinical picture to that of DLB. It is well known that the addition of pathologies may amplify or add symptoms. The clinical role of SIWI in AD has been described as a threshold effect (Brun et al., 1990). Snowden et al 1998 suggested that lacunar infarcts in the basal ganglia, thalamus or deep white matter play an additive role in determining the presence and severity of clinical symptoms of AD. In an attempt to analyse the relative impact of the AD pathology, vascular pathology and LB pathology in 25 cases with predominately AD-type dementia, Goulding et al., 1999 found an inverse relation between Braak stage and cerebrovascular pathology suggesting that these diseases combine to produce the dementia phenomenon. A reinforcing role of two (or more) pathologies might also be part of the explanation of the symptomatology in DLB (Gibb, 1990b).

In the present study vascular pathology that was considered to contribute to the dementia picture was seen in 6 of 13 (46%) cases with clinDLB and clinAD that exhibited LBs (table 5 and 6). In the neuropathological assessment part of CERAD, cerebrovascular disease was found in one third of cases with definite AD (Mirra et al., 1991). Our corresponding figures agree with these data since two thirds of our clinDLB cases also fulfilled clinical AD criteria. In this document the complexity of interpretation and need for reliable data when overlapping pathologies occur is also emphasised.

Studies showing that LBs with neocortical involvement correlate to the dementia syndrome are of importance for the concept of DLB (Lennox et al 1989, Samuel et al., 1996). However, Hughes et al., 1993 found cortical LBs in all of 100 histologically confirmed PaD cases, of which only 4 satisfied the criteria for diffuse Lewy body disease (DLBD) while dementia occurred in 44%. Furthermore, Lindboe et al., 1998, investigated 248 unselected autopsy subjects ≥ 50 years to determine the frequency of cortical LBs. None of the 9 cases with cortical LBs had dementia. As suggested by Perry et al 1996 “to provide a satisfactory explanation of DLB it may be necessary to consider a variety of co-correlates of different clinical features, genetics, cerebral abnormalities, brain regions and different points of time”.

Concluding remarks

This study of the prevailing neuropathological features of clinically defined DLB and AD cases showed similarities in the prevalence of AD pathology and differences in the degree of AD pathology in hippocampal and temporal regions, degree of SN degeneration and prevalence of frontal white matter pathology of ischemic type. The combination of AD pathology, frontal white matter pathology and SN degeneration seemed to result in a clinical symptom constellation apparently identical with the clinical picture of DLB. Cerebrovascular pathology of significant degree was prevalent in almost 50% of the cases with LBs. For the clinician it is important to bear in mind differential diagnoses since clinical indications of disturbed circulatory factors could lead to different therapeutic strategies. As there are positive indications of treatment effects with cholinesterase inhibitors in DLB (Levy et al., 1994, Shea et al., 1998) uncertainty of the clinical diagnostic accuracy of DLB has to be taken into account in drug trials.

To increase the understanding of the diagnostic potential of the clinical DLB criteria and their relationship to brain pathology, patients with dementia have to be diagnosed, followed prospectively longitudinally and extensively investigated post mortem.

References

- Agamanolis DP, Greenstein JI. Ataxia-telangiectasia. 1979. Report of a case Lewy bodies and vascular abnormalities in the cerebral tissue. *J Neuropathol Exp Neurol.* **38**: 475-489.
- Barber R, Scheltens P, Ghokar A, Ballard C, McKeith I, Ince P, Perry R, O'Brien J. 1999. White matter lesions on magnetic resonance imaging in dementia with Lewy bodies, Alzheimer's disease, vascular dementia, and normal aging. *J Neurol Neurosurg Psychiatry.* **67**: 66-72.
- Bergeron C and Pollanen M. Lewy bodies in Alzheimer's disease – one or two diseases? 1989. *Alzheimer Disease and Associated disorders.* **3**: 197-204.
- Bethlem J, Den Hartog Jager WA. 1960. The incidence and characteristics of Lewy bodies in idiopathic paralysis agitans (Parkinson's disease). *J Neurol Neurosurg Psychiatry.* **23**: 74-80.
- Birkett P, Desouky A, Han L, Kaufman M. Lewy bodies in psychiatric patients. *Int J Geriatr Psychiatry.* 1992;**7**:235-240.
- Braak H, Sandmann-Keil D, Gai W, Braak E. 1999. Extensive axonal Lewy neurites in Parkinson's disease: a novel pathological feature by α -synuclein immunocytochemistry. *Neurosci Lett.* **265**: 67-69.
- Brun A, Englund E. 1981. The pattern of degeneration in Alzheimer's disease. Neuronal loss and histopathological grading. *Histopathology.* **5**: 549-64.
- Brun A, Englund E. 1986. A white matter disorder in dementia of Alzheimer type: a patho-anatomical study. *Ann Neurol.* **19**: 253-262.

- Brun A, Gustafson L, Englund E. 1990. Subcortical pathology of Alzheimer's disease. *Adv Neurol*. **51**: 73-77.
- Brun A and Gustafson L. The Lund Longitudinal Dementia Study: A 25-year Perspective on Neuropathology, Differential Diagnoses and Treatment. 1993. In *Alzheimer's Disease: Advances in Clinical and Basic Research*, Corain B, Nicolini M, Winblad B, Wisniewski H, Zatta P (eds). John Wiley & Sons; 4-18.
- Brun A, Englund E, Gustafson L, Passant U, Mann DMA, Neary D, Snowden JS. 1994. Clinical and neuropathological criteria for frontotemporal dementia. *J Neurol Neurosurg Psychiatry*. **57**: 416-418.
- Cummings JL. 2000. Cholinesterase inhibitors: a new class of psychotropic compounds. *Am J Psychiatry*. **157**: 4-15.
- De la Fuente-Fernández R, Calne DB. 1996. What do Lewy bodies tell us about dementia and parkinsonism? In *Dementia with Lewy bodies – clinical, pathological, and treatment issues*, Perry R, McKeith I, Perry E (eds). Cambridge University Press; 287-301.
- Dickson DW, Davies P, Mayeux R, Crystal H, Horoupian DS, Thompson A, Goldman JE. 1987. Diffuse Lewy body disease- neuropathological and biochemical studies of six patients. *Acta Neuropathologica*. **75**: 8-15.
- Englund E, Brun A, Alling C. 1988. White matter changes in dementia of Alzheimer type – Biochemical and neuropathological correlates. *Brain* **111**: 1425-39.
- Englund E, Brun A, Gustafson L. 1989. A white-matter disease in dementia of Alzheimer's type – clinical and neuropathological correlates. *Int J Geriatr Psychiatry*. **4**: 87-102.
- Forno LS. 1969. Concentric hyaline intraneural inclusions of Lewy type in the brains of elderly persons: relationship to parkinsonism. *J Am Geriatr Soc*. **17**: 557-575.
- Förstl H, Burns A, Levy R, Cairns N. 1994. Neuropathological correlates of psychotic phenomena in confirmed Alzheimer's disease. *Br J Psychiatry*. **165**: 53-59.
- Galvin JE, Uryu K, Lee V M-Y, Trojanowski JQ. 1999. Axon pathology in Parkinson's disease and Lewy body dementia hippocampus contains α -, β -, and γ -synuclein. *Proc Nat Acad Sci US*. **96**: 450-455.
- Gibb WRG, Lees AJ. 1988. The relevance of the Lewy body to the pathogenesis of idiopathic Parkinson's disease. *J Neurol Neurosurg Psychiatry*. **51**: 745-752.
- Gibb WGR, Mann DMA, Mountjoy CQ, Lees AJ. 1990a. A pathological study of the association between Lewy body disease and Alzheimer's disease. In *Advances in Neurology, Vol 53: Parkinson's disease: Anatomy, Pathology, and therapy*. Streifler MB, Korczyn AD, Melamed E, Youdim MBH (eds). Raven Press, New York.
- Gibb WRG. 1990b. Cortical Lewy body dementia. *Behavioural Neurology*. **3**: 189-196.
- Goulding JMR, Sinorini DF, Chatterjee S, Nicoll JAR, Stewart J, Morris R, Lammie GA. 1999. Inverse relation between Braak stage and cerebrovascular pathology in Alzheimer predominant dementia. *J Neurol Neurosurg Psychiatry*. **67**: 654-657.
- Greenfield JG, Bosanquet FD. The brainstem lesions in parkinsonism. *J Neurol Neurosurg Psychiatr*. 1953;**16**:213-226.
- Gustafson L, Nilsson L. 1982. Differential diagnosis of presenile dementia on clinical grounds. *Acta Psychiatr Scand*. **65**: 194-209.
- Gustafson L, Brun A, Johansson A, Risberg J. 1990. Diagnostic criteria of Alzheimer's disease. In *Alzheimer's disease. Epidemiology, neuropathology, neurochemistry, and clinics*, Maurer K, Riederer P, and Beckmann H (eds). Springer-Verlag, Wien; 357-364.
- Gustafson L and Hagberg B. 1975. Dementia with onset in the presenile period. *Acta Psychiatr. Scand.* Suppl 257.

- Hachinski VC, Iliff LD, Zilkha E, Du Boulay GH, McAllister VC, Marshall J, Russell RW, Symon L. 1975. Cerebral blood flow in dementia, *Arch Neurol*. **32**: 632-637.
- Hamada S, Ishii T. 1963. The Lewy body in the brain of the aged. *Adv Neurol Sci*. **7**: 184-186.
- Hansen LA, Masliah E, Terry RD, Mirra SS. 1989. A neuropathological subset of Alzheimer's disease with concomitant Lewy body disease and spongiform change. *Acta Neuropathol*. **78**: 194-201.
- Hansen LA, Salmon D, Galasko D, Masliah E, Katzman R, DeTeresa J, Thal L, Pay MM, Hofstetter R, Klauber M, Rice M, Butters N, Alford M. 1990. The Lewy body variant of Alzheimer's disease: a clinical and pathological entity. *Neurology*. **40**: 1-8.
- Hansen LA, Masliah E, Galasko D, Terry RD. 1993. Plaque-only Alzheimer disease is usually the Lewy body variant, and vice versa. *J Neuropathol Exp Neurol*. **52**: 648-654.
- Hansen LA, Samuel W. 1997. Criteria for Alzheimer's disease and the nosology of dementia with Lewy bodies. *Neurology*. **48**: 126-132.
- Helfand M. 1935. Status pigmentatus: its pathology and its relation to Hallervorden-Spatz disease. *J Nerv Ment Dis*. **81**: 662-675.
- Hirai S. 1968. Ageing of the substantia nigra. *Adv Neurol Sci*. **12**: 845-849.
- Hirano A, Kurland LT, Sayre GP. Familial amyotrophic lateral sclerosis- a subgroup characterised by posterior and spinocerebellar tract involvement and hyaline inclusions in the anterior horn cells. *Arch Neurol*. 1967;16:232-243.
- Hohl U, Tiraboschi P, Hansen LA, Thal LJ, Corey-Bloom J. 2000. Diagnostic accuracy of dementia with Lewy bodies. *Arch Neurol*. **57**: 547-351.
- Holmes C, Cairns N, Lantos P, Mann A. 1999. Validity of current clinical criteria for Alzheimer's disease, vascular dementia and dementia with Lewy bodies. *Br J Psychiatry*. **174**: 45-51.
- Hughes AJ, Daniel SE, Blankson S, Lees AJ. 1993. A clinicopathological study of 100 cases of Parkinson's disease. *Arch Neurol*. **50**: 140-148.
- Ince P, Irving D, MacArthur F, Perry RH. 1991. Quantitative neuropathological study of Alzheimer-type pathology in the hippocampus: comparison of senile dementia of Lewy body type, Parkinson's disease and non-demented elderly control patients. *J Neurol Sci*. **106**: 142-152.
- Kosaka K. 1990. Diffuse Lewy body disease in Japan. *J Neurology*. **237**: 197-204.
- Lennox G, Lowe J, Landon M, Byrne EJ, Mayer RJ, Godwin-Austen R. 1989. Diffuse Lewy body disease: correlative neuropathology using anti ubiquitin immunocytochemistry. *J Neurol Neurosurg Psychiatry*. **52**: 1236-47.
- Lennox G. 1992. Lewy body dementia. In *Baillière's Clinical neurology – unusual dementias*. Byres C (ed). Baillière Tindall, London; **1**:661-662.
- Levy R, Eagger S, Griffiths M, Perry E, Honovar M, Dean A, Lantos P. 1994. Lewy bodies and response to tacrine in Alzheimer's disease. *Lancet*. **343**: 176.
- Lewy FH. 1912. Paralysis agitans. I. Patologische anatomie. In: *Handbuch der Neurologie*. Lewandowsky M (ed). Springer, Berlin; **3**: 920-33.
- Lindboe CF, Hansen HB. 1998. The frequency of Lewy bodies in a consecutive autopsy series. *Clinical Neuropathol*. **4**: 204-209.
- Litvan I, McIntyre A, Goetz CG, Wenning GK, Jellinger K, Verny M, Bartko JJ, Jankovic J, McKee A, Brandel JP, Chaudhuri KR, Lai EC, D'Olhaberriague L, Pearce RKB, Agid Y. 1998. Accuracy of the clinical diagnoses of Lewy body disease, Parkinson's disease and dementia with Lewy bodies – a clinicopathological study. *Arch Neurol*. **55**: 969-978.
- Liu Y, Stern Y, Chun MR, Jacobs DM, Yau P, Goldman JE. 1997. Pathological correlates of extrapyramidal signs in Alzheimer's disease. *Ann Neurol*. **41**: 368-374.

- Londos E, Passant U, Brun A, Gustafson L. 2000a. Clinical Lewy body dementia and the impact of vascular components. *Int J Geriatr Psychiat.* **15**: 40-49.
- Londos E, Passant U, Brun A, Ingmar Rosén, Jarl Risberg, Gustafson L. 2000b. Regional cerebral blood flow and EEG in clinically diagnosed dementia with Lewy bodies and Alzheimer's disease (submitted)
- Luis CA, Barker WW, Gajraj D, Harwood D, Petersen R, Kashuba A, Waters C, Jimison P, Pearl G, Petito C, Dickson D, Duara R. 1999. Sensitivity and specificity of three clinical criteria for dementia with Lewy bodies in an autopsy-verified sample. *Int J Geriatr Psychiat.* **14**: 526-533.
- Mann DMA, McDonagh AM, Snowden J, Neary D, Pickering-Brown SM. 2000. Molecular classification of the dementias. *Lancet.* **355**: 626.
- Marttila RJ, Rinne UK. 1976. Dementia in Parkinson's disease. *Acta Neurol Scand.* **54**: 441-441.
- Mayer-Gross W, Slater E, Roth M. 1969. Ageing and the mental diseases of the aged. In *Clinical Psychiatry*, ed 3. Bailliere, Tindall&Carssell, London; 533-629.
- McKeith IG, Galasko D, Kosaka K, Perry EK, Dickson DW, Hansen LA, Salmon DP, Lowe J, Mirra SS, Byrne EJ, Lennox G, Quinn NP, Edwardson, Ince PG, Bergeron C, Burns A, Miller BL, Lovestone S, Collerton D, Jansen ENH, Ballard D, de Vos RAI, Wilcock GK, Jellinger KA, Perry RH. 1996. Consensus guidelines for the clinical and pathological diagnosis of dementia with Lewy bodies (DLB). *Neurology.* **47**: 113-124.
- McKeith IG, Ballard CG, Perry RH, Ince PJ, Jaros E, Neill D, O'Brien JT, Neill D, Lowery K, Jaros E, Brber R, Thompson P, Swann A, Fairbairn AF, Perry EK. 2000. Predictive validation of consensus criteria for the diagnosis of dementia with Lewy bodies. *Neurology.* **54**: 1050-1058.
- McKhann G, Drachman D, Folstein M, Karzman R, Pride D, Stadlan E. 1984. Clinical diagnosis of Alzheimer's disease: Report from the NINCDS-ADRDA work group under the auspices of department of Health and Human Service Task Force on Alzheimer's disease. *Neurology.* **34**: 939-943.
- McShane RH, Esiri MM, Joachim C, Smith AC, Jacoby, RJ. 1998. Prospective evaluation of diagnostic criteria for dementia with Lewy bodies. *Neurobiol Aging.* **19**(4S): 204.
- Michell SL. 1995. Extrapyramidal features in Alzheimer's disease. *Age Ageing.* **28**: 401-409.
- Mirra SS, Heyman A, McKeel D, Sumi SM, Crain BJ, Brownlee LM, Vogel FS, Hughes JP, van Belle G, Berg L. 1991. The consortium to establish a registry for Alzheimer's disease (CERAD). Part II. Standardization of the neuropathologic assessment of Alzheimer's disease. *Neurology.* **42**: 479-486.
- Mirra SS, Hart MN, Terry RD. 1993. Making the diagnosis of Alzheimer's disease. *Arch Pathol Lab Med.* **117**: 132-144.
- Mölsä PK, Marttila RJ, Rinne UK. 1984. Extrapyramidal signs in Alzheimer's disease. *Neurology Cleveland.* **34**: 1114-1116.
- Moroney JT, Bagiella E, Desmond DW, Hachinski VC, Mölsä PK, Gustafson L, Brun A, Fischer P, Erkinjuntti T, Rosen W, Paik MC, Tatemichi TK. 1997. Meta-analysis of the Hachinski ischemic score in pathologically verified dementias. *Neurology.* **49**: 1096-1105.
- Okazaki H, Lipkin LE, Aronson SM. 1961. Diffuse intracytoplasmatic ganglionic inclusions (Lewy type) associated with progressive dementia and quadriplegia in flexion. *J Neuropathol Exp Neurol.* **20**: 237-244.
- Papka M, Schiffer R, Rubio A. 1998. Diagnosing Lewy body disease, accuracy of clinical criteria in detecting Lewy body pathology. *Neurobiol Aging.* **19**(4S): 203.
- Pearce J. 1974. The extrapyramidal disorder of Alzheimer's disease. *Eur Neurol.* **12**: 94-103.

- Perry EK, Kerwin J, Perry RH, Blessed G, Fairbairn AF. 1990a. Visual hallucinations and the cholinergic system in dementia. *J Neurol Neurosurg Psychiatry*. **53**: 88.
- Perry RH, Irving D, Blessed G, Perry, EK, Fairbairn AF. 1989. Clinically and neuropathologically distinct form of dementia in the elderly. *Lancet*. p.166.
- Perry RH, Irving D, Blessed G, Fairbairn A, Perry EK. 1990b. Senile dementia of the Lewy body type. A clinical and neuropathologically distinct form of Lewy body dementia in the elderly. *J Neurol Sci*. 95: 119-139.
- Perry RH, Jaros EB, Irving D, Scoones DJ, Brown A, McMeekin WM, Perry EK, Morris CM, Kelly PJ, Ince PG. 1996. What is the neuropathological basis of dementia associated with Lewy bodies? In Perry R, McKeith I, Perry E (eds). *Dementia with Lewy bodies, clinical, pathological and treatment issues*. Cambridge University press: 212-223.
- Perry R, McKeith I, Perry E. 1997. Lewy body dementia – clinical, pathological and neurochemical interconnections. *J Neural Transm*. suppl 51: 95-109.
- Rösvéti G. 1956. Über Zelleinschlüsse in Substantia nigra und Locus coeruleus bei Fällen ohne Parkinsonsyndrom, zugleich ein Beitrag zur Kenntnis der senilen Veränderungen dieser Gebiete. *Mscr Psychiat Neurol*. **132**:347-363.
- Samuel W, Galasko D, Masliah E, Hansen LA. 1996. Neocortical Lewy body counts correlate with dementia in the Lewy body variant of Alzheimer's disease. *J Neuropath Exp Neurol*. **55**:1: 44-52.
- Samuel W, Alford M, Hofstetter R, Hansen L. 1997. Dementia with Lewy bodies versus pure Alzheimer disease: differences in cognition, neuropathology, cholinergic dysfunction, and synapse density. *J Neuropath Exp Neurol*. **56**: 449-508.
- Shea C, MacKnight C, Rockwood K. 1998. Donepezil for treatment of dementia with Lewy bodies: a case series of nine patients. *Int Psychogeriatr*. **10**: 229-38.
- Shergill S, Mullan E, D'At P, Katona C. 1994. What is the clinical prevalence of Lewy body dementia? *Int.J. psychoger*. **9**, 907-912
- Sigwald J, Lapresle J, Raverdy P, Recondo HJ. 1964. Atrophie cérébelleuse familiale avec association de lésions nigériennes et spinales. *Presse Med*. **72**: 557-62.
- Snowdon, DA, Greiner LH, Mortimer JA, Riley KP, Greiner PA, Markesbery WR. 1997. Brain infarction and the clinical expression of Alzheimer Disease. The nun study. *JAMA*. **277**: 813-817.
- Starkstein SE, Sabe L, Vásquez S, Di Lorenzo G, Martinez A, Petrecca G, Tesón A, Chemerinski E, Leiguarda R. 1997. Neuropathological, psychiatric, and cerebral perfusion correlates of leucoaraiosis in Alzheimer's disease. *J Neurol Neurosurg Psychiatry*. **63**: 66-73.
- Trétiakoff C. 1919. Contribution l'étude de l'anatomie patologique du locus niger de Soemmering. Thèse de Paris.
- Woodard JS. 1962. Concentric hyaline inclusion body formation in mental disease: Analysis of twenty-seven cases. *J Neuropath Exper Neurol*. **21**: 442-449.

Acknowledgement

The Alzheimer foundation, Sjöbring foundation, Stiftelsen Gamla Trotjänarinnor and the Swedish Medical Research Council, project no 3950, supported this study. Dr Masahito Takahashi is acknowledged for help with translation of articles in Japanese and Maria Sjöström for preparation of tables. We also gratefully acknowledge Kerstin Stureson, Annette Persson-Prahl and Christina Andersson, Inst of Pathology and Jessica Nilsson, Biomedical center, Lund University, for histotechnical assistance.

Table 1.
Demographic data (mean and range) in patients with clinically defined Dementia with Lewy bodies (clinDLB) and Alzheimer's disease (clinAD) studied with different histopathological techniques.

	clinDLB		clinAD	
	HE/Ubi	α -sy	HE/Ubi	α -sy
N	48	16	45	10
Male/Female	20/28	7/9	18/27	4/6
Age at death	78 (58-94)	79 (60-94)	79 (61-97)	78 (62-88)
Age of onset	71 (52-82)	71 (54-82)	72 (50-87)	70 (50-86)
Dementia duration	7.1 (1-16)	7.9 (1-14)	7.7(2-19)	8.7 (2-19)

HE= Hematoxylin Eosin

α -sy= α -synuclein

Table 2.
Prevalence of neuropathological changes in clinically defined Alzheimer's disease (clinAD) and dementia with Lewy bodies (clinDLB) (in %)

	ClinAD	ClinDLB
	n=44	n=48
Alzheimer pathology, mild-severe	93,0	81,3
Senile plaques, mild-severe	88,6	81,3
Neurofibrillary tangles, mild-severe	77,3	75,0
Amygdala pathology, mild-severe	77,3	79,2
Hippocampus pathology, mild-severe	90,9	79,2
Limbic involvement	67,5	72,5
Frontal spongiosis	40,9	20,8
Temporal spongiosis	9,1	16,7
Hypertensive angiopathy	13,6	12,5
Atheromatosis of large vessels	34,1	47,9
Fibrohyaline arteriosclerosis	47,7	37,5
Status cribrosus	15,9	14,6
Vascular amyloidosis mild-severe	68,2	54,2
Larger single or multiple infarcts	15,9	20,8
Small infarcts	40,9	31,3
Lacunar infarcts	15,9	16,7
Binswanger pathology	2,3	6,3
SIWI of any size	54,5	50
Frontal white matter pathology	20,5	47,9 *
Microvacuolisation/spongiosis	52,3	43,8
Traumatic lesion	11,4	8,3
SN degeneration mild-severe	36,4	54,2
I.C degeneration mild-severe	40,9	39,6
Cerebellar pathology	29,5	43,8
Lewy bodies	9,1	14,6
Frontal lobe atrophy	27,3	29,2

* p=0.011 (χ^2). All other p-values were non significant, ranging from 0.062-1.000

Table 3.
Comparison of degrees (no-mild-moderate-severe) of pathological change
in clinically defined Alzheimer's disease (clinAD) and Dementia with
Lewy bodies (clinDLB)

	ClinAD	ClinDLB	P
	(n=43)	(n=48)	
Alzheimer pathology	>		0.261
Senile plaques	>		0.065
Neurofibrillary tangles	>		0.047*
Amygdala pathology	>		0.128
Hippocampal pathology	>		0.001**
Parietal Alzheimer pathology	>		0.337
Temporal Alzheimer pathology	>		0.007**
Frontal Alzheimer pathology	>		0.138
Vascular amyloidosis	>		0.099
Extension of white matter pathology	=		1.000
SN degeneration	<		0.013*
LC degeneration	=		1.000
Cortical atrophy (hydrocephalus)	>		0.109

Comparison between groups with the Mann Whitney U test.

* p<0.05, ** p<0.01

Table 4 Clinical and neuropathological characteristics of α -synuclein reassessed 16 cases of dementia with Lewy bodies (clinDLB) and 10 cases of Alzheimer's disease (clinAD).

	Age	Sex	Dem Dur	AD score	IS score	EPS nr of	Fluct	Vis hall	AD deg	Plaque	Tang les	Front wrm	SN deg	LB H/E	LB a-sy
ClinDLB															
	78	F	12	8	5	4	YES	NO	2	3	3	YES	0	NO	NO
	86	F	10	11	3	1	YES	NO	2	3	1	YES	1	NO	NO
	81	M	6	11	5	2	YES	NO	2	3	1	YES	0	NO	NO
	64	M	8	6	1	4	NO	YES	3	3	3	YES	1	NO	NO
	94	M	14	13	1	5	YES	NO	3	3	3	YES	2	NO	NO
	86	M	12	7	7	1	YES	NO	3	3	3	YES	0	NO	NO
	82	F	8	8	5	0	YES	YES	2	2	2	NO	0	NO	NO
	83	M	1	2	9	0	YES	YES	1	1	1	YES	0	NO	NO
	63	F	8	6	3	5	NO	YES	3	3	3	NO	0	NO	NO
	60	F	6	11	4	4	YES	YES	3	3	3	NO	1	NO	NO
	88	M	7	6	5	3	YES	YES	1	1	NO	NO	0	NO	Temporal +, SN ++
	88	F	8	13	3	1	YES	YES	1	2	2	NO	0	NO	Frontal +
	79	M	3	6	7	4	YES	NO	1	2	2	NO	2	YES	Frontal++, Cingulate+, Hypoth ++, Parietal+, Temp+, Mes++
	82	F	11	8	4	4	YES	YES	3	3	3	YES	2	NO	nbM+
	76	M	5	7	9	4	YES	NO	1	3	NO	NO	2	YES	nbM++, SN++, Cortex (+)
	73	F	8	8	2	4	YES	NO	NO	1	NO	NO	2	NO	Cingulate +, Hypoth++, SN++
ClinAD															
	62	F	12	10	1	4	NO	NO	3	3	3	NO	NO	NO	NO
	88	M	2	8	3	2	NO	NO	1	1	1	NO	NO	NO	NO
	88	F	14	9	3	0	NO	YES	2	3	2	NO	NO	Hypoth +	
	77	F	6	7	2	0	NO	YES	2	3	0	NO	1	YES	Mes +, Hypoth +, Cingulate +
	76	F	19	9	0	1	NO	NO	2	3	3	NO	NO	NO	NO
	84	M	3	10	4	3	YES	NO	1	1	0	NO	NO	NO	NO
	69	F	11	7	5	2	YES	NO	2	1	3	YES	NO	NO	Hypoth +
	88	M	8	5	7	2	YES	NO	2	1	3	YES	1	NO	NO
	81	F	6	11	4	2	NO	NO	3	3	3	NO	2	NO	Cingulate+, Hypoth+(+), Mes ++
	71	M	6	7	5	3	NO	NO	2	3	3	NO	1	NO	NO

AD score $\geq 5-6$ indicates AD (Gustafson et al 1982, Brun Gustafson 1993). IS score = ischemic score $\geq 7-8$ indicates vascular etiology (Hachinski et al 1975). Eps = extrapyramidal symptoms. Fluct = fluctuations. Vis hall = visual hallucinations. AD-degree, plaques, tangles: 0=no, 1=mild, 2=moderate, 3=severe. Fron wrm = frontal white matter pathology. SN deg = substantia nigra degeneration. LB H/E = Lewy bodies visualised in Hematoxylin and Eosin staining. a-sy = α -synuclein staining. nbM = nucleus basalis Meynert. Hypoth = hypothalamus. Mes = mesencephalon. +=1-5 LB, ++=6-10 LB, +++>10 LB

Table 5

Combination of dominating pathological diagnoses in cases with clinically defined Dementia with Lewy Bodies, number of cases.

Degree of pathological AD	0	Gray matter infarct(s)	SIWI	Gray matter infarct(s) + SIWI	BW	FTD	Other
No	1	1 ²	3			2	21 ⁵
Subst nigra degen	1	0	2			2	0
Mild	1*	4	3		2*		1**
Subst nigra degen	1	2	1		1		0
Moderate	6**	1	6	3			
Subst nigra degen	3	1	3	1			
Severe	3	4*	2*	1	1		1 ³
Subst nigra degen	2	2	2	0	1		1

1. Atherosclerosis and white matter degeneration (non ischemic)

2. Fahr's disease

3. White matter degeneration (non ischemic)

4. Spongiosis

5. Meningeal pleocytosis

*One case with Lewy bodies ** two cases with Lewy bodies

Substantia nigra degeneration: mild n=11, moderate n=11, severe n=4

Table 6

Combination of dominating pathological diagnoses in cases with clinically defined Alzheimer's disease, number of cases.

Degree of pathological AD	0	Gray matter infarct(s)	SIWI	Gray matter infarct(s) + SIWI	BW	FTD	Trauma	Small vessel disease
No	1	1				1		
Subst nigra degen	1	1				0		
Mild		2*	2					1
Subst nigra degen		1	1					0
Moderate	10***	2*	10	1	1			4
Subst nigra degen	4	1	2	0	0			2
Severe	4*		3*					
Subst nigra degen	0		1					

* One case with Lewy bodies *** Three cases with Lewy bodies

Substantia nigra degeneration: mild n=11, moderate n=3, severe n=0

Table 7.

Neuropathological diagnoses (1985-1994) of the cases with clinical Dementia with Lewy Bodies exhibiting Lewy bodies in α -synuclein staining.

Sex	Age	Neuropathological diagnoses
M	88	Mild AD, temporal – limbic. Spongiform cortical changes. Mild hydrocephalus.
F	88	AD, temporal – limbic, mild amyloid angiopathy.
M	79	AD with degeneration of the substantia nigra.
F	82	AD and MID.
M	76	Mild early AD, temporal – limbic. Moderate central arteriosclerosis with limited incomplete infarct, Binswanger like.
F	73	Temporo – frontal primary degeneration – unspecific, almost corresponding to fronto-temporal degeneration of non-Alzheimer type.

AD=Alzheimer's disease MID= multi infarct dementia

Regional cerebral blood flow and EEG in clinically diagnosed dementia with Lewy bodies and Alzheimer's disease

Elisabet Londos^a, Ulla Passant^a, Arne Brun^b, Ingmar Rosén^c, Jarl Risberg^{a,c} LarsGustafson^a,
Department of ^aPsychogeriatrics, ^bPathology and
^cClinical Neurophysiology, Lund University hospital, SE-221 85 Lund, Sweden

Running title: EEG and rCBF in clinical dementia with Lewy bodies

Key words: Dementia with Lewy bodies, Alzheimer's disease, EEG, regional cerebral blood flow, Lewy bodies.

Corresponding address:

Elisabet Londos, MD
Department of Psychogeriatrics
Lund University hospital
SE-221 85 Lund, Sweden
Tel no: +46 – 46 17 74 63
Fax no: +46 – 46 – 17 74 57
E-mail: elisabet.londos@psykiatr.lu.se

Abstract

Objective: To compare regional cerebral blood flow and EEG findings of patients with clinically diagnosed dementia with Lewy bodies (clinDLB) and Alzheimer's disease (clinAD). Furthermore, within the clinDLB group compare cases with and without neuropathologically verified Lewy bodies (LBs).

Methods: Among 200 dementia cases in a prospective longitudinal dementia study, 48 had clinDLB and 45 clinAD in retrospective analyses. EEG information was analysed in 34 clinDLB and 28 clinAD patients and cerebral blood flow, measured with the Xe 133 inhalation method, in 26 clinDLB and 25 clinAD.

Results: There were no differences in EEG between the clinDLB and clinAD groups or between the cases with and without LBs. The regional cerebral blood flow (rCBF) patterns in the clinDLB and clinAD groups showed similar reductions in the temporoparietal areas. The rCBF in cases with LBs showed heterogeneous pathology.

Conclusion: The imaging results in clinDLB and clinAD were strikingly similar. The EEG and rCBF could not differentiate between cases with or without LB.

The study illustrates the lack of specific changes of EEG and rCBF in cases with LB pathology.

Introduction

The diagnosis of specific types of dementia disorders is of great importance owing to the increasing possibilities of specific pharmacological treatment and care. Brain imaging is offering the possibility to study functional as well as structural changes in dementia thereby strongly contributing to diagnostic accuracy. Comparisons between the clinical picture and results from cerebral imaging, such as regional cerebral blood flow (rCBF) measurements and EEG recordings have been made in numerous studies of organic dementia e.g.(1-3). There is also evidence of relations between EEG and rCBF results and postmortem neuropathological findings (4).

The majority of organic dementias are caused by Alzheimer's disease (AD) and cerebrovascular disease, or a combination of these two. Dementia with Lewy bodies (DLB) has more recently been referred to as the second most common dementia in the elderly, after AD. According to reports it represents 10-20% of all organic dementias in clinical settings (5-8). It was initially identified neuropathologically by presence of Lewy bodies (LB) in cortical and subcortical structures (9) and clinical consensus criteria were published in 1996 (10). The clinical diagnosis of DLB is based on recognition of a progressive dementia disorder with core criteria such as fluctuations of cognition, extrapyramidal symptoms and visual hallucinations. Supporting diagnostic features are frequent falls, loss of consciousness, syncope, neuroleptic sensitivity, auditory hallucinations and delusions. Several of these characteristics are however also present in AD, vascular dementia (VaD) and in Parkinson's disease (PaD) with dementia. The clinical recognition of DLB may therefore be difficult. So far no consistent functional brain imaging findings have proved to increase the diagnostic specificity in vivo and still, pathology remains the only way to confirm the diagnosis.

In our longitudinal dementia study we have a longstanding tradition of using the two-dimensional (2D) xenon inhalation rCBF technique to provide information about the functional level of the cerebral cortex (11-14). In dementia the rCBF pathology can be general, focal or both, reflecting the cortical disease process. Several studies have shown that the patterns of rCBF

changes are consistent with the topography of the pathological changes. The typical rCBF finding in AD is bilateral hypometabolism in the temporoparietal association cortex (3,13,15,16). Specificity for AD with the 2D rCBF method has proved to be excellent, 98%, while sensitivity have proved to be in the order of 75-80% (17). In another cortical dementia, fronto temporal dementia, there is frontal hypometabolism and decreased CBF demonstrated with both 2D and 3 D techniques (18-20). Correspondingly, sensitivity for FTD in 2D rCBF has been shown to be 97% with a specificity of 85-90% (21).

In PaD with dementia, rCBF studies have shown reduced perfusion in the temporoparietal lobes (22-25) and in additional areas, like the frontal and occipital cortices (26). Despite limited possibilities to visualise deep cortical and subcortical structures, the rCBF measurement have proved to be a reliable and highly reproducible tool in the differential diagnosis of dementia (17,27,28).

rCBF studies in DLB using tomographic techniques have demonstrated temporoparietal hypoperfusion similar to the characteristic flow pathology in AD (29-31).

Another important technique that mirrors mainly cortical brain activity is EEG, which is a non-invasive, widely available and inexpensive diagnostic tool in dementia (32). It is well known that the general EEG finding in dementia of Alzheimer type is an increase in slow-wave activity with progression of the disease (33). However, in FTD, EEG often remains normal despite clinical evident dementia (4). Although EEG is highly sensitive to diffuse organic encephalopathy of various aetiologies, it has a rather low specificity for different dementia diagnoses (34). Crystal and co-workers (35) suggested, however, that EEG could be valuable in the differentiation of AD and diffuse Lewy body disease (DLBD). They found a slowing of the postcentral background rhythm and often a frontally dominant burst pattern in neuropathologically diagnosed DLBD cases.

The importance of the cortical involvement of LBs of patients with dementia was first emphasised by Kosaka (36). The density of cortical LBs has also been found to correlate with degree of dementia (37,38). In the present study we are using two mainly cortical imaging techniques, EEG and rCBF.

The aim of this study was

to compare differences in the EEG and rCBF between the clinically defined AD and DLB groups and

to describe EEG and rCBF findings in subgroups of the clinical DLB and AD cases with and without the neuropathological structure Lewy body.

Materials and methods

The patient groups and the design of the study are presented in fig 1. The present patient sample represents a cohort of 200 cases from our longitudinal dementia study (39,40). All the patients were investigated as suspected dementia cases. The majority of cases (>90%) were examined and/or cared for at the Psychogeriatric and Psychiatric departments at Lund University hospital and the rest were treated in other medical departments, in nearby hospitals or nursinghomes. The patients were extensively investigated with neuropsychiatric evaluation including neurological status examination, neuropsychological testing, and measurements of rCBF, EEG, CT and laboratory testing. The patients were selected as consecutively neuropathologically examined cases during the period 1985-1994. The patients were thus clinically investigated before criteria of DLB and cholinergic therapy were available. The criteria for probable DLB (10) and AD (DSM

IV and NINCDS-ADRDA) (41) were applied retrospectively. The clinical diagnoses of AD and DLB were based on the description of symptoms in the patients' medical records and made without any previous knowledge of the neuropathological results (E.L.). The EEGs and rCBF measurements were analysed separately and therefore not included in the retrospective diagnostic procedure. Forty-eight cases fulfilled the clinical consensus criteria of DLB and 45 cases were diagnosed clinically to have AD.

Neuropathological method

The procedures included laboratory standard measures of whole brain semi-serial sections with subsequent extensive microscopical analysis as a prerequisite for a safe neuropathological mapping of type, severity and distribution of changes and also for the exclusion of other types of clinically significant brain pathology. Staining routines included H/E, Luxol Fast Blue with cresyl violet counter staining, Congo red, Van Gieson-elastica, Campbell and Gallyas methods and ubiquitin staining (40). The regional distribution and severity of white matter changes were mapped and quantitated and combined with a similar mapping of the grey matter Alzheimer pathology combining a number of histological variables such as neuronal loss, gliosis, microvacuolization, neurofibrillary tangles, senile plaques and dystrophic neurites (42). The vascular pathology was mapped.

In order to optimise the detection of LBs, 16 cases from the clinDLB group and the 10 cases from the clinAD group were reinvestigated with α -synuclein, tau, ubiquitin and GFAP antibodies. LBs were defined as rounded non-fibrillary intensely immunoreactive inclusions. The results from the whole brain semiserial sectioning investigation were supplemented by examination of tissue sections from the mesencephalon, cingulate gyrus, hypothalamus, basal temporal cortex including hippocampus, parietal cortex and the frontal pole cortex.

The groups were age and sex matched to be representative of the clinDLB (n=48) and clinAD (n=45) groups. Other variables that were accounted for were age of onset of dementia and duration of dementia.

Regional cerebral blood flow

The rCBF was assessed by the xenon-133 inhalation method developed by Obrist et al (43) and modified by Risberg et al (44-45). rCBF was measured in a resting situation with the eyes closed. The inert γ -radiating tracer xenon-133 (90 MBq/l) was inhaled for 1 min through a face mask, followed by 10 min breathing of ordinary air. Up to 1986 the rCBF was assessed with a 32 detector technique which was then replaced by a recording system with 254 scintillating detectors (Cortexplorer 256 HR; Ceretronic Inc, Randers, Denmark) which gave a spatial resolution of about 1 cm for superficial cortex. Because of technical reasons only group results based on rCBF registrations with 254 channels, which were available in 26 cases of the clinDLB and 25 cases of clinAD, will be presented here. The group measured before 1986 with 32 detectors did not differ with respect to gender, age at onset of dementia, dementia duration and age at death from the cases measured with the high-resolution technique. The 254 detector results, presented below, are thus representative also of the patient group with 32 detector recordings. In the special study group with neuropathologically verified LBs, 4 cases were studied with 32, 2 cases with 254 detectors and presented as single cases.

EEG

EEG was recorded with 16 or 24 channel electroencephalographs (Siemens Elema or Nihon Kodhen, time constant 0.3 s; low pass filter 70 Hz) with electrode positions according to the 10-20 system. Bipolar and common reference montages were used. Periods of drowsiness were counteracted by sound stimuli.

The EEG records were reanalysed visually regarding dominant activity frequency, presence of focal abnormalities, side asymmetry, epileptiform activity and degree of abnormality (I.R.). This was done without any knowledge of the clinical diagnosis. The degree of EEG background abnormality was classified in four categories:

1. Normal EEG.
2. Slightly pathologic. Posterior dominant frequency within normal range ($>8\text{Hz}$), increase of diffuse and/or episodic theta.
3. Moderately pathologic. Posterior dominant frequency $<8\text{Hz}$. Moderate increase of delta waves.
4. Highly pathologic. Posterior dominant frequency $\leq 6\text{Hz}$. Marked increase of delta waves.

Statistical analysis

For the comparison of proportions between the clinical AD and DLB groups the Fisher's exact test and χ^2 test (with continuity correction) were applied. The Mann Whitney U test was used to compare the degree of abnormality of the EEGs and the degree of pathology in the clinical AD and DLB groups. The Student's t-test was applied to compare the dominating EEG activity frequency and age at EEG examination. All analyses were carried out as two-tailed tests.

The individual rCBF data were transformed into colour coded interpolated, vertex projection flow maps for both types of flow measurement using the individual average flow value as a reference. The average flow patterns in the 25 clinAD and 26 clinDLB cases were displayed in a similar way. The difference between the flow patterns for the two groups was analysed using a statistical mapping system which displayed only groups of detectors where the difference in relative distribution values were significant at the $p < 0.001$ level, as evaluated by Student's t-test. This high significance level was chosen to reduce the risk of spurious findings due to the large (254) number of regional comparisons made.

Results

The demographic characteristics of the clinDLB and clinAD cases investigated with EEG and rCBF are presented in table 1. There were no differences in age at onset of dementia, age at death or dementia duration between the patient groups.

rCBF

There were no statistically significant group differences in the time interval between onset of dementia and the rCBF measurement (clinAD median 4.5 years, range 1-12, and clinDLB median 5 years, range 1-14). The age of the patients, at the time of the rCBF measurement, did not differ between the two groups (77 years in clinAD, 75 years in clinDLB). There was no evidence in the rCBF protocols that any of the investigated subjects were actively hallucinating during the investigation procedure. The visual evaluation and the statistical analysis of the rCBF showed very similar results in the clinDLB and clinAD groups, with both general and focal

pathologies. There was a decrease of cerebral blood flow in temporoparietal areas, as demonstrated in fig 2. The only region that significantly differed between the groups was a very small area in the right frontodorsal region, where the clinAD cases had lower blood flow values. The mean hemispheric blood flow was symmetrical and at the same low level in both clinical groups.

EEG

There were no statistically significant group differences in the interval between the time of onset of dementia and the EEG recording (clinAD median 5 years, range –3-12, clinDLB median 3 years, range 0-13). The age of the patients, at the time of the EEG recording, did not differ between the two groups (76.5 ± 8.0 years in clinAD, 73.3 ± 10.4 years in clinDLB). The dominating EEG frequency was within the theta frequency band in 82.1% of clinAD and 85.3% of clinDLB cases (range: 5-9 Hz in clinAD and 4.5-9 Hz in clinDLB).

The vast majority of the cases did not show any hemispheric asymmetry, focal abnormality or epileptiform activity in the EEG. The overall degree of abnormality was equal in both groups and indicated a moderately to highly pathologic pattern with generalised slow-wave activity, table 2.

Neuropathology

The neuropathological results are described in detail in another paper (46). In summary, Alzheimer pathology was found in 81% of the clinDLB and 93 % of the clinAD cases. The clinDLB group had a higher prevalence of frontal white matter pathology, mostly of ischemic type, and a more severe degeneration of the substantia nigra compared to the clinAD group. In Hematoxylin/Eosin staining LBs were identified in 7 (15%) of the clinDLB and in 4 (9%) of the clinAD group. 16 clinDLB and 10 clinAD exhibited LBs in 6 and 4 cases respectively. LBs were mainly located in the brainstem. Cortical LBs were found in 4 of 6 clinDLB and in none of the clinAD cases. The density of cortical LBs was low. Within the clinDLB group the degree of AD pathology in cases with LBs was lower than in cases without. Vascular pathology of significant degree was prevalent in almost 50 % of all the cases with verified LBs regardless of clinical diagnosis.

rCBF results in 6 clinDLB cases with neuropathologically verified Lewy bodies

The 6 patients with LBs are presented as individual cases. Fig 3.

It is evident that the six cases are very heterogeneous regarding their flow pathology. Cases 2,4 and 5 show a predominant temporoparietal flow pathology while cases 1 and 3 show more central-parietal flow diminutions. Case 6 shows mainly frontal and frontotemporal decreases, which are also seen in case 4.

EEG in cases with and without neuropathologically verified LB within the clinDLB group

The age, duration of dementia and the time of the EEG recordings did not differ statistically between the groups.

Analysis of the EEG patterns in the α -synuclein stained clinDLB cases showed that the frequency of the dominant activity and the overall degree of EEG abnormality were the same in cases with and without LBs. None of the individuals with LBs exhibited side asymmetry, focal abnormalities or epileptiform activity as opposed to a total of 2 out of 8 individuals without LBs (table 2).

Discussion

Design and data

Retrospective analyses of clinical data risk containing incomplete and unsystematic clinical descriptions. However, our patients were part of a prospective, longitudinal dementia study, which started with a detailed neuropsychiatric assessment and was followed up with regular patient visits and special attention to the clinical course. The data for each patient was therefore considered to be sufficient for the retrospective diagnostic analysis. We are however, strongly aware of the problems of standardised evaluations of symptoms such as hallucinations and fluctuations especially in the retrospect. The original cohort consisted of consecutive cases, which were investigated due to a dementia disorder and followed up with post mortem neuropathological examination. The cases studied with rCBF and EEG in the present study were not selected in any systematic way compared to those not studied. Accordingly there were no differences in age, sex or medication between the cases studied and those not studied.

The clinically defined DLB cases in our study did not differ in demographic data and prevalence of clinical symptoms from populations with DLB in other studies of post mortem verified DLB cases (5, 47-49).

In our unselected dementia population the specificity of DLB, i.e. the percentage of the cases who fulfilled clinical criteria of DLB and also exhibited LBs neuropathologically, was very low, 38% (46). Our specificity was lower than that reported in earlier studies based on preselected neuropathologically diagnosed cases (50-56). Because of the low specificity and the lack of evidence that functional brain imaging could be used for diagnosing DLB, we decided to evaluate the EEG and rCBF in clinically diagnosed DLB cases with neuropathologically verified LBs.

Regional cerebral blood flow methods and results

A reduced global CBF level was seen in all our patient groups, a finding in agreement with findings in other studies of dementia (17). Clinical DLB based on current consensus definition, includes a spectrum of dementia conditions covering PaD with dementia as well as Lewy body variant of Alzheimer's disease (5,6). Our clinically defined DLB and AD groups showed a strikingly similar regional pattern with temporoparietal hypoperfusion and the specific contribution of the possible AD and PaD components in the DLB cases could therefore not be separated. The significant difference in rCBF in a small fronto-dorsal area has to be considered a spurious finding, as it cannot be related to any clinical difference between the groups.

A temporoparietal blood flow reduction pattern, not distinguishable from AD, is a common finding in clinically diagnosed DLB cases although sometimes combined with hypoperfusion in other areas. The temporoparietal rCBF pattern in our clinDLB and clinAD cases is in accordance with findings in several studies of clinically diagnosed DLB cases using SPECT and PET (29-31,57,58). However, we could not confirm the finding of an occipital blood flow reduction compared to AD shown with SPECT in 14 and 7 clinically investigated DLB cases (57,29) and using PET in 6 neuropathologically confirmed cases (59).

There was a very heterogeneous flow pathology in our present six cases with LBs, verified by α -synuclein staining, with rCBF patterns typical for AD (n=2), AD with VaD, VaD, MID, and FTD. Thus the rCBF patterns did here not reflect any pathology that could be linked to the presence of LBs. A detailed clinico-pathological analysis of these 6 cases will be presented in a forthcoming paper.

EEG

The highest sensitivity of EEG is shown in AD and in dementia in PaD (4,60,61). In AD the EEG abnormality has been found to correlate with the severity of the disease (60). In PaD, EEG has shown an abnormal diffuse increase in the degree of low frequency activity and a slowing of the occipital alpha frequency (32,62). Crystal et al (35) found abnormal EEG in patients with neuropathologically verified DLBD, when the subjects were still only mildly demented. The EEGs showed a slowing of the posterior background rhythm and generally a frontal dominant burst pattern. Other findings of EEG abnormalities reported in neuropathologically confirmed DLB patients have demonstrated a generalised slowing and the presence of sharp or triphasic waves (47,63-65). All these reports were, however, based on a limited number of cases. In a recent report, Briel et al (66) compared EEG recordings from DLB and AD cases with confirmed neuropathological diagnoses. They found a more marked slowing of EEG activity in the DLB group and related this to the more severe loss of choline acetyltransferase activity found in DLB (67). There was no evidence, however, that this difference existed between our clinically defined DLB and AD groups or even between the cases, in the clinDLB, with and without LBs. The mean frequency of dominant activity in all the investigated groups was within the theta frequency band. The pathophysiological mechanisms of slow waves in the 4-8 Hz range (theta) are not well known. Theta activity often represents a slowing down of the alpha activity and will thus become the dominant activity. Such a slowing of the background activity is seen in mild to moderate hypoxia, cerebrovascular disease, in dementias and in mild degrees of metabolic encephalopathies (68). The main neuropathological finding in our investigated groups was the Alzheimer pathology, which in combination with the substantia nigra degeneration was considered to be a sufficient explanation for the EEG patterns.

Conclusions

The main findings of this study were that the brain imaging patterns of rCBF and EEG could not differentiate between cases with clinically defined DLB and cases with clinically defined AD. When the cases with and without neuropathologically verified LBs were compared, EEG and rCBF did not exhibit any patterns supportive of, or helpful in, the diagnosis of DLB *in vivo*. The possible cortical impact of LB pathology did not produce any specific or consistent expression in rCBF or EEG in our patients. The prevalent Alzheimer pathology was in our cases a likely correlate to the main imaging patterns. The result of the study illustrates the limited specificity of clinical diagnostic criteria, routine EEG and rCBF in predicting specific LB pathology. Single case evaluations of brain imaging findings in relation to the clinical picture and neuropathology are necessary to establish the impact and relative contribution of the different pathologies involved in DLB.

Acknowledgement

This study was supported by the Alzheimer foundation, Sweden, the Sjöbring foundation, stiftelsen Gamla trotjänarinnor and the Swedish Medical Research Council, projects no 0084, 3950 and 4969. Maria Sjöström and Siv Börjesson are acknowledged for expert technical assistance with pictures and tables.

References

1. Newberg AB, Alavi A, Payer F. Single photon emission computed tomography in Alzheimer's disease and related disorders. *Neuroimag Clin North Am.* 1995;**5**:103-123.
2. Waldemar G. Functional brain imaging with SPECT in normal aging and dementia. Methodological, pathophysiological, and diagnostic aspects. *Cerebrovasc Brain Metab Rev* 1995;**7**:89-130.
3. Jagust WJ, Hohmann KA, Holman BL. SPECT perfusion imaging in the diagnosis of dementia. *J Neuroimag.* 1995;**5**: S45-S52.
4. Jóhannesson G, Brun A, Gustafson L, Ingvar D: EEG in presenile dementia related to cerebral blood flow and autopsy findings. *Acta Neurol Scand* 1977; **56**: 89-103.
5. Perry RH, Irving D, Blessed G, Perry, EK, Fairbairn AF: Senile dementia of Lewy body type. A clinically and neuropathologically distinct type of Lewy body dementia in the elderly. *J Neurol Sci* 1990;**95**: 119-139.
6. Hansen L, Salmon P, Galasko D, Masliah E, Katzman E, DeTeresa R: The Lewy body variant of Alzheimer's disease: a clinical and pathological entity. *Neurology* 1990; **40**: 1-8.
7. Lennox G, Lowe J, Landon M, Byrne EJ, Mayer RJ, Godwin-Austen RB: Diffuse Lewy body disease: correlative neuropathology using anti-ubiquitin immunocytochemistry. *J Neurol Neurosurg Psychiatr.* 1989;**52** :1236-1247.
8. Shergill S, Mullan E, D'At P, Katma C: What is the clinical prevalence of Lewy body dementia? *Int J Ger Psychiatry* 1994; **9** :907-912.
9. Kosaka K, Yoshimura M, Ikeda K, Budka H: Diffuse type of Lewy body disease: progressive dementia with abundant cortical Lewy bodies and senile changes of varying degree-a new disease? *Clin neuropathol* 1984;**3**: 185-192.
10. McKeith IG, Galasko D, Kosaka K, et al: Consensus guidelines for the clinical and pathological diagnosis of dementia with Lewy bodies (DLB). *Neurology* 1996; **47**: 113-124.
11. Lassen NA. Cerebral blood flow and oxygen consumption in man. *Physiol Rev.* 1960;**39**: 183-238.
12. Ingvar DH, Risberg J. Increase of regional cerebral blood flow during mental effort in normals and in patients with focal brain disorders. *Exp Brain Res.* 1967;**3**: 195-211.
13. Ingvar DH, Gustafson L. Regional cerebral blood flow in organic dementia with early onset. *Acta Neurol Scand.* 1970;**46**: 42-73.
14. Ingvar DH. Patterns of brain activity revealed by measurements of regional cerebral blood flow. In: Ingvar DH, Lassen NA., eds. Copenhagen: Brain Work, Munkgaard, 1975:379-413.
15. Gustafson L, Risberg J. Regional cerebral blood measurements by the ¹³³Xe inhalation technique in differential diagnosis of dementia. *Acta Neurol Scand.* 1979; (suppl 72) **60**: 546-547.
16. Friedland RP, Budinger TF, Ganz E, Yano Y, Mathis CA, Koss B, Ober BA, Huesman RH, Derenzo SE. Regional cerebral metabolic alterations in dementia of the Alzheimer type: Positron emission tomography with [¹⁸F] Fluorodeoxyglucose. *J Comp Ass Tomography.* 1983;**7**(4): 590-598.
17. Risberg J, Gustafson L. Regional cerebral blood flow measurements in the clinical evaluation of demented patients. *Dement Geriatr Cogn Disord.* 1997;**8**: 92-97.
18. Risberg J. Frontal lobe degeneration of non-Alzheimer type.III. Regional cerebral blood flow. *Arch Geront Geriatr,* 1987; **6**:225-233.

19. Neary D, Snowden JS, Shields RA, Burjan AWI, Northen B, Madermott N, Prescott MC, Testa HJ. Single photon emission tomography using ^{99m}Tc -AM-PM in the investigation of dementia. *J Neurol Neurosurg Psychiatry*, 1987;**50**:1101-1109.
20. Miller BL, Cummings JL, Villanueva-Meyer J, Boone K, Mehninger CM, Lesser IM, Mena I. Frontal lobe degeneration: Clinical, neuropsychological and SPECT characteristics. *Neurology*, 1991; **42**: 1374-1382.
21. Risberg J, Gustafson L. Regional cerebral blood flow measurements in the clinical evaluation of demented patients. *Dement Geriatr Cogn Disord*. 1997;**8**:92-97.
22. Pizzolato G, Dam M, Borsato N, Saitta B, Da Col C, Perlotto N, Zanco P, Ferlin G, Battistin L. ^{99m}Tc -HM-PAO-SPECT in Parkinson's disease. *J Cereb Blood Flow Metab*. 1988;**8**:S101-S108.
23. Spampinato U, Habert O, Mas JL, Bourdel MC, Ziegler M, de Recondo J, Askienazy S, Rondot P. ^{99m}Tc - HM-PAO-SPECT and cognitive impairment in Parkinson's disease: a comparison with dementia of the Alzheimer type. *J Neurol Neurosurg Psychiatry* 1991;**54**: 787-792.
24. Liu RS, Lin KN, Wang SJ, Shan DE, Fuh JL, Yeh SH, Liu HC. Cognition and ^{99m}Tc -HMPAO SPECT in Parkinson's disease. *Nuclear Medicine Communications*. 1992;**13**: 774-748.
25. Kuhl DE. Imaging local brain function with emission computed tomography. *Radiology*. 1984;**150**: 625-631.
26. Miller BL, Urrutia LE, Cornford M, Mena I. The clinical and functional imaging characteristics of Parkinsonian dementia. In: Perry R, McKeith I, Perry E., eds. *Dementia with Lewy bodies – clinical, pathological and treatment issues*. Cambridge: Cambridge University press, 1996:132-144.
27. Gustafson L, Brun A, Risberg J. Organic dementia: Clinical picture related to regional cerebral blood flow and neuropathology findings. In: Pichot P, Berger P, Wolf R, Thau K., eds. *Psychiatry. Vol 2*. New York: Plenum Publ Co, 1985: 605-611.
28. Warkentin S, Passant U, Brun A, Risberg J, Gustafson L. Cerebral blood flow in dementia related to neuropathological findings. *J Cerebr Blood Flow Metab*. 1993;**13**: 234.
29. Donnemiller E, Heilmann J, Wenning GK, Berger W, Decristoforo C, Moncayo R, Poewe W, Ransmayr G. Brain perfusion scintigraphy with ^{99m}Tc -HMPAO or ^{99m}Tc -ECD and ^{123}I - β -CIT single-photon emission tomography in dementia of the Alzheimer-type and diffuse Lewy body disease. *Eur J Nuc Med*. 1997;**24**: 320-325.
30. Turjanski N, Brooks DJ. PET and the investigation of dementia in the parkinsonian patient. *J Neural Transm*. 1997(suppl);**51**: 37-48.
31. Varma AR, Talbot PR, Snowden JS, Lloyd JJ, Testa HJ, Neary D. A ^{99m}Tc -HMPAO single-photon emission computed tomography study of Lewy body disease. *J Neurol*. 1997;**244**: 349-359.
32. Neufeldt MY, Blumen S, Aitkin I, Parmet Y, Korczyn AD: EEG frequency analysis in demented and nondemented parkinsonian patients. *Dementia* 1994;**5**: 23-28.
33. Petit D, Montplaisir J, Reikkinen PJ Sr, Soinen H, Reikkinen P Jr: Electrophysiological test. In Gauthier S., ed. *Clinical Diagnosis and Management of Alzheimer's Disease*. London: Dunitz, 1996: 107-127.
34. Rosén I: Multichannel EEG frequency analysis and somatosensory-evoked potentials in patients with different types of organic dementia. *Dementia* 1993; **4**: 43-49.
35. Crystal HA, Dickson DW, Lizardi JE, Davies P, Wolfson LI: Antemortem diagnosis of diffuse Lewy body disease. *Neurology* 1990;**40**: 1523-1528.

36. Kosaka K. Lewy bodies in cerebral cortex. Report of three cases. *Acta Neuropathol.* 1978;**42**: 127-134.
37. Lennox G, Lowe J, Landon M, Byrne EJ, Mayer RJ, Godwin-Austen R. 1989. Diffuse Lewy body disease: correlative neuropathology using anti ubiquitin immunocytochemistry. *J Neurol Neurosurg Psychiatry.* **52**: 1236-47.
38. Samuel W, Galasko D, Masliah E, Hansen LA. Neocortical Lewy body counts correlate with dementia in the Lewy body variant of Alzheimer's disease. *J of Neuropathology and Exp neurology.* 1996;**55**: (1) 44-52.
39. Gustafson L, Hagberg B: Dementia with onset in the presenile period. *Acta Psychiatr Scand* 1975; Suppl 257: 1-71.
40. Brun A, Gustafson L: The longitudinal dementia study: A 25- year perspective on neuropathology, differential diagnoses and treatment. In Corain B, Iqbal K, Nicolini M, Winblad B, Wiesniewski H, Zatta P., eds. *Alzheimer's disease advances in clinical an basic research.* New York: John Wiley and Sons Ltd, 1993: 3-18.
41. McKhann G, Drachman D, Folstein M, Karzman R, Pride D, Stadlan E: Clinical diagnosis of Alzheimer's disease: Report from the NINCDS-ADRDA work group under the auspices of department of Health and Human Service Task Force on Alzheimer's disease. *Neurology* 1984;**34**: 939-943.
42. Brun A, Englund E. 1981. The pattern of degeneration in Alzheimer's disease. Neuronal loss and histopathological grading. *Histopathology.* **5**: 549-64.
43. Obrist WD, Thompson HK, Wang HS, Wilkinson WE. Regional cerebral blood flow by 133-xenon inhalation. *Stroke.* 1975;**6**: 245-256.
44. Risberg J, Ali Z, Wilson EM, Wills EL, Halsey JH. Regional cerebral blood flow by 133-xenon inhalation. *Stroke.* 1975;**6**: 142-148.
45. Risberg J. 1980. Regional cerebral blood flow measurements by 133 Xe-inhalation: methodology and applications in neuropsychology and psychiatry. *Brain and Language.* **9**:9-34.
46. Lontos E, Passant U, Brun A, Gustafson L. The neuropathological correlates of clinically diagnosed dementia with Lewy bodies and Alzheimer's disease. (Submitted)
47. Byrne E J, Lennox G, Lowe J, Godwin-Austen RB: Diffuse Lewy body disease: clinical features in 15 cases. *J Neurol Neurosurg Psychiatry* 1989;**52**: 709-717.
48. Lennox G: Lewy body dementia. In Byres C., ed. *Baillière's Clinical neurology – unusual dementias.* London: Baillière Tindall, 1992, vol 1, 3, pp 661-662.
49. McKeith IG, Fairbairn AF, Bothwell RA, Moore PB, Ferrier IN, Thompson P, Perry RH: An evaluation of the predictive validity and interrater reliability of clinical diagnostic criteria for SDLT. *Neurology* 1994; **44**: 872-877.
50. Mega MS, Masterman DL, Benson F et al. Dementia with Lewy bodies: reliability and validity of clinical and pathological criteria. *Neurology.* 1996;**47**: 1403-1409.
51. McShane RH, Esiri MM, Joachim C, Smith AC, Jacoby, RJ. Prospective evaluation of diagnostic criteria for dementia with Lewy bodies. *Neurobiol Aging.* 1998;**19** (4S):204.
52. McKeith IG, Ballard CG, Perry RH, Ince PJ, Jaros E, Neill D, O'Brien JT. 1998. Predictive accuracy of clinical diagnostic criteria for dementia with Lewy bodies: a prospective neuropathological validation study. *Neurology.* **50(4)**: A181-182. S1302.
53. Luis CA, Barker WW, Gajraj D, et al. Sensitivity and specificity of three clinical criteria for dementia with Lewy bodies in an autopsy-verified sample. *Int J Geriat Psychiatry* 1999;**14**: 526-533.

54. Litvan I, McIntyre A, Goetz CG et al. Accuracy of the clinical diagnoses of Lewy body disease, Parkinson's disease and dementia with Lewy bodies. *Arch Neurol*. 1998;**55**: 969-978.
55. Papka M, Schiffer R, Rubio A. Diagnosing Lewy body disease, accuracy of clinical criteria in detecting Lewy body pathology. *Neurobiol Aging*. 1998;**19**(4S): 203.
56. Holmes C, Cairns N, Lantos P, Mann A. Validity of current clinical criteria for Alzheimer's disease, vascular dementia and dementia with Lewy bodies. *Br J Psychiatry*. 1999;**174**: 45-51.
57. Ishii K, Yamaji S, Kitagaki H, Imamura T, Hirono N, Mori E. Regional cerebral blood flow difference between dementia with Lewy bodies and AD. *Neurology*. 1999;**53**: 413-416.
58. Defebvre LJ, Leduc V, Duhamel A, Lecouffe P, Pasquier F, Lamy-Lhullier C, Steinling M, Destee A. Technetium HMPAO SPECT study in dementia with Lewy bodies, Alzheimer's disease and idiopathic Parkinson's disease. *J Nucl Med*. 1999;**40**: 956-962.
59. Albin RL, Minoshima S, Dámató CJ, Frey KA, Kuhl DA, Sima AAF. Fluoro-deoxyglucose positron emission tomography in diffuse Lewy body disease. *Neurology*. 1996;**47**: 462-466.
60. Soininen H, Pastanen V, Helkala E-L, Reikkinen P. EEG findings in senile dementia and normal aging. *Acta Neurol Scand* 1982;**65**: 59-70.
61. Neufeldt M, Inzelberg R, Korczyn A: EEG in demented and nondemented parkinsonian patients. *Acta Neurol Scand* 1988; **78**: 1-5.
62. Soikkeli R, Partanen J, Soininen H, Pääkkönen A, Reikinen P: Slowing of EEG in Parkinson's disease. *Electroencephalogr Clin Neurophysiol*. 1991;**79**: 159-165.
63. Burkhardt CR, Filley CM, Kleinschmidt-DeMasters BK, de la Monte S, Norenberg MD, Schneck SA: Diffuse Lewy body disease and progressive dementia. *Neurology* 1988;**38**: 1520-1528.
64. Yamamoto T, Terukuni I: A case of diffuse Lewy body and Alzheimer's diseases with periodic synchronous discharges. *J Neuropathol Exp Neurol* 1988;**47**: 5: 536-548.
65. Gibb WRG, Luthert PJ, Janota I, Lantos PC: Cortical Lewy body dementia: clinical features and classification. *J Neurol Neurosurg Psychiatry* 1989;**52**: 185-192.
66. Briel RCG, McKieth IG, Barker WA, Hewitt Y, Perry RH, Ince PG, Fairbairn AF: EEG findings in dementia with Lewy bodies and Alzheimer's disease. *J Neurol Neurosurg Psychiatry* 1999;**66**: 401-403.
67. Perry EK, Haroutunian V, Davis DL, Levy R, Lantos P, Eagger S, Honavar M, Dean A, Griffiths M, McKeith IG, Perry R: Neocortical cholinergic activities differentiate Lewy body dementia from classical Alzheimer's disease. *Neuroreport* 1994;**5**: 747-749.
68. Binnie C, Prior P: Electroencephalography. *J Neurol Neurosurg Psychiatry*. 1994;**57**: 1309-1319.

Table 1.

Demographic data (mean and range) of cases with clinically defined dementia with Lewy bodies (clinDLB) and Alzheimer's disease (clinAD) investigated with EEG and rCBF measurements

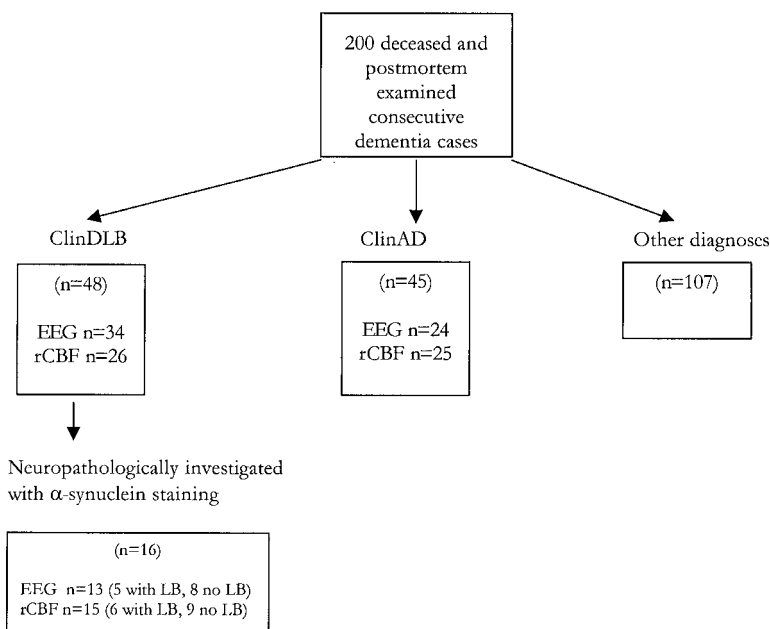
	clinDLB		clinAD	
	EEG	rCBF	EEG	rCBF
N	34	26	28	25
Male/Female	15/19	14/11	11/17	9/16
Age at death	77 (60-94)	77 (60-94)	81 (61-91)	79 (73-88)
Age of onset	70 (52-82)	70 (54-82)	72 (55-86)	72 (65-81)
Dementia duration	7.3 (1-16)	7.2 (1-14)	8.5 (2-19)	7.4(3-11)

Table 2.

EEG findings in clinically defined dementia with Lewy bodies (clinDLB) and Alzheimer's disease (clinAD) and subgroups of clinDLB after α -synuclein investigation

	Total material		clinDLB studied with α -synuclein	
	clinDLB n=34	clinAD n=28	with LB n=5	no LB n=8
Dominating activity frequency (Hz)	6,3 \pm 1,3	6,6 \pm 1,1	6,0 \pm 1,4	6,4 \pm 1,6
Degree of abnormality	3,4 \pm 0,8	3,4 \pm 0,7	3,4 \pm 0,9	3,4 \pm 0,9
Focal abnormality	2 (5,9%)	2 (7,1%)	0 (0%)	2 (25%)
Epileptiform activity	2 (5,9%)	4 (14,3%)	0 (0%)	1 (12,5%)
Side asymmetry	5 (14,7%)	6 (21,4%)	0 (0%)	2 (25%)

Fig 1.
Design of the study.



ClinDLB=clinically diagnosed Dementia with Lewy bodies
ClinAD= clinically diagnosed Alzheimer's disease

Fig 2.Regional cerebral blood flow in clinically defined cases with Alzheimer's disease (clinAD) and dementia with Lewy bodies (clinDLB). **Topographic group mean rCBF patterns during rest showing the vertex view of the cerebral cortex, with the frontal pole at the top, and left hemisphere to the left. The colours represent flow distribution normalised (ISI, regional values in percent of the hemisphere mean), as defined by the colour key to the right.**

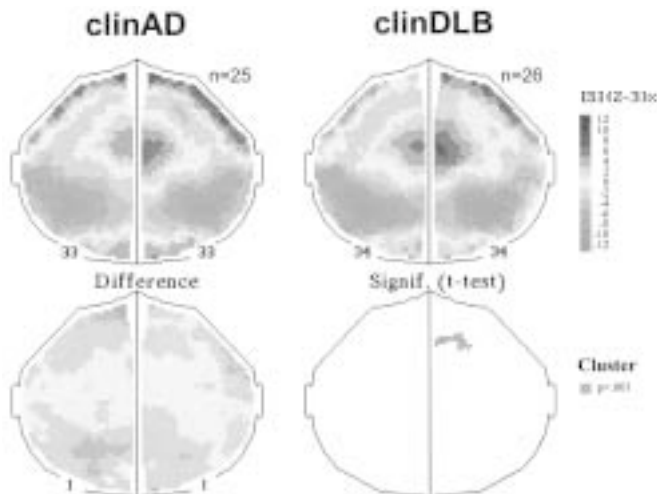
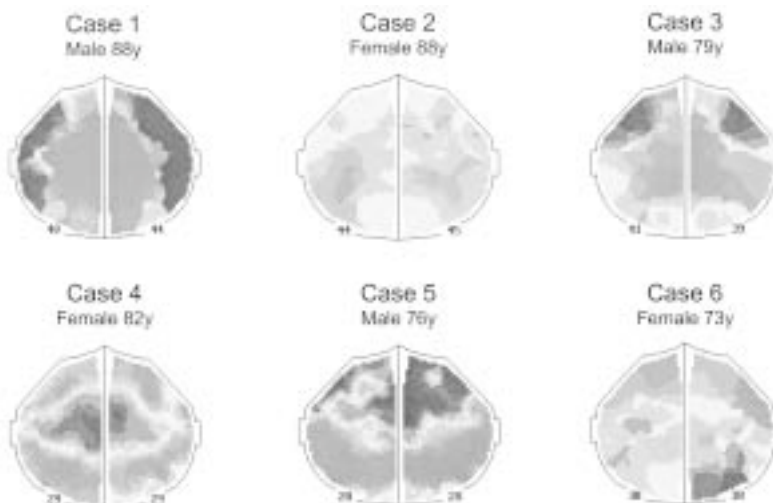


Fig 3.

Regional cerebral blood flow in 6 cases with clinical Dementia with Lewy bodies and Lewy bodies neuropathologically. Asymmetries were seen in case 1,2,5,6 and localised in different brain areas; 2 frontally, 1 temporally and 1 occipitally. Frontal hypoperfusion was seen in case 2,4 and 6 and postcentral hypoperfusion in cases 1,3,4 and 5. (Note that cases 1,2,3 and 6 were assessed with 32 detectors and cases 4 and 5 with 254 detectors).



V

Contributions of other brain pathologies in Dementia with Lewy bodies

E. Londos, U. Passant, J. Risberg, L. Gustafson, A. Brun

Department of psychogeriatrics and Pathology, University hospital, Lund, Sweden

Running title: Clinical pathological correlation in DLB

Key words: Dementia with Lewy bodies, Alzheimer's disease, neuropathology, clinico pathological correlations, cerebral blood flow, blood pressure

Corresponding address:

Elisabet Londos, MD

Department of Psychogeriatrics

Lund University hospital

221 85 Lund, Sweden

Tel no: +46 – 46 17 74 63

Fax no: +46 – 46 – 17 74 57

E-mail: elisabet.londos@psykiatr.lu.se

Abstract

The clinical picture with its pathological correlate was analysed in sixteen patients fulfilling Dementia with Lewy bodies (DLB) consensus criteria. The cases were part of a larger cohort (n=200) of patients within a prospective longitudinal study of dementing disorders. Six cases exhibited not only Lewy bodies but also other brain pathologies such as Alzheimer changes, multiple infarcts or complete and incomplete white matter infarcts. Degeneration of the nucleus basalis Meynert and substantia nigra was also seen. The 10 cases without Lewy bodies all had Alzheimer changes. In 7 cases these changes were combined with mainly incomplete frontal white matter infarcts. However, the degeneration of brainstem nuclei was less pronounced in these cases. Symptoms such as fluctuations in cognition, falls and episodic confusion appeared in association with arterial hypotension which developed during the course of dementia in almost all the 16 cases. The majority of the cases were treated with neuroleptics and other potentially hypotensive medication. The study shows that multiple and different clinico-pathological features may contribute to a clinical symptom constellation as in DLB. The case-study approach reveals the complexity of clinico-pathological relationships in dementia that might otherwise be lost in the analysis of larger group data.

Introduction

Dementia syndromes may be classified on the basis of the major type but above all on the basis of the distribution of pathology in the brain. Some disorders mainly affect cortical structures and regions while others have a more subcortical predominance or affect both structural levels. Alzheimer's disease (AD) and the dominating forms of frontotemporal dementia (FTD) are the major types of predominantly cortical degenerative dementias while progressive supra nuclear palsy, Huntington's disease, Parkinson's disease (PaD) and Binswanger's disease show predominant subcortical involvement [1]. Dementia with Lewy bodies (DLB) belongs to the mixed cortical-subcortical category [2]. The characteristic pathological structure, the Lewy body, is localized in both the brainstem, hypothalamus and in the cortex, in which region also Alzheimer type degeneration is present in the majority of cases. It has been claimed that DLB causes 10-20% of all organic dementias in the elderly [3-6]. The clinical picture of DLB has been described in the consensus documents [7] as a progressive dementia syndrome with extrapyramidal signs (EPS), fluctuations in cognition, visual hallucinations, neuroleptic sensitivity, multiple falls, auditory hallucinations, delusions, syncope and transient loss of consciousness. A diagnosis of DLB is less likely in the presence of neuroimaging or clinical neurological signs of stroke.

The clinical impact of Lewy bodies (LBs) per se, is however, only partially known. The LB, when localised in the brainstem, is a neuropathological hallmark of PaD [8,9]. It is possible to explain EPS, dysphagia and autonomic failure because of the specific locations of LBs in the substantia nigra, dorsal vagal nucleus and sympathetic ganglia [10-12]. The clinical description of "DLB" however, includes a spectrum of neuropathological pictures, from cases with large amounts of diffusely spread LBs without other pathology "pure LB" (also known as "diffuse Lewy body disease"- "DLBD pure type" [13]) to cases with AD and a few nigral LBs (also called "The Lewy body variant of Alzheimer's disease"-LBV [4,14], "Senile dementia of Lewy body type"-SDLT, [15] = "DLBD, common type" [13]). Dementia severity in DLB has been related to density of LBs in the cortex [3,16,17] although in a recent prospective study no correlation was found

between LBs and clinical features [18] It seems logical that high density massively spread cortical LBs might cause a dementia syndrome. It is, however, more difficult to predict the clinical role of LBs located in the brainstem or the sparse cortical LBs in many cases. It is also difficult to predict the effects of interaction between LBs and other brain pathologies.

The aims of the investigation were

to describe and critically compare the clinical and neuropathological data in clinically diagnosed DLB cases with (n=6) and without (n=10) LBs and

to evaluate the clinical expression of the different brain pathologies in these cases.

Patients and methods

In the present study we have applied the clinical criteria of DLB [7] retrospectively on a cohort of 200 consecutive neuropathologically investigated dementia cases all being part of a prospective longitudinal dementia study [19]. The patients were evaluated and followed clinically. The investigations included neuropsychiatric and neurologic evaluations and neuropsychological assessments and routine laboratory testing combined with different forms of brain imaging such as regional cerebral blood flow (rCBF) measurement, computerised tomography (CT) and electroencephalography (EEG). The patients died between 1985-1994, which means that a clinical diagnosis DLB was not considered when they were alive. Diagnostic criteria for DLB, AD, vascular dementia (VaD) and FTD were applied to their medical records. As reported in previous publications 48 cases fulfilled the clinical criteria for DLB alone or combined with AD (and 45 fulfilled clinical criteria for AD only) [20]. Detailed extensive neuropathological reports were available in all cases. Sixteen randomly selected clinical DLB and 10 clinical AD cases were reassessed with α -synuclein staining for sensitive detection of LBs. These cases did not differ from the larger clinical DLB group with regard to gender, age of onset of dementia, dementia duration or other clinical aspects. Six clinical DLB and 4 clinical AD cases exhibited LBs neuropathologically. The 6 cases with clinical DLB and LBs verified neuropathologically were further analysed in the present study and compared to the 10 clinical DLB cases without LBs. Neuropathology findings were correlated to clinical ratings, rCBF and DLB symptoms and interpreted individually and groupwise.

Neuropathological methods

The procedures included whole brain semi-serial sectioning with subsequent extensive microscopical analysis which is a prerequisite for a safe neuropathological mapping of type, severity and distribution of changes and also for the exclusion or verification of other types of brain pathology. Stainings used were Hematoxylin/Eosin, Luxol Fast Blue with cresyl violet counter staining, Congo red, Van Gieson-elastica, Campbell and Gallyas methods and immunostainings with GFAP, β -amyloid and ubiquitin. LBs were defined as rounded, non-fibrillary, ubiquitin immunoreactive inclusions. The regional distribution and severity of the grey matter Alzheimer pathology were mapped semiquantitatively, combining a number of histological variables such as neuronal loss, gliosis, microvacuolization, neurofibrillary tangles, senile plaques and dystrophic neurites [21]. The vascular pathology was mapped, with regard to regional distribution and severity of complete infarcts and selective incomplete white matter infarcts (SIWI). SIWI is characterized by a reduction of both myelin and oligodendroglial cells with mild astrocytic reaction [22].

The whole brain semiserial sectioning investigation was, in the randomly selected cases, supplemented by the examination of tissue sections from the mesencephalon, cingulate gyrus, hypothalamus, parietal cortex, frontal pole cortex and the basal temporal cortex which includes hippocampus stained with antibodies against α -synuclein, tau, ubiquitin and GFAP.

Regional cerebral blood flow

The rCBF was assessed with the xenon-133 inhalation method using the Initial Slope Index (ISI) as an indicator of cortical blood flow [23-25]. The inert γ -radiating tracer xenon-133 (90 MBq/l) was inhaled for 1 min through a facemask, followed by 10 min breathing of ordinary air. Until 1986 the rCBF was assessed with a 32-detector device. This was then replaced by a high resolution recording system with 254 scintillation detectors (Cortexplorer 256 HR; Ceretronix Inc, Randers, Denmark), which gives a spatial resolution of about one cm for the superficial cortex. rCBF measurements were available in 15 cases. Five of the present cases had 32 detector recordings and the remaining ten had 254 detector recordings. The individual rCBF results are displayed as interpolated flow maps with a colour coding of the regional values as a percentage of the individual mean flow [26].

Rating scales

Clinical rating scales for recognition of AD, VaD and FTD were applied to the medical records. The clinical usefulness of the scoring profile of these diagnostic rating-scales has been validated against neuropathology and brain imaging [19,27,28]. The AD score was based on 12 items with a maximum score of 17 and a score of 5 or above indicating AD [29,19]. The ischemic score was based on 13 items with a maximum score of 18 and a score of 8 or above indicating vascular aetiology [30]. The FTD score was based on 9 items with a maximum score of 13 and a score of 5 or above indicating frontal lobe dysfunction [29,19].

Statistical methods

The Students t-test was used to compare the means of basic characteristics in table 1 and the means of differential diagnostic scoring table 2.

Results

The basic characteristics of the 6 LB positive and 10 LB negative clinical DLB cases are presented in table 1. These data do not differ significantly from each other or from those of the total group (n=200) originally investigated. The age of onset of dementia in this group was 70 ± 10.3 years, age at death was 77 ± 10.1 years and dementia duration was 7 ± 3.8 years.

The clinical course of the 6 LB positive patients is presented in figures 1-6, together with rCBF and neuropathological findings. The patients' blood pressure is expressed as mean arterial blood pressure (MABP), which was calculated in the following way:

$$\text{MABP} = \text{diastolic} + \frac{\text{systolic} - \text{diastolic}}{3}$$

Blood pressure recordings from the last month of life were not included.

Neuropathology

The neuropathological data are presented in tables 2 and 3ab.

LB positive cases. Four cases (no 1,2,4,6) had a moderate degeneration of the SN, with LBs in two cases. One additional case (no 5) exhibited LBs in the SN without other degenerative changes. LBs were present in the NbM or hypothalamus in 4 cases. Four cases had cortical LBs although only a small number was evident in 3 cases. Four cases showed degeneration of locus coeruleus (LC). The cases with most LBs also had varying degrees of SN and LC degeneration ranging from moderate to severe. Vascular pathology with cortical and subcortical complete and incomplete infarcts was present in 2 cases (no 1 and 2).

The results of the different neuropathological grading systems for the evaluation of the AD pathology, which was applied on the 6 cases, are shown in table 4. The dementia condition in 3 cases was considered to be due to the AD pathology (highly likely) while in 2 cases the likelihood was intermediate.

LB negative cases. All 10 cases had Alzheimer changes combined with SIWI. A frontal location was especially evident in 7 cases. Complete infarcts of varying sizes were present in 5 of these 7 cases. The Alzheimer pathology when graded according to Brun and Englund [21] was generally more severe compared to the grading of the other systems.

Diagnostic rating scales and neuropathology

The results of the differential diagnostic ratings are presented in table 4 and related to neuropathological findings in tables 2 and 3ab.

LB positive cases. All 6 cases had an AD score=6 indicating Alzheimer type of dementia and showed a significant Alzheimer pathology at the neuropathological examination. Only case 4 exhibited degeneration of non-Alzheimer type, where involvement of temporo-parietal areas probably contributed to the high AD score. The high ischemic score in case 1 correctly indicated vascular pathology. Case 2 with AD score 8 and IS 4 had mixed Alzheimer and vascular pathology. The high AD score was probably due to the temporo-parietal co-location of Alzheimer changes and infarcts. The high FTD scores in cases 3,4 and 5 indicated frontal lobe dysfunction. Case 4 had advanced FLD. Cases 3 and 5 showed late onset of dementia as well as the highest age at death. This is commonly associated with a more general distribution of pathology implying more frontal changes [30]. All patients, except case no 3, had neuronal loss and/or LBs in subcortical structures such as SN.

LB negative cases. Nine out of 10 cases had an AD score of 6 or more, correctly indicating Alzheimer neuropathological changes. Five cases had an FTD score of 5 or above indicating frontal lobe dysfunction. Two cases had a comparably high IS (no 10 and 15) and both cases had significant vascular brain pathology. On the other hand IS was not indicating vascular pathology in 5 cases which had confirmed neuropathological white matter incomplete infarcts. Three out of 6 cases with frontal SIWI had signs of frontal dysfunction according to the FTD score.

Regional cerebral blood flow and neuropathology patterns

The rCBF of the 6 LB positive cases is shown in fig 1-6 while that of the LB negative cases is illustrated in fig 7.

LB positive cases. In cases 1, 2, 4 and 5 the rCBF pathology and neuropathological changes (AD, infarcts, white matter pathology and degeneration of non Alzheimer type) matched to a major extent (figures 1-6). The rCBF in case 5 was measured with the 32 detector device and for technical reasons the recording was difficult to interpret. In case 3 the rCBF and neuropathological patterns were similar, although, the rCBF severity was less marked than that of the

neuropathology. In case 6 the frontotemporal areas were relatively spared with regard to rCBF, although the neuropathological study only showed diffuse frontal microvacuolisation.

LB negative cases. In all 9 available rCBF recordings there was a temporo parietal, sometimes combined with frontal, blood flow decrease. Six of these had 254 detector recordings and are shown in fig 7.

Blood pressure, pharmacological treatment and cardiac disease

LB positive cases. As shown in figures 1-6, the MABP decreased in all 6 LB positive cases during the progression of dementia. The decrease expressed as a percentage of the latest “predementia” MABP value, averaged 28% and ranged from 17 to 37%. Three cases (no 1, 2 and 6) had a history of hypertension and at least two of them had received longstanding antihypertensive treatment. Two cases (no 1 and 6) were also highly orthostatic with blood pressure falls from 150/105 (lying) to 115/85 (immediately standing) and from 150/80 to 120/80. Five cases received neuroleptics. One case (no 1) had atrial fibrillation.

LB negative cases. The MABP decreased in 7 of the 10 LB negative cases during dementia. Corresponding average MABP decrease compared to predementia values was 18% ranging from a 3% increase to a 36% decrease. One patient (no 14) had a history of previous hypertension and became hypotensive and orthostatic. Three additional cases (no 8, 9 and 16) also showed orthostatic blood pressure reactions.

Of the 5 cases with cardiac diseases 2 had angina pectoris, 3 had cardiac incompensation in one case combined with atrial fibrillation. Six of the 7 cases who showed MABP decrease during dementia were treated with neuroleptics and 2 had also received diuretics.

Core symptoms, neuroleptic sensitivity and neuropathology

Core symptoms of the clinical diagnosis of DLB in the 16 cases are presented in table 5 and neuropathological results in table 2 and 3ab. There were no major differences in core symptoms between LB positive and negative cases.

Hallucinations.

LB positive cases. Three cases had visual hallucinations. All three showed hippocampal and temporal AD, one had visual impairment and the other two had some kind of occipital pathology (infarct or microvacuolisation). All three cases with auditory hallucinations (no 3, 5 and 6) had impaired hearing. Case 6 was the only one who developed delusions and who later received antiparkinson medication.

LB negative cases. Four cases had visual hallucinations. Three had moderate to severe temporal AD and the fourth had occipital pathology. The only case with visual impairment also had visual hallucinations. In one case the visual hallucinations were combined with auditory hallucinations. In two cases the type of hallucinations was not specified. Both these cases had temporal and hippocampal Alzheimer pathology.

Extrapyramidal symptoms (EPS).

LB positive cases. All 6 cases suffered from some kind of muscular rigidity while all 4 cases (no 1, 2, 4 and 6) with SN degeneration had bradykinesia. Three of the 4 cases with SN degeneration exhibited tremor as opposed to none among the cases without SN degeneration. The cases with SN degeneration had 3 or more EPS. The 2 cases without SN degeneration showed 2 EPS each.

LB negative cases. Six of 10 cases suffered from muscular rigidity. Five cases had bradykinesia.

Three cases displayed mild SN degeneration. There was no specific pattern of EPS in these 3 cases. Six of 7 cases with frontal white matter pathology exhibited EPS, 5 of these had muscular rigidity and 5 had gait disturbance.

Neuroleptic sensitivity

LB positive cases. Neuroleptic sensitivity was seen in cases 1, 2, 5 and 6. The type of sensitivity described is shown in table 5. Moderate SN degeneration was found in 4 cases (no 1, 2, 4 and 6) of which 3 exhibited Lewy bodies. One additional case without SN degeneration also had nigral LBs. Case 4 with SN degeneration and nigral LBs had not received neuroleptics, and a possible neuroleptic sensitivity was therefore not established. Two cases had shown EPS before they received neuroleptics.

LB negative cases. Neuroleptic sensitivity was reported in 6 of 10 cases. None of these had SN degeneration but 4 had frontal white matter pathology. In 7 of 8 cases EPS were not seen before neuroleptic treatment.

Discussion

The initial description of Dementia with Lewy bodies [5,17] was based on neuropathologically studied cases and a specific symptom constellation was defined based on the retrospective analyses of these cases. Our intention was to reverse this analytic approach and to study the neuropathological picture of cases with clinical DLB. The expectation was that these cases would present important pathological similarities, even if clinical features do not always share the same neuropathological substrate.

The study was based on neuropathologically investigated dementia cases (n=200) within the frame of a longitudinal study [19]. The cases were selected consecutively according to the date of death. Clinical and neuropathological data from these cases have been reported previously [20]. Among 48 cases with clinical DLB diagnosis, 16 randomly selected cases were investigated with α -synuclein for sensitive detection of LB pathology (this staining was not available at the initial neuropathological examination). These 16 cases form the target group of this study.

It is important to note that the term “diagnosis” is used here in three different ways: firstly, the initial clinical diagnosis which was made when the patients were still alive and when consensus DLB criteria were not yet developed; secondly, the clinical diagnosis based on retrospective analysis of the total course of illness using new clinical criteria; thirdly, the neuropathological diagnosis based on the semiserial whole brain sectioning technique with possibilities for a topographic overview and a histopathological description of the brain pathology.

Acknowledging that “subjective judgements are almost unavoidable in assessing the cause of organic dementia” [34] both clinically and neuropathologically, we interpreted the cases in accordance with our tradition of clinical investigation in an attempt to evaluate the impact of the various pathological findings on the symptomatology. The cases with LBs are presented individually.

In **case 1** the symptoms and the differential diagnostic ratings gave rise to a suspicion of a probable AD and a clear subcortical, vascular engagement with an insufficient blood pressure regulation. Earlier hypertension and later hypotension in combination with an orthostatic blood pressure regulation could have given rise to hypoperfusive episodes with subsequent white matter damage [35]. The rCBF 5 years after onset of the disease and 1 year prior to death showed the

classic AD pattern with temporo-parietal blood flow decrease. The EPS could be explained by the nigral degeneration while the likelihood of Alzheimer pathology underlying the dementia was intermediate according to the NIA-Reagan criteria. The contribution of the pronounced vascular white matter damage must, however, be anticipated. The fluctuations could be related to the combination of autonomic instability and vessel pathology [36]. The presence of LBs in autonomic ganglia [37] is another possible explanation, although this structure was not investigated in the present cases. LBs in NbM could be an indication of a degeneration of this cholinergic source and thereby a further potentiation of the AD component.

In **case 2** the clinical diagnostic rating indicated a probable AD component although vascular risk factors such as hypertension and decreasing blood pressure over time were present. The rCBF pattern was in accordance with the classic temporo-parietal AD pattern in combination with bilateral frontal flow decreases, a common pattern in older individuals with more advanced AD [30,38,39]. The bilateral, partially temporo-parietal location of the infarcts could further contribute to the AD symptomatology. The EPS were thought to be the result of the SN degeneration and the frontal subcortical pathology [40]. The strategic location of LBs in NbM could also contribute to the dementia but it is not likely that the LBs are solely responsible.

Case 3 exhibited a clinical picture where diagnostic ratings suggested AD and frontal lobe dysfunction. The mixed dementia diagnosis *in vivo* was probably influenced by the patient's vascular risk factors (hypertension, arteriosclerotic heart disease, smoking) and some focal asymmetry in the rCBF pattern. The SN was not degenerated although the neuroleptic treatment might have contributed to the EPS indicating a dopaminergic deficiency [41]. The relatively pure Alzheimer pathology possibly forms the basis of the dementia, a fact which the Reagan criteria considered as "highly" likely. The pronounced frontal symptomatology had, however, no clear cut pathological correlate. The clinical impact of the few LBs in the frontal cortex is uncertain although the mere presence of LBs may indicate underlying synuclein pathology.

Case 4 had a differential diagnostic rating as probable AD but also a marked frontal profile. Following the rCBF investigation with regional decreases in fronto-temporal areas the diagnosis of fronto-temporal dementia was considered. The dementia syndrome could be correlated to the neuropathological degenerative fronto temporal non-Alzheimer changes. The EPS (also a part of FTD symptomatology) could be explained by the nigral degeneration. The LB pathology might have added to the symptomatology with its strategic location in NbM and the cingulate gyrus, thus amplifying the clinical AD appearance. LBs in SN indicate a disruption of dopaminergic subcortico- frontal projections and this possibly adds to the signs of frontal dysfunction in the rCBF measurement.

Case 5 had a mixed dementia with an even clinical diagnostic rating profile. The brain imaging findings of an asymmetric CBF pattern indicated a vascular genesis. The neuropathological findings of Alzheimer pathology and cortical microvacuolisation were diverse and discrete and could additively form the basis of the dementia, a neuropathological situation not uncommon in the age group >80 [42]. However, according to the Reagan criteria the probability of an Alzheimer pathology underlying the dementia was rated as intermediate. LBs were seen in SN, as possible markers of local damage and as an explanation of the EPS. The LBs in the temporal cortex if indicative of dysfunction [43] may add to the temporal lobe symptoms.

Case 6 had a clear clinical picture and diagnosis of PaD although with cognitive disturbances subsequent to onset. The blood pressure regulation was unstable with decreasing blood pressure over time. The diagnostic ratings suggested a mixed dementia, AD and VaD. The rCBF pattern was typical for both AD and PaD. The pathology showed a classical PaD picture with subcortical and cortical LBs in combination with Alzheimer pathology forming the basis of the dementia.

The Alzheimer pathology contributed “highly” to the dementia, according to the NIA-Reagan criteria and received a comparatively high Braak staging because of widespread cortical Alzheimer changes although these changes were generally mild. In contrast the Brun and Englund grading was “mild AD”. In this case the wide spread LBs along dopaminergic subcortico-cortical projections may be interpreted as a sign of the severity of the degeneration. A more cautious evaluation of the importance for the dementia state is called for since cortical LBs in PaD are also seen in non-demented cases [44].

Thus, with the exception of case 5, who had subliminal pathologies and only few LBs, 4 of the cases had additional pathological findings to LBs with a probable impact on the dementia symptomatology. Case nr 6 was considered to be “the most typical DLB case” both clinically and neuropathologically according to the description in the literature [7].

Visual hallucinations were, however, absent. Case no 4 was also the least likely DLB case since no LBs were found in the brainstem.

Neurological signs are often associated with regional brain pathology while neuropsychiatric symptoms such as deceptions, delusions and depression show a less strict coupling to specific brain areas. The findings in our sample indicate a complex background for deceptions and delusions in brain disease. Several cases showed pathology in the hippocampus, the temporal and occipital cortices combined with sensory deficits, a well known contributory factor to these symptoms [45]. In studies of psychoses and their links to cerebral lesions, cortical as well as subcortical brain abnormalities, have been reported [46,47]. Productive symptoms such as hallucinations and delusions have also been connected to the function of better-preserved cortical areas [48-50]. There was no obvious association between psychotic symptoms and brain pathology in our patient sample although cases 1, 5 and 6 exhibited hallucinations and showed low-grade Alzheimer pathology according to Brun/Englund, combined with relatively sparse additional cortical pathology. On the other hand this occurred in only 2 of 6 hallucinating LB negative cases.

Cognitive fluctuations, confusional episodes, falls and also irritability and aggressiveness seemed to appear at a time when there was a progressive decrease of the arterial blood pressure regardless of the presence of LBs. Low blood pressure and orthostatic hypotension are common in dementia [51] and probably highly hazardous in patients with previous hypertension. This was the case in 3 of our LB positive and one of our LB negative patients. Previous hypertension combined with antihypertensive medication have been associated with a higher risk of dementia in a recent population based study [52]. Decreasing blood pressure during dementia in clinical DLB was found in our full material [53]. Unstable blood pressure regulation, arterial hypotension or ischemia is often related to syncope, transient impaired consciousness, unsteady gait, falls and fractures which constitute supportive criteria in the DLB consensus document [54-56]. It is believed that the development of SIWI results from regionally reduced cerebral perfusion due to small vessel disease combined with systemic hypotension and is coupled to ischemic heart disease [22]. These clinico pathological findings were more abundant in our LB negative cases compared to the LB positive. Cases with combined Alzheimer and SIWI pathology (most commonly frontally located) share several symptoms with DLB; fluctuations, confusion, syncope, hallucinations and tonus increase [57] a fact which implies differential diagnostic difficulties. Fluctuations in cognition are conventionally considered a vascular symptom [36] but are also part of the clinical picture in PaD. The vast majority of our 16 cases had a clear decrease in blood pressure associated with the appearance of fluctuations in cognition. Interestingly, all cases (4 LB pos and 1 LB neg) with moderate to severe degeneration of LC and subsequently a

possible involvement of noradrenergic pathways, had “fluctuations in cognition and variations of attention and alertness”. Noradrenergic dysfunction has been related to disrupted activity of the attention mechanisms of frontal areas [58]. Three of the LB positive and 2 of the LB negative cases had coexistent SN degeneration, which may produce specific attentional deficits in PaD [59].

Another symptom not discussed in the consensus document but reported in 3 of our 6 LB positive cases (and in 2 LB negative cases) was diffuse somatic pain, unrelated to specific underlying lesions. Yet, pain is also a common sensory manifestation of PaD [60].

The importance of finding patients with the clinical core symptoms of DLB early in the course of dementia has been stressed [61], as this would facilitate the discovery of cases with LBs with less interference from other age-depending brain pathologies and would enable early treatment. Recent publications have reported positive responses to treatment with acetylcholinesterase inhibitors in DLB [62,63]. A clear cholinergic dysfunction has also been shown in DLB [64]. There was, however, no consistent pattern or any difference between the cases with and without LBs, in the early appearance of the core symptoms.

Nigral pathology with subsequent dopaminergic deficiency, as well as other subcortical lesions, were prevalent in our cases and probably associated with the DLB symptoms.

In conclusion, our pathological data, using the whole brain semiserial sectioning technique, show that the neuropathological picture is complex and varies between individual cases. It is generally difficult to evaluate the importance of the LB pathology per se compared to other coexisting pathological changes. The single case analysis points to important clinico- pathological relations, which might be lost when analysing data from larger groups. Since AD and vascular diseases require specific clinical considerations and treatment, it is of great importance to acknowledge and diagnose these, even if a LB pathology is suspected.

It is, however, of clinical importance to recognize patients with a symptom constellation caused by deficiencies in the acetylcholine, the dopamine, the noradrenergic and possibly also the serotonergic system. This may allow a delicate, balanced treatment, which would not only alleviate disabling symptoms but would also avoid symptoms associated with and aggravated by deficient control of blood pressure. In addition, neuroleptic sensitivity reactions can be prevented.

References

- 1 Gustafson, L. Clinical classification of dementia conditions. 1992. *Acta Neurol Scand* suppl 139; 16-20.
- 2 Neary D. Classification of dementias. *Reviews in Clinical Gerontology*. 1999;9:55-64.
- 3 Lennox G, Lowe J, Landon M, Byrne EJ, Mayer RJ, Godwin-Austen R. Diffuse Lewy body disease: correlative neuropathology using anti ubiquitin immunocytochemistry. *J Neurol Neurosurg Psychiatry* 1989; 52:1236-47.
- 4 Hansen LA, Salmon D, Galasko D, Masliah E, Katzman R, DeTeresa , Thal L, Pay MM, Hofstetter R, Klauber M, Rice M, Butters N, Alford M. The Lewy body variant of Alzheimer's disease: a clinical and pathological entity. *Neurology* 1990;40:1-8.
- 5 Perry RH, Irving D, Blessed G, Fairbairn A, Perry EK.. Senile dementia of the Lewy body type. A clinical and neuropathologically distinct form of Lewy body dementia in the elderly. *J Neurol Sci*. 1990;95:119-139.

- 6 Shergill S, Mullan E, D'At P, Katona C. What is the clinical prevalence of Lewy body dementia? *Int J Psychoger* 1994;9:907-912.
- 7 McKeith IG, Galasko D, Kosaka K, Perry EK, Dickson DW, Hansen LA, Salmon DP, Lowe J, Mirra SS, Byrne EJ, Lennox G, Quinn NP, Edwardson, Ince PG, Bergeron C, Burns A, Miller BL, Lovestone S, Collerton D, Jansen ENH, Ballard D, de Vos RAI, Wilcock GK, Jellinger KA, Perry RH. Consensus guidelines for the clinical and pathological diagnosis of dementia with Lewy bodies (DLB). *Neurology* 1996;47:113-124.
- 8 Greenfield JG, Bosanquet FD. The brainstem lesions in parkinsonism. *J Neurol Neurosurg Psychiat* 1953;16:213-226.
- 9 Bethlem J, DenHartog Jager WA. The incidence and characteristics of Lewy bodies in idiopathic paralysis agitans (Parkinson's disease). *J Neurol Neurosurg Psychiat* 1960;23:74-80.
- 10 Trétiakoff C. 1919. Contribution l'étude de l'anatomie patologique du locus niger de Soemmering. Thèse de Paris.
- 11 Jackson M, Lennox G, Balsitis M, Lowe J. Lewy body dysphagia. *J Neurol Neurosurg Psychiat*. 1995;58:756-757.
- 12 Oppenheimer D: Neuropathology of autonomic failure; in Bannister R (ed): *Autonomic failure. A textbook of clinical disorders of the autonomic nervous system*. 2nd ed, Oxford, Oxford University Press, 1988, pp 451-463.
- 13 Kosaka, K. Diffuse Lewy body disease in Japan. *J Neurol* 1990;237: 197-204.
- 14 Förstl H, Burns A, Luthert P, Cairns N, Levy R. The Lewy body variant of Alzheimer's disease. Clinical and pathological findings. *Br J Psychiatry*. 1993;162:385-392.
- 15 Perry, R.H., Irving, D., Blessed, G., Perry, E.K., Fairbairn, A.F. Clinically and pathologically distinct form of dementia in the elderly, *Lancet* 1989i:166.
- 16 Samuel W, Galasko D, Masliah E, Hansen LA. Neocortical Lewy body counts correlate with dementia in the Lewy body variant of Alzheimer's disease. *J Neuropathol Exp Neurol* 1996;55:44-52.
- 17 Haroutunian V, Serby M, Purohit DP, Perl DP, Marin D, Lantz M, Mohs RC, Davis KL. Contribution of Lewy body inclusions to dementia in patients with and without Alzheimer's disease neuropathological condition. *Arch Neurol*.2000;57:1145-1150.
- 18 McKeith IG, Ballard CG, Perry RH, Ince PG, O'Brien JT, Neill D, Lowery K, Jaros E, Barber R, Thompson P, Swann A, Fairbairn A, Perry EK. Prospective validation of consensus criteria for the diagnosis of dementia with Lewy bodies. *Neurology* 2000;54:1050-1058.
- 19 Brun A, Gustafson L. The Lund Longitudinal Dementia Study: A 25-year Perspective on Neuropathology, Differential Diagnoses and Treatment; in Corain B, Nicolini M, Winblad B, Wisniewski H, Zatta P (eds): *Alzheimer's Disease: Advances in Clinical and Basic Research*, John Wiley & Sons. 1993, pp 4-18.
- 20 Londos E, Passant U, Brun A, Gustafson L. Clinical Lewy body dementia and the impact of vascular components. *Int J Geriatr Psychiatry* 2000;15:40-49.
- 21 Brun A, Englund E. The pattern of degeneration in Alzheimer's disease. Neuronal loss and histopathological grading. *Histopathology* 1981;5: 549-64.
- 22 Brun A, Englund E. A white matter disorder in dementia of the Alzheimer type. A patho-anatomical study. *Ann Neurol*. 1986;19:253-262.
- 23 Obrist WD, Thompson HK, Wang HS, Wilkinson WE. Regional cerebral blood flow by 133-xenon inhalation. *Stroke* 1975;6:245-256.

- 24 Risberg J, Ali Z, Wilson EM, Wills EL, Halsey JH. Regional cerebral blood flow by 133-xenon inhalation. *Stroke* 1975;6:142-148.
- 25 Risberg J. Regional cerebral blood flow measurements by 133-xenon inhalation: methodology and applications in neuropsychology and psychiatry. *Brain lang* 1980;9:9-34.
- 26 Risberg J. Regional cerebral blood flow; in Hannay JH (ed): *Experimental Techniques in Human Neuropsychology*. New York, Oxford Press, 1986, pp 514-543.
- 27 Risberg J, Gustafson L: 133xe cerebral blood flow in dementia and in neuropsychiatry research; in Phillippe Magistretti C, (ed): *Functional radionuclide imaging of the brain*. Raven Press, New York. 1983, pp151-159.
- 28 Moroney JT, Bagiella E, Desmond DW, Hachinski VC, Mölsä PK, Gustafson L, Brun A, Fischer P, Erkinjuntti T, Rosen W, Paik MC, Tatemichi TK. Meta-analysis of the Hachinski ischemic score in pathologically verified dementias. *Neurology* 1997;49:1096-1105.
- 29 Gustafson L, Nilsson L. Differential diagnosis of presenile dementia on clinical grounds. *Acta Psychiat Scand* 1982;65:194-209.
- 30 Hachinski VC, Iliff LD, Zilkha E, Du Boulay GH, Mcallister VC, Marshall J, Russell RW, Symon L. Cerebral blood flow in dementia. *Arch Neurol* 1975;32:632-637.
- 31 Brun A. The structural development of Alzheimer's disease. *Dan Med Bull* 1985;32:25-27.
- 32 Braak H, Braak E. Neuropathological staging of Alzheimer-related changes. *Acta Neuropathol* 1991; 82:239-259.
- 33 The national institute on aging, and Reagan institute working group on diagnostic criteria for the neuropathological assessment of Alzheimer's disease. Consensus recommendations for the postmortem diagnosis of Alzheimer's disease. *Neurobiology of aging* 1997;18:S1-S2.
- 34 Ulrich J, Probst A, Wuest M. The brain diseases causing senile dementia. A morphological study on 54 consecutive autopsy cases. *J Neurol* 1986;233:118-122
- 35 Brun A, Englund E. A white matter disorder in dementia of Alzheimer's type. *Ann Neurol* 1986;19:253-262.
- 36 Mayer-Gross W, Slater E, Roth M: Ageing and the mental diseases of the aged; in *Clinical Psychiatry*, ed 3. Bailliere, Tindall&Carstell, London 1969, pp 533-629.
- 37 Wakabayashi K, Takahashi H. Neuropathology of autonomic nervous system in Parkinson's disease. *Eur Neurol* 1997;38:2-7.
- 38 Lauter H. Über Spätformen der Alzheimerschen Krankheit and ihre Beziehung sur senilen Demenz. *Psychiat Clin* 1970;3:169-189.
- 39 Risberg J. Cerebral blood flow in dementias. *Dan Med Bull* 1985;32:48-51.
- 40 Wallin, A. and Blennow, K. Heterogeneity of vascular dementia: Mechanisms and subgroups. *J Geriat Psychiat Neurol* 1993;6:177-188.
- 41 McKeith IG, Fairbairn A, Perry R, Thompson P, Perry E. Neuroleptic sensitivity in patients with dementia of Lewy body type. *BMJ* 1992;305:673-678.
- 42 Brun A, Gustafson L, Samuelson S-M, Ericsson C. Neuropathology of late life. *Dementia* 1992;3:125-130.
- 43 Perry R, McKeith I, Perry E. Lewy body dementia – clinical, pathological and neurochemical interconnections. *J Neural Transm* 1997;suppl 51: 95-109.
- 44 Hughes AJ, Daniel SE, Blankson S, Lees AJ. A clinicopathological study of 100 cases of Parkinson's disease. *Arch Neurol* 1993;50:140-148.

- 45 Cooper AF, Porter R. Visual acuity and ocular pathology in the paranoid and affective psychoses of later life. *J Psychosomatic Res* 1976;20:107-114.
- 46 Wertheimer J: Some hypotheses about the genesis of visual hallucinations in dementias; in: Katona C, Levy R (eds): *Delusions and hallucinations in old age*. Gaskell, Bell and Bain Ltd, Glasgow, 1992, pp 201-208.
- 47 Miller BL, Lesser IM, Boone KB, Hill E, Mehninger CM, Wong K. Brain lesions and cognitive function in late-life psychosis. *Br J Psychiatry* 1991;158:76-82.
- 48 Gustafson L, Risberg J. Regional cerebral blood flow related to psychiatric symptoms in dementia with onset in the presenile period. *Acta Psych Scand* 1974;50:516-538.
- 49 Jacoby R, Levy R. Computed tomography in the elderly: II Senile dementia: diagnosis and functional impairment. *Br J Psychiat* 1980;136:256-269.
- 50 Förstl H, Howard R, Almeida OP, Stadtmüller: Psychotic symptoms and the paraphrenic brain; in Katona C, Levy R (eds): *Delusions and hallucinations in old age*. Gaskell, Bell and Bain Ltd., Glasgow 1992, pp 153-170.
- 51 Passant U, Warkentin S, Karlsson S, Nilsson K, Edvinsson L, Gustafson L. Orthostatic hypotension in organic dementia: relationship, cortical blood flow and symptoms. *Clin Auton Res* 1996;6:29-36.
- 52 Ruitenberg A, Skoog I, Ott A, Aevarsson O, Witteman JCM, Lernfelt B, van Harskamp F, Hofman A, Breteler MMB. Bloodpressure and risk of dementia: results from the Rotterdam study and Gothenburg H-70 study. *Dement Geriatr Cogn Disord* 2001;12:33-39.
- 53 Londos E, Passant U, Gustafson L. Blood pressure and drug treatment in clinically diagnosed Lewy body dementia and Alzheimer's disease. *Arch Geront Geriatr* 2000;30:35-46.
- 54 Rubenstein LZ, Robbins AS. 1984. Falls in the elderly. A clinical approach. *Geriatr* 39, 67-78.
- 55 Tinetti ME, Williams TF, Mayewski R. Fallrisk index for elderly patients based on the number of chronic disabilities. *Am J Med* 1986;80:429-434.
- 56 Bradshaw MJ, Edwards RTM. Postural hypotension – pathophysiology and management. *Quarterly. J Med* 1986; 231:643-657.
- 57 Englund E, Brun A, Gustafson L. A white-matter disease in dementia of Alzheimer's type – clinical and neuropathological correlates. *Int J Ger Psychiatry*. 1989;4:87-102.
- 58 Reikkinen M, Laakso MP, Jäkälä P, Reikkinen P Jr: Clonidine impairs sustained attention in Alzheimer's disease; in Iqbal K, Swaab B, Wisniewski HM (eds): *Alzheimer's disease and related disorders*. John Wiley&Sons Ltd, 1999 pp 641-647.
- 59 Downes JJ, Roberts AC, Sahakian BJ, Evenden JL, Morris RG, Robbins TW. Impaired extra-dimensional shift performance in medicated and unmedicated Parkinson's disease: evidence for a specific attentional dysfunction. *Neuropsychologica* 1989;27:1329-1343.
- 60 Goetz CG, Tanner CM, Levy M, Wilson RS, Garron DC. Pain in Parkinson's disease. *Mov Disord*. 1986;1:44-49.
- 61 Lennox GG, Lowe JS: The clinical diagnosis and misdiagnosis of Lewy body dementia; in Perry R, McKeith I, Perry E (eds): *Dementia with Lewy bodies – clinical, pathological, and treatment issues*. Cambridge university press, 1996, pp 9-20.
- 62 Shea C, MacKnight C, Rockwood K. Donepezil for treatment of dementia with Lewy bodies: a case series of nine patients. *Int Psychogeriatr* 1998;10:229-238.

- 63 McKeith IG, Grace JB, Walker Z, Byrne EJ, Wilkinson D, Stevens T, Perry EK. Rivastigmine in the treatment of dementia with Lewy bodies: preliminary findings from an open trial. *Int J Geriatr psychiatry* 2000;15:387-392.
- 64 Perry EK, Haroutunian V, Davis DL, Levy R, Lantos P, Eagger S, Honavar M, Dean A, Griffith M, McKeith IG, Perry R. Neocortical cholinergic activities differentiate Lewy body dementia from classical Alzheimer's disease. *Neuroreport* 1994;5:747-749

Acknowledgement

The Alzheimer foundation, Sjöbring foundation and the Swedish Medical Research Council, projects no 3950 and 4969 supported this study. Siv Börjesson and Helena Andersson, Inst of Neuroscience, Lund University, are thanked for skilful help with the figures. We also gratefully acknowledge Kerstin Sturesson, Annette Persson-Prahl and Christina Andersson, Inst of Pathology and Jessica Nilsson, Biomedical center, Lund University, for histotechnical assistance.

Table1.
Basic characteristics of 16 clinically diagnosed cases with Dementia with Lewy bodies

LB pos cases	Gender	Age at onset	Age at death	Dementia duration
1	M	71	76	5
2	F	71	82	11
3	F	80	88	8
4	F	65	73	8
5	M	81	88	7
6	M	76	79	3
LB neg cases		74±6,1	81±6,2	7±2,7
7	F	76	86	10
8	M	56	64	8
9	M	75	81	6
10	M	74	86	12
11	F	66	78	12
12	F	55	63	8
13	F	54	60	6
14	M	80	94	14
15	M	82	83	1
16	F	74	82	8
		69±10,7	78±11,4	8±3,7

Table 2.
Neuropathological findings in 16 clinically diagnosed cases with Dementia with Lewy bodies

LB pos cases	Cortical Infact/s		White matter infarcts		SN	LC	Lewy Bodies (LBs)	
1	Par	Central	Front		2	3	NbM, SN Cortex	++ (+)
2	Par Central	Occip Front	Front Par	Occip Subcort	2	0	NbM	+
3	Small cortical				0	1	Front	+
4					2	3	SN	++
							NbM, Cing	+
5					0	0	SN	++
							Temp	+
6					2	2	SN, NbM,Front Cing,Temp, Par	++
LB neg cases								+
7			Front Par	Occip	1	1	No	
8			Front Par	Occip	1	1	No	
9	Small cortical		Front		0	0	No	
10	Border zone		Front		0	0	No	
11	Small cortical		Front		0	0	No	
12					0	0	No	
13					1	0	No	
14	Par Temp	Occip	Front Par	Occip Subcort	0	0	No	
15	Pons		Front		0	0	No	
16					0	3	No	

Degeneration: 1= mild, 2=moderate, 3=severe. 1-5 LBs=+, 6-10 LBs=++ per small section (cm³)
Front=frontal, temp=temporal, par=parietal, occip=occipital, hipp=hippocampal, amyg=amygdala, cing=cingulate gyrus, SN=substantia nigra, LC=locus coeruleus.

Table 3a.
Alzheimer pathology in 6 clinically diagnosed cases with Dementia with Lewy bodies (Lewy body positive).

LB pos cases	Local severity Brun and Englund [21]				Total severity Brun and Englund [21]	Braak staging [31]	Likelihood of AD underlying dementia NIA-Reagan criteria [32]
1	Front	1	Uncus	3	Mild templimbic, mild cortical (I)	III-IV	Intermediate
	Temp	3	Amyg	3			
	Hipp	0-1	Par	0-1			
2	Front	0	Uncus	3	Severe temp limbic, severe cortical (III)	V	High
	Temp	3	Amyg	0			
	Hipp	3	Par	3			
3	Front	0	Amyg	2	Moderate temp limbic, moderate cortical (II)	V	High
	Temp	2	Par	2			
	Hipp	2					
4					0	0	No
5	Front	0	Amyg	1	Mild temp limbic Cortical (0)	III-IV	Intermediate
	Temp	0	Uncus	1			
	Hipp	1	Par	0			
6	Front	0	Amyg	1	Mild temp limbic, mild cortical (atypical) (I)	V *	High
	Temp	1	Par	1			
	Hipp	0					

Degeneration: 0=not exceeding normal for age, 1= mild, 2=moderate, 3=severe
Front=frontal, temp=temporal, hipp=hippocampal, amyg=amygdala, par=parietal
Temporal-limbic=involvement of hippocampus, amygdala and entorhinal cortex but not supracallosal limbic (cingulate gyrus) or neocortex.

*The patient was difficult to classify according to this staging.

Table 3b.
Alzheimer pathology in 10 clinically diagnosed cases with Dementia with Lewy bodies
(Lewy body negative).

L13 neg cases	Local severity Brun and Englund [21]				Total severity Brun and Englund [21]	Braak staging ¹ [31]	Likelihood of AD underlying dementia NIA-Reagan criteria [32]
7	Front Temp Hipp	1 2 3	Amyg Par	2 2	Severe temp limbic, moderate cortical (II)	VI	High
8	Front Temp Hipp	3 0 1	Amyg Par Occip	1 3 3	Mild temp limbic severe cortical, frontal accent (III)	VI	High
9	Front Temp Hipp	1 3 2	Amyg Uncus Par	0 3 1	Severe temp limbic, moderate cortical(II)	VI	High
10	Front Temp Hipp	1 3 3	Amyg Uncus Par	2 1 2	Severe temp limbic , severe cortical (III)	VI	High
11	Front Temp Hipp	2 2 3	Amyg Uncus Par	2 1 2	Severe temp limbic, Moderate cortical, (atypical) (II)	VI	High
12	Front Temp Hipp	2 2 2	Amyg Par	3 3	Severe temp limbic, severe cortical (III)	VI	High
13	Front Temp Hipp	2 3 3	Amyg Par	3 3	Severe temp limbic, severe cortical (III)	VI	High
14	Front Temp Hipp	2 3 3	Amyg Par	3 3	Severe temp limbic, severe cortical (III)	VI	High
15	Front Temp Hipp	1 1 1	Amyg Uncus Par	1 1 1	Mild temp limbic, mild cortical (I)	VI	High
16	Front Temp Hipp	1 2 2	Amyg Par	2 0	Moderate temp limbic, moderate cortical (II)	VI*	High

Abbreviations and comment, see table 3a.

Table 4.

Differential diagnostic scoring and initial neuropathological diagnosis in 16 clinically diagnosed cases with Dementia with Lewy bodies.

LB pos cases	AD score	FTD score	IS score	Neuropathological diagnosis
1	7	2	9	VaD*+AD
2	8	2	4	VaD+AD
3	13	10	3	AD
4	8	6	2	FTD
5	6	6	5	AD
6	6	0	7	PaD+AD
LB neg cases	8.0±2.6	4.3±3.7	5.0±2.6	
7	11	8	3	AD+SIWI
8	6	4	1	AD+SIWI
9	11	5	5	AD+SIWI
10	7	2	7	AD+SIWI
11	8	6	5	AD+SIWI
12	6	4	3	AD
13	11	8	4	AD
14	13	4	1	AD+VaD
15	2	0	9	VaD*+AD
16	8	6	5	AD
	8.3±3.3	4.7±2.5	4.3±2.5	

The predominant neuropathological diagnosis is presented first.

Alzheimer's disease (AD) score, Fronto temporal dementia (FTD) score [28,29].

Ischemic (IS) score [29].

VaD= Vascular dementia, PaD= Parkinson's disease, SIWI=Selective incomplete white matter infarct, *=Binswanger type

Table 5.
Core criteria and neuroleptic sensitivity in 16 clinically diagnosed cases with Dementia with Lewy bodies.

LB pos cases	Fluctuations	Hallucinations	Extrapyramidal symptoms (EPS)	Neuroleptic sensitivity
1	Yes	No	a,b,c,d,e	Deterioration
2	No	Visual	a,b,d,f	Rigidity
3	Yes	Visual Auditory	a,b	No
4	Yes	No	a,b,c,d	No neuroleptic treatment
5	Yes	Visual Auditory	a,b,f	Rigidity
6	Yes	Auditory	a,b,c,d,e	Hypersalivation, oversedation
LB neg cases				
7	Yes	No	a,b	No
8	No	Visual Auditory	a,b,d,e,f	Severe EPS
9	Yes	No	b,f	
10	Yes	No	a,e	Hypominia hypersalivation, oversedation
11	Yes	Hallucinations	a,b,c	Rigidity Hypersalivation Leaning
12	No	Visual hallucinations	a,b,c,d,f	Rigidity
13	Yes	Visual hallucinations	a,b,c,f	Overscdation
14	Yes	No	a,b,c,d,f	
15	Yes	Hallucinations	No	Salivation
16	Yes	Visual hallucinations	No	

a=small stepped gait

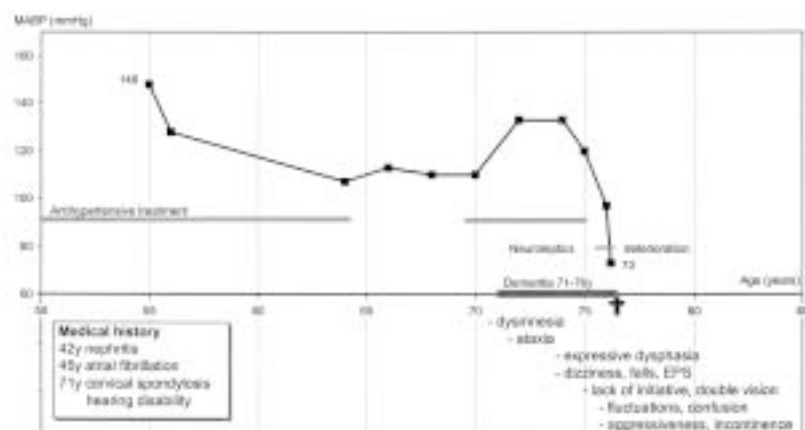
b=(cogwheel) rigidity

c=tremor

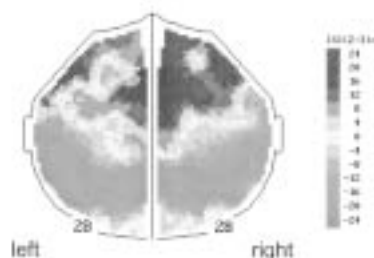
d=bradykinesia

e=masked face

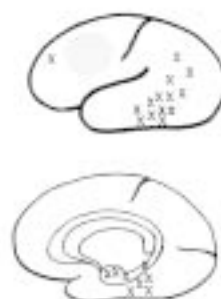
f=postural change



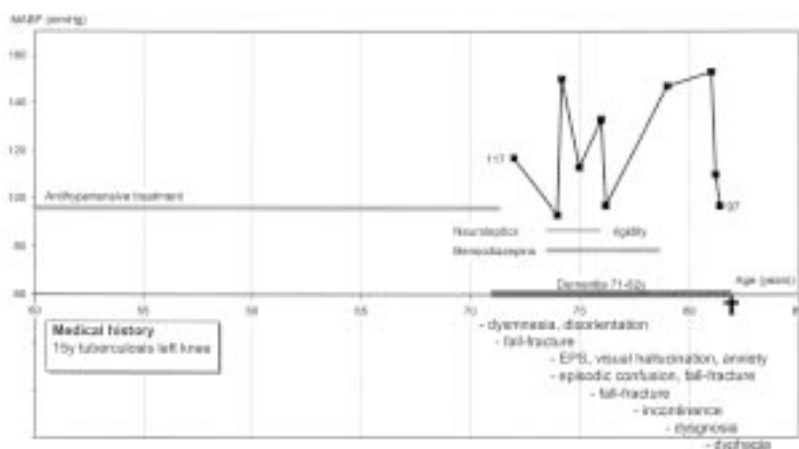
Case 1. This male patient was a retired schoolteacher who developed dementia at the age of 71. Although one uncle suffered from tremor there was no family history of dementia. He suffered from longstanding arterial hypertension but there was a marked blood pressure decrease from the age of 75. The initial clinical diagnoses were vascular dementia of Binswanger's type, and vitamin B12 deficiency. He died at the age of 76.



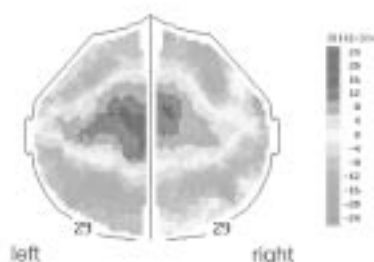
rCBF measurement at the age of 76, after 5 years of dementia, showed a marked general blood flow decrease as well as bilateral, focal flow decreases in temporo-parietal areas.



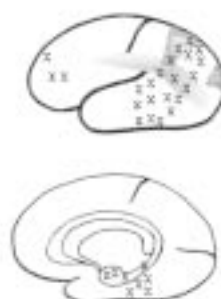
Neuropathology: Mild Alzheimer pathology with temporal-limbic preponderance. Moderate, mainly central arteriosclerosis with limited incomplete infarcts of Binswanger-type. Moderate degeneration of SN and LC were also present as well as moderate cerebellar atrophy. LBs in NbM and SN. Abbreviations see table 2 and 5.



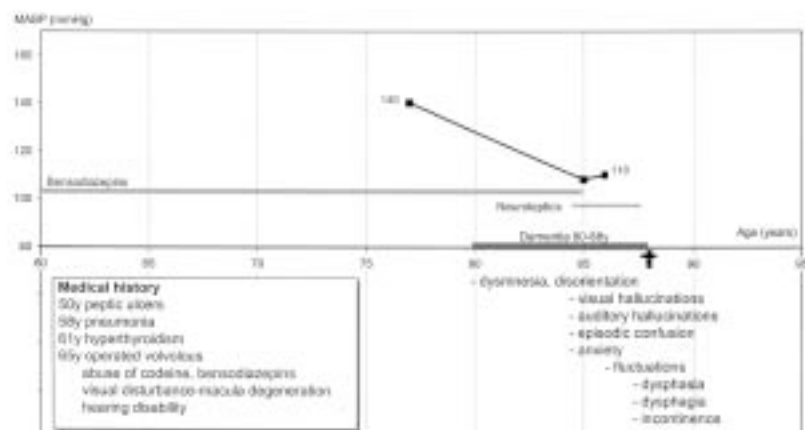
Case 2. This female patient had been working as a hat modiste. She had longstanding arterial hypertension. At the age of 74 she started complaining of diffuse pain and became anxious and restless. She also had visual hallucinations "talked with the furniture" and was episodically confused. She was referred to the psychogeriatric department aged 75. She was described as restless, pacing and constantly calling "help me". Her blood pressure varied markedly during the course of dementia and seemed to decrease during treatment with neuroleptics. There was a further decrease from the age of 81 after medication was stopped. She died at the age of 82 after 7 years in psychiatric/institutional care. The initial clinical diagnoses were mixed AD and vascular dementia as well as vitamin B12 deficiency.




rCBF measurement at the age of 79, after 8 years of dementia, showed a marked general blood flow decrease and focal decreases in temporo-parietal and frontal areas bilaterally.



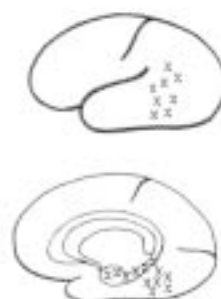
Neuropathology: Alzheimer pathology of varying degree, with temporal limbic accent, also severe in parietal cortex, however with sparse vascular amyloidosis. Multiple large infarcts in both grey and white matter in combination with extensive incomplete white matter infarcts. LBs in NbM. Brain weight 1000g.



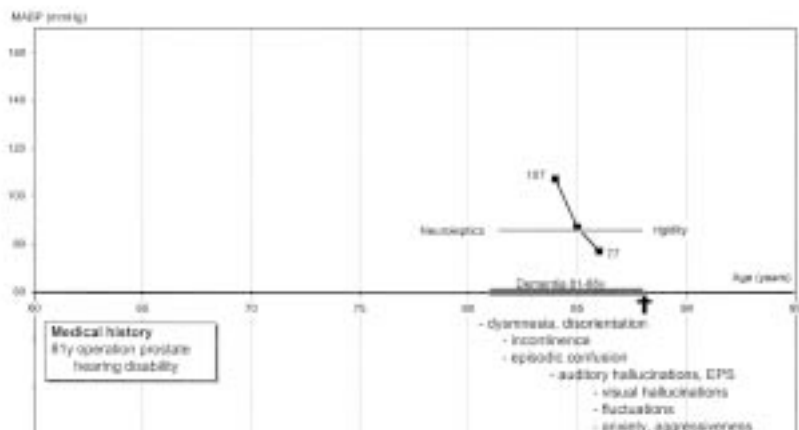
Case 3. This female patient was a former physiotherapist with a family history of dementia and coronary heart disease. She was an excessive smoker. She complained of diffuse pain and suffered from visual and hearing disabilities, memory disturbances, anxiety and personal neglect. She exhibited recurrent visual and auditory hallucinations, "talking to herself". She showed partial insight and explained that she did so to "reduce her loneliness". She had episodic confusion and fluctuations of consciousness described as "attacks of absence, with staring gaze". Transient ischemic attacks were suspected. She became vocally disruptive, continuously calling "da-da". Her blood pressure decreased during dementia but seemed to stabilise despite treatment with neuroleptics. At the age of 85 the clinical diagnosis was mixed AD and vascular dementia. She died at the age of 88.



rCBF measurement at 85, after 5 years of dementia, showed a normal general CBF level with a slightly low postcentral blood flow level, most marked on the left side and a slight focal asymmetry in the premotor area.

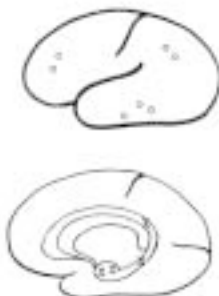

Neuropathology: Moderate Alzheimer pathology with a predominantly temporal-limbic location and a very mild amyloid angiopathy. No nigral degeneration and no infarcts. A few LBs were identified frontally. Brain weight 1100g.




Case 5. This previously healthy male patient came from Estonia where he had worked as a lawyer. At the age of 81 he showed memory disturbances and slight disorientation. He exhibited visual hallucinations "picked non-existing things from the walls". His blood pressure decreased markedly during dementia and the patient became hypotensive. The initial clinical diagnosis was vascular dementia. From the age of 85 until his death at the age of 88, he was cared for at a nursing home and at the psychiatric clinic.

The rCBF in this case was performed on the 32 channel device leading to a technically different illustration and therefore not shown.

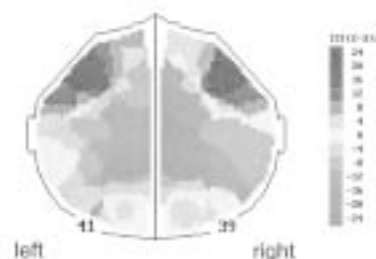


The rCBF findings at 85, 4 years after clinical onset of dementia were difficult to interpret for technical reasons. Tentatively the general CBF level seemed normal but with a marked hemispheric asymmetry and blood flow decreases fronto-temporally on the left side and on the right centrally.

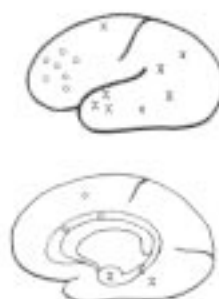Neuropathology: Discrete Alzheimer encephalopathy with temporal-limbic location and unevenly distributed cortical spongiform changes. Mild hydrocephalus. LBs in the SN and in the temporal cortex. Brain weight 1315g.



Case 6. This male patient served in the army and suffered from hearing disability and recurrent headache after an explosion. He had longstanding hypertension that was treated for some years. Parkinson's disease was diagnosed at the age of 75. He had auditory hallucinations "people singing at night", vegetative "attacks" of severe stomach pain, excessive sweating and salivation. He also exhibited "attacks of absence, loss of muscular tonus and a staring vacant gaze". He experienced multiple falls. He developed agitation, verbal (threatening) and physical (fighting, kicking, and throwing things) aggressiveness. His blood pressure decreased markedly during dementia. He was treated with drugs that could have contributed to the hypotension. The initial diagnoses were Parkinson's disease with dementia, vitamin B12 deficiency and hypothyroidism. He died at the age of 79.



The rCBF measurement at 76 years, when the patient became demented, showed a slightly decreased general blood flow level and focal decreases in temporo-parietal, parieto-occipital and frontal areas bilaterally.



Neuropathology: Alzheimer pathology with atypical distribution in the cortex, not accentuated in the amygdala. There was, however, discrepancy between these changes and spongiosis/gliosis which was mainly located in frontal areas. Moderate degeneration of SN. LBs in mesencephalon, the cingulate gyrus, hypothalamus and in frontal, parietal and temporal cortices. Brain weight 1430g.

Regional cerebral blood flow and age at recording in Lewy body negative cases with clinically diagnosed Dementia with Lewy bodies.

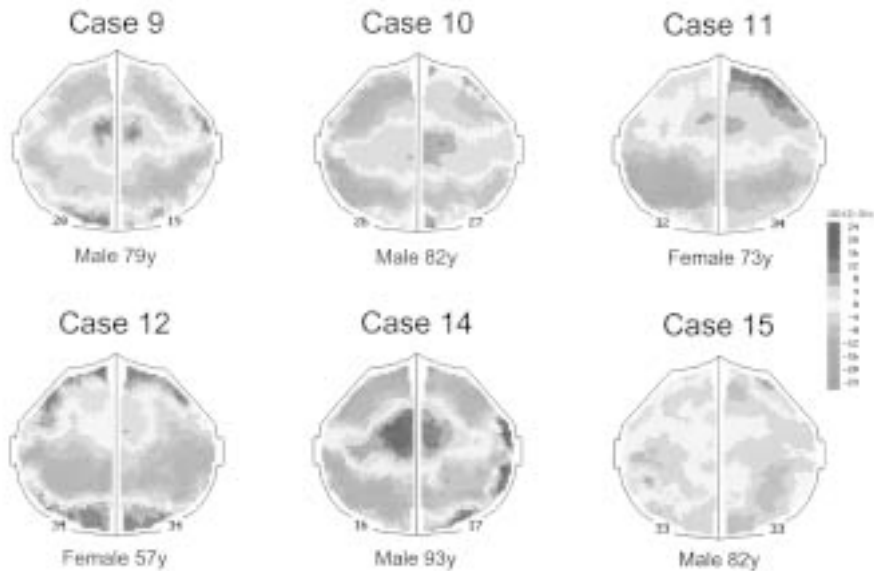


Fig 7

Regional cerebral blood flow and age at recording in LB negative cases with clinically diagnosed Dementia with Lewy bodies.

Regional cerebral blood flow patterns during rest showing the vertex view of the cerebral cortex, with the frontal pole at the top, and left hemisphere to the left. The colours represent flow distribution normalised (ISI, regional values in percent of the hemisphere mean), as defined by the colour key to the right.

