



# LUND UNIVERSITY

## Myocardial Topical Negative Pressure

Lindstedt Ingemansson, Sandra

2008

[Link to publication](#)

*Citation for published version (APA):*

Lindstedt Ingemansson, S. (2008). *Myocardial Topical Negative Pressure*. [Doctoral Thesis (compilation), Thoracic Surgery]. Department of Cardiothoracic Surgery, Clinical Sciences, Lund University.

*Total number of authors:*

1

### General rights

Unless other specific re-use rights are stated the following general rights apply:

Copyright and moral rights for the publications made accessible in the public portal are retained by the authors and/or other copyright owners and it is a condition of accessing publications that users recognise and abide by the legal requirements associated with these rights.

- Users may download and print one copy of any publication from the public portal for the purpose of private study or research.
- You may not further distribute the material or use it for any profit-making activity or commercial gain
- You may freely distribute the URL identifying the publication in the public portal

Read more about Creative commons licenses: <https://creativecommons.org/licenses/>

### Take down policy

If you believe that this document breaches copyright please contact us providing details, and we will remove access to the work immediately and investigate your claim.

LUND UNIVERSITY

PO Box 117  
221 00 Lund  
+46 46-222 00 00



# Myocardial Topical Negative Pressure

**Sandra Lindstedt**



**LUND**  
UNIVERSITY

**Department of Cardiothoracic Surgery**  
**Sweden 2008**



To my family with love



# Contents

List of Publications ..... v

Summary ..... vii

Summary in Swedish..... ix

Abbreviations..... xii

Introduction..... 1

1.1 Development of the topical negative pressure technique ..... 1

1.2 Physiological basis of TNP ..... 6

1.3 Post-sternotomy mediastinitis..... 10

1.4 Coronary anatomy and blood flow ..... 12

1.5 Determinants of coronary blood flow ..... 14

1.6 Factors influencing vasomotor tone..... 18

1.7 Autoregulation..... 20

1.8 Stenosis ..... 21

1.9 Collateral blood flow .....	22
1.10 Ventricular fibrillation .....	23
1.12 Ventricular fibrillation and ischaemia.....	24
1.13 Theory of laser Doppler flowmetry .....	25
1.14 Ultrasonic flow meter .....	28
Aims.....	29
Material and Methods.....	33
3.1 Experimental animals .....	33
3.2 Anesthesia.....	34
3.3 Data acquisition .....	34
3.4 Surgical procedure .....	35
3.5 Experimental protocol.....	38
3.6 Calculations and statistics.....	42
Results .....	45
4.1 Paper I.....	45
4.2 Paper II.....	50
4.3 Paper III.....	53
4.4 Paper IV .....	56
4.5 Paper V.....	58
Discussion .....	61
Conclusions.....	73



Limitations of the Present Work..... 75

Acknowledgements ..... 77

References ..... 81

Original Papers I-V ..... 98



# List of Publications

This thesis is based on five studies reported in the following papers, which are appended at the end of this thesis. The papers are referred to in the text by their Roman numerals.

- I**    **Lindstedt S**, Malmsjo M, Gesslein B & Ingemansson R. Topical negative pressure effects on coronary blood flow in a sternal wound model. *Int Wound J*, Accepted for publication.
  
- II**    **Lindstedt S**, Malmsjo M & Ingemansson R. Blood flow changes in normal and ischemic myocardium during topically applied negative pressure. *Ann Thorac Surg*, 2007;84:568-573.
  
- III**    **Lindstedt S**, Malmsjo M, Sjogren J, Gustafsson R & Ingemansson R. Impact of different topical negative pressure levels on myocardial microvascular blood flow. *Cardiovasc Revasc Med*, 2008;9:29-35
  
- IV**    **Lindstedt S**, Malmsjo M & Ingemansson R. No hypoperfusion is produced in the epicardium during application of myocardial topical negative pressure in a porcine model. *J Cardiothorac Surg*, 2007;2:53, E pub ahead of print.
  
- V**    **Lindstedt S**, Malmsjo M, Gesslein B & Ingemansson R. Evaluation of continuous and intermittent myocardial topical negative pressure. *J Cardiovasc Med*, Accepted for publication.



## Summary

The aim of this research was to determine whether it is possible to increase myocardial microvascular blood flow by applying a topical negative pressure (TNP) directly to the myocardium. The application of topical negative pressure is a relatively new wound healing technique. When used in wound therapy, it has been shown to increase microvascular blood flow, to stimulate granulation tissue formation, and to stimulate angiogenesis in the underlying tissue, mainly subcutaneous tissue and skeletal muscle. It was found that applying a topical negative pressure of -50 mmHg over the left anterior descending artery (LAD) region induced a significant increase, not only in local microvascular blood flow, but also in total coronary blood flow in normal and ischaemic myocardium. A significant correlation was found between changes in coronary blood flow and TNP. Having studied pressures between -50 mmHg and -150 mmHg, it was found that a TNP of -50 mmHg seemed to be the most effective negative pressure. Furthermore, no zone of hypoperfusion was observed in the epicardium at this TNP. Finally, it was established that there was no significant difference between microvascular blood flow during 20 minutes of continuous and

intermittent TNP at -50 mmHg.

In conclusion, the application of topical negative pressure to the myocardium may, in the future, constitute an alternative therapeutic intervention to stimulate blood flow in the failing myocardium in patients with ischaemic heart disease.

# Populärvetenskaplig sammanfattning

(Summary in Swedish)

Infektion i bröstkorgshålan efter hjärtkirurgi (mediastinit) och är en potentiellt livshotande infektion. Traditionellt behandlade man mediastinit med bland annat fördröjd slutning av bröstbenet eller behandling med spoldränage. Med dessa sår vårds behandlingar anses mediastinit ge en dålig prognos för lång tids överlevnad efter hjärtkirurgi. Under de senaste tio åren har undertrycksbehandling introducerats som en alternativ behandlingsmetod.

Undertrycksbehandling av mediastinit patienter har visat sig vara framgångsrik. I studier där man studerat överlevnad har det visat sig att dessa patienter har lika god långtidsöverlevnad som patienter som genomgått hjärtkirurgi utan att ha drabbats av mediastinit.

Undertrycksbehandling ökar blod flödet i den underliggande vävnaden, genom mekanisk sugkraft och genom att stimulera bildningen och tillväxten av nya blodkärl. En möjlig förklaring till de goda behandlingsresultaten kan vara att undertrycket under pågående undertrycksbehandling av patienter med mediastinit, är i direkt

kontakt med hjärtat, och därigenom är det möjligt att undertrycksbehandlingen även ökat blodflödet och kärlnybildningen i hjärtat.

Samtliga försök har gjorts på 70 kilos grisar. Det mikrovaskulära blodflödet har mätts på främre delen av hjärtat med Laser Doppler teknik, och kranskärlens blod flöde har mätts med ultraljudsprober. Mätningarna har gjorts före och efter applicering av olika tryck nivåer, och under olika tidsperioder, och på olika djup i hjärtmuskeln.

Vi har visat att det är möjligt att med hjälp av undertrycks behandling signifikant öka blodflödet under både normala och syrefattiga förhållanden . Vi har också visat att -50 mmHg är det optimala trycket vid undertrycksbehandling av hjärtat, och att blod flödesökningen är ett resultat av en ökning av det totala blod flödet till hjärtat. Då undertrycksbehandling används vid sår läkning har man påvisat en minskning av blod flödet några millimeter ner i vävnaden, närmast undertryckskällan, liknande förhållande kunde vi inte påvisa i hjärtat.

Patienter med svårbehandlad kärlkramp, där konventionella behandlingar så som percutaneous coronary interventions/ballong dilatation eller hjärtoperation i form av bypass-operation inte ha haft önskad effekt, representerar idag en klinisk utmaning, på grund av avsaknad av effektiva alternativa behandlingsmetoder. Olika behandlings strategier har prövats som t ex transmyokardiell laser



behandling och kardiell denervering utan tillfredställande kliniskt resultat. Detta är en relativt stor patient grupp, med ett stort lidande.

Undertrycksbehandling har potential att i framtiden kunna utgöra en alternativ behandlig för patienter med svårbehandlad kärlkramp.

# Abbreviations

CABG	Coronary Artery Bypass Grafting
CCX	Circumflex Coronary Artery
CPB	Coronary Pulmonary Bypass
DPTI	Diastolic Pressure Time Index
EVR	Endocardial Viability Ratio
LAD	Left Anterior Descending Artery
LVEDP	Left Ventricular End-Diastolic Pressure
MMP	Matrix MetalloProteinase
PCI	Percutaneous Coronary Intervention
PU	Perfusion Units
RCA	Right Coronary Artery
TNP	Topical Negative Pressure
TTI	Tension Time Index
VEGF	Vascular Endothelial Growth Factor

---

# Chapter 1

## Introduction

### 1.1 Development of the topical negative pressure technique

Topical negative pressure (TNP) therapy (also called vacuum-assisted closure (VAC) therapy, vacuum sealing or vacuum therapy) has developed from the standard surgical procedure of vacuum-assisted drainage to remove blood or serous fluid from a wound or surgical site. In essence, the TNP technique is very simple. A piece of foam, with an open structure, is inserted into the wound cavity and a wound drain with lateral perforations is placed on top of it. The entire area is then covered with a transparent adhesive membrane, which is firmly secured to the healthy skin around the wound margin. When the exposed end of the drain tube is connected to a vacuum source, fluid is drawn from the wound through the foam into a reservoir for subsequent disposal. The plastic membrane prevents the ingress of air and allows a partial vacuum to form within the wound, reducing its volume and facilitating the removal of fluid.

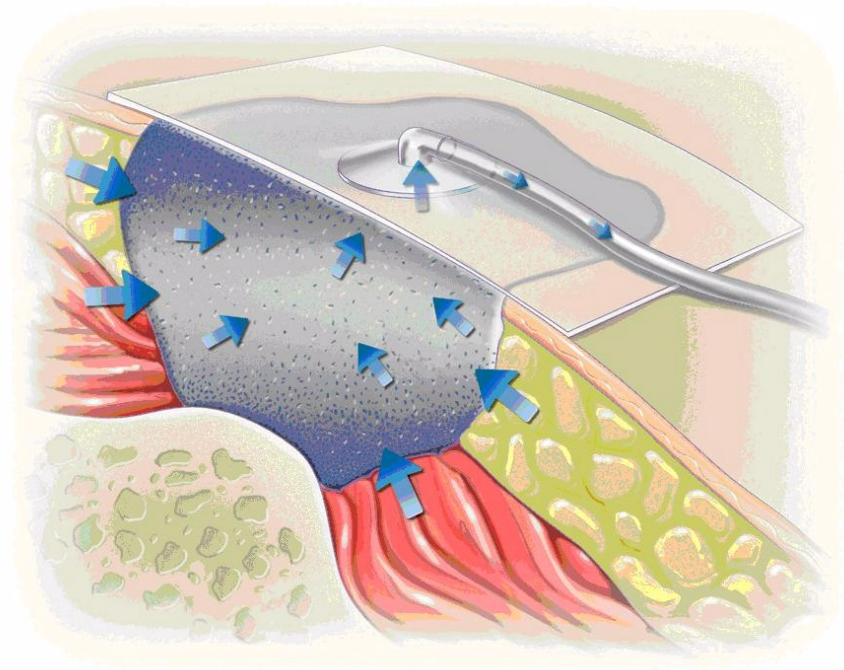


Figure 1.1. Illustration of the application of TNP therapy to a wound, showing the occlusive dressing and vacuum pump (KCI Copenhagen).

The practice of exposing a wound to sub-atmospheric pressure for an extended period of time to promote healing was first described by Fleischmann et al. in 1993, following the successful use of this technique in 15 patients with open fractures. They reported that the treatment resulted in, “efficient cleaning and conditioning of the wound, with marked proliferation of granulation tissue”(1). No bone infections occurred in any of the patients, although one developed a soft tissue infection, which subsequently resolved with further treatment(1). In two further papers, Fleischmann and his colleagues

---

described the treatment of 25 patients with compartment syndromes of the lower limb(2) and 313 patients with various types of acute and chronic infections(3). Further success with topical negative pressure treatment in Germany was reported by Muller (4) following the treatment of 300 patients with infected wounds.

In these early studies, negative pressure was achieved by the use of conventional methods such as wall suction equipment or surgical vacuum bottles. Both these systems are associated with practical problems in terms of the delivery, control and maintenance of the required levels of negative pressure, as discussed by Banwell et al. (5). In 1995, a commercial system for vacuum-assisted closure was introduced in the United States. This equipment, called the VAC®, was designed to overcome some of the problems described by Banwell. The heart of the system is a microprocessor-controlled vacuum unit that is capable of providing controlled levels of continuous or intermittent sub-atmospheric pressure ranging from -25 to -200 mmHg.

In early studies no attempts were made to investigate the physiological mechanisms behind the observed clinical effects, or to determine the optimum level of pressure. A seminal study by Morykwas et al. addressed both these issues using a series of animal studies(6). Deep circular defects, 2.5 cm in diameter, produced on the backs of pigs were dressed with open-cell polyurethane-ether foam with a pore size

---

ranging from 400-600  $\mu\text{m}$ . In the first series of experiments, a laser Doppler technique was used to measure blood flow in the subcutaneous tissue and muscles surrounding the wounds as these were exposed to increasing levels of negative pressure, applied both continuously and intermittently. Their results indicated that while an increase in blood flow equivalent to four times the baseline value occurred with a negative pressure of -125 mmHg, blood flow was inhibited by the application of negative pressures of -400 mmHg and above. A negative pressure of -125 mmHg was therefore used in subsequent studies. The rate of granulation tissue production under negative pressure was determined using the same model by measuring the reduction in wound volume over time. Compared with control wounds dressed with saline-soaked gauze, significantly increased rates of granulation tissue formation were observed with the application of both continuous ( $63.3 \pm 26.1\%$ ) and intermittent ( $103\% \pm 35.3\%$ ) negative pressure.

The observation that intermittent or cycled treatment appeared to be more effective than continuous therapy is interesting, although the reasons for this are not fully understood. Two possible explanations were advanced by Philbeck et al.(7). They suggested that intermittent pressure application results in rhythmic perfusion of the tissue, which is maintained because the process of capillary autoregulation is not activated. They also suggested that as cells that are undergoing mitosis

---

must go through a cycle of rest, cellular component production and division, constant stimulation may cause the cells to 'ignore' the stimulus. Intermittent stimulation allows the cells time to rest and prepare for the next cycle. For this reason, it has been suggested that cyclical negative pressure should be used clinically, although some authors(8) suggest that this should follow a 48-hour period of continuous vacuum to bring about a rapid initial cleansing effect. Following these investigations, Morykwas and colleagues postulated that multiple mechanisms might be responsible for the effects observed. In particular, they suggested that the removal of interstitial fluid decreased localised oedema and increased blood flow, which in turn decreased bacterial levels in tissue. It has since been proposed that the application of sub-atmospheric pressure produces mechanical deformation or stress within the tissue resulting in protein and matrix molecule synthesis(9) and enhanced angiogenesis. Using the rabbit ear as a model, Fabian et al. provided further evidence of the stimulatory effects of sub-atmospheric pressure on the production of granulation tissue, and also demonstrated a trend towards enhanced epithelialisation(10). In experimental partial-thickness burns in pigs, sub-atmospheric pressure was shown to prevent progressive tissue damage in the zone of stasis that surrounds the area of the initial injury. This effect was demonstrable within 12 hours of injury, with treatment times as short as six hours being sufficient to exert a measurable effect(11). The authors proposed that the removal of oedema fluid, containing suspended cellular debris, osmotically active

---

molecules and biochemical mediators released following the initial injury, may lessen the obstruction of blood flow.

Numerous other papers have described the use of TNP in the treatment of a variety of wound types, including extensive degloving injuries(12, 13), infected sternotomy wounds(8, 14) and various soft tissue injuries prior to surgical closure(5, 15-17), and in burn wound management(18, 19).

## 1.2 Physiological basis of TNP

Numerous theories have been advanced to explain the physiological basis of the marked improvement in clinical outcomes achieved with TNP. Two basic, broad mechanisms have been proposed to account for the increased rate of granulation tissue formation and accelerated healing rate: a fluid-based mechanism and a mechanical mechanism. Application of a controlled vacuum to the wound interface facilitates the removal of excess interstitial fluid due to the higher pressure gradient. This physically results in a decrease in interstitial pressure. When the interstitial pressure falls below the capillary pressure, the capillaries reopen and flow to the periwound tissue is restored. This same mechanism is responsible for the success of the vacuum technique for decompression of both muscle compartment and abdominal compartment syndrome. All non-bound soluble factors



---

will also be removed with the fluid, including inhibiting factors and promoting factors. Numerous descriptions have been presented of the change in concentration of various factors over time. Factors measured range from growth factors to metalloproteinases to C-reactive protein. The interactions between the soluble factors related to wound healing, and also those factors and interactions that inhibit or delay healing, are extremely complex. The same factor can both promote and inhibit wound healing, depending on the concentration and timing during the healing process(20). Moreover, the negative pressure and increase in blood flow to the wound bed have been shown to accelerate the formation of granulation tissue (6, 21-23). Interestingly, intermittent application of sub-atmospheric pressure has produced superior results, possibly due to mitigation of the cellular desensitization that occurs with exposure to continuous sub-atmospheric pressure(20). Although it is likely that each of these factors plays a role in the action of TNP, the application of mechanical forces to the wound site is probably the most significant mechanism of action.

Mechanical force is known to be responsible for the induction of cell proliferation and division. Plastic surgeons use tissue expansion to obtain soft-tissue envelopes in reconstructive surgery, while orthopaedic surgeons and maxillofacial surgeons use distraction osteogenesis to lengthen bones(24, 25). Ingber et al. have shown that for cells to respond to soluble mitogenic factors and proliferate, they must be extended, leading to isometric tension, either by adherence to

---

a stiff substrate or by external application of mechanical forces(26). Only stretched cells can divide and proliferate in response to soluble growth factors, whereas cells that are not stretched and assume a more spherical shape are cell-cycle arrested and tend to undergo apoptosis(27, 28). It has also been shown *in vitro* that directional growth of capillary sprouts is promoted by the application of tension in three-dimensional angiogenesis models(28-31). The applied forces deform the extracellular matrix and, as cells are anchorage-dependent, the cells in the stretched tissue are deformed(32, 33). Cell deformation has been shown to cause a wide variety of molecular responses, including changes in ion concentration and permeability of membrane ion channels, release of secondary messengers, stimulation of molecular pathways, and alterations in gene expression(34). Moreover, it is known that vascular endothelial cells express a different array of genes depending on whether they have been exposed to static, laminar or turbulent flow(35-37). It is apparent that cells are able to sense mechanical forces and respond through the regulation of specific genes and the induction of cellular programmes. The exact mechanisms behind these effects are not fully understood, but are probably related to conformational changes in the cytoskeleton in response to mechanical forces. This behaviour provides a natural mechanism for tissue homeostasis, where tissue mass expands, cells are stretched and are thus stimulated to divide.

The application of negative pressure may promote wound angiogenesis by directly stimulating endothelial cells. For example, the

---

application of TNP may cause local wound hypoxia, which is a potent stimulator of vascular endothelial growth factor (VEGF) production, the major endothelial cell mitogen (38). Alternatively, TNP may activate signal transduction pathways leading to endothelial cell division and growth factor production since endothelial tension causes capillary sprouting, gene expression, and changes in matrix metalloproteinase (MMP) activity(29, 36, 39, 40). While TNP may directly stimulate endothelial proliferation by local hypoxia or cell deformation, increased wound angiogenesis may be an indirect effect of the TNP-mediated reduction in MMP activity. Although low levels of MMPs have been shown to favour angiogenesis, elevated MMP activity inhibits neovascularization and is associated with chronic wounds(41-43). Specifically, the levels of the gelatinases MMP-9 and MMP-2 are significantly higher in nonhealing wounds, but return to normal as wound healing progresses towards closure(44-49). In addition, chronic wound exudates that inhibit endothelial activity will instead stimulate angiogenesis after treatment with an MMP inhibitor(50). A reduction in MMP activity may promote endothelial proliferation by lowering MMP-mediated angiostatin and endostatin production(47, 51). Alternatively, the inhibition of a MMP-propagated inflammatory cascade may provide an environment more favourable to capillary growth(52).

Mechanical properties seem to have a greater influence on clinical efficacy than fluid-based properties, according to a recently published article, in which the authors showed that the application of

---

mechanical shear stresses was able to activate the VEGF pathway without any VEGF being present in the culture fluid (53).

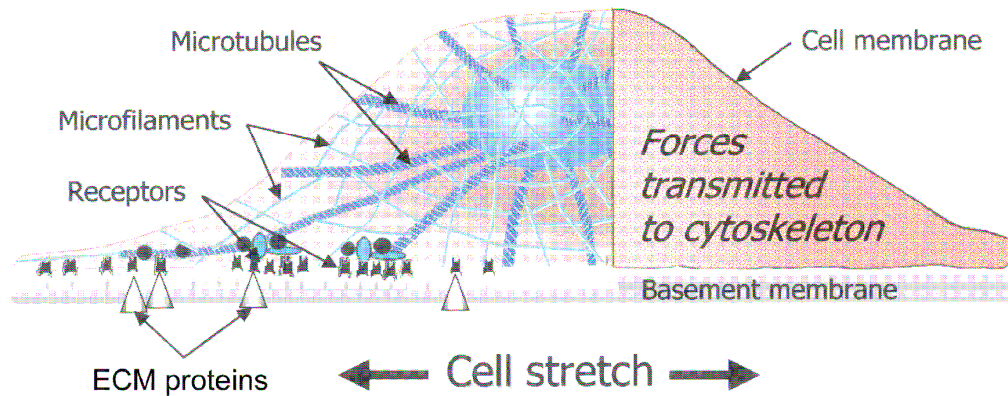


Figure 1.2. Schematic view of a cell (with cytoskeletal elements) attached to a basement membrane. The cell can be extended by attachment to the extracellular matrix and/or by the application of an external force. It has been hypothesized that when microfilaments and microtubules are deformed by cell stretching, they trigger the regulation of gene pathways. From: plastic and reconstructive surgery, October 2004.

### 1.3 Post-sternotomy mediastinitis

Post-sternotomy mediastinitis after coronary artery bypass grafting (CABG) is a serious and potentially life-threatening complication, with a high mortality rate and substantial morbidity(54-57). Recently, the use of TNP has gained acceptance in the treatment of post-sternotomy mediastinitis, and is today the standard mode of treatment in many cardiac surgery centres throughout the world(58-62). Before the introduction of TNP therapy, the risk of late death in patients suffering from mediastinitis after cardiac surgery was reported to be

---

two to three times higher than that of patients without mediastinitis(54-56). Milano and colleagues suggested that mediastinitis may have negative long-terms effects on several organs, such as the heart and kidneys(63). Theoretically, a massive immunological response during a prolonged period of infection may cause adverse effects on bypass grafts. In studies reporting poor long-term survival after mediastinitis, several conventional wound healing techniques were used (closed irrigation, delayed wound closure, or reconstruction with omentum or pectoral flaps). Interestingly, Sjogren and co-workers, found no difference in long-term survival between CABG patients with TNP-treated mediastinitis and CABG patients without mediastinitis(60). During the treatment of post-sternotomy mediastinitis with TNP, the pressure is in direct contact with the heart, which is exposed through the diastase of the sternotomy. These patients may therefore have developed increased coronary collateral blood vessels during TNP, and may be better prepared when bypass grafts fail to work. In the research described in this thesis, richly vascularized granulation tissue was seen to develop over the heart within 7-8 days in patients treated with TNP. It may well be that the stimulation of blood flow and the development of collateral blood vessels resulting from TNP in part account for the reduced long-term mortality in patients treated in this way.

---

#### 1.4 Coronary anatomy and blood flow

The heart has the highest oxygen consumption per unit mass of all human organs. The resting coronary blood flow is 250 ml/min, and represents 5% of the cardiac output. Ischaemia results when the oxygen demand exceeds the supply. Arterial oxygen extraction is 70–80%, compared with 25% for the rest of the body. Therefore, increased oxygen consumption must principally be met by an increase in coronary blood flow, which may increase fivefold during exercise. Supply usually closely matches the change in demand. However, an increase in coronary blood flow can independently increase myocardial oxygen consumption. This may be explained by full coronary arteries splinting the heart and increasing the end-diastolic fibre length and contractility(64). The two coronary ostia arise from the sinuses of Valsalva just above the aortic valve. The left main coronary artery divides into the left anterior descending (LAD) and circumflex (CCX) branches. It supplies the lateral and anterior walls of the left ventricle and the anterior two thirds of the interventricular septum. The right coronary artery (RCA) supplies the right ventricle, the posterior wall of the left ventricle and posterior third of the septum. The major coronary arteries divide into epicardial arteries. These vessels distribute blood to different regions of the heart muscle. When the vessels are not diseased, they have a low vascular resistance relative to their more distal and smaller branches, which comprise the microvascular network. As in all vascular beds, it is the small arteries and arterioles in the microcirculation that are the primary sites of

vascular resistance, and therefore the primary source of regulation of blood flow. The arterioles branch into numerous capillaries that lie adjacent to the cardiac myocytes. A high capillary-to-cardiomyocyte ratio and short diffusion distances ensure adequate oxygen delivery to the myocytes and the removal of metabolic waste products from the cells (e.g.,  $\text{CO}_2$  and  $\text{H}^+$ ). Capillary blood flows into the venules, which join together to form cardiac veins, and then drains into the coronary sinus located on the posterior side of the heart, which in turn drains into the right atrium. There are also anterior cardiac veins and thebesian veins that drain directly into the cardiac chambers(64).

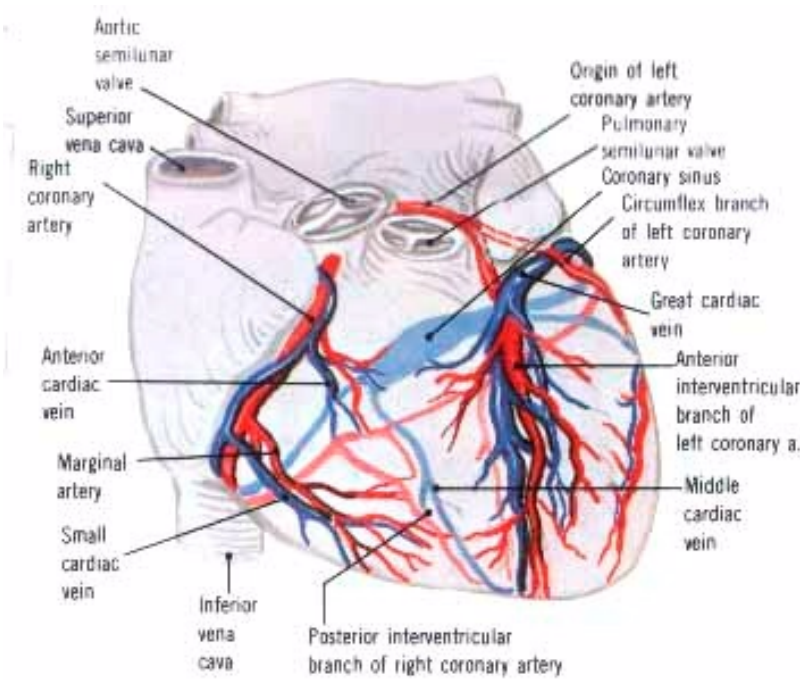


Figure 1.3. Schematic view of the coronary arteries and veins; the arteries are shown in red, and the veins in blue.

---

### 1.5 Determinants of coronary blood flow

The factors that determine coronary blood flow are the coronary perfusion pressure, the perfusion time and the blood vessel wall diameter. During systole, intramuscular blood vessels are compressed and twisted by the contracting heart muscle and blood flow to the left ventricle is at its lowest. The pressure is greatest in the subendocardial layers where it approximates the intramyocardial pressure. In systole, intramyocardial blood is propelled forwards towards the coronary sinus and retrogradely into the epicardial vessels, which act as capacitors. Flow resumes during diastole when the muscle relaxes. The coronary perfusion pressure is the difference between the aortic diastolic pressure and the left ventricular end-diastolic pressure (LVEDP). Phasic changes in blood flow to the right ventricle are less pronounced because of the lesser force of contraction. Central venous pressure may be more appropriate for calculating the right-sided coronary perfusion pressure(64). An increase in heart rate affects the diastolic period more than the systolic period, and reduces the coronary blood vessel perfusion time. Vasomotor tone and deposits inside the vascular lumen determine the vessel wall diameter. The interplay of various mechanisms that regulate the coronary vasomotor tone usually favours vasodilatation(65).

### 1.6 Factors influencing the vasomotor tone

The factors influencing the vasomotor tone are the following: the myocardial metabolism, the autoregulation of the blood vessels, the



---

nervous and humoral control, the vascular endothelium and the myocardial oxygen balance. The vasomotor tone is almost exclusively determined by local metabolic oxygen demand. Hypoxia causes coronary vasodilatation directly but also releases adenosine and opens ATP-sensitive potassium channels. Pre-capillary sphincters are relaxed and more capillaries recruited.

Under resting conditions, coronary blood flow remains constant at mean arterial pressures between 60 and 140 mm Hg. Outside this range, flow becomes pressure-dependent. Probable mechanisms include the myogenic response to intraluminal pressure changes (fast) and metabolic regulation (slow). The myocardial oxygen tension and the presence of vasoconstrictors or vasodilators influences the range of coronary autoregulation(66).

Autonomic influences are generally weak. It is difficult to determine the role of neural control on coronary blood flow, as the metabolic effects of any change in blood pressure, heart rate or contractility dominate the subsequent response. The epicardial blood vessels have primarily receptors, the stimulation of which produces vasoconstriction. Intramuscular and subendocardial blood vessels have predominantly  $\beta_2$  receptors (vasodilatation). Sympathetic stimulation increases myocardial blood flow in response to an increase in metabolic demand and a predominance of  $\beta$  receptor activation. Alpha stimulation may play a role in the distribution of blood flow within the myocardium by restricting metabolically mediated flow

---

increase and exerting an anti-steal effect. Parasympathetic influences are minor and weakly vasodilatory. The vasodilatory effect of acetylcholine is dependent on an intact endothelium(65, 66).

Most vasoactive hormones require an intact vascular endothelium. The peptide hormones include antidiuretic hormone, atrial natriuretic peptide, vasoactive intestinal peptide and calcitonin gene-related peptide. Antidiuretic hormone has little effect on the coronary circulation at physiological concentration, but causes vasoconstriction in stressed patients. The other peptides cause endothelium-mediated vasodilatation. Angiotensin II causes coronary vasoconstriction, independent of sympathetic innervation. It also enhances calcium influx and releases endothelin, the strongest vasoconstrictor peptide yet identified in humans. Angiotensin-converting enzyme inactivates bradykinin, a vasodilator. The vascular endothelium also regulates vasomotor tone. It modulates the contractile activity of the underlying smooth muscle through the synthesis and secretion of vasoactive substances in response to blood flow, circulating hormones and chemical substances. Vasorelaxants include endothelium-derived relaxing factor, nitric oxide, prostacyclin and bradykinin. Vasoconstrictors include endothelin and thromboxane  $A_2$ . The net response depends on the balance between the two opposing groups(67, 68).

Oxygen delivery is the product of arterial oxygen-carrying capacity and myocardial blood flow. The diastolic pressure time index (DPTI) is a

---

useful measure of coronary blood supply, and is the product of the coronary perfusion pressure and diastolic time. Similarly, the oxygen demand can be represented by the tension time index (TTI), which is the product of systolic pressure and systolic time. The ratio  $DPTI/TTI$  is called the endocardial viability ratio (EVR) and represents the balance between myocardial oxygen supply and demand. The EVR is normally 1 or more. A ratio  $<0.7$  is associated with subendocardial ischaemia(66, 69).

Progressive ischaemic coronary artery disease results in the growth of new vessels (angiogenesis) and collateralization within the myocardium. Collateralization increases the myocardial blood supply by increasing the number of parallel vessels, thereby reducing vascular resistance within the myocardium. Coronary artery disease usually leads to a reduction in coronary blood flow. This will increase the amount of oxygen extracted from the coronary blood and decrease the venous oxygen content. This leads to tissue hypoxia and angina. If the lack of blood flow is due to a fixed stenotic lesion in the coronary artery (due to atherosclerosis), blood flow can be improved in that vessel by percutaneous coronary intervention (PCI) or CABG(66).

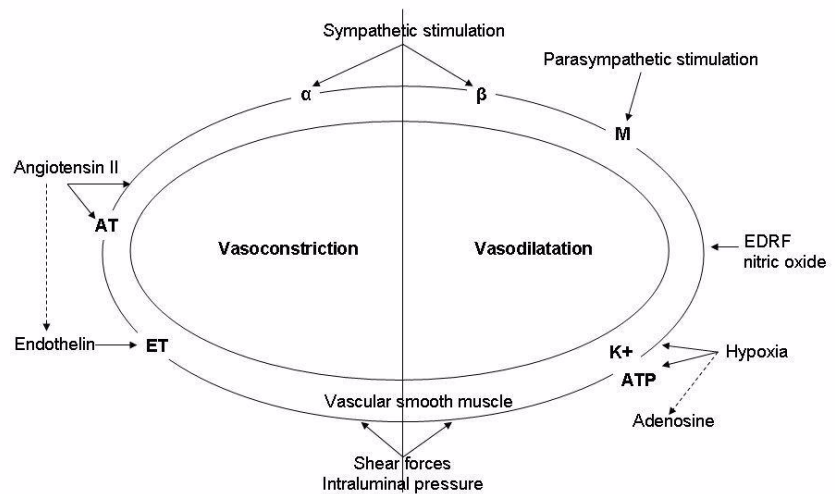


Figure 1.4. Factors affecting coronary vasomotor tone;  $\alpha$ ; alpha receptor,  $\beta$ ; beta receptor, M; muscarinic receptor, AT; angiotensin receptor, ET; endothelin receptor, K<sup>+</sup> ATP; ATP-sensitive potassium channel. Vasomotor tone is ultimately mediated by the vascular endothelium, which secretes vasodilators; endothelium-derived relaxant factor (EDRF), nitric oxide and endothelin, a potent vasoconstrictor.

## 1.7 Autoregulation

Autoregulation is a manifestation of local blood flow regulation. It is defined as the intrinsic ability of an organ to maintain a constant blood flow despite changes in perfusion pressure. For example, if the perfusion pressure to an organ is decreased (e.g., by partially occluding the arterial supply to the organ), blood flow initially falls, then returns towards the normal level over the next few minutes. This autoregulatory response

---

occurs in the absence of neural and hormonal influences and is therefore intrinsic to the organ. When the perfusion pressure (arterial minus venous pressure,  $P_A - P_V$ ) initially decreases, the blood flow (F) falls according to the following relationship between pressure, flow and resistance (R):

When the blood flow falls, the arterial resistance falls as the resistance vessels (small arteries and arterioles) dilate. Many studies suggest that these metabolic, myogenic and endothelial mechanisms are responsible for this vasodilation. As resistance decreases, blood flow increases despite the reduction of perfusion pressure(64). If the perfusion pressure is reduced from 100 to 70 mmHg, it causes flow to initially decrease by approximately 30%. Over the next few minutes, however, flow begins to increase back towards the normal value if the organ is capable of autoregulation. This occurs because vascular resistance falls. If autoregulation does not occur, the flow will remain decreased(64).

Different organs display varying degrees of autoregulatory behaviour. The renal, cerebral and coronary circulations show excellent autoregulation, whereas skeletal muscle and splanchnic circulations show moderate autoregulation. The cutaneous

---

circulation shows little or no autoregulatory capacity(64). There are situations in which arterial pressure does not change, but autoregulation is still very important. Whenever a distributing artery to an organ becomes narrowed (e.g., atherosclerotic narrowing of the lumen, vasospasm or partial occlusion by a thrombus) this can result in an autoregulatory response. Narrowing of distributing arteries increases their resistance and hence the pressure drop along their length. This results in a reduced pressure in smaller arteries and arterioles, which are the primary vessels for regulating blood flow within an organ. These resistance vessels dilate in response to reduced pressure and blood flow. This autoregulation is particularly important in organs such as the brain and heart, in which partial occlusion of large arteries can lead to significant reductions in oxygen delivery, thereby leading to tissue hypoxia and organ dysfunction(64).

## 1.8 Stenosis

Stenosis increases the vascular resistance, as described by Poiseuille's equation, which states that resistance is inversely related to the radius to the fourth power. Therefore, if the radius (or diameter) of a vascular segment is reduced by one-half, the resistance within that narrowed segment increases 16 times. If this vascular segment were being perfused in isolation, the flow would be decreased 16-fold if the perfusion pressure remained constant(64). The term 'critical stenosis' refers to the critical narrowing of an artery (stenosis) that

---

results in a significant reduction in maximal flow capacity in a distal vascular bed. A critical stenosis may or may not reduce the resting flow depending on the organ's capacity to autoregulate its blood flow and the development of collateral blood flow, both of which serve to reduce the overall resistance in the smaller resistance vessels. Resting flow is affected if the diameter is reduced by 80%. With increasing stenosis, distal arterioles dilate maximally to preserve flow up to the point where the vascular bed is maximally dilated. Further stenosis leads to a drop in flow and the flow becomes pressure dependent. Flow diverted into a dilated parallel bed proximal to a stenosis is called 'coronary steal' and can aggravate ischaemia. Flow in collateral vessels is also often pressure dependent(64).

## 1.9 Collateral blood flow

Collateral vessels can play a significant role in supplying oxygen to an organ, particularly when oxygen delivery is limited by disease in the normal vasculature. Collateral vessels may be pre-existing vessels that normally have little or no blood flow. Acute occlusion of normal vessels (e.g., thrombosis of a large artery) can cause the redistribution of pressure within the vascular bed, thereby causing blood flow to occur in collateral vessels. Conditions of chronic stress (e.g., endurance exercise training or chronic hypoxia) can cause new blood vessels to form by angiogenesis(64). Collateral blood vessels are

---

particularly important in the coronary and skeletal muscle circulations. In the heart, collateral vessels can help to supply blood to ischaemic regions caused by stenosis or the occlusion of epicardial arteries. Collateral blood flow may be an important mechanism in limiting infarct size in the heart. Current research is directed towards stimulating the formation of collateral blood vessels by treating the heart with drugs that stimulate angiogenesis (66).

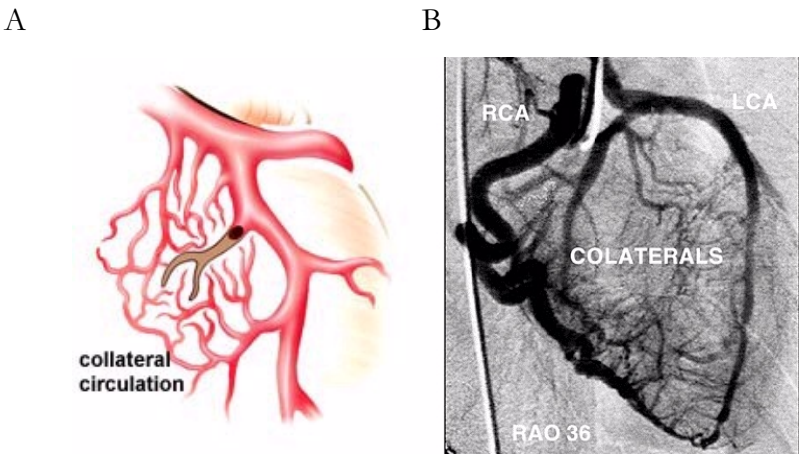


Figure 1.5. (A) A schematic view of a coronary artery with a chronic occlusion, and collateral blood vessel formation around the occluded artery, i.e. collateral circulation. (B) Coronary angiography in the right anterior oblique view (RAO), showing the right coronary artery (RCA) and retrograde flow to the left coronary artery (LCA) via collateral vessels.

### 1.10 Ventricular fibrillation

Sinus rhythm of the heart consists of systolic and diastolic phases. When the left ventricle contracts it compresses vessels in its walls and reduces coronary flow. The compressive force is greater in subendocardial muscle, i.e. the same or higher pressure than in the left



---

ventricular cavity(70). The pressure falls toward the epicardium where it reaches levels close to atmospheric pressure. In diastole all parts of the ventricular wall are perfused, whereas in systole only the epicardial part is perfused(70). During ventricular fibrillation there is no synchronized contraction in the ventricles. However, if the perfusion pressure is kept around 100 mmHg, as for example during coronary pulmonary bypass (CPB), the myocardium will still be adequately perfused(71). If the perfusion pressure is reduced to approximately 50 mmHg, the left ventricular flow may be redistributed away from the subendocardium, and ischaemia may occur in this area(71).

### 1.11 Ventricular fibrillation and ischaemia

Ischaemia is more prone to occur during the circumstances mentioned above if the ventricular wall is hypertrophied(72). Hottenrot et al. showed in 1972 that perfusion of a fibrillating dog heart for one to two hours did not damage the subendocardial muscle unless a strong electrical stimulus was maintained(73). Buckberg et al. showed in 1977 that the myocardial wall tension is always higher in a fibrillating heart than in a beating heart during both normothermia and hypothermia(74). They also showed that left ventricular coronary flow remained distributed equally over the ventricular wall in both the beating and fibrillating heart at temperatures of 28 and 22°C, but was redistributed towards the subendocardium in the fibrillating heart at 37 and 32°C. Moreover, cold fibrillating hearts were found to consume slightly less oxygen per minute than beating hearts at

---

comparable temperatures, as fibrillation consumed less energy under hypothermia(74, 75). To avoid subendocardial ischaemia in the fibrillating heart during CPB no sustained electrical stimuli should be used, the ventricle should be protected from distension with, for example, a ventricular vent, and the perfusion pressure should be kept above 50 mmHg(76). Prolonged ischaemia may also produce a myocardial oedema that may influence subendocardium perfusion(76).

### 1.12 Theory of laser Doppler flowmetry

Laser Doppler flowmetry is a non-invasive method of estimating blood perfusion in the microcirculation. The method was first introduced over 30 years ago and has undergone continuous development since(77, 78). The advantage of the technique is that it provides a continuous, or almost continuous, record of the microvascular blood flow. The principal disadvantage is that it is impossible to calibrate the flow in absolute units. A beam from a red or near infrared, low-power laser is directed via an optical fibre onto the tissue that is to be studied, and the light scattered back from the tissue is collected by one or more optical fibres and analysed. Several parallel fibres are used in a single probe. Light scattered from moving blood cells within the tissue undergoes a change in wavelength, equivalent to a shift in frequency (the Doppler shift), the magnitude of which depends on the velocity of the red blood cells. Light scattered from stationary structures shows no change in frequency. The light

---

collected by the returning fibre is converted into an electronic signal and analysed. The amplitude of the fluctuation will increase with the intensity of the incident light and the number of cells scattering the light. No current laser Doppler instrument can provide absolute values of perfusion, and the results are therefore expressed as arbitrary perfusion units (PU). To enable the comparison of results it is essential to calibrate laser Doppler equipment(79-81).

### 1.13 Laser Doppler measurements on the heart

Laser Doppler flowmetry measurements provide a continuous record of the microvascular blood flow or microvascular perfusion.

Radioactive or coloured microspheres have also been used to measure microvascular perfusion, for example, before and after the injection of a drug into the myocardium(82-84). In 1996, Sidi et al. compared the use of radioactive microspheres to laser Doppler flowmetry for measuring regional myocardial blood flow. Laser Doppler flowmetry was found to correlate better to changes in the microvascular blood flow than the measurements with radioactive microspheres(83).

Laser Doppler measurements of the blood flow in the myocardium are complex. In 1988, Ahn et al. assessed the myocardial perfusion in six empty beating porcine hearts with laser Doppler flowmetry. CPB was instituted and continuous and simultaneous measurements were made of coronary sinus blood flow and local tissue perfusion. An epicardial and an intramuscular probe were used. They found

---

significant linear correlation between changes in the laser Doppler signal and the coronary sinus blood flow, and between laser Doppler signals and changes in extracorporeal bypass flow rate. The correlation between coronary sinus flow rate and bypass flow rate was significant. The muscular activity of the heart contributed to the laser Doppler signal, and the magnitude of the 'noise' varied between different experiments, even in the same animal, which made it difficult to discriminate between the contributions from blood flow and muscular activity(85).

Ahn et al. also applied laser Doppler flowmetry to the arrested heart of four pigs and to the fibrillating heart of three pigs during cardiopulmonary bypass. The rate of coronary blood flow was maintained during cardiac arrest by infusion of hyperkalaemic blood into the aortic root. A significant correlation was found between the laser Doppler signal and coronary blood flow rate during cardiac arrest. During ventricular fibrillation, there was a significant correlation between the laser Doppler signal and extracorporeal blood flow after the release of the aortic cross-clamp. A residual laser Doppler signal, of about 60% of the maximal value, was recorded after the bypass flow was discontinued. Ahn et al. concluded that laser Doppler flowmetry allows the measurement of myocardial perfusion in the arrested porcine heart, and that the muscular activity of the heart contributes to the output signal during ventricular fibrillation(86). However, it is unclear if the venous blood returning to the heart from the superior and inferior vena cava, and also the

---

associated cava (specific to pigs), was occluded in the study when the bypass flow was discontinued, or if the measurements were adjusted to the systemic pressure. If the measurements were not adjusted, the returning venous blood would probably have raised the intraventricular pressure and the tension of the myocardial ventricular wall, which might have influenced the measurements(87). It was shown, in a porcine model, that ventricular fibrillation causes venous congestion, an empty left heart, and a greatly distended right heart within 3 min, and that the blood pressure is 50 mmHg after 20 seconds and 20-30 mmHg after 1½-2 minutes, which might also have influenced the measurements(87).

In 2001, Barclay et al. demonstrated laser Doppler measurements in a canine beating heart without CPB. To obtain a stable measurement of predominately the motion of red cells in the microcirculation they used an ultra-stable laser and achieved measurement stability by heterodyning the laser light and reflected light from the tissue, which introduces further complexity into the measurements(88). Li XF et al. performed myocardial microperfusion measurements by laser Doppler flowmetry in a beating rat heart. To obtain stable measurements they used needle laser Doppler probes with a holder that was adhered to the epicardium(89). During low-intensity ventricular fibrillation, the heart muscle makes small movements, and the artefacts and any possible movement of the probe can be minimized, thereby making measurements of the myocardium with laser Doppler flowmetry easier. Changes in the tissue caused by trauma, including bleeding,

---

ischaemia and oedema, might influence the microvascular circulation leading to erroneous results. Probe movement can also have a significant influence on the laser Doppler measurements.

#### 1.14 Ultrasonic flow meter

An ultrasonic flow meter (or non-intrusive Doppler flow meter) is a volumetric flow meter that requires particulates or bubbles in the flow. The basic principle of the technique is the Doppler shift in frequency, as above, but in this case that of an ultrasound signal when it is reflected by suspended particles or gas bubbles (discontinuities) in motion(90).

---

## Chapter 2

### Aims

The aims of this work were:

#### Paper I

Paper I was designed to elucidate whether the increase in microvascular blood flow due to TNP is the result of an increase in the total amount of coronary blood flow, or merely the redistribution of coronary blood flow. A redistribution of, or decrease in, the total coronary blood flow could cause ischaemia in parts of the myocardium not exposed to TNP. However, an increase in total coronary blood flow would theoretically stimulate granulation tissue formation, i.e. endothelial proliferation, capillary budding and angiogenesis. The paper was also intended to reveal any correlation between microvascular blood flow measured by laser Doppler flowmetry, and coronary blood flow measured by coronary ultrasonic flowmetry.

---

## Paper II

Paper II was designed to investigate whether the application of TNP directly to normal, ischaemic and reperfused myocardium resulted in an increase in microvascular blood flow, such as that seen when exposing skeletal muscle to TNP. Microvascular blood flow was measured using laser Doppler flowmetry.

## Paper III

The aim of paper III was to determine the negative pressure level on the myocardium that would induce maximal increase in myocardial microvascular blood flow in normal and ischaemic myocardium.

## Paper IV

Paper IV was designed to investigate whether a relative hypoperfusion zone is produced in the epicardium, at a depth of 1-2 mm in the heart muscle, during the application of myocardial TNP. A large zone of persistent hypoperfusion could theoretically cause ischaemia in the myocardium. The microvascular blood flow was measured using laser Doppler flowmetry.

## Paper V

Paper V was designed to compare the microvascular blood flow in ischaemic myocardium during continuous and intermittent application



---

of a TNP of -50 mmHg for a period of 20 minutes. The microvascular blood flow was measured using laser Doppler flowmetry.

---

---

## Chapter 3

### Material and Methods

#### 3.1 Experimental animals

A porcine model was used in the studies presented in this thesis. Domestic landrace pigs of both genders, with a mean body weight of 70 kg, were fasted overnight with free access to water. The studies were approved by the Ethics Committee for Animal Research, Lund University, Sweden. The investigation complied with the “Guide for the Care and Use of Laboratory Animals” as recommended by the U.S. National Institutes of Health, and published by the National Academies Press (1996).

---

### 3.2 Anaesthesia

All animals were pre-medicated intramuscularly with ketamine (30 mg/kg) before they were brought into the laboratory. Before commencing surgery sodium thiopental (5 mg/kg), atropine (0.02 mg/kg) and pancuronium (0.5 mg/kg) were given intravenously. Tracheotomy was performed with a Portex endo-tracheal tube (7.5 mm internal diameter, Medcompare™, USA). A servo-ventilator (Siemens Elema 300A, Stockholm, Sweden) was used for mechanical ventilation throughout the experiments. The ventilator settings used were: minute volume = 100 ml/kg,  $\text{FiO}_2 = 0.5$ , breathing frequency = 16 breaths/minute and positive end expiratory pressure = 5 cmH<sub>2</sub>O. Anaesthesia and muscular paralysis were maintained with continuous intravenous infusion of 8-10 mg/kg/hour propofol (Diprivan®, AstraZeneca, Sweden), 0.15 mg/kg/hour fentanyl (Leptanal®, Lilly, France) and 0.6 mg/kg/hour pancuronium (Pavulon®, Organon Teknika, Boxtel, the Netherlands).

### 3.3 Data acquisition

Mean arterial pressure, central venous pressure, heart frequency and ventilatory parameters were recorded throughout the experiments.

---

### 3.4 Surgical procedure

Surgery was performed through median sternotomy. After heparinization (400 IU/kg) a CPB was installed with an arterial cannula (22 French, DLP<sup>®</sup> Elongated One-Piece Arterial Cannula (EOPA<sup>™</sup>), Medtronic Inc., Minneapolis, MO, USA) in the distal ascending aorta, and a venous cannula (32 French, MC2<sup>®</sup> Two-Stage Venous Cannula, also from Medtronic Inc.) inserted through the right atrium. Before cannulation of the heart the cannulae were inserted through the thoracic wall to prevent air leakage during TNP application. CPB was conducted in normothermia. Ventricular fibrillation was subsequently induced in the heart. No aortic cross-clamping was performed and no cardioplegia was employed. The mean arterial pressure was maintained between 60 and 80 mmHg. A left ventricular vent (DLP<sup>®</sup> Vent, also from Medtronic Inc.) was used to protect the left chamber from overloading. Pulmonary ventilation was applied at a rate of 4 litres /minute during the experiments.

A CPB was used to facilitate measurements of the microvascular blood flow using laser Doppler flowmetry. Fibrillation of the heart minimizes the movement artefacts, while the physiological conditions are, to a large extent, conserved. Moreover, CPB prevents the risk of circulatory failure during LAD occlusion, thereby facilitating experimental analysis in the case of the ischaemic myocardium.

---

In Paper I, the coronary ultrasonic flow meter probes (CardioMed CM-4000 Transit Time & Doppler Flow meter, type CM4001; S.N. 0171. Medi-Stim AS, Grefsen, Oslo, Norway) were positioned around the proximal part of the coronary vessels, LAD, CCX, and RCA respectively. The coronary blood flow was measured continuously throughout the experiments. Calibration of each probe was checked *in vitro* at the end of each experiment.

Microvascular blood flow was measured using laser Doppler flowmetry (a Transonic® Laser Doppler Monitor, BLF21, Maastricht, the Netherlands was used in Paper II, and Peri Flux System 5000, PeriMed, Stockholm, Sweden, in Studies I, III, IV and V), employing a technique that quantifies the sum of the motion of the red blood cells in a specific volume. This method is used extensively in plastic surgery procedures and employs a fiberoptic probe carrying a beam of light. Light impinging on cells in motion undergoes a change in wavelength (Doppler shift) while light impinging on static objects remains unchanged. The magnitude and frequency distributions of the changes are directly related to the number and velocity of red blood cells. The information is collected by a returning fiber, converted into an electronic signal, and analyzed(91).

Laser Doppler probes were inserted horizontally into the heart muscle, 6-8 mm lateral of the LAD, at depths of approximately 6-8

---

mm (Studies I, II, III and V), and at depths of approximately 1-2 mm (Paper IV). All probes were carefully fixed to the surface of the heart with a suture (Prolene 7-0; Ethicon Inc., NJ, USA), thereby preventing probe movement. After the experiments, the heart was dissected and the probe location was confirmed.

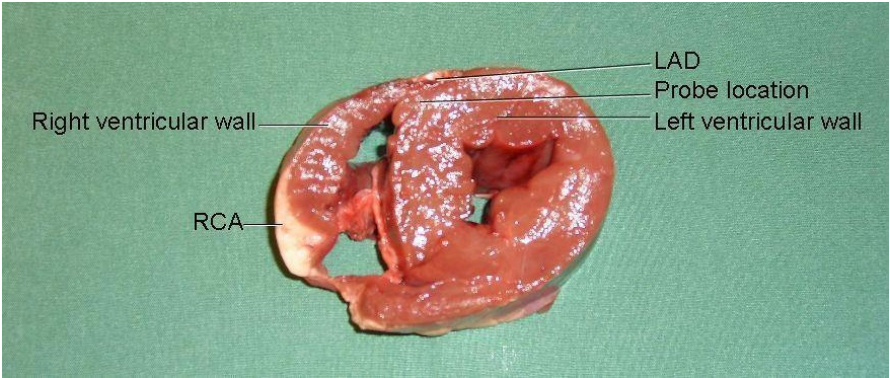


Figure 3.1. A photograph showing the location of the laser Doppler probes. Laser Doppler probes were inserted horizontally into the heart muscle 8-10 mm lateral of the left anterior descending artery (LAD), i.e. the septum of the heart, at depths of approximately 6-8 mm. The photograph also shows the location of right coronary artery (RCA).

A round hole, 5 cm in diameter, was made in the middle of a phrenic nerve pad (Phrenic Nerve Pad<sup>®</sup>, Medtronic Inc.) and placed on top of the heart. The pad was stabilized by 8-10 sutures to the surrounding myocardium (Prolene 5-0; Ethicon Inc.) and by sutures to the posterior sternal edges (Dermalon 2-0; Davis and Geck, St. Louis, NJ, USA). A retractor was used throughout the experiments to keep the

---

myocardium (Prolene 5-0; Ethicon Inc.) and by sutures to the posterior sternal edges (Dermalon 2-0; Davis and Geck, St. Louis, NJ, USA). A retractor was used throughout the experiments to keep the sternal edges apart. A polyurethane foam dressing, with an open pore structure of 400 to 600  $\mu\text{m}$  (KCI, Copenhagen, Denmark) was placed between the sternal edges. The foam was continuously sutured to the surrounding skin (Dermalon 2-0; Davis and Geck). The wound was sealed with a transparent adhesive drape. A Track Pad (KCI) was inserted through the drape and was connected to a vacuum pump, (V.A.C. pump unit, KCI). When the negative pressure is applied, the heart will be drawn up towards the phrenic nerve pad and the foam without interfering with the sternal edges. This procedure causes the application of negative pressure to affect only the myocardium exposed by the 5 cm diameter hole.

### 3.5 Experimental protocol

#### Paper I

The coronary blood flow was measured continuously by ultrasonic flow meter probes and the microvascular blood flow in the myocardium was measured continuously with the laser Doppler filament probes. Recordings were made in normal myocardium, before and while a negative pressure of -50 mmHg was applied.



---

The LAD was then occluded for 20 minutes with an elastic vessel loop. Coronary blood flow and the microvascular blood flow were then measured before, and after 1, 5, 10, 15 and 20 minutes of occlusion. A negative pressure of -50 mmHg was then applied to the heart, and changes in the coronary blood flow and the microvascular blood flow were recorded. The negative pressure was then removed.

## Paper II

The microvascular blood flow was measured continuously by the laser Doppler filament probes. Recordings were made in normal myocardium, before a negative of -50 mmHg pressure was applied, and immediately after the negative pressure was turned of.

The LAD was occluded for 20 minutes with an elastic vessel loop. Microvascular blood flow was then measured before, and after 1, 5, 10, 15 and 20 minutes of occlusion. A negative pressure of -50 mmHg was then applied to the heart, and changes in microvascular blood flow were recorded. The negative pressure was then removed.

LAD occlusion was released and microvascular blood flow was measured before, and after 1, 5, 10, 15 and 20 minutes of reperfusion. A negative pressure of -50 mmHg was then applied to the heart, and changes in microvascular blood flow were measured. The negative pressure was then removed.

---

### Paper III

The microvascular blood flow was measured continuously via the laser Doppler filament probes. Recordings were made in normal myocardium, before negative pressure was applied, and at negative pressures of -50, -75, -100, -125 and -150 mmHg.

The LAD was then occluded for 20 minutes with an elastic vessel loop. Microvascular blood flow was measured before, and after 5, 10, 15 and 20 minutes of occlusion. Recordings were also made in ischaemic myocardium, before negative pressure was applied, and at negative pressures of -50, -75, -100, -125, and -150 mmHg.

### Paper IV

The microvascular blood flow was measured continuously using the laser Doppler filament probes. Recordings were made in normal myocardium, before negative pressure was applied, and at negative pressures of -50 and -125 mmHg. The LAD was then occluded for 20 minutes with an elastic vessel loop. Microvascular blood flow was measured before, and after 5, 10, 15 and 20 minutes of occlusion. Recordings were also made in ischaemic myocardium, before negative pressure was applied, and at negative pressures of -50 and -125 mmHg.

---

## Paper V

Two series of measurements were made in the same animal with a rest period of 20 minutes between them. The microvascular blood flow was measured continuously by the laser Doppler filament probes. The LAD was occluded for 20 minutes with an elastic vessel loop. Recordings were made in ischaemic myocardium, before negative pressure was applied, and every minute for 20 minutes during the continuous application of a negative pressure of -50 mmHg.

Recordings were also made in ischaemic myocardium, before negative pressure was applied, and after every minute for 20 minutes during the intermittent application of a pressure of -50 mmHg 5 minutes followed by 2 minutes without pressure. The order of the measurements was reversed in alternate animals to minimize any possible carry-over effect.

## 3.6 Calculations and statistics

## Paper I

Laser Doppler flowmetry was performed on six pigs. The output was continuously recorded using PeriSoft software (PeriMed, Stockholm, Sweden). Microvascular blood flow was expressed in terms of PU. Calculations and statistical analysis were performed using GraphPad

---

4.0 software. Statistical analysis was performed on microvascular blood flow and coronary blood flow, using Student's paired t-test. Values are presented as means  $\pm$  the standard error on the mean (SEM). The correlation between microvascular blood flow measured by laser Doppler flowmetry, and coronary blood flow measured with an coronary ultrasonic flow meter, was determined using Pearson correlation, with a two-tailed p value. Significance was defined as  $^*p < 0.05$  and  $p > 0.05$  (not significant, n.s.).

## Paper II

Laser Doppler flowmetry measurements were performed on six pigs. The output was continuously recorded using a Transonic® Laser Doppler Monitor. Microvascular blood flow was expressed in terms of PU. Calculations and statistical analysis were performed using GraphPad 4.0 software. Statistical analysis was performed using Student's paired t-test. Significance was defined as:  $^*p < 0.05$ ,  $^{**}p < 0.01$  and  $^{***}p < 0.001$  and  $p > 0.05$  (not significant, n.s.). Values are presented as means  $\pm$  SEM.

## Paper III

Laser Doppler velocimetry measurements were performed on seven pigs. The output was continuously recorded using PeriSoft software. Microvascular blood flow was expressed in terms of PU. A repeated

---

measurement general linear model was used to test the main effect of treatment and subject on normal myocardium and ischaemic myocardium. Post hoc testing of the treatment was performed using Dunnet's test with a control (Baseline/No treatment/0 mmHg). Analysis of the residuals of the model was also performed to check for model adequacy. Anderson-Darling's test was carried out to evaluate the assumption of normality, and Levene's test for heteroscedasticity was used to verify that the assumption of constant residual variance was justified. A level of  $p < 0.05$  was considered statistically significant.

#### Paper IV

Laser Doppler velocimetry measurements were performed on six pigs. The output was continuously recorded using PeriSoft software. Microvascular blood flow was expressed in terms of PU. Calculations and statistical analysis were performed using GraphPad 4.0 software. Statistical analysis was performed using Student's paired t-test. Significance was defined as  $^*p < 0.05$ ,  $^{**}p < 0.01$  and  $^{***}p < 0.001$ . Values are presented as means  $\pm$  SEM.

#### Paper V

Laser Doppler velocimetry measurements were performed on six pigs. The output was continuously recorded using PeriSoft software. The microvascular blood flow was expressed in terms of PU. Calculations

---

and statistical analysis were performed using GraphPad 4.0 software (GraphPad Software Inc, San Diego, CA, USA). Significance was defined as  $*p < 0.05$  and  $p > 0.05$  (not significant using repeated measures ANOVA with Dunnet's post hoc test. Paired Student's t-test was used to compare microvascular blood flow changes between the first and 18th minute of TNP in the two kinds of pressure application. Paired Student's t-test was also used to compare the two kinds of pressure application, continuous and intermittent TNP. Values are presented as means  $\pm$  SEM.

---

## Chapter 4

### Results

#### 4.1 Paper I

##### *Normal myocardium – Coronary flow meters*

A topical negative pressure of -50 mmHg induced an immediate, significant increase in total coronary blood flow in normal myocardium (from  $171.3 \pm 14.5$  ml/min, to  $206.3 \pm 17.6$  ml/min after TNP application,  $p < 0.05$ ) (Figure 4.1). Regarding the three coronary arteries, the application of -50 mmHg induced an immediate increases in local coronary blood flow in the CCX (from  $49.2 \pm 6.1$  ml/min to  $53.7 \pm 5.0$  ml/min,  $p > 0.05$ ), the LAD (from  $60.5 \pm 11.1$  ml/min to  $77.8 \pm 12.2$  ml/min,  $p < 0.05$ ), and the RCA (from  $61.7 \pm 11.6$  ml/min to  $74.8 \pm 13.1$  ml/min,  $p < 0.05$ ). The results for each animal are shown in Figure 4.2A.

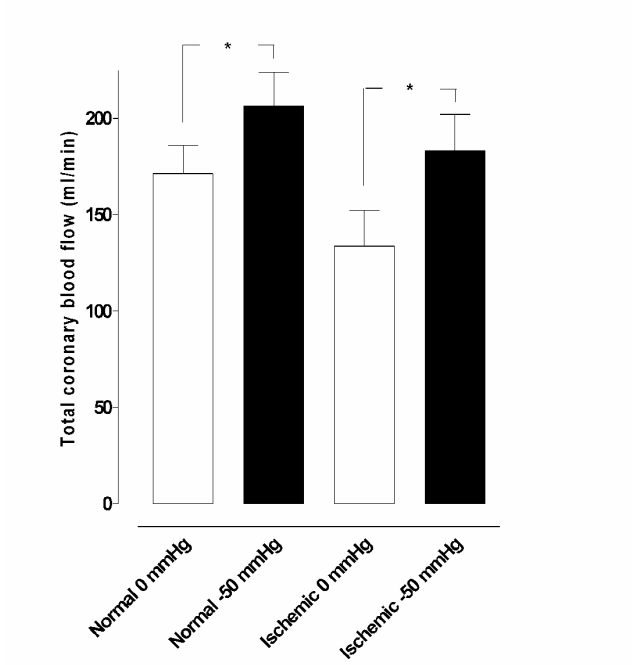


Figure 4.1. The changes in total blood flow measured using coronary ultrasonic flow meter probes in normal and ischaemic myocardium before and during the application of -50 mmHg. The change in total coronary artery blood flow is shown as mean values  $\pm$  SEM (\* =  $p < 0.05$ ).



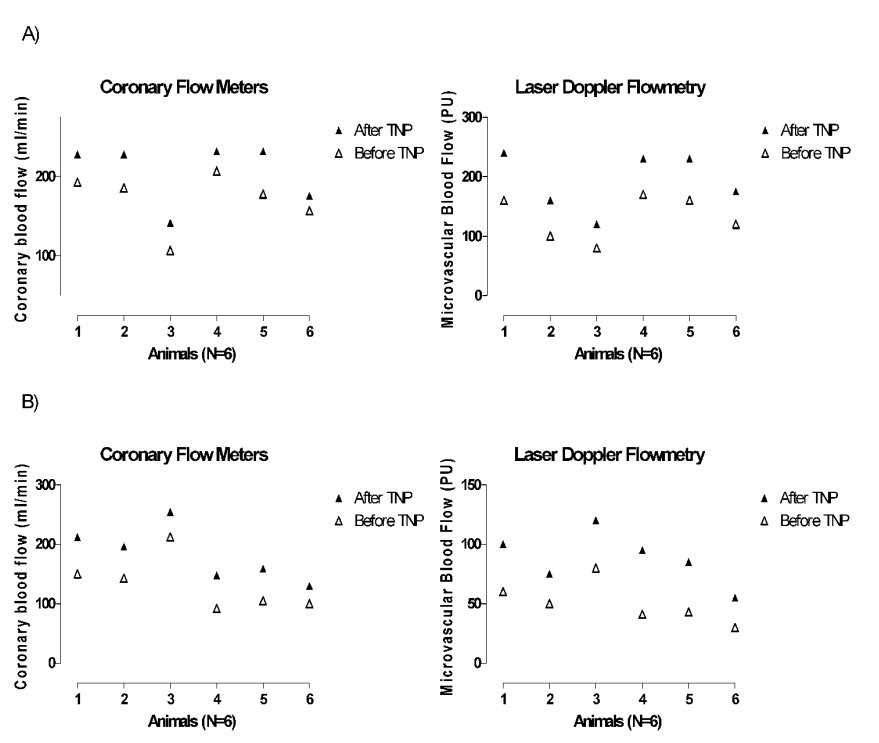


Figure 4.2. The total coronary blood flow measured using coronary ultrasonic flow meter probes, and microvascular blood flow using laser Doppler flowmetry in 6 pigs. (A) shows the values for each animal in normal myocardium before and after the application of a topical negative pressure of -50 mmHg, and (B) the corresponding values in ischaemic myocardium.

LAD occlusion – Coronary flow meters

Ischaemia was induced by occlusion of the LAD for 20 minutes. The coronary blood flow in the LAD decreased significantly (from  $74.3 \pm 9.8$  ml/min to  $13.3 \pm 2.0$  ml/min,  $p < 0.05$ ) after 20 minutes of LAD occlusion (Figure 4.3).

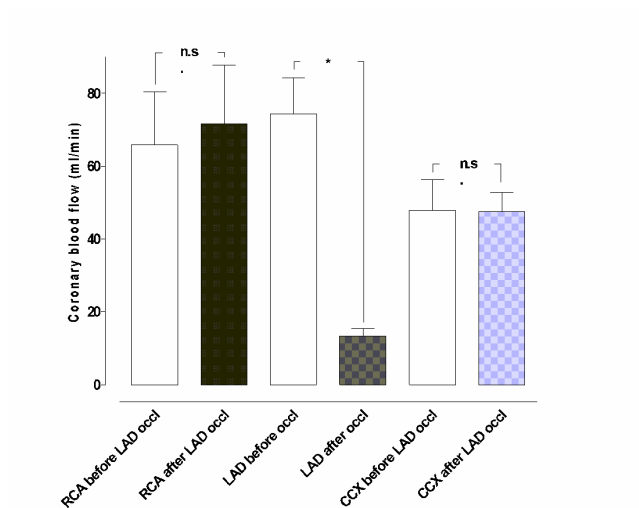


Figure 4.3. The blood flow measured using coronary ultrasonic flow meter probes before and after 20 min of left anterior descending artery (LAD) occlusion. The measurements were performed at the proximal part of the right coronary artery (RCA), left anterior descending artery (LAD) and circumflex coronary artery (CCX) in six pigs. Results are shown as mean values  $\pm$  SEM. \* =  $p < 0.05$ , n.s. = not significant.

### *Ischaemic myocardium – Coronary flow meters*

A topical negative pressure of -50 mmHg induced an immediate, significant increase in total coronary artery blood flow in ischaemic myocardium (from  $133.7 \pm 18.4$  ml/min, to  $183.2 \pm 18.9$  ml/min after TNP application,  $p < 0.05$ ) (Figure 4.1). The application of -50 mmHg induced an immediate increase in local coronary blood flow in the CCX (from  $52.2 \pm 4.2$  ml/min, to  $69.2 \pm 7.0$  ml/min after TNP application,  $p > 0.05$ ). The coronary blood flow in the LAD increased significantly (from  $15.0 \pm 2.4$  ml/min to  $21.0 \pm 7.9$  ml/min,  $p < 0.05$ ), and the coronary blood flow in RCA also increased significantly (from

---

66.2 ± 17.9 ml/min, to 93.0 ± 15.7 ml/min,  $p < 0.05$ ). The results for each animal are shown in Figure 4.2B.

*Normal myocardium – Laser Doppler flowmetry*

A topical negative pressure of -50 mmHg induced an immediate, significant increase in microvascular blood flow in the LAD region in normal myocardium, measured with laser Doppler velocimetry (from 131.7 ± 18.3 PU, to 192.5 ± 23.8 PU,  $p < 0.05$ ). A significant correlation was found between coronary blood flow and laser Doppler signals in normal myocardium ( $r^2 = 0.81$ ,  $p < 0.05$ ). The results for each animal are shown in Figure 4.2A.

*Ischaemic myocardium – Laser Doppler flowmetry*

A topical negative pressure of -50 mmHg also induced an immediate, significant increase in microvascular blood flow in the LAD region of the ischaemic myocardium (from 50.7 ± 7.1 PU, to 88.3 ± 9.1 PU,  $p < 0.05$ ). A significant correlation was found between coronary blood flow and laser Doppler signals in ischaemic myocardium ( $r^2 = 0.96$ ,  $p < 0.05$ ). The results for each animal are shown in Figure 4.2B.

4.2 Paper II

*Normal myocardium*

A topical negative pressure of -50 mmHg induced an immediate significant increase in microvascular blood flow in normal myocardium (from  $14.7 \pm 3.9$  PU, to  $25.8 \pm 6.1$  PU after TNP application,  $p < 0.05$ ) (Figure 4.4?). When the vacuum pump was switched off, the blood flow returned to baseline values ( $13.3 \pm 2.4$  PU).

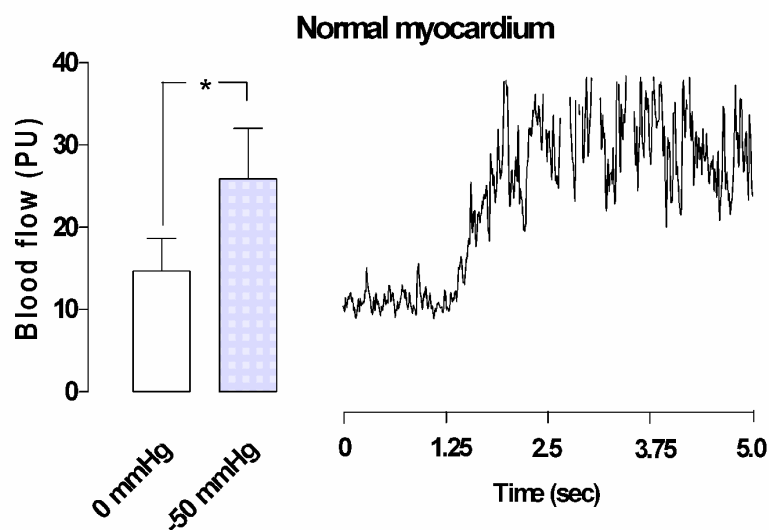


Figure 4.4. Microvascular blood flow measured using laser Doppler flowmetry in normal myocardium exposed to a topical negative pressure of -50 mmHg. The left panel shows the results as mean values  $\pm$  SEM ( $* = p < 0.05$ ). The right panel shows a representative example of changes in microvascular blood flow after the application of -50 mmHg topical negative pressure before LAD occlusion.

*Ischaemic myocardium*

Ischaemia was induced by occlusion of the LAD for 20 minutes. The myocardium distal to the occlusion turned blue, indicating that ischaemia had been established. The blood flow was  $12.8 \pm 2.6$  PU before occlusion of the LAD and decreased to  $7.2 \pm 1.5$  PU ( $p < 0.01$ ) after 20 minutes of LAD occlusion (Figure 4.5). Upon the application of a topical negative pressure of -50 mmHg, an immediate significant increase in blood flow was seen in the ischaemic myocardium (from  $7.2 \pm 1.5$  PU, to  $13.8 \pm 2.6$  PU,  $p < 0.05$ ) (Figure 4.6).

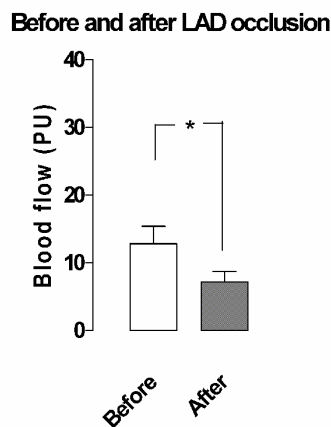


Figure 4.5. Microvascular blood flow in the myocardium measured using laser Doppler flowmetry before and after 20 minutes of LAD occlusion. Note the significant decrease (from  $12.8 \pm 2.6$  PU to  $7.2 \pm 1.5$  PU) in microvascular blood flow in the area after LAD occlusion. Mean values  $\pm$  SEM (\* =  $p < 0.05$ ).

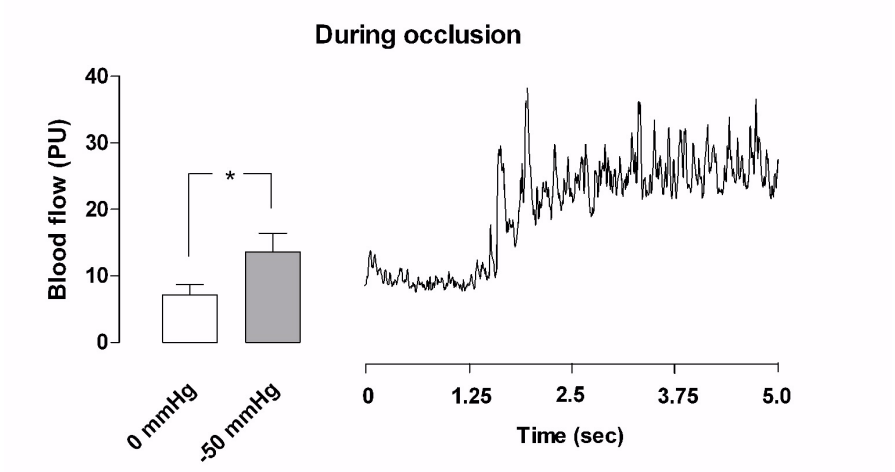


Figure 4.6. Microvascular blood flow in ischaemic myocardium measured using laser Doppler flowmetry. The left panel shows the results as mean values  $\pm$  SEM (\* =  $p < 0.05$ ). The right panel shows a representative example of the change in microvascular blood flow after the application of -50 mmHg topical negative pressure after 20 minutes of LAD occlusion (ischaemic myocardium). Note the immediate response in blood flow when the negative pressure is applied.

### *Reperfused myocardium*

After the LAD occlusion had been released the blue ischaemic myocardium turned red, indicating reperfusion. After 20 minutes of reperfusion, the application of -50 mmHg induced an immediate significant increase in blood flow (from  $10.8 \pm 2.0$  PU, to  $19.3 \pm 5.6$  PU after TNP application,  $p < 0.05$ ) (Figure 4.7).

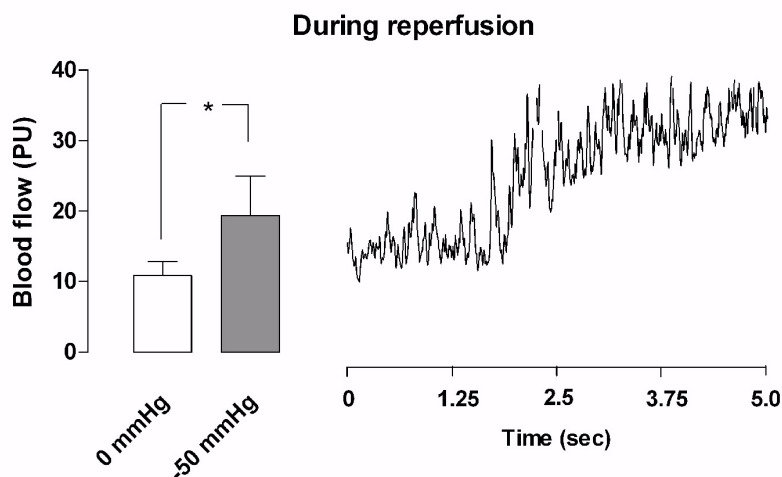


Figure 4.7. Microvascular blood flow in ischaemic myocardium during reperfusion measured using laser Doppler velocimetry. The left panel shows the results as mean values  $\pm$  SEM (\* =  $p < 0.05$ ). The right panel shows a representative example of changes in microvascular blood flow after the application of -50 mmHg topical negative pressure in reperfused myocardium.

### 4.3 Paper III

#### *Normal myocardium*

A topical negative pressure of -50 mmHg induced an immediate significant increase in microvascular blood flow in normal myocardium (from  $320.0 \pm 56.1$  PU, to  $435.7 \pm 65.5$  PU after TNP application,  $p < 0.05$ ). A topical negative pressure of -75 mmHg also resulted in an increase in microvascular blood flow (from  $320.0 \pm 56.1$  PU, to  $418.6 \pm 72.7$  PU,  $p > 0.05$ ). However, the increase was smaller than that induced at -50 mmHg. Topical negative pressures between -100 mmHg and -150 mmHg induced an immediate decrease in

microvascular blood flow in normal myocardium compared to that at -50 mmHg (Figure 4.8).

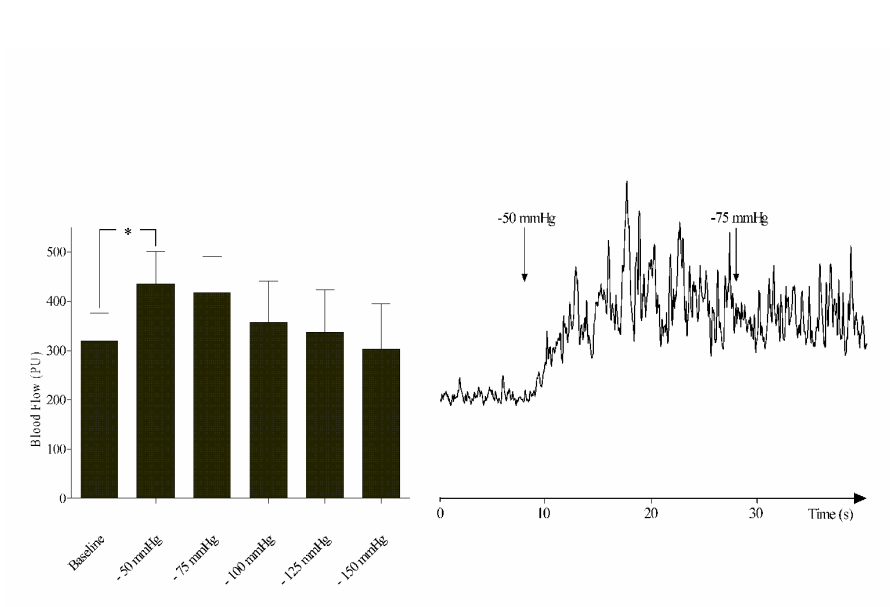


Figure 4.8. Microvascular blood flow in ischaemic myocardium exposed to topical negative pressures of -50, -75, -100, -125 and -150 mmHg, measured using laser Doppler velocimetry. The left panel shows the results as mean values  $\pm$  SEM (\* =  $p < 0.05$ ). The right panel shows a representative example of the change in microvascular blood flow after the application of -50 mmHg and -75 mmHg topical negative pressures to normal myocardium.

### *LAD occlusion*

Ischaemia was induced by occlusion of the LAD for 20 minutes. The blood flow was  $308.6 \pm 56.5$  PU before occlusion of the LAD and decreased to  $108.6 \pm 35.5$  PU after 20 minutes of LAD occlusion ( $p < 0.05$ ).



*Ischaemic myocardium*

Upon the application of a topical negative pressure of -50 mmHg, an immediate significant increased in microvascular blood flow was seen in the ischaemic myocardium (from  $110.0 \pm 36.7$  PU, to  $194.3 \pm 56.2$  PU,  $p < 0.05$ ). A topical negative pressure of -75 mmHg resulted in an increase in microvascular blood flow (from  $110.0 \pm 36.7$  PU, to  $138.6 \pm 38.9$  PU,  $p > 0.05$ ). Topical negative pressures between -100 mmHg and -150 mmHg induced an immediate decrease in microvascular blood flow in ischaemic myocardium compared to that at -50 mmHg (Figure 4.9).

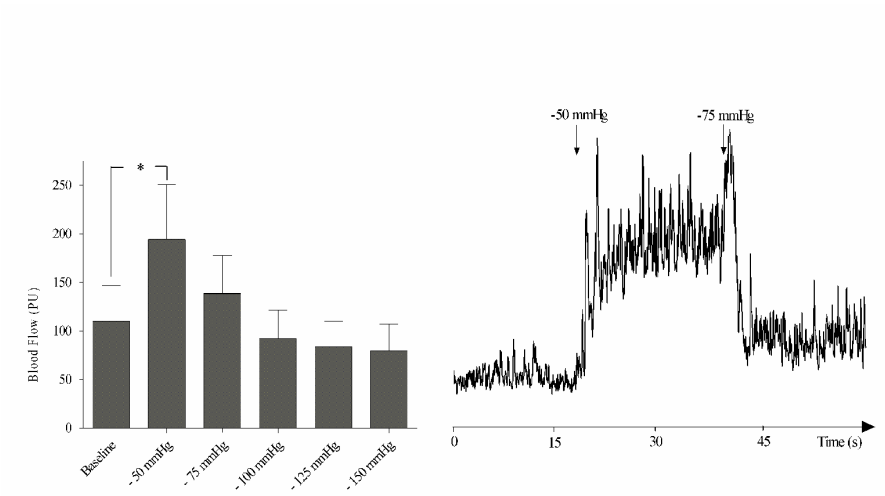


Figure 4.9. Microvascular blood flow in ischaemic myocardium exposed to topical negative pressures of -50, -75, -100, -125 and -150 mmHg, measured using laser Doppler flowmetry. The left panel shows the results as mean values  $\pm$  SEM (\* =  $p < 0.05$ ). The right panel shows a representative example of the change in microvascular blood flow after the application of -50 mmHg and -75 mmHg topical negative pressures ischaemic myocardium.

#### 4.4 Paper IV

##### *Normal myocardium*

A topical negative pressure of -50 mmHg induced an immediate significant increase in microvascular blood flow in normal myocardium (from  $365.8 \pm 111.7$  PU, to  $649.8 \pm 78.3$  PU,  $p < 0.01$ ) (Figure 4.10A). A TNP of -125 mmHg did not result in any significant change in microvascular blood flow ( $365.8 \pm 111.7$  PU before, and  $279.2 \pm 57.1$  PU after TNP application,  $p > 0.05$ ) (Figure 4.10B).

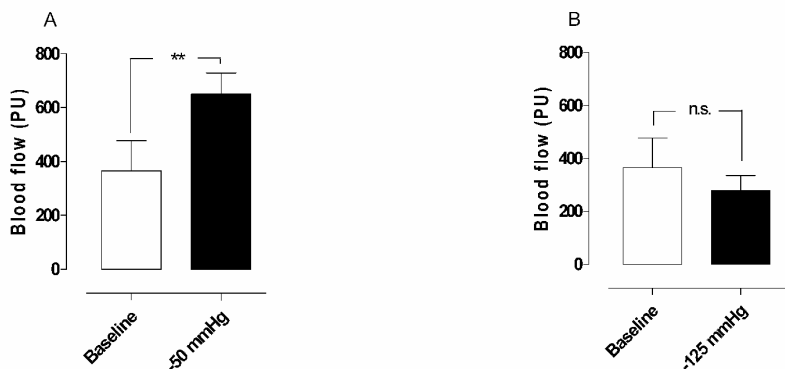


Figure 4.10. Microvascular blood flow in normal myocardium exposed to topical negative pressures of A) -50 mmHg and B) -125 mmHg, measured using laser Doppler flowmetry. Values are presented as means  $\pm$  SEM (\*\* =  $p < 0.01$ ).

##### *LAD occlusion*

Ischaemia was induced by occlusion of the LAD for 20 minutes. The blood flow was  $311.7 \pm 106.2$  PU before occlusion of the LAD, and decreased to  $90.0 \pm 37.3$  PU after 5 minutes ( $p < 0.05$ ), to  $95.0 \pm 32.2$  PU after 10 minutes ( $p < 0.05$ ), to  $95.8 \pm 36.9$  after 15 minutes ( $p <$

0.05), and to  $84.2 \pm 29.9$  after 20 minutes ( $p < 0.05$ ) of LAD occlusion (Figure 4.11).

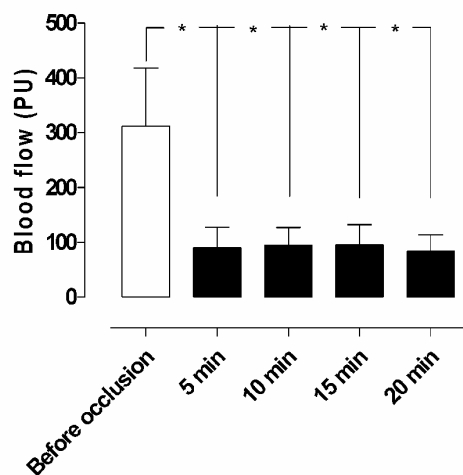


Figure 4.11. Microvascular blood flow in the myocardium before and after 5, 10, 15 and 20 minutes of occlusion of the left anterior descending artery, measured using laser Doppler flowmetry. Note the decrease in microvascular blood flow, from  $311.7 \pm 106.2$  PU before, to  $84.2 \pm 29.9$  PU after 20 minutes' occlusion of the LAD, in the area studied. Values are presented as means  $\pm$  SEM (\* =  $p < 0.05$ ).

*Ischaemic myocardium*

A topical negative pressure of -50 mmHg induced an immediate significant increase in microvascular blood flow in ischaemic myocardium (from  $69.0 \pm 5.5$  PU, to  $147.0 \pm 9.1$  PU after TNP application,  $p < 0.05$ ) (Figure 4.12A). A TNP of -125 mmHg did not

result in any significant change in microvascular blood flow ( $69.0 \pm 5.5$  PU before, and  $75.0 \pm 5.9$  PU after,  $p > 0.05$ ) (Figure 4.12B).

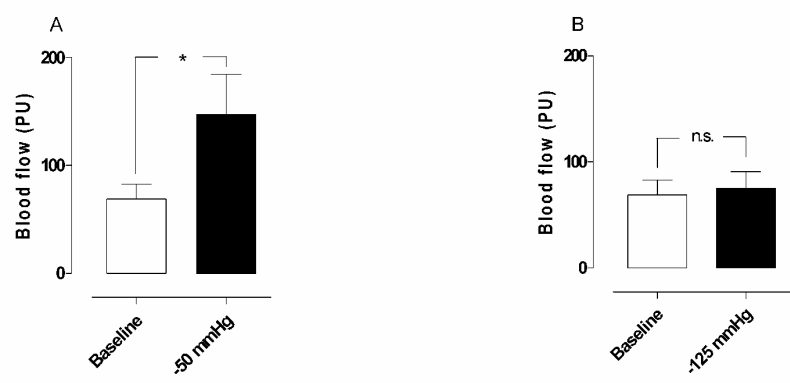


Figure 4.12. Microvascular blood flow (measured using laser Doppler flowmetry) in ischaemic myocardium exposed to topical negative pressures of A) -50 mmHg and B) -125 mmHg. Values are presented as means  $\pm$  SEM. (\* =  $p < 0.05$ , n.s. = not significant).

## 4.5 Paper V

### *Continuous TNP*

Application of a topical negative pressure of -50 mmHg for 20 minutes induced a significant increase in mean microvascular blood flow (from  $56.2 \pm 13.1$  PU, to  $132.8 \pm 7.4$  PU,  $p < 0.05$ ) (Figure 4.13A). The increase in microvascular blood flow did not change over the period of 18 min during which the continuous TNP was applied ( $151.8 \pm 44.6$  PU after 1 min and  $121.3 \pm 34.2$  PU after 18 min of TNP) ( $p > 0.05$ ).

*Intermittent TNP*

The application of an intermittent topical negative pressure (5 min on, 2 min off) of -50 mmHg for 20 minutes also induced a significant increase in mean microvascular blood flow (from  $75.8 \pm 12.1$  PU, to  $153.6 \pm 4.7$  PU during TNP application,  $p < 0.05$ ) (Figure 4.13B). The increase in microvascular blood flow did not change over the period of 18 min during which the intermittent TNP was applied ( $166.7 \pm 14.0$  PU after 1 min and  $177.5 \pm 20.1$  PU after 18 min of TNP) ( $p > 0.05$ ).

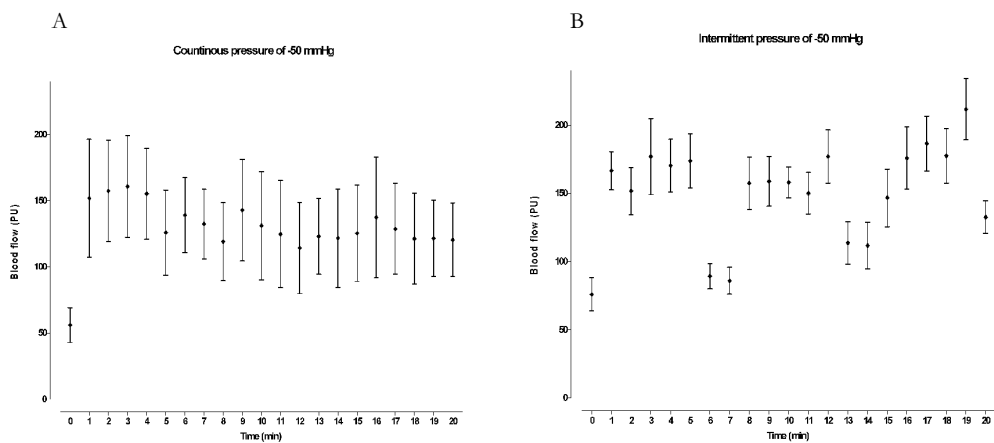


Figure 4.13. Microvascular blood flow (measured using laser Doppler flowmetry) in ischaemic myocardium continuously exposed to a topical negative pressure of -50 mmHg for 20 minutes (A), and intermittently exposed (5 minutes on, 2 minutes off) for 20 minutes (B). The error bars show 1 SEM.

---

*Intermittent TNP versus continuous TNP*

Blood flow was stimulated to similar degrees by continuous and intermittent TNP. The increase in microvascular blood flow during continuous TNP was  $(3473 \pm 1536) \%$  and the increase during intermittent TNP was  $(2579 \pm 778) \%$  (the mean of on and off periods) ( $p > 0.05$ ). The increase is expressed as the percent additive effect during the 20-min period studied.

---

## Chapter 5

### Discussion

Poststernotomy mediastinitis is a rare but potentially lethal complication following cardiac surgery(63, 92, 93). Topical negative pressure, applied to the wound by controlled suction through a porous dressing has recently become the therapy of choice for mediastinitis, due to the exceptionally good clinical outcome(58-61). However, the fundamental scientific mechanism of TNP is only partially understood. Two of the known effects of TNP are enhanced blood flow to the wound edge and granulation tissue formation(6, 21, 39). TNP increases the rate of blood flow and opens up the capillary beds. The mechanical forces and increased blood flow resulting from TNP affect the cytoskeleton in the vascular cells, stimulating endothelial proliferation, capillary budding and angiogenesis, i.e. granulation tissue formation(27, 29, 94, 95).

In patients with post-sternotomy mediastinitis treated with TNP the topical negative pressure is in direct contact with the heart, which is

---

exposed through the diastase of the sternotomy. Studies previously carried out by our group have shown that these patients develop richly vascularized granulation tissue on the exposed surface of the heart within 6-7 days. In the present studies, it was hypothesized that the application of TNP to the surface of the heart would stimulate neovascularization and microvascular blood flow in the myocardium, as seen in skeletal muscle following TNP(96-100). It is commonly known among cardiothoracic surgeons that mediastinitis is a strong predictor of poor long-term survival after CABG, when using conventional wound healing techniques such as closed irrigation, delayed wound closure, or reconstruction with omentum or pectoral flaps. It has been suggested that mediastinitis may cause negative, long-term effects on several organs, such as the heart and kidneys(54-56). Our research group has previously shown that there is no difference in long-term survival between CABG patients with TNP-treated mediastinitis and CABG patients without mediastinitis(60). This may indicate that these patients could have developed increased collateral coronary blood vessels during TNP, and may therefore be better prepared when bypass grafts fail to work. It may be that the stimulation of blood flow and development of collateral blood vessels by TNP in part account for the reduced long-term mortality in patients treated with TNP for poststernotomy mediastinitis after CABG.

In Paper I, a TNP of -50 mmHg was applied over the LAD region of six porcine hearts. Measurements of blood flow were made before and



---

after the application of TNP. The paper was conducted during low-intensity ventricular fibrillation with support by cardiopulmonary bypass. Coronary blood flow was measured with ultrasonic flow meter probes at the proximal part of the LAD, CCX and RCA.

Microvascular blood flow was measured by laser Doppler filament probes located 5-6 mm lateral of the middle part of the LAD, 5-6 mm down into the myocardial wall. A significant correlation was found between coronary blood flow and laser Doppler signals in normal myocardium ( $r^2 = 0.81, p < 0.05$ ), and in ischaemic myocardium ( $r^2 = 0.96, p < 0.05$ ). In Paper I, it was also shown that the application of a topical negative pressure of -50 mmHg directly to the myocardium resulted in an increase in the total coronary blood flow, not only in normal, but also in ischaemic, myocardium. A non-uniform pressure or a decrease in the total coronary blood flow might cause ischaemia in parts of the myocardium not exposed to TNP. Since the present paper shows a significant increase in the total amount of coronary blood flow, ischaemic areas are not likely to occur.

In Paper II microvascular blood flow was measured by laser Doppler filament probes located 5-6 mm lateral of the middle part of the LAD, 5-6 mm down into the myocardial wall. A TNP of -50 mmHg was applied over the LAD region of six pigs, and a significant increase was seen in microvascular blood flow in normal myocardium (non-ischaemic myocardium), in ischaemic myocardium after 20 minutes of LAD occlusion, and in reperfused myocardium (formerly ischaemic myocardium after 20 minutes of reperfusion). The increase in

---

microvascular blood flow appeared immediately when the negative pressure of -50 mmHg was applied. Measurements were made after steady state, which was approximately 10-30 seconds of TNP application. The negative pressure was then removed in all the experiments removed.

Applying different negative pressures to skeletal muscle causes different changes in blood flow(101). When the negative pressure exceeds a specific level it seems to constrict the vessels in the skeletal muscle and a decrease in local blood flow is seen(96, 101). In the treatment of post-sternotomy mediastinitis with TNP, pressures between -75 mmHg and -125 mmHg have been shown to provide optimal conditions for healing. In Paper III it was shown that a topical negative pressure of -50 mmHg significantly increases microvascular blood flow in both normal and ischaemic myocardium. When a negative pressure of -75 mmHg was applied to normal and ischaemic myocardium, the microvascular blood flow increased compared to baseline, however, this increase was not significant. Negative pressures between 100 mmHg and 150 mmHg led to a decrease in microvascular blood flow, compared to baseline, in both normal and ischaemic myocardium. This may indicate that these pressures constrict the vessels, thus reducing the microvascular blood flow to the exposed myocardium.

---

Our group has previously reported that the microvascular blood flow to a wound (subcutaneous and skeletal muscular tissue) increased to four times the baseline value when a negative pressure of 125 mm Hg was applied, whereas it was inhibited at negative pressures of 400 mm Hg and above (96). It has previously also been shown that the change in blood flow is related to local effects, since the blood flow at a distance of 4.5 cm from the wound edge was not affected by the negative pressure (96). A zone of relative hypoperfusion has been seen close to the wound edge. Hypoperfusion induced by TNP is thought to depend on tissue density, distance from the negative pressure source, and the amount negative pressure applied (96). In Paper IV it was shown that a TNP of -50 mmHg applied over the LAD region significantly increased the microvascular blood flow at a depth of 1-2 mm in the myocardium in normal myocardium, while a TNP of -125 mmHg did not significantly change the microvascular blood flow at that depth. This indicates that no hypoperfusion is produced in normal myocardium during TNP. In ischaemic myocardium, the application of a TNP of -50 mmHg over the LAD region resulted in a significant increase in microvascular blood flow at a depth of 1-2 mm in the myocardium. However, a pressure of -125 mmHg did not induce any significant change in microvascular blood flow in the ischaemic myocardium at the same depth. Consequently, no hypoperfusion could be observed during myocardial TNP in either normal or ischaemic myocardium. The absence of hypoperfusion could possibly be explained by the higher density of myocardium than skeletal muscle and subcutaneous tissue. It could be explained by the

---

release of vasodilators close to the negative pressure source. It might also be explained by redistribution of the microvascular blood flow to the epicardium due to microvascular mechanisms. Another possible explanation is that the negative force is greater closer to the vacuum source and subsequently decreases with distance. Moreover, a similar blood flow pattern, without any hypoperfusion in the epicardium, has also been observed during hypothermia in reperfused myocardium (75). However, the present results did not confirm these hypotheses.

The physiological, cellular and molecular mechanisms by which TNP accelerates wound healing are still not known in detail. However, the known effects of TNP are enhanced blood flow to the wound edges and granulation tissue formation (6, 21). TNP increases blood flow and opens up the capillary beds. The mechanical force exerted by TNP and increased blood flow affect the cytoskeleton in the vascular cells, stimulating endothelial proliferation, capillary budding and angiogenesis, i.e. granulation tissue formation (39, 94, 95).

Intermittent application of sub-atmospheric pressure (5 minutes of pressure, followed by 2 minutes without) seems to alter the cytoskeleton of the cells in the wound bed, triggering a cascade of intracellular signals that increases the rate of cell division and subsequent formation of granulation tissue, and thus angiogenesis (6).

Morykwas and co-workers compared continuous and intermittent pressure (5 minutes on and 2 minutes off) in subcutaneous and muscular tissue, and found that continuous application of TNP of -

---

125 mmHg resulted in an average increase in new granulation tissue formation of approximately 60%, while intermittent application of TNP at the same pressure resulted in an average increase of approximately 100%, compared with a control, after 2 weeks of TNP (6). They also found that microvascular blood flow increased to four times the baseline value when a TNP of -125 mm Hg was applied, whereas it was reduced at negative pressures of 400 mm Hg and greater. During continuous TNP they observed a decrease in perfusion after 5-7 minutes. After an initial increase in perfusion, the microvascular blood flow decreased permanently to the baseline value or below. However, the tissue type and distance from the wound edge were not considered in the above-mentioned paper. In Paper V, it was found that both continuous myocardial TNP and intermittent TNP of -50 mmHg for 20 minutes resulted in a significant increase in myocardial microvascular blood flow. During intermittent TNP the mean microvascular blood flow had a tendency to increase during the experiment; however, this increase was not significant. During the 2 minutes without pressure the microvascular blood flow returned almost to the baseline value in the first cycle, but seemed to return to ever-increasing pressure levels above baseline as the experiment proceeded. However, this increase was not significant. When comparing continuous and intermittent myocardial TNP, no significant difference in microvascular blood flow was observed. The increase in microvascular blood flow is greater during the first 5 minutes of TNP application in both settings. These results are not fully understood, but might be explained by a massive opening of the

---

capillary beds during the first few minutes of the application of TNP. However, the increase in microvascular blood flow during the first five minutes showed no statistically significant difference from the increase in microvascular blood flow during the last five minutes, and these findings should therefore be interpreted with caution.

Laser Doppler measurements of the perfusion of the myocardium are complex. In 1988, Ahn et al. assessed the myocardial perfusion in six empty beating porcine hearts with laser Doppler flowmetry (85?). They found significant linear correlations between changes in laser Doppler signal and changes in coronary sinus blood flow, and between laser Doppler signals and changes in extracorporeal bypass flow rate. The correlation between coronary sinus flow and bypass flow was significant in the four pigs studied. They also concluded that the muscular activity of the heart contributed to the laser Doppler signal (85). Ahn et al. also applied Laser Doppler flowmetry to the arrested heart and to the fibrillating heart during cardiopulmonary bypass, and found a significant correlation between laser Doppler signal and coronary blood flow during cardiac arrest. During ventricular fibrillation (after release of the aortic cross-clamp) they found a significant correlation between the laser Doppler signal and extracorporeal blood flow. A residual laser Doppler signal of about 60% of the maximal value was recorded after the bypass flow had been discontinued (86). However, it is unclear if venous blood returning to the heart from the superior and inferior vena cava, and the associated cava (specific to pigs), was occluded when the bypass

---

flow was discontinued, or if the measurements were adjusted to the systemic pressure. If the measurements were not adjusted, the returning venous blood will probably raise the intraventricular pressure and the tension of the myocardial ventricular wall, which might influence the measurements(87). It has been shown, in a porcine model, that ventricular fibrillation causes venous congestion, an empty left heart, and a greatly distended right heart within 3 minutes, and that the blood pressure is 50 mmHg after 20 seconds and 20-30 mmHg after 1½-2 minutes, which might also have influenced the measurements (87). In our opinion, it is crucial that the CPB flow be kept at a constant level, as well as the blood pressure, as changes in these parameters may change the model.

The majority of patients who require intervention for coronary artery disease are adequately treated by PCI or CABG. However, a major reason for failure of these treatments is their dependency on luminal size and coronary outflow. Methods of stimulating myocardial neovascularization that are not dependent on vessel calibre therefore provide an important alternative treatment. A large group of patients suffer from refractory angina pectoris. Conventional treatment such as PCI and CABG has not been successful in these patients. Various other therapies have been tried, such as percutaneous myocardial laser revascularization (102), and enhanced external counter-pulsation (103), with varying success. Even spinal cord stimulation has been used in an attempt to ease their ischaemic pain (104). However, a satisfactory means of treating these patients has yet to be found. A

---

new form of treatment resulting in new collateral vessel formation would thus be of interest for these patients.

Numerous studies have evaluated the efficacy of gene therapy in the treatment of ischaemic heart disease for the restoration of myocardial function by stimulation of angiogenesis and collateral vessel formation (105-109). VEGF has been found to be one of the most interesting growth factors in therapeutic angiogenesis (107, 110-114).

Interestingly, the mechanical forces exerted by TNP stimulate the endogenous production of VEGF (38, 53).

In patients with acute coronary syndrome and coronary vessel occlusion, it is of great importance to improve or, if possible, restore the blood flow to the ischaemic myocardium to protect it from ischaemic stress and, in some cases, acute coronary infarction. Most patients are successfully treated with conventional methods such as PCI or CABG. However, these procedures do not result in satisfactory results in all patients due to extensive coronary disease or small vessel calibre(115). Furthermore, the procedure is not suitable for some patients due to their high age, renal failure, or other complicating factors. In some cases of acute ST elevation myocardial infarction there is no reflow during PCI. No-reflow situations may also arise during saphenous vein graft intervention, and rotational atherectomy. During no-reflow, epicardial flow is reduced due to obstructions at the microvasculature level(116). This no-reflow condition is usually transient, but patients with refractory no-reflow



---

are associated with a markedly increased risk of 30-day mortality, compared with patients in whom no-reflow is transient(117). In the present paper it was found that a TNP of -50 mmHg significantly increased the microvascular blood flow in both the epicardium and the myocardium. Interestingly, TNP increases both the velocity and volume of blood flow by opening up the capillary beds(6). Furthermore, the method is not dependent on vessel calibre.

---

---

## Chapter 6

### Conclusions

A topical negative pressure of -50 mmHg applied over the LAD region induced a significant increase, not only in local microvascular blood flow, but also in total coronary blood flow, in normal and ischaemic myocardium. A significant correlation was found between coronary blood flow changes during TNP and laser Doppler signal.

When a TNP of -50 mmHg was applied over the LAD region a significant increase was observed in the microvascular blood flow in normal, ischaemic and reperfused myocardium.

In the range between -50 mmHg and -150 mmHg, a TNP of -50 mmHg seems to be the most effective negative pressure in increasing the microvascular blood flow in both normal and ischaemic myocardium.

---

No zone of hypoperfusion was observed in the epicardium, in either normal or ischaemic myocardium, when applying a myocardial TNP of -50 mmHg and -125 mmHg.

Both 20 minutes of continuous and intermittent TNP at -50 mmHg resulted in a significant increase in microvascular blood flow. However, no significant difference was found between continuous and intermittent TNP at -50 mmHg.

In conclusion, the application of topical negative pressure to the myocardium may, in the future, constitute an alternative therapeutic intervention to stimulate blood flow in the failing myocardium in patients with ischaemic heart disease.

---

## Limitations of the Present Work

Coronary pulmonary bypass and low-intensity ventricular fibrillation were used to minimize movement artefacts from muscular activity while measuring blood flow in the myocardium using laser Doppler techniques. A part of the laser Doppler signal is probably caused by muscular activity, as suggested by Ahn et al(85, 86). However, believe that the majority of the laser Doppler signal represents microvascular blood flow, and that the majority of the changes in the laser Doppler signal before and after the application of TNP represent changes in microvascular blood flow. The effect of TNP on the beating heart can not be deduced from the present results, although the effect would probably be similar to that observed here.

---

---

## Acknowledgements

I wish to express my sincere appreciation and gratitude to all the people who have contributed to this work.

In particular I would like to thank:

My supervisor, who has also become a very dear friend, Associated Professor Richard Ingemansson. I am grateful for his endless support and encouragement, and I have never met anyone with such devotion to science. I admire your determination to reach every goal you set, and your belief in your theories, even when others consider them totally unrealistic. I am truly grateful to you for sharing your profound experience in research including the tips, tricks and pitfalls of the academic world, and also for teaching me the subtle art of cardiac surgery.

I am also truly grateful to my co-supervisor and good friend Associated Professor Malin Malmsjö, for her excellent scientific guidance, and for sharing her profound knowledge of the secrets of statistics with me. Her innovative attitude created a wonderful

---

atmosphere during the experiments, and her enthusiastic personality was a source of inspiration beyond the work described in this thesis.

Thanks also to my co-authors:

Johan Sjögren, MD, PhD, for being a good friend and a supportive mentor during my work. I am grateful for our valuable discussions and his guidance in science and life and, not least, his sense of humour.

Ronny Gustafsson, MD, PhD, for being a good friend and a supportive and stimulating colleague.

Bodil Gesslein, for her invaluable help with the experiments.

I would also like to thank:

Professor Stig Steen, Director of the Cardiothoracic Surgical Research Centre in Lund, for providing an excellent scientific environment and for sharing his vast knowledge in cardiopulmonary research. His comments and visionary ideas made an everlasting expression on me.

Thanks are also due to my mentor Carsten Lühns, MD, for tutoring me in cardiac surgery, and for always taking the time to answer my questions.



---

Thanks are also due to Pelle Johnsson, M.D, Ph.D, and Atli Eyjolfsson Per-Ola Kimblad, M.D, Ph.D, for their kind support.

My colleague Arash Mokthari, MD, PhD, for being a good friend, and for sharing his computer skills with me.

My former supervisor Associated Professor Magnus Grabe, for generously sharing his experience and knowledge, and for teaching me how to write scientific papers.

Helen Sheppard, at Word for Word in Lund, for correcting my English; for her helpful attitude, and for always returning my manuscripts on time (or even earlier).

Johan Ingemansson at Statistical Solutions, for his help and stimulating discussions regarding the experimental design.

My colleagues at the Department of Cardiothoracic Surgery, Lund University Hospital, for their support and encouragement.

My parents, Anita and Gösta, for all their love and endless support. Never once have you doubted me. I am grateful that you always encouraged me, and never tried to stop me from doing what I really wanted, even if my journey through life sometimes seemed like an adventure.

---

My sister Sabina, and my brother Pierre, for all their support during the years.

My very good friend and colleague Joanna Hlebowicz MD (soon to obtain her PhD), for all her support and encouragement and fruitful discussions during the course of my work; and not least for her wonderful taste in fashion, and for sharing my obsession with shoes.

My very good friend Helena de Maré, for being a truly good friend. I am grateful for all your support during the years and for taking such good care of my three little cats.

Last, but not least, my three little felines, Neo, Calippo, and Tiger, for keeping my nursing skills up to scratch, and for ensuring I got publicity in the local papers – all publicity is good publicity.

The work described in this thesis was supported by the Anders Otto Swärd/Ulrika Eklund Foundation, Anna Lisa and Sven Eric Lundgren's Foundation for Medical Research, the Åke Wiberg Foundation, the M. Bergvall Foundation, the Swedish Medical Association, the Royal Physiographic Society in Lund, the Swedish Medical Research Council, the Crafoord Foundation, the Swedish Government Grant for Clinical Research, and the Swedish Hypertension Society.

---

## References

1. Fleischmann W, Strecker W, Bombelli M, Kinzl L. [Vacuum sealing as treatment of soft tissue damage in open fractures]. *Unfallchirurg*. 1993;96:488-492.
2. Fleischmann W, Lang E, Kinzl L. [Vacuum assisted wound closure after dermatofasciotomy of the lower extremity]. *Unfallchirurg*. 1996;99:283-287.
3. Fleischmann W, Lang E, Russ M. [Treatment of infection by vacuum sealing]. *Unfallchirurg*. 1997;100:301-304.
4. Muller G. [Vacuum dressing in septic wound treatment]. *Langenbecks Arch Chir Suppl Kongressbd*. 1997;114:537-541.
5. Banwell P, Withey S, Holten I. The use of negative pressure to promote healing. *Br J Plast Surg*. 1998;51:79.
6. Morykwas MJ, Argenta LC, Shelton-Brown EI, McGuirt W. Vacuum-assisted closure: a new method for wound control and treatment: animal studies and basic foundation. *Ann Plast Surg*. 1997;38:553-562.
7. Philbeck TE, Jr., Whittington KT, Millsap MH, Briones RB, Wight DG, Schroeder WJ. The clinical and cost effectiveness of externally applied negative pressure wound therapy in the

- 
- treatment of wounds in home healthcare Medicare patients. *Ostomy Wound Manage.* 1999;45:41-50.
8. Tang AT, Ohri SK, Haw MP. Novel application of vacuum assisted closure technique to the treatment of sternotomy wound infection. *Eur J Cardiothorac Surg.* 2000;17:482-484.
  9. Morykwas MJ, Argenta LC. Nonsurgical modalities to enhance healing and care of soft tissue wounds. *J South Orthop Assoc.* 1997;6:279-288.
  10. Fabian TS, Kaufman HJ, Lett ED, Thomas JB, Rawl DK, Lewis PL, Summitt JB, Merryman JI, Schaeffer TD, Sargent LA, Burns RP. The evaluation of subatmospheric pressure and hyperbaric oxygen in ischemic full-thickness wound healing. *Am Surg.* 2000;66:1136-1143.
  11. Morykwas MJ, Kennedy A, Argenta JP, Argenta LC. Use of subatmospheric pressure to prevent doxorubicin extravasation ulcers in a swine model. *J Surg Oncol.* 1999;72:14-17.
  12. Meara JG, Guo L, Smith JD, Pribaz JJ, Breuing KH, Orgill DP. Vacuum-assisted closure in the treatment of degloving injuries. *Ann Plast Surg.* 1999;42:589-594.
  13. DeFranzo AJ, Marks MW, Argenta LC, Genecov DG. Vacuum-assisted closure for the treatment of degloving injuries. *Plast Reconstr Surg.* 1999;104:2145-2148.
  14. Tang AT. Vacuum-assisted suction drainage of sternotomy infection: a new paradigm? *Eur J Cardiothorac Surg.* 2003;23:649-650; author reply 650.

- 
15. Bauer P, Schmidt G, Partecke BD. [Possibilities of preliminary treatment of infected soft tissue defects by vacuum sealing and PVA foam]. *Handchir Mikrochir Plast Chir.* 1998;30:20-23.
  16. Banwell PE. Topical negative pressure therapy in wound care. *J Wound Care.* 1999;8:79-84.
  17. Armstrong DG, Lavery LA. Negative pressure wound therapy after partial diabetic foot amputation: a multicentre, randomised controlled trial. *Lancet.* 2005;366:1704-1710.
  18. Banwell PE. Topical negative pressure wound therapy: advances in burn wound management. *Ostomy Wound Manage.* 2004;50:9S-14S.
  19. Banwell PE, Teot L. Topical negative pressure (TNP): the evolution of a novel wound therapy. *J Wound Care.* 2003;12:22-28.
  20. Webb LX. New techniques in wound management: vacuum-assisted wound closure. *J Am Acad Orthop Surg.* 2002;10:303-311.
  21. Argenta LC, Morykwas MJ. Vacuum-assisted closure: a new method for wound control and treatment: clinical experience. *Ann Plast Surg.* 1997;38:563-576; discussion 577.
  22. Armstrong DG, Lavery LA, Abu-Rumman P, Espensen EH, Vazquez JR, Nixon BP, Boulton AJ. Outcomes of subatmospheric pressure dressing therapy on wounds of the diabetic foot. *Ostomy Wound Manage.* 2002;48:64-68.
  23. Clare MP, Fitzgibbons TC, McMullen ST, Stice RC, Hayes DF, Henkel L. Experience with the vacuum assisted closure

- 
- negative pressure technique in the treatment of non-healing diabetic and dysvascular wounds. *Foot Ankle Int.* 2002;23:896-901.
24. Ilizarov GA. The tension-stress effect on the genesis and growth of tissues. Part I. The influence of stability of fixation and soft-tissue preservation. *Clin Orthop Relat Res.* 1989:249-281.
25. Ilizarov GA. The tension-stress effect on the genesis and growth of tissues: Part II. The influence of the rate and frequency of distraction. *Clin Orthop Relat Res.* 1989:263-285.
26. Huang S, Ingber DE. The structural and mechanical complexity of cell-growth control. *Nat Cell Biol.* 1999;1:E131-138.
27. Chen CS, Mrksich M, Huang S, Whitesides GM, Ingber DE. Micropatterned surfaces for control of cell shape, position, and function. *Biotechnol Prog.* 1998;14:356-363.
28. Huang S, Chen CS, Ingber DE. Control of cyclin D1, p27(Kip1), and cell cycle progression in human capillary endothelial cells by cell shape and cytoskeletal tension. *Mol Biol Cell.* 1998;9:3179-3193.
29. Korff T, Augustin HG. Tensional forces in fibrillar extracellular matrices control directional capillary sprouting. *J Cell Sci.* 1999;112 ( Pt 19):3249-3258.
30. Chen CS, Mrksich M, Huang S, Whitesides GM, Ingber DE. Geometric control of cell life and death. *Science.* 1997;276:1425-1428.
-

- 
31. Mochitate K, Pawelek P, Grinnell F. Stress relaxation of contracted collagen gels: disruption of actin filament bundles, release of cell surface fibronectin, and down-regulation of DNA and protein synthesis. *Exp Cell Res.* 1991;193:198-207.
  32. Silver FH, Siperko LM, Seehra GP. Mechanobiology of force transduction in dermal tissue. *Skin Res Technol.* 2003;9:3-23.
  33. Ingber DE. Mechanical signaling and the cellular response to extracellular matrix in angiogenesis and cardiovascular physiology. *Circ Res.* 2002;91:877-887.
  34. Silver FH, Siperko LM. Mechanosensing and mechanochemical transduction: how is mechanical energy sensed and converted into chemical energy in an extracellular matrix? *Crit Rev Biomed Eng.* 2003;31:255-331.
  35. Tardy Y, Resnick N, Nagel T, Gimbrone MA, Jr., Dewey CF, Jr. Shear stress gradients remodel endothelial monolayers in vitro via a cell proliferation-migration-loss cycle. *Arterioscler Thromb Vasc Biol.* 1997;17:3102-3106.
  36. Nagel T, Resnick N, Dewey CF, Jr., Gimbrone MA, Jr. Vascular endothelial cells respond to spatial gradients in fluid shear stress by enhanced activation of transcription factors. *Arterioscler Thromb Vasc Biol.* 1999;19:1825-1834.
  37. Gimbrone MA, Jr., Nagel T, Topper JN. Biomechanical activation: an emerging paradigm in endothelial adhesion biology. *J Clin Invest.* 1997;100:S61-65.
  38. Detmar M, Brown LF, Berse B, Jackman RW, Elicker BM, Dvorak HF, Claffey KP. Hypoxia regulates the expression of

- 
- vascular permeability factor/vascular endothelial growth factor (VPF/VEGF) and its receptors in human skin. *J Invest Dermatol.* 1997;108:263-268.
39. Saxena V, Hwang CW, Huang S, Eichbaum Q, Ingber D, Orgill DP. Vacuum-assisted closure: microdeformations of wounds and cell proliferation. *Plast Reconstr Surg.* 2004;114:1086-1096; discussion 1097-1088.
40. Yan L, Moses MA, Huang S, Ingber DE. Adhesion-dependent control of matrix metalloproteinase-2 activation in human capillary endothelial cells. *J Cell Sci.* 2000;113 ( Pt 22):3979-3987.
41. Pozzi A, LeVine WF, Gardner HA. Low plasma levels of matrix metalloproteinase 9 permit increased tumor angiogenesis. *Oncogene.* 2002;21:272-281.
42. Pozzi A, Moberg PE, Miles LA, Wagner S, Soloway P, Gardner HA. Elevated matrix metalloprotease and angiostatin levels in integrin alpha 1 knockout mice cause reduced tumor vascularization. *Proc Natl Acad Sci U S A.* 2000;97:2202-2207.
43. Cornelius LA, Nehring LC, Harding E, Bolanowski M, Welgus HG, Kobayashi DK, Pierce RA, Shapiro SD. Matrix metalloproteinases generate angiostatin: effects on neovascularization. *J Immunol.* 1998;161:6845-6852.
44. Tarlton JF, Vickery CJ, Leaper DJ, Bailey AJ. Postsurgical wound progression monitored by temporal changes in the expression of matrix metalloproteinase-9. *Br J Dermatol.* 1997;137:506-516.
-



- 
45. Ladwig GP, Robson MC, Liu R, Kuhn MA, Muir DF, Schultz GS. Ratios of activated matrix metalloproteinase-9 to tissue inhibitor of matrix metalloproteinase-1 in wound fluids are inversely correlated with healing of pressure ulcers. *Wound Repair Regen.* 2002;10:26-37.
  46. Lerman OZ, Galiano RD, Armour M, Levine JP, Gurtner GC. Cellular dysfunction in the diabetic fibroblast: impairment in migration, vascular endothelial growth factor production, and response to hypoxia. *Am J Pathol.* 2003;162:303-312.
  47. Moses MA, Marikovsky M, Harper JW, Vogt P, Eriksson E, Klagsbrun M, Langer R. Temporal study of the activity of matrix metalloproteinases and their endogenous inhibitors during wound healing. *J Cell Biochem.* 1996;60:379-386.
  48. Greene AK, Puder M, Roy R, Kilroy S, Louis G, Folkman J, Moses MA. Urinary matrix metalloproteinases and their endogenous inhibitors predict hepatic regeneration after murine partial hepatectomy. *Transplantation.* 2004;78:1139-1144.
  49. Chen C, Schultz GS, Bloch M, Edwards PD, Tebes S, Mast BA. Molecular and mechanistic validation of delayed healing rat wounds as a model for human chronic wounds. *Wound Repair Regen.* 1999;7:486-494.
  50. Ulrich D, Lichtenegger F, Unglaub F, Smeets R, Pallua N. Effect of chronic wound exudates and MMP-2/-9 inhibitor on angiogenesis in vitro. *Plast Reconstr Surg.* 2005;116:539-545.
  51. O'Reilly MS, Wiederschain D, Stetler-Stevenson WG, Folkman J, Moses MA. Regulation of angiostatin production by matrix

- 
- metalloproteinase-2 in a model of concomitant resistance. *J Biol Chem.* 1999;274:29568-29571.
52. Venturi ML, Attinger CE, Mesbahi AN, Hess CL, Graw KS. Mechanisms and clinical applications of the vacuum-assisted closure (VAC) Device: a review. *Am J Clin Dermatol.* 2005;6:185-194.
53. Chen KD, Li YS, Kim M, Li S, Yuan S, Chien S, Shyy JY. Mechanotransduction in response to shear stress. Roles of receptor tyrosine kinases, integrins, and Shc. *J Biol Chem.* 1999;274:18393-18400.
54. De Feo M, Renzulli A, Ismeno G, Gregorio R, Della Corte A, Utili R, Cotrufo M. Variables predicting adverse outcome in patients with deep sternal wound infection. *Ann Thorac Surg.* 2001;71:324-331.
55. Braxton JH, Marrin CA, McGrath PD, Ross CS, Morton JR, Norotsky M, Charlesworth DC, Lahey SJ, Clough RA, O'Connor GT. Mediastinitis and long-term survival after coronary artery bypass graft surgery. *Ann Thorac Surg.* 2000;70:2004-2007.
56. Loop FD, Lytle BW, Cosgrove DM, Mahfood S, McHenry MC, Goormastic M, Stewart RW, Golding LA, Taylor PC. J. Maxwell Chamberlain memorial paper. Sternal wound complications after isolated coronary artery bypass grafting: early and late mortality, morbidity, and cost of care. *Ann Thorac Surg.* 1990;49:179-186; discussion 186-177.

- 
57. Gardlund B, Bitkover CY, Vaage J. Postoperative mediastinitis in cardiac surgery - microbiology and pathogenesis. *Eur J Cardiothorac Surg.* 2002;21:825-830.
  58. Gustafsson RI, Sjogren J, Ingemansson R. Deep sternal wound infection: a sternal-sparing technique with vacuum-assisted closure therapy. *Ann Thorac Surg.* 2003;76:2048-2053; discussion 2053.
  59. Sjogren J, Gustafsson R, Nilsson J, Malmso M, Ingemansson R. Clinical outcome after poststernotomy mediastinitis: vacuum-assisted closure versus conventional treatment. *Ann Thorac Surg.* 2005;79:2049-2055.
  60. Sjogren J, Nilsson J, Gustafsson R, Malmso M, Ingemansson R. The impact of vacuum-assisted closure on long-term survival after post-sternotomy mediastinitis. *Ann Thorac Surg.* 2005;80:1270-1275.
  61. Fleck TM, Fleck M, Moidl R, Czerny M, Koller R, Giovanoli P, Hiesmayer MJ, Zimpfer D, Wolner E, Grabenwoger M. The vacuum-assisted closure system for the treatment of deep sternal wound infections after cardiac surgery. *Ann Thorac Surg.* 2002;74:1596-1600; discussion 1600.
  62. Domkowski PW, Smith ML, Gonyon DL, Jr., Drye C, Wooten MK, Levin LS, Wolfe WG. Evaluation of vacuum-assisted closure in the treatment of poststernotomy mediastinitis. *J Thorac Cardiovasc Surg.* 2003;126:386-390.

- 
63. Milano CA, Kesler K, Archibald N, Sexton DJ, Jones RH. Mediastinitis after coronary artery bypass graft surgery. Risk factors and long-term survival. *Circulation*. 1995;92:2245-2251.
  64. Guyton A, Hall J. *Textbook of Medical Physiology*. 9th ed. Philadelphia: WB Saunders; 1996.
  65. Rolf N. Central neuroaxis blockade and coronary circulation. *Curr Opin Anaesthesiol*. 1998;11:517-520.
  66. Kaplan J, Reich D, Konstadt S. *Cardiac Anaesthesia*. 4th ed. Philadelphia: WB Saunders; 1999.
  67. Schmermund A, Lerman LO, Ritman EL, Rumberger JA. Cardiac production of angiotensin II and its pharmacologic inhibition: effects on the coronary circulation. *Mayo Clin Proc*. 1999;74:503-513.
  68. Biccard BM. Peri-operative beta-blockade and haemodynamic optimisation in patients with coronary artery disease and decreasing exercise capacity presenting for major noncardiac surgery. *Anaesthesia*. 2004;59:60-68.
  69. Nader-Djalal N, Knight PR. Volatile anesthetic effects on ischemic myocardium. *Curr Opin Anaesthesiol*. 1998;11:403-406.
  70. Baird RJ, Manktelow RT, Shah PA, Ameli FM. Intramyocardial pressure. A study of its regional variations and its relationship to intraventricular pressure. *J Thorac Cardiovasc Surg*. 1970;59:810-823.
  71. Brazier JR, Cooper N, McConnell DH, Buckberg GD. Studies of the effects of hypothermia on regional myocardial blood

- 
- flow and metabolism during cardiopulmonary bypass. III. Effects of temperature, time, and perfusion pressure in fibrillating hearts. *J Thorac Cardiovasc Surg.* 1977;73:102-109.
72. Sink JD, Hill RC, Attarian DE, Wechsler AS. Myocardial blood flow and oxygen consumption in the empty-beating, fibrillating, and potassium-arrested hypertrophied canine heart. *Ann Thorac Surg.* 1983;35:372-379.
73. Hottenrott C, Buckberg GD, Maloney JV, Jr. Effects of ventricular fibrillation on distribution and adequacy of coronary blood flow. *Surg Forum.* 1972;23:200-202.
74. Buckberg GD, Brazier JR, Nelson RL, Goldstein SM, McConnell DH, Cooper N. Studies of the effects of hypothermia on regional myocardial blood flow and metabolism during cardiopulmonary bypass. I. The adequately perfused beating, fibrillating, and arrested heart. *J Thorac Cardiovasc Surg.* 1977;73:87-94.
75. Lindstedt S, Malmjö M, Ingemansson R. The effect of different topical negative pressures on microvascular blood flow in reperfused myocardium during hypothermia. *Innovations.* 2007;2:231-236.
76. Buckberg GD, Hottenrott CE. Ventricular fibrillation. Its effect on myocardial flow, distribution, and performance. *Ann Thorac Surg.* 1975;20:76-85.
77. Oberg PA. Laser-Doppler flowmetry. *Crit Rev Biomed Eng.* 1990;18:125-163.
-

- 
78. Stern MD. In vivo evaluation of microcirculation by coherent light scattering. *Nature*. 1975;254:56-58.
  79. Boggett D, Blond J, Rolfe P. Laser Doppler measurements of blood flow in skin tissue. *J Biomed Eng*. 1985;7:225-232.
  80. Nilsson GE. Signal processor for laser Doppler tissue flowmeters. *Med Biol Eng Comput*. 1984;22:343-348.
  81. Vongsavan N, Matthews B. Some aspects of the use of laser Doppler flow meters for recording tissue blood flow. *Exp Physiol*. 1993;78:1-14.
  82. Sidi A, Rush W. An alternative to radioactive microspheres for measuring regional myocardial blood flow, Part 1: Colored microspheres. *J Cardiothorac Vasc Anesth*. 1996;10:368-373.
  83. Sidi A, Rush W. An alternative to radioactive microsphere for measuring regional myocardial blood flow, Part 2: Laser-Doppler perfusion monitor. *J Cardiothorac Vasc Anesth*. 1996;10:374-377.
  84. Kowallik P, Schulz R, Guth BD, Schade A, Paffhausen W, Gross R, Heusch G. Measurement of regional myocardial blood flow with multiple colored microspheres. *Circulation*. 1991;83:974-982.
  85. von Ahn HC, Ekroth R, Nilsson GE, Svedjeholm R. Assessment of myocardial perfusion with laser Doppler flowmetry. An experimental study on porcine heart. *Scand J Thorac Cardiovasc Surg*. 1988;22:145-148.
  86. Ahn HC, Ekroth R, Hedenmark J, Nilsson GE, Svedjeholm R. Assessment of myocardial perfusion in the empty beating

- 
- porcine heart with laser Doppler flowmetry. *Cardiovasc Res.* 1988;22:719-725.
87. Steen S, Liao Q, Pierre L, Paskevicius A, Sjoberg T. The critical importance of minimal delay between chest compressions and subsequent defibrillation: a haemodynamic explanation. *Resuscitation.* 2003;58:249-258.
88. Barclay KD, Klassen GA, Wong RW, Wong AY. A method for measuring systolic and diastolic microcirculatory red cell flux within the canine myocardium. *Ital Heart J.* 2001;2:740-750.
89. Li XF, Wang YP. Laser Doppler flowmetry for assessment of myocardial microperfusion in the beating rat heart. *Vascul Pharmacol.* 2007;46:207-214.
90. Laustsen J, Pedersen EM, Terp K, Steinbruchel D, Kure HH, Paulsen PK, Jorgensen H, Paaske WP. Validation of a new transit time ultrasound flowmeter in man. *Eur J Vasc Endovasc Surg.* 1996;12:91-96.
91. Zografos GC, Martis K, Morris DL. Laser Doppler flowmetry in evaluation of cutaneous wound blood flow using various suturing techniques. *Ann Surg.* 1992;215:266-268.
92. Braxton JH, Marrin CA, McGrath PD, Morton JR, Norotsky M, Charlesworth DC, Lahey SJ, Clough R, Ross CS, Olmstead EM, O'Connor GT. 10-year follow-up of patients with and without mediastinitis. *Semin Thorac Cardiovasc Surg.* 2004;16:70-76.
93. Lu JC, Grayson AD, Jha P, Srinivasan AK, Fabri BM. Risk factors for sternal wound infection and mid-term survival
-

- 
- following coronary artery bypass surgery. *Eur J Cardiothorac Surg.* 2003;23:943-949.
94. Greene AK, Puder M, Roy R, Arsenault D, Kwei S, Moses MA, Orgill DP. Microdeformational wound therapy: effects on angiogenesis and matrix metalloproteinases in chronic wounds of 3 debilitated patients. *Ann Plast Surg.* 2006;56:418-422.
95. Vandeburgh HH. Mechanical forces and their second messengers in stimulating cell growth in vitro. *Am J Physiol.* 1992;262:R350-355.
96. Wackenfors A, Gustafsson R, Sjogren J, Algotsson L, Ingemansson R, Malmsjo M. Blood flow responses in the peristernal thoracic wall during vacuum-assisted closure therapy. *Ann Thorac Surg.* 2005;79:1724-1730; discussion 1730-1721.
97. Petzina R, Gustafsson L, Mokhtari A, Ingemansson R, Malmsjo M. Effect of vacuum-assisted closure on blood flow in the peristernal thoracic wall after internal mammary artery harvesting. *Eur J Cardiothorac Surg.* 2006;30:85-89.
98. Chen SZ, Cao DY, Li JQ, Tang SY. [Effect of vacuum-assisted closure on the expression of proto-oncogenes and its significance during wound healing]. *Zhonghua Zheng Xing Wai Ke Za Zhi.* 2005;21:197-200.
99. Wackenfors A, Sjogren J, Algotsson L, Gustafsson R, Ingemansson R, Malmsjo M. The effect of vacuum-assisted closure therapy on the pig femoral artery vasomotor responses. *Wound Repair Regen.* 2004;12:244-251.
-



- 
100. Koller A, Kaley G. Endothelial regulation of wall shear stress and blood flow in skeletal muscle microcirculation. *Am J Physiol.* 1991;260:H862-868.
  101. Wackenfors A, Sjogren J, Gustafsson R, Algotsson L, Ingemansson R, Malmso M. Effects of vacuum-assisted closure therapy on inguinal wound edge microvascular blood flow. *Wound Repair Regen.* 2004;12:600-606.
  102. Leon MB, Kornowski R, Downey WE, Weisz G, Baim DS, Bonow RO, Hendel RC, Cohen DJ, Gervino E, Laham R, Lembo NJ, Moses JW, Kuntz RE. A blinded, randomized, placebo-controlled trial of percutaneous laser myocardial revascularization to improve angina symptoms in patients with severe coronary disease. *J Am Coll Cardiol.* 2005;46:1812-1819.
  103. Cohn PF. Enhanced external counterpulsation for the treatment of angina pectoris. *Prog Cardiovasc Dis.* 2006;49:88-97.
  104. Deer TR, Raso LJ. Spinal cord stimulation for refractory angina pectoris and peripheral vascular disease. *Pain Physician.* 2006;9:347-352.
  105. Takaba K, Jiang C, Nemoto S, Saji Y, Ikeda T, Urayama S, Azuma T, Hokugo A, Tsutsumi S, Tabata Y, Komeda M. A combination of omental flap and growth factor therapy induces arteriogenesis and increases myocardial perfusion in chronic myocardial ischemia: evolving concept of biologic coronary artery bypass grafting. *J Thorac Cardiovasc Surg.* 2006;132:891-899.

- 
106. Sarateanu CS, Retuerto MA, Beckmann JT, McGregor L, Carbray J, Patejunas G, Nayak L, Milbrandt J, Rosengart TK. An Egr-1 master switch for arteriogenesis: studies in Egr-1 homozygous negative and wild-type animals. *J Thorac Cardiovasc Surg.* 2006;131:138-145.
  107. Biswas SS, Hughes GC, Scarborough JE, Domkowski PW, Diodato L, Smith ML, Landolfo C, Lowe JE, Annex BH, Landolfo KP. Intramyocardial and intracoronary basic fibroblast growth factor in porcine hibernating myocardium: a comparative study. *J Thorac Cardiovasc Surg.* 2004;127:34-43.
  108. Min JY, Chen Y, Malek S, Meissner A, Xiang M, Ke Q, Feng X, Nakayama M, Kaplan E, Morgan JP. Stem cell therapy in the aging hearts of Fisher 344 rats: synergistic effects on myogenesis and angiogenesis. *J Thorac Cardiovasc Surg.* 2005;130:547-553.
  109. Funatsu T, Sawa Y, Ohtake S, Takahashi T, Matsumiya G, Matsuura N, Nakamura T, Matsuda H. Therapeutic angiogenesis in the ischemic canine heart induced by myocardial injection of naked complementary DNA plasmid encoding hepatocyte growth factor. *J Thorac Cardiovasc Surg.* 2002;124:1099-1105.
  110. Rosengart TK, Lee LY, Patel SR, Kligfield PD, Okin PM, Hackett NR, Isom OW, Crystal RG. Six-month assessment of a phase I trial of angiogenic gene therapy for the treatment of coronary artery disease using direct intramyocardial administration of an adenovirus vector expressing the

- 
- VEGF121 cDNA. *Ann Surg.* 1999;230:466-470; discussion 470-462.
111. Rosengart TK, Lee LY, Patel SR, Sanborn TA, Parikh M, Bergman GW, Hachamovitch R, Szulc M, Kligfield PD, Okin PM, Hahn RT, Devereux RB, Post MR, Hackett NR, Foster T, Grasso TM, Lesser ML, Isom OW, Crystal RG. Angiogenesis gene therapy: phase I assessment of direct intramyocardial administration of an adenovirus vector expressing VEGF121 cDNA to individuals with clinically significant severe coronary artery disease. *Circulation.* 1999;100:468-474.
112. Kim C, Li RK, Li G, Zhang Y, Weisel RD, Yau TM. Effects of cell-based angiogenic gene therapy at 6 months: persistent angiogenesis and absence of oncogenicity. *Ann Thorac Surg.* 2007;83:640-646.
113. Yau TM, Kim C, Li G, Zhang Y, Fazel S, Spiegelstein D, Weisel RD, Li RK. Enhanced angiogenesis with multimodal cell-based gene therapy. *Ann Thorac Surg.* 2007;83:1110-1119.
114. Yau TM, Kim C, Ng D, Li G, Zhang Y, Weisel RD, Li RK. Increasing transplanted cell survival with cell-based angiogenic gene therapy. *Ann Thorac Surg.* 2005;80:1779-1786.
115. Gowda RM, Khan IA, Punukollu G, Vasavada BC, Nair CK. Treatment of refractory angina pectoris. *Int J Cardiol.* 2005;101:1-7.
116. Kang S, Yang Y. Coronary microvascular reperfusion injury and no-reflow in acute myocardial infarction. *Clin Invest Med.* 2007;30:E133-145.
-

- 
117. van Gaal WJ, Banning AP. Percutaneous coronary intervention and the no-reflow phenomenon. *Expert Rev Cardiovasc Ther.* 2007;5:715-731.





## Coronary blood flow changes before and during application of myocardial topical negative pressure

\*Sandra Lindstedt, MD<sup>1</sup>; Malin Malmsjö, MD, PhD<sup>2</sup>; Bodil Gesslein MSc<sup>2</sup>; Richard Ingemansson, MD, PhD<sup>1</sup>

*Department of Cardiothoracic Surgery<sup>1</sup> and Department of Medicine<sup>2</sup>,  
Lund University Hospital, Lund, Sweden*

**Category of Manuscript:** Original Article

**Keywords:** Collateral blood flow, myocardium, ischemia, coronary blood flow.

**\*Corresponding Author:** Sandra Lindstedt, MD, Department of Cardiothoracic Surgery, Heart and Lung Center, Lund University Hospital, SE-221 85 Lund, Sweden, Phone: +46 46 173803, Fax: +46 46 158635, e-mail: sandra.lindstedt@skane.se

### Abstract

**Background** – Topical negative pressure (TNP), commonly used in wound therapy, has been shown to increase blood flow and stimulate angiogenesis. We have previously showed that myocardial TNP of -50 mmHg increases microvascular blood flow in the underlying myocardium in both normal and ischemic porcine myocardium. The present study was designed to elucidate if topical negative pressure, applied over the myocardium, resulted in an increase of the total amount of coronary blood flow.

**Methods** – Six pigs underwent median sternotomy. The blood flow was measured, before and after the application of TNP, using coronary ultrasonic flow meter probes and laser Doppler flowmetry. Analyses were performed before LAD occlusion (normal myocardium) and after 20 minutes of LAD occlusion (ischemic myocardium).

**Results** – A TNP of -50 mmHg induced an immediate, significant increase in total coronary blood flow in normal myocardium ( $171.3 \pm 14.5$  ml/min before, to  $206.3 \pm 17.6$  ml/min after TNP application,  $*p < 0.05$ ). A TNP of -50 mmHg induced a significant increase in

total coronary blood flow in ischemic myocardium ( $133.7 \pm 18.4$  ml/min before, to  $183.2 \pm 18.9$  ml/min after TNP application,  $*p < 0.05$ ).

**Conclusions** – TNP of -50 mmHg applied over the LAD region induced a significant increase not only in local microvascular blood flow but also in total coronary blood flow in normal and ischemic myocardium. In the present study we also found a significant correlation between coronary blood flow changes during TNP and laser Doppler signal.

### Introduction

Topical negative pressure (TNP) has been shown to facilitate the healing of chronic and problematic wounds[1-10]. The physiological and molecular biological mechanisms by which TNP promotes wound healing are still largely unknown. However, TNP is known to stimulate blood flow in tissues such as subcutaneous tissue and skeletal muscle[11-13]. TNP produces mechanical stress and a pressure gradient across the tissue, which cause a surge of blood to the area. Mechanical forces and increased blood flow are known to stimulate granulation tissue formation, i.e. endothelial proliferation, capillary budding and angiogenesis[14-16].

Several studies have suggested that mediastinitis, when conventional wound healing techniques were used (closed irrigation, delayed wound closure, or reconstructing with omentum or pectoral eleflaps), is a strong predictor for poor long-term survival after coronary artery by-pass surgery (CABG)[17-22]. Braxton and coworkers demonstrated in a large study including 36 078 patients after CABG that actuarial survival after 10 years was 39% in patients with mediastinitis and 70% in patients without mediastinitis[20]. Milano and collages have suggested that mediastinitis may cause negative long-terms effects on several organs such as the heart and kidneys[19]. Previously, we have showed no difference in long-term survival between CABG patients with TNP-treated mediastinitis and CABG patients without mediastinitis[23]. This might indicate that these patients might have developed increased coronary collateral blood vessels during TNP, since the heart is in direct contact with the vacuum source during TNP treatment, and may therefore be better prepared when bypass grafts fail to work. It may be that the TNP stimulation of blood flow and development of collateral blood vessels in part account for the reduced long-term mortality in patients.

In a previous report we applied a TNP of -50 mmHg over the LAD region on six pigs, and was able to show a significant increase in microvascular blood flow in normal myocardium (non-ischemic myocardium), in ischemic myocardium after 20 minutes of LAD occlusion, and also in reperfused myocardium (former ischemic myocardium after 20 minutes of reperfusion). The microvascular changes were measured by laser Doppler Flowmetry. [24]. The present study was designed to elucidate if the increase in microvascular blood flow is a result of an increase of the total amount of coronary blood flow or a redistribution of blood from other areas of the heart. An unchanged or decreased amount of the

total coronary blood flow to the heart might theoretically cause ischemia in parts of the myocardium not exposed to TNP. However, an increase in total coronary blood flow would theoretically stimulate granulation tissue formation, i.e. endothelial proliferation, capillary budding and angiogenesis. The study was also designed to elucidate any correlation between microvascular blood flow, measured by laser Doppler flowmetry, and coronary blood flow, measured by coronary ultrasonic flow meter. No such study has to our knowledge been done before.

## Material and Methods

### Experimental animals

A porcine model was use for the present study. Six domestic landrace pigs of both genders, with a mean body weight of 70 kg, were fasted overnight with free access to water. The study was approved by the Ethics Committee for Animal Research, Lund University, Sweden. The investigation complied with the "Guide for the Care and Use of Laboratory Animals" as recommended by the U.S. National Institutes of Health, and published by the National Academies Press (1996).

### Anesthesia

All animals were pre-medicated intramuscularly with ketamine (30 mg/kg) before they were brought into the laboratory. Before commencing surgery sodium thiopental (5 mg/kg), atropine (0.02 mg/kg) and pancuronium (0.5 mg/kg) were given intravenously. Tracheotomy was performed with a Portex endo-tracheal tube (7.5 mm internal diameter, Medcompare™, USA). A servo-ventilator (Siemens Elema 300A, Stockholm, Sweden) was used for mechanical ventilation throughout the experiment. The ventilator settings used were: minute volume = 100 ml/kg, FiO<sub>2</sub> = 0.5, breathing



frequency = 16 breaths/minute and positive end expiratory pressure = 5 cmH<sub>2</sub>O.

Anesthesia and muscular paralysis were maintained with a continuous intravenous infusion of 8-10 mg/kg/hour propofol (Diprivan®, AstraZeneca, Sweden), 0.15 mg/kg/hour fentanyl (Leptanal®, Lilly, France) and 0.6 mg/kg/hour pancuronium (Pavulon®, Organon Teknika, Boxtel, the Netherlands).

### Data acquisition

Mean arterial pressure, central venous pressure, heart frequency, and ventilatory parameters were recorded throughout the experiments.

### Surgical procedure

Surgery was performed through median sternotomy. After heparinization (400 IU/kg) a cardiopulmonary bypass (CPB) was installed with an arterial cannula (22 French, DLP® Elongated One-Piece Arterial Cannula (EOPA™), Medtronic Inc., Minneapolis, MO, USA) in the distal ascending aorta, and a venous cannula (32 French, MC2® Two-Stage Venous Cannula, also from Medtronic Inc.) inserted through the right atrium. Before cannulation of the heart the cannulae were inserted through the thoracic wall to prevent air leakage during TNP application. CPB was conducted in normothermia. Ventricular fibrillation was subsequently induced in the heart. No aortic cross-clamping was performed and no cardioplegia was employed. The mean arterial pressure was maintained between 60 and 80 mmHg. A left ventricular vent (DLP® Vent, also from Medtronic Inc.) was used to protect the left chamber from overloading. Pulmonary ventilation was applied at a rate of 4 liters/minute during the experiments.

A CPB was used to facilitate the measurements of microvascular blood flow using laser Doppler velocimetry. Fibrillation of the heart minimizes the movement artifacts, while the

physiological conditions are, to a large extent, conserved. Moreover, CPB prevents the risk of circulatory failure during LAD occlusion, thereby facilitating experimental analysis in the case of the ischemic myocardium.

The coronary ultrasonic flow meter probes (model BL 613; Biotronex Laboratory Inc., Chester, MD, USA) were positioned around the proximal part of the coronary vessels left anterior descending artery (LAD), circumflex coronary artery (CCX), and right coronary artery (RCA) respectively. The coronary blood flow was measured continuously throughout the experiments. Calibration of each probe was checked *in vitro* at the end of each experiment.

Microvascular blood flow was measured using laser Doppler velocimetry (Transonic® Laser Doppler Monitor, BLF21, Maastricht, the Netherlands, and Peri Flux System 5000, Perimed, Stockholm, Sweden), employing a technique that quantifies the sum of the motion of the red blood cells in a specific volume. This method is extensively applied in plastic surgery procedures and employs a fiberoptic probe carrying a beam of light. Light impinging on cells in motion undergoes a change in wavelength (Doppler shift) while light impinging on static objects remains unchanged. The magnitude and frequency distributions of the changes are directly related to the number and velocity of red blood cells. The information is collected by a returning fiber, converted into an electronic signal, and analyzed[25].

Laser Doppler probes were inserted horizontally into the heart muscle 6-8 mm lateral of the LAD at depths of approximately 6-8 mm. All probes were carefully fixed to the surface of the heart with a suture (Prolene 7-0; Ethicon Inc., New Jersey, USA), thereby preventing probe movement. After the experiments,

the heart was dissected and the probe location was confirmed. A round hole, 5 cm in diameter, was made in the middle of a phrenic nerve pad (Phrenic Nerve Pad<sup>®</sup>, Medtronic Inc.) and placed on top of the heart. The pad was stabilized by 8-10 sutures to the surrounding myocardium (Prolene 5-0; Ethicon Inc., New Jersey, USA) and by sutures to the posterior sternal edges (Dermalon 2-0; Davis and Geck, St. Louis, New Jersey, USA). A retractor was used throughout the experiments to keep the sternal edges apart. A polyurethane foam dressing, with an open pore structure of 400 to 600  $\mu\text{m}$  (KCI, Copenhagen, Denmark) was placed between the sternal edges. The foam was continuously sutured to the surrounding skin (Dermalon 2-0; Davis and Geck). The wound was sealed with a transparent adhesive drape. A Track Pad (KCI, Copenhagen, Denmark) was inserted through the drape and was connected to a vacuum pump, (V.A.C. pump unit, KCI, Copenhagen, Denmark). When the negative pressure is applied, the heart will be drawn up towards the phrenic nerve pad and the foam without interfering with the sternal edges. This procedure causes the application of negative pressure to affect only the myocardium exposed by the 5 cm diameter hole.

### Experimental protocol

The coronary blood flow was measured continuously by ultrasonic flow meter probes and the microvascular blood flow response in the myocardium was measured continuously by the laser Doppler filament probes. Recordings were made in normal myocardium, before and while a negative pressure of -50 mmHg was applied.

The LAD was then occluded for 20 minutes with an elastic vessel loop. Coronary blood flow and the microvascular blood flow were then measured before, and after 1, 5, 10, 15, and 20 minutes of occlusion. A negative pressure of -50 mmHg was then applied to

the heart, and coronary blood flow changes and the microvascular blood flow changes were recorded. The negative pressure was then removed.

### Calculations and statistics

Laser Doppler velocimetry measurements were performed on six pigs. The output was continuously recorded using PeriSoft software (Perimed, Stockholm, Sweden). Microvascular blood flow was expressed in terms of perfusion units (PU). Calculations and statistical analysis were performed using GraphPad 4.0 software. Statistical analysis on microvascular blood flow, and coronary blood flow, was performed using Student's paired t-test. Values are presented as means  $\pm$  the standard error on the mean (SEM). The correlation between microvascular blood flow, measured by laser Doppler flowmetry, and coronary blood flow, measured by coronary ultrasonic flow meter, was performed by using Pearson correlation, with two tailed p value. Significance was defined as \* $p < 0.05$ , and  $p > 0.05$  (not significant, n.s.).

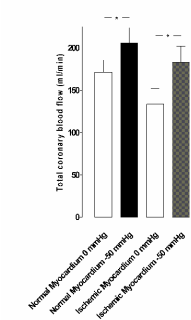
## Results

### Coronary flow meters

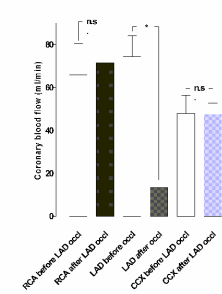
#### Normal myocardium

A topical negative pressure of -50 mmHg induced an immediate, significant increase in total coronary blood flow, in normal myocardium ( $171.3 \pm 14.5$  ml/min before, to  $206.3 \pm 17.6$  ml/min after TNP application, \* $p < 0.05$ ) (Figure 1). Divided between the three coronary arteries, -50 mmHg induced an immediate, increase in local coronary blood flow in the CCX ( $49.2 \pm 6.1$  ml/min before, to  $53.7 \pm 5.0$  ml/min after TNP application, n.s.  $p > 0.05$ ), the LAD ( $60.5 \pm 11.1$  ml/min before, to  $77.8 \pm 12.2$  ml/min after TNP application, \* $p < 0.05$ ), and the RCA ( $61.7 \pm 11.6$  ml/min before, to  $74.8 \pm 13.1$  ml/min after TNP application, \* $p < 0.05$ )

(Figure 2). The results for every animal are shown in figure 5A.



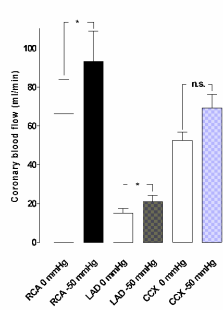
**Figure 1** The total blood flow changes using coronary ultrasonic flow meter probes in normal and ischemic myocardium before and during application of -50 mmHg. The measurements were performed at the proximal part of the right coronary artery (RCA), the left anterior descending artery (LAD), and the circumflex coronary artery (CCX) in six pigs. The change in total coronary artery blood flow is shown as mean values  $\pm$  SEM. Statistical analysis was performed using Student's paired t-test, and significance was defined as \*  $p < 0.05$ , and  $p > 0.05$  (not significant, n.s.).



**Figure 2** The blood flow measured using coronary ultrasonic flow meter probes in normal myocardium. The measurements were performed at the proximal part of the right coronary artery (RCA), left anterior descending artery (LAD), and circumflex coronary artery (CCX) in the myocardium in six pigs, with a topical negative pressure of -50 mmHg. The results are shown as mean values  $\pm$  SEM. Statistical analysis was performed using Student's paired t-test, and significance was defined as \*  $p < 0.05$ , and  $p > 0.05$  (not significant, n.s.).

**LAD occlusion**

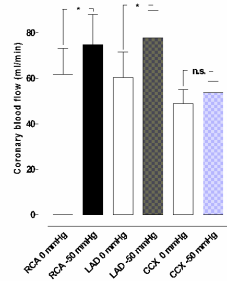
Ischemia was induced by occlusion of the LAD for 20 minutes. The coronary blood flow in the LAD decreased significantly (from  $74.3 \pm 9.8$  ml/min before to  $13.3 \pm 2.0$  ml/min, \* $p < 0.05$ ) after 20 minutes of LAD occlusion (Figure 3).



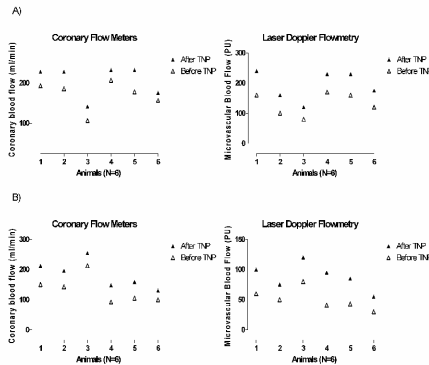
**Figure 3** The blood flow measured using coronary ultrasonic flow meter probes before and after 1, 5, and 20 min of left anterior descending artery (LAD) occlusion. The measurements were performed at the proximal part of the right coronary artery (RCA), LAD, and circumflex coronary artery (CCX) in six pigs. Results are shown as mean values  $\pm$  SEM. Statistical analysis was performed using Student's paired t-test, and significance was defined as \*  $p < 0.05$ , and  $p > 0.05$  (not significant, n.s.).

**Ischemic myocardium**

A topical negative pressure of -50 mmHg induced an immediate, significant increase in total coronary artery blood flow in ischemic myocardium ( $133.7 \pm 18.4$  ml/min before, to  $183.2 \pm 18.9$  ml/min after TNP application, \* $p < 0.05$ ) (Figure 1). Application of -50 mmHg induced an immediate, increase in local coronary blood flow in the CCX ( $52.2 \pm 4.2$  ml/min before, to  $69.2 \pm 7.0$  ml/min after TNP application, n.s.  $p > 0.05$ ). The coronary blood flow in the LAD significantly increased (from  $15.0 \pm 2.4$  ml/min before to  $21.0 \pm 7.9$  ml/min, \* $p < 0.05$ ), and the coronary blood flow in RCA also significantly increased ( $66.2 \pm 17.9$  ml/min before, to  $93.0 \pm 15.7$  ml/min after TNP application, \* $p < 0.05$ ) (Figure 4). The results for every animal are shown in figure 5B.



**Figure 4)** The blood flow measured using coronary ultrasonic flow meter probes in ischemic myocardium. The measurements were performed at the proximal part of the right coronary artery (RCA), the left anterior descending artery (LAD), and the circumflex coronary artery (CCX) in the myocardium in six pigs, with a topical negative pressure of -50 mmHg. The results are shown as mean values  $\pm$  SEM. Statistical analysis was performed using Student's paired t-test, and significance was defined as \*  $p < 0.05$ , and  $p > 0.05$  (not significant, n.s.).



**Figure 5)** Total coronary blood flow measured using coronary ultrasonic flow meter probes, and microvascular blood flow using laser Doppler flowmetry. The total coronary blood flow measurements were performed at the proximal part of the right coronary artery, the left anterior descending artery (LAD), and the circumflex coronary artery, and the measurements of microvascular blood flow were performed 6-8 mm down into the myocardium, 6-8 mm lateral of the LAD, in six pigs. All the animals (N=6) measured values are shown in normal myocardium before and after application of topical negative pressure (TNP) of -50 mmHg (A), and in ischemic myocardium before and after application of topical negative pressure (TNP) of -50 mmHg (B).

**Laser Doppler flowmetry**

**Normal myocardium**

A topical negative pressure of -50 mmHg induced an immediate, significant increase in laser Doppler velocimetry measured microvascular blood flow response in the LAD region in normal myocardium ( $131.7 \pm 18.3$  PU before, to  $192.5 \pm 23.8$  PU after

TNP application, \* $p < 0.05$ ) (Figure 5A). A significant correlation was found between coronary blood flow and laser Doppler signals in normal myocardium ( $r^2 = 0.81$ , \* $p < 0.05$ ).

**Ischemic Myocardium**

A topical negative pressure of -50 mmHg also induced an immediate, significant increase in laser Doppler velocimetry measured microvascular blood flow response in the LAD region of the ischemic myocardium ( $50.7 \pm 7.1$  PU before, to  $88.3 \pm 9.1$  PU after TNP application, \* $p < 0.05$ ) (Figure 5B). A significant correlation was found between coronary blood flow and laser Doppler signals in ischemic myocardium ( $r^2 = 0.96$ , \* $p < 0.05$ ).

**Comments**

Poststernotomy mediastinitis is a rare but potentially lethal complication following cardiac surgery[17, 19, 26]. Lately, TNP has become the therapy of choice for mediastinitis, due to the exceptional clinical outcome[6, 7, 10, 23]. Topical negative pressure acts by a subatmospheric pressure application over the wound by controlled suction through a porous dressing. However, the fundamental scientific mechanism of TNP is only partially understood. One of the known effects of TNP is enhanced blood flow to the wound edge and granulation tissue formation[1, 2, 15]. TNP increases blood flow velocity and opens up the capillary beds. Mechanical forces exerted by TNP and increased blood flow affect the cytoskeleton in the vascular cells, stimulating endothelial proliferation, capillary budding and angiogenesis, i.e. granulation tissue formation[14, 16, 27, 28].

In patients with poststernotomy mediastinitis treated with TNP the topical negative pressure is in direct contact with the heart, which is exposed through the

diastase of the sternotomy. We have previously observed that these patients develop a richly vascularized granulation tissue over the heart within 6-7 days on the exposed surface of the heart. In the present study, we hypothesized that the application of TNP to the surface of the heart would stimulate neovascularization and microvascular blood flow in the myocardium, as seen in skeletal muscle during TNP[13, 29-32]. It is commonly known among cardiothoracic surgeons that mediastinitis is a strong predictor of poor long-term survival after CABG, when using conventional wound healing techniques (such as closed irrigation, delayed wound closure, or reconstructing with omentum or pectoral flaps). It has been suggested that mediastinitis may cause negative, long-term effects on several organs, such as the heart and kidneys[18, 20, 33]. Previously, we have showed no difference in long-term survival between CABG patients with TNP-treated mediastinitis and CABG patients without mediastinitis[23]. This might indicate that these patients might have developed increased coronary collateral blood vessels during TNP, and may therefore be better prepared when bypass grafts fail to work. It may be that the TNP stimulation of blood flow and development of collateral blood vessels in part account for the reduced long-term mortality in patients treated with TNP for poststernotomy mediastinitis after CABG.

In a previous report we applied a TNP of -50 mmHg over the LAD region on six pigs, and was able to show a significant increase in microvascular blood flow in normal myocardium, ischemic myocardium, and in reperfused myocardium (former ischemic myocardium after 20 minutes of reperfusion). The microvascular blood flow changes were measured by laser Doppler Flowmetry. We have also demonstrated that among TNP pressure levels between -50 mmHg and -150 mmHg

only, -50 mmHg result in a significant increase in myocardial microvascular blood flow in ischemic myocardium[34]. In the present study we show that application of a topical negative pressure of -50mmHg directly on the myocardium (over the LAD region) result in an increase of the total coronary blood flow not only in normal but also in ischemic myocardium (Figure 1). An unchanged or decreased amount of the total coronary blood flow might theoretically cause ischemia in parts of the myocardium not exposed to TNP. Since the present study shows a significant increase in the total amount of coronary blood flow, ischemic areas are not likely to occur.

Measurement of myocardial microvascular blood flow is complex. Laser Doppler flowmetry provides a continuous record of the microvascular blood flow. Ahn et al. have assessed the myocardial perfusion in an empty beating porcine heart with laser Doppler flowmetry. Their findings suggests that laser Doppler signals from probes in the epicardium and a few centimetres down into the ventricular wall had a significant linear correlation between coronary sinus blood flow changes and changes of the CPB flow. They also found that muscular activity of the heart contributed to the laser Doppler signal, which makes it difficult to discriminate the results between blood flow and muscular contribution[35]. They also assessed the myocardial perfusion during ventricular fibrillation in a porcine heart with laser Doppler flowmetry, and found a significant correlation between laser Doppler signal, coronary blood flow, and CPB flow[36]. During low intense ventricular fibrillation the heart muscle will not make large movements and the artefacts and possible probe sliding could be minimized, thereby making measurements of the myocardium with laser Doppler flowmetry easier. In the present study, CPB was used, which facilitated the intervention since arrhythmia and circulatory failure were

avoided during the induction of ischemia. The experiment was conducted during low intense ventricular fibrillation to minimize movement artifacts from heart beats, and minimize tissue trauma, and sliding of the laser Doppler probes, while measuring blood flow in the myocardium[35]. Ventricular fibrillation does differ from sinus rhythm. During ventricular fibrillation there is no synchronized contraction in the ventricles. If perfusion pressure is kept around 100 mmHg the ventricular wall will still be perfused[37], but the myocardial wall tension may become higher than in a beating heart[38]. Hottenrot et al. showed in 1972 that perfusion of a fibrillating dog heart for one to two hours did not damage the subendocardial muscle unless a strong maintained electrical stimulus was used[39]. In the present study we found a significant correlation between coronary blood flow changes during TNP and laser Doppler signal (Figure 6).

The future clinical application of myocardial TNP is still too early to determine. However, the potential application of myocardial TNP speculatively, in the future, might become in the treatment of patients with extensive coronary disease or/and refractory angina pectoris but also in the acute phase of a ST-elevation myocardial infarction. Therapeutic angiogenesis, wherein exogenous growth factors are administered to ischemic tissue to enhance the reperfusion of these tissues, has been investigated as a potential therapy for patients with advanced coronary artery disease as an alternative to conventional treatment such as PCI and CABG. It includes both protein and gene therapy, and they have both successfully induced angiogenic responses in animal studies, but optimal delivery of the angiogenic factor is difficult[40, 41]. However, VEGF proteins have been shown to play a key role in the modulation of angiogenesis and vascular growth[42, 43]. Moreover, TNP produces a

mechanical shear stress that is known to activate VEGF[44-48].

## Conclusions

In the present study we show that topically applied negative pressure of -50 mmHg over the LAD region result in a significant increase of the total amount of coronary blood flow. In the present study we also found a significant correlation between coronary blood flow changes during TNP and laser Doppler signal. The increase in blood flow might in part explain the improved long-term outcome using TNP treatment on patients with poststernotomy mediastinitis compared to conventional therapy[23].

## Acknowledgements

We would like to thank Johan Ingemansson (Statistical Solutions IP) for his expert contribution to the statistic analyses.

## Funding sources

This study was supported by Anders Otto Swärd's Foundation / Ulrika Eklund's Foundation, Anna Lisa and Sven Eric Lundgren's Foundation for medical research, the Åke Wiberg Foundation, the M. Bergvall Foundation, the Swedish Medical Association, the Royal Physiographic Society in Lund, the Swedish Medical Research Council, the Crafoord Foundation, the Swedish Heart-Lung Foundation, the Swedish Government Grant for Clinical Research, and the Swedish Hypertension Society.

## References

1. Morykwas MJ, Argenta LC, Shelton-Brown EI, McGuirt W. Vacuum-assisted closure: a new method for wound control and treatment: animal studies and basic foundation. *Ann Plast Surg.* 1997;38:553-562.

2. Argenta LC, Morykwas MJ. **Vacuum-assisted closure: a new method for wound control and treatment: clinical experience.** *Ann Plast Surg.* 1997;38:563-576; discussion 577.

3. Armstrong DG, Lavery LA. **Negative pressure wound therapy after partial diabetic foot amputation: a multicentre, randomised controlled trial.** *Lancet.* 2005;366:1704-1710.

4. O'Connor J, Kells A, Henry S, Scalea T. **Vacuum-assisted closure for the treatment of complex chest wounds.** *Ann Thorac Surg.* 2005;79:1196-1200.

5. Brown KM, Harper FV, Aston WJ, O'Keefe PA, Cameron CR. **Vacuum-assisted closure in the treatment of a 9-year-old child with severe and multiple dog bite injuries of the thorax.** *Ann Thorac Surg.* 2001;72:1409-1410.

6. Gustafsson RI, Sjogren J, Ingemansson R. **Deep sternal wound infection: a sternal-sparing technique with vacuum-assisted closure therapy.** *Ann Thorac Surg.* 2003;76:2048-2053; discussion 2053.

7. Sjogren J, Gustafsson R, Nilsson J, Malmso M, Ingemansson R. **Clinical outcome after poststernotomy mediastinitis: vacuum-assisted closure versus conventional treatment.** *Ann Thorac Surg.* 2005;79:2049-2055.

8. Gustafsson R, Johnsson P, Algotsson L, Blomquist S, Ingemansson R. **Vacuum-assisted closure therapy guided by C-reactive protein level in patients with deep sternal wound infection.** *J Thorac Cardiovasc Surg.* 2002;123:895-900.

9. Cowan KN, Teague L, Sue SC, Mahoney JL. **Vacuum-assisted wound closure of deep sternal infections in high-risk patients after cardiac surgery.** *Ann Thorac Surg.* 2005;80:2205-2212.

10. Fleck TM, Fleck M, Moidl R, Czerny M, Koller R, Giovanoli P, Hiesmayer MJ, Zimpfer D, Wolner E, Grabenwoger M. **The vacuum-assisted closure system for the treatment of deep sternal wound infections after cardiac surgery.** *Ann Thorac Surg.* 2002;74:1596-1600; discussion 1600.

11. Wackenfors A, Sjogren J, Gustafsson R, Algotsson L, Ingemansson R, Malmso M. **Effects of vacuum-assisted closure therapy on inguinal wound edge microvascular blood flow.** *Wound Repair Regen.* 2004;12:600-606.

12. Chen SZ, Li J, Li XY, Xu LS. **Effects of vacuum-assisted closure on wound microcirculation: an experimental study.** *Asian J Surg.* 2005;28:211-217.

13. Wackenfors A, Gustafsson R, Sjogren J, Algotsson L, Ingemansson R, Malmso M. **Blood flow responses in the peristernal thoracic wall during vacuum-assisted closure therapy.** *Ann Thorac Surg.* 2005;79:1724-1730; discussion 1730-1721.

14. Vandenburgh HH. **Mechanical forces and their second messengers in stimulating cell growth in vitro.** *Am J Physiol.* 1992;262:R350-355.

15. Saxena V, Hwang CW, Huang S, Eichbaum Q, Ingber D, Orgill DP. **Vacuum-assisted closure: microdeformations of wounds and cell proliferation.** *Plast Reconstr Surg.* 2004;114:1086-1096; discussion 1097-1088.

16. Greene AK, Puder M, Roy R, Arsenault D, Kwei S, Moses MA, Orgill DP. **Microdeformational wound therapy: effects on angiogenesis and matrix metalloproteinases in chronic wounds of 3 debilitated patients.** *Ann Plast Surg.* 2006;56:418-422.

17. Lu JC, Grayson AD, Jha P, Srinivasan AK, Fabri BM. **Risk factors for sternal wound infection and mid-term survival following coronary artery bypass surgery.** *Eur J Cardiothorac Surg.* 2003;23:943-949.

18. Loop FD, Lytle BW, Cosgrove DM, Mahfood S, McHenry MC, Goormastic M, Stewart RW, Golding LA, Taylor PC. **J. Maxwell Chamberlain memorial paper. Sternal wound complications after isolated coronary artery bypass grafting: early and late mortality, morbidity, and cost of care.** *Ann Thorac Surg.* 1990;49:179-186; discussion 186-177.

19. Milano CA, Kesler K, Archibald N, Sexton DJ, Jones RH. **Mediastinitis after coronary artery bypass graft surgery. Risk factors and long-term survival.** *Circulation.* 1995;92:2245-2251.

20. Braxton JH, Marrin CA, McGrath PD, Ross CS, Morton JR, Norotsky M, Charlesworth DC, Lahey SJ, Clough RA, O'Connor GT. **Mediastinitis and long-term survival after coronary artery bypass graft surgery.** *Ann Thorac Surg.* 2000;70:2004-2007.

21. Toumpoulis IK, Anagnostopoulos CE, Derosé JJ, Jr., Swistel DG. **The impact of deep sternal wound infection on long-term survival after coronary artery bypass grafting.** *Chest.* 2005;127:464-471.

22. Stahle E, Tammelin A, Bergstrom R, Hambreus A, Nystrom SO, Hansson HE. **Sternal wound complications--incidence, microbiology and risk factors.** *Eur J Cardiothorac Surg.* 1997;11:1146-1153.

23. Sjogren J, Nilsson J, Gustafsson R, Malmso M, Ingemansson R. **The impact of vacuum-assisted closure on long-term survival after post-sternotomy mediastinitis.** *Ann Thorac Surg.* 2005;80:1270-1275.

24. Lindstedt S, Malmso M, Ingemansson R. **Blood flow changes in normal and ischemic myocardium during topically applied negative pressure.** *Ann Thorac Surg.* 2007;84:568-573.

25. Zografos GC, Martis K, Morris DL. **Laser Doppler flowmetry in evaluation of cutaneous wound blood flow using various suturing techniques.** *Ann Surg.* 1992;215:266-268.

26. Braxton JH, Marrin CA, McGrath PD, Morton JR, Norotsky M, Charlesworth DC, Lahey SJ, Clough R, Ross CS, Olmstead EM, O'Connor GT. **10-year follow-up of patients with and without mediastinitis.** *Semin Thorac Cardiovasc Surg.* 2004;16:70-76.

27. Korff T, Augustin HG. **Tensional forces in fibrillar extracellular matrices control directional capillary sprouting.** *J Cell Sci.* 1999;112 ( Pt 19):3249-3258.

28. Chen CS, Mrksich M, Huang S, Whitesides GM, Ingber DE. **Micropatterned surfaces for control of cell shape, position, and function.** *Biotechnol Prog.* 1998;14:356-363.

29. Petzina R, Gustafsson L, Mokhtari A, Ingemansson R, Malmso M. **Effect of vacuum-assisted closure on blood flow in the peristernal thoracic wall after internal mammary artery harvesting.** *Eur J Cardiothorac Surg.* 2006;30:85-89.

30. Chen SZ, Cao DY, Li JQ, Tang SY. **[Effect of vacuum-assisted closure on the expression of proto-oncogenes and its significance during wound healing].** *Zhonghua Zheng Xing Wai Ke Za Zhi.* 2005;21:197-200.

31. Wackenfors A, Sjogren J, Algotsson L, Gustafsson R, Ingemansson R, Malmso M. **The effect of vacuum-assisted closure therapy on the pig femoral artery vasomotor responses.** *Wound Repair Regen.* 2004;12:244-251.

32. Koller A, Kaley G. **Endothelial regulation of wall shear stress and blood flow in skeletal muscle microcirculation.** *Am J Physiol.* 1991;260:H862-868.

33. De Feo M, Renzulli A, Ismeno G, Gregorio R, Della Corte A, Utili R, Cotrufo M. **Variables predicting adverse outcome in patients with deep sternal wound infection.** *Ann Thorac Surg.* 2001;71:324-331.

34. Lindstedt S, Malmso M, Sjogren J, Gustafsson R, Ingemansson R. **Impact of different topical negative pressure levels on myocardial**

microvascular blood flow *Cardiovasc Revasc Med.* 2007;IN PRESS.

35. Ahn HC, Ekroth R, Hedenmark J, Nilsson GE, Svedjeholm R. **Assessment of myocardial perfusion in the empty beating porcine heart with laser Doppler flowmetry.** *Cardiovasc Res.* 1988;22:719-725.

36. von Ahn HC, Ekroth R, Nilsson GE, Svedjeholm R. **Assessment of myocardial perfusion with laser Doppler flowmetry. An experimental study on porcine heart.** *Scand J Thorac Cardiovasc Surg.* 1988;22:145-148.

37. Brazier JR, Cooper N, McConnell DH, Buckberg GD. **Studies of the effects of hypothermia on regional myocardial blood flow and metabolism during cardiopulmonary bypass. III. Effects of temperature, time, and perfusion pressure in fibrillating hearts.** *J Thorac Cardiovasc Surg.* 1977;73:102-109.

38. Buckberg GD, Brazier JR, Nelson RL, Goldstein SM, McConnell DH, Cooper N. **Studies of the effects of hypothermia on regional myocardial blood flow and metabolism during cardiopulmonary bypass. I. The adequately perfused beating, fibrillating, and arrested heart.** *J Thorac Cardiovasc Surg.* 1977;73:87-94.

39. Hottenrott C, Buckberg GD, Maloney JV, Jr. **Effects of ventricular fibrillation on distribution and adequacy of coronary blood flow.** *Surg Forum.* 1972;23:200-202.

40. Yau TM, Kim C, Li G, Zhang Y, Fazel S, Spiegelstein D, Weisel RD, Li RK. **Enhanced angiogenesis with multimodal cell-based gene therapy.** *Ann Thorac Surg.* 2007;83:1110-1119.

41. Kim C, Li RK, Li G, Zhang Y, Weisel RD, Yau TM. **Effects of cell-based angiogenic gene therapy at 6 months: persistent angiogenesis and absence of oncogenicity.** *Ann Thorac Surg.* 2007;83:640-646.

42. Rosengart TK, Lee LY, Patel SR, Kligfield PD, Okin PM, Hackett NR, Isom OW, Crystal RG. **Six-month assessment of a phase I trial of angiogenic gene therapy for the treatment of coronary artery disease using direct intramyocardial administration of an adenovirus vector expressing the VEGF121 cDNA.** *Ann Surg.* 1999;230:466-470; discussion 470-462.

43. Rosengart TK, Lee LY, Patel SR, Sanborn TA, Parikh M, Bergman GW, Hachamovitch R, Szulc M, Kligfield PD, Okin PM, Hahn RT, Devereux RB, Post MR, Hackett NR, Foster T, Grasso TM, Lesser ML, Isom OW, Crystal RG. **Angiogenesis gene therapy: phase I assessment of direct intramyocardial administration of an adenovirus vector expressing VEGF121 cDNA to individuals with clinically significant severe coronary artery disease.** *Circulation.* 1999;100:468-474.

44. Chen KD, Li YS, Kim M, Li S, Yuan S, Chien S, Shyy JY. **Mechanotransduction in response to shear stress. Roles of receptor tyrosine kinases, integrins, and Shc.** *J Biol Chem.* 1999;274:18393-18400.

45. Detmar M, Brown LF, Berse B, Jackman RW, Elicker BM, Dvorak HF, Claffey KP. **Hypoxia regulates the expression of vascular permeability factor/vascular endothelial growth factor (VPF/VEGF) and its receptors in human skin.** *J Invest Dermatol.* 1997;108:263-268.

46. Shyu KG, Chang ML, Wang BW, Kuan P, Chang H. **Cyclical mechanical stretching increases the expression of vascular endothelial growth factor in rat vascular smooth muscle cells.** *J Formos Med Assoc.* 2001;100:741-747.

47. Milkiewicz M, Mohammadzadeh F, Ispanovic E, Gee E, Haas TL. **Static strain stimulates expression of matrix metalloproteinase-2 and VEGF in microvascular endothelium via JNK- and ERK-dependent pathways.** *J Cell Biochem.* 2007;100:750-761.

48. Seko Y, Seko Y, Takahashi N, Shibuya M, Yazaki Y. **Pulsatile stretch stimulates vascular endothelial growth factor (VEGF) secretion by cultured rat cardiac myocytes.** *Biochem Biophys Res Commun.* 1999;254:462-465.



II



# Blood Flow Changes in Normal and Ischemic Myocardium During Topically Applied Negative Pressure

Sandra Lindstedt, MD, Malin Malmström, MD, PhD, and Richard Ingemansson, MD, PhD

Departments of Cardiothoracic Surgery and Medicine, Lund University Hospital, Lund, Sweden

**Background.** Topical negative pressure (TNP) therapy has been adopted as a first-line treatment for wound healing. One of the mechanisms by which TNP improves healing is by stimulating blood flow to the wound edge. Among patients with ischemic heart disease, it is of great importance to improve the microvascular blood flow in the myocardium during episodes of ischemia to protect the myocardium from infarction. The present study was designed to elucidate the effect of TNP on microvascular blood flow in the myocardium.

**Methods.** Six pigs underwent median sternotomy. The microvascular blood flow in the myocardium was recorded, before and after the application of TNP, by using laser Doppler velocimetry. Analyses were performed before left anterior descending artery (LAD) occlusion (normal myocardium), after 20 minutes of LAD occlusion

(ischemic myocardium), and after 20 minutes of reperfusion (reperfused myocardium).

**Results.** TNP at  $-0$  mm Hg increased microvascular blood flow in the normal myocardium from  $14.7 \pm 3.9$  perfusion units (PU) before to  $25.8 \pm 6.1$  PU after TNP application ( $p < 0.05$ ), in the ischemic myocardium from  $7.2 \pm 1.5$  PU before to  $13.8 \pm 2.6$  PU after TNP application ( $p < 0.05$ ), and in the reperfused myocardium from  $10.8 \pm 2.0$  PU before to  $19.3 \pm 5.6$  PU after TNP application ( $p < 0.05$ ).

**Conclusions.** TNP increases the microvascular blood flow significantly in normal, ischemic, and reperfused myocardium and may provide a novel therapeutic tool in the treatment of ischemic myocardium.

(Ann Thorac Surg 2007;84:568–73)

© 2007 by The Society of Thoracic Surgeons

Topical negative pressure (TNP) has been shown to facilitate the healing of chronic and problematic wounds, including diabetic wounds [1], burn wounds [2], and poststernotomy mediastinitis [3–5]. One mechanism by which TNP promotes wound healing is by stimulating wound edge blood flow, as has been demonstrated in peripheral [6] and in skeletal muscle in sternotomy wounds [7, 8]. TNP produces mechanical stress and a pressure gradient across the tissue, which may cause a surge of blood to the area [6, 9–11]. Mechanical forces and increased blood flow are known to stimulate endothelial proliferation, capillary budding, and angiogenesis [12].

In ischemic heart disease, therapeutic interventions such as percutaneous coronary intervention (PCI) and coronary artery bypass grafting surgery (CABG) are performed to improve blood flow to the ischemic myocardium. These treatments are successful in most cases, although such interventions are not possible for patients with refractory angina pectoris because of extensive coronary vessel disease. Percutaneous myocardial laser revascularization [13, 14] and enhanced external counterpulsation [15, 16] have been tried with varying results

[17]. A means of increasing microvascular blood flow in the ischemic myocardium would thus be beneficial.

TNP is known to stimulate blood flow in various tissues [6], including the skeletal muscle [7, 8]. We conducted this study to examine the effects of TNP on microvascular blood flow in normal, ischemic, and reperfused myocardium. Blood flow was measured using laser Doppler velocimetry in a porcine model. The effect of TNP on microvascular blood flow was investigated in the myocardium before, during, and after occlusion of the left anterior descending artery (LAD).

## Material and Methods

### Experimental Animals

A porcine model was used for the present study. Six domestic Landrace pigs of both genders (mean body weight, 70 kg) were fasted overnight with free access to water. The study was approved by the Ethics Committee for Animal Research, Lund University, Sweden. The investigation complied with the *Guide for the Care and Use of Laboratory Animals* (US National Institutes of Health, National Academies Press; 1996).

### Anesthesia

The animals were premedicated intramuscularly with ketamine (30 mg/kg) before they were brought into the laboratory. Before the procedure began, sodium thiopen-

Accepted for publication Feb 22, 2007.

Address correspondence to Dr Lindstedt, Department of Cardiothoracic Surgery, Heart and Lung Center, Lund University Hospital, SE-221 85 Lund, Sweden; e-mail: sandra.lindstedt@skane.se.

tal (5 mg/kg), atropine (0.02 mg/kg), and pancuronium (0.5 mg/kg) were given intravenously. A tracheotomy was performed with a Portex endotracheal tube (7.5 mm internal diameter, Smiths Medical, Carlsbad, CA). A servo-ventilator (Siemens Elema 300A, Stockholm, Sweden) was used for mechanical ventilation throughout the experiment. The ventilator settings were minute volume, 100 mL/kg; fraction of inspired oxygen, 0.5; breathing frequency, 16 breaths/min; and positive end expiratory pressure, 5 cm H<sub>2</sub>O.

Anesthesia and muscular paralysis were maintained with a continuous intravenous infusion of 8 to 10 mg/(kg · hour) propofol (Diprivan, AstraZeneca, Södertälje, Sweden), 0.15 mg/(kg · hour) fentanyl (Leptanal, Lilly, Suresnes, France), and 0.6 mg/(kg · hour) pancuronium (Pavulon, Organon Teknika, Boxtel, The Netherlands).

Mean arterial pressure, central venous pressure, heart frequency, and ventilatory measurements were recorded throughout the experiments.

#### Surgical Procedure

The procedure was performed through median sternotomy. After heparinization (400 IU/kg), cardiopulmonary bypass (CPB) was initiated with a 22F arterial cannula (DLP, elongated one-piece arterial cannula, Medtronic Inc, Minneapolis, MN) in the distal ascending aorta, and a 32F venous cannula (MC2 two-stage venous cannula, Medtronic, Inc) inserted through the right atrium. Before cannulation of the heart, the cannulas were inserted through the thoracic wall to prevent air leakage during TNP application. CPB was conducted in normothermia. Ventricular fibrillation was subsequently induced in the heart.

No aortic cross-clamping was performed, and no cardioplegia was used. The mean arterial pressure was maintained between 60 and 80 mm Hg. A left ventricular vent (DLP Vent, Medtronic Inc) was used to protect the left chamber from overloading. Pulmonary ventilation was applied at a rate of 4 L/min during the experiments.

CPB was used to facilitate the measurements of microvascular blood flow using laser Doppler velocimetry. Fibrillation of the heart minimizes the movement artifacts, while the physiologic conditions are largely conserved. Moreover, CPB prevents the risk of circulatory failure during LAD occlusion, thereby facilitating experimental analysis in the case of the ischemic myocardium.

Microvascular blood flow was measured with laser Doppler velocimetry (Transonic Laser Doppler Monitor, BLF21, Maastricht, The Netherlands) by using a technique that quantifies the sum of the motion of the red blood cells in a specific volume. This method, which is extensively applied in plastic surgery procedures [18], uses a fiberoptic probe carrying a beam of light. Light impinging on cells in motion undergoes a change in wavelength (Doppler shift), and light impinging on static objects remains unchanged. The magnitude and frequency distributions of the changes are directly related to the number and velocity of red blood cells. The information is collected by a returning fiber, converted into an electronic signal, and analyzed.

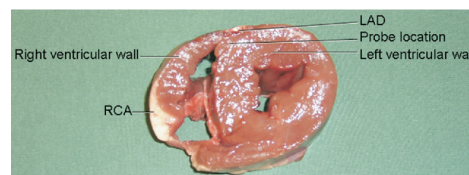


Fig 1. As shown in this photograph, the laser Doppler probes were inserted horizontally into the heart muscle 8 to 10 mm lateral of the left anterior descending artery (LAD); that is, the septum of the heart, at depths of approximately 6 to 8 mm. The photograph also shows the location of right coronary artery (RCA).

Laser Doppler probes were inserted horizontally into the heart muscle 8 to 10 mm lateral of the LAD at depths of approximately 6 to 8 mm. All probes were carefully fixed to the surface of the heart with a Prolene 7-0 suture (Ethicon Inc, Somerville, NJ), thereby preventing probe movement. After the experiments, the heart was dissected and the probe location was confirmed (Fig 1).

A round hole 5 cm in diameter was made in the middle of a phrenic nerve pad (Medtronic Inc) and placed on top of the heart. The pad was stabilized by 8 to 10 Prolene 5-0 sutures to the surrounding myocardium and by Dermalon 2-0 sutures (Syneture, Norwalk, CT) the posterior sternal edges. A retractor was used throughout the experiments to keep the sternal edges apart. A polyurethane foam dressing with an open pore structure of 400 to 600  $\mu$ m (KCI, Copenhagen, Denmark) was placed between the sternal edges. The foam was continuously sutured to the surrounding skin with Dermalon 2-0. The wound was sealed with a transparent adhesive drape.

A Track Pad (KCI) was inserted through the drape and was connected to a vacuum pump, (V.A.C. pump unit, KCI). When the negative pressure is applied, the heart is drawn up towards the phrenic nerve pad and the foam without interfering with the sternal edges. This procedure causes the application of negative pressure to affect only the myocardium exposed by the 5 cm diameter hole.

#### Experimental Protocol

The microvascular blood flow was measured continuously by the laser Doppler filament probes. Recordings were made in normal myocardium before a  $-50$  mm Hg pressure was applied and immediately after the negative pressure was turned off.

The LAD was occluded for 20 minutes with an elastic vessel loop. Microvascular blood flow was then measured before and after 1, 5, 10, 15, and 20 minutes of occlusion. A negative pressure of  $-50$  mm Hg was then applied to the heart, and microvascular blood flow changes were recorded. The negative pressure was then removed.

The LAD occlusion was released and microvascular blood flow was measured before and after 1, 5, 10, 15, and 20 minutes of reperfusion. A negative pressure of  $-50$  mm Hg was then applied to the heart, and microvascular blood flow changes were measured. The negative pressure was then removed.

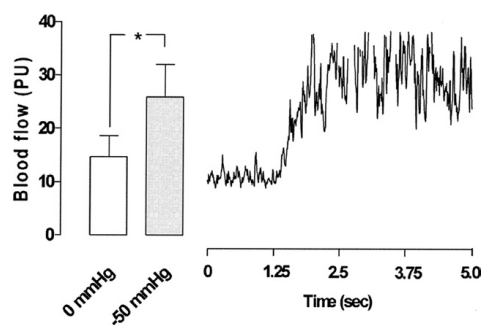


Fig 2. Microvascular blood flow measured in normal myocardium using laser Doppler velocimetry. The measurements were performed at a depth at 6 to 8 mm in the myocardium in 6 pigs, with a topical negative pressure of  $-50$  mm Hg (grey bar) compared with no negative pressure (open bar). The results are shown in blood flow perfusion units (PU) as mean values  $\pm$  standard error of the mean ( $*p < 0.05$ ). The right panel shows a representative example of microvascular blood flow changes after the application of  $-50$  mm Hg topical negative pressure before left anterior descending artery occlusion (normal myocardium). Note the immediate blood flow response when the negative pressure is applied.

#### Calculations and Statistics

Laser Doppler velocimetry measurements were performed on 6 pigs. The output was continuously recorded using PeriSoft software (Perimed, Stockholm, Sweden). Microvascular blood flow was expressed in terms of perfusion units (PU). Calculations and statistical analysis were performed using GraphPad 4.0 software (GraphPad Software, San Diego, CA). Statistical analysis was per-

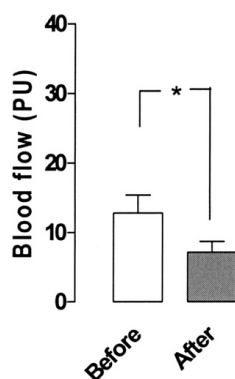


Fig 3. Microvascular blood flow measured using laser Doppler velocimetry in the myocardium before and after 20 minutes of left anterior descending artery (LAD) occlusion. Note the significant decrease from  $12.8 \pm 2.6$  perfusion units (PU) to  $7.2 \pm 1.5$  PU in microvascular blood flow in the area after LAD occlusion. The results are shown as mean values  $\pm$  standard error of the mean ( $*p < 0.05$ ).

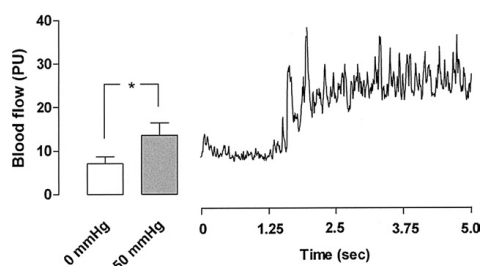


Fig 4. Microvascular blood flow measured during occlusion using laser Doppler velocimetry in ischemic myocardium. The measurements were performed at a depth at 6 to 8 mm in the myocardium in 6 pigs, with a topical negative pressure of  $-50$  mm Hg (grey bar) compared with 0 pressure (open bar). In the left pane, the results in blood flow perfusion units (PU) are shown as mean values  $\pm$  standard error of the mean ( $*p < 0.05$ ). The right panel shows a representative example of microvascular blood flow changes after the application of  $-50$  mm Hg topical negative pressure after 20 minutes of left anterior descending artery occlusion (ischemic myocardium). Note the immediate blood flow response when the negative pressure is applied.

formed using Student paired *t* test. Significance was defined as  $p < 0.05$ . Values are presented as means  $\pm$  the standard error of the mean.

#### Results

##### Normal Myocardium

A topical negative pressure of  $-50$  mm Hg induced an immediate significant increase in microvascular blood flow in normal myocardium from  $14.7 \pm 3.9$  PU before to  $25.8 \pm 6.1$  PU after TNP application ( $p < 0.05$ ; Fig 2). When the vacuum pump was switched off, the blood flow returned to baseline values of  $13.3 \pm 2.4$  PU.

##### Ischemic Myocardium

Ischemia was induced by occlusion of the LAD for 20 minutes. The myocardium distal to the occlusion turned blue, indicating that ischemia of the myocardium had been established. The blood flow was  $12.8 \pm 2.6$  PU before occlusion of the LAD and decreased to  $7.2 \pm 1.5$  PU ( $p < 0.01$ ) after 20 minutes of LAD occlusion (Fig 3). Upon application of a topical negative pressure of  $-50$  mm Hg, an immediate significant increase in blood flow was seen in the ischemic myocardium from  $7.2 \pm 1.5$  PU before to  $13.8 \pm 2.6$  PU after TNP application ( $p < 0.05$ ; Fig 4).

##### Reperfused Myocardium

The LAD occlusion was then released and the blue ischemic myocardium turned red, indicating reperfusion. After 20 minutes of reperfusion, the application of  $-50$  mm Hg induced an immediate significant increase in blood flow from  $10.8 \pm 2.0$  PU before to  $19.3 \pm 5.6$  PU after TNP application ( $p < 0.05$ ; Fig 5).

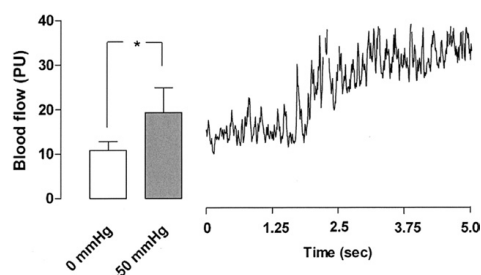


Fig 5. Microvascular blood flow measured using laser Doppler velocimetry in ischemic myocardium during reperfusion. The measurements were performed at a depth at 6 to 8 mm in the myocardium in 6 pigs with a topical negative pressure of  $-50$  mm Hg (grey bar) compared with  $0$  pressure (open bar). In the left panel, the results in perfusion units (PU) are shown as mean values  $\pm$  standard error of the mean ( $*p < 0.05$ ). The right panel shows a representative example of microvascular blood flow changes after application of  $-50$  mm Hg topical negative pressure after 20 minutes of LAD occlusion, followed by 20 minutes of reperfusion (reperfused myocardium). Note the immediate blood flow response when negative pressure is applied.

#### Comment

Among patients with ischemic heart disease, it is of great importance to improve the microvascular blood flow in the myocardium during episodes of ischemia to protect the myocardium from infarction. Today, many different drugs and sophisticated techniques such as PCI and CABG are used with remarkable results [19]. Despite this, there is a large group of patients who have been heavily treated with different drugs (leading to drug-resistant angina pectoris) who have already undergone one or more PCIs or CABG, or both, and who still have serious ischemic heart disease, also called refractory angina pectoris. Among the many different therapies that have been tried [17] are percutaneous myocardial laser revascularization [13, 14] and enhanced external counterpulsation [15, 16], with varying results. A satisfactory mode of treatment for these patients has yet to be found.

Poststernotomy mediastinitis is a rare but serious and potentially lethal complication after cardiac surgery. Conventional treatment involves surgical revision with open dressings, closed irrigation, or reconstruction with vascularized soft tissue flaps, such as omentum or pectoral muscle. Recently, TNP has become the therapy of choice for mediastinitis because of the excellent clinical outcome [5]. TNP involves subatmospheric pressure application over the wound by controlled suction through a porous dressing.

Despite the extensive clinical use and excellent outcome of TNP in wound therapy, the fundamental scientific mechanism is, to a large extent, unknown. One of the known effects of TNP is enhanced blood flow to the wound edge, as has been shown in a sternotomy wound model [7]. TNP increases blood flow velocity and opens up the capillary beds [6, 10]. Mechanical forces exerted by

TNP and increased blood flow affect the cytoskeleton in the vascular cells and stimulate granulation tissue formation, which involves endothelial proliferation, capillary budding, and angiogenesis [12].

In the present study, we hypothesized that the application of TNP on the surface of the heart would stimulate microvascular blood flow in the myocardium, as seen in skeletal muscle during TNP. Indeed, we have observed that patients with poststernotomy mediastinitis treated with TNP develop a thick layer of well-vascularized granulation tissue on the exposed surface of the heart.

Mediastinitis is a strong predictor of poor long-term survival after CABG [20–25], and it has been suggested that mediastinitis may cause negative, long-term effects on several organs, such as the heart and kidneys. Of interest was a recently published study that showed no difference in long-term survival between isolated CABG patients with TNP-treated mediastinitis and CABG patients without mediastinitis [26]. Because the topical negative pressure is in direct contact with the heart, which is exposed through the diastase of the sternotomy in patients with poststernotomy mediastinitis during TNP, increased coronary collateral blood vessels may have developed during TNP and these patients might therefore be better prepared when bypass grafts fail to work.

The present study provides interesting new information on how topically applied negative pressure may improve microvascular blood flow in the myocardium. When the area of the myocardium studied was exposed to a topical negative pressure of  $-50$  mm Hg, an immediate significant increase in microvascular blood flow was observed. This is in accordance with previous results showing increased microvascular blood flow of the skeletal muscle upon application of TNP [7, 8, 27].

To investigate whether similar results could be obtained in an ischemic model, the LAD was occluded for 20 minutes. It is commonly accepted that 20 minutes of LAD occlusion establishes ischemia in the myocardium. When the ischemic area of the myocardium was exposed to a topical negative pressure of  $-50$  mm Hg, an immediate significant increase in microvascular blood flow was detected. Furthermore, after 20 minutes of reperfusion, myocardial blood flow significantly increased when  $-50$  mm Hg was applied.

Increasing blood flow to the myocardium is the aim of any form of treatment of ischemic heart disease. For most patients, commonly used interventions such as PCI and CABG are successful. In patients with refractory angina pectoris, no satisfactory therapy yet exists. TNP stimulation of myocardial blood flow may be a possible therapeutic intervention. It is believed that the sheering forces exerted by TNP stimulate angiogenesis [8, 11, 12, 28]. We have indeed observed in patients treated with TNP that richly vascularized granulation tissue develops over the heart within 4 to 5 days. These newly formed blood vessels may provide collateral blood supply that is needed when the native circulation fails to provide sufficient blood flow. It may be that the TNP stimulation of blood flow and development of collateral blood vessels in

part accounts for the reduced long-term mortality in patients treated with TNP for poststernotomy mediastinitis after CABG [5, 26].

A negative pressure of -50 mm Hg was used in the present study. Blood flow stimulation by TNP has been found to be a function of tissue density, the negative pressure applied, and the distance from the wound edge [7, 28]. The most commonly used negative pressures of -75 mm Hg and -125 mm Hg stimulate blood flow to a depth of 25 mm in the skeletal muscle, whereas lower negative pressures such as -50 mm Hg stimulate blood flow closer to the surface [7]. The laser Doppler probes were placed at a depth of approximately 6 to 8 mm. To stimulate blood flow this close to the surface of the tissue, the lower negative pressure of -50 mm Hg was used.

CPB was used to minimize movement artifacts while measuring blood flow in the myocardium using laser Doppler technology. The effect of TNP on the beating heart can not be deduced from the present results, although we believe that the effect would be similar to that observed here. Furthermore, CPB facilitated the intervention because arrhythmia and circulatory failure were avoided during the induction of ischemia and reperfusion.

In this study, we applied TNP to the myocardium and showed that a topical negative pressure of -50 mm Hg causes a significant increase in microvascular blood flow, not only in normal and ischemic myocardium but also in ischemic myocardium during reperfusion. TNP may thus constitute an alternative therapeutic intervention to stimulate blood flow in the failing myocardium in patients with refractory angina pectoris. Extended preclinical trials and clinical studies on humans will be required before any clinical recommendations can be made.

We would like to thank Johan Ingemansson and Kristoffer Peters (Statistical Solutions IP) for their expert contribution to the statistic analyses. This study was supported by Anders Otto Swärd's Foundation/Ulrika Eklund's Foundation, Anna Lisa and Sven Eric Lundgren's Foundation for medical research, the Åke Wiberg Foundation, the M. Bergvall Foundation, the Swedish Medical Association, the Royal Physiographic Society in Lund, the Swedish Medical Research Council, the Crafoord Foundation, the Swedish Heart-Lung Foundation, the Swedish Government Grant for Clinical Research, and the Swedish Hypertension Society.

## References

1. Armstrong DG, Lavery LA. Negative pressure wound therapy after partial diabetic foot amputation: a multicentre, randomised controlled trial. *Lancet* 2005;366:1704-10.
2. Banwell PE. Topical negative pressure wound therapy: advances in burn wound management. *Ostomy Wound Manage* 2004;50:9S-14S.
3. Gustafsson RI, Sjogren J, Ingemansson R. Deep sternal wound infection: a sternal-sparing technique with vacuum-assisted closure therapy. *Ann Thorac Surg* 2003;76:2048-53; discussion 2053.
4. Domkowski PW, Smith ML, Gonyon DL Jr, et al. Evaluation of vacuum-assisted closure in the treatment of post-sternotomy mediastinitis. *J Thorac Cardiovasc Surg* 2003;126:386-90.
5. Sjogren J, Gustafsson R, Nilsson J, Malmso M, Ingemansson R. Clinical outcome after poststernotomy mediastinitis: vacuum-assisted closure versus conventional treatment. *Ann Thorac Surg* 2005;79:2049-55.
6. Morykwas MJ, Argenta LC, Shelton-Brown EI, McGuirt W. Vacuum-assisted closure: a new method for wound control and treatment: animal studies and basic foundation. *Ann Plast Surg* 1997;38:553-62.
7. Wackenfors A, Gustafsson R, Sjogren J, Algotsson L, Ingemansson R, Malmso M. Blood flow responses in the peristernal thoracic wall during vacuum-assisted closure therapy. *Ann Thorac Surg* 2005;79:1724-30; discussion 1730-1.
8. Petzina R, Gustafsson L, Mokhtari A, Ingemansson R, Malmso M. Effect of vacuum-assisted closure on blood flow in the peristernal thoracic wall after internal mammary artery harvesting. *Eur J Cardiothorac Surg* 2006;30:85-9.
9. Fabian TS, Kaufman HJ, Lett ED, et al. The evaluation of subatmospheric pressure and hyperbaric oxygen in ischemic full-thickness wound healing. *Am Surg* 2000;66:1136-43.
10. Fleck TM, Fleck M, Moidl R, et al. The vacuum-assisted closure system for the treatment of deep sternal wound infections after cardiac surgery. *Ann Thorac Surg* 2002;74:1596-600; discussion 1600.
11. Chen SZ, Li J, Li XY, Xu LS. Effects of vacuum-assisted closure on wound microcirculation: an experimental study. *Asian J Surg* 2005;28:211-7.
12. Vandenberg HH. Mechanical forces and their second messengers in stimulating cell growth in vitro. *Am J Physiol* 1992;262:R350-5.
13. Leon MB, Kornowski R, Downey WE, et al. A blinded, randomized, placebo-controlled trial of percutaneous laser myocardial revascularization to improve angina symptoms in patients with severe coronary disease. *J Am Coll Cardiol* 2005;46:1812-9.
14. Salem M, Rotevatn S, Nordrehaug JE. Long-term results following percutaneous myocardial laser therapy. *Coron Artery Dis* 2006;17:385-90.
15. Yu W, Pettersson T, Ohlsson O, Bondesson S, Edvinsson L, Johnsson P. [EECP—new treatment in refractory angina. Clinical trials show good results]. *Lakartidningen* 2006;103:1930, 1933-4.
16. Pettersson T, Bondesson S, Cojocaru D, Ohlsson O, Wackenfors A, Edvinsson L. One year follow-up of patients with refractory angina pectoris treated with enhanced external counterpulsation. *BMC Cardiovasc Disord* 2006;6:28.
17. Gowda RM, Khan IA, Punukollu G, Vasavada BC, Nair CK. Treatment of refractory angina pectoris. *Int J Cardiol* 2005;101:1-7.
18. Zografos GC, Martis K, Morris DL. Laser Doppler flowmetry in evaluation of cutaneous wound blood flow using various suturing techniques. *Ann Surg* 1992;215:266-8.
19. Moustapha A, Anderson HV. Revascularization interventions for ischemic heart disease. *Curr Opin Cardiol* 2000;15:463-71.
20. Lu JC, Grayson AD, Jha P, Srinivasan AK, Fabri BM. Risk factors for sternal wound infection and mid-term survival following coronary artery bypass surgery. *Eur J Cardiothorac Surg* 2003;23:943-9.
21. Braxton JH, Marrin CA, McGrath PD, et al. Mediastinitis and long-term survival after coronary artery bypass graft surgery. *Ann Thorac Surg* 2000;70:2004-7.
22. Loop FD, Lytle BW, Cosgrove DM, et al. J. Maxwell Chamberlain memorial paper. Sternal wound complications after isolated coronary artery bypass grafting: early and late mortality, morbidity, and cost of care. *Ann Thorac Surg* 1990;49:179-86; discussion 186-7.
23. Milano CA, Kesler K, Archibald N, Sexton DJ, Jones RH. Mediastinitis after coronary artery bypass graft surgery. Risk factors and long-term survival. *Circulation* 1995;92:2245-51.



24. Toumpoulis IK, Anagnostopoulos CE, Derose JJ Jr, Swistel DG. The impact of deep sternal wound infection on long-term survival after coronary artery bypass grafting. *Chest* 2005;127:464–71.
25. Stahle E, Tammelin A, Bergstrom R, Hambreus A, Nystrom SO, Hansson HE. Sternal wound complications—incidence, microbiology and risk factors. *Eur J Cardiothorac Surg* 1997;11:1146–53.
26. Sjogren J, Nilsson J, Gustafsson R, Malmso M, Ingemansson R. The impact of vacuum-assisted closure on long-term survival after post-sternotomy mediastinitis. *Ann Thorac Surg* 2005;80:1270–5.
27. Wackenfors A, Sjogren J, Gustafsson R, Algotsson L, Ingemansson R, Malmso M. Effects of vacuum-assisted closure therapy on inguinal wound edge microvascular blood flow. *Wound Repair Regen* 2004;12:600–6.
28. Wackenfors A, Sjogren J, Algotsson L, Gustafsson R, Ingemansson R, Malmso M. The effect of vacuum-assisted closure therapy on the pig femoral artery vasomotor responses. *Wound Repair Regen* 2004;12:244–51.

# INVITED COMMENTARY

Patients with severe diffuse coronary artery disease and refractory angina who can not be treated with conventional coronary artery bypass graft surgery or angioplasty represent a clinical challenge due to the absence of proven effective alternative treatments. Therapies such as transmyocardial laser and cardiac denervation have not had the expected results, and our own group demonstrated that although these two treatment modalities can induce angina relief in the short-term, their efficacy was limited (eg, most patients remained with some degree of angina) and their efficacy was also transient (eg, the benefit was partly lost by 42-month follow-up), and this is not associated with detectable improvement in myocardial perfusion as assessed by magnetic resonance imaging [1]. Our group has also found that myocardial revascularization by arterialization of the coronary venous system (eg, grafts connected to the venous system) do not endure [2].

A great variety of angiogenic factors administered in the form of proteins or genes can induce angiogenesis and the growth of collateral arteries leading to an improvement in regional blood flow and the preservation of tissue. However, despite promising laboratory outcomes, the preliminary clinical studies carried out to date have not shown a clear benefit and the real clinical potential of angiogenic factors remains unresolved. More recently the potential of stem cells to differentiate into practically any cell type have been realized and a number of cells have been used in myocardial repair to improve blood flow. There is no doubt that the use of stem cells and genetic modifications have opened up new horizons in angiogenic therapy, but the field is still in its infancy and much more investigation will be required before a wider clinical use is considered.

Lindstedt and co-authors [3] report that the application of negative pressure to the surface of the pig heart increases myocardial blood flow in the normal, ischemic, and reperfused myocardium, and conclude that it may represent a new approach to treat ischemic myocardium. The usefulness of negative pressure for wound healing, including post-sternotomy mediastinitis, is well recognized. A potential mechanism for the beneficial effect of negative pressure may be the stimulation of blood flow that is supported by the findings of Lindstedt and colleagues' [3] study. However it should be noted that in this study there is a methodological problem that the anterior

descending coronary artery was occluded, and the flow changes were assessed in the anterior wall of the right ventricle rather than in the left ventricle. This means that although the reported increase in myocardial blood flow in the normal muscle can be real, the flow changes in the ischemic myocardium need to be confirmed by appropriately designed experiments.

The concept that topical application of negative pressure to the myocardium can be used for increasing the blood flow to ischemic areas of the heart is worth exploring, and if proven to be effective, this may become a valuable therapy to control refractory angina in patients that can not receive conventional revascularization procedures. It can even be argued that the treatment could be useful as an adjuvant to conventional revascularization when complete revascularization can not be achieved. However, before topical negative pressure is considered for clinical use, it would require the demonstration that any increase in blood flow to ischemic myocardium is sufficient to support normal metabolism and function of the affected heart muscle. Furthermore, the application of such a technology would need the design and development of devices that could be selectively applied to the chosen myocardial areas without impairment of the cardiac function.

Manuel Galiñanes, MD, PhD

Cardiac Surgery Group  
Department of Cardiovascular Sciences  
University of Leicester  
Glenfield Hospital  
Groby Rd  
Leicester, LE3 9QP United Kingdom  
e-mail: mg50@le.ac.uk

# References

1. Galiñanes M, Loubani M, Sensky PR, et al. Efficacy of transmyocardial laser revascularization and thoracic sympathectomy for the treatment of refractory angina. *Ann Thorac Surg* 2004;78:122–8.
2. Chowdhry MF, Davies J, McCance A, Galiñanes M. Lack of durability of surgical arterialization of coronary veins for the treatment of ischemic heart disease. *J Card Surg* 2005;20:1–3.
3. Lindstedt S, Malmjö M, Ingemansson R. Blood flow changes in normal and ischemic myocardium during topically applied negative pressure. *Ann Thorac Surg* 2007;84:568–73.







## Impact of different topical negative pressure levels on myocardial microvascular blood flow<sup>☆</sup>

Sandra Lindstedt<sup>a,\*</sup>, Malin Malmjö<sup>b</sup>, Johan Sjögren<sup>a</sup>,  
Ronny Gustafsson<sup>a</sup>, Richard Ingemansson<sup>a</sup>

<sup>a</sup>Department of Cardiothoracic Surgery, Lund University Hospital, Lund, Sweden

<sup>b</sup>Department of Medicine, Lund University Hospital, Lund, Sweden

Received 23 July 2007; received in revised form 17 September 2007; accepted 18 September 2007

### Abstract

**Background:** We have previously shown that a myocardial topical negative pressure (TNP) of –50 mmHg significantly increases microvascular blood flow in the underlying myocardium in normal, ischemic, and reperfused porcine myocardium. The present study was designed to elucidate the effect of different TNP levels between –50 and –150 mmHg on microvascular flow in normal and ischemic myocardium.

**Materials and methods:** Seven pigs underwent median sternotomy. The microvascular blood flow in the myocardium was recorded, before and after the application of TNP, using laser Doppler velocimetry. Analyses were performed before left anterior descending artery (LAD) occlusion (normal myocardium) and after 20 min of LAD occlusion (ischemic myocardium).

**Results:** A TNP of –50 mmHg significantly increased microvascular blood flow in both normal (from 320.0±56.1 PU before TNP application to 435.7±65.5 PU after TNP application,  $P=.028$ ) and ischemic myocardium (from 110.0±36.7 PU before TNP application to 194.3±56.2 PU after TNP application,  $P=.012$ ). TNP between –75 and –150 mmHg showed no significant increase in microvascular blood flow in normal or ischemic myocardium.

**Conclusions:** Of pressures between –50 and –150 mmHg, a TNP of –50 mmHg seems to be the most effective negative pressure concerning significant increase in microvascular blood flow in both normal and ischemic myocardium.

© 2008 Elsevier Inc. All rights reserved.

### Keywords:

TNP; Microvascular blood flow; Ischemia; Revascularization

### 1. Introduction

Topical negative pressure (TNP) has been shown to facilitate the healing of chronic and problematic wounds [1,2] including diabetic wounds [3] and poststernotomy mediastinitis [4–7]. The physiological and molecular biological mechanisms by which TNP promotes wound healing are, to a large extent, unknown. However, one of the mechanisms by which TNP promotes wound healing is by stimulating wound edge blood flow, which has been shown in both peripheral [8] and skeletal muscle in sternotomy wounds [9]. TNP produces a mechanical stress and a

<sup>☆</sup> This study was supported by the Anders Otto Swärd Foundation/ Ulrika Eklund Foundation, Anna Lisa and Sven Eric Lundgren's Foundation for Medical Research, the Åke Wiberg Foundation, the M. Bergvall Foundation, the Swedish Medical Association, the Royal Physiographic Society in Lund, the Swedish Medical Research Council, the Crafoord Foundation, the Swedish Heart–Lung Foundation, the Swedish government grant for clinical research, and the Swedish Hypertension Society.

\* Corresponding author. Department of Cardiothoracic Surgery, Heart and Lung Centre, Lund University Hospital, SE-221 85 Lund, Sweden. Tel.: +46 46 173803; fax: +46 46 158635.

E-mail address: sandra.lindstedt@skane.se (S. Lindstedt).

pressure gradient across the tissue, which may cause a surge of blood to the area. Mechanical forces and increased blood flow are known to stimulate granulation tissue formation, that is, endothelial proliferation, capillary budding, and angiogenesis, or secondary new vessel formation [10–12].

The majority of patients who require intervention for coronary artery disease are adequately treated by percutaneous coronary intervention (PCI) or coronary artery bypass grafting (CABG). However, a major reason for failure of these treatments is their dependency on luminal size and coronary outflow. Methods of stimulating myocardial neovascularization that are not dependent on vessel caliber therefore provide an important alternative treatment. Numerous studies have evaluated the efficacy of gene therapy in the treatment of ischemic heart disease for the restoration of myocardial function by stimulation of angiogenesis and collateral vessel formation [13–17].

TNP is known to stimulate blood flow in tissues [1], such as the skeletal muscle [9,18]. We have earlier shown that a TNP of  $-50$  mmHg significantly increases microvascular blood flow in the underlying tissue, in both normal and ischemic myocardium [19]. No study has been performed to examine the effects of different negative pressure levels on microvascular blood flow in the myocardium. The aim of the study was to elucidate the optimal negative pressure level for the heart muscle that would induce maximal increase in myocardial microvascular blood flow. In this study, blood flow was measured using laser Doppler velocimetry in a porcine model. The effect of different TNPs, between  $-50$  and  $-150$  mmHg, on microvascular blood flow was investigated in the myocardium before and during occlusion of the left anterior descending artery (LAD) to imitate ischemic coronary disease.

## 2. Materials and methods

### 2.1. Experimental animals

A porcine model was used for the present study. Seven domestic Landrace pigs of both genders, with a mean body weight of 70 kg, were fasted overnight with free access to water. The Ethics Committee for Animal Research, Lund University, Sweden, approved the study. The investigation complied with the *Guide for the Care and Use of Laboratory Animals* as recommended by the U.S. National Institutes of Health and published by the National Academies Press (1996).

### 2.2. Anesthesia

All the animals were premedicated intramuscularly with ketamine (30 mg/kg) before they were brought into the laboratory. Before commencing surgery, sodium thiopental (5 mg/kg), atropine (0.02 mg/kg), and pancuronium (0.5 mg/kg) were given intravenously. Tracheotomy was

performed with a Portex endotracheal tube (7.5 mm internal diameter, Medcompare, USA). A Servo ventilator (Siemens Elema 300A, Stockholm, Sweden) was used for mechanical ventilation throughout the experiment. The ventilator settings used were the following: minute volume=100 ml/kg,  $\text{FiO}_2=0.5$ , breathing frequency=16 breaths/min, and positive end expiratory pressure=5 cm  $\text{H}_2\text{O}$ .

Anesthesia and muscular paralysis were maintained by continuous intravenous infusion of Diprivan (propofol, AstraZeneca, Sweden) 8–10 mg/kg/h, Leptanal 0.15 mg/kg/h (fentanyl, Lilly, France), and Pavulon 0.6 mg/kg/h (pancuronium, Organon Teknika, Boxtel, the Netherlands).

### 2.3. Data acquisition

Mean arterial pressure, central venous pressure, body temperature, and ventilatory parameters were recorded throughout the experiments.

### 2.4. Surgical procedure

Surgery was performed through median sternotomy. After heparinization (400 IU/kg), a cardiopulmonary bypass (CPB) was installed with an arterial cannula (22 French, DLP Elongated One-Piece Arterial Cannula, Medtronic Inc., Minneapolis, MN, USA) in the distal ascending aorta and a venous cannula (32 French, MC2 Two-Stage Venous Cannula, Medtronic Inc.) inserted through the right atrium. Before cannulation of the heart, the cannulae were inserted through the thoracic wall to prevent air leakage during TNP application. CPB was conducted in normothermia. Ventricular fibrillation was subsequently induced in the heart. No aortic cross clamping was performed, and no cardioplegia was employed. The mean arterial pressure was maintained between 60 and 80 mmHg. A left ventricular vent (DLP Vent, Medtronic Inc.) was used to protect the left chamber from overloading. Pulmonary ventilation was applied at 4 l/min during the experiments.

CPB was used to facilitate the measurement of microvascular blood flow using laser Doppler velocimetry. Fibrillation of the heart minimizes the movement artifacts, while the physiological conditions are, to a large extent, conserved. Moreover, CPB prevents the risk of circulatory failure during LAD occlusion, thereby facilitating experimental analysis in the ischemic myocardium.

Microvascular blood flow was measured by laser Doppler velocimetry (Peri Flux System 5000, Perimed, Stockholm, Sweden), using a technique that quantifies the sum of the motion of the red blood cells in a specific volume, extensively applied in plastic surgery procedures [20]. In this method, a fiber-optic probe carries a beam of light. Light impinging on cells in motion undergoes a change in wavelength (Doppler shift), while light impinging on static objects remains unchanged. The magnitude and frequency distribution of the changes are directly related to the number and velocity of red blood cells. The information

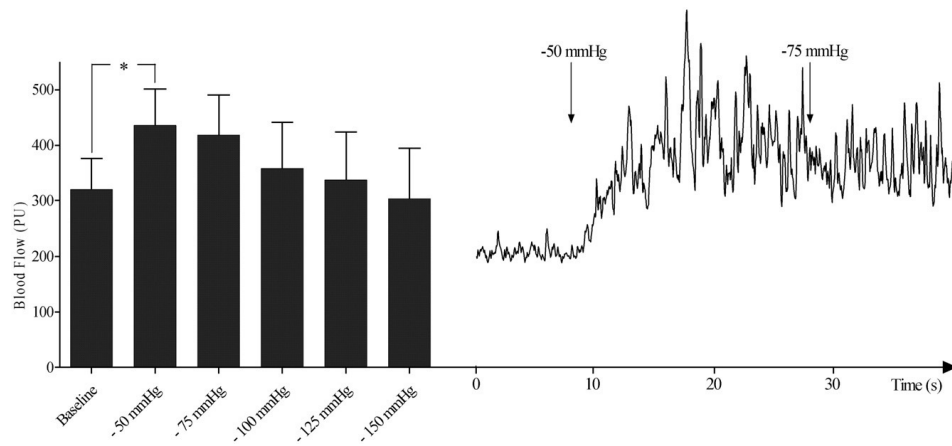


Fig. 1. Microvascular blood flow measured using laser Doppler velocimetry in ischemic myocardium exposed to TNPs of  $-50$ ,  $-75$ ,  $-100$ ,  $-125$ , and  $-150$  mmHg. The measurements were performed at a depth of 6–8 mm in the myocardium in seven pigs. In the left panel, the results are shown as mean $\pm$ S.E.M. A level of  $*P<0.05$  was considered statistically significant. The right panel shows a representative example of the change in microvascular blood flow after the application of  $-50$  and  $-75$  mmHg TNPs in normal myocardium.

is collected by a returning fiber, converted into an electronic signal and analyzed.

Laser Doppler probes were inserted horizontally into the heart muscle 6–8 mm lateral of the LAD at depths of approximately 6–8 mm. The mean thickness of the chamber wall was approximately 20–25 mm. All probes were carefully fixed to the surface of the heart with a suture (Prolene 7-0; Ethicon Inc., Somerville, NJ, USA), thereby preventing the probe from sliding. A round hole with a diameter of 5 cm was made in the middle of a phrenic nerve pad (Phrenic Nerve Pad, Medtronic Inc.) and placed on top of the heart. The pad was stabilized to the surrounding myocardium with 8–10 sutures (Prolene 5-0; Ethicon Inc.) and to the posterior sternal edges with sutures (Dermalon 2-0; Davis and Geck, St. Louis, MO, USA). A retractor was used throughout the experiments to keep the sternal edges apart. A polyurethane foam dressing, with an open pore structure of 400 to 600  $\mu$ m (KCI, Copenhagen, Denmark), was placed between the sternal edges. The foam was continuously sutured to the surrounding skin (Dermalon 2-0; Davis and Geck). The wound was sealed with a transparent adhesive drape. A track pad (KCI) was inserted through the drape and was connected to a continuous vacuum source (V.A.C. pump unit, KCI). When the negative pressure is applied, the heart will be drawn up toward the phrenic nerve pad and the foam without interfering with the sternal edges. This procedure causes the application of negative pressure to affect only the myocardium exposed by the 5-cm-diameter hole. After the experiment, the heart was dissected to confirm probe location.

## 2.5. Experimental protocol

The microvascular blood flow was measured continuously by the laser Doppler filament probes. Recordings were made in normal myocardium, before negative pressure was applied, at negative pressures of  $-50$ ,  $-75$ ,  $-100$ ,  $-125$ , and  $-150$  mmHg.

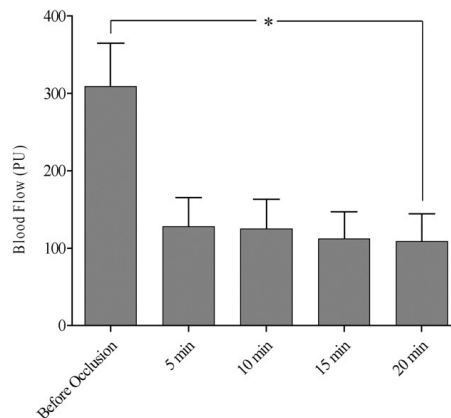


Fig. 2. Microvascular blood flow measured using laser Doppler velocimetry in the myocardium before and after 5, 10, 15, and 20 min of occlusion of the LAD. Note the decrease in microvascular blood flow, from  $308.6\pm56.5$  PU before occlusion of the LAD to  $108.6\pm35.5$  PU after 20 min occlusion of the LAD, in the area studied. The results are shown as mean $\pm$ S.E.M. A level of  $*P<0.05$  was considered statistically significant.

The LAD was then occluded for 20 min with an elastic vessel loop. Microvascular blood flow was measured before and after 5, 10, 15 and 20 min of occlusion.

Moreover, recordings were made in ischemic myocardium, before negative pressure was applied, at negative pressures of  $-50$ ,  $-75$ ,  $-100$ ,  $-125$ , and  $-150$  mmHg.

### 2.6. Calculation and statistics

Laser Doppler velocimetry measurements were performed on seven pigs. The output was continuously recorded using PeriSoft software (Perimed, Stockholm, Sweden). Microvascular blood flow was expressed in terms of perfusion units (PU). A repeated measurement general linear model was used to test the main effect of treatment and subject on normal myocardium and ischemic myocardium. Post hoc testing of the treatment was performed using Dunnett's test with a control (baseline/no treatment/0 mmHg). Analysis of the residuals of the model was also performed to check for model adequacy. Anderson–Darling's test was carried out to evaluate the assumption of normality, and Levene's test for heteroscedasticity was used to verify that the assumption of constant residual variance was justified. A level of  $P < 0.05$  was considered statistically significant.

## 3. Results

### 3.1. Normal myocardium

A TNP of  $-50$  mmHg induced an immediate significant increase in microvascular blood flow in normal myocardium

(from  $320.0 \pm 56.1$  PU before TNP application to  $435.7 \pm 65.5$  PU after TNP application,  $P = .028$ ). A TNP of  $-75$  mmHg resulted in an increase in microvascular blood flow (from  $320.0 \pm 56.1$  PU before TNP application to  $418.6 \pm 72.7$  PU after TNP application,  $P = .090$ ). However, the increase in microvascular blood flow was lower than the blood flow induced at  $-50$  mmHg. TNPs between  $-100$  and  $-150$  mmHg induced an immediate decrease in microvascular blood flow in normal myocardium compared to that at  $-50$  mmHg (Fig. 1).

### 3.2. LAD occlusion

Ischemia was induced by occlusion of the LAD for 20 min. The blood flow was  $308.6 \pm 56.5$  PU before occlusion of the LAD and decreased to  $108.6 \pm 35.5$  PU after 20 min of LAD occlusion ( $P = .022$ ; Fig. 2).

### 3.3. Ischemic myocardium

Upon application of a TNP of  $-50$  mmHg, an immediate significant increase in microvascular blood flow was seen in the ischemic myocardium (from  $110.0 \pm 36.7$  PU before TNP application to  $194.3 \pm 56.2$  PU after TNP application,  $P = .012$ ). A TNP of  $-75$  mmHg resulted in an increase in microvascular blood flow (from  $110.0 \pm 36.7$  PU before TNP application to  $138.6 \pm 38.9$  PU after TNP application,  $P = .571$ ). TNPs between  $-100$  and  $-150$  mmHg induced an immediate decrease in microvascular blood flow in ischemic myocardium compared to that at  $-50$  mmHg (Fig. 3).

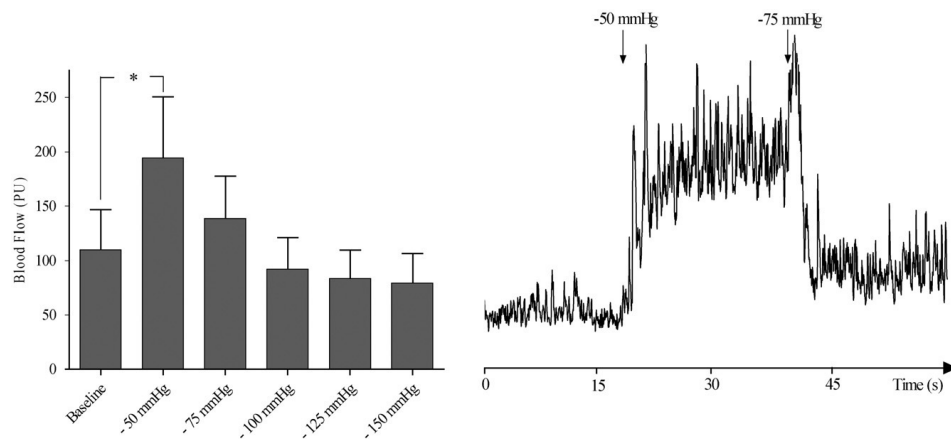


Fig. 3. Microvascular blood flow measured using laser Doppler velocimetry in ischemic myocardium exposed to TNPs of  $-50$ ,  $-75$ ,  $-100$ ,  $-125$ , and  $-150$  mmHg. The measurements were performed at a depth of 6–8 mm in the myocardium in seven pigs. In the left panel, the results are shown as mean  $\pm$  S.E.M. A level of  $*P < 0.05$  was considered statistically significant. The right panel shows a representative example of the change in microvascular blood flow after the application of  $-50$  and  $-75$  mmHg TNPs after 20 min of occlusion of the LAD (ischemic myocardium). Note the immediate increase in blood flow when the negative pressure of  $-50$  mmHg is applied and the immediate decrease when  $-75$  mmHg is applied.

#### 4. Discussion

We have earlier shown that a TNP of  $-50$  mmHg significantly increases microvascular blood flow in the underlying tissue, in both normal and ischemic myocardium [19]. Applying different negative pressures to skeletal muscle causes different changes in blood flow [9]. When the negative pressure exceeds a specific level, it seems to constrict the vessels in the skeletal muscle and a decrease in local blood flow is seen [9,21]. In the treatment of poststernotomy mediastinitis with TNP, pressures between  $-75$  and  $-125$  mmHg have been shown to provide optimal conditions for healing. The application of different TNPs directly on the myocardium has not, to our knowledge, been attempted previously. Our intention is to create a new mode of treatment for ischemic heart disease in cases where other therapies have failed or are not suitable. It is therefore important to determine the negative pressure that provides maximal blood flow in the heart muscle while avoiding negative side effects. To minimize movement artifacts while measuring blood flow in the myocardium using laser Doppler technology, we used CPB. The effect of TNP on the beating heart cannot be deduced from the present results, although we believe that the effect would be similar to that observed here. Furthermore, CPB facilitated the intervention since arrhythmia and circulatory failure were avoided during the induction of ischemia.

In the present study, we have shown that a TNP of  $-50$  mmHg significantly increases microvascular blood flow in both normal ( $P=.028$ ) and ischemic myocardium ( $P=.012$ ). As seen in a previous study [19], when a negative pressure of  $-75$  mmHg was applied to normal and ischemic myocardium, the microvascular blood flow increased compared to baseline; however, this increase was not significant. In both normal and ischemic myocardium, negative pressures, between  $-100$  and  $-150$  mmHg, led to a decrease in microvascular blood flow, as compared to baseline; this may indicate that those pressures may constrict the vessels, thus reducing the microvascular blood flow to the exposed myocardium (Figs. 1 and 3).

Despite the extensive clinical use and excellent outcome of TNP in wound therapy, the fundamental scientific mechanism is only partly understood. The known effects of TNP are enhanced blood flow to the wound edge and granulation tissue formation [1,2]. TNP increases blood flow velocity and opens up the capillary beds. The mechanical force exerted by TNP and increased blood flow affect the cytoskeleton in the vascular cells, stimulating endothelial proliferation, capillary budding, and angiogenesis, that is, granulation tissue formation [10,11]. TNP has recently been shown to increase angiogenesis and decrease matrix metalloproteinases, both of which promote new vessel formation [12].

In the present study, we hypothesized that the application of TNP to the surface of the heart would stimulate microvascular blood flow in the myocardium, as seen in

skeletal muscle during TNP [9,21]. Indeed, we have observed that patients with poststernotomy mediastinitis treated with TNP develop a thick layer of well-vascularized granulation tissue on the exposed surface of the heart. Mediastinitis is a strong predictor of poor long-term survival after CABG, and it has been suggested that mediastinitis may cause negative, long-term effects on several organs, such as the heart and kidneys [22]. Interestingly, a recently published study showed no difference in long-term survival between isolated CABG patients with TNP-treated mediastinitis and CABG patients without mediastinitis [23]. Since the TNP is in direct contact with the heart, which is exposed through the diastase of the sternotomy, these patients might have developed increased coronary collateral blood vessels during TNP and may therefore be better prepared when bypass grafts fail to work. We have indeed observed, in patients treated with TNP, that richly vascularized granulation tissue develops over the heart within 7–8 days. These newly formed blood vessels may provide collateral blood supply that is needed when the grafts fail to maintain sufficient blood flow. It may well be that the stimulation of blood flow and development of collateral blood vessels by TNP in part account for the reduced long-term mortality in patients treated with TNP for poststernotomy mediastinitis after CABG.

Among patients with chronic ischemic heart disease, it is important to improve the microvascular blood flow in the myocardium during episodes of ischemia to protect the myocardium from infarction. However, a large group of patients suffer from refractory angina pectoris. Conventional treatment such as PCI and CABG has not been successful in these patients. Various other therapies have been tried, such as percutaneous myocardial laser revascularization [24] and enhanced external counterpulsation [25], with varying results. Even spinal cord stimulation has been used in an attempt to ease their ischemic pain [26]. However, a satisfactory means of treating these patients has yet to be found. A new form of treatment resulting in new collateral vessel formation would thus be of interest for these patients.

Recognition of the central role played by angiogenic growth factors in the endogenous process of tissue vascularization has led to the development of therapeutic angiogenesis in which exogenous growth factors are administered to ischemic tissue to enhance the reperfusion of these tissues. Vascular endothelial growth factor (VEGF) proteins have been shown to play a key role in the modulation of angiogenesis and vascular growth [15,27,28]. Moreover, TNP produces a mechanical shear stress that is known to activate VEGF without the need for any exogenous VEGF administration [29–31].

In conclusion, effects of different TNPs on myocardial microvascular blood flow have not previously been studied. In the present study, we have shown that TNP causes a significant increase in microvascular blood flow, not only in normal myocardium but also in ischemic myocardium. Our results also indicate that TNP of  $-50$  mmHg seems to be the

most suitable pressure, as greater negative pressure seems to constrict the vessels and decrease microvascular blood flow. TNP may thus constitute an alternative therapeutic intervention to stimulate blood flow in the failing myocardium in patients with ischemic heart disease. Extended preclinical trials and clinical studies on humans will be required before any clinical recommendations can be made.

## 5. Summary

TNP produces a mechanical shear stress, which is known to increase blood flow and stimulate angiogenesis. A TNP of  $-50$  mmHg significantly increases the microvascular blood flow in normal and ischemic myocardium. This may provide a novel therapeutic tool in the future treatment of ischemic heart disease.

## Acknowledgments

We would like to thank Johan Ingemansson (Statistical Solutions IP) for his expert contribution to the statistic analyses.

## References

- [1] Morykwas MJ, Argenta LC, Shelton-Brown EI, McGuirt W. Vacuum-assisted closure: a new method for wound control and treatment: animal studies and basic foundation. *Ann Plast Surg* 1997;38:553–62.
- [2] Argenta LC, Morykwas MJ. Vacuum-assisted closure: a new method for wound control and treatment: clinical experience. *Ann Plast Surg* 1997;38:563–76 [discussion 577].
- [3] Armstrong DG, Lavery LA. Negative pressure wound therapy after partial diabetic foot amputation: a multicentre, randomised controlled trial. *Lancet* 2005;366:1704–10.
- [4] Domkowski PW, Smith ML, Gonyon DL, Drye C, Wooten MK, Levin LS, et al. Evaluation of vacuum-assisted closure in the treatment of poststernotomy mediastinitis. *J Thorac Cardiovasc Surg* 2003;126:386–90.
- [5] Gustafsson RI, Sjogren J, Ingemansson R. Deep sternal wound infection: a sternal-sparing technique with vacuum-assisted closure therapy. *Ann Thorac Surg* 2003;76:2048–53 [discussion 2053].
- [6] Sjogren J, Gustafsson R, Nilsson J, Malmso M, Ingemansson R. Clinical outcome after poststernotomy mediastinitis: vacuum-assisted closure versus conventional treatment. *Ann Thorac Surg* 2005;79:2049–55.
- [7] Gustafsson R, Johnsson P, Algotsson L, Blomquist S, Ingemansson R. Vacuum-assisted closure therapy guided by C-reactive protein level in patients with deep sternal wound infection. *J Thorac Cardiovasc Surg* 2002;123:895–900.
- [8] Chen SZ, Li J, Li XY, Xu LS. Effects of vacuum-assisted closure on wound microcirculation: an experimental study. *Asian J Surg* 2005;28:211–7.
- [9] Wackenfors A, Sjogren J, Gustafsson R, Algotsson L, Ingemansson R, Malmso M. Effects of vacuum-assisted closure therapy on inguinal wound edge microvascular blood flow. *Wound Repair Regen* 2004;12:600–6.
- [10] Vandenburgh HH. Mechanical forces and their second messengers in stimulating cell growth in vitro. *Am J Physiol* 1992;262:R350–5.
- [11] Saxena V, Hwang CW, Huang S, Eichbaum Q, Ingber D, Orgill DP. Vacuum-assisted closure: microdeformations of wounds and cell proliferation. *Plast Reconstr Surg* 2004;114:1086–96 [discussion 1097–1088].
- [12] Greene AK, Puder M, Roy R, Arsenault D, Kwei S, Moses MA, et al. Microdeformational wound therapy: effects on angiogenesis and matrix metalloproteinases in chronic wounds of 3 debilitated patients. *Ann Plast Surg* 2006;56:418–22.
- [13] Takaba K, Jiang C, Nemoto S, Saji Y, Ikeda T, Urayama S, et al. A combination of omental flap and growth factor therapy induces arteriogenesis and increases myocardial perfusion in chronic myocardial ischemia: evolving concept of biologic coronary artery bypass grafting. *J Thorac Cardiovasc Surg* 2006;132:891–9.
- [14] Sarateanu CS, Retuerto MA, Beckmann JT, McGregor L, Carbray J, Patejunas G, et al. An Egr-1 master switch for arteriogenesis: studies in Egr-1 homozygous negative and wild-type animals. *J Thorac Cardiovasc Surg* 2006;131:138–45.
- [15] Biswas SS, Hughes GC, Scarborough JE, Domkowski PW, Diodato L, Smith ML, et al. Intramyocardial and intracoronary basic fibroblast growth factor in porcine hibernating myocardium: a comparative study. *J Thorac Cardiovasc Surg* 2004;127:34–43.
- [16] Min JY, Chen Y, Malek S, Meissner A, Xiang M, Ke Q, et al. Stem cell therapy in the aging hearts of Fisher 344 rats: synergistic effects on myogenesis and angiogenesis. *J Thorac Cardiovasc Surg* 2005;130:547–53.
- [17] Funatsu T, Sawa Y, Ohtake S, Takahashi T, Matsumiya G, Matsuura N, et al. Therapeutic angiogenesis in the ischemic canine heart induced by myocardial injection of naked complementary DNA plasmid encoding hepatocyte growth factor. *J Thorac Cardiovasc Surg* 2002;124:1099–105.
- [18] Petzina R, Gustafsson L, Mokhtari A, Ingemansson R, Malmso M. Effect of vacuum-assisted closure on blood flow in the peristernal thoracic wall after internal mammary artery harvesting. *Eur J Cardiothorac Surg* 2006;30:85–9.
- [19] Lindstedt S, Malmso M, Ingemansson R. Blood flow changes in normal and ischemic myocardium during topically applied negative pressure. *Ann Thorac Surg* 2007;84:568–73.
- [20] Zografos GC, Martis K, Morris DL. Laser Doppler flowmetry in evaluation of cutaneous wound blood flow using various suturing techniques. *Ann Surg* 1992;215:266–8.
- [21] Wackenfors A, Gustafsson R, Sjogren J, Algotsson L, Ingemansson R, Malmso M. Blood flow responses in the peristernal thoracic wall during vacuum-assisted closure therapy. *Ann Thorac Surg* 2005;79:1724–30 [discussion 1730–1721].
- [22] Toumpoulis IK, Anagnostopoulos CE, Deroose JJ, Swistel DG. The impact of deep sternal wound infection on long-term survival after coronary artery bypass grafting. *Chest* 2005;127:464–71.
- [23] Sjogren J, Nilsson J, Gustafsson R, Malmso M, Ingemansson R. The impact of vacuum-assisted closure on long-term survival after poststernotomy mediastinitis. *Ann Thorac Surg* 2005;80:1270–5.
- [24] Leon MB, Kornowski R, Downey WE, Weisz G, Baim DS, Bonow RO, et al. A blinded, randomized, placebo-controlled trial of percutaneous laser myocardial revascularization to improve angina symptoms in patients with severe coronary disease. *J Am Coll Cardiol* 2005;46:1812–9.
- [25] Cohn PF. Enhanced external counterpulsation for the treatment of angina pectoris. *Prog Cardiovasc Dis* 2006;49:88–97.
- [26] Deer TR, Raso LJ. Spinal cord stimulation for refractory angina pectoris and peripheral vascular disease. *Pain Physician* 2006;9:347–52.
- [27] Ueyama K, Bing G, Tabata Y, Ozeki M, Doi K, Nishimura K, et al. Development of biologic coronary artery bypass grafting in a rabbit model: revival of a classic concept with modern biotechnology. *J Thorac Cardiovasc Surg* 2004;127:1608–15.
- [28] Horvath KA, Lu CY, Robert E, Pierce GF, Greene R, Sosnowski BA, et al. Improvement of myocardial contractility in a porcine model of



- chronic ischemia using a combined transmyocardial revascularization and gene therapy approach. *J Thorac Cardiovasc Surg* 2005;129:1071–7.
- [29] Korff T, Augustin HG. Tensional forces in fibrillar extracellular matrices control directional capillary sprouting. *J Cell Sci* 1999;112 (Pt 19):3249–58.
- [30] Chen CS, Mrksich M, Huang S, Whitesides GM, Ingber DE. Micropatterned surfaces for control of cell shape, position, and function. *Biotechnol Prog* 1998;14:356–63.
- [31] Chen KD, Li YS, Kim M, Li S, Yuan S, Chien S, et al. Mechanotransduction in response to shear stress. Roles of receptor tyrosine kinases, integrins, and Shc. *J Biol Chem* 1999;274:18393–400.



IV



## Research article

## Open Access

# No hypoperfusion is produced in the epicardium during application of myocardial topical negative pressure in a porcine model

Sandra Lindstedt\*<sup>1</sup>, Malin Malmsjö<sup>2</sup> and Richard Ingemansson<sup>1</sup>

Address: <sup>1</sup>Department of Cardiothoracic Surgery, Lund University Hospital, Lund, Sweden and <sup>2</sup>Department of Medicine, Lund University Hospital, Lund, Sweden

Email: Sandra Lindstedt\* - [sandra.lindstedt@skane.se](mailto:sandra.lindstedt@skane.se); Malin Malmsjö - [malin.malmsjo@skane.se](mailto:malin.malmsjo@skane.se); Richard Ingemansson - [richard.ingemansson@skane.se](mailto:richard.ingemansson@skane.se)

\* Corresponding author

Published: 6 December 2007

Received: 24 July 2007

*Journal of Cardiothoracic Surgery* 2007, **2**:53 doi:10.1186/1749-8090-2-53

Accepted: 6 December 2007

This article is available from: <http://www.cardiothoracicsurgery.org/content/2/1/53>

© 2007 Lindstedt et al; licensee BioMed Central Ltd.

This is an Open Access article distributed under the terms of the Creative Commons Attribution License (<http://creativecommons.org/licenses/by/2.0>), which permits unrestricted use, distribution, and reproduction in any medium, provided the original work is properly cited.

## Abstract

**Background:** Topical negative pressure (TNP), commonly used in wound therapy, has been shown to increase blood flow and stimulate angiogenesis in skeletal muscle. We have previously shown that a myocardial TNP of -50 mmHg significantly increases microvascular blood flow in the myocardium. When TPN is used in wound therapy (on skeletal and subcutaneous tissue) a zone of relative hypoperfusion is seen close to the wound edge. Hypoperfusion induced by TNP is thought to depend on tissue density, distance from the negative pressure source, and the amount negative pressure applied. When applying TNP to the myocardium, a significant, long-standing zone of hypoperfusion could theoretically cause ischemia, and negative effects on the myocardium. The current study was designed to elucidate whether hypoperfusion was produced during myocardial TNP.

**Methods:** Six pigs underwent median sternotomy. Laser Doppler probes were inserted horizontally into the heart muscle in the LAD area, at depths of approximately, 1–2 mm. The microvascular blood flow was measured before and after the application of a TNP. Analyses were performed before left anterior descending artery (LAD) occlusion (normal myocardium) and after 20 minutes of LAD occlusion (ischemic myocardium).

**Results:** A TNP of -50 mmHg induced a significant increase in microvascular blood flow in normal myocardium (\*\* $p = 0.01$ ), while -125 mmHg did not significantly alter the microvascular blood flow. In ischemic myocardium a TNP of -50 mmHg induced a significant increase in microvascular blood flow (\* $p = 0.04$ ), while -125 mmHg did not significantly alter the microvascular blood flow.

**Conclusion:** No hypoperfusion could be observed in the epicardium in neither normal nor ischemic myocardium during myocardial TNP.

## Introduction

Vacuum therapy, or topical negative pressure (TNP), can be regarded as an established clinical routine for wound care, in use since the mid or late 1990's, and it has been shown to promote the healing of chronic and problematic

wounds [1-3], for example, post-sternotomy mediastinitis[4,5]. The physiological and molecular biological mechanisms by which TNP accelerates wound healing are to a large extent unknown. However, TNP is known to increase the blood flow as a result of mechanical stress

and a pressure gradient across the tissue, and increased blood flow is known to stimulate granulation tissue formation, and angiogenesis in subcutaneous tissue and skeletal muscle [6-10].

Mediastinitis is a strong predictor for poor long-term survival after coronary artery by-pass grafting (CABG), when using conventional wound healing techniques (closed irrigation, delayed wound closure, or reconstructing with omentum or pectoral flaps) [11-16]. Recently, the use of TNP has gained acceptance in the treatment of post-sternotomy mediastinitis, and is today the standard mode of treatment in many cardiac surgery centers [4,5,17,18].

Previously, we have showed no difference in long-term survival between CABG patients with TNP-treated mediastinitis and CABG patients without mediastinitis [17]. It may be that the TNP stimulation of blood flow and development of collateral blood vessels in part account for the reduced long-term mortality.

Patients with ungraftable coronary disease may benefit from methods that increase blood flow to the area and stimulate myocardial angiogenesis that are not dependent on vessel caliber. Vascular endothelial growth factor (VEGF) has been found to be one of the most interesting growth factors in therapeutic angiogenesis [19-24]. Interestingly, the mechanical forces exerted by TNP stimulate the endogenous production of VEGF [25,26].

We have previously shown that a myocardial TNP of -50 mmHg significantly increases microvascular blood flow in the underlying myocardium at a depth of 6-8 mm in porcine myocardium [27]. We have also shown that TNP produces relative hypoperfusion close to the wound edge in muscular and subcutaneous tissue [8]. Hypoperfusion in myocardial TNP could theoretically lead to ischemia, with negative consequences in the myocardium. The present study was designed to elucidate whether a relative hypoperfusion zone is produced in the epicardium, at a depth of 1-2 mm in the heart muscle, during the application of TNP.

The microvascular blood flow was measured using laser Doppler velocimetry in a porcine model. The effect of a TNP of -50 and -125 mmHg was investigated before and during occlusion of the left anterior descending artery (LAD) to imitate ischemic coronary disease. No such study has to our knowledge been performed previously.

## Methods

### Experimental animals

A porcine model was used in the present study. Six domestic landrace pigs of both genders, with a mean body weight of 70 kg, were fasted overnight with free access to

water. The study was approved by the Ethics Committee for Animal Research, Lund University, Sweden. The investigation complied with the "Guide for the Care and Use of Laboratory Animals" as recommended by the U.S. National Institutes of Health, and published by the National Academies Press (1996).

### Anesthesia

All animals were pre-medicated intramuscularly with ketamine (30 mg/kg) before they were brought into the laboratory. Before commencing surgery sodium thiopental (5 mg/kg), atropine (0.02 mg/kg) and pancuronium (0.5 mg/kg) were given intravenously. Tracheotomy was performed with a Portex endo-tracheal tube (7.5 mm internal diameter, Medcompare™, USA). A servo-ventilator (Siemens Elema 300A, Stockholm, Sweden) was used for mechanical ventilation throughout the experiment. The ventilator settings used were: minute volume = 100 ml/kg,  $\text{FiO}_2$  = 0.5, breathing frequency = 16 breaths/minute and positive end expiratory pressure = 5 cmH<sub>2</sub>O.

Anesthesia and muscular paralysis were maintained with a continuous intravenous infusion of 8-10 mg/kg/hour propofol (Diprivan®, AstraZeneca, Sweden), 0.15 mg/kg/hour fentanyl (Leptanal®, Lilly, France), and 0.6 mg/kg/hour pancuronium (Pavulon®, Organon Teknika, Bostel, the Netherlands).

### Data acquisition

Mean arterial pressure, central venous pressure, heart frequency, and ventilatory parameters were recorded throughout the experiments.

### Surgical procedure

Surgery was performed through median sternotomy. After heparinization (400 IU/kg) a cardiopulmonary bypass (CPB) was installed with an arterial cannula (22 French, DLP® Elongated One-Piece Arterial Cannula (EOPA™), Medtronic Inc., Minneapolis, MO, USA) in the distal ascending aorta, and a venous cannula (32 French, MC2® Two-Stage Venous Cannula, also from Medtronic Inc.) inserted through the right atrium. Before cannulation of the heart the cannulae were inserted through the thoracic wall to prevent air leakage during TNP application. CPB was conducted in normothermia. Ventricular fibrillation was subsequently induced in the heart. No aortic cross-clamping was performed and no cardioplegia was employed. The mean arterial pressure was maintained between 60 and 80 mmHg. A left ventricular vent (DLP® Vent, also from Medtronic Inc.) was used to protect the left chamber from overloading. Pulmonary ventilation was applied at a rate of 4 liters/minute during the experiments.

A CPB was used to facilitate the measurements of microvascular blood flow using laser Doppler velocimetry. Fibrillation of the heart minimizes the movement artifacts, while the physiological conditions are, to a large extent, conserved. Moreover, CPB prevents the risk of circulatory failure during LAD occlusion, thereby facilitating experimental analysis in the case of the ischemic myocardium.

Microvascular blood flow was measured using laser Doppler velocimetry (Transonic® Laser Doppler Monitor, BLF21, Maastricht, the Netherlands, and Peri Flux System 5000, Perimed, Stockholm, Sweden), employing atech-nique that quantifies the sum of the motion of the red blood cells in a specific volume. This method is extensively applied in plastic surgery procedures and employs a fiberoptic probe carrying a beam of light. Light impinging on cells in motion undergoes a change in wavelength (Doppler shift) while light impinging on static objects remains unchanged. The magnitude and frequency distributions of the changes are directly related to the number and velocity of red blood cells. The information is collected by a returning fiber, converted into an electronic signal, and analyzed[28].

Laser Doppler probes were inserted horizontally into the heart muscle 6–8 mm lateral of the LAD at depths of approximately 1–2 mm. All probes were carefully fixed to the surface of the heart with a suture (Prolene 7-0; Ethicon Inc., New Jersey, USA), thereby preventing probe movement. After the experiments, the heart was dissected and the probe location was confirmed. A round hole, 5 cm in diameter, was made in the middle of a phrenic nerve pad (Phrenic Nerve Pad® Medtronic Inc.) and placed on top of the heart. The pad was stabilized to the surrounding myocardium by 8–10 sutures (Prolene 5-0; Ethicon Inc., New Jersey, USA) and by sutures to the posterior sternal edges (Dermalon 2-0; Davis and Geck, St. Louis, New Jersey, USA). A retractor was used throughout the experiments to keep the sternal edges apart. A polyurethane foam dressing, with an open pore structure of 400 to 600 µm (KCI, Copenhagen, Denmark) was placed between the sternal edges. The foam was continuously sutured to the surrounding skin (Dermalon 2-0; Davis and Geck). The wound was sealed with a transparent adhesive drape. A Track Pad (KCI, Copenhagen, Denmark) was inserted through the drape and was connected to a vacuum pump, (V.A.C. pump unit, KCI, Copenhagen, Denmark). When the negative pressure is applied, the heart will be drawn up towards the phrenic nerve pad and the foam without interfering with the sternal edges. This procedure causes the application of negative pressure to affect only the myocardium exposed through the 5 cm diameter hole.

### Experimental protocol

The microvascular blood flow was measured continuously by the laser Doppler filament probes. Recordings were made in normal myocardium, before negative pressure was applied, and at negative pressures of -50 and -125 mmHg.

The LAD was then occluded for 20 minutes with an elastic vessel loop. Microvascular blood flow was measured before, and after 5, 10, 15 and 20 minutes of occlusion.

Recordings were also made in ischemic myocardium, before negative pressure was applied, and at negative pressures of -50 and -125 mmHg.

### Calculations and statistics

Laser Doppler velocimetry measurements were performed on six pigs. The output was continuously recorded using PeriSoft software (Perimed, Stockholm, Sweden). Microvascular blood flow was expressed in terms of perfusion units (PU). Calculations and statistical analysis were performed using GraphPad 4.0 software. Statistical analysis was performed using Student's paired t-test. Significance was defined as \* $p < 0.05$ , \*\* $p < 0.01$ , \*\*\* $p < 0.001$  and  $p > 0.05$  (not significant, n.s.). Values are presented as means  $\pm$  the standard error on the mean (SEM).

## Results

### Normal myocardium

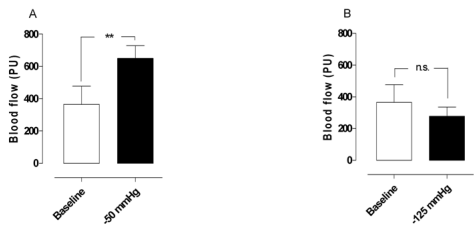
A topical negative pressure of -50 mmHg induced an immediate significant increase in microvascular blood flow in normal myocardium (from  $365.8 \pm 111.7$  PU before, to  $649.8 \pm 78.3$  PU after TNP application, \*\*  $p = 0.01$ ) (Figure 1A). A TNP of -125 mmHg did not result in any significantly change in microvascular blood flow ( $365.8 \pm 111.7$  PU before, and  $279.2 \pm 57.1$  PU after TNP application,  $p = 0.33$ ) (Figure 1B).

### LAD occlusion

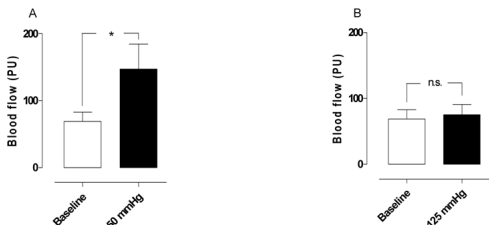
Ischemia was induced by occlusion of the LAD for 20 minutes. The blood flow was  $311.7 \pm 106.2$  PU before occlusion of the LAD, and decreased to  $90.0 \pm 37.3$  PU after 5 minutes (\* $p = 0.03$ ), to  $95.0 \pm 32.2$  PU after 10 minutes (\* $p = 0.04$ ), to  $95.8 \pm 36.9$  after 15 minutes (\* $p = 0.04$ ), and to  $84.2 \pm 29.9$  after 20 minutes (\* $p = 0.02$ ) of LAD occlusion (Figure 2).

### Ischemic myocardium

A topical negative pressure of -50 mmHg induced an immediate significant increase in microvascular blood flow in ischemic myocardium (from  $69.0 \pm 5.5$  PU before, to  $147.0 \pm 9.1$  PU after TNP application, \*  $p = 0.04$ ) (Figure 3A). A TNP of -125 mmHg did not result in any significantly change in microvascular blood flow ( $69.0 \pm 5.5$  PU before, and  $75.0 \pm 5.9$  PU after,  $p = 0.68$ ) (Figure 3B).



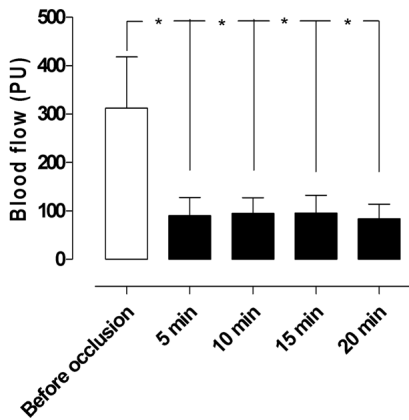
**Figure 1**  
Microvascular blood flow measured using laser Doppler velocimetry in normal myocardium exposed to topical negative pressures of A) -50 mmHg, and B) -125 mmHg. The measurements were performed in six pigs at a depth of 1–2 mm in the myocardium. Significance was defined as \* $p < 0.05$ , \*\* $p < 0.01$ , \*\*\* $p < 0.001$  and  $p > 0.05$  (not significant, n.s.). Values are presented as means  $\pm$  the standard error on the mean (SEM).



**Figure 3**  
Microvascular blood flow measured using laser Doppler velocimetry in ischemic myocardium exposed to topical negative pressures of A) -50 mmHg, and B) -125 mmHg. The measurements were performed in six pigs at a depth of 1–2 mm in the myocardium. Significance was defined as \* $p < 0.05$ , \*\* $p < 0.01$ , \*\*\* $p < 0.001$  and  $p > 0.05$  (not significant, n.s.). Values are presented as means  $\pm$  the standard error on the mean (SEM).

**Conclusion**

Post-sternotomy mediastinitis after CABG is a serious and potentially life-threatening complication, with a high mortality rate and substantial morbidity[12,14,29].



**Figure 2**  
Microvascular blood flow measured using laser Doppler velocimetry in the myocardium before and after 5, 10, 15, and 20 minutes of occlusion of the left anterior descending artery (LAD). Note the decrease in microvascular blood flow, from  $311.7 \pm 106.2$  PU before, to  $84.2 \pm 29.9$  PU after 20 minutes' occlusion of the LAD, in the area studied. Significance was defined as \* $p < 0.05$ , \*\* $p < 0.01$ , \*\*\* $p < 0.001$  and  $p > 0.05$  (not significant, n.s.). Values are presented as means  $\pm$  the standard error on the mean (SEM).

Recently, the use of TNP has gained acceptance in the treatment of post-sternotomy mediastinitis, and is today the standard mode of treatment in many cardiac surgery centers [4,5,17,18]. Before the introduction of TNP therapy, the risk of late death in patients suffering from mediastinitis after cardiac surgery was reported to be two to three times higher than that of patients without mediastinitis[12,14,29]. Milano and collages have suggested that mediastinitis may cause negative long-terms effects on several organs such as the heart and kidneys [13]. Theoretically, a massive immunological response during a prolonged period of infection may cause adverse effects on by-pass grafts. In those studies, reporting poor long-term survival after mediastinitis, several conventional wound healing techniques were used (closed irrigation, delayed wound closure, or reconstructing with omentum or pectoral flaps). Interestingly, Sjogren and coworkers, found no difference in long-term survival between CABG patients with TNP-treated mediastinitis and CABG patients without mediastinitis [17]. During the treatment of post-sternotomy mediastinitis, the TNP is in direct contact with the heart, which is exposed through the diastase of the sternotomy. These patients may therefore have developed increased coronary collateral blood vessels during TNP, and may be better prepared when bypass grafts fail to work. We have indeed observed in patients treated with TNP, that richly vascularized granulation tissue develops over the heart within 7–8 days. It may well be that the stimulation of blood flow and the development of collateral blood vessels resulting from TNP in part account for the reduced long-term mortality in patients treated in this way.



We have previously shown that TNP induces an increase in the blood flow of the peristernal soft tissue (i.e. skeletal muscular and subcutaneous tissue), and also that the change is related to local effects, since the blood flow at a distance of 4.5 cm from the wound edge was not affected by the negative pressure[8]. The blood flow increased with elevated subatmospheric pressure in both subcutaneous and skeletal muscular tissue[8]. When the area under the flow-distance curve was analyzed, covering 0.5 to 4.5 cm from the wound edge, a maximal net increase in blood flow was observed at -75 and -100 mmHg, in muscular tissue. Interestingly, a difference in the profiles of the blood flow responses was observed between the subcutaneous and the muscular tissue. The distance from the wound edge to the point at which the blood flow increased was shorter in muscular tissue than in subcutaneous tissue[8]. This may indicate that pressure is transduced differently in a soft and in a dense tissue, and a less dense tissue collapses more easily when affected by pressure. In the immediate proximity of the wound edge, a zone of relative hypoperfusion was observed. This zone was larger at high negative pressures and was especially prominent in subcutaneous tissue. The size of the hypoperfused zone depended on the pressure applied, and increased with increasing negative pressure. In summary, the changes in the peristernal wound blood flow caused by TNP vary with the distance from the wound edge. A few centimeters away from the wound edge, the blood flow increased when subatmospheric pressure was applied. Conversely, in the immediate proximity of the wound, the negative pressure induced relative hypoperfusion[8].

We have recently shown that a myocardial TNP of -50 mmHg significantly increases microvascular blood flow in the underlying myocardium, at a depth of 6–8 mm in the heart muscle, i.e. the middle of the myocardial ventricular wall, in both normal, ischemic, and reperfused porcine myocardium[27]. We have also demonstrated that TNP levels between -75 mmHg and -150 mmHg, applied to the myocardium, do not alter myocardial microvascular blood flow, also at depths at 6–8 mm down into the myocardium[30]. In skeletal muscle and subcutaneous tissue, application of different negative pressure levels causes different changes in microvascular blood flow[8]. When the negative pressure exceeds a specific level it seems to constrict the vessels in subcutaneous tissue and skeletal muscle and a decrease in microvascular blood flow close to the vacuum source, i.e. a zone of hypoperfusion, is seen[8]. The hypoperfusion zone seen in subcutaneous tissue was greater than the one seen in skeletal muscle at same pressure levels[8]. However, when applying TNP to the myocardium, a significant, long-standing zone of hypoperfusion could theoretically cause ischemia, and negative effects on the myocardium. The current study was designed to determine whether a zone

of relative hypoperfusion was produced during myocardial TNP, as seen in subcutaneous and muscular tissue[8]. In the present study we show that, a TNP of -50 mmHg applied over the LAD region significantly increases the microvascular blood flow in normal myocardium, while a TNP of -125 mmHg did not significantly alter the microvascular blood flow. This indicates that no hypoperfusion is produced in normal myocardium during TNP. In ischemic myocardium, application of a TNP of -50 mmHg over the LAD region resulted in a significant increase in microvascular blood flow. However, a pressure of -125 mmHg did not induce any significant change in microvascular blood flow in the ischemic myocardium. Consequently, no hypoperfusion could be observed during myocardial TNP in neither normal nor ischemic myocardium. The absence of hypoperfusion might be explained by the higher density of myocardium than skeletal muscle and subcutaneous tissue.

Among patients with ischemic heart disease, some are not suitable for current revascularization procedures such as percutaneous coronary interventions (PCI) and CABG, because of extensive and technically problematic coronary lesions, i.e. refractory angina pectoris. The natural response to myocardial ischemia is neovascularization. This angiogenic process is a physiological attempt to limit myocardial ischemia. Therapeutic angiogenesis, wherein exogenous growth factors are administered to ischemic tissue to enhance reperfusion, has been investigated as a potential form of treatment for patients with advanced coronary artery disease as an alternative to conventional treatment such as PCI and CABG. VEGF proteins have been shown to play a key role in the modulation of angiogenesis and vascular growth [20,21]. Interestingly, TNP produces a mechanical shear stress that is known to activate endogenous VEGF[25,26,31-33].

## Conclusion

In conclusion, no hypoperfusion could be observed in the epicardium in neither normal nor ischemic myocardium during myocardial TNP. Myocardial TNP may in the future, constitute an alternative therapeutic intervention to stimulate blood flow in the failing myocardium in patients with ischemic heart disease.

## List of abbreviations used

CABG Coronary Artery Bypass Grafting

LAD Left Anterior Descending Artery

PCI Percutaneous Coronary Interventions

PU Perfusion Units

TNP Topical Negative Pressure

VEGF Vascular Endothelial Growth Factor

### Competing interests

The author(s) declare that they have no competing interests.

### Authors' contributions

SL and RI carried out the animal studies. SL and MM carried out the acquisition, analysis, and the interpretation of the data. SL wrote the manuscript. RI, MM, and SL made substantial contribution to concept and design of the study.

### Acknowledgements

We would like to thank Johan Ingemansson (Statistical Solutions IP) for his expert contribution to the statistic analyses. This study was supported by Anders Otto Sward's Foundation/Ulrika Eklund's Foundation, Anna Lisa and Sven Eric Lundgren's Foundation for medical research, the Åke Wiberg Foundation, the M. Bergvall Foundation, the Swedish Medical Association, the Royal Physiographic Society in Lund, the Swedish Medical Research Council, the Crafoord Foundation, the Swedish Heart-Lung Foundation, the Swedish Government Grant for Clinical Research, and the Swedish Hypertension Society.

### References

- Morykwas MJ, Argenta LC, Shelton-Brown EI, McGuirt W: **Vacuum-assisted closure: a new method for wound control and treatment: animal studies and basic foundation.** *Ann Plast Surg* 1997, **38**(6):553-562.
- Argenta LC, Morykwas MJ: **Vacuum-assisted closure: a new method for wound control and treatment: clinical experience.** *Ann Plast Surg* 1997, **38**(6):563-76; discussion 577.
- Armstrong DG, Lavery LA: **Negative pressure wound therapy after partial diabetic foot amputation: a multicentre, randomised controlled trial.** *Lancet* 2005, **366**(9498):1704-1710.
- Sjogren J, Gustafsson R, Nilsson J, Malmjö M, Ingemansson R: **Clinical outcome after poststernotomy mediastinitis: vacuum-assisted closure versus conventional treatment.** *Ann Thorac Surg* 2005, **79**(6):2049-2055.
- Gustafsson RI, Sjogren J, Ingemansson R: **Deep sternal wound infection: a sternal-sparing technique with vacuum-assisted closure therapy.** *Ann Thorac Surg* 2003, **76**(6):2048-53; discussion 2053.
- Wackenfors A, Sjogren J, Gustafsson R, Algotsson L, Ingemansson R, Malmjö M: **Effects of vacuum-assisted closure therapy on inguinal wound edge microvascular blood flow.** *Wound Repair Regen* 2004, **12**(6):600-606.
- Chen SZ, Li J, Li XY, Xu LS: **Effects of vacuum-assisted closure on wound microcirculation: an experimental study.** *Asian J Surg* 2005, **28**(3):211-217.
- Wackenfors A, Gustafsson R, Sjogren J, Algotsson L, Ingemansson R, Malmjö M: **Blood flow responses in the peristernal thoracic wall during vacuum-assisted closure therapy.** *Ann Thorac Surg* 2005, **79**(5):1724-30; discussion 1730-1.
- Saxena V, Hwang CW, Huang S, Eichbaum Q, Ingber D, Orgill DP: **Vacuum-assisted closure: microdeformations of wounds and cell proliferation.** *Plast Reconstr Surg* 2004, **114**(5):1086-96; discussion 1097-8.
- Greene AK, Puder M, Roy R, Arsenaault D, Kwei S, Moses MA, Orgill DP: **Microdeformational wound therapy: effects on angiogenesis and matrix metalloproteinases in chronic wounds of 3 debilitated patients.** *Ann Plast Surg* 2006, **56**(4):418-422.
- Lu JC, Grayson AD, Jha P, Srinivasan AK, Fabri BM: **Risk factors for sternal wound infection and mid-term survival following coronary artery bypass surgery.** *Eur J Cardiothorac Surg* 2003, **23**(6):943-949.
- Loop FD, Lytle BW, Cosgrove DM, Mahfood S, McHenry MC, Goormastic M, Stewart RW, Golding LA, Taylor PC: **J. Maxwell Chamberlain memorial paper. Sternal wound complications after isolated coronary artery bypass grafting: early and late mortality, morbidity, and cost of care.** *Ann Thorac Surg* 1990, **49**(2):179-86; discussion 186-7.
- Milano CA, Kesler K, Archibald N, Sexton DJ, Jones RH: **Mediastinitis after coronary artery bypass graft surgery. Risk factors and long-term survival.** *Circulation* 1995, **92**(8):2245-2251.
- Braxton JH, Marrin CA, McGrath PD, Ross CS, Morton JR, Norotsky M, Charlesworth DC, Lahey SJ, Clough RA, O'Connor GT: **Mediastinitis and long-term survival after coronary artery bypass graft surgery.** *Ann Thorac Surg* 2000, **70**(6):2004-2007.
- Toumpoulis IK, Anagnostopoulos CE, Derose JJ Jr., Swistel DG: **The impact of deep sternal wound infection on long-term survival after coronary artery bypass grafting.** *Chest* 2005, **127**(2):464-471.
- Stable E, Tammelin A, Bergstrom R, Hambreus A, Nystrom SO, Hansson HE: **Sternal wound complications-incidence, microbiology and risk factors.** *Eur J Cardiothorac Surg* 1997, **11**(6):1146-1153.
- Sjogren J, Nilsson J, Gustafsson R, Malmjö M, Ingemansson R: **The impact of vacuum-assisted closure on long-term survival after post-sternotomy mediastinitis.** *Ann Thorac Surg* 2005, **80**(4):1270-1275.
- Fleck TM, Fleck M, Moidl R, Czerny M, Koller R, Giovanoli P, Hiesmayer MJ, Zimpfer D, Wolner E, Grabenwoger M: **The vacuum-assisted closure system for the treatment of deep sternal wound infections after cardiac surgery.** *Ann Thorac Surg* 2002, **74**(5):1596-600; discussion 1600.
- Biswas SS, Hughes GC, Scarborough JE, Domkowski PW, Diodato L, Smith ML, Landolfo C, Lowe JE, Annex BH, Landolfo KP: **Intramyocardial and intracoronary basic fibroblast growth factor in porcine hibernating myocardium: a comparative study.** *J Thorac Cardiovasc Surg* 2004, **127**(1):34-43.
- Rosengart TK, Lee LY, Patel SR, Kligfield PD, Okin PM, Hackett NR, Isom OW, Crystal RG: **Six-month assessment of a phase I trial of angiogenic gene therapy for the treatment of coronary artery disease using direct intramyocardial administration of an adenovirus vector expressing the VEGF121 cDNA.** *Ann Surg* 1999, **230**(4):466-70; discussion 470-2.
- Rosengart TK, Lee LY, Patel SR, Sanborn TA, Parikh M, Bergman GW, Hachamovitch R, Szulc M, Kligfield PD, Okin PM, Hahn RT, Devereux RB, Post MR, Hackett NR, Foster T, Grasso TM, Isom OW, Crystal RG: **Angiogenesis gene therapy: phase I assessment of direct intramyocardial administration of an adenovirus vector expressing VEGF121 cDNA to individuals with clinically significant severe coronary artery disease.** *Circulation* 1999, **100**(5):468-474.
- Kim C, Li RK, Li G, Zhang Y, Weisel RD, Yau TM: **Effects of cell-based angiogenic gene therapy at 6 months: persistent angiogenesis and absence of oncogenicity.** *Ann Thorac Surg* 2007, **83**(2):640-646.
- Yau TM, Kim C, Li G, Zhang Y, Fazel S, Spiegelstein D, Weisel RD, Li RK: **Enhanced angiogenesis with multimodal cell-based gene therapy.** *Ann Thorac Surg* 2007, **83**(3):1110-1119.
- Yau TM, Kim C, Ng D, Li G, Zhang Y, Weisel RD, Li RK: **Increasing transplanted cell survival with cell-based angiogenic gene therapy.** *Ann Thorac Surg* 2005, **80**(5):1779-1786.
- Chen KD, Li YS, Kim M, Li S, Yuan S, Chien S, Shyy JY: **Mechanotransduction in response to shear stress. Roles of receptor tyrosine kinases, integrins, and Shc.** *J Biol Chem* 1999, **274**(26):18393-18400.
- Detmar M, Brown LF, Berse B, Jackman RW, Elicker BM, Dvorak HF, Claffey KP: **Hypoxia regulates the expression of vascular permeability factor/vascular endothelial growth factor (VPF/VEGF) and its receptors in human skin.** *J Invest Dermatol* 1997, **108**(3):263-268.
- Lindstedt S, Malmjö M, Ingemansson R: **Blood flow changes in normal and ischemic myocardium during topically applied negative pressure.** *Ann Thorac Surg* 2007, **84**(2):568-573.
- Zografos GC, Martis K, Morris DL: **Laser Doppler flowmetry in evaluation of cutaneous wound blood flow using various suturing techniques.** *Ann Surg* 1992, **215**(3):266-268.
- De Feo M, Renzulli A, Ismeno G, Gregorio R, Della Corte A, Utili R, Cotrufo M: **Variables predicting adverse outcome in patients with deep sternal wound infection.** *Ann Thorac Surg* 2001, **71**(1):324-331.

30. Lindstedt S, Malmjö M, Sjögren J, Gustafsson R, Ingemansson R: **Impact of different topical negative pressure levels on myocardial microvascular blood flow**. *Cardiovasc Revasc Med* in press.
31. Shyu KG, Chang ML, Wang BW, Kuan P, Chang H: **Cyclical mechanical stretching increases the expression of vascular endothelial growth factor in rat vascular smooth muscle cells**. *J Formos Med Assoc* 2001, **100**(11):741-747.
32. Milkiewicz M, Mohammadzadeh F, Ispanovic E, Gee E, Haas TL: **Static strain stimulates expression of matrix metalloproteinase-2 and VEGF in microvascular endothelium via JNK- and ERK-dependent pathways**. *J Cell Biochem* 2007, **100**(3):750-761.
33. Seko Y, Seko Y, Takahashi N, Shibuya M, Yazaki Y: **Pulsatile stretch stimulates vascular endothelial growth factor (VEGF) secretion by cultured rat cardiac myocytes**. *Biochem Biophys Res Commun* 1999, **254**(2):462-465.

Publish with **BioMed Central** and every scientist can read your work free of charge

*"BioMed Central will be the most significant development for disseminating the results of biomedical research in our lifetime."*

Sir Paul Nurse, Cancer Research UK

Your research papers will be:

- available free of charge to the entire biomedical community
- peer reviewed and published immediately upon acceptance
- cited in PubMed and archived on PubMed Central
- yours — you keep the copyright

Submit your manuscript here:  
[http://www.biomedcentral.com/info/publishing\\_adv.asp](http://www.biomedcentral.com/info/publishing_adv.asp)











## Evaluation of continuous and intermittent myocardial topical negative pressure

Sandra Lindstedt<sup>a</sup>, Malin Malmjö<sup>b</sup>, Bodil Gesslein<sup>b</sup> and Richard Ingemansson<sup>a</sup>

**Objective** Topical negative pressure, commonly used in wound therapy, has been shown to increase blood flow and stimulate angiogenesis in subcutaneous tissue and skeletal muscle. In wound therapy, intermittent negative pressure is often preferred to continuous negative pressure as tissue exposed to intermittent therapy shows twice as much granulation tissue formation than that exposed to continuous pressure after 2 weeks of therapy. The present study was designed to elucidate the differences in microvascular blood flow in the left anterior descending artery area between continuous and intermittent myocardial topical negative pressure of  $-50$  mmHg.

**Methods** Six pigs underwent median sternotomy. Laser Doppler probes were inserted horizontally into the heart muscle in the left anterior descending artery area at depths of approximately 5–6 mm. Measurements of microvascular blood flow were performed in normal myocardium and ischemic myocardium during 20 min of continuous and intermittent topical negative pressure at  $-50$  mmHg.

**Results** Both continuous and intermittent topical negative pressure of  $-50$  mmHg significantly increased

microvascular blood flow in the underlying myocardium: from  $56.2 \pm 13.1$  perfusion units (PU) before to  $132.8 \pm 7.4$  PU during continuous topical negative pressure application ( $*P < 0.05$ ) and from  $75.8 \pm 12.1$  PU before to  $153.6 \pm 4.7$  PU during intermittent topical negative pressure application ( $*P < 0.05$ ).

**Conclusion** No statistically significant difference was found between microvascular blood flow during 20 min of continuous and intermittent topical negative pressure at  $-50$  mmHg in this porcine model. *J Cardiovasc Med* 9:000–000 © 2008 Italian Federation of Cardiology.

Journal of Cardiovascular Medicine 2008, 9:000–000

**Keywords:** collateral blood flow, ischemia, myocardium, topical negative pressure

<sup>a</sup>Department of Cardiothoracic Surgery and <sup>b</sup>Department of Medicine, Lund University Hospital, Lund, Sweden

Correspondence to Sandra Lindstedt, MD, Department of Cardiothoracic Surgery, Heart and Lung Center, Lund, University Hospital, SE-221 85 Lund, Sweden

Tel: +46 46 173803; fax: +46 46 158635; e-mail: sandra.lindstedt@skane.se

## Introduction

Topical negative pressure (TNP) was introduced in wound treatment in the mid 1990s. Since the late 1990s, it has been used in the treatment of poststernotomy mediastinitis with excellent clinical results, and today it is routinely used at many cardiothoracic surgery centers around the world [1–5]. The physiological and molecular biological mechanisms by which TNP accelerates wound healing are to a large extent unknown. TNP is, however, known to increase blood flow and stimulate the formation of granulation tissue in subcutaneous tissue and skeletal muscle [6–10]. TNP produces mechanical stress and a pressure gradient across the tissue, which cause a surge of blood to the area. Mechanical forces and increased blood flow are known to stimulate granulation tissue formation, that is endothelial proliferation, capillary budding and angiogenesis [11,12].

A pressure drop has been seen in skeletal muscle and subcutaneous tissue after 5–7 min of continuous pressure

therapy [6]. When pressure was applied for 5 min followed by 2 min without pressure, a lower mean blood flow was seen during the period of therapy than when applying continuous pressure. After 2 weeks of TNP, the formation of granulation tissue in the tissue exposed to intermittent therapy was, however, found to be twice as high as in the tissue exposed to continuous pressure [6].

We have previously shown that applying a TNP of  $-50$  mmHg over the left anterior descending artery (LAD) region induces a significant increase in microvascular blood flow in normal, ischemic and reperfused myocardium [13]. We have also demonstrated that among TNP pressure levels between  $-50$  and  $-150$  mmHg only,  $-50$  mmHg results in a significant increase in myocardial microvascular blood flow [14]. The present study was designed to compare the microvascular blood flow in ischemic myocardium during continuous and intermittent application of a TNP of  $-50$  mmHg. The

microvascular blood flow was measured in a porcine model using laser Doppler velocimetry. To our knowledge, no such study has been performed previously.

## Materials and methods

### Experimental animals

A porcine model was used in the present study. Six domestic landrace pigs of both sexes, with a mean body weight of 70 kg, were fasted overnight with free access to water. The study was approved by the Ethics Committee for Animal Research, Lund University, Sweden. The investigation complied with the 'Guide for the Care and Use of Laboratory Animals' as recommended by the U.S. National Institutes of Health and was published by the National Academies Press (1996).

### Anesthesia

All animals were premedicated intramuscularly with ketamine (30 mg/kg) before they were brought into the laboratory. Before commencing surgery, sodium thiopental (5 mg/kg), atropine (0.02 mg/kg) and pancuronium (0.5 mg/kg) were given intravenously. Tracheotomy was performed with a Portex endotracheal tube (7.5 mm internal diameter, Medcompare, South San Francisco, California, USA). A servo-ventilator (Siemens Elema 300A, Stockholm, Sweden) was used for mechanical ventilation throughout the experiment. The ventilator settings used were as follows: minute volume = 100 ml/kg,  $\text{FiO}_2$  = 0.5, breathing frequency = 16 breaths/min and positive end expiratory pressure = 5 cmH<sub>2</sub>O.

Anesthesia and muscular paralysis were maintained with a continuous intravenous infusion of 8–10 mg/kg/h propofol (Diprivan; AstraZeneca, Mölndal, Sweden), 0.15 mg/kg/h fentanyl (Leptanal; Lilly, Suresnes, France) and 0.6 mg/kg/h pancuronium (Pavulon; Organon Teknika, Boxtel, the Netherlands).

### Data acquisition

Mean arterial pressure, central venous pressure, heart frequency and ventilatory parameters were recorded throughout the experiments.

### Surgical procedure

Surgery was performed through median sternotomy. After heparinization (400 IU/kg), a cardiopulmonary bypass (CPB) was installed with an arterial cannula [22 French, DLP elongated one-piece arterial cannula (EOPA); Medtronic Inc., Minneapolis, Missouri, USA] in the distal ascending aorta, and a venous cannula (32 French, MC2 two-stage venous cannula, also from Medtronic Inc.) was inserted through the right atrium. Before cannulation of the heart, the cannulae were inserted through the thoracic wall to prevent air leakage during TNP application. CPB was conducted in normothermia. Ventricular fibrillation was subsequently induced in the heart. No aortic cross-clamping was per-

formed and no cardioplegia was employed. The mean arterial pressure was maintained between 60 and 80 mmHg. A left ventricular vent (DLP Vent, also from Medtronic Inc.) was used to protect the left chamber from overloading. Pulmonary ventilation was applied at a rate of 4 l/min during the experiments.

A CPB was used to facilitate the measurements of microvascular blood flow using laser Doppler velocimetry. Fibrillation of the heart minimizes the movement artifacts, whereas the physiological conditions are, to a large extent, conserved. Moreover, CPB prevents the risk of circulatory failure during LAD occlusion, thereby facilitating experimental analysis in the case of the ischemic myocardium.

Microvascular blood flow was measured using a Transonic Laser Doppler Monitor, Model BLF21 (Transonic Systems, Maastricht, the Netherlands) and a Peri Flux System 5000 (Perimed, Stockholm, Sweden), by employing a technique that quantifies the sum of the motion of the red blood cells in a specific volume. This method is extensively applied in plastic surgery procedures and employs a fiberoptic probe carrying a beam of light. Light impinging on cells in motion undergoes a change in wavelength (Doppler shift) whereas light impinging on static objects remains unchanged. The magnitude and frequency distributions of the changes are directly related to the number and velocity of red blood cells. The information is collected by a returning fiber, converted into an electronic signal and analyzed [15].

Laser Doppler probes were inserted horizontally into the heart muscle 6–8 mm lateral of the LAD at depths of approximately 5–6 mm. All probes were carefully fixed to the surface of the heart with a suture (Prolene 7–0; Ethicon Inc., Somerville, New Jersey, USA), thereby preventing probe movement. After the experiments, the heart was dissected and the probe location was confirmed. A round hole, 5 cm in diameter, was made in the middle of a Phrenic Nerve Pad (Medtronic Inc.) and placed on top of the heart. The pad was stabilized by 8–10 sutures to the surrounding myocardium (Prolene 5–0; Ethicon Inc.) and by sutures to the posterior sternal edges (Dermalon 2–0; Davis and Geck, St. Louis, New Jersey, USA). A retractor was used throughout the experiments to keep the sternal edges apart. A polyurethane foam dressing with an open pore structure of 400–600  $\mu\text{m}$  (KCI, Copenhagen, Denmark) was placed between the sternal edges. The foam was continuously sutured to the surrounding skin (Dermalon 2–0; Davis and Geck). The wound was sealed with a transparent adhesive drape. A Track Pad (KCI) was inserted through the drape and was connected to a vacuum pump (V.A.C. pump unit, KCI). When the negative pressure is applied, the heart will be drawn up towards the phrenic nerve pad and the foam without interfering with the sternal edges. This



procedure causes the application of negative pressure to affect only the myocardium exposed by the 5 cm diameter hole.

#### Experimental protocol

Two series of measurements were made in the same animal with a rest period of 20 min between the two measurements. The microvascular blood flow was measured continuously by the laser Doppler filament probes. The LAD was occluded for 20 min with an elastic vessel loop. Recordings were made in ischemic myocardium, before negative pressure was applied and every minute for 20 min during the continuous application of a negative pressure of  $-50$  mmHg.

Recordings were also made in ischemic myocardium, before negative pressure was applied and after every minute for 20 min during the intermittent application of a pressure of  $-50$  mmHg 5 min followed by 2 min without pressure. The order of the measurements was reversed in alternate animals to minimize any possible carry-over effect.

#### Statistical analysis

Laser Doppler velocimetry measurements were performed on six pigs. The output was continuously recorded using PeriSoft software (Perimed, Stockholm, Sweden). The microvascular blood flow was expressed in terms of perfusion units (PU). Calculations and statistical analysis were performed using GraphPad 4.0 software (GraphPad Software Inc., San Diego, California, USA). Significance was defined as  $*P$  value of less than 0.05 and  $P$  value of more than 0.05 (not significant using repeated measures ANOVA with Dunnett's post-hoc test. Paired Student's  $t$ -test was used to compare microvascular blood flow changes between the first and 18th minute of TNP in the two kinds of pressure application. Paired Student's  $t$ -test was also used to compare the two kinds of pressure application, continuous and intermittent TNP. Values are presented as mean  $\pm$  SEM.

## Results

#### Continuous topical negative pressure

Measurements were made before TNP of  $-50$  mmHg was applied and after every minute of TNP application for a total duration of 20 min. The mean values and SEM for each measurement are given below. Before TNP was applied, mean microvascular blood flow was  $56.2 \pm 13.1$  PU, and after 1 min of TNP application  $151.8 \pm 44.6$  PU, after 2 min of TNP application  $157.5 \pm 38.1$  PU, after 3 min of TNP application  $160.8 \pm 38.3$  PU, after 4 min of TNP application  $155.3 \pm 34.3$  PU, after 5 min of TNP application  $126.0 \pm 32.2$  PU, after 6 min of TNP application  $139.2 \pm 28.4$  PU, after 7 min of TNP application  $132.5 \pm 26.4$  PU, after 8 min of TNP application  $119.2 \pm 29.4$  PU, after 9 min of TNP application

$143.0 \pm 38.3$  PU, after 10 min of TNP application  $131.2 \pm 40.8$  PU, after 11 min of TNP application  $124.8 \pm 40.5$  PU, after 12 min of TNP application  $114.3 \pm 34.4$  PU, after 13 min of TNP application  $123.2 \pm 28.8$  PU, after 14 min of TNP application  $121.8 \pm 37.2$  PU, after 15 min of TNP application  $125.5 \pm 36.4$  PU, after 16 min of TNP application  $137.5 \pm 45.7$  PU, after 17 min of TNP application  $128.8 \pm 34.5$  PU, after 18 min of TNP application  $121.3 \pm 34.2$  PU, after 19 min of TNP application  $121.7 \pm 29.0$  PU; and finally after 20 min of TNP application, the mean microvascular blood flow was  $120.5 \pm 27.8$  PU (Fig. 1).

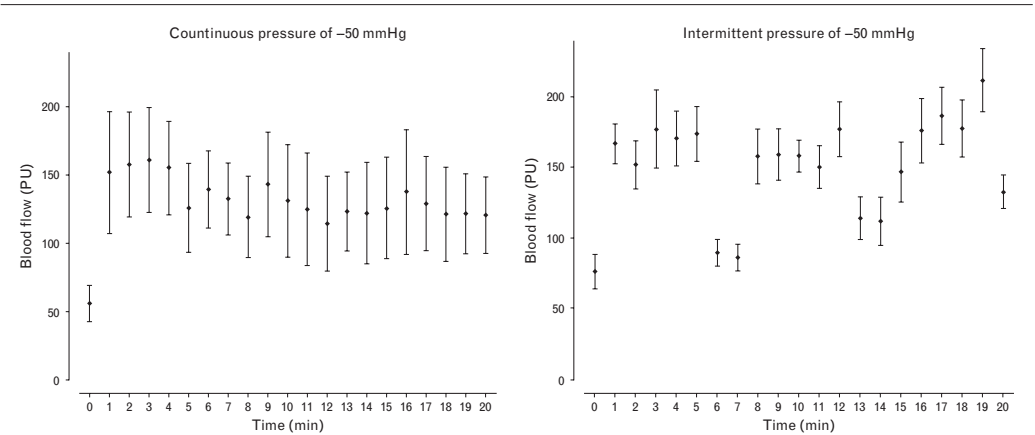
In summary, application of a TNP of  $-50$  mmHg for 20 min induced a significant increase in total mean microvascular blood flow ( $56.2 \pm 13.1$  PU before TNP application to  $132.8 \pm 7.4$  PU during TNP application;  $*P < 0.05$ ) (Figs 1 and 2). The increase in microvascular blood flow did not change over time, when comparing 1 and 18 min of continuous TNP application ( $151.8 \pm 44.6$  PU after 1 min and  $121.3 \pm 34.2$  PU after 18 min of TNP;  $*P > 0.05$ ).

#### Intermittent topical negative pressure

Intermittent TNP of  $-50$  mmHg was applied, with 5 min on periods followed by 2 min off periods for a total duration of 20 min. Measurements were made before TNP was applied and after every minute of TNP application (both on and off periods of TNP included). The mean values and SEM for each measurement are given below. Before TNP was applied, mean microvascular blood flow was  $75.8 \pm 12.1$  PU, and after 1 min of TNP application  $166.7 \pm 14.0$  PU, after 2 min of TNP application  $151.7 \pm 17.3$  PU, after 3 min of TNP application  $177.0 \pm 27.9$  PU, after 4 min of TNP application  $170.3 \pm 19.3$  PU, after 5 min of TNP application  $173.8 \pm 19.7$  PU, after 6 min  $89.2 \pm 9.2$  PU (off period), after 7 min  $85.8 \pm 9.9$  PU (off period), after 8 min of TNP application  $157.5 \pm 19.2$  PU, after 9 min of TNP application  $158.8 \pm 18.3$  PU, after 10 min of TNP application  $158.0 \pm 11.4$  PU, after 11 min of TNP application  $150.0 \pm 15.2$  PU, after 12 min of TNP application  $177.0 \pm 19.6$  PU, after 13 min  $113.7 \pm 15.5$  PU (off period), after 14 min  $11.7 \pm 17.1$  PU (off period), after 15 min of TNP application  $146.7 \pm 21.2$  PU, after 16 min of TNP application  $175.8 \pm 22.8$  PU, after 17 min of TNP application  $186.5 \pm 20.3$  PU, after 18 min of TNP application  $177.5 \pm 20.1$  PU, after 19 min of TNP application  $211.7 \pm 22.6$  PU; and after 20 min of TNP application, the mean microvascular blood flow was  $132.5 \pm 12.0$  PU (Fig. 1).

In summary, intermittent TNP (5 min on, 2 min off) of  $-50$  mmHg for 20 min induced a significant increase in total mean microvascular blood flow [ $75.8 \pm 12.1$  PU before TNP application to  $153.6 \pm 4.7$  PU during TNP

Fig. 1



Microvascular blood flow (measured using laser Doppler velocimetry) in ischemic myocardium continuously exposed to a topical negative pressure of  $-50$  mmHg for 20 min (left panel) and intermittently exposed, 5 min with TNP followed by 2 min without, for 20 min (right panel). The measurements were performed in six pigs at a depth at 5–6 mm in the myocardium. The error bars shown 1 SEM. PU, perfusion units.

application (both on and off periods included);  $*P < 0.05]$  (Figs 1 and 2). The increase in microvascular blood flow did not change over time, when comparing 1 and 18 min of intermittent TNP application ( $166.7 \pm 14.0$  PU

after 1 min and  $177.5 \pm 20.1$  PU after 18 min of TNP;  $*P > 0.05$ ).

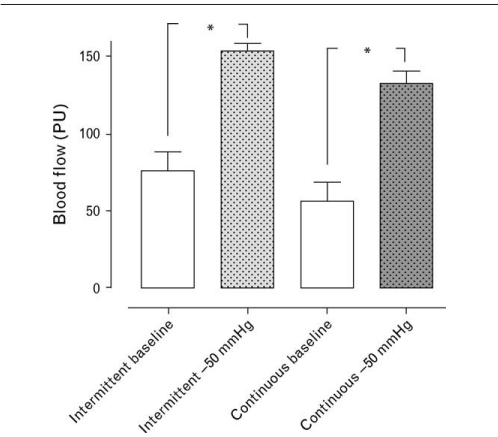
#### Intermittent topical negative pressure versus continuous topical negative pressure

Blood flow was stimulated to similar degrees by continuous and intermittent TNP. The increase in microvascular blood flow during continuous TNP was  $3473 \pm 1536\%$  PU and the increase during intermittent TNP was  $2579 \pm 778\%$  PU (the mean of on and off periods) ( $*P > 0.05$ ). The increase is expressed as the percentage additive effect during the 20-min period studied (Figs 1 and 2).

#### Discussion

Poststernotomy mediastinitis is a serious and potentially life-threatening complication, with a high mortality rate and substantial morbidity. It is also a strong predictor of poor long-term survival after coronary artery by-pass surgery (CABG) [16–21]. In a large study including 36 078 patients, Braxton *et al.* [19] demonstrated that actuarial survival 10 years after CABG was 39% in patients with mediastinitis and 70% in patients without mediastinitis. Milano *et al.* [18] have suggested that mediastinitis may cause negative long-term effects on several organs such as the heart and kidneys. Theoretically, a massive immunological response during a prolonged period of infection may cause adverse effects on bypass grafts. In the above-mentioned studies reporting poor long-term survival after mediastinitis, several conventional wound-healing techniques were used (closed irrigation, delayed wound closure or reconstruction with omentum or pectoral flaps). A recently published study

Fig. 2



Microvascular blood flow (measured using laser Doppler velocimetry) in ischemic myocardium exposed to topical negative pressures of  $-50$  mmHg continuously during a time period of 20 min, and cyclic pressure of 5 min with  $-50$  mmHg followed by 2 min of 0 mmHg, during a time period of 20 min. The measurements were performed in six pigs at a depth at 5–6 mm in the myocardium. The differences between baseline values and blood flow during TNP were significant for both modes of pressure application. Mean value  $\pm$  SEM from six pigs is shown.  $*P < 0.05$ .

[5] by our group showed no difference in long-term survival between CABG patients with TNP-treated mediastinitis and those without mediastinitis. The reason for this remains unclear, but it may be that as the TNP is in direct contact with the heart, which is exposed through the diastase of the sternotomy, these patients may have developed increased collateral coronary blood vessels during TNP, and may therefore be better prepared when bypass grafts fail to work. This may, in part, explain the reduced long-term mortality.

The physiological, cellular and molecular mechanisms by which TNP accelerates wound healing are still not known in detail. Nevertheless, the known effects of TNP are enhanced blood flow to the wound edges and granulation tissue formation [6,7]. TNP increases blood flow and opens up the capillary beds. The mechanical force exerted by TNP and increased blood flow affect the cytoskeleton in the vascular cells, stimulating endothelial proliferation, capillary budding and angiogenesis, that is granulation tissue formation [8,9,22]. Intermittent application of subatmospheric pressure (5 min of pressure, followed by 2 min without) seems to alter the cytoskeleton of the cells in the wound bed, triggering a cascade of intracellular signals that increases the rate of cell division and subsequent formation of granulation tissue, and thus angiogenesis [6].

Morykwas *et al.* [6] compared the continuous and intermittent pressure therapy modes (5 min on and 2 min off) in subcutaneous and muscular tissue and found that continuous application of TNP of  $-125$  mmHg resulted in an average increase in new granulation tissue formation of approximately 60%, whereas intermittent application of TNP at the same pressure resulted in an average increase of approximately 100%, compared with the control, after 2 weeks of TNP. They also found that microvascular blood flow increased to four times the baseline value when a TNP of  $-125$  mmHg was applied, whereas it was reduced at negative pressures of 400 mmHg and greater. During continuous TNP, they observed a decrease in perfusion after 5–7 min. After an initial increase in perfusion, the increased microvascular blood flow decreased permanently to the baseline value or below. The tissue type and distance from the wound edge were, however, not considered in the above-mentioned study.

Wackenfors *et al.* [23] demonstrated that TNP elicits an increase in microvascular blood flow a few centimeters from the wound edge. The peak increase in blood flow was found to occur closer to the wound edge in muscular than in subcutaneous tissue. In the immediate proximity of the wound edge, a zone of relative hypoperfusion was observed. This zone was larger at high negative pressures and was especially prominent in subcutaneous tissue. The extent of the hypoperfusion zone in subcutaneous

and muscular tissue appeared to depend on the amount of pressure applied, the distance from the vacuum source and the density of the tissue [23]. A minimal zone of hypoperfusion may be beneficial, as it is well known that hypoxia induces angiogenesis and revascularization of tissues. On the contrary, long-standing hypoperfusion may cause ischemia. To balance these effects, a negative pressure that does not cause a large ischemic zone may be preferable.

In a previous report, we applied a TNP of  $-50$  mmHg over the LAD region on six pigs and were able to show a significant increase in microvascular blood flow in normal myocardium (nonischemic myocardium), in ischemic myocardium after 20 min of LAD occlusion and also in reperfused myocardium (former ischemic myocardium after 20 min of reperfusion). The increase in microvascular blood flow appeared immediately as the pressure of  $-50$  mmHg was applied. Measurements were made after steady state, which was approximately 10–30 s of TNP application. The negative pressure was then removed in all three experiments [13]. We have also demonstrated that among TNP pressure levels between  $-50$  and  $-150$  mmHg only,  $-50$  mmHg results in a significant increase in myocardial microvascular blood flow [14]. In the present study, we have shown that both continuous myocardial TNP and intermittent TNP of  $-50$  mmHg for 20 min result in a significant increase in myocardial microvascular blood flow (Fig. 1). During intermittent TNP, the mean microvascular blood flow had a tendency to increase during the experiment; however, this increase was not significant. During the 2 min without pressure, the microvascular blood flow returned almost to the baseline value in the first cycle, but seemed to return to ever-increasing pressure levels above baseline as the experiment proceeded. This increase was, however, not significant. When comparing continuous and intermittent myocardial TNP, no significant difference in microvascular blood flow was observed. The increase in microvascular blood flow is greater during the first 5 min of TNP application in both settings, as seen in Fig. 1. The results are not fully understood but might be explained by a massive opening of the capillary beds during the first few minutes of the application of TNP, which might explain the higher blood flow during this phase. Moreover, the increase in microvascular blood flow during the first 5 min showed no statistically significant difference from the increase in microvascular blood flow during last 5 min and might therefore be analyzed with caution. The hypothesis could not be deduced by the results in the present study.

Patients with refractory angina pectoris represent a difficult problem due to the absence of a proven effective treatment. Many different therapies have been tried, such as percutaneous myocardial laser revascularization [24] and enhanced external counter-pulsation [25], with

AQ2

varying results. Spinal cord stimulation has been used in an attempt to ease their ischemic pain, also with unsatisfactory results [26]. Therapeutic angiogenesis, wherein exogenous growth factors are administered to ischemic tissue to enhance collateral vessel formation, revascularization and reperfusion, has been investigated as a potential means of treating patients with refractory angina pectoris. Laboratory results have been promising, but clinical studies have not shown satisfactory results. Vascular endothelial growth factor (VEGF) proteins have been shown to play a key role in the modulation of angiogenesis and vascular growth [27,28]. Interestingly, TNP produces a mechanical shear stress that is known to activate endogenous VEGF [29–33].

No-reflow sometimes occurs when using percutaneous coronary intervention (PCI) to treat cases of acute ST-elevation myocardial infarction. The treatment of established no-reflow is mainly pharmacological, as the obstruction occurs at the microvasculature level. Compared with patients in whom no-reflow is transient, refractory no-reflow is associated with a markedly increased risk of 30-day mortality [34,35]. To apply TNP at those areas in the acute phase, with for example a transthoracic device, might be useful for those patients. The method might also, in the future, serve as an alternative treatment for patients with extensive coronary artery disease, as VEGF proteins, that are also stimulated by TNP [29–33], have been shown to play a key role in the modulation of angiogenesis and vascular growth [27,28]. Of course, a treatment period over 2–3 weeks would be needed concerning neo-revascularization.

In conclusion, both continuous and intermittent TNP of –50 mmHg for 20 min significantly increase microvascular blood flow in the underlying myocardium. No significant difference in the increase in microvascular blood flow was observed between the two kinds of pressure application. Results from studies carried out by others, however, indicate that intermittent TNP probably causes a greater increase in granulation tissue formation than continuous TNP, during long-term use.

Acknowledgement

We would like to thank Johan Ingemansson (Statistical Solutions IP) for his expert contribution to the statistical analyses.

Funding sources: This study was supported by Anders Otto Swärd’s Foundation/Ulrika Eklund’s Foundation, Anna Lisa and Sven Eric Lundgren’s Foundation for Medical Research, the Åke Wiberg Foundation, the M. Bergvall Foundation, the Swedish Medical Association, the Royal Physiographic Society in Lund, the Swedish Medical Research Council, the Crafoord Foundation, the Swedish Heart-Lung Foundation, the Swedish Govern-

ment Grant for Clinical Research and the Swedish Hypertension Society.

References

- 1 Sjogren J, Gustafsson R, Nilsson J, Malmso M, Ingemansson R. Clinical outcome after poststernotomy mediastinitis: vacuum-assisted closure versus conventional treatment. *Ann Thorac Surg* 2005; **79**:2049–2055.
- 2 Gustafsson RI, Sjogren J, Ingemansson R. Deep sternal wound infection: a sternal-sparing technique with vacuum-assisted closure therapy. *Ann Thorac Surg* 2003; **76**:2048–2053; [discussion 2053].
- 3 Petzina R, Gustafsson L, Mokhtari A, Ingemansson R, Malmso M. Effect of vacuum-assisted closure on blood flow in the peristernal thoracic wall after internal mammary artery harvesting. *Eur J Cardiothorac Surg* 2006; **30**:85–89.
- 4 Domkowski PW, Smith ML, Gonyon DL Jr, Drye C, Wooten MK, Levin LS, Wolfe WG. Evaluation of vacuum-assisted closure in the treatment of poststernotomy mediastinitis. *J Thorac Cardiovasc Surg* 2003; **126**:386–390.
- 5 Sjogren J, Nilsson J, Gustafsson R, Malmso M, Ingemansson R. The impact of vacuum-assisted closure on long-term survival after poststernotomy mediastinitis. *Ann Thorac Surg* 2005; **80**:1270–1275.
- 6 Morykwas MJ, Argenta LC, Shelton-Brown EI, McGuirt W. Vacuum-assisted closure: a new method for wound control and treatment: animal studies and basic foundation. *Ann Plast Surg* 1997; **38**:553–562.
- 7 Argenta LC, Morykwas MJ. Vacuum-assisted closure: a new method for wound control and treatment: clinical experience. *Ann Plast Surg* 1997; **38**:563–576; [discussion 577].
- 8 Saxena V, Hwang CW, Huang S, Eichbaum Q, Ingber D, Orgill DP. Vacuum-assisted closure: microdeformations of wounds and cell proliferation. *Plast Reconstr Surg* 2004; **114**:1086–1096; [discussion 1097–1088].
- 9 Greene AK, Puder M, Roy R, Arsenaault D, Kwei S, Moses MA, Orgill DP. Microdeformational wound therapy: effects on angiogenesis and matrix metalloproteinases in chronic wounds of 3 debilitated patients. *Ann Plast Surg* 2006; **56**:418–422.
- 10 Genecov DG, Schneider AM, Morykwas MJ, Parker D, White WL, Argenta LC. A controlled subatmospheric pressure dressing increases the rate of skin graft donor site reepithelialization. *Ann Plast Surg* 1998; **40**:219–225.
- 11 Chen CS, Mksich M, Huang S, Whitesides GM, Ingber DE. Micropatterned surfaces for control of cell shape, position, and function. *Biotechnol Prog* 1998; **14**:356–363.
- 12 Urschel JD, Scott PG, Williams HT. The effect of mechanical stress on soft and hard tissue repair; a review. *Br J Plast Surg* 1988; **41**:182–186.
- 13 Lindstedt S, Malmso M, Ingemansson R. Blood flow changes in normal and ischemic myocardium during topically applied negative pressure. *Ann Thorac Surg* 2007; **84**:568–573.
- 14 Lindstedt S, Malmso M, Sjogren J, Gustafsson R, Ingemansson R. Impact of different topical negative pressure levels on myocardial microvascular blood flow. *Cardiovasc Revasc Med* (in press).
- 15 Zografos GC, Martis K, Morris DL. Laser Doppler flowmetry in evaluation of cutaneous wound blood flow using various suturing techniques. *Ann Surg* 1992; **215**:266–268.
- 16 Lu JC, Grayson AD, Jha P, Srinivasan AK, Fabri BM. Risk factors for sternal wound infection and mid-term survival following coronary artery bypass surgery. *Eur J Cardiothorac Surg* 2003; **23**:943–949.
- 17 Loop FD, Lytle BW, Cosgrove DM, Mahfood S, McHenry MC, Goomastic M, et al. Maxwell Chamberlain memorial paper. Sternal wound complications after isolated coronary artery bypass grafting: early and late mortality, morbidity, and cost of care. *Ann Thorac Surg* 1990; **49**:179–186; [discussion 186–177].
- 18 Milano CA, Kesler K, Archibald N, Sexton DJ, Jones RH. Mediastinitis after coronary artery bypass graft surgery. Risk factors and long-term survival. *Circulation* 1995; **92**:2245–2251.
- 19 Braxton JH, Marrin CA, McGrath PD, Ross CS, Morton JR, Norotsky M, et al. Mediastinitis and long-term survival after coronary artery bypass graft surgery. *Ann Thorac Surg* 2000; **70**:2004–2007.
- 20 Toumpoulis IK, Anagnostopoulos CE, Derosé JJ Jr, Swistel DG. The impact of deep sternal wound infection on long-term survival after coronary artery bypass grafting. *Chest* 2005; **127**:464–471.
- 21 Stahle E, Tammelin A, Bergstrom R, Hambreus A, Nystrom SO, Hansson HE. Sternal wound complications: incidence, microbiology and risk factors. *Eur J Cardiothorac Surg* 1997; **11**:1146–1153.
- 22 Vandenburgh HH. Mechanical forces and their second messengers in stimulating cell growth in vitro. *Am J Physiol* 1992; **262**:R350–R355.

- 23 Wackenfors A, Gustafsson R, Sjogren J, Algotsson L, Ingemansson R, Malmstro M. Blood flow responses in the peristernal thoracic wall during vacuum-assisted closure therapy. *Ann Thorac Surg* 2005; **79**:1724–1730; [discussion 1730–1721].
- 24 Leon MB, Kornowski R, Downey WE, Weisz G, Baim DS, Bonow RO, *et al.* A blinded, randomized, placebo-controlled trial of percutaneous laser myocardial revascularization to improve angina symptoms in patients with severe coronary disease. *J Am Coll Cardiol* 2005; **46**:1812–1819.
- 25 Cohn PF. Enhanced external counterpulsation for the treatment of angina pectoris. *Prog Cardiovasc Dis* 2006; **49**:88–97.
- 26 Deer TR, Raso LJ. Spinal cord stimulation for refractory angina pectoris and peripheral vascular disease. *Pain Physician* 2006; **9**:347–352.
- 27 Rosengart TK, Lee LY, Patel SR, Kligfield PD, Okin PM, Hackett NR, *et al.* Six-month assessment of a phase I trial of angiogenic gene therapy for the treatment of coronary artery disease using direct intramyocardial administration of an adenovirus vector expressing the VEGF121 cDNA. *Ann Surg* 1999; **230**:466–470; [discussion 470–462].
- 28 Rosengart TK, Lee LY, Patel SR, Sanborn TA, Parikh M, Bergman GW, *et al.* Angiogenesis gene therapy: phase I assessment of direct intramyocardial administration of an adenovirus vector expressing VEGF121 cDNA to individuals with clinically significant severe coronary artery disease. *Circulation* 1999; **100**:468–474.
- 29 Chen KD, Li YS, Kim M, Li S, Yuan S, Chien S, Shyy JY. Mechanotransduction in response to shear stress. Roles of receptor tyrosine kinases, integrins, and Shc. *J Biol Chem* 1999; **274**:18393–18400.
- 30 Detmar M, Brown LF, Berse B, Jackman RW, Elicker BM, Dvorak HF, Claffey KP. Hypoxia regulates the expression of vascular permeability factor/vascular endothelial growth factor (VPF/VEGF) and its receptors in human skin. *J Invest Dermatol* 1997; **108**:263–268.
- 31 Shyu KG, Chang ML, Wang BW, Kuan P, Chang H. Cyclical mechanical stretching increases the expression of vascular endothelial growth factor in rat vascular smooth muscle cells. *J Formos Med Assoc* 2001; **100**:741–747.
- 32 Milkiewicz M, Mohammadzadeh F, Ispanovic E, Gee E, Haas TL. Static strain stimulates expression of matrix metalloproteinase-2 and VEGF in microvascular endothelium via JNK- and ERK-dependent pathways. *J Cell Biochem* 2007; **100**:750–761.
- 33 Seko Y, Seko Y, Takahashi N, Shibuya M, Yazaki Y. Pulsatile stretch stimulates vascular endothelial growth factor (VEGF) secretion by cultured rat cardiac myocytes. *Biochem Biophys Res Commun* 1999; **254**:462–465.
- 34 Kang S, Yang Y. Coronary microvascular reperfusion injury and no-reflow in acute myocardial infarction. *Clin Invest Med* 2007; **30**:E133–E145.
- 35 van Gaal WJ, Banning AP. Percutaneous coronary intervention and the no-reflow phenomenon. *Expert Rev Cardiovasc Ther* 2007; **5**:715–731.

<b>JCM</b>
Manuscript No. 200574

**Journal of Cardiovascular Medicine  
Typeset by Thomson Digital  
for Lippincott Williams & Wilkins**

Dear Author,

During the preparation of your manuscript for typesetting, some queries have arisen. These are listed below. Please check your typeset proof carefully and mark any corrections in the margin as neatly as possible or compile them as a separate list. This form should then be returned with your marked proof/list of corrections to the Production Editor.

<b>QUERIES: to be answered by AUTHOR/EDITOR</b>		
<b>AUTHOR:</b> The following queries have arisen during the editing of your manuscript. Please answer the queries by marking the requisite corrections at the appropriate positions in the text.		
QUERY NO.	QUERY DETAILS	
<AQ1>	Please check the information furnished for the following manufacturers for correctness: Medcompare, Siemens Elema 300A, Lilly, AstraZeneca.	
<AQ2>	Please check the edit in the sentence ``Moreover, ...caution".	
<AQ3>	Please update Ref. [14] by providing complete publication details such as volume, year of publication, and page range.	

