



LUND UNIVERSITY

Gene therapy in a new model of delayed wound healing

Velander, Patrik

2010

[Link to publication](#)

Citation for published version (APA):

Velander, P. (2010). *Gene therapy in a new model of delayed wound healing*. [Doctoral Thesis (compilation), Surgery]. Lund University.

Total number of authors:

1

General rights

Unless other specific re-use rights are stated the following general rights apply:

Copyright and moral rights for the publications made accessible in the public portal are retained by the authors and/or other copyright owners and it is a condition of accessing publications that users recognise and abide by the legal requirements associated with these rights.

- Users may download and print one copy of any publication from the public portal for the purpose of private study or research.
- You may not further distribute the material or use it for any profit-making activity or commercial gain
- You may freely distribute the URL identifying the publication in the public portal

Read more about Creative commons licenses: <https://creativecommons.org/licenses/>

Take down policy

If you believe that this document breaches copyright please contact us providing details, and we will remove access to the work immediately and investigate your claim.

LUND UNIVERSITY

PO Box 117
221 00 Lund
+46 46-222 00 00

GENE THERAPY IN A NEW MODEL OF DELAYED WOUND HEALING

Patrik Velander

AKADEMISK AVHANDLING

Som för avläggande av doktorsexamen vid Lunds Universitet kommer att offentligen försvaras i Medicinska klinikens aula, ingång 35, Skånes universitetssjukhus, Malmö, torsdagen den 21 oktober 2010 kl 13.00

Fakultetsopponent: Professor Anders Lindahl, Avd. För klinisk kemi och transfusionsmedicin, Göteborgs universitet




Department of Plastic and Reconstructive Surgery
Skåne University Hospital
Department of Clinical Sciences, Malmö
Faculty of Medicine
Lund University
2010

Organization LUND UNIVERSITY Department of Plastic and Reconstructive Surgery Skåne University Hospital Department of Clinical Sciences, Malmö Faculty of medicine	Document name DOCTORAL DISSERTATION	
	Date of issue 2010-09-09	
Author(s) Patrik Velander	Sponsoring organization	
Title and subtitle GENE THERAPY IN A NEW MODEL OF DELAYED WOUND HEALING		
Abstract Diabetes wounds result in significant morbidity, prolonged hospitalization and huge health care expenses. As of yet, no optimal animal models of diabetic wound healing exist to study potential beneficial therapies. Porcine wound healing is very similar to human wound healing. We stipulated that by inducing diabetes in yorkshire pigs, wound healing would be delayed and exhibit abnormalities similar to those seen in human diabetic wound healing. Furthermore we hypothesized that cell therapy and gene therapy may enhance epidermal healing in this model of delayed wound healing. In study one, we establish a delayed wound healing model in yorkshire pigs, mimicking diabetic wound healing, by injecting streptozotocin intravenously. High serum glucose was established and wound healing was considerably delayed and showed alterations in the intrinsic pathways. In study two, transplantation of suspensions of fibroblasts or keratinocytes enhanced re-epithelialization in this new model of delayed wound healing. In study three, the beneficial effect of transplanting keratinocytes seen in study two was enhanced by transfecting keratinocytes with a plasmid coding for IGF-1. Results showed a substantial over expression of IGF-1 in the wound as well as improved epidermal healing in the treated group. In study four, the beneficial effect of allogenic cells transfected with EGF was shown in healthy non-diabetic pigs. In study five, the beneficial effect of EGF seen in study four, was taken into account and autologous keratinocytes transfected with EGF were transplanted into cutaneous wounds in our model of delayed wound healing. Clear beneficial effects were demonstrated. Collectively, we demonstrate a new model of delayed wound healing in the pig which mimicks deficiencies seen in diabetic wounds. We were able to accelerate wound healing in this model by using cell therapy and further improved it using gene therapy.		
Key words: Diabetes, Animal model, Gene therapy, IGF-1, EGF		
Classification system and/or index termes (if any):		
Supplementary bibliographical information:	Language English	
ISSN and key title: 1652-8220 Faculty of Medicine Doctoral Dissertation Series 2010:86	ISBN 978-91-86671-02-0	
Recipient's notes	Number of pages 108	Price
	Security classification	

Distribution by (name and address)

I, the undersigned, being the copyright owner of the abstract of the above-mentioned dissertation, hereby grant to all reference sources permission to publish and disseminate the abstract of the above-mentioned dissertation.

Signature



Date 2010-09-09

GENE THERAPY IN A NEW MODEL OF DELAYED WOUND HEALING



LUND UNIVERSITY
Faculty of Medicine

Patrik Velander
Department of Plastic and Reconstructive
Surgery
Skåne University Hospital
Department of Clinical Sciences, Malmö
Faculty of medicine
Lund University
2010

Copyright ©
Patrik Velander 2010

ISSN 1652-8220

ISBN 978-91-86671-02-0

Lund University, Faculty of Medicine Doctoral Dissertation Series 2010:86

Printed by Media-Tryck, Lund University, Lund, Sweden 2010

Dimidium facti qui coepit habet

Quintus horacius flaccus (65-8 bc)

To my parents, Kerstin & Erik

Contents

Abstract	9
List of Publications	11
Background	13
Wound healing	13
Diabetes	14
Wound healing and diabetes	14
Aims	17
Material and Methods	19
Animals	19
Induction of Diabetes (papers I, II, III & V)	19
Harvesting of skin cells	20
Cell Culture	20
Transfection	20
Lac-Z staining and transfection efficiency	22
Wounding and chamber treatment	22
Cell transplantation (paper II-V)	23
Wound contraction	24
Histology	24
Re-epithelialization measurements	24
Measurements of growth factor and protein	25
Statistics	25
Results and Comments	27
Paper I	27
Paper II	29
Paper III	32
Paper IV	34
Paper V	36
Discussion	39
Research models	39
In vitro studies	39
In vivo studies	39
Diabetes	40
Chamber Model	41

Cell transplantation	42
Gene Therapy	43
Growth factors	43
Epithelialization	45
Conclusion	47
Future directions	49
Populärvetenskaplig sammanfattning (summary in swedish)	51
Acknowledgements	53
References	55

Abstract

Diabetes wounds result in significant morbidity, prolonged hospitalization and huge health care expenses. As of yet, no optimal animal models of diabetic wound healing exist to study potential beneficial therapies. Porcine wound healing is very similar to human wound healing. We stipulated that by inducing diabetes in yorkshire pigs, wound healing would be delayed and exhibit abnormalities similar to those seen in human diabetic wound healing. Furthermore we hypothesized that cell therapy and gene therapy may enhance epidermal healing in this model of delayed wound healing.

In study one, we establish a delayed wound healing model in yorkshire pigs, mimicking diabetic wound healing, by injecting streptozotocin intravenously. High serum glucose was established and wound healing was considerably delayed and showed alterations in the intrinsic pathways.

In study two, transplantation of suspensions of fibroblasts or keratinocytes enhanced re-epithelialization in this new model of delayed wound healing.

In study three, the beneficial effect of transplanting keratinocytes seen in study two was enhanced by transfecting keratinocytes with a plasmid coding for IGF-1. Results showed a substantial over expression of IGF-1 in the wound as well as improved epidermal healing in the treated group.

In study four, the beneficial effect of allogenic cells transfected with EGF was shown in healthy non-diabetic pigs.

In study five, the beneficial effect of EGF seen in study four, was taken into account and autologous keratinocytes transfected with EGF were transplanted into cutaneous wounds in our model of delayed wound healing. Clear beneficial effects were demonstrated.

Collectively, we demonstrate a new model of delayed wound healing in the pig which mimicks deficiencies seen in diabetic wounds. We were able to accelerate wound healing in this model by using cell therapy and further improved it using gene therapy.

List of Publications

In the text, studies will be referred by their roman numerals.

Paper I:

Impaired wound healing in an acute diabetic pig model and the effects of local hyperglycemia.

Velander P, Theopold C, Hirsch T, Bleiziffer O, Zuhaili B, Fossum M, Hoeller D, Gheerardyn R, Chen M, Visovatti S, Svensson H, Yao F, Eriksson E.

Wound Repair Regen. 2008 Mar-Apr;16(2):288-93.

Paper II:

Cell suspensions of autologous keratinocytes or autologous fibroblasts accelerate the healing of full thickness skin wounds in a diabetic porcine wound healing model.

Velander P, Theopold C, Bleiziffer O, Bergmann J, Svensson H, Feng Y, Eriksson E.

J Surg Res. 2009 Nov;157(1):14-20.

Paper III:

Insulin-like growth factor-1 gene therapy and cell transplantation in diabetic wounds.

Hirsch T, Spielmann M, Velander P, Zuhaili B, Bleiziffer O, Fossum M, Steinstraesser L, Yao F, Eriksson E.

J Gene Med. 2008 Nov;10(11):1247-52.

Paper IV:

Cell suspension cultures of allogenic keratinocytes are efficient carriers for ex vivo gene transfer and accelerate the healing of full-thickness skin wounds by overexpression of human epidermal growth factor.

Vranckx JJ, Hoeller D, Velander PE, Theopold CF, Petrie N, Takedo A, Eriksson E, Yao F.

Wound Repair Regen. 2007 Sep-Oct;15(5):657-64.

Paper V:

Cell suspensions of autologous keratinocytes transfected with PCEp4-EGF accelerate the healing of full thickness skin wounds in a diabetic porcine model and serve as efficient vectors for ex-vivo gene transfer

Velander P, Theopold C, Bleiziffer O, Svensson H, Yao F, Eriksson E. Manuscript

Background

A short outline of the two main topics described in this thesis follows to help in interpreting the main findings of the present studies.

Wound healing

Injury to skin results in a complex and well regulated cascade of events as the body tries to repair itself. The four phases of wound healing: hemostasis, inflammation proliferation and remodeling overlap with each other in a well orchestrated matter.

Within minutes of an injury to skin, platelets aggregate, form a fibrin plug to limit bleeding (hemostasis), and express a number of inflammatory factors (cytokines, growth factors, serotonin, bradykinin, prostaglandin, prostacyclins, thromboxane and histamine) to start the inflammatory phase¹. Capillaries dilate and inflammatory cells (neutrophils and macrophages) migrate to the wound bed².

Neutrophils are the body's scavengers clearing the wound of debris and bacteria. Macrophages are the most important mediators of wound healing. They release growth factors attracting fibroblasts allowing the wound healing process to enter the proliferative stage, two to three days after the injury³. In this phase, new blood vessels are formed bringing oxygen and nutrients to feed the fibroblasts accumulating in the wound. During two to four weeks, fibroblasts secrete collagen and construct a provisional extra cellular matrix facilitating cell migration. Once this tissue is viable, keratinocytes, the predominant cell type in the outermost layer of skin, migrate over the wound site. Keratinocyte proliferation start at the wound edges and stops by contact inhibition when cells meet in the middle⁴. Contraction also occurs in the proliferative stage. Fibroblasts are stimulated by growth factors and differentiate into myofibroblasts which connect the extra cellular matrix to the wound edges. As the myofibroblast contract, the wound edges are brought closer together decreasing the size of the wound. At the same time, fibroblasts secrete collagen onto these links, reinforcing the wound. Once sufficient strength is reached, fibroblasts gradually stop migrating and proliferating signaling the start of the remodeling phase.

Remodeling involves maturation of the wound. Collagen is realigned along tension lines giving extra strength and excessive cells are removed. This process can last from 6 months to one year. The final wound strength will approach 80 % of the strength of uninjured tissue⁵.

In wound healing, growth factors coordinate the complex processes involved in cell migration, division, differentiation and protein expression⁶. Different families of growth factors exist and they are expressed in varying levels during different phases by cells involved with healing⁷.

The process of wound healing is not only complex but also fragile. Different factors may lead to the formation of chronic non-healing wounds. Diabetes is one of the most common contributing factors to poor healing.

Diabetes

Diabetes mellitus is a chronic disorder of glucose homeostasis due to the body's inability to produce or use insulin. It affects about 7-8% of the population in the United States (Center for disease control, National diabetes fact sheet 2007). It is the only metabolic disease that is approaching worldwide pandemic levels. The incidence of diabetes is increasing dramatically primarily because of a rise in obesity and old age.

The first reference of diabetes is thought to date back to an egyptian papyrus from 1550BC that described a disease causing weight loss and excessive urination.

However, a greek physician named Aretaeus (30-90AD) was the first to give a name to a disease causing constant thirst, excessive urination and loss of weight. He named it diabetes (a flowing through). In 1675, Thomas Willis added the word mellitus (honey in latin) as a reference to the sweet taste of the urine. Sir Frederick Grant Banting was the first to purify insulin from bovine pancreas which led to the first patient treatment in 1922. Insulin injection is still part of the treatment today along with controlled nutrition and exercise. Sir Banting was recognized for his achievement with a Nobel prize in 1923⁸.

Throughout the 20th century, treatment and understanding of the disease has advanced significantly. Although prevention and management remains difficult, the life of an average diabetic person is becoming both longer and easier all the time.

Wound healing and diabetes

Wound healing is greatly delayed in diabetes mellitus. Both extrinsic and intrinsic factors contribute to the poor healing in diabetic wounds^{9 10}. Neuropathy, which leads to poor protective sensation, and atherosclerosis, which leads to poor blood flow to the wound, are examples of extrinsic factors¹¹.

Many changes in the intrinsic factors have been demonstrated such as a delayed inflammatory process, high sugar concentration in the wound leading to the formation of advanced end glycation products (AGE)¹² and free oxygen radicals¹³. The concentration of proteases is increased in diabetic wounds. This leads to an abnormally high level of

protein degradation in the wound which results in defective scaffolds upon which cells find it difficult to attach which in turn reduces cell proliferation¹⁴⁻¹⁶.

Delayed wound healing is a big problem in diabetes. Fifteen to twenty five percent of people with diabetes will suffer a wound problem in their lifetime¹⁷. More than 60 % of non traumatic lower limb amputations occur in people with diabetes¹⁸. This leads to pain, physical limitations and psychosocial distress.

Debridement of the wound with or without split skin grafting remains the treatment of choice today. Several new treatments are under investigations in different animal models but have not shown results in keeping with expectations. One contributing factor may be the models used in diabetic wound healing research. Numerous diabetic wound models have been described in mice, such as db mice and ob mice, and there are also models in rats and rabbits.¹⁹⁻²³ However the wound healing physiology in small loose skin mammals differ greatly from human wound healing. Porcine skin physiology and wound healing has been found to be significantly more similar to that of man²⁴. A diabetic porcine wound healing model may therefore be a better model to develop aimed at evaluating new treatment modalities.

Aims

The main objective of this thesis was to develop a new model of delayed cutaneous wound healing that could be used to study new treatment modalities for diabetic wounds. Treatment focus was directed at defective cell function and altered growth factor levels seen in diabetic wounds.

More specifically:

1. To develop a new model of delayed wound healing
2. To study the effect of transplanting keratinocytes or fibroblasts in cutaneous wounds in this new delayed wound healing model
3. To study the effect of over expressing insulin like growth factor 1 (IGF-1) in the wound microenvironment in the delayed wound healing model
4. To study the effect of transplanting allogenic cells tranfected with epidermal growth factor (EGF) in normal healthy pigs
5. To study the effect of over expressing epidermal growth factor (EGF) in cutaneous wounds in the diabetic pig

Material and Methods

Animals

Female pigs (Parson's Farm, Westhampton, MA) weighing 60 kg at arrival were allowed to acclimatize for one week prior to the initiation of any experiment. They were kept in smooth walled stainless steel cages to minimize wound trauma and disruption of applied wound chamber. The animal protocol was approved by the Harvard Medical Area Standing Committee on Animals and all operative procedures took place in a specialized operation room under sterile conditions.

Anesthesia was induced according to our laboratory protocol. The animals were premedicated with an intramuscular injection of Ketamine (Hospira, Lake Forest, IL)/Xylazine (Xyla-Ject, Phoenix, St. Josephs, MO). Once sedated, isoflurane (Novaplus, Hospira, IL) was used as inhalation anesthesia. Intramuscular injections of buprenorphine (0.001 mg/kg; Bedford Laboratories, Bedford, OH) and metoclopramide (0.15 mg/kg; GensiaSicox, Irvine, CA) were used as post-operative analgesia and anti-emetic, respectively. Pigs were euthanized by intravenous injection of Euthasol (Virbac AH, Fort Worth, TX).

Induction of Diabetes (papers I, II, III & V)

Under general anesthesia, streptozotocin (Zanosar; Pharmacia, Pfizer, New York, NY) was administered at a dose of 150 mg/kg body weight. The pigs were continuously observed for the first 3 hours and then hourly for the following 33 hours. Buprenorphine (Bedford laboratories, Bedford, OH) and metoclopramide (Gensia Sicox, Irvine, CA) were administered intramuscularly every 12 hours for the first two days. Serum glucose was taken twice daily during the experiment. The pigs were treated with a subcutaneous injection of short acting insulin (Normulin; NovoNordisk, Princeton, NJ) and long acting insulin zinc suspension (Humulin; Eli Lilly, Indianapolis, IN) to keep blood glucose in a range between 300 and 500 mg/dL.

Harvesting of skin cells

To harvest skin cells, the hair from the nape of the neck was clipped and the skin was cleaned with povidone iodine solution (Medline Industries, Mundelein, IL). Two strips of 0.38 mm split skin grafts measuring 23x2 cm were harvested with an electric dermatome (Padgett Instruments, Kansas City, KS). The resulting partial thickness wounds were dressed with vaseline gauze and sterile dressing.

Cell Culture

In papers II to V, autologous keratinocytes and fibroblasts were isolated from these split thickness skin grafts. The grafts were washed in sterile phosphate buffered saline. The skin grafts were then cut into 1 x 3 cm squares and left in 2 U/mL Dispase solution (Roche, Indianapolis, IN) at 37°C for 1 hour, at which time the epidermis could be peeled off the dermis.

The dermal sheets were put in 0.1% collagenase for 2 hours at 37°C then passed through an 80 mesh sterile sieve. The resulting solution was centrifuged at 1000 rpm at 37°C for 6 min. The fibroblasts pellet was then suspended in Dulbecco's modified eagle medium (DMEM; invitrogen, San Diego, CA) with 10 % fetal bovine serum (Sigma, MO), streptomycin (Gibco, Carlsbad, CA), penicillin (Gibco, Carlsbad, CA), gentamicin (Invitrogen, San Diego, CA) and amphotericin (Bristol-Myers Squibb, New York, NY) added. Cells were then seeded onto 100 mm BD Falcon cell culture dishes (Becton Dickinson, Franklin lakes, NJ). Fibroblasts were subcultured at 90 % confluence.

For the epidermal sheets, 5 mL 0.0625 % trypsin (Invitrogen, San Diego, CA) was added and left for 3 min at 37°C. The epidermis/trypsin solution was then passed through an 80 mesh sterile sieve and the trypsin neutralized by addition of fetal bovine serum (Sigma, St. Louis, MO). The resulting solution was centrifuged at 750 rpm for 6 min at 37°C to pellet the keratinocytes. Keratinocytes were resuspended in keratinocytes serum free medium (Invitrogen, San Diego, CA) containing bovine pituitary hormone, epidermal growth factor (Invitrogen, San Diego, CA), calcium depleted fetal bovine serum (Sigma, MO), calcium dichloride, streptomycin (Gibco, Invitrogen, San Diego, CA), penicillin (Gibco, Invitrogen, San Diego, CA), gentamicin (Invitrogen, San Diego, CA) and amphotericin (Bristol Myers Squibb, New York, NY). The cells were seeded onto BD biocoat I collagen-coated dishes (Becton-Dickinson, Franklin Lakes, NJ) at a density of 6×10^6 cells per 100 mm dish. Keratinocytes were sub-cultured at 90 % confluence.

Transfection

Transfection is the process of deliberately introducing nucleic acids into cells.

Transfection of cells typically involves opening transient pores or “holes” in the cell membrane to allow the uptake of material. In these papers, transfection was carried out by mixing a cationic lipid with the plasmid to produce liposomes, which fuse with the cell membrane and deposit their cargo inside.

In paper III, keratinocytes were seeded at a density of 6×10^6 cells per 100 mm dish and subcultured at 90 % confluence. Keratinocytes were passed and seeded at a density of 3×10^5 cells per 100-mm dish; 72 h later, they were transfected with 10 μ g of pBLAST-hIGF-1 or pCEP4-LacZ plasmid lipoplexed with either Lipofectin (Invitrogen, San Diego, CA) at a ratio of 1:4 or Lipofectamin 2000 (Invitrogen, San Diego, CA) at a ratio of 1:2. pBLAST-hIGF-1 is a plasmid that contains an EF-1 composite promoter and the blasticidin resistance gene under the control of a mammalian and bacterial promoters. This plasmid encodes the IGF-1 gene. This solution was placed in serum-free medium, added to the cells, and incubated at 37°C for 4 h and 1 h, respectively. The transfection medium was replaced with regular growth medium after incubation. Medium was collected daily for quantitative analysis of insulin-like growth factor 1 (IGF-1) expression. Cells were incubated for 48 h after transfection before transplantation into wounds.

In paper IV, passage 3 keratinocytes were seeded at a density of 1×10^6 cells/100 mm collagen I-coated cell culture dish 24 hours before transfection. Transfection was performed with Lipofectin (Invitrogen, San Diego, CA) at a ratio of 1 mg DNA : 4 mL Lipofectin. Each transfection was performed with either 5 mg of pCEP-hEGF plasmid or 5 mg pCEP-LacZ plasmid in a final volume of 1 mL of the transfection reagent. pCEP-hEGF is an episomal replicating plasmid that encodes the hEGF gene under the control of human cytomegalovirus (hCMV) major immediate-early promoter. Five micrograms of DNA and 20 mL of Lipofectin were each incubated in 500 mL serum- and antibiotic-free keratinocyte basic medium (KBM, Clonetics/Cambrex, Rockland, MA) for 45 minutes. The DNA solution was added in drops to the Lipofectin solution, incubated for another 15 minutes, and added to the cells. After 5 hours of incubation at 37°C, the transfection medium was replaced by SFM (GIBCO/Invitrogen, San Diego, CA). Cells were incubated for another 60–66 hours before transplantation. To determine hEGF expression, the cell supernatant was collected daily, transferred on ice, and stored at -80°C until assayed.

In paper V, passage three keratinocytes were seeded at a density of 500,000 cells per 100 mm dish 24 hours prior to transfection. Transfection was performed with lipofectin (Invitrogen, San Diego, CA) at a ratio of 1 μ g DNA for 4 μ L Lipofectin. 10 μ g of either PCEp4-EGF or Lac-Z plasmid were placed in a total volume of SFM and 80 μ L of Lipofectin was placed in a similar total volume. Both solutions were left for 30-40 minutes at room temperature. The DNA solution was added to the lipofectin solution drop by drop, gently mixed and left at room temperature for 15 minutes before being added to the cells. After 5 hours incubation at 37°C, the transfection medium was replaced with SFM with added components. Medium was collected on a daily basis for quantitative analysis of epidermal growth factor (EGF) expression.

Cells were incubated for 72 hours after transfection prior to transplantation into wounds.

Lac-Z staining and transfection efficiency

Transfection with plasmids that contain LacZ, and the addition of X-Gal, allows for the transfection efficiency to be determined i.e the percentage of cells that have taken up the chosen plasmid DNA.

48 hours post transfection, the dish transfected with Lac-Z plasmid was washed twice with phosphate buffered saline (PBS). The cells were fixed for 30 minutes in of 0.05% Gutraldehyde solution at which time they were washed twice with PBS and stained for 3 hours with 0.5mg/ml X-Gal substrate (FisherScientific, Waltham, MA). Cells transfected with Lac-Z stained blue. Transfection efficiency was calculated as the percentage of stained cells in the dish.

Wounding and chamber treatment

Fourteen days after induction of diabetes, pigs received anesthesia as per the protocol and were transferred to a panepinto sling (Fulton, Mosinee, WI). The pig's dorsum was waxed thoroughly (Nair, Church & Dwight, Princeton, NJ), shaved, and thoroughly disinfected. 18 to 21 squares measuring 1.5 by 1.5 cm were outlined on the dorsum with a template and a skin marker. The edges of these squares were retraced with a tattoo machine (Special Electric Tattoo Marker, Spaulding Enterprises, Voorheesville, NY) to allow measurement of wound contraction. After the skin was prepared with povidone iodine, the skin within the squares was excised with a no. 11 blade to create 18–21 full-thickness wounds (FTW) measuring 1.5 by 1.5 cm with a depth of 0.8 cm. Adhesive polyurethane chambers (Corium International, Grand Rapids, MI) were applied over each wound, and the chambers were then injected with 2 mL of sterile saline containing penicillin 100 U/mL (Gibco, Invitrogen, Carlsbad, CA) and streptomycin 100 mg/mL, (Gibco, Invitrogen). For nondiabetic high-glucose wound concentration experiments (paper I), the 2 mL sterile saline solution was adjusted to 1,800 mg/dL (100 mM) glucose concentration. The wound fluid collected in the chambers was completely aspirated at 24-hour intervals and chilled on ice before being stored at -80°C for later analysis. Each chamber was reinjected with 2 mL of sterile saline (containing penicillin/streptomycin) to restore the wet wound environment.

Cell transplantation (paper II-V)

In paper II, two sets of experiments were performed on 136 wounds. For the first experiment we investigated the effect of transplanting a suspension of fibroblasts on the healing of FTW in the diabetic pig. 650,000 fibroblasts suspended in 300 mL DMEM were injected into half of the wounds (n=34) and 300 mL DMEM only into control wounds (n=34).

For the second experiment, we investigated the effect of transplanting a suspension of keratinocytes into FTW in the diabetic pig. 500,000 keratinocytes suspended in 300 mL SFM were injected into half of the wounds (n=34) and 300 mL SFM into control wounds (n=34).

In both experiments, wounds were left intact for 2 hours to allow for the cells to settle. At this time, 2 mL normal saline was injected into each wound. The wound fluid that collected in the chambers was completely aspirated at 24-h interval for analysis of glucose concentration. The chambers were then re-injected with 2 mL of 0.9% saline solution (containing penicillin/streptomycin).

In paper III, we investigated the use of keratinocytes as gene-transfer vehicles for the growth factor IGF-1 and the influence of over expressing IGF-1 in the wound microenvironment. FTW were randomly divided into three groups: wounds transplanted with a suspension of 5×10^5 transfected keratinocytes, wounds transplanted with a suspension of 5×10^5 native keratinocytes (transplant control) and wounds treated with 0.9% sterile saline solution (control). Cells were allowed to settle as in paper II.

All chambers were injected with 2 ml of cell suspension or 0.9% sterile saline (containing penicillin/streptomycin). The wound fluid collected in the chambers was completely aspirated at 24-h intervals and chilled on ice before being stored at approximately -80°C for later analysis. Each chamber was re-injected with 2 ml of sterile saline (containing penicillin/streptomycin).

In paper IV, three different sets of experiments were performed on 97 FTW.

In the first set of experiments, 29 wounds were transplanted with 5×10^5 of either allogenic (n=10) or autogenic (n=10) keratinocytes as a single-cell suspension. As a control, a group of wounds were treated with saline only (n=9). Wound biopsies were performed on day 8.

In the second experiment, we investigated whether the rejection of allogenic cells would cause a breakdown of the wound and result in epithelial defects or clinical blister formation. Thirty-two FTW were treated with either 5×10^5 allogenic keratinocytes (n=16) or saline (n=16). Wound biopsies were performed on postoperative days 8, 11, 14, 21, 28, and 35. Digital photography of individual wounds was used to assess clinical features such as color, wound contraction, hair growth, blister formation, and desiccation.

The third set of experiments aimed at investigating the use of allogenic keratinocytes as gene-transfer vehicles for growth factors into the wound environment and their influence on wound healing. Thirty-six FTW were treated with 3×10^5 hEGF-expressing allogenic keratinocytes (n=9), 3×10^5 untransfected allogenic keratinocytes (n=12),

or saline as control (n=15). Wound biopsy specimens were taken at day 9 after the operation. To monitor the viability of transplanted keratinocytes in vitro, the same amount of keratinocytes as transplanted into FTW was seeded into 35-mm dishes. Cells were monitored for 3–5 days in vitro and medium from transfected cells was collected to determine the levels of hEGF-expression after subcultivation. In all experiments cells were allowed to settle as in paper II.

In paper V, we investigated if the beneficial effect seen in paper IV could be reproduced using autologous keratinocytes as a gene transfer vehicle for hEGF in diabetic pig wounds. Wounds were randomly divided into three groups: wounds transplanted with a suspension of 3×10^5 transfected keratinocytes (n=21), wounds transplanted with a suspension of 3×10^5 native keratinocytes (transplant control, n=21) and wounds treated with 0.9% sterile saline solution (control, n=18). All wounds were left intact for 2 h to allow for the cells to settle. At this time, chambers were injected with 2 ml of 0.9% sterile saline (containing penicillin/streptomycin). The wound fluid collected in the chambers was completely aspirated at 24-h intervals and chilled on ice before being stored at approximately -80°C for later analysis. Each chamber was re-injected with 2 ml of sterile saline (containing penicillin/streptomycin).

Wound contraction

Wound contraction was determined by digitized planimetry of the tattooed margins. The area of the wounds at specific days was measured using Scion image software (Scion, Frederick, MD) and the percentage of contraction was calculated by the formula $[(\text{area at biopsy day})/(\text{area on wounding day})] \times 100$.

Histology

Cross-sectional wound biopsies, 2 mm wide, were taken from the middle of the wounds; the sample included unwounded skin surrounding the wound and subcutaneous tissue at the bottom. Biopsies were collected on days 8, 12, 16, and 18 after wounding (paper I), on days 8, 12 and 14 (paper II), days 8, 11, 14, 21, 28, and 35 (paper IV), and on day 12 (papers III and V). Samples were fixed in 4 % buffered paraformaldehyde and processed for routine Hematoxylin&Eosin staining.

Re-epithelialization measurements

Re-epithelialization was defined as the area within the tattooed marks that was covered with epithelium. This was calculated by scanning the slides (Epson Perfection 3600,

Epson Inc., Long Beach, CA), measuring the epithelial tongues from the computerized image using Paintshop Pro® (Jasc Software 7.0, Corel, Ottawa, Canada). The percentage re-epithelialization was determined using the formula:

$$[(\text{Sum of epithelial tongues}) / (\text{Distance between tattoo marks})] \times 100$$

Measurements of growth factor and protein

Levels of platelet derived growth factor bb (PDGF-BB), transforming growth factor beta (TGF- β), and IGF-1 in the wound environment were measured in wound fluid by a specific enzyme-linked immunosorbent assay and a protein assay (R&D Systems, Minneapolis, MN). Levels of hEGF expression were determined by an hEGF-specific enzyme-linked immunosorbent assay (ELISA) in the cell supernatant of keratinocyte cultures in vitro, as well as in the daily collected wound fluids in the animal model. Anti-hEGF monoclonal antibody (R&D, Minneapolis, MN), anti-hEGF polyclonal antibody (Santa-Cruz Biotechnology, Santa Cruz, CA), and an HRP-goat-anti-rabbit polyclonal antibody were used as primary, secondary, and tertiary antibodies, respectively. All results were evaluated by a V Max Kinetic Microplate Reader (Molecular Devices, Sunnyvale, CA) at 450 nm with SoftMax Pro Software (v. 4.0). The results were averaged for each group and compared graphically.

Statistics

Values are presented as means \pm SD. Groups were compared with a conventional nonparametrical test, and statistical calculations were performed with GraphPad Instat software (GraphPad Software, San Diego, CA). A p-value < 0.05 was considered to indicate a statistical difference.

Results and Comments

Paper I

At present most diabetic animal wound healing models exist in loose skin animals such as rodents. Unfortunately, these animals heal mostly by wound contraction and have low similarity to human healing²⁵. As porcine wounds heal mostly by repithelialization, they are physiologically similar to human healing. In this study, a new model of delayed wound healing in pigs was developed by chemically inducing diabetes.

Following the injection of streptozotocin there was an initial triphasic glucose response during the first 30 hours with an initial hyperglycemia lasting from hours 1–8, followed by a marked hypoglycemia that lasts from hours 10–20. A permanent hyperglycemic state (blood glucose above 350 mg/dL) established at 22 hours post induction. Wound fluid was collected on a daily basis, and the glucose concentration was measured. The glucose levels in wound fluid closely followed the levels in serum until day 5, at which time the glucose levels in wound fluid progressively decreased until they reached undetectable levels at day 9 (Figure 1). All animals that received streptozotocin survived in good general condition for the duration of the experiment. Nondiabetic pigs showed no detectable glucose concentrations in the wound fluid throughout the experiment, whereas wounds with local hyperglycemia in nondiabetic pigs showed a mean glucose concentration of 201.2 mg/dL. Urine glucose was 7.1 mg/dL in the fasting nondiabetic pig and > 500 mg/dL in the diabetic pig.

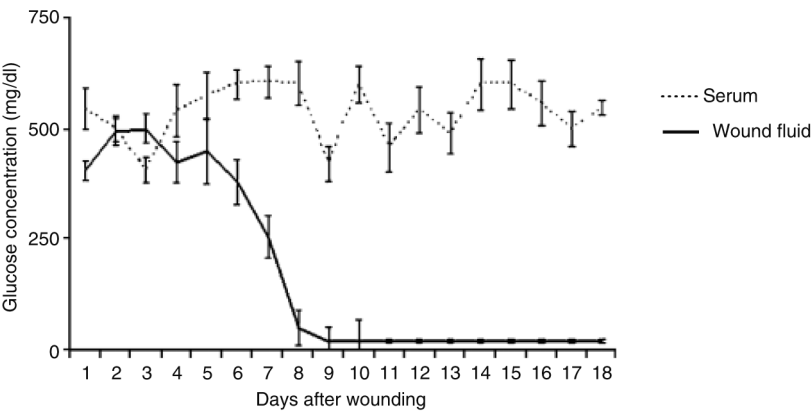


Figure 1: Relation between the glucose concentration in wound fluid and in serum in the diabetic pig after the creation of wounds (n=52 in three pigs). Glucose concentrations in wound fluid followed that in serum closely until day 5, when it decreased, becoming undetectable on day 9.

In all pigs, cross-sectional biopsies were done on days 8, 12, 14, 16, and 18 after wounding. Epidermal healing in diabetic pigs was significantly delayed as compared with healing in nondiabetic pigs. On day 8, the wounds in diabetic pigs were 12% reepithelialized, whereas those in non-diabetic pigs were 44% reepithelialized. On day 12, the wounds of diabetic pigs were 42 % reepithelialized and those in nondiabetic pigs were 96 % epithelialized. Full re-epithelialization was delayed in diabetic pigs (day 18) as compared with nondiabetic animals (days 12–14) (Figures 2). Local hyperglycemic wounds on nondiabetic animals showed no statistical difference compared with control wounds on day 12 (83 vs. 88 %)

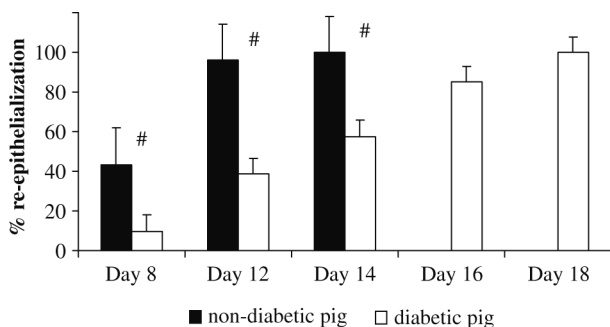


Figure 2: Level of reepithelialization of full-thickness wounds in nondiabetic and diabetic pigs. Wounds measuring 1.5 x 1.5 cm were created on the backs of the pigs. Biopsy samples were obtained on days 8 (n=4), 12 (n=12), 14 (n=12), 16 (n=12), and 18 (n=12) for the diabetic pigs and on days 8 (n=12), 12 (n=12), and 14 (n=10) for the healthy pigs. #diabetic vs. nondiabetic group: $p < 0.001$.

Diabetic wounds contracted 24 % on day 8 and 34 % on day 12. Wounds in nondiabetic pigs contracted 35 % on day 8 and 42 % on day 12. Diabetic wounds contracted less at both time points, but the difference between the two groups was not statistically significant.

Expression of IGF-1 in diabetic wounds was 15-fold lower than expression in nondiabetic wounds at day 3, 10-fold lower at day 5, and fourfold lower at day 7 (Figure 3). The concentration of transforming growth factor b(TGF-b) was lower in the wound fluid of diabetic pig than in the wound fluid of nondiabetic pigs with a significant lower expression of TGF-b at day 7 in diabetic pigs as compared with nondiabetic pigs. The difference in expression of PDGF-BB in the wound fluid of diabetic and nondiabetic pigs was not statistically significant.

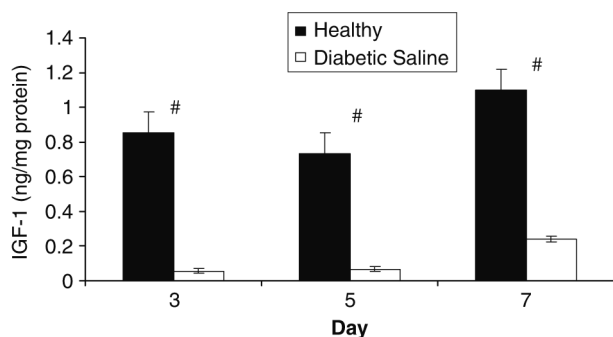


Figure 3: Level of expression of IGF-1 from the wound fluid of nondiabetic and diabetic pigs. Each bar represents the mean standard deviation for three diabetic pigs or four healthy pigs. All samples were assayed in duplicate. $p < 0.05$

Clinical similarity is important when studying new treatment modalities in animal models. In this experiment, we not only successfully developed a delayed wound healing model in streptozotocin induced diabetic pigs but also demonstrated decreased intrinsic factors in the wound environment similar to those seen in human diabetic wound healing.

Paper II

Keratinocytes and fibroblasts cell morphology is altered in diabetic wounds leading to reduced cellular activity and proliferation. When a full thickness wound is created, a fibrin matrix is progressively formed to allow for cellular mobility. Earlier studies from our laboratory demonstrate that transplanted keratinocytes proliferate and form cell colonies, which progressively move upward across the fibrin matrix to the wound surface during the course of the healing process and thus regenerate into a structurally intact epidermis. Svensjo et al. showed that transplantation of autologous fibroblast has little effect on healing of full thickness wound in healthy normal pigs. Based on our finding that most keratinocyte transplanted wounds healed on day 10 post-transplantation and healing of full-thickness wounds is delayed in diabetic pigs (paper I), we decided to analyze the degree of re-epithelialization on days 8, 12, and 14 post-keratinocyte transplantation and on day 12 post fibroblast transplantation.

Treatment of full thickness diabetic wounds with a suspension of keratinocytes showed no difference in re-epithelialization on day 8, as the transplanted keratinocytes had not yet reached the wound surface as they were still migrating through the collagen matrix. However on day 12 there was a significantly enhanced epidermal healing with a 91.3% re-epithelialization rate compared with 56.8% in the saline treated group. On day 14, the keratinocyte treated group were fully re-epithelialized compared with a rate of 59% in the saline treated group ($P < 0.001$; Fig. 4). The contribution of the transplanted keratinocytes to the new epidermis is illustrated in Fig. 5, showing that the ke-

keratinocyte colonies have fused with the newly formed epidermis, compared with the saline treated group where epidermis is absent in the center of the wound. This is further illustrated in the histological slides presented in Fig. 6, where the upward migration of the keratinocyte colonies contributed directly to the newly formed epidermis. These colonies are absent in the saline treated control group. There was no statistical difference in the rate of contraction between the two groups on days 3, 6, and 9. However there was a statistical difference on day 12; keratinocyte treated wounds contracted less than saline wounds ($P = 0.0136$).

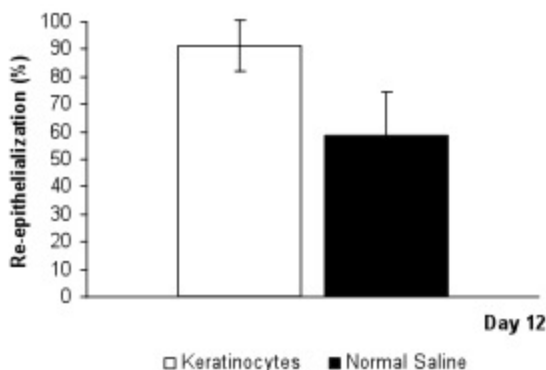


Figure 4: Transplantation of keratinocytes or fibroblasts accelerates epidermal healing in the diabetic pig. (A) Level of re-epithelialization of full thickness wounds treated with a suspension of 500,000 keratinocytes or normal saline. Wounds measuring 1.5 x 1.5 cm were created on the backs of pigs. On the day of wounding, an injection of either a suspension of keratinocytes or normal saline was done into each wound. On days 8, 12, and 14, biopsies were harvested, embedded in paraformaldehyde and stained with hematoxylin and eosin for analysis. The error bars refer to SD. $P < 0.001$

Next, we transplanted a suspension of 650,000 fibroblasts into full thickness wounds in diabetic pigs. As shown in Fig.7, treatment of full thickness wounds with transplanted fibroblasts showed a significant faster re-epithelialization 86.7% compared with 56.8% for the saline treated control group ($P < 0.035$). There was no statistical difference between the contraction rate of the fibroblasts group and saline control group. The fibroblasts treated wounds contracted 40.2% at day 12, whereas control group contracted 42.7% ($P > 0.05$).

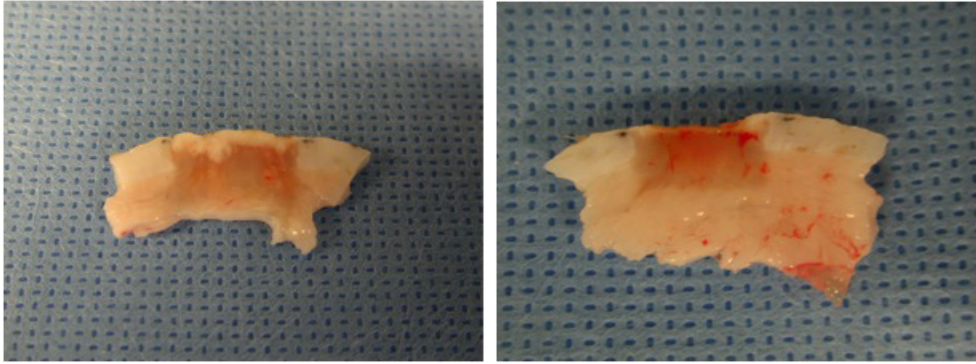


Figure 5: Transplantation of keratinocyte into full thickness wounds in diabetic pigs leads to the formation of keratinocyte colonies, which contribute to epidermal healing. Vertical wound biopsies 2 mm wide were taken from the middle of the wounds, which included unwounded skin at the sides and subcutaneous tissue at the bottom. Biopsies were collected on day 12 post-wounding, embedded in para- formaldehyde and stained with H and E for analysis. The arrows show the edge of re-epithelialization. (A) Wounds treated with a sus- pension of 500,000 keratinocytes. (B) Normal saline treated wound. Scale 6.5 mm for A and B.

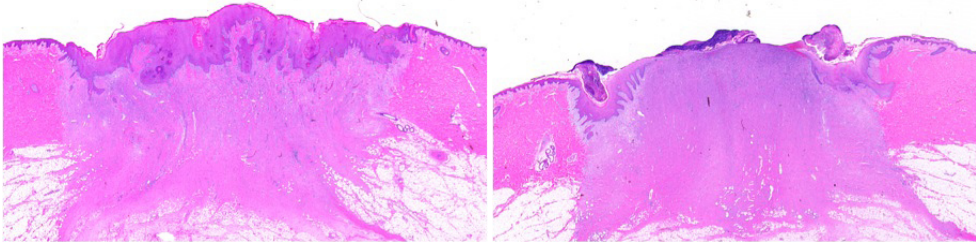


Figure 6: Keratinocyte colonies migrate upwards from the base of the wound to enhance epidermal healing. Histology of wounds on day 12 (H and E staining). Pictures shows the center of the wound. The arrows show the end of the epithelial tongues. (A) Wound treated with a suspension of 500,000 keratino- cytes. (B) Normal saline treated wound Scale 500 mm.

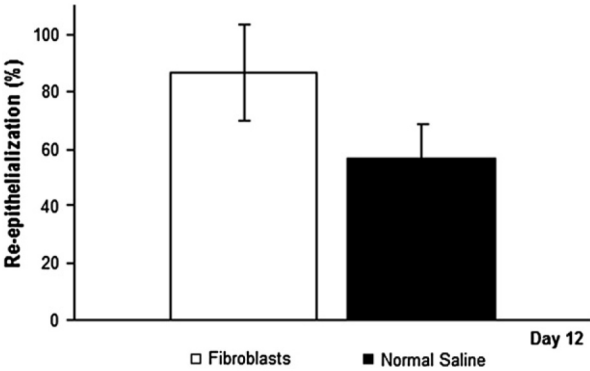


Figure 7: Re- epithelialization on day 12 of full thickness wounds treated with a sus- pension of 650,000 fibroblasts or normal saline. Wounds measuring 1.5 x 1.5 x 0.8 cm were created on the backs of pigs. On the day of wounding, an injection of either a suspension of fibroblasts or normal saline was done into each wound. On day 12, biopsies were harvested, embedded in paraformaldehyde and stained with hematoxylin and eosin for analysis. The error bars refer to SD. $P \leq 0.035$.

The beneficial effect of transplanting a suspension of keratinocytes or fibroblasts into diabetic wounds was demonstrated. As the concentration of various growth factors is decreased in diabetic wounds, a logical refinement of this methodology would be to deliver genetically altered cells, expressing growth factors, into the wounds.

Paper III

In this study, gene therapy was consequently added using transplanted keratinocytes as vectors (carriers) of the new genetic material. As described in paper I, the concentration of IGF-1 was decreased in the diabetic wounds. For this reason, plasmids coding for IGF-1 were added to keratinocytes which were then transplanted to wounds. IGF-1 is a growth factor that potently stimulates cell growth and proliferation, as well as an inhibitor of apoptosis (cell death).

Cells were transfected with 10 µg of IGF-1 or LacZ plasmid complexed with either Lipofectamin 2000 or Lipofectin. X-gal staining showed higher transfection efficiency for the Lipofectamin 2000 group [79 ± 12 % transfection efficiency/high power field] than for the Lipofectin group (28 ± 9 % transfection efficiency/ high power field). Quantification of hIGF-1 transgene expression showed up to 740 ng/ml IGF concentration for Lipofectamin 2000 lipoplex. We detected an initial increase from day 1 (550 ng/ml) to day 2 (740 ng/ml), followed by a slow decrease over time (708 ng/ml on day 3, 455 ng/ml on day 5, 57 ng/ml on day 7, 48 ng/ml on day 10), with a final measurement of 7.47 ng/ml at the end of the experiment (day 14). Lipofectin gene transfer showed peak expression on day 2 with 68.5 ng/ml, followed by a decrease to 20 – 30 ng/ml on days 3 and 5, 2 ng/ml on day 7, and 0.8 ng/ml on day 14. LacZ-transfected controls showed hIGF-1 concentrations between 0.86 and 0.36 ng/ml over the time course.

Forty-eight hours after ex vivo transfection, cells were transplanted into the created full-thickness wounds. Wounds treated with 5×10^5 cells transfected with a pBLAST-hIGF-1/Lipofectin lipoplex achieved up to 3.29 ng/ml total IGF-1 concentration, with a peak on day 4 followed by a decrease until day 12. Wounds receiving cells transfected with pBLAST- hIGF-1/Lipofectamin 2000 lipoplex achieved transgene expression level on day 1 after re-transplantation of 457 ng/ml versus 0.51 ng/ml for untransfected keratinocyte control. From day 2 to day 12, IGF-1 concentration in the wound fluid showed a steady decrease over time, with a final concentration of 5.05 ng/ml on day 12 and still a significantly higher IGF-concentration than in both untransfected keratinocytes and normal saline treated groups over the whole course of experiment ($p < 0.05$; Figure 8).

Histology showed almost completely re-epithelialized wounds for the Lipofectamin 2000 gene therapy group. Evenly formed new epithelium was observed, including connective tissue papillae. Native cell transplanted wounds showed successfully transplanted cells still in the process of migrating upwards from the wound bed towards the wound surface, integrating into the newly-forming epithelium. Thus, the epithelium was less organized than in the wounds treated with transfected cells. Control wounds showed regular wound healing, including re-epithelialization by keratinocytes

migrating from the wound edges towards the center of the defect by forming epithelial tongues. Lipofectamin 2000-lipoplex treated wounds showed significantly faster re-epithelialization ($83 \pm 17\%$) than the keratinocyte group ($57 \pm 12\%$), and both groups were significantly different from the control ($32 \pm 1\%$; $p < 0.0001$ and 0.001 , respectively; figure 9). For the Lipofectin lipoplex-treated wounds, re-epithelialization did not significantly differ between the transfected keratinocyte and native keratinocyte groups. Wound contraction showed no significant difference among all groups.

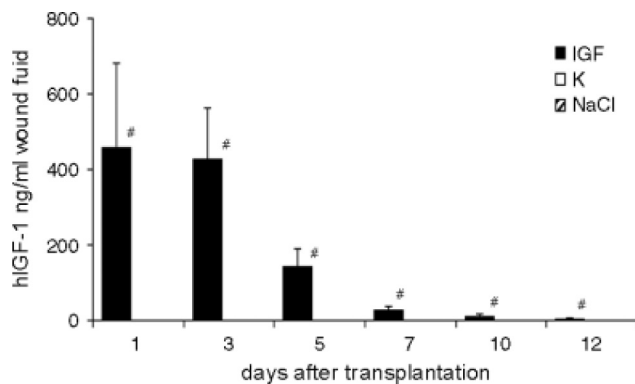


Figure 8: hIGF-1 transgene expression in vivo. $p < 0.05$ gene transfer group versus controls (untransfected keratinocytes showed hIGF-1 expression in the range 1.3–0.5 ng/ml wound fluid; saline control wounds showed expression in the range 0.8–0.5 ng/ml wound fluid)

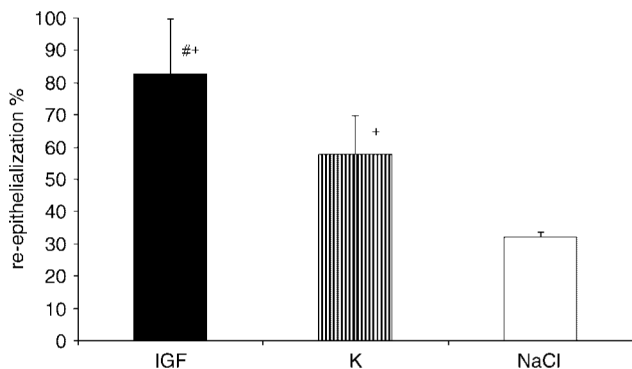


Figure 9: Re-epithelialization on day 12. $\#p < 0.01$ IGF-1 transgene keratinocyte-treated wounds versus keratinocyte-transplanted control; $+p < 0.0001$ versus saline control

Optimized gene transfer of IGF-1 to keratinocytes leads to a significantly increase of the concentration of IGF-1 in the wound. This increased concentration, in turn, enhances epithelial healing in diabetic porcine wounds and opens the door to further study the effect of over expressing growth factors in the wound as well as to the optimal delivery method.

Paper IV

Transplanting autologous cells carrying new genetic material provide a combination of cell based wound healing strategies and gene therapy in one treatment. It is though a time consuming and an elaborate process to create a stable cell line from the harvested cells. Cryopreserved allogenic cells transfected with various growth factors can be stored until needed. EGF is a growth factor produced by platelets, keratinocytes and macrophages, and stimulates epithelial cell proliferation and migration. In this study, all experiments were done in normal healthy pigs (non-diabetic).

In the first experiment, biopsies were taken on postoperative day 8. We measured a reepithelialization percentage (RE%) of 41.7% in wounds treated with allogenic keratinocytes (n=7), 42.2% in wounds treated with autogenic keratinocytes (n=7), and 41.1% in wounds treated with a mixture of allogenic keratinocytes and autogenic cells (n=7). Saline-treated controls (n=7) had a RE% of 31 % and dry-treated wounds had an RE% of 18.1%. There was no statistical difference in RE% between wounds treated with allogenic, autogenic, or mixed allogenic/autogenic keratinocytes. However, RE% in the allogenic, autogenic, and mixed keratinocyte-treated wounds was significantly higher when compared with saline control wounds ($p < 0.02$), whereas saline-treated wounds had a significantly faster RE% than dry-treated wounds ($p < 0.02$).

Histological examination of wound biopsies revealed an inflammatory infiltrate in the granulation tissue. The inflammatory response in wounds treated with allogenic keratinocytes exhibited the same intensity in H & E-stained sections as in the saline control wounds. Multiple foci with granulomatous and mixed lymphocytic cells were observed. Keratinocyte cell clusters were visible throughout the granulation tissue in all cell-treated wounds. Planimetry of wound surfaces showed no significantly different contraction rates between any of the keratinocyte treated wounds vs. saline-treated wounds, while wounds treated in a wet wound environment (all cell-treated and saline-treated groups) showed a significantly lower contraction ratio than the dry-treated wounds ($p < 0.02$).

In the second set of experiments, wound biopsies were taken at different time points up to postoperative day 35 to determine the long-term effects of allogenic keratinocytes on the stability of FTW. On postoperative day 8, when all FTW were compared, wounds treated with allogenic keratinocytes (n=3) reepithelialized 100% and saline control wounds (n=3) reepithelialized at a rate of 66.6%. The difference between the groups was statistically significant ($p < 0.02$). On days 11 (n=4), 14 (n=2), 21 (n=3), 28 (n=2), and 35 (n=2), wounds of both groups were 100 % reepithelialized. When the thickness of the epidermal layer and the size of the rete ridges were evaluated, no significant differences were noted between the allogenic vs. autogenic cell suspension-treated wounds. Histology showed an increased presence of inflammatory cells throughout the first 21 days of the experiment in all wound sections. There was no significant difference in the evaluation of the degree of inflammation histologically when allogenic keratinocytes or saline treated wounds were compared at days 21 and 35. The wounds treated with allogenic keratinocytes did not reveal clinical signs of sus-

tained inflammation or epithelial defects. Wound contraction in wounds treated with allogenic keratinocytes was 44.1% on day 8 (n=16) and 61.5% on day 10 (n=13), as compared with 42.2% (n=16) and 54.9% (n=13) in saline control wounds, respectively. On day 21, wound contraction was 65.6% in allogenic keratinocytes treated wounds and decreased to 61.8% on day 28 and 58.7% (n=4) on day 35 (n=2). Saline control wounds contracted 57.7% on day 21 (n=7), 60.7% on day 28 (n=4), and 71.5% on day 35 (n=2). Differences in wound contraction between the groups were not statistically significant.

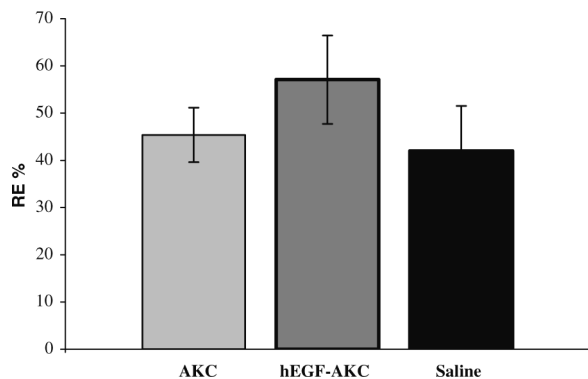


Figure 10: Full-thickness skin wounds measuring 1.5x1.5cm were created on the back of two 4-month-old Yorkshire pigs before transplantation of 300,000 hEGF transfected or 300,000 un- transfected AKC in single-cell suspension or saline controls. Reepithelialization percentages were measured on postoperative day 8. Reepithelialization was significantly greater in wounds treated with hEGF-transfected AKCs, than in wounds treated with untransfected AKC or saline. No significant difference in reepithelialization rates was found on day 8 when 300,000 AKC were used vs. saline. AKC, allogenic keratinocyte; hEGF, human epidermal growth factor.

The third set of experiments determined whether allogenic keratinocytes could function as gene transfer vehicles to deliver growth factors into the wound environment and further enhance wound healing. To emphasize the effect of hEGF-transfected keratinocytes on wound healing, we reduced the number of transplanted keratinocytes to 300,000 cells/wound. On postoperative day 8, wounds treated with allogenic keratinocytes (n=12) had a RE% of 45 % and wounds treated with transiently transfected-hEGF expressing allogenic keratinocytes (n=9) had an RE of 57 %. We found an RE% for the saline-treated control wounds (n=15) of 42 %. The differences in RE% between the allogenic keratinocytes and hEGF-expressing allogenic keratinocytes ($p < 0.02$), and between saline control and hEGF-expressing allogenic keratinocytes ($p < 0.02$) were statistically significant (fig.10). No difference in RE% could be detected between wounds treated with untransfected allogenic keratinocytes and saline-treated control wounds ($p > 0.05$) when 300,000 cells were used per wound in contrast to former experiments where 500,000 cells were seeded per wound. To determine successful transfection in vitro, one dish of keratinocytes was transfected with LacZ-containing plasmid under conditions similar to hEGF transfection. Forty-eight hours after transfection, cells were stained for LacZ expression. Microscopic cell count per field showed

a 15 to 25 % transfection rate. To determine the ability of transfected keratinocytes to express hEGF, medium from in-vitro cultured EGF-transfected and un-transfected keratinocytes was collected 24 hours post- transfection up to postoperative day 5. The in-vitro levels of hEGF expression were 1,678 ng/mL 24 hours after transfection and 902 ng/mL 48 hours after transfection.

Two pigs were used in the third set of experiments. In the first pig, hEGF levels in wounds transplanted with hEGF-transfected keratinocytes revealed 920.8 pg/mL hEGF on day 1 and 624.5 pg/mL on day 2. The levels of hEGF decreased to 94.2 pg/mL on day 3, 68.9 pg/mL on day 4, and 36.9 pg/mL on day 5, and ranged between 12.7 and 6.5 pg/mL on days 6–9. In wounds treated with untransfected AKC or saline, hEGF was between 6.6 and 0.98 pg/mL. In the second pig, hEGF expression was lower: 188 pg/mL on day 1, 88 pg/mL on day 2, and 106 pg/mL on day 3. Expression decreased to 56 pg/mL by day 4 and 18 pg/mL by day 5. No expression was detectable after day 5. Control wounds did not reveal any expression of hEGF. Besides the lower peak expression, the ratio of hEGF expression in wounds treated with hEGF-transfected allogenic keratinocytes vs. untransfected allogenic keratinocytes and saline controls was similar in both experiments.

Allogenic keratinocytes serve as an efficient gene transfer vehicle to the wound and when transfected with EGF, lead not only to increased EGF expression but also an increased epithelial healing. Rejection of the allogenic cells takes place gradually without any resulting epithelial defects. The beneficial effect of EGF in normal non diabetic wounds bodes well for the analysis of EGF overexpression in diabetic wounds.

Paper V

As positive results have been achieved by transplanting a suspension of EGF transfected keratinocytes into healthy normal porcine wounds, a logical next step was to analyze the effect of transplanting EGF transfected keratinocytes into diabetic porcine wounds. For this study, autologous keratinocytes were used as gene transfer vehicles.

Wounds that received a suspension of 300,000 PCEp4-EGF transfected keratinocytes started expressing EGF from day 1 (1,6 ng/ml). After day 2, EGF concentration showed a decrease in expression over time but showed a significantly increased concentration during the whole course of the experiment compared with the control groups (Fig.11). The hEGF treated group showed a significant enhancement in RE% (92%) compared to the keratinocyte treated group (72%) and the saline group (55%). (fig.12) There was no statistical difference in the rate of wound contraction between the three study groups.

Similar results to study IV were demonstrated. Overexpression of EGF in the wound microenvironment is achieved and leads to enhanced re-epithelialization in diabetic porcine wounds. The level of expression is time dependent and decreases steadily over time. This is at present a limiting factor in using gene therapy for treating wounds.

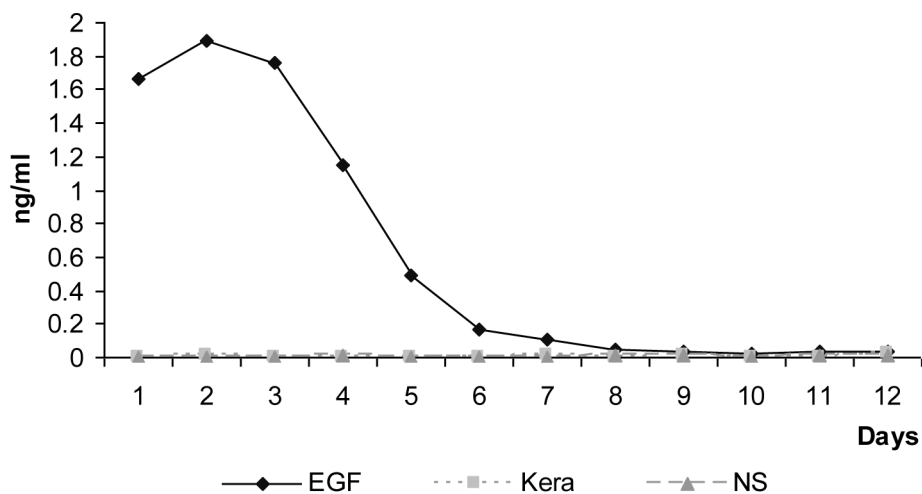


Figure 11: Expression of hEGF in the wound fluid in the different groups. Wound fluid was collected at 24 hours interval and stored at -80°C. Levels of expression of EGF were measured from the wound fluid using specific enzyme linked immunosorbant assay (Elisa) developed in our laboratory. Results were calculated by using a Vmax kinetic Microplate Reader (Molecular Devices, CA) and Soft Max Pro software.

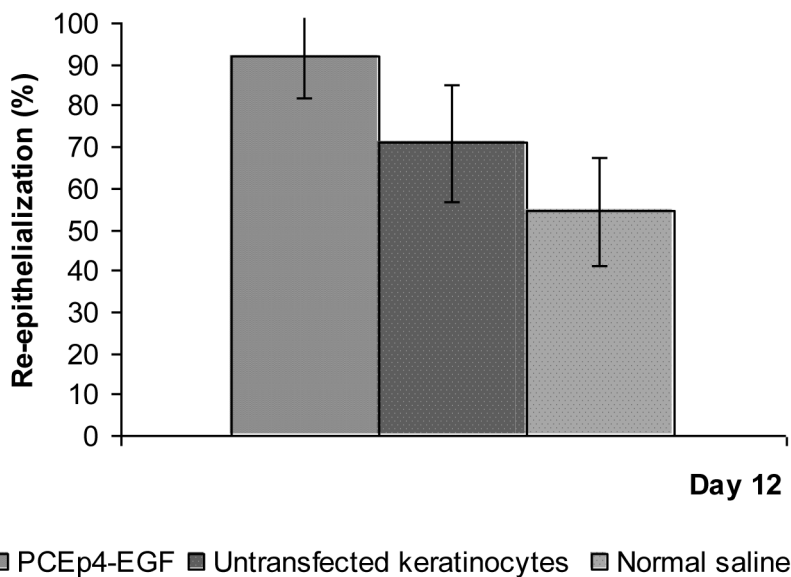


Figure 12: Level of re-epithelialization of full thickness wounds in the different groups: PCEp-4 transfected keratinocyte suspension (n=16 wounds), untransfected keratinocyte suspension (n=16 wounds), normal Saline solution (n=14 wounds)

The results were analysed using one way analysis of variance (ANOVA) which showed a p value of 0.0003 considered significant.

Discussion

Research models

Wound healing research, like medical research in general, is usually performed in a step-wise fashion. At first a hypothesis is created and experiments are designed to test this hypothesis; initially by doing in-vitro testing to determine feasibility of the study, concentrations of products, efficacy of different products and their effect on specific cells.

In vitro studies

The main advantages of in-vitro tests is that they are inexpensive, practical for the researcher, and provide information rapidly. They also possess ethical and safety advantages as no animals are used. In wound healing research, in-vitro testing is best suited for determining possible effectiveness of various healing factors such as the effect of different proteins on cellular mechanisms, the optimal concentration of specific chemicals in the medium, or establishment of new cell lines. However, biological conditions seen in wounds cannot be accurately replicated with in vitro methodology. Once in vitro testing has shown the feasibility of a project or indicated the optimal dose of a treatment modality, the next logical step is to investigate the "product" in an animal model.

In vivo studies

There is currently no such thing as an ideal animal model to study human wound healing. Nevertheless, several different types of animal models exist. These can be broadly divided into two groups: small animal models and large animal models, each having both advantages and disadvantages.

Small animal models

These are the model of choice for most researchers as they are inexpensive, easy to handle, require little space and when desired, these animals are easily genetically manipulated. These loose skin animals have an accelerated mode of healing compared with humans which allows for faster experiments. However, they are also a number of

limiting factors. A limited number of wounds can be investigated per animal, which leads to an increase in the amount of animals needed per experiment. Small mammals differ greatly anatomically and physiologically to humans. They have a dense layer of body hair. The epidermis is just a few cell layer thick and in the sub-epithelial layer there is smooth muscle present called panniculus carnosus muscle. This muscle is responsible for the contractibility of wounds in small mammals and these heal mostly by contraction as opposed to humans who heal mostly by re-epithelialization²⁶.

When choosing which animal model to use, it is important to focus on one or a limited number of wound healing factors, such as re-epithelialization and granulation tissue formation, to enhance consistency and simplify analysis. Concordance to human wound healing should also be considered.

Large animal model

A pig animal model was used in this thesis because porcine skin is structurally very similar to human skin both anatomically and physiologically. Both the epidermis and the dermis are thick. The rete ridges are well developed. Body hair is sparse which is important in wound healing as adnexal structures play an important part in re-epithelialization. There is a high level of elasticity in the dermis and wounds heal mostly by re-epithelialization. Neither pigs nor humans have a panniculus carnosus which is responsible for the pronounced wound contractibility in rodents^{22 24 25}.

A few differences exist though. Pigs have a less well developed subepidermal plexus (blood vessels supplying adnexal structures, hair follicle and glands in the skin) and no eccrine glands. However, compared to the great similarities, these differences ought to be of limited importance. Porcine wounds should be the best possible environment to study new treatment modality.

Diabetes

The risk of developing a chronic wound is high for patients with diabetes mellitus. The patient burden with pain, psychological distress and social discomfort is enormous. The cost to society is equally high. In 1994, Appelqvist et al calculated the cost of treatment per ulcer episode in diabetic patients in Sweden²⁷. The average cost for primary healing with conservative treatment was €6245 and the average cost for healing with amputation was €41743. Taking into account that 4-6% of the population have diabetes and, that 15-25% of these patients will develop a wound needing treatment, better treatment modalities need to be developed. To research these new treatments, a good diabetic animal model, which mimics human healing, is crucial.

Different methods exist to render various animals diabetic. Alloxan and streptozotocin are two chemicals widely used to induce experimental diabetes in animals²⁸⁻³⁰. Streptozotocin is a naturally occurring chemical that is particularly toxic to the insulin-

producing beta cells of the pancreas in mammals. It is used in medicine for treating certain tumours of the islets of Langerhans and used in medical research to produce diabetic animal models. It is commonly used in mice and rats. The main advantage of using streptozotocin is that when giving it under controlled conditions little morbidity is seen³¹⁻³³. This is in contradiction to a surgical approach of inducing diabetes in mammals. Pancreatectomy, the process of removing the pancreas and thus rendering the animal diabetic, has a high mortality rate. Up to 50 % mortality has been described³⁴.

Neuropathy and vascular changes seen in long standing diabetes are common contributing factors in clinical ulcers and are not present in this model. Streptozotocin induced diabetes provides an acute diabetic state with the advantage that research can focus on the altered intrinsic factors seen in diabetic wound healing. In these studies, streptozotocin injection was well tolerated by all animals and a stable long-term diabetic state was achieved in the Yorkshire pigs. Insulin therapy helped maintain blood glucose on an elevated level throughout the experiment and a permanent hyperglycemic state was achieved.

A state of systemic hyperglycemia, as seen in diabetes, may influence wound closure in numerous ways¹². Several hypotheses have been described in the literature such as the formation of glycation end products, hyperosmolarity, and altered insulin signaling in various ways^{11 13 35-37}. However, molecular mechanisms whereby diabetes alters skin and wound physiology have sparsely been elucidated to date. To evaluate the sole effect of local hyperglycemia in wounds, the other potential effects of systemic hyperglycemia need to be excluded. To achieve this, we studied the effects of a high-glucose wound concentration on the healing of FTW in non-diabetic pigs. Wounds that were subjected to a local hyperglycemic environment healed slightly but not significantly faster than control wounds. These findings suggest that wound-healing impairment in diabetes is not induced by local hyperglycemia within the wound environment itself and that local hyperosmolarity does not play a key role in our studies.

We could show that wound healing in diabetic pigs was significantly delayed compared to non-diabetic pigs. A diabetic state for 4 months before wounding did not further delay wound healing significantly and several intrinsic changes were demonstrated in wound healing such as altered growth factor concentrations (paper I).

The streptozotocin induced diabetic pig possesses several qualities to study cutaneous healing and new treatment modalities.

Chamber Model

Desiccation was prevented by the use of liquid-tight polyurethane chambers filled with normal saline. The wound fluid inside the chamber equilibrates with the concentrations of electrolytes, proteins, growth factors found in the interstitial space. The beneficial effect of a wet wound environment using this chamber model has previously been demonstrated³⁸⁻⁴¹. The sealed chamber allows for the wound microenvironment to be readily monitored and modified, giving us insight into how wounds heal. It protects

the wound; the liquid medium or saline in the chamber provides *in vivo* tissue culture-like conditions. The wound chamber causes no injury to the wound itself or to the surrounding intact skin. Antibiotics, analgesics, and various molecules can be delivered to the wound through the chamber. Topical delivery of various substances can provide very high concentrations at the wound site and with a favorable direction of the concentration gradient.

Cell transplantation

Fibroblasts play a vital role in the proliferative stage of acute wound healing. They migrate into the wound, secreting collagen and other proteins that are essential for the extra cellular matrix (ECM). Once in the ECM, they form an interconnected network of cells that interact by mechanical, chemical, and electrical signals. Fibroblasts from diabetic wounds have been shown to have an altered morphology and a decreased activity^{42 43}. In study II, a significant enhancement in epidermal healing was demonstrated by transplanting autologous fibroblasts into wounds in diabetic pigs. These fibroblasts may have contributed to restoring some of the function normally seen in the proliferative phase by increasing the number of fibroblasts in the ECM. This may increase collagen secretion and protein concentration and may have helped to essentially normalize wound healing.

In diabetes, the rate of proliferation and differentiation of keratinocytes is greatly reduced contributing to delayed wound healing⁴⁴. Early studies from our institution, the laboratory of tissue repair and gene transfer, have shown that transplanting a suspension of keratinocytes to normal non-diabetic porcine wounds leads to an enhanced reepithelialization^{45 46}. The transplanted cells proliferate at the base of the wound and form clusters of cells that progressively migrate upward to the wound surface to contribute to the regeneration of the epidermis⁴⁶. A similar beneficial effect was seen in study II. Study IV demonstrated similar positive effects using allogenic keratinocytes in non-diabetic wounds. This adds the option of using cells "off the shelf". Several studies have demonstrated the beneficial effects of using allogenic cells in helping healing chronic wounds and burns⁴⁷⁻⁵¹.

Our interest to transplant cells into wounds is twofold. One purpose is simply to improve epidermal healing by adding more cells, ie strengthening the troops at the battle field. An other interest is to use cells as a transport medium to deliver genetic material where it is most needed, ie strengthening the troops with better weapons. This process is referred to as gene therapy, altering the genetic material of cells.

Gene Therapy

Gene therapy is gaining interest as a treatment modality for non healing wounds. There are different methods to deliver beneficial new genetic materials into wounds. They vary widely in their cost, practicality and effectiveness.

The simplest method is to inject the new DNA directly into the wound⁵²⁻⁵³. The poor uptake of the DNA strand into cells leads to poor production of the resulting protein and thus little or no benefit in healing⁵⁴⁻⁵⁵. Alternatively, a protein can be directly applied to the wound such as using an ointment rich in growth factors directly on the wound. Some studies have shown some limited positive effect⁵⁶⁻⁶². One main problem is the vast amount of proteases in the wound environment that quickly neutralizes the growth factor⁶³⁻⁶⁵. To achieve a more beneficial effect, the growth factors need to be produced constantly to compensate for the protease activity. To achieve a constant production of growth factor in the wound environment, two main methods exist. Transfection and infection.

Infection involves using a virus as a vector. A vector carries the new genetic material and deliver it into the cells so that this new genetic material can be expressed.

In our laboratory, we have used a non-replicant herpes virus as a vector. In vitro testing have shown very promising results but further research is needed to achieve stronger expression in vivo.

Transfection is the process of deliberately introducing nucleic acids into cells. Transfection of cells typically involves opening transient pores or “holes” in the cell membrane to allow the uptake of material⁵⁵. In the papers involved in this study, transfection was carried out by mixing a cationic lipid with the plasmid to produce liposomes, which fuse with the cell membrane and deposit their cargo inside. Keratinocytes were used to transfect rather than fibroblasts. In vitro experiments have shown superior and longer lasting expression from transfected keratinocytes than fibroblasts⁶⁶. These keratinocytes are then used as a transport vehicle to deliver the new nucleic acid in the wound. The beneficial effects are twofold as keratinocytes contribute to improved wound healing by themselves. By over expressing a growth factor such as EGF or IGF-1, epidermal healing is further improved.

Over expression of growth factors needs to be studied further to analyze possible long term risks. Over stimulation in the complex wound healing cascade could lead to hypertrophic or keloid scars or even tumours. Over expression of VEGF has shown an angiogenesis similar to that seen in tumours⁶⁷.

Growth factors

Growth factors are naturally occurring proteins or steroids which are typically released at the wound site during injury. They are produced by cells involved in the healing process such as macrophages and platelets, and play a key role in orchestrating the complex

wound healing cascade by regulating cell to cell interactions^{7 68 69}. In chronic diabetic wounds, the concentration of several growth factors has been shown to be decreased compared with acute non diabetic wounds. The response to growth factors has also be shown to be decreased^{11 14 36 37 64 70-73}.

Many attempts at delivering growth factors at the wound site have been done⁷⁴⁻⁸². However, it has proved difficult to achieve a high expression where it is needed in the wound. A suggested explanation is that growth factors degrade rapidly and delivery systems are often ineffective.

Insulin-like growth factor 1 (IGF-1) is a polypeptide that acts in a similar way to hormones. It is transferred from blood and local sites of production by binding to transfer proteins to reach its target⁶⁵. The concentration of binding proteins is decreased in diabetic wounds. Similarly the level of IGF-1 antagonist is increased in diabetic wounds.³⁶ The concentration of IGF-1 has been shown to be drastically reduced in fibroblasts and in the basal layer from skin of diabetic patients as well as in diabetic ulcers compared to nondiabetic wounds. As IGF-1 has shown proliferative effects on keratinocytes and fibroblasts in vitro⁸³, paper III investigated the effect of over expressing IGF-1 in the wound micro-environment to compensate for the defects seen in diabetic wounds. Results showed a beneficial effect in epidermal healing.

EGF is a polypeptide that was first isolated in 1962 by Stanley Cohen who received a Nobel prize for his work with growth factors⁸⁴. It is released by α -granules of platelets and is thought to stimulate the G1 phase of the cell cycle. By binding to specific EGF receptors on the cell surfaces of endothelial cells, fibroblasts and keratinocytes, it stimulates epidermal cell growth, differentiation and migration⁸⁵. However, in diabetic wounds, EGF receptors are also targets for advanced glycation end products precursor. By competing with EGF with binding to specific receptors, they further decrease the effect of EGF, hence limiting cell differentiation, proliferation and migration¹³. In study V, we transplanted keratinocytes transfected with an EGF plasmid into diabetic porcine wounds. A very high level of EGF expression was achieved in the wound microenvironment compared with the non treated wounds. By increasing the level of EGF considerably, we may have been able to minimize AGE precursors binding to EGF receptors. The constant over-production of EGF also limited the effect of proteases. A protease is an enzyme that breaks down proteins. In diabetic wounds, the concentration of proteases is greatly increased and contributes to limiting the effect of growth factors. By overcoming the negative effects of proteases and AGE precursors, EGF could bind to its specific receptors and stimulate differentiation, proliferation and migration of cells to enhance wound healing.

We were able to demonstrate a positive effect on epidermal healing in diabetic porcine wounds by over-expressing either EGF or IGF-1. The over-expression seem to compensate for the arduous environment seen in diabetic wounds such as competition with AGE precursors, increased protease concentration and decreased concentration of binding protein. The next logical step would have been to combine the over-expression of EGF with IGF-1 in the same wound. This was investigated but as healing with either EGF transfected cells or IGF-1 transfected cells showed such beneficial effect,

no significant additional effect was seen compared to single growth factor transfection though a more favorable trend was noticed (unpublished data).

Epithelialization

Measurement of epidermal healing can be done invasively or non-invasively. The non-invasive method involves the use of planimetry and allows for repeated measurements of each wound during the course of wound healing. The invasive method involves taking a biopsy of the wound at a specific time point.

Planimetry involves either tracing the re-epithelized area macroscopically with the use of transparent paper or taking a photograph of the wound with the help of a close up lens. With the help of software, such as sigma imaging, the re-epithelialization area is calculated. The advantage of this method is that it allows for multiple measurements of each wound without interfering with the healing process itself. However the drawback is the risk of errors. It is necessary to photograph each wound at constant distance and enlargement to ensure an accurate measurement.

In the invasive method of measurement, a biopsy of the wound is taken. It is then embedded in paraffin and the resulting slides are stained with H&E for analysis. With the help of microscopy, reepithelialization can be measured accurately on a repeated basis by measuring the epithelial tongues. To minimize errors, the wound margins are tattooed prior to wounding. This provides a definite starting point to measure re-epithelialization. The advantage of this methodology is the superior accuracy of the measurements.

Macroscopic analysis of epidermal healing is less accurate than microscopic analysis and is more prone to subjective measurement. In the studies involved in this thesis, an invasive method of measurement was chosen for its accuracy and reliability.

Conclusion

The presented studies highlight the development of a new model of delayed wound healing and its use in diabetic wound healing research. Valuable insights were gained on the effect of using cell suspensions on their own, or genetically altered, as a novel treatment modality for diabetic wounds. Further insights were gained on the effect of "normalizing" growth factor levels in the wound microenvironment of experimental diabetic wounds.

More specifically

1. A novel model of diabetic impaired wound healing was developed for large animal studies that can be used toward the discovery of pathophysiologic mechanisms in impaired wound healing and investigations of new approaches to treatment of wounds.
2. A cell suspension of fibroblasts or keratinocytes doesn't only survive in the hostile wound environment of this new wound healing model, but also contribute to improved epidermal healing.
3. Keratinocytes can be used as a vector to deliver IGF-1 transgene in the wound microenvironment. The expression of IGF-1 is increased drastically and improves epidermal healing.
4. Allogenic keratinocytes transfected with EGF plasmid can be used as a vector and survive long enough in the wound to allow for prolonged over-expression of EGF. They also contribute to enhance re-epithelialization in normal non-diabetic porcine wounds.
5. Autologous keratinocytes transfected with EGF overexpress EGF in the wound microenvironment for a period of time, which is clinically relevant, and enhance re-epithelialization.

Future directions

Many obstacles still need to be overcome before gene therapy becomes a realistic alternative for treating diabetic wounds. A gene needs to be easily inserted into a wound, and its expression must be sufficient where, and when, it is needed. Any potential risk of tumour genesis arising due to over expression of growth factors also needs to be fully assessed⁸⁶⁻⁸⁸.

The optimal therapy for a non-healing wound would be a treatment that can be adjusted to the specific needs of the individual patient. Such therapy should allow for the control of when over expression of a growth factor is started, how much is produced, at which time and for how long. In gene therapies, a promoter present in the viral genome controls the expression of a transgene, excluding any outside control.

F. Yao and E. Eriksson, from the laboratory of tissue repair and gene transfer in Boston have developed a TET-switch that can be inserted into a viral genome⁸⁹⁻⁹². A TET-switch is a promoter dependent on tetracyclin, which allows for outside control of transgene expression. When tetracyclin is given, expression starts and is dose dependent. This means that expression of a growth factor is regulated as to when, how much and how long it is produced simply by changing the dose of tetracyclin.

In studies III to V, keratinocytes were used as a delivery vehicle for various growth factor expressing genes. This involves cell harvesting, culture and transfection of cells with the appropriate transgene before treatment can be started. Using a viral vector would inhibit this delay as it could be used "off the shelf". With a TET-switch, production of growth factors could be modulated to obtain optimal concentrations during the different stages of wound healing.

Even though research continues to improve wound-healing modalities and shows promising options for the future, the importance of prevention cannot be overemphasized.

Populärvetenskaplig sammanfattning (summary in swedish)

Diabetes är en folksjukdom där c:a 350000 människor i Sverige är drabbade. Fotsår är en vanlig komplikation vid diabetes, och sådana svårläkta sår leder till c:a 700 diabetesrelaterade amputationer årligen. Såväl sårerna som amputationssituationen orsakar funktionshinder, smärta, sociala bekymmer samt psykisk stress för dem som drabbas. Att utveckla nya och förbättrade behandlingar för sårsläkning vid diabetes är angeläget, men det finns idag igen riktigt bra sårsläkningsmodell som lämpar sig för forskning inom detta område.

Syftet med detta projekt var att utveckla en ny djurmodell för diabetisk sårsläkning som kan användas i forskningsarbetet. Modellen skulle inte bara medge möjlighet att värdera nya behandlingar för diabetiska sår i vid bemärkelse utan också kunna belysa betydelsen av olika former av cellterapi och genterapi. Eftersom grishud har stora likheter med människans hud valdes grisen som bas för den diabetiska sårsläkningsmodellen.

I det första delprojektet visades att inducerad diabetes hos grisar leder till försämrad sårsläkning som i allt väsentligt liknar den hos människan med diabetes.

I det andra delprojektet visades att sårsläkningen förbättrades hos diabetiska grisar genom att tranplantera antingen hudceller eller bindvävsceller. Resultaten från studien ledde också till tanken att använda dessa celler som bärare av nya gener med läkningsbefrämjande effekter.

I det tredje delprojektet användes således hudceller som transportmedel för en gen som producerar tillväxtfaktorn insulin like growth factor I (IGF-1). Transplantation av dessa IGF-1-innehållande celler visade kraftig ökad produktion av IGF-1 i sårområdet samt förbättrad sårsläkning.

I det fjärde delprojektet användes hudceller från en annan donator med en gen som producerar tillväxtfaktorn epidermal growth factor (EGF). Transplantation av dessa celler i normala icke-diabetiska sår ledde till kraftigt ökad produktion av EGF i sårområdet samt förbättrad sårsläkning.

I det femte delprojektet användes kunskapen från fjärde delprojektet, och hudceller med tillsatt gen för EGF tranplanterades i sår på diabetiska grisar. Produktionen av EGF blev kraftigt ökad i sårområdet och läkningen blev påfallande förbättrad.

Tillsammans har dessa studier lett till utvecklingen av en ny diabetisk sårläkningsmodell på gris och denna lämpar sig väl för forskning kring diabetisk sårlekning. Studierna har därtill lett till insikter om hur celler kan användas i kombination med genterapi för att förbättra sårlekning vid diabetes.

Acknowledgements

The work underlying this thesis has been performed through collaboration between Lund University and the laboratory of tissue repair and gene transfer, Harvard Medical School.

I would like to express my gratitude to everyone who supported me in this project as well as to financial sponsors. I am particularly indebted to Christoph Theopold, Oliver Bleiziffer & Daniela Hoeller.

To Henry Svensson, Principal supervisor, for his guidance, support and understanding.

To Elof Eriksson, assistant supervisor, for his mentorship, his endless patience and strong support during all times.

To Feng Yao, for his patience when introducing the world of laboratory based research.

To Kerstin and Erik, my parents, for always being there.

To Anna och Edwin Bergers stiftelse for their generous financial support.

References

1. Martin P. Wound healing--aiming for perfect skin regeneration. *Science* 1997;276(5309):75-81.
2. Singer AJ, Clark RA. Cutaneous wound healing. *N Engl J Med* 1999;341(10):738-46.
3. Bowler PG. Wound pathophysiology, infection and therapeutic options. *Ann Med* 2002;34(6):419-27.
4. Puccinelli TJ, Bertics PJ, Masters KS. Regulation of keratinocyte signaling and function via changes in epidermal growth factor presentation. *Acta Biomater* 2010;6(9):3415-25.
5. Gurtner GC, Werner S, Barrandon Y, Longaker MT. Wound repair and regeneration. *Nature* 2008;453(7193):314-21.
6. Ansel J, Perry P, Brown J, Damm D, Phan T, Hart C, et al. Cytokine modulation of keratinocyte cytokines. *J Invest Dermatol* 1990;94(6 Suppl):101S-07S.
7. Bennett NT, Schultz GS. Growth factors and wound healing: Part II. Role in normal and chronic wound healing. *Am J Surg* 1993;166(1):74-81.
8. Banting FG. An Address on Diabetes and Insulin: Being The Nobel Lecture Delivered at Stockholm on September 15th, 1925. *Can Med Assoc J* 1926;16(3):221-32.
9. Dechert TA, Ducale AE, Ward SI, Yager DR. Hyaluronan in human acute and chronic dermal wounds. *Wound Repair Regen* 2006;14(3):252-8.
10. Yki-Jarvinen H. Toxicity of hyperglycaemia in type 2 diabetes. *Diabetes Metab Rev* 1998;14 Suppl 1:S45-50.
11. Kamal K, Powell RJ, Sumpio BE. The pathobiology of diabetes mellitus: implications for surgeons. *J Am Coll Surg* 1996;183(3):271-89.
12. Porte D, Jr., Schwartz MW. Diabetes complications: why is glucose potentially toxic? *Science* 1996;272(5262):699-700.
13. Friedman EA. Advanced glycosylated end products and hyperglycemia in the pathogenesis of diabetic complications. *Diabetes Care* 1999;22 Suppl 2:B65-71.
14. Greenhalgh DG. Wound healing and diabetes mellitus. *Clin Plast Surg* 2003;30(1):37-45.
15. Mostow EN. Diagnosis and classification of chronic wounds. *Clin Dermatol* 1994;12(1):3-9.
16. Yuan S, Liu Y, Zhu L. Vascular complications of diabetes mellitus. *Clin Exp Pharmacol Physiol* 1999;26(12):977-8.
17. Singh N, Armstrong DG, Lipsky BA. Preventing foot ulcers in patients with diabetes. *JAMA* 2005;293(2):217-28.
18. Sen CK, Gordillo GM, Roy S, Kirsner R, Lambert L, Hunt TK, et al. Human skin wounds: a major and snowballing threat to public health and the economy. *Wound Repair Regen* 2009;17(6):763-71.
19. Tsuboi R, Rifkin DB. Recombinant basic fibroblast growth factor stimulates wound healing in healing-impaired db/db mice. *J Exp Med* 1990;172(1):245-51.
20. Davidson JM. Animal models for wound repair. *Arch Dermatol Res* 1998;290 Suppl:S1-11.
21. Fang RC, Mustoe TA. Animal models of wound healing: utility in transgenic mice. *J Biomater Sci Polym Ed* 2008;19(8):989-1005.
22. Greenhalgh DG. Models of wound healing. *J Burn Care Rehabil* 2005;26(4):293-305.
23. Komesu MC, Tanga MB, Buttrots KR, Nakao C. Effects of acute diabetes on rat cutaneous wound healing. *Pathophysiology* 2004;11(2):63-67.
24. Montagna W, Yun JS. The Skin of the Domestic Pig. *J Invest Dermatol* 1964;42:11-21.
25. Sullivan TP, Eaglstein WH, Davis SC, Mertz P. The pig as a model for human wound healing. *Wound Repair Regen* 2001;9(2):66-76.
26. Bell RH, Jr., Hye RJ. Animal models of diabetes mellitus: physiology and pathology. *J Surg Res* 1983;35(5):433-60.

27. Apelqvist J, Ragnarson-Tennvall G, Persson U, Larsson J. Diabetic foot ulcers in a multidisciplinary setting. An economic analysis of primary healing and healing with amputation. *J Intern Med* 1994;235(5):463-71.
28. Elsner M, Gurgul-Convey E, Lenzen S. Relation between triketone structure, generation of reactive oxygen species, and selective toxicity of the diabetogenic agent alloxan. *Antioxid Redox Signal* 2008;10(4):691-9.
29. Lenzen S. The mechanisms of alloxan- and streptozotocin-induced diabetes. *Diabetologia* 2008;51(2):216-26.
30. Islam MS, Loots du T. Experimental rodent models of type 2 diabetes: a review. *Methods Find Exp Clin Pharmacol* 2009;31(4):249-61.
31. Grussner R, Nakhleh R, Grussner A, Tomadze G, Diem P, Sutherland D. Streptozotocin-induced diabetes mellitus in pigs. *Horm Metab Res* 1993;25(4):199-203.
32. Gabel H, Bitter-Suermann H, Henriksson C, Save-Soderbergh J, Lundholm K, Brynner H. Streptozotocin diabetes in juvenile pigs. Evaluation of an experimental model. *Horm Metab Res* 1985;17(6):275-80.
33. Wilson JD, Dhall DP, Simeonovic CJ, Lafferty KJ. Induction and management of diabetes mellitus in the pig. *Aust J Exp Biol Med Sci* 1986;64 (Pt 6):489-500.
34. Morel P, Kaufmann DB, Matas AJ, Tzardis P, Field MJ, Lloveras JK, et al. Total pancreatectomy in the pig for islet transplantation. Technical alternatives. *Transplantation* 1991;52(1):11-5.
35. Bitar MS. Insulin and glucocorticoid-dependent suppression of the IGF-I system in diabetic wounds. *Surgery* 2000;127(6):687-95.
36. Blakytyn R, Jude EB, Martin Gibson J, Boulton AJ, Ferguson MW. Lack of insulin-like growth factor 1 (IGF1) in the basal keratinocyte layer of diabetic skin and diabetic foot ulcers. *J Pathol* 2000;190(5):589-94.
37. Choi JS, Leong KW, Yoo HS. In vivo wound healing of diabetic ulcers using electrospun nanofibers immobilized with human epidermal growth factor (EGF). *Biomaterials* 2008;29(5):587-96.
38. Eriksson E, Vranckx J. Wet wound healing: from laboratory to patients to gene therapy. *Am J Surg* 2004;188(1A Suppl):36-41.
39. Vogt PM, Andree C, Breuing K, Liu PY, Slama J, Helo G, et al. Dry, moist, and wet skin wound repair. *Ann Plast Surg* 1995;34(5):493-9; discussion 99-500.
40. Svensjo T, Pomahac B, Yao F, Slama J, Eriksson E. Accelerated healing of full-thickness skin wounds in a wet environment. *Plast Reconstr Surg* 2000;106(3):602-12; discussion 13-4.
41. Breuing K, Eriksson E, Liu P, Miller DR. Healing of partial thickness porcine skin wounds in a liquid environment. *J Surg Res* 1992;52(1):50-8.
42. Hendrickx B, Verdonck K, Van den Berge S, Dickens S, Eriksson E, Vranckx JJ, et al. Integration of blood outgrowth endothelial cells in dermal fibroblast sheets promotes full thickness wound healing. *Stem Cells* 2010;28(7):1165-77.
43. Loots MA, Lamme EN, Mekkes JR, Bos JD, Middelkoop E. Cultured fibroblasts from chronic diabetic wounds on the lower extremity (non-insulin-dependent diabetes mellitus) show disturbed proliferation. *Arch Dermatol Res* 1999;291(2-3):93-9.
44. Spravchikov N, Sizyakov G, Gartsbein M, Accili D, Tennenbaum T, Wertheimer E. Glucose effects on skin keratinocytes: implications for diabetes skin complications. *Diabetes* 2001;50(7):1627-35.
45. Vogt PM, Thompson S, Andree C, Liu P, Breuing K, Hatzis D, et al. Genetically modified keratinocytes transplanted to wounds reconstitute the epidermis. *Proc Natl Acad Sci U S A* 1994;91(20):9307-11.
46. Svensjo T, Yao F, Pomahac B, Eriksson E. Autologous keratinocyte suspensions accelerate epidermal wound healing in pigs. *J Surg Res* 2001;99(2):211-21.
47. Delaere P, Vranckx J, Verleden G, De Leyn P, Van Raemdonck D. Tracheal allotransplantation after withdrawal of immunosuppressive therapy. *N Engl J Med* 2010;362(2):138-45.
48. Cuono C, Langdon R, McGuire J. Use of cultured epidermal autografts and dermal allografts as skin replacement after burn injury. *Lancet* 1986;1(8490):1123-4.
49. Hefton JM, Madden MR, Finkelstein JL, Shires GT. Grafting of burn patients with allografts of cultured epidermal cells. *Lancet* 1983;2(8347):428-30.

50. Rosenberg AS, Singer A. Cellular basis of skin allograft rejection: an in vivo model of immune-mediated tissue destruction. *Annu Rev Immunol* 1992;10:333-58.
51. Rouabhia M. Permanent skin replacement using chimeric epithelial cultured sheets comprising xenogeneic and syngeneic keratinocytes. *Transplantation* 1996;61(9):1290-300.
52. Fernandez-Montequin JI, Betancourt BY, Leyva-Gonzalez G, Mola EL, Galan-Naranjo K, Ramirez-Navas M, et al. Intralesional administration of epidermal growth factor-based formulation (Heberprot-P) in chronic diabetic foot ulcer: treatment up to complete wound closure. *Int Wound J* 2009;6(1):67-72.
53. Fernandez-Montequin JI, Valenzuela-Silva CM, Diaz OG, Savigne W, Sancho-Soutelo N, Rivero-Fernandez F, et al. Intra-lesional injections of recombinant human epidermal growth factor promote granulation and healing in advanced diabetic foot ulcers: multicenter, randomised, placebo-controlled, double-blind study. *Int Wound J* 2009;6(6):432-43.
54. Eriksson E, Yao F, Svensjo T, Winkler T, Slama J, Macklin MD, et al. In vivo gene transfer to skin and wound by microseeding. *J Surg Res* 1998;78(2):85-91.
55. Hoeller D, Petrie N, Yao F, Eriksson E. Gene therapy in soft tissue reconstruction. *Cells Tissues Organs* 2002;172(2):118-25.
56. Brown GL, Nanney LB, Griffen J, Cramer AB, Yancey JM, Curtsinger LJ, 3rd, et al. Enhancement of wound healing by topical treatment with epidermal growth factor. *N Engl J Med* 1989;321(2):76-9.
57. Pierce GF, Tarpley JE, Tseng J, Bready J, Chang D, Kenney WC, et al. Detection of platelet-derived growth factor (PDGF)-AA in actively healing human wounds treated with recombinant PDGF-BB and absence of PDGF in chronic nonhealing wounds. *J Clin Invest* 1995;96(3):1336-50.
58. Steed DL. Clinical evaluation of recombinant human platelet-derived growth factor for the treatment of lower extremity ulcers. *Plast Reconstr Surg* 2006;117(7 Suppl):143S-49S; discussion 50S-51S.
59. Mustoe TA, Cutler NR, Allman RM, Goode PS, Deuel TF, Prause JA, et al. A phase II study to evaluate recombinant platelet-derived growth factor-BB in the treatment of stage 3 and 4 pressure ulcers. *Arch Surg* 1994;129(2):213-9.
60. Smiell JM, Wieman TJ, Steed DL, Perry BH, Sampson AR, Schwab BH. Efficacy and safety of becaplermin (recombinant human platelet-derived growth factor-BB) in patients with nonhealing, lower extremity diabetic ulcers: a combined analysis of four randomized studies. *Wound Repair Regen* 1999;7(5):335-46.
61. Wieman TJ, Smiell JM, Su Y. Efficacy and safety of a topical gel formulation of recombinant human platelet-derived growth factor-BB (becaplermin) in patients with chronic neuropathic diabetic ulcers. A phase III randomized placebo-controlled double-blind study. *Diabetes Care* 1998;21(5):822-7.
62. Falanga V, Eaglstein WH, Bucalo B, Katz MH, Harris B, Carson P. Topical use of human recombinant epidermal growth factor (h-EGF) in venous ulcers. *J Dermatol Surg Oncol* 1992;18(7):604-6.
63. Castronuovo JJ, Jr., Ghobrial I, Giusti AM, Rudolph S, Smiell JM. Effects of chronic wound fluid on the structure and biological activity of becaplermin (rhPDGF-BB) and becaplermin gel. *Am J Surg* 1998;176(2A Suppl):61S-67S.
64. Fahey TJ, 3rd, Sherry B, Tracey KJ, van Deventer S, Jones WG, 2nd, Minei JP, et al. Cytokine production in a model of wound healing: the appearance of MIP-1, MIP-2, cachectin/TNF and IL-1. *Cytokine* 1990;2(2):92-9.
65. Loots MA, Lamme EN, Zeegelaar J, Mekkes JR, Bos JD, Middelkoop E. Differences in cellular infiltrate and extracellular matrix of chronic diabetic and venous ulcers versus acute wounds. *J Invest Dermatol* 1998;111(5):850-7.
66. Dickens S, Van den Berge S, Hendrickx B, Verdonck K, Luttun A, Vranckx J. Non-viral gene therapy strategies for keratinocytes, fibroblasts and endothelial progenitor cells for ex vivo gene transfer to skin wounds. *Tissue Eng Part C Methods* 2010.
67. Li B, Sharpe EE, Maupin AB, Teleron AA, Pyle AL, Carmeliet P, et al. VEGF and PlGF promote adult vasculogenesis by enhancing EPC recruitment and vessel formation at the site of tumor neovascularization. *FASEB J* 2006;20(9):1495-7.

68. Breuing K, Andree C, Helo G, Slama J, Liu PY, Eriksson E. Growth factors in the repair of partial thickness porcine skin wounds. *Plast Reconstr Surg* 1997;100(3):657-64.
69. Lynch SE, Colvin RB, Antoniadis HN. Growth factors in wound healing. Single and synergistic effects on partial thickness porcine skin wounds. *J Clin Invest* 1989;84(2):640-6.
70. Bitar MS, Labbad ZN. Transforming growth factor-beta and insulin-like growth factor-I in relation to diabetes-induced impairment of wound healing. *J Surg Res* 1996;61(1):113-9.
71. Mustoe TA, Tae Ahn S, Tarpley JE, Pierce GF. Role of hypoxia in growth factor responses: differential effects of basic fibroblast growth factor and platelet-derived growth factor in an ischemic wound model. *Wound Repair Regen* 1994;2(4):277-83.
72. Doxey DL, Ng MC, Dill RE, Iacopino AM. Platelet-derived growth factor levels in wounds of diabetic rats. *Life Sci* 1995;57(11):1111-23.
73. Jeffcoate WJ, Price P, Harding KG. Wound healing and treatments for people with diabetic foot ulcers. *Diabetes Metab Res Rev* 2004;20 Suppl 1:S78-89.
74. Pierce GF, Tarpley JE, Allman RM, Goode PS, Serdar CM, Morris B, et al. Tissue repair processes in healing chronic pressure ulcers treated with recombinant platelet-derived growth factor BB. *Am J Pathol* 1994;145(6):1399-410.
75. Bennett SP, Griffiths GD, Schor AM, Leese GP, Schor SL. Growth factors in the treatment of diabetic foot ulcers. *Br J Surg* 2003;90(2):133-46.
76. Fu X, Li X, Cheng B, Chen W, Sheng Z. Engineered growth factors and cutaneous wound healing: success and possible questions in the past 10 years. *Wound Repair Regen* 2005;13(2):122-30.
77. Andree C, Swain WF, Page CP, Macklin MD, Slama J, Hatzis D, et al. In vivo transfer and expression of a human epidermal growth factor gene accelerates wound repair. *Proc Natl Acad Sci U S A* 1994;91(25):12188-92.
78. Albertson S, Hummel RP, 3rd, Breeden M, Greenhalgh DG. PDGF and FGF reverse the healing impairment in protein-malnourished diabetic mice. *Surgery* 1993;114(2):368-72; discussion 72-3.
79. Greenhalgh DG, Rieman M. Effects of basic fibroblast growth factor on the healing of partial-thickness donor sites. A prospective, randomized, double-blind trial. *Wound Repair Regen* 1994;2(2):113-21.
80. Hollinger JO, Hart CE, Hirsch SN, Lynch S, Friedlaender GE. Recombinant human platelet-derived growth factor: biology and clinical applications. *J Bone Joint Surg Am* 2008;90 Suppl 1:48-54.
81. Steed DL. Modifying the wound healing response with exogenous growth factors. *Clin Plast Surg* 1998;25(3):397-405.
82. Vranckx JJ, Yao F, Petrie N, Augustinova H, Hoeller D, Visovatti S, et al. In vivo gene delivery of Ad-VEGF121 to full-thickness wounds in aged pigs results in high levels of VEGF expression but not in accelerated healing. *Wound Repair Regen* 2005;13(1):51-60.
83. Kratz G, Lake M, Ljungstrom K, Forsberg G, Haegerstrand A, Gidlund M. Effect of recombinant IGF binding protein-1 on primary cultures of human keratinocytes and fibroblasts: selective enhancement of IGF-1 but not IGF-2-induced cell proliferation. *Exp Cell Res* 1992;202(2):381-5.
84. Hardwicke J, Schmaljohann D, Boyce D, Thomas D. Epidermal growth factor therapy and wound healing--past, present and future perspectives. *Surgeon* 2008;6(3):172-7.
85. Berlanga-Acosta J, Gavilondo-Cowley J, Lopez-Saura P, Gonzalez-Lopez T, Castro-Santana MD, Lopez-Mola E, et al. Epidermal growth factor in clinical practice - a review of its biological actions, clinical indications and safety implications. *Int Wound J* 2009;6(5):331-46.
86. Robson MC, Mustoe TA, Hunt TK. The future of recombinant growth factors in wound healing. *Am J Surg* 1998;176(2A Suppl):80S-82S.
87. Rumalla VK, Borah GL. Cytokines, growth factors, and plastic surgery. *Plast Reconstr Surg* 2001;108(3):719-33.
88. Sweitzer SM, Fann SA, Borg TK, Baynes JW, Yost MJ. What is the future of diabetic wound care? *Diabetes Educ* 2006;32(2):197-210.
89. Yao F, Pomahac B, Visovatti S, Chen M, Johnson S, Augustinova H, et al. Systemic and localized reversible regulation of transgene expression by tetracycline with tetR-mediated transcription repression switch. *J Surg Res* 2007;138(2):267-74.

90. Yao F, Eriksson E. A novel tetracycline-inducible viral replication switch. *Hum Gene Ther* 1999;10(3):419-27.
91. Yao F, Svensjo T, Winkler T, Lu M, Eriksson C, Eriksson E. Tetracycline repressor, tetR, rather than the tetR-mammalian cell transcription factor fusion derivatives, regulates inducible gene expression in mammalian cells. *Hum Gene Ther* 1998;9(13):1939-50.
92. Yao F, Theopold C, Hoeller D, Bleiziffer O, Lu Z. Highly efficient regulation of gene expression by tetracycline in a replication-defective herpes simplex viral vector. *Mol Ther* 2006;13(6):1133-41.

Paper I



Impaired wound healing in an acute diabetic pig model and the effects of local hyperglycemia

Patrik Velander, MD^{1,2}; Christoph Theopold, MD¹; Tobias Hirsch, MD¹; Oliver Bleiziffer, MD¹; Baraa Zuhaili, MD¹; Magdalena Fossum, MD, PhD¹; Daniela Hoeller, MD¹; Raphael Gheerardyn, MD¹; Michael Chen, MD¹; Scott Visovatti, MD¹; Henry Svensson, MD²; Feng Yao, PhD¹; Elof Eriksson, MD, PhD¹

1. Laboratory of Tissue Repair and Gene Transfer, Division of Plastic Surgery, Brigham and Women's Hospital, Harvard Medical School, Boston, Massachusetts, and

2. Department of Clinical Sciences, Division of Plastic Surgery, Lund University, Malmö, Sweden

Reprint requests:

Elof Eriksson, MD, PhD, Chief, Division of Plastic Surgery, Brigham and Women's Hospital, 75 Francis Street, Boston, MA 02115.

Email: eeriksson@partners.org

Manuscript received: December 4, 2006
Accepted in final form: December 3, 2007

DOI:10.1111/j.1524-475X.2008.00367.x

ABSTRACT

Diabetic wounds result in significant morbidity, prolonged hospitalization, and enormous health-care expenses. Pigs have been shown to have wound healing resembling that in humans. The aim of this study was to develop a large-animal model for diabetic wound healing. Diabetes was induced by streptozotocin injection in Yorkshire pigs. Full-thickness wounds were created and dressed with a sealed chamber. Nondiabetic pigs with or without high glucose wound fluid concentration served as controls. Glucose concentration in serum and wound fluid was measured and collected. Wound contraction was monitored, and biopsies were obtained for measurement of reepithelialization. Wound fluid was analyzed for insulin-like growth factor-1 (IGF-1), platelet-derived growth factor, and transforming growth factor. Glucose concentration in wound fluid initially followed serum levels and then decreased to undetectable on day 9. Reepithelialization was significantly delayed in diabetic pigs. In nondiabetic pigs, wounds treated in a local hyperglycemic environment, and thus excluding the effects of systemic hyperglycemia, showed no difference in wound closure compared with controls. This suggests that delayed wound healing in diabetes is not induced by local high-glucose concentration itself. Analysis of growth factor expression showed a marked reduction in IGF-1 in the diabetic wounds. Diabetic pigs have impaired healing that is accompanied by a reduction of IGF-1 in the healing wound and is not due to the local hyperglycemia condition itself.

Approximately 5 million patients in the United States suffer from chronic wounds.¹ With the increased longevity, obesity, and diabetes, the problem of chronic wounds has increased, resulting in significant morbidity, lost time from work, and enormous health-care expenses. According to the American Diabetes Association, 25% of people with diabetes will suffer from a wound problem during their lifetime, and approximately 82,000 limb amputations for nontraumatic wounds were performed in people with diabetes in 2002.² The Agency for Health Care Policy and Research reports that wound care for pressure ulcers uses \$200 billion a year for hospitalization, durable medical goods, nursing home care, physicians, and transportation.³ Surgical treatment of diabetic wounds remains difficult and often insufficient, leading to high morbidity among those patients.⁴ We need better ways to treat diabetic wounds and relevant preclinical models are needed to develop new therapeutic strategies.

Numerous diabetic wound healing models have been described.^{5,6} Small mammals, such as rats, rabbits, guinea pigs, and mice, are frequently used in wound healing studies because of cost and ease of handling. However, the anatomy and physiology of small mammals differ from those of humans in many ways.⁷ Pig physiology and wound healing has been found to be significantly more similar to humans.^{8,9} In wound healing models investigat-

ing basic fibroblast growth factor (bFGF), wounds in genetically diabetic db/db mice treated with bFGF healed significantly faster than wounds in control mice.¹⁰ However, studies evaluating the use of bFGF in porcine partial-thickness wound models did not support these findings,¹¹ and a small randomized, double-blind study of 11 human patients found no effect of bFGF on reepithelialization of split skin graft donor sites as compared with vehicle-treated control wounds.¹²

Furthermore, the overall physiology of pigs is close to that of humans, with the anatomy and function of most key organ systems being similar. The many similarities between humans and pigs have led to the conclusion that the pig is an excellent animal model for wound-healing studies.

Sullivan et al.⁷ evaluated 25 different wound therapies and showed that, in studies that could be compared with human studies, the results in porcine models agreed with those of human studies 78% of the time, whereas results of small-mammal models showed only 53 and 57% for in vitro studies.

These and other findings show that the pig is more suitable than small-animal models for simulation of human wound healing.

Although streptozotocin-induced diabetic pigs have been well established for the study of diabetes¹³

(especially islet cell transplantation), no diabetic wound healing model in large animals is available to date.

Our study aim was to develop a large-animal model of wound healing for diabetes-impaired wound healing and to investigate pathophysiologic mechanisms of diabetic wound healing.

Several growth factors and cytokines are considered to be important in mediating, coordinating, and controlling cellular interactions that occur during normal wound healing.¹⁴ They influence cell proliferation and cellular activity, induce migration of inflammatory cells into the wound environment, and stimulate protein synthesis or down-regulate certain cellular functions as healing progresses.^{15,16} Therefore, changes in the levels and timing of their expression in diabetes could alter the wound-healing process. Little is known about the influence of different disease states such as diabetes on the levels or actions of growth factors in the wound environment.¹⁷ Growth factors and cytokines such as insulin-like growth factor (IGF), platelet-derived growth factor (PDGF), and transforming growth factor- β (TGF- β), have been found to influence wound healing in a variety of small animal models and are diminished in diabetic wounds in humans.^{18–24} To confirm that this new wound healing model is comparable to the situation in humans, we analyzed these growth factors in our preclinical wound healing model.

To study wound healing, we used a previously developed external polyurethane chamber that can be sealed around the edges of the wound.²⁵ The chambers protect the wound like a dressing but allow the wound environment to be standardized and monitored and provide access for delivery of growth medium and potential therapeutic agents. It functions as an *in vivo* incubator, providing a bridge between *in vitro* and *in vivo* experimentation. The wounds were analyzed for glucose concentration, reepithelialization, contraction, and concentrations of different growth factors during healing.

METHODS

Animals

All animal procedures were approved by the Harvard Medical Area Standing Committee on Animals. All procedures conformed to the regulations related to animal use and other federal statutes. Female Yorkshire pigs (Parson's Farm, MA) weighing 60 kg at arrival were allowed to acclimatize for 1 week before initiation of the experiment. They were kept in smooth-walled stainless-steel cages to minimize wound trauma and disruption of applied wound chambers. $N=10$ animals were used in this study ($n=3$ served as diabetic models, $n=4$ as nondiabetic controls, and $n=3$ for high-glucose wound concentration study).

Induction of diabetes

Pigs were fasted for 12 hours before diabetes was induced to prevent possible asphyxia and nausea during and after the procedure. At the day of operation, the animals received induction anesthesia with ketamine (Hospira, Lake Forest, IL)/xylazine (Xyla-Ject, Phoenix, St. Joseph, MO) via intramuscular injection and were weighed. While ani-

mals were under general anesthesia with isoflurane (Novaplex, Hospira), a 21-gauge intravenous catheter (Becton Dickinson, Franklin Lakes, NJ) was inserted into an ear vein. Streptozotocin (Zanosar, Pharmacia, Pfizer, NY) was prepared at a dose of 150 mg/kg body weight diluted in 9.5 mL/mg sterile saline (0.9% NaCl injection USP, Baxter, Deerfield, IL) and sterilized by filtration. The solution was administered through the catheter over 1 minute. Intramuscular injections of buprenorphine (0.001 mg/kg; Bedford Laboratories, Bedford, OH) and metoclopramide (0.15 mg/kg; GensiaSicco, Irvine, CA) were used as post-operative analgesia and anti-emetic, respectively. Buprenorphine and metoclopramide were administered intramuscularly every 12 hours for the first 2 days. Serum glucose concentrations were measured on an hourly basis for the first 36 hours and twice daily for the remainder of the experiment. The pigs were treated with a subcutaneous injection of short-acting insulin (Normulin, Novo Nordisk, Princeton, NJ) and long-acting insulin zinc suspension (Humulin, Eli Lilly, Indianapolis, IN) to keep the blood glucose concentration between 350 and 550 mg/dL.

Wounding and chamber treatment

Fourteen days after induction of diabetes, pigs received anesthesia as mentioned above and were transferred to a panepinto sling (Fulton, Mosinee, WI). The pig's dorsum was waxed thoroughly (Nair, Church & Dwight, Princeton, NJ), shaved, and thoroughly disinfected. Eighteen to 21 squares measuring 1.5×1.5 cm were outlined on the dorsum with a template and a skin marker. The edges of these squares were retraced with a tattoo machine (Special Electric Tattoo Marker, Spaulding Enterprises, Voorheesville, NY) to allow measurement of wound contraction. After the skin was prepared with povidone iodine, the skin within the squares was excised with a no. 11 blade to create 18–21 full-thickness wounds measuring 1.5×1.5×0.8 cm. Adhesive polyurethane chambers (Corium International, Grand Rapids, MI) were applied over each wound, and the chambers were then injected with 2 mL of sterile saline containing penicillin 100 U/mL (Gibco, Invitrogen, Carlsbad, CA) and streptomycin 100 μ g/mL (Gibco, Invitrogen). For nondiabetic high-glucose wound concentration study, the 2 mL sterile saline solution was adjusted to 1,800 mg/dL (100 mM) glucose concentration. The wound fluid collected in the chambers was completely aspirated at 24-hour intervals and chilled on ice before being stored at -80°C for later analysis. Each chamber was reinjected with 2 mL of sterile saline (containing penicillin/streptomycin; Gibco, Invitrogen). For analgesia, buprenorphin was administered intramuscularly every 12 hours for the first 2 days. Before the wounds were retrieved, the pigs were killed by intravenous injection of Euthasol (Virbac AH, Fort Worth, TX).

Wound contraction

Wound contraction was determined by digitized planimetry of the tattooed margins. The area of the wounds at specific days was measured using Scion image software (Scion, Frederick, MD) and the percentage of contraction was calculated by the formula (area at biopsy day)/(area on wounding day) × 100.

Histology

Cross-sectional wound biopsies 2 mm wide were taken from the middle of the wounds; the sample included unwounded skin at the sides and subcutaneous tissue at the bottom. Biopsies were collected on days 8, 12, 16, and 18 after wounding. Samples were fixed in 4% buffered paraformaldehyde and processed for routine hematoxylin-eosin staining.

Reepithelialization was calculated by scanning the slides (Epson Perfection 3600, Epson, Long Beach, CA) and measuring the epithelial tongues from the computerized image with Paintshop Pro 7.0 (Jasc Software, Corel, Ottawa, Canada).

Measurements of growth factor and protein

Levels of PDGF-BB, TGF- β , and IGF-1 in the wound environment were measured in wound fluid by a specific enzyme-linked immunosorbent assay and a protein assay (R&D Systems, Minneapolis, MN). Results were calculated by using a Vmax kinetic Microplate Reader and Soft Max Pro software (Molecular Devices, Sunnyvale, CA).

Statistics

Values are presented as means \pm SE. Groups were compared with a nonparametrical test, and statistical calculations were performed with GraphPad Instat software (GraphPad Software, San Diego, CA). A p -value < 0.05 was considered statistically significant.

RESULTS

Serum glucose levels

All the animals that received streptozotocin survived in good general condition for the duration of the experiment. Following the injection of streptozotocin there was an initial triphasic glucose response during the first 30 hours with an initial hyperglycemia lasting from hours 1–8, followed by a marked hypoglycemia that lasts from hours 10–20. A permanent hyperglycemic state (blood glucose above 350 mg/dL) established at 22 hours postinduction.

Glucose levels in wound fluid and urine

Wound fluid was collected on a daily basis, and the glucose concentration was measured. The glucose levels in wound fluid closely followed the levels in serum until day 5, at which time the glucose levels in wound fluid progressively decreased until they reached undetectable levels at day 9 (Figure 1). Nondiabetic pigs showed no detectable glucose concentrations in the wound fluid throughout the experiment, whereas wounds with local hyperglycemia in nondiabetic pigs showed a mean glucose concentration of 201.2 mg/dL.

Urine glucose was 100.25 ± 7.1 mg/dL in the fasting nondiabetic pig and > 500 mg/dL in the diabetic pig.

Reepithelialization

In all pigs, cross-sectional biopsies were done on days 8, 12, 14, 16, and 18 after wounding. Epidermal healing in

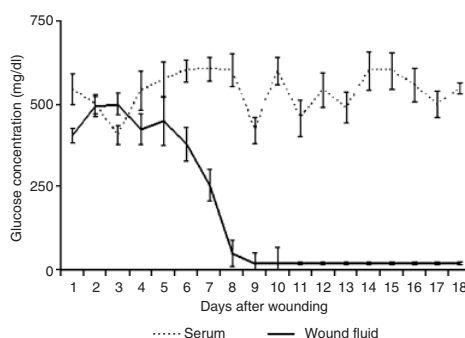


Figure 1. Relation between the glucose concentration in wound fluid and in serum in the diabetic pig after the creation of wounds ($n=52$ in three pigs). Glucose concentrations in wound fluid followed that in serum closely until day 5, when it decreased, becoming undetectable on day 9.

diabetic pigs was significantly delayed as compared with healing in nondiabetic pigs: On day 8, the wounds in diabetic pigs were 12% reepithelialized, whereas those in nondiabetic pigs were 44% reepithelialized. On day 12, the wounds of diabetic pigs were 42% reepithelialized and those in nondiabetic pigs were 96% epithelialized. Full reepithelialization was delayed in diabetic pigs (day 18) as compared with nondiabetic animals (days 12–14) (Figures 2 and 3). Local hyperglycemic wounds on nondiabetic animals showed no statistical difference compared with control wounds on day 12 (83 vs. 88%; Figure 4)

Wound contraction

Diabetic wounds contracted 24% on day 8 and 34% on day 12. Wounds in nondiabetic pigs contracted 35% on day 8 and 42% on day 12. Diabetic wounds contracted less

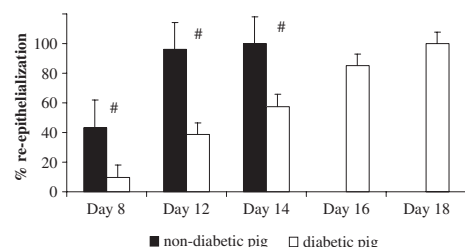


Figure 2. Level of reepithelialization of full-thickness wounds in nondiabetic and diabetic pigs. Wounds measuring 1.5×1.5 cm were created on the backs of the pigs. Biopsy samples were obtained on days 8 ($n=4$), 12 ($n=12$), 14 ($n=12$), 16 ($n=12$), and 18 ($n=12$) for the diabetic pigs and on days 8 ($n=12$), 12 ($n=12$), and 14 ($n=10$) for the healthy pigs. # = diabetic vs. nondiabetic group: $p < 0.001$.

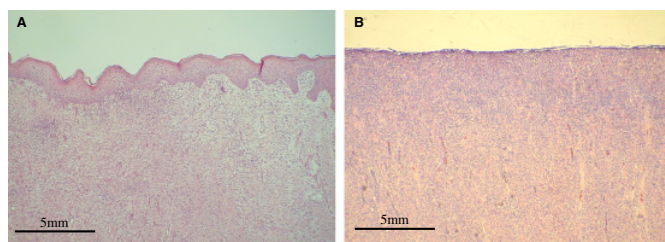


Figure 3. Histology of wounds on day 12 after wounding (H&E staining). Pictures show the center of the wounds at $\times 10$ magnification. (A) Nondiabetic pig at day 12; (B) Diabetic pig at day 12.

at both time points, but the difference between the two groups was not statistically significant.

Cytokine and growth factors

Expression of IGF-1 in diabetic wounds was 15-fold lower than expression in nondiabetic wounds at day 3, 10-fold lower at day 5, and fourfold lower at day 7 (Figure 5A). The concentration of TGF- β was lower in the wound fluid of diabetic pig than in the wound fluid of nondiabetic pigs (Figure 5B) with a significant lower expression of TGF- β at day 7 in diabetic pigs as compared with nondiabetic pigs. The difference in expression of PDGF-BB in the wound fluid of diabetic and nondiabetic pigs was not statistically significant.

DISCUSSION

In this study, streptozotocin injection was well tolerated by the animals and a stable long-term diabetic state was achieved in the Yorkshire pigs. Multiple studies have shown a zero rate of mortality and little morbidity, such as polydipsia and polyuria.^{13,26,27}

Insulin therapy helped maintain blood glucose on a high level throughout the experiment. The glucose concentration in wound fluid followed the serum concentration closely until day 5, when the wound fluid concentration decreased. The glucose level in the wound fluid seems to be associated with the state of healing in the diabetic wound. This may be due to decreasing vessel permeability in the healing wound.¹⁴

We could show that wound healing in diabetic pigs was significantly delayed as reepithelialization was decreased as compared with nondiabetic pigs. A diabetic state for 4

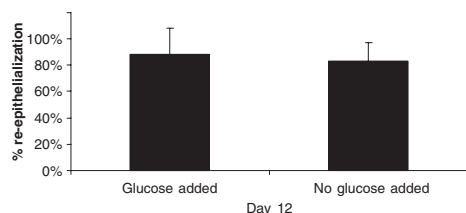


Figure 4. Reepithelialization of nondiabetic full-thickness wounds under local high-glucose condition and normoglycemic controls on day 12.

months before wounding did not further delay wound healing significantly (data not shown).

A state of systemic hyperglycemia, as seen in diabetes, may influence wound closure in numerous ways. Several hypotheses have been described in the literature such as the formation of glycation end products,²⁸ hyperosmolality,²⁹ and altered insulin signaling in various ways.³⁰ However, molecular mechanisms whereby diabetes alters skin and wound physiology have not been elucidated to date.³¹ To evaluate the sole effect of local hyperglycemia in wounds, the other potential effects of systemic hyperglycemia need to be excluded. To achieve this, we studied the effects of a high-glucose wound concentration on the healing of full-thickness wounds in nondiabetic pigs. Wounds that were subjected to a local hyperglycemic environment healed slightly but not significantly faster than control wounds. These findings suggest

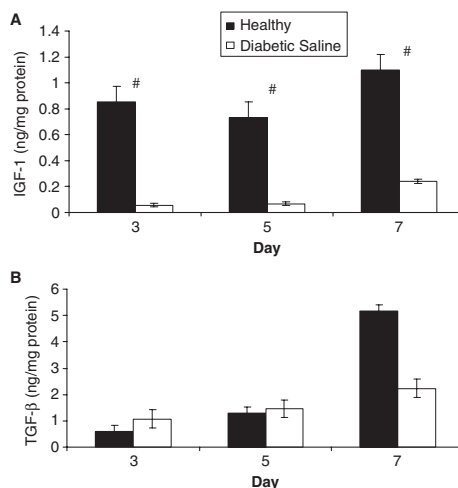


Figure 5. Level of expression of growth factor from the wound fluid of nondiabetic and diabetic pigs. Each bar represents the mean \pm standard deviation for three diabetic pigs or four healthy pigs. All samples were assayed in duplicate. (A) IGF-1: # diabetic vs. nondiabetic pigs; $p < 0.05$. TGF- β : # diabetic vs. nondiabetic pigs; $p < 0.05$.

that wound-healing impairment in diabetes is not induced by local hyperglycemia within the wound environment itself and that local hyperosmolarity does not play a key role in our study.

Neuropathy, vascular damage, and malnutrition are described as further reasons for complicated wound healing.³² In our model, a diabetic metabolic state was induced only 2 weeks before the experiment, which suggests that no long-term side effects such as neuropathy are responsible for impaired wound healing. This highlights a limitation of our model, since it omits long-term effects such as neuropathy and vasculopathy.

PDGF-BB growth factor has become the only growth factor licensed for topical application to stimulate the healing of chronic full-thickness diabetic foot ulcers.³³ Doxey et al.³⁴ reported significantly lower concentrations of PDGF-BB protein in a diabetic rat wound model. Their findings suggest that the absence of an initial increase in PDGF may play a role in the poor wound healing observed in diabetic rats.

In clinical studies, the response rate to PDGF-BB application varies widely.^{35,36} PDGF has not been detected in chronic nonhealing wounds in humans. Pierce et al. detected only a minimal expression of PDGF isoforms in normal skin and in nonhealing dermal ulcers.³⁷ In accord with this finding, we found only low levels of PDGF-BB in the wound fluid (0.9–1.2 ng/mg protein in the wound fluid) and no statistically significant differences in the expression of diabetic and nondiabetic animals.

Ferguson et al.³⁸ reported an increase in acute inflammatory cells and an absence of cellular growth and migration of the epidermis over the wound in diabetic humans. The healing wound is a site of intense metabolism, involving a cascade of complex molecular interactions. Many alterations at the molecular level have been found in patients with diabetes that together could severely compromise healing, potentially leading to ulcer formation.

In other animal studies, topical application of TGF- β improved acute wound healing.³⁹ TGF- β has important functions in the normal healing process, including as a chemoattractant for monocytes, leukocytes, macrophages, lymphocytes, neutrophils, keratinocytes, and fibroblasts, and the induction of these cells to release growth factors.^{39,40} In the present experiment in diabetic pigs, the expression of TGF- β in the wound environment decreased significantly on day 7 as compared with expression in nondiabetic pigs.

In this study, the most significant decrease of the concentrations of growth factors in the wound fluid was in the expression of IGF-1. The level of expression during the first 7 days after wounding decreased up to 15-fold.

Systemic concentrations of IGF-1 detected on day 14 after induction of diabetic metabolic state was 0.18 ng/mL compared with 1.33 ng/mL before streptozotocin induction, which is 7.4-fold lower. This observation indicates that the lower levels of IGF-1 detected in the diabetic wounds is in part due to the reduced IGF-1 expression in circulation.

In other studies, IGF-1 was shown to induce chemotactic activity in endothelial cell lines, as well as to stimulate keratinocyte and fibroblast proliferation and reepithelialization and to increase wound strength.⁴¹ Human studies have been limited. Blakytyn et al.²² showed that

IGF-1 is reduced within the basal layer of the epidermis in human diabetic skin, in fibroblasts from diabetic patients, and in their ulcer margins. We could show that the expression levels of the growth factors analyzed in our porcine model followed the findings in humans.

From the review of different animal models of wound healing, it becomes clear that skin wounds are difficult to manipulate and analyze in a standardized fashion. Therefore, we developed a polyurethane chamber that fits tightly around a wound and is simple to use for healing of porcine wounds in a liquid environment.²⁵ Previous reports have documented the beneficial effect of a wet over a dry wound environment, in both partial- and full-thickness wounds in nondiabetic pigs.^{42,43} We confirmed, as documented earlier by Gabel et al.,²⁷ that a stable long-term diabetic state can be achieved in the Yorkshire pig. We also observed a high concentration of glucose in the wound microenvironment and showed a significant delay in epidermal healing, with full reepithelialization occurring 50% later in the diabetic than in the nondiabetic pig.

In this study, we developed the first model of diabetic impaired wound healing for large-animal studies that can be directed toward the discovery of pathophysiologic mechanisms in impaired wound healing and investigation of the efficacy of new approaches to the treatment of wounds.

ACKNOWLEDGMENT

This study was supported by National Institutes of Health grant 5ROIGM51449.

REFERENCES

- Mostow EN. Diagnosis and classification of chronic wounds. *Clin Dermatol* 1994; 12: 3–9.
- (ADA), A.D.A., Complications of Diabetes in the United States. www.diabetes.org/diabetes-statistics/complications.jsp, 2006; (3/13).
- Rees RH. Wound care centers: costs, care and strategies. *Advanc Wound Care* 1999; 12 (Suppl. 2): 4–7.
- Bowler PG. Wound pathophysiology, infection and therapeutic options. *Ann Med* 2002; 34: 419–27.
- Greenhalgh DG. Models of wound healing. *J Burn Care Rehabil* 2005; 26: 293–305.
- Bell RH Jr, Hye RJ. Animal models of diabetes mellitus: physiology and pathology. *J Surg Res* 1983; 35: 433–60.
- Sullivan TP, Eaglstein WH, Davis SC, Mertz P. The pig as a model for human wound healing. *Wound Repair Regen* 2001; 9: 66–76.
- Vardaxis NJ, Brans TA, Boon ME, Kreis RW, Marres LM. Confocal laser scanning microscopy of porcine skin: implications for human wound healing studies. *J Anat* 1997; 190 (Part 4): 601–11.
- Montagna W, Yun JS. The skin of the domestic pig. *J Invest Dermatol* 1964; 42: 11–21.
- Tsuboi R, Rifkin DB. Recombinant basic fibroblast growth factor stimulates wound healing in healing-impaired db/db mice. *J Exp Med* 1990; 172: 245–51.
- Lynch SE, Colvin RB, Antoniadis HN. Growth factors in wound healing. Single and synergistic effects on partial thickness porcine skin wounds. *J Clin Invest* 1989; 84: 640–6.

12. Greenhalgh DG, Rieman M. Effects of basic fibroblast growth factor on the healing of partial-thickness donor sites. A prospective, randomized, double-blind trial. *Wound Repair Regen* 1994; 2: 113–21.
13. Grüssner R, Nakhleh R, Grüssner A, Tomadze G, Diem P, Sutherland D. Streptozotocin-induced diabetes mellitus in pigs. *Horm Metab Res* 1993; 25: 199–203.
14. Singer AJ, Clark RA. Cutaneous wound healing. *N Engl J Med* 1999; 341: 738–46.
15. Andree C, Swain WF, Page CP, Macklin MD, Slama J, Hatzis D, Eriksson E. In vivo transfer and expression of a human epidermal growth factor gene accelerates wound repair. *Proc Natl Acad Sci USA* 1994; 91: 12188–92.
16. Martin P. Wound healing-aiming for perfect skin regeneration. *Science* 1997; 276: 75–81.
17. Greenhalgh DG. Wound healing and diabetes mellitus. *Clin Plast Surg* 2003; 30: 37–45.
18. Albertson S, Hummel RP III, Breeden M, Greenhalgh DG. PDGF and FGF reverse the healing impairment in protein-malnourished diabetic mice. *Surgery* 1993; 114: 368–72; discussion 372–3.
19. Ansel J, Perry P, Brown J, Damm D, Phan T, Hart C, Luger T, Hefeneider S. Cytokine modulation of keratinocyte cytokines. *J Invest Dermatol* 1990; 94 (Suppl. 6): 101–7S.
20. Fahey TJ III, Sherry B, Tracey KJ, van Deventer S, Jones WG II, Minei JP, Morgello S, Shires GT, Cerami A. Cytokine production in a model of wound healing: the appearance of MIP-1, MIP 2, cachectin/TNF and IL-1. *Cytokine* 1990; 2: 92–9.
21. Grande JP. Role of transforming growth factor-beta in tissue injury and repair. *Proc Soc Exp Biol Med* 1997; 214: 27–40.
22. Blakytyn R, Jude EB, Martin Gibson J, Boulton AJ, Ferguson MW. Lack of insulin-like growth factor 1 (IGF1) in the basal keratinocyte layer of diabetic skin and diabetic foot ulcers. *J Pathol* 2000; 190: 589–94.
23. Castronuovo JJ Jr, Ghobrial I, Giusti AM, Rudolph S, Smiell JM. Effects of chronic wound fluid on the structure and biological activity of becaplermin (rhPDGF-BB) and becaplermin gel. *Am J Surg* 1998; 176 (Suppl. 2A): 61S–7S.
24. Jude EB, Blakytyn R, Bulmer J, Boulton AJ, Ferguson MW. Transforming growth factor-beta 1, 2, 3 and receptor type I and II in diabetic foot ulcers. *Diabet Med* 2002; 19: 440–7.
25. Breuing K, Andree C, Helo G, Slama J, Liu PY, Eriksson E. Growth factors in the repair of partial thickness porcine skin wounds. *Plast Reconstr Surg* 1997; 100: 657–64.
26. Wilson JD, Dhall DP, Simeonovic CJ, Lafferty KJ. Induction and management of diabetes mellitus in the pig. *Aust J Exp Biol Med Sci* 1986; 64 (Part 6): 489–500.
27. Gäbel H, Bitter-Suermann H, Henriksson C, Säve-Söderbergh J, Lundholm K, Brynner H. Streptozotocin diabetes in juvenile pigs. Evaluation of an experimental model. *Horm Metab Res* 1985; 17: 275–80.
28. Friedman EA. Advanced glycosylated end products and hyperglycemia in the pathogenesis of diabetic complications. *Diabetes Care* 1999; 22 (Suppl. 2): B65–71.
29. Yki-Järvinen H. Toxicity of hyperglycaemia in type 2 diabetes. *Diabetes Metab Rev* 1998; 14 (Suppl. 1): S45–50.
30. Porte D Jr, Schwartz MW. Diabetes complications: why is glucose potentially toxic? *Science* 1996; 272: 699–700.
31. Spravchikov N, Szyakov G, Gartsbein M, Accili D, Tenenbaum T, Wertheimer E. Glucose effects on skin keratinocytes: implications for diabetes skin complications. *Diabetes* 2001; 50: 1627–35.
32. Perschel WT, Langefeld TW, Federlin K. Susceptibility to infections in diabetes—effects on metabolism. *Immun Infect* 1995; 23: 196–200.
33. Bennett SP, Griffiths GD, Schor AM, Leese GP, Schor SL. Growth factors in the treatment of diabetic foot ulcers. *Br J Surg* 2003; 90: 133–46.
34. Doxey DL, Ng MC, Dill RE, Iacopino AM. Platelet-derived growth factor levels in wounds of diabetic rats. *Life Sci* 1995; 57: 1111–23.
35. Smiell JM, Wieman TJ, Steed DL, Perry BH, Sampson AR, Schwab BH. Efficacy and safety of becaplermin (recombinant human platelet-derived growth factor-BB) in patients with nonhealing, lower extremity diabetic ulcers: a combined analysis of four randomized studies. *Wound Repair Regen* 1999; 7: 335–46.
36. Wieman TJ, Smiell JM, Su Y. Efficacy and safety of a topical gel formulation of recombinant human platelet-derived growth factor-BB (becaplermin) in patients with chronic neuropathic diabetic ulcers. A phase III randomized placebo-controlled double-blind study. *Diabetes Care* 1998; 21: 822–7.
37. Pierce GF, Tarpley JE, Tseng J, Bready J, Chang D, Kenney WC, Rudolph R, Robson MC, Vande Berg J, Reid P, et al. Detection of platelet-derived growth factor (PDGF)-AA in actively healing human wounds treated with recombinant PDGF-BB and absence of PDGF in chronic nonhealing wounds. *J Clin Invest* 1995; 96: 1336–50.
38. Ferguson MW, Herrick SE, Spencer MJ, Shaw JE, Boulton AJ, Sloan P. The histology of diabetic foot ulcers. *Diabet Med* 1996; 13 (Suppl. 1): S30–3.
39. Roberts AB. Transforming growth factor-beta: activity and efficacy in animal models of wound healing. *Wound Repair Regen* 1995; 3: 408–18.
40. Bennett NT, Schultz GS. Growth factors and wound healing: part II. Role in normal and chronic wound healing. *Am J Surg* 1993; 166: 74–81.
41. Kratz G, Lake M, Ljungström K, Forsberg G, Haegerstrand A, Gidlund M. Effect of recombinant IGF binding protein-1 on primary cultures of human keratinocytes and fibroblasts: selective enhancement of IGF-1 but not IGF-2-induced cell proliferation. *Exp Cell Res* 1992; 202: 381–5.
42. Svensjö T, Pomahac B, Yao F, Slama J, Eriksson E. Accelerated healing of full-thickness skin wounds in a wet environment. *Plas Reconstr Surg* 2000; 106: 602–12; discussion 613–4.
43. Vogt PM, Andree C, Breuing K, Liu PY, Slama J, Helo G, Eriksson E. Dry, moist, and wet skin wound repair. *Ann Plast Surg* 1995; 34: 493–9; discussion 499–500.

Paper II

Cell Suspensions of Autologous Keratinocytes or Autologous Fibroblasts Accelerate the Healing of Full Thickness Skin Wounds in a Diabetic Porcine Wound Healing Model

Patrik Velander, M.D.,^{*,†,‡} Christoph Theopold, M.D.,^{*} Oliver Bleiziffer, M.D.,^{*} Juri Bergmann, M.D.,^{*} Henry Svensson, M.D, Ph.D.,^{†,‡} Yao Feng, Ph.D.,^{*} and Elof Eriksson, M.D., Ph.D.^{*,1}

^{*}Laboratory of Tissue Repair and Gene Transfer, Harvard Medical School, Division of Plastic Surgery, Brigham and Women's Hospital, Boston, Massachusetts; [†]Department of Clinical Science, Malmoe, Lund University, Malmoe, Sweden; and [‡]Division of Surgery, Malmoe University Hospital, Malmoe, Sweden

Submitted for publication February 14, 2008

Autologous dermal fibroblasts may be useful in the treatment of diabetic skin wounds. We hypothesized that cultured fibroblasts or cultured keratinocytes would not only survive in a hyperglycemic wound environment but also enhance the rate of re-epithelialization. We previously developed a new porcine model of delayed cutaneous wound healing in the diabetic pig. Full thickness wounds were created on the dorsum and dressed with polyurethane chambers to keep the wounds wet and to allow for wound fluid monitoring. Suspensions of either autologous fibroblasts or autologous keratinocytes were injected into full thickness wounds and compared with wounds treated in a wet environment in normal saline. Serum glucose and wound fluid glucose concentrations were monitored daily. Wound contraction was monitored and biopsies taken on day 12. Transplantation of suspensions of autologous fibroblasts or autologous keratinocytes enhanced re-epithelialization of cutaneous full thickness wounds.

Wounds treated with autologous fibroblasts showed a re-epithelialization rate of 86.75% and wounds treated with autologous keratinocytes showed a re-epithelialization rate of 91.3%. This is compared with a re-epithelialization rate of 56.8% seen in the normal saline treated wounds. While previous studies have shown fibroblasts suspension to have little effect in the treatment of full thickness wounds in nondiabetic wounds, this study shows a clear beneficial effect in the use of fibroblast or keratinocyte suspensions for

the cutaneous healing of diabetic wounds in pigs. © 2009 Elsevier Inc. All rights reserved.

Key Words: diabetes; wound healing; animal model; keratinocytes; fibroblasts, re-epithelialization; streptozotocin.

INTRODUCTION

Diabetes mellitus is a chronic disorder of glucose homeostasis, affecting about 6% of the population in the United States. The incidence is increasing dramatically because of a rise in obesity and old age. Twenty-five percent of people with diabetes will suffer a wound problem in their lifetime, leading to pain, physical limitations, and psychological stress. Healing of these impaired wounds represents a challenge with currently available treatment. In an effort to develop an effective therapy to overcome the impaired healing associated with diabetes, we developed a large animal model to mirror delayed diabetic wound healing. Since porcine skin is physiologically very close to human skin, impaired healing in a diabetic pig would represent a suitable model to study diabetic wound healing. We demonstrated a significant delay in epidermal healing in the streptozotocin induced diabetic pig [1]. Previous publications have shown the beneficial effect of a wet wound environment compared with dry wounds [2], and that a keratinocyte cell suspension not only survives in this liquid environment but also contributes to epidermal healing [3] in normal acute wound healing. Several publications have shown impaired keratinocyte proliferation in a hyperglycemic environment both *in*

¹ To whom correspondence and reprint requests should be addressed at Division of Plastic Surgery, Brigham and Women's Hospital, 75 Francis Street, Boston, MA 02115. E-mail: eeriksson@partners.org.

vitro and *in vivo* [4]. However, transplantation of autologous fibroblast into full thickness cutaneous wounds has shown little improvement in re-epithelialization in a nondiabetic pig study [5].

The aim of this study was to investigate whether autologous transplanted keratinocytes and fibroblasts can accelerate wound closure in a diabetic situation.

MATERIALS AND METHODS

Animals

Female pigs (Parson's Farm, Westhampton, MA) weighing 60 kg at arrival were allowed to acclimatize for 1 wk prior to the initiation of any experiment. They were kept in smooth walled stainless steel cages to minimize wound trauma and disruption of applied wound chamber. The animal protocol was approved by the Harvard Medical Area Standing Committee on animals and all operative procedures took place in a specialized operation room under sterile conditions. Anesthesia was induced according to our laboratory protocol [2]. The animals were premedicated with an intramuscular injection of Ketamine (Hospira, Lake Forest, IL)/Xylazine (Xyla-Ject, Phoenix, St. Josephs, MO). Once sedated, isoflurane (Novaplus, Hospira, IL) was used as inhalation anesthesia. Intramuscular injections of buprenorphine (0.001 mg/kg; Bedford Laboratories, Bedford, OH) and metoclopramide (0.15 mg/kg; GensiaSicco, Irvine, CA) were used as post-operative analgesia and anti-emetic, respectively. Pigs were euthanized by intravenous injection of Euthasol.

Induction of Diabetes

Under general anesthesia, streptozotocin (Zanosar; Pharmacia, Pfizer, New York, NY) was administered at a dose of 150 mg/kg body weight. The pigs were continually observed for the first 3 h and then hourly for the following 33 h. Buprenorphine and metoclopramide were administered IM every 12 h for the first 2 d. Serum glucose was taken twice daily during the experiment. The pigs were treated with a subcutaneous injection of short acting insulin (Normulin; NovoNordisk, Princeton, NJ) and long acting insulin zinc suspension (Humulin; Eli Lilly, Indianapolis, IN) to keep blood glucose in a range between 300 and 500 mg/dL.

Harvesting of Split Skin Grafts

Following the induction of diabetes, the hair from the nape of the neck was clipped and the skin was cleaned with povidone iodine solution (Medline Industries, Mundelein, IL). Two strips of 0.38 mm split skin grafts measuring 2×8 cm were harvested with an electric dermatome (Padgett Instruments, Kansas City, KS). The resulting partial thickness wounds were dressed with vaseline gauze and sterile dressing.

Cell Culture

Autologous keratinocytes and fibroblasts were isolated from these split thickness skin grafts. The grafts were washed in sterile phosphate buffered saline. The skin grafts were then cut into 1×1 cm squares and left in 2 U/mL Dispase (Roche, Indianapolis, IN) solution at 37°C for 1 h, at which time the epidermis could be peeled off the dermis.

The dermal sheets were put in 0.1% collagenase for 2 h at 37°C then passed through an 80 mesh sterile sieve. The resulting solution was centrifuged at 1000 rpm at 37°C for 6 min. The fibroblasts pellet was then suspended in Dulbecco's modified eagle medium (DMEM; Invitrogen, Carlsbad, CA) with 10% Fetal Bovine Serum (Sigma,

MO), streptomycin, penicillin, gentamicin (Invitrogen, NY) and amphotericin (Bristol-Myers Squibb, New York, NY) added. Cells were then seeded onto 100 mm BD Falcon cell culture dishes. Fibroblasts were subcultured at 90% confluence.

For the epidermal sheets, 5 mL 0.0625% trypsin (Invitrogen) was added and left for 3 min at 37°C. The epidermis/trypsin solution was then passed through an 80 mesh sterile sieve and the trypsin neutralized by addition of fetal bovine serum (Sigma, St. Louis, MO). The resulting solution was centrifuged at 750 rpm for 6 min at 37°C to pellet the keratinocytes. Cells were resuspended in keratinocytes serum free medium (SFM; Invitrogen) containing bovine pituitary hormone, epidermal growth factor (Invitrogen), calcium depleted fetal bovine serum (Sigma, MO), calcium dichloride, streptomycin (Gibco, Invitrogen, Carlsbad, CA), penicillin (Gibco, Invitrogen), gentamicin (Invitrogen) and amphotericin (Bristol Myers Squibb). The cells were seeded onto BD biocoat 1 collagen-coated dishes (Becton-Dickinson, Franklin Lakes, NJ) at a density of 6×10^6 cells per 100 mm dish. Keratinocytes were sub-cultured at 90% confluence.

Wounding and Chamber Treatment

Nine to 12 d post-induction of diabetes; the pig's dorsum was waxed (Nair microwable wax; Church and Dwight, Princeton, NJ) and shaved. Ten to 12 pairs of squares measuring 1.5×1.5 cm were outlined on the dorsum using a skin marker. The edges of these squares were retraced using a tattoo machine (Special Electric Tattoo Marker; Spaulding Enterprises, Voorheesville, NY) to allow for later wound contraction measurements. Following skin preparation with povidone iodine, the skin within the squares was excised using a number 11 blade to create 20 full thickness wounds measuring 1.5×1.5 . The depth of the wound was standardized at 0.8 cm as this delineated a natural cleavage. Once good hemostasis was achieved, adhesive polyurethane chambers (Corium International, Grand Rapids, MI) were applied over each wound.

For the fibroblasts experiment, 650,000 fibroblasts suspended in 300 μ L DMEM were injected into half of the wounds and 300 μ L DMEM only into control wounds.

For the keratinocytes experiment, 500,000 keratinocytes suspended in 300 μ L SFM were injected into half of the wounds and 300 μ L SFM into control wounds. The wounds were left intact for 2 h to allow for the cells to settle. At this time, 2 mL normal saline was injected into each wound. The wound fluid that collected in the chambers was completely aspirated at 24-h interval for analysis of glucose concentration. The chambers were then re-injected with 2 mL of 0.9% saline solution.

Wound Contraction

Wound contraction was measured, on days 3, 6, 9, and 12, using the permanent boundaries left by the tattooed margins and planimetry. The area of the wounds was measured using Scion Image software (Scion Corporation, Frederick, MD) and the percentage of contraction was calculated using the following formula: (area at wounding day – area at biopsy day)/(area on wounding day) \times 100.

Histology and Re-epithelialization

For histological analysis, cross sectional wound biopsies 2 mm wide were taken from the middle of the wounds, including unwounded skin at the sides and subcutaneous tissue at the bottom. Biopsies were collected on days 8, 12, and 14 post-wounding. Samples were fixed in 4% buffered paraformaldehyde and processed for routine hematoxylin and eosin staining.

Re-epithelialization was defined as the part of the wound within the tattooed marks that was covered with epithelium. This was calculated by scanning the histological slides (Epson Perfection 3600; Epson Inc., Long Beach, CA), measuring the epithelial tongues from the computerized image using Paintshop Pro (Jasc Software 7.0; Corel, Ottawa,

Ontario, Canada). The percentage re-epithelialization was determined using the formula: (sum of epithelial tongues + epithelial islands)/(distance between tattoo marks) \times 100.

Statistics

The fibroblast study included wounds treated with a fibroblasts suspension ($n = 34$) and control wounds treated with 0.9% saline solution ($n = 34$) in three diabetic pigs. The keratinocyte study included wounds treated with a keratinocyte suspension ($n = 34$) and control wounds treated with 0.9% saline solution ($n = 34$) in three diabetic pigs. Values are presented as means \pm STD. Groups were compared with unpaired *t*-test with Welch corrections. Statistical calculations were performed with GraphPad Instat software (San Diego, CA). A *P* value inferior to 0.05 was considered to indicate statistical significance.

RESULTS

Re-epithelialization of Wounds Transplanted With Autologous Keratinocytes

Early studies from our laboratory demonstrate that transplanted keratinocytes proliferate and form cell colonies, which progressively move upward to the wound surface during the course of the healing process and thus regenerate into a structurally intact epidermis [3, 6]. Based on our finding that most keratinocyte transplanted wounds healed on day 10 post-transplantation and healing of full-thickness wounds is delayed in diabetic pigs [1], in the current report we analyze the degree of re-epithelialization on day 12 post-fibroblast transplantation and on days 8, 12, and 14 post-keratinocyte transplantation.

Treatment of full thickness wounds with a suspension of keratinocytes showed no difference in re-epithelialization on day 8, as the transplanted keratinocytes had not yet reached the wound surface. However on day 12 there was a significantly enhanced epidermal healing with a 91.3% re-epithelialization rate compared with 56.8% in the normal saline treated group. On day 14, the keratinocyte treated group were fully re-epithelialized compared with a rate of 59% in the normal saline treated group ($P = 0.001$; Fig. 1A). The contribution of the transplanted keratinocytes to the new epidermis is illustrated in Fig. 2A, showing that the keratinocyte colonies have fused with the newly formed epidermis, compared with the normal saline treated group (Fig. 2B) where epidermis is absent in the center of the wound. This is further illustrated in the histological slides presented in Fig. 3, where the upward migration of the keratinocyte colonies contributed directly to the newly formed epidermis (Fig. 3A). These colonies are absent from the normal saline treated control group (Fig. 3B). There was no statistical difference in the rate of contraction between the two groups on days 3, 6, and 9. However there was a statistical difference on day 12; keratinocyte treated wounds contracted less than control wounds ($P = 0.0136$; Fig. 4A).

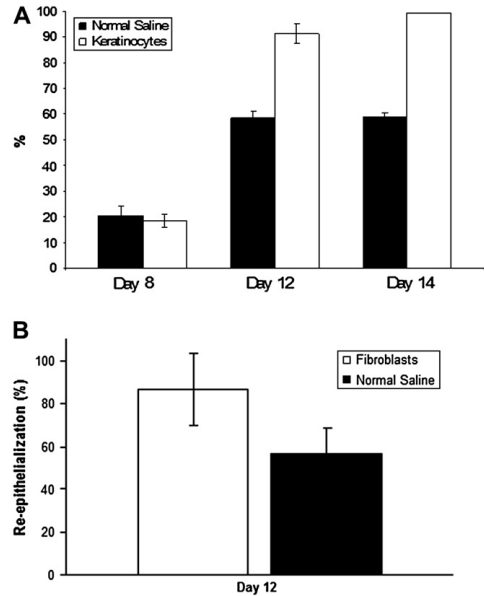


FIG. 1. Transplantation of keratinocytes or fibroblasts accelerates epidermal healing in the diabetic pig. (A) Level of re-epithelialization of full thickness wounds treated with a suspension of 500,000 keratinocytes or normal saline. Wounds measuring 1.5×1.5 cm were created on the backs of pigs. On the day of wounding, an injection of either a suspension of keratinocytes or normal saline was done into each wound. On days 8, 12, and 14, biopsies were harvested, embedded in paraformaldehyde and stained with hematoxylin and eosin for analysis. The error bars refer to SD. $P = 0.001$ (B) Re-epithelialization on day 12 of full thickness wounds treated with a suspension of 650,000 fibroblasts or normal saline. Wounds measuring $1.5 \times 1.5 \times 0.8$ cm were created on the backs of pigs. On the day of wounding, an injection of either a suspension of fibroblasts or normal saline was done into each wound. On day 12, biopsies were harvested, embedded in paraformaldehyde and stained with hematoxylin and eosin for analysis. The error bars refer to SD. $P = 0.035$.

Re-epithelialization of Wounds Transplanted With Autologous Fibroblasts

Svensjo *et al.* showed that transplantation of autologous fibroblast has little effect on healing of full-thickness wound in healthy normal pigs [5]. Here, we transplanted a suspension of 650,000 fibroblasts into full thickness wounds in diabetic pigs. As shown in Fig. 1B, treatment of full thickness wounds with transplanted fibroblasts showed a significant faster re-epithelialization 86.7% compared with 56.8% for the normal saline treated control group ($P = 0.035$; Fig. 1B). There was no statistical difference between the contraction rate of the fibroblasts group and normal saline control group. The fibroblasts treated wounds

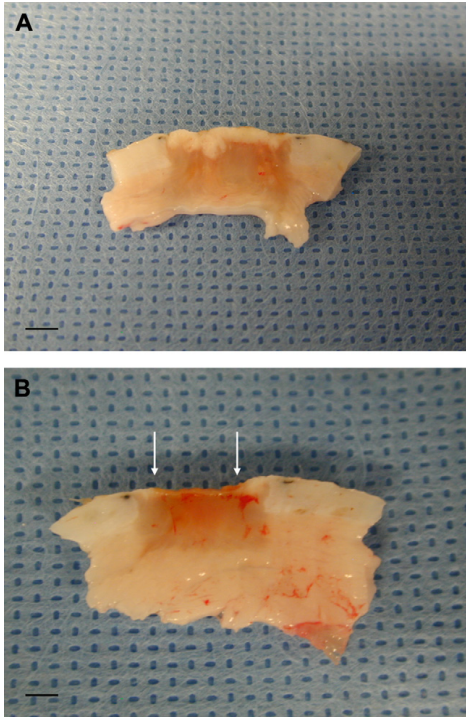


FIG. 2. Transplantation of keratinocyte into full thickness wounds in diabetic pigs leads to the formation of keratinocyte colonies, which contribute to epidermal healing. Vertical wound biopsies 2 mm wide were taken from the middle of the wounds, which included un wounded skin at the sides and subcutaneous tissue at the bottom. Biopsies were collected on day 12 post-wounding, embedded in para-formaldehyde and stained with H and E for analysis. The arrows show the edge of re-epithelialization. (A) Wounds treated with a suspension of 500,000 keratinocytes. (B) Normal saline treated wound. Scale 6.5 mm for A and B. (Color version of figure is available online.)

contracted 40.2% at day 12, whereas control group contracted 42.7% ($P > 0.05$; Fig. 4B).

DISCUSSION

Debridement of the wound, with or without split skin grafting, remains the treatment of choice today. Several new treatments are being studied in animal models. Various growth factors have been studied, such as vascular endothelial growth factor, epidermal growth factor, keratinocyte growth factor, and platelet derived growth factor. These studies have not shown results in keeping with expectations when the growth factor is delivered on its own *in vivo*. A suggested explanation for this would be failure to deliver the selected growth factor to where it is needed. A recombinant platelet

derived growth factor is available commercially, and when applied topically onto wounds, it has shown some promising results in clinical studies [7].

Platelet concentrate transplantation has shown encouraging results in clinical trials but large volume of blood must be aspirated from patients and a platelet separator is required [8]. Multiple studies are investigating the effect of hyaluronidase, nitric oxide, interleukins, and thrombin to enhance diabetic wound healing [9, 10].

However, until more effective treatment becomes available, preventive measures such as education, good glycemic control, and adequate foot care will be the preferred treatment of patients at risk. With a recurrence rate of 100% within 4 y of an ulcer [11], there is clearly a need for better methods of treatment.

Porcine cutaneous wound healing is physiologically similar to human healing. These wounds heal mostly by epithelialization with a comparatively low contraction rate compared with rodent wound healing [12]. Wound size and number of wounds per animal is limited on rodents, leading to large animal numbers and increased animal to animal variability. Our laboratory has previously demonstrated a delayed epidermal wound healing and altered levels of growth factors in the streptozotocin induced diabetic pig [1].

Other systems have been designed for cultured skin grafting. These employ a matrix, fibrin glue, or dermal tissue to fix the cells to the wound bed. In this study, cells were directly injected onto the wound bed. Desiccation was prevented by the use of liquid-tight polyurethane chambers with normal saline. The wound fluid inside the chamber equilibrates with the concentrations of electrolytes, proteins, growth factors found in the interstitial space. The beneficial effect of a wet wound environment using this chamber model has previously been demonstrated [2]. The sealed chamber allows for the wound microenvironment to be readily monitored and modified like a tissue culture *in vivo*, giving us insight into how wounds heal.

This study demonstrated the beneficial effect of transplanting a suspension of keratinocytes or fibroblasts. As diabetic wounds have a decreased concentration of various growth factors [13, 14], an interesting development to this methodology would be to manipulate these cells with genes expressing various growth factors. Some encouraging results have been shown in healthy pigs by Vranckx *et al.*, showing that hEGF-expressing allogenic keratinocytes can further accelerate healing of full-thickness wounds compared with non-hEGF-expressing keratinocytes [15]. The effect of transplantation of hEGF-expressing autologous keratinocytes on healing of full-thickness wounds in diabetic pigs is currently under investigation.

Injury to skin produces a complex and well-regulated cascade of events in the wound as the body tries to repair

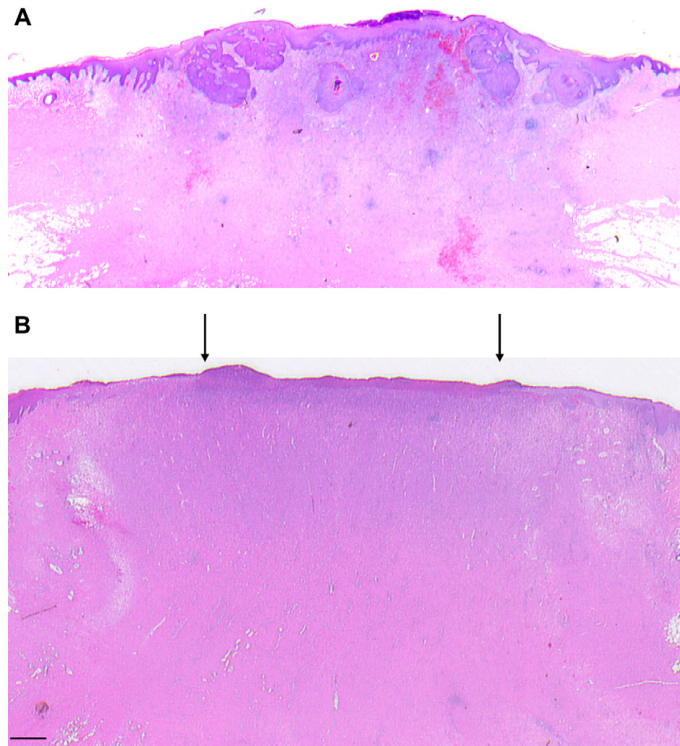


FIG. 3. Keratinocyte colonies migrate upwards from the base of the wound to enhance epidermal healing. Histology of wounds on day 12 (H and E staining). Pictures shows the center of the wound. The arrows show the end of the epithelial tongues. (A) Wound treated with a suspension of 500,000 keratinocytes. (B) Normal saline treated wound Scale 500 μ m. (Color version of figure is available online.)

itself. In normal acute wound healing, the four phases of hemostasis, inflammation, proliferation, and remodeling overlap each other in a highly orchestrated matter. The very nature of diabetic wounds creates a multifaceted problem as diabetic wound healing differs greatly from healthy acute wound healing. Both extrinsic and intrinsic factors contribute to this. Extrinsic factors include neuropathy, giving rise to loss of protective sensation, and atherosclerosis leading to ischemia.

Many changes in the intrinsic factors of diabetic wound healing have been demonstrated in the literature. Several of these changes are seen in patients with chronic ulcers, and in various diabetic animal models [16–21]. These include a defective leucocyte function, where response to inflammation is delayed due to poor migration [13]. This is thought to contribute to the abnormal concentration of growth factors, affecting the wound-healing cascade. The high concentration of glucose in the wound environment promotes glycation and abnormal binding of proteins that lead to the

formation of advanced glycation end-product (AGE) and oxygen free radicals [11]. Free radicals disrupt the redox balance, damaging the DNA, and lead to poor healing.

The concentration of proteases is increased in diabetic wounds. Proteases contribute to unwanted degradation of tissue proteins and disrupt the formation of new extra cellular matrix (ECM). The ECM is abnormal in diabetic wounds with lower concentration of collagen and protein. The resulting defective scaffold, upon which cells should attach, diminishes the stimulation of cell proliferation. In the proliferative phase, fibroblasts have a reduced activity and the migration of keratinocytes is impaired [4, 11].

This study focused on epidermal regeneration of full thickness diabetic wounds. Fibroblasts play a vital role in the proliferative stage of acute wound healing. They migrate into the wound, secreting collagen and other proteins that are essential for the ECM. Once in the ECM, they form an interconnected network of cells

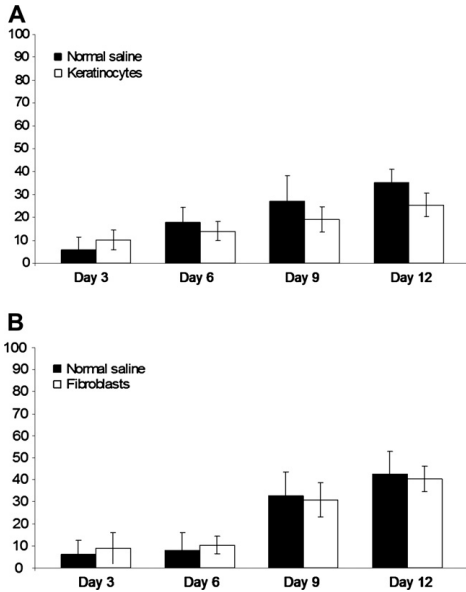


FIG. 4. The effect of keratinocytes or fibroblasts transplantation on the contraction of full thickness wounds in the diabetic pig. Full thickness wounds measuring $1.5 \times 1.5 \times 0.8$ cm were created on the backs of pigs, and were treated with either a suspension of 500,000 keratinocytes (panel A), a suspension of 650,000 fibroblasts (panel B), or normal saline (panels A and B). On day 3, 6, 9, and 12, wound contractions were measured using the permanent boundaries left by the tattooed margins and planimetry. The percentage of contraction was calculated using the following formula: (area at wounding day – area at biopsy day)/(area on wounding day) \times 100. The error bars refer to SD.

that interact by mechanical, chemical, and electrical signals. Loot *et al.* compared *in vitro* culture of fibroblasts from diabetic wounds and non diabetic wounds [4]. Fibroblasts from diabetic wounds showed an altered morphology and a decreased activity. Svensjo *et al.* demonstrated little benefit in injecting a suspension of autologous fibroblasts into acute wounds in healthy Yorkshire pigs [5], suggesting that endogenous fibroblasts are sufficient in promoting healing of the full-thickness wound in this model.

In the current study, a significant enhancement in epidermal healing has been demonstrated with the transplantation of autologous fibroblasts compared with wounds treated with only normal saline. These fibroblasts contributed to restoring some of the function in the proliferative phase by increasing the number of fibroblasts in the ECM. This may increase collagen secretion and protein concentration and may help normalize wound healing.

Re-epithelialization takes place from the wound edges in full thickness wounds with migration of keratinocytes. In diabetic wounds, keratinocytes show an altered morphology and a slower cellular hindering normal epidermal closure [22]. Transplantation of a suspension of autologous keratinocytes into diabetic wounds demonstrated accelerated re-epithelialization comparable to the results demonstrated by Svensjo *et al.* [3] in acute full thickness wounds in healthy Yorkshire pigs.

CONCLUSIONS

The results of this study demonstrated that a suspension of keratinocytes or fibroblasts not only survive in the hostile environment but also contribute to wound healing. This opens the door for possible gene therapy using these cells as vectors.

ACKNOWLEDGMENTS

This study was supported by NIH grant 5R01GM51449.

REFERENCES

1. Velander P, Theopold C, Hirsch T, et al. Impaired wound healing in an acute diabetic pig model and the effects of local hyperglycemia. *Wound Repair Regen* 2008;16:288.
2. Svensjo T, Pomahac B, Yao F, et al. Accelerated healing of full-thickness skin wounds in a wet environment. *Plast Reconstr Surg* 2000;106:602. discussion 613.
3. Svensjo T, Yao F, Pomahac B, et al. Autologous keratinocyte suspensions accelerate epidermal wound healing in pigs. *J Surg Res* 2001;99:211.
4. Loots MA, Lamme EN, Mekkes JR, et al. Cultured fibroblasts from chronic diabetic wounds on the lower extremity (non-insulin-dependent diabetes mellitus) show disturbed proliferation. *Arch Dermatol Res* 1999;291:93.
5. Svensjo T, Yao F, Pomahac B, et al. Cultured autologous fibroblasts augment epidermal repair. *Transplantation* 2002;73:1033.
6. Vogt PM, Thompson S, Andree C, et al. Genetically modified keratinocytes transplanted to wounds reconstitute the epidermis. *Proc Natl Acad Sci USA* 1994;91:9307.
7. Steed DL. Clinical evaluation of recombinant human platelet-derived growth factor for the treatment of lower extremity ulcers. *Plast Reconstr Surg* 2006;117(7 Suppl). 143S; discussion 150S.
8. Han SK, Kim DW, Jeong SH, et al. Potential use of blood bank platelet concentrates to accelerate wound healing of diabetic ulcers. *Ann Plast Surg* 2007;59:532.
9. Schaffer M, Bongartz M, Fischer S, et al. Nitric oxide restores impaired healing in normoglycemic diabetic rats. *J Wound Care* 2007;16:311.
10. Dechert TA, Ducale AE, Ward SI, et al. Hyaluronan in human acute and chronic dermal wounds. *Wound Rep Regen* 2006;14:252.
11. Sweitzer SM, Fann SA, Borg TK, et al. What is the future of diabetic wound care? *Diabetes Educ* 2006;32:197.
12. Bell RH, Jr., Hye RJ. Animal models of diabetes mellitus: Physiology and pathology. *J Surg Res* 1983;35:433.
13. Blakytyn R, Jude E. The molecular biology of chronic wounds and delayed healing in diabetes. *Diabet Med* 2006;23:594.
14. Greenhalgh DG. Wound healing and diabetes mellitus. *Clin Plast Surg* 2003;30:37.

15. Vranckx JJ, Hoeller D, Velander PE, et al. Cell suspension cultures of allogenic keratinocytes are efficient carriers for ex vivo gene transfer and accelerate the healing of full-thickness skin wounds by overexpression of human epidermal growth factor. *Wound Rep Regen* 2007;15:657.
16. Bitar MS. Insulin and glucocorticoid-dependent suppression of the IGF-I system in diabetic wounds. *Surgery* 2000;127:687.
17. Bitar MS, Labbad ZN. Transforming growth factor-beta and insulin-like growth factor-I in relation to diabetes-induced impairment of wound healing. *J Surg Res* 1996;61:113.
18. Jeffcoate WJ, Price P, Harding KG. Wound healing and treatments for people with diabetic foot ulcers. *Diabetes Metab Res Rev* 2004;20(Suppl 1). S78.
19. Kamal K, Powell RJ, Sumpio BE. The pathobiology of diabetes mellitus: implications for surgeons. *J Am Coll Surg* 1996;183:271.
20. Komesu MC, Tanga MB, Buttros KR, et al. Effects of acute diabetes on rat cutaneous wound healing. *Pathophysiology* 2004;11:63.
21. Yuan S, Liu Y, Zhu L. Vascular complications of diabetes mellitus. *Clin Exp Pharmacol Physiol* 1999;26:977.
22. Spravchikov N, Sizyakov G, Gartsbein M, et al. Glucose effects on skin keratinocytes: implications for diabetes skin complications. *Diabetes* 2001;50:1627.

Paper III

Insulin-like growth factor-1 gene therapy and cell transplantation in diabetic wounds

Tobias Hirsch¹
Malte Spielmann¹
Patrik Velander¹
Baraa Zuhaili¹
Oliver Bleiziffer¹
Magdalena Fossum¹
Lars Steinstraesser²
Feng Yao¹
Elof Eriksson^{1*}

¹*Division of Plastic Surgery, Brigham and Women's Hospital and Harvard Medical School, Boston, MA, USA*

²*Department of Plastic Surgery, Burn Center, BG University Hospital Bergmannsheil, Ruhr University Bochum, Germany*

*Correspondence to: Elof Eriksson, Chief, Division of Plastic Surgery, Brigham and Women's Hospital, 75 Francis Street, Boston, MA 02115, USA. E-mail: eeriksson@partners.org

Abstract

Background Impaired wound healing is a frequent phenomenon in diabetes mellitus. However, little is known of the fundamental cause of this pathology. The present study examined the effect of human insulin-like growth factor (hIGF)-1 overexpression in combination with autologous cell transplantation to diabetic wounds in a preclinical large-animal model.

Methods Diabetes was induced in Yorkshire pigs with streptozotocin. Keratinocytes were cultured and transfected with hIGF-1 or LacZ transgene. Plasmids were lipoplexed with either Lipofectin or Lipofectamin 2000. Transgene expression was assessed by enzyme-linked immunosorbent assay or X-gal staining. For *in vivo* studies, full-thickness wounds were created and dressed with a sealed chamber. Transfected cells were transplanted into the wounds. Wound contraction was monitored and biopsies were obtained for measurement of re-epithelialization. Wound fluid was collected and analysed for IGF-1 concentrations.

Results Quantification showed up to 740 ng/ml IGF-1 *in vitro* and significantly higher concentrations over 14 days compared to controls for the Lipofectamin 2000 group. Lipofectin-mediated gene transfer showed peak expression on day 2 with 68.5 ng/ml. *In vivo*, transfected cells showed peak expression of 457 ng/ml at day 1, followed by subsequent decline to 5 ng/ml on day 12 with Lipofectamin 2000. For Lipofectin, no significant IGF-1 expression could be detected. Gene therapy caused significantly faster wound closure (83%) than both controls (native-cell therapy = 57%; control wounds = 32%).

Conclusions The present study demonstrates that optimized nonviral gene transfer increased IGF-1 expression in diabetic wounds by up to 900-fold. This high IGF-1 concentration in combination with cell therapy improved diabetic wound healing significantly. Copyright © 2008 John Wiley & Sons, Ltd.

Keywords cell transplantation; diabetes; gene therapy; IGF-1; re-epithelialization; wound healing

Introduction

Approximately 5 million patients in the USA suffer from chronic wounds [1]. With increased longevity, obesity and diabetes, the problem of chronic wounds has increased, resulting in significant morbidity, lost time from work, and enormous health-care expenses. According to the American Diabetes Association, 25% of people with diabetes will suffer from a wound problem during their lifetime; approximately 82 000 limb amputations for

Received: 16 March 2008

Revised: 16 June 2008

Accepted: 28 July 2008

nontraumatic wounds were performed in people with diabetes in 2002 [2]. The Agency for Health Care Policy and Research reports that wound care for pressure ulcers costs \$200 billion per year for hospitalization, durable medical goods, nursing home care, physicians, and transportation [3]. Surgical treatment of diabetic wounds remains difficult and often insufficient, leading to high morbidity among those patients [4].

Human insulin-like growth factor-1 (IGF-1) has been shown to be drastically reduced in fibroblasts and in the basal layer from skin of diabetic patients as well as in diabetic ulcers compared to nondiabetic wounds [5]. On the other hand, IGF-1 showed proliferative effects on keratinocytes and fibroblasts *in vitro* [6]. In our diabetic wound-healing model, we confirmed these data: Expression of human IGF (hIGF)-1 in diabetic wounds was markedly reduced compared to nondiabetic wounds [7]. These findings led us to the hypothesis that enhanced IGF-1 expression in diabetic wounds can alter wound healing.

Because the half-life of proteins such as growth-factors in the aggressive wound environment is short [8], we considered gene transfer to constantly overexpress hIGF-1 growth-factor in the wound. Most approaches for the transfection of keratinocytes and skin have been performed with viral vectors [9]. Virus-mediated gene transfer, such as adenoviral [10], adeno-associated [11] or retroviral techniques [12], have been described. However, major disadvantages of viral vectors led to the development of nonviral techniques for gene transfer to skin [13]. Nonviral gene transfer has several advantages over other gene delivery techniques, such as low immunogenicity [14], transient expression of the transgene without stable integration into the host genome [15,16], safe and inexpensive production, and the possibility of repeated administration [17]. On the other hand, *in vivo* application of nonviral gene transfer vehicles is significantly hampered by their low transgene expression in the target tissue [18,19]. However, in skin and particularly in cutaneous wounds, significant transgene expression is required for therapeutic effects. Some efforts have been made to improve cDNA-derived gene transfer to skin: physical methods such as subcutaneous injection [20], gene gun [21], microseeding [22] and electroporation [23] have been developed. Furthermore, chemical methods such as liposomal complexation have been applied [24]. Although many approaches and techniques have been developed to date, none is ideal, and more work is necessary to further improve gene-therapy vectors.

The present study aimed to investigate whether hIGF-1 overexpression can improve wound healing in diabetes-impaired wounds. Therefore, nonviral gene delivery to wounds in a preclinical diabetic large animal wound healing model [7,25] was employed and optimized to reach significant transgene expression during the wound-healing process.

Materials and methods

Animals

All animal procedures were approved by the Harvard Medical Area Standing Committee on Animals and conformed to the regulations related to animal use and other federal statutes. Female Yorkshire pigs (Parson's Farm, MA, Hadley USA), weighing 50–60 kg at arrival, were allowed to acclimatize for 1 week before initiation of the experiment.

Anaesthesia and procedures

Animals received induction anaesthesia with ketamine (Hospira; Lake Forest, IL, USA) and xylazine (Xylaject; Phoenix, St Josephs, MO, USA) followed by general anaesthesia with isoflurane (Novaplus; Hospira, IL, USA), inhalation (2–3%Vol) and were weighed. Streptozotocin (Zanosar; Pharmacia, Pfizer, New York, NY, USA) was applied at a dose of 150 mg/kg body weight. Buprenorphine was administered for pain control. Serum glucose concentration was measured daily. Pigs received insulin (Normulin; Novo Nordisk, Princeton, NJ, USA; Humulin; Eli Lilly, Indianapolis, IN, USA) treatment to keep the blood glucose concentration between 300 and 500 mg/dl.

Harvesting of split-thickness skin graft

At the time of induction, the hair from the nape of the neck was clipped and the skin was thoroughly disinfected. Two small strips of 0.38-mm split skin grafts measuring 2 × 8 cm were harvested with an electric dermatome (Padgett Instruments, Plainsboro, NJ, USA). The resulting partial-thickness wounds were dressed with vaseline gauze and sterile dressing.

Cell culture

Autologous keratinocytes were isolated from these split-thickness skin grafts. The grafts were washed in sterile phosphate-buffered saline (PBS; Sigma, St Louis, MO, USA) cut into 1 × 1 cm squares, and left in 2 U/ml dispase (Invitrogen, Carlsbad, CA, USA) solution at 4 °C overnight. The epidermis was peeled off the dermis; 5 ml of 0.0625% trypsin (Invitrogen, Carlsbad, CA, USA) was added to the epidermal sheets and left for 3 min at 37 °C. The epidermis/trypsin solution was then passed through a sterile sieve, and the trypsin was neutralized by addition of fetal bovine serum (FBS; Sigma). The resulting solution was centrifuged at 750 r.p.m. for 6 min at 37 °C to pellet the keratinocytes, which were resuspended in keratinocyte serum-free medium (Invitrogen) containing added bovine pituitary hormone, epidermal growth factor, calcium-depleted FBS, calcium

dichloride, streptomycin, penicillin, gentamicin, and amphotericin (Gibco, Carlsbad, CA, USA). Keratinocytes were seeded at a density of 6×10^6 cells per 100-mm dish and subcultured at 90% confluence.

hIGF-1 gene transfer

Keratinocytes were passed and seeded at a density of 3×10^5 cells per 100-mm dish; 72 h later, they were transfected with 10 μ g of pBLAST-hIGF-1 or pCEP4-LacZ plasmid lipoplexed with either Lipofectin (Invitrogen) at a ratio of 1:4 or Lipofectamin 2000 (Invitrogen) at a ratio of 1:2. This solution was placed in serum-free medium, added to the cells, and incubated at 37°C for 4 h and 1 h, respectively. The transfection medium was replaced with regular growth medium after incubation. Medium was collected daily for quantitative analysis of IGF expression. Cells were incubated for 48 h after transfection before transplantation into wounds.

Wounding and chamber treatment

Fourteen days after induction of diabetes, pigs received anaesthesia as mentioned above and were transferred to a Panepinto sling (Fulton, Mosinee, WI, USA) for the time of surgery. The pig's dorsum was waxed (Nair, Church & Dwight, Princeton, NJ, USA), shaved, and thoroughly disinfected. Eighteen to 21 squares measuring 1.5×1.5 cm were outlined on the dorsum by tattoo machine (Special Electric Tattoo Marker; Spaulding Enterprises, Voorheesville, NY, USA) to allow measurement of wound contraction. After the skin was prepared with povidone iodine, the tissue within the squares was excised to create 18–21 full-thickness wounds, 0.8 cm in depth. An adhesive polyurethane chamber (Corium International, Grand Rapids, MI, USA) were applied over each wound.

Transplantation of autologous keratinocytes

Wounds were randomly divided into three groups: (i) wounds transplanted with 5×10^5 transfected keratinocytes (study group); (ii) wounds transplanted with 5×10^5 native keratinocytes (transplant control); and (iii) wounds treated with 0.9% sterile saline solution (control).

The chambers were injected with 2 ml of cell suspension or 0.9% sterile saline, containing penicillin 100 units/ml and streptomycin 100 μ g/ml. The wound fluid collected in the chambers was completely aspirated at 24-h intervals and chilled on ice before being stored at approximately 80°C for later analysis. Each chamber was re-injected with 2 ml of sterile saline (containing penicillin/streptomycin). For analgesia, buprenorphine was administered intramuscularly every 12 h for the first 2 days.

Wound contraction

Wound contraction was determined by digitized planimetry of the tattooed margins. The area of the wounds at specific days was measured with Scion image software (Scion, Frederick, MD, USA), and the percentage of contraction was calculated by the formula: [area at biopsy (day)/area on wounding (day)] \times 100.

Histology

On day 12, pigs were euthanized by intravenous injection of Euthasol (Virbac AH, Fort Worth, TX, USA). Cross-sectional wound biopsies, 2 mm wide, were taken from the middle of the wounds; the sample included unwounded skin at the sides and subcutaneous tissue at the bottom. Samples were fixed in 4% buffered paraformaldehyde and processed for hematoxylin and eosin staining.

Re-epithelialization was calculated by scanning the slides (Epson Perfection 3600; Epson, Longbeach, CA, USA) and measuring the epithelial tongues from the computerized image with Paintshop Pro software, version 7.0 (Corel, Fermont, CA, USA).

Measurements of hIGF-1 growth factor

Level of hIGF-1 in the wound environment was measured in wound fluid by a specific enzyme-linked immunosorbent assay (R&D Systems, Minneapolis, MN, USA). Results were calculated by a Vmax kinetic Microplate Reader and Soft Max Pro software (Molecular Devices, Sunnyvale, CA, USA).

X-Gal staining and histological analysis

Forty-eight hours after transfection, cells transfected with Lac-Z plasmid were washed twice with PBS. They were fixed for 30 min in 0.05% glutaraldehyde solution, washed twice with PBS, and stained for 3 h with 0.5 mg/ml X-Gal substrate (Fisher Scientific, Worcester, MA, USA). Successfully transfected cells were counted in 32 randomly selected high power fields.

Statistical analysis

The present study included 60 wounds in three diabetic pigs randomly divided into three groups: (a) pBLAST-hIGF-1 transfected autologous keratinocytes ($n = 21$); (B) autologous untransfected keratinocytes (carrier control, $n = 21$); and (C) 0.9% sterile saline solution (no treatment control, $n = 18$). Values are presented as the means \pm SE. Groups were compared with a nonparametric test, and statistical calculations were performed with GraphPad InStat software (GraphPad

Software, La Jolla, CA, USA). $p < 0.05$ was considered statistically significant.

Results

Optimization of *ex vivo* gene transfer to porcine keratinocytes

Cells were transfected with 10 μ g of IGF-1 or LacZ plasmid complexed with either Lipofectamin 2000 or Lipofectin. X-gal staining showed higher transfection efficiency for the Lipofectamin 2000 group [$79 \pm 12\%$ transfection efficiency/high power field (HPF)] than for the Lipofectin group ($28 \pm 9\%$ transfection efficiency/HPF) (Figure 1). Quantification of hIGF-1 transgene expression showed up to 740 ng/ml IGF concentration for Lipofectamin 2000 lipoplex. We detected an initial increase from day 1 (550 ng/ml) to day 2 (740 ng/ml), followed by a slow decrease over time (708 ng/ml on day 3, 455 ng/ml on day 5, 57 ng/ml on day 7, 48 ng/ml on day 10), with a final measurement of 7.47 ng/ml at the end of the experiment (day 14). Lipofectin lipoplex gene transfer showed peak expression on day 2 with 68.5 ng/ml, followed by a decrease to 20–30 ng/ml on days 3 and 5, 2 ng/ml on day 7, and 0.8 ng/ml on day 14. LacZ-transfected controls showed hIGF-1 concentrations between 0.86 and 0.36 ng/ml over the time course (Figure 2).

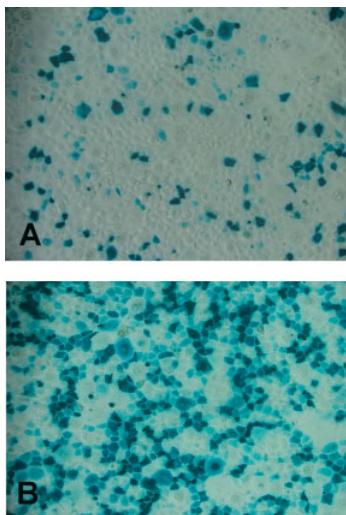


Figure 1. X-gal staining 48 h after transfection of primary keratinocytes. (A) Lipofectin lipoplex transfection. (B) Lipofectamin 2000 lipoplex transfection

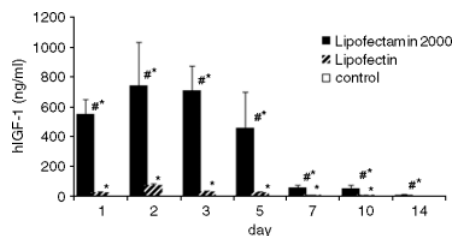


Figure 2. Quantitative analysis of hIGF-1 *in vitro* expression. Comparison among cDNA: lipoplex with either Lipofectamin 2000, Lipofectin, or Control ($\#p < 0.05$ Lipofectamin 2000 versus Lipofectin; $*p < 0.05$ versus control)

Serum and wound fluid glucose levels

Following the injection of streptozotocin, there was a triphasic glucose response during the first 30 h, with an initial hyperglycemia followed by marked hypoglycemia and finally a permanent hyperglycemic state (blood glucose above 300 mg/dl) for the duration of the experiment. Wound fluid was collected daily, and the glucose concentration was measured. The glucose levels in wound fluid closely followed the levels in serum until day 4, when the levels in wound fluid constantly decreased.

In vivo transgene expression

Forty-eight hours after *ex vivo* transfection, cells were re-transplanted into the created full-thickness wounds. Wounds treated with 5×10^5 cells transfected with a pBLAST-hIGF-1/Lipofectin lipoplex achieved up to 3.29 ng/ml total IGF-1 concentration, with the highest peak on day 4 followed by a decrease until day 12.

Wounds receiving cells transfected with pBLAST-hIGF-1/Lipofectamin 2000 lipoplex achieved transgene expression level on day 1 after re-transplantation of 457 ng/ml versus 0.51 ng/ml for keratinocyte control. From day 2 to day 12, IGF-1 concentration in the wound fluid showed a steady decrease over time, with a final concentration of 5.05 ng/ml on day 12 and still a significantly higher IGF-concentration than in both controls over the whole course of experiment ($p < 0.05$; Figure 3).

Re-epithelialization and wound contraction

Histology showed almost completely re-epithelialized wounds for the Lipofectamin 2000 gene therapy group. Evenly formed new epithelium was observed, including connective tissue papillae (Figure 4A). Native cell-transplanted wounds showed successfully transplanted cells still in the process of migrating upwards from the wound bed towards the wound surface, integrating into the newly-forming epithelium. Thus, the epithelium was

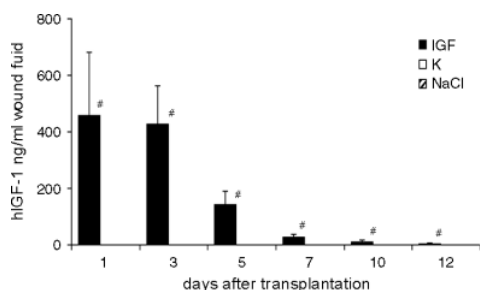


Figure 3. hIGF-1 transgene expression *in vivo*. # $p < 0.05$ gene transfer group versus controls (untransfected keratinocytes showed hIGF-1 expression in the range 1.3–0.5 ng/ml wound fluid; saline control wounds showed expression in the range 0.8–0.5 ng/ml wound fluid)

less organized than in the wounds treated with transfected cells (Figure 4B). Control wounds showed regular wound healing, including re-epithelialization by keratinocytes migrating from the wound edges towards the center of the defect by forming epithelial tongues (Figure 4C).

Lipofectamin 2000-lipoplex treated wounds showed significantly faster re-epithelialization ($83 \pm 17\%$) than the keratinocyte group ($57 \pm 12\%$), and both groups were significantly different from the negative control ($32 \pm 1\%$; $p < 0.0001$ and 0.001 , respectively; Figure 5). For the Lipofectin lipoplex-treated wounds, re-epithelialization did not significantly differ between the transfected keratinocyte and native keratinocyte groups. Wound contraction showed no significant difference among all groups.

Discussion

Although much advancement in gene transfer to tissue has been achieved in recent years, it remains difficult to achieve high transgene concentrations *in vivo*. Particularly in skin, successful gene delivery still presents a challenge, although high-level transgene expression is crucial to obtain therapeutically relevant concentrations in wounds [26].

Therefore, we assessed and optimized *ex vivo* nonviral gene transfer to autologous keratinocytes and *in vivo* IGF-1 growth-factor concentrations in wounds. Two different liposomes, Lipofectamin 2000 and Lipofectin, were complexed with cDNA. Lipofectin showed low cytotoxicity but also little transgene expression, whereas Lipofectamin 2000 revealed high transgene expression but also high cytotoxicity, with an incubation time of 4 h in previous experiments (data not shown). Therefore, we limited the incubation time stepwise until we received optimal transfection efficiency. We could optimize transfection technique by limiting incubation time to 1 h for keratinocyte transfection. Finally, *in vitro* hIGF-1 transgene expression reached 740 ng/ml. Using

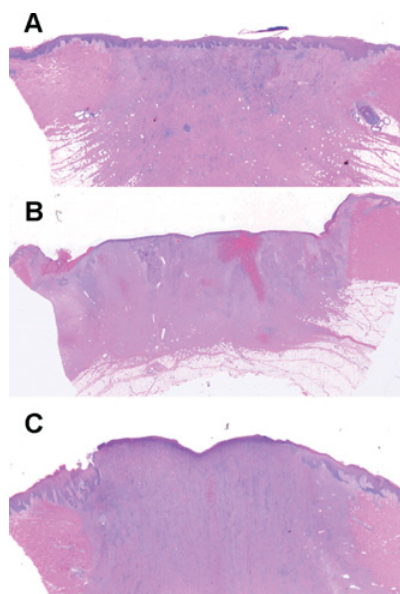


Figure 4. (A) Histology of hIGF-1-treated wound with newly formed epithelium. (B) Native keratinocyte transplanted control wound. (C) Untreated control wound (hematoxylin and eosin staining; $\times 10$ magnification)

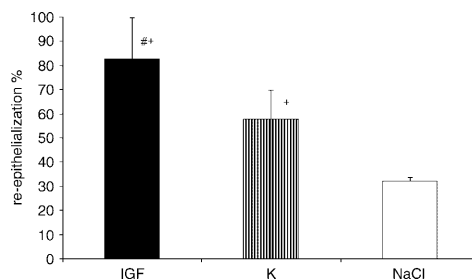


Figure 5. Re-epithelialization on day 12. # $p < 0.01$ IGF-1 transgene keratinocyte-treated wounds versus keratinocyte-transplanted control; + $p < 0.0001$ versus saline control

retroviral vectors, Eming *et al.* [27] obtained 560 ng/ml IGF-1 concentration in cultured keratinocytes. To our knowledge, no higher transgene expression for hIGF-1 growth-factor gene transfer in dermal cell culture has been described to date. Thus, we were able to optimize the transduction efficiency for nonviral *ex vivo* gene transfer significantly by modifying the transfection protocol to gain therapeutically relevant growth-factor concentrations.

Regarding the evidence that growth factor half-life is limited by the aggressive wound environment [8,28], it is of paramount importance to provide high transgene expression levels. Rolland [29] reported

remarkable differences between *in vitro* and *in vivo* transgene expression in skin and cutaneous cells when lipoplexes are used. In the present study, *in vivo* measurements mirrored the *in vitro* findings: With the modified Lipofectamin 2000 transfection technique, hIGF growth-factor concentrations overcame the IGF concentration measured in diabetic wounds by up to 900-fold. When we used Lipofectin for *ex vivo* gene transfer, only low hIGF-1 concentrations could be detected in the wound fluid.

Thus, we could show that therapeutic success using hIGF-1 gene transfer to diabetic wounds is dose dependent in large-animal models. This shows the importance of quantification of transgene products, when gene therapy is applied.

Native re-transplanted cells also improved wound closure significantly. However, the high hIGF-1 concentration in the transfected study group finally led to further improved re-epithelialization and significantly faster wound healing, with more than 80% wound closure at day 12, versus approximately 60% and 30% in the control groups, respectively. These data indicate that hIGF-1 transfected and re-transplanted cells cause > 25% faster wound healing than untreated re-transplanted keratinocytes.

In the present study, we could alter the diabetes-impaired wound-healing process from 30–40% wound-closure to 83% using combined gene- and cell therapy. In a previous study, we could show that wounds in a nondiabetic pig showed 96% re-epithelialization by day 12 after wounding using the same animal model [7]. Thus, we were able to significantly enhance diabetes impaired wound healing close to the normal (nondiabetic) level of reepithelialization in the present study.

Acknowledgements

This work was supported by the National Institutes of Health (NIH; 5ROIGM51449). T.H. was partially supported by the Deutsche Forschungsgemeinschaft (DFG HI1279/1-1).

References

- Mostow EN. Diagnosis and classification of chronic wounds. *Clin Dermatol* 1994; **12**: 3–9.
- (ADA) ADA Complications of Diabetes in the United States. <http://www.diabetesorg/diabetes-statistics/complications.jsp> [08/20/2008].
- Rees RH, Hirschberg JA. Wound care centers: costs, care and strategies. *Adv Wound Care* 1999; **12**: 4–7.
- Bowler PG. Wound pathophysiology, infection and therapeutic options. *Ann Med* 2002; **34**: 419–427.
- Blakytyn R, Jude EB, Martin Gibson J, et al. Lack of insulin-like growth factor 1 (IGF1) in the basal keratinocyte layer of diabetic skin and diabetic foot ulcers. *J Pathol* 2000; **190**: 589–594.
- Kratz G, Lake M, Ljungstrom K, et al. Effect of recombinant IGF binding protein-1 on primary cultures of human keratinocytes and fibroblasts: selective enhancement of IGF-1 but not IGF-2-induced cell proliferation. *Exp Cell Res* 1992; **202**: 381–385.
- Velander P, Theopold C, Hirsch T, et al. Impaired wound healing in an acute diabetic pig model and the effects of local hyperglycemia. *Wound Repair Regen* 2008; **16**: 288–293.
- Lynch SE, Nixon JC, Colvin RB, et al. Role of platelet-derived growth factor in wound healing: synergistic effects with other growth factors. *Proc Natl Acad Sci USA* 1987; **84**: 7696–7700.
- Zellmer S, Gauntitz F, Salvetter J, et al. Long-term expression of foreign genes in normal human epidermal keratinocytes after transfection with lipid/DNA complexes. *Histochem Cell Biol* 2001; **115**: 41–47.
- Jacobsen F, Mittler D, Hirsch T, et al. Transient cutaneous adenoviral gene therapy with human host defense peptide hCAP-18/LL-37 is effective for the treatment of burn wound infections. *Gene Ther* 2005; **12**: 1494–1502.
- Galeano M, Deodato B, Altavilla D, et al. Effect of recombinant adeno-associated virus vector-mediated vascular endothelial growth factor gene transfer on wound healing after burn injury. *Crit Care Med* 2003; **31**: 1017–1025.
- Lee JA, Conejero JA, Mason JM, et al. Lentiviral transfection with the PDGF-B gene improves diabetic wound healing. *Plast Reconstr Surg* 2005; **116**: 532–538.
- Niidade T, Huang L. Gene therapy progress and prospects: nonviral vectors. *Gene Ther* 2002; **9**: 1647–1652.
- Zhang S, Xu Y, Wang B, et al. Cationic compounds used in lipoplexes and polyplexes for gene delivery. *J Control Release* 2004; **100**: 165–180.
- Tao Z, Herndon D, Hawkins H, et al. Insulin-like growth factor-I cDNA gene transfer in vitro and in vivo. *Biochem Genet* 2000; **38**: 41–55.
- Vogel JC. Nonviral skin gene therapy. *Hum Gene Ther* 2000; **11**: 2253–2259.
- Jeschke MG, Richter G, Herndon DN, et al. Therapeutic success and efficacy of nonviral liposomal cDNA gene transfer to the skin in vivo is dose dependent. *Gene Ther* 2001; **8**: 1777–1784.
- Dass CR. Lipoplex-mediated delivery of nucleic acids: factors affecting in vivo transfection. *J Mol Med* 2004; **82**: 579–591.
- Felgner PL. Improvements in cationic liposomes for in vivo gene transfer. *Hum Gene Ther* 1996; **7**: 1791–1793.
- Hengge UR, Walker PS, Vogel JC. Expression of naked DNA in human, pig, and mouse skin. *J Clin Invest* 1996; **97**: 2911–2916.
- Steintraesser L, Fohn M, Klein RD, et al. Feasibility of biolistic gene therapy in burns. *Shock* 2001; **15**: 272–277.
- Eriksson E, Yao F, Svensjo T, et al. In vivo gene transfer to skin and wound by microseeding. *J Surg Res* 1998; **78**: 85–91.
- Maruyama H, Ataka K, Higuchi N, et al. Skin-targeted gene transfer using in vivo electroporation. *Gene Ther* 2001; **8**: 1808–1812.
- Dasu MR, Herndon DN, Nesci O, et al. IGF-I gene transfer effects on inflammatory elements present after thermal trauma. *Am J Physiol Regul Integr Comp Physiol* 2003; **285**: R741–R746.
- Hirsch T, Spielmann M, Zuhaili B, et al. Enhanced susceptibility to infections in a diabetic wound healing model. *BMC Surg* 2008; **8**: 5.
- Hirsch T, Spielmann M, Yao F, Eriksson E. Gene therapy in cutaneous wounds. *Front Biosci* 2007; **12**: 2507–2518.
- Eming SA, Snow RG, Yarmush ML, et al. Targeted expression of insulin-like growth factor to human keratinocytes: modification of the autocrine control of keratinocyte proliferation. *J Invest Dermatol* 1996; **107**: 113–120.
- Cross SE, Roberts MS. Defining a model to predict the distribution of topically applied growth factors and other solutes in excisional full-thickness wounds. *J Invest Dermatol* 1999; **112**: 36–41.
- Rolland AP. From genes to gene medicines: recent advances in nonviral gene delivery. *Crit Rev Ther Drug Carrier Syst* 1998; **15**: 143–198.

Paper IV



Cell suspension cultures of allogenic keratinocytes are efficient carriers for ex vivo gene transfer and accelerate the healing of full-thickness skin wounds by overexpression of human epidermal growth factor

Jan Jeroen Vranckx, MD^{1,2*}; Daniela Hoeller, MD^{1,3*}; Patrik E. M. Velander, MD¹; Christoph F. P. Theopold, MD¹; Nicola Petrie, MD¹; Akira Takedo, MD¹; Elof Eriksson, MD, PhD¹; Feng Yao, PhD¹

1. Laboratory of Wound Repair and Gene Transfer, Division of Plastic Surgery, Brigham & Women's Hospital, Harvard Medical School, Boston, Massachusetts;

2. Laboratory of Plastic Surgery and Tissue Engineering Research, KUL Leuven University Hospitals, UZ-Gasthuisberg, Leuven, Belgium, and

3. Department of Dermatology, University Clinic of the RWTH University, Aachen, Germany

Reprint requests:

Feng Yao, PhD, Laboratory of Tissue Repair and Gene Transfer, Division of Plastic Surgery, Brigham & Women's Hospital, 75 Francis Street, Boston, MA 02115.
Tel: +1 617 732 4836;
Fax: +1 617 278 6918;
Email: fyao@rics.bwh.harvard.edu

*Contributed equally to this work

Manuscript received: June 16, 2006

Accepted in final form: March 12, 2007

DOI:10.1111/j.1524-475X.2007.00272.x

ABSTRACT

The concept of using growth factor therapy to induce wound repair has been endorsed in studies that show reduced growth factors in wound fluid from chronic and aged wounds. In this study, we used cell suspensions of allogenic keratinocytes as gene-delivery vehicles for human epidermal growth factor (hEGF) and analyzed their impact on wound repair in a porcine wound-healing model. Full-thickness wounds were created on the backs of six Yorkshire pigs and covered with a wound chamber to create a wet wound-healing environment. First, 5×10^5 allogenic, autogenic, or mixed keratinocytes were transplanted into wounds and healing parameters were analyzed. Second, we measured long-term reepithelialization and contraction rates from day 8 until day 35. In the third experiment, allogenic keratinocytes were transfected with an hEGF-expressing plasmid pCEP-hEGF and transplanted in full-thickness wounds to improve repair. Wounds treated with autogenic, allogenic, or mixed keratinocytes showed a significantly higher rate of reepithelialization relative to saline-treated control wounds. Repetitive biopsies indicated that the use of allogenic keratinocytes did not lead to long-term wound breakdown. Wounds treated with hEGF-expressing allogenic keratinocytes reepithelialized faster than wounds treated with allogenic keratinocytes or control wounds. With a peak hEGF expression of 920.8 pg/mL, hEGF was detectable until day 5 after transplantation compared with minimal hEGF expression in control wounds. This study shows that allogenic keratinocytes can serve as efficient gene transfer vehicles for ex vivo growth factor delivery to full-thickness wounds and overexpression of hEGF further improves reepithelialization rates.

Growth factors are omnipresent in each phase of the wound-healing process. Cells that orchestrate the healing response produce them. Growth factors influence the growth rate of these cells when bound to specific receptors.^{1,2} The advent of gene therapy has addressed many of the intrinsic restrictions of topical recombinant growth factor therapy to wounds and has enabled genetic material to be successfully introduced into cells with the intent of altering protein synthesis to modify the healing response.³⁻⁵ Gene therapy can offer targeted local and persistent delivery of de novo synthesized growth factors to the wound microenvironment over many days but can also be used to selectively elevate or down-regulate expression of a particular growth factor.

We hypothesized that wound repair can be accelerated by the overexpression of targeted exogenous growth factor genes into the wound microenvironment.

In a standardized full-thickness skin wound (FTW) model in young and old pigs, established in our laborato-

ry, we analyzed the impact of in vivo and ex vivo gene transfer of growth factors such as epidermal growth factor (EGF), keratinocyte growth factor (KGF), platelet-derived growth factor (PDGF), vascular endothelial growth factor (VEGF), and transforming growth factor- β 1 (TGF- β 1) on wound repair.⁶⁻¹⁰

BSA	Bovine serum albumin
BW	Body weight
ELISA	Enzyme-linked immunosorbent assay
FBS	Fetal bovine serum
H & E	Hematoxylin & eosin
hEGF	Human epidermal growth factor
KBM	Keratinocyte basal medium
MHC	Major histocompatibility complex
PBS	Phosphate-buffered saline
SFM	Serum-free medium

In this study, we used ex vivo gene transfer mediated by cationic liposomes to transfect cell suspensions of porcine keratinocytes with human EGF (hEGF). EGF is produced by platelets, keratinocytes, monocytes, and macrophages and is present in high quantities in the early phase of wound healing. EGF likely increases wound healing by stimulating the proliferation and migration of epithelial cells and mesenchymal cells.^{11,12} However, topical application of recombinant growth factors to wounds encounters intrinsic problems such as short half-life of recombinant protein, thus requiring repetitive doses at frequent intervals with subsequent high cost and effort, irregular secretion profiles due to the bioavailability parameters of the utilized vehicle, and lack of proper post-translational modifications that may impair its biological functions.^{13,14}

Ex vivo gene transfer of EGF-expressing allogenic keratinocytes (AKC) may combine cell-based wound-healing strategies and gene therapy for coverage of large chronic ulcers or extensive burn wounds, where donor sites are minimal and precious. Such gene-expressing allogenic cells could be cryopreserved in large numbers and stored until required. Once applied to wounds, AKC may contribute to healing by de novo expression of growth factors as well as by their direct involvement in epidermal regeneration as a temporary bioscaffold. In this study, we hypothesized that cell suspensions of AKC serve as efficient gene-delivery vehicles for hEGF, further accelerate wound healing, and lead to long-term repair of porcine full-thickness wounds in a wet wound-healing environment.

MATERIALS AND METHODS

Harvest of a split-thickness skin graft for porcine KC cell cultures

Consecutively, six 4-month-old female Yorkshire pigs (Parson's & Sons Inc., Hadley, MA) entered the animal facility 1 week before surgery. Pigs were penned individually to minimize the risk of chamber disruption. The environment was set to a temperature range of 20 °C, 65% humidity, and a 12-hour on-off light cycle. Animals were fed 2 pounds of standard porcine diet per day and clean, fresh water was administered ad libitum. A custom-made mobile sling adjustable in height (Universal Metals Company, Boston, MA) was used to transport and hold animals during the initial operation and during daily maintenance of wound chambers and fluid.¹⁰

Anesthesia was performed following a standard protocol: pigs were premedicated in the sling in the ventral decubitus position with 0.3 mg/kg body weight (BW) of ketamine and 2 mg/kg BW of xylazine through a flexible butterfly needle. Subsequently, the animals were induced with 5% isoflurane for 5 minutes through a snout mask. For procedures longer than 45 minutes, pigs were intubated with 6.5 mm intratracheal tubes in ventral decubitus. During the operation, pigs received 1.5–2.0% isoflurane and 4 L O₂. Pulse oximetry, heart rate (Datex Ohmeda sensors, Andover, MA), and rectal temperature were monitored throughout the procedure.

After hair removal (Nair microwave wax; Church & Dwight, Princeton, NJ), a split-thickness skin graft was harvested from the neck of the pig using an electrical

dermatome, set on a thickness of 0.0014 in. (Padgett Instruments, Integra Life Sciences, Plainsboro, NJ). The donor site was covered with Tegaderm (3M, St. Paul, MN).

After the surgical intervention, pigs were left to awaken in the sling while monitoring of the vital functions continued. After awakening, the pig was transported in the mobile sling to the cage. Twice a day, 0.3 mg/kg buprenorphine was injected IM for pain relief. All animal procedures were approved by The Harvard Medical Area Standing Committee on Animals.

Cell cultures

Split-thickness skin grafts were washed once in 70% ethanol and three times in sterile phosphate-buffered saline (PBS) containing 100 U/mL penicillin, 100 µg/mL streptomycin, 10 µg/mL gentamicin (Invitrogen, Grand Island, NY), and 0.05 µg/mL amphotericin B (Bristol-Myers Squibb, Princeton, NJ), cut into pieces approximately 2×2 cm, and left in a dispase solution (2 U/mL; Roche, Indianapolis, IN) for 2 hours at 37 °C, after which the dermis was peeled gently from the epidermis. Epidermal sheets were treated with 0.0625% trypsin/EDTA (Invitrogen) for 10 minutes at 37 °C. The trypsin was neutralized by addition of one volume of fetal bovine serum (FBS; Sigma, St. Louis, MO). Following centrifugation at 700 r.p.m. (1000g) for 5 minutes, cells were resuspended in keratinocyte serum-free medium (SFM) (Invitrogen) containing 25 µg/mL bovine pituitary extract, 0.15 ng/mL recombinant EGF, 2% calcium-depleted FBS, 100 U/mL penicillin, 100 µg/mL streptomycin, 0.01 mg/mL gentamycin (Invitrogen), and 0.05 µg/mL amphotericin B (Bristol-Myers Squibb), seeded at a density of 9×10^5 keratinocytes per collagen I-coated 100-mm dish, and incubated in a CO₂ incubator (Model 2250; VWR, West Chester, PA) at 37 °C in a humidified atmosphere with 5% CO₂. The porcine keratinocyte cell line 4K3 was used as the source of AKC,¹⁵ cultured in SFM, and subcultured at 80% confluence.

Transfection procedure

Keratinocytes at passage 3 were seeded at a density of 1×10^6 cells/100 mm collagen I-coated cell culture dish 24 hours before transfection. Transfection was performed with Lipofectin (Invitrogen) at a ratio of 1 µg DNA:4 µL Lipofectin. Each transfection was performed with either 5 µg of pCEP-hEGF plasmid or 5 µg pCEP-LacZ plasmid in a final volume of 1 mL of the transfection reagent.

pCEP-hEGF is an episomal replicating plasmid that encodes the hEGF gene under the control of human cytomegalovirus (hCMV) major immediate-early promoter.

Five micrograms of DNA and 20 µL of Lipofectin were each incubated in 500 µL serum- and antibiotic-free keratinocyte basic medium (KBM, Clonetics/Cambrex, Rockland, MA) for 45 minutes. The DNA solution was added in drops to the Lipofectin solution, incubated for another 15 minutes, and added to the cells. After 5 hours of incubation at 37 °C, the transfection medium was replaced by SFM (GIBCO/Invitrogen). Cells were incubated for another 60–66 hours before transplantation. To determine hEGF expression, the cell supernatant was collected daily, transferred on ice, and stored at –80 °C until assayed.

X-gal staining

Forty-eight hours after transfection, cells transfected with the LacZ-containing plasmid were washed twice with 1× PBS and fixed for 20 minutes with 0.25% glutaraldehyde. After washing with 1× PBS, cells were treated with 0.2% Triton×100 for 20 minutes, washed again with 1× PBS, and stained for 3–24 hours with 0.5 mg/mL X-Gal substrate (Fisher Scientific, Suwanee, GA) in an X-Gal staining solution. Effectively transfected cells stained blue.

Experimental groups in the animal model

Three different sets of experiments were performed on 97 FTWs wounds.

In the first set of experiments, 29 FTWs measuring 1.5×1.5 cm were created on the dorsum of two 4-month-old Yorkshire pigs. Wounds were transplanted with 5×10^5 of either allogenic ($n=10$) or autogenic ($n=10$) keratinocytes as a single-cell suspension. As a control, a group of wounds were treated with saline only ($n=9$). Wound biopsies were performed on day 8.

In the second experiment, we investigated whether the rejection of allogenic cells would cause a breakdown of the wound and result in epithelial defects or clinical blister formation. Thirty-two FTWs of 1.5×1.5 cm were created on the back of two 4-month-old Yorkshire pigs. Wounds were treated with either 5×10^5 AKCs ($n=16$) or saline ($n=16$). Wound biopsies were performed on postoperative days 8, 11, 14, 21, 28, and 35. Digital photography of individual wounds was used to assess clinical features such as color, skin elasticity, hair growth, blister formation, and desiccation.

The third set of experiments aimed at investigating the use of AKC as gene-transfer vehicles for growth factors into the wound environment and their influence on wound healing. Thirty-six FTWs 1.5×1.5 cm in size were created on the dorsum of two 4-month-old Yorkshire pigs. Wounds were treated with 3×10^5 hEGF-expressing AKC ($n=9$), 3×10^5 untransfected AKCs ($n=12$), or saline as control ($n=15$). Wound biopsy specimens were taken at day 9 after the operation.

To monitor the viability of transplanted keratinocytes in vitro, the same amount of keratinocytes as transplanted into FTWs was seeded into 35-mm dishes. Cells were monitored for 3–5 days in vitro and medium from transfected cells was collected to determine the levels of hEGF-expression after subcultivation.

Full-thickness wound preparation in the animal model

Once the third passage keratinocyte cultures reached a confluence of 70–80%, the first operation (day 0) was performed in the operation theater under general anesthesia as mentioned above. After cell count, using the trypan blue exclusion test, the cells were divided into individual 2 cc syringes in serum- and antibiotic-free KBM (one per wound) and transferred to the operation theater on ice.

Simultaneously, a second team anesthetized the pig. After anesthesia, waxing, and skin preparation (cf. supra), the pig's dorsum was prepped and draped. Square wounds measuring 1.5×1.5 cm were outlined with a surgical marker and template, and wound edges were retraced with a

tattoo marker (Special Electric Tattoo Marker, Huck Spaulding Enterprises Inc., Voorheesville, NY), allowing planimetry of wound size and calculation of amount of wound contraction every third day.

FTWs were created with a # 11 blade at the inner margin of the tattoo mark to a depth of 1 cm, comprising a full-thickness skin layer down to the fascial plane. Following hemostasis with gentle bipolar coagulation, a thin layer of medical adhesive glue (Hollister, Libertyville, IL) was applied to the skin surrounding the wound and self-adhesive transparent vinyl chambers (TMED, Columbia, TN) were placed over each wound.

We injected the cell suspension cultures into each wound via the self-sealing injection pad incorporated into the chambers. Cells were allowed to settle for 2 hours, during which the pig was kept under anesthesia. At the end of the procedure, 1 mL of normal saline (NS) solution containing 100 U/mL penicillin and 100 µg/mL streptomycin was added to each wound. After recovering from the anesthesia, pigs were penned separately in custom-made, smooth-sided stainless-steel cages. Pigs received 0.03 mg/kg BW buprenorphine IM every 12 hours as analgesia for 1 week following surgery.

Postoperative follow-up

Every 20–24 hours postsurgery, we collected wound fluids until the experiment was terminated. Pigs were premedicated in the sling and inhalation anesthesia was performed via the rubber self-sealing snout mask as mentioned above. During the intervention, pigs received 1.5–2.0% isoflurane and 4 L O₂. Pulse oximetry, heart rate, and rectal temperature were also monitored throughout these short procedures. Where leaking, new chambers were applied and 1.5 mL of NS solution containing 100 U/mL penicillin and 100 µg/mL streptomycin was added to each wound. Wound fluid from each experimental group was pooled, transported on ice, and stored at –80 °C. Wounds were examined daily for signs of infection, such as redness and heat around the wound edges, putrid or cloudy wound fluid, elevated body temperature, or other illnesses. Every third day wound, surface linings were traced for scanning and measurement by planimetry.

On the last day of wound collection, pigs were euthanized after induction with isoflurane and oxygen, by an IV injection of 20 mg/kg BW pentobarbital through a peripheral vein. Half-centimeter wide full-thickness skin biopsies were harvested from each wound and placed in 4% formalin solution and sent to the Pathology Laboratory at the Brigham & Women's Hospital for routine histological processing and hematoxylin & eosin (H & E) staining. We discarded all wound sections that showed disrupted epithelial or dermal layers after histological processing.

Analysis of wound healing

Each H & E-stained biopsy slide was scanned (Epson Perfection 636 U with slide attachment; Epson America Inc., Long Beach, CA) into a computerized image (jpeg format) and analyzed with Paint Shop Pro (v. 7.0, Jasc Software, Eden Prairie, MN), allowing measurement of wound length, epithelial tongues, and keratinocyte islands. The lateral margins of the wounds were histologically

detectable by the tattoo mark. Starting at the lateral margin, the length of the epithelial tongues covering the wound surface was measured. The extent of reepithelialization was determined by dividing the sum of the length of epithelial tongues by the total length of the wound times 100 and expressed as a percentage with the microscopic view as a parallel control.

The degree of inflammatory infiltrate in the granulation tissue was scored on a 0–4 (max) scale by the histologist. They focused on granulomatous and mixed lymphocytic cells.

To measure wound contraction, planimetric measures of each wound were scanned into 24-bit bitmap computer images (Epson). Scion Image software (Scion Corporation, Frederick, MD) was used to measure the area of each wound tracing and a contraction percentage was calculated for each wound on each day, with day 0 as a reference.

Analysis of hEGF

We determined hEGF expression by an hEGF-specific enzyme-linked immunosorbent assay (ELISA) in the cell supernatant of keratinocyte cultures in vitro, as well as in the daily collected wound fluids in the animal model.

Anti-hEGF monoclonal Ab (R&D, Minneapolis, MN), anti-hEGF polyclonal Antibody (Santa-Cruz Biotechnology, Santa Cruz, CA), and an HRP-goat-anti-rabbit polyclonal antibody were used as primary, secondary, and tertiary antibodies, respectively. Results were evaluated by a V Max Kinetic Microplate Reader (Molecular Devices, Sunnyvale, CA) at 450 nm with SoftMax Pro Software (v. 4.0). The results were averaged for each group and compared graphically.

Statistical analysis

To determine the significance of hEGF expression, reepithelialization, and wound contraction, variances within the data were analyzed with the *F* test for variance. Based on these results, the Student's *t* test for equal or unequal variance was used to determine the significance between the different treatment groups. All tests were two-sided, and a *p*-value of 0.05 or less was considered to be statistically significant.

RESULTS

Influence of AKC on Wound healing of Full-Thickness Wounds

In the first experiment, biopsies were taken on postoperative day 8. We measured a mean reepithelialization percentage (MRE%) of 41.7% in wounds treated with AKCs ($n=7$), 42.2% in wounds treated with autogenic keratinocytes ($n=7$), and 41.1% in wounds treated with a mixture of AKC and autogenic cells ($n=7$). Saline-treated controls ($n=7$) had an MRE% of 31% and dry-treated wounds had an MRE of 18.1% (Figure 1A). There was no statistical difference in MRE% between wounds treated with AKCs, autogenic, or mixed AKC/autogenic keratinocytes. However, MRE% in the AKC, autogenic, and mixed keratinocyte-treated wounds was significantly higher when

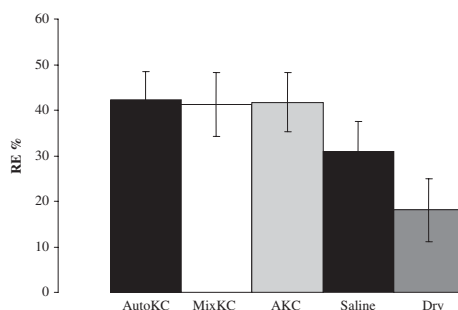


Figure 1. Mean reepithelialization percentages of full-thickness skin wounds treated with suspensions of AKC, autogenic keratinocytes, mixed AKC/autogenic cells with saline, and dry-treated wounds as controls. Biopsies were taken at day 8. X-axis, groups; Y-axis, reepithelialization percentage. Significantly higher rates of reepithelialization were measured in wounds treated with cell suspensions than in saline-treated wounds. No significant difference was noted in reepithelialization percentage between wounds treated with AKC, Autologous KC, or mixed AKC/AutoKC. Auto KC = 5×10^5 autogenic keratinocyte cell suspensions; AKC = 5×10^5 allogenic keratinocyte cell suspensions; MixKC, mixed cell suspensions of 2.5×10^5 Auto KC and 2.5×10^5 AKC.

compared with saline control wounds ($p < 0.02$), whereas saline-treated wounds had a significantly faster MRE% than dry-treated wounds ($p < 0.02$).

Histological examination of wound biopsies revealed an inflammatory infiltrate in the granulation tissue. The inflammatory response in wounds treated with AKC exhibited the same intensity in H & E-stained sections as in the saline control wounds. Multiple foci with granulomatous and mixed lymphocytic cells were observed.

Keratinocyte cell clusters were visible throughout the granulation tissue in all cell-treated wounds.

Planimetry of wound surfaces showed no significantly different contraction rates between any of the cell vs. saline-treated wounds ($p > 0.05$), while wounds treated in a wet wound environment (all cell-treated and saline-treated groups) showed a significantly lower contraction ratio than the dry-treated wounds ($p < 0.02$).

Long-term assessment of wounds treated with AKC

Reepithelialization

In the second set of experiments, wound biopsies were taken at different time points up to postoperative day 35 to determine the long-term effects of AKC on the stability of FTWs. On postoperative day 8, when all FTW at the midline of the dorsum were compared, wounds treated with AKC ($n=3$) reepithelialized 100% and saline control wounds ($n=3$) reepithelialized at a rate of 66.6% (Figure 2A). The difference between the groups was statistically significant ($p < 0.02$). On days 11 ($n=4$), 14 ($n=2$), 21

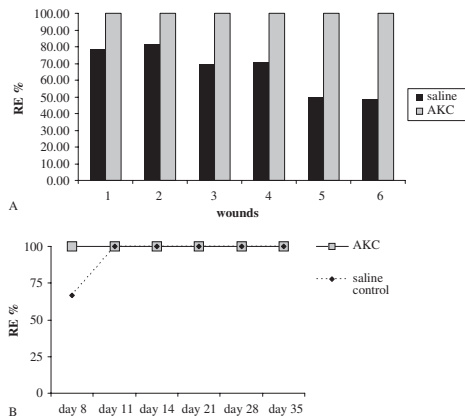


Figure 2. (A) Reepithelialization percentages were measured in wound biopsies taken from wounds that were treated with 5×10^5 allogenic KC or saline in a mirror image pattern aside the midline of the dorsum for optimal comparison. All wounds treated with AKC had a 100% epithelial cover at biopsy day 8. The mean healing rate for saline-treated wounds was 66%. (B) The remaining wounds were biopsied at later time points to determine the long-term clinical and histological stability of the newly formed epidermis. No epithelial breakdown or blister formation was noted by day 35 in either group. AKC, allogenic keratinocyte cell suspensions, RE%, percentage of reepithelialization.

($n=3$), 28 ($n=2$), and 35 ($n=2$), wounds of both groups were 100% reepithelialized (Figure 4A).

When the thickness of the epidermal layer and the size of the rete ridges were evaluated, no significant differences were noted between the allogenic vs. autogenic cell suspension-treated wounds. Histology showed an increased presence of inflammatory cells throughout the first 21 days of the experiment in all wound sections. There was no significant difference in the evaluation of the degree of inflammation by the histologist when AKC- or saline-treated wounds were compared at days 21 and 35. The wounds treated with AKC did not reveal clinical signs of sustained inflammation or epithelial defects (Figure 2B).

Wound contraction

Wound contraction in wounds treated with AKCs was 44.1% on day 8 ($n=16$) and 61.5% on day 10 ($n=13$), as compared with 42.2% ($n=16$) and 54.9% ($n=13$) in saline control wounds, respectively. On day 21, wound contraction was 65.6% in AKC-treated wounds and decreased to 61.8% on day 28 and 58.7% ($n=4$) on day 35 ($n=2$). Saline control wounds contracted 57.7% on day 21 ($n=7$), 60.7% on day 28 ($n=4$), and 71.5% on day 35 ($n=2$). Differences in wound contraction between the groups were never statistically significant.

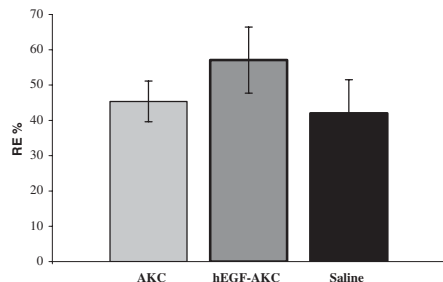


Figure 3. Full-thickness skin wounds measuring 1.5×1.5 cm were created on the back of two 4-month-old Yorkshire pigs before transplantation of 3×10^5 hEGF transfected or 3×10^5 untransfected AKC in single-cell suspension or saline controls. Reepithelialization percentages were measured on postoperative day 8. Reepithelialization was significantly greater in wounds treated with hEGF-transfected AKCs, than in wounds treated with untransfected AKC or saline. No significant difference in reepithelialization rates was found on day 8 when 3×10^5 AKC were used vs. saline. AKC, allogenic keratinocyte; hEGF, human epidermal growth factor.

Influence of hEGF-transfected AKC on the healing time of full-thickness wounds

Reepithelialization

The third set of experiments determined whether AKCs could function as gene transfer vehicles to deliver growth factors into the wound environment and further enhance wound healing. To emphasize the effect of hEGF-transfected keratinocytes on wound healing, we reduced the number of transplanted keratinocytes to 3×10^5 cells/wound. On postoperative day 8, wounds treated with AKC ($n=12$) had a reepithelialization percentage (RE%) of 45.38% and wounds treated with transiently transfected-hEGF expressing AKCs ($n=9$) had an RE% of 56.96%. We found an RE% for the saline-treated control wounds ($n=15$) of 42.01% (Figure 3). The differences in RE% between the AKCs and hEGF-expressing AKCs ($p < 0.02$), and between saline control and hEGF-expressing AKCs ($p < 0.02$) were statistically significant (Figure 4B and C). No difference in RE% could be detected between wounds treated with untransfected AKCs and saline-treated control wounds ($p > 0.05$) when 3×10^5 cells were used per wound in contrast to former experiments where 5×10^5 cells were seeded per wound.

In vitro expression of EGF

To determine successful transfection in vitro, one dish of keratinocytes was transfected with LacZ-containing plasmid under conditions similar to hEGF transfection. Forty-eight hours after transfection, cells were stained for LacZ expression. Microscopic cell count per field showed a 15–25% transfection rate.

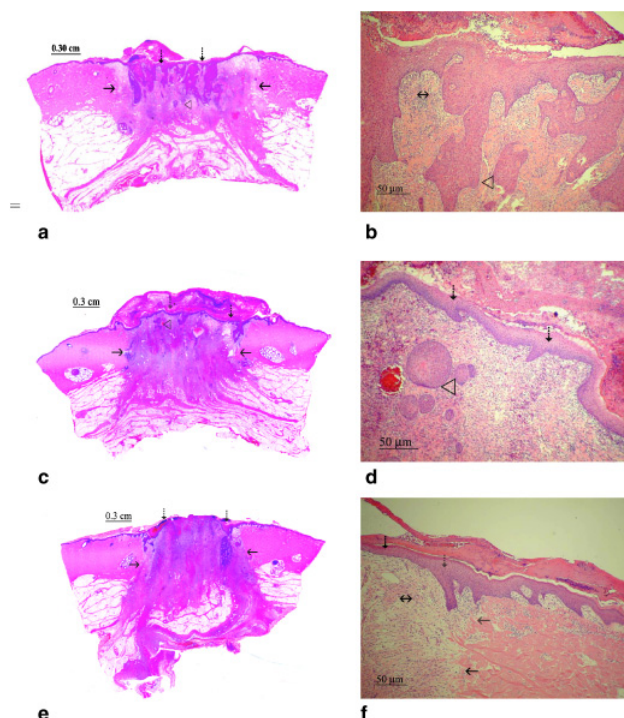


Figure 4. (A–F) H & E-stained histological sections of FTW. (A, B) FTW treated with 5×10^5 EGF-expressing AKC, 8 days after wounding. The fully restored epithelial layer stains purple (↓) on top of the granulation tissue, which is filled with epidermal cysts, which will migrate further and incorporate into the epithelium (◁). Arrows indicate the transition zone between the neodermis (wounded area) and the intact nonwounded dermis (↔). Multiple granulomatous and mixed lymphocytic cells are observed in the inflammatory infiltrate in the neodermis (↔). (C, D) FTW treated with 3×10^5 AKC, 8 days after wounding. The fully restored epithelial layer stains purple (↓) on top of the granulation tissue and migrated underneath a thick scab attached on the wound. Only a few epidermal cysts are visible in the granulation tissue (◁). Arrows indicate the transition zone between the neodermis (wounded area) and the intact nonwounded dermis (↔). (E, F) FTW treated with plain saline, 8 days after wounding. The neoeplithelium expands as epithelial tongues (↓) over the granulation tissue. There are no epidermal cysts in the granulation tissue. Multiple granulomatous and mixed lymphocytic cells are observed in the inflammatory infiltrate in the neodermis (↔). Arrows indicate the transition zone between the neodermis (wounded area) and intact nonwounded dermis (↔). AKC, allogenic keratinocyte; EGF, epidermal growth factor; FTW, full-thickness skin wound; H & E, hematoxylin & eosin.

To determine the ability of transfected keratinocytes to express hEGF, medium from hEGF-transfected and -untransfected keratinocytes was collected 24 hours post-transfection up to postoperative day 5. The levels of hEGF expression were 1,678 ng/mL 24 hours after transfection and 902 ng/mL 48 hours after transfection.

In vivo expression of hEGF (Figure 5)

In the first experiment, hEGF levels in wounds transplanted with hEGF-transfected keratinocytes revealed 920.8 pg/mL hEGF on day 1 and 624.5 pg/mL on day 2. The levels of hEGF decreased to 94.2 pg/mL on day 3, 68.9 pg/mL on day 4, and 36.9 pg/mL on day 5, and ranged between 12.7 and 6.5 pg/mL on days 6–9. In wounds treated with untransfected AKC or saline, hEGF was between 6.6 and 0.98 pg/mL. In the second experiment, hEGF expression was lower: 188 pg/mL on day 1, 88 pg/mL on day 2, and 106 pg/mL on day 3. Expression decreased to 56 pg/mL by day 4 and 18 pg/mL by day 5. No expression was detectable after day 5. Control wounds did not reveal any expression of hEGF. Besides the lower peak expression, the ratio of hEGF expression in wounds treated with hEGF-transfected AKCs

vs. untransfected AKCs and saline controls was similar in both experiments.

DISCUSSION

It is generally accepted that allografts (homografts) are efficient biodressings that temporarily cover the floor of chronic wounds and acute burns and induce granulation and vascularization.^{16–19} It has also been shown that such allografts are rejected from wounds after 10–14 days. Several authors have reported that AKCs reject at a slower rate than allogenic skin grafts. Aubock et al.²⁰ investigated the properties of allogenic and autogenic cultured epidermis and concluded that a Langerhans-cell free allogenic cultured epidermis does not survive permanently, but the rejection rate was delayed by 4–5 days, compared with allografted skin grafts.

It was postulated that absence of the major histocompatibility complex (MHC) proteins could lead to a diminished host response against allografts.^{21,22} Dierckx et al.,²³ however, showed that both MHC-I and MHC-II knockout allografts still underwent rejection, which was considered to be the result of the existence of "Minor Antigens." Hunt et al.²⁴ reported that allogenic cultured keratinocytes

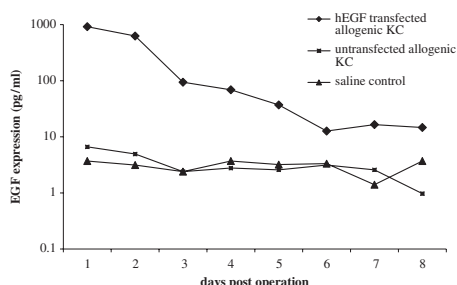


Figure 5. In vivo expression of human epidermal growth factor (EGF) in wound fluid retrieved daily from the wound chambers and determined by ELISA. EGF expression: 920 pg/mL hEGF on day 1 and 624.5 pg/mL on day 2. In control wounds, EGF expression reached 6.6 pg/mL on day 1. Legend: EGF-Allo, transfected AKC expressing EGF; Allo, AKC; Auto, autogenic keratinocytes; saline, saline-treated full-thickness wounds.

grown from MHC-II knock-out mice created fewer immunogenic cells. They concluded that host priming, rather than Target Antigen Type, determines the rejection rate in their mouse model. Using "xenogeneic-syngeneic" mixed epithelial sheets, a histologically well-organized epidermis could be grown, presenting basal and suprabasal cell layers and an active dermo-epidermal junction. The xenogeneic cells were "selectively" eliminated without rejection of the entire "mixed" implant, in contrast to purely allogenic cells, which had a 100% rejection rate. Immunofluorescence staining showed that syngeneic cells gradually replaced the AKC.^{25,26}

We were able to demonstrate that AKC covered the wound surface from within the wound and promoted reepithelialization compared with saline controls. After completion of wound coverage, neither an increased inflammatory reaction, or epithelial thinning, nor wound breakdown could be detected in wounds over a period of 35 days posttransplantation. Based on these findings and the knowledge that AKC are gradually replaced by autogenic keratinocytes, it appears that transplantation of AKC not only provides accelerated wound coverage but also allows for ingrowth of autogenic keratinocytes. Therefore, transplantation of AKC in a single-cell suspension can reduce the need for retransplantation and therefore reduce the cost of wound treatment in the wound-healing model used in this study. Moreover, to further eliminate the impact of rejection of allogenic cells in larger wound settings, a mixture of allogenic and autogenic keratinocytes can be used for wound treatment. This strategy reduces the amount of autogenic keratinocytes required for wound coverage while offering accelerated healing of large wounds.

Gene therapy justifiably gains interest as a treatment modality for wound repair and tissue regeneration. In vivo gene transfer of growth factor-encoding genes into the wound environment by a "gene gun" or microseeding may lead to a high expression of growth factors in the wound^{8,27} but does not add a supplementary cell substrate

to the defect. In large full-thickness skin wounds such as extensive third-degree burns or large chronic wounds, this lack of substrate might be critical to repair. Ex vivo gene transfer of transgene-expressing cells brings both cell substrate and growth-promoting genes into wounds, which might lead to more effective treatment than either therapy alone.

Stable gene expression remains a difficult issue in gene transfer protocols. Creating stable autogenic cell lines that have been selected and cultivated to express a particular gene represents an elaborate and time-consuming process.²⁸

In a clinical context, cell cultures need to be readily available for treatment, such as in an extensively burned patient, where rapid debridement of the burn scar must be immediately followed by coverage of the defect.¹⁶ Stored allogenic cell cultures can be thawed, grown, transfected, and subsequently used for coverage after 7–10 days.^{17,18}

We found that AKCs transiently transfected with the hEGF gene expressed high levels of EGF in wound fluids over a period of 5–6 days. Wounds treated with these transfected cells showed a significantly greater reepithelialization rate than untransfected AKCs and saline-treated control wounds.

AKCs are effective carriers for gene transfer of growth factors to the wound environment. Given the fact that keratinocytes do not express EGF, the transient transfection of keratinocytes with this growth factor resulted in a prolonged expression and acceleration of wound healing in these experiments.

CONCLUSIONS

Our results show that the transplantation of EGF-expressing AKC as a single-cell suspension accelerates wound healing in the model used in this study. Rejection takes place gradually and does not lead to epithelial thinning or defects. Furthermore, AKC, as single-cell suspensions, can serve as efficient gene-transfer vehicles to the wound environment, resulting in prolonged transient hEGF expression and further enhancement of wound healing.

ACKNOWLEDGMENTS

This work was supported by Public Health Grants RO1 GM51449 from the National Institutes of Health. Dr. JJ Vranckx was supported by grants from the Fulbright Commission Belgium-USA and a Francqui grant of the Belgian American Educational Foundation. Dr. D. Hoeller was supported by START grant 694019 from the medical faculty of the RWTH Aachen, Germany.

REFERENCES

1. Bennett N, Schultz P. Growth factors and wound healing: biochemical properties of growth factors and their receptors. *Am J Surg* 1993; 165: 728–37.
2. Singer A, Clark RA. Mechanisms of disease: cutaneous wound healing. *N Engl J Med* 1999; 341: 738–46.
3. Robson MC, Mustoe TA, Hunt TK. The future of recombinant growth factors in wound healing. *Am J Surg* 1998; 176: 80–2S.

4. Steed DL. Modifying the wound healing response with exogenous growth factors. *Clinics in Plast Surg* 1998; 25: 397–405.
5. Fu X, Li X, Cheng B, Chen W, Sheng Z. Engineered growth factors and cutaneous wound healing: success and possible questions in the past ten years. *Wound Repair Regen* 2005; 13: 122–30.
6. Breuing K, Eriksson E, Liu OY, Miller DR. Healing of partial thickness porcine skin wounds in a liquid environment. *J Surg Res* 1992; 52: 50–8.
7. Eriksson E, Vranckx JJ. Wet wound healing: from laboratory to patient to Gene therapy. *Am J Surg* 2004; 188: 36–41.
8. Vranckx JJ, Yao F, Eriksson E. Gene transfer of growth factors for wound repair. In: Rovee D, Maibach H, editors. *The epidermis in wound healing*. Boca Raton, FL, USA: CRC Press, 2004: 265–83.
9. Andree C, Swain WF, Page C, Macklin MD, Slama J, Eriksson E. In vivo transfer and expression of a human epidermal growth factor gene accelerates wound repair. *Proc Natl Acad Sci USA* 1994; 91: 1288–92.
10. Vranckx JJ, Yao F, Petrie N, Augustinova H, Hoeller D, Visovatti S, Slama J, Eriksson E. In vivo gene delivery of Ad-VEGF121 to full-thickness wounds in aged pigs results in high levels of VEGF expression but not in accelerated healing. *Wound Repair Regen* 2005; 13: 51–60.
11. Brown GL, Nanney LB, Griffen J, Cramer AB, Yancey JM, Curtsinger LJ, Holtzin L, Schultz GS, Jurkiewicz MJ, Lynch JB. Enhancement of wound healing by topical treatment with epidermal growth factor. *N Engl J Med* 1989; 321: 76–80.
12. Falanga V, Eaglestein WH, Bucalo B, Katz MH, Harris B, Carson P. Topical use of human recombinant epidermal growth factor in venous ulcers. *J Dermatol Surg Oncol* 1992; 18: 604–6.
13. Rumalla VK, Borah GL. Cytokines, growth factors and plastic surgery. *Plast Reconstr Surg* 2001; 108: 719–24.
14. Martin P. Wound healing—aiming for perfect skin regeneration. *Science* 1997; 276: 75–81.
15. Svensjo T, Yao F, Pomahac B, Eriksson E. Autogenic keratinocyte suspensions accelerate epidermal wound healing in pigs. *J Surg Res* 2001; 99: 211–21.
16. Hunt JL, Purdue GF, Pownell P, Rohrich R. Burns: acute burns, burn surgery and post-burn reconstruction. *Select Read Plast Surg* 1997; 8: 1–37.
17. Cuono C, Langdon R, McGuire J. Use of cultured epidermal autografts and dermal allografts as skin replacement after burn injury. *Lancet* 1986; 1: 1123–4.
18. De Luca M, Albanese E, Bondanza S, Megna M, Ugozzoli L, Molina F, Cancedda R, Santi PL, Bormioli M, Stella M, et al. Multicentre experience in the treatment of burns with autogenic and allogenic cultured epithelium, fresh or preserved in a frozen state. *Burns* 1989; 15: 303–9.
19. Hefton JM, Madden MR, Finkelstein JL, Shires GT. Grafting of burn patients with allografts of cultured epidermal cells. *Lancet* 1983; 2: 428–30.
20. Aubock J, Irschick E, Romani N, Kompatscher P, Hopfl R, Herold M, Schuler G, Fritsch P. Rejection, after a slightly prolonged survival time, of Langerhans cell-free allogenic cultured epidermis used for wound coverage in humans. *Transplantation* 1988; 45: 730–7.
21. Rosenberg AS. Cellular basis of skin allograft rejection: an *in vivo* model of immune-mediated tissue destruction. *Ann Rev Immunol* 1992; 10: 333–7.
22. Morhenn VB, Benike CJ, Cox AJ, Charron DJ, Engleman EG. Cultured human epidermal cells do not synthesize HLA-DR. *J Invest Dermatol* 1982; 78: 32–6.
23. Dierch A, Chan SH, Benoist C, Mathis D. Graft rejection by T cells not restricted by conventional major histocompatibility complex molecules. *Eur J Immunol* 1993; 23: 2725–8.
24. Hunt JP, Hunter CT, Brownstein M, Hultman C, deSerres S, Bracey L, Frelinger J, Meyer A. Host priming, not target antigen type, decides rejection rate in mice primed with MHC-II “knock-out” cultured keratinocytes. *J Surg Research* 1998; 76: 32–6.
25. Thivolet J, Faure M, Demidem A, Mauduit G. Long-term survival and immunological tolerance of human epidermal allografts produced in culture. *Transplantation* 1985; 42: 274–80.
26. Rouabhia M. Permanent skin replacement using chimeric cultured sheets comprising xenogeneic and syngeneic keratinocytes. *Transplantation* 1996; 61: 1290–300.
27. Eriksson E, Yao F, Svensjo T, Winkler T, Slama J, Macklin M, Andree C, McGregor M, Hinshaw V, Swain W. In vivo gene transfer to skin by microseeding. *J Surg Res* 1998; 78: 85–91.
28. Vogt PM, Thompson S, Andree C, Liu P, Breuing K, Hatzis D, Mulligan RC, Eriksson E. Genetically modified keratinocytes transplanted to wounds reconstitute the epidermis. *Proc Natl Acad Sci USA* 1994; 91: 9307–11.

Paper V

Cell Suspensions of autologous Keratinocytes Transfected with PCEp4-EGF Accelerate the Healing of Full Thickness Skin Wounds in a Diabetic Porcine Model and Serve as Efficient Vectors for Ex-Vivo Gene Transfer

Velander.P^{1,2}, MRCSEd; Theopold.C¹, MRCSEd; Bleiziffer.O¹, MD; Svensson.H², MD PhD; Yao. F¹, PhD; Eriksson.E¹, MD PhD

Affiliation:

1.Laboratory of Tissue Repair and Gene Transfer
Harvard Medical School
Brigham and Woman's Hospital
Division of Plastic Surgery
75 Francis Street
Boston, MA 02115

2.Department of Clinical Science
Division of Plastic Surgery
Lund University
Malmö, Sweden

Subject category:

Wound Healing/Plastic Surgery

Address for manuscript correspondence:

Elof Eriksson, MD, PhD
Chief, Division of Plastic Surge
Brigham and Women's Hospital
75 Francis Street
Boston, MA 02115
tel: 617 732 7409

Abstract

Diabetes is one of the leading causes of chronic wounds in the U.S.A. Its incidence is increasing dramatically due to obesity and old age. Healing of these impaired wounds often represent a difficult challenge with the currently available treatment. We recently established a delayed wound-healing model in the Yorkshire pig rendered diabetic by administration of Streptozotocin. This study evaluated epidermal regeneration in fluid treated skin wounds treated with suspensions of cultured autologous keratinocytes transfected with PCEp4-EGF plasmid.

Diabetes was induced by injecting Streptozotocin into a three months old female Yorkshire pig. Keratinocytes were harvested from the neck of the pig and transfected at passage 2 with a PCEp4-EGF plasmid using lipofectin. On the third day post-transfection, full thickness wounds were created on the dorsum and dressed with polyvinyl chambers to keep the wounds wet and to allow for wound fluid monitoring. Suspensions of untransfected keratinocytes (n=7), PCEp4-EGF transfected keratinocytes (n=7) or normal saline (n=6) were injected into the wounds. Serum glucose and wound fluid glucose concentrations were monitored daily. Wound contraction was monitored and biopsies taken on day 12. The expression of EGF was measured from the wound fluid using Elisa. The serum glucose was significantly increased for the duration of the experiment (>350 mg/dl). Wound fluid glucose closely followed serum glucose concentration. Transplantation of EGF transfected keratinocytes significantly accelerated re-epithelialization in the diabetic pig. There was no statistical difference between the wound contraction rates in any of the treated groups. The expression of EGF was greatly enhanced in the transfected keratinocytes treated group and was prolonged for the duration of the experiment.

This study shows that wound healing is delayed in the streptozotocin-induced diabetic pig model. A single-cell suspension of keratinocytes transfected with PCEp4-EGF not only survives in the hyperglycemic wound environment but also expresses EGF locally over a prolonged period of time which stimulates the formation of a neo-epithelium

Key words: Wound healing, diabetes, streptozotocin, re-epithelialization, gene transfer, EGF, Growth factor

Introduction

Diabetes Mellitus is a chronic disorder of glucose homeostasis, affecting about 6% of the population in the United States. The incidence is increasing dramatically because of a rise in obesity and old age. 25% of people with diabetes will suffer a wound problem in their lifetime, leading to pain, handicap and psychological stress (American diabetes association). Healing of these impaired wounds often represent a difficult challenge with the currently available treatment. In an effort to develop an effective therapy to overcome the impaired healing associated with diabetes, various diabetic animal models have been developed in the past 20 years. Streptozotocin induced diabetic rats and db/db mice have been, and are being extensively used, in many laboratories to investigate diabetic wound healing, such as the effect of different growth factor therapies. Since porcine skin is physiologically very close to human skin, impaired healing in a diabetic pig would represent a suitable model to study diabetic wound healing. Although streptozotocin induced diabetic pigs have been established for the study of diabetes (1), especially islet cells transplantation, it had yet to be adapted to the field of wound healing research. Our laboratory has previously demonstrated in the healthy pig, the beneficial effect of a wet wound environment compared to a dry wounds (2) and that a cell suspension not only survive in this liquid environment but also contribute to epidermal healing (3). In this study, we investigate the healing of full thickness wounds treated with a local overexpression of hEGF in streptozotocin induced diabetic pigs and demonstrate a significant enhancement in epidermal healing.

Materials and Methods

Animals

Female pigs (Parson's Farm, MA) weighing 60 kg at arrival were allowed to acclimatize for one week prior to the initiation of any experiment. They

were kept in smooth walled stainless steel cages to minimize wound trauma and disruption of applied wound chamber. The animal protocol was approved by the Harvard Medical Area Standing Committee on animals and all operative procedures took place in a specialized operation room under sterile conditions. Anaesthesia was induced as per our laboratory protocol (27). Intramuscular injections of Buprenorphine (0.001mg/kg) and Metochlopramide (0.15mg/kg) were used as post-operative analgesia and anti-emetic respectively. Pigs were euthanised by intravenous injection of Euthasol®.

Induction of Diabetes

Vomiting and diarrhea has been associated with intravenous injection of streptozotocin (4). To minimize this, pigs were fasted for 12 hours prior to induction. Under general anaesthesia, a 20G intravenous catheter was inserted into an ear vein and Streptozotocin (Zanosar®, Pharmacia) was administered through the catheter at a dose of 150mg/kg body weight over a period of one minute. The pigs were continually observed for the first three hours and then hourly for the following 33 hours. Buprenorphine and metochlopramide were administered IM every 12 hours for the first two days. Serum glucose was taken on an hourly basis for the first 36 hours and then twice daily for the remainder of the experiment. The pigs were treated with a subcutaneous injection of short acting insulin (Normulin®) and long acting insulin zinc suspension (Humulin®).

Harvesting of split skin grafts

On the day of induction, the hair from the nape of the neck was clipped and the skin was prepared with povidone iodine solution. Two small strips of 0.38mm split skin grafts measuring 2x8 cm were harvested with an electric dermatome (Padgett instruments). The resulting partial thickness wounds were dressed with vaseline gauze and sterile dressing.

Cell culture

Autologous keratinocytes were isolated from these split thickness skin grafts. The grafts were dipped once in 70% ethanol and left in sterile phosphate buffered saline for ten minutes. The last step was repeated twice. The skin grafts were then cut into 1x1cm squares and left in 2U/ml Dispase solution at 37°C for one hour at which time the dermis could easily be peeled off the epidermis. Five ml 0.0625% trypsin (Invitrogen, NY) was added to the epidermal sheets and left for three minutes at 37°C. The epidermis/trypsin solution was then passed through a 80 mesh sterile sieve and the trypsin neutralized by addition of Fetal Bovine Serum (Sigma, MO). The resulting solution was centrifuged at 750rpm for 6 minutes at 37°C to pellet the keratinocytes. These were re-suspended in keratinocytes serum free medium (SFM) (Invitrogen, NY) containing added bovine pituitary hormone, epidermal growth factor, calcium depleted fetal bovine serum, calcium dichloride, streptomycin, penicillin, gentamicin and amphotericin. The cells were seeded onto collagen coated dishes at a density of 6×10^5 cells per 100 mm dish. Keratinocytes were sub-cultured at 90% confluence.

Transfection with PCEp4-EGF

Keratinocytes at passage three were seeded at a density of 500,000 cells per 100 mm dish 24 hours prior to transfection. Transfection was performed with lipofectin (Invitrogen, NY) at a ratio of 1 µg DNA for 4 µl Lipofectin.

10 µg of either PCEp4-EGF or Lac-Z plasmid were placed in a total volume of keratinocyte serum free medium and 80 µl of Lipofectin was placed in a similar total volume. Both solution were left for 30-40 minutes at room temperature. The DNA solution was added to the lipofectin solution drop by drop, gently mixed and left at room temperature for 15 minutes before being added to the cells. After 5 hours incubation at 37°C, the transfection medium was replaced with SFM with added components. Medium was collected on a daily basis for quantitative analysis of the EGF expression.

Cells were incubated for 72 hours after transfection prior to transplantation into wounds.

Lac-Z staining and transfection efficiency

48 hours post transfection, the dish transfected with Lac-Z plasmid was washed twice with PBS. The cells were fixed for 30 minutes in of 0.05% Gutraldehyde solution at which time they were washed twice with PBS and stained for 3 hours with 0.5mg/ml X-Gal substrate (FisherScientific). Cells transfected with Lac-Z stained blue. Transfection efficiency was calculated as the percentage of stained cells in the dish.

Wounding and chamber treatment

Nine days post induction of diabetes, the pig's dorsum was waxed (Nair® microwable wax, Church&Dwight, Princeton, NJ) and shaved to improve chamber adherence. Twenty squares measuring 1.5 x 1.5 cm were outlined on the dorsum using a template and a skin marker. The edges of these squares were retraced using a tattoo machine (Special Electric tattoo Marker, Spaulding Enterprises, Voorheesville, NY) to allow for later wound contraction measurements. Following skin preparation with povidone iodine, the skin within the squares was excised using a number 11 blade to create 20 full thickness wounds measuring 1.5x1.5x0.8 cms. Once good haemostasis was achieved, adhesive polyurethane chambers were applied over each wound. Seven chambers were then injected with 200 µl keratinocytes serum free medium (SFM) (Invitrogen, NY) containing 300000 untransfected keratinocytes. Seven chambers were then injected with 200 µl keratinocytes serum free medium (SFM) (Invitrogen, NY) containing 300000 PCEp4-EGF transfected keratinocytes. Six chambers were injected with 200 µl keratinocytes serum free medium (SFM) (Invitrogen, NY). After two hours, the chambers were injected with 2 ml of Normal Saline (0.9% NaCl injection USP, Baxter, with penicillin 100u/ml and streptomycin 100µg/ml). The wound fluid that collected in the chambers was completely aspirated at 24 hours interval with 5 ml syringes

fitted with 20 gauge needles. The wound fluids were chilled on ice prior to being stored at -80°C for later analysis, while the chambers were injected with 2 ml of normal saline (with penicillin/streptomycin).

Wound contraction

Wound contraction was measured using the permanent boundaries left by the tattooed margins and planimetry. The area of the wounds at specific days was measured using Scion image software® (Scion corporation, MD) and the percentage of contraction was calculated using the following formula:

$$(\text{Area at biopsy day}) / (\text{Area on wounding day}) \times 100.$$

Histology

Vertical wound biopsies 2mm wide were taken from the middle of the wounds which included unwounded skin at the sides and subcutaneous tissue at the bottom. Biopsies were collected on day 12 post wounding. Samples were fixed in 4% buffered paraformaldehyde and processed for routine Haematoxylin and Eosin staining.

Re-epithelialization was defined as the area within the tattooed marks that was covered with epithelium. This was calculated by scanning the slides (Epson Perfection 3600, Epson Inc., CA), measuring the epithelial tongues from the computerized image using Paintshop Pro® (Jasc Software 7.0, MN). The percentage re-epithelialization was determined using the formula:

$$(\text{Sum of epithelial tongues}) / (\text{Distance between tattoo marks}) \times 100$$

Growth Factor and Protein measurements

Determination of hEGF levels were measured from the wound fluid using specific enzyme linked immunosorbant assay (Elisa) developed in our laboratory. Results were calculated by using a Vmax kinetic Microplate Reader (Molecular Devices, CA) and Soft Max Pro software.

Statistics

This study included 40 wounds in 2 diabetic pigs divided into three groups:

1. Wounds treated with a suspension of 300,000 untransfected keratinocytes (=14)
2. Wounds treated with a suspension of 300,000 PCEp4-EGF transfected keratinocytes (n=14)
3. Wounds treated with a normal saline solution (n=12)

Values are presented as means +/- STD. Groups were compared with a non-parametrical test and statistical calculations were performed with GraphPad InStat® software. A p-value inferior to 0.05 was considered to indicate statistical significance.

Results

Serum Glucose Levels

All the animals which received streptozotocin survived for the duration of the whole experiment in good general condition. The time course of serum glucose levels is shown in figure 3. Following the injection of Streptozotocin, there is an initial tri-phasic response in the first 30 hours (fig 1a). This comprises an initial Hyperglycaemia lasting 1-5 hours followed by a marked hypoglycaemia lasting 6-22 hours. This is due to insulin released from damaged β -cells. As the released insulin is being consumed, a permanent hyperglycaemic state is achieved (22 hours onwards) (fig 1b)

Wound Fluid Glucose Levels

Our laboratory has previously developed an external polyurethane chamber sealed around the edges of the wound. It allows us to standardize the wound environment, to study the biology of the wound and to gain access to a local route of delivery for potential therapeutic agents. When injecting a liquid inside, such as normal saline or growth medium, the chamber functions as an in-vivo incubator, providing a bridge between in-

vitro methodology and in vivo treatment of the wound. Our laboratory has previously shown a liquid wound environment to promote healing of partial thickness and full thickness wounds in healthy pigs. In this experiment, wound fluid was collected on daily basis and its glucose concentration measured. The wound fluid was then stored at -80°C for later quantitative analysis. Figure 4 shows the correlation between the wound fluid glucose levels and the serum glucose levels over time. The wound fluid glucose levels closely follow the serum glucose until day 6-8 when the wound fluid levels progressively tail down to low levels at day 8.

Re-epithelialization

The hEGF treated group showed a significant enhancement in re-epithelialization (92%) compared to the keratinocyte treated group (72%) and the Normal saline control group (55%). (fig2)

Wound contraction

There was no statistical difference in the rate of wound contraction between the three study groups. (fig.3)

In vivo EGF expression

Wounds that received a suspension of 300000 PCEp4-EGF transfected keratinocytes started expressing EGF from day 1 (1,6 ng/ml) (Fig.4a). After day 2, EGF concentration showed a decrease in expression over time but showed a significantly increased concentration during the whole course of the experiment compared to the control groups (Fig.4b).

Discussion

Normal acute wound healing is a well orchestrated cascade, overlapping the four phases of wound healing: hemostasis, inflammation, proliferation, and remodelling.

The processes involved in diabetic wound healing differs greatly from this. (4-6)

As treatment results of diabetic wounds are discouraging and as the incidence of diabetes is expanding at an alarming rate worldwide (7), further research in the area is recommended.

Several animal models have been developed to simulate diabetic wound healing (8,9). Our laboratory has previously described the decreased healing found in the streptozotocin induced diabetic pig (10) as well as the positive effects on wound healing when transplanting a suspension of keratinocytes or fibroblasts (11,12).

Growth factors are involved in stimulating cellular growth, proliferation and differentiation. They are produced by cells involved in the healing process and are regulated by complex intracellular signalling cascades. In diabetic wounds, the concentration of several growth factors has been shown to be decreased(13-18)

Many attempts at delivering various growth factors into wounds have been done. However, it has proved difficult to achieve high expression in wounds. A suggested explanation is that growth factors degrade rapidly and delivery systems are often ineffective (19).

Hirsch et al demonstrated a high expression of IGF-1 in diabetic porcine wounds when transplanting a suspension of autologous keratinocytes transfected with IGF-1 directly into the wound environment. He also noted improved re-epithelialization in the IGF-1 treated group. (20).

Epidermal growth factor is a determinant factor in wound healing. It is produced by platelets at the wound site. It stimulates epidermal cell growth, differentiation and migration (21,22). EGF binds to an EGF receptor on the cell membrane of fibroblasts, keratinocytes and endothelial cells, initiating a powerful mitogenic activity (23).

EGF levels are severely decreased in diabetic wounds. The EGF receptor is also a target for advanced glycation end products precursors which further decreases activity(24). This leads to impaired fibroblasts and keratinocytes as well as limited angiogenic response. All together preventing normal wound healing.

Vranckx et al demonstrated the beneficial effect of transplanting keratinocytes transfected with EGF in non-diabetic healthy pig wounds (25).

The present study demonstrated a very high level of EGF expression in the wounds treated with a suspension of keratinocytes transfected with PCEp4-EGF. This expression was maintained over several days overcoming the adverse wound environment.

Wounds exposed to high EGF levels also showed a significant increase in re-epithelializa-

tion on day 12 compared to the control groups. (92% vs 72% and 55%).

We demonstrated that a constant overexpression of EGF in the wound environment cancels out the severe decrease normally seen in a diabetic wound environment and significantly enhance epidermal healing.

Further research is needed to improve the delivery process and to control the expression of EGF. A viral vector with a TET switch could be an option.

Figures

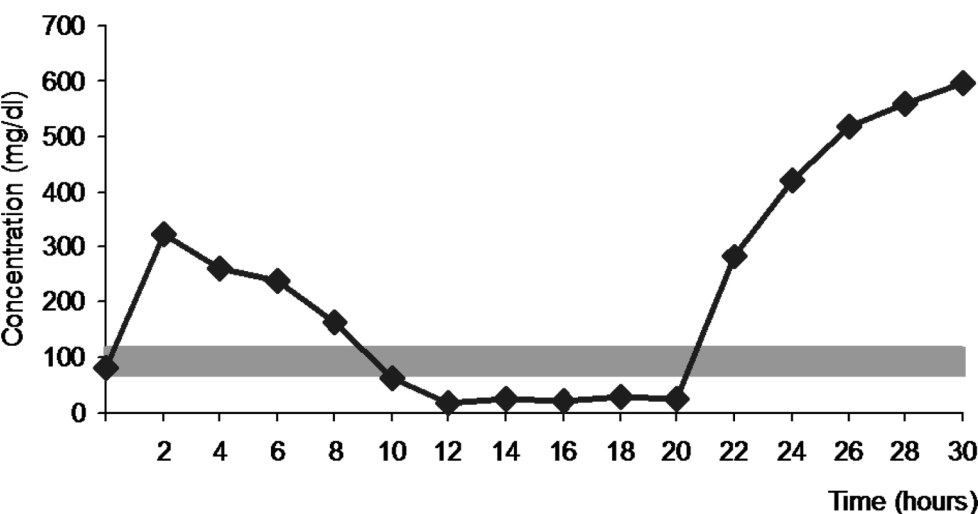


Figure 1a: The initial triphasic response seen after injection of Streptozotocin. (n=2 pigs)

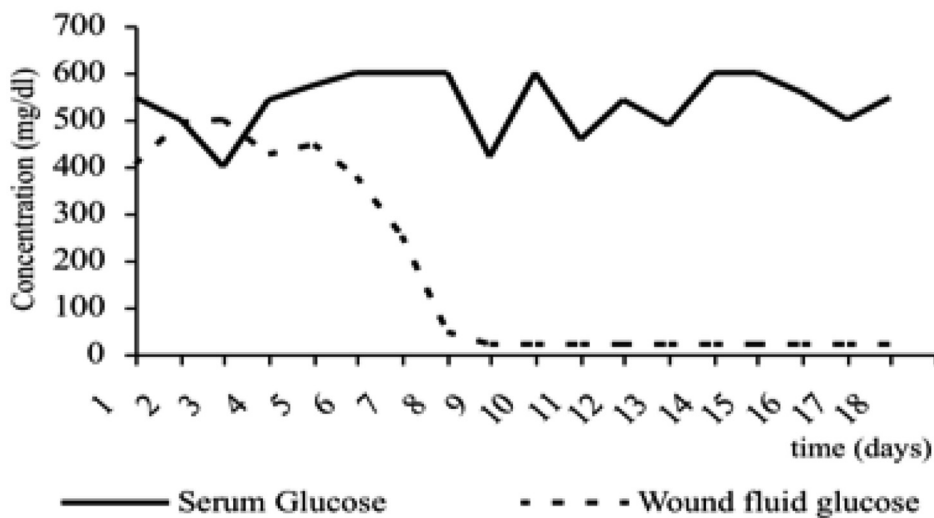


Figure 1b: The association of the wound fluid and the serum glucose concentration in the diabetic pig. Wound fluid was collected on a daily basis and its glucose concentration was measured and compared to serum glucose concentration. (n=40 wounds)

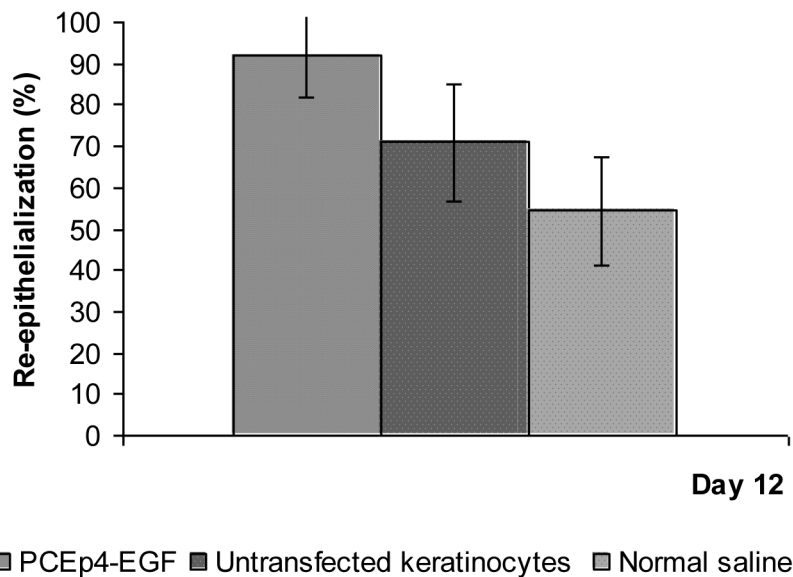


Figure 2: Level of re-epithelialization of full thickness wounds in the different groups:

1. PCEp-4 transfected keratinocyte suspension (n=16 wounds)
2. Untransfected keratinocyte suspension (n=16 wounds)
3. Normal Saline solution (n=14 wounds)

The results were analysed using one way analysis of variance (ANOVA) which showed a p value of 0.0003 considered extremely significant.

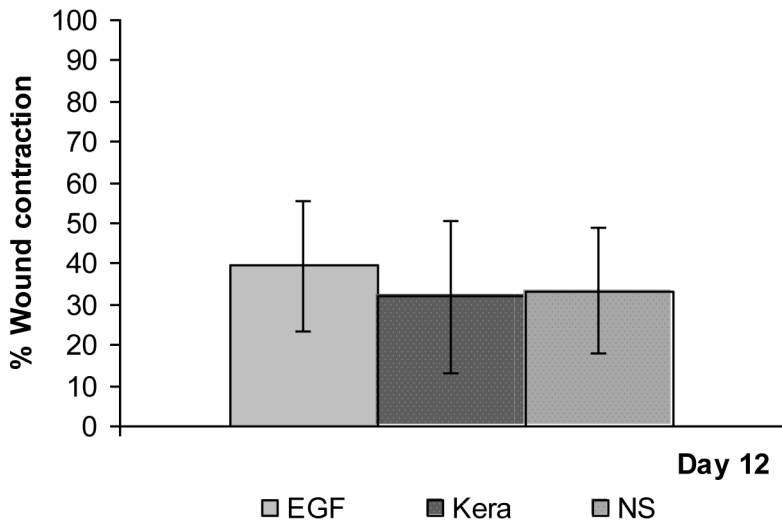


Figure 3: Rate of wound contraction in the different groups. Wound contraction was measured using the permanent boundaries left by the tattooed wound edges. The percentage of the wound area at day 12 was calculated using planimetry and Scion image software® (Scion corporation, MD).

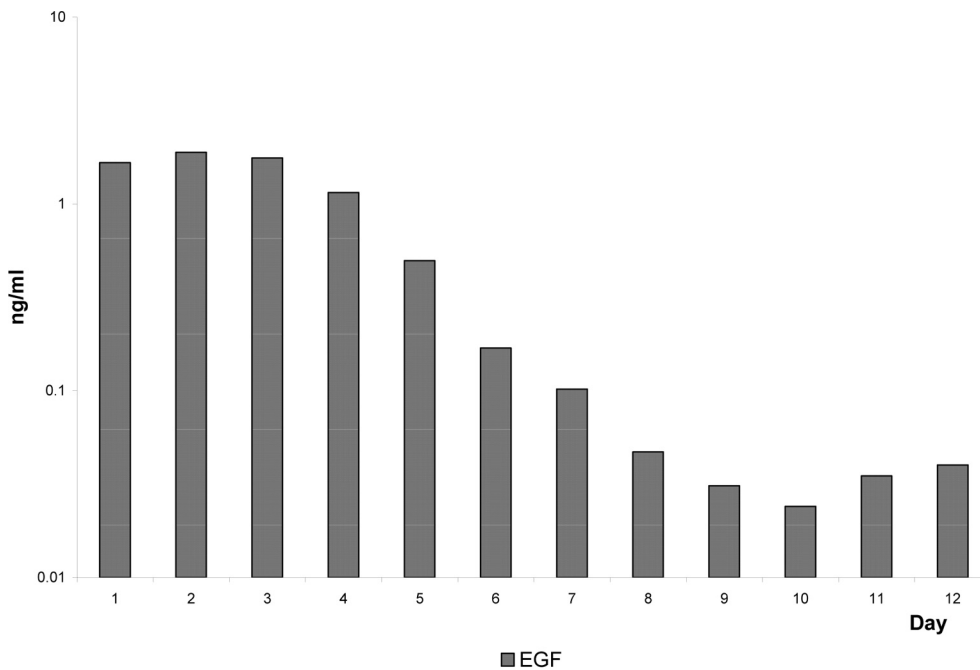


Figure 4a: Expression of hEGF in the wound fluid in the different groups. Wound fluid was collected at 24 hours interval and stored at -80°C. Levels of expression of EGF were measured from the wound fluid using specific enzyme linked immunosorbant assay (Elisa) developed in our laboratory. Results were calculated by using a Vmax kinetic Microplate Reader (Molecular Devices, CA) and Soft Max Pro software.

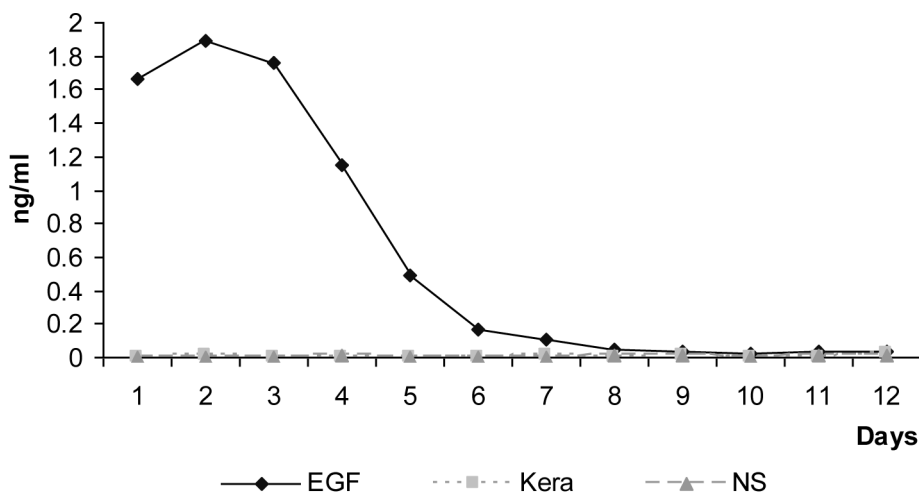


Figure 4b: Expression of hEGF in the wound fluid of PCEp4-EGF transfected keratinocyte suspension treated wounds for the duration of the experiment.

References

1. Streptozotocin-induced diabetes mellitus in pigs. Grüssner R, Nakhleh R, Grüssner A, Tomadze G, Diem P, Sutherland D. *Horm Metab Res.* 1993 Apr;25(4):199-203
2. Wet wound healing. Vranckx JJ, Slama J, Preuss S, Perez N, Svensjö T, Visovatti S, Breuing K, Bartlett R, Pribaz J, Weiss D, Eriksson E. *Plast Reconstr Surg.* 2002 Dec;110(7):1680-7.
3. Autologous keratinocyte suspensions accelerate epidermal wound healing in pigs. Svensjö T, Yao F, Pomahac B, Eriksson E. *J Surg Res.* 2001 Aug;99(2):211-21.
4. [Susceptibility to infections in diabetes--effects on metabolism] Perschel WT, Langefeld TW, Federlin K. *Immun Infekt.* 1995 Dec;23(6):196-200
5. Blakytyn R, Jude E, The molecular biology of chronic wounds and delayed healing in diabetes. *Diabet Med* 2006;23:594
6. Greenhalgh DG. Wound healing and diabetes mellitus. *Clin Plas Surg* 2003;30:37.
7. A.D.A Complications of Diabetes in the United States. [WWW.Diabetes.org/diabetes statistics/ complications](http://WWW.Diabetes.org/diabetes%20statistics/complications). JSP; 2006; (3/13)
8. Greenhalgh DG. Models of wound healing. *J Nurn care Rehabil* 2005;26:293-305
9. Bell RH Jr, Hye RJ. Animal models of diabetes mellitus: physiology and pathology. *J Surg Res* 1983; 35:433-60
10. Impaired wound healing in an acute diabetic pig model and the effects of local hyperglycemia. Velander P, Theopold C, Hirsch T, Bleiziffer O, Zuhaili B, Fossum M, Hoeller D, Gheerardyn R, Chen M, Visovatti S, Svensson H, Yao F, Eriksson E. *Wound Repair Regen.* 2008 Mar-Apr;16(2):288-93.
11. Cell suspensions of autologous keratinocytes or autologous fibroblasts accelerate the healing of full thickness skin wounds in a diabetic porcine wound healing model. Velander P, Theopold C, Bleiziffer O, Bergmann J, Svensson H, Feng Y, Eriksson E. *J Surg Res.* 2009 Nov;157(1):14-20. Epub 2008 Nov 4.
12. Cultured autologous fibroblasts augment epidermal repair. Svensjö T, Yao F, Pomahac B, Winkler T, Eriksson E. *Transplantation.* 2002 Apr 15;73(7):1033-41.
13. Bitar MS, Labbad ZN. Transforming growth factor beta and insulin like growth factor 1 in relation to diabetes-induced impaired wound healing. *J Surg Res* 1996;61:113
14. Bitar MS. Insulin and glucocorticoid-dependent suppression of the IGF-1 system in diabetic wounds. *Surgery* 2000;127:687

15. Jeffcoate WJ, Price P, Harding KG. Wound healing and treatments for people with diabetic foot ulcers. *Diabetes Metab Res Rev* 2004;20(suppl 1). S78
16. Kamal K, Powell RJ, Sumpio BE. The pathobiology of diabetes mellitus: implications for surgeons. *J AM Coll Surg* 1996;183:271
17. Komesu MC, Tanga MB, Buttros KR, et al. Effects of acute diabetes on rat cutaneous wound healing. *Pathophysiology* 2004;11:63
18. Yuan S, Liu Y, Zhu L. Vascular complications of diabetes mellitus. *Clin Exp Pharmacol Physiol* 1999;26:977
19. Puccinelli TJ, Bertics PJ, Masters KS. Regulation of keratinocyte signaling and function via changes in epidermal growth factor presentation. *Acta Biomater* 2010,
20. Insulin-like growth factor-1 gene therapy and cell transplantation in diabetic wounds. Hirsch T, Spielmann M, Velander P, Zuhaili B, Bleiziffer O, Fossum M, Steinstraesser L, Yao F, Eriksson E. *J Gene Med.* 2008 Nov;10(11):1247-52.
21. Jost M, Kari C, Rodeck U. The EGF receptor- an essential regulator of multiple epidermal functions. *Eur J Dermatol* 2000;10:505
22. Martin P. Wound healing- aiming for perfect skin regeneration. *Science* 1997;276:75
23. Benner N, Schultz G. Growth factors and wound healing: biochemical properties of growth factors and their receptors. *Am J Surg* 1993;165:728-737
24. Portero-otín M, Pamplona R, Bellmunt MJ, Ruiz MC, Prat J, Salvayre R, Negre-Salvayre A. Advanced glycation end products precursors impair epidermal growth factor receptor signalling. *Diabetes* 2002;51:1535-42
25. Cell suspension cultures of allogenic keratinocytes are efficient carriers for ex vivo gene transfer and accelerate the healing of full-thickness skin wounds by overexpression of human epidermal growth factor. Vranckx JJ, Hoeller D, Velander PE, Theopold CF, Petrie N, Takeda A, Eriksson E, Yao F. *Wound Repair Regen.* 2007 Sep-Oct;15(5):657-64.