



LUND UNIVERSITY

Effect of Drugs on Rabbit Retina

Cardiakidis Myers, Anna

2013

[Link to publication](#)

Citation for published version (APA):

Cardiakidis Myers, A. (2013). *Effect of Drugs on Rabbit Retina*. [Doctoral Thesis (compilation), Ophthalmology, Lund]. Ophthalmology (Lund), Lund University.

Total number of authors:

1

General rights

Unless other specific re-use rights are stated the following general rights apply:

Copyright and moral rights for the publications made accessible in the public portal are retained by the authors and/or other copyright owners and it is a condition of accessing publications that users recognise and abide by the legal requirements associated with these rights.

- Users may download and print one copy of any publication from the public portal for the purpose of private study or research.
- You may not further distribute the material or use it for any profit-making activity or commercial gain
- You may freely distribute the URL identifying the publication in the public portal

Read more about Creative commons licenses: <https://creativecommons.org/licenses/>

Take down policy

If you believe that this document breaches copyright please contact us providing details, and we will remove access to the work immediately and investigate your claim.

LUND UNIVERSITY

PO Box 117
221 00 Lund
+46 46-222 00 00

EFFECTS OF DRUGS ON RABBIT RETINA

**Function and histopathology after medication with rifabutin,
inhibitors of vascular endothelial growth factors,
triamcinolone and adalimumab**

Anna Cardiakidis Myers, MD

Supervisor: Vesna Ponjavic, MD, PhD

Co-supervisors: Sten Andréasson, MD, PhD

Fredrik Ghosh, MD, PhD

Anitha Bruun, PhD

FACULTY OF MEDICINE
Lund University

2013

THIS DOCTORAL THESIS
IS DEDICATED TO
VINCENT AND SAMMY

Acknowledgements

I owe million thanks and a tremendous debt of gratitude to:

My head supersupervisor Vesna Ponjavic and our best supporting supervisors: Sten Andréasson, Fredrik Ghosh and Anitha Bruun. By joint forces you made this doctoral thesis possible, driving me through the work with firm and steady hands. And it must be said - several have tried but only you have succeeded!

My dear co-authors Monica Lövestam Adrian, Sten Kjellström and Björn Isaksson.

Boel Nilsson and Karin Arnér for allowing me to lean on your enormous practical knowledge, for your kind help with the handling of our animals and for good and fun conversations.

My colleagues and coworkers at the Department of Ophthalmology for making it the best place to work at, inspite of mighty and persistant forces pulling in the opposite direction.

My lab colleagues for creating an intellectual, warm and welcoming environment to where a simple medic can come and learn new things.

Abstract

The adverse effects of drugs in the eye are not easily detected, and the underlying pathogenesis not fully understood. The effects of four different kinds of drugs have been investigated in the rabbit eye, using electroretinography, ocular examination and histochemical methods.

Rifabutin is a broad spectrum antibiotic with known ocular adverse effects (corneal opacities, uveitis and vascular retinopathy) in the human eye. In the rabbit eye rifabutin causes lens discoloration and it significantly reduces both total rod-cone function and isolated cone function, but it does not affect retinal morphology.

Ranibizumab, bevacizumab, and pegaptanib are inhibitors of the cytokine vascular endothelial growth factor. Pegaptanib and ranibizumab are approved for injection into the vitreous. Bevacizumab is a cancer drug injected off-label intravitreally. In rabbit rod-mediated function was found depressed 8 weeks after a single injection of all three VEGF inhibitors. Rod bipolar cells were affected in the groups injected with pegaptanib and ranibizumab, but not with bevacizumab.

Triamcinolone acetonide is a corticosteroid with depot properties, used for intramuscular and intraarticular injections. In Europe, triamcinolone is commercially available only in combination with the preservative benzyl alcohol, and is not approved for intraocular use. Triamcinolone has been and is extensively used off-label for injections into the vitreous body. Intravitreal injection of triamcinolone and benzyl alcohol, separately and in combination, affected both retinal function and histology.

Adalimumab, a monoclonal antibody against the pro-inflammatory cytokine tumor necrosis factor α is approved for subcutaneous injection in autoimmune diseases. The level of TNF α is raised in ocular inflammatory conditions. No functional disturbances were found on examination with ffERG after injection into the vitreous body of rabbits. Retinal histology was found to be intact.

These studies have shown that drugs may affect both retinal function and histology in the rabbit eye, and that retinal electrophysiology combined with histochemistry can detect the retinal level and the cell type involved in these processes, or exclude retinal damage by the drug. This knowledge should alert ophthalmologists to perform extensive investigations in patients on medication who present with unaccountable visual symptoms.

Key words:

Drug toxicity, electroretinography, histopathology, intravitreal injection, rifabutin, anti-VEGF, triamcinolone, benzyl alcohol, anti-TNF-alpha, adalimumab

Contents

Acknowledgements	3
Abstract	4
ABBREVIATIONS	8
LIST OF PAPERS	9
INTRODUCTION	10
GENERAL BACKGROUND	11
The rabbit eye vs. the human eye	11
Full-field electroretinography	12
Multifocal electroretinography	15
Histochemistry	17
AIMS OF THE STUDY	18
General aim	18
Specific aims	18
THE TESTED DRUGS	19
Rifabutin	19
Vascular endothelial growth factor inhibitors: bevacizumab, pegaptanib and ranibizumab	20
Triamcinolone acetonide and benzyl alcohol	21
The TNF alpha inhibitor, adalimumab	23
MATERIALS AND METHODS	24
Table 1. Research design overview for the four studies involved	24
Animals	25
Drug administration	25
Full-field ERG and multifocal ERG	26
Study of the effects of rifabutin.....	28
Study of the effects of VEGF inhibitors	29
Study of the effects of triamcinolone acetonide and benzyl alcohol.....	29
Study of the effects of adalimumab	29
Histology	30
Tissue preparation	30
Immunohistology	30
Glial fibrillary acidic protein, protein kinase C alpha, vimentin, calbindin, parvalbumin & rhodopsin	30
Peanut agglutinin	31
STATISTICAL ANALYSES	32
Analyses used for the effects of rifabutin	32
Analyses used for the effects of VEGF inhibitors.....	32
Analyses used for the effects of triamcinolone acetonide and benzyl alcohol	33
Analyses used for the effects of adalimumab.....	33
RESULTS	34
The effects of long-term oral administration of rifabutin	34

The effects of VEGF inhibitors.....	35
The effects of TA and BA	35
The effects of adalimumab.....	37
DISCUSSION	38
CONCLUSIONS	42
POPULÄRVETENSKAPLIG SAMMANFATTNING	44
REFERENCES	48

ABBREVIATIONS

AMD - age-related macular degeneration

BA - benzyl alcohol

BSS-balanced salt solution

FfERG - full-field electroretinography

ERG - electroretinography

GFAP - glial fibrillary acidic protein

MfERG - multifocal electroretinography

ND filter - neutral density filter

PKC α - protein kinase C-alpha

PNA - peanut agglutinin

RPE - retinal pigment epithelium

ROP - retinopathy of prematurity

TA - triamcinolone acetate

TNF α - tumor necrosis factor alpha

VEGF - vascular endothelial growth factor

LIST OF PAPERS

This thesis is based on the following papers, which will be referred to in the text by their Arabic numbers.

1. Rifabutin accumulates in the lens and reduces retinal function in the rabbit eye. Cardiakidis Myers A, MD, Kjellström S, MD, Bruun A, PhD, Isaksson B, MSc, PHARM, Ghosh F, MD, PhD, Andréasson S, MD, PhD, Ponjavic V, MD, PhD. *Retina*, 29(1);106-111, 2009.
2. Retinal function and morphology in rabbit after intravitreal injection of VEGF inhibitors. Cardiakidis Myers A, MD, Lövestam Adrian M, MD, PhD, Bruun A, PhD, Ghosh F, MD, PhD, Andréasson S, MD, PhD, Ponjavic V, MD, PhD. *Current Eye Research*, 37(5);399-407, 2012.
3. Intravitreal injection of triamcinolone acetonide into healthy rabbit eye alters retinal function and morphology. Cardiakidis Myers A, MD, Bruun, A, PhD, Ghosh F, MD, PhD, Lövestam Adrian M, MD, PhD, Andréasson S, MD, PhD, Ponjavic V, MD, PhD. *Current Eye Research*, 38(6): 649-661, 2013.
4. Retinal function and morphology in the rabbit eye after intravitreal injection of adalimumab. Cardiakidis Myers A, MD, Ghosh F, MD, PhD, Andréasson S, MD, PhD, Ponjavic V, MD, PhD.
Submitted

INTRODUCTION

Medical treatment sometimes has undesirable effects, in addition to the intended action. The retina, which is responsible for vision, is vulnerable to toxic insult, and changes in visual function sometimes provide the first signs of toxicity. As in the brain, the retina is protected by barriers: the outer retinal blood–ocular barrier, which consists of complexes holding the cells of the retinal pigment epithelium tightly together, and the inner retinal blood – ocular barrier, consisting of tight junctions between the endothelial cells of the retinal arteries and capillaries. In spite of these barriers, there are classical examples of drug retinopathy resulting from systemic administration of drugs.

Four drugs of current ophthalmological interest have been studied in this thesis. They were chosen based on observations in everyday clinical practice, for example, patients who presented with unexplained visual dysfunction, or the fact that the drug profile was considered interesting for application to ophthalmological disease. To achieve a better understanding of drug-induced retinal effects, an animal model was used to investigate visible retinal pathology and function together with retinal histology to elucidate pathogenic mechanisms. When choosing an appropriate animal model for this research, factors such as feasibility, ocular similarity to the human eye, cost and experience in animal research were taken into consideration. Some larger animals have eyes that bear a greater similarity to the human eye, but ethical considerations and cost led to the decision to use pigmented rabbits. The rabbit eye is large enough for intravitreal injection, and the size of the animal allows fairly large experimental groups to be used. In addition, our research group has previous experience of using both full-field electroretinography (ffERG) (Gjörloff K, Andreasson S, 2004) and multifocal electroretinography (mfERG), as well as histological methods in rabbits. (Gjörloff Wallentén K, Andreasson S, 2006)

Minimal modifications in equipment were needed, and only a slight adaptation of the clinical routine was necessary to use the clinical procedure in the laboratory environment.

GENERAL BACKGROUND

The rabbit eye vs. the human eye

An experimental model employing pigmented rabbits was used in the four studies described in this thesis. Electroretinography (ffERG and mfERG) can be performed in rabbits using the same equipment as in humans (Gjörloff K, Andreasson S, 2004) (Gjörloff Wallenten K, Andreasson S, et al., 2006). The waveforms obtained using ffERG when examining rabbits are similar to those obtained from humans (Kjellström U, 2010). However, there are several anatomical differences between the human eye and the rabbit eye. The antero-posterior length of the adult human eye is approximately 24 mm, while that of the rabbit is 16 mm, and the volume of the human vitreous cavity is 4.0 mL, and that of the rabbit 1.5 mL. The rabbit cornea is flatter with a larger diameter: 15 mm in rabbit versus 11.5 mm in humans (Cibis GW and Abdel-Latif AA, 2003). The rabbit retina is rod dominated (Strettoi E, Masland EH, 1995). Instead of a macula the rabbit has a horizontal band-like structure called the visual streak, located just under the optical disc, with a relatively higher density of cones and ganglion cells (Szel A, Röhlich P, 1996). A photograph of the rabbit fundus is shown in **Figure 1**. The peak cone density of the visual streak is $13\text{-}18 \times 10^3/\text{mm}$, while the peak cone density of the human fovea is $140 \times 10^3/\text{mm}$. The rabbit retina has two kinds of cones, making it dichromatic (Szel A, Röhlich P, 1996) (Famiglietti, EV, Sharpe, SJ, 1995), while the human retina has three kinds affording us polychromatic sight. The retinal arterial system is more developed in the human eye. Oxygen is delivered to the retina via a combination of the choroidal vascular bed, which lies immediately below the retina, and the retinal vasculature, which lies within the inner retina (Yu D-Y and Cringle SJ, 2001). The central retinal artery enters the eye with the optic nerve and divides into 4 branches that subsequently diverge into smaller arteries that spread over the mid-peripheral retina. In the rabbit, medullary rays are formed by myelinated nerve fibers, which extend nasally and temporally. The retinal blood vessels follow the routes of the medullary rays, and these blood vessels are responsible for the circulation in the retina. In the rest of the retina, the blood supply is provided by the choroidal circulation (Yu D-Y and Cringle SJ, 2001). However, even in species with vascularized retinas, as in humans, the choroid, having the highest blood flow of any tissue in the body, is the main provider of retinal oxygen, and the retinal blood circulation provides only 5% of the oxygen

required (Regillo C et al, 2008).

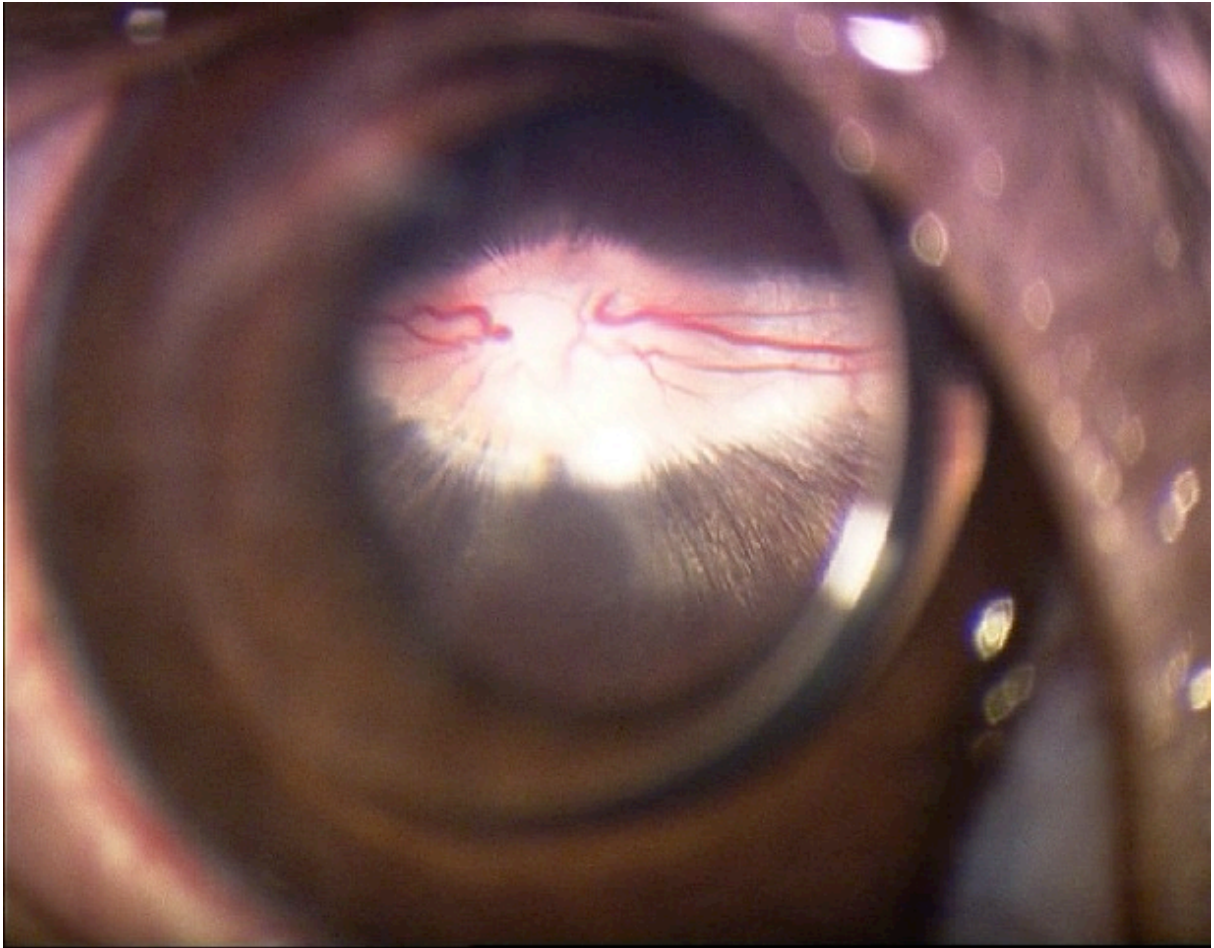


Figure 1.

Full-field electroretinography

Electroretinography (ERG) is used to record the electrical responses from the cells in the retina. An electrode is placed on the cornea and the retina is illuminated. Currents are generated by the selective flow of ions, mainly sodium and potassium, across cell membranes.

Under dark-adapted conditions, there is a current through the photoreceptors, the dark current. Photons alter the state of membrane-bound rhodopsin, activating the phototransduction cascade. The sodium channels of the photoreceptors shut, leading to hyperpolarization. The change in

polarity of the photoreceptors decreases the release of the synaptic transmitter substance, and activates the bipolar cells, which in turn transmit the signal to the ganglion cells. Horizontal and amacrine cells act by modulating the synaptic connections, transmitting information from nearby retinal cells. The radial organization of the photoreceptors and other cells gives rise to a measurable current flowing away from the inner nuclear layer towards the retinal pigment epithelium. The functions of the rods and cones can be differentiated by changing the conditions under which the electroretinogram is recorded: i.e., by altering the state of retinal adaptation, or by changing the wavelength, intensity, frequency, or the duration of the light stimulus (Ponjavic V, Andreasson S, 2003). Rod function is investigated following dark adaptation for at least 20 minutes under scotopic (low light) conditions, and using dim stimulus flashes. The combined rod and cone function is also studied under scotopic conditions, but using a brighter white light stimulus. Pure cone-derived recordings can be achieved by light adapting the retina with bright background light (photopic conditions). After the rod system has been desensitized by the background light, the cone function can be analyzed using flashes of bright light.

The major components of an electroretinogram are the cornea-negative a-wave and the cornea-positive b-wave, shown in **Figure 2**. The scotopic a-wave primarily reflects the response of the rod photoreceptors to light (Penn RD, Hagins WA, 1969) (Breton MEA, Schueller AW et al., 1994), and the b-wave reflects post-synaptic bipolar cell activity, in turn driven by photoreceptor input (Newman EA, Odette LL, 1984) (Stockton RA, Slaughter MM, 1989) (Xu X, Karwoski CJ, 1994) (Robson JG, Frishman LJ, 1995). The ERG recording obtained using high-intensity 30 Hz flickering light is mainly mediated by the cone photoreceptors, although other retinal cells, such as bipolar cells, contribute to varying degrees depending on the frequency and duration of the light flashes. The amplitudes of the a- and b-waves are measured in microvolt (μV) and the time to peak, implicit time, in milliseconds (ms). The amplitude of the a-wave is measured from the baseline to the a-wave trough, and the amplitude of the b-wave is measured from the a-wave trough to the b-wave peak. The implicit time of the a-wave is measured from stimulus onset to the a-wave trough, and the implicit time of the b-wave from stimulus onset to the b-wave peak, as illustrated in **Figure 2**.

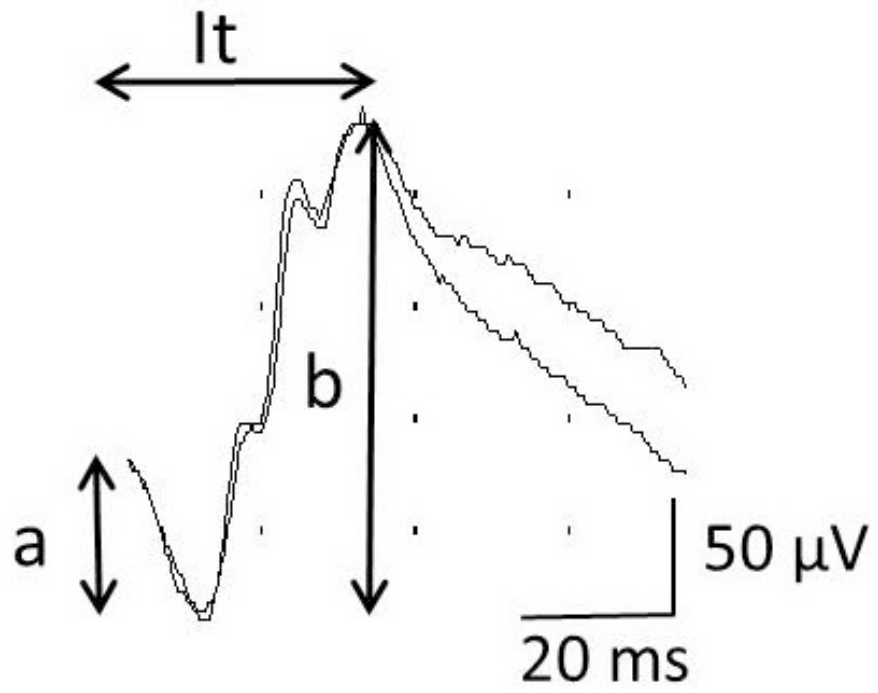
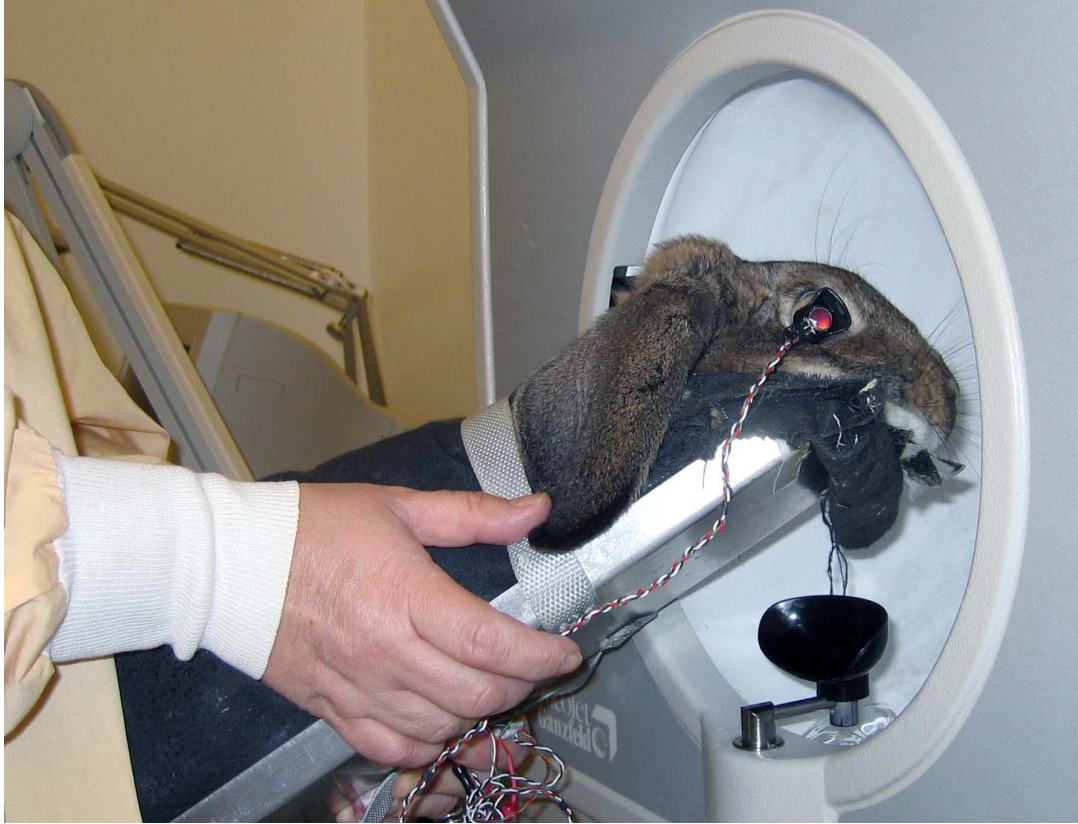

Figure 2.

Multifocal electroretinography

Full-field ERG provides a mass potential reflecting the global retinal function, but does not reveal localized lesions in the retina. Multifocal ERG was developed to provide a topographical view of the electrophysiological activity of the retina, mainly for the detection of maculopathy. In mfERG, the retina is stimulated with an array of hexagonal elements, each of which has a 50% chance of being illuminated every time the frame changes. The examination provides a map of local ERG activity, as shown in **Figure 3**. The typical waveform of the basic mfERG response (also called the first-order response or first-order kernel) is a biphasic wave with an initial negative deflection followed by a positive peak. There is usually a second negative deflection after the positive peak. These three peaks are called N1, P1 and N2. The amplitude of these waves are measured in nanovolt (nV). There is evidence that N1 includes contributions from the same cells that contribute to the a-wave of the light-adapted ffERG signal, and that P1 and N2 include contributions from the cells contributing to the light-adapted b-wave and oscillatory potentials. Although there are homologies between the mfERG waveform and conventional ERG, the stimulation rates are higher in mfERG, and the mfERG responses are mathematical extractions. Therefore, technically, the mfERG responses are not simply “low-amplitude ERGs”, and the designations “a-wave” and “b-wave”, used in ffERG, are not appropriate when describing the features of the mfERG waveform (Hood D C, Bach M et al., 2012).

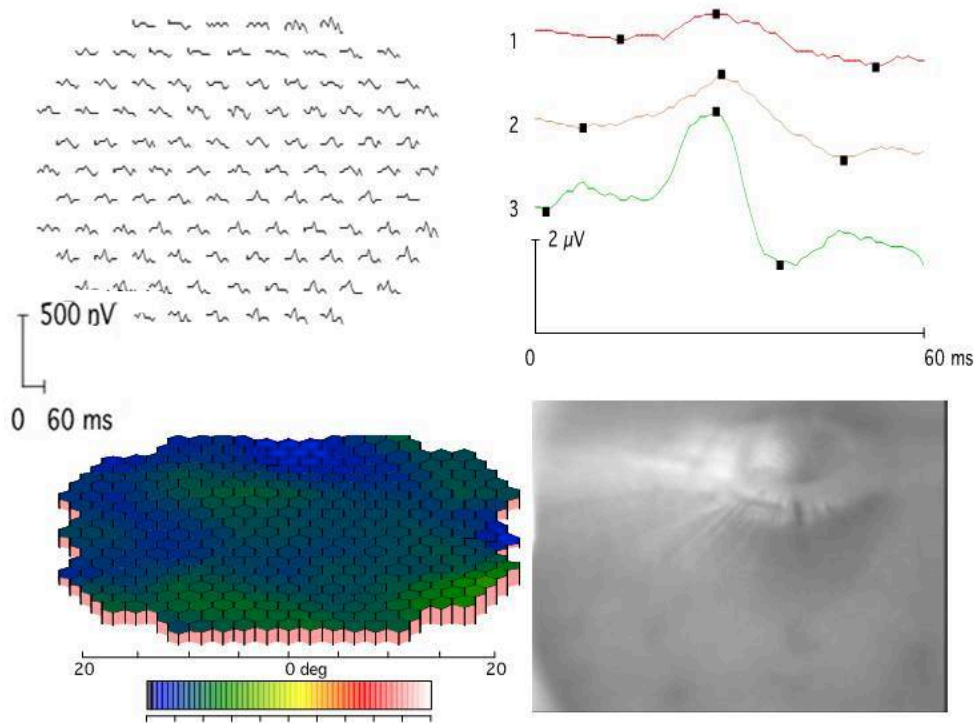
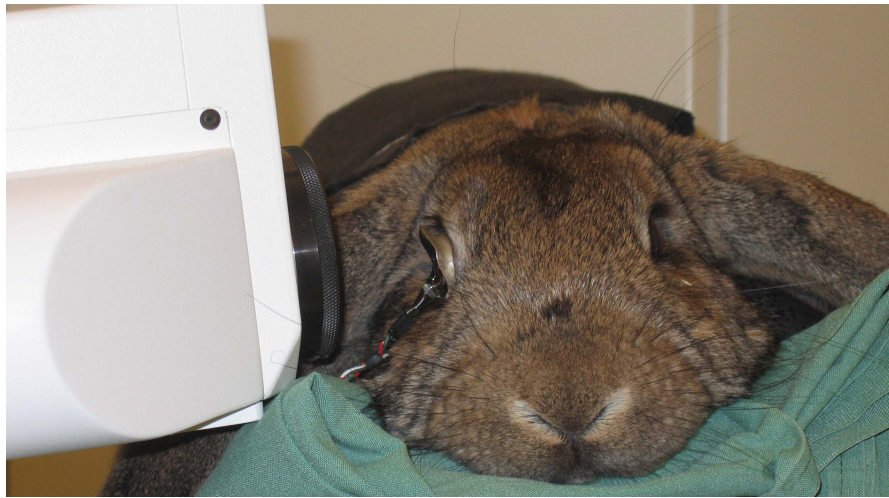


Figure 3.

Histochemistry

In the papers included in this thesis, specific cell groups in the retinal sections were examined with one of two methods: by immunofluorescence or by using a lectin. In these methods a molecule adheres to an antigen or to a carbohydrate, specific for the group of cells to be examined. In immunofluorescence, a type of immunohistochemistry, an antibody binds to a specific antigen on a cell and the antigen antibody interaction is visualized by a fluorophore tagged onto the antibody as the fluorophore is excited by light. Immunofluorescence was used in all the papers included in this study (Kostinaho J, Sagar SM, 1994)(Wood JPM, McCord RJ et al.,1997)(Lewis P, Fisher S K, 2003)(Casini G, Rickman DW, et al.,1995)(Mac Kenzie D, Arnedt A et al., 1994)(Massey SC, Mills SL, 1996)

Lectins are carbohydrate-binding proteins, in these studies, labeled with a biotin molecule. Lectins adhere strongly to specific carbohydrate found on the cell to be examined. Streptavidin has a very strong affinity for biotin. Streptavidin was conjugated with a red fluorophore, rhodamine. In papers 2, 3, and 4, the lectin peanut agglutinin was used as it binds specifically to cone inner and outer segments (Blanks J, Johnson LV,1982).

AIMS OF THE STUDY

General aim

The general aim of the research presented in this thesis is to objectively characterize function and morphology in the rabbit retina after administration of drugs, systemically or directly into the eye, in order to confirm or exclude toxic drug effects.

Specific aims

The specific aims of each of the studies were:

- to study the effects of systemically administered rifabutin in the rabbit eye, especially retinal function and histopathology (Paper 1),
- to study the histology and function of the rabbit retina after high-dose intravitreal injection of three commonly used vascular endothelial growth factor inhibitors (Paper 2),
- to study the effects of intravitreally injected triamcinolone acetonide and/or its preservative benzyl alcohol in healthy rabbit retina (Paper 3), and
- to study the effects of intravitreally injected tumor necrosis factor alpha (TNF α) inhibitor, adalimumab, on healthy rabbit retina (Paper 4).

THE TESTED DRUGS

Rifabutin

Rifabutin (4-deoxy-3,4-[2-spiro-(N-isobutyl-4-piperidyl)-2,5-dihydro-1H-imidazole]-rifamycin-S) is a broad-spectrum antibiotic. It is an inhibitor of RNA polymerase, and is used to treat patients with severe infections such as tuberculosis and osteomyelitis, and for prophylaxis against mycobacteria in HIV-infected patients. The systemic adverse effects include discoloration of the skin and the body fluids (Soukasian SK & Raizman MB, 2000). In the eye it has been shown to cause specific adverse effects such as anterior uveitis (Fraunfelder FT, Meyer SM, 1989)(Brogden RN, Fitton A, 1994)(Jacobs DS, Pilleroy PJ et al., 1984)(Saran BR, Maguire AM et al., 1994) (Becker K, Schimkat M et al., 1996) (Arevalo JF, Russack V et al., 1997) (Fraunfelder FW & Rosebaum JT, 1997)(Fineman MS, Vander J et al., 2001), posterior uveitis with vitreous opacity (Khan MA, Singh J et al., 2000) (Chaknis MJ, Brooks SE et al., 1996), and vascular retinopathy (Arevalo JF, Russack V et al., 1997)(Skolik S, Willermain F et al., 2005). Corneal endothelial deposits associated with rifabutin have been reported by several research groups (Coutinho AB, Cheema D et al., 2005) (Smith JA, Mueller BU et al., 1999) (Holland SP, Chang CW et al., 1999), as well as intracorneal opacity (Chu DS, Zaidman GW et al., 2001).

In 2002, our research group published a case report describing an 8-year-old boy with osteomyelitis, who was referred to our department because of reduced vision after four years of treatment with rifabutin. We found reduced visual acuity, opacities of the cornea and the lens, and a reduced full-field electroretinogram. He showed no vitreous opacity or retinal angiopathy (Ponjavic V, Gränse L et al., 2002). After termination of the treatment, his retinal function improved, but the corneal and lens pathology were unchanged five years after terminating treatment with rifabutin.

Previous toxicological studies of animals given rifabutin have demonstrated brownish deposits of lipofuscin-like material in several organs (Brughera M, Scampini G et al., 1995). However, no animal studies have been conducted to evaluate the effects of rifabutin in the function of the eye. In the present work, the toxicology of rifabutin in the rabbit eye was studied, with emphasis on retinal function and histopathology.

Vascular endothelial growth factor inhibitors: bevacizumab, pegaptanib and ranibizumab

Modern therapies for the treatment of neovascular age-related macular degeneration (AMD) are evolving rapidly (Wong TY, Chakravarty U et al., 2008). Blocking the vascular endothelial growth factor (VEGF) in the eye has shown dramatic improvement in the visual outcome in these patients, compared to the previous treatment of choice (Schmidt-Erfurth U, Richard G et al., 2007). Intravitreal administration of VEGF inhibitors has also shown promising results in other conditions involving neovascularization, such as diabetic retinopathy (Simo R, Hernandez C, 2008) and macular edema in retinal vein occlusion (Kriechbaum K, Michels S, 2008) (Kreutzer TC, Alge CS, 2008). As early as 1948, Michelson stated that a specific factor (factor X) was necessary for the normal development and growth of the retinal vasculature (Michelson IC, 1948). Many years later, Folkman identified a tumor angiogenic factor as a candidate for therapeutic anti-angiogenesis (Folkman J, 1971). Today, we also know that VEGF is essential for the normal development of the choriocapillaris and visual function (Marneros AG, Fan J et al., 2005).

Several agents have been developed to inhibit VEGF, of which pegaptanib, ranibizumab and bevacizumab are the most commonly used in the eye (Pieramici DJ, Rabena MD, 2008)(Klettner A, Roider J, 2008)(Moreira IS, Fernandes PA, 2007)(Spitzer MS, Yoeuruk E et al., 2007). The efficacy of these drugs is well documented, as are some aspects of their safety profiles and mode of action (Ip MS, Scott IU et al., 2008) (Patel PJ, Bunce C et al., 2008)(Ziemssen F, Lüke M et al., 2008). The effects of VEGF inhibitors on the eye have been studied in animal models such as the monkey and the rat (Peters S, Heiduschka P et al., 2007) (Heiduschka P, Fietz H et al., 2007) (Iriyama A, Chen YN et al., 2007). However, specific evaluation of retinal function using several different light stimulation modalities, and morphological investigations have only been performed in a few animal studies. A recent publication reports increased apoptosis in the retina of mice after systemic VEGF neutralization, verified by reduced retinal function (Saint-Geniez M, Maharaj ASR et al., 2008).

Adverse effects related to VEGF inhibition are uncommon in the adult human eye, but transient changes in the electroretinograms of individual patients have been reported, as well as sporadic

cases of retinochoroiditis (Stahl A, Feltgen N et al., 2009) (Maier M, Feucht N et al., 2008) (Lipski A, Bornfeld N et al., 2007). Another study describing a transient change in retinal function in patients with AMD after intravitreal injection of bevacizumab has recently been published (Pedersen KB, Møller F et al., 2010). VEGF inhibition has been explored as monotherapy and as an adjuvant for retinopathy of prematurity (ROP) (Wu WC, Yeh PY et al., 2011)(Kusaka S, Shima C et al., 2008). The administered dose has been arbitrarily set at 40-50% of that used in AMD in the adult eye. Since the vitreous volume of the premature infant is smaller than that of the adult (Tasman W, Jaeger EA et al., 1998)(Larsen JS, 1971) investigation of the retinal effects resulting from a relatively high concentration of VEGF inhibitors may be of clinical value. One of the aims of the present work was thus to explore and compare retinal morphology and function after the administration of VEGF inhibitors at a relatively high concentration using an animal model.

Triamcinolone acetonide and benzyl alcohol

Triamcinolone acetonide (TA) is an intermediate-acting crystalloid synthetic corticosteroid used for intramuscular and intraarticular injections in rheumatoid arthritis and seasonal allergies. In the USA, TA without preservatives has been approved for intraocular use by the US Food and Drug Administration. In Europe, TA is commercially available only in combination with the preservative benzyl alcohol (BA), and is not approved for intravitreal use. TA has been used extensively off-label for injections into the vitreous to treat inflammatory and ischemic ocular conditions (diabetic retinopathy, retinal vein occlusion, neovascular AMD, and uveitis) in order to prevent neovascularization and macular edema. It has been used alone or in conjunction with VEGF-blocking substances, and with panretinal or grid laser therapy (Cho WB, Moon J W et al., 2010)(Bandello F, Parodi Battaglia M et al., 2010). TA can be administered to the eye by several routes. The suspension may be injected sub-conjunctivally, into the subtenon space, as a retrobulbar injection, or into the vitreous body/cavity. The intraocular concentration of TA varies as the diffusion of the particles is limited by Tenon's capsule and the sclera, and exact intraocular concentrations can only be achieved through injection into the vitreous body/cavity (Couch SM, Bakri SJ, 2009).

Intravitreally administered TA has been reported to have a positive effect on retinal function in patients with diabetic macular edema, branch retinal vein occlusion, central retinal vein occlusion and non-infectious uveitis, at least in the short term (Elman MJ, Aiello LP et al., 2010)(Grover DA, Li T et al., 2008)(Sallam A, Comer RM, 2008) (Kok H, Lau C et al., 2005)(Jermak CM, Dellacroce JT et al., 2007). It has been found to reduce hemorrhage-mediated retinotoxicity on the outer nuclear layer when injected into the vitreous cavity of the rabbit (Bhisitkul RB, Winn BJ et al., 2008).

Intravitreal injection of TA has well-known adverse effects: ocular hypertension, cataract formation and endophthalmitis (Grover DA, Li T et al., 2008)(Sallam A, Comer RM, 2008)(Kok H, Lau C et al., 2005)(Jermak CM, Dellacroce JT, et al. 2007)(Jonas JB, 2006). Furthermore, in a recent study, in which the therapeutic effects of TA on uveitic macular edema were studied, retinal toxicity was demonstrated by pathological findings using ocular coherence tomography and ERG (Schulze-Döbold C, Weber M, 2009). The question of whether TA, alone, or in combination with BA, is safe or not, has been investigated in several animal and cell culture studies, resulting in conflicting results (Morrison VL, Koh HJ, 2006). This, together with the fact that intravitreal pharmacotherapy using corticosteroids appears to be expanding, means that detailed investigations of the effects of TA and its preservative BA are warranted (Zhenguy S, Fang W et al., 2009)(Yeung CK, Chan KP et al., 2004)(Szurman P, Kaczmarek R et al., 2006)(Kai W, Yanrong J et al., 2006)(Albini TA, Abd-El Barr M et al., 2006)(Macky TA, Helmy D et al., 2007)(Narayanan R, Mungcal JK et al., 2006)(Yu SY, Damico FM et al., 2006)(Li Q, Wang J et al., 2008)(Lang Y, Zemel E et al., 2007)(Maia M, Penha FM et al., 2008)(Citirik M, Dilsiz N, 2009)(Hida T, Chandler D et al., 1986). The effects of TA, separately, and in combination with the preservative BA, on the healthy rabbit eye, were investigated in this work by studying the retinal function using ERG, and retinal subtype morphology with histochemistry.

The TNF alpha inhibitor, adalimumab

Adalimumab is a fully humanized monoclonal antibody against the pro-inflammatory cytokine TNF α , which plays a pivotal role in the initiation and perpetuation of inflammation. TNF α is normally produced by macrophages and T cells. In uveitis, activated retinal microglia, Müller cells, and pigment epithelial cells can also produce TNF α (Dick AD, Forrester JV et al., 2004). It is of great importance for host defense and for apoptosis (Khera T K, Dick AD et al., 2011)(Mirshahi A, Hoehn R et al., 2012)(Dick AD, Forrester JV 2004)(Malaviya AP, Ostör AJK 2012), but persistent production of TNF α , as occurs in many autoimmune diseases, including non-infectious uveitis, can cause significant tissue damage (Khera TK, Dick AD et al., 2011). Blocking TNF α has proven successful in the treatment of autoimmune conditions such as rheumatoid arthritis, ankylosing spondylitis, Crohn's disease, psoriatic arthritis, and juvenile idiopathic arthritis (Khera TK, Dick AD et al., 2011)(Malaviya AP, Ostör AJK, 2012). In uveitis, the level of TNF α is raised in the aqueous humor and ocular tissues (Dick AD, Forrester JV et al., 2004). Injection of TNF α into the vitreous results in uveitis, with disruption of the blood–retina barrier and neovascularization (Rosenbaum JT, Howes EL et al., 1988). In experimental autoimmune uveitis, the clinical onset of disease and histological damage were suppressed by neutralizing TNF α activity (Dick AD, Forrester JV et al., 2004).

Systemic treatment with TNF α -blocking substances has been used successfully as an off-label alternative to traditional immunosuppressive therapy in the treatment of severe and refractory ocular inflammation, such as Behçet's disease, sarcoidosis, juvenile uveitis and idiopathic uveitis (Mirshahi A, Hoehn R et al., 2012)(Mushtaq B, Saeed T et al., 2007)(Galor A, Perez VL et al., 2006)(Erckens RJ, Mostard RLM et al., 2012)(Accorinti M Pirraghlia MP, 2007)(Biester S, Deuter C et al., 2007)(Bawaseer A, Raffa LH et al., 2010)(vanLaar JAM, Missotten T et al., 2007)(Joseph A, Raj D, 2003)(Guignard S, Gossec L et al., 2006)(Foeldevari I, Nielsen S, 2007). Intravitreal injection of adalimumab may offer a useful therapeutic tool in the treatment of uveitis, avoiding adverse systemic side effects and therefore we wanted to investigate whether adalimumab is well tolerated in the vitreous body using a rabbit model.

MATERIALS AND METHODS

Table 1. Research design overview for the four studies involved

	Study1	Study2	Study3	Study4
No. of animals	7 in rifabutin group 6 controls	12 in bevacizumab group 10 in ranibizumab group 12 in pegaptanib group 12 controls	12 in triamcinolone group 10 in triamcinolone + benzyl alcohol group 12 in benzyl alcohol group 12 controls	11 in 2.5 mg adalimumab group 10 in 1.25 mg adalimumab group 11 in BSS group 11 controls
Rabbit age at start (Months)	7-8	6	4	9-12
Route of drug administration and drug concentration	Orally: rifabutin (10 mg/kg body weight) or vehicle (controls)	Intravitreal injection, right eye: bevacizumab (1.25 mg, 0.05 mL), ranibizumab (0.5mg, 0.05mL), pegaptanib (0.3mg, 0.09mL) BSS (0.05mL) (controls)	Intravitreal injection, right eye, 0.05 mL of: triamcinolone and benzyl alcohol (4 mg and 1 mg), purified triamcinolone (4mg), benzyl alcohol (1mg) or BSS (controls)	Intravitreal injection, right eye, 0.05 mL of: adalimumab 1.25 or 2.5 mg, BSS, or not injected (controls)
FfERG	FfERG 11 times before medication and during the study. Ophthalmoscopic examination.	FfERG before injection, and 8 weeks after injection. Ophthalmoscopic examination.	FfERG before injection, 1 and 7 weeks after injection. Ophthalmoscopic examination.	FfERG before injection, 1 and 7 weeks after injection Ophthalmoscopic examination
Ophthalmoscopic examination and macroscopic inspection of tissues	Yes	Yes	Yes	Yes
MfERG	No	MfERG before injection, and 9 weeks after injection.	No	No
Histology	Immuno-histochemistry for glial fibrillary acidic protein, protein kinase alpha, vimentin, peanut agglutinin.	Hematoxylin and eosin. Immuno-histochemistry for glial fibrillary acidic protein, protein kinase alpha, calbindin, parvalbumin, rhodopsin. Lectin against peanut agglutinin.	Hematoxylin and eosin. Immuno-histochemistry for glial fibrillary acidic protein, protein kinase alpha, calbindin, parvalbumin, rhodopsin. Lectin against peanut agglutinin	Hematoxylin and eosin. Immuno-histochemistry for glial fibrillary acidic protein, protein kinase alpha, calbindin, parvalbumin, rhodopsin. Lectin against peanut agglutinin
Study period	15 months	9 weeks	7 weeks	6 weeks
Statistics used	ERG: Wilcoxon signed rank test. Histology: descriptive analysis	ERG: Mann–Whitney U test and Wilcoxon signed rank test. Histology: Mann-Whitney U test and descriptive analysis	ERG: ANOVA mixed model and Mann–Whitney U test. Histology: Mann–Whitney U test and descriptive analysis.	ERG: ANOVA mixed model Histology: Kruskal Wallis one-way analysis of variance and descriptive analysis.

Animals

Mixed-strain, Swedish lop-eared rabbits, with a body weight of approximately 3 kg, was used in the studies described in this thesis. The rabbits came from a breeder who has bred this strain for 30 years. This strain was originally developed by interbreeding normal-sized Swedish lop-eared rabbits and dwarf lop-eared rabbits, producing animals that weigh approximately 3 kg at 4 months. They were all pigmented, with varied colors, i.e. no albino phenotypes. The rabbits were housed at the breeder in separate cages, with provided with standard nutrition and water ad libitum. The rabbits were randomized into study groups or control groups, and examined with ERG before exposure to medication, and during the course of the study. At the end of the studies, the rabbits were euthanized by an intravenous overdose of pentobarbital. The eyes were immediately enucleated and fixed. The retinas were sectioned and processed for hematoxylin and eosin staining, and for immunohistochemical investigation. For number of rabbits involved in each study, and age at start of study, see **Table 1**. The study was conducted with the approval of the Ethics Committee for Animal Research at Lund University, Sweden, and all procedures were performed in compliance with the guidelines of the Association for Research in Vision and Ophthalmology.

Drug administration

For overview see **Table 1**.

In Study 1, seven rabbits received a daily oral dose of rifabutin (10 mg/kg body weight) for 15 months. Six rabbits received only the vehicle, and were used as controls.

In Study 2, 3 and 4, the drugs were administered by intravitreal injection into the right eye. The eye was first anesthetized with oxybuprocaine 0.4% eye drops (Chauvin, Bausch and Lomb) and a lid speculum was placed under the eyelid. The drug was then injected 1.5 mm behind the limbus into the vitreal body using a 30-gauge needle. Care was taken to avoid touching the lens with the needle.

In Study 2, forty-eight rabbits were randomized into 4 groups. They were given one intravitreal injection of bevacizumab (1.25 mg, 0.05 mL), ranibizumab (0.5 mg, 0.05 mL), pegaptanib (0.3 mg, 0.09 mL) or 0.05 mL balanced salt solution (BSS) in the right eye. The group injected with BSS served as a control group.

In Study 3, forty-eight rabbits were randomized into 4 groups. The rabbits in three of the groups were given one intravitreal injection with a volume of 0.05 mL, containing TA and the preservative BA (4 + 1 mg), or unpreserved TA (4 mg), or the preservative BA (1 mg) in the right eye. The fourth group was given the same volume of BSS, and served as a control group.

In Study 4, forty-eight rabbits were randomized into 4 groups. Two groups were given an intravitreal injection of 0.05 mL adalimumab at one of two concentrations (1.25 mg or 2.5 mg) in the right eye. The third group was given 0.05 mL BSS, and the fourth group given no injection at all.

Full-field ERG and multifocal ERG

Standardized ffERG, slightly modified for the rabbit by placing the ground electrode on the neck and by not using light adaptation preceding the 30 Hz flicker stimulation, were recorded with a Nicolet analysis system (Nicolet Biomedical Instruments, Madison Wisconsin, USA) as described previously (Görloff-Wallenten K, Andréasson S, 2004). During the examination the rabbits were sedated by an intramuscular injection of Hypnorm^R (fentanylcitrate 0.315 mg /mL and fluanisone 10 mg/ml), 0.1 mL/kg. The ffERG examinations were conducted according to standards of the International Society for Clinical Electrophysiology of Vision (Marmor M, Fulton AB 2008). The right eye was tested after maximal pupil dilation using a topical application of 1% cyclopentolate hydrochloride (Chauvin, Bausch and Lomb, Stockholm, Sweden), and after 30 minutes of dark adaptation. A Burian-Allen bipolar ERG contact lens electrode was applied to the topically anesthetized cornea together with a subcutaneous ground

electrode on the neck as seen in **Figure 2**. Responses were obtained with a wide-band filter (-3 dB at 1 Hz and 500 Hz) following stimulation with single full-field flashes (30 μ s) and with 30 Hz flickering white light.

Rod responses were obtained under dark-adapted conditions by stimulation with single full-field flashes (30 μ s) with dim blue or dim white light, and combined rod and cone responses with a single white light flash (W1.0) (integrated luminance 3.93 $\text{cd}\cdot\text{s}/\text{m}^2$). The cone-mediated response was obtained with 30 Hz flickering white light (integrated luminance 0.81 $\text{cd}\cdot\text{s}/\text{m}^2$), averaged over 20 sweeps, and with a light-adapted single flash (integrated luminance 3.93 $\text{cd}\cdot\text{s}/\text{m}^2$) with background illumination.

The luminance of the different light stimuli had been measured on the light reflected from a Ganzfeld sphere (350 Linear/Log Optometer, Graseby Optronics, calibrated by UDT Instruments, Baltimore, MD, USA). The recordings were repeated at each stimulus intensity, to ensure reproducibility (i.e., two consecutive identical responses were obtained).

Multi-focal ERG was carried out as described previously (Gjörloff K, Andréasson S et al., 2006) using the VERIS Science 4.3 system (Visual Evoked Response Imaging System; EDI, San Mateo, CA, USA), developed by Sutter et al. In the anti VEGF study, study 2, the rabbits were examined with mfERG 1 week prior to intravitreal injection, and 9 weeks post-injection. During the examination, the rabbits were sedated by an intramuscular injection of a combination of ketamine (35 mg/kg) and xylazine (5 mg/kg). The pupil was dilated to a size of 8-9 mm as described above, using topical cyclopentolate hydrochloride (1%). The animals were kept in normal room light (120 lux) one hour before examination. A (Hansen Ophthalmic Development Laboratory, Iowa City, IO, USA) was applied. The lens was lubricated with methylcellulose (2%). A needle was inserted into the skin on the neck, as ground electrode, as described above. The stimulus consisted of 103 unscaled hexagons, delivered by a miniature cathode ray tube seen in **Figure 3**.

The frame of the monitor changed every 13.3 ms; each hexagon having a 50% chance of displaying a brief flash (white) or no flash (black). The pattern seems to flicker randomly, but each element follows a fixed, predetermined sequence (the m-sequence). The equipment was calibrated according to the manufacturer's instructions regarding both the grid and the luminance. The light intensity in the recording area was 0.110 lux. Two additional blank, dark

frames were inserted into every m-sequence, as this was empirically found to increase the signal differences in different parts of the trace arrays. The signal gain was 100 000, and the filter range 3-300 Hz with no additional notch filtering. The luminance flickered between light and dark according to a pseudorandom binary m-sequence of 75 Hz, with a mean stimulus luminance of 16.6 cd/m². Spatial averaging was set to 17%, as in the VERIS Clinic settings. One iteration of the artifact removal rejection system (included in the VERIS software program) was used.

During the mfERG the fundus of the rabbit eye was visualized using an infrared camera so that the stimulus pattern was consistently placed with the optic nerve head in the upper central part of the recording area.

At the end of each recording, a fundus photograph derived from the infrared detection system was taken to document the correct fundus position (**Figure 3**). Instead of the traditional circular grouping for summed analysis of the mfERG responses, three different areas in the mfERG response were defined in order to obtain a more logical grouping based on the anatomy of the rabbit retina, with the visual streak running horizontally over the upper part of the defined area:

1. the upper 3 rows of hexagonal responses representing the optic nerve,
2. 3 rows representing the visual streak, and
3. the remaining 5 rows representing the visually sensitive central part of the retina.

Amplitude and the latency of the summed responses were analyzed in these three areas.

Study of the effects of rifabutin

The effects of rifabutin were investigated in Study 1 using ffERG, as described.

Rod response was measured as the dark-adapted response to a single flash of dim white light, 2.5 log units below the standard flash (integrated luminance 0.81 cd·s/m²), by adding a neutral density (ND) filter. The combined rod and cone response was measured as the dark-adapted response to a single flash of bright white light (integrated luminance 3.93 cd·s/m²). Cone response was measured as the light-adapted response to a single flash of bright white light (3.93 cd·sm²) with background illumination, and using 30 Hz flickering white light (0.81 cd·s/m²) averaged over 20 sweeps with background illumination.

Study of the effects of VEGF inhibitors

The effects of VEGF inhibitors were studied in Study 2, as follows. Rod response was measured as the dark-adapted response to a single flash of dim blue light (Wratten filter # 47, 47a and 47b combined) (integrated luminance $0.0045 \text{ cd}\cdot\text{s}/\text{m}^2$). The combined rod and cone response was determined as the dark-adapted response to a single flash of white light ($3.93 \text{ cd}\cdot\text{s}/\text{m}^2$). The cone response was measured using 30 Hz flickering white light ($0.81 \text{ cd}\cdot\text{s}/\text{m}^2$) averaged over 20 sweeps without background illumination. Cone response of central retina was studied using mfERG as described.

Study of the effects of triamcinolone acetonide and benzyl alcohol

The effects of TA and BA (Study 3) were investigated as follows. Rod response was measured as the dark-adapted response to a single flash of dim white light, 2.5 log units below the standard flash (integrated luminance $0.81 \text{ cd}\cdot\text{s}/\text{m}^2$) by adding a ND filter. The combined rod and cone response was measured as the dark-adapted response to a single white flash at two different intensities: low, integrated luminance $0.81 \text{ cd}\cdot\text{s}/\text{m}^2$ and high, $3.93 \text{ cd}\cdot\text{s}/\text{m}^2$. The cone response was measured with 30 Hz flickering white light ($0.81 \text{ cd}\cdot\text{s}/\text{m}^2$) averaged over 20 sweeps without background illumination.

Study of the effects of adalimumab

The effects of adalimumab were investigated in Study 4, as follows. Rod response was measured as the dark-adapted response to a single flash of dim white light ($0.81 \text{ cd}\cdot\text{s}/\text{m}^2$) by adding a ND filter. The combined rod and cone response was measured as the dark-adapted response to a single flash of white light ($3.93 \text{ cd}\cdot\text{s}/\text{m}^2$). The cone response was measured with a single flash of white light ($3.93 \text{ cd}\cdot\text{s}/\text{m}^2$) with background illumination as well as with 30 Hz flickering white light ($0.81 \text{ cd}\cdot\text{s}/\text{m}^2$) averaged over 20 sweeps without background illumination.

Histology

Tissue preparation

After the last ERG examination the rabbits were euthanized with an intravenous overdose of barbiturates. The eyes were immediately enucleated and fixed for 30 minutes in 0.1 M Sørensen's phosphate buffer, at pH 7.4, containing 4% paraformaldehyde (Merck, Darmstadt, Germany). The bulbs were then transected at the ora serrata and the anterior and posterior segments separated. The posterior segments were postfixated in the same fixative for 3.5 hours, at 4°C. The tissue was rinsed and cryoprotected by transferring it stepwise through two solutions containing 10% and 20% sucrose in Sørensen's buffer. The posterior segments were divided into two by a vertical incision from the superior to the inferior retinal margins through the center of the optic disc. The posterior segments were then embedded in Yazulla medium (30% egg albumen and 3% gelatin in water) and sectioned (12 µm) in a cryostat (-21°C). The sections were collected on chrome-alum-coated slides, air dried and stored at -20°C until analyzed.

Immunohistology

Glial fibrillary acidic protein, protein kinase C alpha, vimentin, calbindin, parvalbumin & rhodopsin

The sections were thawed and rinsed in 0.1 M sodium-phosphate-buffered saline, (PBS) pH 7.2, with 0.25% Triton X-100 (PBST). Bovine serum albumin (1%) was added to the PBST to dilute the primary and secondary antibodies. The sections were then incubated with the primary antibodies for 16-18 h at 4°C. After 1 hour at room temperature, the slides were rinsed in PBST and further incubated with the appropriate fluorescent secondary antibodies (1:200), for 45 min in darkness. After rinsing, the slides were mounted in a custom-made anti-fading mounting medium. The same labeling procedure but without the primary antibody was performed to obtain negative control samples. To confirm their efficacy, the primary antibodies were used on sections that have previously stained positive for glial fibrillary acidic protein (GFAP), protein kinase C alpha (PKC α), calbindin, parvalbumin and rhodopsin, respectively. Specimens were also stained with hematoxylin and eosin. The slides were examined using immunofluorescence

imaging and photographed using a digital camera (Nikon Eclipse 800). The same exposure time and aperture were used for each kind of staining, and the same magnification (x40) was used for all photographs. No image processing was applied to the photographs.

Peanut agglutinin

The sections were thawed and rinsed in 0.1 M PBS, pH 7.2. They were first incubated for 45 minutes in biotinylated peanut agglutinin (PNA) in PBS (1:500), and then in rhodamine-conjugated streptavidin in PBS (1:1000) for 30 minutes. After rinsing with PBS, the slides were mounted in the same custom-made anti-fading mounting medium. The same labeling procedure but without the primary antibody was performed to obtain negative controls. PNA staining was classified as either positive or negative for each individual. As a positive control, PNA labeling was performed on normal adult rabbit retina. The slides were examined using immunofluorescence imaging and photographed using the digital camera. No image processing was applied.

Table 2.

Mono-clonal antibody against:	Vimentin	Glial fibrillary acidic protein	Peanut agglutinin	Calbindin	Rhodopsin	Parvalbumin	Protein kinase C alpha
Target cells	Müller cells and astrocytes	Activated Müller cells and astrocytes	Cone photoreceptors	Horizontal cells	Rod photoreceptors	Amacrine cells	Rod bipolar cells

STATISTICAL ANALYSES

Statistical analyses used in each study are also presented in **Table 1**.

All analyses were performed using SPSS Statistics 18 or 20 (IBM Corporation, Somers, NY, USA).

Analyses used for the effects of rifabutin

In the analysis of the ffERG results in this study, the Wilcoxon signed rank test was used. It is a non-parametric test, accommodating for ERG parameters which are positively skewed in distribution, comparing two related samples.

The results of the histological examinations were evaluated using descriptive analysis.

Analyses used for the effects of VEGF inhibitors

ERG results from the study on effects of VEGF inhibiting substances, were analyzed using two non-parametric tests. The Mann–Whitney U test was used for testing two independent groups against each other and the Wilcoxon signed rank test for comparing two related samples.

For the statistical analysis of the histology results, PKC α -labeled rod-bipolar cells were counted using the method previously described by Kjellström et al., i.e. the number of stained perikarya and axons/terminals per window on photographs obtained under the microscope with the x40 objective in one representative retinal section (Kjellström U, Bruun A, et al., 2009). The scores for the perikarya and axons/terminals were compared separately. The investigator was blinded to the identity of the retinal sections of PKC α -labeled cells. Comparative statistical analyses were carried out using Mann–Whitney U test.

The results of the other histological examinations were evaluated using descriptive analysis.

Analyses used for the effects of triamcinolone acetonide and benzyl alcohol

ffERG results from the study on effects of triamcinolone and its preservative benzyl alcohol, were analyzed using two tests. Mann-Whitney U test was used to compare data from the rabbits injected with the 3 different active substances, to results from BSS-injected rabbits. The data were corrected for mass significance by multiplying the p-values by 3. The ANOVA Mixed Model test was also applied. The different ERG parameters were analysed separately, using the same procedure. First, an overall analysis of the effect of treatment at both times post-injection simultaneously was performed using mixed model analysis with repeated measurements. In that model the measurements at the two times post-injection were assumed to be dependent, and different covariance structures were tried to model the dependence. However, the different structures gave similar results and finally an AR(1)(first order autoregressive) model was chosen. Treatment, time, and the interaction between treatment and time were assumed to be fixed factors in the mixed model. In addition, the pre-injection measurements were included as a linear covariate. In the second step of the analysis, the results at the two points in time post-injection were analysed separately using an ANOVA model with treatment as a fixed factor, and the pre-injection measurement was applied as a linear covariate. An overall treatment effect was estimated using this model, in addition to comparisons of the effects of TA+BA, TA and BA, to BSS. For the statistical analysis of the histology results, PKC α -labeled rod-bipolar cells were counted using the method previously described by Kjellström et al., i.e. the number of stained perikarya and axons/terminals per window on photographs obtained under the microscope with the x40 objective in one representative retinal section (Kjellström U, Bruun A, et al., 2009). The scores for the perikarya and axons/terminals were compared separately. The investigator was blinded to the identity of the retinal sections of PKC α -labeled cells. Comparative statistical analyses were carried out using Mann–Whitney U test.

The results of the other histological examinations were evaluated using descriptive analysis.

Analyses used for the effects of adalimumab

The four groups were compared using ANOVA Mixed Model analysis. The ffERG parameters at 1 and 6 weeks post-injection were compared, using the pre-injection value as covariate. An overall

analysis of the treatment effect at both post injection time points simultaneously was performed using a mixed model analysis with repeated measurements. In that model the measurements at the two time points were assumed to be dependent and different covariance structures were tried out to model the dependence. However, the different structures gave similar results and finally an AR(1)(first order autoregressive) model was chosen.

For the statistical analysis of the histology results, PKC α -labeled rod-bipolar cells were counted using the method previously described by Kjellström et al., i.e. the number of stained perikarya and axons/terminals per window on photographs obtained under the microscope with the x40 objective in one representative retinal section (Kjellström U, Bruun A, et al., 2009). The scores for the perikarya and axons/terminals were compared separately. The investigator was blinded to the identity of the retinal sections of PKC α -labeled cells. Comparative statistical analyses were carried out using the Kruskal-Wallis one-way analysis of variance, which is a non-parametric alternative to the one-way analysis of variance (ANOVA). Descriptive analyses were performed without further quantification for the other antibodies.

RESULTS

The effects of long-term oral administration of rifabutin

Easily detectable and reproducible ffERG responses were obtained in dark- and light-adapted states without the use of additional filters. Rifabutin was detected in the serum of all the medicated rabbits four months after medication and in none of the controls. During the treatment period a progressive decline was seen in ffERG amplitudes. The ffERG responses after 15 months of oral treatment with rifabutin were compared to those before treatment. A reduction was seen in the isolated rod response, in the combined dark-adapted rod and cone response (a- and b-waves), and in the isolated cone response. The implicit time of the 30 Hz flicker was prolonged. Only a subtle yellow discoloration was seen in the corneas of the treated rabbits, while a very distinct yellow/brown discoloration of the lens was seen in all the rifabutin-treated animals, but not in any of the control animals. No retinal pathology was found using immunohistochemical methods.

The effects of VEGF inhibitors

Easily detectable and reproducible ERG responses were obtained in the dark- and light-adapted states. No additional filters had to be added

The groups injected with VEGF inhibitors all showed a significantly lower b-wave amplitude in the rod-mediated response: bevacizumab ($p=0.028$), ranibizumab ($p=0.025$), and pegaptanib ($p=0.008$). No difference was seen in the b-wave in response to a single flash of bright white light or to 30 Hz flicker. The statistical analysis, comparing data before and 8 weeks after injection, showed a significant increase in the amplitude of the rod-mediated response in the group given a BSS injection ($p=0.006$). This increase was not seen in the animals given VEGF inhibitors. The total retinal response and the isolated cone-mediated response were similar, and showed no change in any of the groups after injection. No statistically significant differences were seen in mfERG responses between the medicated groups and the control group.

On immunohistochemical examination, significantly fewer labeled rod bipolar cells (perikarya and/or axons) were seen in the groups given pegaptanib or ranibizumab than in the BSS group (pegaptanib: p perikarya= 0.0001 , p axons= 0.0001 , ranibizumab: p perikarya= 0.007 , p axons= 0.552). Hematoxylin–eosin-stained slides showed normal retinal architecture with no signs of vacuoles or edema in all the groups. No difference was seen in PKC α labeling of the bipolar cells between the bevacizumab group and the BSS group (p perikarya= 0.862 , p axons= 0.225).

Immunohistochemical tests were carried out for rods (rhodopsin), bipolar cells (PKC α), amacrine cells (parvalbumin), horizontal cells (calbindin), and activated Müller cells (GFAP) and with a lectin against cones (biotinylated PNA) and showed similar results for the medicated and BSS groups.

The effects of TA and BA

Immediately after the injection of TA or TA+BA, a white substance was seen inferiorly in the vitreous. When the animals were sacrificed, 7 weeks after the injection, a white substance was found inferiorly in about 50% of the eyes. At the end of the study, retinal detachment was seen in

the eye of one rabbit in the TA+BA group. This rabbit was excluded from the study. Ophthalmoscopic examination and dissection of the eyes from the other rabbits showed that the retinas had remained attached.

The fFERG responses obtained in the dark- and light-adapted state were easily detectable and reproducible. No additional filters were necessary.

Two methods were used to test statistical difference Mann –Whitney’s U test and ANOVA mixed model. The results are given in **Table 3**.

Table 3.

	<i>ANOVA Mixed Model Overall treatment effect</i> <i>p-value</i>	<i>ANOVA Mixed Model Overall treatment effect 1 week</i> <i>p-value</i>	<i>ANOVA Mixed Model Overall treatment effect 7 weeks</i> <i>p-value</i>	<i>Mann-Whitney U test Compared to BSS 1 week post inj.</i> <i>p-value</i>	<i>Mann-Whitney U test Compared to BSS 7 weeks post inj.</i> <i>p-value</i>
WND2 b-wave amplitude	0.013	0.004	>0.05	BA 0.021 TA >0.05 TA+BA >0.05	BA >0.05 TA >0.05 TA+BA >0.05
W0.25 b-wave amplitude	0.004	0.001	>0.05	BA >0.05 TA 0.035 TA+BA 0.004	BA >0.05 TA >0.05 TA+BA >0.05
W1.0 b-wave amplitude	0.013	0.007	>0.05	BA >0.05 TA 0.037 TA+BA 0.016	BA >0.05 TA >0.05 TA+BA >0.05
Flicker b-wave amplitude	>0.05	0.002	>0.05	BA >0.05 TA 0.002 TA+BA >0.05	BA >0.05 TA >0.05 TA+BA >0.05
W0.25 a-wave amplitude	0.002	0.038	0.012	BA >0.05 TA >0.05 TA+BA >0.05	BA >0.05 TA 0.002 TA+BA >0.05
W1.0 a-wave amplitude	0.002	0.005	>0.05	BA >0.05 TA >0.05 TA+BA >0.05	BA >0.05 TA >0.05 TA+BA >0.05

Hematoxylin–eosin-stained slides showed normal retinal architecture without signs of vacuoles or edema in all groups. Immunohistochemical examination showed that fewer rod bipolar cells were labeled with the PKC α antibody in the TA, TA+ BA and BA groups, than in the group given BSS (in the TA+BA group: $p=0.001$ for perikarya, and $p=0.0001$ for axons/terminals; in the TA group: $p=0.016$ for perikarya and $p=0.011$ for axons/terminals; and in the BA group: $p=0.018$ for perikarya and $p=0.001$ for axons/ terminals). Immunohistochemical tests for rods (rhodopsin), amacrine cells (parvalbumin), horizontal cells (calbindin) and activated Müller cells (GFAP), and using a lectin against cones (biotinylated peanut agglutinin) showed similar results for the medicated and BSS groups.

The effects of adalimumab

The ERG responses in this study (Paper 4) were also clear and reproducible.

Five rabbits were excluded, one died after baseline ffERG and four died 1 week after injection (one in the non-injected group, one in the BSS group, two in the group injected with 1.25 mg adalimumab and one in the group injected with 2.5 mg adalimumab), leaving 11 rabbits in the non-injected group, 11 in the BSS group, 10 in the 1.25 mg adalimumab group and 11 in the 2.5 mg adalimumab group. The ERG parameters at 1 and 6 weeks post-injection were compared using the pre-injection value as a covariate. Simultaneous overall analysis of the treatment effect, at both 1 and 6 weeks post-injection, done simultaneously using a mixed model analysis with repeated measurements, showed no significant difference in ERG amplitudes between the four groups at any time point. Ophthalmoscopic examination and dissection of the right eye showed that all the retinas were attached, and there were no cataracts in any of the eyes. Hematoxylin–eosin-stained slides showed normal retinal architecture with no signs of vacuoles or edema in all the groups.

Immunohistochemistry for rod bipolar cells (PKC α), rods (rhodopsin), amacrine cells (parvalbumin), horizontal cells (calbindin) and activated Müller cells (GFAP), and using a lectin against cones (biotinylated peanut agglutinin) showed similar results in the medicated and BSS groups.

DISCUSSION

When new drugs are introduced, their effects on different systems in the body must be carefully assessed in order to identify possible adverse effects. Furthermore, the routes of administration in ocular medication have changed. Since the introduction of VEGF inhibitors for the treatment of neovascular AMD, injection into the vitreous body has become a routine procedure. In this work, retinal function and morphology have been studied after the administration of 4 different types of medical drugs, one given orally, and the 3 others by injection into the vitreous body, using a rabbit model, ERG and histochemistry. Adverse effects have been found for 3 of these drugs, while the fourth has been found to be safe for injection into the rabbit eye. Our research group has previously developed a method for examining rabbits with ERG, using the same equipment as that used for human ERG (Gjörloff K, Andréasson S et al., 2004). The ERG amplitudes have been found to be easily detectable and reproducible.

Rifabutin is a highly effective drug, valuable in the treatment of mycobacterial and staphylococcal infections. The ocular side effects in rabbits appear to be similar to those previously observed in a patient undergoing long-term treatment with rifabutin (Ponjavic V, Gränse L et al., 2002). The progressive decrease in ERG amplitudes, in combination with the absence of pathological findings using immunohistochemical methods, implies a functional impairment rather than structural damage. It could be argued that the discoloration of the lens may reduce the ERG amplitude. However, the retinal function in the reported patient increased to normal levels after the discontinuation of rifabutin, despite remaining lens discoloration (Ponjavic V, Gränse L et al., 2002). The discoloration of the lens was similar in appearance to that observed in the rabbits in the present study (Paper 1). The specific composition of the substance accumulated in the lens and cornea is not known, but similar discoloration of several organs has been described by Brughera to be due to a lipofuscin-like material (Brughera M, Scampini G et al., 1995). In summary, the use of rifabutin significantly reduced both total rod and cone function and isolated cone function, but did not appear to affect the retinal morphology in rabbits. The results of this study (Paper 1) indicate that rifabutin accumulates in the rabbit eye in a similar way to the human eye. Further studies on drug mechanisms in the eye and their possible reversibility are

needed to ensure safe treatment of patients.

The results of the second study indicate that intravitreal injection of VEGF-inhibiting substances has pathological effects on normal rabbit retina. ERG examination 8 weeks after injection showed that pegaptanib, bevacizumab, and, to a lesser extent, ranibizumab, all led to a significant reduction in the amplitudes of the isolated rod response, the b-wave dark-adapted response to dim white light, compared to the responses in the BSS group. The difference in reactions seen in the three groups given the different VEGF inhibitors may be due to differences in molecular structure and size, and action of the inhibitors. Pegaptanib is an aptamer, a small molecule neutralizing only one isoform of VEGF-A. Both ranibizumab and bevacizumab inhibit all isoforms of VEGF-A. Ranibizumab is a very strong inhibitor of VEGF, potentiated compared to bevacizumab, and it is also a smaller molecule, with a shorter half-life in the vitreous body. It has been reported that bevacizumab, but not ranibizumab, accumulates in the RPE cells over time, implying substantial differences between these two drugs (Klettner AK, Kruse M-L et al., 2009). To determine whether VEGF inhibitors affect the photoreceptors, the a-wave response to a single flash of white light was studied. No statistically significant differences were found between the groups. This could indicate that the change in the isolated rod response (i.e. the b-wave amplitude of the dark-adapted response to a single flash of dim light) represents a change in retinal function not derived from the photoreceptors, but from bipolar cells. This is supported by the reduced PKC α labeling of rod bipolar cells in the pegaptanib and ranibizumab groups, and by the normal rhodopsin labeling seen in all groups. PKC α is an important enzyme for phototransduction, and when activated it is depleted after translocation from the perikarya to the terminal (Wood JPM, McCord RJ et al., 1997). In the pegaptanib group, both rod bipolar perikarya and axons exhibited reduced PKC α labeling, while in the ranibizumab group, the enzyme could often be seen in the axons but not in the perikarya. Chemically blocking the outer nuclear bipolar cells eliminates the b-wave (Hood DC, Birch DG, 1996), and the observed changes in retinal morphology in eyes into which VEGF inhibitors were injected correlated well with the ffERG results in our study, indicating that these substances affect the function of the retinal rod bipolar cells.

A recent clinical study demonstrated a reduction in the function of cone photoreceptors three months after intravitreal injection of bevacizumab in patients with AMD, indicating that VEGF inhibition also has a negative effect in humans (Pedersen KB, Møller F et al., 2010). The retinal anatomy of rabbits differs from that in humans in that they have very few cones, and a rod-dominated retina, possibly explaining the observed effect of VEGF inhibition on rod-mediated ERG response only. The significance of changes in bipolar cell function and morphology is difficult to evaluate from a clinical perspective, but may be of special interest in the treatment of ROP. The doses of VEGF inhibitors were chosen with the intention of achieving a high concentration in the vitreous body, corresponding to the relatively high doses used in the treatment of ROP (Wu WC, Yeh PY et al., 2010)(Kusaka S, Shima C et al., 2008). VEGF inhibition has shown promising results in ROP, and it is possible that the favorable effects are, at least in part, due to PKC downregulation (Xia P, Aiello LP et al., 1996). The observed effects on retinal bipolar function and morphology should, however, be interpreted with caution, as the effects of long-term use of high-dose VEGF inhibitors in the premature eye have yet to be evaluated.

In summary, the results of Study 2 show that VEGF inhibition influences not only vascular pathology, but also retinal function, and the expression of PKC. These results, which would not be apparent to the ophthalmologist when testing visual acuity or by fundus examination, are important additions to the possible side effects of the expanding group of therapies involving VEGF inhibition.

Paper 3 describes significant effects following the intravitreal injection of triamcinolone acetonide or benzyl alcohol, as well as the combination of the two, on rabbit retina. The paper presents a detailed investigation of short- and long-term ERG responses, using several stimulus modalities, and an analysis of the expression of several important retinal subtype proteins.

The preservative alone, BA, had a transient effect on the isolated rod-mediated ERG response. This means that visual parameters based on cone function, such as visual acuity and color vision, used in the clinical setting, may fail to reveal the adverse effects of some drugs on retinal function. TA alone, and together with its preservative, had a transient effect on the amplitude of the combined rod-cone response. TA alone had an effect on the b-wave response to 30 Hz flicker

and, an effect on the a-wave amplitude. The changes in ERG amplitudes resulting from the administration of TA and BA correlated well with the immunohistochemical findings, indicating that TA and BA may affect the retina by mechanisms still unknown. Furthermore, the significant effect on the a-wave amplitude in the combined response to single-flash white light remained 7 weeks post-injection, indicating that this specific effect is not transient, which was further supported by the immunohistochemical results.

The results described above demonstrate that the injection of TA+BA affects retinal function and morphology up to 7 weeks post-injection, which may have important clinical implications on the expanding field of intravitreal pharmacology.

The study presented in Paper 4 indicates that adalimumab, a fully humanized monoclonal antibody against the cytokine TNF α , is safe for intravitreal use in the rabbit eye, at doses up to 2.5 mg. Full-field ERG amplitudes were not affected by the injection of adalimumab, indicating that it caused no functional disturbances. Likewise, normal retinal architecture was seen with hematoxylin–eosin staining. No difference in the labeling of rods, cones, rod bipolar cells, horizontal or amacrine cells was detected in any of the groups using immunohistochemical tests on retinal sections.

The recommended route of administration of adalimumab is subcutaneous injection. To avoid systemic adverse effects, and to achieve a satisfactory drug concentration in the eye, the vitreous may be used as a reservoir. Since the introduction of VEGF inhibitors for the treatment of neovascular macular degeneration, injection into the vitreous body has become a routine procedure. It offers a way of delivering an accurate dose directly to the target organ, decreasing systemic exposure. Using tracers, Peyman et al. reported that when a substance was injected into the vitreous body it traveled across the retina and stopped at the junctional complexes of the retinal pigment epithelium, and, similarly, a substance injected into the systemic circulation passed through the choriocapillaris and Bruch's membrane and stopped at the junctional complexes of the retinal epithelium and retinal endothelial cells. (Peyman GA, Conway MD et al., 2009). However, as the blood-retina barrier is circumvented, toxicological testing using the same route will be necessary. As the appropriate therapeutic dose of adalimumab for intravitreal use has not been determined, two empiric doses of 1.25mg/0.05 mL and 2.5 mg/0.05 mL

adalimumab were chosen. The eye constitutes about 0.012% of the total bodyweight, assuming that the average weight of a human being is 65 kg and that the eye weighs 7.5 g. The recommended starting dose for subcutaneous administration of adalimumab is 40 mg every 14 days. Dosing according to weight would give a dose to the eye of 0.5 mg adalimumab. As the goal is to avoid repetitive intravitreal injections, as far as possible, the higher doses of 1.25 and 2.5 mg were chosen.

Considering that the volume of the vitreous cavity of the rabbit eye is smaller than that of the human eye (1.5 vs. 4.0 mL), the dose of adalimumab that is safe for the human eye may be higher than the 2.5 mg injected in this study. The obvious potential indication for intravitreal use of adalimumab is sight threatening, noninfectious uveitis with no or slight systemic involvement, after failure of first-line therapy.

CONCLUSIONS

New drugs are constantly being developed, modified and released onto the market, sometimes intended for the treatment of conditions that have previously been untreatable. In addition, the indications for treatments are widening. Potent medical drugs often have some adverse effects in addition to their intended actions. As ophthalmic pharmacotherapy is a rapidly evolving field and adverse medical effects are not always easily detected, experimental retinal research is of value. Four medicinal drugs, one administered systemically and three by injection into the vitreous body have been tested in a rabbit model. Retinal function has been assessed by ERG, and morphology using histochemical methods. Morphology and function of the retina do not always correlate; in some diseases, the retina may appear intact while its function is impaired. Function can be severely reduced before it is detected at a routine clinical examination. Ideally, fundus examination should be combined with an assessment of retinal function. In our clinical studies on hereditary retinal degenerative diseases and on drug-induced retinopathies, we often find this discrepancy. We have also found that many drug-induced ocular symptoms are reported and classified using nonspecific terminology because the underlying mechanisms involving the retina are not yet understood.

Long-term systemic medication of rabbits with the broad-spectrum antibiotic rifabutin leads to severe discoloration of the lens and affects retinal function, seen as a progressive decrease in ERG amplitudes. This, combined with the absence of pathological findings upon histochemical examination, implies a functional impairment rather than structural damage.

Injecting inhibitors of vascular endothelial growth factor into the vitreous affects retinal function and morphology in the healthy rabbit eye.

Intravitreal injection of crystalloid synthetic corticosteroid triamcinolone acetonide and its preservative benzyl alcohol, separately and in combination, affect retinal function and histology in healthy rabbit eyes.

The TNF α inhibitor adalimumab, a fully humanized monoclonal antibody indicated for subcutaneous injection in autoimmune diseases such as rheumatoid arthritis, ankylosing spondylitis, Behçets disease, psoriatic arthritis and juvenile idiopathic arthritis, can be injected into the vitreous of healthy rabbit eyes without disturbing retinal function or histology.

While pathology of the eye is sometimes easily detected, it is not always visible by simple inspection of the fundus. Function can be severely reduced before it is detected in a routine clinical examination. Ideally, the fundus examination should be combined with an assessment of retinal function and retinal histology. This study has shown that drugs may affect both retinal function and histology in the rabbit eye, and that retinal electrophysiology combined with histochemistry can be used to detect which retinal level and cell type are involved, or exclude retinal damage by the drug. This knowledge should alert ophthalmologists to perform extensive investigations in patients on medication who have unexplainable visual symptoms.

POPULÄRVETENSKAPLIG SAMMANFATTNING

De fyra studier som ingår i denna avhandling är gjorda för att undersöka eventuella oönskade effekter av läkemedel på näthinnan. Näthinnan är en del av det centrala nervsystemet och känslig för toxiska substanser. För att skydda näthinnan så finns två barriärer – en yttre och en inre blod–näthinne- barriär. Dessa barriärer består av strukturer som håller samman celler i retinala pigment epitelet och inuti blodkärlen hårt och tätt för att substanser inte skall släppas igenom. Trots detta så kan skadliga substanser ibland ta sig igenom. Under de senaste åren så har injektion av läkemedel direkt in i ögat blivit en mycket vanlig metod för att tillföra läkemedel. Injektion i ögat har fördelar: en exakt dos kan tillföras, som inte påverkas av eller påverkar resten av kroppen och glaskroppen kan utnyttjas som en depå. För att undersöka eventuella oönskade effekter av läkemedel så har vi använt en djurmodell, till vilken vi tillfört läkemedlet i fråga, elektrofysiologi för att undersöka näthinnans funktion före och efter tillförelse och i slutet av studien, 6-9 veckor efter tillförelse av läkemedlet, har näthinnans histologi undersökts.

Näthinnan är en tunn hinna som täcker på insidan av ögongloben. Hornhinnan och linsen bryter tillsammans ljusstrålar så att de fokuseras på näthinnan för att forma en skarp bild. Fotoreceptorer i näthinnan omvandlar ljusenergi till elektriska signaler som skickas via synnerven och synbanorna till hjärnbarken i nackloben till syncentrum. Den mänskliga näthinnan innehåller ca 130 miljoner fotoreceptorer, 92-125 miljoner stavar och 4,6- 6,8 miljoner tappar. Stavarna, som gör att vi kan se i mörker, är mycket ljuskänsliga och deras pigment, rhodopsin, bleks snabbt av ljus och de blir därigenom inaktiverade. Stavar finns spridda över hela näthinnan utom i ett område centralt, gula fläcken, macula lutea, där enbart tappar sitter, tätt ansamlade. Tapparna ger färg och detaljseende. Ett fåtal tappar finns spridda utanför gula fläcken, antalet minskar ju längre perifert man undersöker.

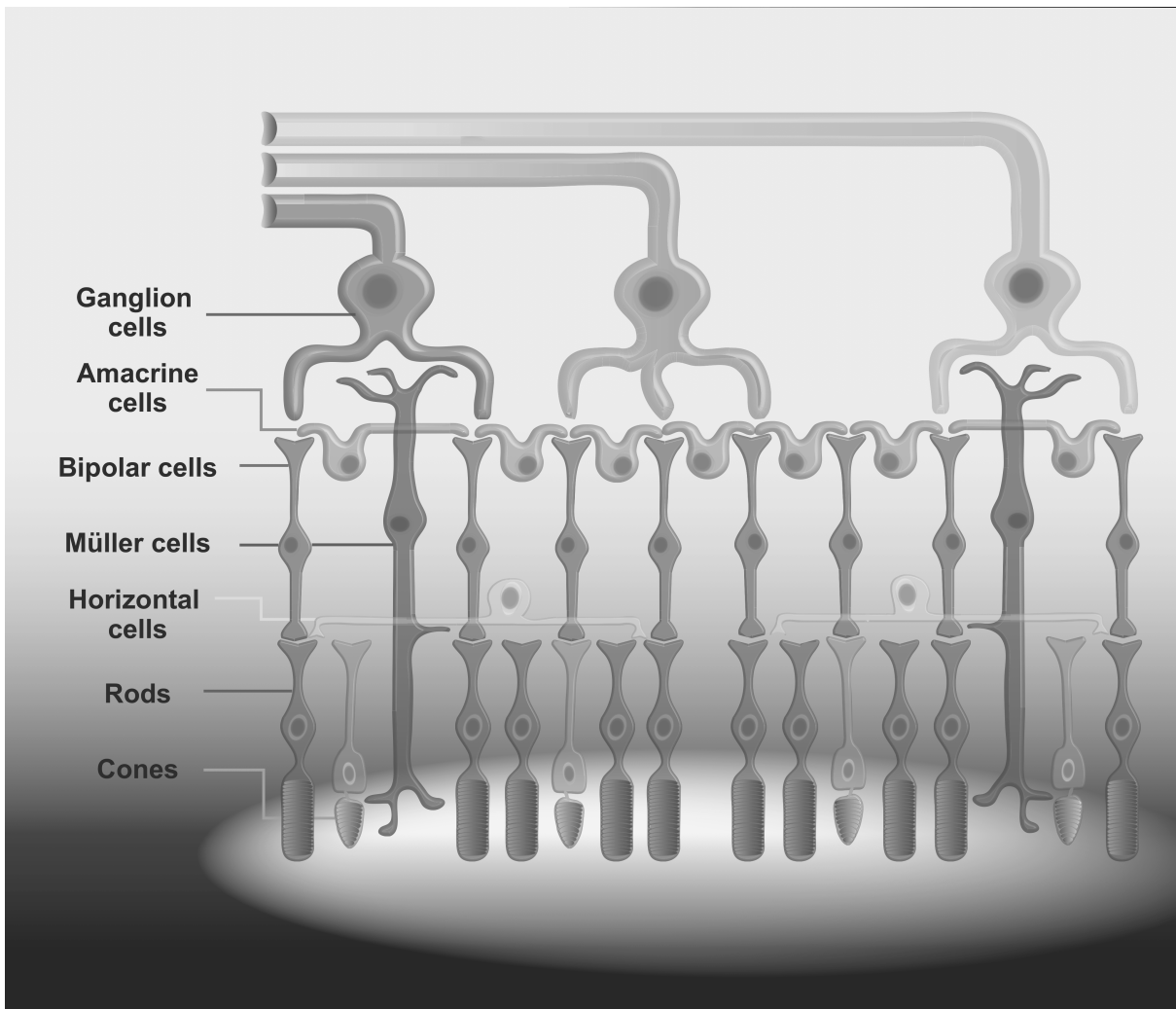


Figure 4.

Näthinnans funktion kan objektivt undersökas med fullfälts elektroretinografi (ffERG). Individens näthinna skall då vara mörker anpassad så att stavarna har förmåga att reagera på ljuset som ingår i undersökningen. En kontaktlinn placeras på hornhinnan och patienten skall se in i en Ganzfeld skärm där ljus presenteras. Genom att modulera ljusstyrka, frekvens med vilken ljuset presenteras och näthinnans mörker/ljus anpassning så kan svar från tappor och stavar särskiljas. FfERG är en bra metod för att visa global skada på tappor och/eller stavar men en dålig metod för att visa lokaliserade skador. För att kompensera för denna svaghet så utvecklades multifokal elektroretinografi, mfERG. Denna metod görs med näthinnan i ljus anpassat tillstånd och visar enbart tappars funktion. I gengäld så kan man med denna metod visa lokaliserade områden med dålig tapp funktion. Detta är mycket användbart vid åldersrelaterade förändringar i gula fläcken

(AMD, age-related macular degeneration) som är en mycket vanlig sjukdom hos äldre. Vid detta tillstånd så visar mfERG sämre funktion i gula fläcken men FfERG visar normal funktion hos både tappar o stavar eftersom att gula fläcken representerar ett mycket litet område i näthinnan och svaret härifrån drunknar i svaren från övriga fotoreceptorer i näthinnan.

I det första arbetet undersöks effekten av ett bredspektrum antibiotikum, rifabutin. Tanken att utforska rifabutin uppkom efter att en pojke med långvarig rifabutin medicinering remitterats till ögonkliniken pga. allvarliga ögonbiverkningar. För att utforska om biverkningarna uppkommit av medicineringen gavs kaniner en motsvarande dos under 15 månader och jämfördes med en grupp som inte fått substansen. Under studiens gång så visade undersökning av näthinnans funktion en progressiv sänkning av fotoreceptorernas funktion. Vävnadsundersökning av näthinnan visade inga morfologiska förändringar vid jämförelse mot kontroll gruppen, men linserna hos samtliga kaniner som fått rifabutin var kraftigt missfärgade.

I det andra arbetet undersöktes näthinnans funktion och morfologi på kaniner efter injektion av substans som hämmar tillväxtfaktorn "vascular endothelial growth factor", VEGF, i högra ögat. Vid tidpunkten för den här studien fanns 3 sådana substanser på marknaden: pegaptanib, bevacizumab och ranibizumab. Kaninerna jämfördes mot kaniner som fått balanserad saltlösning injicerad i ögat. Man fann att alla 3 substanser, i olika grad, påverkade näthinnans funktion negativt. Undersökning med mfERG visade ingen skillnad mellan medicinerade och kontroll kaniner. Vävnads undersökning av näthinnan visade minskad inmärkning av stavbipolära celler i den medicinerade gruppen, men i övrigt normal näthinna.

I den tredje och fjärde studien använde vi oss av samma modell och undersökte effekten av läkemedel som injicerats direkt in i kaninögat. Triamcinolon (Kenacort®, Kenalog®) är en syntetisk corticosteroid. I Europa säljs triamcinolon som medel för injektion vid behandling av inflammatoriska tillstånd och tillstånd där reglering av ett överaktivt immunsystem behövs. Ofta behandlas allergiska tillstånd som uppkommer under begränsad tidsperiod, så som pollenallergi, astma och inflammatoriska tillstånd i leder och muskler. Beredningen ligger i kristallform som ger en långsam utsöndring av triamcinolon under en längre period, och används därför som ett

”depot” läkemedel. Denna egenskap har gjort att man använt medlet för injektion vid lokala inflammatoriska tillstånd i ögat, utanför indikationen för läkemedlet. Vissa studier har visat att medlet är toxiskt för näthinnan, andra att det inte är det. I Europa säljs medlet alltid konserverat med benzyl alkohol medan det i USA finns beredningar utan konserveringsmedel, ämnat för injektion i ögat. Vår studie visar att både triamcinolon och konserveringsmedlet har negativ effekt på näthinnans funktion.

Adalimumab är en monoklonal antikropp riktad mot den kroppsegna inflammations höjande substansen ”tumor necrosis alpha”, TNF α . TNF α startar och underhåller inflammatorisk reaktion i kroppens vävnader. Adalimumab och andra TNF α hämmande medel har förbättrat utsikterna för patienter med autoimmuna sjukdomar, sjukdomar där kroppens immunsystem angriper den egna vävnaden, så som vid ledgångs reumatism och inflammatoriska tarmsjukdomar, genom att sänka nivån av TNF α och därmed minska inflammationen som bryter ner vävnaderna i kroppen. Vid inflammatoriska ögonsjukdomar har man funnit ökad mängd TNF α i ögat, samt att om man sprutar in substansen TNF α i ögat så uppkommer en inflammatorisk reaktion. Vi har ägnat vårt fjärde arbete åt att undersöka möjligheten att injicera TNF α hämmaren adalimumab direkt i ögat. Undersökning av näthinnans funktion och morfologi visar inga tecken till skada som följd av en injektion av adalimumab.

Avhandlingen visar att läkemedel kan påverka både näthinnans funktion och morfologi. Elektroretinografi tillsammans med vävnadsundersökningar kan visa vilka celler i näthinnan som påverkats eller utesluta påverkan på näthinna i vald djurmodell. Kunskapen bör påverka behandlade läkare till att vara uppmärksamma på eventuella syn störningar i samband med läkemedelsbehandling.

REFERENCES

- Accorinti M, Pirraglia MP, Paroli MP, Priori R, Conti F, Pivetti-Pezzi P. Infliximab Treatment for Ocular and Extraocular Behçet's Disease. *Jpn J Ophthalmol.*2007;51:191-196
- Bawazeer A, Raffa LH, Nizamuddin SH. Clinical Experience with Adalimumab in the treatment of Ocular Behçet Disease. *Ocul Immunol Inflamm.*2010; 18, 226-232
- Arevalo JF, Russack V, Freeman WR. *Ophthalmic Surg Lasers.*1997;28:321-324
- Bandello F, Parodi Battaglia M, Tremolada G, Lattanzio R, De Benedetto U, Iacono B. Steroids as Part of Combination Treatment: The Future for the Management of Macular Edema? *Ophthalmologica.*2010;224:41-45
- Becker K, Schimkat M, Jablonowski H, Häussingen D. Anterior uveitis associated with rifabutin medication in AIDS patients. *Infection.*1996;24: 34-36
- Bhisitkul RB, Winn BJ, Lee OT, Wong J, Pereira Dde S, Porco TC, He X, Hahn P, Dunaief JL. Neuroprotective effect of intravitreal triamcinolone acetonide against photoreceptor apoptosis in a rabbit model of subretinal hemorrhage. *Invest Ophthalmol Vis Sci.*2008;49:4071-4077
- Biester S, Deuter C, Michels H, Haefner R, Kuemmerle-Deschner J, Doycheva D, Zierhut M. Adalimumab in the therapy of uveitis in childhood. *Br J Ophthalmol.*2007;91:319-324
- Blanks J, Johnson LV. Specific binding of Peanut Lectin to a Class of Retinal Photoreceptor Cells. *Invest Ophthalmol Vis Sci.*1982;25:546-557
- Breton ME, Schueller AW, Lamb TD, Pugh EN Jr. Analysis of ERG a-wave amplification and kinetics in terms of the G-protein cascade of phototransduction. *Invest Ophthalmol Vis Sci.*1994; 35: 295-309
- Brogden RN, Fitton A. Rifabutin a review of its antimicrobial activity, pharmacokinetic properties and therapeutic efficacy. *Drugs.*1994; 47: 983-1009
- Brughera M, Scampini G, Newman AJ, Castellino S, Sammartini U, Mazué G. Overview of toxicological data on rifabutin. *Exp Toxic Pathol.*1995; 47: 1-9
- Casini G, Rickman DW, Brecha NC. All amacrine cell population in the rabbit retina: identification by parvalbumin immunoreactivity. *J Comp Neurol.*1995;356:132
- Chaknis MJ, Brooks SE, Mitchell KT, Marcus DM. Inflammatory opacities of the vitreous in rifabutin-associated uveitis. *Am J Ophthalmol.*1996; 122: 580-582
- Cho WB, Moon JW, Chan H K. Intravitreal triamcinolone and bevacizumab as adjunctive treatments to panretinal photocoagulation in diabetic retinopathy. *Br J Ophthalmol.*2010; 94:858-863
- Chu DS, Zaidman GW, Meisler DM, Lowder C, Jacobs DS, Rapuano CJ, Green GJ. Human immunodeficiency virus-positive patients with posterior intracorneal precipitates. *Ophthalmol.*2001; 108:1853-1857

- Cibis GW, Abdel-Latif AA, Bron AJ, Chalam KV, Tripathi B J, Tripathi RC, Wiggs J, Brown SVL. Topographic feature of the globe. *Fundamentals and principles of ophthalmology*. Liesegang TJ, Skuta GL, Cantor LB, Editor. American Academy of Ophthalmology.2003;44
- Citirik M, Dilsiz N, Batman C, Zilelioglu O. Comparative toxicity of 4 commonly used intravitreal corticosteroids on rat retina. *Can J Ophthalmology*.2009;44:3-8
- Couch SM, Bakri SJ. Intravitreal triamcinolone for intraocular inflammation and associated macular edema. *Clinical ophthalmology* 2009;3:41-47
- Coutinho AB, Cheema D, Pereira PR, Souza Filho JP, Burnier MN. Corneal endothelial deposits associated with rifabutin use. *J Ocul Pharmacol Ther*. 2005; 21:166-169
- Dick AD, Forrester JV, Liversidge J, Cope AP .The role of tumour necrosis factor (TNS-a) in experimental autoimmune uveoretinitis (EAU). *Progress in Retinal and Eye Research*.2004;23:617-663
- Elman MJ, Aiello LP, Beck RW, Bressler NM, Bressler SB, Edwards AR, Ferris FL, Friedman SM, Glassman AR, Miller KM, Scott IU, Stockdale CR, Sun JK. Randomized trial evaluating ranibizumab plus prompt or deferred laser or triamcinolone plus prompt laser for diabetic macular edema. *Ophthalmology*.2010;117:1064-1077
- Erckens RJ, Mostard RL, Wijnen PA, Schouten JS, Drent M. Adalimumab successful in sarcoidosis patients with refractory chronic non-infectious uveitis. *Graefes Arch Clin Exp Ophthalmol*.2012; 250:713-720
- Famiglietti EV, Sharpe SJ. Regional topography of rod and immunocytochemically characterized “blue” and “ green” cone photoreceptors in rabbit retina. *Vis Neurosci*.1995;12:115-175
- Fineman MS, Vander J, Regillo CD, Fineman SW, Brown GC. Hypopion uveitis in immunocompetent patients treated for Mycobacterium avium complex pulmonary infection with rifabutin. *Retina* 2001;21:531-533
- Foeldvari I, Nielsen S, Kümmerle-Deschner J, Espada G, Horneff G, Bica B, Olivieri AN, Wierk A, Saurenmann RK..Tumor necrosis factor alpha blocker in treatment of juvenile idiopathic arthritis associated uveitis refractory to second line agents: results of a multinational survey. *J Rheumatol*.2007;34:1146-1150
- Folkman J. Tumor angiogenesis: therapeutic implications. *N Engl J Med*.1971;285: 1182-1186
- Fraunfelder FW, Rosembaum JT. Drug-induced uveitis. Incidence, prevention and treatment. *Drug Safety*.1997;17:197-207
- Galor A, Perez VL, Hammel JP, Lowder CY. Differential effectiveness of etanercept and infliximab in the treatment of ocular inflammation. *Ophthalmology*. 2006;113:2317-2323.
- Gjörloff K, Andréasson S, Ehinger B. Standardized full-field electroretinography in rabbits. *Doc Ophthalmol*.2004;109:163-168
- Gjörloff -Wallentén K, Andréasson S, Ghosh F. MfERG in normal and lesioned rabbit retina. *Graefe Arch Clin Exp Ophthalmol*.2006;244: 83-89
- Grover DA, Li T, Chong CCW. Intravitreal steroids for macular edema in diabetes (Review). *Cochrane Database Syst Rev*.2008;23
- Guignard S, Gossec L, Salliot C, Ruysen-Witrand A, Luc M, Duclos M, Dougados M. Efficacy of tumour necrosis factor blockers in reducing uveitis flares in patients with spondylopathy: a retrospective study. *Ann Rheum Dis*.2006;65:1631-1634

- Heiduschka P, Fietz H, Hofmeister S, et al. Penetration of bevacizumab through the retina after intravitreal injection in the monkey. *Invest Ophthalmol Vis Sci.*2007;48: 2814-2823
- Hida T, Chandler D, Arena JE, Machermer R. Experimental and clinical observation of the intraocular toxicity of commercial corticosteroid preparations. *Am J Ophthalmol.*1986;101:190-195
- Holland SP, Chang CW, Vagh M, Courtright P. Corneal endothelial deposits in patients with HIV infection or AIDS: Epidemiologic evidence of the contribution of rifabutin. *Can J Ophthalmol.*1999; 34: 204-209
- Hood DC, Bach M, Brigell M, Keating D, Kondo M, Lyons JS, Marmor MF, Mc Culloch DL, Palmowski-Wolfe A M. ISCEV standard for clinical multifocal electroretinography (mfERG) (2011 edition). *Doc Ophthalmol.*2012;124:1-13
- Hood DC, Birch DG. Beta wave of the scotopic (rod) electroretinogram as a measure of the activity of human on-bipolar cells. *J Opt Soc Am A Opt Image Sci Vis.* 1996; 13:623-633
- Ip MS, Scott IU, Brown GC, Brown MM, Ho AC, Huang SS, Recchia FM. Anti-vascular endothelial growth factor pharmacotherapy for age-related macular degeneration. *Ophthalmology.* 2008;115:1837-1846
- Iriyama A, Chen YN, Tamaki Y, Yanagi Y. Effect of anti-VEGF antibody on retinal ganglion cells in rats. *Br J Ophthalmol.*2007;91:1230-1233
- Jacobs DS, Pillero PJ, Kupperwasser MG, Smith JA, Harris SD, Flanigan TP, Goldberg JH, Ives DV. Acute uveitis associated with rifabutin use in patients with human immunodeficiency virus infection. *Am J Ophthalmol.*1994; 118: 716-722
- Jermak CM, Dellacrocce JT, Heffez J, Peyman GA. Triamcinolone acetonide in ocular therapeutics. *Surv Ophthalmol.*2007;52:503-522
- Jonas JB. Intravitreal triamcinolone acetonide: a change in paradigm. *Ophthalmic Res.*2006;38:218-245
- Joseph A, Raj D, Dua HS et al. Infliximab in the treatment of refractory posterior uveitis. *Ophthalmology.*2003;110:1449-1453
- Kai W, Yanrong J, Xiaoxin L. Vehicle of triamcinolone acetonide is associated with retinal toxicity and transient increase of lens density. *Graefe's Arch Clin Exp Ophthalmol.* 2006;244:1152-1159
- Khan MA, Singh J, Dhillon B. Rifabutin-induced uveitis with inflammatory vitreous infiltrate. *Eye.*2000;14:344-346
- Khera TK, Dick AD, Nicholson LB. Mechanisms of TNF α regulation in uveitis: Focus on RNA-binding proteins. *Progress in Retinal and Eye Research.*2011;30:610-621
- Kjellström U, Bruun A, Ghosh F, Andréasson S, Ponjavic V. Dose-related changes in retinal function and PKC-alpha expression in rabbits on vigabatrin medication. *Graefe's Arch Clin Exp Ophthalmol.*2009; 247: 1057-1067
- Kjellström U. Ocular function and morphology in humans and rabbits exposed to vigabatrin medication. *Anatomy of the rabbit eye. Doctoral dissertation* 2010;16
- Klettner A, Roider J. Comparison of bevacizumab, ranibizumab and pegaptanib in vitro: efficiency and possible additional pathways. *Invest Ophthalmol Vis. Sci* 2008;49: 4523-4527

- Klettner AK, Kruse M-L, Meyer T, Wesch D, Kabelitz D, Roeder J. Different properties of VEGF-antagonists: Bevacizumab but not Ranibizumab accumulates in the RPE Cells. *Graefes Arch Clin Exp Ophthalmol.*2009;247:1601–1608.
- Koistinaho J, Sagar SM. Localization of protein kinase C subspecies in the rabbit retina. *Neuroscience Letters* 1994;177:15-18.
- Kok H, Lau C, Maycock N, McCluskey P, Lightman S. Outcome of intravitreal triamcinolone in uveitis. *Ophthalmology.*2005;112:1916-1921
- Kriechbaum K, Michels S, Prager F, Georgopoulos M, Funk M, Geitzenauer W, Polak K, Schmidt-Erfurth U. Intravitreal Avastin for macular edema secondary to retinal vein occlusion. A prospective study. *Br J Ophthalmol.*2008;92:518-522
- Kusaka S, Shima C, Wada K, Arahori H, Shimojyo H, Sato T, Fujikado T. Efficacy of intravitreal injection of bevacizumab for severe retinopathy of prematurity: a pilot study. *Br J Ophthalmol.*2008;92:1450-1455
- Lang Y, Zemel E, Miller B, Perlman I. Retinal toxicity of intravitreal Kenolog in albino rabbits. *Retina.*2007;27:778-788
- Larsen JS. The sagittal growth of the eye. *Acta Ophthalmol.*1971;49:441- 453
- Lewis P, Fisher SK. Up regulation of Glial Fibrillary Acidic Protein in Response to Retinal Injury: Its Potential role in Glial Remodeling and a Comparison to Vimentin Expression. *International Review of Cytology.* 2003;230:263-289
- Li Q, Wang J, Yang L, Mo B, Zeng H, Wang N, Liu WA. A morphologic study of retinal toxicity induced by triamcinolone acetonide vehicles in rabbit eyes. *Retina.*2008; 28:504 -510
- Lipski A, Bornfeld N, Jurklics B. Multifocal Electroretinography in patients with exudative AMD and intravitreal treatment with pegaptanib sodium. *Retina.* 2007;27:864 -872
- MacKenzie D, Arendt A, Hargrave P, McDowell JH, Molday RS. Localization of binding sites for carboxyl terminal specific antirhodopsin monoclonal antibodies using synthetic peptides. *Biochemistry.* 1984;18:6544-6549.
- Macky TA, Helmy D, El Shazly N. Retinal toxicity of triamcinolone's vehicle (benzyl alcohol): an electrophysiological and electron microscopic study. *Graefe's Arch Clin Exp Ophthalmol.*2007;245:817-824
- Maia M, Penha FM, Farah ME, Dib E, Príncipe A, Lima Filho AAS, Magalhaes Jr. O, Freymüller E, Rodrigues EB. Subretinal injection of preservative-free triamcinolone acetonide and supernatant vehicle in rabbits: an electron microscopy study. *Graefe's Arch Clin Exp Ophthalmol.*2008;246:379-388
- Maier M, Feucht N, Lanzi I, Kook P, Lohmann CP. Retinchoroidopathy after intravitreal anti-VEGF treatment. *Ophthalmologie.*2009;106:729-734
- Malaviya, AP, Östör AJK, Rheumatoid arthritis and the era of biologic therapy. *Inflammopharmacol.*2012;20:59-69
- Marmor M, Fulton AB, Holder GE, Miyake Y, Brigell M, Bach M. ISCEV standard for full-field clinical electroretinography (2008 update). *Doc Ophthalmol.*2008;118:69-77
- Marneros AG, Fan J, Yokoyama Y, Gerber HP, Ferrara N, Crouch RK, Olsen BR.. Vascular endothelial growth factor expression in the retinal pigment epithelium is essential for choriocapillaris development and visual function. *Am J Pathol* 2005;167:1451-1459

- Massey SC, Mills SL. A Calbindin-Immunoreactive Cone Bipolar Cell Type in the Rabbit Retina. *Journal of Comparative Neurology*.1996;366:15-33
- Michelson IC. The mode of development of the vascular system of the retina, with some observations on its significance for central retinal diseases. *Eye*.1948;136-180
- Mirshahi A, Hoehn R, Lorenz K, Kramann C, Baatz H. Anti-Tumor Necrosis Factor Alpha for Retinal Diseases: Current Knowledge and Future Concepts. *J Ophthalmic Vis Res*.2012;7:39-44
- Moreira IS, Fernandes PA, Ramos MJ. Vascular endothelial growth factor (VEGF) inhibition – a critical review. *Anticancer Agents Med Chem*.2007;7:223-245
- Morrison VL, Koh HJ, Cheng L, Bessho K, Davidson MC, Freeman WR. Intravitreal toxicity of the Kenalog vehicle (benzyl alcohol) in rabbits. *Retina*.2006;26:339-344
- Mushtaq B, Saeed T, Situnayake RD, Murray PI. Adalimumab for sight-threatening uveitis in Behçet's disease. *Eye*. 2007;21:824-825
- Narayanan R, Mungcal JK, Kenney MC, Seigel GM, Kuppermann BD. Toxicity of triamcinolone acetonide on retinal neurosensory and pigment epithelial cells. *Invest Ophthalmol Vis Sci*.2006;47:722-728
- Newman EA, Odette LL. Model of electroretinogram b-wave generation: a test of the K+ hypothesis. *J Neurophysiol*.1984;51:164-182
- Patel PJ, Bunce C, Tufail A. A randomized double-masked phase III/IV study of the efficacy and safety of Avastin (bevacizumab) intravitreal injections compared to standard therapy in subjects with choroidal neovascularization secondary to age-related macular degeneration: clinical trial design. *Trials* 2008;9:56
- Pedersen KB, Møller F, Sjølie AK, Andréasson S. Electrophysiological assessment of retinal function during 6 months of bevacizumab treatment in neovascular AMD. *Retina*. 2010; 30:1025-33
- Penn RD, Hagins WA. Signal transmission along retinal rods and the origin of electroretinographic a-wave.1969;223:201-204
- Peters S, Heiduschka P, Julien S, Ziemssen F, Fietz H, Bartz-Schmidt KU; Tübingen Bevacizumab Study Group, Schraermeyer U. Ultrastructural findings in the primate eye after intravitreal injection of bevacizumab. *Am J Ophthalmol* 2007;143:995-1002
- Peyman GA, Conway MD, Fiscella R. Interaction of Intravitreal Combination Drugs and the Effect on the Targeted Site. *Journal of Ocular Pharmacology and Therapeutics*. 2009;25:387-394
- Pieramici DJ, Rabena MD. Anti-VEGF therapy: comparison of current and future agents. *Eye*.2008;22;1330-1336
- Ponjavic V, Andreasson S. *Electrophysiology and Retinal Function*. Adler's physiology of the eye. 2003 Mosby, Inc
- Ponjavic V, Gränse L, Bengtsson Stigmar E, Andréasson S. Retinal dysfunction and anterior segment deposits in a patient treated with rifabutin. *Acta Ophthalmol. Scand*. 2002;80:553-556
- Regillo, C et al (2008). Section 12:Retina and vitreous. San Francisco: American Academy of Ophthalmology.12.
- Robson JG, Frishman LJ. Inner-retinal components contribute to the a-wave of the ERG of the dark- adapted cat. 1995; *Vision Research* 35: 71-71

- Rosenbaum JT, Howes E L, Rubin R, Samples JR. Ocular Inflammatory Effects of Intravitreally-Injected Tumour Necrosis Factor. *American Journal of Pathology*.1988;133: 47-53
- Saint-Geniez M, Maharaj AS, Walshe TE, Tucker BA, Sekiyama E, Kurihara T, Darland DC, Young MJ, D'Amore PA. Endogenous VEGF is required for visual function: evidence for a survival role on Müller cells and photoreceptors. *PLoS One* 2008;3(11)
- Sallam A, Comer RM, Chang JH, Grigg JR, Andrews R, McCluskey PJ, Lightman S. Short-term safety and efficacy of intravitreal triamcinolone acetonide for uveitic macular edema in children. *Arch Ophthalmol*.2008;126:200-205
- Saran BR, Maguire AM, Nichols C, Frank I, Hertle RW, Brucker AJ, Goldman S, Brown M, Van Uitert B. Hypopion uveitis in patient with acquired immunodeficiency syndrome treated for systemic Mycobacterium avium complex infection with rifabutin. *Arch Ophthalmol*.1994; 112: 1159-1165
- Schmidt-Erfurth UM, Richard G, Augustin A, Aylard WG, Bandello F, Corcòstegui B, Cunha-Vaz J, Gaudric A, Leys A, Schlingemann RO. Guidance for the treatment of neovascular age-related macular degeneration. *Acta Ophthalmol. Scand*. 2007;85:486-494
- Schulze-Döbold C, Weber M. Loss of visual function after repeated intravitreal injections of triamcinolone acetonide in refractory uveitic macular oedema. *Int Ophthalmol*. 2009;29:427-429
- Simo R, Hernandez C. Intravitreal anti-VEGF for diabetic retinopathy: hopes and fears for a new therapeutic strategy. *Diabetologia*. 2008;51:1574-80
- Skolik S, Willermain F, Caspers LE. Rifabutin associated panuveitis with retinal vasculitis in pulmonary tuberculosis. *Ocul Immunol Inflamm*. 2005;13:483-485
- Smith JA, Mueller BU, Nussenblatt RB, Whitcup SM. Corneal endothelial deposits in children positive for human immunodeficiency virus receiving rifabutin prophylaxis for Mycobacterium avium complex bacteremia. *Am J Ophthalmol*.1999;127: 164-169
- Soukasian SK, Raizman MB. Ocular toxicity of systemic medications. Albert DM, Jacobiec FA, editors. *Principles and practice of ophthalmology*. Philadelphia, W.B. Saunders Company. 2000; Chapter 42;455-446
- Spitzer MS, Yoeruek E, Sierra A, Sierra A, Wallenfels-Thilo B, Schraermeyer U, Spitzer B, Bartz-Schmidt KU, Szurman P. Comparative antiproliferative and cytotoxic profile of bevacizumab (Avastin), pegaptanib (Macugen) and ranibizumab (Lucentis) on different ocular cells. *Graefes Arch Clin Exp Ophthalmol* 2007;245:1837-1842
- Stahl A, Feltgen N, Fuchs A, Bach M. Electrophysiological evaluation of retinal photoreceptor function after repeated bevacizumab injections. *Doc Ophthalmol*.2009;118:81-88
- Stockton RA, Slaughter MM. B-wave of the electroretinogram. A reflection of ON bipolar cell activity. *Journal of General Physiology*.1989;93:101
- Strettoi E, Masland RH. The organization of the inner nuclear layer of the rabbit retina. *J Neurosci*. 1995;15:875-888
- Szel A, Röhlich P, Caffé AR, van Veen T. Distribution of cone photoreceptors in the mammalian retina. *Microsc Res Tech*.1996. 35: 445-462

- Szurman P, Kaczmarek R, Spitzer MS, Jaissle GB, Decker P, Grisanti S, Hebke-Fahle S, Aisenbrey S, Bartz-Schmidt KU. Differential toxic effect of dissolved triamcinolone and its crystalline deposits on cultured human retinal pigment epithelial (ARPE19) cells. *Experimental eye research*.2006;83:584-592
- Tasman W, Jaeger EA, editors. *Duane's foundations of clinical ophthalmology*.Vol1,Chap16. Philadelphia, Pennsylvania: Lippincott Williams & Wilkins, 1998
- van Laar JA, Missotten T, van Daele PL, Jammitski A, Baarsma GS, van Hagen PM. Adalimumab: a new modality for Behçet's disease? *Ann Rheum Dis*.2007;66:565-566
- Wong TY, Chakravarthy U, Klein R, Mitchel P, Zlateva G, Buggage R, Fahrback K, Probst C, Siedge I. The natural history and prognosis of neovascular age-related macular degeneration: a systematic review of the literature and meta-analysis. *Ophthalmology*.2008;115:116-126
- Wood JPM, McCord RJ, Osborne NN. Retinal protein kinase C. *Neurochem Int*.1997;30:119-136
- Wu WC, Yeh PT, Chen SN, Yang CM, Lai CC, Kuo HK. Effects and complications of bevacizumab use in patients with retinopathy of prematurity: a multicenter study in Taiwan. *Ophthalmology* 2011;118:176-183
- Xia P, Aiello LP, Ishii H, Jiang Z Y, Park D J, Robinson G S, Takagi H, Newsome W P, Jirousek M R, King GL. Characterization of vascular endothelial growth factor's effect on the activation of protein kinase C, its isoforms, and endothelial cell growth. *J Clin Invest*.1996;98:2018-2026
- Xu X, Karwoski CJ. Current source density (CSD) analysis of the ERG-d wave. *IOVS*.1994
- Yeung CK, Chan KP, Chan CKM, Pang CP, Lam DSC. Cytotoxicity of triamcinolone on cultured human retinal pigment epithelial cells: comparison with dexamethasone and hydrocortisone. *Jpn J Ophthalmol*.2004;48:236-242
- Yu SY, Damico FM, Viola F, D'amico DJ, Young LH. Retinal toxicity of intravitreal triamcinolone acetonide: a morphological study. *Retina* 2006;26:531-536
- Yu, D-Y. Cringle SJ. Oxygen Distribution and Consumption within the Retina in Vascularized and Avascular Retinas and in Animal Models of Retinal Disease. *Progress in Retinal and Eye Research*.2001;20:175- 208
- Zhenguy S, Fang W, Ying F. Vehicle Used for Triamcinolone Acetonide Is toxic to Ocular Tissues of the Pigmented Rabbit. *Current Eye Research*.2009;34:769-776
- Ziemssen F, Lüke M, Messias A, Beutel J, Tatar O, Zrenner E, Bartz-Schmidt KU. Safety monitoring in bevacizumab (Avastin) treatment: retinal function assessed by psychophysical (visual fields, color vision) and electrophysiological (ERG/EOG) tests in two subgroups of patients. *Int Ophthalmol*.2008;28:101-109

