



LUND UNIVERSITY

Video assisted gastrostomy in children

Backman, Torbjörn

2014

[Link to publication](#)

Citation for published version (APA):

Backman, T. (2014). *Video assisted gastrostomy in children*. [Doctoral Thesis (compilation), Paediatrics (Lund)]. Lund University: Faculty of Medicine.

Total number of authors:

1

General rights

Unless other specific re-use rights are stated the following general rights apply:

Copyright and moral rights for the publications made accessible in the public portal are retained by the authors and/or other copyright owners and it is a condition of accessing publications that users recognise and abide by the legal requirements associated with these rights.

- Users may download and print one copy of any publication from the public portal for the purpose of private study or research.
- You may not further distribute the material or use it for any profit-making activity or commercial gain
- You may freely distribute the URL identifying the publication in the public portal

Read more about Creative commons licenses: <https://creativecommons.org/licenses/>

Take down policy

If you believe that this document breaches copyright please contact us providing details, and we will remove access to the work immediately and investigate your claim.

LUND UNIVERSITY

PO Box 117
221 00 Lund
+46 46-222 00 00

Video assisted gastrostomy in children

Torbjörn Backman, MD



LUND
UNIVERSITY

Akademisk avhandling

som med vederbörligt tillstånd av Medicinska fakulteten vid Lunds Universitet
för avläggande av doktorexamen i medicinsk vetenskap
kommer att offentligen försvaras
lördagen den 8 mars 2014, kl 10.00 i Segerfalksalen
Biomedicinskt Centrum (BMC), Lund.


Fakultetsopponent

Docent Gunnar Göthberg
Barnkirurgiska kliniken
Drottning Silvias Barnsjukhus
Göteborg, Sverige

LUND UNIVERSITY Department of clinical science, Section of Pediatric Surgery, Lund. Author(s) Torbjörn Backman, MD		DOCTORAL DISSERTATION
		Date of issue 2014-03-08
		Sponsoring organization
Title and subtitle Video assisted gastrostomy in children		
Abstract Children with severe diseases can be provided nutritional support through a gastrostomy if needed. At the Department of Paediatric Surgery in Lund we have used the Video Assisted Gastrostomy (VAG) procedure since 1994 when establishing gastrostomies. In this thesis, children with different diseases and whom all had a VAG procedure performed were studied in five different clinical studies. Postoperative complications were collected and validated. We have not seen any major complications associated with the surgical procedure in any of the studies, such as peritonitis due to leakage of gastric contents into the abdominal cavity, tube dislodgement, or gastro-colic fistula or severe haemorrhage. Complications discussed below are therefore to be characterized as minor and include local infections, leakage and development of granulation tissue Based on our studies, we have found that the VAG-procedure is safe method when performed in children less than 1 year of age, and that these patients had a significant weight gain 6 months postoperatively (paper I). Children with malignant diseases and treated with chemotherapy, did not have a higher incidence of postoperative complications after the VAG-procedure as compared to children with neurologic impairment. In the patients with postoperative complications such as granuloma formation and infection, we did not find a correlation between these complications and the timing of the administration of the chemotherapy treatment (paper II). Children with previously placed VPS due to underlying neurosurgical diseases, did not present any serious intra abdominal complications, VPS or central nervous system infections after a VAG procedure. No difference were seen between the children with neurosurgical diseases with a VPS and the control group including children with neurological impairment without a VPS concerning minor complication rates (paper III) We developed and hereafter used a new suturing technique when adapting the ventricle to the abdominal wall when performing a VAG procedure in children. We noticed a significant decrease in the incidence of granulation tissue development in the group using the new suture coined "the continuous double U-stich suture", as compared to the group of children that had used our previously suturing technique, the purse-string suture (paper IV). Vomiting is a common symptom in children with severe diseases and is most frequent in children with neurological impairment. The VAG procedure does not lead to increased vomiting in children. In children with vomiting symptoms before a VAG procedure, 78% have persisting symptoms six months after surgery (paper V)		
Key words Children, Gastrostomy, Laparoscopy, VAG, Complications, VPS, Malignancy, Vomiting, Double U-stitch suture		
Supplementary bibliographical information		Language English
ISSN and key title 1652-8220, Doctoral Dissertation Series 2014:2		ISBN 978-91-87651-27-4
Recipient's notes	Number of pages	Price
	Security classification	

I, the undersigned, being the copyright owner of the abstract of the above-mentioned dissertation, hereby grant to all reference sources permission to publish and disseminate the abstract of the above-mentioned dissertation.

Signature



Date

2014-01-29

Video assisted gastrostomy in children

Torbjörn Backman, MD



LUND
UNIVERSITY

© Torbjörn Backman, MD
Department of Pediatric Surgery,
Skånes University Hospital and
Department of Pediatrics, Clinical Sciences
Faculty of Medicine, Lund University, Sweden

ISBN 978-91-87651-27-4
ISSN 1652-8220

Printed in Sweden by Media-Tryck, Lund University
Lund 2013



*Pain is temporary
Glory is forever*

Contents

Abstract	9
List of publications	11
Abbreviations	13
Aims	15
Introduction/Background	17
Introduction	17
History	18
Gastroscopy	19
Percutaneous endoscopic gastrostomy (PEG)	20
Laparoscopy in children	21
Indications for gastrostomy	22
Contraindications for gastrostomy	23
Gastrostomy related complications	23
Major complications	23
Minor complications	24
Gastrostomy in Lund	25
Material and Methods	27
The Video Assisted Gastrostomy (VAG) Procedure	28
In all five papers	35
Paper I	36
Paper II	37
Paper III	39
Paper IV	40
Paper V	44

Results	45
In all five Papers	45
Paper I	45
Paper II	47
Paper III	49
Paper IV	49
Paper V	50
Discussion	53
Gastrostomy in infants less than 1 year of age	54
Gastrostomy in children with malignant diseases	55
Gastrostomy in children with a VPS	57
The continuous double U-stitch suture	59
Vomiting frequency in children undergoing a VAG operation	61
Conclusions and future aspects	63
Conclusions	63
Future perspectives	64
Populärvetenskaplig sammanfattning	65
Acknowledgements	69
References	71

Abstract

Children with severe diseases can be provided nutritional support through a gastrostomy if needed. At the Department of Paediatric Surgery in Lund we have used the Video Assisted Gastrostomy (VAG) procedure since 1994 when establishing gastrostomies. In this thesis, children with different diseases, who all had undergone the VAG procedure, were studied in five different clinical studies. Postoperative complications were collected and validated. We have not seen any major complications associated with the surgical procedure in any of the studies, such as peritonitis due to leakage of gastric contents into the abdominal cavity, tube dislodgement, gastro-colic fistula or severe haemorrhage. Complications discussed below are therefore to be characterized as minor and include local infections, leakage and development of granulation tissue.

Based on our studies, we have found that the VAG procedure is a safe method even when performed in children less than 1 year of age, and that these patients had a significant weight gain six months postoperatively (Paper I).

Children with malignant diseases and treated with chemotherapy, did not have a higher incidence of postoperative complications after the VAG procedure compared to children with neurologic impairment. In the patients with postoperative complications, such as granuloma formation and infection, we did not find a correlation between these complications and the timing of the administration of the chemotherapy treatment (Paper II).

Children with a previously placed ventriculo-peritoneal shunt (VPS) due to underlying neurosurgical diseases, did not present with any serious intra-abdominal complications, VPS or central nervous system infections after a VAG procedure. Concerning minor complication rates, no differences were seen between the children with neurosurgical diseases with a VPS and the control group including children with neurological impairment without a VPS (Paper III)

We developed, and thereafter used, a new suturing technique when adapting the ventricle to the abdominal wall when performing a VAG procedure in children. We noticed a significant decrease in the incidence of granulation tissue development in the group where the new suture was used, coined “the continuous double U-stitch suture”, compared to the group of children in whom we had used our previously suturing technique, the purse-string suture (Paper IV).

Vomiting is a common symptom in children with severe diseases and is most frequent in those with neurological impairment. The VAG procedure does not lead to increased vomiting in children. In children with vomiting symptoms before a VAG procedure, 78% had persisting symptoms six months after surgery (Paper V).

List of publications

This thesis is based upon the following papers, referred to by their Roman numerals:

- I. **Backman T**, Arnbjörnsson E, Berglund Y, Larsson LT. Video-assisted gastrostomy in infants less than 1 year. *Pediatr Surg Int* (2006) 22:243-246
- II. Arnbjörnsson E, **Backman T**, Mörse H, Berglund Y, Kullendorff CM, Lövkvist H. Complications of video-assisted gastrostomy in children with malignancies or neurological diseases. *Acta Paediatrica*, 2006; 95: 467-470
- III. **Backman T**, Berglund Y, Sjöwie H, Arnbjörnsson E. Complications of video-assisted gastrostomy in children with or without a ventriculoperitoneal shunt. *Pediatr Surg Int* (2007) 23:665-668
- IV. **Backman T**, Sjöwie H, Kullendorff CM, Arnbjörnsson E. Continuous Double U-stich gastrostomy in children. *Eur J Pediatr Surg* 2010; 20: 14-17

All papers are reprinted with the permission from respective publisher

Supplementary material Paper V

- V. **Backman T**, Sjöwie H, Mellberg M, Anderberg M, Börjesson A, Kullendorff CM, Arnbjörnsson E. Vomiting in children undergoing video-assisted gastrostomy tube placement. Submitted

Abbreviations

CVC	Central Venous Catheter
GER	Gastro Esophageal Reflux
GERD	Gastro Esophageal Reflux Disease
MIS	Minimal Invasive Surgery
PEG	Percutaneous Endoscopic Gastrostomy
PICU	Paediatric Intensive Care Unit
TPN	Total Parenteral Nutrition
VAG	Video Assisted Gastrostomy
VPS	Ventriculo Peritoneal Shunt

Aims

- I. To report our experiences of a Video Assisted Gastrostomy (VAG) operation in infants less than 1 year with regard to postoperative complications and long-term weight gain.
- II. To determine if pre- or postoperative administration of cytostatic drugs close to a VAG operation influences the rate of postoperative complications in children with malignancies.
- III. To determine if the presence of a ventriculo-peritoneal shunt (VPS) influences the rate of postoperative complications after a VAG operation. Do children with a VPS run a greater risk for shunt infections after a VAG operation?
- IV. To determine whether a new suturing technique when adapting the ventricle to the abdominal wall influences the rate of postoperative complications after a VAG operation.
- V. To determine the incidence of vomiting frequency pre- and post operatively in children undergoing a VAG operation. Does the VAG procedure affect the vomiting frequency and is vomiting more frequent in patients with certain diagnoses?

Introduction/Background

Gastrostomy, derived from two Greek words: Gaster (stomach) and Stomoun (opening or mouth) is the operative creation of a fistulous tract between the stomach and the abdominal surface.

Introduction

The surgical establishment of a gastrostomy has been used for more than one century in general surgical practice, making it one of the oldest known surgical abdominal methods in continuous use. This enteral route for nutrition has been developed as a practical alternative to parenteral or oral feeding for patients with a functioning gastrointestinal tract but the inability to take food by mouth. Enteral feeding is most often accomplished through a nasogastric tube as it is simple to insert, but it is often poorly tolerated by the patient, especially children. For long-term enteral feeding, i.e. more than 3 months, a more permanent solution such as gastrostomy is chosen. There are basically two methods used nowadays for establishing a gastrostomy, either through open surgery or by minimal invasive surgery using gastroscopy or laparoscopy. The open surgical method with its many variations such as Stamm and Witzel fistulas was the gold standard until 1979 when the Percutaneous Endoscopic Gastrostomy (PEG) was introduced (Gauderer 1980, 1986). This was the first Minimal Invasive Surgery (MIS) procedure in children and the introduction of the PEG method very soon received worldwide acceptance for both children and adults and is still the dominant method for establishing a gastrostomy.

The use of the laparoscopic technique gained popularity when it was introduced in 1991 because of better visual control intra-abdominally and the secure positioning of the stoma to the gastric wall during the procedure. In combination with a gastroscopical control of the gastrostomy button placement in the ventricle cavity, the laparoscopic method is considered safer for the patient than the PEG technique (Rothenberg 1999, Tomicic 2002, Zanakhsary 2005, Jones VS 2007, Lantz 2010, Akay 2010)

At the Department of Paediatric Surgery in Lund, all congenital malformations of the gastrointestinal and genitourinary tract are treated as well as solid tumours and

elective surgery of paediatric patients. We are able to provide highly specialized surgical treatment for neonates and children from the southern part of Sweden due to excellent paediatric competence in anaesthetics, intensive care, oncology, neonatal care and cardiology.

Many of the patients treated at our university hospital have in common severe feeding problems due to their underlying diagnoses such as neurological diseases, severe congenital cardiac malformations and malignancies. Independent of the underlying diagnosis, when feeding problems persist for a long period of time, the patient is referred to a paediatric surgeon for consultation regarding a gastrostomy.

In Lund, since the introduction in 1994 of the laparoscopic technique when establishing a gastrostomy, the outcomes for these patients have been closely followed.

In this thesis we have studied the following:

- Is there a lower age limit as to when we should not establish a gastrostomy?
- Does cytostatic medication in close relation to the surgical procedures for establishing a gastrostomy increase the complication rate?
- Does a VPS placed before a VAG operation, influence the frequency of postoperative complications? Is there a higher risk for postoperative shunt infections?
- Can a new suturing technique when adapting the ventricle to the abdominal wall while performing a VAG influence the complication rate?
- Does a VAG operation influence the frequency of vomiting and is vomiting more frequent in any specific diagnosis?

The five papers included in the thesis are all based on clinical observations and the purpose has been to review our own results and compare them with other published studies. This is done in order to increase our own knowledge regarding gastrostomies, in turn hopefully leading to better information given to the patient's parents upon consultation.

History

The history of gastrostomies, from the first known publications throughout its surgical evolution, is excellently presented and described in a previous publication by Gauderer and Stellato in 1986 (Gauderer 1986).

Historically, the first known gastrocutaneous fistula was described in 1635 by Daniel Schwaben (Moehlau 1896), who operated on a man who had swallowed a knife and

postoperatively, the patient developed a fistula. The first surgically created gastrostomies were carried out as gastrocutaneous fistulas secondary to surgery due to some kind of traumatic injury, and should be seen as forerunners of the upcoming procedures.

Gastrostomy, as a planned surgical method in humans, was first introduced in 1849 by Sedillot (Sedillot 1846,1849,1853). Two patients were operated on but unfortunately without success since both died. The first operation where the patient survived was done in 1875 and was performed by Jones (Jones S 1875). The poor outcome after surgery at that time can probably be attributed to a variety of reasons. The great loss of nutrients and gastric juices through the fistula being one, the fact that many of the patients were malnourished because of underlying diseases such as oesophageal cancer another, and postoperative infections before the era of antibiotics and stricter hygiene a third reason.

To overcome the problem with external leakage of gastric contents, different surgical procedures making valves and conduits in the ventricle wall were developed. These were effective in leakage control but more complex to construct. With time the use of canals, utilizing catheters to form a channel became the dominant procedure for leakage control. In 1894, Stamm described one of the most widely used procedures in constructing a temporary and a permanent gastrostoma in both children and adults (Stamm 1894). A Stamm gastrostomy or fistula is constructed by two concentric purse-string sutures in the ventricle wall around the gastrotomy, forming a seromuscular canal around the catheter when tied. A similar technique was used by Witzel, utilizing the anterior side of the ventricle wall to create a seromuscular sleeve which surrounds the catheter upon the ventricle wall before its entrance into the ventricle cavity (Witzel 1891). After their introduction, these two procedures became the gold standard when creating gastrostomies among surgeons worldwide for many decades.

Gastroscopy

The next step in the evolution of gastrostomies is closely related to the development of gastroscopy. The first attempts to examine the ventricle without open surgery were made in 1868 with a long rigid tube; the patient was a sword swallower (Morgenstern 2009). The position that made it possible to introduce the rigid gastroscope into the oesophagus was with the head and neck flexed backwards and was coined “the sword swallower’s position”.

The semiflexible gastroscope was introduced in 1932 by Rudolf Schindler and Georg Wolf (Morgenstern 2009). With the possibility of moving the distal part of the gastroscope separately, a better visualization of the oesophagus and especially the ventricle was achieved. Schindler, who was a great endoscopist, made further

improvements of this “first modern” gastroscope as well as refining the technique and is therefore often referred to as the “Father of Gastroscopy”.

In 1957, Hirschowitz introduced a totally flexible gastroscope (Hirschowitz 2000) equipped with fiberoptics creating new possibilities for a better examination of the oesophagus and ventricle. With these properties, the new gastroscope provided conditions for further development in the era of gastrostomies.

In the late 70s, gastroscopy was a standard procedure for examining the oesophagus and ventricle. Nasogastric tubes were used for short-term enteral feeding, but had their limitations such as nasal discomfort, blockage or displacement of the tube, recurrent pulmonary aspiration, irritation and in rare cases even penetration of the larynx. For long-term enteral feeding, gastrostomies were established as earlier described through open surgical techniques.

In the paediatric population requiring gastrostomies, the underlying condition is most often severe neurological impairment, cardiac malformations or metabolic diseases, which in turn means a high risk for these patients with regard to anaesthesia. This motivated the search for a simplified yet safe method to establish a gastrostomy. The main criteria for the new technique were to have good control of the site of the placement in the ventricle and protection of surrounding organs from accidental injury. To establish these criteria it was found that gastroscopy was the key procedure.

Percutaneous endoscopic gastrostomy (PEG)

In 1979, the first PEG was performed in Cleveland USA (Gauderer 1980, 1986) on a 6 month-old girl in local anaesthesia.

The method was basically performed as follows. With a gastroscope placed in the ventricle while insufflating air, the flexible part of it was turned towards the abdominal wall. A small incision was made in the skin where light was seen from outside. A trocar with a needle was pushed through this incision into the ventricle under complete endoscopic visualization. A thread or a guide wire was inserted through the trocar after removing the needle and the thread was snared with an instrument inserted through the gastroscope. The gastroscope was then removed with the snare holding the thread. A suitably sized PEG tube was connected to the thread which was then pulled from the skin incision. The PEG tube was then pulled through the patient’s mouth, oesophagus and the ventricle wall, where an internal bolster retained it. An external bolster was placed loosely on the skin to keep the tube in place and avoid external leakage.

The PEG method was initially developed for children with long-term enteral feeding problems, but was soon also adapted to become the gold standard procedure worldwide in adults when a gastrostomy was needed. This was because of apparent advantages such as minimal postoperative discomfort, no need for general anaesthesia,

a faster procedure and lower operation costs compared with open surgical gastrostomies.

Nowadays general anaesthesia is mandatory when establishing a gastrostomy in children independent of the method used. In adults, however, where PEG is still the most commonly used method to establish a gastrostomy, the procedure is still carried out in local anaesthesia.

Laparoscopy in children

Laparoscopic surgery was first performed in humans in 1910 by Jacobaeus. Using a trocar and a cystoscope he examined the abdomen without any further surgical interactions (Jacobaeus 1910). However, the method did not gain acceptance until the first laparoscopic cholecystectomy in adults was performed in 1989 (Reddick 1989, Dubois 1990). The possibility to operate with better cosmesis, fewer analgesic requirements and less respiratory associated morbidity as well as shorter hospital stay led to gained popularity of this procedure. The laparoscopic cholecystectomy has become the standard bearer for minimal invasive surgery (MIS) in general surgery. Since its introduction, laparoscopic surgery has expanded tremendously and combined with modern technology the safety and efficacy of this surgical approach has been vastly improved.

The first true neonatal laparoscopy was described in 1973 by Gans and Berci (Gans 1973). Laparoscopy in children was presumed to be a safe method already in early 90s (Chen 1996), but because of presumed technical challenges and/or unacceptably high risk in this group of neonatal patients the development lagged behind. However, as the skills of paediatric surgeons improved, coupled with improved optics, video technology, refined instruments specifically designed for neonates and children and the energy of a new generation of surgeons, the MIS in this group gained momentum. MIS in neonates and children was accepted worldwide in the beginning of the 90s after the first fundoplication was performed in 1991 by Lobe (Lobe 2007) and the technique has hereafter developed enormously (Ure 2000, Chandrasen K 2009, Parelkar 2013).

At the Department of Paediatric Surgery in Lund, MIS is now the standard procedure for undescended/impalpable testis, acute appendicitis, gastrostomies, fundoplication and pyeloplasty, among others.

At centres more laparoscopically oriented, significantly more advanced MIS is performed such as neonatal surgery including atresia of the oesophagus, duodenum and biliary tract, diaphragmal hernia, necrotizing enterocolitis and malrotation (Ponsky 2008, Chandrasen 2009, Kuebler 2011, Parelkar SV 2013).

The first laparoscopic method when establishing a gastrostomy was described in 1991 (Edelman 1991, Shallman 1991). Many variations in the performance concerning

techniques have hereafter been published and the differences consist mainly in the suturing technique and adaptation of the ventricle to the abdominal wall (Aprahamian 2006, Jones VS 2007, Antonoff 2009, Backman 2009).

A decade ago, the PEG technique was the most commonly used method at three out of four paediatric surgery centres in Sweden. However, nowadays the laparoscopic procedure is used at all four centres when establishing a gastrostomy.

Indications for gastrostomy

When oral intake is inadequate to meet nutritional demand, enteral feeding can be accomplished through nasogastric, nasojejunal, gastrostomy or jejunostomy tubes.

A nasogastric tube is the most commonly used short-term alternative for enteral feeding since it is simple to insert. It is, however, often poorly tolerated by the child, is difficult to maintain in position and has an associated risk for aspiration of gastric contents into the airways.

There is a general consensus that when the need for enteral feeding exceeds three months a more permanent solution should be chosen such as gastrostomy to avoid complications, reduce feeding time and parents' stress in feeding situations (Heine 1995, Norton 1996, Haynes 1996, Behrens 1997)

Children with the following conditions fall under this category:

1. Neurological disorders. This category is the most common and most of the children are suffering from cerebral palsy with dysphagia or inability to swallow. Some of them also suffer from epilepsy and need the gastrostomy for enteral medication intake. Recurrent aspiration secondary to neurological disorder may result in failure to use oral intake safely and further aggravate the indication for gastrostomy.
2. Cardiac malformations. Children with cardiac malformations sometimes have a need for nutritional support, because nutritional demand exceeds oral intake capacity.
3. Chronic diseases. Short bowel syndrome, renal failure, cystic fibrosis.
4. Metabolic diseases.
5. Oncology problems with malnutrition. With underlying malignant disease, in addition to aggressive chemo- and radiotherapy, it is very important to establish adequate nutritional intake for improving the outcome of the underlying disease. It also serves as a way for medication and nutrition in case of severe mucositis in oesophagus.

6. Anatomical malformation. In e.g. oesophageal atresia with long distance between the two ends, so-called long gap, a gastrostomy can provide the rest of the intestines with nutrition to ensure growth.
7. Craniofacial abnormalities Children with congenital facial abnormalities or severe head trauma may have problems with parenteral feeding.

Contraindications for gastrostomy

The only absolute contraindication for gastrostomy is bowel outlet obstruction preventing passage of gastric contents to the intestines. This might be caused by anatomical malformation e.g. atresia and/or stenosis of the duodenum or the small intestine as well as malrotation.

Gastrostomy related complications

A number of complications related to gastrostomies are well known and can be divided into major and minor complications.

Major complications

1. Peritonitis. If the ventricle is not attached securely to the abdominal wall, leakage of gastric contents into the abdominal cavity can occur, leading to peritonitis. The peritonitis often develops immediately after gastrostomy insertion or after a “routine” tube change when the tube is inadvertently inserted (Kimber 1998).
2. Bleeding. Iatrogenic rupture or stab punctures of parenchymal organs such as the liver and spleen or vessels in the abdomen during the gastrostomy operation may cause severe intra-abdominal bleeding in which case an acute conversion to open surgery is required.
3. Gastroenteric fistula formation. If the gastrostomy tube is accidentally inserted into the intestine instead of the ventricle, a fistula formation is established. This is a well-known complication in the PEG procedure (Khattak 1998; Kubiak 1999; Patwardhan 2004; Lantz 2010). Due to the blind puncture of the ventricle in the PEG procedure, an intestinal segment may be placed in between the ventricle and the abdominal wall and may therefore accidentally be punctured.

4. Tube dislodgement. The first four to six weeks after a gastrostomy operation, the ventricle stoma is still in a process of healing. If the gastrostomy button dislodges during this period there is a significant risk that the ventricle becomes unattached from the abdominal wall during placement of a new gastrostomy device. This is the reason why tube replacement during the first six weeks postoperatively should be done by specialized personal at the hospital. After replacement of the tube it should be checked with a contrast X-ray to assure a correct position within the ventricle. A permanent canal is established 4-6 weeks postoperatively from the skin into the cavity of the ventricle and lined with ventricle mucosa. If the gastrostomy button dislodges after this period of time, it can most usually be replaced by the parents or personnel at a hospital. It is very important that replacement is done quickly since gastrostomas often close spontaneously within 24-48 hours when the tube is removed.

Minor complications

1. Inflammation and infections in the tissue surrounding the gastrostoma. Leakage of gastric contents might cause an inflammatory reaction in the skin surrounding the gastrostoma making it more susceptible to infection by skin bacteria. Treatment with antibiotics might be needed in severe cases, can otherwise be handled with careful foment of the stoma.
2. Granulation tissue. Granulation tissue is a vessel-rich tissue formed at the site of an injury during the healing process, in order to bring oxygen and nutrition to the site of injury and at the same time remove waste products. Sometimes there is hypertrophy of granulation tissue around the gastrostoma leading to bleeding and soiling at direct manual contact or by movement of the gastrostomy button. Small granulations are treated with local application of silver nitrate and more extended granulation tissue is removed by cauterisation in general anaesthesia.
3. Leakage. Leakage of gastric contents along the gastrostomy button causes skin irritation and infection. One approach to reduce the leakage is to temporarily replace the gastrostomy button with a tube/catheter with smaller dimensions, hopefully leading to a retraction of the gastrostoma, thus diminishing further leakage when the button is inserted again.

Gastrostomy in Lund

At the beginning of the 1990s there was an increasing interest for laparoscopic surgery in children worldwide. At the Department of Paediatric Surgery in Lund the first equipment for laparoscopic surgery was purchased in 1993. The main reason for this investment was to have the opportunity to diagnose rare conditions such as biliary atresia without to perform a laparotomy.

In order to gain experience in using laparoscopy, it was initially decided that appendectomies should be performed with the new technique. Because of the method's reputation for good intra-abdominal visualization, only the more difficult cases were chosen for laparoscopy. Many of the first operations were not surprisingly converted to open surgery due to their complexity. The technique received an undeserved bad reputation and was therefore, for many years, not adopted by all colleagues for performing routine appendectomies nor for diagnosing rare conditions. The latter because conditions such as biliary atresia were not often seen at our department during this period and were therefore performed with open surgery.

However, gastrostomies were still performed with the open surgery technique at the Department of Paediatric Surgery in Lund at that time. The PEG method was introduced and adapted at the Department of Surgery in Lund for adults. Reputation has it that the early results and experiences were discouraging due to high complication rates and morbidity and that was the reason why it was not introduced at our surgical department in Lund.

In 1991 a new laparoscopic method was described (Edelman 1991, Shallman 1991), using a video screen for visualizing during the laparoscopic performance when establishing a gastrostomy. Among the benefits seen with this technique was the possibility of a controlled placement of the gastrostomy tube in an anatomically correct position in the ventricle wall. Furthermore iatrogenic bowel injury could be avoided. The technique was named the Video Assisted Gastrostomy (VAG) procedure.

The procedure was adapted in Lund and the first operation was performed in November 1994 (Mikaelson 1995). At our paediatric surgical centre the VAG procedure has been the customary procedure ever since then when establishing gastrostomies.

Material and Methods

At the Department of Paediatric Surgery in Lund, the VAG procedure has been the standard method for establishing a gastrostomy since 1994. This method was initially chosen because of a number of serious complications reported after the PEG technique. Approximately 1000 gastrostomies have been established at our clinic since the start, and a yearly performance of 50 operations has been reported during the last years.

At our department we have used the operation as laparoscopic training for younger colleagues under supervision and tutoring of more experienced surgeons. The author of this thesis has performed and assisted colleagues in many of these operations and has also been one of the inventors of the new suturing technique described in Paper IV.

The method is described below.

The Video Assisted Gastrostomy (VAG) Procedure

Prophylactic antibiotics are given. The operation is performed under general and local anaesthesia.

For orientation of the operation area see Figure 1.

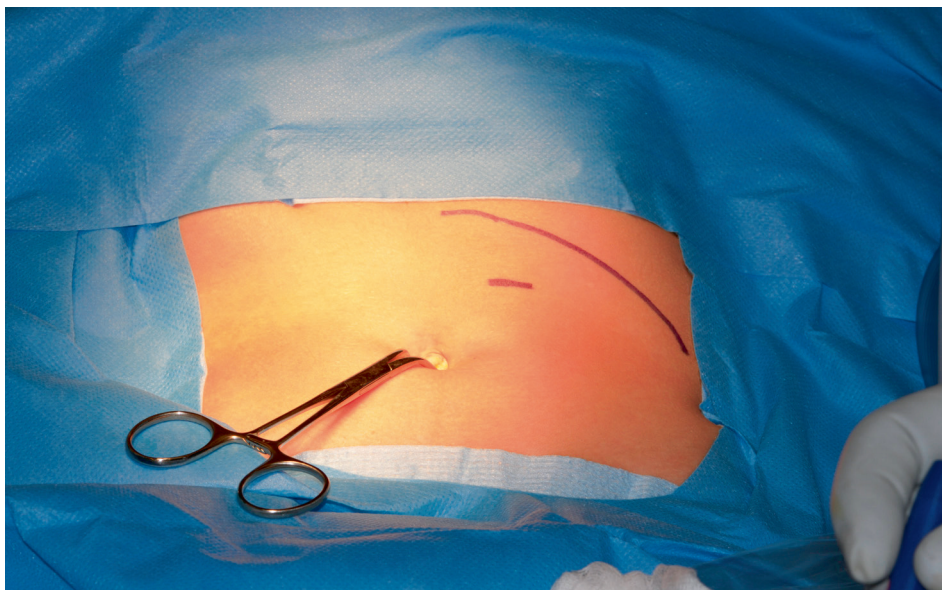


Figure 1. The patient is lying on his back with the head up in the picture. The left costal margin is marked with a curved line up to the right (the left side of the patient), the umbilicus is grasped with a instrument. In between the costal margin and the umbilicus the place for the gastrostoma is marked.

A 3 mm trocar (Versa Step[®]) is safely inserted intra abdominally by performing a mini-laparotomy below the umbilicus (Figure 2 and 3).

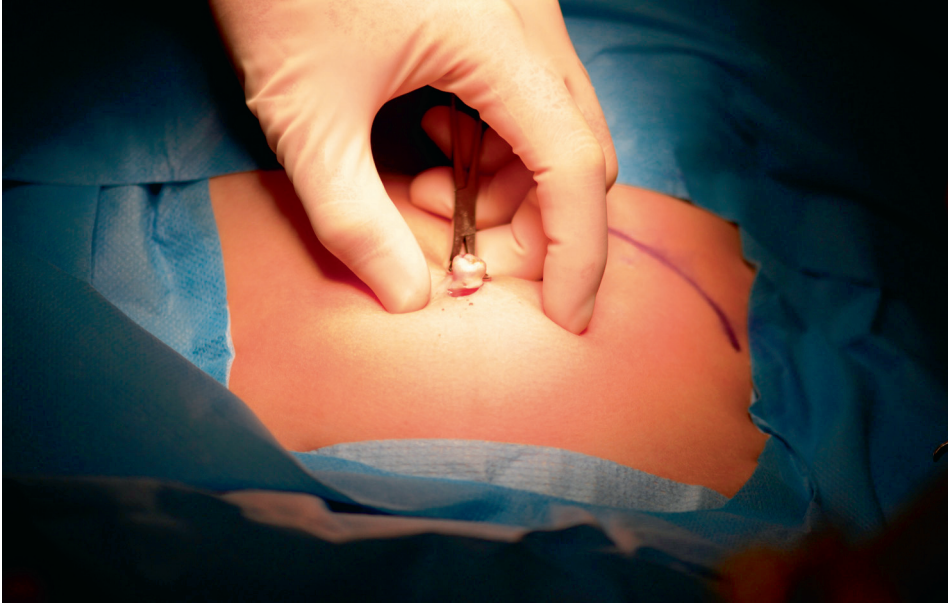

Figure 2. A mini laparotomy is performed below the umbilicus

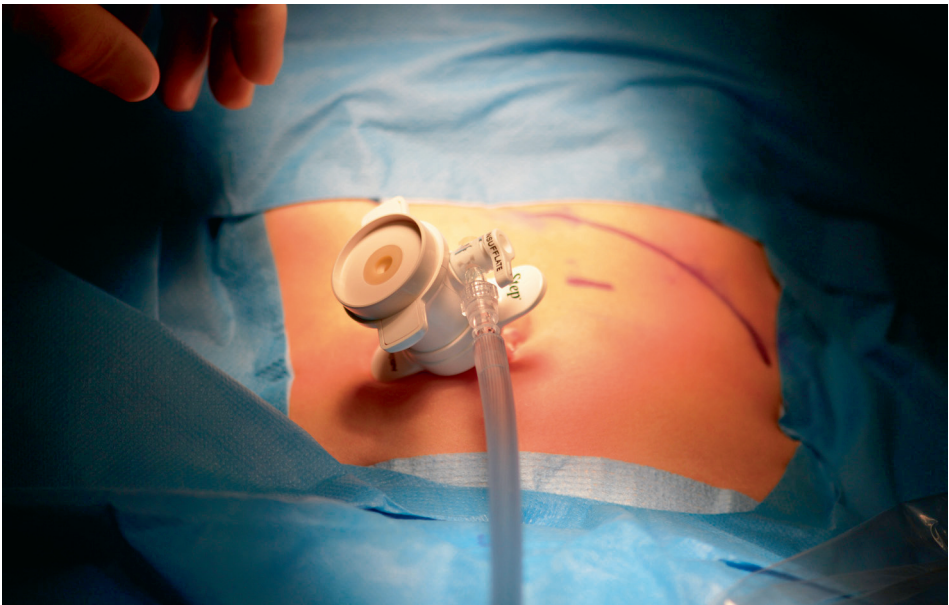


Figure 3. The trocar is placed and insufflation of CO₂ is started to achieve pneumoperitoneum.

The abdomen is insufflated with CO₂, up to a pressure of 8-10 mmHg at a flow rate of 1.0-1.5 l/min, to achieve pneumoperitoneum. Using a 30° laparoscope through the 3 mm port, the ventricle is detected intra-abdominally (Figure 4).

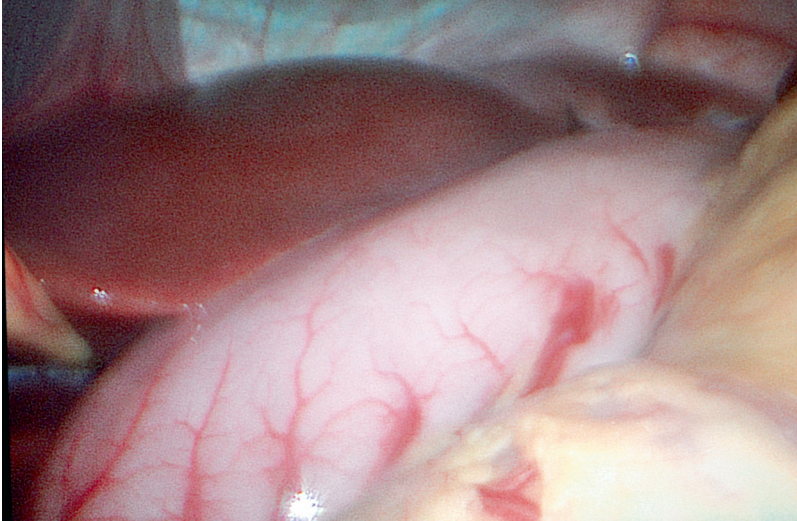


Figure 4. The ventricle in the centre and the liver up to the left.

A site for the gastrostomy is chosen approximately at the midpoint from the left costal margin and the umbilicus. This site should be placed over the left rectal muscle and far enough from the costal margin to ensure that the button does not ride against the cartilage when the abdomen is desufflated. A small skin incision is made at this point and a 5 mm trocar is inserted intra-abdominally under visual control with the laparoscope (Figure 1 and 5).

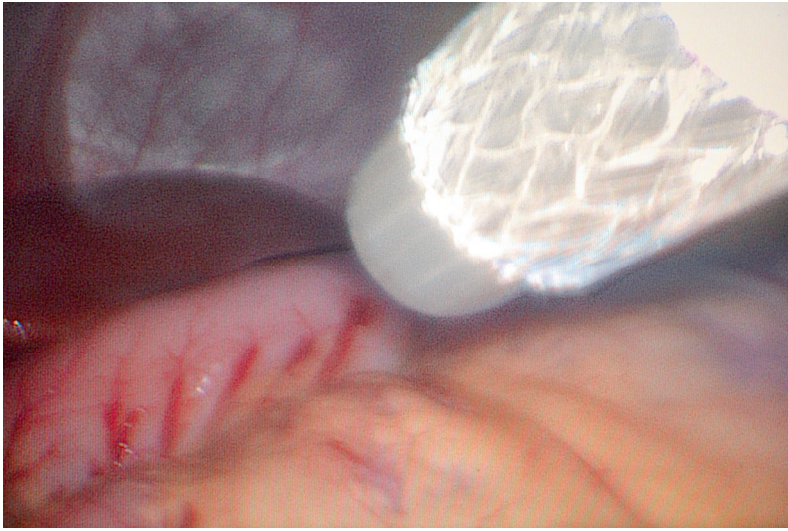


Figure 5. A 5 mm trocar is inserted safely intra abdominally under visual control with the laparoscope.

Through this port the ventricle is grasped with an instrument at the site selected for the gastrostoma at its major side (Figure 6). The grasping site needs to have clear margins from the pylorus to prevent gastric outlet obstruction caused by the intraluminal balloon on the gastrostomy tube; this is especially important in small infants.

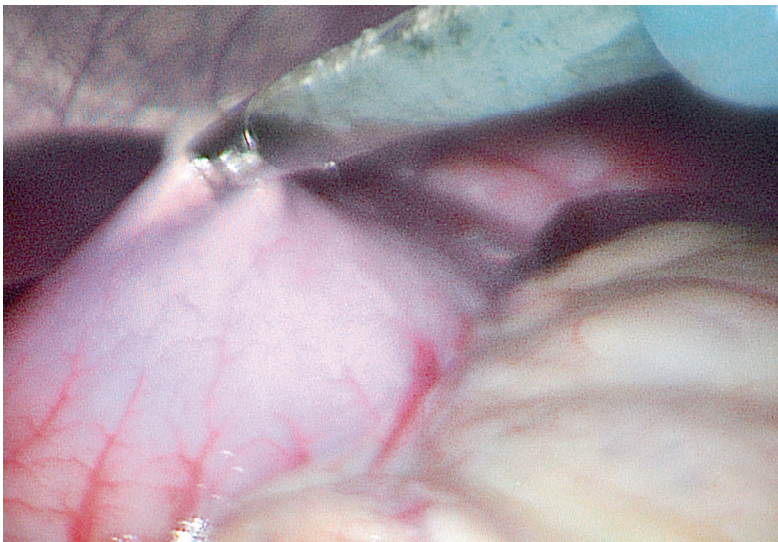


Figure 6. The ventricle is grasped with a laparoscopic instrument at its major side with clear margins from the pylorus.

The ventricle is exteriorized when the trocar and the grasper is withdrawn (Figure 7).

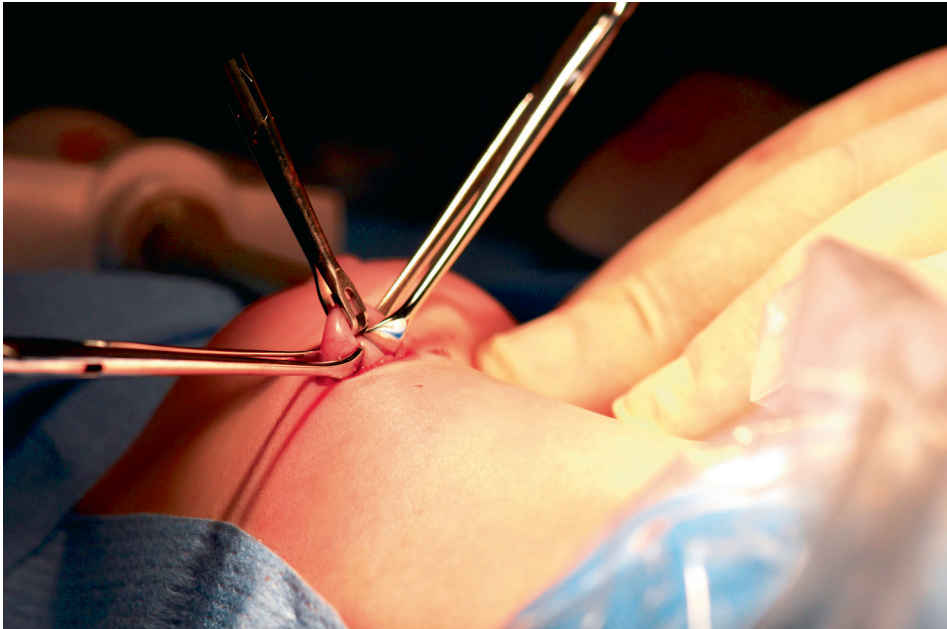

Figure 7. The ventricle is exteriorized and held with the laparoscopic instrument in the middle and two external graspers on either side.

A clamp is commonly used to mildly dilate the tract to allow adequate access of the ventricle through the skin incision. The ventricle wall is then sutured and attached to the abdominal wall with an absorbable continuous double U-stitch suture, described in Paper IV (Figures 11-15). After placing the suture, an incision is made in the ventricle using scissors (Figure 8). An appropriately sized gastrostomy tube is chosen, after measuring the thickness of the abdominal wall, and placed in to the ventricle cavity over a catheter used as a guidewire (Figure 9).

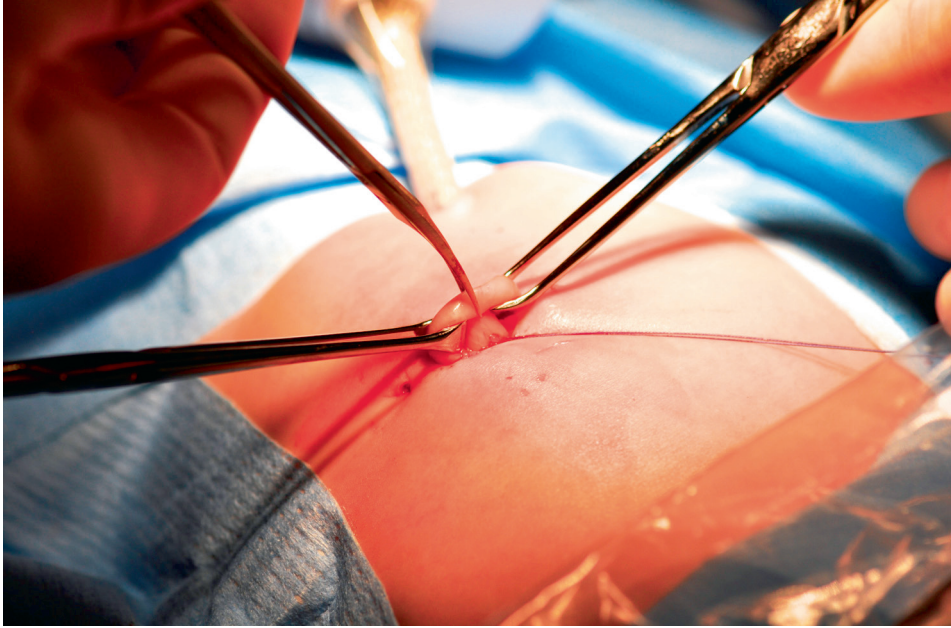


Figure 8. The ventricle wall is opened using a scissor (the instrument in the middle).

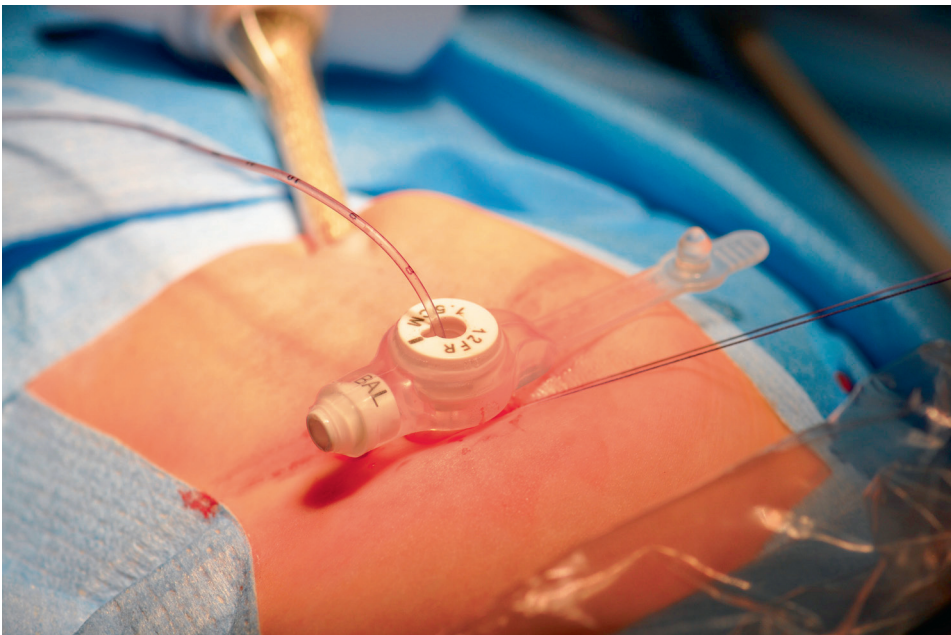


Figure 9. The continuous double U-stitch suture is tied after the gastrostomy tube is placed in the ventricle cavity.

The double U-stitch suture is tied, without forming dimples in the laterally placed skin incisions (Figure 9). The balloon is inflated with approximately 3-5 ml sterile water and the skin incision around the button is sometimes tightened with one suture.

To ensure that the gastrostomy tube is correctly placed in the ventricle, a gastroscopy is performed as the last part of the operation (Figure 10).

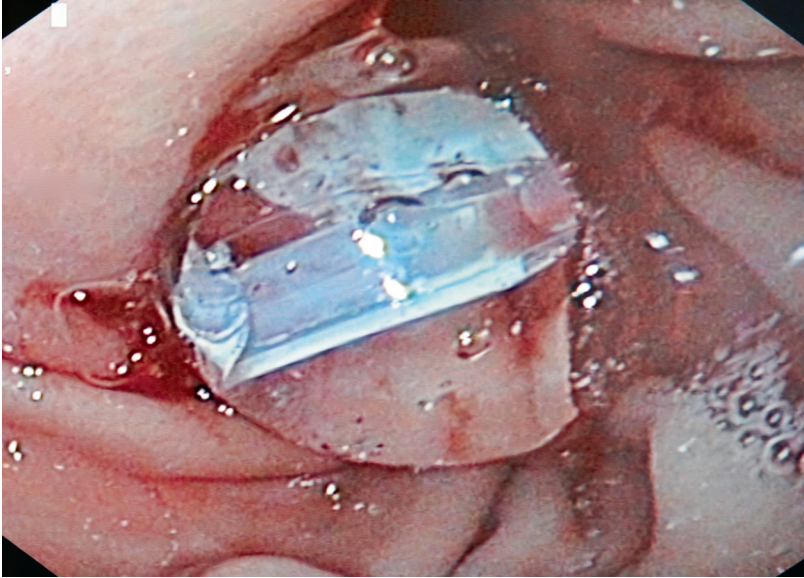


Figure 10. The inflated balloon in the gastrostomy tube is visualized by gastroscopy confirming a correct placement.

In all five papers

- All children in our studies were operated on with a VAG procedure. The indication for a gastrostomy was a need for long-term enteral nutritional support exceeding 3 months.
- Preoperatively all children underwent an upper gastrointestinal X-ray including the oesophagus, stomach and duodenum to rule out any gastric outlet obstructions, severe gastro-oesophageal reflux or hiatus hernia. 24 h pH monitoring was not routinely performed.
- The operation was never performed prophylactically.
- Prophylactic antibiotics were given preoperatively.
- The VAG operation was performed when the children were considered to be in such a condition that surgical intervention was judged to be safe.
- All operations were performed according to the operational description “The Video Assisted Gastrostomy (VAG) procedure”, see above.
- Nutrition through the gastrostomy was started 4-6 hours after surgery, and continued with increasing amounts of fluid as tolerated by the child. Oral feeding and bolus feeding through the gastrostomy were used in all children.
- A specially trained nurse documented all complications according to a special protocol at follow-up controls the first postoperative days until admission and at one and six months after the operation. The endpoint in all five studies was at six months after surgery.
- Only postoperative complications requiring some kind of treatment were included. Documented complications were: development of granulation tissue resulting in intervention such as cauterization or extirpation, infections requiring antibiotics and external leakage demanding some form of management.

Table 1 Summary of all patients in the different studies listed. Number, age and gender of the patients at the time of the study are presented. (SP=Study patient), (CP=Control patient), (m=months), (y=years)

Patients in studies I-V

Paper		Number of pat	Mean age \pm SD	Range	Gender male/female
I	SP	53	6m \pm 3m	3m-11m	35/18
II	SP	27	6.1y \pm 5,4y	6m-18y	16/11
	CP	27	6,0y \pm 5,0y	5m-16y	16/11
III	SP	15	4.2y \pm 4,2y	2m-12y	8/7
	CP	15	4.1y \pm 4,0	4m-11y	8/7
IV	SP	62	2.7y \pm 3,1	1m-14y	39/23
	CP	68	2.9y \pm 3,4	1m-12y	36/32
V	SP	180		1m-14y	

Paper I

This study was performed to report our experience with the VAG technique in children less than 1 year of age.

A total number of 53 severely disabled children underwent the VAG operation during the period from January 1997 through March 2003.

For demographic data see Table 1 and for underlying diagnoses see Table 2.

All the children were prospectively followed up recording complications and weight. The outcome measure was the number and type of complications as well as the weight gain using the age-adjusted Z-score of weight. The body weight was recorded on the day before the operation and at follow-up 6 months later. The Z-score of weight was calculated as: (actual weight - mean weight) / standard deviation (Liou 2001) according to the national standardized weight curves (Albertson-Wikland 1994). No correction was made for prematurity. If the Z-score of weight after operation was higher than before, it indicated an accelerated weight gain i.e. catch-up

Table 2 The underlying diagnosis noted in 53 children, less than 1 year of age, undergoing VAG

Diagnosis	Number of patients
Neurological dysfunction	19
Metabolic disorders	13
Chromosomal anomalies	8
Cardiac anomalies	7
Respiratory insufficiency	6
Total	53

Statistical analysis

The Wilcoxon Signed Rank test for paired samples was used for statistical calculations. A p-value < 0.05 was considered significant.

Paper II

This study was performed to test the hypothesis whether the administration of chemotherapy close to a VAG operation influences the rate of postoperative complications in children with malignancies.

Included in the study group were 27 children with ongoing treatment with chemotherapy for malignant diseases and operated on with a VAG procedure during the period from 1997 through 2002. The children's demographic data are summarized in Table 1 and diagnosis in Table 3.

Table 3 Summary of diagnoses in 27 children with cytostatic treatment due to malignancies who underwent a VAG operation

Diagnosis	Number of patients
Acute leukaemia	11
Malignant CNS tumours	8
Neuroblastoma	3
Lymphoma	2
Rhabdomyosarcoma	1
Ewing's sarcoma	1
Malignant nasopharyngeal tumour	1
Total	27

The control group consisted of 27 neurologically impaired children, matched with the study group for age, sex, and operative procedure. They were selected from a cohort of 154 patients with neurological disabilities and operated on with a VAG

procedure during the same time as the study group. See Table 1 for their demographic data.

The decision to operate in the study group did not depend on the timing of given chemotherapy.

None of the patients were neutropenic at operation and their laboratory status is summarized in Table 4

Table 4 Laboratory status at operation of 27 children with malignancies undergoing a VAG procedure

Laboratory status at operation	Mean	SD	Range
Hb (g/l)	102	11	81-127
White blood count (x10 ⁹ /l)	6	7	1.1-9.3
Neutrophil count (x10 ⁹ /l)	2	1	0.7-4.6
Platlet count (x10 ⁹ /l)	271	218	29-805

The number of days after the last chemotherapy session to the VAG operation were documented, as well as the number of days after surgery until the start of the next postoperative treatment.

All children in the groups were prospectively followed after the surgery. All complications were correlated to the number of days elapsed from the last chemotherapy session to surgery and the number of days from surgery to the first chemotherapy session after the operation.

Statistical analysis

Each patient with malignant disease was matched with a control patient with corresponding personal data. McNemar's test was used in order to find possible differences between "effect of exposure" and "effect of control" and achieve significant p-value of < 0.05. The 27 patients receiving chemotherapy and the 27 patients in the control group were considered as two independent groups in a case-control study.

To test the possible statistical correlation between postoperative complications and chemotherapy given pre- and postoperatively Spearman's rank test was used.

Paper III

This study was performed to see if the presence of a ventriculo-peritoneal shunt (VPS) influences the frequency of postoperative complications after a VAG operation in children.

The study group consisted of 15 children with a VPS due to underlying neurological diseases. All VPS had been placed at least 8 weeks before the VAG operation. All the patients were prospectively followed up.

Included in the control group were 15 neurologically disabled children without a VPS. They were retrospectively selected and matched for age, sex and operative procedure from a cohort of 167 patients operated on with a VAG procedure during the study period.

Demographic data and the children's diagnoses are summarized in Tables 1 and 5.

No patient in the study group had any signs of intra-peritoneal infections at the time for surgery. Prophylactic antibiotics (Cefuroxim 20 mg/kg body weight) were given prior to the operation in both groups.

Table 5 The diagnoses summarized in both groups in the study

Diagnosis	Study group with VPS	Control group
Brain tumour	6	
Hydrocephalus/myelomeningocele	3	
Premature with intracranial bleeding	3	
Malformation or syndrome	2	
Post traumatic brain damage	1	
Neurological dysfunction		
Cerebral palsy		15

Statistical analysis

Student's t-test for paired samples was used to achieve significant p-value of < 0.05 . Wilcoxon's non-parametric test gave the same result.

Paper IV

This study was performed to evaluate if a new surgical technique when adapting the ventricle to the abdominal wall influences the rate of postoperative complications after a VAG operation.

The study included 130 children who were operated on with a VAG procedure during the period January 2005 through December 2008.

The study group consisted of the 62 latest consecutive children operated on with the new suturing technique. The control group consisted of the latest 68 children, operated on with our previously used suturing technique when adapting the ventricle to the abdominal wall.

The demographic data of the children in both groups are summarized in Table 1 and their diagnosis in Table 6

Table 6 Diagnoses of the children included in the study

Diagnosis	Study patients	Control patients
Cerebral Palsy	31	29
Metabolic disease and syndrome	10	15
Gastrointestinal malformations	6	9
Malignancy	7	8
Cardiac anomaly	8	7
Total	62	68

All the children in the control group were operated on with the previously used suturing technique when adapting the ventricle to the abdominal wall. After the ventricle was exteriorized through the skin incision at the midpoint from the costal margin and umbilicus, two concentric purse-string sutures were placed with a distance of approximately 1-2 centimetres from one another in the ventricular wall and making a canal of ventricular tissue up to the skin as a modified Stamm fistula. The sutures were attached to the anterior rectus muscle fascia in the gastrostoma's superior and inferior limitations but not ligated until the button was in place in the ventricular cavity.

In the study group we used the new suturing technique after the ventricle was exteriorized as earlier described. A small skin incision was made approximately 1-2 cm on each side of the gastrostoma (Figure 11). The ventricle wall was attached superiorly with an absorbable suture. The needle was pulled through the entire abdominal wall including the rectus muscle, and up in one of the skin incisions (Figure 12). The needle was then turned 180 degrees and passed back through the abdominal wall and up in the gastrostoma where the ventricle wall was attached

inferiorly (Figure 13). The procedure was then repeated on the contralateral side of the gastrostoma, passing the needle through the abdominal wall to the skin incision and back to the gastrostoma where the ventricle wall was attached for the second time superiorly (Figure 14 and 15). Thus, the ventricle was fixated to the abdominal wall with a continuous double U-stitch suture forming a purse-string in the abdominal wall with the gastrostoma in the centre of the loop. To facilitate placement of this suture, the exteriorized ventricle could be pulled back into the abdomen, with a grasper in its wall, allowing greater exposure of the fascia. The ventricle was opened and the gastrostomy tube put in place in its cavity and the balloon inflated with sterile water. The suture was not ligated before the button was in place. To ensure correct placement of the gastrostomy tube, a gastroscopy was performed as the last part of the operation.

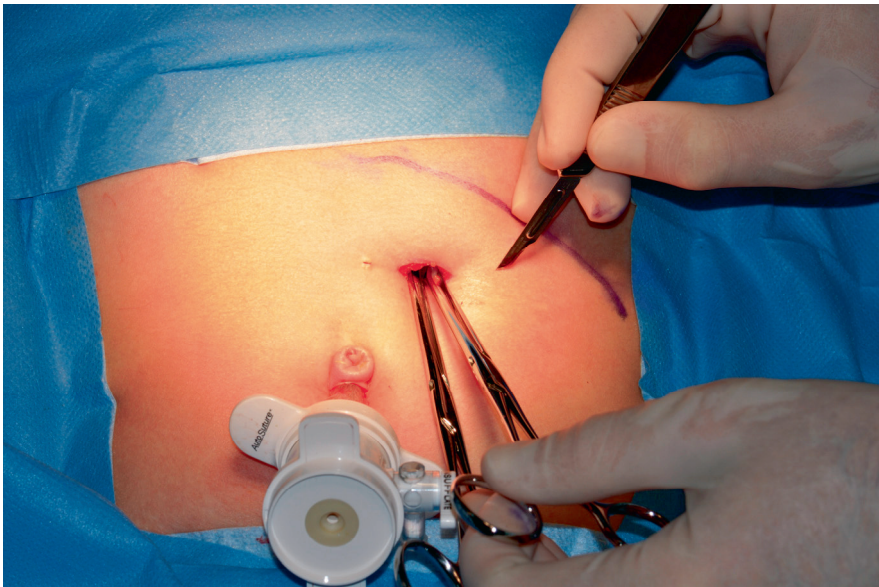


Figure 11. Small skin incisions are made on both sides of the gastrostoma.

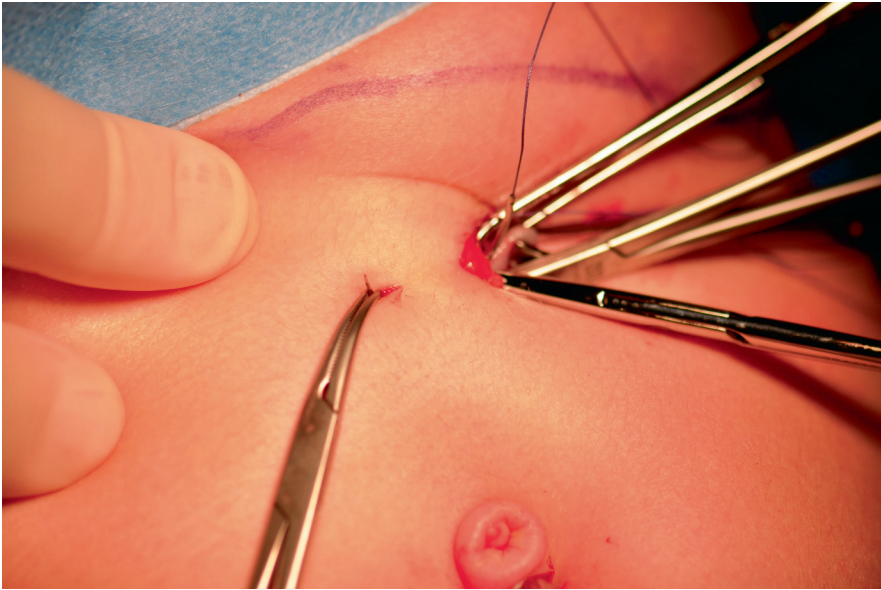


Figure 12. The needle is pulled through the entire abdominal wall from the gastrostoma to the skin incision after the ventricle wall was attached superiorly.

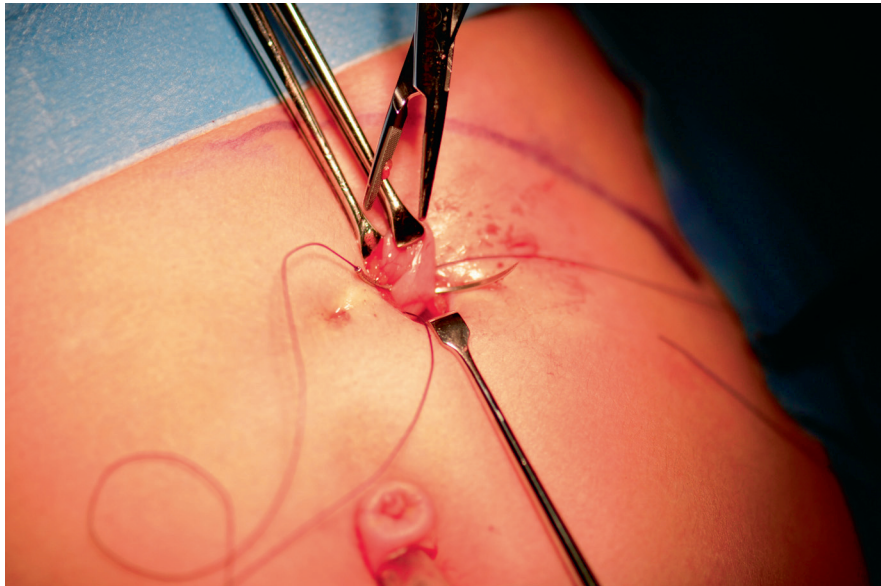


Figure 13. The needle was turned 180 degrees and pulled back through the abdominal wall and attaching the ventricle wall inferiorly.

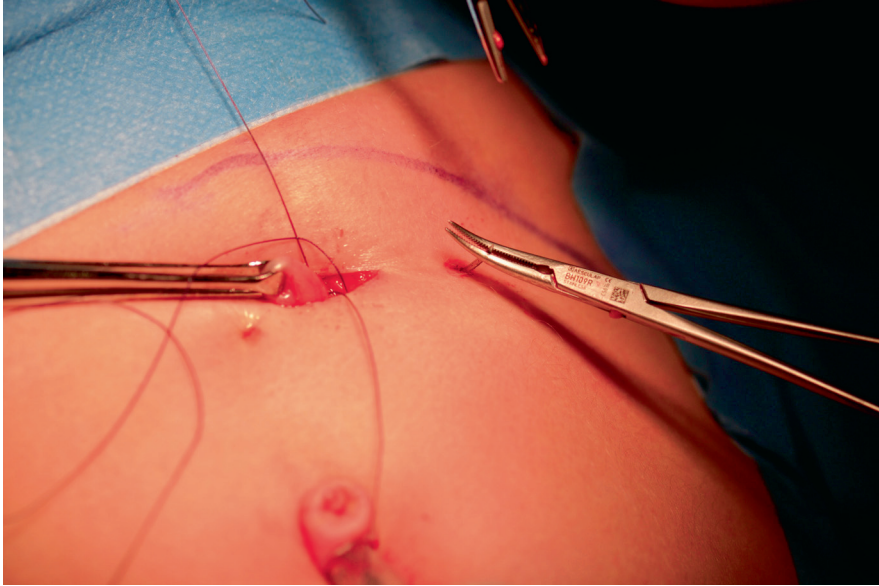


Figure 14. The needle pulled through the abdominal wall to the skin incision on the other side of the gastrostoma.

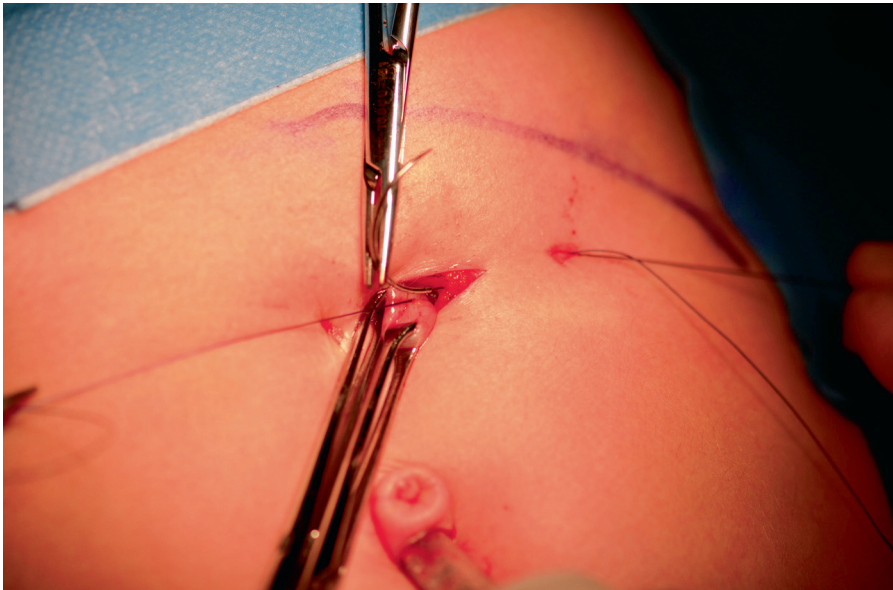


Figure 15. Completing the continuous double U-stitch suture when the needle is pulled back to the gastrostoma and the ventricle attached for the second time superiorly.

Statistical analysis

Students t-test for paired samples was used. The non-parametric Wilcoxon test gave the same result. A p-value < 0.05 was considered significant.

Paper V

This study was performed to evaluate the vomiting frequency pre- and postoperatively in children undergoing a VAG operation.

From June 2006 to December 2011, 180 children underwent a VAG operation and all were included in this study. The children were subdivided into groups based on their underlying diagnosis.

Their demographic data are summarized in Table 1 and their diagnoses in Table 7.

Table 7. The diagnoses of the 180 patients included in the study

Diagnosis	N
Cerebral palsy	61
Cardiac malformation	30
Metabolic disease	37
GI malformations	7
Malignancy	11
Respiratory insuffience	15
Syndrome	19
Total	180

An anamnesis with respect to vomiting was taken from the patients and their parents before the operation. Vomiting was documented pre- and postoperatively according to the parents' experiences of the frequency of vomiting during the follow-up. In other words, there were no exact measurements of the frequency of vomiting (vomit/day) or of the amount of vomit (millilitre), but the symptoms were based upon the parents' observations.

The patients were prospectively followed up.

Statistical analysis

Data were analysed by Fisher's exact t-test and a non-parametric statistical analysis including the Mann-Whitney test.

A p-value < 0.05 was considered significant.

Results

In all five Papers

- All the patients were operated on with a VAG operation, described earlier in “Material and Methods”. In Papers IV and V, the new suturing technique was used when adapting the ventricle to the abdominal wall.
- There were no serious per- or postoperative complications such as gastrocolic fistula, puncture of hollow organs in the abdomen, bleeding, intra-abdominal leakage or tube dislodgement.
- The VAG operation procedure was well tolerated by all the patients and no reoperations were required.

Paper I

Complications seen in the study group are summarized in Table 8. Granulation tissue formation requiring cauterization and extirpation under general anaesthesia was seen in 2 patients. Minor infections around the stoma treated with antibiotics were seen in 10 patients. Fifteen patients had irritation localised around the stoma due to slight leakage around the gastrostomy button and were treated conservatively. In 5 patients the gastrostomy button was removed for 24-48 h to let the stoma constrict before replacing the gastrostomy button.

Vomiting was a clinical problem in 27 patients before surgery according to the parents' observations and not further defined by us. Fourteen patients had persisting vomiting problems at 6 months after surgery and were treated conservatively by thickening the food, changing posture after the meals and, in two patients, medication with proton pump inhibitors. The problem decreased with time in most patients, see Table 8, but led to a need for temporary gastro-jejunal tube feeding in 2 patients. Anti-reflux surgery was considered unnecessary in this patient group.

Table 8 Summarized complications seen at 1 and 6 months after a VAG operation in children under 1 year of age

	Pre-op	1 month	6 months
No gastrostomy problems		9	32
Granuloma formation		27	6
Extirpated under general anaesthesia			2
Local treatment		27	4
Leakage		14	6
Conservatively treated only		13	2
Button removed for 12-24 h		1	4
Infection		13	2
Local treatment		13	2
Antibiotics		8	2
Vomiting problem	27	25	14
Increased		5	2
Unchanged		8	2
Decreased		12	10
Changed to gastro-jejuno tube due to vomiting			2
Gastrostomy button removed, no longer needed			1
*Died of their underlying disease			4

*Intracranial bleeding due to astrocytoma (n=1), progressive neurological disease (n=1), circulatory failure with constricted cardiomyopathy (n=1), single ventricle anomaly with double outlet right ventricle, mitral atresia and hypoplastic aortic arch (n=1)

The weight before and 6 months after surgery is summarized in Table 9 together with the Z-score increase, indicating a postoperative weight catch-up and showing a significant increase in weight-for-age, $p < 0,001$.

Table 9. A summary of changes in weight before and 6 months after a VAG operation in 53 children under 1 year of age

	At the operation	6 months post-op
Number of patients	53	49
Male/ Female	35 / 18	31 / 18
Age, months	6 ± 3	
Range	3 - 11	
Weight, kg	5.5 ± 1.6	8.5 ± 1.6
Range	2.6 – 9.3	4.6 – 12.8
Z-score *	-2.7 + 1.5 **	-1.7 + 1.0 **
Range	-0.13 to -5.58	-0.40 to -5.20
Increased		44
Decreased		5

These figures are also expressed as weight-for-age Z-scores. * Calculated as (actual weight – mean weight) / standard deviation (ref Liou), according to the nationally standardized weight curves (ref Albertson-Wikland). ** A significant difference was found between the Z-score at operation compared with 6 months later, $P < 0.001$

Paper II

In Paper II the study group consisted of children with malignant diseases and the control group neurologically impaired children. The number and type of complications in the two groups are summarized in Table 10. There was no difference in postoperative complications between the children with malignant diseases compared with the neurologically impaired children.

Table 10. Summary of postoperative complications in the two groups

	Children with malignant disease	Children with neurological impairment
Number of patients	27	27
Complications during the first postoperative month	5	6
Granuloma	10	7
Infection	5	4
Complications at 6 months postoperatively	8	5

The relation between surgery and the elapse of time from the pre- to the postoperative administration of chemotherapy is summarized in Table 11. The 27 patients treated for malignant diseases were indexed and ranked according to post-surgery complications. The possible statistical correlation between those ranked values and (a) the number of days from interrupting the chemotherapy administration until the day of surgery, and (b) the number of days from surgery until reinitiating the chemotherapy administration was computed using Spearman.

No significant correlation was seen between the variables and the postoperative complication rank ($R(\text{rank: variable (a)}) = -0.19, p=0.92$); and ($R(\text{rank: variable (b)}) = 0.11, p = 0.58$).

There was no increase in postoperative complications relating either to a shorter interval from the last preoperative treatment with chemotherapy or timing of the first postoperative chemotherapy treatment.

Table 11. Postoperative complications relating to the time from the last preoperative treatment or to the first postoperative cytostatic drug treatment. Statistical correlation using Spearman

	Total no of patients	Granuloma	Infection	Leakage external	Problem 6 mo post-op
Number of days from last cytostatic treatment to surgery					
< 14 d	4	0	1	0	1
14-18 d	4	2	3	0	2
21-28 d	8	0	3	2	2
> 30 d	11	3	3	3	3
					p=0.92
Number of days from surgery to first cytostatic treatment					
No treatment	6	3	2	1	0
0-3 d	6	0	2	2	3
4-7 d	6	0	2	0	1
12-28 d	5	2	1	2	3
> 30 d	4	0	3	0	1
					p=0.58

No correlation was seen between white blood cell count, neutrophil count or platelet count at the time of surgery and the frequency of postoperative complications.

Paper III

In Paper III the study group with neurologically impaired children with VPS was compared with a control group of neurologically impaired children without a VPS. There were no significant differences in the frequency of postoperative complications between the two groups, see Table 12. No children in the study group with VPS presented any serious postoperative intra-abdominal complications or central nervous infections due to shunt catheter infection.

Table 12. Summary of the number and type of complications in the two groups of patients.

	Pat with VPS	Pat without VPS
Complications during the first post-op month		
Granuloma	7	6
Infection	3	5
Leakage	2	1
Complications at 6 months postoperation	3	4

Paper IV

In Paper IV the study group consisted of children in whom a new technique was used for adapting and suturing the ventricle wall to the abdominal wall. In the control group a double purse-string suture was used for adaptation. There were no significant differences between the two groups regarding age, sex, body weight and length, see Table 13.

Table 13. Summary of demographic data in the two groups

	Study group	Control group	<i>p</i> -value
Number of patients	62	68	
Male / Female	39 / 32	36 / 32	
Age (years) mean \pm SD	2.7 \pm 3.1	2.9 \pm 3.4	
Median (range)	1.5 (0.1-12)	1.8 (0.1-14)	
Body weight (kg)	11.2 \pm 7.0	11.1 \pm 7.0	0.98
Z-score for weight	-2.2 \pm 1.8	-2.0 \pm 1.7	0.67
Range	-7.1-0,3	-6.6-1.9	
Body height(cm)	82 \pm 23	83 \pm 26	0.97
Median	74 (55-147)	76 (50-159)	
Z-score for height	-1.7 \pm 1.5	-2.0 \pm 1.8	0.95
Range	-5.8-0.9	-7.0-1.7	

There was no difference between the study group and the control group with regard to the operating time for placement of a button, the time to full enteral feeding, the treatment of postoperative pain and the duration of hospital stay.

Complications in the study and control group are summarized in Table 14. In the study group we found a significantly lower incidence of granuloma around the gastrostoma compared to the control group.

Table 14. Summary of the number and type of complications presented during the first six postoperative months in the two groups

	Study group	Control group	p-value
Leakage	11 (18%)	13 (19%)	0.88
Granuloma	18 (29%)	37 (54%)	0.01*
Infection	15 (24%)	19 (28%)	0.32

*Significant difference between the two groups

Paper V

In Paper V the study group consisted of children subdivided into groups based on their underlying diagnosis.

The incidences of vomiting pre- and postoperatively are summarized in Table 15. In the group of 51 children with preoperative vomiting symptoms, 43 (84%) had symptoms one month after surgery and 40 (78%) had remaining symptoms at the endpoint of the study, 6 months postoperatively.

Table 15. Vomiting pre- and postoperatively after operation using the VAG technique in 180 children

Vomiting pre-op	Vomiting post-op	Vomiting post-op	
		1 month	6 months
N =180			
Yes 51	Yes	43	40
	No	8	11
No 129	Yes	2	14
	No	127	115

Of the children who had no preoperative vomiting symptoms (n=129), 14 (11%) had a gradual increase in vomiting frequency during the follow-up.

The vomiting frequencies in each group of patients pre- and postoperatively and at the 6 month follow-up are listed in Table 16.

Table 16. The diagnosis of the included 180 patients and their vomiting frequency pre- and postoperatively at study endpoint at 6 months. The children had comorbidity in the form of epilepsy in 27 patients (17%), ventricular-peritoneal shunt in 9 patients (5%) and mitochondrial disease in 6 patients (4%)

Diagnosis	N	%	Vomiting pre- op	%	Vomiting post- op	%
Cerebral pares	61	34	12	24	14	35
Cardiac malformation	30	17	11	22	7	18
Metabolic disease	37	21	10	20	5	13
GI malformations	7	4	2	4	1	3
Malignancy	11	6	2	4	2	5
Respiratory insufficiency Syndrome	15	8	7	14	6	15
Sum	180	100	51	100	40	100
P-value			P=0.0152		P=0.0049	

There were differences in vomiting frequencies between the patient groups based on the underlying diagnosis both pre- and postoperatively ($p=0.0152$ and $p=0.0049$). There was, however, no difference in vomiting frequency pre- and postoperatively within the same patient group.

The development of granulation tissue and vomiting were the most common postoperative complications; these are shown together with the other registered complications in Table 17. Most of the patients had full resolution of their complications at six months after surgery ($p<0.05$) except vomiting and tube dislodgement (Table 17).

Table 17. Minor complications found at prospective follow-up in 180 patients operated on with the VAG technique. Statistical method: Fisher's exact t-test.

Minor complications	1 month	6 month	P-value
Vomiting	51 (28%)	40 (22%)	0.148
Granulation tissue	49 (27%)	24 (13%)	0.002
Infection	36 (20%)	5 (3%)	0.001
Infection treated with antibiotics	26 (14%)	4 (2%)	0.001
Leakage	26 (14%)	6 (3%)	0.002
Tube dislodgement	8 (4%)	10 (6%)	0.809

Discussion

Children who are unable to receive normal oral feeding due to underlying diseases, but where the gastrointestinal tract is intact, need enteral nutritional support. For short-term use a nasogastric tube is chosen, but if the need for support is prolonged for more than three months a gastrostomy is preferable (Behrens 1997, Norton 1996). Over the years, many different operative techniques have been developed for establishing a gastrostomy, striving to minimize the rate of postoperative complications and to optimize the wellbeing of the patient postoperatively and increase the safety of the surgical procedure. After its introduction in 1979 (Gauderer 1980), the PEG method became widespread and was used in both paediatric and adult surgical care. In 1991 the first laparoscopic-assisted gastrostomy was established (Edelman 1991, Shallman 1991). At our Department of Paediatric Surgery we have used the laparoscopic technique in the VAG method since 1994 (Mikaelsson 1995, Andersson 1997) and so far approximately 1000 gastrostomies have been established. Over the years we have had great interest in following our patients thoroughly concerning postoperative complications in order to gain more knowledge, in turn, hoping to serve our patients better. Our efforts have resulted in several publications.

This thesis deals with children with different diseases who all are operated on with a VAG procedure. In the five papers included in the thesis we have looked at the feasibility of operating children under 1 year of age (I), children with malignancies under cytostatic medication (II), children with a former VPS insertion (III), children in which a new suturing technique was applied when placing the gastrostomy (IV) and finally we aimed at determining whether or not a VAG operation influences vomiting symptoms (V). All five papers are clinical work.

Gastrostomy in infants less than 1 year of age

The first aim in this thesis was to;

“Report our experience of a VAG operation in infants less than 1 year of age with regard to postoperative complications and long-term weight gain”.

Surgery performed on small children poses other questions and problems compared with surgery on older individuals. Children are not “small adults” in aspects of perioperative management, including nursing as well as anaesthesiological and surgical considerations. Because of this it is our opinion that paediatric surgery should be concentrated to centres with these facilities.

In laparoscopic surgery on infants, anaesthesia aspects as well as the physiological effects of MIS have to be considered. While achieving pneumoperitoneum with CO₂-insufflation, the neonates’ sensitivity to CO₂ absorption, hypercapnia, has to be taken into consideration to avoid the development of respiratory acidosis and blood pressure fall. Combined with surgical aspects i.e. small spaces and technical challenges with a potential unacceptable high risk for the patients, the development of MIS in neonates and children was delayed in the 1990s. However, with improved and adjusted surgical instruments for neonates and children, development of modern CO₂ insufflators and more skilled surgeons due to special training, advanced procedures are now performed safely. Recent publications (Al-Qahtani AR 2006, Ponsky 2008, Parelkar SV 2013) conclude that MIS in newborns and small infants weighing less than 5 kg nowadays is a feasible and safe procedure. Operations like a laparoscopic fundoplication, with low complication and conversion rates, appear to be well suited for average-trained paediatric laparoscopic surgeons even outside MIS centres, if enough anaesthesia competence is available. More complex MIS procedures such as repair of oesophageal atresia and diaphragmatic hernia are feasible but technically much more demanding and require the highest level of expertise for a successful outcome (Chandrasen 2009).

A VAG procedure in infants is not considered a technically demanding surgical procedure but there is still a need for a high level of anaesthesia competence in combination with experienced surgeons for a safe performance. In the group of infants less than 1 year of age with severe diseases, we noticed increased requests for a VAG operation during the study period. Since the age group was considered special in many aspects discussed above and the experience limited concerning the performance of a VAG operation, we were interested to learn of the outcome.

In our study (I), we found that postoperative complication rates after a VAG procedure were lower than reported in the literature for both PEG and open surgical

gastrostomy performances (Haws 1966, Larson 1987, Gauderer 1991 2001, Marin 1994, Khattak 1997, Patwardham 2004). We did not see any major complications such as gastro colic fistulas, bleeding, peritonitis or leakage into the abdominal cavity. No differences were seen in incidence of complications between the different patient groups in the study. No obvious complications from the administration of anaesthetics were recorded but in some cases the child needed postoperative care at the PICU because of deterioration of their underlying disease.

Even though almost all the infants were nutritionally supported with a nasogastric tube preoperatively, we found, as previously reported in the literature, an improvement in the patients' nutritional status after the VAG operation at the study endpoint at six months (Andersson 1997, Chang 2003).

Using the age-adjusted Z-score of weight (Liou 2001), according to the nationally standardized weight curves (Albertsson-Wikland 1991), we found a postoperative significant increase in weight i.e. a weight catch-up at study endpoint.

Based on our findings in Paper I, we consider a VAG operation a safe way to establish a gastrostomy in infants less than 1 year of age. We also believe that enteral nutritional support through a gastrostomy is beneficial with regard to weight gain and weight catch-up.

Gastrostomy in children with malignant diseases

The second aim in the thesis was:

“To determine if pre- or postoperative administration of chemotherapy close to a VAG operation, influences the rate of postoperative complications in children with malignant diseases”.

Malignant diseases as well as chemotherapy treatment may lead to malnutrition in patients due to loss of appetite, nausea, vomiting and mucositis (Mathew 1996, Pedersen 1999, Skolin 1997). Enteral feeding is often established with a nasogastric tube but due to mucositis caused by the chemotherapy treatment this might cause severe discomfort for the patient making gastrostomies a possible alternative for enteral feeding.

Total parenteral nutrition (TPN) can be effective in reversing the malnutrition associated with cancer and its treatment (Aquino 1997). Parenteral nutrition, given in the same central venous catheter (CVC) as the chemotherapy, always carries the risk for catheter related infections with subsequent complications such as sepsis and the need to remove the CVC. This might, in turn, lead to a possible delay in the chemotherapy treatment regime (Christensen 1993).

In 1997 Aquino et al. found that the same benefits regarding nutritional status that are seen with parenteral TPN were found with a PEG for enteral nutritional support in children with cancer, but without the serious complications seen in patients on TPN (Aquino 1997).

Surgical interventions in patients with malignancies that are treated with chemotherapy have always been a matter of timing in order to avoid pre- and postoperative complications. Depletion of white blood cells including neutrophil count as well as platelets are well known side effects of the treatment, and values are carefully registered during the treatment to find optimal conditions for surgery when such interventions are needed

In our study group including children with malignancies, a VAG operation was performed to adequately support the children with enteral feeding when the use of a nasogastric tube had failed. Several questions needed to be answered. Should chemotherapy be withheld during the week before surgery and/or the first postoperative days? Is the rate of postoperative complications influenced by administration of chemotherapy? To our knowledge no studies with similar questions had been published, and this increased our curiosity.

Children with malignancies are special in their clinical spectra due to their underlying malignant disease and different cytotoxic drugs, and therefore hard to match with a relevant control group. Neurologically impaired children were chosen because this is the largest group of children operated on with a VAG and therefore the easiest to match regarding age and sex with the children with malignancies.

A more logical and even more interesting study would have been to compare children with ongoing chemotherapy treatment divided into two groups, one group with and another group without cytotoxic effects e.g bone marrow depression. Because a VAG operation never has been performed prophylactically at our department but always because of a need for nutritional support, a study like that would have been unethical and impossible to do.

In our study we did not find any difference in postoperative complications between the two groups i.e. malignancies vs neurological impairment. There was no increase in frequency of postoperative complications either in children receiving chemotherapy within a few days prior to the operation or within the first postoperative week. There was no correlation between laboratory status concerning white blood cell count, neutrophils and platelets at the time of surgery and the frequency of complications.

We were surprised by the results of our study. We had expected to find an increased frequency of complications in children who received chemotherapy within the perioperative period, based on our experience before starting the study. These findings might be explained by the small study population, but were nevertheless unexpected.

Despite our findings, we recommend a chemotherapy free interval for some days both before and after a VAG operation despite lack of evidence for this advice. This recommendation is especially addressed to children with Mb Down and acute lymphatic leukaemia, in which we have seen serious complications after the study was closed.

At the time of the study, it was a common policy at our department to provide almost all the children who had malignancies with a VAG. At other paediatric surgery centres in Sweden it was, and still is, almost mandatory to establish a gastrostomy before the start of the treatment, because of the strong probability that future nutritional support during the treatment would be required. However, nowadays it is a procedure almost never performed in children with malignancies at our department and there is no obvious reason for this trend.

Maybe improved routines regarding the care of the CVC have led to a lower complication frequency with regard to catheter related complications despite the fact that both chemotherapy and TPN are given simultaneously. The nutritional support is then provided parenterally, and the need for enteral feeding through a gastrostomy therefore reduced.

Another reason might be that our expectations of presumed complications, leading to delayed chemotherapy treatment according to protocol, keeps the number of operations down.

Based on our findings in Paper II we can recommend a VAG operation in children with a malignant disease in whom a nasogastric tube is poorly tolerated.

Gastrostomy in children with a VPS

The third aim of this thesis was:

To determine if the presence of a ventriculo-peritoneal shunt (VPS) influences the rate of postoperative complications after a VAG operation. Do children with a VPS run a higher risk for shunt infections after a VAG operation?

Children with neurosurgical diseases such as brain tumour, hydrocephalus-/myelomeningocele, intracranial bleeding due to prematurity, malformation or syndromes and post traumatic brain damage, among others, may require insertion of a VPS during their treatment. Despite treatment, all children will not improve sufficiently enough or even have the ability to recover a safe swallowing function, and as a consequence will benefit from long-term enteral feeding through a gastrostomy.

In daily practice we are sometimes counselled about the possibilities to establish a gastrostomy in children with a VPS. In this category of patients the indications for the procedure have to be narrowed down because an infection in a VPS might contaminate the CNS with subsequent potential risk for meningitis. Studies concerning safety with the combination of a gastrostomy insertion in patients with VPS are not many and the patient materials that have had both procedures performed are small. Only PEG procedures have been reported. With foreign material inserted in the body there is always a high risk for rejection or infection. In published studies the general incidence of infected VPS requiring revision for infection in patients without any other foreign devices varies from 5-10% (Taylor 1997, Schulman 2005, Nabika 2006, Roeder 2007, Cairns 2009). The same studies report VPS infections with coexisting PEG ranging from 0-50%.

So what are the risk factors? Does the timing between the PEG and VPS insertions influence the complication rate and does it matter which procedure is performed first?

Potential sources for VPS infection in combination with a PEG insertion are peritoneal contamination by skin bacteria as the trocar is inserted intra-abdominally or oropharyngeal contamination as the PEG is pulled through the pharynx. In addition there is a potential translocation of skin bacteria into the peritoneum during the healing of the gastrostoma, which normally takes about 2-4 weeks. Use of prophylactic antibiotics was recommended at PEG insertion for children with VPS (Taylor 2001). Recommendations for time between the two procedures vary from “at least 10 days” (Cairns 2009) to “at least 1 month” (Nabika 2006) to avoid infections. This is probably of great importance because in patients who had the procedures done more than 10 days apart, infection was seen in 14% of them, but if the procedures were performed within 10 days of each other the incidence was 30% (Cairns 2009). These recommendations are independent of which procedure is performed first.

In our study we used the VAG procedure for establishing the gastrostomy. We did not see any major complications such as VPS infections and thus no shunt revisions were performed. The reason for these findings can only be speculated upon. Maybe the study population is too small to achieve statistical significance. According to the literature the coexistence of VPS and a need for gastrostomy is a rather unusual combination but when comparing our material with other publications the number of patients is rather similar. Another reason for our findings might be that the time interval between the two procedures was more than two months in our study in contrast to the recommended 10 days to one month in the literature, and that has most likely benefited our outcome. Another possible and liable reason might be based on the operation method. Oropharyngeal bacterial contamination is avoided with a VAG procedure but the placement of the two trocars needed for a VAG procedure still remains as potential entrances for skin bacteria and peritoneal dissemination. Compared with the PEG procedure there is no need for maturation of the

exteriorized ventricle that has been sutured to the abdominal wall and skin during the VAG procedure and the risk for potential peritoneal contamination by skin bacteria is therefore decreased.

Based on our findings in Paper III we can recommend a VAG procedure in neurologically impaired children with a previously placed VPS.

The continuous double U-stitch suture

The fourth aim of this thesis was:

Is the rate of postoperative complications after a VAG operation influenced by the use of a new surgical technique when suturing the ventricle to the abdominal wall?

At the Department of Paediatric Surgery in Lund, gastrostomies have, as earlier described, been established by means of a VAG procedure since 1994 (Andersson 1997). At the start in 1994, the surgical technique to attach the ventricle to the abdominal wall was with two concentric purse-string sutures in the ventricle ligated to the rectus muscle in order to establish a canal of ventricular tissue. This is a modification of a Stamm fistula (Stamm 1894) and a rather easy technique to adapt and perform for the surgeon. The two purse-string sutures were placed 1-2 cm apart to make a 2-3 cm long canal from the proximal suture to the opening in the ventricle with a desirable anti-reflux mechanism. With such a long canal there will be a lot of ventricle tissue exteriorized in the gastrostoma after the purse-string sutures have been tightened. This tissue was susceptible for external influences from the gastrostomy button with potential risk for complications such as skin inflammation leading to infection and development of granulation tissue.

In many ways we were satisfied with the method. Compared to previously reported studies concerning PEG (Beasley 1995, Khattak 1998), the complication rates noted with our VAG method at that time (Arnbjörnsson 1998, 1999) were fully comparable with other techniques. We were not aware of any major complications such as gastrocolic fistulas in our material compared to an incidence of 3% in the PEG procedure (Khattak 1998, Patwardhan 2004), but the rate of minor complications was comparable with ours (Arnbjörnsson 1998, 1999). Even though minor complications such as leakage, granulation tissue around the stoma and infections are not life threatening, they consume a lot of resources at the out-patient clinic and cause parents and patients considerable frustration.

We therefore started to look for possible errors or weak points in our method and found that the suturing technique when adapting the ventricle to the abdominal wall was one. We suspected that the reason for granulation tissue formation and infections might be “the collar” of ventricle tissue that was exposed around the gastrostomy button when the two purse-string sutures were tightened, because of its susceptibility to mechanical trauma from the button. To prevent an excess of ventricle tissue we had to find a different suturing technique when attaching the ventricle to the abdominal wall.

In 2006 there was a study published by Aprahamian et al. using a suturing technique coined the U-stitch laparoscopic gastrostomy technique (Aprahamian 2006). With two separate non-absorbable U-stitches passed through both the abdominal wall and the anterior wall of the ventricle under videoscopic guidance, the ventricle was adapted. The double U-stitch method was first described by Georgeson in 1993 and was used when establishing a gastrostomy in combination with a fundoplication operation in children (Georgeson 1993, Sampson 1996).

This method inspired us and we used it as a model when creating our own technique, the continuous double U-stitch, described in the chapter Material and Methods. The aim was to create a safe suturing technique, with good cosmetic result and, of course, decrease the complication rates.

In our study we found a decreased incidence of granulation tissue when using the new suturing technique. This is probably because the continuous double U-stitch suture pulls the ventricle back into the abdomen when tightened and therefore reduces “the collar” of ventricle tissue in the gastrostoma as described earlier, instead of pulling the ventricle out as was the case with the double purse-string method. The two small skin incisions on either side of the gastrostoma enabled the suture to be tied subcutaneously and is not visible. To avoid small dimples in the skin and poor cosmesis, the suture should not be too tight but just tied enough to ensure closure of the knot and in combination with the inflated balloon in the gastrostomy button secure the ventricle to the abdominal wall and prevent dislodgement.

Based on our findings in Paper IV we recommend the continuous double U-stitch suture in the VAG procedure instead of the previously used purse-string suture.

Vomiting frequency in children undergoing a VAG operation

The aim of this supplementary paper was:

To determine the incidence of vomiting frequency pre-and postoperatively in children undergoing a VAG operation. Does the VAG procedure affect the vomiting frequency and is vomiting more frequent in certain diagnoses?

Vomiting or regurgitation of gastric contents into the oesophagus and mouth in infants and young children is a common symptom and is considered a natural process. The symptom often resolves spontaneously by the age of 12 to 14 months (Hegar 2013). If the symptoms continue and even become aggravated it is called gastro esophageal reflux disease (GERD) and will need treatment such as thickening of food, positional changes after meals, pharmacological treatment and in the worst cases anti-reflux surgery.

In children with severe diseases, the frequency of vomiting is high due to their underlying diagnoses and the treatment they are exposed to. Many of these children are also in need of long-term enteral nutritional support that is provided by a gastrostomy. Previous studies have disputed about the relationship between PEG insertion and eventual exacerbation of GERD symptoms, but no current evidence or data in the literature can convincingly demonstrate that PEG insertion precipitates or aggravates GERD (Noble 2012). In a study of children undergoing a VAG procedure no aggravation of acid reflux was seen postoperatively (Plantin 2006), which supports Noble et al in their conclusion.

In our study (V) we wanted to investigate the relationship between the specific vomiting symptom and a VAG procedure; we had two questions to be answered:

Does the VAG procedure affect the vomiting frequency?

The results of the study showed that vomiting is a common symptom both pre- and postoperatively in severely ill children. In the group of children with preoperative vomiting, 78% still vomited at six months postoperatively. These findings might indicate that the operation itself does not considerably influence the vomiting symptom, but that the reason why it persists is more likely to be found in the children's underlying diagnoses.

In the group of patients that did not vomit preoperatively there was a gradual increase in vomiting frequency of 1.5% at one month and 11% at six months postoperatively. These findings cannot be traced to a certain diagnosis or age group.

The reason or reasons behind this increase in vomiting frequency can only be speculated upon. One possible reason might be placement of the gastrostomy button

close to the pylorus, causing a slight gastric outlet obstruction. This was not, however, noted or commented upon during the gastroscopy at the end of the VAG procedure.

Another potential explanation for the increased vomiting frequency might be a general deterioration in the child's underlying disease.

This group might then be equalled with the group with preoperative vomiting, i.e. the cause is to be found in their underlying diagnosis and not in the VAG procedure.

The second question we sought an answer to was:

Is vomiting more frequent in certain diagnosis?

There was a difference in vomiting frequency between the patient groups based on their underlying diagnosis both pre- and postoperatively. Vomiting occurred more frequently in the neurologically impaired children than in the other groups. This might be because of oesophageal dysmotility with reduced lower oesophageal sphincter tonus. The same finding has been described earlier in the literature, but then as a part of GER symptom (Sherman 2009, Vandenplas 2009, Noble 2012, Hegar 2013). There was, however, no difference in vomiting frequency pre- and postoperatively within each specific group. This finding supports the hypothesis that the underlying diseases influence the frequency of vomiting and not the VAG operation.

Throughout the study period, the recording of vomiting frequency has been based on the parents' observations and therefore the interpretation of the results may be queried. There was no definition of volume required for it to be called vomiting and no registration during hospitalization or at the out-patient clinic during follow-up as to how many times/day the patients vomited. But since the same parents have observed vomiting frequency in the same patients, we consider the results to be reliable. It is, however, possible that a more objective definition and registration of vomiting might have led to different results regarding vomiting frequency.

Even with the knowledge of the vomiting frequencies seen in this study, the VAG operation is still beneficial for many of the children and their families. Prolonged forced meals orally or frequent replacement of nasogastric tubes without any secure weight gain, cause a lot of frustration for the children and their parents. The vomiting frequency might not change with a gastrostomy, but the ease in nutritional support that comes with it often compensates for the vomiting.

Based on our findings in Paper V we consider the vomiting symptom unchanged after a VAG procedure.

Conclusions and future aspects

Conclusions

Based on Papers I-V presented in this thesis the following conclusions were reached

- The Video Assisted Gastrostomy (VAG) procedure is a safe method when establishing a gastrostomy. The incidence of complications when performing a VAG procedure at our department is lower compared to other methods such as PEG and open surgery. The complications seen by us are characterized as minor and include granulation tissue, infections and leakage. No major complications such as peritonitis due to leakage intra-abdominally, bleeding or appearance of gastrocolic fistulas were seen in our studies.
- We consider a VAG operation a safe way to establish a gastrostomy in infants less than 1 year. We also believe that enteral nutritional support through a gastrostomy is beneficial in children less than 1 year of age regarding weight gain and weight catch-up.
- We did not find any difference in postoperative complications after a VAG procedure between children with malignant diseases and neurological impairment. There was no increase in frequency of postoperative complications either in children receiving chemotherapy within a few days prior to the operation nor within the first postoperative week. Based on our findings in Paper II we recommend a VAG procedure in children with a malignant disease for whom a nasogastric tube is poorly tolerated.
- Based on our findings in Paper III we can recommend a VAG procedure in neurologically impaired children with a previously placed Ventriculo-Peritoneal Shunt (VPS). In our material we found no major complications such as VPS infection in children with neurological impairment on whom both a VPS and a VAG had been performed. Concerning the rate of minor complications, there was no difference between neurologically impaired children with a VPS and a VAG and neurologically impaired children who had no VPS but who had undergone a VAG procedure.
- Based on our findings in Paper IV we recommend the continuous double U-stitch suture when adapting the ventricle to the abdominal wall. When using

this new suture there is a decrease in the development of granulation tissue in the gastrostoma as compared to our formerly used purse-string suture.

- The VAG procedure does not lead to increased vomiting in children. Vomiting is a common symptom in severely ill children and is most frequent in those with neurological impairment. In children with vomiting symptoms before a VAG procedure, 78% have persisting symptoms six months after surgery.

Future perspectives

“There are many roads leading to Rome” is a Swedish proverb with the meaning that a problem may have many solutions. In this thesis we have described the VAG procedure for establishing a gastrostomy in children, but it is certainly not the only way. Nor is it the definite final solution to the problem of performing a gastrostomy in children. Surgeons have been very creative over the years in performing this communication between the ventricle and the skin and inventions will most certainly continue to flourish in the future for the benefit of the children. The surgical equipment used today will improve and new techniques will enter the scene. Better materials and design of gastrostomy tubes will be provided and maybe thereby avoid complications seen today.

Time will tell if the VAG procedure can be further improved or soon replaced with a safer and better procedure. One thing is for sure though, the rapid development in the surgical field will lead to new techniques in the field of gastrostomy in the future.

So every paediatric surgeon, only the sky is the limit for ideas !!

Populärvetenskaplig sammanfattning

Att kunna äta och dricka via munnen är för de allra flesta barn en självklarhet och grunden för en god tillväxt och välmående. Problem uppstår när barnen av någon anledning inte kan svälja eller har ett så stort behov av näring, exempelvis pga en bakomliggande sjukdom att de basala behoven inte kan tillfredsställas på normalt sätt.

För att underlätta tillmatning under en kortare period kan en nutritionssond s.k. ventrikelsond (v-sond) användas. Om behovet av ökat näringstillskott förväntas pågå minst tre månader eller om användandet av v-sond ger patienten uttalade besvär, finns kirurgiska möjligheter att etablera en förbindelse mellan huden och magsäcken, en sk gastrostomi.

Gastrostomi, efter grekiskans gastro (mage) och stoma (öppning), innebär att en passage mellan huden och magens kavitet etableras. Denna kanal gör det möjligt att ge näring i adekvata mängder för att upprätthålla ett gott nutritionsstatus via upptag av näringen i tarmarna trots ex sväljningssvårigheter.

Öppna operationer för att anlägga gastrostomier, såsom Witzelfistel och Stammfistel, är välkända metoder sedan slutet av 1800 talet men används numera nästan enbart i speciella fall som tex vid uttalade sammanväxningar i bukhålan.

Utvecklingen av den gastrokopiska tekniken med flexibla instrument på 1970-talet öppnade möjligheten för att anlägga gastrostomier utan öppen operation. 1979 genomfördes den första Percutana Endoskopiska Gastrostomi (PEG), som innebar att patienter utan narkoskrävande insatser kunde få en gastrostomi anlagd. Metoden fick stort internationellt genomslag ffa på vuxna patienter men även på barn där det dock krävdes narkos, och var länge den absolut mest använda metoden. P.g.a. komplikationer, t.ex. uppkomna fistlar mellan hud och tarm, som noterades på patienter med anlagd PEG, utvecklades laparoskopiska metoder för att anlägga gastrostomier. Med laparoskopins fördelar med säker anatomisk identifikation av bukhålans organ, gavs möjligheter att undvika komplikationer och därmed blev kirurgin säkrare. 1991 introducerades den första laparoskopiska gastrostomi operationen. Den laparoskopiska tekniken började användas vid barnkirurgiska kliniken i Lund 1994 och benämndes laparoskopisk Video Assisterad Gastrostomi (VAG) p.g.a. utnyttjandet av en videoskärm kopplad till den laparoskopiska optiken för att återge det kirurgiska hantverket inuti bukhålan på skärmen. Nationellt i

Sverige dominerar numera den laparoskopiska tekniken med lokala mindre skillnader i det operativa förfarandet.

Avhandlingen utgörs av fem delarbeten. I samtliga arbeten har barn med kroniska sjukdomar o/ell allvarliga sjukdomstillstånd opererats med anläggning av gastrostomi med VAG tekniken p.g.a. långvarigt behov av nutritionellt stöd. Efter operationen har barnen följts upp och komplikationer har registrerats och värderats. I ett delarbete beskrivs även en metodförbättring av det operativa förfarandet i samband med operationen. Målet med avhandlingsarbetet har varit att införskaffa kunskap och erfarenheter som kan användas i den kliniska vardagen för att förbättra rutiner vid anläggande av gastrostomier, och på detta sätt förhoppningsvis minska komplikationsfrekvensen samt även bättre kunna selektera patientgrupper för operationen.

I delarbete I var målet att rapporterat om våra erfarenheter av VAG operation på barn som är under 1 år. Denna patientkategori är på många sätt speciell t.ex. ur anestesilogisk och kirurgisk hänseende och kräver stor vana och kunnande av behandlande personal. Totalt inkluderades 53 barn i studien med diagnoser som neurologiska sjukdomar, metabola sjukdomar, hjärtmissbildningar och kromosomavvikelser. Några allvarliga komplikationer noterades inte utan endast mindre komplikationer som granulationsvävnad, lindriga lokala infektioner samt läckage runt gastrostomin. Vid mätningar av vikten precis före och sex månader efter VAG operationen, kunde en signifikant viktökning noteras. Resultaten uppmuntrar användandet av VAG tekniken i denna patientgrupp.

I delarbete II studerades barn med maligna sjukdomar som cellgiftsbehandlats. Denna behandling har kända sidoeffekter som kräkningar, viktnedgång, aptitlöshet, samt benmärgspåverkan som i sin tur ger förändrad blodbild och nedsatt immunförsvar. Frågan var om cellgiftsbehandling i nära anslutning till en VAG operation påverkar komplikationsfrekvensen. I undersökningen ingick 27 barn med maligna sjukdomar och som kontrollgrupp valdes 27 barn med neurologiska sjukdomar, samtliga matchade för ålder, vikt och kön. Resultaten visade att det inte förelåg någon skillnad i komplikationsfrekvens efter VAG operationen mellan barnen med maligna sjukdomar och barn med neurologiska sjukdomar. Vi fann inte heller något som pekade på att cellgiftsbehandling i nära anslutning till en VAG operation påverkade frekvensen av komplikationer.

I delarbete III studerades 15 barn med neurokirurgiska sjukdomar som tidigare fått en ventrikulo peritoneal shunt (VPS) inopererad p.g.a. deras bakomliggande sjukdomar och härefter erhållit en gastrostomi. Kontrollgruppen utgjordes av 15 neurologiskt handikappade barn som opererats med VAG tekniken för anläggning av gastrostomi dock utan tidigare inopererad VPS, samtliga matchade v.g. ålder och kön med studiegruppen. Hypotesen var om en sedan tidigare inopererad VPS påverkade frekvens och förekomst av komplikationer efter en VAG operation. Ingen allvarlig

komplikation noterades såsom VPS infektion med behov av revision eller ascenderande infektion till meningar mm. Resultaten visade ingen skillnad på förekomsten av komplikationer efter en VAG operation mellan barnen med VPS och barnen utan VPS och gav oss stöd för att anlägga gastrostomier på barn med tidigare inopererad VPS.

I delarbete IV introducerade vi en ny sutureringsteknik av magsäcken när den adapteras mot bukvägg och hud vid en VAG operation. Suturen benämns kontinuerlig dubbel U-sutur och i studien jämfördes 62 barn hos vilka dubbel U-suturen användes med 68 barn där den tidigare sutureringstekniken med en sk tobakspungssutur användes. Frekvensen av komplikationer efter operationerna kontrollerades och resultaten visade en signifikant minskning av granulationsvävnad runt gastrostomin i patientgruppen där den nya kontinuerliga dubbla U-suturen användes. En anledning till detta ansågs vara att den nya suturen drog magsäcksvävnaden runt om gastrostomislagen tillbaka ner mot bukhålan när suturen knöts åt och således exponerade magsäcksvävnaden mindre, till skillnad från den tidigare använda tobakspungssuturen som närmast hade motsatt effekt och snarare lyfte fram magsäcksvävnaden. Denna minskade exponering av magsäcksvävnaden leder till mindre yttre mekanisk påverkan och därmed minskad tendens till utveckling av granulationsvävnad. Den kontinuerliga dubbla U-suturen resulterade inte i minskad förekomst av komplikationerna läckage och infektioner. Konklusionen blev att den nya sutureringstekniken var lätt att lära sig, resulterade i mindre komplikationer och implementerades därför i verksamheten och är fortfarande den teknik som används vid anläggande av gastrostomier på barnkirurgen i Lund.

I delarbete V granskades förekomsten av kräkningar hos barnen som opererades med en VAG operation. I studien inkluderades 180 barn med olika diagnoser som samtliga genomgått en VAG operation. Syftet med studien var att kontrollera om en VAG operation påverkade frekvensen av kräkningar före respektive efter operationen samt om någon patientgrupp var mer utsatt för symptomet. Resultaten visade att av barnen som kräktes innan operationen hade 78 % kvarvarande symptom sex månader efter operationen. Konklusionen blev att det var barnens bakomliggande sjukdomar som orsakade kräkningarna och att själva operationen inte bidrog till att varken förvärra eller förbättra symptomen. Barn med neurologiska sjukdomar var den patientgrupp som hade högst kräkningsfrekvens i studien.

Acknowledgements

“That’s one small step for a man, one giant leap for mankind” (Neil Armstrong)

The scientific content in this thesis might not be one giant leap for mankind but it has certainly been one small, or actually one big step for me to finish this project. This work would definitely not have been possible without the support and encouragement from colleagues, friends and family.

I would like to express my special thanks to:

Einar Arnbjörnsson, Associate Professor and my supervisor, for taking me under your wing the first years of my residency as a paediatric surgeon and tutoring me so well. My gratitude for your engagement and never-ending enthusiasm throughout this project is beyond all limits. I’m looking forward to entitling you Professor Einar soon, because you’re worth it!!

Anna Börjesson, PhD and co-supervisor, for your outstanding encouragement and support while finishing this project, and for your invaluable linguistic help and suggestions for improvement when going through the draft of this book.

Magnus Anderberg, PhD and co-supervisor, for all pep talks and proofreading the draft of this book and for giving me the dedication “A book like this every man should have in his bookshelf” when handing your thesis to me. These words have guided me through my struggle in finishing this book and I can finally look at myself in the mirror and say “I am such a man”.

Carl-Magnus Kullendorff, Associate Professor, my clinical mentor in the most interesting field of paediatric surgery in my opinion, oncological surgery. Even though our tracks are not always parallel, we usually reach the same destination in the end. I truly appreciate you as colleague and friend, CMK.

Christina Clementson-Kockum, Associate Professor, for your good work as our Head of the Department of Paediatric Surgery in Lund and for your insistence that I must finish this thesis at our yearly co-worker talk for almost 10 years. Now it is finally done and we can talk about something else next time!!

Lena Andersson, Yvonne Berglund, Helené Sjöwie and Malin Mellberg, registered nurses with special interest in gastrostomies, for your documentation and registration of complications and excellent care of our patients. It is always a pleasure to work with you.

Present and former **colleagues at the Department of Paediatric Surgery in Lund** for spreading so much joy at work. It's truly wonderful to have the feeling of going to a party every morning because you are about to meet people you like and spend an interesting working day together. A more loyal staff is hard to find.

All **colleagues at the section for Paediatric Oncology in Lund** for empathy and encouragement during difficult clinical moments in the past and for teaching me how to act with respect and compassion in my work as a doctor. May SIOP live forever so we can make many trips together in the future.

Gun Wendel and Ingrid Billström, secretaries and friends, for having patience with me and always reaching out a helping hand when administrative trouble turns up.

All **personnel at Department 65, at the Surgical out-patient clinic and at the Operating Unit** for your positive attitude, all jokes and fun in daily work and for your excellent care of all patients.

Gillian Sjö Dahl for linguistic revision, **Håkan Lökvist** for statistical advice

To my **friends** and especially to the three Billy Boys; **Jan Brun, Mikael Sylmé and Hans Belfrage**. Your friendship means so much to me !

Anna Börjesson, for opening emotional doors and showing me rooms whose existence I have not been aware of before. I am eager to learn more and cannot wait until we open the next door, and the next and the next.... ! P

My aunt **Brita**, for all support and for always being such a good friend

My dear sister **Kristin** and her wonderful family **Fredric, Calle and Anna** for all joy you bring to my children and me.

My parents **Gunilla** and **Ulf**, for your unconditional love and encouraging support at every step and situation in life. You have always been there for me and I will always be there for you.

My three true loves, **Olle, Elsa and Jakob**, my wonderful children and essence of my life. I'm so proud of you and there are no words strong enough to describe how much I love you. May happiness, luck and good health follow you through your lives. **Sofia**, for being their wonderful mother.

A lot of colleagues, friends and co-workers are not named here, but definitely not forgotten.

References

- Akay B, Capizzani TR, Lee AM, Drongowski RA, Geiger JD, Hirschl RB, Mychaliska GB. Gastrostomy tube placement in infants and children: is there a preferred technique? *J Pediatr Surg* (2010) 45, 1147-1157
- Albertsson-Wikland K, Karlberg J. Natural growth in children born small for gestational age with and without catchup growth. *Acta Paediatr Suppl* 1994; 399: 64–70
- Al-Qahtani AR, Almaramhi H (2006) Minimal access surgery in neonates and infants. *J Pediatr Surg* 41:910-913. Doi:10.1016/j.jpedsurg.2006.01.009
- Andersson L, Mikaelsson C, Arnbjörnsson E, Larsson LT. Laparoscopy aided gastrostomy in children. *Ann Chir Gynaecol* 1997;86:19-22
- Antonoff MB, Donavon JH, Saltzman DA, Acton RD. Modified approach to laparoscopic gastrostomy tube placement minimizes complications. *Pediatr Surg Int* (2009)25;349-353
- Aprahamian CJ, Morgan TL, Harmon CM, Georgeson KE, Barnhart DC. U-stitch laparoscopic gastrostomy technique has a low rate of complications and allows primary button placement: experience with 461 pediatric procedures. *J Laparoendosc Adv Surg Tech A* 2006; 16: 643-649
- Aquino VM, Smyrl CB, Hagg R, McHard KM, Prestridge L, Sandler ES. Enteral nutritional support by gastrostomy tube in children with cancer. *J Pediatr* 1995;127:58-62
- Arnbjörnsson E, Larsson LT, Lindhagen T. Complications of laparoscopy-aided gastrostomies in pediatric practice. *J Pediatr Surg* 1999;34:1843-6
- Arnbjörnsson E, Larsson LT. Laparoscopic button is a safe method in pediatric gastrostomy. *Lakartidningen*. 1998; 95:3919. Swedish
- Arnbjörnsson E, Larsson LT. Video-assisted placing of a gastrostomy button in children. Ten years of experiences show advantages of the method. *Lakartidningen* 2005; 102:3451-3455. Swedish.
- Backman T, Sjövie H, Kullendorff CM, Arnbjörnsson E. (2010). Continuous double U-stitch gastrostomy in children. *Eur J Pediatr Surg*. 2010; 20:14-17. Epub 2009 Oct 14
- Baird R, Salasidis R. Percutaneous gastrostomy in patients with a ventriculoperitoneal shunt: case series and review. *Gastrointest Endosc*. 2004 Apr;59(4):570-4.
- Beasley SW, Catto-Smith AG, Davidson PM. How to avoid complications during percutaneous endoscopic gastrostomy. *Journal of Pediatric Surgery*, Vol 30, No 5(May),1995;pp671-673

- Behrens R, Lang T, Muschweck H, et al (1997) Percutaneous endoscopic gastrostomy in children and adolescents. *J Pediatr Gastroenterol Nutr* 25:487-91
- Cairns A, Geraghty J, Al-Rifai A, Babbs C. Percutaneous endoscopic gastrostomy and ventriculoperitoneal shunts: a dangerous combination? *Digestive Endoscopy* (2009)21,228-231
- Chandrasen SK, Paramalingam S, Patel S, Davenport M, Ade-Ajayi N. Feasibility of complex minimally invasive surgery in neonates. *Pediatr Surg Int* 2009;25:217-21
- Chang PF, Ni YH, Chang MH (2003) Percutaneous endoscopic gastrostomy to set up a long-term enteral feeding route in children: an encouraging result. *Pediatr Surg Int* 19:283-5
- Chen MK, Schropp KP, Lobe TE: Complications of minimal- access surgery in children. *J Pediatr Surg* 31:1161-1165, 1996
- Christensen ML, Hancock ML, Gattuso J, Hurwitz CA, Smith C, McCormick J et al. Parenteral nutrition associated with increased infection rate in children with cancer. *Cancer* 1993;72:2732-8
- Dubois F, Icard F, Berthelot G et al. Coelioscopic cholecystectomy. Preliminary report of 36 cases. *Ann Surg* 1990;211:60-2
- Edelman DS, Unger SW: Laparoscopic gastrostomy. *Surgery, Gynecology and Obstetrics* 173: 401-402,1991
- Gans SL, Berci G. Peritoneoscopy in infants and children. *J Pediatr Surg* 1973;8:399-405
- Gauderer MW, Ponsky JL, Izant Jr RJ (1980). Gastrostomy without laparotomy: a percutaneous endoscopic technique. *J Pediatr Surg* 15(6):872-875
- Gauderer MW, Stellato TA. Gastrostomies: evolution, techniques, indications, and complications. *Curr Probl Surg.* 1986 ;23:657-719
- Gauderer MW. Percutaneous endoscopic gastrostomy-20 years later: a historical perspective. *J Pediatr Surg* 2001; 36:217–219
- Gauderer MWL. Percutaneous endoscopic gastrostomy: a 10 year experience with 220 children. *J Pediatr Surg* 1991; 26: 288–294
- Georgeson KE (1993) Laparoscopic gastrostomy and fundoplication. *Pediatr Ann* 22:675-7
- Haws EB, Sieber WK, Kiesewetter WB (1966) Complications of tube gastrostomy in infants and children. 15-year review of 240 cases. *Ann Surg* 164:284-90
- Haynes L, Atherton DJ, Ade-Ajayi N et al (1996). Gastrostomy and growth in dystrophic epidermolysis bullosa. *Br J Dermatol* 134:872-9
- Heine RG, Reddihough DS, Catto-Smith AG (1995) Gastro-oesophageal reflux and feeding problems after gastrostomy in children with severe neurological impairment. *Dev Med Child Neurol* 37:320-9
- Hegar B, Vandenplas Y. Gastroesophageal reflux: natural evolution, diagnostic approach and treatment. *The Turkish Journal of Pediatrics* 2013;55:1-7
- Hirschowitz B. Endoscopy-40 years since Fiber optics. *Dig Surg* 2000;17:115-117

- Jacobaeus HC. Über die Möglichkeit die Zystoskopie bei untersuchung seröser Höhlungen anzuwenden. *Munch Med Wochenschr* 57:2090-2092, 1910
- Jones S: Gastrostomy for stricture (cancerous) of esophagus; death from bronchitis forty days after operation. *Lancet* 1875; 1:678
- Jones VS, La Hei ER, Shun A. Laparoscopic gastrostomy: the preferred method of gastrostomy in children. *Pediatr Surg Int.* 2007;23:1085-9
- Kellnar ST, Till H, Bohn R (1999) Laparoscopically assisted performance of gastrostomy--a simple, safe and minimal invasive technique. *Eur J Pediatr Surg* 9:297-8
- Khattak IU, Kimber C, Kiely EM, Spitz L. Percutaneous endoscopic gastrostomy in paediatric practice: complications and outcome. *J Pediatr Surg* 1998; 33: 67-72
- Kimber CP, Khattak IU, Kiely EM, Spitz L. Peritonitis following percutaneous gastrostomy in children: management guidelines. *Aust N Z J Surg* 1998;68:268-70.
- Kubiak R, Wilcox DT, Spitz L. Gastrojejunal fistula after insertion of percutaneous endoscopic gastrostomy. *J Pediatr Surg* 1999; 34: 1287-1288
- Kuebler JF, Ure BM. Minimally invasive surgery in the neonate. Review article. *Seminars in fetal and neonatal medicine.* Volume 16, Issue 13, June 2011, Pages 151-156
- Lantz M, Hultin Larsson H, Arnbjörnsson E. Literature review comparing laparoscopic and percutaneous endoscopic gastrostomies in a pediatric population. *Int J Pediatr.* 2010;507616. Epub 2010 Mar 10
- Lantz M, Larsson HH, Arnbjörnsson, E. Video-assisted technique is best when performing laparoscopic gastrostomy in children. Meta-analysis of the frequency of fistulas following two different methods. *Lakartidningen.* 2009; 106:3078, 3080-3082. Swedish
- Larson DE, Burton DD, Schroeder KW, et al (1987) Percutaneous endoscopic gastrostomy. Indications, success, complications, and mortality in 314 consecutive patients. *Gastroenterology* 93:48-52
- Liou TG, Adler FR, Fitzsimmons SC, Cahill BC, Hibbs JR, Marshall BC. Predictive 5-year survivorship model of cystic fibrosis. *Am J Epidemiol* 2001; 153: 345-352
- Lobe TE(2007) The current role of laparoscopic surgery for gastroesophageal reflux disease in infants and children. *Surg Endosc* 21:167-174. Doi:10.1007/s00464-006-0238-6
- Marin OE, Glassman MS, Schoen BT, et al (1994) Safety and efficacy of percutaneous endoscopic gastrostomy in children. *Am J Gastroenterol* 89:357-61
- Mathew P, Bowman L, Williams R, Jones D, Rao B, Schropp K et al. Complications and effectiveness of gastrostomy feedings in pediatric cancer patients. *J Pediatr Hematol Oncol* 1996;18:81-5
- Mikaëlsson C, Arnbjörnsson E, Larsson LT. [The laparoscopy button. A new method with minimal surgical trauma in gastrostomy in children] *Lakartidningen* 1995;92:3237-8
- Moehlau FG. Gastrostomy in the 17th century. *Buffalo Med J* 1896;35:395
- Morgenstern L . From the sword to Schindler: A saga of gastroscopy. *Surg Innov* 2009 16:93 (<http://sri.sagepub.com/content/16/2/93>)

- Nabika S, Oki S, Sumida M, Isobe N, Kanou Y, Watanabe Y. Analysis of risk factors for infection in coplacement of percutaneous endoscopic gastrostomy and ventriculoperitoneal shunt. *Neurol Med Chir (Tokyo)*. 2006 May;46(5):226-9; discussion 229-30..
- Noble LJ, Dalzell MA, El-Matary W. The relationship between percutaneous endoscopic gastrostomy and gastro-oesophageal reflux disease in children. A systematic review. *Surg Endosc* (2012) 26:2504-2512
- Norton B, Homer-Ward M, Donnelly MT, et al (1996) A randomised prospective comparison of percutaneous endoscopic gastrostomy and nasogastric tube feeding after acute dysphagic stroke. *BMJ* 312:13-16
- Parelkar SV, Oak SA, Bachani MK, Sanghvi BV, Gupta R, Prakash A, Patil R, Sahoo S. Minimal access surgery in newborns and small infants; five years experience. *Journal of Minimal Access Surgery*. January-March 2013, Volume 9, Issue 1
- Patwardhan N, McHugh K, Drake D, Spitz L. Gastroenteric fistula complicating percutaneous endoscopic gastrostomy. *J Pediatr Surg* 2004; 39: 561-564
- Pedersen AM, Kok K, Petersen G, Nielsen OH, Michaelsen KF, Schmiegelow K. Percutaneous endoscopic gastrostomy in children with cancer. *Acta Paediatr* 1999;88:849-52
- Plantin I, Arnbjörnsson E, Larsson LT. No increase in gastroesophageal reflux after laparoscopic gastrostomy in children. *Pediatr Surg Int*. 2006; 22:581-4. Epub 2006 Jun
- Ponsky TA, Rothenberg SS. Minimally invasive surgery in infants less than 5 kg: Experience of 649 cases. *Surg Endosc* 2008;22:2214-9
- Reddick EJ, Olsen DO. Laparoscopic laser cholecystectomy. A comparison with minilap cholecystectomy. *Surg Endosc* 1989;3:131-3
- Roeder BE, Said A, Reichelder M, Gopal DV. Placement of gastrostomy tubes in patients with ventriculoperitoneal shunts does not result in increased incidence of shunt infection or decreased survival. *Dig. Dis. Sci.* 2007;52:518-22. Epub 2006 Dec 29
- Rothenberg SS, Bealer JF, Chang JH. Primary laparoscopic placement of gastrostomy buttons for feeding tubes. A safer and simpler technique. *Surg Endosc* 1999; 13: 995-997
- Sampson LK, Georgeson KE, Winters DC. Laparoscopic gastrostomy as an adjunctive procedure to laparoscopic fundoplication in children. *Surg Endosc* (1996) 10:1106-1110
- Sedillot C: De la gastrostomie fistuleuse. *Compt Rend Acad Sci* 1846;23:222
- Sedillot C: Operation de gastrostomie, practiquee pour la premiere fois le 13 Novembre 1849. *Gaz méd Strassbourg* 1849;9:566
- Sedillot C: Observation de gastrostomie. *Gaz Hôp* 1853; 26:160
- Shallman RW. Laparoscopic percutaneous gastrostomy. *Gastrointest Endosc* 37:493-494, 1991

- Sherman PM et al(2009). A global, evidence-based consensus on the definition of gastroesophageal reflux disease in the pediatric population. *AM J Gastroenterol.* 2009May;104(5):1278-95;quiz 1296.doi:
- Shulman AS, Saywer RG. The safety of percutaneous endoscopic gastrostomy tube placement in patients with existing ventriculoperitoneal shunts. *JPEN.J.Parenter. Enteral. Nutr.* 2005;29:442-4
- Skolin I, Axelsson K, Ghannad P, Hernell O, Wahlin YB. Nutrient intake and weight development in children during chemotherapy for malignant disease. *Oral Oncol* 1997;33:364-8
- Stamm M: Gastrostomy by a new method. *Med News (NY)* 1894; 65:324
- Taylor AL, Carroll TA, Jakubowski J, O'Reilly G. Percutaneous endoscopic gastrostomy in patients with ventriculoperitoneal shunts. *Br J Surg.* 2001 May;88:724-7
- Tomicic JT, Luks FI, Sharon L, et al (2002) Laparoscopic gastrostomy in infants and children. *Eur J Pediatr Surg* 12:107-10
- Ure MB, Bax NM, van der Zee DC. Laparoscopy in infants and children:a prospective study on feasibility and the impact on routine surgery. *J Pediatr Surg* 2000;35:1170-3
- Vandenplas Y, Ashkenazi A, Belli D, Boige N, Bouquet J, Cadranel S, Cezard JP, Cucchiara S, Dupont C, Geboes K. A proposition for the diagnosis and treatment of gastroesophageal reflux disease in children: a report from a working group on gastroesophageal reflux disease. *Eur J Pediatr.* 1993; 152:704–711
- Witzel O: Zur Technik der Magenfistelanlegung. *Zbl Chir* 1891; 18:601
- Zanakhshary M, Jamal M, Blair GK, Murphy JJ, Webber EM, Skarsgard ED. Laparoscopic versus percutaneous endoscopic gastrostomy tube insertion: A new pediatric gold standard? *J Pediatr Surg.* 2005; 40:859–862

Torbjörn Backman · Einar Arnbjörnsson
Yvonne Berglund · Lars-Torsten Larsson

Video-assisted gastrostomy in infants less than 1 year

Accepted: 22 December 2005 / Published online: 10 January 2006
© Springer-Verlag 2006

Abstract The objectives of this study were to report our experience with the laparoscopic video-assisted gastrostomy technique in infants operated during their first year of life. A total of 53 infants (35 males, 18 females) aged 6 ± 3 months, varying from 3 weeks to 11 months, underwent video-assisted gastrostomy. They were prospectively followed up. Included are infants with neurological dysfunction, chromosomal anomalies, metabolic disorders, cardiac anomalies or respiratory insufficiency. All the infants were operated under general and local anaesthesia. Gastrostomy tube feeding began within 4 h after the operation. The infants were followed with a scheduled control at 1 and 6 months postoperatively documenting complications and weight gain. The main outcome measure was the number and type of complications as well as weight gain using the age-adjusted Z-score of weight to normalize the data relative to a reference population. The weight before and 6 months after the video-assisted gastrostomy was 5.5 ± 1.6 and 8.5 ± 1.6 kg, respectively. The Z-score increased significantly ($P < 0.001$) from -2.7 ± 1.5 to -1.7 ± 1.0 . This illustrates the postoperative weight gain and catch-up. Short and long-term complications included minor local wound infection, leakage around the gastrostomy tube and granuloma, but no severe complications. Our results encourage the use of video-assisted gastrostomy as a safe technique to provide a route for long-term nutritional support even in infants less than 1 year.

Keywords Gastrostomy · Laparoscopy · Infants

Introduction

To achieve adequate enteral nutritional support in chronically sick infants with poor oral intake, there are

different techniques of gastrostomy available, from the time-honoured open surgical to percutaneous endoscopic gastrostomy techniques (PEG) [1, 2] and most recently the laparoscopically video-assisted technique [3–7]. Using the latter two methods a laparotomy is avoided, thereby reducing morbidity. The use of PEG is widespread, accepted and the most preferred technique to establish a route of enteral feeding, in spite of some serious complications that especially in infants may call for safer techniques [8–10].

The laparoscopic video-assisted technique is now well established in paediatric surgical practice [3, 11] and developed to reduce the number of serious postoperative complications reported after PEG [10]. In this paper we review our experience with 53 infants less than 1 year who underwent video-assisted gastrostomy placement, both with respect to postoperative complications and long-term weight gain.

Patients

The study comprised a consecutive series of 53 severely disabled infants who underwent a video-assisted gastrostomy during the period from January 1997 through March 2003. Their underlying diseases are summarized in Table 1 and their demographic data in Table 2.

The indications for gastrostomy were nutritional problems with dependence on a nasogastric tube for continuous or bolus feeding. Upper gastrointestinal X-ray including oesophagus, stomach and duodenum was performed to rule out gastric outlet obstruction and severe gastro-oesophageal reflux or hiatus hernia. No routine 24 h pH monitoring or scintigraphic gastric emptying studies were performed preoperatively.

Methods

The infants were operated with a laparoscopic video-assisted gastrostomy. Premedication was given with

T. Backman · E. Arnbjörnsson (✉) · Y. Berglund · L.-T. Larsson
Department of Pediatric Surgery, University Hospital,
221 85 Lund, Sweden
E-mail: einar.arnbjornsson@skane.se
Tel.: +46-46-178297

Table 1 A summary of underlying diseases noted in 53 infants, less than 1 year, undergoing video-assisted gastrostomy

Diagnosis	Number of patients
Neurological dysfunction	19
Chromosomal anomalies	8
Metabolic disorders	13
Cardiac anomalies	7
Respiratory insufficiency	6
Total	53

Midazolam, Dormicum® 5 mg/ml rectally using 0.3 mg/kg body weight

All the operations were performed under general and local anaesthesia. We used local analgesia with Bupivacain, Marcain® 0.25%, 1 ml/kg body weight, in the two abdominal wounds. One dose of antibiotics, Cefuroxim, Zinacef® 20 mg/kg, was given at the induction of anaesthesia.

A 2 or 3 mm Verres-type needle was introduced through the umbilicus into the abdominal cavity. A 2 or 3 mm, 0 or 30° optic was then introduced through the Verres cannula and the abdominal cavity inspected. At the selected location of the gastrostomy button, a 2, 3 or 5 mm trocar was introduced into the abdominal cavity under direct vision. The location was usually at the midpoint between the umbilicus and the costal margin and through the left rectus muscle.

A grasper was used to seize the anterior stomach wall at the point selected for placement of the gastrostomy button. The seized part of the stomach wall was exteriorized and sutured from the outside to the fascia of the abdominal wall. Through two purse string sutures, with at least 0.5 cm in between, the stomach wall was opened and a gastrostomy button, MicKey® (Ballard Medical Product, UT, USA), inserted. The purse string sutures were then pulled and tightly tied. The gastrostomy balloon was inflated with approximately 6 ml of sterile water. The button size was 14 Fr with a length varying

Table 2 A summary of changes in weight before and 6 months after a video-assisted gastrostomy operation in 53 infants less than 1 year

	At the operation	Six months later
Number of patients	53	49
Male/female	35/18	31/18
Age, months	6 ± 3	
Range	3–11	
Weight, kg	5.5 ± 1.6	8.5 ± 1.6
Range	2.6–9.3	4.6–12.8
Z-score*	-2.7 + 1.5**	-1.7 + 1.0**
Range	-0.13 to -5.58	-0.40 to -5.20
Increased		44
Decreased		5

These figures are also expressed as weight-for-age Z-scores

*Calculated as: (actual weight – mean weight)/standard deviation [12], according to the nationally standardized weight curves [13]

**A significant difference was found between the Z-score at operation compared with that 6 months later, $P < 0.001$

between 0.8 and 1.2 cm. The umbilical port incision was left without sutures, only adapted by tapes. Gastroscopy was used for inspection of the oesophagus and for verifying the location of the gastrostomy button.

The operating time including the final gastroscopy was 33 ± 12 min, varying from 15 to 65 min.

Nutrition through the gastrostomy was started within 4 h postoperatively and continued with increasing amounts of fluid as tolerated by the infants. Bolus or continuous feeding was continued as preoperatively.

The infants were followed-up by a specially trained nurse at 1 and 6 months postoperatively. The body weight was recorded on the day before the operation and at follow-up 6 months later. The weight at operation and at follow-up was compared using the age-adjusted Z-score of weight. The Z-score of weight was calculated as: (actual weight – mean weight)/standard deviation, [12] according to the nationally standardized weight curves [13]. No corrections were made for prematurity. If the Z-score of weight after operation is higher than before, it indicates an accelerated weight gain i.e. catch-up.

The Wilcoxon Signed Rank Test for paired samples was used for statistical calculations.

Results

The procedure was well tolerated by all the infants. Serious complications including gastrocolic fistula, peritonitis, bleeding and intraabdominal leakage, dislodgement of the tube or tube occlusion were not seen. There was no mortality related to the video-assisted gastrostomy placement. Four infants died of underlying diseases later. Two patients died of intracranial bleeding, one with an astrocytoma and one with a progressive neurological disease. Two died of circulatory failure, one due to a constrictive cardiomyopathy and one due to a cardiac anomaly (Table 2). There were no deaths related to gastro-oesophageal reflux or pneumonia.

Complications of the video-assisted gastrostomy in our patients are summarized in Table 3 and included minor local wound infection, treated with antibiotics in ten cases. Furthermore, we noted a conservatively treated leakage causing a reversible local slight irritation around the tube in 15 patients. In five children we had to remove the gastrostomy tube for 24–48 h to let the stoma constrict before replacing the gastrostomy button. Granulomas requiring extirpation under general anaesthesia were seen in two patients.

Vomiting was a clinical problem in 27 patients before surgery and in 14 patients 6 months postoperatively. It was treated conservatively by thickening the food, change in posture after meal and, in two children, with proton pump inhibitor. The vomiting problem decreased with time in most patients, as shown in Table 3, but led to a need for a temporary gastro-jejunum tube feeding in two patients. An antireflux surgery was considered unnecessary in this patient group.

Table 3 The problems met with at 1 and 6 months after video-assisted gastrostomy in 53 infants less than 1 year

	One month	Six months
No gastrostomy problems	9	32
Granuloma formation	27	6
Extirpated under general anaesthesia		2
Locally treated only	27	4
Leakage	14	6
Locally treated only	13	2
Button removed for 12–24 h	1	4
Infection	13	2
Locally treated only	5	2
Treated with antibiotics	8	2
Vomiting, a preoperative problem in 27 patients	25	14
Increased	5	2
Unchanged	8	2
Decreased	12	10
Changed to a gastro-jejunum tube due to vomiting		2
Gastrostomy button removed, no longer needed		1
Died of their underlying disease		4

Intracranial bleeding in one child with an astrocytoma and in one child with a progressive neurological disease; circulatory failure in one child with a constrictive cardiomyopathy and another with a single ventricle anomaly with double outlet right ventricle, mitral atresia and hypoplastic aortic arch

The weight before and 6 months after the video-assisted gastrostomy is summarized in Table 2 together with the Z-score increase, indicating a postoperative weight catch-up, showing a significant increase in weight for age, $P < 0.001$.

Discussion

Gastrostomy feeding is advocated if nasogastric feeding is likely to persist for more than 3–6 months [14, 15]. Aspiration and chest infections, as well as reduction in feeding time and parents' stress are the major reasons for direct enteral feeding using either nasogastric tube or gastrostomy [16, 17]. The methods of gastrostomy, video-assisted or PEG, have the same advantage.

The gastrostomy feeding regimen provides adequate nutrition to promote normal growth and development and supports the increased or special requirements for those patients with an underlying diseased condition. To analyse the nutritional consequences of gastrostomy in this group of patients we used the age-adjusted Z-score [12], which normalizes the data in relation to a reference population. As in other reports we found an improvement in the patients' nutritional status after supplementary enteral feeding via gastrostomy [3, 18], in spite of the fact that the children were preoperatively fed by a nasogastric tube.

The complication rate in our series is lower than that reported by others in the literature for both PEG and surgical gastrostomy [9, 10, 19–24]. Gastro-colic fistulas, bleeding, leakage to the peritoneal cavity,

peritonitis, dislodgement or occlusion of the gastrostomy button were not seen. The problems met by the infants and their parents, summarized in Table 3, are scarcely reported in the literature, although they are well known and often seen after a surgical gastrostomy or PEG. These problems, albeit not life-threatening, affect the lives of the infants and their families; they should be taken into account in patient counselling and when discussing the need for a gastrostomy in each individual patient.

In order to avoid these problems we have ongoing studies on the following measures:

- Increasing the length of the gastrostomy canal by increasing the distance between the two purse string sutures on the stomach wall.
- Washing the skin around the gastrotoma with chlorhexidine (Hibiscrub®) daily during the first three postoperative days.
- Reducing the movements of the gastrostomy button by leaving the catheter in place and by fastening it with tape onto the skin.

When correlating the incidence of complications in this group of infants with different groups of diagnosis, there was no significant difference found between the groups. This is not in agreement with our previous reports on 98 children, 0–18 years, where we found that patients with congenital heart disease, chronic respiratory failure and metabolic diseases experienced the highest rate of minor postoperative complications [11].

Using the method described here as well as the open surgical procedure, the gastrostomy button is put in place directly, eliminating the need for a later change to a gastrostomy button as is the case after a PEG, where this is usually done after 3–6 weeks [24].

Our results encourage the use of video-assisted gastrostomy as a long-term route for safe and effective nutritional support even in infants less than 1 year.

Acknowledgement The authors are grateful to Håkan Lökvist, Statistician, Competence Centre for Clinical Research, Lund University Hospital, SE-221 85 Lund, Sweden, for statistical advice.

References

1. Fanelli RD, Ponsky JL (1992) A simplified technique for percutaneous endoscopic gastrostomy. *Surg Endosc* 6:261–262
2. Gauderer MW, Ponsky JL, Izant RJ Jr (1998) Gastrostomy without laparotomy: a percutaneous endoscopic technique. *Nutrition* 14:736–738
3. Andersson L, Mikaelsson C, Arnbjörnsson E et al (1997) Laparoscopy aided gastrostomy in children. *Ann Chir Gynaecol* 86:19–22
4. Georgeson KE (1993) Laparoscopic gastrostomy and fundoplication. *Pediatr Ann* 22:675–677
5. Kellnar ST, Till H, Bohn R (1999) Laparoscopically assisted performance of gastrostomy—a simple, safe and minimal invasive technique. *Eur J Pediatr Surg* 9:297–298
6. Rothenberg SS, Bealer JF, Chang JH (1999) Primary laparoscopic placement of gastrostomy buttons for feeding tubes. A safer and simpler technique. *Surg Endosc* 13:995–997

7. Tomicic JT, Luks FI, Shalon L et al (2002) Laparoscopic gastrostomy in infants and children. *Eur J Pediatr Surg* 12:107–110
8. Khattak IU, Kimber C, Kiely EM et al (1998) Percutaneous endoscopic gastrostomy in paediatric practice: complications and outcome. *J Pediatr Surg* 33:67–72
9. Larson DE, Burton DD, Schroeder KW et al (1987) Percutaneous endoscopic gastrostomy. Indications, success, complications, and mortality in 314 consecutive patients. *Gastroenterology* 93:48–52
10. Patwardhan N, McHugh K, Drake D, Spitz L (2004) Gastroenteric fistula complicating percutaneous endoscopic gastrostomy. *J Pediatr Surg* 39:561–564
11. Arnbjornsson E, Larsson LT, Lindhagen T (1999) Complications of laparoscopy-aided gastrostomies in pediatric practice. *J Pediatr Surg* 34:1843–1846
12. Liou TG, Adler FR, Fitzsimmons SC et al (2001) Predictive 5-year survivorship model of cystic fibrosis. *Am J Epidemiol* 153:345–352
13. Albertsson-Wikland K, Karlberg J (1994) Natural growth in children born small for gestational age with and without catch-up growth. *Acta Paediatr Suppl* 399:64–70
14. Behrens R, Lang T, Muschweck H et al (1997) Percutaneous endoscopic gastrostomy in children and adolescents. *J Pediatr Gastroenterol Nutr* 25:487–491
15. Norton B, Homer-Ward M, Donnelly MT et al (1996) A randomised prospective comparison of percutaneous endoscopic gastrostomy and nasogastric tube feeding after acute dysphagic stroke. *BMJ* 312:13–16
16. Haynes L, Atherton DJ, Ade-Ajayi N et al (1996) Gastrostomy and growth in dystrophic epidermolysis bullosa. *Br J Dermatol* 134:872–879
17. Heine RG, Reddihough DS, Catto-Smith AG (1995) Gastroesophageal reflux and feeding problems after gastrostomy in children with severe neurological impairment. *Dev Med Child Neurol* 37:320–329
18. Chang PF, Ni YH, Chang MH (2003) Percutaneous endoscopic gastrostomy to set up a long-term enteral feeding route in children: an encouraging result. *Pediatr Surg Int* 19:283–285
19. Gauderer MW (1991) Percutaneous endoscopic gastrostomy: a 10-year experience with 220 children. *J Pediatr Surg* 26:288–292
20. Grant JP (1988) Comparison of percutaneous endoscopic gastrostomy with Stamm gastrostomy. *Ann Surg* 207:598–603
21. Haws EB, Sieber WK, Kiesewetter WB (1966) Complications of tube gastrostomy in infants and children. 15-year review of 240 cases. *Ann Surg* 164:284–290
22. Hogan RB, DeMarco DC, Hamilton JK et al (1986) Percutaneous endoscopic gastrostomy—to push or pull. A prospective randomized trial. *Gastrointest Endosc* 32:253–258
23. Kimber CP, Khattak IU, Kiely EM et al (1998) Peritonitis following percutaneous gastrostomy in children: management guidelines. *Aust NZ J Surg* 68:268–270
24. Marin OE, Glassman MS, Schoen BT et al (1994) Safety and efficacy of percutaneous endoscopic gastrostomy in children. *Am J Gastroenterol* 89:357–361

Paper II

Complications of video-assisted gastrostomy in children with malignancies or neurological diseases

EINAR ARNBJÖRNSSON¹, TORBJÖRN BACKMAN¹, HELENA MÖRSE²,
YVONNE BERGLUND¹, CARL MAGNUS KULLENDORFF¹ & HÅKAN LÖVKVIST³

¹Section of Paediatric Surgery, Department of Paediatrics, University Hospital, Lund, Sweden, ²Section of Oncology, Department of Paediatrics, University Hospital, Lund, Sweden, and ³Competence Centre for Clinical Research, University Hospital, Lund, Sweden

Abstract

Aim: To test the hypothesis whether the administration of cytostatic drugs close to surgery in children with malignancies influences the rate of postoperative complications. **Method:** Included in the study were 27 children with malignancies and a control group of 27 neurologically impaired children. All the children had nutritional problems and underwent a video-assisted gastrostomy (VAG) operation during the period 1997–2002. The children were postoperatively followed up. All complications were documented according to a protocol by a specially trained nurse and correlated to the time elapsed from completion of the last preoperative or the first postoperative cytostatic drug treatment. The complications in the two groups were compared. **Results:** The children with malignant diseases did not have more postoperative complications of the VAG than those having neurological defects. There was no correlation to complications regarding timing of the operation and administration of cytostatic drugs.

Conclusion: This study revealed no aggravated influence of cytostatic drug treatment on early postoperative problems of VAG. The timing of cytostatic drug administration in relation to the surgical intervention did not influence the frequency of postoperative complications.

Key Words: Children, complications, cytostatic drugs, gastrostomy, laparoscopy, malignancy, neurological impairment

Introduction

A gastrostomy is frequently used as an alternative to a nasogastric tube in children who are unable to receive normal oral feeding and in whom the nasogastric tube causes respiratory or other problems. Different operative procedures have been described including the time-honoured open surgical methods and the more recently introduced minimally invasive methods for gastrostomy. Among them are the widely performed percutaneous endoscopic gastrostomy (PEG) [1] and the video-assisted gastrostomy (VAG) procedure, previously described by us [2,3].

Surgery in children with malignancies has been uncertain regarding the timing of cytostatic drug treatment. Should cytostatic drugs be withheld during the week before surgery and/or the postoperative days? Is the rate of postoperative complications influenced by the immediate administration of cytostatic drugs, and is it higher than when performed in children with neurological disability?

This study was undertaken to test the hypothesis whether administration of cytostatic drugs close to surgery in children with malignancies influences the rate of complications after a VAG procedure. We are not aware of other similar reports in the literature.

Material and methods

Patients

The study group comprised a heterogeneous group of 27 children with malignancies treated with cytostatic drugs and a VAG procedure during the period 1997–2002. There were 16 boys and 11 girls. Their age varied from 6 mo to 18 y, with a mean of 6 ± 5 y. The control group consisted of 27 neurologically impaired children matched for age, sex and operative procedure, selected from a cohort of 154 patients with neurological disabilities operated with VAG during the same period.

The indications for a gastrostomy were nutritional problems either during treatment with cytostatic drugs or in neurologically impaired children. The VAG procedure was never performed prophylactically. The operation was carried out when it was considered that the child's condition would safely allow a surgical intervention. The decision to operate did not depend on the timing of the chemotherapy. Their laboratory blood status at the time of surgery is summarized in Table I. None of the children were neutropenic, with absolute neutrophil count (ANC) $< 0.5 \times 10^9/l$.

Methods

All operations were performed under general and local anaesthesia using the video-assisted gastrostomy that we have described earlier [2,3]. The gastrostomy button was inserted directly. Oral feeding was started soon after the child was awake. Nutrition through the gastrostomy was commenced within 4 h and continued with increasing amounts of fluid as tolerated by the child. Bolus feeding through the gastrostomy and oral feeding were used in all children. Depending on the child's condition during the postoperative weeks, a varying percentage of the feeding was given through the gastrostomy.

The number of days after finishing the last cytostatic treatment and the performance of the VAG were documented. The number of days after surgery to the start of postoperative treatment with cytostatic drugs was also documented.

All the children in the two groups were prospectively followed up during the first postoperative days in hospital and at 1 and 6 mo after the operation, as well as at any time the child's guardians felt the need for help or advice. All complications were documented according to a special protocol and correlated to the time elapsed from the last cytostatic drug treatment before and the time of the first treatment after the operation.

We have only included significant postoperative complications requiring treatment, e.g. granuloma resulting in intervention such as cauterization or extirpation, infection requiring antibiotics and external leakage demanding some form of management.

Table I. Laboratory status at operation of 27 children with malignancies undergoing a VAG procedure.

Laboratory status at operation	Mean	SD	Range
Hb (g/l)	102	11	81–127
White blood count ($\times 10^9/l$)	6	7	1.1–9.3
Neutrophil count ($\times 10^9/l$)	2	1	0.78–4.6
Platelet count ($\times 10^9/l$)	271	218	29–805

The children guardians' informed consent was obtained for the use of records for this prospective research.

Statistical considerations

Each patient with malignant diseases was matched with a control subject having corresponding personal data. McNemar's test was used in order to find possible differences between "effect of exposure" and "effect of control".

We considered the discordant results and expected that children who were going through cytostatic treatment were more frequently suffering from postoperative side effects than the matching non-cytostatic-treated children. We assumed that the former group would include twice as many complications as the latter group.

An appropriate sample size was determined by employing the McNemar test, which is equivalent to using the binomial distribution of the discordant data. If alpha is 0.05, $\pi = 1/2$, $S = 2n/3$, then the required minimum discordant sample size for significance ($p > 1\alpha$) will be $n = 18$ or more. Consequently, the total minimum sample size required will be n/f , where f is the fraction of discordant observations.

We considered the 27 patients treated for malignant tumours by receiving cytostatic treatment and the 27 control subjects as two independent groups in a case-control study. With an alpha level of 0.05 and a relative risk of 2, i.e. the prevalence of complications in the cancer group is assumed to be twice as high as the prevalence of the control subjects group, the power will reach 0.80 or higher only when the prevalence of complications in the cancer group is above 0.8 (and the prevalence rate of the control group is consequently above 0.4).

Simultaneously, with an alpha of 0.05, a prevalence rate of 0.40 within the group receiving cytostatic treatment and a prevalence rate of 0.20 within the control subject group, the sample size must exceed 91 to meet the requirements concerning a power rating of at least 0.80.

Results

There were no serious operative complications such as the puncture of hollow organs or bleeding. There were no re-operations of the VAG due to adhesions or leakage into the peritoneal cavity. Patient diagnoses and the cytostatic drugs used are summarized in Table II.

The number and type of complications in the two groups are described in Table III. There was no difference in postoperative complications between the study group and the control group.

Table II. Summary of diagnoses and the cytostatic drugs used in 27 children with malignancies undergoing a VAG.

	Number of patients
<i>Diagnosis</i>	
Malignant CNS tumours	8
Lymphoma	2
Acute leukaemia	11
Malignant nasopharyngeal tumours	1
Rhabdomyosarcoma	1
Neuroblastoma	3
Ewing's sarcoma	1
Total	27
<i>Drug</i>	
Antimetabolites (MXT [®] , Thioguanine [®] , Cytarabine [®] , Fludarabine [®])	17
Alkylating drugs (Carboplatin [®] , Melphalan [®] , Cisplatin [®] , Cyklo [®] and Ifosfamide [®] , BCNU [®])	13
Podophyllotoxin derivatives (Etoposide [®])	6
Mitosis inhibitors (Vincristine [®])	8
Anthracyclines (Doxorubicin [®] , Mitoxantrone [®])	8
Others (Topotecan [®] , Dactinomycin [®])	14
Steroids	7

The relation to the time elapsed from pre- and postoperative administration of cytostatic drugs is summarized in Table IV. The 27 patients treated for malignant tumours were indexed and ranked due to post-surgery complications. The possible statistical correlation between those ranked values and (a) the number of days from interrupting the cytostatic treatment until the day of surgery, and (b) the number of days from surgery until reinitiating the cytostatic treatment was computed using Spearman. However, none of the variables were significantly correlated with the post-surgery complication rank ($R_{\text{rank: variable (a)}} = -0.19$, $p = 0.92$; and $R_{\text{rank: variable (b)}} = 0.11$, $p = 0.58$). The non-significant values might be explained by the small sample size.

There was no increase in postoperative complications related either to a shorter interval from the last

Table III. Summary of postoperative complications in the two groups of patients.

	Children with malignant disease	Neurologically impaired children
Number of patients	27	27
Male/female	16/11	16/11
Age, y (\pm SD), range	6.13 (\pm 5.36) 6 mo–18 y	5.98 (\pm 5.02) 5 mo–16 y
Complications during the first postoperative month	5	6
Granuloma	10	7
Infection	5	4
Leakage		
Complications at 6 mo postoperation	8	5

preoperative treatment with cytostatic drugs or timing of the first postoperative cytostatic drug treatment. There was no correlation between white blood cell count, neutrophil count or platelet count at the time of surgery and the frequency of post-surgery complications.

Discussion

Nutrition in children with a malignant disease often poses serious problems. Intensive chemotherapy may result in malnutrition as it may lead to loss of appetite, food aversions, mucositis, nausea and vomiting [4–6]. A nasogastric tube has previously been the standard method for administering enteral nutrition to a child with malignant disease who is unable to eat adequately. Tube feeding is associated with several side effects, especially pain from severe mucositis as well as infection and perforation of the oesophagus [7]. Parenteral nutrition carries the risk of catheter-related infections, and a lack of enteral nutrition may contribute to the passage of bacteria into the systemic circulation [8].

Percutaneous endoscopic gastrostomy (PEG) was introduced in 1980 [1], and it has since become the routine procedure in many institutions. We have developed another modality, which is a video-assisted laparoscopic gastrostomy (VAG) [2,3]. This procedure, where a button is placed directly into the gastrostoma, has been valuable in neurologically impaired children.

The present study was designed to determine whether the VAG procedure is also valuable in children with a malignant disease and whether it leads to a higher rate of early postoperative complications compared to a control group of neurologically impaired children. Surgical intervention in children with malignancies could potentially be more dangerous and subject to a higher frequency of complications as a consequence of the treatment with cytostatic drugs.

It has been speculated that children with malignancies and a gastrostomy often have more problems from their gastrostomy while on treatment with cytostatic drugs. It therefore seemed a reasonable assumption that surgery in a child undergoing treatment with cytostatic drugs would lead to more postoperative complications than in neurologically impaired children. The findings of previous studies and our presented study do not support this suggestion [9].

The study population receiving chemotherapy was heterogeneous and varied widely in age (from 6 mo to 18 y), in the type of disease and in chemotherapy given. This is significant. For example, age would have had a major effect on the ability of the child to tolerate chemotherapy. Furthermore, age matching with neurologically impaired children does not negate

Table IV. Postoperative complications related to the time from the last preoperative treatment or to the first postoperative cytostatic drug treatment. Statistical correlation computed using Spearman.

	Total no. of patients	Granuloma	Infection	Leakage external	Problem 6 mo postop.
Number of days from last cytostatic treatment to surgery (mean 19 ± 8 d)					
<14 d	4	0	1	0	1
14–18 d	4	2	3	0	2
21–28 d	8	0	3	2	2
>30 d	11	3	3	3	3
					<i>p</i> = 0.92
Number of days from surgery to first cytostatic treatment (mean 14 ± 17 d)					
No treatment	6	3	2	1	0
0–3 d	6	0	2	2	3
4–7 d	6	0	2	0	1
12–28 d	5	2	1	2	3
>30 d	4	0	3	0	1
					<i>p</i> = 0.58

these problems. These children also vary widely in terms of operative risk and complications.

A more logical study would have compared oncology children with and without cytotoxic effects, e.g. bone marrow depression. Such a study would be ethically impossible at our department since no prophylactic operations are performed.

VAG complications in this study were recorded prospectively and therefore were probably more reliable than retrospective information obtained from other reported series in the medical literature.

Complications resulting from the VAG button were recorded, including local infections and mechanical problems with leakage as well as feeding intolerance with nausea, vomiting and diarrhoea [10]. We were surprised at not finding any increased frequency of complications in the children receiving cytostatic drugs within a few days before or even within 1 wk after surgery, as had been our expectation before starting the study. The same types and frequency of complications were encountered in the control group of disabled children with no malignant disease or cytostatic drug treatment [9].

Furthermore, this study showed no differences in the rate of postoperative complications in children with malignant diseases compared to neurologically impaired children. Moreover, the time of cytostatic drug administration did not significantly change the rate of complications.

ANC at the time of the operation would be a better marker of chemotherapy effect than the time from chemotherapy. However, this was not statistically verified in this study.

As a conclusion of this study, we recommend a VAG procedure even in children with a malignant disease. We also recommend postponement of cytostatic treatment for some days after surgery

despite the lack of clear evidence supporting this statement. We strongly advise a careful surgical technique carried out by a trained surgeon and management in cooperation with the paediatric oncology team.

References

- [1] Gauderer MW, Ponsky JL, Izant RJ Jr. Gastrostomy without laparotomy: a percutaneous endoscopic technique. *Nutrition* 1998;14:736–8.
- [2] Andersson L, Mikaelsson C, Arnbjörnsson E, Larsson LT. Laparoscopy aided gastrostomy in children. *Ann Chir Gynaecol* 1997;86:19–22.
- [3] Mikaelsson C, Arnbjörnsson E, Larsson LT. The laparoscopy button. A new method with minimal surgical trauma in gastrostomy in children. *Lakartidningen* 1995;92:3237–8.
- [4] Mathew P, Bowman L, Williams R, Jones D, Rao B, Schropp K, et al. Complications and effectiveness of gastrostomy feedings in pediatric cancer patients. *J Pediatr Hematol Oncol* 1996;18:81–5.
- [5] Pedersen AM, Kok K, Petersen G, Nielsen OH, Michaelsen KF, Schmiegelow K. Percutaneous endoscopic gastrostomy in children with cancer. *Acta Paediatr* 1999;88:849–52.
- [6] Skolin I, Axelsson K, Ghannad P, Hernell O, Wahlin YB. Nutrient intake and weight development in children during chemotherapy for malignant disease. *Oral Oncol* 1997;33:364–8.
- [7] Doyle FM, Kennedy NP. Nutritional support via percutaneous endoscopic gastrostomy. *Proc Nutr Soc* 1994;53:473–82.
- [8] Christensen ML, Hancock ML, Gattuso J, Hurwitz CA, Smith C, McCormick J, et al. Parenteral nutrition associated with increased infection rate in children with cancer. *Cancer* 1993;72:2732–8.
- [9] Arnbjörnsson E, Larsson LT, Lindhagen T. Complications of laparoscopy-aided gastrostomies in pediatric practice. *J Pediatr Surg* 1999;34:1843–6.
- [10] Aquino VM, Smyrl CB, Hagg R, McHard KM, Prestridge L, Sandler ES. Enteral nutritional support by gastrostomy tube in children with cancer. *J Pediatr* 1995;127:58–62.

Paper III

Complications of video-assisted gastrostomy in children with or without a ventriculoperitoneal shunt

Torbjörn Backman · Yvonne Berglund ·
Helen Sjövie · Einar Arnbjörnsson

Accepted: 5 April 2007 / Published online: 9 May 2007
© Springer-Verlag 2007

Abstract The aim of the study was to test the hypothesis that the presence of a ventriculoperitoneal shunt (VPS) influences the frequency of postoperative complications after video-assisted gastrostomy (VAG) in children. When using a power of 80%, a critical value for significance of 5% and an assumed population-based standard deviation of 0.4, it will be required to have a sample size of at least 14 children to show that a difference of 0.6 is significant when using Student's *t* test for paired samples. Thus, 15 consecutive children with VPSs were included in the present study. All the children had nutritional problems and underwent a VAG operation at a tertiary care university hospital. After the operation, the children were prospectively followed up. Specially trained nurses documented all complications according to a protocol. For the purpose of comparison, we had a control group of neurologically disabled children without VPSs, matched for age and operated with VAG. The children did not present with any serious postoperative intra-abdominal complications or central nervous system infection. There was no significant difference in the frequency of minor complications between the studied group and the control group. This study did not reveal that children with VPSs who undergo a VAG button placement are at high risk for infection and subsequent shunt malfunction. They did not have more postoperative problems than a matched control group of neurologically disabled children.

Keywords Gastrostomy · Laparoscopy · Children · Hydrocephalus · Complications · Neurological disability · Ventriculoperitoneal shunt

Introduction

A gastrostomy is frequently used as an alternative to a nasogastric tube in children who are unable to manage normal oral feeding for a long time and in whom the nasogastric tube causes respiratory or other problems. Different operative procedures have been described, including the time-honoured open surgical methods and the more recently introduced minimal invasive methods for gastrostomy. Since its introduction in 1980, the percutaneous endoscopic gastrostomy (PEG) procedure has become firmly established and is widely used [1]. The complications of the PEG procedures in children are well documented and are mainly related to the blind puncture of the abdominal wall with a risk of perforation of internal organs, bleeding, obstruction or development of a gastroenteric fistula in 3.5% of the children [2, 3].

In order to avoid the complications associated with PEG, the laparoscopy or video-assisted gastrostomy (VAG) technique [4–7] has been used at our centre since 1994. Laparoscopy reduces the risk of unnoticed intra-abdominal injury and allows for the exact positioning of the gastrostomy site on the stomach as well as on the abdominal wall. Suture of the stomach to the anterior abdominal wall decreases the risk of dislodgement. Placement of a primary low profile gastrostomy button eliminates the need for anaesthesia later when changing the gastrostomy device.

The safety of VAG was prospectively studied in 15 consecutive children who had a ventriculoperitoneal shunt

T. Backman · Y. Berglund · H. Sjövie · E. Arnbjörnsson (✉)
Section for Paediatric Surgery,
Department of Paediatrics,
University Hospital, 221 85 Lund, Sweden
e-mail: einar.arnbjornsson@telia.com

(VPS). This study was undertaken to test the hypothesis whether the presence of a VPS influences the type and frequency of complications after a VAG procedure in children. We are not aware of any other similar report in the literature.

Materials and methods

The study group comprised a heterogeneous sample of 15 consecutive children with VPSs and operated with the VAG procedure and prospectively included. There were eight boys and seven girls. Their age varied from 2 months to 12 years with a mean of 4.2 ± 4.2 years. The control group consisted of 15 neurologically disabled children without VPSs, matched for age, sex and operative procedure, retrospectively selected from a cohort of 167 patients with neurological disabilities operated with VAG during the study period.

The indications for a gastrostomy were nutritional problems in neurologically impaired children. The VAG procedure was never performed prophylactically. The operation was carried out when it was considered that the child's condition would safely allow surgical intervention and when the need for nutritional support was considered necessary for more than 6 months. An upper GI X-ray had been performed in all patients. All patients were clinically evaluated for GER before the gastrostomy placement. In nine studied patients and in eight control patients an endoscopy and 24 h pH measurements were performed. None had the indications for surgery for GER. No patient in the present study had clinical signs of an intra-abdominal infection at the time of PEG placement and none were on steroid medication.

All the VPSs had been placed at least 8 weeks prior to the placement of the gastrostomy button. Prophylactic antibiotics, Cefuroxim, Zinacef[®], 20 mg/kg body weight were given prior the operative intervention. All operations were performed under general and local anaesthesia. A previously described method was used [4–6].

A 2 or 3 mm Verres-type needle (MiniPortTM provided by AutoSuture, manufactured by United States Surgical Corporation, Norwalk, CT, USA) was introduced into the abdominal cavity by an open access technique through the umbilicus, using a mini laparotomy. Pneumoperitoneum was created by carbon dioxide (CO₂) insufflation with a flow rate of 1 l/min and an intra-abdominal pressure of 8 mm mercury (HG). A 2 or 3 mm, 0° or 30° optic was then introduced through the Verres cannula and the abdominal cavity inspected, whereby the VPS catheter was localised.

At the selected location for the gastrostomy button, a 2, 3 or 5 mm trocar was introduced into the abdominal cavity under direct vision. The location was usually at the mid-point between the umbilicus and the costal margin and through the left rectum muscle. A grasper was introduced into the abdomen through the trocar and used to seize the anterior stomach wall at the point selected for placement of the gastrostomy button. The stomach wall was then pulled out and sutured to the fascia in the abdominal wall. Through two purse string sutures the stomach wall was opened and a gastrostomy button (Mickey[®] provided by Ballard Medical Product, UT, USA) inserted. The purse string sutures were then pulled and tied tightly. The gastrostomy balloon was inflated with 6 ml of sterile water. The button size was 14 or 12 French thick with a length between 1.0 and 1.7 cm.

Oral feeding was started soon after the child had woken up. Nutrition through the gastrostomy was commenced within 2–4 h and continued with increasing amounts of fluid as tolerated by the child. Bolus feeding through the gastrostomy and oral feeding was used in all children. Depending on the child's condition during the postoperative weeks, a varying percentage of the feeding was given through the gastrostomy.

All the children were prospectively followed up during the first postoperative days in hospital and at 1 and 6 months after the operation, as well as any time the child's guardians felt the need for help or advice. All complications were documented according to a protocol. We have only included significant postoperative complications requiring treatment, e.g. granuloma resulting in intervention, such as cauterisation, infection requiring antibiotics and leakage demanding some form of management.

This report complies with the current laws in the country in which it is written. The design of the study included only routine follow-up of the routinely operated patients. The informed consent of the children's guardians was obtained. This work was performed in accordance with the rules of the ethical committee at our centre and the ethical standards laid down in the 1964 Declaration of Helsinki.

Statistical considerations

The sample size $N = 15$ is sufficient to perform a paired-sample t test, obtaining a significant difference when the mean difference is 0.6, the standard deviation is 0.4, the alpha level for rejecting the null-hypothesis of mean difference = 0 is 5% and the power is above 80%. The Student's t test, paired-sample t test, was used. Non-parametric test, Wilcoxon, gave the same result. All statistical computations were made using SPSS version 15.

Results

There were no serious operative complications, such as puncture of hollow organs or bleeding. In the immediate postoperative period, no wound or intra-abdominal complications occurred. There were no reoperations of the VAG due to adhesions or leakage.

The patients’ demographic data and diagnoses are summarised in Table 1. The number and type of complications in the two groups are described in Table 2. There was no difference in postoperative complications between the study and the control group.

Discussion

Ventriculoperitoneal shunt is frequently associated with complications, such as shunt obstruction, infection and migration with or without erosion into nearby structures. These complications may occur at the abdominal site of a VPS raising the question of whether concurrent use of a separate intra-abdominal catheter such as a PEG, is safe and effective. Surgical intervention in children with VPS could potentially be more dangerous and subject to a higher

Table 2 Summary of the number and type of complications in the two groups of patients

	Control ^a , Subjects (N = 15)	Case ^b , Patients (N = 15)
Complications during the first postoperative months		
Granuloma	6	7
Infection	5	3
Leakage	1	2
Complications at 6 months postoperation	4	3

^a All control subjects underwent a video-assisted gastrostomy (VAG) operation only

^b Case patients had a ventriculoperitoneal shunt and underwent a VAG operation

Table 1 The demographic data of the children and controls included in the study

	Control ^a Subjects	Case ^b Patients
Number of patients	15	15
Male/female	8/7	8/7
Age, years (±SD)	4.1 ± 4.0	4.2 ± 4.2
Range	4 months–11 years	2 months–12 years
Diagnoses		
Brain tumour		6
Hydrocephalus/ Myelomeningocele		3
Premature with intracranial bleeding		3
Malformation or syndrome		2
Post-traumatic brain damage		1
Neurological dysfunction		
Cerebral palsy	15	
Position of abdominal shunt catheter		
Left		8
Middle		5
Right		2

^a All control subjects underwent a video-assisted gastrostomy (VAG) operation only

^b Case patients had a ventriculoperitoneal shunt and underwent a VAG operation

frequency of complications. Many of the complications from VPS could preclude a VAG operation or raise serious concern with respect to VAG placement. Thus, it is acknowledged that the rate of peritonitis may be increased by the presence of a VPS. This issue remains unresolved and is influenced by institutional and individual expertise of which some have concluded that simultaneous placement of a VPS and PEG should be avoided [8].

Some 5–10% of all inserted VP shunts eventually require revision for infection [8]. The infective complications of PEG include stoma site infection in 3–9% and peritonitis in 1–7% [9]. The standard pull-through technique of PEG insertion exposes the gastrostomy tube to oropharyngeal bacterial flora. Thus, following PEG, there are a number of factors that could lead to an intra-peritoneal catheter becoming exposed to bacterial pathogens. In fact, an increased rate of VP shunt infections following PEG insertion has not yet been established. Previous reports have shown that there was no significant morbidity associated with a PEG in presence of a VPS [10, 11]. Although our study does not indicate that children with VPSs who undergo the VAG procedure are at greater risk of infection and subsequent shunt malfunction, there are other studies recommending prophylactic antibiotic therapy to cover skin and oral flora [8, 11]. Our patients have received antibiotic prophylaxis.

The placement of a percutaneous gastrostomy feeding tube, in the acute phase, in children with brain tumours and VP shunts may increase the risk of ascending meningitis especially if there are early gastrostomy-related complications [12]. Highly disabled patients often have other potential risk factors for VP shunt infections, such as poor nutritional status, long-term hospitalisation, subclinical infections and pressure ulcers. There seems to be consensus in the literature that antibiotic prophylaxis for PEG insertion is desirable in order to reduce the percentage of PEG site infection [13].

Coplacement of PEG and a VPS is reported [14]; the authors recommended at least 1 month between the procedures as well as administration of antibiotic prophylaxis. In the case series presented here, there was a lapse of at least 2 months between VPS and VAG.

The VAG complications in this study were recorded prospectively and were, therefore, more reliable than retrospective information obtained from other reported series in the medical literature. The complications from the VAG button were recorded, including local infections and mechanical problems with pain and leakage. To our surprise, and contrary to our expectations at the outset of the study, we did not find any increased frequency of complications following VAG in the children with VPS. The same types and frequency of complications were encountered in the control group of disabled children with no malignant disease or cytostatic drug treatment as had been reported earlier [6].

In conclusion, placement of a gastrostomy button in patients with VPSs raises valid concern for CSN infection and shunt malfunction. Ideally, the gastrostomy button should be performed several weeks after VPS placement, and the patients should be given an antibiotic prophylactically to prevent infection with skin flora. Using the laparoscopy and visualising the VPS catheter should be preferable to a blind trans-abdominal puncture as when placing a PEG. Our study indicates children with VPSs who undergo a VAG are at no greater risk of infection and subsequent shunt malfunction. Until the results of larger clinical trials are available, it is our recommendation to use VAG in patients with VPS when long-term enteral nutrition is required.

Acknowledgments Authors acknowledge Gillian Sjö Dahl, Lexis English for Writers, Persikevägen 11, 22355 Lund Sweden, for linguistic revision of the manuscript and Håkan Lövkvist MSc, Biostatistician, Competence Centre for Clinical Research, University Hospital, SE-221 85 Lund, Sweden, for statistical advice. This study was financially supported by Stiftelsen Samariten, Sachska Children's Hospital, 118 83 Stockholm, Sweden and The Skåne Region Research and Development Foundation, Box 1, 221 00 Lund, Sweden.

References

1. Gauderer MW, Ponsky JL, Izant RJ Jr (1998) Gastrostomy without laparotomy: a percutaneous endoscopic technique. *Nutrition* 14:736–738
2. Khattak IU, Kimber C, Kiely EM, Spitz L (1998) Percutaneous endoscopic gastrostomy in paediatric practice: complications and outcome. *J Pediatr Surg* 33:67–72
3. Patwardhan N, McHugh K, Drake D, Spitz L (2004) Gastroenteric fistula complicating percutaneous endoscopic gastrostomy. *J Pediatr Surg* 39:561–564
4. Mikaelsson C, Arnbjörnsson E, Larsson LT (1995) The laparoscopy button. A new method with minimal surgical trauma in gastrostomy in children. *Läkartidningen* 36:3237–3238
5. Arnbjörnsson E, Larsson LT, Lindhagen T (1999) Complications of laparoscopy-aided gastrostomies in pediatric practice. *J Pediatr Surg* 34:1843–1846
6. Arnbjörnsson E, Backman T, Morse H, Berglund Y, Kullendorff CM, Lovkvist H (2006) Complications of video-assisted gastrostomy in children with malignancies or neurological diseases. *Acta Paediatr* 95(4):467–470
7. Rothenberg SS, Bealer JF, Chang JH (1999) Primary laparoscopic placement of gastrostomy buttons for feeding tubes. A safer and simpler technique. *Surg Endosc* 13:995–997
8. Taylor AL, Carroll TA, Jakubowski J, O'Reilly G (2001) Percutaneous endoscopic gastrostomy in patients with ventriculoperitoneal shunts. *Br J Surg* 88(5):724–727
9. Sane SS, Towbin A, Bergley EA, Kaye RD, Fitz CR, Albright L, Towbin RB (1998) Percutaneous gastrostomy tube placement in patients with ventriculoperitoneal shunts. *Pediatr Radiol* 28(7):521–523
10. Graham SM, Flowers JL, Scott TR, Lin F, Rigamonti D (1993) Safety of percutaneous endoscopic gastrostomy in patients with a ventriculoperitoneal shunt. *Neurosurgery* 32(6):932–934
11. Baird R, Salasidis R (2004) Percutaneous gastrostomy in patients with a ventriculoperitoneal shunt: case series and review. *Gastrointest Endosc* 59(4):570–574
12. Gassas A, Kennedy J, Green G, Connolly B, Cohen J, Dag-Ellams U, Kulkarni A, Bouffet E (2006) Risk of ventriculoperitoneal shunt infections due to gastrostomy feeding tube insertion in pediatric patients with brain tumors. *Pediatr Neurosurg* 42(2):95–99
13. Nicholson FB, Korman MG, Richardson MA (2000) Percutaneous endoscopic gastrostomy: a review of indications, complications and outcome. *J Gastroenterol Hepatol* 15(1):21–25
14. Nabika S, Oki S, Sumida M, Isobe N, Kanou Y, Watanabe Y (2006) Analysis of risk factors for infection in coplacement of percutaneous endoscopic gastrostomy and ventriculoperitoneal shunt (discussion 229–230). *Neurol Med Chir (Tokyo)* 46(5):226–229

Paper IV

Continuous Double U-stitch Gastrostomy in Children

Authors

T. Backman, H. Sjövie, C.-M. Kullendorff, E. Arnbjörnsson

Affiliation

University Hospital, Department of Pediatric Surgery, Lund, Sweden

Key words

- gastrostomy
- laparoscopy
- child

Abstract

Background: In children, a gastrostomy button was placed as the initial feeding tube, using laparoscopy and a modified surgical technique. The aim of this study was to test the hypothesis that a new surgical procedure developed at our institution would result in fewer postoperative complications.

Patients and methods: Sixty-two consecutive children with nutritional problems underwent a video-assisted gastrostomy operation (VAG). The technique requires the use of a 2 or 3 mm laparoscope optic and a 5 mm trocar placed at the exit site chosen for the gastrostomy. A continuous double U-stitch absorbable suture created a purse string suture around the gastrostoma on the stomach and fixated the stomach to the abdominal wall. For comparison, we used a control group of 68 children with nutritional

problems operated on with our previously published VAG technique. After surgery, the children were followed up at one and six months and all complications were documented according to a protocol.

Results: The two groups of children were comparable with regard to their demographic data. There were no serious intra-operative or postoperative intra-abdominal complications requiring reoperation. There was a significantly lower incidence of the minor complication of granuloma around the gastrostoma in the study group compared with the control group.

Conclusion: This variation of the surgical technique is simple and effective. It allows primary placement of a gastrostomy button that is functionally and cosmetically comparable to a gastrostomy tube surgically placed by other methods. In this study, the patients had fewer postoperative problems than the control group.

received July 01, 2009
accepted after revision
July 18, 2009

Bibliography

DOI <http://dx.doi.org/10.1055/s-0029-1238316>
Published ahead of print:
14 October 2009
Eur J Pediatr Surg 2010; 20:
14–17 © Georg Thieme
Verlag KG Stuttgart · New York
ISSN 0939-7248

Correspondence

Dr. Torbjörn Backman
University Hospital
Department of Pediatric
Surgery
22185 Lund
Sweden
Tel.: +46/461/71000
Fax: +46/461/72299
torbjorn.backman@skane.se

Introduction

The surgical placement of a gastrostomy tube in children with substantial neurologic impairment, feeding disorders or failure to thrive may cause significant complications, including wound infection, leakage and excessive granulation tissue. The use of a percutaneous gastrostomy tube (PEG) obviates the need for a laparotomy. The technique is associated with the same complications, as well as the risk of inadvertent bowel injury [3, 8–13, 16, 17]. At our pediatric surgical center, laparoscopic assisted gastrostomy has been the customary procedure during the last 15 years [2, 4–7, 15]. Among the benefits of laparoscopic assisted gastrostomy is the possibility of controlled placement of the tube in an anatomically correct position. Furthermore bowel injury can be better avoided, and the placement of a

definitive gastrostomy button is possible during the first surgery.

This report describes our experience with a modified technique for primary laparoscopic placement of a gastrostomy button in children compared with our earlier technique. We are not aware of any similar report in the literature comparing two different minimally invasive video-assisted techniques for constructing a gastrostomy in children.

Material and Method

A gastrostomy button was placed consecutively in 130 children with nutritional problems using a laparoscopic technique during the period from January 2005 through December 2008. Of these, the study group comprised a heterogeneous sample of the 62 latest consecutive children operated

on with a modified surgical procedure. The control group consisted of the first 68 children operated on with our previously published video-assisted gastrostomy (VAG) procedure. The demographic data of all the children are summarized in [Table 1](#) and their diagnoses in [Table 2](#).

The indication for gastrostomy was severe nutrition problems when nutritional support was considered necessary for more than the next six months. The operation was carried out when the child's condition permitted surgical intervention safely. The gastrostomy operation was never performed prophylactically. Before gastrostomy button placement, all children were clinically evaluated for gastroesophageal reflux and gastric emptying. An upper GI X-ray and a 24 h pH measurement in the esophagus were performed when considered necessary. A gastric emptying scan or measure of impedance was not performed. In the present study, no patient had clinical signs of intra-abdominal infection nor was being treated with cytostatic drugs or steroid medication at the time of surgery.

A 2 or 3 mm trocar was inserted by performing a mini laparotomy through the umbilicus. The abdomen was insufflated with CO₂ up to a pressure of 8 mmHg at a flow rate of 1 l/min. In order to visualize the abdominal cavity a 2 or 3 mm, 0° or 30° laparoscope optic was used. A site was chosen for the gastrostomy located approximately at the midpoint from the left costal margin to the umbilicus, far enough from the costal margin to ensure that the button did not ride against cartilage when the abdomen was desufflated. At that site, a single 5 mm trocar was placed. Through the trocar, a grasper was passed which was used under direct vision to catch the stomach wall at the site selected for the gastrostoma. The grasping site needs to be far enough away from the pylorus to prevent gastric outlet obstruction by the intraluminal balloon on the button, especially in small infants. The stomach wall was then exteriorized when withdrawing the instrument and trocar. If necessary, a clamp was used to mildly dilate the tract. In patients with a thicker abdominal wall, this procedure may be more difficult and the incision may have to be enlarged to allow adequate access to the stomach.

With the grasper holding the stomach wall, a needle with an absorbable suture was inserted through the abdominal wall, beginning through a small incision half a centimeter from the gastrostoma. Using the previous method two purse string sutures were placed directly on the stomach wall around the gastrostoma, grasping the abdominal wall at two points. With the method reported here, the suture, as shown in [Fig. 1](#), was passed through the abdominal wall and the anterior wall of the stomach and visualized using either the videoscope or under direct vision on the abdominal wall. The suture was then pulled up through the abdominal wall on the contra lateral side half a centimeter from the gastrostoma. The needle was then turned 180 degrees and the procedure repeated, passing the suture back through the two small incisions on each side of the gastrostoma. Thus, the stomach was fixated to the abdominal wall with two continuous double U-stitches forming a purse string suture on the stomach wall around the gastrostoma in the center of the loop. To facilitate placement of this suture, the retracted stomach was returned into the abdomen to allow greater exposure of the fascia. It is important not to tighten these sutures until the button is in place, since they pull the stomach back into the abdomen and close the gastrostomy.

Before or after the stitches were placed, the stomach was opened with a needle diathermy or scissors and a catheter put in, leading the button into the stomach. After measurement, an appro-

Table 1 Summary of the demographic data of the children operated with the new technique and controls. No significant differences were found between the groups.

	Controls	Study patients	p value
number of patients	68	62	
male/female	36/32	39/23	
age (years) mean ± SD	2.9 ± 3.4	2.7 ± 3.1	
median (range)	1.8 (0.1–14)	1.5 (0.1–12)	
body weight (kg) mean ± SD	11.1 ± 7.0	11.2 ± 7.0	0.98
median (range)	9.2 (4–39)	9.1 (4–41)	
Z-score for weight	-2.0 ± 1.7	-2.2 ± 1.8	0.67
range	-6.6–1.9	-7.1–0.3	
body length (cm) mean ± SD	83 ± 26	82 ± 23	0.97
median (range)	76 (50–159)	74 (55–147)	
Z-score for length	-2.0 ± 1.8	-1.7 ± 1.5	0.95
range	-7.0–1.7	-5.8–0.9	
during the first postoperative month			
increased in weight	58 (85%)	54 (87%)	
decreased in weight	4 (6%)	2 (3%)	
unchanged	6 (9%)	6 (10%)	
died	0	0	

Controls: patients operated on with the previously published method for video-assisted gastrostomy

Study patients: patients operated on with the continuous double U-stitch method described here

Table 2 Diagnoses of the children and controls included in the study.

	Controls (n=68)	Study patients (n=62)
cerebral pares	29 (42%)	31 (50%)
malignancy	8 (12%)	7 (11%)
cardiac anomaly	7 (11%)	8 (13%)
metabolic disease and syndrome	15 (22%)	10 (16%)
gastrointestinal malformations	9 (13%)	6 (10%)

Controls: patients operated on with the previously published method for video-assisted gastrostomy

Study patients: patients operated on with the continuous double U-stitch method described here

No significant differences were found between the two groups

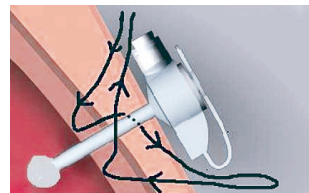


Fig. 1 Schematic drawing showing placement of a gastrostomy button through the abdominal wall and the stomach. The double U-stitch suture is placed starting half a centimeter from the gastrostoma on one side, following the arrow and passing to the contralateral side, turning around and grabbing the stomach again and finally passing through the first incision where the two ends can be tied together to form a purse string suture around the gastrostoma and the button.

proportionally sized button (12–14 Fr 1.0, 1.2, 1.5 cm) with a balloon tip was then placed through the gastrostomy. We used a MicKey® gastrostomy button type (provided by Ballard Medical Product, Draper, UT, USA). Lubrication of the button with water may be needed to ease its placement, as the tract is usually quite snug. The suture was tightly tied and the balloon inflated with 5 cc of water. The incision was not sutured around the button.

The nutrition or decompression tube was connected to the button and taped securely to the anterior abdominal wall to prevent any twisting or traction on the button. The tube, connected to the button was left open to gravity drainage for two to four hours until the child was awake and could be fed. At the end of the operation a gastroscopy was performed to evaluate if there were any signs of esophagitis and to verify that the placement of the gastrostomy button was not causing any hindrance to passage through the stomach.

Nutrition through the gastrostomy or oral feeding, if tolerated by the child, was started as soon as the child awoke from anesthesia, usually within two to four hours, and continued with increasing amounts as tolerated by the child. Later, bolus feeding through the gastrostomy and oral feeding were used in all children. A varying percentage of the feeding was given through the gastrostomy, depending on the child's condition.

All the children were prospectively followed up by a specially trained nurse during the first postoperative days in hospital and at one and six months after the operation, and at any time the child's guardians felt the need for help or advice. The endpoint of the study was at six months follow-up in all patients, documenting the type and number of complications. All complications were documented according to a special protocol. Serious complications were those demanding an emergency operative intervention, minor complications demanded only minor interventions. We have only included postoperative complications requiring treatment in this report, e.g. granuloma calling for and resulting in an intervention such as cauterization, infection requiring antibiotics, and leakage demanding some form of management.

Approval by our Hospital Institutional Review Board for the study protocol was not required because our group changed policy and transitioned from the older procedure to the new technique during the study period. This study included only conventional follow-up of routinely operated patients. As the protocol was designed to meet the requirements of legislative documentation required in the country of origin, no formal approval from the ethical committee was necessary and not asked for. The verbal informed consent of the children's guardians was obtained, and carried out in accordance with the ethical standards laid down in the 1964 Declaration of Helsinki.

Statistical considerations

When using a power of 80%, a critical value for significance of 5% and an assumed population-based standard deviation of 0.4, a sample size of at least 50 children is required to show that a difference of 0.3 is significant when using Student's *t*-test for paired samples.

Student's *t*-test was used. The non-parametric Wilcoxon test gave the same result. A *p* value < 0.05 was considered significant. All statistical computations were made using SPSS version 15 (SPSS, Inc., Chicago, IL, USA).

Table 3 Postoperative course in 130 children operated on with a laparoscopy-assisted gastrostomy using two different methods for suturing. The hospital stay was terminated when the child no longer required need of morphine analgesia and had received two full enteral meals.

	Controls	Study patients	<i>p</i> value
number of patients	68	62	ns**
operating time [minutes] (range)	24 (18–48)	22 (1–44)	ns
time to full enteral feeding [days] (range)	2 (1–4)	2 (1–5)	ns
pain treated with morphine* in	16 children	18 children	ns
hospital stay [days] (range)	2 (1–5)	2 (1–6)	ns

Controls: patients operated on with the previously published method for video-assisted gastrostomy

Study patients: patients operated on with the continuous double U-stitch method described here

*All children were treated with paracetamol regularly every six hours during the first 1–2 postoperative days

**No significant difference

Table 4 Summary of the number and type of complications occurring during the first six months postoperatively in the two groups of patients.

	Controls (n=68)	Study patients (n=62)	<i>p</i> value
complications during the first six postoperative months			
leakage	13 (19%)	11 (18%)	0.88
granuloma around the gastrostoma	37 (54%)	18 (29%)	0.01*
infection (treated with antibiotics)	19 (28%)	15 (24%)	0.32

Controls: operated on with the previously published method for video-assisted gastrostomy

Study patients: operated on with the continuous double U-stitch method described here

*Significant difference between the two groups

Results



All buttons were successfully placed laparoscopically. The operative time for placement of a button, the treatment of postoperative pain, the time to full enteral feeding and the duration of hospital stay are summarized in **Table 3**. There were no serious intra-operative complications, defined as complications demanding an emergency reoperation. There was no significant difference between the study group and the control group with regard to age, diagnosis, body weight and body length. We used the age-adjusted Z-scores of weight and length to normalize the data relative to a reference population. These figures are expressed as weight-for-age Z-scores calculated as: (actual weight – mean weight)/standard deviation [14], according to the nationally standardized weight curves [1].

The postoperative complications summarized in **Table 4** showed a significantly lower incidence of granuloma around the gastrostoma compared to the control group.

Discussion



The surgical method described here differs from previously published reports [3] in that the U-stitch is a double stitch performed with a single absorbable thread and tied subcutaneously outside

the gastrostomy instead of the double U-stitches using non-absorbable material tied around the gastrostomy button. Thus, it is not necessary to pull out any sutures with the method described here. Whether or not this improves the patient's condition cannot be answered by our data.

The results show a significant lower incidence of granuloma around the gastrostoma in the study group compared with the control group. This is because the suture fixating the stomach to the abdomen at the side of the stoma pulls the stomach back into the abdomen instead of pulling the stomach wall out through the abdominal wall as was the case when using the previously published method.

The rate of serious complications in this series was lower than that previously reported for PEG or standard Stamm gastrostomies. It has recently been documented that parents of a child with a gastrostomy need to be made aware that there is a 6% chance that the gastrostomy will require revision [8]. The most serious complications were wound infections that resolved with oral antibiotics or a frequent change of dressing. We tried to reduce the frequency of these complications by immobilizing the button, leaving the feeding tube connected to it and taped to the skin on the abdominal wall with the initial dressing, which is left in place for five days. This prevents any torque on the button site that might lead to leakage and become a source of infection. However, dislodgement can happen, for example, secondary to balloon failure. Since the stomach was well secured to the abdominal wall, the button could be easily replaced without incident in the form of a leakage into the abdominal cavity.

In conclusion, the laparoscopic placement of a primary gastrostomy button with the method described here is safe, effective, and easy to perform and postoperative problems are fewer compared to those seen after other laparoscopy-aided insertions of gastrostomy tubes. The method described here requires no special instrumentation. Primary placement of a button helps to avoid many of the wound care problems and cosmetic issues that have been commonly associated with traditional gastrostomy tubes.

Conflict of interest: None

References

- 1 Albertsson-Wikland K, Karlberg J. Natural growth in children born small for gestational age with and without catchup growth. *Acta Paediatr Suppl* 1994; 399: 64–70
- 2 Andersson L, Mikaelsson C, Arnbjörnsson E et al. Laparoscopy aided gastrostomy in children. *Ann Chir Gynaecol* 1997; 86: 19–22
- 3 Aprahamian CJ, Morgan TL, Harmon CM et al. U-stitch laparoscopic gastrostomy technique has a low rate of complications and allows primary button placement: experience with 461 pediatric procedures. *J Laparoendosc Adv Surg Tech A* 2006; 16: 643–649
- 4 Arnbjörnsson E, Backman T, Morse H et al. Complications of video-assisted gastrostomy in children with malignancies or neurological diseases. *Acta Paediatr* 2006; 95: 467–470
- 5 Arnbjörnsson E, Larsson LT, Lindhagen T. Complications of laparoscopy-aided gastrostomies in pediatric practice. *J Pediatr Surg* 1999; 34: 1843–1846
- 6 Backman T, Arnbjörnsson E, Berglund Y et al. Video-assisted gastrostomy in infants less than 1 year. *Pediatr Surg Int* 2006; 22: 243–246
- 7 Backman T, Berglund Y, Sjövie H et al. Complications of video-assisted gastrostomy in children with or without a ventriculoperitoneal shunt. *Pediatr Surg Int* 2007; 23: 665–668
- 8 Conlon SJ, Janik TA, Janik JS et al. Gastrostomy revision: incidence and indications. *J Pediatr Surg* 2004; 39: 1390–1395
- 9 Fonkalsrud EW, Ashcraft KW, Coran AG et al. Surgical treatment of gastroesophageal reflux in children: A combined hospital study of 7467 patients. *Pediatrics* 1998; 101: 419–422
- 10 Gauderer MWL. Percutaneous endoscopic gastrostomy: A 10 year experience with 220 children. *J Pediatr Surg* 1991; 26: 288–294
- 11 Khattak IU, Kimber C, Kiely EM et al. Percutaneous endoscopic gastrostomy in paediatric practice: complications and outcome. *J Pediatr Surg* 1998; 33: 67–72
- 12 Kimber CP, Khattak IU, Kiely EM et al. Peritonitis following percutaneous gastrostomy in children: Management guidelines. *Aust N Z J Surg* 1998; 68: 268–270
- 13 Kubiak R, Wilcox DT, Spitz L. Gastrojejunal fistula after insertion of percutaneous endoscopic gastrostomy. *J Pediatr Surg* 1999; 34: 1287–1288
- 14 Liou TG, Adler FR, Fitzsimmons SC et al. Predictive 5-year survivorship model of cystic fibrosis. *Am J Epidemiol* 2001; 153: 345–352
- 15 Noren E, Gunnarsdóttir A, Hanséus K et al. Laparoscopic gastrostomy in children with congenital heart disease. *J Laparoendosc Adv Surg Tech A* 2007; 17: 483–489
- 16 Patwardhan N, McHugh K, Drake D et al. Gastroenteric fistula complicating percutaneous endoscopic gastrostomy. *J Pediatr Surg* 2004; 39: 561–564
- 17 Rothenberg SS, Bealer JF, Chang JH. Primary laparoscopic placement of gastrostomy buttons for feeding tubes. A safer and simpler technique. *Surg Endosc* 1999; 13: 995–997

Paper V

Vomiting in children undergoing video-assisted gastrostomy tube placement

Torbjörn Backman, Helene Sjöwie, Malin Mellberg, Anna Börjesson, Magnus Anderberg, Carl-Magnus Kullendorff, Einar Arnbjörnsson

Department of Paediatric Surgery, Skåne University Hospital, Lund, Sweden and the Institution of Clinical Research, Lund University, Sweden

Corresponding author:

Torbjörn Backman

torbjorn.backman@skane.se

Department of Paediatric Surgery, Skåne University Hospital, S-221 85 Lund, Sweden

Phone work +4646178299 and home +46733396766

Fax +4646177051

Part of the material presented here, has been published as abstract number 305 with oral presentation at the 14th Congress of the European Paediatric Surgeon's Association in Leipzig, Germany, 5-8 June 2013

Abstract

Background:

Gastrostomy tube placement in sick children is commonly used when long-term enteral feeding is necessary. Many methods for establishing a gastrostomy have evolved and the laparoscopic technique is commonly used for the insertion. The aim of this study was to determine the incidence of pre- and postoperative vomiting in children undergoing a Video-Assisted Gastrostomy (VAG) operation.

Patients and methods:

From June 2006 to December 2011, 180 patients with nutritional problems underwent a VAG operation at our department. The children were subdivided into groups based on their underlying diagnosis. The work-up included an upper GI X-ray, gastroscopy and a 24 h pH measurement whenever considered necessary to rule out the need for anti-reflux surgery. An anamnesis with respect to vomiting was taken from each of the patients' parents before the operation. After the VAG operation all patients were followed prospectively during the first postoperative days, and at one and six months after surgery. All complications including vomiting were documented according to a standardized protocol.

Results:

Vomiting occurred preoperatively in 51 children (28%). Postoperatively at one month the incidence was 43 (24%) in the same group of children and at six months after surgery in 40 (22%) children. Vomiting occurred more frequently in the neurologically impaired children than in those with other diagnoses.

There was a difference in vomiting frequency both pre- and postoperatively between the groups included in the study. There was, however, no difference in pre- and postoperative vomiting frequency within each specific diagnosis group.

Other complications such as granulation, infections, leakage and tube dislodgement occurred but were almost fully resolved at 6 months postoperatively.

Conclusion;

The incidence of vomiting 6 months postoperatively in children with preoperative vomiting symptoms was 78%, i.e. preoperative vomiting symptoms persisted after the VAG operation. Neurologically impaired children had a higher incidence of vomiting than patients with other diagnoses, but this was probably due to their underlying

diagnosis and not the VAG operation. This information can be useful when counselling parents and colleagues preoperatively.

Key words:

Gastrostomy; Laparoscopy; VAG; Children; Complications; Vomiting

Introduction:

Gastrostomy is advocated for children with long-term nutritional feeding problems exceeding 3 months, independent of the underlying diagnosis. The percutaneous endoscopic gastrostomy (PEG) technique has been the most widely used method to achieve enteral access since its introduction in 1980 by Gauderer et al (1). Due to an association between the PEG procedure and a high frequency of complications (2,3) such as gastroenteric fistulas, we have, at our Department of Paediatric Surgery, chosen to use and further develop the VAG technique since 1994 (6,13). The advantages of the VAG technique over PEG are better visual control intra abdominally, the secure positioning of the stoma to the gastric wall and the gastroscopical control of the gastrostomy button placement in the ventricle cavity (3,6). Many centres now use the laparoscopic technique because it is considered to be a safer method (4,5).

Vomiting is a common symptom in children and associated with gastroesophageal reflux (GER). In infants this is a natural physiological process occurring several times a day in healthy children. This vomiting or regurgitation is often spontaneously resolved by 12-14 months of age. If the symptoms continue and become aggravated they might lead to gastroesophageal reflux disease (GERD). GERD is present when reflux of gastric contents is the cause of troublesome symptoms and/or complications (10), such as vomiting, leading to weight loss, recurrent upper airway infections, irritability, feeding refusal or dysphagia.

Whether gastrostomies lead to exacerbation of GERD has been debated, but guidelines and consensus nowadays dismiss that idea (11, 12), with the exception of neurologically impaired children. There is a higher incidence of GERD in children with neurological diseases than in healthy children probably due to oesophageal dysmotility with reduced lower oesophageal sphincter tonus. The majority of paediatric patients requiring gastrostomies are neurologically impaired (10,11,12) and postoperatively achieved anatomical alterations in the angle of His and gastric distension because of increased amounts of food might lead to exacerbation of GERD.

Previously published material concerning children operated on with VAG and undergoing oesophageal 24 h pH measurements pre- and postoperatively, have not shown an increased acid reflux after the operation (13). In a systematic review of GERD after the PEG procedure (14) the authors concluded that there was no current evidence that PEG insertion improved or aggravated GERD.

Similar systematic reviews studying the relationship between VAG and GERD are not known to us.

The aim of this study was to prospectively determine the incidence of vomiting pre- and postoperatively in children undergoing a VAG operation. Does the VAG procedure affect the vomiting frequency and is vomiting more frequent in certain diagnoses?

Material and methods:

From June 2006 to December 2011, 180 children underwent a VAG operation and all are included in this study. Demographic data are summarized in Table 1 and their underlying diagnoses in Table 2.

The indication for a gastrostomy was nutritional problems in severely ill or neurologically impaired children when the need for nutritional support was considered necessary for more than three months. The operation was carried out only if the child's condition allowed safe operative intervention.

The work-up included an upper GI X-ray to rule out gastric outlet obstruction. All the patients and their parents were interviewed by a doctor and a specialized nurse and clinically evaluated for GERD before the VAG operation. The vomiting symptoms were recorded according to a standardized protocol and added to the patient's case notes. Endoscopy and 24 h pH measurements were carried out when an anti-reflux operation seemed indicated. No operations were performed prophylactically.

The VAG operation was performed as described in previously published articles (5,6,12). Preoperative antibiotic prophylaxis was given. Through a lower umbilical skin incision, a mini laparotomy was done. A 3 mm VersaStep[®] troacar was safely inserted in the abdomen and pneumoperitoneum was established with CO₂ insufflation. Using a 3 mm 30 degree laparoscope the ventricle was identified. In between the left costal margin and the umbilicus a skin incision was made destined for the gastrostoma. A 5 mm troacar was inserted at this point into the abdomen under visual control with the laparoscope. Through this port the ventricle was

grasped with an instrument at its major side, with clear margins from the pylorus and exteriorized when the grasper and troacar were pulled back. The ventricle was then sutured to the rectus muscle fascia and the gastrostomy tube inserted into the cavity of the ventricle through a small incision in the ventricle wall. The placement of the gastrostomy tube was then controlled gastroscopically at the end of the surgical procedure.

All the children commenced oral feeding immediately postoperatively. Depending on the child's postoperative condition, a varying percentage of the total feeding was given through the gastrostomy.

All the children were followed up prospectively during the first postoperative days in the hospital and at one and six months after surgery at our day care unit. Specialized nurses recorded all complications during the follow-up according to a standardized protocol. The endpoint of the study was at six months. Additional follow-ups were performed at any time on request from the parents.

Vomiting was documented pre- and postoperatively according to the parents' reports with regard to the frequency of vomiting during the follow-up. In other words, there were no exact measurements of the frequency of vomiting (vomits/day) or on the amount of vomit (millilitre), but the symptoms were based upon the parents' observations.

Statistical analysis:

Data were analysed by Fisher's exact t-test, as well as non- parametric tests including the Mann-Whitney test. A p-value less than 0.05 was considered significant.

Ethical consideration:

The regional research ethics committee approved the study (registration number 2010/49). Permission to create a register of the patients was thereby obtained in accordance with the Swedish Privacy Protection Law.

Results

All 180 patients included in the study were operated on with the VAG method using the double U-stitch technique (12). All the children tolerated the procedure.

The development of granulation tissue and vomiting were the most common postoperative complications; these are shown together with the other registered complications in Table 3. Most of the patients had full resolution of their

complications at six months after surgery ($p<0.05$) except vomiting and tube dislodgement (Table 3).

The incidences of vomiting pre- and postoperatively are summarized in Table 4. In the group of 51 children with preoperative vomiting symptoms, 43 (84%) had symptoms one month after surgery and 40 (78%) had remaining symptoms at the endpoint of the study, 6 months postoperatively.

Of the children who had no preoperative vomiting symptoms ($n=129$), 14 (11%) had a gradual increase in vomiting frequency during the follow-up.

The vomiting frequencies in each group of patients pre- and postoperatively and at the 6 month follow-up are listed in Table 5.

There were differences in vomiting frequencies between the patient groups based on the underlying diagnosis both pre- and postoperatively ($p=0.0152$ and $p=0.0049$). There was, however, no difference in vomiting frequency pre- and postoperatively within the same patient group.

Discussion

The results of this prospective study of 180 consecutively VAG- operated children, show that vomiting is a common symptom both pre- and postoperatively.

Throughout the study period, the recording of vomiting frequency has been based on the parents' observations and therefore the interpretation of the results may be queried. There was no definition of volume required for it to be called vomiting and no registration during hospitalization or at the out-patient clinic during follow-up as to how many times/day the patients vomited. But since the same parents have observed vomiting frequency in the same patients, we consider the results to be reliable. It is, however, possible that a more objective definition and registration of vomiting might have led to different results regarding vomiting frequency.

This study also shows that preoperative vomiting persists after a VAG operation. In the group of children with preoperative vomiting, 78 % still vomited at six months postoperatively. These findings might indicate that the operation itself does not considerably influence the vomiting symptom, but that the reason why it persists is more likely to be found in the children's underlying diagnoses.

In the group of patients that did not vomit preoperatively there was a gradual increase in vomiting frequency of 1.5% at one month and 11% at six months postoperatively. These findings cannot be traced to a certain diagnosis or age group.

The reason or reasons behind this increase in vomiting frequency can only be speculated upon. One possible reason might be placement of the gastrostomy button close to the pylorus, causing a slight gastric outlet obstruction. This was not, however, noted or commented upon during the gastroscopy at the end of the VAG procedure.

Another potential explanation for the increased vomiting frequency might be a general deterioration in the child's underlying disease.

This group might then be equalled with the group with preoperative vomiting, i.e. the cause is to be found in their underlying diagnosis and not in the VAG procedure.

There was a difference in vomiting frequency between the patient groups based on their underlying diagnosis both pre- and postoperatively. Vomiting occurred more frequently in the neurologically impaired children than in the other groups. The same finding has been described earlier in the literature, but then as a part of GER symptom (10-12,14). There was, however, no difference in vomiting frequency pre- and postoperatively within each specific group.

Even with the knowledge of the vomiting frequencies seen in this study, the VAG operation is still beneficial for many of the children and their families. Protracted forced meals orally or frequent replacement of nasogastric tubes without any secure weight gain, cause a lot of frustration for the children and their parents. The vomiting frequency might not change with a gastrostomy, but the ease in nutritional support that comes with it often compensates for the vomiting. Preoperative information to the parents about our experience for their understanding of eventual future complications is a keystone for a successful postoperative result.

Conclusion

Vomiting, observed preoperatively, persisted six months postoperatively in 78 % of the patients; its cause is most likely to be found in the children's underlying diagnosis and not the VAG procedure.

Neurologically impaired children had a higher incidence of vomiting than those with other diagnoses.

These conclusions can be useful information for parents and colleagues when counselling before a VAG operation.

Acknowledgements to:

Gillian Sjö Dahl, Lexis English for Writers, Lund Sweden, for linguistic revision of the manuscript.

Fredrik Nilsson, biostatistician of the Competence Centre for Clinical Research, Skåne University Hospital, Lund, Sweden, for statistical advice

References

- Gauderer MW, Ponsky JL, Izant RJ (1980) Gastrostomy without laparotomy: a percutaneous endoscopic technique. *J Pediatric Surg* 15(6):872-875 (ISBN 10: 0340813407; ISBN 13: 9780340813409)
- Khatak IU, Kimber C, Kiely EM, et al: Percutaneous endoscopic gastrostomy in pediatric practice: Complications and outcome. *J Pediatr Surg* 33:67-72, 1998
- Lantz M, Hultin Larsson H, Arnbjörnsson E. Literature review comparing laparoscopic and percutaneous endoscopic gastrostomies in a pediatric population. *Int J Pediatr*. 2010;2010:507616
- B Akay, T R Capizzani, A M Lee, R A Drongoowski, J D Geiger, R B Hirschl, G B Gastrstostomy tube placement in infants and children: is there a preferred technique? *J Pediatr Surg* (2010) 45, 1147-1152
- V.S Jones, E.R La Hei, A Shun Laparoscopic gastrostomy: the preferred method of gastrostomy in children, *Pediatr Surg Int* (2007) 23:1085-1089
- Andersson L, Mikaelsson C, Arnbjörnsson E et al. Laparoscopy aided gastrostomy in children. *Ann Chir Gynaecol* 1997; 86: 19-22
- Arnbjörnsson E, Backman T, Morse H et al. Complications of videoassisted gastrostomy in children with malignancies or neurological diseases. *Acta Pediatr* 2006; 95: 467-470
- Arnbjörnsson E, Larsson LT, Lindhagen T. Complications of laparoscopy aided gastrostomies in pediatric practice. *J Pediatr Surg* 1999; 34: 1843-1846
- Backman T, Arnbjörnsson E, Berglund Y et al. Video-assisted gastrostomy in infants less than 1 year. *Pediatr Surg Int* 2006; 22: 243-246
- Hegar B, Vandenplas Y. Gastroesophageal reflux: natural evolution, diagnostic approach and treatment. *The Turkish Journal of Pediatrics* 2013;55:1-7

- Vandenplas Y, Rudolph CD, Di Lorenzo C et al. (2009) Pediatric gastroesophageal reflux clinical practice guidelines: joint recommendations of the North American Society for Pediatric Gastroenterology, Hepatology and Nutrition (NASPGHAN) and the European Society for Pediatric Gastroenterology, Hepatology, and Nutrition (ESPGHAN). *J Pediatr Gastroenterol Nutr* 49(4):498-547
- Sherman PM et al (2009). A global, evidence-based consensus on the definition of gastroesophageal reflux disease in the pediatric population. *Am J Gastroenterol*. 2009 May;104(5):1278-95;quiz 1296.doi: 10.1038/ajg.2009.129.Epub 2009 Apr 7. Review.
- Plantin I, Arnbjörnsson E, Larsson LT. No increase in gastroesophageal reflux after laparoscopic gastrostomy in children. *Pediatric Surg Int*. 2006 Jul; 22(7):581-4. Epub 2006 Jun 1. PubMed PMID: 16807719
- Noble LJ, Dalzell AM, El-Matary W. The relationship between percutaneous gastrostomy and gastroesophageal reflux disease in children: a systematic review. *Surg Endosc*. 2012 Mar 22. (Epub ahead of print)
- Backman T, Sjöwie H, Kullendorff CM, Arnbjörnsson E. Continuous double U-stitch gastrostomy children. *Eur J Pediatric Surg*. 2009 Oct 14

Table 1. The demographic data of the 180 children included in the study. All figures are given in median and (range)

Age (years)	1(1 month – 14 years)
Weight (kg)	9 (3 – 41)
Length (cm)	75 (36 – 162)
BMI (kg / m ²)	15 (11 – 22)

Table 2 The summarized diagnoses of the 180 children in the study

Diagnosis	N
Cerebral pares	61
Cardiac malformation	30
Metabolic disease	37
GI malformations	7
Malignancy	11
Respiratory insufficiency	15
Syndrome	19
Sum	180

Table 3. Minor complications found at prospective follow-up in 180 patients operated on with the VAG technique. Statistical method: Fisher’s exact t-test.

Minor complications	1 month	6 month	P-value
Vomiting	51 (28%)	40 (22%)	0.148
Granulation tissue	49 (27%)	24 (13%)	0.002
Infection	36 (20%)	5 (3%)	0.001
Infection treated with antibiotics	26 (14%)	4 (2%)	0.001
Leakage	26 (14%)	6 (3%)	0.002
Tube dislodgement	8 (4%)	10 (6%)	0.809

Table 4. Vomiting pre- and postoperatively after operation using the VAG technique in 180 children

Vomiting pre-op	Vomiting post-op		
		1 month	6 months
N =180			
Yes 51	Yes	43	40
	No	8	11
No 129	Yes	2	14
	No	127	115

Table 5. The diagnosis of the included 180 patients and their vomiting frequency pre- and postoperatively at study endpoint at 6 months. The children had comorbidity in the form of epilepsy in 27 (17%), ventricular-peritoneal shunt in 9 patients (5%) and mitochondrial disease in 6 patients (4%)

Diagnosis	N	%	Vomiting pre-op	%	Vomiting postop	%
Cerebral pares	61	34	12	24	14	35
Cardiac malformation	30	17	11	22	7	18
Metabolic disease	37	21	10	20	5	13
GI malformations	7	4	2	4	1	3
Malignancy	11	6	2	4	2	5
Respiratory insufficiency	15	8	7	14	6	15
Syndrome	19	10	7	14	5	13
Sum	180	100	51	100	40	100
P-value			P=0.0152		P=0.0049	

