



LUND UNIVERSITY

Enhancing bone healing through concurrent anabolic- and anti-catabolic pharmacological treatment

Bosemark, Per

2014

[Link to publication](#)

Citation for published version (APA):

Bosemark, P. (2014). *Enhancing bone healing through concurrent anabolic- and anti-catabolic pharmacological treatment*. [Doctoral Thesis (compilation), Orthopaedics (Lund)]. Department of Orthopaedics, Lund University.

Total number of authors:

1

General rights

Unless other specific re-use rights are stated the following general rights apply:

Copyright and moral rights for the publications made accessible in the public portal are retained by the authors and/or other copyright owners and it is a condition of accessing publications that users recognise and abide by the legal requirements associated with these rights.

- Users may download and print one copy of any publication from the public portal for the purpose of private study or research.
- You may not further distribute the material or use it for any profit-making activity or commercial gain
- You may freely distribute the URL identifying the publication in the public portal

Read more about Creative commons licenses: <https://creativecommons.org/licenses/>

Take down policy

If you believe that this document breaches copyright please contact us providing details, and we will remove access to the work immediately and investigate your claim.

LUND UNIVERSITY

PO Box 117
221 00 Lund
+46 46-222 00 00

Enhancing bone healing through concurrent anabolic- and anti- catabolic pharmacological treatment

Per Bosemark



LUND
UNIVERSITY

DOCTORAL DISSERTATION

by due permission of the Faculty of Medicine, Lund University, Sweden.

To be defended in the lecture hall of the department of Radiotherapy, 3rd floor,
Klinikgatan 5, Skånes universitetssjukhus, Lund.

Friday September 26th 9 am.

Faculty opponent

Prof. Sune Larsson

Akademiska sjukhuset, Uppsala University Hospital

Organization: LUND UNIVERSITY Dept. of Orthopaedics, Clinical Sciences, Lund Lund University, Sweden Author Per Bosemark		Document name: DOCTORAL DISSERTATION Date of issue: 2014-09-26 Sponsoring organization:	
Title: Enhancing bone healing through concurrent anabolic- and anti-catabolic pharmacological treatment			
Abstract <p>Most fractures heal uneventfully but some evolve into nonunions. Autologous bone graft is the gold standard for stimulating healing. However, donor site morbidity, and limited graft supply make alternatives interesting. Bone Morphogenetic Proteins, BMPs, are growth factors involved in bone signaling. They are available in recombinant form for local application in nonunions and stimulate differentiation and proliferation of osteoblasts. However, BMPs also induce osteoclastic activation, which can lead to callus resorption. In this thesis, we hypothesized that concurrent treatment with the bisphosphonate zoledronate (ZOL) could counteract this resorption, leading to superior healing compared to isolated BMP-7 treatment. In studies 1, 2 and 3, the synergistic effect of BMP-7 and zoledronate was investigated in a rat femoral osteotomy model, that untreated is known to heal in only 60 %.</p> <p>In study 1, autograft was compared with autograft+BMP-7 and autograft+BMP-7+ZOL with the hypothesis that the latter treatment would lead to superior healing compared with the others. All three treatments increased the healing rate from 60 % to 100 %. The autograft group reached half the strength compared with the non-operated controls, while the autograft+BMP-7 and the autograft+BMP-7+ZOL equaled and doubled the strength of the controls respectively.</p> <p>In study 2, we investigated if allograft+BMP can replace autograft. Allograft and different combinations of allograft, BMP-7 and ZOL were compared with; no treatment, autograft and autograft+ZOL with the hypothesis that allograft+BMP-7+ZOL would lead to superior union compared with autograft. Allograft+BMP-7+ZOL-treatment yielded a substantially higher peak force than all other groups.</p> <p>In study 3, we investigated if the testing method influenced the results of the mechanical tests. BMP-7 and BMP-7+ZOL were compared with controls and each other. Calluses were tested both in three-point bending and twisting. All femurs healed. BMP-7+ZOL-treatment led to higher ultimate force and greater stiffness than BMP-7 alone. This difference was most evident in the three-point bending test</p> <p>In study 4, the Masquelet induced membrane technique, was used to study the healing of a 6 mm rat femoral critical size defect. A synthetic scaffold was compared with BMP-7, BMP-7+scaffold and BMP-7+scaffold+ZOL. We found the combination of BMP-7+scaffold+ZOL to be superior to the other treatments.</p> <p>In conclusion we could show a synergistic effect by concurrent treatment with BMP-7 and zoledronate in all four studies. This supports the use of the combination, either alone or as a supplement to autograft, allograft or synthetic scaffold in both nonunions and bone defects.</p>			
Key words: autograft, BMP, bisphosphonate, nonunion, Masquelet			
Classification system and/or index terms (if any):			
Supplementary bibliographical information:		Language: English	
ISSN and key title: 1652-8220		ISBN: 978-91-7619-033-3	
Recipient's notes:		Number of pages:	Price:
		Security classification:	

I, the undersigned, being the copyright owner of the abstract of the above-mentioned dissertation, hereby grant to all reference sources permission to publish and disseminate the abstract of the above-mentioned dissertation.

Signature _____ Date 2014-07-08

Enhancing bone healing through concurrent anabolic- and anti- catabolic pharmacological treatment

Per Bøsemark



LUND
UNIVERSITY

Contact address

Per Bosemark, MD

Department of Orthopaedics,

Skåne University Hospital

Lund, Sweden

Tel: +46 46 171000

Mail: per.bosemark@med.lu.se

Copyright © Per Bosemark

Cover illustration by Magnus Tägil

Lund University, Faculty of Medicine Doctoral Dissertation Series 2014:104

ISBN 978-91-7619-033-3

ISSN 1652-8220

Printed in Sweden by Media-Tryck, Lund University

Lund 2014



“...there is danger inherent in the mechanical efficiency of our modern methods, lest the craftsman forget that union cannot be imposed but may have to be encouraged, for a bone is a plant with its roots in the soft tissues. When the vascular connections are damaged, it often requires not the technique of a cabinet maker but rather the patient care and understanding of a gardener.”

Gathorne Robert Girdlestone

Contents

List of papers	7
Abbreviations	9
Introduction	11
Hypotheses	17
Bone biology	19
Fracture healing	23
Bone grafts and bone substitutes	27
Bone active drugs	29
Materials and methods	33
Results	41
Discussion	45
Conclusions	53
Summary in English	55
Sammanfattning på svenska	59
Acknowledgements	65
References	67

List of papers

1. Bosemark P, Isaksson H, McDonald MM, Little DG, Tägil M.

Augmentation of autologous bone graft by a combination of bone morphogenic protein and bisphosphonate increased both callus volume and strength.

Acta Orthop. 2013 Feb;84(1):106-11

2. Mathavan N, Bosemark P, Isaksson H, Tägil M.

Investigating the synergistic efficacy of BMP-7 and zoledronate on bone allografts using an open rat osteotomy model.

Bone. 2013 Oct;56(2):440-8

3. Bosemark P, Isaksson H, Tägil, M.

Influence of systemic bisphosphonate treatment on mechanical properties of BMP-induced calluses in a rat fracture model: Comparison of three-point bending and twisting test.

J Orthop Res. 2014 May;32(5):721-6

4. Bosemark P, Perdikouri C, Pelkonen M, Isaksson H, Tägil M.

The Masquelet induced membrane technique with BMP and a synthetic scaffold can heal a rat femoral critical size defect.

Submitted June 2014.

Abbreviations

ABG	autologous bone graft
AP-plane	anteroposterior plane
ATP	adenosine triphosphate
BMD	bone mineral density
BMP	bone morphogenetic protein
BP	bisphosphonate
BV_{high}	volume of highly mineralized bone
BV_{high}/TV_c	bone volume fraction
BV_{low}	volume of lowly mineralized bone
CMC	carboxymethyl cellulose
CT	cartilaginous tissue
DBM	demineralized bone matrix
ECM	extra cellular matrix
EDTA	ethylenediaminetetraacetic acid
FDA	Food and Drug Administration
FPPS	farnesyl pyrophosphate synthase
FT	fibrous tissue
FTIR	Fourier transform infrared
HIV	human immunodeficiency virus
IB	immature bone
IGF	insulin-like growth factor
IL	interleukin
K-wire	Kirschner wire
LMTA	low melting temperature alloy

MSC	mesenchymal stem cell
N	newton
NSAID	non-steroidal anti-inflammatory drug
OPG	osteoprotegerin
PBS	phosphate-buffered saline
PMMA	polymethyl methacrylate
PTH	parathyroid hormone
RANK	receptor activator of nuclear factor kappa β
RANKL	receptor activator of nuclear factor kappa β ligand
rhBMP	recombinant human bone morphogenetic protein
RIA	reamer irrigator aspirator
ROI	region of interest
TGF- β	transforming growth factor β
TMD	tissue mineral density
TV _c	total callus volume
ZA	zoledronic acid
ZOL	zoledronic acid
μ CT	micro-computed tomography
2D	two dimensional
3D	three dimensional

Introduction

Fractures are common in all age groups but are a heterogeneous entity; ranging from simple benign low energy fractures treatable by splinting, to complex high energy compound fractures requiring multiple surgeries. The last couple of decades have seen the introduction of many novel concepts, products and techniques for fracture fixation. However, new plating- and nailing systems are not a panacea. The importance of the local fracture environment and the soft tissue envelope are today well known. Indirect reduction techniques (Mast et al., 1988), low contact plates and limited incisions (Farouk et al., 1999) are today all used in an attempt to preserve local fracture biology.

Even with today's best practice of care, approximately 5-10 % of fractures fail to heal (Tzioupis and Giannoudis, 2007). This can be due to many different factors, both patient related and fracture related (Calori et al., 2007, Perumal and Roberts, 2007). Irrespective of which, a nonunion is problematic for the patient and a burden for the health care system and society. Nonunions are often multifactorial (Calori et al., 2008). Conceptually, the underlying cause can be stability related, biology related or often both. In cases where lack of fracture stability seems to be the major cause of the problem, this has to be addressed. On the other hand, if poor biologic conditions are believed to be paramount this should be corrected. Malnutrition and certain medications e.g. NSAIDs, corticosteroids etc. are systemic causes of poor local fracture biology and can be corrected by nutritional supplements and cessation of medication. If the problem is compromised local biology at the fracture site as in open fractures or after extensive surgical approaches, the classic treatment is bone grafting. Autologous bone graft (ABG) remains the gold standard (Flierl et al., 2013) as this is osteogenic, i.e. has the ability to form bone independently. However, allograft, demineralized bone matrix (DBM), and different compounds of synthetic bone and growth factors are also used, either in isolation or as supplements to the autologous bone graft (Gazdag et al., 1995). Traditionally ABG has been harvested from the iliac crest. This however has certain limitations. It is associated with significant donor site morbidity in terms of pain, infection and even iatrogenic fracture (Arrington et al., 1996, Conway 2010, Dimitriou et al., 2011). Iliac crest bone graft harvest prolongs theatre time, the amount of available graft is limited and the biologic activity of the mesenchymal stem cells in the graft decrease with age and systemic disease. New techniques for harvesting ABG have evolved but it is still not without complications (Conway 2010, Dimitriou et al., 2011). The use of allograft is

complicated by the fear for disease transmission (HIV, hepatitis) (Palmer et al., 1999). Also, allograft has very limited, if any osteoinductive capabilities and should be seen as an osteoconductive scaffold. Despite the use of ABG, nonunion sometimes persists and alternative ways to stimulate the local fracture biology have been investigated. In 1965 Urist discovered a group of proteins that would later be referred to as Bone Morphogenetic Proteins (BMPs) (Urist, 1965). They constitute a heterogeneous group (Urist and Strates, 1971, Wozney and Rosen, 1998, Sykaras and Opperman, 2003) and today 20 different BMPs are known. Not all of them are in fact involved in bone signaling. BMP-2 and BMP-7 are potent bone anabolic proteins and are available in human recombinant form. They have been approved by the US Food and Drug Administration, (FDA) for clinical use in open tibial shaft fractures, recalcitrant nonunions of the long bones and in spinal fusion. However, no clinical study has been able to show BMP superior to ABG in promoting fracture healing. Bisphosphonates are a group of drugs that target osteoclasts, rendering them apoptotic (Russel et al., 2008, Rogers et al., 2011). They are thus anticatabolics.

Fracture healing is a complex process that depends on an intricate interplay between different cells and factors. Simply speaking, one can view successful fracture healing as an equilibrium between anabolic and catabolic drives (Little et al., 2007). Greater understanding of these pathways and how to regulate them separately has made it possible to pharmacologically modulate fracture repair. Anabolic agents such as BMPs can be used to increase anabolism, and anti-catabolics such as bisphosphonates can be used to counteract undesired catabolism. The commercially available BMPs, in addition to being bone anabolic, have also been shown to induce osteoclastic bone resorption (Kanatani et al., 1995, Itoh et al., 2001 Giannoudis et al., 2007). This is an obvious disadvantage in clinical practice when treating nonunions where an isolated anabolic drive is sought. In light of this, the combination of an anabolic BMP and an anti-catabolic bisphosphonate seems attractive (Doi et al., 2011, Yu et al., 2012, Bosemark et al., 2013, Mathavan et al., 2013).

Bone defects pose an even greater challenge than nonunions. Bone defects can be secondary to trauma, or resections due to infection or tumor. Smaller defects up to five centimeters with adequate soft tissue envelope and vascularity can often be successfully managed by cancellous autologous bone grafting. Larger defects, however, usually do not heal without further intervention. Vascularized fibular grafting or bone transport can both be used to manage large defects (Lasanianos et al., 2009). An alternative to this is the so called induced membrane technique, introduced by Masquelet (Masquelet and Begue, 2010, Giannoudis et al., 2011, Karger et al., 2012). This is a staged procedure. During the first procedure necrotic bone is removed, the defect filled with a polymethylmetacrylate cement spacer and the bone stabilized by spanning the defect with either a nail or a plate. The cement spacer has several objectives. It stabilizes the fracture, helps combat infection

locally through the release of antibiotics, hinders fibrous ingrowth and importantly acts as a foreign body, inducing the formation of a vascularized pseudo-membrane. The membrane has been shown to express a host of different growth factors involved in fracture healing (Pelissier et al., 2004, Gruber et al., 2013). After six to eight weeks the membrane is carefully incised, the cement spacer removed piecemeal and the membranous tube grafted (Masquelet and Begue, 2010, Karger et al., 2012). Typically cancellous ABG is used. The results when using this technique are generally good with a reported healing rate of 90% (Karger et al., 2012). However, it would be advantageous if the ABG could be replaced with a combination of synthetic bone substitute scaffold and a bone anabolic drug, obviating the need for bone harvest. This would have many benefits such as shorter theatre time and no bone harvest associated donor site morbidity.

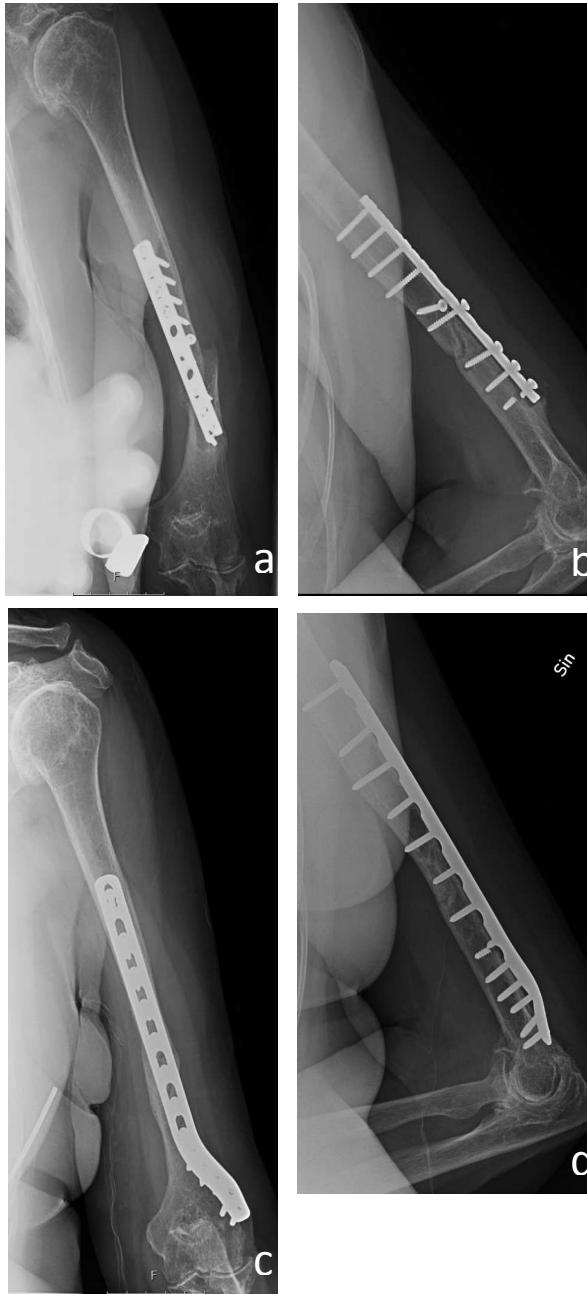


Figure 1 a-d: Atrophic nonunion following plate osteosynthesis in a patient with rheumatoid disease. a & b) Anteroposterior and lateral radiographs showing displaced fracture and broken screw. c & d) Anteroposterior and lateral radiographs showing healed fracture after revision surgery with compression plating and autologous bone grafting.

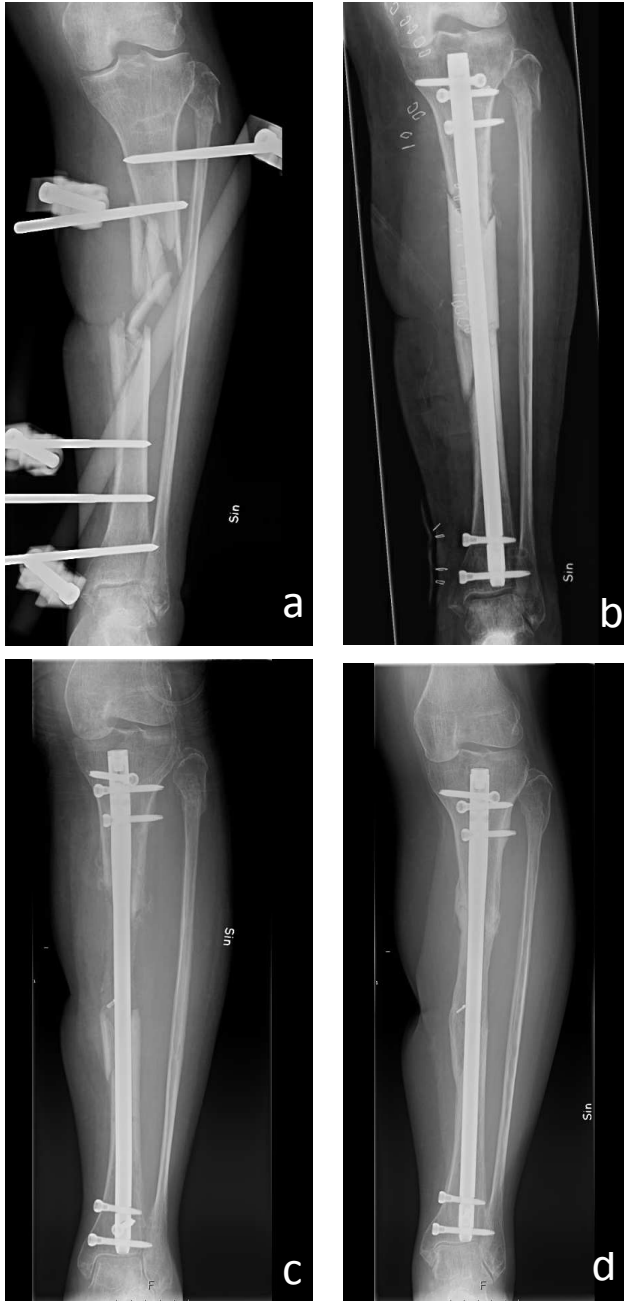


Figure 2 a-d: Severely comminuted grade III B open tibial shaft fracture treated with the Masquelet induced membrane technique. a) After initial external fixation, b) After debridement of avascular fracture fragments, nailing and cement spacer implantation. c) After spacer removal and autologous bone grafting into membranous tube. d) Healed fracture eight months after bone grafting.

Hypotheses

The hypotheses below are investigated in the four studies of this thesis respectively:

1. The combined treatment of autologous bone graft, BMP-7 and the bisphosphonate zoledronate may lead to stronger union than treatment with autologous bone graft and BMP-7 or autologous bone graft alone.
2. The combined treatment of allograft, BMP-7 and the bisphosphonate zoledronate may lead to stronger union than autologous bone graft.
3. The combined treatment of BMP-7 and the bisphosphonate zoledronate may lead to stronger union than BMP-7 alone. Secondly, the influence of the mechanical testing modality is investigated with the hypothesis that the increased callus diameter induced by BMP-7-treatment alone and the increased callus diameter and density induced by BMP-7 +bisphosphonate treatment, provide different resistance to breaking when tested in bending or twisting.
4. The combination of tricalcium phosphate hydroxyapatite scaffold, BMP-7 and zoledronate, is hypothesized to be superior to BMP-7 alone, tricalcium phosphate hydroxyapatite scaffold alone or the combination of the two in a rat Masquelet model.

Bone biology

Composition of normal bone

Bone has optimized its mechanical strength while minimizing its mass. Thus, for the mass it has a high resistance to fracture. It is not inert but a dynamic tissue responding to environmental stimuli. It has the unique ability to heal without scarring and remodels throughout life (Proff and Römer, 2009). Bone is made up of extracellular matrix (ECM) and cells. The ECM is a composite material of mineral, protein, water, salts, lipids, glycoproteins and proteoglycans. The osteoblasts produce the ECM. In mature bone, 60-70 % of the ECM is mineralized with calcium phosphate and hydroxyapatite. The organic part of the matrix (20-25 %) is composed of mainly collagen type I. The remaining volume is water. BMPs and other growth factors, such as transforming growth factor-beta (TGF- β), insulin-like growth factor, (IGF), interleukins (IL-1, IL-6) are incorporated into the mineralized matrix (Miller et al., 2007). Osteocytes, osteoblasts, osteoclasts and bone lining cells are found on and within the bone matrix and are responsible for its synthesis and degradation. Within the bone and in its vicinity, several other cell types are found. Certain marrow stromal cells are osteoprogenitor cells, which can differentiate into osteoblasts. Hematopoietic stem cells found in the bone marrow are osteoclast precursors.

Cell types

Osteoblasts are derived from mesenchymal stem cells residing in the marrow. These cells are called marrow stromal cells and can give rise to different mesenchymally derived cells such as osteoblasts, fibroblasts, chondrocytes, adipocytes and myocytes and are therefore also called mesenchymal stem cells (MSCs). BMPs are thought to play an important role in osteoblastic differentiation. A cell committed to osteoblastic differentiation is termed an osteoprogenitor cell. Further differentiation under the influence of various growth factors results in a mature osteoblast capable of producing osteoid matrix (Miller et al., 2007). During the differentiation process the location of the cells change. The immature stromal cells that are located in the marrow migrate towards the surface of the bone as they differentiate to become mature osteoblasts. During the differentiation, the proliferative capacity of the cells decline and mature

osteoblasts do not divide. Mature osteoblasts produce osteoid in response to hormonal and mechanical factors and have a half-life of around 100 days. After this active period they can transform into bone lining cells and remain on the bone surface or become embedded in the ECM as osteocytes. They can also die by apoptosis.

Bone lining cells: As previously mentioned some osteoblasts evolve into bone lining cells. At any given time, all bone surfaces are lined with cells. The cell type depends on the metabolic state of the bone. Most bone surfaces are not metabolically active and are covered by the resting bone lining cells. However, in areas of active bone formation, osteoblasts reside side by side on the surface. In areas of bone resorption, osteoclasts line the surface. The bone lining cells are flat and have lost the metabolic activity of their osteoblastic precursors. Their function is not known but they might have the ability to be “reactivated” to again function as osteoblasts. They might also block osteoclastic resorption by physically covering the bone. During remodeling they may play a role through cleansing of the osteoclastic resorption pits so that new bone can be laid down (Miller et al., 2007).

Osteocytes: About a third of osteoblasts will ultimately become embedded in the mineralizing matrix as osteocytes. They are the most numerous bone cells. They can live for decades and are found in the lacunar spaces of the mineralized matrix of both trabecular and cortical bone. In contrast to osteoblasts, they are not highly metabolically active but produce small amounts of matrix proteins. The osteocyte cell body is smaller than that of an osteoblast and displays abundant small cell processes that traverse the bone within the canaliculi. These cell processes resemble neural dendrites. The osteocytes are interconnected by, and signal through these processes. Thus, every osteocyte is connected to a network of neighboring cells. This elaborate network includes the bone lining cells and osteoblasts on the bone surface as well as cells within the marrow. The function of the osteocytes are not known fully, but they are known to play a role in mechanosensing (Miller et al., 2007, Nakamura, 2007) with the intracellular canaliculi lattices that are well suited to monitor mechanical strain and respond to damage to the matrix.

Bone resorption is mediated through osteoclasts, cells closely related to macrophages that arise from hematopoietic precursors and develop through an ordered differentiation process. They are found on the bone surface where they resorb mineralized bone. Precursors come from the marrow space itself or from the circulation via marrow capillaries. Mononuclear “preosteoclasts” fuse to ultimately form the mature, multinucleated osteoclasts. Osteoclasts are very large cells with up to 20 nuclei. Their cytoplasm contains many mitochondria and lysosomes with degradative enzymes. On the cell surface osteoclasts exhibit receptor activator of nuclear factor-kappa β (RANK) that plays an important role in the activation of osteoclasts (Nakamura, 2007, Proff and Römer, 2009) this will be

described in detail in the next section. Osteoclasts are polarized cells with a ruffled border at the cell-bone interface, and with a functional secretory domain at the opposite end. During bone resorption, the osteoclasts adhere to the bone surface through a “sealing zone” that surrounds the ruffled border and carbonic acid and degradative enzymes are secreted through the basal membrane into the resultant confined space. The ruffled border increases the surface area of the basal membrane in contact with the bone, thereby making resorption more effective. Bone resorption releases matrix residues and calcium and phosphate ions into the resorption space, where they are subsequently transported across the basal membrane through endocytosis. They are then either degraded in the intracellular lysosomes or transported to the apical cell membrane for release into the extracellular space. Osteoclasts have a half-life of around 10 days (Miller et al., 2007, Nakamura, 2007).

Fracture healing

Conceptually, fracture healing can be divided into four stages; inflammation, soft callus formation, hard callus formation and remodeling. This model implies a certain temporal distribution of events. However, there is considerable overlap between these stages during fracture healing (Schindeler et al., 2008).

Stage 1, inflammation: Bony injury is accompanied by some degree of soft tissue disruption. This results in activation of non-specific healing pathways. Macrophages, degranulating platelets, and other inflammatory cells within the fracture hematoma clear dead cells, secrete growth factors and cytokines and promote clotting. Various growth factors and cytokines, including TGF- β , IL-1, IL-6 and BMPs are responsible for this initial response. These factors stimulate migration and invasion of multipotent mesenchymal stem cells into the fracture hematoma. These mesenchymal stem cells can be recruited from the bone marrow, periosteum, circulation or soft tissues.

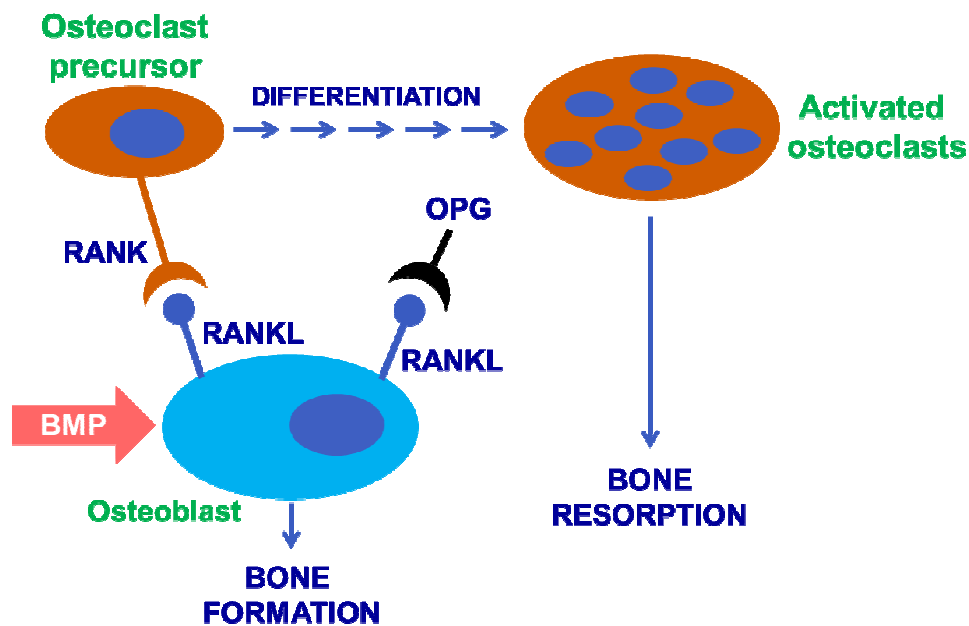
Stage 2, soft callus formation: Except for cases of absolute stability, a cartilaginous template precedes bony callus formation during fracture healing. This is called endochondral ossification. Chondrocytes and fibroblasts proliferate and differentiate in response to different growth factors and form a soft callus. Finally, before becoming apoptotic, the chondrocytes hypertrophy and mineralize the cartilaginous matrix that is later vascularized.

Stage 3, hard callus formation: Mesenchymal stem cells from different sources differentiate into osteoprogenitor cells that subsequently proliferate and differentiate into osteoblasts. BMPs play a critical role in this process. The initial soft callus is gradually removed. This is not believed to be an osteoclast mediated process, but rather the result of a more non-specific catabolism, possibly mediated by matrix metalloproteases (Colnot et al., 2003, Behnonick et al., 2007). The soft callus is then replaced by immature hard callus by the osteoblasts. This initial bone matrix is woven and contains both protein and mineral.

Stage 4, remodeling: The last stage of fracture healing is a coupled process (McDonald et al., 2008). This implies a strictly regulated relationship between catabolism and anabolism to recreate the pre-fracture architecture of the bone. Osteoclasts resorb woven immature bone, which is replaced with mature lamellar bone by osteoblasts. Remodeling is usually associated with a volume reduction of the callus but due to a more optimized tissue orientation, callus strength is

maintained. Osteoblasts and bone lining cells can regulate osteoclast proliferation and activity through cytokine secretion. Macrophage colony stimulating factor, (M-CSF) secreted from the osteoblast plays a role in the differentiation of the hematopoietic stem cell towards the osteoclast lineage. Receptor activator of nuclear factor kappa β ligand, (RANKL), is produced by mature osteoblasts and controls the coordination of bone resorption and bone formation i.e. coupling. Osteoclasts and osteoclast progenitors display the receptor RANK on their surface. If they bind to RANKL on the osteoblast surface they fuse and become activated osteoclasts. Osteoblasts and bone lining cells also produce Osteoprotegerin (OPG) that acts as a decoy receptor for RANKL, inhibiting osteoclastic differentiation (Boyce and Xing, 2007, Nakamura, 2007).

Figure 3: BMP-induced RANKL-RANK mediated osteoclastic activation.



It is interesting to note however, that although remodeling takes place both during the transition of soft callus to hard callus and during ultimate remodeling of hard callus the two events do not seem to be the result of the same process. Soft callus remodeling has been shown to be an osteoclast independent activity (Flick et al., 2003, Delos et al., 2008). On the other hand, osteoclast antagonists such as bisphosphonates delay ultimate remodeling during fracture repair (McDonald et

al., 2008) indicating that this indeed is an osteoclast dependent process (Colnot et al., 2003).

Nonunion

Approximately 5-10 % of all long bone fractures develop a nonunion (Tzioupis and Giannoudis, 2007). The FDA has defined a nonunion as a fracture that is more than 9 months old and that has not shown radiographic signs of progression toward healing for 3 consecutive months. A nonunion is a serious complication that frequently leads to decreased limb function secondary to joint stiffness, muscle wasting and disuse osteopenia. An infected nonunion is a particularly difficult problem.

There are several risk factors for developing a nonunion (Calori et al., 2007, Perumal and Roberts, 2007). These can broadly be categorized as being fracture related or patient related. Fracture related risk factors include high-energy compound fractures with periosteal stripping and bone loss, segmental fractures, extensive surgical approaches, deep infection and poor or inadequate fixation. Patient related risk factors include advanced age, poor nutritional status, smoking, alcohol abuse, diabetes, chronic disease and certain medications e.g. NSAIDs and corticosteroids. Often a nonunion is multifactorial and multiple issues have to be addressed in order to bring about union. Classically, based on radiographic findings, nonunions have been divided into atrophic and hypertrophic nonunions (Frölke and Patka, 2007). This is solely a descriptive classification and does not implicate the underlying cause. Further, combinations of the two obviously exist. Atrophic nonunions are due to poor biology and lack callus on radiographs. Hypertrophic nonunions are due to excessive motion at the fracture site and display large amounts of callus on radiographs but the callus is not bridging the fracture. Atrophic nonunions are typically treated with ABG. Hypertrophic nonunions lack stability and are typically treated with rigid internal fixation with compression across the fracture if possible. One can also view nonunion as a result of derangement to the balance of anabolism and catabolism normally present in healing bone. This paradigm makes pharmacological modulation of fracture healing interesting. Anabolic drugs can be used to fuel poor intrinsic anabolism and anti-catabolic drugs can be used to counteract unwanted catabolism (Little et al., 2005, Little et al., 2007, Doi et al., 2011).

Bone grafts and bone substitutes

When discussing bone grafts and bone substitutes, the definitions of osteogenesis, osteoinduction and osteoconduction must be clear as well as the abilities and limitations of the different grafts and substitutes (Greenwald et al., 2006).

Graft osteogenesis: De novo synthesis of bone at recipient site through living cellular elements in donor graft (Flierl et al., 2013). Only ABG is capable of this.

Graft osteoinduction: Bone formation at the recipient site through active recruitment, proliferation and differentiation of host mesenchymal stem cells and osteoprogenitor cells, which differentiate into osteoblasts (Goldberg, 2000). This process is facilitated by growth factors in the graft, mainly BMPs.

Graft osteoconduction: Facilitation of blood vessel ingrowth and new bone formation into a passive scaffold (Goldberg, 2000). Allograft and different synthetic bone substitutes such as calcium phosphates are osteoconductive.

Bone grafts

ABG is the benchmark for bone grafting in nonunion surgery. Although ABG has the ability to support new bone growth by osteogenesis, osteoinduction and osteoconduction its use has certain limitations. Classically, cancellous ABG has been harvested from the iliac crest. This is associated with a relatively high incidence of complications and donor site morbidity (Arrington et al., 1996, Conway, 2010, Dimitriou et al., 2011). Furthermore the amount of obtainable graft from the iliac wing is limited. The Reamer Irrigator Aspirator system, RIA, (Synthes, Davos, Switzerland) offers an alternative method for ABG harvest (Newman et al., 2008). This system makes it possible to harvest bone from the intramedullary canal of the long bones. The reamer is flushed with saline, and concomitant suctioning collects the reamed material in a bag. Using this system one can harvest more graft than from the iliac crest and the reported donor site morbidity is lower than that for iliac crest graft harvest although it is not without its specific dangers (Dimitriou et al., 2011). Thus, investing alternatives to ABG is of high interest.

Cancellous allograft has the advantage of being readily available in larger quantities and not being associated with donor site morbidity. There is, however

concern about possible disease transmission (Palmer et al., 1999). This risk could be eliminated by sterilization and processing of the graft but aggressive processing can further blunt the already weak osteoinductive properties of allograft. Allograft should be considered predominantly osteoconductive and to a lesser degree osteoinductive. Commercially available demineralized bone grafts have some osteoinductive properties and are easy to use due to their putty like formula.

Synthetic bone substitutes

An ideal bone substitute should be biocompatible, undergo remodeling and support new bone formation. It should also have mechanical strength similar to that of the native bone it replaces and final material properties that mimic bone to prevent long term stress shielding and stress fracture formation under cyclic loading.

Various calcium compounds have some of these properties. Many modern bone substitutes are composed of beta tricalcium phosphate or a mixture of beta tricalcium phosphate and hydroxyapatite. They are often used in granular porous form or blocks or as an injectable paste that sets at body temperature. Beta tricalcium phosphate undergoes resorption over a 6-18 month period. The resorption rate for hydroxyapatite is very slow, being 1 to 2 % per year. It is commonly used as a bone graft extender.

Bone active drugs

BMPs

In 1965, Urist in his pivotal paper “Bone: Formation by autoinduction” showed that an a-cellular, devitalized decalcified bone matrix had the ability to stimulate bone production when implanted into a host tissue (Urist, 1965). The article was the result of some 70 experiments using both bone from laboratory animals and samples of human cortical bone. The bone samples were treated in different ways to alter chemically reactive groups in the matrix. This included decalcification by various means and also alcohol fixation, heat shrinkage and denaturation. The decalcified bone matrix was implanted either intramuscularly at different sites, in an ulnar defect in rats or between lumbar vertebrae in dogs. He found that the implanted matrix was resorbed and that new bone was deposited by osteoprogenitor cells. He also noted the presence of stem cells and ingrowth of small capillaries. Urist hypothesized that nonspecific substances or degradation products of dead tissue stimulated histiocytes to migrate to the implanted matrix tissue. He called this autoinduction. He also postulated that the new osteoblasts were derived from pluripotent cells of the host and not from the donor tissue (matrix). Urist later coined the name “Bone Morphogenetic Protein” (Urist and Strates, 1971). In the seventies and the eighties BMPs were extracted and purified from bone of different animal species as well as humans. However, this was severely limited by its low yield process. This prompted the development of recombinant BMP production. Today rhBMP-2 and rhBMP-7 are commercially available and approved for use in spinal fusion, open fractures and recalcitrant nonunions. BMPs are soluble, local acting signaling proteins. Today, at least 20 BMPs have been isolated (Alaoui-Ismaili and Falb, 2009). With the exception of BMP-1, they all belong to the Transforming Growth Factor- β (TGF- β) superfamily (Wozney and Rosen, 1998). BMPs are involved in a multitude of cellular events throughout the body. Most but not all, have functions in bone- and/or cartilage signaling. Their target cells are mesenchymal progenitor cells and they exert their effect through binding to transmembrane, serine-threonine kinase receptors on the cell surfaces (Sykaras and Opperman, 2003). The BMP-ligand binds to a type II receptor which recruits and phosphorylates a type I receptor. The receptor type I then itself phosphorylates, intracellular receptor regulated proteins called SMADS. Two R-SMADS bind one co-SMAD and the resultant complex translocates into the nucleus where it acts as a transcription factor and participates

in the regulation of target gene expression of proteins such as Runt-related transcription factor 2 (Runx2) and Osterix that are both key factors in osteoblast differentiation.

BMPs are mainly active as local agents. The clinical utilization of their osteoinductive effect requires surgical implantation. RhBMP-7, OP-1 (Olympus Biotech Corporation, Hopkinton, USA) has a half-life of 10-15 hours. Unbound, it is rapidly cleared from the implantation site. The commercially available BMPs are therefore combined with some kind of carrier to enhance their bioavailability locally. RhBMP-7 is combined with granular bovine collagen. One vial of OP-1 contains 3.3 mg of BMP-7. In a large, prospective, controlled, randomized multicenter study on tibial nonunions, treatment with BMP-7 was compared with autologous bone grafting and was found to produce healing rates that were comparable (Friedlander et al., 2001). Another multicenter study on open tibial fractures compared standard of care with standard of care plus local BMP-2 treatment in different doses. The highest BMP-2 dosing was significantly superior to standard of care in reducing the frequency of secondary interventions and the overall invasiveness of the procedures. It accelerated fracture and wound-healing, and reduced the infection rate in patients with an open fracture of the tibia (Govender et al., 2002).

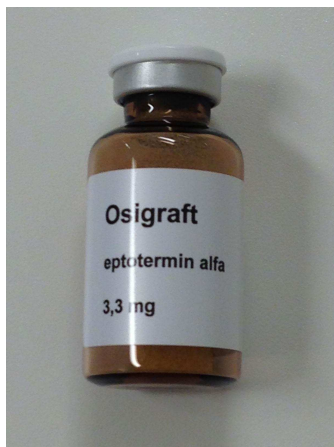

Figure 4: A vial of rhBMP-7, Osigraft.

The maximum human dose of OP-1 is two vials, i.e. 6.6 mg. It is an expensive drug, one vial costing nearly 4000 €. In view of the supraphysiologic dosing of rhBMPs, several side effects have been reported. According to the manufacturer, the use of OP-1 is contraindicated in patients who (1) are pregnant or plan to become pregnant within 2 years of treatment (2) have or have had a malignancy (3) are skeletally immature (4) have a known hypersensitivity to the active

substance or to collagen (5) have an autoimmune disease or immune suppression (6) have been previously treated with OP-1. Ectopic bone formation and stimulation of cancer cells have been feared. Ectopic bone formation has been observed in animal studies but these were associated with very high doses of BMP and remodeling ultimately restored the bone to its normal contour.

Bisphosphonates

Bisphosphonates (BPs) are drugs that inhibit bone resorption. Clinically they are used for the treatment of osteoporosis, Paget's disease, Osteogenesis imperfecta, myeloma, bone metastases and primary hyperparathyroidism (Landesberg et al., 2009, Hamson and Fogelman, 2012). They all share the same P-C-P-backbone and they all have two side chains, R1 and R2. Their name relates to their two phosphate groups (PO₃). Their structure resembles that of pyrophosphate. In the bisphosphonates the two phosphate groups are connected by a carbon atom, while in pyrophosphate they are connected by an oxygen atom. The short R1 side chain influences chemical properties and pharmacokinetics. The longer R2 side chain determines chemical properties, mode of action and potency (Russel et al., 2008 Rogers et al., 2011). BPs target and bind to bone mineral due to their molecular structure and their ability to chelate calcium ions. BPs can be given orally or intravenously, the administration route does not affect their bone accumulation or renal excretion. Most circulating BPs accumulate in bone tissue. They bind strongly to mineral and practically remain bound until they are released during bone resorption (Kozloff et al., 2010). BPs accumulate in areas of active remodeling. Due to their strong affinity to bone, other cell types are minimally exposed to them. During osteoclastic bone resorption, the acidification of the bone releases the BP that is then internalized into osteoclasts by means of endocytosis. One can divide BPs into simple BPs and nitrogen containing BPs. The nitrogen containing ones feature a nitrogen atom in the R2 chain and are much more potent antiresorptives than the simple ones. The configuration of the nitrogen atom determines the potency. Alendronate with a nitrogen atom in an alkyl side chain is 10-100 fold more potent than the simple BP etidronate. Zoledronate with a nitrogen atom within a heterocyclic ring has been shown to be up to 10.000 fold more potent than etidronate. The very potent nitrogen containing BPs, such as zoledronate, are often referred to as third generation drugs. The modes of action by which the BPs inhibit osteoclastic resorption differ between the simple BPs and the nitrogen containing ones. The simple BPs are metabolized and metabolically incorporated into analogues of ATP. These metabolite analogues contain the P-C-P-backbone of the metabolized bisphosphonate instead of the pyrophosphate (P-O-P) moiety of ATP. These analogues of ATP, are resistant to hydrolytic breakdown and thus accumulate within the osteoclasts where their inhibition of enzymatic pathways leads to apoptosis. The more potent nitrogen-containing BPs are not

metabolized but inhibit the enzyme Farnesyl Pyro-Phosphate Synthase (FPPS) a key enzyme in the mevalonate pathway. This inhibits the synthesis of certain lipids necessary for post-translational prenylation (addition of hydrophobic molecules) of small GTPases (hydrolase enzymes) disrupting normal function of these proteins. The GTPases are important for osteoclast function. They are involved in cytoskeletal arrangement, membrane ruffling vesicular trafficking and cell survival (Russel et al., 2008, Rogers et al., 2011).

In all our studies the very potent third generation nitrogen-containing BP zoledronic acid was used. Clinically it is administered intravenously, once yearly for osteoporosis and more frequently when used for metastatic bone disease.

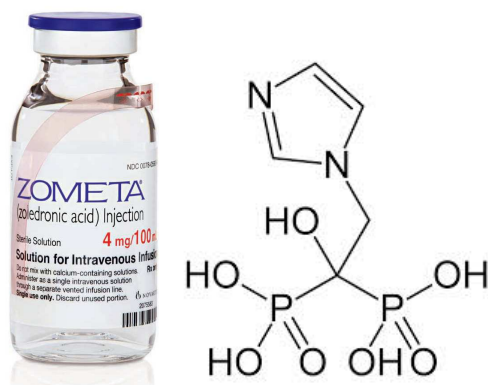


Figure 5: Zoledronic acid is a potent third generation nitrogen containing bisphosphonate.

Materials and methods

Animal model and surgery

In all four studies, male Sprague Dawley rats (Taconic, Ry, Denmark) were used. This is an outbred albino rat. The animals used by us were approximately two months of age and 300 mg at the time of the surgeries. Laboratory rats can reach an age of 3.5 years. Compared to humans they have a much accelerated childhood. They become sexually mature at about six weeks of age and the transition into adulthood starts after the eighth week of life. The rats used by us should thus be seen as young adults. Noteworthy there is no epiphyseal closure in the long bones of the rat. However, around seven to eight months of age the skeletal growth of the long bones tapers off (Sengupta, 2013).



Figure 6: A Sprague Dawley rat.

All procedures relating to the rats were approved by the local animal ethics committee in Lund. Both before and after the procedures, the rats were kept in pairs with unrestricted access to food and water.

In all four experiments, the same anesthesiology-, infection prophylaxis- and pain management protocol was used. The rats were anesthetized using pentobarbital sodium (15 mg/mL), diazepam (2.5 mg/mL) and saline administered intraperitoneally. Streptocillin was given preoperatively as infection prophylaxis. Subcutaneous buprenorphine was given immediately postoperatively and then once daily the first postoperative days for pain relief. In papers 1, 2 and 3 we used a femoral osteotomy model prone to nonunion. In previous experiments using this model without any healing adjuncts, the healing rate at 6 weeks was 60 % (Tägil 2010). Post induction, the legs were shaved and prepped and the rats put in the lateral decubitus position. Through a lateral muscle splitting approach the femur was exposed and the periosteum denuded circumferentially at the mid diaphysis. A single transverse cut was then made through the diaphysis with a power saw equipped with a 0.2 mm thick saw blade. The femurs were then pinned in apposition with a single K-wire. After fixation of the osteotomy the respective treatments were applied locally at the osteotomy site and the incision closed in layers. In study 1, 2 and 3 the rats were killed after six weeks by an injection of pentobarbital sodium administered intraperitoneally and the femurs harvested and frozen. In study number 1, three treatments were compared against controls and each other. The treatments were; i) Autograft, ii) autograft+BMP-7 and iii) autograft+BMP-7+zoledronate (ZOL). Radiography, micro-CT and three-point bending testing were used to evaluate the calluses.

In study number 2, allograft and different combinations of allograft, BMP-7 and zoledronate were evaluated against no treatment, autograft and autograft together with zoledronate. Seven treatments in all were tested. i) saline, ii) autograft, iii) allograft, iv) allograft+BMP-7, v) autograft+ZOL, vi) allograft+ZOL, vii) allograft+BMP-7+ZOL. Radiography, micro-CT, three-point bending testing and histology were used to evaluate the calluses.

In study number 3, two different treatments; i) BMP-7 and ii) BMP-7+ZOL were compared against controls and each other. Samples were evaluated using radiography, qualitative micro-CT and mechanical testing in both three-point bending and twisting.

In study number 4 the surgical procedure was quite different since this involved locked nailing of the femur and the creation of a reproducible critical size defect of 6 mm. The surgery started in the supine position and a medial parapatellar incision was made and the patella displaced laterally. The femoral trochlea was opened with a burr and the medullary canal reamed to accept the Rat-nail XL (Risystem, Davos, Switzerland). With the nail in place the rat was put in the lateral decubitus position and the femur exposed through a long lateral incision. With the lateral

aspect of the femur fully exposed, the aiming device was mounted and the nail locked both proximally and distally. Following locking, the saw guide was put onto the aiming device and two osteotomies, 5 mm apart, were made with a Gigli saw. The cut segment of bone was crushed and removed piecemeal and the resultant 6 mm defect filled with a premade two-piece spacer that was secured around the nail with a suture. The spacers were manufactured by us by casting of a two component epoxy filler in a 1 ml syringe. A K-wire was used to create the center hole. When the filler had cured, the cylinder was cut in 6 mm pieces. A small trench was made along the circumference of each spacer, to hinder subsequent slippage of the suture. Finally the spacers were halved and then sterilized. A second surgical procedure was carried out 4 weeks after the initial operation. During this operation the femur was carefully approached through a lateral incision, the newly formed membrane incised, the spacer removed and the defect grafted according to the protocol. There were four different treatment groups: A) scaffold, B) BMP-7, C) BMP-7+scaffold and D) BMP-7+scaffold+bisphosphonate injection at 2 weeks. Finally the incisions were closed in layers. The rats were killed after an additional eleven weeks by an overdose of pentobarbital sodium and the femurs explanted. After radiography the nails were removed the bones manually assessed and then frozen for later histological analysis, micro-CT-, Fourier Transform Infrared (FTIR) spectroscopy.

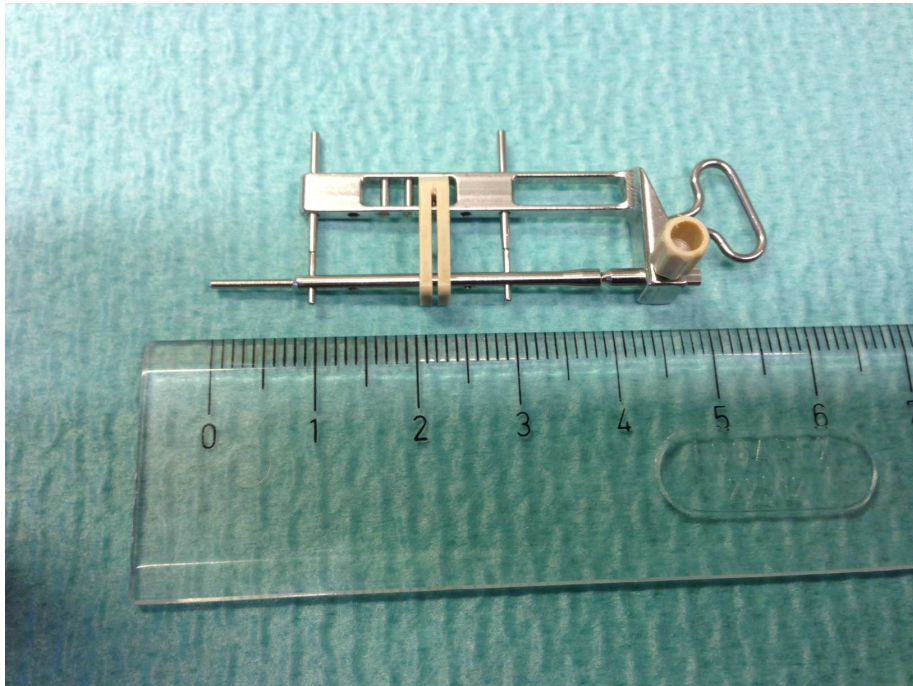


Figure 7: RatNail XL with aiming device and saw guide.

Drug treatment and delivery

We used BMP-7, OP-1 PUTTY (Stryker, Kalamazoo, USA) for all the experiments. One vial containing 3.3 mg of recombinant human BMP-7 (rhBMP-7) and 1 g of purified type I bovine collagen, which is used as a carrier, is mixed with 230 mg of sterile carboxymethylcellulose (CMC) and saline to form a putty for local implantation at the nonunion site. The maximum human dosage is 2 vials, i.e. 6.6 mg BMP-7. In study 1, 2 and 3 the BMP dosing was 50 µg per animal. In study 4 the BMP dosing was 25 µg per animal.

The bisphosphonate used in all the experiments was zoledronic acid, (Zometa, Novartis), a potent nitrogen containing third generation bisphosphonate. The dosing was 0.1 mg/kg. In all the studies zoledronate was given as a subcutaneous injection at two weeks. This timing was chosen based on the finding that zoledronate injection at two weeks resulted in larger calluses than injection at time of surgery or at 1 week (Amanat et al., 2007). This mode of administration has not been shown to inhibit the initial non-specific remodeling of soft callus into hard callus but does delay ultimate remodeling of hard callus (McDonald et al., 2008).

Histology

Histology was used in study 1, 2 and 4. The bones were fixed in 4% formaldehyde in phosphate buffered saline for 24 hours, decalcified in 10% EDTA for 2.5 weeks and dehydrated in graded alcohol and cleared in xylene before being embedded in paraffin. A microtome (Microm HM355S) with a section transfer system (Thermo Scientific, Germany) was used to cut centerpiece sections with 5µm thickness. The sections were stained with hematoxylin-eosin using standard protocol.

Mechanical testing

Three-point bending testing was used in studies 1, 2 and 3. In all the studies the non-operated femurs were also tested to serve as controls. The same load frame was used for all the mechanical testing, (Instron 8511 load frame, High Wycombe, UK with an MTS TestStar II controller, Minneapolis, USA). A custom made test rig, with 3 mm solid brass bars was used (Bosemark et al., 2013). The distance between the supports was 16 mm. The first support was placed immediately distal to the lesser trochanter and the second just proximal to the femoral condyles. The femurs were mounted for testing in the AP-plane with the posterior surface of the bone resting on the two lower supports. The bones were preloaded to 10 N at a speed of 0.1 mm/sec and allowed to adapt for ten seconds. Thereafter, the bones were tested until failure with a constant speed of 1.0 mm/sec. Time, force and displacement were recorded. Based on a force-displacement curve, the ultimate

force for each of the bones was determined and the stiffness and the absorbed energy were calculated.




Figure 8: Three-point bending test rig with a rat femur.

In study 3, in addition to the three-point bending test, a rotational type testing was also used. In a true torsion test both ends of the specimen are equally and oppositely rotated around the neutral axis. A simplified version of this test, in which one end is fixed and the other is twisted, was used in this study and is referred to as a twist test (Saunders et al., 2010). The proximal and distal ends of the bones were each rigidly fixed to metal nuts (M6) by embedding the bone ends in Low Melting Temperature Alloy (LMTA, Legierung 47° Grad FA16; Alpha-Fry Technologies B.V., Cookson Electronics Assembly Materials, Naarden, The Netherlands). The end-to-end distance between the two nuts in each specimen were 20 mm. The nuts were securely fixed in the load frame and the bones were preloaded to 10 N and allowed to adapt for 10 seconds before they were subjected to twisting at an angular displacement of 6 degrees/second until failure. During the test, the upper metal nut was stationary in the load frame and the lower was twisted.




Figure 9: Metal nuts secured to bone ends for twisting testing and twisting test rig.

Micro-CT

For the analyses in study 1, 2 and 3, the micro-CT equipment used was a SkyScan 1172, SkyScan, Aartsele Belgium. In study 4 we used a nanoScan, Mediso Medical Imaging Systems, Budapest Hungary. In study 1, 2, 3 and 4 the femurs were scanned using an isotropic voxel size of 19, 25, 36 and 21 μm respectively. The energy settings were either, 50 kV and 200 μA (study 1), 100 kV and 100 μA (studies 2 and 3) or 65kV and 123 μA (study 4). A 0.5 mm aluminum filter was used in studies 1-3 and a RamLack filter in study 4. The region of interest, ROI, was different in all the studies. 3 mm in study 1, 1.5 mm in study 2, 2 mm in study 3 and 7.5 mm in study 4.

Calibration of bone mineral density (BMD) was performed through scanning of one water phantom and two hydroxyapatite phantoms of known densities (0.25 and 0.75 g/cm^3). To distinguish fully mineralized tissue, from poorly mineralized tissue and soft tissue, two thresholds were used. Total callus volume (TVc), fully mineralized bone volume (BVhigh), poorly mineralized tissue volume (BVlow), bone volume fraction (BVhigh / TVc) and average tissue mineral density (TMD) was measured. The TMD was calculated by using only the voxels that exceeded the threshold for fully mineralized bone.

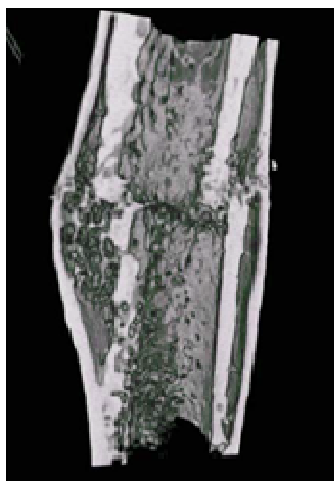


Figure 10: Example micro-CT image.

Fourier Transform Infrared spectroscopy

Fourier Transform Infrared (FTIR) spectroscopy was utilized in study 4. The 3 μm sections were measured with a Bruker 66V FTIR spectrometer coupled to a Bruker Hyperion 3000 IR microscope using a focal plane array detector at the Max-IV synchrotron laboratory, Lund, Sweden. Based on the light microscope image, three areas (340x340 μm) of newly formed bone within the defect (callus) and one cortex area per sample were chosen for analysis using 64 scans and a spectral resolution of 4 cm^{-1} . The IR spectra were collected at the range of 800 to 3800 cm^{-1} .

Mineral-to-matrix ratio, crystallinity, acid phosphate substitution, and collagen maturity were all determined after removing the spectrum of the epoxy.

Methodological considerations

When evaluating pharmacological treatment in vivo, animal models are often used. Based on power analysis, large enough groups have to be utilized in order to be able to analyze the material statistically. Strict adherence to protocols and standardized procedures concerning surgical technique, drug delivery etc. are needed to produce reliable and reproducible results. In our experiments we used inbred male Sprague Dawley rats. The reason for using male rats was to avoid the hormonal fluctuations associated with the polyestral cycle in female rats. Rats are often used in animal fracture studies as homogenous populations are readily available. However, they have their own physiological features and one must be

cautious in making direct parallels to humans. In humans 90 % of the organic matrix is made up of collagen while in rats only 60 % of the organic matrix is collagenous. The architecture of cortical bone also differs between humans and rats. With the above taken into account, the basic cellular mechanisms involved in fracture healing and remodeling is similar to that of humans and a rat model is appropriate for evaluating pharmacological modulation of fracture healing (Frost and Jee, 1992, Sandhu and Khan, 2002).

Results

Study number 1

Radiographically, all osteotomies healed. The calluses in the autograft+BMP-7+ZOL-group were larger and denser than the calluses in all the other groups.

The total callus volumes (TVc) were significantly greater ($p<0.001$) in the two BMP-7 treated groups compared to the autograft group. Also, the TVc was significantly greater in the autograft+BMP-7+ZOL-group compared to the autograft+BMP-7-group; ($p<0.01$).

Both the highly and lowly mineralized bone volumes were significantly higher ($p<0.01$) in the two groups receiving BMP-7 compared to the autograft-group. The autograft+BMP-7+ZOL-group showed further increased BVhigh and BVlow compared to the autograft+BMP-7-group; ($p<0.01$). Compared to the autograft-group, the bone volume fraction (BVhigh / TVc) was lower ($p<0.01$) in the autograft+BMP-7-group, while it was similar in the autograft+BMP-7+ZOL-group.

The ultimate force to fracture of the non-osteotomized, control femurs, ranged from 158N to 170N. The osteotomized femurs in the autograft-group fractured at approximately half that force ($p<0.001$). When BMP-7 was added to the autograft, the strength doubled compared to the autograft-treated bones and then equaled the non-osteotomized femurs. When zoledronate was given systemically, in addition to the locally applied autograft and BMP-7, the ultimate force doubled compared to control femurs ($p<0.001$). The bending stiffness decreased ($p<0.01$) in both, the autograft-group and the autograft+BMP-7-group compared to the control femurs, whereas the stiffness in the autograft+BMP-7+ZOL-group was comparable to controls. Energy absorption of the bones treated with autograft in isolation was less than half of that of the control femurs. The bones in the autograft+BMP-7-group were equivalent to the controls and the bones in the autograft+BMP-7+ZOL-group were able to absorb more than three times the energy before failure compared to controls.

When comparing the treatment combinations in the osteotomized femurs with each other, the autograft+BMP-7+ZOL-group showed significantly higher ultimate force ($p<0.001$), bending stiffness ($p<0.05$) and absorbed energy ($p<0.001$) compared to all the other treatment combinations.

Table 1: Mechanical testing outcome for experimental (osteotomized) and the control (contralateral non-fractured) femurs. Based on three-point bending, the ultimate force, stiffness and absorbed energy were calculated. The percentage differences (Diff.) and the statistical differences between the experimental and control side (Wilcoxon signed rank test) are given.

Group	N	Ultimate force (N)				Diff. (%)	p-value	Stiffness (N/mm)				Diff. (%)	p-value	Absorbed energy (Nmm)				Diff. (%)	p-value
		Exp. Mean	Exp. SD	Control Mean	Control SD			Exp. Mean	Exp. SD	Control Mean	Control SD			Exp. Mean	Exp. SD	Control Mean	Control SD		
A: ABG	11	88	31	158	24	-57	< 0.001	207	72	461	88	-55	< 0.001	33	36	70	39	-52	0.06
B: ABG + BMP	11	170	38	164	33	3	0.7	257	98	415	111	-38	0.002	107	38	88	28	22	0.1
C: AGB + BMP + ZOL	12	357	104	156	21	129	< 0.001	356	138	398	80	-10	0.3	299	131	59	26	406	< 0.001

Study number 2

Radiography: Complete healing was observed in all samples in the two BMP-groups.

Allograft+BMP-7+ZOL produced large and dense calluses.

In the autograft-group 66% healed. When autograft was combined with ZOL, complete healing was seen in only 33%. Also allograft together with ZOL healed 33% of osteotomies. Allograft treatment resulted in a 42% healing rate.

Micro-CT: Total callus volume was greater with allograft+BMP-7+ZOL compared to all other treatments ($p < 0.001$). The callus volume was double that of autograft alone and 85% larger than autograft+ZOL ($p < 0.001$). The groups with BMP-7 and/or ZOL had significantly larger highly mineralized bone volumes ($p < 0.01$, $p < 0.001$) than the saline or autograft alone groups. The largest amount of highly mineralized bone was found in the allograft+BMP-7+ZOL group. In the allograft+BMP-7+ZOL group callus volume increased by 84% and the highly mineralized bone volume by 87% compared to the allograft+BMP-7 group.

Three-point bending test: The allograft+BMP-7+ZOL group yielded a significantly higher ultimate force than all other groups ($p < 0.01$, $p < 0.001$). Compared to controls the ultimate force of the allograft+BMP-7+ZOL-group was 59% higher ($p < 0.01$). All other treatments, including the allograft+BMP-group displayed lower peak forces than their respective controls. All experimental groups were less stiff than controls. However, the allograft+BMP-7+ZOL group was 89% stiffer than the allograft+BMP-group. The experimental bones in the allograft+BMP-7+ZOL group were able to absorb 147% more energy than their controls while all the other groups had equivalent or lower energy absorption relative to their respective controls.

Study number 3

Radiography and callus size measurement: All fractures healed. The BMP-7+ZOL-induced calluses were 9% ($p<0.05$) larger than BMP-7 alone calluses.

Three-point bending: The BMP-7+ZOL-group showed significantly higher ultimate force than both the BMP-7 alone group ($p<0.01$) and the two control groups ($p<0.01$). In the BMP-7+ZOL-group the stiffness matched controls and was more than double that of the BMP-7 alone group ($p<0.01$). Both treatments increased the ability to absorb energy relative to controls. Energy absorption was greater for the BMP-7+ZOL-group compared to the BMP-7 alone group ($p<0.05$). In the BMP-7 alone group, lower breaking force ($p<0.05$) and stiffness ($p<0.01$) was found in the experimental side compared to the control side. All fractures were transverse-oblique and callus associated.

Twisting: Similar trends were noted, although less pronounced. The ultimate force for the BMP-7+ZOL-group was 24% higher than for the BMP-7 alone group ($p<0.05$). For the BMP-7+ZOL-group, both ultimate force and stiffness were comparable to the controls. All fractures from both treatment groups were spiral and located away from the fracture with extension to – or into the calluses All but one of the bones tested in torsion were fractured in the structurally weaker supracondylar region, distal to the callus.

Micro-CT: The total callus volume was only slightly higher in the BMP-7+ZOL-group compared to the BMP-7-group, whereas the mineralized bone volume and bone volume fraction were approximately double in the BMP-7+ZOL-group compared to the BMP-7 alone group.

Table 2: Results from the three-point bending test indicating mean and standard deviation (SD) for each group.

		Max Force (N)		Bending Stiffness (N/mm)		Flexural Rigidity (kN mm ²)		Absorbed Energy (N mm)	
Experiment group	Group	Mean	SD	Mean	SD	Mean	SD	Mean	SD
	BMP	165.0	34.1	253.3	87.6	20.4	7.1	102.3	50.1
	BMP + ZOL	315.7	84.8	580.8	225.1	46.8	18.2	148.1	82.4
Control group	BMP	195.7	32.7	604.1	101.5	48.7	8.2	77.7	27.8
	BMP + ZOL	200.9	30.5	630.8	99.7	50.9	8.0	86.9	36.3

Table 3: Results from the twisting test indicating mean and standard deviation (SD) for each group.

		Max Torque (Nm)		Stiffness (Nm/deg)		Absorbed Energy (J or Nm)	
Experiment group	Group	Mean	SD	Mean	SD	Mean	SD
	BMP	0.517	0.146	0.039	0.009	5.255	2.155
	BMP + ZOL	0.643	0.093	0.048	0.008	5.228	1.223
Control group	BMP	0.580	0.130	0.047	0.007	4.127	1.325
	BMP + ZOL	0.606	0.162	0.050	0.009	4.077	1.352

Study number 4

There was complete correlation between radiography and manual assessment in all groups. Isolated scaffolds (group A), failed to produce radiographic healing or rigid union in any of the samples ($p < 0.01$), compared to group B, ($p < 0.001$) compared to group D and ($p < 0.0001$) compared to group C. Isolated BMP-7-treatment, (group B) led to radiographic healing and rigid union in seven out of ten samples. Of the healed samples, two had visible fracture lines proximally or distally. BMP-7+scaffold (group C) induced radiographic healing and rigid union in ten out of ten samples but 9 out of ten samples still had visible fracture lines proximally and/or distally. BMP-7+scaffold+systemic bisphosphonate treatment (group D) led to radiographic healing and rigid union in nine out of ten samples and only one out of the nine healed samples had a visible fracture line.

The total callus volume of the two groups receiving combined treatment with BMP-7+scaffold (groups C and D) was significantly greater ($p < 0.001$) compared to groups A and B. The volume of highly mineralized bone in group D (BMP-7+scaffold+systemic bisphosphonate) was significantly greater compared to groups A, B ($p < 0.001$) and C ($p < 0.01$). There was no difference in total callus volume between groups C and D. However, the bone volume fraction was significantly higher in group D compared to group C ($p < 0.001$) and groups A and B ($p < 0.01$). Thus, the treatment combination in group C (BMP-7+scaffold) increased callus volume compared to groups A and B ($p < 0.001$) but did not increase the bone volume fraction, whereas the treatment in group D (BMP-7+scaffold +systemic bisphosphonate) increased both callus volume and bone volume fraction.

Histologically, the previous defects in group A were filled with scaffold interspersed by fibrous tissue. No bony callus was seen. In group B there was abundant bone tissue throughout the previous defects with bridging bony callus. In group C most of the scaffold was resorbed. There appeared to be less bone than in groups B and D. The calluses in group D appeared larger compared to the others. The defects were filled by abundant bony callus and little fibrous tissue. There was more remaining scaffold than in group C.

Table 4: Scoring from manual assessment and radiography.

	A scaffold	B BMP-7	C BMP-7+scaffold	D BMP- 7+scaffold+BP
radiographically healed of total (n)	0/10	7/10	10/10	9/10
manual palpation rigid union of total (n)	0/10	7/10	10/10	9/10
samples with visible # lines of healed samples (n)	na	2/7	9/10	1/9

Discussion

Study number 1

Improving the gold standard - can we make a bone inductive cocktail that outperforms autograft?

In the first study we investigated if the addition of autograft could improve the healing rate in a rat model in which untreated, approximately 40% of fractures have been shown not to heal (Tägil et al., 2010) and if addition of bone active drugs would further increase the healing rate and/or make the calluses stronger. We showed that treatment with autograft resulted in healing of all osteotomies. Adding BMP-7 to the autograft not only led to healing of all fractures but also doubled the strength of the calluses compared to autograft alone. Micro-CT analysis revealed that BMP-7-treatment as expected caused an increase in total callus volume but also somewhat surprisingly, a decreased bone volume fraction. Theoretically, this could be due to BMP-induced premature resorption of the callus through RANKL-RANK mediated osteoclastic activation, leading to resorption and remodeling of the newly formed callus. This has previously been found, both in vitro (Kanatani et al., 1995, Itoh et al., 2001, Giannoudis et al., 2007) and in previous fracture studies (Doi et al., 2011).

Through the addition of a single bisphosphonate injection, we counteracted this premature resorption, rendering large, dense and strong calluses with bone volume fractions similar to those of autograft induced calluses. Additionally, a further doubling of the strength was reached in the mechanical testing with the combination of autograft+BMP-7+ZOL compared to BMP alone and four times as strong as with isolated autograft treatment. In the clinic fast and reliable union is an obvious advantage.

As anabolic and catabolic events are coupled, there have been concerns regarding possible bisphosphonate mediated early callus inhibition. However, the catabolism associated with initial endochondral repair is not osteoclast dependent and is thus not affected (McDonald et al., 2008).

When combining autograft with BMP and an anti-remodeling agent such as bisphosphonate, one would expect the calluses to be larger and denser but also potentially less remodeled. An immature, non-remodeled callus can, due to its biomechanically suboptimal random trabecular orientation, be expected to be

inferior in strength compared to a mature, remodeled one, with a biomechanically superior organization. In this study, we were able to show that the, per se, inferior mechanical properties of immature, less remodeled calluses can more than be compensated for by an increase in callus size and mineralization. Both the autograft alone treatment and the combination with BMP-7 resulted in weaker calluses than the combination of autograft, BMP-7 and zoledronate.

Study number 2

Alternatives to autograft - is allograft+BMP an option?

In the second study we investigated if allograft+BMP would be superior to autograft and whether the addition of a bisphosphonate would further improve the result. Our aim was to enhance the allograft with bone active drugs to make it outperform today's gold standard, autograft. In the few prospective randomized clinical studies, BMP has never proven to be superior to autograft, by speculation due to BMP-induced osteoclastic resorption. The use of autograft is limited by harvest associated donor site morbidity and supply limitations. In this study we confirmed the hypothesis that the combination of allograft+BMP-7+ZOL is a superior bone healing adjunct than the present gold standard, autograft. Allograft+BMP-7+ZOL more than doubled the callus volume compared to autograft and mechanical testing revealed that the increased volume also correlated to a doubling in peak force in the allograft+BMP-7+ZOL group compared to the autograft group. However, the influence of living cells in the osteogenic autograft is obvious when comparing the results from this study with results of autograft+BMP-7+ZOL treatment from study number 1 (Bosemark et al., 2013). Here, the combination of autograft, BMP-7 and ZOL lead to even larger and stronger calluses than allograft+BMP-7+ZOL. Our results support the practice of combining BMP-7 with a bisphosphonate in order to control unwanted premature callus catabolism, while still retaining the anabolic drive. The combination of an anabolic- and an anti-catabolic drug is an effective adjunct to both autograft and allograft.

Study number 3

Mechanical testing

The drugs used in this thesis influence bone healing in different ways. BMPs seem to increase callus size substantially but at the cost of decreased callus density, due to the increased resorption previously mentioned. Bisphosphonates on the other hand increase callus density, but at the cost of inferior callus architecture, and as a single treatment, probably at the cost of decreased callus formation. In the third study the influence of the testing modality on the mechanical testing results is investigated. The hypothesis being, that the increased callus diameter induced by BMP-treatment and the increased callus diameter and density induced by BMP+bisphosphonate-treatment, would provide different resistance to breaking, when tested in bending or in twisting. Due to the anisotropic nature of bone, and the inherent limitations associated with different mechanical tests, the method chosen to evaluate callus strength is likely to affect the result.

During a three-point bending test the breaking force exerted by the intender is centered between the two lower supports and thus the breaking point should ideally be identical to the load-application point. In our testing situation, the intender was overlying the previous osteotomy and thus also the corresponding calluses. When tested in three-point bending, the often larger and more dense BMP+bisphosphonate treated calluses, clearly provided additional resistance to fracture, being much stronger than both controls and the bones treated with BMP in isolation. Macroscopically the fractures caused by the three-point bending test were noted to be relatively transverse and occurring either entirely- or partially-through the newly formed callus or in some cases immediately adjacent to it.

When tested in twisting, the measured differences between the two groups and controls were less pronounced. During a twisting test, the entire bone between the fixation points, located at either end of the bone, is loaded equally and therefore the weakest part of the bone fails first. Due to the nature of the test, a twisting test cannot measure callus strength when the calluses are stronger than the surrounding native bone. Since the fractures caused by the twisting test were not callus associated, we made the interpretation that the BMP+bisphosphonate treated calluses were stronger than the surrounding native bone. Macroscopically all fractures were spiral as expected and all but one were located in the distal femoral metaphysis with a proximal extension towards or into the callus. In specimens treated with BMP+bisphosphonate, the fractures seem to be initiated in the structurally weaker supracondylar area where the cortex is thin and then propagate obliquely proximal and exit the bone just before the more resilient callus is encountered. Since the bones in the BMP alone group were weaker than the controls it is reasonable to assume that the fractures were initiated around the previous osteotomy and propagated distally towards the supracondylar region.

Lamellar bone found in mature cortical bone or in remodeled calluses has superior intrinsic mechanical properties compared to woven bone of the same size. It is both stronger and stiffer, due to a more structured internal architecture. The advantage of woven bone however, is that it can be formed rapidly and thus can provide early initial fracture stability. Also, woven bone has the ability to become more highly mineralized than lamellar bone thereby reducing its relative lack in stiffness compared to lamellar bone (Miller et al., 2007). In theory, co-treatment with BMP and bisphosphonate during fracture healing could be expected to produce a large but immature and disorganized callus, with high collagen and mineral content due to the delayed resorption. These traits could compensate for the mechanically inferior internal architecture of woven bone compared to mature lamellar bone. Even though the mechanical properties of the calluses treated with the combination of BMP and bisphosphonate cannot match those of remodeled bone, callus size and density compensate for this.

From previous experiments we know that if no healing adjunct is added, mid-shaft femoral osteotomies in this rat model heal in 60% of cases (Tägil et al., 2010). If we add autograft, or autograft together with BMP, all osteotomies heal, with corresponding callus strengths of 50% and 100% respectively compared to the intact controls. If we add BMP and bisphosphonate to the autograft, the calluses become twice as strong as controls (Bosemark et al., 2013). In the present study, we have shown similar results without the concomitant use of autograft. This would be an obvious advantage in clinical practice in nonunion surgery, reducing theatre time and eliminating donor site morbidity from bone graft harvest.

One could argue that BMP in isolation also induces healing in 100% in this study, but, importantly, callus strength did not match controls at 6 weeks. In fracture surgery or nonunion surgery it is desirable that the bone heals in a predictable way and in a timely fashion and that the callus is at least as strong as the surrounding native bone as early as possible in the healing process. We believe that the combination of BMP and bisphosphonate, either with or without autograft leads to fast and reliable bony union with early calluses that are at least as strong as the native bone. However, mechanical testing of bone in fracture- or osteotomy studies are best conducted using bending tests when the strength of the tested calluses are expected to exceed that of the surrounding native bone.

Study number 4

The Masquelet technique

For the treatment of nonunions and large bone defects a synthetic bone substitute as an alternative to either autograft or allograft would be ideal. A synthetic graft would eliminate supply issues and donor site morbidity associated with autograft harvest, shorten theater time and eliminate the risk for disease transmission from allografts. However, synthetic bone substitutes lack osteoinductive properties and are in isolation therefore not viable options in the clinical situation. The Masquelet technique for infected nonunions and large bone defects makes use of an induced membrane providing immediate vascular support to the autograft which is transplanted into the membrane at a second operation. The membrane itself has been shown to express bone inductive growth factors but probably to a limited extent. We hypothesized that the defects in study four would not heal with the bone substitute alone but maybe with a combination of bone substitute and BMP. We hypothesized that also in this model the addition of a bisphosphonate would counteract the BMP induced resorption and further improve the healing.

Masquelet has reported his group's experiences of mixing BMP-7 with autograft for Masquelet procedures. Interestingly, they noticed resorption of the graft on follow up radiographs. Masquelet also describes cases with late deformity, after apparent radiographic consolidation and removal of the external fixator. These two observations lead the group to stop using BMP in conjunction with autograft for Masquelet procedures. The authors speculated that their negative findings might be attributed to the BMP being "trapped" inside the membranous tube, leading to high local concentrations of the BMP which in turn could be toxic to the graft. By speculation, these clinically adverse events can also be explained by BMP-mediated osteoclastic resorption. Decreased bone mineral content secondary to resorption could lead to a decline in the intrinsic stiffness- and an increased ductility of the callus, which in turn could explain the clinical cases of late deformity.

BMP mediated osteoclastic activation, can be counteracted by bisphosphonate administration. Through the combined treatment with BMP, the anabolic effect on osteoblasts is retained while the osteoclast mediated catabolism is stalled by the bisphosphonate. In a critical defect study in rats, where a 6 mm femoral defect was stabilized with a plate, no defects healed on their own or with the carrier alone at eight weeks. However, all defects treated with local application of 50 µg BMP-7 healed. In a group in which the same BMP-7 dose was combined with a bisphosphonate injection at two weeks, the bone mineral content and the mechanical strength was doubled.

Previous studies have shown the BMP dosage to be important. We used a BMP dose of 25 µg per rat. In a BMP-7 dose response study utilizing a rat femoral

critical size defect stabilized with a plate, 25 µg BMP-7 did not induce healing in any rats at eight weeks. However 50 µg healed all defects. Similarly, our group has previously shown that allograft+50 µg BMP-7+bisphosphonate in a rat femoral nonunion model produce strong and reliable union and thus have the potential to replace ABG. Interesting to note is that the above studies have demonstrated BMP-7 to be efficacious when dosed at 50 µg. However, in the present study 25 µg BMP-7 in isolation healed 70 % of defects and 25 µg BMP-7+scaffold+/-bisphosphonate induced healing in 90-100 %. This finding reinforces the potency of the induced membrane.

A limitation of the study is the lack of an autograft group, as ABG is the current gold standard for Masquelet procedures. However, harvest of the required amount of cancellous autograft from rats is not possible and we therefore chose to focus on synthetic bone substitutes. Moreover we did not include a pure control group simply because previous studies have shown that a 6 mm femoral defect in a rat represents a true critical defect. This notion was supported by the finding that isolated scaffold treatment failed to induce healing in any of the rats.

In this study, utilizing a novel rat Masquelet model, we have shown that a synthetic scaffold together with BMP-7 and zoledronate can heal a critical size defect. Importantly, the BMP-7 dosing used in this experiment has previously been shown unable to heal a critical size defect. Clinically, a low dose of BMP would be advantageous, reducing cost and theoretically also possible dose dependent negative side effects from the BMP.

The future

In this thesis we have found support for ways of improving our current practice regarding atrophic nonunion management- i.e. autograft transplantation. Sometimes union cannot be achieved and amputation might be the only option after repeated failed surgeries. BMPs have been used for many years now but have never been shown to lead to a higher healing rate than autograft (Friedlander et al., 2001). We believe that this is due to osteoclastic induction by BMPs and that concurrent treatment with bisphosphonates, or other anti-catabolic drugs, can make BMPs more effective clinically. However, BMPs have been questioned in the last few years mainly due to possible carcinogenic effects (Lad et al., 2013). Further there are issues with underreported side effects in some studies (Carragee et al., 2011). Recently, the company manufacturing the rhBMP-7 used in the studies in this thesis was reported to be leaving the biotech industry. We do not know the commercial future of the BMPs or whether we will have access to it in the future. Also the bisphosphonates have been questioned lately, especially regarding the risk for development of osteonecrosis of the jaw (Sigua-Rodriguez et

al., 2014), seen especially in high dosed oncologic patients. However, alternatives to both these drugs exist or may be developed, for example shorter chain peptides, which will be much cheaper to manufacture than the expensive recombinant BMPs. Also more short-acting alternatives to bisphosphonates are already present and could be preferable in fracture treatment, like antibodies interfering with the RANKL/RANK pathway such as the osteoprotegerin-analogue Denosumab.

Conclusions

1. The combination of autograft, BMP-7 and the bisphosphonate zoledronate is superior to autograft alone or autograft in combination with BMP-7. The combination may prove valuable in the treatment of nonunions.
2. Allograft combined with BMP-7 and the bisphosphonate zoledronate is more potent than autograft alone. Clinically this would be an advantage, eliminating the need for graft harvest.
3. The combination of BMP-7 and zoledronate produces calluses that are mechanically superior to calluses induced by BMP-7 alone, when tested both in three-point bending and in twisting. For the mechanical evaluation of pharmacologically enhanced calluses with breaking strengths exceeding the native bone, the bending test is recommended.
4. A synthetic scaffold+BMP-7 combined with a bisphosphonate injection at two weeks improve the callus properties in a rat femoral critical size defect, compared to BMP-7 alone, scaffold alone or the combination of the two.

Summary in English

Fractures are common in all age groups. Most heal uneventfully. However, about 5-10% fail to heal which can be due to a number of different reasons. An unhealed fracture is called a nonunion and is often debilitating for the patient and a financial burden for society and the health care system. Classically, autologous bone graft (bone graft obtained from the patient, often from the pelvis) is used locally to stimulate healing. However, this is associated with potential problems and limitations. The bone harvest from the pelvis is often associated with postoperative pain. There is a risk of infection and even iatrogenic fracture of the pelvic wing. It is also a time consuming and therefore costly procedure. Sometimes a nonunion does not heal even with bone grafting. Alternatives to autologous bone graft are therefore interesting.

Bone Morphogenetic Proteins, BMPs, are molecules existing naturally in the body that act as growth factors. Some of them play a role in fracture healing. The bone forming cells, osteoblasts respond to BMP-signaling and two types of BMPs are today synthesized and commercially available as bone-healing promoting drugs. However, BMP-treatment also stimulates bone resorbing cells, the osteoclasts. This effect is not desired in clinical practice.

Bisphosphonates are a group of drugs that are bone anti resorptive. They do not occur naturally in the body. They inactivate the bone resorbing cells. They are used in the treatment of osteoporosis and metastatic bone disease. However, they can also be used together with BMPs to control their undesired bone resorbing properties while still maintaining the desired stimulatory effect on the bone forming osteoblasts.

This thesis, comprising four studies, investigates bone healing and more specifically, pharmacological modulation of bone healing by the use of different combinations of bone graft, BMP-7 and the bisphosphonate zoledronate. A rat model has been used in all four of the studies. In the first three studies the same osteotomy model was used. In this model, the thigh bone on one side was cut with a saw and then pinned with a non-locking intramedullary nail. Different local treatments were delivered around the osteotomy. In the fourth study, a locked intramedullary nail was used and part of the thigh bone was removed to create a defined reproducible defect, known not to heal on its own. The resultant defect was the grafted with different drugs, alone or in combination.

Radiography, mechanical tests, micro-CT and histology were used to evaluate the samples.

Study 1

In this study, with three treatment groups, autograft, the classical adjunct in nonunion surgery was compared to treatments with autograft+BMP and autograft+BMP+bisphosphonate. The animals in the autograft+BMP+bisphosphonate-group were injected with the bisphosphonate zoledronate at two weeks. The rats were sacrificed after six weeks. We found that all three treatments healed the osteotomies. Both co-treatments produced stronger unions than autograft, with the autograft+BMP+bisphosphonate group being clearly superior with breaking strengths four times that of the autograft group and double that of the non-operated control femurs. Furthermore the calluses in the autograft+BMP+bisphosphonate-group also had the ability to absorb the most energy and were the stiffest of the treated bones. Micro-CT revealed large calluses with more mineralized tissue than the other groups. We concluded that the combination of autograft, BMP and bisphosphonate is superior to both autograft and autograft+BMP.

Study 2

This experiment compared allograft and different combinations of allograft and BMP and bisphosphonate with autograft and no treatment. The groups were: i) no treatment, ii) autograft, iii) allograft, iv) allograft+BMP, v) autograft+bisphosphonate, vi) allograft+bisphosphonate and vii) allograft+BMP+bisphosphonate.

Radiography revealed that the two BMP-treatments resulted in healing of all osteotomies. Autograft-treatment produced healing in 66% of samples. No treatment, autograft+bisphosphonate and allograft+bisphosphonate all lead to healing in 33% of samples. Allograft in isolation resulted in healing in 42 % of osteotomies.

Calluses treated with BMP were larger than all other groups. The combination of allograft, BMP and bisphosphonate produced the largest calluses. The groups with BMP and/or bisphosphonate expressed significantly larger highly mineralized bone volumes than the other groups. The largest amount of highly mineralized bone was found in the allograft+BMP+bisphosphonate group.

Three-point bending test: The allograft+BMP+bisphosphonate group yielded a significantly higher peak force than all other groups. It was also 59% stronger than controls, and was stiffer and able to absorb more energy than all the other groups.

We found the combination of allograft+BMP+bisphosphonate to be superior to all other tested treatments in the study.

Study 3

In this study we compared two treatments, BMP and BMP+bisphosphonate. This time we wished to assess the influence of two different mechanical tests on the results. BMP was delivered locally in all animals. In 50% of the animals a bisphosphonate injection was administered at two weeks. All the animals were sacrificed after six weeks.

Both treatments resulted in radiographic healing of all osteotomies. The calluses in the BMP+bisphosphonate group were larger, more mineralized and proved stronger than both the BMP-treated calluses and the native bone in the control femurs. When tested in three-point bending, the BMP+bisphosphonate-group was nearly twice as strong as the BMP-group and more than 50% stronger than the controls. The three-point bending test produced callus associated transverse fractures. A three-point bending test subjects the central region of an object to a localized bending force. In our test the previous osteotomy and thus the corresponding calluses matched the loading point.

During the twisting test the whole bone was loaded in shear and thus the calluses were not isolated. The weakest part of the bone therefore failed first. In the twisting test, the differences between the groups were less than in the three-point bending test and the fractures were spiral and located in the weaker supracondylar area. The BMP+bisphosphonate-treated bones were 24% stronger than the BMP-treated bones and on par with the control femurs. Micro-CT of a few example samples revealed larger calluses with more mineralized tissue in the BMP+bisphosphonate group.

We concluded that co-treatment with BMP+bisphosphonate is superior to isolated BMP treatment and that mechanical testing of pharmacologically induced calluses in an osteotomy model, is best done with a three-point bending test, especially if the resulting calluses are expected to be stronger than the surrounding native bone.

Study 4

In this experiment we investigated the healing potency of purely synthetic grafts. We utilized a rat Masquelet model developed by us to compare four treatments. A) scaffold, B) BMP-7, C) BMP-7+scaffold and D) BMP-7+scaffold+bisphosphonate injection at two weeks. The rats underwent two surgical procedures. During the first operation, unilateral locked femoral nailing, 6 mm femoral segment removal and spacer implantation was performed. Four and a half weeks later the spacers

were carefully removed and the defects grafted according to the protocol. Eleven weeks after grafting of the defects the rats were sacrificed and the experimental femurs harvested. The bones were evaluated with radiography, manual assessment, micro-CT, histology and FTIR spectroscopy.

There was complete correlation between radiography and manual assessment in all groups. Isolated scaffold (group A), failed to heal any of the samples. Isolated BMP-7-treatment, (group B) healed seven out of ten of samples. BMP-7+scaffold (group C) healed all ten samples but all but one displayed visible fracture lines. BMP-7+scaffold+systemic bisphosphonate treatment (group D) healed nine out of ten samples of which only one had a visible fracture line.

The treatment in group D (BMP-7+scaffold +systemic bisphosphonate) increased both callus volume and bone volume fraction.

Histologically, abundant fibrous tissue interspersed among the scaffold was seen in group A. In group B there was abundant bone tissue. In group D, the defects were filled by abundant bony callus and little fibrous tissue.

We concluded that a synthetic scaffold+BMP-7 combined with a bisphosphonate injection at two weeks improved the callus properties in a rat femoral critical size defect, compared to BMP-7 alone, scaffold alone or the combination of the two.

Sammanfattning på svenska

Benbrott är vanliga i alla åldrar. De flesta läker, men 5-10% av alla benbrott läker inte av olika skäl. Ett oläkt benbrott innebär ett handikapp för den drabbade och en ekonomisk belastning för samhället och sjukvården. En oläkt fraktur kräver oftast kirurgisk behandling. Vanligtvis används lokal bentransplantation med ben från patienten själv, (ofta från bäckenvingen) för att stimulera benläkningen. Benskörden från bäckenet kan dock vara förknippad med komplikationer och begränsningar. Den leder inte sällan till långvarig smärta och kan kompliceras av lokal infektion eller till och med fraktur av bäckenvingen. Benskörden förlänger också operationstiden vilket leder till ökade kostnader. Ibland leder inte heller bentransplantation till läkning. Detta har lett till ett stort intresse för alternativ till kroppseget ben vid behandlingen av oläkta benbrott.

Bone Morphogenetic Proteins, BMPs, är i kroppen normalt förekommande tillväxtfaktorer som är viktiga för normal frakturläkning. Två olika BMPs är idag rekombinant framställda och godkända för behandling av oläkta benbrott. BMP kan stimulera de benbildande cellerna, osteoblasterna att producera ny benvävnad. Dock stimulerar BMP även kroppens bennedbrytande celler, osteoklasterna. Denna effekt är inte önskvärd vid frakturbehandling.

Bisfosfonater är läkemedel som hindrar bennedbrytning. De förekommer inte naturligt i kroppen utan är syntetiskt framställda läkemedel. De inaktiverar de bennedbrytande cellerna, osteoklasterna. De används vid behandling av benskörhet och cancermetastaser i skelettet men de kan också användas tillsammans med BMP för att motverka dess osteoklaststimulerande effekt utan att påverka den önskade benstimulerande effekten.

Den här avhandlingens fyra delarbeten, handlar om benläkning. Särskilt inflytandet av olika läkemedel eller läkemedelskombinationer vid benläkning. En råttmodell användes i alla fyra delarbetena. I de tre första studierna användes en sk osteotomimodell. Lårbenet på ena sidan sågades av och stiftades. Vid det avsågade benet gavs olika lokalbehandlingar. I den fjärde studien, användes en mer avancerad spik som låstes med tvärgående låsskruvar vid höften och knät. I denna studie studerades en 6 mm stor bedefekt som man vet inte läker spontant. Denna bedefekt fylldes med benersättningsmedel, BMP, eller kombinationer av dessa. I en grupp gavs bisfosfonat som tillägg till benersättningsmedel och BMP. Röntgen, mekaniska test, micro-CT och histologi användes för att utvärdera benen.

Delarbete 1

I det här arbetet med tre stycken behandlingsgrupper, jämfördes autograft med autograft+BMP och autograft+BMP+bisfosfonat. Råttorna i autograft+BMP+bisfosfonat-gruppen injicerades med bisfosfonat två veckor postoperativt. Efter sex veckor avlivades råttorna. Röntgen visade att alla tre behandlingar ledde till läkning. Båda behandlingarna med BMP ledde till starkare läkning än autograft. Autograft+BMP+bisfosfonat-behandlingen ledde till absolut starkast läkning, fyra gånger starkare än autograft och dubbelt så stark som de icke opererade kontrollbenen. Vidare, absorberade benen i autograft+BMP+bisfosfonat-gruppen mest energi och var styvast av alla experimentbenen. Micro-CT-undersökning visade att autograft+BMP+bisfosfonat-gruppen hade större callusar med mer mineraliserad vävnad än de andra grupperna. Vi kunde således med denna studie visa att kombinationsbehandling med autograft+BMP+bisfosfonat leder till starkare callusar än behandling med autograft och autograft+BMP.

Delarbete 2

Detta experiment jämförde allograft (bengraft utan levande benceller från andra individer av samma art, i detta fall avlivade råttor.), och olika kombinationer av allograft och BMP och bisfosfonat med autograft och ingen behandling. De olika grupperna var: i) ingen behandling, ii) autograft, iii) allograft, iv) allograft+BMP, v) autograft+bisfosfonat, vi) allograft+bisfosfonat and vii) allograft+BMP+bisfosfonat.

Röntgen visade att de två olika BMP-behandlingarna båda ledde till läkning av samtliga osteotomier. Autograft-behandling ledde till läkning i 66 % av benen. Gruppen utan behandling liksom grupperna med autograft+bisfosfonat och allograft+bisfosfonat ledde alla till läkning i 33 %. I allograft-gruppen läkte 42 % av osteotomierna.

De BMP-behandlade callusarna var större än övriga. Kombinationsbehandling med allograft+BMP+bisfosfonat resulterade i störst callusar. Grupperna med BMP och/eller bisfosfonatbehandling hade callusar med klart större volym av höggradigt mineraliserat ben än övriga grupper. Den största volymen höggradigt mineraliserat ben återfanns i allograft+BMP+bisfosfonat-gruppen.

I tre-punkts böjtestet var allograft+BMP+bisfosfonat-gruppen starkast. Den var 59 % starkare än de icke opererade kontroll-benen. Den var även styvare och kunde absorbera mer energi än alla de andra experiment-grupperna.

Vår slutsats blev att kombinationen av allograft+BMP+bisfosfonat ledde till bättre och starkare benläkning än övriga grupper i det aktuella experimentet.

Delarbete 3

I det här experimentet jämfördes två behandlingar. BMP och BMP+bisfosfonat. Denna gång önskade vi även undersöka betydelsen av typen av mekaniskt test för utfallet. Detta gjordes genom att jämföra båda grupperna, både med tre-punkts böjtest, och ett vridningstest. BMP gavs lokalt till alla djur. Hälften av råttorna fick en injektion med bisfosfonat två veckor postoperativt. Råttorna avlivades efter sex veckor.

Röntgenologiskt, ledde båda behandlingarna till läkning av samtliga ben. Callusarna i BMP+bisfosfonat-gruppen var större, mer mineraliserade och starkare än callusarna i BMP-gruppen. De var också starkare än de icke-opererade kontrollbenen. I tre-punkts böjtestet var BMP+bisfosfonat-gruppen nästan dubbelt så stark som BMP-gruppen och mer än 50 % starkare än de icke-opererade kontrollbenen. Tre-punkts böjtestet genererade tvära, callus-nära frakturer. Vid ett tre-punkts böjtest belastas en central region av ett objekt av en lokal böjkraft. I vår testsituation sammanföll den tidigare osteotomin och således callusen med belastningspunkten vid bryttestet.

Vid vridtestet, belastades hela benets längd och callusarna kunde därför inte testas isolerat. Sålunda gav det svagaste partiet av benet vika först. Skillnaderna mellan de två grupperna var mindre uttalade i vridtestet än i tre-punkts böjtestet. Frakturerna var spiralförmade och inte belägna i anslutning till callusarna utan närmare knät där benet är svagare. De BMP+bisfosfonat behandlade benen var 24 % starkare än de BMP-behandlade och likvärdiga med de icke-opererade kontrollbenen. Micro-CT-undersökning av ett par callusar från varje grupp visade större callusar med mer mineraliserad vävnad i BMP+bisfosfonat-gruppen jämfört med BMP-gruppen.

Vi drog slutsatsen att behandling med BMP+bisfosfonat leder till bättre benläkning än behandling med enbart BMP. Samt att mekanisk testning av läkemedelsbehandlade callusar, bäst görs med tre-punkts böjtest, särskilt om callusarna kan förväntas vara starkare än den omgivande benvävnaden.

Delarbete 4

Detta försök studerade läkningsförmågan hos syntetiska bengraft i en egenutvecklad Masquelet-modell. Vi jämförde fyra olika behandlingar, A) benersättning, B) BMP-7, C) BMP-7+benersättning och D) BMP-7+benersättning+bisfosfonatinjektion efter två veckor. Råttorna opererades två gånger. Under den första operationen märgspikades ena lårbenet varefter 6 mm av lårbenet sågades ut och ersattes med en epoxy-plugg. Fyra och en halv vecka senare avlägsnades pluggarna försiktigt och de membranomslutna defekterna lokalbehandlades i enlighet med försöksprotokollet. Elva veckor efter den andra

operationen avlivades råttorna och lårbenen togs till vara för att senare utvärderas med röntgen, manuell palpation, micro-CT, histologi och FTIR spektroskopi.

Det förelåg fullständig överensstämmelse mellan röntgen och manuell palpation i alla grupper. Enbart benersättning (grupp A), ledde inte till läkning av något ben. Enbart BMP-7-behandling, (grupp B) läkte sju av tio ben. BMP-7+benersättning (grupp C) läkte alla tio ben men alla utom ett av benen uppvisade synliga frakturlinjer. BMP-7+benersättning+systemisk bisfosfonat-behandling (grupp D) läkte nio av tio ben varav endast hade en synlig frakturlinje.

Behandlingen i grupp D (BMP-7+benersättning+systemisk bisfosfonat) ledde till både ökad callus-volym och ökad benvolym-fraktion.

Histologiskt, noterades rikligt med fibrös vävnad omgivandes benersättningsmaterialet i grupp A. I grupp B noterades rikligt med callus. I grupp D, sågs de tidigare defekterna vara ersatta med rikligt med callus och mindre mängd fibrös vävnad.

Vår slutsats av studien blev att behandling med syntetisk benersättning+BMP-7 i kombination med en systemisk bisfosfonatinjektion efter två veckor förbättrar callus-egenskaperna i en kritisk defekt-modell jämfört med enbart benersättning, enbart BMP-7 och en kombination av de båda

Acknowledgements

I am truly grateful to all those who have helped and guided me in various ways during the writing of this thesis.

Magnus Tägil, my mentor for patient assistance, supervision and encouragement.

Hanna Isaksson, my assistant mentor for multiple reviews of my drafts, and for providing technical expertise with micro-CT analysis, FTIR spectroscopic analysis and statistics.

Mea Pelkonen, my dear friend and rock in the laboratory, for always being supportive and providing invaluable assistance with animal surgeries and histological preparations.

My co-authors Neashan Mathawan, Christina Perdikouri, Michelle McDonald and David Little.

My friends and colleagues in the Orthopaedic department for inspiration, especially Jamie Brown for editing my English.

Mats Christensson for his excellent craftsmanship in designing our test-rig for mechanical testing.

Håkan Arnfors and Jian-Sheng Wang for kind assistance with mechanical testing and collection of data.

Gun-Britt Nyberg for invaluable assistance with all practical things.

My parents, Olle and Titti Bosemark for encouragement and support.

Last but definitely not least, my beloved wife, Elif for putting up with me and editing my English, and my wonderful children Lily and Tom. I love you all!

This thesis was supported by grants from: The Faculty of Medicine, Lund University, the Maggie Stephens Foundation, Region Skåne, the Erik and Angelica Sparre Research Foundation, Stiftelsen för Bistånd åt Rörelsehindrade i Skåne, the Greta and Johan Kock Foundations and the Alfred Österlund Foundation.

References

- Alaoui-Ismaili M.H, Falb D. 2009. Design of second generation therapeutic recombinant bone morphogenetic proteins. *Cytokine Growth Factor Rev* 20(5-6): 501-507.
- Amanat N, McDonald M, Godfrey C, et al. 2007. Optimal timing of a single dose of zoledronic acid to increase strength in rat fracture repair. *J Bone Miner Res* 22(6): 867-876.
- Arrington E, Smith W, Chambers H, et al. 1996. Complications of Iliac Crest Bone Graft Harvesting. *Clin Orthop Relat Res* (329): 300-309.
- Behnonick D.J, Xing Z, Lieu S, et al. 2007. Role of matrix metalloproteinase 13 in both endochondral and intramembranous ossification during skeletal regeneration. *PLoS One* 7;2(11): e 1150.
- Bosemark P, Isaksson H, McDonald M.M et al. 2013. Augmentation of autologous bone graft by a combination of bone morphogenic protein and bisphosphonate increased both callus volume and strength. *Acta Orthop* 84(1): 106-111.
- Boyce B.F, Xing L. 2007. Biology of RANK, RANKL and osteoprotegerin. *Arthritis Res Ther* 9 Suppl 1:S1.
- Calori G.M, Albisetti W, Agus A, et al. 2007. Risk factors contributing to fracture non-unions. *Injury* 38 Suppl 2: S11-18.
- Calori G.M, Philips B, Jeetle S, et al. 2008. Classification of non-union: Need for a new scoring system? *Injury* 39 Suppl 2: S59-63.
- Carragee E.J, Hurwitz E.L, Weiner B.K. 2011. A critical review of recombinant human bone morphogenetic protein-2 trials in spinal surgery: emerging safety concerns and lessons learned. *Sine J* 11(6): 471-491.
- Colnot C, Thomson Z, Miclau T, et al. 2003. Altered fracture repair in the absence of MMP9. *Development* 130(17): 4123-4133.
- Conway J.D. 2010. Autograft and Nonunions: Morbidity with Intramedullary Bone Graft versus Iliac Crest Bone Graft. *Orthop Clin North Am* 41(1): 75-84.
- Delos D, Yang X, Ricciardi B.F, et al. 2008. The effects of RANKL inhibition on fracture healing and bone strength in a mouse model of osteogenesis imperfecta. *J Orthop Res* 26(2): 153-164.
- Dimitriou R, Mataliotakis G.I, Angoules A.G, et al. 2011. Complications following autologous bone graft harvesting from the iliac crest and using the RIA: A systematic review. *Injury* 42 Suppl 2: S3-15.
- Doi Y, Miyazaki M, Yoshiiwa T, et al. 2011. Manipulation of the anabolic responses with BMP-2 and zoledronic acid in a rat femoral fracture model. *Bone* 49(4): 777-782.

- Farouk O, Krettek C, Miclau T, et al. 1999. Minimally Invasive Plate Osteosynthesis: Does Percutaneous Plating Disrupt Femoral Blood Supply Less Than the Traditional Technique? *J Orthop Trauma* 13(6): 401-406.
- Flick L.M, Weaver J.M, Ulrich-Vinther M, et al. 2003. Effects of receptor activator of NFkappaB (RANK) signaling blockade on fracture healing. *J Orthop Res* 21(4): 676-684.
- Flierl M.A, Smith W.R, Mauffrey C, et al. 2013. Outcomes and complication rates of different bone grafting modalities in long bone fracture nonunions: a retrospective cohort study in 182 patients. *J Orthop Surg Res* 9;8:33.
- Friedlander G.E, Perry C.R, Cole J.D, et al. 2001. Osteogenic protein-1 (bone morphogenetic protein-7) in the treatment of tibial nonunions. *J Bone Joint Surg Am* 83-A Suppl 1(Pt2): 151-158.
- Frost H.M, Jee W.S 1992. On the rat model of human osteopenias and osteoporosis. *Bone Miner* 18(3): 227-236.
- Frölke J.P.M, Patka P. 2007. Definition and classification of fracture non-unions. *Injury* 38 Suppl 2: S19-22.
- Gazdag A.R, Lane J.M, Glaser D, Forster R.A. 1995. Alternatives to Autogenous Bone Graft: Efficacy and Indications. *J Am Acad Orthop Surg* 3(1): 1-8.
- Giannoudis P.V, Faour O, Goff T, et al. 2011. Masquelet technique for the treatment of bone defects: Tips-tricks and future directions. *Injury* 42(6): 591-598.
- Giannoudis P.V, Kanakaris N.K, Einhorn T.A. 2007. Interaction of bone morphogenetic proteins with cells of the osteoclast lineage: review of the existing evidence. *Osteoporos Int* 18(12): 1565-1581.
- Goldberg V.M. 2000. Selection of bone grafts for revision total hip arthroplasty. *Clin Orthop* (381): 68-76.
- Govender S, Csimma C, Genant H.K, et al. 2002. Recombinant human bone morphogenetic protein-2 for treatment of open tibial fractures: a prospective, controlled, randomized study of four hundred and fifty patients. *J Bone Joint Surg Am* 84-A(12): 2123-2134.
- Greenwald S.A, Boden S.D, Goldberg V.M, et al. Bone-graft substitutes: Facts, fictions & applications. *Orthopaedic Device Forum. AAOS 73rd Annual Meeting, Chicago* 2006.
- Gruber H.E, Gettys F.K, Montijo H.E, et al. 2013. Genomewide Molecular and Biologic Characterization of Biomembrane Formation Adjacent to a Methacrylate Spacer in the Rat Femoral Segmental Defect Model. *J Orthop Trauma* 27(5): 290-297.
- Hamson G, Fogelman I. 2012. Clinical role of bisphosphonate therapy. *Int J Womens Health* 4: 455-469.
- Itoh K, Udagawa N, Katagiri T, et al. 2001. Bone morphogenetic protein 2 stimulates osteoclast differentiation and survival supported by receptor activator of nuclear factor-kappa B ligand. *Endocrinology* 142(8): 3656-3662.
- Kanatani M, Sugimoto T, Kaji H, et al. 1995. Stimulatory effect of bone morphogenetic protein-2 on osteoclast-like cell formation and bone-resorbing activity. *J Bone Miner Res* 10(11): 1681-1690.

- Karger C, Kishi T, Schneider L, et al. 2012 Treatment of posttraumatic bone defects by the induced membrane technique. *Orthop Traumatol Surg Res* 98(1): 97-102.
- Kozloff K.M, Volakis L.I, Manni J.C, Caird M.S. 2010. Near-infrared fluorescent probe traces bisphosphonate delivery and retention in vivo. *J Bone Miner Res* 25(8): 1748-1758.
- Lad S.P, Bagley J.H, Karikari I.O, et al. 2013. Cancer after spinal fusion: the role of bone morphogenetic protein. *Neurosurgery* 73(3): 440-449.
- Landesberg R, Eisig S, Fennoy I, Siris E. 2009. Alternative indications for bisphosphonate therapy. *J Oral Maxillofac Surg* 67(5 Suppl): 27-34.
- Lasanianos N.G, Kanakaris N.K, Giannoudis P.V. 2010. Current management of long bone large segmental defects. *Orthop Trauma* 24(2): 149-163.
- Little D.G, McDonald M, Bransford R, et al. 2005. Manipulation of the Anabolic and Catabolic Responses With OP-1 and Zoledronic Acid in a Rat Critical Defect Model. *J Bone Miner Res* 20(11):2044-2052.
- Little D.G, Ramachandran M, Schindeler A. 2007. The anabolic and catabolic responses in bone repair. *J Bone Joint Surg Br* 89(4): 425-433.
- Masquelet A.C, Begue T. 2010. The Concept of Induced Membrane for Reconstruction of Long Bone Defects. *Orthop Clin North Am* 41(1): 27-37.
- Mast J, Jakob R, Ganz R. 1989. *Planning and Reduction Technique in Fracture Surgery*. 1st edition. Springer-Verlag Berlin, Heidelberg.
- Mathavan N, Bosemark P, Isaksson H, Tägil M. 2013. Investigating the synergistic efficacy of BMP-7 and zoledronate on bone allografts using an open rat osteotomy model. *Bone* 56(2): 440-448.
- McDonald M.M, Dulai S, Godfrey C, et al. 2008. Bolus or weekly zoledronic acid administration does not delay endochondral fracture repair but weekly dosing enhances delays in hard callus remodeling. *Bone* 43(1): 653-662.
- Miller J.D, McCreadie B.R, Alford A.I, et al. 2007. Form and Function of Bone. In: *Einhorn T.A, O'Keefe R.J, Buckwalter J.A, eds. Orthopaedic Basic Science, Foundations of Clinical Practice*. 3rd ed. Rosemont, IL: American Academy of Orthopaedic Surgeons: pp 129-159.
- Nakamura H. 2007. Morphology, Function and Differentiation of Bone Cells. *J Hard Tissue Biol* 16(1): 15-22.
- Newman J.T, Stahel P.F, Smith W.R, et al. 2008. A New Minimally Invasive Technique for Large Volume Bone Graft Harvest for Treatment of Fracture Nonunions. *Orthopedics* 31(3): 257-261.
- Palmer S.H, Gibbons C.L, Athanasou N.A. 1999. The pathology of bone allograft. *J Bone Joint Surg Br* 81(2): 333-335.
- Pelissier P, Masquelet A.C, Bareille R, et al. 2004. Induced membranes secrete growth factors including vascular and osteoinductive factors and could stimulate bone regeneration. *J Orthop Res* 22(1): 73-79.
- Perumal V, Roberts C.S. 2007 Factors contributing to nonunion of fractures. *Curr Orthop* 21: 258-261.
- Proff P, Römer P. 2009. The molecular mechanism behind bone remodeling: a review. *Clin Oral Investig* 13(4): 355-362.

- Rogers M.J, Crockett J.C, Coxon F.P, Mönkkönen J. 2011. Biochemical and molecular mechanisms of action of bisphosphonates. *Bone* 49(1): 34-41.
- Russell R.G.G, Watts N.B, Ebetino F.H, Rogers M.J. 2008. Mechanisms of action of bisphosphonates: similarities and differences and their potential influence on clinical efficacy. *Osteoporos Int* 19(6): 733-759.
- Sandhu H.S, Khan S.N. 2002. Animal models for preclinical assesment of bone morphogenetic proteins in the spine. *Spine* 15;27(16 Suppl 1): 32-38.
- Saunders M.M, Burger R.B, Kalantari B, et al. 2010. Development of a cost-effective torsional unit for rodent long bone assessment. *Med Eng Phys* 32(7): 802-807.
- Schindeler A, McDonald M.M, Bokko P, Little D.G. 2008. Bone remodeling during fracture repair: The cellular picture. *Semin Cell Dev Biol* 19(5): 459-466.
- Sengupta P. 2013. The Laboratory Rat: Relating Its Age With Human´s. *Int J Prev Med* 4(6): 624-630.
- Sigua-Rodriguez E.A, da Costa Ribeiro R, de Brito A.C, et al. 2014. Bisphosphonate-related osteonecrosis of the jaw: a review of the literature. *Int J Dent* 2014: 192320.
- Sykaras N, Opperman L.A. 2003. Bone morphogenetic proteins (BMPs): how do they function and what can they offer the clinician? *J Oral Sci* 45(2): 57-73.
- Tzioupis C, Giannoudis P.V. 2007. Prevalence of long bone non-unions. *Injury* 38 Suppl 2: S3-9.
- Tägil M, McDonald M.M, Morse A, et al. 2010. Intermittent PTH(1-34) does not increase union rates in open rat femoral fractures and exhibits attenuated anabolic effects compared to closed fractures. *Bone* 46(3): 852-859.
- Urist M.R, Strates B.S. 1971. Bone morphogenetic protein. *J Dent Res* 50(6): 1392-1406.
- Urist M.R. 1965. Bone: Formation by Autoinduction. *Science* 12;150(3698): 893-899.
- USFDA. Guidance Document for the Preparation of Investigational Device Exemptions and Pre-market Approval Applications for Bone Growth Stimulator Devices. Rockville, MD: United States Food and Drug Administration; 1988.
- Wozney J.M, Rosen V. 1998. Bone morphogenetic protein and bone morphogenetic protein gene family in bone formation and repair. *Clin Orthop Relat Res* (346): 26-37.
- Yu N.Y, Schindeler A, Tägil M, et al. 2012. Application of BMPs and bisphosphonates in improving bone fracture healing. *Front Biosci (Elite Ed.)* 1;4: 2647-2653.