



# LUND UNIVERSITY

## Preterm intraventricular haemorrhage - Effects of extracellular haemoglobin

Sveinsdottir, Snjolaug

2014

[Link to publication](#)

*Citation for published version (APA):*

Sveinsdottir, S. (2014). *Preterm intraventricular haemorrhage - Effects of extracellular haemoglobin*. [Doctoral Thesis (compilation), Paediatrics (Lund)]. Paediatrics, Faculty of Medicine, Lund University.

*Total number of authors:*

1

### General rights

Unless other specific re-use rights are stated the following general rights apply:

Copyright and moral rights for the publications made accessible in the public portal are retained by the authors and/or other copyright owners and it is a condition of accessing publications that users recognise and abide by the legal requirements associated with these rights.

- Users may download and print one copy of any publication from the public portal for the purpose of private study or research.
- You may not further distribute the material or use it for any profit-making activity or commercial gain
- You may freely distribute the URL identifying the publication in the public portal

Read more about Creative commons licenses: <https://creativecommons.org/licenses/>

### Take down policy

If you believe that this document breaches copyright please contact us providing details, and we will remove access to the work immediately and investigate your claim.

LUND UNIVERSITY

PO Box 117  
221 00 Lund  
+46 46-222 00 00

# Preterm Intraventricular Haemorrhage

Effects of extracellular haemoglobin

Snjólaug Sveinsdóttir



**LUND**  
UNIVERSITY

## **DOCTORAL DISSERTATION**

by due permission of the Faculty of Medicine, Lund University, Sweden.

To be defended at Belfragesalen, D15, BMC, Lund, Sweden, May 24<sup>th</sup>,  
2014 at 10:00.

### **Faculty opponent**

Professor Axel Heep, School of Clinical Sciences Bristol University,  
Bristol, United Kingdom

Organization LUND UNIVERSITY Division of Paediatrics Department of Clinical Sciences		Document name Doctoral dissertation	
		Date of issue May 24 <sup>th</sup> 2014	
Author(s) Snjólaug Sveinsdóttir		Sponsoring organization	
Title and subtitle Preterm Intraventricular haemorrhage- effects of extracellular haemoglobin			
Abstract <p>Intraventricular haemorrhage (IVH) is the most common brain lesion in preterm infants. The prognosis is dire and there is no available therapy to prevent infants from developing either post-haemorrhagic ventricular dilatation (PHVD) or serious neurological disability. Mechanisms leading to brain damage and hydrocephalus following IVH are complex and incompletely understood.</p> <p>Our working hypothesis is that cell-free Hb and its metabolites act as causal initiators of inflammation following IVH, constituting a critical up-stream event eventually leading to periventricular cell death. We further hypothesize that inflammation of the choroid plexus alters the ability of the epithelium to maintain CSF homeostasis contributing to the formation of post-haemorrhagic hydrocephalus. To test the hypothesis we used the rabbit pup model of preterm IVH. We found that the formation of metHb is a key up-stream event leading to inflammation following IVH and there is extensive damage to the choroid plexus epithelium, which develops over time. There is a distinct inflammatory and cellular response induced by haemoglobin metabolites and alteration of aquaporin expression, a key transmembrane protein. Injection or co-incubation with haptoglobin, a haemoglobin scavenger, reduces or reverses the effects of haemoglobin both <i>in vivo</i> and <i>in vitro</i>.</p> <p>In conclusion; following IVH released cell free haemoglobin, metabolized to metHb and hemin, constitutes a causal up-stream initiator of inflammation and cellular damage. Scavenging or removal of haemoglobin might be an efficient and feasible approach to reduce brain damage following preterm IVH.</p>			
Key words: Preterm, IVH, Hydrocephalus, Haemoglobin, Inflammation, Haptoglobin, Choroid plexus			
Classification system and/or index terms (if any)			
Supplementary bibliographical information			Language English
ISSN and key title: 1652-8220		ISBN: 978-91-87651-88-5	
Recipient's notes		Number of pages	Price
		Security classification	

Signature \_\_\_\_\_ Date \_\_\_\_\_

# Preterm Intraventricular Haemorrhage

Effects of extracellular haemoglobin

Snjólaug Sveinsdóttir



**LUND**  
UNIVERSITY



*When men are sick, they are sick in fear. They take everything they need from you and as a doctor it is your job to give it, to comfort them, to hold their hand.*

*But children are sick just as they live - in hope. They don't know what's happening, so they expect nothing, they don't ask you to hold their hand – but you end up needing them to hold yours.*

*The Tiger's Wife by Téa Obreht*

To my grandfather Kjartan who watched the stars with me when I was a little girl and told me I could be one of them.

To my father Sveinn, in whose footsteps I have gladly followed

To my mother Lára for unconditional love

**Cover design: Sóley Þórisdóttir**

This thesis was supported with grants from  
Linnea and Josef Carlssons stiftelse  
Drottning Silvias Jubileumsfond

Copyright © Snjólaug Sveinsdóttir

Lund University, Faculty of Medicine Doctoral Dissertation Series 2014:62  
ISBN 978-91-87651-88-5  
ISSN 1652-8220

Printed in Sweden, Lund University  
Lund 2014

# Contents

## Table of Contents

<b>CONTENTS</b>	<b>1</b>
<b>LIST OF PUBLICATIONS</b>	<b>5</b>
<b>SUMMARY</b>	<b>6</b>
<b>LIST OF ABBREVIATIONS</b>	<b>8</b>
<b>BACKGROUND</b>	<b>9</b>
<b>PRETERM INTRAVENTRICULAR HAEMORRHAGE</b>	<b>9</b>
INTRAVENTRICULAR HAEMORRHAGE – AETIOLOGY	9
DIAGNOSIS AND CLASSIFICATION OF IVH	10
POST-HAEMORRHAGIC VENTRICULAR DILATATION (PHVD)	11
<b>THE CHOROID PLEXUS, PRODUCTION OF CSF AND THE EPENDYMA</b>	<b>12</b>
PRODUCTION OF CSF	13
EPENDYMAL BREAKDOWN	14
<b>MECHANISMS OF BRAIN INJURY FOLLOWING IVH</b>	<b>15</b>
GLUTAMATE	15
THROMBIN	15
HAEMOGLOBIN	16
INFLAMMATION	17
<b>RABBIT PUP MODEL OF IVH</b>	<b>18</b>
ULTRASOUND IMAGING OF IVH	19
<b>HYPOTHESIS AND AIMS</b>	<b>21</b>
HYPOTHESIS	21
AIMS	21



<b>MATERIAL AND METHODS</b>	<b>23</b>
<b>THE RABBIT PUP MODEL</b>	<b>23</b>
<b>CSF FROM PRETERM INFANTS</b>	<b>27</b>
<b><i>IN VITRO</i> EXPERIMENTS</b>	<b>27</b>
<b>LABORATORY ANALYSIS</b>	<b>29</b>
<b>STATISTICS</b>	<b>33</b>
PAPER I	33
PAPER II-IV	33
<b>RESULTS AND COMMENTS</b>	<b>34</b>
<b>I. APPLICATION OF HIGH FREQUENCY ULTRASOUND IN THE RABBIT PUP MODEL OF IVH</b>	<b>34</b>
RESULTS	34
COMMENTS	35
<b>II. METHAEMOGLOBIN INDUCES INFLAMMATION FOLLOWING PRETERM IVH</b>	<b>36</b>
RESULTS	36
COMMENTS	37
<b>III. EXPRESSION OF AQUAPORIN 1 AND 5 IN THE CHOROID PLEXUS FOLLOWING PRETERM IVH</b>	<b>38</b>
RESULTS	38
COMMENTS	39
<b>IV. HAEMOGLOBIN, A MEDIATOR OF INFLAMMATION AND DAMAGE IN THE CHOROID PLEXUS FOLLOWING IVH</b>	<b>40</b>
RESULTS	40
COMMENTS	42
<b>GENERAL DISCUSSION AND FUTURE PERSPECTIVES</b>	<b>44</b>
GENERAL DISCUSSION	44
FUTURE PERSPECTIVES	45
<b>SVENSK SAMMANFATTNING</b>	<b>47</b>
<b>ÍSLENSK SAMANTEKT</b>	<b>49</b>
<b>ACKNOWLEDGEMENTS</b>	<b>52</b>





# List of publications

This thesis is based on the following papers, which are referred to in the text by their roman numerals (I-IV)

- I. Sveinsdottir S, Cinthio M, Ley D. High-frequency ultrasound in the evaluation of cerebral intraventricular haemorrhage in preterm rabbit pups. *Ultrasound in medicine & biology* 2012;38:423-431
  
- II. Gram M, Sveinsdottir S, Ruscher K, Hansson SR, Cinthio M, Åkerström B, Ley D. Hemoglobin induces inflammation after preterm intraventricular hemorrhage by methemoglobin formation. *J Neuroinflammation*. 2013 Aug 6;10:100. MG and SS equal contribution.
  
- III. Sveinsdottir S, Gram M, Cinthio M, Sveinsdottir K, Mörgelin M and Ley D. Altered expression of aquaporin 1 and 5 in the choroid plexus following preterm intraventricular hemorrhage. *In revision*. SS and MG equal contribution.
  
- IV. Gram M, Sveinsdottir S, Cinthio M, Sveinsdottir K, Hansson S, Åkerström B, Mörgelin M, and Ley D. Free haemoglobin - mediator of inflammation, cell death and structural damage in the choroid plexus following preterm intraventricular haemorrhage. *In manuscript*. MG and SS equal contribution.

# Summary

Intraventricular haemorrhage (IVH) is the most common brain lesion in preterm infants and is most commonly seen in the sickest children, with 15-20% of very preterm infants developing IVH. The mortality of infants with severe IVH is 20-50 % in the neonatal period and over 50 % of surviving infants develop post-haemorrhagic ventricular dilatation (PHVD) and 40-80 % develop severe neurological impairment, mainly cerebral palsy and mental retardation. To date there is no available therapy to prevent infants from developing either hydrocephalus or serious neurological disability. Infants who develop hydrocephalus receive a life-long ventriculo-peritoneal shunt, which is an efficient means of preventing ventricular distension but does not reduce neurological impairment.

Mechanisms leading to brain damage and hydrocephalus following IVH are complex and incompletely understood. However, inflammation and oxidative stress have been identified as two major culprits leading to irreversible damage in the vulnerable immature periventricular brain matter. Dysfunction of cerebrospinal fluid (CSF) production contributes to the development of PHVD but the exact molecular mechanisms remain unknown. The choroid plexus, which produces the CSF, is adjacent to the origin of IVH and is the first organ to encounter the extravasated blood. The subsequent haemolysis of red blood cells causes release of cell-free haemoglobin (Hb), which will with time further degrade releasing the toxic substances hemin, free iron, and various ROS (reactive oxygen species). Metabolites of cell-free Hb have been identified as an initiator of inflammation in the context of adult cerebral haemorrhage and inflammation of the ependyma has been shown to cause alterations of the blood-brain barrier (BBB).

Our working hypothesis is that cell-free Hb and its metabolites act as causal initiators of inflammation following IVH, constituting a critical up-stream event eventually leading to periventricular cell death. We further hypothesize that inflammation of the choroid plexus alters the ability of the

epithelium to maintain CSF homeostasis contributing to the formation of post-haemorrhagic hydrocephalus.

To test the hypothesis we used the rabbit pup model of preterm IVH. It is excellently suited since rabbit pups have a germinal matrix with vulnerable capillary meshwork prone to rupture and have CNS maturation comparable to a 28-30 weeks preterm human infant. The application of high-frequency ultrasound enabled accurate measurements of haemorrhagic size and distension as well as ultrasound guided intraventricular injections and CSF sampling.

Following IVH there is a release of free haemoglobin in its reduced form, oxyHb, into the intraventricular space. OxyHb autooxidises to metHb over time and the concentration of the key inflammatory cytokine TNF- $\alpha$  is highly correlated to that of metHb. In an astrocyte cell culture, metHb induces TNF- $\alpha$  production whereas oxyHb does not. We therefore conclude that the formation of metHb is a key up-stream event leading to inflammation following IVH.

Following IVH there is extensive damage to the choroid plexus epithelium, which develops over time. There is a distinct inflammatory and cellular response induced by haemoglobin metabolites. Injection or co-incubation with haptoglobin, a haemoglobin scavenger, reduces or reverses the effects of haemoglobin both *in vivo* and *in vitro*.

Aquaporins (AQP) are water transporting transmembrane proteins playing a central role in CSF production. Following IVH the expression of AQP1, the key AQP in the choroid plexus, is down-regulated whereas the expression of AQP5, not previously described in the choroid plexus, is up-regulated. This probably represents an adaptive response to insult and might be of importance in understanding the development of PHVD.

In conclusion; following IVH released cell free haemoglobin, metabolized to metHb and hemin, constitutes a causal up-stream initiator of inflammation and cellular damage. Scavenging or removal of haemoglobin might be an efficient and feasible approach to reduce brain damage following preterm IVH.

# List of abbreviations

AQP	Aquaporin
BBB	Blood-brain barrier
CNS	Central nervous system
CSF	Cerebrospinal fluid
CV	Coefficient of variation
CyanHb	Cyanhaemoglobin
EM	Electron microscopy
Hb	Haemoglobin
HCPEpiC	Human primary choroid plexus epithelial cells
HFU	High-frequency ultrasound
HO	Heme oxygenase
IHC	Immunohistochemistry
IL-1	Interleukin-1
i.p.	Intraperitoneal
i.v.	Intravenous
IVH	Intraventricular haemorrhage
MetHb	Methaemoglobin
NMDA	N-methyl-D-aspartate
OxyHb	Oxyhaemoglobin
PBS	Phosphate-buffered saline
PHVD	Post-haemorrhagic ventricular dilatation
RBC	Red blood cells
ROS	Reactive oxygen species
TGF- $\beta$	Transforming growth factor- $\beta$
TLR	Toll-like receptor
TNF- $\alpha$	Tumour necrosis factor- $\alpha$
VP	Ventriculoperitoneal

# Background

## Preterm intraventricular haemorrhage

Intraventricular haemorrhage (IVH) is the most common brain lesion in preterm infants and is a problem of enormous importance in neonatal medicine. It occurs in 15-25 % of extremely preterm infants<sup>1-4</sup> and it is the most common cause for poor developmental outcome in this population. The mortality of infants with severe IVH is 20-50 % in the neonatal period and 40-80 % of survivors are diagnosed with severe neurodevelopmental disability<sup>5-7</sup>. Over 50 % of infants diagnosed with severe IVH develop post-haemorrhagic ventricular dilatation (PHVD) and most require progressively invasive measures to alleviate the intracranial pressures ranging from serial lumbar punctures to temporal intraventricular reservoirs to permanent ventriculoperitoneal (VP) shunts. Children with VP shunts are more likely to develop complications, such as shunt malfunction and shunt infection than children with hydrocephalus of other causes requiring further surgical interventions<sup>8</sup>. There is currently no available therapy to prevent infants from developing either hydrocephalus or serious neurological disability following IVH.

### **Intraventricular haemorrhage – Aetiology**

IVH usually initiates in the periventricular germinal matrix located between the ventricular wall and the caudate nucleus in the thalamostriate groove. This area consists of rapidly dividing neuronal and glial progenitor cells embedded in a mesh of poorly supported fragile vessels which makes it highly vulnerable to haemorrhage<sup>9,10</sup>. This area decreases in thickness from 24 weeks of gestation and has completely disappeared by 35 weeks of gestation<sup>11</sup>. Most haemorrhages occur during the first three days of life and



are associated with decreasing gestational ages and hemodynamic instability

12

### Diagnosis and classification of IVH

In preterm infants the diagnosis of IVH is readily made by a bedside routine cranial ultrasound and it has been used both as a prognostic tool as well as an indicator for intervention<sup>13, 14</sup>. The degree of IVH is graded according to the Papile classification, which is based on the extent of the bleeding as well as ventricular dilatation (Figure 1)<sup>15</sup>. Grade I is confined to the subependymal germinal matrix with no blood in the ventricles. Grade II is a germinal matrix bleeding which extends into the lateral ventricles but only comprises less than 50 % of the ventricular volume. Grade III is a bleeding, which comprises over 50 % of the ventricular volume and with ventricular distension. Grade IV is an IVH with haemorrhage extension into the brain parenchyma but may also represent a haemorrhagic infarction.

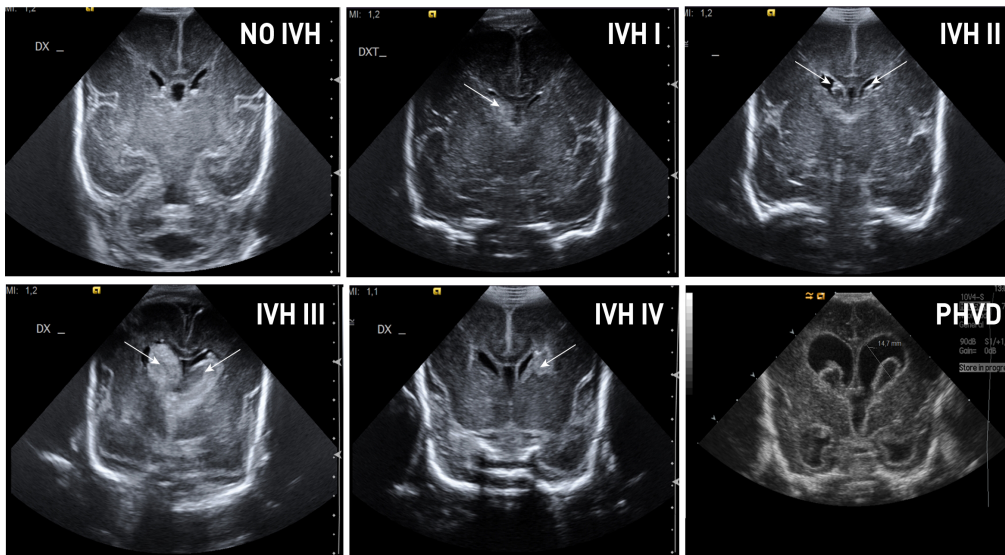


Figure 1. Cranial ultrasound from preterm infants.

Traditionally grade III and IV have been considered severe IVH and the long-term neurodevelopmental prognosis for infants diagnosed with severe IVH is abysmal<sup>2, 7, 16</sup>. Even though infants with IVH grade I and II fare much better than those with grade III and IV, recent studies have shown that grade I and II are also associated with adverse neurodevelopmental outcomes<sup>3, 4, 17</sup>.

### **Post-haemorrhagic ventricular dilatation (PHVD)**

Following IVH, infants are monitored with cranial ultrasound for signs of post-haemorrhagic ventricular dilatation (PHVD) (Fig 1). About 50 % of infants with severe IVH develop PHVD and half of those become shunt dependant<sup>6, 18, 19</sup>. The linear dimensions of the ventricles in preterm infants with and without IVH are well characterized and in use in clinical practice<sup>20, 21</sup> and decisions whether to intervene are based upon measurements of the ventricles.

#### *Mechanisms of PHVD*

Cellular and molecular mechanisms leading to PHVD following IVH are poorly understood but the risk of developing PHVD has been related to the amount of blood seen in the ventricles following IVH<sup>22</sup>. Post-haemorrhagic hydrocephalus has been explained by mechanistic models, such as clogging of the cerebral aqueduct or interventricular foramina by coagulated blood leading to an accumulation of cerebrospinal fluid (CSF). However, this notion has very little scientific support<sup>23</sup>. PHVD has also been attributed to malfunction of the microscopic arachnoid granules, which are precursors to the arachnoidal villi, which resorb excess CSF to the venous system in the adult brain<sup>24</sup>. Experimental data have been unable to support this notion mainly due to the fact that arachnoid granulations are not seen in the foetal brain until late in pregnancy<sup>25</sup>. To date the exact mechanisms of CSF absorption in foetal life remain unknown.

There has been much speculation that fibrosis of the ependymal lining following IVH might contribute to the hydrocephalus formation. Normal function of the cilia of the ependymal cells is essential for the normal flow of CSF<sup>26, 27</sup>. It has been suggested through animal models that transforming growth factor- $\beta$  (TGF- $\beta$ ) is a key cytokine leading to ependymal fibrosis following IVH<sup>28, 29</sup> but this has not been confirmed in human subjects.

Contrary, a study analysing CSF from hydrocephalic neonates showed that vascular endothelial growth factor was elevated in PHVD but TGF-  $\beta$  was not<sup>30</sup>.

Inflammation is a key component leading to ependymal damage following IVH<sup>31</sup>. CSF from infants with PHVD contains high concentrations of pro-inflammatory cytokines<sup>32</sup>. Recently a study established a causal link between inflammation and disrupted ependymal ciliogenesis<sup>33</sup> leading to hydrocephalus formation. The role of inflammation in brain damage and BBB disruption following IVH will be further discussed below.

To date, the main focus has been on dysfunction of CSF absorption but that might be an over-simplistic view on the pathogenesis of PHVD. Following IVH there is an increased protein content in the CSF, which may result in increasing production of CSF. Indeed, in an experimental model of hydrocephalus, an intraventricular infusion of hyperosmolar dextran did produce hydrocephalus<sup>34</sup>. However, it is unclear what role over-production of CSF plays in the established hydrocephalus.

## The Choroid Plexus, Production of CSF and the Ependyma

The choroid plexuses are a collection of villi composed of a single layer of highly specialized epithelial cells overlying a core of intercellular matrix and fenestrated capillaries that protrude into the ventricles of the brain. The largest is located in the floor of the lateral ventricles, right adjacent to the germinal matrix. It is therefore the first organ to encounter extravasal blood following germinal matrix haemorrhage. Its main function is the production and homeostasis of CSF<sup>35</sup>. The choroid plexus is a highly vascularized structure, containing fenestrated capillaries allowing unhindered movement of water and small molecules into the stroma. The choroid plexus epithelial cells are highly polarized with tight junctions on the apical side facing the ventricles but allowing free passage of molecules from the surrounding

stroma into the cells<sup>35</sup>. The choroid plexuses form part of the blood-brain barrier, which is composed of cerebral endothelial cells joined by virtually impenetrable tight junctions, which allows the epithelial cells of the choroid plexuses to regulate the passage of molecules between the blood and the CSF.

## **Production of CSF**

On the ventricular side of the epithelial cells there are a number of highly specialized transmembrane proteins that tightly regulate the composition of the CSF regarding osmolality, electrolyte content and nutrients, which is fundamental for the optimal function of the central nervous system<sup>36</sup>. The CSF is actively secreted by the choroid plexus epithelial cells with a turnover rate of about six hours in humans<sup>37</sup>. The composition of the CSF is very similar to that of plasma with the important exception of protein content, which is about 300 times lower in CSF as compared to plasma<sup>36</sup>. There is a marked developmental shift in the choroid plexus permeability during fetal life towards higher water content of the CSF at later gestational age<sup>38,39</sup> and there is evidence that the regulation of CSF composition is very important to normal brain development<sup>40</sup>.

### *Aquaporins*

Aquaporins (AQP) are a family of transmembrane channel proteins, which facilitate transport of water and solutes across membranes<sup>41</sup>. A number of AQPs have been described in the brain, e.g. AQP1, 3, 4, 5, 8 and 9<sup>42</sup>, and have been assigned to different cell types. There is mounting evidence that in order to regulate the CSF composition, the epithelial cells of the choroid plexus utilize the transmembrane proteins of the AQP family<sup>43,44</sup>. AQP1 is described as the key AQP in the choroid plexus and has an important role as a water transporter in CSF production both during physiological and pathological conditions<sup>42,43</sup>. The choroid plexus exhibits the highest concentration of AQP1 of any human tissue further indicating its importance<sup>45</sup>. There is a paucity of studies addressing the role of AQP1 in hydrocephalus and a recent review on the topic only found five studies addressing the issue<sup>46</sup>. In the study by Paul et al.<sup>47</sup>, using a rat model of congenital hydrocephalus, a down-regulation of AQP1 was observed. Conversely, the study by Mao et al.<sup>48</sup>, using kaolin-induced hydrocephalus in rats, did not show any changes in the expression of AQP1. In AQP1

deficient mice with hydrocephalus there was a decrease in CSF production as compared to wild type mice <sup>49</sup>, suggesting the importance of AQP1 in CSF homeostasis.

AQP 4 is the most abundant and well-studied aquaporin in the brain and is mainly localized on the cytoplasmic membrane and end-feet of astrocytes, where it plays a crucial role in regulating water flow into and out of the brain. AQP4 has been shown to be involved in brain swelling and oedema following ischemia <sup>50</sup> and has been shown to be up-regulated in a rat model of hydrocephalus <sup>48</sup>. Modulation of AQP4 expression is associated with improved functional outcome following cerebral haemorrhage <sup>51</sup>. The role and localization of AQP4 in the choroid plexus is currently unknown.

AQP5 has been described in rat brain astrocytes <sup>52</sup> but the role or presence of AQP5 in the choroid plexus has not been described. However, AQP5 is abundantly expressed in several other organs with secretory functions, such as the lacrimal glands <sup>53</sup>, salivary glands <sup>54</sup> and lung <sup>55</sup>. The main function of AQP5 is to regulate water permeability <sup>56</sup>, paracellular water transfer <sup>57</sup> and cell cytoskeleton organization and stabilization <sup>58</sup>. Furthermore, the expression of AQP5 in astrocytes is differentially regulated during metabolic and traumatic brain injury <sup>52</sup>.

### **Ependymal breakdown**

The ependyma lines the ventricles controlling the interface between the CSF and the brain parenchyma and the choroid plexus epithelium is a direct continuum of the ependymal lining. The ependymal breakdown is a key event in the ensuing periventricular brain damage following IVH <sup>59</sup> and an understanding of the molecular mechanisms leading to ependymal/choroid plexus damage is of utmost importance.

The exact mechanisms leading to epithelial cell damage following IVH remain unknown but direct toxicity and oxidative stress of blood components <sup>60</sup> has been shown to cause BBB disruption and systemic <sup>61</sup> as well as intraventricular inflammation <sup>31</sup>.

## Mechanisms of brain injury following IVH

Mechanisms leading to brain injury following IVH are complex and incompletely understood. Following IVH there is an immediate damage due to mass effect of the blood clot. However, secondary brain injury, which develops over time, is by far more important in determining the final degree of brain damage. The immature brain is more vulnerable to the detrimental effects of blood components as compared to the adult brain<sup>62</sup> but as most studies on this issue are done in adult models of intracerebral haemorrhage the mechanisms in the immature brain are unknown. There are three main mechanisms that have been identified as initiators of secondary brain damage.

### **Glutamate**

With cell death, mainly due to red blood cell lysis there is a massive release of glutamate into the extracellular space resulting in glutamate-mediated excitotoxicity<sup>63</sup>. Glutamate acts directly on neuronal N-methyl-D-aspartate (NMDA) receptors inducing neuronal injury and cell death<sup>64</sup>.

### **Thrombin**

The formation of blood clot after haemorrhage releases large amounts of thrombin. Thrombin has been shown to induce brain injury following adult intracerebral haemorrhage<sup>64, 65</sup> and injection of thrombin into the striatum of neonatal mice results in greater damage than injection with whole blood or saline<sup>62</sup>. It exacerbates brain oedema<sup>66</sup> causes inflammatory cell infiltration and direct neuronal injury<sup>67</sup>. Treatment with thrombin inhibitors has been shown to diminish brain damage in adult models of haemorrhage<sup>68, 69</sup> but not in neonatal model of intracerebral haemorrhage<sup>70</sup>.

## Haemoglobin

Haemorrhage causes a release of red blood cells into the intraventricular space, which subsequently haemolyse releasing extracellular haemoglobin (Hb). Intracerebral injection of red blood cells show a lag of 24 hours before signs of brain oedema and damage surrounding the hematoma emerge whereas intracerebral injection of lysed red blood cells causes immediate effects<sup>71</sup>. Following haemolysis of red blood cells the haemoglobin released is in its reduced form, oxyHb. OxyHb (*i.e.*, ferrous ( $\text{Fe}^{2+}$ ) Hb) can undergo spontaneous auto-oxidation in which metHb (*i.e.*, ferric ( $\text{Fe}^{3+}$ ) Hb) and superoxide are formed. Downstream reactions lead to the formation of ferryl ( $\text{Fe}^{4+}$ ) Hb, ROS, and free heme. The subsequent degradation of heme results in the generation of bilirubin, carbon monoxide, and free iron<sup>72</sup>. Heme and iron are highly neurotoxic generating free radicals and adding to the oxidative damage<sup>73,74</sup> and cell death.

Cell-free Hb has been proposed as an initiator of pro-inflammation, chemotaxis, and necrosis/apoptosis in intracranial haemorrhage<sup>64,75</sup>. Studies have indicated that metabolites of extracellular Hb have pro-inflammatory effects in microglia, endothelial cells, and macrophages and indeed may behave as activators of innate immunity, *i.e.*, as ligands of the Toll-like receptor (TLR) system<sup>76-78</sup>.

### *Haemoglobin clearance*

Cell free haemoglobin binds to haptoglobin forming an inert complex to be phagocytized by CD-163 positive macrophages<sup>79</sup>. The haptoglobin-CD 163 scavenging system is the body's most important detoxification system for free haemoglobin. Haptoglobin is an acute phase glycoprotein produced mainly in the liver in response to systemic inflammation and haemolysis<sup>80</sup>. Even though the plasma haptoglobin levels are relatively high the concentration of haptoglobin in the brain is very low. In a recent study in human adults the resting state capacity of the intrathecal CD163-haptoglobin-Hb clearing system was 50,000-fold lower than that of the circulation and this system was quickly saturated following subarachnoidal haemorrhage with a residual inability to deal effectively with extracellular Hb<sup>81</sup>. Another recent study found oligodendroglia to be the principal source of brain haptoglobin but this study also found that the haptoglobin scavenging system quickly saturates following brain haemorrhage<sup>82</sup>. The normal circulating levels of haptoglobin are reported to be very low in

preterm infants, indicating a heightened vulnerability to extracellular Hb<sup>83</sup>. To date, the concentration of intraventricular haptoglobin in preterm infants has not been determined, but it is reasonable to assume that it is extremely low.

There are other systems for elimination of haemoglobin derivatives in the brain. Hemopexin binds to heme with a high affinity and the hemopexin-heme complexes are readily endocytosed by CD-91 positive macrophages<sup>84</sup>. Heme is further degraded by phagocytotic cells containing heme oxygenase (HO) to form biliverdin, carbon monoxide and iron<sup>73</sup> leading to relative iron overload. As oligodendrocytes have the highest levels of intracellular iron of all brain cells and the greatest iron storage capacity through high levels of ferritin, they are most susceptible for oxidative damage due to iron toxicity<sup>64</sup>.

Following IVH the protective systems in the CNS designed to eliminate the cell free haemoglobin and haemoglobin degrading products are overwhelmed. Finding means of controlling haemolysis could be a feasible approach to neuroprotection following IVH.

## **Inflammation**

Inflammation and oxidative stress have been identified as two major culprits leading to irreversible brain damage in the vulnerable immature periventricular brain matter<sup>85</sup>.

Inflammation-infection and hypoxia-ischemia are exogenous and endogenous activators of innate immunity causing astrogliosis and microglial activation resulting in a pro-inflammatory response and generation of ROS that cause cell death and/or maturational arrest in the vulnerable pre-oligodendrocyte population<sup>86</sup>. IVH has been identified as a chief inducer of both inflammation and ischemia in the immature brain and is followed by microglial and astrocytic activation and increased expression of the pro-inflammatory cytokines TNF- $\alpha$  and IL-1 $\beta$  in periventricular brain tissue<sup>87</sup>.

TNF- $\alpha$  signalling is involved in multiple aspects of inflammatory brain injury and results in two major responses: apoptosis and inflammation<sup>88</sup>. TNF- $\alpha$  knockout mice and antisense oligodeoxynucleotide-treated adult rats with cerebral haemorrhage exhibit diminished cell death and inflammation



compared to controls<sup>89,90</sup>. A more recent study showed that treatment with a TNF- $\alpha$  inhibitor is associated with decreased periventricular cell death, gliosis, and neuronal degeneration in the rabbit pup model of preterm IVH<sup>91</sup>.

IL-1 has been identified as a key initiator of ischemic brain injury and the activation of the IL-1 receptor initiates the IL-1 related pathway<sup>92</sup> initiating release of pro-inflammatory cytokines such as IL-1  $\beta$ , IL-6 and TNF- $\alpha$ . Currently an ongoing phase II trial treatment with IL-receptor antagonist has shown considerable promise in patients with subarachnoid haemorrhage<sup>93</sup>.

The activation of TLR-4 is believed to play a prominent role in brain damage following adult intracerebral haemorrhage<sup>75</sup> but its importance in the immature brain remains unknown. There are numerous ligands that bind and activate TLR-4 and recently heme was shown to activate TLR-4 in a mouse model of cerebral haemorrhage<sup>78</sup>. Following activation TLR-4 acts through two different intracellular signaling pathways both ultimately leading to NF- $\kappa$ B transcription and ultimately expression of pro-inflammatory cytokines<sup>75</sup>. TLR-4 protein and mRNA expression peak at 3 days after haemorrhage and can be detected in neurons, astrocytes, and predominantly in microglia<sup>94</sup>. The activation of TLR-4 contributes to poor outcome following cerebral haemorrhage in an adult rat model and TLR-4 knockout mice showed less inflammatory response and faster resolution of hematoma than wild type mice in a mouse model of intracerebral haemorrhage<sup>78</sup>.

## Rabbit pup model of IVH

In order to understand the consequences of IVH and to develop treatment strategies to prevent the neurological sequelae of IVH and PHVD it is necessary to utilize an animal model which mimics the effects of preterm IVH. Various animal models have been described, but the characteristic development of PHVD and periventricular white matter damage of the immature brain of premature infants with resulting neurobehavioral deficits have been difficult to accomplish<sup>95</sup>.

The rabbit pup model of preterm cerebral IVH was first described in 1982<sup>96</sup><sup>97</sup> and has more recently been used by a group in the US<sup>87,98</sup>. The rabbit pups have a germinal matrix and develop spontaneous IVH similar to that of

preterm babies as well as PHVD and abnormal neurological function similar to that in cerebral palsy<sup>98</sup>. Rabbits also have a relatively late cerebral development compared to other rodents but an early lung development enabling them to survive in room air following preterm birth. In this animal model the rabbit pups are delivered at gestational day 28/29 (full term 32 days) and at that time point they exhibit brain maturation corresponding to that of a human infant at 28 to 30 weeks of gestation<sup>99</sup>.

In this model the IVH is induced by an intraperitoneal injection of glycerol causing intracranial hypotension and an increased transmural pressure gradient, which predisposes to rupture of the fragile germinal matrix capillaries leading to IVH<sup>97</sup>. This closely resembles the origin of IVH in preterm children, considered to be caused by germinal matrix vessel rupture following intracranial blood pressure fluctuations. Other small animal models of IVH have utilized injection of autologous blood into the ventricles but in these models the characteristic periventricular brain damage with resulting neurobehavioral deficits as well as the development of PHVD is not observed<sup>95</sup>.

### **Ultrasound imaging of IVH**

In preterm infants, cerebral IVH and the resulting PHVD is monitored non-invasively with bedside ultrasound of the brain and used both as a prognostic tool and as an indicator for intervention<sup>13,14</sup>. Optimally, an animal model for IVH should, as in the clinical setting, allow for accurate evaluation of haemorrhage size and extension and for reproducible measurement of degree of ventricular dilatation over time. In addition, an experimental model should ideally allow for repeated sampling of intra-ventricular CSF for monitoring breakdown of the blood clot over time as well as for accurate intra-ventricular injection of study solutions for therapeutic intervention.

In the rabbit pup model the size and distension of the haemorrhage is variable since the amount of blood in the ventricles is the result of a physiological process. Although this mimics what is seen in the preterm infants it diminishes the reproducibility of the model. Therefore, when using rabbit pups it is very important to be able to diagnose and monitor the haemorrhage *in vivo*. Previous reports of this model, ultrasound imaging of cerebral IVH was performed using the Acuson Sequoia C256, Siemens, Germany<sup>87,98</sup>. Obtained ultrasound images provided a crude indication of the

haemorrhage but the resolution of the images did not allow for any accurate measurements.

Accurate measurements of ventricular size following IVH in the preterm rabbit pup model would enhance the usefulness of the model and provide an *in vivo* tool to evaluate the efficacy of intervention.

#### *High-frequency ultrasound*

High-frequency ultrasound (HFU) has been applied in various fields of pre-clinical research including vascular research reproductive medicine and cancer research. It uses high-frequency transducers (30-100 MHz) and can provide high-resolution ultrasound images with microscopic resolutions in experimental systems requiring limited tissue penetration and depth. Early high-frequency ultrasound systems used mechanical single element transducers with fixed focus depth<sup>100</sup> with serious limitations in depth-of-field and in their ability to provide functional maps of Doppler blood flow in real time. Recently, array-based micro-ultrasound scanners for pre-clinical use with a frequency range up to 70 MHz have been launched<sup>101</sup> offering ease of use and improved image quality compared with mechanical systems. A linear array-based scanner allows implementation of variable transmit focus and dynamical receive focus allowing uniform high resolution maintained over the full field-of-view. The clinical application of HFU was first described in skin imaging<sup>102</sup> but has also been used for ocular imaging<sup>103</sup> and the thyroid<sup>104</sup>. Currently, HFU is being tried on a range of novel applications; intravascular ultrasound<sup>105</sup> and scanning acoustic microscope system<sup>106</sup> where tissue samples are scanned *ex vivo*.

HFU has not been used in the context of brain research mostly due to the fact that there is no penetration through the skull. Preterm rabbit pups have an open fontanel at birth providing an acoustic window for ultrasound imaging. HFU could therefore be an invaluable tool in assessing haemorrhage size and extension thus circumventing the drawbacks of reproducibility in the rabbit pup model of IVH.

# Hypothesis and Aims

## Hypothesis

Our working hypothesis is that cell-free haemoglobin and its metabolites act as causal initiators of inflammation and oxidative stress following preterm IVH, constituting a critical up-stream event eventually leading to brain damage. We further hypothesize that damage to the choroid plexus epithelium caused by haemoglobin metabolites alters the ability of the choroid plexus to maintain CSF homeostasis contributing to the development of post-haemorrhagic hydrocephalus.

## Aims

The overall aim of this thesis was to investigate the role of free haemoglobin and its degrading products in brain damage and the development of PHVD following preterm IVH.

The specific aims for each study:

- I. To evaluate the application of high-frequency ultrasound in the preterm rabbit pup model of IVH
- II. To characterize the degradation of haemoglobin *in vivo* following IVH in correlation to intra- and periventricular inflammation and to investigate cell-free haemoglobin metabolites as causal initiators of inflammation in preterm IVH.
- III. To characterize the expression and localization of aquaporin 1, 4 and 5 in the choroid plexus following preterm IVH
- IV. To investigate the structural and functional damage of the choroid plexus epithelium following preterm IVH and to characterize the inflammatory and cellular response of the

choroid plexus epithelium following exposure to haemoglobin metabolites.

# Material and Methods

## The rabbit pup model

All four papers in this thesis are based upon experiments using the rabbit pup model.

### *Animal handling*

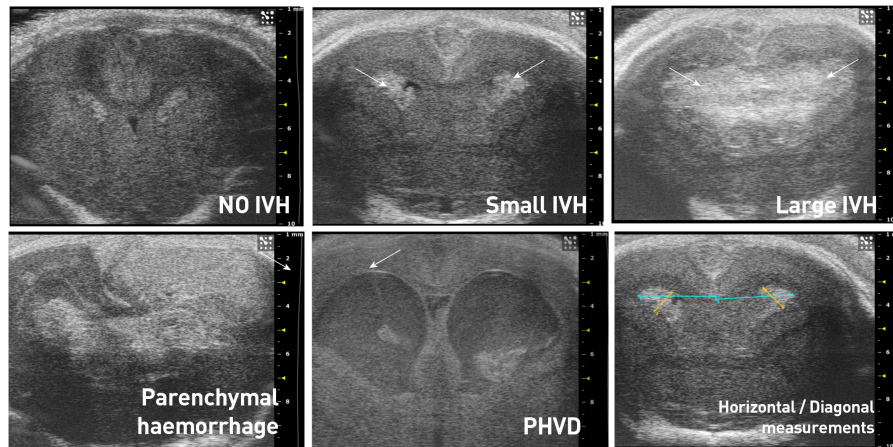
The animal protocols were approved by the Swedish Animal Ethics Committee in Lund. The experiments were performed using rabbit pups from a half-breed between New Zealand White and Lop, delivered at gestational day 29 (full gestational age 32 days). The pups were delivered by caesarean section after the does were anesthetized with i.v. propofol (5 mg/kg) and by local infiltration of the abdominal wall using lidocaine with adrenaline (10 mg/ml + 5 µl/ml, 20–30 ml). After delivery, the pups were dried vigorously, weighed, and placed in an infant incubator with a constant temperature of 36°C and 60% ambient humidity. At 2–3 hours of age, the pups were fed 1 ml of cat milk formula (KMR; PETAG Inc., USA), and subsequently every 12 hours, increasing each meal by 0.5 ml. At 2 hours of age, the pups received an i.p. injection of 50% glycerol (6.5 g/kg) to induce IVH. Endotoxin analysis (using the QCL-1000™ Endpoint Chromogenic LAL Assay, Lonza, Switzerland) of the glycerol solution displayed no detectable levels of endotoxins. The rabbit pups were euthanized with an intracardiac injection of pentothal (100 mg/ml, 0.5 ml) either at 24, 48 or 72 hours according to each experiment protocol. In the experiments all rabbit pups used for analysis received i.p. glycerol.

### *Ultrasound*

The Visualsonics Vevo 2100 (VisualSonics Inc., ON, Canada) was used for brain ultrasound with a MS-550D 40MHz transducer. Ultrasound imaging of

the brain was performed at 6 hours of age to detect haemorrhage and subsequently at 24, 48 and at 72 hours of age. The examinations were performed without sedation and by securing movements manually holding the rabbit pups in an up-right position. As the skull bones of the rabbit pups are not fused, the fontanel provided an acoustic window for coronal brain scans without requirement of shaving.

Ultrasound images were graded in 1) no IVH; 2) small IVH: blood in the ventricles but no ventricular distension; 3) large IVH: blood filling the ventricles; 4) large IVH with parenchymal haemorrhage; 5) post haemorrhagic ventricular dilatation (PHVD); significant extension of the ventricles (Fig 2).



**Fig. 2. Cranial ultrasound images of rabbit pup brains**

Macroscopic post-mortem examination of the brain was used to confirm the ultrasound grading of IVH.

Measurements of ventricular size were obtained at the level of the midseptal nucleus in a coronal view. Each ventricle was measured separately in two different planes, diagonally from the roof of the lateral ventricle to its floor at the widest point and horizontally from the mid-brain plane to the lateral wall of the ventricle (Fig 2).

### *Ultrasound-guided CSF sampling and intra-ventricular injections*

Ultrasound guided intraventricular injections were performed on rabbits with IVH at 6 hours of age. A proportion of the rabbit pups were randomized to receive either 10 µl haptoglobin (50 mg/ml; BioProducts Laboratory, London, UK) or 10 µl sterile vehicle solution using 31G Hamilton syringe.

Ultrasound guided CSF sampling from rabbits with IVH was performed using a 27G needle at 24, 48 and 72 hours of age collecting 10-250 µl of CSF. CSF samples were centrifuged immediately (2000 ×g, 20°C, 10 minutes) to remove cells, and the supernatant was stored at -80°C until further analysis.

For these procedures the rabbit pup was gently fixated on a pre-heated thermostat-controlled platform at 39° C in a prone position with the probe hand-held by one of the investigators. The other investigator performed the needle-insertion under guidance of HFU. The procedure was performed without sedation of the rabbit pups.

### *Intra-observer and inter-observer variability*

To assess intra-observer variability the two respective ventricular measurements from ten rabbit pups were repeated six times by the same observer. The optimal two-dimensional image was frozen on screen, saved and the measurements registered. Then the screen was unfrozen for the next optimal image and measurement.

To assess inter-observer variability two observers blinded to each other scanned and measured the lateral ventricles of ten rabbit pups. The first observer scanned and measured the lateral ventricles of a rabbit pup six times as described above and then after a 15-30 min pause the other observer repeated the procedure on the same pup.

### *Normal value ranges and development of post-haemorrhagic hydrocephalus*

To establish normal value ranges for linear measurements of the lateral ventricles, 17 rabbit pups with no IVH were measured serially at 6, 24, 48 and 72 hours of age at the level of the midseptal nucleus. At each time point three measurements were performed and a mean value was calculated and used for statistical analysis. Post-mortem confirmation of no IVH was performed in each pup. Development of PHVD was evaluated in 14 rabbit pups with IVH detected at 6 hours on ultrasound with serial measurements of ventricular size as described above.



### *Tissue collection and processing*

**Paper I:** After the rabbit pups were euthanized, the brain was removed from the skull and sectioned coronally at the level of the midseptal nucleus. Coronal sections were photographed and examined for macroscopic signs of IVH. Brains from eight rabbit pups were removed whole from the skull, fixed in 4% formaldehyde with phosphate-buffered saline (PBS), embedded in paraffin blocks and sectioned into 4.5  $\mu\text{m}$  sections. Sections were stained with hematoxylin-eosin (H-E) and examined with light microscopy and photographed.

**Paper II:** Rabbit pups were euthanized at 24 and 72 hours of age (IVH = 6, sham control = 17), and the brains were removed from the skulls and sectioned at the level of the midseptal nucleus. A 1-mm section around the periventricular zone was dissected, snap frozen, and stored at  $-80^{\circ}\text{C}$  until further mRNA and protein analysis. Perfusion-fixation of brains was performed in an additional five rabbit pups (*i.e.*, not included in the groups for sampling of periventricular tissue, IVH = 3, sham control = 2) under isoflurane anaesthesia at 72 hours of age by trans-cardiac infusion of saline solution followed by 4% paraformaldehyde in PBS. Brains were then immersed in cryoprotective sucrose solution prior to cryosectioning for subsequent immunofluorescent analysis.

**Paper III and IV:** Rabbit pups were euthanized at 24 (IVH+PHVD, n=6; sham control n=6; IVH+haptoglobin, n=6; IVH+Sham, n=6) and 72 hours of age (IVH+PHVD n=9; sham control n=9), and the brains were removed from the skulls and sectioned at the level of the midseptal nucleus. The choroid plexus was carefully removed from the lateral ventricles, snap frozen, and stored at  $-80^{\circ}\text{C}$  until further mRNA and protein analysis. For electron microscopy immunostaining (EM-IHC), the choroid plexus from 2 rabbit pups with IVH+PHVD and 2 sham controls at 72 hours was fixed and prepared. For immunohistochemistry (IHC), the choroid plexus was removed and placed in formaldehyde from 2 pups with IVH+PHVD, 2 sham controls, 2 IVH+Hp and 2 IVH+Sham at 24 hours and in 3 pups with IVH+PHVD and 2 sham controls at 72 hours of age and prepared.

## CSF from preterm infants

CSF was sampled serially from preterm infants (gestational age at birth 25–28 weeks) 5–35 days after detection of IVH, by spinal tap or ventricular reservoir puncture. Immediately after sampling, the CSF was centrifuged (2000 ×g, 20°C for 10 minutes) and stored at -80°C until further use. The sampling was performed following written consent from the parents, and the study was approved by the ethical committee review board for studies in human subjects at Lund University.

## *In vitro* experiments

Papers II-IV contain *in vitro* experiments

### *Primary rabbit pup astrocyte cultures*

Rabbit pup primary astroglial cell cultures were used in paper II and prepared from 3-day-old healthy rabbit pups (not used for any other sampling) according to a modified method described previously<sup>107</sup>. Briefly, after decapitation, the brain regions of interest were mechanically dissected and digested in trypsin/EDTA solution. The tissue then was dissociated using a glass Pasteur pipette and centrifuged, and cells were resuspended in fresh culture medium and seeded in 75 cm<sup>2</sup> flasks (cells from one brain/flask). Cells were grown in complete culture medium, which was changed every third day. After 10 days, cultures were shaken for 1 hour (250 rpm) to remove microglial cells, and astrocytes were resown in subcultures into appropriate culture dishes. When cells reached confluence (cultivation day 6 to 8), oxyHb, metHb, cyan-Hb, and hemin (prepared immediately prior to the experiment) and a mixture of (NH<sub>4</sub>)Fe(SO<sub>4</sub>)<sub>2</sub>, hydrogen peroxide, and ascorbate (denoted the Fenton reaction) were added to the astrocyte cultures, and cells were incubated for 1–4 hours. After incubation, culture medium was collected and cells harvested using Qiazol™ Lysis reagent (QIAGEN Sciences, Germantown, MD, USA). Culture medium was analyzed for cell viability, total protein, and TNFα protein concentration,

and total RNA was extracted from cells to evaluate TNF $\alpha$ , IL-1 $\beta$ , and HO-1 mRNA expression.

*Primary human choroid plexus epithelial cells*

Human primary choroid plexus epithelial cells (HCPEpiC, ScienCell, Carlsbad, CA USA) were used in papers III and IV and were cultured in epithelial cell medium containing 2% foetal bovine serum, 1% epithelial cell growth supplement, 100 units/mL penicillin and 100  $\mu$ g/mL streptomycin (all ScienCell). When cells reached approximately 90% confluence CSF from preterm infants with IVH, metHb and hemin were added to the HCPEpiC cultures, and cells were incubated for 1-24 hours. After incubation, cells were harvested using either Qiazol™ Lysis reagent (for RNA extraction, QIAGEN) or cell extraction buffer (for protein extraction, Invitrogen, Camarillo, CA, USA). Total RNA and protein was extracted from cells to evaluate mRNA expression and protein content.

*Preparation of oxy-, met-, and cyan-hemoglobin and hemin*

Fetal oxyHb (HbF) was purified as previously described<sup>108</sup> from freshly drawn human umbilical cord blood. Briefly, red blood cells (RBCs) were isolated by centrifugation (1200  $\times$ g, 10 minutes) and washed with excess PBS. The RBCs were then lysed by resuspension in hypotonic buffer (20 volumes H<sub>2</sub>O:1 volume PBS) on ice, and the membranes were separated from the cytosol by centrifugation (14000  $\times$ g, 4°C, 20 minutes). The supernatant was applied to a DEAE-Sephadex A-50 (Amersham Biosciences AB, Uppsala, Sweden) column and separated using an increasing ion gradient. Fractions were collected and the absorbance measured to identify and determine the concentration of oxyHb. Human Hb was from Sigma Chemical Co. (St. Louis, MO, USA) and shown spectrophotometrically<sup>108</sup> to contain at least 70–80% metHb. This preparation is referred to here as “metHb”. Furthermore, metHb was also prepared by incubating the above described oxyHb solution at 37°C for 72 hours. The metHb concentration was quantified as described previously<sup>108</sup>. Hemin (Ferriprotoporphyrin IX chloride) was purchased from Porphyrin Products, Inc. (Logan, UT, USA), and a 10 mM stock solution was prepared using DMSO (Sigma).

Cyan-Hb was prepared as described previously<sup>109</sup>, by mixing HbF (1 mM) with KCN (10 mM) and incubating the mix for 10 minutes at 20°C. The solution was desalted on a Sephadex G-25 column (Amersham). Addition of cyanide to oxyHb locks the Fe<sup>2+</sup> atom in its ferrous form, which disables spontaneous oxidation to metHb. All Hb derivatives (oxy-, met- (purchased and in-house prepared), cyan-Hb, and hemin) was purified from endotoxin contamination using the endotoxin removing product EndoTrap (Hyglos GmbH, Germany) as described by the manufacturer. The absolute purity of all Hb derivatives (oxy-, met-, cyanHb, and hemin) from contamination with endotoxin (0 EU/mg Hb/hemin) was determined using the QCL-1000™ Endpoint Chromogenic LAL Assay (Lonza, Switzerland) and the Lipopolysaccharide (LPS) ELISA Assay kit (Usen Life Science Inc, Wuhan, China) as described by the manufacturers.

## Laboratory analysis

In papers II-IV the following laboratory analysis are used.

### *RNA isolation and real-time PCR*

Total RNA was isolated from periventricular brain tissue, choroid plexus, primary rabbit pup astrocytes and HCPEpiC cells using the acid guanidinium phenol chloroform method and RNeasy Mini Kit supplied by QIAGEN. The OD ratio (optical density at 260 nm/280 nm) of RNA was always higher than 1.9. Reverse transcription was performed according to manufacturer on 0.1-1 µg total RNA using iScript™ cDNA Synthesis Kit (Bio-Rad, CA, USA) and RT<sup>2</sup> First Strand Kit (QIAGEN). Real-time PCR and RT<sup>2</sup> PCR Profiler Array real-time PCR (custom made by QIAGEN) was used to quantify the mRNA expression of target genes. Data were normalized to glyceraldehyde-3-phosphate dehydrogenase (GAPDH). The fold change values were calculated by normalizing against control samples from untreated animals or cells. Expression was analyzed using RT<sup>2</sup> SYBR Green

Fluor qPCR Mastermix (QIAGEN). Amplification was performed as described by the manufacturer (QIAGEN) for 40 cycles in an iCycler Thermal Cycler (Bio-Rad) and data analyzed using iCycler iQ Optical System Software (Bio-Rad).

#### *Protein analysis*

Total protein from choroid plexus and HCPEpiC were determined by Pierce•BCA Protein Assay Kit (Thermo Scientific).

#### SDS-PAGE and Western blot

SDS-PAGE was performed on 10 µg protein extracts from choroid plexus or HCPEpiC using precast 4-20% Mini-Protean TGX gels from Bio-Rad and run under reducing conditions using molecular weight standard (precision protein plus all blue marker, Bio-Rad). The separated proteins were transferred to polyvinylidene difluoride (PVDF) membranes (Bio-Rad) and blocked with 3-5% blocker grade dry milk (Bio-Rad). The membranes were then incubated with antibodies against AQP1 (polyclonal rabbit-anti human AQP1, 1 µg/ml, Abnova, Taipei, Taiwan), AQP4 (polyclonal goat anti-human AQP4, 1 µg/ml, Santa Cruz, Dallas, Texas, USA), AQP5 (polyclonal goat anti-human AQP5, 1 µg/ml, Santa Cruz) and β-actin (monoclonal mouse anti-human β-actin, Abcam, Cambridge, UK). Western blot was performed using Alexa 647-conjugated secondary antibodies (Life Technologies). The bands were detected in a ChemiDoc XRS unit (Bio-Rad). The relative quantification of AQP1 and 5 bands were performed by densitometry using Image Lab software (Bio-Rad). Levels of AQP1 were normalized against those of β-actin for respective samples

#### *TNF-α ELISA*

The concentrations of TNFα in extracted periventricular brain tissue, choroid plexus tissue, CSF from rabbit pups and from preterm infants as well as astrocyte cell culture medium were determined using the Rabbit and Human TNFα DuoSet ELISA Development kits from R&D Systems (UK).

The analysis was performed according to the instructions from the manufacturer.

#### *Cell viability assay*

The levels of lactate dehydrogenase (LDH) in astrocyte and choroid plexus cell culture media were measured using the CytoTox 96® Non-Radioactive Cytotoxicity Assay (Promega, Madison, WI, USA) according to the instructions from the manufacturer.

#### *Caspase-3/7 Assay*

The levels of activate caspase-3/7 in choroid plexus cells were measured using the caspase-3/7 assay as described by the manufacturer (Promega).

#### *Measurement of Hb metabolites in CSF*

Hb metabolite concentrations were determined in CSF from rabbit pups and preterm infants using a spectrophotometric method described previously<sup>108</sup>.

#### *Determination of Hp concentrations in CSF*

The concentrations of Hp in CSF from rabbit pups were determined using the Human and Rabbit Hp ELISA Quantification Kit from Genway Biotech Inc. (San Diego, CA, USA). The analysis was performed according to the instructions from the manufacturer.

#### *Immunohistochemistry*

**Paper II:** Brain sections (40 µm) from paraformaldehyde-perfused animals were washed in PBS, blocked with 2% normal horse serum, and incubated with a polyclonal goat anti-TNFα (1:50, Santa Cruz, CA, USA). After overnight incubation at 4°C, sections were incubated with a donkey anti-goat biotinylated secondary antibody (diluted at 1:200, Jackson Laboratories, CT, USA). Sections were further incubated with an Alexa-488 streptavidin conjugate (1:200, Invitrogen) and a Cy3-conjugated monoclonal anti-glial fibrillary acidic protein (GFAP) antibody (1:500, Sigma-Aldrich). Fluorescent signals were visualized using a confocal microscopy system (LSM510, Zeiss, Germany).

**Paper III-IV:** Immunohistochemistry sections were deparaffinized by routine procedures and endogenous peroxidase activity was blocked with 3% H<sub>2</sub>O<sub>2</sub> in methanol for 15 minutes. After washing with Triton-X-100 (0.25%) in PBS, sections were blocked with normal goat serum (5%) for 1 hour at RT. The slides were then incubation with AQP1 (1 µg/ml), AQP4 (1 ug/ml), AQP5 (2 ug/ml) or cleaved caspase-3 primary antibody overnight at 4°C. Antibody detection was performed with a standard avidin-biotin complex detection system after which they were developed with 3,3'-diaminobenzidine tetrahydrochloride as the chromogenic substrate (Vectastain avidin-biotin complex, Vector Laboratories, Burlingame, California). Sections were mounted with Pertex (Histolab Products AB, Gothenburg, Sweden) and examined and photographed (Olympus BHS photomicrographic system).

*Transmission electron microscopy (TEM)*

Immunolabeling of thin sections with gold-labelled anti-AQP1, 5 or TNFα were performed as described previously<sup>110</sup> with the modification that Aurion-BSA was used as a blocking agent. Specimens were observed in a JEOL JEM 1230 electron microscope operated at 80 kV accelerating voltage. Images were recorded with a Gatan Multiscan 791 CCD camera.

# Statistics

## Paper I

The intra-observer and inter-observer variability was evaluated by calculating the coefficient of variation (CV). The CV was calculated and defined as

$$CV = \frac{\text{Random difference}}{\text{Overall mean}} = \frac{\sqrt{\frac{1}{2 \cdot n} \sum_{i=1}^n d_i^2}}{\frac{1}{2 \cdot n} \sum_{i=1}^{2n} m_i}$$

where  $d_i$  is the difference between the measurements of each subject,  $n$  is the number of subjects and  $m_i$  is the measurement.

The paired  $t$  test was used for assessment of differences of mean values over time within groups and the independent sample  $t$  test for that of differences in mean values between groups. P-values  $<0.05$  were considered significant. Values are given as mean  $\pm$  1 SD.

## Paper II-IV

Pair-wise comparisons between unrelated groups were performed with the Students  $t$ -test or the Mann–Whitney U test as appropriate. Comparisons between multiple groups were performed by ANOVA with *post hoc* Bonferroni correction. Correlations were assessed by linear regression analysis.  $P$  values  $<0.05$  were considered significant.



# Results and comments

## I. Application of High Frequency Ultrasound in the Rabbit Pup Model of IVH

### Results

At 6 hours of age 61 % (126/206) of the rabbit pups who had received i.p. glycerol had developed IVH with varying degree of ventricular enlargement. 1,2 % (3/206) of the rabbit pups had parenchymal involvement. 70 % (88/126) of pups with IVH survived until 72 h of age and 90 % (72/80) of pups with no IVH survived until 72h of age.

We were able to visualise in a reliable and accurate way the haemorrhagic distension and the development PHVD (Fig 3).

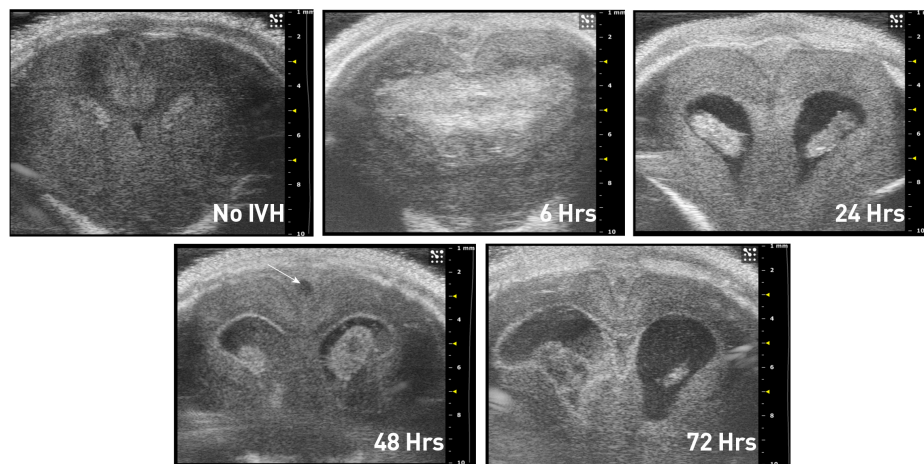


Figure 3. Development of PHVD in rabbit pups as seen on cranial ultrasound

A post mortem macroscopic examination of the rabbit pup brains confirmed the ultrasound diagnosis.

Imaging with HFU enabled accurate real-time visualization of the intraventricular space following IVH. Repeated ultrasound-guided intraventricular injection and sampling could be performed excluding requirement of stereotactic procedures and sedation.

In pups with no IVH measurements of diagonal and horizontal ventricular width did not increase with postnatal age. In contrast, in rabbit pups with IVH horizontal and diagonal ventricular width increased over time. The coefficient of variation for inter- and intra-observer variability in two measurements of ventricular size was less than 8.8 % and 9.3 % respectively.

## Comments

When studying the molecular mechanisms of brain damage following IVH the animal model used is of utmost importance. In this thesis all studies are based upon the rabbit pup model of IVH. It mimics the pathophysiology of preterm IVH better than other small animal models<sup>87, 95, 98</sup>. However, due to the nature of the model the haemorrhagic size and extension cannot be controlled. We found the application of HFU to be a reliable and accurate tool for diagnostic evaluation and intervention in the rabbit pup model thus circumventing the main drawback of this animal model. Evaluation of haemorrhagic extension was accurate as confirmed by post-mortem examinations and repeated linear measurements of PHVD could be performed with high intra- and inter-observer reproducibility and we were able to perform both intraventricular injections and sampling with great accuracy.

Recently, the validity of the rabbit pup model has been questioned as a suitable model for preterm IVH<sup>111</sup>. The main objections are the inconsistency of the haemorrhagic size and extension as well the possibility of an alternative interpretation that the observed brain injury is due to glycerol toxicity. In the studies contributing to this thesis we have only used rabbit pups with similar sized haemorrhages and all our control animals are sham controls that received i.p. glycerol but did not develop IVH as seen on cranial high frequency ultrasound. We are therefore confident that observed

results are not due to glycerol toxicity and that the size and extension of the haemorrhage is of similar character in all reported studies.

## II. Methaemoglobin induces inflammation following preterm IVH

### Results

Following IVH in preterm rabbit pups, the intraventricular CSF concentration of cell-free metHb increased from 24 to 72 hours whereas the concentration of oxyHb remained constant. The concentration of metHb was strongly correlated with that of TNF- $\alpha$  at 72 hours ( $r^2 = 0.896$ ,  $P < 0.001$ ) in the CSF.

Serial CSF samples from four preterm infants with IVH were collected and a positive correlation was observed between concentrations of metHb and TNF $\alpha$  ( $r = 0.24$ ,  $P = 0.01$ ) but no significant correlation was identified between those of oxyHb and TNF $\alpha$  ( $r^2 = 0.01$ ,  $P = 0.7$ ).

In periventricular brain tissue, the mRNA expression of TNF- $\alpha$ , IL-1 $\beta$ , and TLR-4 as well as TNF $\alpha$  protein levels were significantly increased in pups with IVH at 72 hours as compared to control animals. This was accompanied by an extensive astrocyte activation (*i.e.* glial fibrillary acidic protein (GFAP) staining).

Exposure of primary rabbit astrocyte cell cultures to oxyHb, cyanHb, metHb or hemin at increasing concentration led to a dose-dependent increase in mRNA TNF- $\alpha$  expression only when the cells were exposed to metHb. Furthermore, exposure to metHb caused a significant, dose-dependent increase in TNF $\alpha$  protein concentrations. Exposure to oxyHb at corresponding concentrations resulted in a small but significant increase in levels of TNF- $\alpha$  protein. This increase was not observed following cyan-Hb exposure, strongly indicating that conversion of oxyHb to metHb is necessary for TNF $\alpha$  induction.

## Comments

Even though the down-stream mechanisms for brain injury of prematurity are fairly well known<sup>85</sup> the up-stream initiators of brain damage following preterm IVH remain to be elucidated.

In this study we show that following IVH metHb induces the key inflammatory cytokine TNF- $\alpha$ . TNF- $\alpha$  signalling is central to inflammatory brain damage resulting both in caspase activation and apoptosis as well as inflammation<sup>112, 113</sup>. Indeed, binding of TNF- $\alpha$  to the TNF receptor (TNFR) 1 has been described as a pivotal upstream event in the induction of intracellular pathways leading to apoptotic and necrotic cell death<sup>114</sup>. Furthermore, suppression of TNF- $\alpha$  expression decreased periventricular cell death and gliosis following IVH<sup>91</sup>.

In adult intracerebral haemorrhage the activation of the TLR-4 receptor is considered a key event leading to inflammation, oedema and neurological sequelae<sup>64, 75</sup> and has been shown to mediate microglial activation in the neonatal rat brain following hypoxia<sup>94</sup>. We found an up-regulation of TLR-4 in the periventricular brain tissue suggesting that TLR-4 activation also is of importance in the immature brain and the pro-inflammatory effect of metHb might be mediated through this mechanism.

MetHb is an oxidized form of oxyHb, the latter being released into the intraventricular space following haemolysis. Other studies have shown that the metHb accumulates over time following adult intracerebral haemorrhage<sup>115</sup> and that this accumulation is accompanied by maximal brain oedema<sup>66</sup>.

MetHb further degrades into the highly cell toxic heme, CO<sub>2</sub> and iron. We conclude that following IVH there might be a defined time window allowing for a therapeutic intervention aiming at scavenging free haemoglobin or preventing oxidation of oxyHb to metHb.

### III. Expression of aquaporin 1 and 5 in the choroid plexus following preterm IVH

#### Results

Following IVH, choroid plexus AQP1 mRNA expression decreased both at 24 and 72 hours, whereas AQP1 protein levels increased. Analysis of choroid plexus AQP1 localization and distribution, using IHC and EM-IHC staining, displayed a continuous staining of the ventricular surface of the epithelial cells at 72 hours (Fig 4).

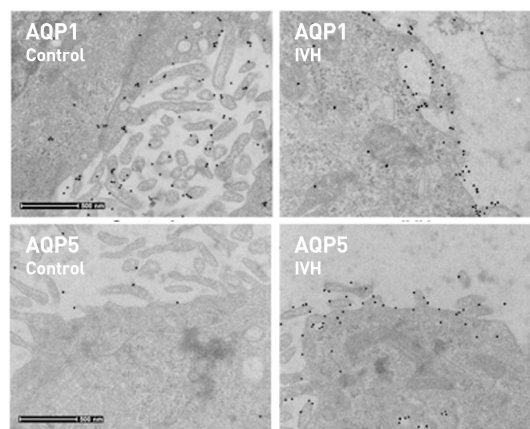


Figure 4. Electron microscopy images at 72 hours showing expression of AQP1 and AQP5

AQP5 mRNA expression increased at 24 and 72 hours in pups with IVH as compared to control pups and there was a corresponding increase of AQP5 at protein level. Following IVH, IHC and EM-IHC of AQP5 displayed an increased staining and a distribution of AQP5 towards the ventricular surface of the epithelial cells at 72 hours. Furthermore, epithelial vesicles containing AQP5 were observed in animals with IVH (Figure 4). Analysis of choroid plexus cells *in vitro*, following exposure to post-haemorrhagic CSF and to

hemin, displayed results concordant to those observed *in vivo*, *i.e.* a down-regulation of AQP1 mRNA- and up-regulation of AQP5 mRNA expression. AQP4 was neither detectable *in vivo* nor *in vitro*.

## Comments

The production and homeostasis of CSF is essential for normal function of the CNS and the normal development of the immature brain<sup>38</sup>. AQP1 is the key water transporter in the choroid plexus and plays an essential role in the production of CSF<sup>42-44</sup>. Aquaporins have been implicated in formation of brain oedema<sup>116</sup> as well as hydrocephalus formation<sup>46,117</sup>.

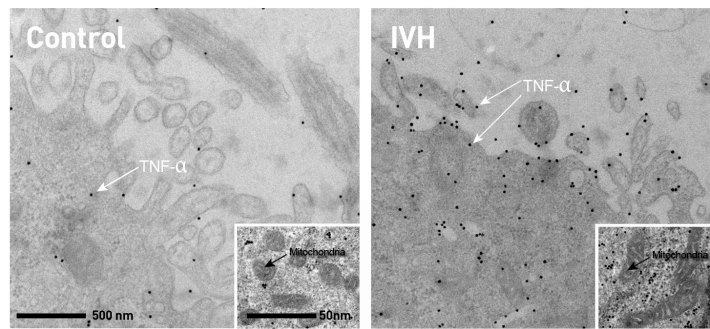
We found a down-regulation of AQP1 mRNA following preterm IVH but an up-regulation of AQP1 protein. Following IVH there is an abrupt increase in CSF osmolality. The AQP1 protein increase and apical localization might be an adaptive response to increase the intraventricular water influx thus aiming to normalize CSF osmolality. The down-regulation of AQP1 mRNA expression might, however, be a cellular response aiming at decreasing CSF production.

AQP5 has not previously been described in the choroid plexus and its function remains unknown. Following IVH there was an up-regulation both at mRNA level as well as at protein level. AQP5 is amply expressed in other organs with secretory functions<sup>53-55</sup> conveying paracellular water transport<sup>118</sup>, enhancing extracellular matrix stability and increasing tight junction strength<sup>119</sup>. Shear stress has been shown to increase AQP5 expression<sup>57</sup> and recently Chai *et al.* described plasticity in AQP5 expression in astrocytes according to type of insult<sup>52</sup>. From the results of our study, it might be speculated that the significant up-regulation following IVH is a cellular adaptive response where cell matrix strengthening and increased paracellular water movement would be an advantageous response to this type of insult.

## IV. Haemoglobin, a mediator of inflammation and damage in the choroid plexus following IVH

### Results

Following IVH there was a structural damage of the choroid plexus at 24 hours, which was more extensive at 72 hours. IHC for caspase-3 as a marker for apoptosis was highly positive at 24 hours. Electron microscopy at 72 hours revealed severe epithelial disintegration, microvilli fragmentation and swollen mitochondria and increased staining of TNF- $\alpha$  (Fig 5).



**Figure 5. Choroid plexus electron microscopy images at 72 hours.** There is profound disintegration of the choroid plexus epithelium with loss of villi. Small image in higher magnification shows swollen mitochondria indicating preapoptotic state.

A highly significant up-regulation of receptor related signaling genes TLR4, IL1R1, CD14, MyD88, cFAS, NF- $\kappa$ B, c-JUN, IRAK1 and JAK-2 was detected at 72 hours following IVH. Analysis of inflammatory effector molecule activation revealed a highly significant upregulation of MCP-1, IL8, IL6, TNF- $\alpha$  and IL-1 $\beta$  following IVH.


Intraventricular injection of haptoglobin in animals with IVH significantly reduced the cellular and inflammatory response seen at 24 hours as

compared to sham treated animals with IVH. The haptoglobin concentration in CSF from animals with IVH was virtually undetectable. However, a median haptoglobin concentration of 389  $\mu\text{g/ml}$  (target concentration 1000  $\mu\text{g/ml}$  Hp) was detected in animals, which had received intraventricular injection of haptoglobin. The CSF concentration of  $\text{TNF}\alpha$ , following haptoglobin injection, showed a trend towards reduced inflammatory secretion of  $\text{TNF}\alpha$  with increasing amount of CSF haptoglobin. Also, analysing the levels of oxyHb and metHb showed that injection of Hp blocks the autooxidation of oxyHb into metHb. Electron microscopy images at 24 hours showed a loss of normal villous anatomy in animals with IVH as compared to controls. Electron microscopy images from animals with IVH which had received intraventricular haptoglobin showed retained epithelial cell structure and anatomy.

Characterisation of choroid plexus epithelial cells *in vitro*, following exposure to post-haemorrhagic CSF, metHb and hemin displayed concordant results to those observed *in vivo*. Exposing the plexus cells to CSF showed a dose-dependent NF- $\text{K}\beta$ , JUN, MCP-1, IL8, and IL6 increase at 4 hours. At 24 hours exposure, only a slight increase was observed for IL8, whereas NF- $\text{K}\beta$  and JUN displayed a significant downregulation. Furthermore, exposing the plexus cells to the Hb metabolites metHb and heme showed a similar mRNA expression pattern as seen for CSF with significant increase, at 4 hours, of NF- $\text{K}\beta$ , JUN, IL8, IL6 and IL-1 $\beta$  following exposure to 10  $\mu\text{M}$  heme and MCP-1 was increased after exposure to 10  $\mu\text{M}$  metHb. At 24 hours, a significant up-regulation of IL8, IL6 and IL-1 $\beta$  was also observed following exposure to heme and MCP-1 was increased following exposure to metHb. Congruent to the CSF results, exposure to metHb and heme resulted in a down-regulation of NF- $\text{K}\beta$  at 24 hours. Exposure of plexus epithelial cells to hemin caused cell death by necrosis whereas exposure to metHb caused predominantly apoptosis.

Co-incubation with haptoglobin displayed a protective effect towards the metHb- and hemin-induced effects and reversed or reduced cell death and cellular- and inflammatory response (Figure 6).





**Figure 6. Choroid plexus electron microscopy images at 24 hours.** There is a loss of normal epithelial structure in animals with IVH. Animals treated with haptoglobin retained normal villous structure.

## Comments

The choroid plexus is the first structure to encounter the full force of the damaging effects of extravasated blood following IVH. As a free-floating organ it is bathed in CSF, it is homogenic, it is a continuum of the ventricular ependyma, it is an integral part of the BBB and ependymal dysfunction and BBB disruption is a crucial step leading to periventricular brain damage. Further, it produces the CSF and disturbances in CSF production could contribute to the development of PHVD. This renders the choroid plexus a sublime target organ to study the detrimental effects of haemoglobin following preterm IVH.

In the choroid plexus we found an intense early cellular response with up-regulation of genes related to activation of TLR-4 and IL-1R1 pathways with induction of the transcription factor NF- $\kappa$ B in the choroid plexus. This activation leads to inflammation as well as both apoptotic and necrotic cell death. Indeed, activation of transcription factor NF- $\kappa$ B in postnatal mouse ependyma has been associated with impaired ciliogenesis and connects inflammation to the development of hydrocephalus<sup>33</sup>. Our *in vitro* results show that methHb and heme are potent activators of inflammation in human primary plexus epithelial cell but methHb predominantly induces apoptosis whereas heme mainly induces necrosis. Haptoglobin is an intrinsic protein, which main function is binding haemoglobin into inert haptoglobin-

haemoglobin complexes. Co-incubation of the plexus epithelial cells reduced or reversed the effects of haemoglobin. To further investigate the blocking effects of haptoglobin rabbit pups with IVH received an intraventricular injection of haptoglobin. Animals with IVH that had not received haptoglobin had almost undetectable concentrations of haptoglobin but in animals, which received intraventricular haptoglobin high concentrations were detected. The injected haptoglobin concentration was calculated based on the haemoglobin concentration in the CSF, which we had previously measured<sup>120</sup>.

There was a significant decrease in the cellular and inflammatory response at 24 hours in animals that received haptoglobin indicating that haemoglobin is indeed a major culprit leading to choroid plexus damage, BBB dysfunction, PHVD and eventually brain damage following IVH.

# General discussion and future perspectives

## General discussion

Preterm intraventricular haemorrhage remains one of the most challenging issues in modern neonatal care. The insult is readily diagnosed with bedside cranial ultrasound, the prognosis is dire and clinicians are often faced with difficult ethical decisions. Currently there is no effective therapy available for these infants and clinicians do not have the tools to predict the final outcome for each individual child. In order to improve care for these children it is vital to fully understand the mechanisms leading to brain damage following IVH. This thesis focuses on the role of cell free haemoglobin as an initiator of inflammation and cell damage in the intraventricular space following preterm IVH.

We found that the oxidation of oxyHb to metHb in the intraventricular space is a key up-stream event in haemoglobin toxicity initiating cellular and inflammatory response. Following IVH there is a release of red blood cells and plasma into the intraventricular space.

Thrombin has been shown to cause significant brain damage in the adult brain following intracerebral haemorrhage<sup>65, 121</sup> but the effects in the neonatal brain are considerable less<sup>70</sup>. We found a high correlation between metHb formation and inflammatory initiation both in CSF, periventricular brain matter and the choroid plexus *in vivo*. When we exposed plexus epithelial cells to haemoglobin metabolites or CSF we found that metHb and heme initiate both inflammation and cell death and the same effects were seen when cells were exposed to CSF. Co-incubation with haptoglobin, a haemoglobin scavenger, blocked these effects effectively both in cells incubated with haemoglobin as well as in CSF exposed cells. This would indicate that the effects of haemoglobin metabolites are even greater in the development of brain damage in the immature brain than in the adult brain.

The pathogenesis of PHVD is still unknown but emerging evidence suggest that inflammation of the ventricular ependymal lining leading to arachnoiditis and gliosis<sup>23, 122</sup> as well as disturbance in the CSF production is important. We found a profound cellular damage of the choroid plexus following IVH as well as functional alteration in the AQP expression. *In vitro*, the observed alterations of AQP expression were triggered by exposure to haemoglobin metabolites in the choroid plexus epithelial cells. The changes observed in AQP1 and 5 expression in the choroid plexus suggest an adaptive response to the haemorrhagic insult which may have a functional implication for CSF homeostasis and thus for development of PHVD. However, our observations are strictly observational and further studies are needed to assess the functional implications of these changes on CSF production.

Recently, the rabbit pup model of IVH has come under scrutiny<sup>111</sup>. It is therefore important to stress that the control animals in our studies had received i.p. glycerol and did not have IVH on cranial HFU. We further validated our results by measuring haemoglobin metabolites and TNF- $\alpha$  in CSF from preterm infants and our results were in concordance with the results from the animal studies. Finally, our *in vitro* data in studies III and IV are exclusively from human cells. Therefore, we are confident that our results are not due to glycerol toxicity in the rabbit pups.

In conclusion, the degrading products of cell free haemoglobin released from red blood cells following IVH are key initiators of inflammation and cellular damage in the intraventricular space and of the choroid plexus following preterm IVH. The detrimental effects of free haemoglobin develop over time allowing for a window of opportunity for therapeutic intervention aiming at removal or scavenging of haemoglobin.

## Future perspectives

New treatment strategies to prevent the development of PHVD and brain damage following IVH are sorely needed. In the context of adult cerebral haemorrhage a few treatment strategies are currently being investigated<sup>123</sup>, where thrombin inhibitors, the iron chelator desferoxamine, immune modulation with G-CSF and mild hypothermia has shown greatest promise.

However, as seen with thrombin inhibitors, which did not show the same efficacy in preterm IVH as in adult cerebral haemorrhage, the immature brain has unique properties and interventions aiming at reducing brain damage following IVH need to be tailored accordingly.

In our experiments we blocked the detrimental effects of haemoglobin effectively using haptoglobin. Haptoglobin has been used in Japan as treatment of acute haemoglobinemias but currently there are only case reports regarding this therapy in the literature <sup>124, 125</sup>. Scavenging of haemoglobin with haptoglobin could be a feasible way to protect the immature brain from the effect of IVH. A number of unanswered questions need to be addressed to evaluate if such approach would be feasible. The haemoglobin-haptoglobin complex binds to CD163 positive macrophages for removal. Currently the origin of these immunologic cells in the CNS is unknown and it is not clear whether the increased amount of haemoglobin-haptoglobin complexes would attract sufficient number of CD163 positive macrophages. In our study we found that haptoglobin induces the chemotactic effector molecule MCP-1, which might be a physiologic relevant effect. Further studies to assess the immunological effects of IVH as well as haptoglobin are warranted.

In our studies we only evaluated the effects of haemoglobin scavenging with haptoglobin *in vitro* and for 24 hours *in vivo*. To further assess the effects of haptoglobin long term animal studies need to be performed where functional outcome and white matter damage as well as laboratory parameters need to be evaluated. The HFU could provide invaluable information in this setting in assessing the development of hydrocephalus *in vivo*.

Currently, the only therapy shown to improve long-term outcome in preterm infants with IVH is the DRIFT therapy, where following IVH, blood is irrigated from the ventricles <sup>126-128</sup> over a period of 72 hours. In light of the results in current thesis the efficacy of DRIFT is logical, irrigation of red blood cells and free haemoglobin would be beneficial. A combination of irrigation of intraventricular blood and binding haemoglobin in its inert form might be a future therapeutic option.

# Svensk sammanfattning

Framsteg inom neonatal intensivvård har ökat överlevnaden hos extremt för tidigt födda barn. Prognosen för dessa barn är generellt god, men 15-20 % av drabbas av en större hjärnblödning där blod tränger in i hjärnans hålrum, vilket innebär en sämre prognos och en ökad dödlighet. Av barnen som överlever drabbas hälften av en ökad huvudomfångstillväxt på grund av en tilltagande vidgning av hjärnans hålrum som också trycker på omgivande hjärnvävnad och detta resulterar i en ökad risk för neurologiska handikapp vilket inkluderar både motoriska handikapp och inlärningssvårigheter. Barnen som utvecklar en bestående vidgning av hjärnans hålrum (vattenskalle) behöver oftast en livslång behandling med en så kallad shunt som dränerar överskott av vätska från hålrummen. Behandling med shunt är i sin tur förenad med komplikationer som till exempel stopp i shunten eller shuntinfektion. I dagsläget finns ingen etablerad behandling som förhindrar utveckling av vattenskalle eller senare neurologiska handikapp.

Mekanismer bakom de skador som uppstår i samband med hjärnblödning är komplexa och till en stor del okända. Dock har studier påvisat att inflammation och skadliga effekter av reaktiva fria syreföreningar skadar den omogna hjärnans vita substans. Även mekanismerna som ligger bakom uppkomst av vattenskalle efter en större hjärnblödning är också okända men störningar i produktionen av ryggmärgsvätska verkar vara en bidragande faktor. Området i hjärnan som producerar ryggmärgsvätska, plexus choroideus, ligger precis bredvid den plats där blödningen brukar uppstå och är således den struktur som först utsätts för kontakt med blod. I blödningen finns röda blodkroppar som sedan brister (hemolyserar) och frisätter fritt hemoglobin som är det protein som normalt fungerar som kroppens syretransportör. Fritt hemoglobin bryts i sin tur vidare ner till olika nervtoxiska substanser och studier hos vuxna har visat att fritt hemoglobin kan initiera en inflammation efter en hjärnblödning. Man har också kunnat påvisa att en uppkommen inflammation förstör den ömtåliga blod-hjärnbarriären.

Vår hypotes är att fritt hemoglobin och dess nedbrytningsprodukter initierar inflammation i den omogna hjärnan efter hjärnblödning och direkt orsakar hjärnskada. Vi tror också att inflammation av plexus choroideus orsakar störningar i produktion av ryggmärgsvätska som bidrar till utveckling av vattenskalle.

För att testa vår hypotes använde vi en prematur kaninmodell. Prematurfödda kaninungar har en mognadsgrad i det centrala nervsystemet som är jämförbar med ett prematurfött barn som är fött efter 28-30 graviditetsveckor. Kaninungar har också ett känsligt område i hjärnan varifrån det kan blöda precis som hos det för tidigt födda barn. För att på ett noggrant sätt kunna studera hjärnblödningarna använde vi en högupplösande ultraljudsmetod där vi kunde visualisera hjärnblödningarna och även kunde öka noggrannheten för provtagning av ryggmärgsvätska från hjärnans hålrum.

Efter hemolys frisläpps fritt hemoglobin ut i ryggmärgsvätskan. Vi har kunnat visa att det fria hemoglobinet och dess nedbrytningsprodukter initierar den inflammatoriska kaskaden efter en uppkommen hjärnblödning. Vi kunde också visa att celler i plexus choroideus skadas allvarligt efter hjärnblödning och att denna skada utvecklas över tid samt att både inflammation i cellerna och själva cellskadan orsakas av fritt hemoglobin. Tillförsel av haptoglobin, ett kroppseget protein som binder hemoglobin, minskar denna skada avsevärt.

Aquaporiner är kroppsegna proteiner vars huvudfunktion är att transportera vatten över cellmembran och de tros spela en central roll i produktion av ryggmärgsvätska. Efter hjärnblödning såg vi en nedreglering av aquaporin 1 i plexus choroideus, den akvaporin som tros vara delaktig i produktion av ryggmärgsvätska. Vi konstaterade också en tydlig uppreglering av aquaporin 5, ett protein vars existens inte har beskrivits tidigare i strukturen plexus choroideus. Betydelsen av dessa förändringar är inte känd, men skulle kunna spela roll i utvecklingen av den ventrikelvidgning som ses efter blödning i ventrikelrummet.

Sammanfattningsvis, så visar denna avhandling att nedbrytning av fritt hemoglobin initierar inflammation och cellskada som sedan leder till hjärnskada efter hjärnblödning. Framtida studier får utvisa om behandling med haptoglobin skulle kunna vara en möjlig väg att blockera negativa effekter av fritt hemoglobin efter en uppkommen hjärnblödning, för att på så sätt minska risken för hjärnskador

# Íslensk samantekt

Nýburalækningum hefur fleygt fram á undanförunum áratugum. Flestir fyrirburar sem nú fæðast allt að 17 vikum fyrir tímenn (eftir 23 meðgönguvikur) lifa af, fá þeir bestu mögulegu umönnun. Þó svo að horfur þessara barna séu almennt góðar þá sést aukin tíðni ýmissa þroskafrávik. Heilablæðing er mikilvægasti, einstaki áhættuþáttur þess að greinast síðar með þroskafrávik. Af börnum sem fædd eru fyrir 28 meðgönguvikur fá 15-20% blæðingu í heila við fæðinguna eða skömmu síðar. Hjá þessum börnum eru horfur mun verri. Allt að helmingur þeirra deyr í kjölfarið og meirihluti barnanna sem lifa af hljóta ýmis konar fatlanir af völdum blæðingarinnar. Börnin eiga einnig á hættu að fá svo kallað vatnshöfuð þar sem óeðlilega mikið af heila- og mænuvökva safnast fyrir í holrýmum heilans og veldur auknum þrýstingi vegna stíflu á eðlilegu flæði. Til að létta á þrýstingnum þurfa börnin að fara í aðgerð en því fylgir töluverð hættu á fylgikvillum. Engin önnur meðferð er tiltæk sem minnkar líkur á fötlun eða vatnshöfði og ekki er hægt að segja með vissu fyrirfram hvaða barn skaðast í kjölfar heilablæðingar.

Orsakir heilaskemmda eftir blæðingar eru margvíslegar og flóknar og ekki að fullu kunnar en ónæmissvar og oxunaráhrif skipta þar miklu máli. Ekki er heldur fyllilega þekkt hvað veldur vatnshöfði en nýjar rannsóknir hafa leitt líkur að því að truflun á framleiðslu mænuvökva skipti hér verulegu máli. Svæðið sem framleiðir mænuvökva, „choroid plexus“, er staðsett við hliðina á upptökum heilablæðinga hjá fyrirburum og verður því strax fyrir skaðlegum áhrifum blóðs. Við niðurbrot rauðra blóðkorna losnar blóðrauði sem áfram brotnar niður í ýmis skaðleg efni. Rannsóknir í fullorðnum einstaklingum í kjölfar heilablæðinga hafa leitt í ljós að blóðrauði framkallar heiftarlegt bólgusvar umhverfis blæðingu sem veldur heilaskemmdum.

Okkar tilgáta er sú blóðrauði og niðurbrotsefni hans valdi ónæmissvari sem eykur á heilaskemmdir í óþroskuðum heila fyrirbura í kjölfar blæðingar.



Einnig teljum við að bólgusvar í „choroid plexus“ valdi truflunum í framleiðslu á mænuvökva og stuðli að myndun vatnshöfuðs.

Til að rannsaka þetta nánar gerðum við tilraunir á kanínuungum. Kanínur eru með heila og taugaproska sem svarar til barna eftir 28-30 meðgönguvikur. Þær eru einnig með viðkvæmt svæði í heilanum sem blæðir auðveldlega frá alveg eins og hjá börnum sem fædd eru fyrir tímann. Til að geta rannsakað blæðingarnar á sem nákvæmasta máta þróuðum við aðferð þar sem blæðingar voru metnar með ómtækni. Með aðstoð þessarar tækni gátum við einnig tekið mænuvökvasýni og sprautað efnum inn í heilahólfín.

Í rannsóknum okkar sýndum við fram á að blóðrauði og niðurbrotsefni hans valda kröftugu bólgusvari í kjölfar heilablæðingar. Við sýndum einnig fram á að blóðrauði skaðar frumur „choroid plexus“ í kjölfar blæðingar og að verulegar breytingar verða á magni og staðsetningu þeirra prótína sem stjórna vatnsmagni við framleiðslu mænuvökva. Þegar við sprautuðum prótíni (haptoglobin) sem bindur blóðrauða inn í heilahólfín sáum við verulega minnkun á skaðlegum áhrifum blóðrauða bæði á frumur „choroid plexus“ sem og á bólgusvar.

Hugsanlegt er því að hægt verði að meðhöndla fyrirbura sem fá heilablæðingu með haptoglobíni og þannig koma í veg fyrir heilaskemmdir.



# Acknowledgements

There are a number of people who have contributed to this thesis, either directly with scientific input or indirectly with moral support and fun. Some have even managed both.

**Professor David Ley.** I would like to express my immense gratitude to my main supervisor. Your support, wisdom and knowledge has guided me through the tides of pre-clinical research. However, after five years I do think we break even. I am now a full-fledged scientist and you are an expert on women's shoes.

**Magnus Gram.** I had the preconceived notion that all lab rats were a bunch of boring nerds. You proved me wrong. Our collaboration has been pure joy and I sincerely look forward to future projects.

**Magnus Cinthio.** Dunder!! What else is there to say?

**Karsten Ruscher.** Teaching a clinician lab-work is never easy but you did absolutely beautifully.

**Kristbjörg Sveinsdóttir.** My sister Sveinsdóttir and comrade in arms at the animal lab. How wonderful life is that you are in the world.

Neonatal colleagues. I am very lucky to be an offspring of the neonatal unit in Lund. I have learned neonatology in an inspiring environment at a leading unit. Buildings are only gravel but people are the key to success. **Lars Björklund, Elisabeth Norman, Ingrid Pupp, Kristina Bergentz, Eva Morsing**, you contributed to my flowering as a neonatologist.

I also found my very special friend **Ann Forsberg** in the neonatal unit. Lucky me.

**Sóley Þórisdóttir.** Designercousin. Thanks to you my thesis not only has excellent scientific value but also; It looks good!!!

**Aðalheiður and Gísli Bragi.** When I closed the front door and went to work I always knew that my children would be loved and taken care of. From the bottom of my heart, thank you.

My family. Icelandic, of course.

First, the matriarch **Unnur**, my grandmother who raised five daughters and innumerable granddaughters, including me. I truly believe I have made you proud.

The fun in my family, my aunt **Unnur**, joy in all your visits.

**Linda**, firstborn like me, competitive like me and my friend since birth. My cousins **Katrin Rós, Unnur** and **Erla Hlíf**, life in Lomma would not have been the same without you.

**Kjartan Páll**, my brother and his family, **Phoebe, Jóhann Kári, Sigrún Lára** and **Una**, we have supported each other through good times and bad times, through thick and thin.

And last but not least my baby brother **Jóhann**, Joe the Ant, the most fun person I know.

My friends for life. **Matta, Eva, Sigga, Erla, Hildur.** There is not much we don't know about each other.....and what we don't know is probably not worth knowing.

**Sveinn and Lára.** I am a mixture of you both. There have never been more supportive parents.

**Svenni, Lára Lilja, Heiða and Jóhanna.** Four hearts of my heart. Obviously, you have done nothing to ease my path towards the letters PhD but I see your faces in every child I treat and my patients are the reason for my research.

**Hjörtur Gíslason.** My lover, my companion, my friend. Before I met you I did not think I was cut out for happiness. Now I have it all.

# References

1. Fellman V, Hellstrom-Westas L, Norman M, Westgren M, Kallen K, Lagercrantz H, et al. One-year survival of extremely preterm infants after active perinatal care in Sweden. *JAMA*. 2009;301:2225-2233
2. Adams-Chapman I, Hansen NI, Stoll BJ, Higgins R, Network NR. Neurodevelopmental outcome of extremely low birth weight infants with posthemorrhagic hydrocephalus requiring shunt insertion. *Pediatrics*. 2008;121:e1167-1177
3. Futagi Y, Toribe Y, Ogawa K, Suzuki Y. Neurodevelopmental outcome in children with intraventricular hemorrhage. *Pediatr Neurol*. 2006;34:219-224
4. Bolisetty S, Dhawan A, Abdel-Latif M, Bajuk B, Stack J, Lui K, et al. Intraventricular hemorrhage and neurodevelopmental outcomes in extreme preterm infants. *Pediatrics*. 2014;133:55-62
5. Brouwer A, Groenendaal F, van Haastert IL, Rademaker K, Hanlo P, de Vries L. Neurodevelopmental outcome of preterm infants with severe intraventricular hemorrhage and therapy for post-hemorrhagic ventricular dilatation. *J Pediatr*. 2008;152:648-654
6. Murphy BP, Inder TE, Rooks V, Taylor GA, Anderson NJ, Mogrige N, et al. Posthaemorrhagic ventricular dilatation in the premature infant: Natural history and predictors of outcome. *Arch Dis Child Fetal Neonatal Ed*. 2002;87:F37-41
7. Wilson-Costello D, Friedman H, Minich N, Fanaroff AA, Hack M. Improved survival rates with increased neurodevelopmental disability for extremely low birth weight infants in the 1990s. *Pediatrics*. 2005;115:997-1003
8. Tubbs RS, Banks JT, Soleau S, Smyth MD, Wellons JC, 3rd, Blount JP, et al. Complications of ventriculosubgaleal shunts in infants and children. *Child's nervous system : ChNS : official journal of the International Society for Pediatric Neurosurgery*. 2005;21:48-51

9. Ballabh P, Braun A, Nedergaard M. Anatomic analysis of blood vessels in germinal matrix, cerebral cortex, and white matter in developing infants. *Pediatr Res*. 2004;56:117-124
10. Braun A, Xu H, Hu F, Kocherlakota P, Siegel D, Chander P, et al. Paucity of pericytes in germinal matrix vasculature of premature infants. *The Journal of neuroscience : the official journal of the Society for Neuroscience*. 2007;27:12012-12024
11. Gould SJ, Howard S. Glial differentiation in the germinal layer of fetal and preterm infant brain: An immunocytochemical study. *Pediatric pathology / affiliated with the International Paediatric Pathology Association*. 1988;8:25-36
12. Whitelaw A. Intraventricular haemorrhage and posthaemorrhagic hydrocephalus: Pathogenesis, prevention and future interventions. *Seminars in neonatology : SN*. 2001;6:135-146
13. Whitelaw A, Aquilina K. Management of posthaemorrhagic ventricular dilatation. *Arch Dis Child Fetal Neonatal Ed*. 2011
14. Shooman D, Portess H, Sparrow O. A review of the current treatment methods for posthaemorrhagic hydrocephalus of infants. *Cerebrospinal Fluid Res*. 2009;6:1
15. Papile LA, Burstein J, Burstein R, Koffler H. Incidence and evolution of subependymal and intra-ventricular hemorrhage - study of infants with birth weights less than 1,500 gm. *Journal of Pediatrics*. 1978;92:529-534
16. Group E. Incidence of and risk factors for neonatal morbidity after active perinatal care: Extremely preterm infants study in sweden (express). *Acta Paediatr*. 2010;99:978-992
17. Klebermass-Schrehof K, Czaba C, Olischar M, Fuiko R, Waldhoer T, Rona Z, et al. Impact of low-grade intraventricular hemorrhage on long-term neurodevelopmental outcome in preterm infants. *Child's nervous system : ChNS : official journal of the International Society for Pediatric Neurosurgery*. 2012;28:2085-2092
18. Futagi Y, Suzuki Y, Toribe Y, Nakano H, Morimoto K. Neurodevelopmental outcome in children with posthemorrhagic hydrocephalus. *Pediatr Neurol*. 2005;33:26-32
19. Limbrick DD, Jr., Mathur A, Johnston JM, Munro R, Sagar J, Inder T, et al. Neurosurgical treatment of progressive posthemorrhagic ventricular dilation in preterm infants: A 10-year single-institution study. *Journal of neurosurgery. Pediatrics*. 2010;6:224-230
20. Levene MI. Measurement of the growth of the lateral ventricles in preterm infants with real-time ultrasound. *Arch Dis Child*. 1981;56:900-904

21. Davies MW, Swaminathan M, Chuang SL, Betheras FR. Reference ranges for the linear dimensions of the intracranial ventricles in preterm neonates. *Arch Dis Child Fetal Neonatal Ed.* 2000;82:F218-223
22. Hanley DF. Intraventricular hemorrhage: Severity factor and treatment target in spontaneous intracerebral hemorrhage. *Stroke; a journal of cerebral circulation.* 2009;40:1533-1538
23. Strahle J, Garton HJ, Maher CO, Muraszko KM, Keep RF, Xi G. Mechanisms of hydrocephalus after neonatal and adult intraventricular hemorrhage. *Translational stroke research.* 2012;3:25-38
24. Volpe J. *Neurology of the newborn.* Philadelphia: Saunders Elsevier; 2008.
25. Oi S, Di Rocco C. Proposal of "evolution theory in cerebrospinal fluid dynamics" and minor pathway hydrocephalus in developing immature brain. *Child's nervous system : ChNS : official journal of the International Society for Pediatric Neurosurgery.* 2006;22:662-669
26. Zhang J, Williams MA, Rigamonti D. Genetics of human hydrocephalus. *Journal of neurology.* 2006;253:1255-1266
27. Del Bigio MR. Ependymal cells: Biology and pathology. *Acta neuropathologica.* 2010;119:55-73
28. Cherian S, Thoresen M, Silver IA, Whitelaw A, Love S. Transforming growth factor-betas in a rat model of neonatal posthaemorrhagic hydrocephalus. *Neuropathology and applied neurobiology.* 2004;30:585-600
29. Whitelaw A, Christie S, Pople I. Transforming growth factor-beta1: A possible signal molecule for posthemorrhagic hydrocephalus? *Pediatr Res.* 1999;46:576-580
30. Heep A, Stoffel-Wagner B, Bartmann P, Benseler S, Schaller C, Groneck P, et al. Vascular endothelial growth factor and transforming growth factor-beta1 are highly expressed in the cerebrospinal fluid of premature infants with posthemorrhagic hydrocephalus. *Pediatric research.* 2004;56:768-774
31. Simard PF, Tosun C, Melnichenko L, Ivanova S, Gerzanich V, Simard JM. Inflammation of the choroid plexus and ependymal layer of the ventricle following intraventricular hemorrhage. *Translational stroke research.* 2011;2:227-231
32. Savman K, Blennow M, Hagberg H, Tarkowski E, Thoresen M, Whitelaw A. Cytokine response in cerebrospinal fluid from preterm

- infants with posthaemorrhagic ventricular dilatation. *Acta Paediatr.* 2002;91:1357-1363
33. Lattke M, Magnutzki A, Walther P, Wirth T, Baumann B. Nuclear factor kappaB activation impairs ependymal ciliogenesis and links neuroinflammation to hydrocephalus formation. *The Journal of neuroscience : the official journal of the Society for Neuroscience.* 2012;32:11511-11523
  34. Krishnamurthy S, Li J, Schultz L, McAllister JP, 2nd. Intraventricular infusion of hyperosmolar dextran induces hydrocephalus: A novel animal model of hydrocephalus. *Cerebrospinal Fluid Res.* 2009;6:16
  35. Wolburg H, Paulus W. Choroid plexus: Biology and pathology. *Acta neuropathologica.* 2010;119:75-88
  36. Brown PD, Davies SL, Speake T, Millar ID. Molecular mechanisms of cerebrospinal fluid production. *Neuroscience.* 2004;129:957-970
  37. Wright EM. Transport processes in the formation of the cerebrospinal fluid. *Reviews of physiology, biochemistry and pharmacology.* 1978;83:3-34
  38. Johansson PA, Dziegielewska KM, Liddel SA, Saunders NR. The blood-csf barrier explained: When development is not immaturity. *BioEssays : news and reviews in molecular, cellular and developmental biology.* 2008;30:237-248
  39. Dziegielewska KM, Hinds LA, Mollgard K, Reynolds ML, Saunders NR. Blood-brain, blood-cerebrospinal fluid and cerebrospinal fluid-brain barriers in a marsupial (*Macropus eugenii*) during development. *The Journal of physiology.* 1988;403:367-388
  40. Dziegielewska KM, Ek J, Habgood MD, Saunders NR. Development of the choroid plexus. *Microscopy research and technique.* 2001;52:5-20
  41. Agre P. The aquaporin water channels. *Proceedings of the American Thoracic Society.* 2006;3:5-13
  42. Badaut J, Lasbennes F, Magistretti PJ, Regli L. Aquaporins in brain: Distribution, physiology, and pathophysiology. *J Cereb Blood Flow Metab.* 2002;22:367-378
  43. Boassa D, Yool AJ. Physiological roles of aquaporins in the choroid plexus. *Current topics in developmental biology.* 2005;67:181-206
  44. Papadopoulos MC, Verkman AS. Aquaporin water channels in the nervous system. *Nature reviews. Neuroscience.* 2013;14:265-277
  45. Mobasher A, Marples D. Expression of the aqp-1 water channel in normal human tissues: A semiquantitative study using tissue



- microarray technology. *American journal of physiology. Cell physiology*. 2004;286:C529-537
46. Kalani MY, Filippidis AS, ReKate HL. Hydrocephalus and aquaporins: The role of aquaporin-1. *Acta neurochirurgica. Supplement*. 2012;113:51-54
  47. Paul L, Madan M, Rammling M, Chigurupati S, Chan SL, Pattisapu JV. Expression of aquaporin 1 and 4 in a congenital hydrocephalus rat model. *Neurosurgery*. 2011;68:462-473
  48. Mao X, Enno TL, Del Bigio MR. Aquaporin 4 changes in rat brain with severe hydrocephalus. *The European journal of neuroscience*. 2006;23:2929-2936
  49. Oshio K, Watanabe H, Song Y, Verkman AS, Manley GT. Reduced cerebrospinal fluid production and intracranial pressure in mice lacking choroid plexus water channel aquaporin-1. *FASEB journal : official publication of the Federation of American Societies for Experimental Biology*. 2005;19:76-78
  50. Zador Z, Bloch O, Yao X, Manley GT. Aquaporins: Role in cerebral edema and brain water balance. *Progress in brain research*. 2007;161:185-194
  51. Zhong Z, Wang B, Dai M, Sun Y, Sun Q, Yang G, et al. Carvacrol alleviates cerebral edema by modulating aqp4 expression after intracerebral hemorrhage in mice. *Neuroscience letters*. 2013;555:24-29
  52. Chai RC, Jiang JH, Kwan Wong AY, Jiang F, Gao K, Vatcher G, et al. Aqp5 is differentially regulated in astrocytes during metabolic and traumatic injuries. *Glia*. 2013;61:1748-1765
  53. Ding C, Parsa L, Nandoskar P, Zhao P, Wu K, Wang Y. Duct system of the rabbit lacrimal gland: Structural characteristics and role in lacrimal secretion. *Investigative ophthalmology & visual science*. 2010;51:2960-2967
  54. Satoh K, Seo Y, Matsuo S, Karabasil MR, Matsuki-Fukushima M, Nakahari T, et al. Roles of aqp5/aqp5-g103d in carbamylcholine-induced volume decrease and in reduction of the activation energy for water transport by rat parotid acinar cells. *Pflugers Archiv : European journal of physiology*. 2012;464:375-389
  55. Verkman AS. Role of aquaporins in lung liquid physiology. *Respiratory physiology & neurobiology*. 2007;159:324-330
  56. Incidence of and risk factors for neonatal morbidity after active perinatal care: Extremely preterm infants study in sweden (express). *Acta Paediatr*. 2010;99:978-992

57. Sidhaye VK, Schweitzer KS, Caterina MJ, Shimoda L, King LS. Shear stress regulates aquaporin-5 and airway epithelial barrier function. *Proceedings of the National Academy of Sciences of the United States of America*. 2008;105:3345-3350
58. Sidhaye VK, Chau E, Srivastava V, Sirimalle S, Balabhadrapatruni C, Aggarwal NR, et al. A novel role for aquaporin-5 in enhancing microtubule organization and stability. *PloS one*. 2012;7:e38717
59. Volpe JJ. Brain injury in premature infants: A complex amalgam of destructive and developmental disturbances. *Lancet neurology*. 2009;8:110-124
60. Butt OI, Buehler PW, D'Agnillo F. Blood-brain barrier disruption and oxidative stress in guinea pig after systemic exposure to modified cell-free hemoglobin. *The American journal of pathology*. 2011;178:1316-1328
61. Stolp HB, Johansson PA, Habgood MD, Dziegielewska KM, Saunders NR, Ek CJ. Effects of neonatal systemic inflammation on blood-brain barrier permeability and behaviour in juvenile and adult rats. *Cardiovascular psychiatry and neurology*. 2011;2011:469046
62. Xue M, Del Bigio MR. Injections of blood, thrombin, and plasminogen more severely damage neonatal mouse brain than mature mouse brain. *Brain pathology*. 2005;15:273-280
63. Qureshi AI, Ali Z, Suri MF, Shuaib A, Baker G, Todd K, et al. Extracellular glutamate and other amino acids in experimental intracerebral hemorrhage: An in vivo microdialysis study. *Critical care medicine*. 2003;31:1482-1489
64. Xi G, Keep RF, Hoff JT. Mechanisms of brain injury after intracerebral haemorrhage. *Lancet neurology*. 2006;5:53-63
65. Babu R, Bagley JH, Di C, Friedman AH, Adamson C. Thrombin and hemin as central factors in the mechanisms of intracerebral hemorrhage-induced secondary brain injury and as potential targets for intervention. *Neurosurgical focus*. 2012;32:E8
66. Xi G, Keep RF, Hoff JT. Erythrocytes and delayed brain edema formation following intracerebral hemorrhage in rats. *Journal of neurosurgery*. 1998;89:991-996
67. Ohnishi M, Katsuki H, Fujimoto S, Takagi M, Kume T, Akaike A. Involvement of thrombin and mitogen-activated protein kinase pathways in hemorrhagic brain injury. *Experimental neurology*. 2007;206:43-52
68. Kitaoka T, Hua Y, Xi G, Nagao S, Hoff JT, Keep RF. Effect of delayed argatroban treatment on intracerebral hemorrhage-induced

- edema in the rat. *Acta neurochirurgica. Supplement.* 2003;86:457-461
69. Kudo A, Suzuki M, Kubo Y, Watanabe M, Yoshida K, Doi M, et al. Intrathecal administration of thrombin inhibitor ameliorates cerebral vasospasm. Use of a drug delivery system releasing hirudin. *Cerebrovascular diseases.* 2000;10:424-430
  70. Xue M, Balasubramaniam J, Parsons KA, McIntyre IW, Peeling J, Del Bigio MR. Does thrombin play a role in the pathogenesis of brain damage after periventricular hemorrhage? *Brain pathology.* 2005;15:241-249
  71. Wu J, Hua Y, Keep RF, Schallert T, Hoff JT, Xi G. Oxidative brain injury from extravasated erythrocytes after intracerebral hemorrhage. *Brain research.* 2002;953:45-52
  72. Faivre B, Menu P, Labrude P, Vigneron C. Hemoglobin autooxidation/oxidation mechanisms and methemoglobin prevention or reduction processes in the bloodstream. Literature review and outline of autooxidation reaction. *Artificial cells, blood substitutes, and immobilization biotechnology.* 1998;26:17-26
  73. Wagner KR, Sharp FR, Ardizzone TD, Lu A, Clark JF. Heme and iron metabolism: Role in cerebral hemorrhage. *J Cereb Blood Flow Metab.* 2003;23:629-652
  74. Nakamura T, Keep RF, Hua Y, Hoff JT, Xi G. Oxidative DNA injury after experimental intracerebral hemorrhage. *Brain research.* 2005;1039:30-36
  75. Fang H, Wang PF, Zhou Y, Wang YC, Yang QW. Toll-like receptor 4 signaling in intracerebral hemorrhage-induced inflammation and injury. *J Neuroinflammation.* 2013;10:27
  76. Liu X, Spolarics Z. Methemoglobin is a potent activator of endothelial cells by stimulating il-6 and il-8 production and e-selectin membrane expression. *American journal of physiology. Cell physiology.* 2003;285:C1036-1046
  77. Figueiredo RT, Fernandez PL, Mourao-Sa DS, Porto BN, Dutra FF, Alves LS, et al. Characterization of heme as activator of toll-like receptor 4. *J Biol Chem.* 2007;282:20221-20229
  78. Lin S, Yin Q, Zhong Q, Lv FL, Zhou Y, Li JQ, et al. Heme activates tlr4-mediated inflammatory injury via myd88/trif signaling pathway in intracerebral hemorrhage. *J Neuroinflammation.* 2012;9:46
  79. Zuwala-Jagiello J. Haemoglobin scavenger receptor: Function in relation to disease. *Acta biochimica Polonica.* 2006;53:257-268

80. Wang Y, Kinzie E, Berger FG, Lim SK, Baumann H. Haptoglobin, an inflammation-inducible plasma protein. *Redox report : communications in free radical research*. 2001;6:379-385
81. Galea J, Cruickshank G, Teeling JL, Boche D, Garland P, Perry VH, et al. The intrathecal cd163-haptoglobin-hemoglobin scavenging system in subarachnoid hemorrhage. *J Neurochem*. 2012;121:785-792
82. Zhao X, Song S, Sun G, Strong R, Zhang J, Grotta JC, et al. Neuroprotective role of haptoglobin after intracerebral hemorrhage. *The Journal of neuroscience : the official journal of the Society for Neuroscience*. 2009;29:15819-15827
83. Chavez-Bueno S, Beasley JA, Goldbeck JM, Bright BC, Morton DJ, Whitby PW, et al. 'Haptoglobin concentrations in preterm and term newborns'. *Journal of perinatology : official journal of the California Perinatal Association*. 2011;31:500-503
84. Hvidberg V, Maniecki MB, Jacobsen C, Hojrup P, Moller HJ, Moestrup SK. Identification of the receptor scavenging hemopexin-heme complexes. *Blood*. 2005;106:2572-2579
85. Khwaja O, Volpe JJ. Pathogenesis of cerebral white matter injury of prematurity. *Archives of disease in childhood. Fetal and neonatal edition*. 2008;93:F153-161
86. Volpe JJ, Kinney HC, Jensen FE, Rosenberg PA. The developing oligodendrocyte: Key cellular target in brain injury in the premature infant. *International journal of developmental neuroscience : the official journal of the International Society for Developmental Neuroscience*. 2011;29:423-440
87. Georgiadis P, Xu H, Chua C, Hu F, Collins L, Huynh C, et al. Characterization of acute brain injuries and neurobehavioral profiles in a rabbit model of germinal matrix hemorrhage. *Stroke; a journal of cerebral circulation*. 2008;39:3378-3388
88. Ginis I, Jaiswal R, Klimanis D, Liu J, Greenspon J, Hallenbeck JM. Tnf-alpha-induced tolerance to ischemic injury involves differential control of nf-kappab transactivation: The role of nf-kappab association with p300 adaptor. *J Cereb Blood Flow Metab*. 2002;22:142-152
89. Mayne M, Fotheringham J, Yan HJ, Power C, Del Bigio MR, Peeling J, et al. Adenosine a2a receptor activation reduces proinflammatory events and decreases cell death following intracerebral hemorrhage. *Annals of neurology*. 2001;49:727-735

90. Hua R, Walz W. Minocycline treatment prevents cavitation in rats after a cortical devascularizing lesion. *Brain research*. 2006;1090:172-181
91. Vinukonda G, Csiszar A, Hu F, Dummula K, Pandey NK, Zia MT, et al. Neuroprotection in a rabbit model of intraventricular haemorrhage by cyclooxygenase-2, prostanoid receptor-1 or tumour necrosis factor-alpha inhibition. *Brain*. 2010;133:2264-2280
92. Brough D, Tyrrell PJ, Allan SM. Regulation of interleukin-1 in acute brain injury. *Trends in pharmacological sciences*. 2011;32:617-622
93. Singh N, Hopkins SJ, Hulme S, Galea JP, Hoadley M, Vail A, et al. The effect of intravenous interleukin-1 receptor antagonist on inflammatory mediators in cerebrospinal fluid after subarachnoid haemorrhage: A phase ii randomised controlled trial. *J Neuroinflammation*. 2014;11:1
94. Yao L, Kan EM, Lu J, Hao A, Dheen ST, Kaur C, et al. Toll-like receptor 4 mediates microglial activation and production of inflammatory mediators in neonatal rat brain following hypoxia: Role of tlr4 in hypoxic microglia. *J Neuroinflammation*. 2013;10:23
95. Balasubramaniam J, Del Bigio MR. Animal models of germinal matrix hemorrhage. *J Child Neurol*. 2006;21:365-371
96. Lorenzo AV, Welch K, Conner S. Spontaneous germinal matrix and intraventricular hemorrhage in prematurely born rabbits. *Journal of neurosurgery*. 1982;56:404-410
97. Conner ES, Lorenzo AV, Welch K, Dorval B. The role of intracranial hypotension in neonatal intraventricular hemorrhage. *Journal of neurosurgery*. 1983;58:204-209
98. Chua CO, Chahboune H, Braun A, Dummula K, Chua CE, Yu J, et al. Consequences of intraventricular hemorrhage in a rabbit pup model. *Stroke; a journal of cerebral circulation*. 2009;40:3369-3377
99. Clancy B, Kersh B, Hyde J, Darlington RB, Anand KJ, Finlay BL. Web-based method for translating neurodevelopment from laboratory species to humans. *Neuroinformatics*. 2007;5:79-94
100. Foster FS, Zhang MY, Zhou YQ, Liu G, Mehi J, Cherin E, et al. A new ultrasound instrument for in vivo microimaging of mice. *Ultrasound Med Biol*. 2002;28:1165-1172
101. Foster FS, Mehi J, Lukacs M, Hirson D, White C, Chaggares C, et al. A new 15-50 mhz array-based micro-ultrasound scanner for preclinical imaging. *Ultrasound Med Biol*. 2009;35:1700-1708

102. Alexander H, Miller DL. Determining skin thickness with pulsed ultra sound. *The Journal of investigative dermatology*. 1979;72:17-19
103. Silverman RH. High-resolution ultrasound imaging of the eye - a review. *Clin Experiment Ophthalmol*. 2009;37:54-67
104. Wong KT, Ahuja AT. Ultrasound of thyroid cancer. *Cancer imaging : the official publication of the International Cancer Imaging Society*. 2005;5:157-166
105. Zacharatos H, Hassan AE, Qureshi AI. Intravascular ultrasound: Principles and cerebrovascular applications. *AJNR Am J Neuroradiol*. 2010;31:586-597
106. Saijo Y, Santos Filho E, Sasaki H, Yambe T, Tanaka M, Hozumi N, et al. Ultrasonic tissue characterization of atherosclerosis by a speed-of-sound microscanning system. *IEEE transactions on ultrasonics, ferroelectrics, and frequency control*. 2007;54:1571-1577
107. Ruscher K, Freyer D, Karsch M, Isaev N, Megow D, Sawitzki B, et al. Erythropoietin is a paracrine mediator of ischemic tolerance in the brain: Evidence from an in vitro model. *The Journal of neuroscience : the official journal of the Society for Neuroscience*. 2002;22:10291-10301
108. Winterbourn CC. Oxidative reactions of hemoglobin. *Methods in enzymology*. 1990;186:265-272
109. Olsson MG, Allhorn M, Olofsson T, Akerstrom B. Up-regulation of alpha 1-microglobulin by hemoglobin and reactive oxygen species in hepatoma and blood cell lines. *Free radical biology & medicine*. 2007;42:842-851
110. Roth J. Post-embedding cytochemistry with gold-labelled reagents: A review. *Journal of microscopy*. 1986;143:125-137
111. Traudt CM, McPherson RJ, Studholme C, Millen KJ, Juul SE. Systemic glycerol decreases neonatal rabbit brain and cerebellar growth independent of intraventricular hemorrhage. *Pediatr Res*. 2014;75:389-394
112. Hallenbeck JM. The many faces of tumor necrosis factor in stroke. *Nat Med*. 2002;8:1363-1368
113. Hua Y, Wu J, Keep RF, Nakamura T, Hoff JT, Xi G. Tumor necrosis factor-alpha increases in the brain after intracerebral hemorrhage and thrombin stimulation. *Neurosurgery*. 2006;58:542-550; discussion 542-550
114. Northington FJ, Chavez-Valdez R, Martin LJ. Neuronal cell death in neonatal hypoxia-ischemia. *Annals of neurology*. 2011;69:743-758

115. Bradley WG, Jr. Mr appearance of hemorrhage in the brain. *Radiology*. 1993;189:15-26
116. Papadopoulos MC, Saadoun S, Binder DK, Manley GT, Krishna S, Verkman AS. Molecular mechanisms of brain tumor edema. *Neuroscience*. 2004;129:1011-1020
117. Filippidis AS, Kalani MY, ReKate HL. Hydrocephalus and aquaporins: The role of aquaporin-4. *Acta neurochirurgica Supplement*. 2012;113:55-58
118. King LS, Kozono D, Agre P. From structure to disease: The evolving tale of aquaporin biology. *Nature reviews. Molecular cell biology*. 2004;5:687-698
119. Kawedia JD, Nieman ML, Boivin GP, Melvin JE, Kikuchi K, Hand AR, et al. Interaction between transcellular and paracellular water transport pathways through aquaporin 5 and the tight junction complex. *Proceedings of the National Academy of Sciences of the United States of America*. 2007;104:3621-3626
120. Gram M, Sveinsdottir S, Ruscher K, Hansson SR, Cinthio M, Akerstrom B, et al. Hemoglobin induces inflammation after preterm intraventricular hemorrhage by methemoglobin formation. *J Neuroinflammation*. 2013;10:100
121. Lee KR, Kawai N, Kim S, Sagher O, Hoff JT. Mechanisms of edema formation after intracerebral hemorrhage: Effects of thrombin on cerebral blood flow, blood-brain barrier permeability, and cell survival in a rat model. *J Neurosurg*. 1997;86:272-278
122. Robinson S. Neonatal posthemorrhagic hydrocephalus from prematurity: Pathophysiology and current treatment concepts. *Journal of neurosurgery. Pediatrics*. 2012;9:242-258
123. Belur PK, Chang JJ, He S, Emanuel BA, Mack WJ. Emerging experimental therapies for intracerebral hemorrhage: Targeting mechanisms of secondary brain injury. *Neurosurgical focus*. 2013;34:E9
124. Ohshiro T, Kosaki G, Funakoshi S. Haptoglobin therapy: Effect on prevention and treatment of hemoglobinuria. *Medical journal of Osaka University*. 1978;29:269-279
125. Hattori K, Hirano T, Oshimi K. Protease inhibitors and haptoglobin for treatment of renal failure in paroxysmal nocturnal hemoglobinuria. *American journal of hematology*. 2000;63:61-62
126. Whitelaw A, Pople I, Cherian S, Evans D, Thoresen M. Phase I trial of prevention of hydrocephalus after intraventricular hemorrhage in newborn infants by drainage, irrigation, and fibrinolytic therapy. *Pediatrics*. 2003;111:759-765

127. Whitelaw A, Jary S, Kmita G, Wroblewska J, Musialik-Swietlinska E, Mandra M, et al. Randomized trial of drainage, irrigation and fibrinolytic therapy for premature infants with posthemorrhagic ventricular dilatation: Developmental outcome at 2 years. *Pediatrics*. 2010;125:e852-858
128. Whitelaw A, Evans D, Carter M, Thoresen M, Wroblewska J, Mandra M, et al. Randomized clinical trial of prevention of hydrocephalus after intraventricular hemorrhage in preterm infants: Brain-washing versus tapping fluid. *Pediatrics*. 2007;119:e1071-1078