



LUND UNIVERSITY

Advanced clinical MRI for better outcome in epilepsy surgery. Focusing on fMRI and prediction of verbal memory decline.

Strandberg, Maria

2014

[Link to publication](#)

Citation for published version (APA):

Strandberg, M. (2014). *Advanced clinical MRI for better outcome in epilepsy surgery. Focusing on fMRI and prediction of verbal memory decline.* [Doctoral Thesis (compilation), Neurology, Lund]. Neurology, Lund.

Total number of authors:

1

General rights

Unless other specific re-use rights are stated the following general rights apply:

Copyright and moral rights for the publications made accessible in the public portal are retained by the authors and/or other copyright owners and it is a condition of accessing publications that users recognise and abide by the legal requirements associated with these rights.

- Users may download and print one copy of any publication from the public portal for the purpose of private study or research.
- You may not further distribute the material or use it for any profit-making activity or commercial gain
- You may freely distribute the URL identifying the publication in the public portal

Read more about Creative commons licenses: <https://creativecommons.org/licenses/>

Take down policy

If you believe that this document breaches copyright please contact us providing details, and we will remove access to the work immediately and investigate your claim.

LUND UNIVERSITY

PO Box 117
221 00 Lund
+46 46-222 00 00

Advanced clinical MRI for better outcome in epilepsy surgery

Focusing on fMRI and prediction of verbal memory decline

Maria C Strandberg



LUND
UNIVERSITY

DOCTORAL DISSERTATION

With due permission of the Faculty of Medicine, Lund University, Sweden.

To be defended on November 29th 2014 at 10.30 in Segerfalksalen, Wallenberg Neurocentrum, Lund, Sweden.

Faculty opponent

Professor John Duncan,

MA, DM, FRCP, FMedSci,
Professor of Neurology – UCL, U.K.

Organization LUND UNIVERSITY Department of Clinical Sciences, Lund Faculty of Medicine, Neurology Lund University Hospital 221 85 Lund Author(s) Maria C Strandberg	Document name DOCTORAL DISSERTATION	
	Date of issue November 29 th 2014	
	Sponsoring organization	
Title and subtitle Advanced clinical MRI for better outcome in epilepsy surgery - Focusing on fMRI and prediction of verbal memory decline		
Abstract Aim: The aim of the thesis was to evaluate the use of advanced MRI technology to improve results of epilepsy surgery, with focus on language and memory functions. Methods: In paper I, 25 patients with drug-resistant epilepsy were retrospectively included in the study for having been referred to high resolution 3T MRI with and without surface coils. The surface coils were placed over the suspected epileptogenic zone. The efficacy of the coils was assessed and graded in relation to their placement. In papers II, III and IV, a functional MRI (fMRI) paradigm, including both a verbal encoding task and a visuospatial task, was designed and implemented. The medial temporal lobe (MTL) for memory and the anterior language area were studied. In paper III, a standard word generation fMRI paradigm was also included. In these three studies, the test was performed in 15 healthy right handed subjects (paper II), 6 patients with drug-resistant temporal lobe epilepsy (TLE) with mixed handedness and 10 controls (paper III) and 14 TLE patients eligible for resective surgery (paper IV), respectively. A bootstrap algorithm was used to calculate lateralization indices (LI) and LI-curves. In paper IV, a clinical risk assessment score was created from collected clinical data. Additional value from fMRI LI was correlated to post-surgical memory decline. Results: Surface coil 3T MRI did not contribute to detection of previously undiagnosed lesions. In 20% of patients, 3T MRI, compared with previous 1.0-1.5T MRI, provided new information about cortical lesions. The fMRI paradigm visualized memory-related activity in the MTL and provided information regarding language processes. LI and LI-curves for memory at group level were consistent with previous studies, but a variety of activation effects were found at the individual level. LI-curves added complementary information for individual subjects with uncharacteristic results. The verbal encoding task provided information on verbal memory, which had equal lateralization as language in right-handed subjects, but not always in left-handed subjects and TLE patients. Bilateral fMRI language representation was seen in 2 right TLE patients who later suffered verbal memory decline post-operatively. Conclusion: High resolution 3T MRI is valuable for lesion detection, but surface coils do not provide further crucial information. The fMRI paradigm activates memory and language areas that can be studied at an individual level using LI-curves. Analysis of language patterns seems to be important for prediction of memory outcome in both left and right TLE. fMRI indices may identify an unexpected high risk for post-operative verbal memory decline in right TLE patients.		
Key words 3T MRI, surface coils, epilepsy surgery, fMRI, TLE, lateralization index, MTL, verbal encoding		
Classification system and/or index terms (if any)		
Supplementary bibliographical information		Language English
ISSN and key title 1652-8220		ISBN 978-91-7619-061-6
Recipient's notes	Number of pages 143	Price
	Security classification	

I, the undersigned, being the copyright owner of the abstract of the above-mentioned dissertation, hereby grant to all reference sources permission to publish and disseminate the abstract of the above-mentioned dissertation.

Signature 

Date 2014-10-29

Advanced clinical MRI for better outcome in epilepsy surgery

Focusing on fMRI and prediction of verbal memory
decline

Maria C Strandberg



LUND
UNIVERSITY

Copyright © Maria C Strandberg

Faculty of Medicine
Department of Clinical Sciences, Lund
Department of Neurology

Lund University, Faculty of Medicine Doctoral Dissertation Series 2014:132

ISBN 978-91-7619-061-6

ISSN 1652-8220

Printed in Sweden by Media-Tryck, Lund University, Lund 2014



Contents

Abstract	7
List of papers	9
Abbreviations	11
1. Introduction and background	13
1.1 Epilepsy	13
1.1.1 Classification of epilepsy – focal and generalized	13
1.1.2 Treatment and treatment success of epilepsy	14
1.1.3 Epilepsy-surgery; types of surgery, neuropathology	14
1.1.4 Risk of post-surgical deficits	14
1.1.5 Success of epilepsy surgery – predictive factors	15
1.1.6 Outlining the two patient groups in the thesis	15
1.2 Neuroimaging	16
1.2.1 Basic MRI physics	16
1.2.2 Signal-to-noise-ratio, SNR	16
1.2.3 Surface coils	17
1.3 Functional MRI (fMRI)	17
1.3.1 The blood oxygenation level dependent (BOLD) contrast	17
1.3.2 The use of fMRI	19
1.4 Introducing neuropsychology	19
1.4.1 Taxonomy of memory	20
1.4.2 The anatomical structures of episodic memory	21
1.4.3 Connecting fMRI and memory	21
1.5 fMRI paradigm design	22
1.5.1 fMRI paradigm design in language	23
1.5.2 fMRI paradigm design in memory	23
1.5.3 fMRI memory and language research in TLE patients	24
1.6 Lateralization of function in fMRI	25
1.6.1 Statistical issues in laterality assessment	25
1.6.2 The bootstrap method, the LI toolbox and LI curves	25
1.7 Issues in fMRI research	26
2. Aims of the Thesis	27
2.1 Paper 1	27
2.2 Paper II-IV	27

3.	Material and Methods	29
3.1	Paper I	29
3.1.1	Patients and clinical data	29
3.1.2	MRI evaluation	30
3.1.3	Surface coils – assessment of placement	30
3.2	Paper II, III and IV	30
3.2.1	Subjects/Patients	30
3.2.2	fMRI paradigms	31
3.2.3	Behavioral data	32
3.2.4	Statistical analysis	32
3.2.5	Clinical data and risk assessment – paper IV	33
4.	Results	35
4.1	Paper I	35
4.1.1	Image analysis	35
4.1.2	Surface coil placement	36
4.2	Paper II	36
4.2.1	fMRI activation results	36
4.2.2	Lateralization indices and laterality curves	39
4.3	Paper III	40
4.3.1	fMRI activation results	40
4.3.2	Lateralization indices and laterality curves	41
4.4	Paper IV	43
4.4.1	Outcome data	43
4.4.2	fMRI lateralization data	43
4.4.3	Risk assessment score and fMRI LI data	44
4.4.4	Neuropsychological outcome and fMRI results	45
5.	Discussion Including Future Aspects	47
5.1	Paper I	47
5.2	Paper II	48
5.3	Paper III	50
5.4	Paper IV	51
6.	Conclusions	55
6.1	Paper I	55
6.2	Paper II, III and IV	55
7.	Swedish summary (Populärvetenskaplig sammanfattning)	57
8.	Acknowledgements	59
9.	References	61

Abstract

Aim: The aim of the thesis was to evaluate the use of advanced MRI technology to improve results of epilepsy surgery, with focus on language and memory functions.

Methods: In paper I, 25 patients with drug-resistant epilepsy were retrospectively included in the study for having been referred to high resolution 3T MRI with and without surface coils. The surface coils were placed over the suspected epileptogenic zone. The efficacy of the coils was assessed and graded in relation to their placement. In papers II, III and IV, a functional MRI (fMRI) paradigm, including both a verbal encoding task and a visuospatial task, was designed and implemented. The medial temporal lobe (MTL) for memory and the anterior language area were studied. In paper III, a standard word generation fMRI paradigm was also included. In these three studies, the test was performed in 15 healthy right handed subjects (paper II), 6 patients with drug-resistant temporal lobe epilepsy (TLE) with mixed handedness and 10 controls (paper III) and 14 TLE patients eligible for resective surgery (paper IV), respectively. A bootstrap algorithm was used to calculate lateralization indices (LI) and LI-curves. In paper IV, a clinical risk assessment score was created from collected clinical data. Additional value from fMRI LI was correlated to post-surgical memory decline.

Results: Surface coil 3T MRI did not contribute to detection of previously undiagnosed lesions. In 20% of patients, 3T MRI, compared with previous 1.0-1.5T MRI, provided new information about cortical lesions. The fMRI paradigm visualized memory-related activity in the MTL and provided information regarding language processes. LI and LI-curves for memory at group level were consistent with previous studies, but a variety of activation effects were found at the individual level. LI-curves added complementary information for individual subjects with uncharacteristic results. The verbal encoding task provided information on verbal memory, which had equal lateralization as language in right-handed subjects, but not always in left-handed subjects and TLE patients. Bilateral fMRI language representation was seen in 2 right TLE patients who later suffered verbal memory decline post-operatively.

Conclusion: High resolution 3T MRI is valuable for lesion detection, but surface coils do not provide further crucial information. The fMRI paradigm activates memory and language areas that can be studied at an individual level using LI-curves. Analysis of language patterns seems to be important for prediction of memory outcome in both left and right TLE. fMRI indices may identify an unexpected high risk for post-operative verbal memory decline in right TLE patients.

List of papers

The thesis is based on the following paper, which will be referred to in the text by their Roman numerals.

- I. Strandberg M, Larsson EM, Backman S, Källén K. *"Pre-surgical evaluation using 3T MRI. Do surface coils provide additional information?"* Epileptic Disorders 2008 June; vol. 10, No.2.
- II. Strandberg M, Elfgren C, Mannfolk P, Olsrud J, Stenberg L, Van Westen D, Larsson EM, Rorsman I, Källén K. *"fMRI memory assessment in healthy subjects: A new approach to view lateralization data at an individual level."* Brain imaging and behaviour (2011) 5: 1-11.
- III. Strandberg M, Mannfolk P, Stenberg L, Källén K. *"Verbal encoding fMRI paradigm adds complementary information to cerebral language lateralization."* Submitted to Annals of Neuroscience and Psychology August 2014.
- IV. Strandberg, M, Mannfolk P, Stenberg L, Ljung H, Källén, K. *"An fMRI-based model for individual assessment of patients eligible for ATR - a pilot study."* Manuscript

Abbreviations

AED	Antiepileptic drugs
ATLR	Anterior temporal lobe resection
BOLD	Blood oxygenation level dependent
CBF	Cerebral blood flow
CD	Claeson-Dahl
CT	Computer tomography
DM	Difference due to memory
EEG	Electroencephalography
FMRI	Functional magnetic resonance imaging
HRF	Hemodynamic response function
IAT	Intracarotid Amytal Test
LI	Lateralization index
LOP	Levels of processing
MCD	Malformation of cortical development
MNI	Montreal neurological institute
MRI	Magnetic resonance imaging
MTL	Medial temporal lobe
PET	Positron emission tomography
RCFT	Rey Complex Figure Task
ROI	Region of interest
SNR	Signal to noise ratio
TLE	Temporal lobe epilepsy

1. Introduction and background

1.1 Epilepsy

Epilepsy is a well-documented disease, described in historic records dated several hundred years BC. The word epilepsy is derived from Greek (*epilambanein*) and means “to attack” or “to seize”. Over the years, the disease has been illustrated vividly in art and literature due to its unique and mysterious expressions.

Today, epilepsy is the most common chronic neurological disease in Sweden, affecting approximately 60 000 persons, whereof 10 000 are children. Epilepsy is a serious medical disorder and a high seizure frequency poses a serious risk to patients, including the risk of injury and of premature death. The actual epileptic seizure affects the brain negatively as it disrupts function and repeated seizures can cause long-term neuronal deficits (*Cascino, 2009*). Adding to medical issues, epilepsy also has psychological and socioeconomic consequences. Isolation due to fear of seizing, decreased social interaction and participation, limited choice of career and special consideration when starting and raising a family are examples of such consequences.

1.1.1 Classification of epilepsy – focal and generalized

In 1874 John Hughlings Jackson recognized seizures as being disordered electric activity in the brain. The discovery and mapping of the neurophysiologic correlates of seizures became the base for a classification of epilepsy still used today. Electroencephalographic (EEG) recordings of seizures and electrical activity between seizures are still a cornerstone in the diagnosis of the disease. The clinical manifestations of a seizure depend on where the electric discharges originate and how they spread. If a seizure originates from a particular part of the brain it is classified as focal seizure. A seizure afflicting both hemispheres of the brain initially, either clinically or as measured by EEG, is classified as a generalized seizure.

Other classification systems are based on semiology (what we can observe in the person during a seizure) and etiology (the known cause of the epilepsy).

In the late 20th century the rapid development of neuroimaging, computer tomography (CT) followed by magnetic resonance imaging (MRI), has meant pronounced advances in the investigation of epilepsy. Adding to previous observations regarding EEG, semiology and possible etiology is the increased knowledge of underlying anatomy.

Where EEG and semiology points to the origin of seizure, neuroimaging provides insight into the morphology – sometimes even the neuropathology - of the disease.

1.1.2 Treatment and treatment success of epilepsy

Approximately 70% of patients with epilepsy become seizure free with antiepileptic drugs (AEDs), but about 30% continue to have recurring seizures (*Kwan & Brodie, 2000; Schuele & Lüders, 2008*). In this group, some patients may benefit from surgery aiming at removing the origin of the epileptic seizure, i.e. the epileptogenic zone. Once drug resistance has been established, these patients should be referred to a specialist center and offered the possibility to be evaluated for epilepsy surgery. The evaluation process is usually a combination of diagnostic and localizing examinations including video-EEG-monitoring, advanced neuroimaging and neuropsychological assessment.

1.1.3 Epilepsy-surgery; types of surgery, neuropathology

The most common type of focal therapy-resistant epilepsy is temporal lobe epilepsy (TLE). Resection of the anterior temporal lobe (ATLR) can be a valuable treatment and in well-selected cases up to 70-80% become seizure free following surgery (*Wiebe et al, 2001*). Temporal lobe resection is the most common type of resective surgery. Extra-temporal resection, usually lesionectomy in the frontal lobe, is the second most common type of surgery and it aims at removing an isolated brain lesion (e.g. a malformation, a tumor) that has been deemed responsible for seizures.

Neuropathological examination – the detailed study of the removed tissue - follows surgery and provides important retrospective answers as to what was actually seen in pre-operative examinations. The most common histopathological finding in therapy-resistant focal epilepsy is sclerosis of the hippocampus (*Blümcke, 2009*). The third most common finding (following epilepsy-associated tumor) is a malformation of cortical development (MCD) - cortical dysplasia – a congenital malformation of a small area of the cortex.

1.1.4 Risk of post-surgical deficits

Removing parts of the brain is a major medical procedure. Apart from the medical risks involved in any surgery (reactions to anesthesia, excessive bleeding, infection, stroke etc.), any damage to or removal of viable tissue can result in a subsequent deficit and/or lack of function. The most consistently reported post-operative deficit following resection of the language-dominant temporal lobe is decline in verbal memory and learning (*Baxendale and Thompson, 2005*). Decline of non-verbal – visuospatial - memory has been associated with resection of the non-dominant temporal lobe, but not as consistently or to the same extent (*Helmstaedter, 2013*). The risk of decline

following surgery should be seen in light of the fact that chronic temporal lobe epilepsy is also associated with progressive memory impairment (*Helmstaedter et al., 2003*).

1.1.5 Success of epilepsy surgery – predictive factors

Successful surgery is contingent on two crucial conditions: post-operative seizure control and minimal deficits following resection of viable brain tissue. The entire pre-surgical evaluation aims to delineate the epileptogenic zone and, using all possible investigating modalities, minimizing the resection area. The collected data of this extensive investigation serves to determine the probable course of disease, if in fact the patient is a surgical candidate or not and the likelihood of seizure freedom following surgical intervention. All patients need to be investigated thoroughly and counseled individually regarding chance of seizure freedom and the risk of deficit. For TLE patients, the risk of various cognitive deficits and its implications in daily life is a key point.

It is important to remember that the prediction of seizure freedom remains separate from the prediction regarding cognitive decline. Positive predictors for seizure outcome in TLE patients are hippocampal sclerosis and an abnormal MRI (*Tonini et al, 2004*) where pathological findings increase the chance to obtain seizure freedom following surgery. Following extra-temporal resection negative predictors for poor long-term outcome has been identified as a normal MRI and subsequent neuropathological findings of cortical dysplasia, non-localized ictal EEG and incomplete resection of known lesion (*Jeba et al, 2007*). This underlines the importance of high quality structural MR imaging.

Regarding the prediction of cognitive decline following ATR, two main points are important: which temporal lobe is to be resected and the pre-operative memory capacity. Resection of the temporal lobe connected to the language-dominant hemisphere poses a much greater risk for decline in verbal learning and memory. If baseline memory function in the patient is good, the risk for decline is also elevated (“if you have much, you lose much”; *Baxendale et al., 2006; Baxendale, 2008; Binder et al., 2008*).

1.1.6 Outlining the two patient groups in the thesis

Paper I includes patients that were investigated for epilepsy surgery and where, as part of the work-up, advanced MRI technique was applied in order to increase the possibility to visualize cortical pathology. This paper pertains to the prediction of seizure outcome.

Paper II, III and IV aim at developing and using another advanced MRI technique, fMRI, in order to improve the prediction for verbal memory decline in patients eligible for temporal lobe resection.

1.2 Neuroimaging

Since the 1990s when MRI came to large-scale clinical use, its role in neuroimaging has become of undisputed importance. The possibility of using non-ionizing radiation to acquire images of the brain in multiple planes is very attractive. From the beginning of the 21st century Lund University Hospital has acquired and sustained advanced MRI equipment for clinical and research purposes. The high-resolution MRI scanners used in the projects described in this thesis have a static main field strength of 3 tesla (T), which is about 50 000 times greater than the magnetic field of the Earth.

Putting this great force and advanced machineries to best use is intrinsically multidisciplinary. Solely to describe the way MRI generates images is complicated and requires an advanced understanding of physics. Immensely simplified, but hopefully understandable for the clinical neurologist, the basic MR scanner consists of a large magnet, a gradient coil, a radio frequency coil and a computer.

1.2.1 Basic MRI physics

In MRI it is the magnetic signal from hydrogen nuclei (protons) that is detected. The human body contains large amounts of water, i.e. large amounts of hydrogen protons. Outside the magnetic field, the protons are randomly oriented. However, when a subject (patient) is placed in the scanner, a small fraction of the moments (protons) align with the static, main field of the scanner. In order to achieve a change in signal, this equilibrium needs to be disturbed by adding energy. A Radio Frequency (RF) pulse is transmitted into the subject exciting the aligned moments and increasing their angle relative to the static field. The proton moments will subsequently relax, seeking a lower energy state, realigning themselves with the static magnetic field whilst re-transmitting energy in the form of an RF signal.

This signal is picked up by a receiver coil and stored as the excitation process is repeated a number of times in the chosen MR pulse sequence. In the sequence, various magnetic field gradients that encode proton position around the main field are applied. These gradients can be applied in three different directions to spatially encode the MRI signal. The subsequent computerized reconstruction of data provides us with images of the brain with superior soft tissue contrast compared to CT and with excellent temporal and spatial resolution.

1.2.2 Signal-to-noise-ratio, SNR

The quality of the images is affected by a number of different factors such as magnetic field inhomogeneity, magnetic field strength, patient body movement, respiratory motions, slice thickness, scan parameters, etc. These disturbing influences, or random signals, are called noise. The relationship between the amount of noise present and the

MR signal is expressed as the Signal-to-Noise Ratio (SNR). Simplified, SNR describes why the MR image is grainy or how much of the signal from the subject you are examining describes the subject as opposed to originating from other factors (noise).

1.2.3 Surface coils

One way to improve SNR is to use surface coils. A high SNR – good signal, little noise - is desirable in MRI and a constant field of improvement. By adjusting parameters like slice thickness, receiver bandwidth, number of acquisitions and various scan parameters, image quality can be improved.

The surface coils that receive radio frequency energy (RF pulses), should be placed as close to the region of interest as possible, in order to get the strongest possible signal. How the coil is positioned is of great importance, as only the region close to the surface coil will contribute to the signal. The referring clinician should provide as much localizing information as possible, i.e. anatomical correlates from semiology and electrophysiological examinations, so that the surface coil can be placed over the most interesting cortical area.

1.3 Functional MRI (fMRI)

fMRI was first used to explore brain function in humans in 1992 (*Belliveau et al., 1992; Bandettini et al., 1992*) and the method has since then dominated brain mapping research due to its non-invasive nature. Functional neuroimaging is a significant part of cognitive neuroscience. It is extensively used in research and can be combined with other methods, such as EEG and NIRS (near infra-red spectroscopy). The technical equipment, including the software and statistical approaches, are constantly evolving.

1.3.1 The blood oxygenation level dependent (BOLD) contrast

When a specific region of the cortex increases its neuronal activity in response to a given task (for instance, movement of the right hand), Cerebral Blood Flow (CBF) increases, delivering oxygenated hemoglobin to the activated area. Oxygenated and deoxygenated hemoglobin have different magnetic properties which, coupled with the local changes in blood flow and volume, cause a measurable, localized difference in the MR signal. This indirect measurement of neural activity is the BOLD - Blood Oxygenation Level Dependent – response (Figure 1).

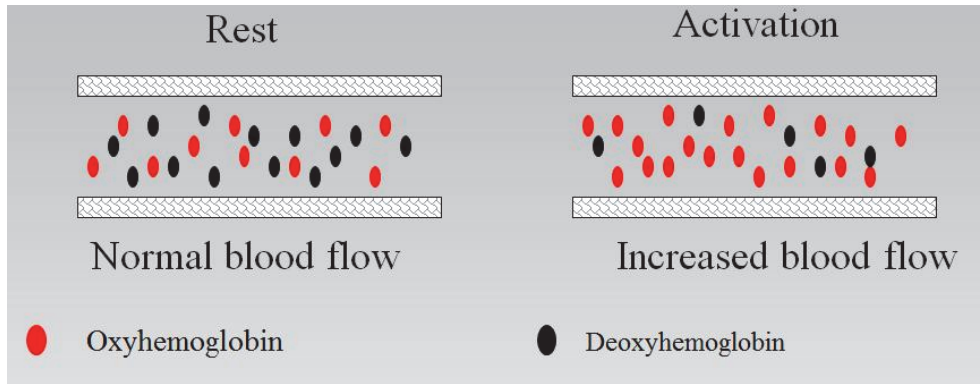


Figure 1. Source: Maria Strandberg

The hemodynamic response of the BOLD signal typically reaches a maximum 4-6 seconds following a performed task. It undershoots at around 10-30 seconds before returning to baseline. It is a transient effect sensitive to both physiological factors (like response to medication) and psychological effects (repetition, expectations and unconscious strategies).

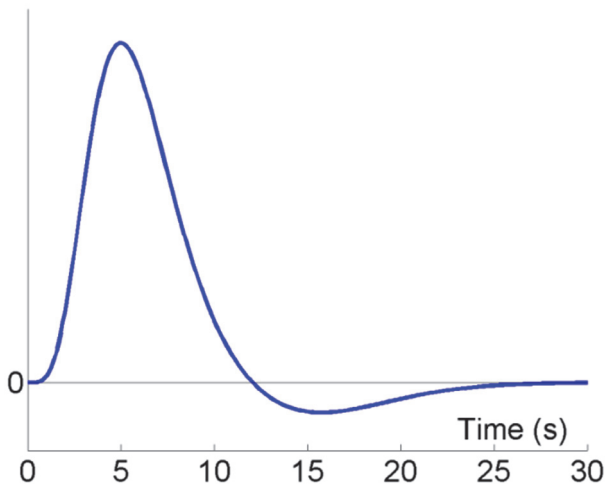


Figure 2. The Hemodynamic Response Function (HRF) of the BOLD signal which illustrates how activation elicits a brief, but intense period of neuron stimulation with increased blood flow before returning to homeostatic levels. Image source: Wikipedia – printed with permission.

The underlying physics of fMRI is the same as for MRI, but the fMRI sequence is designed to enhance the BOLD contrast. To extract the BOLD signal, however, and to present it in colored-coded activation maps, advanced statistical procedures have to

be applied. The brain is constantly active and the BOLD contrast is a relative change. The color-coded activation maps have to be interpreted with beforehand knowledge of function and anatomy. If the patient has activated the right hand, the most activated area should be over the motor cortex on the left side. fMRI images are considered to have good spatial resolution (millimeters), but poorer temporal resolution (seconds).

1.3.2 The use of fMRI

For research purposes, fMRI is widely used to study the functional connectivity of the brain. In the clinic, it has an established position when it comes to the localization of motor and sensory areas of the cortex and to map the visual and auditory cortex.

In recent years it has also replaced the previous gold standard Intracarotid Amytal Test (IAT, also known as the Wada test), to lateralize language. IAT can reliably determine hemisphere dominance for language, but its capability to quantify the risk for verbal memory decline is limited aside from grave deficits such as the amnesic syndromes. Furthermore, the IAT is an invasive procedure that can cause complications, stroke being the most serious one.

Language lateralization using fMRI has an 80-90% concordance compared to IAT (*Binder et al., 1996; Aldenkamp et al., 2003*) and there is some evidence that fMRI is more sensitive to right hemisphere processing than IAT (*Janecek et al., 2013*). The ability of fMRI to map the two different - Wernicke and Broca - language areas has evoked increased interest during the last years.

Functional activation is usually expressed as a relative difference of activation between the two hemispheres. For example, if language is tested and the resulting activation is pre-dominantly on the left side of the brain, the subject's language is *left lateralized* for language. This can also be expressed as a numerical value, a Lateralization Index (LI). LI can be calculated between whole hemispheres, but usually certain anatomic regions are of interest in connection with certain functions. To minimize the risk of not relevant activation interfering with data, a Region of Interest (ROI) can be characterized in advance and the lateralized index calculated for that area only.

1.4 Introducing neuropsychology

Neuropsychological assessment of the individual patients brain function is fundamental in epilepsy surgery investigations and cannot be replaced with other investigations. The tests should be standardized, validated and testing should be performed by a trained neuropsychologist. The testing is a time-consuming process that can take 2-3 hours. The psychometric test battery consists of an array of tasks testing multiple cognitive functions, including memory, language and spatial skills, problem-solving, attention

and processing speed. Results provide an overall view of the cognitive level of the patient.

For TLE, the testing of memory is of particular importance as resection involves anatomical structures crucial to memory. The material-specific model for memory maintains that the dominant temporal lobe is specialized for processing verbal information and the non-dominant hemisphere for learning and recalling non-verbal information. It is a general finding that TLE patients develop material- and hemisphere-specific deficits following long-standing therapy-resistant seizures (*Jones-Gotman et al., 2000; Helmstaedter et al., 2003*).

1.4.1 Taxonomy of memory

The memory system can be divided into short-term and long-term memory, where short-term memory also serves as working memory. Long-term memory consists of declarative and non-declarative memory. Declarative consists of semantic memory, which is memory for facts and learned information (“Stockholm is the capital of Sweden”) and of episodic memory. Episodic memory refers to personal experiences and past events. It is a “one exposure”-memory formation, like remembering yesterday’s dinner or that you left the umbrella in the car. Episodic memory is particularly afflicted in epilepsy and deficits have serious implications on patients’ daily life and function. Different factors, including sentimental cues, affect the efficacy of encoding in episodic memory.

In paper II we explore the LOP-effect (Levels-of-Processing) and the DM-effect (Difference-due-to-Memory). When a stimulus is being processed in a meaningful manner, so called deep processing, the material will be better remembered compared to if the same stimulus was being processed with emphasis on perceptual features, so called shallow processing. The comparison of deep encoding trials compared to shallow encoding trials is the main effect of encoding, the “level-of-processing” (LOP). The LOP-effect has previously been identified as a robust effect in human memory (*Craik and Lockhart, 1972; Otten et al., 2001; Petersson et al., 2003*).

The DM effect, “difference-due-to-memory”, is the comparison between correctly remembered (encoded) words and forgotten (not encoded words). This contrast is the event-related part of the paradigm and it requires a post-hoc recognition test to sort out successfully encoded events. The DM effect has previously been observed in memory relevant structures such as the prefrontal cortex and the MTL (*Craik and Lockhart, 1972; Fletcher et al., 2003*).

Of particular interest is the study of incidental episodic memory as it has shown to have a high ecological validity, i.e. correlating significantly to memory in everyday life (*Helmstaedter et al., 1998*). Incidental encoding requires the tested subject to be unaware of the fact that memory effects will subsequently be tested.

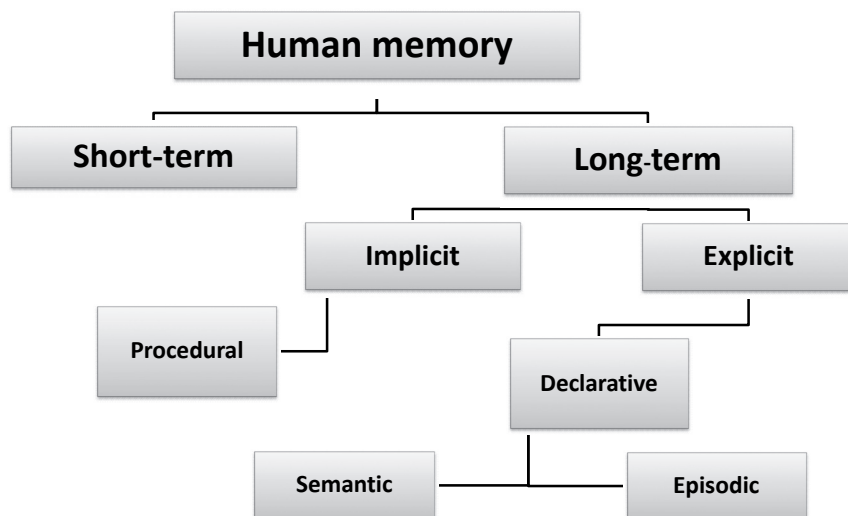


Figure 3. Schematic overview of human memory. Image source: Maria Strandberg

1.4.2 The anatomical structures of episodic memory

The medial temporal lobes and the hippocampi in particular, are very important for memory function as they play a critical role in learning and establishing episodic memories. Without the medial temporal lobe, the capacity to form procedural memories is intact (e.g. how to play the piano), but there are no recollections of related events. The anatomical structures of the memory system are mainly situated in the temporal lobe and consist of the hippocampus, the entorhinal, the perirhinal and the parahippocampal cortices.

1.4.3 Connecting fMRI and memory

From a clinician's point of view, cognitive fMRI is all about creating a desired state and then measuring the task-induced brain activation associated with this state. The reality is, of course, much more complicated and requires multidisciplinary input from physicists, engineers, neurologists, neuroradiologists and neuropsychologists. There are a number of factors to take into consideration before the moment when the subject lies in the MR scanner performing a particular task.

1.5 fMRI paradigm design

As previously stated MRI is used to acquire structural images and visualizing anatomical structures. The investigated subject has only to lie as still as possible to avoid movement artifacts. In fMRI, the focus is on the functional connectivity in the brain of the subject while performing a specific task. The task can be a particular activity that should be performed or stimulus that is presented. A stimulus can be presented visually on a small screen mounted in front of the patient or presented orally by headphones.

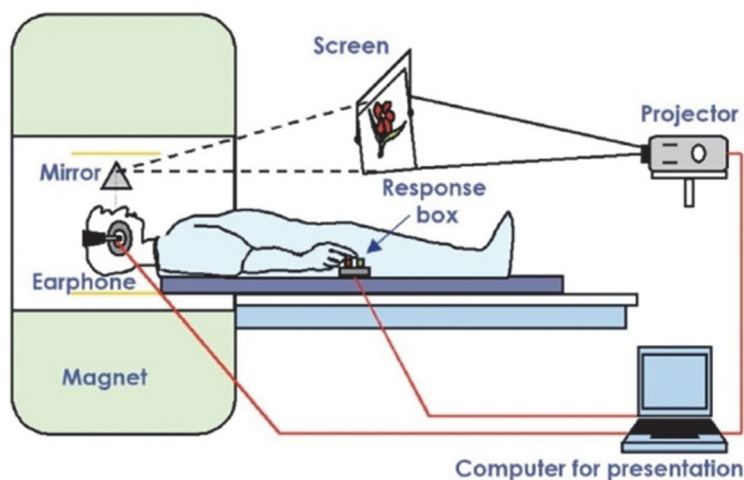


Figure 4. This is a typical setting in the MR scanner with the set-up (screen, mirror, response box and computer) to perform an fMRI experiment. <http://openi.nlm.nih.gov/faq.php> – open access use

The stimulus sequence presented is usually referred to as an fMRI paradigm. The design of the paradigms depends on the brain function of interest and it comprises a clearly defined task. The transient nature of the BOLD effect puts certain demands on the task design to evoke meaningful activation. For visualization of motor-sensory cortex, repetitive movement of or sensory stimulation on the hand, foot or mouth is performed. A patient eligible for neurosurgical intervention adjacent to the motor cortex can be subjected to a motor-sensory fMRI paradigm in order to localize eloquent tissue.

There are two possible paradigm designs: block design and event-related design. The block design is the most common design and it consists of blocks of activity (e.g., movement of the hand) separated from blocks of inactivity (baseline, in this case rest). This translates into the detection of increase in neuronal activity when a subject performs a certain task compared to another moment when the task is not performed.

This design is typically used to test motor-sensory function and to lateralize language, usually with robust results. However, it does not permit analysis of individual trials within the block and often has no performance measurement. The repetitive nature of

the task can cause effects of habituation and expectation. In other words: the task becomes almost effortless (“boring”), not requiring extra oxygenation and thereby not a measurable BOLD effect.

The event-related design is more complex as it permits the study of individual events. Each image or word that the subject is exposed to during the fMRI scanning is defined as an event. As each event is short and transient many events have to be collected to create a contrast. Although less robust and more difficult to analyze, event-related design has the advantages of making it more suitable for exploring cognitive abilities. Subject expectation and use of strategy can be minimized by a randomized trial order and a post-hoc classification of the subjects’ response to trials can be performed. In memory research, both block and event-related designs – and even a mix of the two – have been used (*Burgund et al, 2003; Powell et al., 2005; Peterson & Dubis, 2011*).



Figure 5. This is an illustration of the block and event-related designs (presentation of stimulus and image acquisition). Edited from Démonet J et al. *Physiol Rev* 2005; 85:49-95; image printed with permission. <http://physrev.physiology.org/content/85/1/49>

1.5.1 fMRI paradigm design in language

There is an array of language tasks aiming at either lateralizing language or localizing more specific linguistic processes. The tasks include word generation from auditory or visual cues, rhyming, listening or reading a text. Although several anatomical structures and functional networks are engaged in language, in case of investigation for temporal lobe surgery, the crucial issue is to lateralize language to the left or the right hemisphere. The involved fMRI paradigms are most often block designed as they are the most robust for this purpose and provide clear-cut results.

1.5.2 fMRI paradigm design in memory

The advent of event-related fMRI has opened up the possibility to further divide memory into its principal components such as encoding, storing and recalling and to search for the anatomical correlates. To study episodic memory, particularly verbal episodic memory, an event-related paradigm design is required. Each exposure (event) is a possibility to encode, i.e. to create an episodic memory. Post-hoc sorting of events, where subsequent memory effects can be identified, makes it possible to study the actual

encoding state. Although countless studies have been performed to this end, no gold standard fMRI paradigm to study memory and its constituents exists.

1.5.3 fMRI memory and language research in TLE patients

The introduction of fMRI have confirmed that material-specific memory deficits in TLE patients can be visualized as asymmetric functional activation in the MTL (*Golby et al., 2001; Golby et al., 2002; Powell et al., 2007; Banks et al., 2012*). In the first years of the 21st century, several groups published studies reporting predictive value for memory deficits using various fMRI paradigms (*Rabin et al., 2004; Richardson et al., 2006*). Successful group studies inspired hope for development of a quantitative test with predictive power for the individual patients' outcome. Richardson and colleagues (*Richardson et al., 2004*) were first to demonstrate a predictive value in a clinical setting using an event-related fMRI-paradigm on patients with temporal lobe epilepsy in order to predict post-operative memory decline at an individual level. The extent of surgery-related verbal memory decline in patients undergoing left TLR was predicted by the relative verbal memory encoding activity, measured by fMRI, in the left hippocampus compared to the right.

The findings of this study has not been identically reproduced, but several studies have published fMRI reports pointing to a predictive value for assessment of post-surgical memory outcome (*Janszky et al., 2005; Binder et al., 2008; Bonelli et al., 2010*). In order to increase the predictive value and taking surrounding factors into consideration, multivariate models including fMRI data together with other clinical parameters have been constructed (*Baxendale et al., 2006; Bonelli et al., 2010*).

In recent years, data clearly point to the importance of investigating both memory and language as they are closely linked (*Baldo et al., 2006; Binder et al., 2008 and 2009; Labudda et al., 2010*). Binder et al (*Binder et al., 2008*) reported that fMRI language activity in frontal language areas had the strongest predictive value for verbal memory outcome following temporal lobe resection. The underlying hypothesis is that language processes and verbal encoding co-lateralize, a theory that is supported by other researchers (*Powell et al., 2008; Helmstaedter et al., 2008; Bonelli et al., 2011*) and concurs with previous theories of material-specificity.

1.6 Lateralization of function in fMRI

A good fMRI paradigm should show interhemispheric asymmetry with increased/decreased activity in a pre-defined area either on the left or the right side. Visual assessment should be performed by a trained neuroradiologist, and complemented by statistical laterality assessment with numerical indices.

1.6.1 Statistical issues in laterality assessment

There are several methods to calculate asymmetry index/lateralization. In fMRI the smallest units of activation are voxels (three-dimensional units of volume containing numerous brain cells). Signals from voxels matching the expected time-course of the BOLD signal well are given a high activation score and voxels with little or no correlation to the expected signal are given a low score.

One of the most common methods to calculate a lateralization index (LI) is to subtract active voxels from left to right and divide with the sum all active voxels (left and right together): $LI = (Left - Right)/(Left + Right)$. This approach requires that a definite cut-off threshold for when a voxel is active or not has to be set, making it a highly threshold-dependent method. Choosing a threshold is intricate as it is intended to separate active voxels from inactive. A generous (high) threshold could mean including task-irrelevant activation, whereas setting a strict (low) threshold means possibly excluding relevant activation.

1.6.2 The bootstrap method, the LI toolbox and LI curves

In our studies, we opted for another approach to calculate lateralization, a method described in an original article by Wilke and Schmithorst (2006). A lateralization index toolbox, LI toolbox (*Wilke & Lidzba, 2007*), is included in the computer software used to independently analyse each voxel by Statistical Parametric Mapping (*Wellcome Department of Cognitive Neurology, <http://www.fil.ion.ucl.ac.uk/spm>*). This toolbox applies a statistical method called bootstrap, a technique that tries to find the distribution of the sample by intensive resampling. Data quality is enhanced by outlier detection and by broadening the underlying information, resulting in very stable mean lateralization indices. The toolbox presents results not only as a single numerical laterality index; it also offers laterality indices for a range of consecutive thresholds eliminating the need for a pre-defined cut-off threshold (*Wilke and Schmithorst 2006; Seghier 2008*).

1.7 Issues in fMRI research

The multidisciplinary aspect of fMRI research is evident from the set of difficulties that one has to face in this field. Stating the obvious, humans are all individuals, pinpoints the first and foremost consideration in all cognitive research. Humans *are* individuals with unique experiences, abilities and circumstances. For instance, a language task has to take into consideration if it is the primary language of the subject or not, educational level and state of basic reading ability. Similar concerns have to be registered for each investigated subject individually.

Also, the crucial structure in memory research, the medial temporal lobe, is an anatomical region difficult to visualize (*Wagner et al., 2005*). It is afflicted by susceptibility artifacts like geometric distortion and loss of signal (*Constable et al., 2000; Fransson et al., 2001; Powell et al., 2004*) and the hippocampus is a relatively small formation given the typical voxel sizes used in fMRI. Choosing a small region of interest, ROI, may provide detailed information of where different processes are located, but likely it will make it more difficult to achieve robust results on an individual level. Opting for a larger ROI increases the risk of activation related to co-existing processes to interfere with data.

After coming to terms with technical issues and deciding on a suitable ROI, comes the design of the actual fMRI task. The BOLD response is an indirect response to neural activation influenced by factors affecting neurons. Expectation and strategy have impact on outcome. If the task consists of a series of images, most subjects will automatically look for a pattern to anticipate what will come. After a zebra and a lion, it would be more logic to display an elephant rather than a chair. If the subject has been asked to remember displayed images, the investigated subject may try to categorize the images or look for cues to trig memory. A too repetitive task can decrease the BOLD signal as the neurons adapt to the condition whereas incidental learning may need cueing to be effective. Some of these effects are wanted, some unwanted, but most likely they all influence the BOLD effect.

Finally, with the patient, the ROI and the task in place, the most important issue still to remember is that areas activated by a specific task may not be crucial for that task and all areas necessary to perform a task may not be activated at a given point. As clinical neurologists investigating TLE patients who are eligible for surgery, we must keep in mind that we are looking for lack of activation in the temporal lobe afflicted by epilepsy. At present, in fMRI research lack of activation does not equal lack of function, but may reflect the imperfections of the measuring tools at hand.

2. Aims of the Thesis

The overall aim of this thesis was to evaluate, develop and implement advanced MRI technology to improve outcome in epilepsy surgery.

The specific aims were:

2.1 Paper 1

To investigate the added value of surface coils for patients undergoing 3T MRI in the course of an epilepsy surgery evaluation.

2.2 Paper II-IV

To develop a comprehensive, clinically applicable fMRI test for assessment of memory related activity in the medial temporal lobe structures.

To investigate the possibility of language lateralization during the verbal memory paradigm.

To explore a new method to analyze and present single subject fMRI lateralization data with laterality curves and indices produced by a bootstrap algorithm.

To explore two conceptually different fMRI paradigms' ability to lateralize language.

To investigate if the pre-operative fMRI-task added predictive information regarding post-surgical memory deficits.

3. Material and Methods

The following is a summary of material and methods of the different papers in this thesis. For more detailed information including more figures and tables, the reader is referred to papers I-IV. Paper I is a retrospective study of a structural MRI-technique. In paper II, we developed an fMRI test to visualize memory and language. In paper III, the fMRI test was compared to traditional fMRI in terms of language lateralization. In paper IV, the fMRI test was subsequently applied on patients eligible for TLR and related to post-operative memory outcome.

3.1 Paper I

3.1.1 Patients and clinical data

For paper I, we retrospectively identified 25 patients that had been investigated at low Tesla (1.5T or lower), high resolution 3T and 3T with surface coils during their investigation for possible epilepsy surgery. The patients were both adults and children (14 females; age range 4-51 years, median 15 years) and five participants ultimately proceeded to resective surgery.

The initial MRI:s at 1.5T or lower were performed at the referring centers and the patients were then transferred to the University Hospital of Lund for radiological expertise. At referral, the patients were judged to be MRI-negative ($n = 15$), or to have unclear findings ($n = 10$), on previous MRI at 1.0-1.5T.

Surface coils had been applied over the suspected epileptogenic zone after imaging in the head coil. In MRI-negative patients, placement of the coils was defined by semiological analysis, extra-cranial video-EEG and, in selected cases, subtraction ictal SPECT co-registered with MRI and PET. In order to assess the use of the method, we collected and re-evaluated the clinical information and data from other investigational modalities, calling on the expertise of the multidisciplinary epilepsy surgery team.

3.1.2 MRI evaluation

All 3T and 3T surface coil scans were performed at a 3T Philips Intera MR scanner in Lund. The scanner used a 4-channel head coil and parallel imaging. The head coil was then exchanged for two flexible surface coils. The protocol included a T2-weighted FLAIR, T1-weighted 3D gradient echo sequences covering the entire brain and T1-weighted inversion recovery (IR) sequences in 2 planes covering the region with the suspected epileptogenic zone. Further scanning information is available in the original report. All images were retrospectively evaluated by an experienced neuroradiologist with knowledge only of the lateralization of the epileptogenic zone.

3.1.3 Surface coils – assessment of placement

For the MRI negative patients, coil placement was reanalyzed and graded, based on the degree of convergence between different investigational modalities. This categorization was created to evaluate if the specific purpose of the investigation, namely to identify a possible epileptogenic lesion, was optimally used. Category I was reserved for cases with good support for coil placement. Category II was for partial support and category III was for cases where there was no support for epileptogenicity in the underlying region where the coils were applied

3.2 Paper II, III and IV

3.2.1 Subjects/Patients

For paper II, fifteen healthy right-handed subjects were recruited (7 females, median age 34 years). For paper III, five healthy right-handed and five healthy left-handed subjects were recruited. Median age was 38 years and only two of them were females. In addition, six patients with therapy-resistant temporal lobe epilepsy participated in this study. Two of these patients were females, two were left-handed and the median age was 33 years. All six were under investigation for ATR and four proceeded to surgery at the end of the investigation.

For paper IV, an initial number of 24 patients with therapy-resistant TLE were recruited, but only fourteen could be included at the closing of this study. Out of these fourteen, eight patients underwent left ATR and six right ATR. All fourteen were left hemisphere dominant for language and nine of them were females. Age at disease onset was between 1 and 47 years and the disease duration ranged between 4-32 years.

For all the patients, being completely fluent in Swedish was an absolute criterion for inclusion. Any previous neurosurgical event was a criterion for exclusion.

3.2.2 fMRI paradigms

For paper II, a methodological study, we constructed a double fMRI test encompassing both a verbal encoding task and visuospatial task. The verbal encoding task used a mixed design (event-related and block) design with a subsequent recognition task post-scanning. It was a modified version of a task previously reported to activate MTL structures during encoding (*Fletcher et al., 2003*).

The verbal encoding task mixed two different tasks connected to underlined letters in a total of 192 nouns that were presented during scanning. Subjects were asked to perform one of two tasks: decide if the word was pleasant or not or if the underlined letters were in alphabetical order or not. In the deep encoding task, “pleasant or not”, subjects were instructed to make a personal assessment. For the shallow encoding task, “correct alphabetical order”, subjects were instructed to answer according to their knowledge of the alphabet. Below are examples from this task, showing how the task was presented.




Figure 6. Image source: Maria Strandberg

The block-designed visuospatial task was a mental navigation task initially designed for a PET study (*Roland et al., 1987*), but later modified for fMRI use. Beforehand subjects had been asked to write down a familiar walk in their hometown. The walk was divided into eight different stages and defined in words, e.g. “front door to bus stop”, “bus stop to school yard”. The subjects were instructed to, in their minds, for each visualized stage, walk from one point to another while trying to recall as many landmarks and details as they possibly could.

For paper III, the verbal encoding task was again used and it was compared with a standard language lateralization task, namely “word generation”. This task is block-designed and requires the subject to, in their minds, think of words starting with a certain letter. The generation of words is interrupted by periods of rest before another letter is seen. The task is block-designed and it is routinely used to determine language hemisphere dominance for clinical purposes.

For paper IV, the double fMRI task was again implemented.

3.2.3 Behavioral data

In paper II and paper IV, a post-scanning test was administered. The recognition test included the 192 shown words (96 words for deep and 96 words for shallow encoding) as well as an additional 96 words not projected during the scan. Subjects were asked if they had previously seen the words or not, allowing a post-hoc sorting of successfully encoded events and calculation of discrimination rate. In paper II, the behavioral data from this test was analyzed to determine the subjects' success rate and their possible inclination to respond positively when unsure if a word was familiar/remembered. Results were also used to create the contrast of remembered vs forgotten events (DM effect).

In paper IV, the behavioral data was used to control for task compliance and determine encoding success rate.

3.2.4 Statistical analysis

All data analysis was performed using MATLAB and pre-processing and statistical analysis was performed with SPM5 software (*Wellcome Department of Cognitive Neurology, <http://www.fil.ion.ucl.ac.uk/spm>*). The advanced procedure is described in more detail in paper II, and it involves motion correction, slice time correction, normalization and spatial smoothing of images. The BOLD time course was modeled by combining the resulting onset vectors from the various paradigms with the canonical hemodynamic response function (HRF). The resulting contrasting images were entered into a second level random effect analysis and the statistical parametric maps were thresholded at $p < 0.001$, uncorrected for multiple comparisons. This threshold was chosen to reduce the occurrence of false negatives. This threshold was consistently used throughout paper II, III and IV.

To calculate laterality indices a toolbox running within the SPM5 environment (*Wilke & Lidzba 2007*) was used. Lateralization indices were calculated in two regions of interest: the medial temporal lobe, MTL (paper II and IV) and the anterior language area of Broca (paper II, III and IV). Each paradigm produced one lateralization index (at least) for each region of interest (ROI), for instance: verbal encoding LI in the MTL ROI, or verbal encoding LI in the Broca ROI. This reflects the lateralization of activity during that task in that specific area.

Consistently, through paper II-IV, an overall LI mean greater than 0.1 was classified as left lateralized/typical (with regards to language processes) and an overall LI mean less than -0.1 was classified as right-lateralized/atypical. An overall mean LI between 0.1-(-0.1) was classified as bilateral (no lateralization). The previously described laterality curves visualize the numerical laterality indices as a function of the consecutive threshold, facilitating the assessment of trend and range of activation effects. The curves are presented in paper II and again used for analysis in paper III.

For the statistical analysis of neuropsychological data and fMRI LI data in paper IV the software SPSS Statistics was used. Multiple univariate logistic regressions were performed and Spearman correlation coefficients were calculated.

3.2.5 Clinical data and risk assessment – paper IV

The patients included in paper IV were all eligible for ATR at inclusion and they were consequently operated and examined post-surgery. Clinical data before (including age at disease onset, disease duration, number of antiepileptic drugs, findings on MRI) and after surgery (including seizure outcome, extent of resection, remaining hippocampal volume and histopathological diagnosis) were collected. Following a routine protocol, patients were tested psychometrically before and after surgery. A series of memory tests were drawn from this protocol and the results were corrected for age and education. The chosen parameters aimed at reflecting different aspects of memory, including encoding, retention and recollection. For verbal encoding we used a list learning task (Claeson-Dahl, CD; *Claeson et al., 1971*), including both immediate and delayed recall. For visuospatial memory we chose delayed recall from a constructional task, RCFT (Rey Complex Figure Test, *Lezak 1983*).

A clinical risk assessment score (RAS 0-3) was constructed from MRI, neuropsychological testing and hemisphere dominance. The RAS served as a basis for the assessment of added value from the fMRI lateralization indices. The judgment for added risk indicated by fMRI lateralization indices was based on assumptions of how the fMRI LI pattern should look like for any given patient with consideration to handedness and side of seizure origin. These assumptions were founded on previous fMRI research involving temporal lobe epilepsy patients (*Powell et al., 2007; Powell et al., 2008*). Deviations from expected pattern could result in either a possible added risk (+) or added risk (++). Expected fMRI LI pattern was considered no (0) added risk.

4. Results

The following is a summary of the results of the different papers in this thesis. For detailed information including more figures and tables, the reader is referred to papers I-IV.

4.1 Paper I

4.1.1 Image analysis

Possible epileptogenic lesions were detected on 3T MRI in 12 patients and no abnormalities were found in the remaining 13 patients. The identified lesions were malformation of cortical development (MCD) in 6, heterotopic gray matter in 1, hippocampal sclerosis in 3, white matter lesions in 1 and atrophy in 1 patient. 3T MRI provided new or additional information about the cortex, compared with reports from previous 1.0-1.5T MRI in 5 patients (20%).

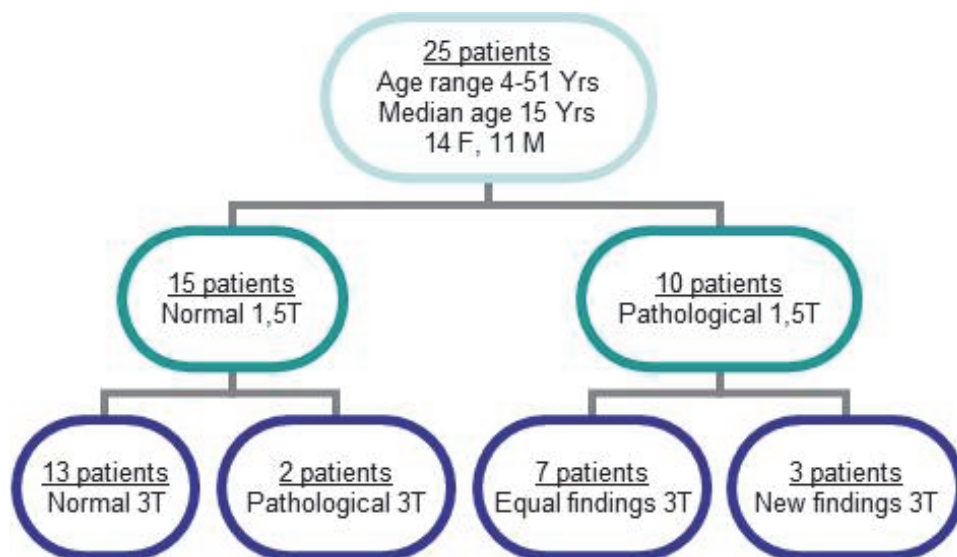


Figure 7. Schematic overview of the patients in the surface coil study. Image source: Maria Strandberg

Surface Coil MRI visualized the cortical lesions with somewhat better demarcation and improved morphological detail, but did not contribute to detection of previously undiagnosed lesions or added information regarding type of lesion in any of the cases reviewed in this study. Deep brain structures were less well depicted with surface coils due to decreasing SNR with distance from coil.

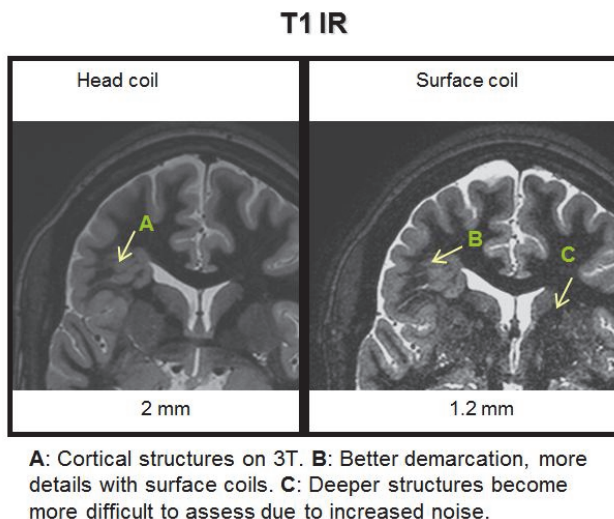


Figure 8. Head coil compared to surface coil images. Images provided by Elna-Marie Larsson

4.1.2 Surface coil placement

In the evaluation of surface coil placement, eight cases qualified for category I, i.e. good support for coil placement. Six cases were placed in category II (partial support) and one case was classified as category III (= no support for coil placement). Surface coil placement was not evaluated for the MRI-positive patients, as the coils were placed over the previously seen pathology.

4.2 Paper II

4.2.1 fMRI activation results

The initial analysis of fMRI activation results was whole-brain analysis. For the verbal encoding paradigm, we analyzed two contrasts related to language: the LOP, levels-of-processing, effect and the DM, difference-due-to-memory, effect. Both effects were studied for incidental memory and results were consistent with previous research: main regions of strong activation for the LOP effect was the left pre-frontal cortex and the

left MTL (*Fletcher et al., 2003*). Activation was sparser for the DM effect, but an interesting point of activation was found in the very close proximity to the left hippocampus in the left MTL.

For the visuospatial paradigm, a strong bilateral activation in the temporal lobes were seen with local maxima in the parahippocampal cortices bilaterally, a finding also consistent with previous research (*Ávila et al., 2006; Schacter et al., 2006; Beisteiner et al., 2008*).

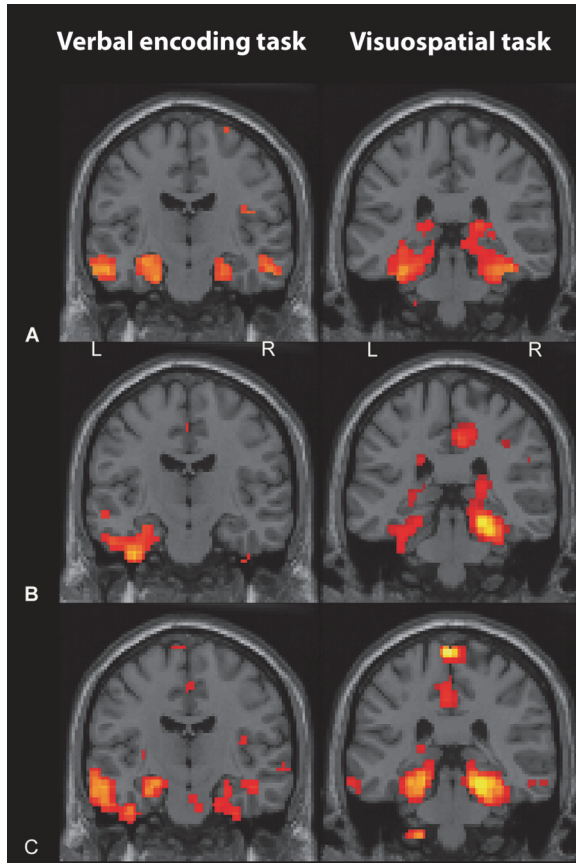


Figure 9. Functional activation results for the verbal memory paradigm (left; deep vs shallow contrast) and the visuospatial task (right; active vs baseline contrast) – group and individual results. Activation threshold was set at $p < 0.001$.

- A. Group results (top row)
- B. Individual results (subject 2)
- C. Individual results (subject 4)

Table 1 shows activated brain regions during the two tasks for each of the three contrasts with MNI coordinates, anatomical correlate and Z score listed.

Table 1: Functional neuroimaging data (paper II)

Verbal encoding task (A)										Visuospatial task (B)					
Deep-shallow contrast (LOP effect)					Hit-miss contrast (Dm effect)					Active-baseline contrast					
x	y	z	Anatomical structure	Z-score	x	y	z	Anatomical structure	Z-score	x	y	z	Anatomical structure	Z-score	
-9	48	39	L superior frontal gyrus	5.17	57	3	12	R frontal cortex (BA 6)	3.76	39	-72	27	R middle temporal gyrus	5.71	
0	33	-6	L anterior cingulum	4.73	-27	-18	-6	L, white matter/MTL	3.61	-6	-60	66	R medial parietal cortex	5.59	
-6	51	36	L superior frontal gyrus	4.50	-51	-78	12	L occipital cortex (BA 19)	3.55	-9	-57	54	R somatosens ass cortex	5.57	
27	-90	-36	Uvula (vermis)	4.50	12	27	45	R medial frontal gyrus	3.50	27	15	57	R middle frontal gyrus	5.18	
-66	-21	-18	L middle temporal gyrus	4.38	12	-60	12	R posterior cingulated	3.49	-21	6	57	L superior frontal gyrus	5.02	
-27	-21	-18	L hippocampus	4.21	21	-48	6	R corpus callosum	3.48	-27	51	6	L middle frontal gyrus	4.35	
-54	-6	-33	L inf temporal gyrus	4.17	30	-81	-9	R middle occipital gyrus	3.47	36	-30	-24	R parahippocampal cortex	4.70	
54	-9	-18	R middle temporal gyrus	4.32	-36	-90	-15	L inferior occipital gyrus	3.46	-33	-30	-24	L parahippocampal cortex	4.66	
45	18	-39	R temporal pole mid	4.31	21	-63	33	R medial parietal cortex	3.45	-33	57	-9	L orbitofrontal area (BA 11)	4.23	
-45	-60	33	L angular gyrus	4.18	36	-3	42	R frontal lobe (BA 6)	3.40	-9	-51	-51	L cerebellar tonsil	4.35	
-39	9	51	L middle frontal gyrus	4.17	33	-9	-24	R parahippocampal gyrus	3.37	30	-45	-42	R cerebellar tonsil	4.56	
-3	-48	30	L cingulate cortex, dors post	4.08	-24	-36	-30	L culmen (ant cerebellum)	3.36	-30	-36	-18	L fusiform gyrus (BA 37)	4.49	
-6	57	33	L prefrontal cortex (dorsolat)	4.05	6	-33	-51	L medulla	3.33	-45	-63	15	L angular gyrus (BA 39)	3.97	
3	-51	-51	R cerebellar tonsil	4.00	-39	-90	18	L occipital cortex (BA 18)	3.29	30	33	39	R prefront cortex, dorsolat	3.93	
-3	56	33	L prefrontal cortex (dorsolat)	3.58	30	12	-24	R superior temporal gyrus	3.27	24	33	-21	R inferior frontal gyrus	3.93	
6	33	6	R cingulate cortex, dors ant	3.31	-33	-18	27	L postcentral gyrus	3.21	57	-42	-18	R inf temporal gyrus	3.80	
39	33	-18	R frontal lobe	3.72	-51	-12	24	L postcentral gyrus	3.18	-42	36	33	L middle frontal gyrus	3.75	
57	27	-3	R inferior prefrontal gyrus	3.66	-15	-60	9	L cingulate cortex (BA 30)	3.18	21	-9	6	R putamen	3.66	

Statistical contrast maps were thresholded at $p < 0.001$ uncorrected; $T = 3.8$. Coordinates are selected activated clusters of interest, not the all activated areas in the whole brain analysis. Coordinates are given in MNI stereotaxic space. Numbers in parenthesis refer to Brodmann areas (BA). L – left hemisphere, R – right hemisphere.

4.2.2 Lateralization indices and laterality curves

For the analysis of lateralization indices, the two ROIs were applied: the MTL ROI and the Broca ROI. Each subject yielded three individual LI:s: two for verbal encoding (MTL and Broca) and one for visuospatial encoding (MTL). Eleven out of the fifteen subjects were left lateralized for verbal encoding in the MTL and fourteen out of fifteen in the Broca ROI.

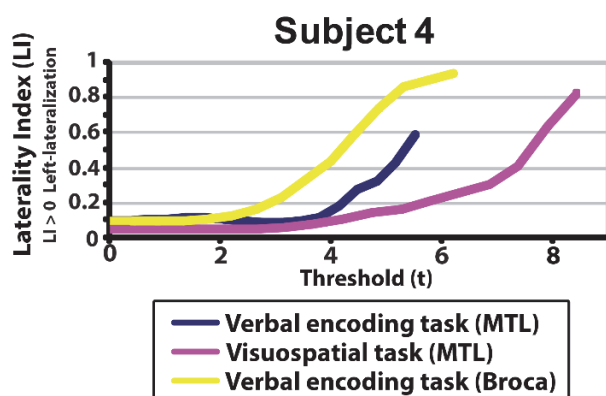


Figure 10. Each subject produced three LI:s. In this subject (subject 4), activation was left lateralized for verbal encoding in both the MTL and the Broca ROI. Visuospatial memory in the MTL was also left lateralized.

For the visuospatial task, group analysis showed no lateralization in the MTL. Individual results however, presented six subjects as right-lateralized, seven subjects as left and only two as non-lateralized or with equal bilateral MTL activity.

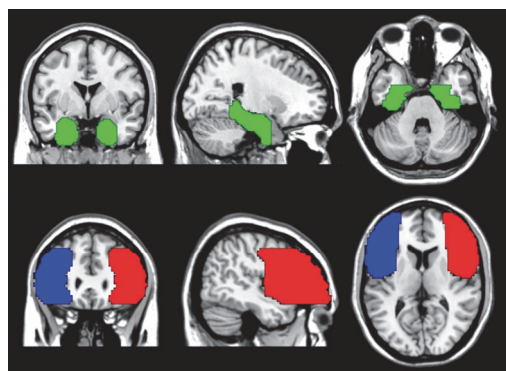


Figure 11 shows the ROI:s. Green = MTL region of interest, ROI, includes hippocampi, parahippocampi, entorhinal cortices, perirhinal cortices and amygdalae. Blue and red = language areas of interest, Broca ROI, includes the inferior frontal gyrus, the main part of the middle frontal gyrus and the dorsolateral prefrontal cortex bilaterally. Image source: Maria Strandberg

4.3 Paper III

4.3.1 fMRI activation results

Whole-brain group analysis of fMRI data showed activation for verbal encoding in the left superior temporal gyrus and the left middle frontal gyrus with contralateral activity in the right cerebellum.

The same analysis for the word generation task displayed a typical pattern of activation for language, with lateralization to the left hemisphere with contralateral cerebellar activity. The functional neuroimaging tasks are listed below (table 2) with MNI coordinates, anatomical correlates and Z-score.

Table 2. Functional neuroimaging results (paper III)

Word generation task					Verbal encoding task				
X	Y	Z	Anatomical structure	Z-score	X	Y	Z	Anatomical structure	Z-score
27	-63	-33	R Culmen	5.18	-39	15	-39	L BA 38	5.91
15	-69	-51	R Inferior semi-lunar lobule	5.07	39	-81	-42	R Pyramis	5.52
-33	-63	57	L BA 7	4.62	-6	18	66	L BA 6	5.13
-30	-66	45	L Superior parietal lobule	4.17	51	0	-36	R BA 20	4.83
39	27	-12	R Inferior frontal gyrus	4.58	-12	36	45	L Middle frontal gyrus	4.68
-6	18	45	L BA 32	4.55	-6	-51	21	L Posterior cingulated	4.62
0	27	39	L Frontal superior medial lobe	4.32	-48	-69	30	L BA 39	4.35
0	21	54	L Superior frontal gyrus	4.04	54	33	-6	R Inferior frontal gyrus	4.14
-3	-15	-21	Midbrain	4.51	24	-15	-21	R Parahippocampal gyrus	4.06
-42	18	-9	L Inferior frontal gyrus	4.20	-12	42	51	L Superior frontal gyrus	4.06

Statistical contrast maps were thresholded at $p < 0.001$ uncorrected; $T = 3.8$. Coordinates correspond to selected activated clusters of interest, not all activated areas in the wholebrain analysis. The listed coordinates refer to peaks in larger clusters of activation where anatomic structures of importance are listed in the text. Coordinates are given in MNI stereotaxic space. BA refer to Brodmann areas. L – Left hemisphere, R – right hemisphere.

4.3.2 Lateralization indices and laterality curves

Eleven out of the sixteen subjects showed clear pre-dominantly left-sided activity for language for both paradigms. One left-handed subject showed clear right-sided activity for both paradigms. Three subjects, all left-handed showed discordant results with one task being right-lateralized and one being left-lateralized.

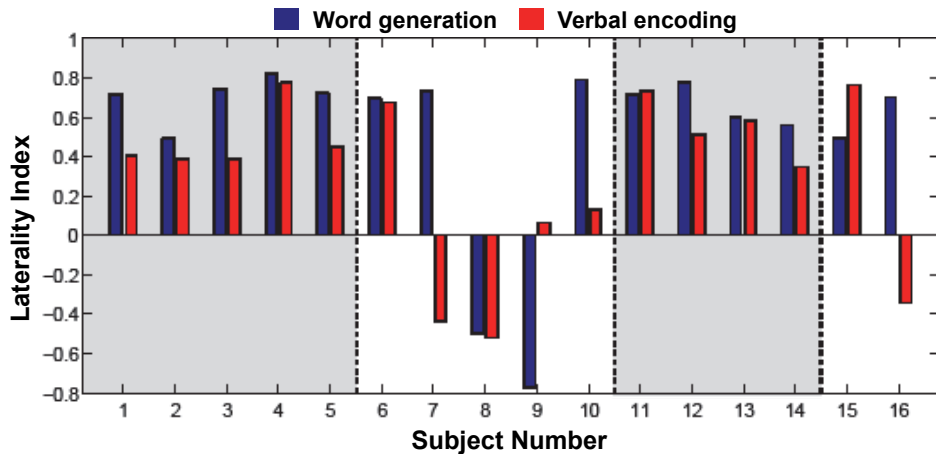


Figure 12. Individual laterality indices for all subjects are shown in bars: blue bars correspond to activation from word generation, red bars from verbal encoding. Grey backgrounds encompass dexterous individuals and white background non-dexterous individuals.

For two subjects (9 and 10) with low numerical LI:s the laterality curves were useful in determining lateralization for the verbal encoding task: one subject was deemed to have concordant, but not clear results and one subject was considered discordant. The verbal encoding LI curve for subject 9 indicates equal use of both hemispheres with a slight trend toward the left hemisphere until very high thresholds where activation deviates towards the right hemisphere. The LI curve for subject 10 deviates toward the left, although the numerical mean LI of the curve is low (0.13).

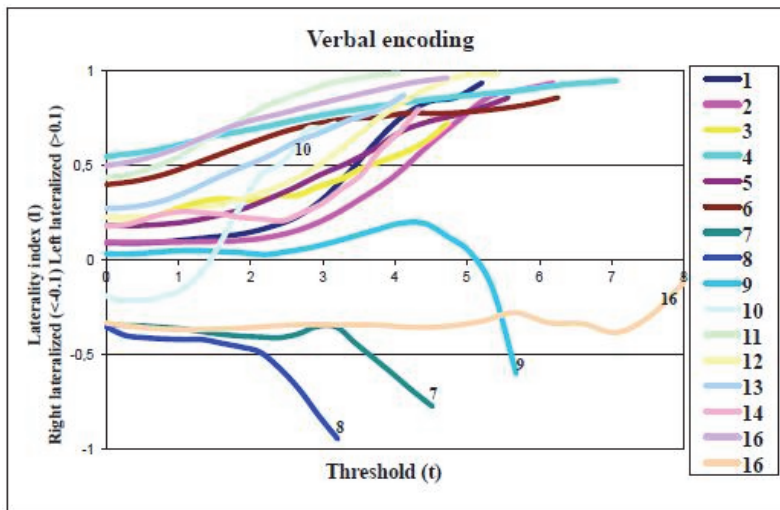
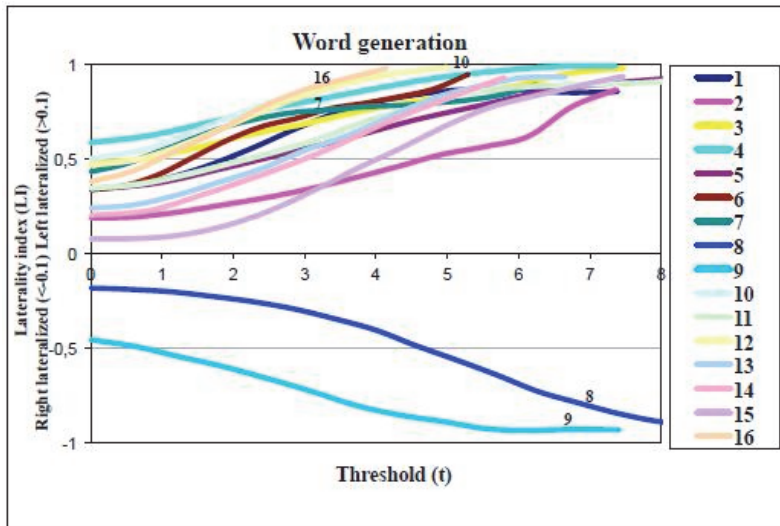


Figure 13. The individual laterality curves for all subjects, each represented with their own colour: one for each paradigm. The curves for the word generation paradigm clearly show the left lateralization for all but two subjects. For the verbal encoding paradigm, the left-sided dominance is also obvious, with the exception of four subjects where the curves offer information that complements the single lateralization index. Range of activation effects can be studied for both paradigms.

4.4 Paper IV

4.4.1 Outcome data

At the closing of the study, ten of the operated patients were seizure free, three experienced a 75% seizure reduction, one patient a 50-75% reduced seizures and one a 50-74% seizure reduction. The most common histopathological finding was hippocampal sclerosis (n=10) with single cases of neuronal heterotypes, disturbance of neuronal migration and astrocytoma grade I-II.

The median resected volume was 24 cm³ and the median remaining hippocampal volume was 0.2 cm³. Neither resection volume, remaining hippocampal volume, age at disease onset or disease duration showed significant correlation to the psychometric outcome parameters.

The post-surgical neuropsychological testing revealed that three patients in the RTLE group and five patients in the LTLE group suffered significant verbal memory decline. One patient from each group suffered significant decline in visuospatial memory.

4.4.2 fMRI lateralization data

According to our initial predictions, all patients were expected to have left-lateralized fMRI dominance for language as all but one patient were right-handed. The single left-handed patient performed an fMRI word generation task to establish language dominant hemisphere (left).

In figure 14 side of language hemisphere dominance as measured with fMRI in the Broca ROI is visualized by the large yellow oval. The lateralization of verbal encoding in the MTL ROI is the smaller red ovals and the side of the epileptogenesis is marked by the black dot.

On the top row, our initial assumptions for the RTLE and LTLE-group respectively can be seen. The second row shows the actual outcome of fMRI LI patterns for the patients with the added fMRI risk assessment (0, + or ++).

For the RTLE group, lateralization for verbal memory (red oval) was anticipated to be left-lateralized, but three patients did not exhibit the anticipated patterns.

For the LTLE group, five patients exhibited the anticipated fMRI LI pattern of left-lateralized language and three patients did not exhibit the anticipated patterns.

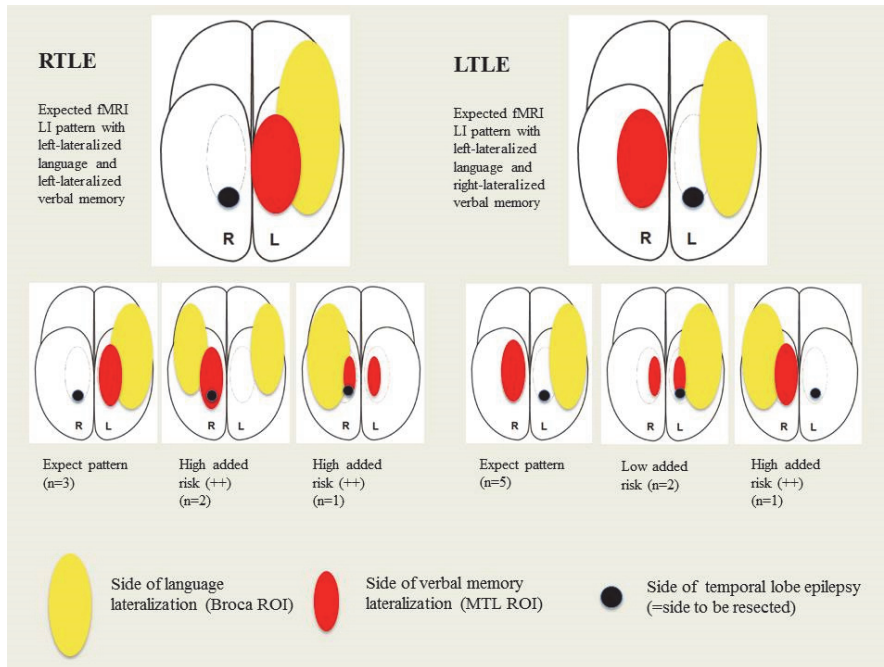


Figure 14. Source: Maria Strandberg

4.4.3 Risk assessment score and fMRI LI data

The risk assessment score (RAS) contained four levels from 0-3 where RAS 0-1 was considered low risk and 2-3 was considered medium-high risk for post-operative verbal memory deficit. Six patients were considered low and eight patients were considered medium-high risk. Eight patients were judged to have no added risk according to their fMRI indices. Two patients were judged to have low (+) and four patients high (++) added risk due to their fMRI indices pattern. The six patients with increased risk due to fMRI were dispersed over all RAS-levels (see table 3).

Table 3.

RAS	Nr of patients/RAS level
0	1 (++)
1	5 (1 (++) , 4 (0))
2	7 (4 (0) , 1 (+) , 2 (++))
3	1 (1 (+))

Four patients had an unexpected outcome defined as RAS 2-3 with post-operative intact memory or RAS 0-1 with post-surgical decline in verbal memory. Two RTLE patients (RAS 2) that suffered verbal memory decline post-operatively were identified

by fMRI due to their bilateral language representation. Two patients that suffered verbal memory decline following surgery were identified neither by RAS (RAS 1) nor fMRI (anticipated LI patterns).

4.4.4 Neuropsychological outcome and fMRI results

Correlations between neuropsychological outcome and fMRI LI results were calculated for the whole patient group and for left and right TLE patients separately.

For the whole group the only significant correlation was between fMRI visuospatial memory LI in the MTL ROI and for change in figural memory (RCFT change score): strong left lateralization correlated to greater loss in figural memory. The same correlation was seen for the LTLE, but not for RTLE patients.

The fMRI verbal encoding LI correlated to different parameters for right respectively left TLE patients. For RTLE, left-lateralization for verbal encoding in the MTL ROI correlated with better verbal memory outcome. For LTLE, left-lateralization for verbal encoding in the Broca ROI correlated with worse verbal memory outcome.

5. Discussion Including Future Aspects

This discussion should be seen as a complementary discussion of the papers in the thesis. For more detailed discussions, see respective paper.

5.1 Paper I

In paper I, we concluded that 3T MRI with high resolution is valuable for lesion detection, especially MCD, in patients with drug-resistant epilepsy. A previous paper (*Knake et al., 2006*) reported this and our findings were supported in the same year as it was published (*Phal et al., 2008*). However, following the results of our study, we question the additional contribution from supplementary surface coil imaging at 3T MRI as we could not establish that the application contributed with information that influenced therapeutic decisions.

The administration of surface coils is awkward and time-consuming. It prolongs the scan time for the patient who has to lie still and cooperate for a longer period of time. If general anesthesia is involved, it is extended as scan time is prolonged with 6-7 minutes per sequence. In our center the placement of coils required the presence of a radiologist during the scan and the placement was, as shown, strongly dependent on information in the remitting form. The referents' wish for cutting edge neuroradiology is not necessarily accompanied by knowledge of the advantages and disadvantages of the methods.

A known phenomenon in epilepsy patients is "dual pathology" which describes the occurrence of two potentially epileptogenic lesions in the same patient (*Cendes et al., 1995; Salanova et al., 2004*). The epileptic activity may be generated by either lesion. For example, a patient may have a hippocampal sclerosis on one side and an extra temporal malformation of the cortex somewhere else. In a pre-surgical investigation it is important to determine which focus is the epileptogenic culprit. Focusing on a single lesion too much, for instance by applying surface coils over an anatomic area where other investigational data show little or no support for epileptogenesis, may cloud vision for pathology elsewhere. Lesions of interest in these investigations are often very subtle and not easily visible in a routine examination. A dedicated epilepsy protocol evaluated by the good eyes of an experienced neuroradiologist is required.

Our study includes quite a small number of patients. It is also a retrospective study forcing us to accept data at face value without designing our own examination protocols. Nevertheless, it provides a realistic view of the field at the time. In fact, in recent years surface coils in neuroimaging are no longer used in our center. Increased field strength, improved head coil with additional channels and upgraded software have been implemented to increase lesion detection.

Yet surface coils *may* still have a place in neuroimaging. In our study, the focus was mainly on MR negative patients and the possibility to improve lesion detection. Perhaps surface coils do have a potential role in further delineating a known lesion in MR positive patients. With increasing field strength (7 Tesla) and ever-improving software, connecting a specific cortical lesion as seen on MRI to a known neuropathological diagnosis is within reach. Histopathological classification of cortical pathologies has an important prognostic value for the patient (*Kim et al., 2011; Wang et al., 2013*), thus motivating extended use of surface coils to further delineate known lesions.

5.2 Paper II

The study for paper II started with the creation of the paradigm. The paradigm was created with the specific intention of future clinical testing of patients with temporal lobe epilepsy. For verbal encoding, we modified an event-related paradigm, known to produce activation in relevant areas like the pre-frontal cortex and the medial temporal lobes (*Fletcher et al., 2003*). Our focus was on incidental learning and we wanted to study the point of “event-exposure”. “Exposure” means, in this context, when the event reaches the MTL for possible encoding (the LOP effect). Inspired by the previous work of Richardson (*Richardson et al., 2006*), we also wanted to study successful encoding exposure (the DM effect).

The visuospatial task, the mental hometown navigation task, was initially included as a control task. Previous studies on healthy subjects using this task have produced robust bilateral MTL activation (*Janszky et al., 2005; Ávila et al., 2006; Schacter et al., 2006*). The task has also been utilized to test non-dominant temporal lobe function (non-verbal tasks) and has shown correlation between fMRI activation and RCFT test scores (*Jokeit et al., 2001*).

The novelty of this paradigm and study was the combination of factors, such as the inclusion of both verbal and non-verbal memory tasks. The combination of tasks has been proposed previously, but in the context of the subject performing one task after another (*Ávila et al., 2006; Sanjuán et al., 2010; Zacà et al., 2012*). With our paradigm we hoped to study two aspects of memory (verbal and non-verbal), but also two diverse cognitive functions relating to verbal encoding: actual encoding in the medial temporal lobe (MTL ROI) and verbal ability in the frontal language areas, the Broca ROI. In clinical practice, to study two cognitive functions in the same session holds obvious

practical and economic advantages. From a scientific point of view, to study two closely connected processes while they are being performed, rather than striving to test them separately, is attractive as it resembles reality, but, of course, complicates the interpretation of results.

The double paradigm was launched in the relatively safe setting of healthy right-handed subjects with a high likelihood of left lateralized language. We expected to find a high-proportion of left lateralized verbal memory and bilateral non-verbal memory. We also needed to establish functionality of the situation in itself. The total scan time of 50 minutes with a follow-up recognition test is a fairly long.

14 out of our 15 subjects showed left lateralized language, although left-lateralization for verbal encoding was not so clear at an individual level: 11/14 from expected 14/14. We were satisfied that we visualized the DM effect with our paradigm, but continued with the use of the more robust contrast, deep-shallow (LOP-effect), for the same task. All subjects were able to complete the investigation and behavioral data was satisfying. Our results spurred us to further explore the language activation and compare it to the clinically used language lateralization task, “word generation” (paper III).

At a group level, we could verify earlier results for the healthy subjects - i.e. bilateral MTL activation - but not at an individual level. We interpreted this as a possible consequence of strategy where a verbal strategy to solve the task (e.g. mentally “talking your way” through the walk) would produce a more left-lateralized response and visualization (“scenes”) a response to the right. The task has no performance measurement and the healthy subjects were not tested psychometrically. Aiming at future testing of patients the navigation task remained in the fMRI paradigm protocol.

The validity of lateralization indices lies in the activation the paradigm evokes, but also in how the LI is calculated. Cognitive contrasts can be subtle. In order to insure more robust LI:s to be studied at an individual level, we needed a solid system. In neuroscience, group results are sufficient, but for clinical purposes solid individual data are demanded.

The initial threshold for lateralization was inspired by a report published by Szafarski (*Szafarski et al., 2006*) and we used it consistently through paper II-IV. At the time of our study the toolbox based on the bootstrap method was novel (*Wilke & Schmithorst, 2006*), with few publications for reference (*Lidzba et al., 2008; Everts et al., 2009; Kurland et al., 2008*). Today, the LI toolbox based on bootstrapping is widely used and not under the magnifying glass in the same manner. The method produces robust LI:s and LI curves offer the opportunity to in depth study the threshold LI effects.

5.3 Paper III

In paper III the verbal encoding paradigm was re-used for language lateralization purposes and further exploration of its ability to lateralize language. The commonly used and well-established fMRI paradigm, “word generation”, was compared to results from verbal encoding. LI curves were used to extract information in individual subjects with borderline results. The studied subjects were a small group of healthy subjects and patients with mixed handedness (both right- and left-handed subjects), making results and conclusions preliminary at best. This study served as a trial run for our future patient cohort, which was also expected to be quite small and heterogenic with mixed handedness.

For right-handed subjects concordance between the two tasks for language lateralization was total (9/9). This emphasizes the connection between verbal encoding and traditional language lateralization. In most individuals the left hemisphere has an intrinsic aptitude for language and therein verbal skills are highly prioritized functions. The basis for the co-lateralization hypothesis for language and memory is that the cortex provides the ipsilateral temporal lobe with input, thus creating the setting for verbal and non-verbal material-specificity in the MTL. In this case, verbal encoding in the left hemisphere should be conditioned by activation through verbal processing in the left hemisphere, the most well-known asymmetry in humans (*Springer & Deutsch, 1993*). On the other hand, an extensive network activation and increased bilaterality can be protective, as the degree of language lateralization determines susceptibility to unilateral brain lesions (*Knecht et al., 2000*).

The nature of the connectivity between anterior areas and the medial temporal lobes is not completely clear. The deficits in naming and verbal episodic memory in TLE patients strongly suggest intertwined functional networks. The co-lateralization hypothesis is supported by studies combining structural and functional imaging (*Powell et al., 2006; Saur et al., 2008*). A model for language with a ventral and a dorsal pathway has been presented (*Saur et al., 2008; Griffiths et al., 2012; Price, 2012*) and it has been suggested that the uncinate fascicle in the temporal stem, which connects the amygdala and the hippocampus in the medial temporal lobe with the prefrontal lobe, is – if not an essential – at least a supporting pathway of language (*Duffau et al., 2009*).

For left-handed subjects results were, as expected, ambiguous. The difficulties in lateralizing language with fMRI mainly pertain to individuals with atypical handedness (*Szaflarski et al., 2006*). About 70% of healthy non-right-handed persons have left hemisphere dominance for language compared to 95% of healthy right-handed persons (*Szaflarski et al., 2002; Somers et al., 2011*). These numbers are *not* valid for an epilepsy population (*Dijkstra and Ferrier, 2013*) and hippocampal pathology, a common feature in this group, is connected with atypical language patterns (*Weber et al., 2006*). The discordance between the two paradigms’ results in itself is informative and supports previous reports stating that subjects with greater likelihood of atypical language representation should be investigated more carefully, using more than one language

paradigm (*Centeno et al., 2014*). Atypical handedness, lesions in proximity to the classical language areas, and lesions/injury acquired at an early age are factors all affecting language laterality. Our results highlight issues involving atypical language representation, issues that have to be addressed in a clinical context.

5.4 Paper IV

In paper IV the double fMRI paradigm was finally used for its original purpose: to test TLE patients eligible for surgery. As with the healthy subjects, patients had no major difficulties in the test situation. Behavioral data was similar to that of the subjects in paper II. Outcome results were also standard with regard to seizure outcome (*Télliez-Zenteno et al., 2005*), resected volumes (*Shamim et al., 2009*) and histopathological diagnosis (*Blümcke, 2009*).

Neuropsychological outcome showed that 3/6 of RTLE patients and 5/8 of LTLE patients suffered significant decline in verbal encoding following surgery. Numbers are reasonable, although slightly elevated compared to previous reports (*Sherman et al., 2011; Helmstaedter, 2013*), likely due to our stricter cut-off (1 standard deviation, SD) for significant decline.

Our study has a very limited number of study subjects, but it reflects the comparably small volumes that pass through our center. We chose to retain a clinically relevant perspective with choices, like the cut-off for significant memory decline, equal to what we effectively work with.

In our study, three of the four patients that received an (++) added risk due to unexpected fMRI LI indices were eligible for non-dominant resections. All three exhibited bilateral language patterns and this relates to our most interesting finding. RLTE patients suffer verbal memory decline after surgery, but to a lesser extent than LTLE (*Sherman et al., 2011; Rosvall-Andersson et al., 2012*). The prediction of risk patients in this group is most likely overlooked (*Helmstaedter, 2013*) as many of them have intact baseline memory.

Two of the three RTLE-patients with (++) added risk suffered verbal memory decline post-surgery. Without visible hippocampal sclerosis on MRI and with good pre-operative verbal memory, the fMRI indices add valuable information as it indicates an increased risk for these individuals. We interpret the unpredicted lateralization indices as a result of atypical language representation coupled with an atypically organized verbal memory, increasing these patients' vulnerability to intervention in non-dominant MTL structures. Histopathological examination for these patients revealed hippocampal pathology not visible on MRI. In fact, a recent study established an equal risk for postoperative memory decline in both RTLE and LTLE patients with unilateral hippocampal sclerosis and intact verbal memory before surgery (*Baxendale et al., 2013*).

The fMRI pattern for the third patient was similar to that of the other two mentioned earlier, but she received a very low risk assessment score. Although her fMRI patterns indicated increased risk, her poor pre-operative memory likely decreased the absolute risk of further decline. One explanation for this difference in verbal memory outcome between these three patients could be that the atypical language patterns originate from different critical stages of language development. These periods in time relate to cerebral functional plasticity at times of language development, age at disease onset and disease duration (*Helmstaedter 2013*).

The correlation we found between language (LI Broca) and verbal encoding in the MTL for the RTLE group also emphasizes the importance of visualizing connections between language and verbal encoding in the non-dominant hemisphere. The increased sensitivity of fMRI to non-dominant hemisphere processing (*Janecek et al., 2013*) can be of aid and improve individual counseling for patients eligible for resection of non-dominant TL. Atypical language representation should always raise alert in an epilepsy surgery investigation, considering the impact hippocampal pathology can have on language patterns and language lateralization (*Weber et al., 2006*).

In the LTLE group, most data regarding the fMRI indices for language and encoding confirmed the expected risk for verbal memory decline. In our study increased language lateralization in anterior language regions seemed to protect against post-operative decline. To comprehend this connection, the anatomical structures in our two different ROIs should be seen as a collaborating network where increased lateralization can be viewed as a compensatory activation in the language area that post-operatively manifests as a smaller change in verbal memory decline.

This reasoning is supported by the functional adequacy model, one of the two central models usually referred to in predictive studies of memory outcome following temporal lobe resection (*Chelune et al., 1991; Chelune, 1995*): **the functional reserve hypothesis** and **the functional adequacy model**. The functional reserve hypothesis suggests that the level of function of the hippocampus contralateral to the resected one will determine memory outcome. The functional adequacy model predicts that memory outcome will be inversely related to preoperative functioning of the resected tissue (*Chelune, 1995; Chelune and Najm, 2000*). Several fMRI studies have supported the functional adequacy model (*Binder et al., 2008; Powell et al., 2008; Bonelli et al., 2010*), as well as many earlier studies (*Helmstaedter and Elger, 1996; Stroup et al., 2003; Baxendale et al., 2006*).

Much emphasis has been on the damaged tissue in the temporal lobe, but we propose that the assessment of functional adequacy should not be limited to the MTL. It should include the collaborative network of the to-be-resected tissue as well and include evaluation of functional adequacy in the language network of the anterior frontal lobe. Interesting data is emerging regarding temporal lobe epilepsy as a network disease with widespread network disruptions, and ideas that intrinsic connectivity reflects behavioral capacities are demonstrated (*McCormick et al., 2013; Protzner et al., 2013*). Three out of the four MRI-negative patients that suffered significant verbal memory decline in

our study could be identified by unexpected fMRI patterns, suggesting that functional network changes precede structural changes. Although this again underlines the importance of high quality neuroimaging to search for lesions (paper I), functional connectivity reflects potentially responsive networks. Freedom from seizures can stop progressive memory impairment and even reverse decline (*Helmstaedter et al., 2003*). The functional adequacy of language has been sporadically examined compared to the studies of memory, but it seems to be fundamental (*Hermann et al., 1992; Bartha-Doering and Trinka, 2014*). It has been shown that 17-33% of TLE patients exhibit language deficits in more than one language domain (*Bartha-Doering and Trinka, 2014*).

Recently, focus has shifted somewhat from the functional adequacy model to network theories and the functional reserve hypothesis has also been revived. Bonelli et al (2010) found support for a predictive value for verbal memory according to the functional reserve hypothesis when studying fMRI activation asymmetry in the *posterior* MTL. In the same study however, activation patterns in the *anterior* MTL supported the functional adequacy model. Not only can the two models explain processes in different parts of the MTL, but they can also be applied differently depending on side of seizure focus. It has been suggested that the memory outcome in patients with left TLE is best predicted by a well-functioning right MTL, while patients with right TLE may depend more on the extent of the remaining memory function of ipsilateral memory structures (*Banks et al., 2012*).

“Active task fMRI” has in later years been complemented with “resting state fMRI” (*McCormick et al., 2013; Protzner et al., 2013*). Initial interest came from observations that particular networks, e.g. “the default mode network”, emerged as more active during scanning stages when subjects/patients were not asked to do anything in particular. Data is emerging that epilepsy is a network disease and even focal epilepsies are accepted in this entity where networks far from the focal epileptogenic zone are involved. However, the necessity to assess encoding and language in TLE patients is still undisputed. Handedness is subject to genetic and environmental influences and cannot be used for the determination of language lateralization. Advanced functional neuroimaging should be used to lateralize language on all patients eligible for resection of either dominant or non-dominant temporal lobe resection.

Prevailing theories and models for the intricate system of function and restoration in the brain aside, what remains is the patient. fMRI today holds a unique place in neurocognitive imaging and research. Improved active paradigm tasks with better correlates to neuropsychological tasks are being developed. The further characterization of resting state networks and their psychometric correlates in TLE patients raise the hope for improved prognostication for the individual patient.

6. Conclusions

6.1 Paper I

3T MRI is valuable and improved lesion detection in the cortex. The application of surface coils did not add value to 3T MRI investigation of patients evaluated for epilepsy surgery.

6.2 Paper II, III and IV

fMRI lateralization data was effectively analyzed using a bootstrap algorithm. LI data was presented as numerical indices and laterality curves. The clinically applicable fMRI test evoked relevant memory activity in the medial temporal lobe. The test also produced activity relating to processes in the anterior language area.

The verbal encoding paradigm was able to lateralize language to the same extent as the commonly used word generation paradigm in right-handed individuals. Subjects with discordant data from the two paradigms demonstrate the difficulties to characterize language processes in connection with atypical handedness.

The fMRI test produced relevant activity in regions of interest for language and memory in TLE patients. fMRI lateralization indices added information to traditional predictive markers, in particular patients eligible for non-dominant resection.

7. Swedish summary (Populärvetenskaplig sammanfattning)

Epilepsi är idag den vanligaste kroniska neurologiska sjukdomen i Sverige. Ca 60 000 människor, varav 10 000 barn, har epilepsi. De flesta blir av med sina anfall med hjälp av läkemedel, men ca 1/3 av patienterna blir inte hjälpta av farmakologisk behandling. En liten andel av dessa s.k. terapi-resistenta patienter kan vara aktuella för kirurgisk behandling av sin epilepsi.

De terapi-resistenta patienterna remitteras till utredning vid enheter som bedriver högspecialiserad epilepsivård. En del av utredningen går ut på att framställa bilder på hjärnan, dels hjärnans struktur, dels hjärnans funktion. Magnet-Resonans-Imaging (MRI) används för att ta bilder på hjärnans anatomi. Funktionell MRI (fMRI) används för att ta bilder på hjärnan i arbete. Vid den senare tekniken utnyttjar man lokala skillnader mellan syrerikt och syrefattigt blod som ett indirekt mått på nervscellsaktivitet som uppträder när en person utför en uppgift medan den ligger i MRI-kameran.

Den här avhandlingens syfte var att utvärdera och förbättra avancerade MRI tekniker för att förbättra resultat vid epilepsi-kirurgi. Detta har vi gjort dels genom att utvärdera en bildgivande metod som redan är i bruk, dels genom att utarbeta och implementera en ny metod där man använder sig av fMRI-tekniken.

Bilder av hög kvalitet är av största vikt inför en operation eftersom möjligheterna till anfallsfrihet ökar om en tydlig förändring kan lokaliseras och sedermera opereras bort. Operationen innebär dock risk för att viktiga funktioner i hjärnan skadas. Det vanligaste ingreppet innebär att man opererar bort en del av tinningloben (partiell temporallobsektomi). Tinningloben innehåller strukturer som är viktiga för språk och minne. En funktionell MR-undersökning av hjärnans minne- och språkområden syftar till att kartlägga dessa funktioner för att kunna förutsäga hur stort minnestapp en patient riskerar vid operation.

I delarbete I har vi undersökt värdet av ytspolar vid högfälts MRI (3 Tesla (T)). Ytspolar används för att lokalt för att få bättre bildupplösning. Våra resultat kunde visa att ytspolar inte tillförde något vid utredning av patienter med terapi-resistent epilepsi. När man ökade fältstyrkan i kameran till 3Tesla, ökades däremot möjligheten att finna fler förändringar i hjärnbarken.

I delarbete II, III och IV har vi använt oss av fMRI för att utveckla ett kliniskt användbart minnestest. Minnestestet, som avbildar språkligt och bildligt minne samt

till viss del även språkfunktion, prövades initialt på friska forskningspersoner. I den uppföljande studien (delarbete III) jämförde vi vårt minnestest mot det kliniskt använda fMRI-testet för språk. I den studien ingick friska forskningspersoner och patienter med terapi-resistent tinninglobs-epilepsi. I delarbete IV användes testet för sitt slutgiltiga syfte, nämligen att testa minnet hos patienter aktuella för kirurgisk borttagning av en del av en tinninglob på grund av terapi-resistent tinninglobs-epilepsi. Före operationen genomgick patienterna, förutom fMRI-undersökning av minnet, en omfattande utredning med bl.a. högfälts MR-undersökning och neuropsykologisk testning. Del av höger eller vänster tinninglob (beroende på epilepsins ursprung) togs bort i syfte att bota epilepsin. Efter operationen följdes patienterna upp med ny högfälts MRI och ny neuropsykologisk testning av minne och språk.

Baserat på resultat av dessa tre studier är vi övertygade om att minnestestet avbildar minne och till viss del även språk hos både friska människor och patienter med epilepsi. Vi har implementerat nya analysmetoder som numera används som standard inom detta forskningsområde. Testet är även använt för att undersöka personer med förväntat avvikande mönster för språk och minne. Vi har undersökt patienter som sedermera genomgått tinninglobsresektion. Vi har kunnat konstatera att avvikande språkmönster skulle kunna ha betydelse för hur minnet fungerar efter operation.

8. Acknowledgements

“Gratitude is the memory of the heart” (Jean Baptiste Massieu)

This thesis could not have been completed without the help, support and presence of many people. I would like to express my sincere gratitude to all who have supported and helped me over the years. I hope my thoughts expressed here is not the first sign of my appreciation.

First of all, I want to thank my supervisor, **Kristina Källén**, associate professor, for making this thesis possible – from start to finish. Eight years ago I casually mentioned that all residents should be presented with the opportunity to do research and you immediately offered me the opportunity to sit in on an fMRI research meeting, the first of many. Through the years you have guided and supported me - as a novice researcher, as a neurologist and as a fellow woman colleague in the making. In many things, I have come to depend on your honest advice, your extensive knowledge and resourcefulness. I thank you for this journey and I hope that it is not over yet.

I express my gratitude to my co-supervisor **Elna-Marie Larsson**, professor, who was crucial to my initiation to neuroimaging. You accepted my presence during hours of assessing images and always provided me with expert advice in our exciting, difficult field of research. Although distance has come between our common projects, I remain grateful for the start you gave me.

Thank you

Johan Olsrud, Christina Elfgrén, Danielle van Westen, Lars Stenberg and Ia Rorsman - all members of the initial fMRI research group with expert knowledge in various fields: MRI physics, neuropsychology and neuroradiology. **Peter Mannfolk**, thank you for the many hours of analysis and, on my request, re-analysis and personal tutorials.

All the **personnel at the MR-department** that I spent a lot of time with during the scans, holding our fingers crossed for the MR-unit not to play tricks on us.

My colleagues – past and present - at the department of neurology. Neuroscience attracted me from the start in the medical school, but the department of clinical neurology immediately became my professional home when I first started working there in 1999. It feels good to have a friendly banter with a scientific edge first thing in the morning. Even in these trying times, we share the joy of having a meaningful and interesting profession.

The members of the epilepsy team: **Britta Hesslow, Tobias Cronberg, Ariadni Zampeli, Carl Rosenblad, Hanna Ljung** and in particular, **Anna Hugoson**, who has been the voice of reason during this last very intensive year. I enjoy immensely working with you all and I foresee great things for our team.

The epilepsy surgery team and my collaborators in the department of neurophysiology: **Ingmar Rosén, Sofia Backman, Pernilla Lindén-Mickelson** and **Lisa Svensson**.

The epilepsy surgery teams in Göteborg and Uppsala, in particular **Kristina Malmgren** and **Eva Kumlien**.

A special thanks goes to **family members, friends, colleagues, patients** and **controls** that put their brains in the MR unit and made the accomplishment of these studies possible.

To **my friends** – with whom I share and want to share more of the good things in life - I vow to now dedicate more time to you. Thank you for standing by me during these years, solidly representing "life outside". I look forward to stimulating conversations on all matters, good food, good wine, travels and in general just existing together.

Above all, this thesis is a professional accomplishment, but it would not have materialized at all without my family. To my parents, **Christer** and **Kristin Strandberg**, I want to express my deepest gratitude. You have always given me unconditional love and support to do anything I want in my life. Thank you to my brother, **Olof Strandberg**, for your patience with all my questions and pleas for help in matters of imaging and computers. I feel lucky that we now have a professional, as well as familiar, connection.

To my wonderful children - **Alessia, Viktor, Sofia** and **Simon** – you are the most important miracles in my life and a constant source of joy and inspiration! Last, but not least, thank you, **Michele**, my partner in love and life, for all your love, support and endless patience. Words are not enough to describe my feelings - whatever I could write, it would still be just words...

9. References

- Andersson-Roswall L, Malmgren K, Engman E, Samuelsson H. (2012). Verbal memory decline is less frequent at 10 years than at 2 years after temporal lobe surgery for epilepsy. *Epilepsy & Behavior*, Volume 24, Issue 4, Pages 462-467.
- Aldenkamp, A, Boon P, Deblaere K, Achten E, Backes WH. (2003). Usefulness of language and memory testing during intracarotid amobarbital testing: Observations from an fMRI study. *Acta Neurol Scand*; 108: 147–152.
- Ávila C, Barrós-Loscertales A, Mallo R, Parcet M-A, Belloch S, Campos S, Feliu-Tatay R, González-Darder JM. (2006). Memory Lateralization with 2 functional MR Imaging Tasks in Patients with Lesions in the Temporal Lobe. *AJNR Am J Neuroradiol*; 27: 498-503.
- Baldo JV, Schwartz S, Wilkins D, Dronkers NF. (2006). Role of frontal versus temporal cortex in verbal fluency as revealed by voxel-based lesion symptom mapping. *J. Int. Neuropsychol. Soc.* 12, 896-900.
- Bandettini PA, Wong EC, Hinks RS, Tikofsky RS, Hyde JS (1992): Time course EPI of human brain function during task activation. *Magn Reson Med* 25:390–397.
- Banks SJ, Sziklas V, Sodums DJ, Jones-Gotham M. (2012). fMRI of verbal and nonverbal memory processes in healthy and epileptogenic medial temporal lobes. *Epilepsy & Behavior* 25: 42–49.
- Bartha-Doering L and Trinka E. (2014). The interictal language profile in adult epilepsy. *Epilepsia*: 1–14.
- Baxendale S, Thompson P. (2005). Defining meaningful postoperative change in epilepsy surgery patients: measuring the unmeasurable? *Epilepsy Behav.* 6:207–211
- Baxendale S, Thompson P, Harkness W, Duncan J. (2006). Predicting Memory Decline Following Epilepsy Surgery: A Multivariate Approach. *Epilepsia* 47(11): 1887-1894.
- Baxendale, Sallie. (2008). The impact of epilepsy surgery on cognition and behaviour. *Epilepsy & Behavior* 12: 592-599.
- Baxendale S, Thompson PJ, Sander JW. (2013). Neuropsychological outcomes in epilepsy surgery patients with unilateral hippocampal sclerosis and good preoperative memory function. *Epilepsia*, 54(9):e131–e134.
- Belliveau JW, Kennedy DN, McKinsty RC, Buchbinder BR, Weisskoff RM, Cohen MS, et al. (1991): Functional mapping of the human visual cortex by magnetic resonance imaging. *Science* 254:716–719.

- Beisteiner R, Drabeck K, Foki T, Geißler A, Gartus A, Lehner-Baumgartner E, Baumgartner C. (2008). Does clinical memory fMRI provide a comprehensive map of medial temporal lobe structures? *Experimental Neurology* 213:154–162.
- Binder JR, Swanson SJ, Hammeke TA, Morris GL, Mueller WM, Fischer M, Benbadis S, Frost JA, Rao SM, Houghton VM. (1996). Determination of language dominance using functional MRI: A comparison with the Wada test. *Neurology* 1996; 46; 978-984.
- Binder JR, Sabsevitz DS, Swanson SJ, Hammeke TA, Raghavan M, Mueller WM. (2008). Use of preoperative functional MRI to predict verbal memory decline after temporal lobe epilepsy surgery. *Epilepsia* 109, 57—69.
- Binder JR, Swanson SJ, Sabsevitz DS, Hammeke TA, Raghavan M, Mueller WM. (2009). A comparison of two fMRI methods for predicting verbal memory decline after left temporal lobectomy: language lateralization versus hippocampal activation asymmetry. *Epilepsia* 51, 618—626.
- Blümcke I. (2009) Neuropathology of focal epilepsies: A critical review. *Epilepsy & Behavior* 15: 34–39
- Bonelli SB, Powell RHW, Yogarajah M, Samson RS, Symms MR, Thompson PJ, Koepp MJ, Duncan JS. (2010). Imaging memory in temporal lobe epilepsy: predicting the effects of temporal lobe resection. *Brain*; 133: 1186–1199.
- Bonelli SB, Powell R, Thompson PJ, Yogarajah M, Focke NK, Stretton J, Vollmar C, Symms MR, Price CJ, Duncan JS, Koepp MJ. (2011). Hippocampal activation correlates with visual confrontation naming: fMRI findings in controls and patients with temporal lobe epilepsy. *Epilepsy Res*; 95: 246-254.
- Burgund ED, Lugar HM, Miezin FM, Petersen SE. (2003). Sustained and transient activity during an object-naming task: a mixed blocked and event-related fMRI study. *Neuroimage* 19: 29–41.
- Cascino GD. (2009) Temporal lobe epilepsy is a progressive neurologic disorder: time means neurons! *Neurology* 72:1718–1719.
- Cendes F, Cook MJ, Watson C, Andermann F, Fish DR, Shorvon SD, Bergin P, Free S, Dubeau F, Arnold DL. (1995). Frequency and characteristics of dual pathology in patients with lesional epilepsy. *Neurology*. 1995 Nov; 45(11):2058-64.
- Centeno M, Koepp MJ, Vollmar C, Stretton J, Sidhu M, Michalief C, Symms MR, Thompson PJ, Duncan JS. (2014). Language dominance assessment in a bilingual population: Validity of fMRI in the second language. *Epilepsia*. 2014 Sep 2. doi: 10.1111/epi.12757. [Epub ahead of print]
- Chelune GJ, Naugle RI, Lüders H, Awad IA. (1991). Prediction of cognitive change as a function of preoperative ability level among temporal lobectomy patients at six months follow-up. *Neurology*; 41:399–404.
- Chelune GJ (1995). Hippocampal adequacy versus functional reserve: predicting memory functions following temporal lobectomy. *Arch. Clin.Neuropsychol.* 10, 413–432.
- Chelune GJ and Najm IM. (2000). Risk factors associated with postsurgical decrements in memory. In: Lüders, HO; Comair, Y, editors. *Epilepsy surgery*. 2nd edition. Lippincott; Philadelphia: p. 497-504.

- Claeson L-E, Esbjörnsson E, Carté B-M, Wahlbin M. (1971). Manual to Claeson-Dahls learning test for clinical use (In Swedish). Stockholm: Skandinaviska Testförlaget.
- Constable RT, Carpentier A, Pugh K, Westerveld M, Oszunar Y, Spencer DD. (2000). Investigation of the hippocampal formation using a randomized event-related paradigm and z-shimmed functional MRI. *Neuroimage*; 12:55–62.
- Craik FIM and Lockhart RS. (1972). Levels of processing: a framework for memory research. *J Verbal Learning Verbal Behav*; 11, 671–684.
- Dijkstra KK and Ferrier CH. (2013). Patterns and predictors of atypical language representation in epilepsy. *J Neurol Neurosurg Psychiatry*. 2013 Apr;84(4):379-85.
- Duffau H, Gatignol P, Moritz-Gasser S, Mandonnet E. (2009). Is the left uncinate fasciculus essential for language? *J Neurol* 256:382–389.
- Everts R, Lidzba, K, Wilke M, Kiefer C, Mordasini M, Schroth G, Perrig W, Steinlin M. (2009). Strengthening of laterality of verbal and visuospatial functions during childhood and adolescence. *Human Brain Mapping*, 30, 473–483.
- Fletcher PC, Stephenson CM, Carpenter TA, Donovan T, Bullmore ET. (2003). Regional brain activations predicting subsequent memory success: an event-related fMRI study of the influence of encoding tasks. *Cortex*. 39, 1009-26.
- Fransson P, Merboldt KD, Ingvar M, Petersson KM, Frahm J. (2001). Functional MRI with reduced susceptibility artifact: high-resolution mapping of episodic memory encoding. *Neuroreport*;12: 1415–1420.
- Golby AJ, Poldrack RA, Brewer JB, Spencer D, Desmond JE, Aron AP and Gabrieli JDE. (2001). Material-specific lateralization in the medial temporal lobe and prefrontal cortex during memory encoding. *Brain* 124, 1841-1854.
- Golby AJ, Poldrack RA, Illes J, Chen D, Desmond JE and Gabrieli JDE. (2002). Memory Lateralization in Medial Temporal Lobe Epilepsy Assessed by Functional MRI. *Epilepsia*, 43(8):855–863.
- Griffiths JD, Marslen-Wilson WD, Stamatakis EA, Tyler LK. (2013). Functional Organization of the Neural Language System: Dorsal and Ventral Pathways Are Critical for Syntax. *Cereb Cortex*; 23(1): 139-47.
- Helmstaedter C and Elger CE. (1996). Cognitive Consequences of Two-Thirds Anterior Temporal Lobectomy on Verbal Memory in 144 Patients: A Three-Month Follow-Up Study. *Epilepsia* Volume 37, Issue 2, pages 171–180, February.
- Helmstaedter C, Hauff M, and Elger CE. (1998). Ecological Validity of List-Learning Tests and Self-Reported Memory in Healthy Individuals and Those with Temporal Lobe Epilepsy. *Journal of Clinical and Experimental Neuropsychology*, Vol. 20, No. 3, pp. 365-375
- Helmstaedter C, Kurthen M, Lux S, Reuber M and Elger CE (2003). Chronic epilepsy and cognition: a longitudinal study in temporal lobe epilepsy. *Ann.Neurol*. 54, 425–432.
- Helmstaedter C, Richter S, Roske S, Oltmanns F, Schramm J, Lehmann TN. (2008). Differential effects of temporal pole resection with amygdalohippocampectomy versus selective amygdalohippocampectomy on material-specific memory in patients with mesial temporal lobe epilepsy. *Epilepsia*; 49:88–97.

- Helmsteadter C. (2013). Cognitive outcome in different surgical approaches in temporal lobe epilepsy. *Epileptic disorders*. September, Volume 15, Issue 3, 221-239.
- Hermann BP, Seidenberg M, Haltiner A, Wyler AR. (1992). Adequacy of language function and verbal memory performance in unilateral temporal lobe epilepsy. *Cortex*. Sep;28(3):423-33.
- Janecek JK, Swanson SJ, Sabsevitz DS, Hammeke TA, Raghavan M, E Rozman M, Binder JR. (2013). Language lateralization by fMRI and Wada testing in 229 patients with epilepsy: rates and predictors of discordance. *Epilepsia*; 54 (2): 314-22.
- Janzky J, Jokeit H, Kontopoulou K, Mertens M, Ebner A, Pohlmann-Eden B, Woermann FG. (2005). Functional MRI predicts memory performance after right mesiotemporal epilepsy surgery. *Epilepsia*. Feb; 46 (2):244-50.
- Jeha LE, Najm IM, Bingaman WE, Khandwala F, Widdess-Walsh P, Morris HH, Dinner DS, Nair D, Foldvary-Schaeffer N, Prayson RA, Comair Y, O'Brien R, Bulacio J, Gupta A, Luders HO. (2006) Predictors of outcome after temporal lobectomy for the treatment of intractable epilepsy. *Neurology* 66:1938–1940.
- Jokeit H, Okujava M and Woermann FG. (2001). Memory fMRI lateralizes temporal lobe epilepsy. *Neurology*. November 27, vol. 57 no. 10 1786-1793.
- Jones-Gotman M., Harnadek M.C., and Kubu C.S.(2000). Neuropsychological assessment for temporal lobe epilepsy surgery. *Can. J. Neurol. Sci.* 27(Suppl.1).
- Knake S, Triantafyllou C, Wald LL, Wiggins G, Kirk GP, Larsson PG, Stufflebeam SM, Foley MT, Shiraishi H, Dale AM, Halgren E, Grant PE. (2005). 3T phased array MRI improves the presurgical evaluation in focal epilepsies: A prospective study. *Neurology* 2005; 65: 1026-31.
- Knecht S, Drager B, Deppe M, Bobe L, Lohmann H, Floel A.(2000). Handedness and hemispheric language dominance in healthy humans. *Brain*; 123: 2512–2518.
- Kim YH, Kang HC, Kim DS, Kim SH, Shim KW, Kim HD, and Lee JS. (2011). Neuroimaging in identifying focal cortical dysplasia and prognostic factors in pediatric and adolescent epilepsy surgery. *Epilepsia*, 52(4):722–727.
- Kurland J, Cortes CR, Wilke M, Sperling AJ, Lott SN, Tagamets MA, Vanmeter J, Friedman RB. (2008). Neural mechanisms underlying learning following semantic mediation treatment in a case of phonologic alexia. *Brain Imaging and Behavior*, 2, 147–162.
- Kwan P, Brodie MJ. (2000) Early identification of refractory epilepsy. *N Engl J Med* 342:314–319.
- Labudda K, Mertens M, Aengenendt J, Ebner A, Woermann FG. (2010). Presurgical language fMRI activation correlates with postsurgical verbal memory decline in left-sided temporal lobe epilepsy. *Epilepsy Research*: 92, 258—261
- Lezak MD. (1983). *Neuropsychological assessment* (2nd ed.). New York: Oxford University Press.
- Lidzba K, Wilke M, Staudt M, Krägeloh-Mann I, Grodd W. (2008). Reorganization of the cerebro-cerebellar network of language production in patients with congenital left-hemispheric brain lesions. *Brain and Language*, 106, 204–210.

- McCormick C, Quraan M, Cohn M, Valiante TA and McAndrews MP (2013). Default mode network connectivity indicates episodic memory capacity in mesial temporal lobe epilepsy. *Epilepsia* 54, 809–818
- Otten LJ, Henson RN, Rugg MD. (2001). Depth of processing effects on neural correlates of memory encoding: relationship between findings from across- and within-task comparisons. *Brain*; 124: 399-412.
- Petersson KM, Sandblom J, Elfgrén C, Ingvar M. (2003). Instruction-specific brain activations during episodic encoding: a generalized level of processing effect. *Neuroimage*; 20: 1795-1810.
- Petersen S, Dubis JW. (2012). The mixed block/event-related design. *NeuroImage* 62: 1177–1184.
- Phal PM, Usmanov A, Nesbit GM, Anderson JC, Spencer D, Wang P, Helwig JA, Roberts C, Hamilton BE. (2008). Qualitative comparison of 3-T and 1.5-T MRI in the evaluation of epilepsy. *AJR Am J Roentgenol*. Sep;191(3):890-5.
- Powell HWR, Koepp MJ, Richardson MP, Symms MR, Thompson PJ, Duncan JS. (2004). The Application of Functional MRI of Memory in Temporal Lobe Epilepsy: A Clinical Review. *Epilepsia* 45 (7):885-863.
- Powell HWR, Parker GJM, Alexander DC, Symms MR, Boulby PA, Wheeler-Kingshott CAM, Barker GJ, Noppeney U, Koepp MJ, Duncan JS. (2006). Hemispheric asymmetries in language-related pathways: A combined functional MRI and tractography study. *NeuroImage*; 32: 388 – 399.
- Powell HWR, Richardson MP, Symms MR, Boulby PA, Thompson PJ, Duncan JS, Koepp MJ. (2007). Reorganization of Verbal and Nonverbal Memory in Temporal Lobe Epilepsy Due to Unilateral Hippocampal Sclerosis. *Epilepsia*, 48(8): 1512-1525.
- Powell HW, Parker GJ, Alexander DC, Symms MR, Boulby PA, Wheeler-Kingshott CA, Barker GJ, Koepp MJ, Duncan JS. (2007). Abnormalities of language networks in temporal lobe epilepsy. *Neuroimage* 36, 209–221.
- Powell HW, Parker GJ, Alexander DC, Symms MR, Boulby PA, Barker GJ, Thompson PJ, Koepp MJ, Duncan JS. (2008). Imaging language pathways predicts postoperative naming deficits. *J Neurol Neurosurg Psychiatry*. Mar;79(3):327-30.
- Powell HWR, Parker GJM, Alexander DC, Symms MR, Boulby PA, Barker GJ, Thompson PJ, Koepp MJ, Duncan JS. (2008). Imaging language pathways predicts postoperative naming deficits. *J Neurol Neurosurg Psychiatry*; 79: 327–330.
- Protzner AB, Kovacevic N, Cohn M, and McAndrews MP. (2013). Characterizing Functional Integrity: Intraindividual Brain Signal Variability Predicts Memory Performance in Patients with Medial Temporal Lobe Epilepsy. *The Journal of Neuroscience*, June 5: 33(23):9855–9865.
- Price CJ. (2012). A review and synthesis of the first 20 years of PET and fMRI studies of heard speech, spoken language and reading. *NeuroImage*; 62: 816–847.
- Rabin ML, Narayan VM, Kimberg DY, Casasanto DJ, Glosser G, Tracy JI, French JA, Sperling MR, Detre JA. (2004). Functional MRI predicts post-surgical memory following temporal lobectomy. *Brain*; 127:2286–2298.

- Richardson MP, Strange BA, Thompson PJ, Baxendale SA, Duncan JS and Dolan RJ. (2004). Pre-operative verbal memory fMRI predicts post-operative memory decline after left temporal lobe resection. *Brain*, 127, 2419-2426.
- Richardson MP, Strange BA, Duncan JS, Dolan RJ. (2006). Memory fMRI in left hippocampal sclerosis: Optimizing the approach to predicting postsurgical memory. *Neurology*; 66; 699-705.
- Roland PE, Eriksson L, Stone-Elander S, Widen L. (1987). Does Mental Activity Change the Oxidative Metabolism of the Brain? *J Neurosci* 7 (8), 2373-2389.
- Salanova V, Markand O, Worth R. (2004). Temporal lobe epilepsy: analysis of patients with dual pathology. *Acta Neurol Scand*. 2004 Feb;109 (2):126-31.
- Sanjuán A, Bustamante JC, Forn C, Ventura-Campos N, Barrós-Loscertales A, Martínez JC, Villanueva V, Ávila C. (2010). Comparison of two fMRI tasks for the evaluation of the expressive language function. *Neuroradiology*; 52:407–415.
- Saur D, Kreher BW, Schnell S, Kümmerer D, Kellmeyer P, Vry MS, Umarova R. (2008). Ventral and dorsal pathways for language. *Proc. Natl Acad. Sci. USA*; 105: 18035–18040.
- Schacher M, Haemmerle B, Woermann FG, Okujava M, Huber D, Grunwald T, Krämer G and Jokeit H. (2006). Amygdala fMRI lateralizes temporal lobe epilepsy. *Neurology* 2006; 66; 81-87.
- Schuele SU, Lüders HO. (2008). Intractable epilepsy: management and therapeutic alternatives. *Lancet Neurol*. Jun;7 (6):514-24.
- Seghier ML, Kherif F, Josse G, Price CJ. (2011) Regional and Hemispheric Determinants of Language Laterality: Implications for Preoperative fMRI. *Human Brain Mapping* 2011; 32:1602–1614.
- Shamim S, Wiggs E, Heis J, Sato S, Liew Clarissa, Solomon J, Theodore WH. (2009) Temporal Lobectomy: Resection Volume, Neuropsychological Effects and Seizure Outcome. *Epilepsy Behav*. Oct; 16(2): 311–314.
- Sherman EM, Wiebe S, Fay-McClymont TB, Tellez-Zenteno J, Metcalfe A, Hernandez-Ronquillo L, Hader WJ, Jette N. (2011). Neuropsychological outcomes after epilepsy surgery: systematic review and pooled estimates. *Epilepsia*; 52(5): 857-869.
- Stroup E, Langfitt J, Berg M, McDermott M, Pilcher W, Como P. (2003). Predicting verbal memory decline following anterior temporal lobectomy (ATL). *Neurology* 2003;60:1266–1273.
- Somers M, Neggers SF, Diederer KM, Boks MO, Kahn RS, Sommer IE. (2011). The measurement of language lateralization with functional transcranial Doppler and functional MRI: a critical evaluation. *Front Hum Neurosci*. Mar 28; 5:31.
- Springer S & Deutsch G. (1993) *Left brain, Right brain*. Freeman, New York
- Szaflarski JP, Binder JR, Possing ET, McKiernan KA, Ward BD, Hammeke TA. (2002). Language lateralization in left-handed and ambidextrous people fMRI data. *Neurology* 2002; 59: 238–244.

- Szaflarski JP, Holland AK, Schmithorst VJ, Byars AW. (2006). fMRI Study of Language Lateralization in Children and Adults. *Human Brain Mapping* 27, 202-212.
- Télléz-Zenteno JF, Raj Dhar R, Wiebe S. (2005). Long-term seizure outcomes following epilepsy surgery: a systematic review and meta-analysis. *Brain*, 128, 1188–1198.
- Tonini C, Beghi E, Berg AT, Bogliun G, Giordano L, Newton RW, Tetto A, Vitelli E, Vitezic D, Wiebe S. (2004). Predictors of epilepsy surgery outcome: a meta-analysis. *Epilepsy Res. Nov*; 62(1):75-87.
- Wang DD, Deans AE, Barkovich AJ, Tihan T, Barbaro NM, Garcia PA, Chang EF. (2013). Transmantle sign in focal cortical dysplasia: a unique radiological entity with excellent prognosis for seizure control. *J Neurosurg. Feb*;118(2):337-44.
- Wagner, K. Frings L, Quiske A, Unterrainer J, Schwarzwald R, Spreer J, Halsband U and Schulze-Bonhage A. (2005). The reliability of fMRI activations in the medial temporal lobes in a verbal episodic memory task. *Neuroimage* 28:122-131.
- Weber B, Wellmer J, Reuber M, Mormann F, Weis S, Urbach H, Ruhlmann J, Elger CE, Fernandez G, (2006). Left hippocampal pathology is associated with atypical language lateralization in patients with focal epilepsy. *Brain* 129, 346–351.
- Wiebe S, Blume WT, Girvin JP, Eliasziw M. (2001) A randomized, controlled trial of surgery for temporal-lobe epilepsy. *N Engl J Med. Aug 2*; 345(5):311-8.
- Wilke M and Lidzba K. (2007). LI-tool: A new toolbox to assess lateralization in functional MR-data. *Journal of Neuroscience Methods* 163, 128-136.
- Wilke M and Schmithorst, V J. (2006). A combined bootstrap/histogram analysis approach for computing a lateralization index from neuroimaging data. *NeuroImage*. Volume 33, Issue 2, 1 November 2006, Pages 522-530.
- Zacà D, Nickerson JP, Deib G and Pillai JJ. (2012). Effectiveness of four different clinical fMRI paradigms for preoperative regional determination of language lateralization in patients with brain tumors. *Neuroradiology*; 54:1015–1025.

Paper I

Pre-surgical epilepsy evaluation using 3T MRI. Do surface coils provide additional information?

Maria Strandberg¹, Elna-Marie Larsson², Sofia Backman³, Kristina Källén¹

¹ Department of Neurology, Institution of Clinical Neurosciences, Lund University, Sweden

² Department of Radiology, Århus University Hospital/Aalborg Hospital, Aalborg, Denmark

³ Department of Clinical Neurophysiology, Institution of Clinical Neurosciences, Lund University, Sweden

Received November 13, 2007; Accepted March 14, 2008

ABSTRACT – Purpose. To assess if 3T MRI can be further improved by adding surface coil imaging, in the context of detection and characterization of cerebral lesions in patients with drug-resistant epilepsy. **Methods.** Twenty five patients with drug-resistant epilepsy undergoing evaluation for epilepsy surgery were examined with high resolution 3T MRI. The patients were MRI-negative (n = 15), or had unclear findings (n = 10), on previous MRI at 1.0-1.5T. Surface coils were applied over the suspected epileptogenic zone after imaging in the head coil. In MRI-negative patients, placement of the coils was defined by semiological analysis, extracranial video-EEG, and, in selected cases, subtraction ictal SPECT co-registered with MRI and PET. Coil placement was re-analyzed and graded, based on the degree of convergence between different investigational modalities. **Results.** Surface coil MRI allowed visualization of the cortical lesions with somewhat better demarcation and detail, but did not contribute to detection of previously undiagnosed lesions and did not provide additional information regarding type of lesion. Possible epileptogenic lesions were detected on 3T MRI in 12 patients. No abnormalities were found in the remaining 13 patients. 3T MRI provided new or additional information about the cortex, compared with reports from previous 1.0-1.5T MRI in 5 patients (20%). **Conclusion.** 3T MRI with high resolution is valuable for lesion detection, especially MCD, in patients with drug-resistant epilepsy. We question the additional contribution from supplementary surface coil imaging at 3T MRI.

Key words: 3T MRI, surface coils, epilepsy surgery, malformation of cortical development

Epilepsy surgery renders approximately 50-60% of patients seizure-free. High quality neuroradiology contributes both to etiological diagnosis and a favourable prognosis following surgery. The likelihood of seizure freedom increases if an epileptogenic lesion has been identified on magnetic

resonance imaging (MRI) during the pre-surgical work-up (Kuzniecky 1996, Ruggieri 2000, Kuzniecky and Knowlton 2002, Kral *et al.* 2003). Malformation of cortical development (MCD) is a common finding in surgical series (Li *et al.* 1995, Wiesmann 2003, Lüders and Schuele 2006). The

Correspondence:

M. Strandberg
Department of Neurology,
Lund University Hospital,
221 85 Lund, Sweden
<maria.strandberg@med.lu.se>

detection and delineation of MCD in brain imaging is crucial for complete resection and is a significant factor for favourable, long term outcome (Hamiwka *et al.* 2005). Despite advances in imaging technology, previous studies have shown that not all lesions can be visualized with MRI as histopathological examination has revealed a higher proportion of epileptogenic lesions than was detected by pre-surgical radiology (Raymond *et al.* 1995, Von Oertzen *et al.* 2002). Furthermore, MRI often showed only part of the lesion in patients with MCD.

Improved image quality in selected regions of the cerebral cortex can potentially be achieved by using surface coils provided by the MRI scanner manufacturers. There are two previously published studies examining an epilepsy population with 1.5T MRI and surface coils (Gomez-Hassan *et al.* 2004, Grant *et al.* 1997). Gomez-Hassan *et al.* advocated the use of surface coils, and Grant *et al.* found the method to have great potential for the evaluation of patients with neocortical, partial epilepsy.

Knake *et al.* (2005) examined patients with focal epilepsies with 3T MRI, and added an eight-channel, phased array coil which was specifically built, and not a readily available surface coil provided by the manufacturer. The study showed improved lesion detection rate compared with 1.5T MRI. To our knowledge, there is no systematic, clinical observational study comparing 3T MRI with and without added surface coil examination.

Potential problems with surface-coil imaging include limited brain coverage and an overall increase in scan time (Moore *et al.* 2002, Bronen *et al.* 2002). It is therefore essential to establish if the use of surface coils improves the detection of epileptogenic lesions compared to head coil 3T MRI without additional surface coils.

In this study, we evaluate whether supplementary imaging using surface coils at 3T can improve the detection and delineation of epileptogenic lesions in a selected group of patients with pharmacoresistant epilepsy.

Methods and materials

Patient selection

Patients were recruited from the epilepsy surgery program at Lund University Hospital, Sweden. From our database, we retrospectively identified and included 25 patients (median age 15 years, range 4–51 years, 14 females and 11 males), who had been examined with 3T MRI, with and without adjunctive surface coils, during the clinical evaluation for epilepsy surgery. Disease duration ranged from 2–38 years (median 10 years) and both adults and children were included. Twenty-three patients had focal epilepsy and two were unclassified at referral to the University Hospital.

MRI protocol and evaluation

The patients had all been examined according to the same protocol, from November 2004 to June 2005, in the department of radiology at our hospital. All patients had previously undergone MRI at 1.0–1.5T, either at a University hospital or other referring centres in Sweden.

Head coil acquisition

MRI was performed with a 3T scanner (Philips Intera) using a 4-channel head coil and parallel imaging. The protocol for presurgical evaluation included a coronal, T2-weighted, fluid attenuated, inversion recovery (FLAIR) sequence (31 slices, thickness 5 mm, FOV 230 mm, matrix 288x384, TR 11000 ms, TE 120 ms, TI 2800 ms, acceleration factor 2), a coronal, T1-weighted, 3D gradient, echo sequences covering the entire brain (200 partitions, thickness 1 mm, FOV 256 mm, matrix 256x256, TR 8 ms, TE 3–4 ms, TI 2800 ms, acceleration factor 2.5) and a T1-weighted inversion recovery (IR) sequences in 2 planes (slices 33, thickness 2 mm, FOV 220 mm, matrix 268x336, TR shortest, TE 15 ms, TI 400 ms, acceleration factor 1) covering the region where the suspected epileptogenic zone was thought to be located. The scan time for the IR sequence was nine minutes for each plane.

Surface coil acquisition

The head coil was exchanged for two flexible surface coils (SENSE-flex-M, Philips), applied bilaterally on the head of the patient and centred according to the description below. The surface coil scans comprised a T1-weighted inversion recovery (IR) in two planes, without parallel imaging (33 slices, thickness 1.2 mm, FOV 220 mm, matrix 268x336, TR shortest, TE 15 ms, TI 400 ms, acceleration factor 1.2). The scan time was six minutes for each plane.

Real, as well as modulus images were reconstructed from the head coil IR sequence, whereas only modulus images could be reconstructed from the surface coil images with the software version available. On the real images, white matter has high signal intensity (white in the images), and grey matter has a lower signal intensity (grey), and the image background is grey. On modulus images, the white matter has low signal (black) and the grey matter has higher signal intensity (grey); the image background is black.

In the clinical, presurgical, MRI protocol used for the patients in this study, the T2-weighted FLAIR sequence and the T1-weighted, 3D, gradient echo (T1 3D GRE) sequence, both covering the whole brain, were used to detect signal changes and morphological abnormalities, respectively. The T1-weighted, inversion recovery (T1-IR) sequence with only subtotal brain coverage (for scan time reasons) had higher resolution and better grey/white matter differentiation. An inversion time of 400 ms was used to optimize grey-/white matter contrast on the T1-IR images. The in-plane spatial resolution was identical for head

and surface coil T1-IR images, 0.7 mm x 0.8 mm reconstructed to 0.4 mm x 0.4 mm, which is superior to the T1-weighted, 3D, gradient echo (T1 3D GRE) sequence, where it was 1 mm x 1 mm. The latter sequence had a slice (partition) thickness of 1 mm, whereas the T1-IR images obtained with the head coil had a slice thickness of 2 mm and the T1-IR- surface coil images had a thickness of 1.2 mm. Because of the thicker slices, the T1-IR sequences were acquired in two perpendicular planes, to optimize the spatial resolution in all planes. In order to maximize the SNR, no acceleration factor was used for the head coil T1-IR imaging. A low acceleration factor (1.2) was used for the corresponding surface coil imaging in order to somewhat reduce scan time without reducing SNR too much. 3T images were re-evaluated by an experienced neuroradiologist with knowledge of only the lateralization of the suspected epileptogenic zone. Pathological findings were noted with regard to type and localization. They were divided into malformations of cortical development, abnormalities of the hippocampus, white matter signal abnormalities and parenchymal loss. The malformations of cortical development were classified according to the well established Barkovich classification system (2001, 2005, 2004). Additional information from the surface coil images was described.

Surface coil placement

Surface coils were applied over the suspected epileptogenic brain region to further improve the image quality in selected regions of the cerebral cortex. In patients referred from other centers, the clinical data provided were used to guide coil placement. Discussions during the epilepsy surgery management rounds with the multidisciplinary epilepsy surgery team provided localizing information for surface coil placement for patients referred from the surgical team in Lund. In MRI-negative patients, placement of the coils was defined by localizing data from semiological analysis, extracranial video-EEG, ictal SPECT, SISCOM (subtraction ictal SPECT co-registered on MRI) and PET-findings. In MRI-positive patients, and patients with diffuse or non-specific lesions, placement of the coils was guided by previous MRI findings and additional localizing information.

We retrospectively re-analyzed the basis for surface coil localization to assess the accuracy of placement. The zones providing independent localizing information were defined: 1) the symptomatogenic zone, 2) the ictal onset zone by extracranial video-EEG and/or ictal SPECT or SISCOM; 3) the irritative zone by interictal EEG; and 4) the functional deficit zone by interictal SPECT and PET (Lüders and Carreño 2001). Authors were blinded to other investigational results during the re-evaluation of each separate modality, but as both epileptologists are involved in the surgical program they may have recognized some patients.

Semiological analyses

Semiological seizure classification was performed by two epileptologists. Information from video-EEG recorded seizures was available for 18 patients. For seven patients with normal 1.0-1.5T MRI findings, we had no access to video-EEG as they were referred to our institution primarily for high field strength imaging, and for these patients, seizure classification was done by review of medical records (*table 1*; patients # 12, 13, 15, 21-23 and 25). We used the semiological seizure classification proposed by Lüders *et al.* (1998). Anatomical correlates to the symptomatogenic zones were categorized by lobe when localizing seizure semiology was found; in patients with focal motor seizures, the symptomatogenic zone was localized to the fronto-central region, visual auras to the occipital lobe, sensory auras to the parietal lobe, automotor seizures to the temporal lobe, and hypermotor seizures to the frontal lobe.

EEG analyses from video monitoring

Each patient's ictal EEG was recorded during the video-EEG monitoring and was reviewed and classified for clinical purposes. For study purposes, the VEEG performed locally was re-evaluated by a neurophysiologist. EEG onset patterns were classified as regional by lobe or brain region, lateralized by hemisphere, or non-localizing/generalized. Interictal EEG was classified in the same manner.

Ictal SPECT, SISCOM and PET analyses

In six cases, complementary localizing data were obtained by subtraction ictal SPECT co-registered with MRI (SISCOM). Functional imaging was reviewed by a neurophysiologist, and localization of significant hotspots and significant hyperperfusions were defined by lobe or brain region. Five patients had undergone ictal SPECT examination at other University hospitals (*table 1*; patients # 12, 21-23 and 25). SISCOM was not performed at the external institutions. In four patients, interictal positron emission tomography (PET) investigations were available. All PET scans were carried out at Uppsala University Hospital, Sweden. Externally performed functional imaging results were taken from patient records.

We graded the level of evidence for coil positions into three categories depending on the degree of convergence between different investigational modalities and coil placement:

I. good support for coil placement. Convergence between coil position and localizing information from investigational modalities existed, indicating a certain region where no previous pathology had been found on 1.0T-1.5T MRI;

II. partial support for coil placement. When surface coils were positioned over one or multiple lobes or regions, in convergence with other localizing findings, even though

Table 1. Patient demographics - results from pre-surgical evaluation (video-EEG, functional and anatomical imaging) and histopathology.

Pat #	Age (y/sex)	Disease duration (y)	Seizure semiology	Video-EEG sz onset	Ictal SPECT/SISCOM/PET	Type of lesion on 1.0-1.5 T MRI*	Type of lesion on 3T MRI	Location of lesion	Histo-pathology
1	51/F	29	Automotor sz	R temporal	-	MCD*	MCD: polymicrogyria	R fronto-temporal + insula	-
2	49/M	38	Bilat tonic sz	R fronto-central	SISCOM: L parietal, bilat medial fronto-parietal	Unspecific*	MCD: focal transmantle cortical dysplasia	L fronto-parietal	MCD
3	30/F	12	Visual aura → automotor sz, + R hand sensory aura	R + L temporal	-	Normal	Normal	-	-
4	27/F	16	Automotor sz	Lateralized L	SISCOM: L + R temporal, L front temporal	MCD*	MCD: subcortical (transmantle) heterotopia + cortical thickening	R parietal	-
5	27/F	13	GTC sz	L temporal + R occipito-temporal	-	Normal	Normal	-	Unspecific
6	24/F	21	Automotor sz	L temporal + R occipito-temporal	SISCOM: L temporal + L occipital	HS	HS	L medial temporal	-
7	32/F	18	Aura	L temporal	SISCOM: L temporal	Normal	Normal	-	-
8	37/M	27	Hypermotor	Non-localized	SISCOM: L temporal	Heterotopic tissue	MCD: Subcortical heterotopia	Bilat temporal	HS + MCD (micro-dysgenesis)
9	17/M	17	Automotor	R fronto-central	-	Cortical atrophy*	MCD: Focal cortical dysplasia	R parietal	-
10	17/F	14	Psychic aura	L temporal	-	L HS + increased signal	L HS + increased signal	L medial temporal + L occipital	-
11	14/M	9	Aura	No sz during monitoring	SISCOM: L temporal	Normal*	Normal	-	-
12	14/M	7	Atonic szs, aphasic szs	R + L frontal	SPECT: L frontal	Normal	Parenchymal loss, possibly post-traumatic	R frontal	-
13	13/F	10	L motor sz	-	-	Normal	MCD: focal transmantle CD	R frontal (precentral gyrus)	-
14	13/F	3	Abdominal/olfactory + visual aura	L temporal	-	Normal	Normal	-	-

Table 1. suite.

Pat #	Age (y/sex)	Disease duration (y)	Seizure semiology	Video-EEG sz onset	Ictal SPECT/SISCOM/PET	Type of lesion on 1.0-1.5 T MRI*	Type of lesion on 3T MRI	Location of lesion	Histo-pathology
15	10/M	5	Myoclonic sz + absences	-	PET: R temp-occipital + L temporal PET: R parietal	Normal	Normal	-	-
16	9/F	9	Bilat tonic sz	R TPO-junction	PET: R parietal	Normal	Normal	-	-
17	8/M	7	Hypomotor sz	R occipital	-	Increased signal on FLAIR sequences	Increased signal on FLAIR sequences	Bilat subcortical occipital	-
18	6/F	4	Automotor sz	R occipital	-	R HS + parenchymal loss	R HS + parenchymal loss	R medial temporal + R occipital	-
19	20/M	14	L arm sensory aura	Non-localizing	-	Normal*	Normal	-	-
20	19/M	15	Bilat tonic sz	R fronto-central	SISCOM: R central	Increased signal (changes after previous subpial transection)	MCD: Focal cortical dysplasia, + postop subpial transection	R frontal	-
21	11/M	6	R motor sz	-	SPECT: L frontal PET: L frontal	Normal	Normal	-	MCD (biopsy only)
22	15/F	9	R arm motor sz → mouth sensory-motor sz	-	SPECT: L frontal	Normal	Normal	-	-
23	11/F	6	L leg motor sz	-	SPECT: R parietal	Normal*	Normal	-	MCD (micro-dysgenesis)
24	8/F	3	Myoclonic sz	Generalized	-	Normal	Normal	-	-
25	4/M	2	Bilat tonic sz	-	SPECT: L frontal PET: L frontal	Normal	Normal	-	-

Pat: patients; #: number; y: years; sz: seizure, R: right, L: left; M: male; F: female; TPO: temporo-parieto-occipital; sz: seizure; TPO: temporo-parieto-occipital; MCD: malformation of cortical development; CD: cortical dysplasia; HS: hippocampal sclerosis; SPECT: single photon emission computed tomography; SISCOM: subtraction ictal SPECT co-registered on MRI; PET: positron emission tomography; * examined with 1.0T.

there was the indication of other possible epileptogenic regions, *i.e.* uncovered separate regions of interest; III. no support for epileptogenicity in the underlying region where coils were applied.

Ethics committee approval and funding

This study was performed retrospectively and the study subjects were not submitted to any additional investigation other than that which the referring physician had originally requested. The study was performed in accordance with the regulations of the local ethics committee. This material has not been previously published. No potential for commercial bias was declared by the authors.

Results

New lesions identified on 3T MRI

3T MRI provided new or additional information about structural grey matter abnormalities, compared to reports from 1.0-1.5T MRI, in five patients (20%). In one 1.5T MRI-negative patient, an MCD was identified (*table 1*; patient # 13), and in four patients with unspecific findings on 1.0T or 1.5T MRI, MCDs were identified (*table 1*; patients # 2, 8, 9 and 20) on 3T MRI.

Table 1 provides demographics for the entire study group, results available from presurgical evaluation and histopathology from patients who underwent surgery. *Table 1* also shows the type and the location of findings on 3T MRI and 1.0-1.5T. The lesions identified on 3T MRI were malformations of cortical development in seven, hippocampal sclerosis in three, white matter lesions in one, and regional atrophy in one patient.

Surface coil examination

Surface coil 3T MRI visualized the cortical lesions with somewhat better demarcation and detail (*figures 1, 2, 3*), but did neither contribute to detection of previously undiagnosed lesions nor add information regarding type of lesion in any of the cases reviewed in this study. The improved details using surface coils only pertained to cortical structures situated close to the coils. Better demarcation of cortical structures was a general finding wherever pathology was delineated. This was particularly noted in four patients with MCDs (*table 1*; patients # 1, 4, 9 and 20).

Table 2 shows the level of evidence for surface coil placement and type of investigational modalities providing localizing information for each patient with normal 1.0-1.5T MRI.

Discussion

In our study, surface coils did not provide additional information over and above that provided by head coil 3T

MRI for the detection and characterization of MCDs in patients with drug-resistant epilepsy. Surface coil MRI visualized the cortical lesions with somewhat better demarcation and detail (*figures 1, 2, 3*), but did not improve lesion detection or provide information regarding type of lesion in any of the cases reviewed.

High resolution MRI is able to detect MCD in an increasing number of patients, as previously described by several authors (Barkovich and Kuzniecky 1996, Grant *et al.* 1998, Colliot *et al.* 2006, Knake *et al.* 2005). In our study population, 3T MRI revealed MCDs that had not been detected on clinical 1.0-1.5T MRI in five out of the 25 patients. MCDs are subtle abnormalities that can easily be missed without the use of high resolution imaging and sequences with good grey/white matter differentiation (Vattipally and Bronen 2004). We consider this finding clinically important, although it was not the primary topic of our study.

Grant *et al.* (1997) found improved detection and differentiation of focal cortical lesions in 64% of patients (16/25). In that study, two acquisitions with different coil positioning were occasionally used to increase coverage. Knake *et al.* (2005) demonstrated an increased number of MRI findings in focal epilepsy using 3T, phased-array MRI in previously 1.5T MRI-negative patients, with a 37.5% (15/40) new lesion detection rate. One limitation of that study was, as the authors pointed out themselves, the inability to separate the effects of 3T imaging and phased array coil imaging.

In our patients, there was a 20% (5/25) detection rate of new lesions, but our patients were retrospectively selected from our pre-surgical MRI database and only patients with results from 3T MRI, with and without adjunctive surface coil investigation, were included. Therefore, MRI-positive patients with new and clear-cut epileptogenic lesions on 3T without surface coils compared to lower field strength MRI were not included in our study. Thus, the difference in detection rate may be explained by the disparity in study design and selection bias. Furthermore, two patients (*table 1*, patients # 15 and # 24) had an unspecified epilepsy syndrome diagnosis at referral, but were later determined to have primary generalized epilepsy, and in an unlikely category for cortical pathology.

A crucial question is the placement of the surface coils, as it is only possible to cover a limited volume of the cerebral cortex. A clear hypothesis must be provided to guide coil placement, taking into account all the localizing data for zones of interest pointing to the epileptogenic focus. From our re-evaluation, we concluded that localizing information was not taken into full account in several patients (*table 2*; level of evidence II), *i.e.* when surface coils were positioned over one or multiple lobes or regions in convergence with localizing findings, even though there was indication for non-covered separate zones of interest. It is a weakness in our study that all possible epileptogenic regions were not adequately covered by surface coils.

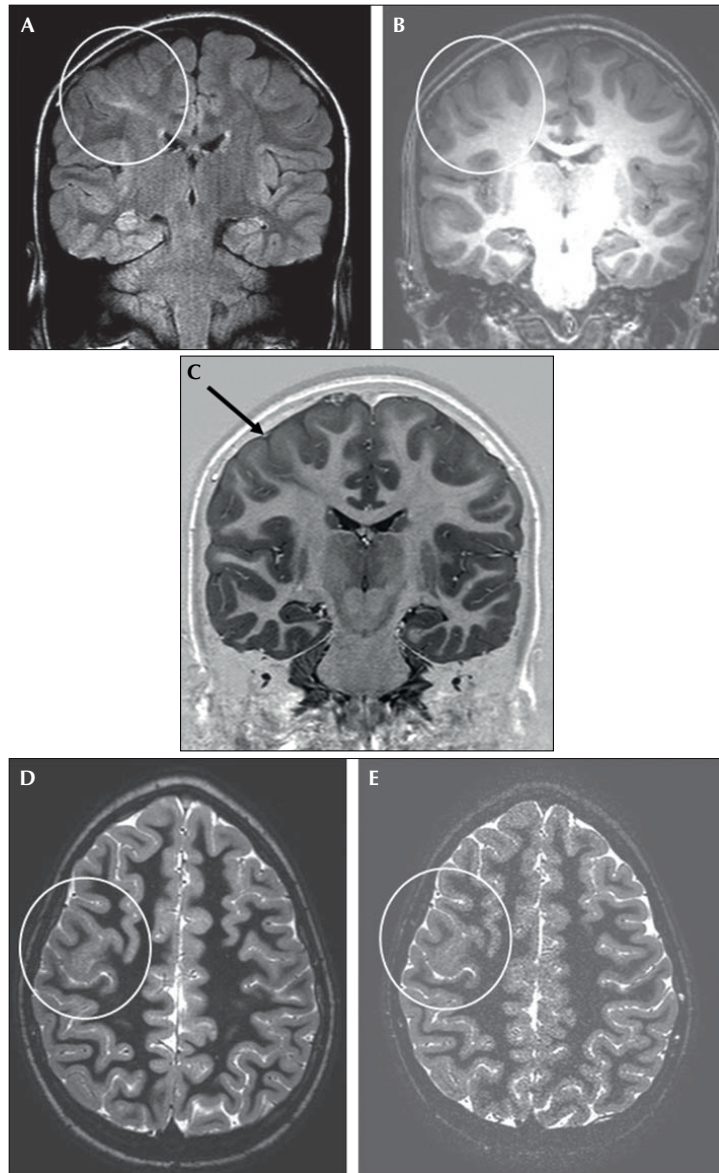


Figure 1. 13-year-old girl with right frontal lobe epilepsy (pat # 13 in *table 1*) and focal transmantle cortical dysplasia on MRI. **A)** 3T, coronal, T2-w FLAIR sequence shows right-sided, subcortical, hyperintensity extending radially towards the lateral ventricle (white circle). **B)** 3T, coronal, T1-w 3D GRE sequence confirms cortical abnormality (white circle) in the same region. **C)** 3T, head coil, coronal T1-w IR real image better depicts the cortical thickening and blurring of the cortical-white matter junction (arrow). Tissue with grey matter signal extends radially towards the lateral ventricle. **D)** Axial head coil, T1-w IR modulus image confirms the cortical thickening and blurring on the right side (white circle). **E)** The corresponding surface coil, T1-w, modulus image provides a few more details, but is noisier. Decreasing signal-to-noise ratio and thereby image quality with increasing distance from the surface coils.

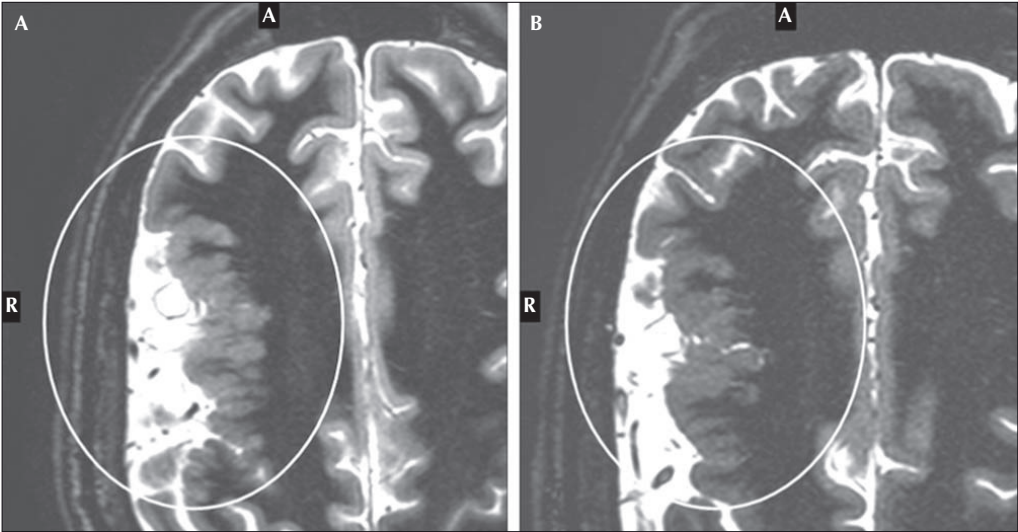


Figure 2. 51-year-old woman with right temporal lobe epilepsy (pat # 1 in table 1) and polymicrogyria in the right frontal and temporal lobes on MRI. **A), B)** Magnified, axial T1w IR modulus images obtained with head coil (**A**) and surface coils (**B**) show the slightly superior demarcation on the surface coil image.

A different choice of coil placement, taking in account all localizing data, may have contributed to a more positive outcome.

Furthermore, in four cases, surface coils were placed over the temporal lobes bilaterally illustrating an attempt to

cover deeper structures not perfectly suited for this method (table 2; patients # 3, 5, 6 and 12). Patient # 5 experienced an abdominal aura at seizure-onset, a symptom closely linked to mesial temporal lobe epilepsy. Even if there were a good rationale for examining the mesial structures in the

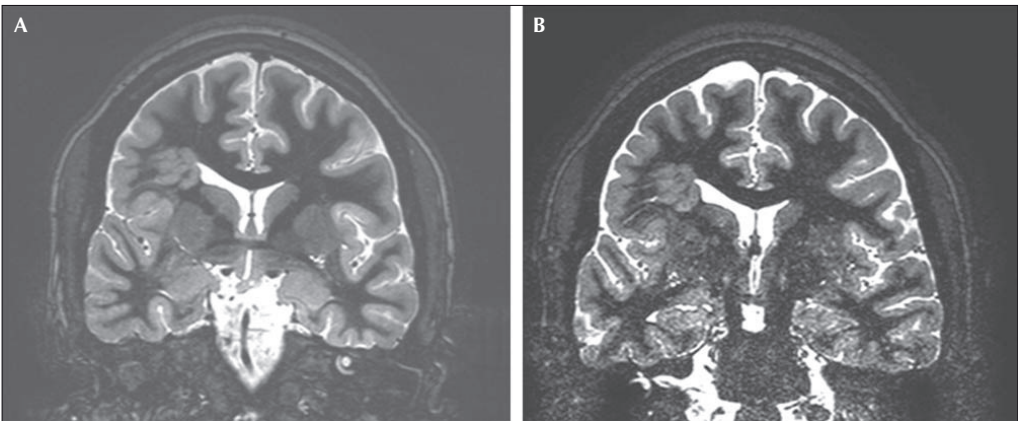


Figure 3. 28-year-old woman with partial epilepsy (pat # 4 in table 1) and a right parietal, subcortical (transmantle) heterotopia on MRI. **A)** 3T, T1-w IR modulus image shows the right-sided malformation (white circle). **B)** 3T, surface coil T1-w IR modulus image provides slightly better demarcation of subtle details in the right-sided, heterotopic grey matter. Decreasing signal-to-noise ratio at a distance from the surface coil with markedly deteriorated image quality in the inferior portion of the image.

Table 2. Localizing data from medical history and pre-surgical evaluation in the 1.0-1.5T MRI-negative patients. The level of evidence for coil positions was graded into three categories depending on the degree of convergence between different investigational modalities and coil placement. Grade I = good support; grade II = partial support; grade III = no support for coil placement.

Patient number (corresponding # in table 1)	Seizure semiology by medical history and/or video-EEG	Symptomatogenic zone (anatomical correlates)	Seizure onset zone by video-EEG	Irritative zone by interictal EEG during VEEG/or routine EEG*	Ictal SPECT/SISCOM/PET	Surface coil placement	Evidence grade for coil placement
1 (3)	Visual aura → automatic sz. R hand sensory aura	L or R occipital lobes L parietal lobe	R + L temporal	L temporal	-	L parietal	II
2 (5)	Visual aura → GTC sz	L or R occipital lobes	L temporal and R occipito-temporal	L + R temporal	-	L occipito-parietal	II
3 (7)	Psychic aura	TPO-junction	L temporal	L temporal	-	Bilat temporal	I
4 (11)	Aura	Non-localizing sz	No sz during monitoring	-/L + R frontal	SISCOM: L temporal	Bilat frontal + temporal	I
5 (14)	Abdominal/olfactory aura + visual aura	L or R temporal lobe + L or R occipital	L temporal	L temporal	-	Bilat temporal	II
6 (15)	Myoclonic sz	Bilat fronto-central	-	-	PET: R temporo-occipital + L temporal	Bilat temporal	II
7 (16)	Bilat tonic sz	Bilat frontal	R TPO	R temporo-occipital	PET: R parietal	R hemisphere	II
8 (19)	L arm sensory aura	R parietal lobe	Non-localizing	R temporo-occipital	-	R central region	I
9 (21)	R motor sz	L fronto-central	-	-/L fronto-temporal	SPECT: L frontal PET: L frontal	L fronto-temporal	I
10 (22)	R arm motor sz → mouth sensory-motor sz	L fronto-central	-	-/L fronto-central	SPECT: L frontal	L hemisphere, central region	I
11 (23)	L leg motor sz	R fronto-central	-	-/R parietal	SPECT: R parietal	R frontal	II
12 (24)	Myoclonic sz with L predominance	Bilat fronto-central	Generalized	Bilat, L predominance	-	Bilat temporal	III
13 (25)	Bilat tonic sz	Bilat fronto-central	-	-/L + R frontal	SPECT: L frontal PET: L frontal	Bilat frontal	I
14 (12)	Atonic szs, aphasic szs	L frontal	R + L frontal	-/R + L frontal	SPECT: L frontal	Bilat frontal	I
15 (13)	L motor sz	R fronto-central	-	R frontal	-	Bilat fronto-central region	I

Sz: seizure; R: right; L: left; bilat: bilateral; EEG: electroencephalogram; SPECT: single-photon emission computed tomography; SISCOM: subtraction ictal SPECT co-registered on MRI; PET: positron emission tomography; TPO: temporo-parieto-occipital; VEEG: video-electroencephalogram; * VEEG performed locally/previous routine EEG and VEEG performed externally.

temporal lobe in this particular patient, surface coil MRI is not the method of choice for detection of hippocampal sclerosis. Enhanced delineation can only be accomplished in the cortex while there is a rapid decrease in signal intensity from the brain surface close to the coil to the centre of the head, compromising image quality for assessment of deeper, underlying structures. With improved hardware it may be possible to decrease the slice thickness for head coil T1-IR imaging. This will enable further improvement of imaging of the cortex, as well as of the deeper structures of the brain.

In conclusion, surface coils did not provide additional information over and above that provided by head coil 3T MRI in our study of patients with drug-resistant epilepsy. It was confirmed that 3T MRI with high resolution is valuable for lesion detection, especially MCDs. Considering the high quality imaging obtained at 3T when also using T1-weighted inversion recovery sequences with high resolution and excellent grey/white matter differentiation, we question the additional contribution from supplementary surface coil imaging at 3T MRI. □

Acknowledgments. The authors would like to thank Professor Ingmar Rosén (department of Clinical Neurophysiology, Lund University Hospital) for his invaluable assistance and guidance. The authors would also like to thank Professor Paul Uvebrant (The Queen Silvia Children's Hospital, Gothenberg), Drs Tommy Södergren (Falu Hospital), Bo Strömberg, (Uppsala University Hospital), Lars-Göran Andersson, (Uppsala University Hospital) and Professor Roland Flink, (Department of Clinical Neurophysiology, Uppsala University Hospital) for their assistance in gathering patient data. We confirm that we have read the journal's position involved in ethical publication and affirm that this report is consistent with those guidelines. The authors have nothing to disclose.

References

- Barkovich AJ, Kuzniecky RI. Neuroimaging of Focal Malformations of Cortical Development. *J Clin Neurophysiol* 1996; 13: 481-94.
- Barkovich AJ, Kuzniecky RI, Jackson GD, et al. Classification system for malformations of cortical development. *Neurology* 2001; 57: 2168-78.
- Barkovich AJ, Raybaud A. Malformations of cortical development. *Neuroimaging Clin N Am* 2004; 14: 401-23.
- Barkovich AJ, Kuzniecky RI, Jackson GD, et al. A developmental and genetic classification of malformations of cortical development. *Neurology* 2005; 65: 1873-87.
- Bronen RA, Knowlton R, Garwood M, et al. High-Resolution Imaging in Epilepsy. *Epilepsia* 2002; 43 (Suppl. 1): 11-8.
- Colliot O, Bernasconi N, Khalil N, et al. Individual voxel-based analysis of gray matter in focal cortical dysplasia. *Neuroimage* 2006; 29: 162-71.
- Gomez-Hassan DM, Blaesing C, Shattock S, et al. Improving Cerebral Cortical Magnetic Resonance Imaging Using a Readily Available Surface Coil. *J Neuroimaging* 2004; 14: 231-4.
- Grant PE, Barkovich AJ, Wald LL, et al. High-Resolution Surface-Coil MR of Cortical Lesions in Medically Refractory Epilepsy: A Prospective Study. *AJNR Am J Neuroradiol* 1997; 18: 291-301.
- Grant PE, Vigneron DB, Barkovich AJ. High-resolution imaging of the brain. *Magn Reson Imaging Clin N Am* 1998; 6: 139-54.
- Hamiwka L, Jayakar P, Resnick T, et al. Surgery for Epilepsy Due to Cortical Malformations: Ten-year Follow-Up. *Epilepsia* 2005; 46: 556-60.
- Knake S, Triantafyllou C, Wald LL, et al. 3T phased array MRI improves the presurgical evaluation in focal epilepsies: A prospective study. *Neurology* 2005; 65: 1026-31.
- Kral T, Clusmann H, Blümcke I, et al. Outcome of epilepsy surgery in focal cortical dysplasia. *J Neurol Neurosurg Psychiatry* 2003; 74: 183-8.
- Kuzniecky RI. Neuroimaging in pediatric epilepsy. *Epilepsia* 1996; 37(Suppl. 1): S10-S21.
- Kuzniecky RI, Knowlton RC. Neuroimaging of epilepsy. *Semin Neurol* 2002; 22: 279-88.
- Li LM, Fish DR, Sisodiya SM, et al. High resolution magnetic resonance imaging in adults with partial or secondary generalised epilepsy attending a tertiary referral unit. *J Neurol Neurosurg Psychiatry* 1995; 59: 384-7.
- Lüders H, Acharya J, Baumgartner C, et al. Semiological seizure classification. *Epilepsia* 1998; 39: 1006-13.
- Lüders H, Carreño M. General principles of presurgical evaluation. In: Lüders H, Comair YG, eds. *Epilepsy Surgery*. (2nd ed). Philadelphia: Lippincott Williams & Wilkins, 2001: 185-97.
- Lüders H, Schuele SU. Epilepsy surgery in patients with malformations of cortical development. *Curr Opin Neurol* 2006; 19: 169-74.
- Moore KR, Funke ME, Constantino T, et al. Magnetoencephalographically Directed Review of High-Spatial-Resolution Surface-Coil MR Images Improves Lesion Detection in Patients with Extratemporal Epilepsy. *Radiology* 2002; 225: 880-7.
- Raymond AA, Fish DR, Sisodiya SM, et al. Abnormalities of gyration, heterotopias, tuberous sclerosis, focal cortical dysplasia, microdysgenesis, dysembryoplastic neuroepithelial tumour and dysgenesis of archicortex in epilepsy: Clinical, EEG and neuroimaging features in 100 adult patients. *Brain* 1995; 118: 629-60.
- Ruggieri P. Magnetic resonance imaging. In: Lüders HO, Noachtar S, eds. *Epileptic seizures: pathophysiology and clinical semiology*. London: Churchill Livingstone, 2000: 85-93.
- Vattipally VA, Bronen R. MR imaging of epilepsy: strategies for successful interpretation. *Neuroimaging Clin N Am* 2004; 14: 349-72.
- Von Oertzen J, Urbach H, Jungbluth S, et al. Standard magnetic resonance imaging is inadequate for patients with refractory focal epilepsy. *J Neurol Neurosurg Psychiatry* 2002; 73: 643-7.
- Wiesmann UC. Clinical application of neuroimaging in epilepsy. *J Neurol Neurosurg Psychiatry* 2003; 74: 466-70.

Paper II

fMRI memory assessment in healthy subjects: a new approach to view lateralization data at an individual level

Maria Strandberg · Christina Elfgrén · Peter Mannfolk · Johan Olsrud · Lars Stenberg · Danielle van Westen · Elna-Marie Larsson · Ia Rorsman · Kristina Källén

Published online: 23 September 2010
© Springer Science+Business Media, LLC 2010

Abstract We present a comprehensive and clinically applicable fMRI test—including both a verbal and a visuospatial task—for assessment of hemispheric specific memory in the medial temporal lobe (MTL). fMRI data was collected from 15 healthy right-handed volunteers. Whole-brain activation was analyzed as well as activation in two regions of interest: the MTL and the anterior speech area. Laterality indices (LI) and LI-curves were calculated using the LI toolbox of Wilke and Lidzba, 2007. The fMRI paradigms successfully visualized memory-related activity in the MTL, the verbal memory measure also provided information of language lateralization. Eleven subjects showed left lateralized verbal encoding in the

MTL, visuospatial memory activation was divided equally between left and right, and 14/15 subjects had left lateralized language. Lateralization data at the group level were consistent with previous studies, but a variety of activation effects were found at the individual level indicating differences in strategy during verbal and visuospatial processing. Further studies using the presented method are needed to determine its clinical usefulness.

Keywords Medial temporal lobe · Verbal episodic memory · Mental navigation task · Laterality index · Laterality curves · Visuospatial memory

As authors of this paper we agree with this version of our paper and that it has not previously been published nor is it currently under consideration by any other journal.

The experiments were undertaken with the understanding and written consent of each subject and with the approval of the local ethics committee.

M. Strandberg (✉) · I. Rorsman · K. Källén
Department of Neurology, Dept of Clinical Sciences,
Lund University Hospital,
221 85 Lund, Sweden
e-mail: maria.strandberg@med.lu.se

C. Elfgrén
Division of Geriatric Psychiatry, Dept of Clinical Sciences,
Lund University Hospital,
221 85 Lund, Sweden

P. Mannfolk · J. Olsrud · L. Stenberg · D. van Westen
Diagnostic Radiology, Dept of Clinical Sciences,
Lund University Hospital,
221 85 Lund, Sweden

E.-M. Larsson
Department of Radiology, Uppsala University Hospital,
75185 Uppsala, Sweden

Introduction

The advent of event-related functional MRI (fMRI) has made it possible to study the neural correlates of both encoding and retrieval processes of memory. In recent years, there has been an increasing interest for fMRI in presurgical examination of episodic memory in patients with mesial temporal lobe epilepsy, as resective surgery in the dominant mesial temporal lobe (MTL) may cause verbal memory deficits and decline on language-dependent cognitive tasks.

Previous fMRI studies have mainly reported results at a group level (Powell et al. 2005; Narayan et al. 2005). Group results may be satisfactory for neuroscientific questions, but in a clinical setting individual data is crucial (Jansen et al. 2009). Only a few investigations have shown solid results at an individual level (Golby et al. 2001; Branco et al. 2006). Richardson et al. (Richardson et al. 2006) reported a predictive value from presurgical memory fMRI by demonstrating that a difference between the left and right hippocampal encoding activity correlated to post-operative memory change for single subjects. In their study they applied a

spherical ROI in the anterior hippocampus of both hemispheres, and fMRI asymmetry was expressed as the ratio of left minus right activation to right minus left activation. This approach is similar to the classical fMRI laterality index (LI) frequently used to determine hemispheric dominance.

The process of data collection and calculation of LIs in fMRI is complex and affected by many factors. Differences are seen in the design of the memory task, the choice of functional or anatomical region of interest (ROI) and the threshold used in data analysis. Most commonly episodic memory function tasks, such as encoding of new words or scenes, are used to induce fMRI MTL activation (Squire et al. 2004). Various paradigms aim at visualizing the encoding process and the choice of either an event-related or a block-designed paradigm may affect the activation patterns in the limbic system and the hippocampus (Powell et al. 2005). Furthermore, different aspects of the memory process activate different areas within the MTL structures (Ávila et al. 2006; Schacher et al. 2006). When a pre-defined anatomical region of interest is used to test an a priori hypothesis, the choice of the location and the size of the area in itself are of crucial importance.

In the present study we aimed at developing a comprehensive, clinically applicable fMRI test for assessment of hemispheric specific memory related activity in the medial temporal lobe structures. We applied an fMRI paradigm combining results from two different memory paradigms: a verbal episodic memory task and a commonly used visuospatial memory task (Roland et al. 1987). The verbal memory task was a slightly modified version of a paradigm that has previously shown MTL activation during encoding (Fletcher et al. 2003) and it was designed to make it possible to model both event-related and block effects. The visuospatial task is a frequently applied clinical test not known to show hemispheric preference.

Secondly, we investigated the possibility of language lateralization during the verbal memory paradigm. As language and memory are closely connected we included anatomical regions of interest for both the MTL and the anterior speech area. Binder et al. have previously shown that hemispheric dominance measured by fMRI during a semantic decision task is the second most powerful predictor of verbal memory decline following temporal lobe resection, the first being pre-operative memory performance measured by neuropsychological tests (Binder et al. 2008).

In addition to careful consideration of design and regions of interest we chose a recently published approach for analysis of lateralization. The method is described in an original article by Wilke and Schmithorst (2006), and it includes the use of a laterality index (LI)-toolbox (Wilke and Lidzba 2007). The algorithm in the LI-toolbox is based on a modern statistical method—"bootstrapping"—estimating the sampling distribution by intensive resampling. It enhances data quality by detecting outliers and by broadening the underlying information. The toolbox presents

laterality indices for a range of consecutive thresholds instead of a single index based on a pre-defined cut-off (Wilke and Schmithorst 2006; Seghier 2008). The indices are presented as a curve and as a single LI with an attached confidence interval representing the curve in each individual. This entails our third and final aim, namely to explore this new method to analyze and present single subject fMRI lateralization data with laterality curves and indices produced by a bootstrap algorithm.

Methods

Subjects

Fifteen healthy right-handed fluent Swedish speaking volunteers (7 females, median age 34) without history of neurological or psychiatric illness were recruited. Handedness was classified according to the Edinburgh Handedness Questionnaire (Oldfield 1971) with a cut-off criterion of six out of seven items for right-handedness. Fourteen subjects scored seven out of seven items. Structural MRI scans were reviewed by an experienced neuroradiologist and no pathology (focal lesions or signal changes) was detected. The study was approved by the Lund University Ethics Committee and all subjects gave their written informed consent.

fMRI-task—experimental design

The study comprised two different tasks: (A) a verbal memory paradigm and (B) a visuospatial recall paradigm. The subjects received information about the first task on arrival; the second task was prepared at home. Subjects performed a trial-run to familiarize themselves with the task and the response procedure before scanning. During scanning, images containing words or instructions were back-projected on a screen mounted at the back of the scanner tunnel which could be viewed in a mirror mounted on the head coil. E-prime software (Psychology Software Tools, Inc., Pittsburgh, USA) was used for the presentation and timing of the stimuli and for the collection of response data. Response data was used to confirm that the subjects participated fully during the task.

Detailed description of the two paradigms:

(A) The verbal memory paradigm:

Two different encoding tasks were mixed, for deep or shallow encoding. During scanning subjects were presented with 192 nouns. In each noun, two letters were underlined and subjects were asked to perform one of two tasks. In the deep encoding task subjects were asked to decide if the word was pleasant or not.

In the shallow encoding task the subjects were asked if the underlined letters were in alphabetical order or not (e. g. PADDEL). When stimulus material is being processed in an elaborate meaning-based manner, so called deep processing, the material will be better remembered compared to when the same stimulus material is processed with an emphasis on perceptual features, so called shallow processing.

Subjects indicated their answer—yes or no—by pressing a button on a mouse pad. Answers were logged and served as confirmation of task compliance and basic behavioural data. The 192 words consisted of 96 words for deep encoding and 96 words for shallow encoding. Each word was presented for 4.25 s followed by 2 s pause and they were randomly presented in blocks of eight subsequent deep and shallow encoding tasks, respectively. The words were presented in a total of three scan sessions of 6:54 min each with a 1 min pause. Each scan session consisted of eight 50-s duration blocks.

(B) The visuospatial recall paradigm:

The second paradigm was a mental navigation task originally designed for a PET study (Roland et al. 1987), recently modified for fMRI use. This task is easily performed and activates, foremost, the parahippocampal cortex (Beisteiner et al. 2008). Previous fMRI studies have shown no systematic or marked asymmetry for healthy controls performing this task, presumably due to bilateral visuospatial memory encoding by MTL structures (Jokeit et al. 2001a, b; Ávila et al. 2006).

Before scanning the study subjects were asked to write down a familiar walk in their hometown, a walk divided into eight different stages. In the scanning phase, the verbal description of each stage (for example, garage door to post box) was then projected for 30 s during which the subject had been instructed to, in their minds, imagine walking from one point to the other while trying to recall details and landmarks such as familiar houses, trees, etc. The baseline task, projected 30 s between the different stages in the walk, was to count odd numbers starting from 21. The total scanning time was 8:12 min (eight task and eight baseline blocks).

An unexpected recognition test followed the scanning as we aimed at testing for incidental learning. All subjects had been informed that the task could be discussed only after testing was completed, if the subject so desired. Participants were placed in front of a computer screen and asked to answer the following question: “have you seen this word during the scanning?” The subject was then presented with a random mix of the 192 nouns previously seen during

scanning and an additional 96 words not seen before. Answers were logged as subjects replied yes or no by pressing indicated mouse pad buttons. Letters were underlined in an equal manner as in the scanner and the font used was identical throughout testing, both inside and outside the scanner.

Behavioral data

Logged answers from the unexpected recognition test conducted after the fMRI session were categorized as: Hits = correct answers (seen and recognized); misses = incorrect answers (seen, but not recognized); and false alarms, FA. FA was defined as a word “recognized” in the recognition test even though it was not previously shown during scanning (false positives). Discrimination rate was calculated by subtracting false alarms from hits ($D_r = \text{hits} - \text{false alarms}$).

MRI scanning

Magnetic resonance imaging was performed using a 3T Siemens Magnetom Allegra MR unit with a standard quadrature head coil. A GRE-EPI pulse sequence (matrix size 64×64 , TE=30 ms, TR=3000 ms, FoV=192 mm, 49 slices, slice thickness=3 mm, 0 mm slice gap, interleaved slice acquisition) was used for functional imaging. (T1) MPRAGE and (T2) FLAIR sequences were used to obtain anatomical images for anatomical overlay of functional activation maps and to exclude pathology.

Preprocessing and statistical analysis

All data analysis was performed using MATLAB (Mathworks, Natick, MA). Preprocessing and statistical analysis was performed with SPM5 software (Wellcome Department of Cognitive Neurology, <http://www.fil.ion.ucl.ac.uk/spm>). Preprocessing included motion correction, where images were realigned to the first image to correct for movement-related variance, as well as slice time correction. For normalization the SPM5 EPI template was used, which is based on a standard Montreal Neurological Institute (MNI) space (Ashburner and Friston 1999; Friston et al. 1995). Finally, the images were then spatially smoothed with an 8-mm isotropic Gaussian kernel to fulfill the assumptions of Gaussian random field theory (Worsley et al. 1995).

Using the general linear model, statistical maps were computed for the verbal memory paradigm. Onset vectors were created from the logged data of each participant’s recognition test corresponding to the four possible event types, i.e. correctly remembered word belonging to the deep encoding task (deep hit), erroneously remembered word from the deep encoding task (deep miss) and analogously for the shallow encoding task (shallow hit

and shallow miss). For the visuospatial task a single onset vector (active state) was created from the onsets of the eight blocks of mental navigation. The BOLD time course was modeled by convolving the onset vectors with the SPM5 canonical hemodynamic response function (HRF).

The following contrasts were analyzed:

(A) For the verbal memory paradigm:

- A:1. The comparison of the deep encoding trials (“pleasant or not pleasant?”) with the shallow encoding trials (“correct alphabetical order or not?”) irrespective of successful encoding. This is the main effect of the encoding task, the “level of processing”—“the LOP-effect”—which has previously been identified as a robust encoding effect in human memory, particularly in the left prefrontal cortex, the MTL and the cingulate cortex (Craik and Lockhart 1972; Otten et al. 2001; Petersson et al. 2003).
- A:2. The comparison of the correctly remembered words with the erroneously remembered words (hits versus misses) during the encoding phase. This contrast reflects the event-related design and explores the “differences due to memory” (“Dm effect”) also observed in the prefrontal cortex and the MTL (Craik and Lockhart 1972; Fletcher et al. 2003).

(B) For the visuospatial paradigm:

- B. The active state (mental navigation) was contrasted against the baseline state (counting odd numbers).

The resulting contrast images were entered into a second level random effects analysis. The statistical parametric maps were thresholded at $p < 0.001$, uncorrected for multiple comparisons. This quite low threshold was chosen to reduce the occurrence of false negatives and it is the threshold used in clinical practice in our department, e.g. with language and motor tasks. Finally, all corresponding inverse contrasts were obtained in separate analyses and the statistical parametric maps were likewise thresholded at $p < 0.001$, uncorrected for multiple comparisons.

Laterality assessment

Laterality indices (LIs) and laterality curves were calculated using a toolbox running within the SPM5 environment (Wilke and Lidzba 2007). Prior to the LI calculation procedure, two masks for analysis of activation within regions of interest (ROI) were constructed. The ROIs were drawn symmetrically, i.e. contained the same structures in both hemispheres. Symmetry with respect to the exact number of voxels included in the LI calculation was ensured by a mask weighting factor which was

applied to the ROIs within the LI toolbox (Wilke and Lidzba 2007).

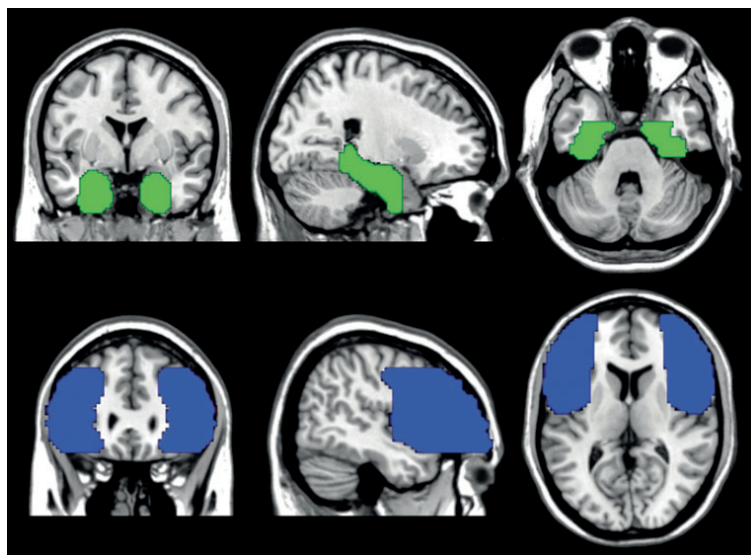
- I. The MTL ROI encompassed the mesial temporal lobe structures that are relevant with respect to memory functions; hippocampus, parahippocampus, entorhinal cortex, perirhinal cortex and amygdala (Fig. 1). The ROI was drawn using a standard single subject T1-weighted MR-image (ch2-template) in the MRICroN software (Rorden and Brett 2000) by an experienced neuroradiologist. It was then slightly enlarged to include active voxels in the MTL border regions according to the group analysis results (deep vs. shallow, $p < 0.001$ uncorrected).
- II. The Broca ROI was identical to the ROI commonly used in our department for clinical lateralization of language using a verbal fluency task. The ROI was drawn by an experienced neuroradiologist and includes the inferior frontal gyrus, the main part of the middle frontal gyrus and the dorsolateral pre-frontal cortex. This includes the area of Broca and its homologue in the right hemisphere. It was used for additional analyses of areas corresponding to language functions in the deep versus shallow contrast during the verbal paradigm (Fig. 1).

The bootstrap algorithm included as an option in the toolbox was applied in order to calculate robust LIs at different thresholds. The algorithm was applied to masked statistical maps (t-maps) according to the previously defined ROIs obtained for the deep versus shallow contrast (the verbal paradigm, A:1) and the active versus baseline contrast (the visuospatial paradigm, B). This was done for each of the 15 subjects. The bootstrap re-sampling technique broadens the base of underlying information and restricts the influence of outliers by repeatedly resampling the original sample, in this case 100 bootstrapped re-samples. Default settings were used so that a mean based on 10000 LIs resulting from the bootstrap procedure was obtained at each of a maximum of 20 different thresholds ranging from zero to the maximum t-value in the masked t-map. The algorithm always terminated at a threshold that allowed at least five voxels at both the left and the right side to remain for the LI-calculation. A mean lateralization index for each threshold was calculated according to:

$$LI = \frac{(\sum nAct_{left}) / mwf - \sum nAct_{right}}{(\sum nAct_{left}) / mwf + \sum nAct_{right}}$$

“*nAct*” is the number of activated voxels and “*mwf*” is the mask weighting factor (Wilke and Lidzba 2007). When using symmetrical masks, “*mwf*” is equal to 1. The result is a lateralization index between -1 and $+1$ where -1 is complete right-lateralization and $+1$ is complete left-lateralization. An overall LI mean greater than 0.1 were

Fig. 1 The MTL ROI (top row, green) and the Broca ROI (bottom row, blue) in three different projections overlaid on the MNI single subject T1 template. The chosen images show the ROIs approximate size and location, not necessarily optimal view in all projections (for example, the transversal cut of the MTL ROI)



classified as left-lateralized and an overall LI mean less than -0.1 were classified as right-lateralized. This classification was based on an fMRI-study published in 2006 (Szaflarski et al. 2006).

Output from the LI toolbox contained laterality curves comprising numerical laterality-indices as a function of consecutive thresholds. It also provided a single numerical value, an overall mean of all laterality indices comprising each curve.

As a result, one laterality index curve (LI versus threshold) per subject was obtained for:

I.(A:1) The verbal paradigm with the MTL ROI

II.(A:1) The verbal paradigm with the Broca ROI

I.(B) The visuospatial paradigm with the MTL ROI

The contrast hits versus misses for the verbal paradigm (A:2) was not included in the LI-analysis as the majority of laterality curves terminated at thresholds of presumed low clinical significance (the range of activation effects did not exceed a threshold set at $p < 0.001$, uncorrected for multiple comparisons).

The statistical analysis of data ($p < 0.001$, uncorrected) was chosen to make data comparable to the original paper by Fletcher and co-workers (Fletcher et al. 2003), particularly with regards to the DM effect. It was also chosen with the intent to reduce false negatives. The three presented contrasts (I.(A:1), II.(A:1) and I.(B)) were also analyzed using false discovery rate (FDR) with a p -value set at 0.05 and an extent threshold set at 15 voxels which did not alter the results significantly.

Results

Behavioural results

All participants were able to complete the fMRI tasks during scanning and the following recognition test. During the verbal paradigm, performance did not change significantly during the three scan sessions for any of the participants. The median hit rate for the group was 73% (range 58–83%) for deeply encoded words and 26% (range 11–67%) for shallowly encoded words. The discrimination measure was substantially higher for deeply encoded words (median 61%; range 44–70%) than for shallowly encoded words (median 13%; range 2–51%) for all subjects. This difference was significant (paired t test, DF 14; $p < 0.001$ (9.2×10^{-8})). Analysis also yielded subjects 6 and 10 as having a liberal bias, i.e. more inclined to respond positively if they were unsure.

Functional neuroimaging results

- The verbal memory paradigm (A)

Whole-brain analysis at the group level showed the general activation patterns for the LOP effect. Main regions of strong activation were the left prefrontal cortex and the left medial temporal lobe.

A:1 Analyzing the contrast of the deep versus shallow (LOP effect) encoding tasks showed activation with a peak in the left prefrontal cortex (left superior

frontal gyrus: $-9, 48, 39$; $Z=5.17$) and a peak in hippocampus ($-27, -21, -18$; $Z=4.21$) in the left MTL. In addition to the pre-dominantly left-sided activation in frontal structures, activation was also seen in the left cingulate cortex, the left parietal cortex, the cerebellum and the right MTL. Selected brain regions activated during the fMRI tasks ($p < 0.001$, uncorrected) with MNI coordinates, anatomical correlate and Z score are listed in Table 1.

Regions that showed activation during the shallow versus deep encoding task included right prefrontal cortex, right inferior temporal, right inferior parietal and cerebellar cortex which is consistent with previous findings (Fletcher et al. 2003).

A:2 The contrast for recognized words (hits) compared to non-recognized (misses) (Dm effect) showed weaker activation overall with a more scattered pattern. The most anatomically interesting activation was found in the coordinate $(-27, -18, -6)$, localized in very close proximity to the hippocampus and our MTL ROI. A very small area in the middle frontal gyrus showed activation in the reverse direction ($p < 0.001$, uncorrected).

- The visuospatial recall paradigm (B)

The contrast between the active retrieving task and the baseline task yielded strong activation in the temporal lobe, the middle frontal gyrus, as well as in the cerebellum. The peak maximum for the whole brain was in the right middle temporal gyrus ($39, -72, 27$; $Z=5.71$), but local maxima were seen in the left fusiform gyrus and the parahippocampal cortices bilaterally. No regions showed activation in the reverse direction ($p < 0.001$, uncorrected).

Lateralization indices (LI)

For the verbal paradigm we used the contrast that resulted in the strongest and most robust activation of the MTL structures (represented by the MTL ROI), i.e. the deep versus shallow contrast. In addition to the MTL ROI, LIs were calculated in the Broca ROI for the same contrast.

- I.(A:1) The verbal paradigm with MTL ROI analysis

Mean LI calculated from fMRI activation in the MTL region showed a left-lateralized median value of 0.24 (range -0.26 – 0.64) for the group. Single subject analysis showed left-lateralized verbal encoding in 11 out of the 15 subjects. Two subjects were right lateralized whereas two showed bilateral, almost equal MTL activity.

- II.(A:1) The verbal paradigm with Broca ROI analysis

LIs calculated in a ROI including the area of Broca showed a strong left-lateralized median of 0.53 (range -0.31 – 0.88) at a group-level. Hemispheric language dominance was lateral-

ized to the left for all but one of the subjects at individual analysis.

- I.(B) The visuospatial paradigm with MTL ROI analysis

No lateralization at the group level was revealed as the LI was close to zero: median 0.018 (range -0.36 – 0.35). Visual inspection showed bilateral activity in the hippocampus and parahippocampal gyrus in 13 out of 15 subjects at $p < 0.001$, uncorrected for multiple comparisons. Six subjects were right-lateralized, seven were left-lateralized and two subjects showed almost symmetrical, non-lateralized activity in the MTL at individual-level analysis.

Based on functional neuroimaging results, single subject LIs with attached confidence intervals were calculated to characterize the inter-hemispheric relation. Results are listed in Table 2. The lateralization was based on the overall LI mean, even though in some cases, the confidence interval indicates a less certain lateralization. The subjects' individual LI curves for the verbal paradigm in the MTL and Broca ROIs are presented in Fig. 2, as well as the visuospatial paradigm in the MTL ROI. Each curve represents a subject, the x axis shows increasing threshold (t-values) and the y axis the laterality index (LI; between 1 and -1 where negative values are right lateralized). The curves provide information about the range of activation effects at consecutive thresholds visualized on the x-axis, and the y-axis expresses the degree of lateralization. At increasing thresholds some subjects' curves seemingly shift lateralization, demonstrating the importance of thresholding and how a diminishing number of activated voxels can affect a single numerical lateralization index (subjects 9 and 15; Fig. 2a). The shift in lateralization occurs at the end of activation effects indicating that a few intensely active voxels survive the increasing threshold and affect lateralization. For subject 5 the shifting lateralization is seen before activation effects end. In this case, it indicates bilateral activity, which is confirmed by an overall LI mean that is barely left-lateralized by definition and a confidence interval indicating uncertainty.

Discussion

We have presented an fMRI test for memory assessment in both verbal and non-verbal memory domains, feasible and easily performed by healthy subjects. All participants were able to complete the test with consistent behavioral data. fMRI activation was seen in essential anatomical structures for both encoding of memory traits and for generation of language. ROI analysis and LI curves for each subject showed a variety of activation effects at the individual level indicating differences in strategy during the verbal and visuospatial processing.

Table 1 Functional neuroimaging data

Verbal encoding task (A)			Visuospatial task (B)			Z-score								
Deep-shallow contrast (LOP effect)			Active-baseline contrast											
x	y	z	Anatomical structure	Z-score	x		y	z	Anatomical structure	Z-score				
-9	48	39	L superior frontal gyrus	5.17	57	3	12	R frontal cortex (BA 6)	3.76	39	-72	27	R middle temporal gyrus	5.71
0	33	-6	L anterior cingulum	4.73	-27	-18	-6	L, white matter close to MTL	3.61	-6	-60	66	R medial parietal cortex (Precuneus)	5.59
-6	51	36	L superior frontal gyrus	4.50	-51	-78	12	L occipital cortex (BA 19)	3.55	-9	-57	54	R somatosens ass cortex (BA 7)	5.57
27	-90	-36	Uvula (vermis)	4.50	12	27	45	R medial frontal gyrus	3.50	27	15	57	R middle frontal gyrus	5.18
-66	-21	-18	L middle temporal gyrus	4.38	12	-60	12	R posterior cingulate	3.49	-21	6	57	L superior frontal gyrus	5.02
-27	-21	-18	L hippocampus	4.21	21	-48	6	R corpus callosum	3.48	-27	51	6	L middle frontal gyrus	4.35
-54	-6	-33	L inf temporal gyrus	4.17	30	-81	-9	R middle occipital gyrus	3.47	36	-30	-24	R parahippocampal cortex (BA 36)	4.70
54	-9	-18	R middle temporal gyrus	4.32	-36	-90	-15	L inferior occipital gyrus	3.46	-33	-30	-24	L parahippocampal cortex (BA 36)	4.66
45	18	-39	R temporal pole mid	4.31	21	-63	33	R medial parietal cortex (precuneus)	3.45	-33	57	-9	R orbitofrontal area (BA 11)	4.23
-45	-60	33	L angular gyrus	4.18	36	-3	42	R frontal lobe (BA 6; guenon)	3.40	-9	-51	-51	L cerebellar tonsil	4.35
-39	9	51	L middle frontal gyrus	4.17	33	-9	-24	R parahippocampal gyrus	3.37	30	-45	-42	R cerebellar tonsil	4.56
-3	-48	30	L cingulate cortex, dors post (BA 31)	4.08	-24	-36	-30	L culmen (ant cerebellum)	3.36	-30	-36	-18	L fusiform gyrus (BA 37)	4.49
-6	57	33	L prefrontal cortex (dorsolat) BA 9	4.05	6	-33	-51	L medulla	3.33	-45	-63	15	L angular gyrus (BA 39)	3.97
3	-51	-51	R cerebellar tonsil	4.00	-39	-90	18	L occipital cortex (BA 18)	3.29	30	33	39	R prefrontal cortex, dorsolat (BA 9)	3.93
-3	56	33	L prefrontal cortex (dorsolat) BA 9	3.58	30	12	-24	R superior temporal gyrus	3.27	24	33	-21	R inferior frontal gyrus	3.93
6	33	6	R cingulate cortex, dors ant (BA 24)	3.31	-33	-18	27	L postcentral gyrus	3.21	57	-42	-18	R inf temporal gyrus (BA 20)	3.80
39	33	-18	R frontal lobe	3.72	-51	-12	24	L postcentral gyrus	3.18	-42	36	33	L middle frontal gyrus	3.75
57	27	-3	R Inferior prefrontal gyrus	3.66	-15	-60	9	L cingulate cortex (BA 30)	3.18	21	-9	6	R putamen	3.66

Statistical contrast maps were thresholded at $p < 0.001$ uncorrected; $T = 3.8$. Coordinates are selected activated clusters of interest, not all activated areas in the whole brain analysis. Coordinates are given in MNI stereotaxic space. Numbers in parentheses refer to Brodmann areas (BA). *L* left hemisphere, *R* right hemisphere

Table 2 Overall mean laterality indices for each subject ($n=15$)

Subject	I.A:1 Verbal/MTL	+/-	II. A:1 Verbal/Broca	+/-	I. B Visuospatial/MTL	+/-
1	0.40	0.22	0.39	0.31	-0.01	0.08
2	0.64	0.18	0.66	0.17	-0.36	0.19
3	0.31	0.12	0.19	0.13	-0.19	0.19
4	0.18	0.14	0.38	0.32	0.2	0.22
5	-0.17	0.21	0.63	0.26	0.11	0.14
6	-0.04	0.16	-0.31	0.11	0.35	0.23
7	0.24	0.17	0.59	0.23	0.27	0.14
8	0.27	0.21	0.81	0.10	-0.24	0.26
9	0.01	0.31	0.53	0.18	-0.23	0.13
10	0.36	0.26	0.7	0.2	0.19	0.23
11	0.43	0.21	0.38	0.29	-0.14	0.06
12	0.56	0.2	0.88	0.09	0.02	0.13
13	-0.26	0.22	0.38	0.15	0.32	0.23
14	0.12	0.07	0.46	0.24	0.2	0.06
15	0.11	0.15	0.66	0.23	-0.29	0.25

A positive value means a left-lateralization and a negative value right-lateralization. LI greater than 0.1 were classified as left-lateralized and LI less than -0.1 were classified as right-lateralized. Verbal/MTL (I. A:1): Contrast Deep > shallow during verbal memory paradigm, overall mean value (laterality index). Verbal/Broca (II.A:1): Contrast Deep > shallow during verbal memory paradigm in the language ROI, overall mean value (laterality index). Visuospatial/MTL (I.B): Visuospatial task, overall mean value (laterality index). I = MTL ROI; II = Broca ROI.

Our first aim was to develop a comprehensive and clinically applicable fMRI test for assessment of hemispheric specific memory related activity in the mesial temporal lobes. Despite the combination of tasks, all of our subjects performed the test flawlessly. This paper reports data from healthy individuals, but the paradigms will be performed by patients with temporal lobe epilepsy. The patients at high risk for post-temporal lobe resection memory deficits are those without pre-operative decline in verbal memory performance and well-preserved cognitive function. Therefore we believe that the complexity of the task will be mastered by the patients we aim at investigating.

Initially we tested a verbal encoding memory paradigm exploring the Dm effect and the activation patterns associated with LOP manipulations. Our results replicate a previous study (Fletcher et al. 2003) regarding main effect of encoding and it confirms differences due to memory in the anatomic region of interest. We identified a coordinate in accordance with a comparable coordinate for the Dm effect, reported by Fletcher (-26, -20, -8), which strongly supports that our paradigm visualizes an engaging memory process in the MTL. We explored the actual encoding process using the LOP effect which gave strong MTL activation. Behavioral data confirmed the robustness of the more engaging task by revealing a hit rate twice as high for deeply encoded versus shallowly encoded words. We combined the verbal memory paradigm with a visuospatial memory task that has been reported to give bilateral activation with a laterality index close to zero for healthy subjects (Jokeit et al. 2001a, b; Spiers et al. 2001). Our results from visuospatial memory testing were concordant with previous reports at a group level, with a robust bilateral activity in the parahippocampal cortices.

Our second aim was to investigate the possibility of language lateralization by using our verbal memory paradigm. Two previous studies have shown particularly interesting results in terms of predicting verbal memory outcome after anterior temporal lobe resection: Richardson et al. (2006) and Binder et al. (2008). Richardson and co-workers used an extensive and complicated verbal memory task in order to study fMRI activation in a small MTL ROI, while Binder et al. used a semantic decision task in a large ROI comprising the area of Broca. We chose to analyze activation in both MTL and frontal language areas from our verbal episodic memory task. As expected, whole brain fMRI data for the healthy right-handed subjects gave expected left lateralized language results at the group level.

Our third aim was to explore a method for analysis of single subject fMRI lateralization data, presenting laterality curves and indices produced by the bootstrap algorithm. The rationale for choosing this statistical strategy was that previous studies working with fixed thresholds have shown LI-variability both on the inter- and intra-subject level. Lateralization can change from task to task (Golby et al. 2001; Ávila et al. 2006), with age (Grady et al. 2005; Szafarski et al. 2006) and with gender (Frings et al. 2006). Variations like these make it difficult to determine clinically relevant t-values for thresholding (Jansen et al. 2006; Weber et al. 2007; Jansen et al. 2009; Abbott et al. 2010), highlighting the importance of minimizing the influence of statistical thresholds.

Our lateralization data at the group level were consistent with previous studies, but a variety of activation effects were found at the individual level. During the verbal encoding task, 14 out of 15 participants showed left lateralized activation patterns in the frontal language area.

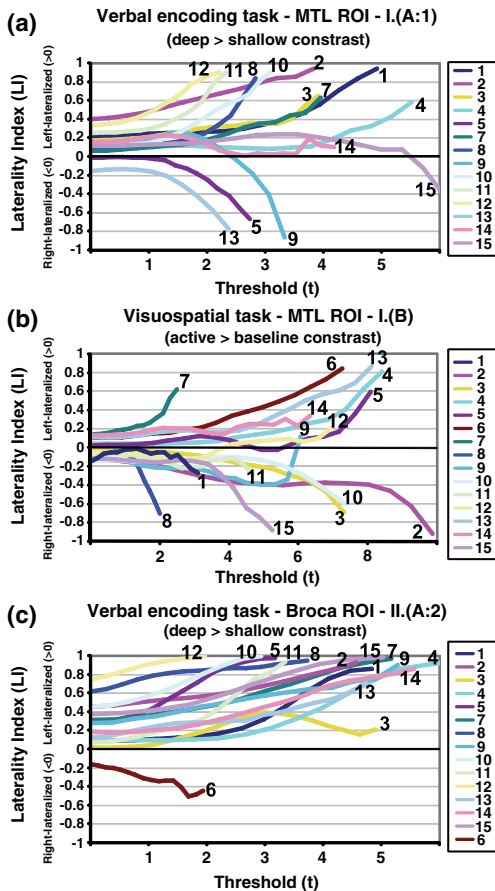


Fig. 2 a–c LI curves for all 15 subjects performing: **a** the verbal encoding task (deep vs shallow contrast), activation in the MTL ROI, **b** the visuospatial task (active vs baseline contrast), activation in the MTL ROI and **c** again, the verbal encoding task (deep vs shallow contrast), activation in the Broca ROI. The curves illustrate the group pattern and the extent of lateralization and the significant range of activation effects. Subject 6 is not included in (a) as no activation survived the threshold of 1

Subject 6 showed right lateralization both in the frontal and the MTL ROI, indicating atypical lateralization for both hemispheric dominance and for verbal memory. A mixed lateralization was seen in two participants; subjects 5 and 13 had left lateralized language activation (based on the overall mean laterality indices presented in Table 2), but right lateralized LI in the MTL indicating that the verbal memory task was solved using different strategies or abilities. Our hypothesis is that a mixed activation pattern

can be informative, and it may reflect a flexibility in strategies during memory encoding with a positive predictive value minimizing the risk for a memory deficit in patient with epilepsy eligible for dominant temporal lobe resection.

Subject 9 is left-dominant at low thresholds, right-dominant at high thresholds (Fig. 2a) and has an overall LI mean that indicates no laterality (0.01). The confidence interval (± 0.31) clearly indicates uncertain laterality. The curve, the overall LI mean and the confidence interval all point to the same conclusion: no clear lateralization in the domain of verbal encoding. In a clinical setting this information could be important as it may indicate that the patient makes good, or equally little, use of both medial temporal lobes.

For the visuospatial task we found a variability in the LI results at the individual level, where right-lateralization was almost as common as left-lateralization (Fig. 2b). These results diverge from expected results of bilaterality in the domain of non-verbal encoding. The individual lateralization indices from this task performed by healthy subjects have not been previously discussed to any great extent, even though the task is commonly used both for research and clinical purposes (Jokeit et al. 2001b; Schacher et al. 2006; Beisteiner et al. 2008). One possible explanation is that this visuospatial paradigm was previously studied in patients with known or suspected MTL pathology, but has not been systematically studied in healthy subjects at an individual level. Another possibility is that the task was solved using different tactics, and various degrees of verbal strategies during the encoding process of visuospatial information.

The laterality curves produced by the bootstrap algorithm eliminate the necessity of predefining a cut-off threshold and it has been shown to be more robust and stable compared to standard methods (Wilke and Schmithorst 2006). LI curves allow for the assessment of trend and it visualizes the range of activation effects. The method has potential to present lateralization more clearly and to facilitate the interpretation when applied on patient categories as well. The LI toolbox has been sparsely used in clinical settings so far (Lidzba et al. 2008; Everts et al. 2009) and to our knowledge, only one study has shown individual LI curves based on data from the LI toolbox: Kurland et al. (2008) utilized the laterality curve option to demonstrate a trend in shifting patterns of lateralization over the course of treatment in a patient who had suffered a stroke.

In our study we have identified essentially different patterns among the healthy volunteers by threshold independent curve presentation, illustrated by Fig. 2. For example, subject 2 (Figs. 2a–c and 3b) had results concordant with group data with consistent left-lateralization at consecutive thresholds in the Broca and

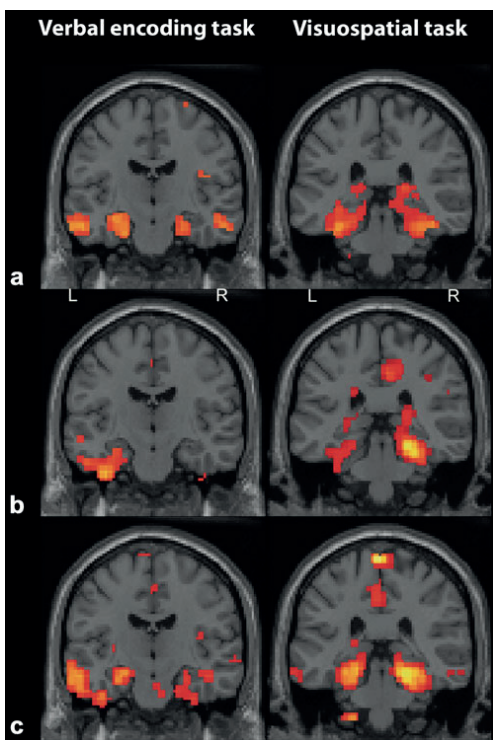


Fig. 3 Functional activation results for the verbal memory paradigm (*left*; deep vs shallow contrast) and the visuospatial task (*right*; active vs baseline contrast). Activation threshold was set at $p < 0.001$. Analogously with Fig. 2, this picture shows: **a** Group results (*top row*). **b** Individual results for subject 2 (*middle row*). **c** Individual results for subject 4 (*bottom row*)

the MTL ROIs during the verbal encoding task, whereas the visuospatial task yielded bilateral MTL activation with some lateralization to the right. Subject 4 (Figs. 2a–c, 3c and 4) was left-lateralized in all three ROI analyses pointing to the possibility of a suppression of the right temporal lobe function within the normal range. This pattern may indicate increased vulnerability for memory decline following dominant hemisphere temporal lobe resection.

A limitation in our study is that we could not test for reproducibility of the verbal memory paradigm and we did not test for strategy during the visuospatial memory test. Subjects were not asked to remember anything in particular prior to the verbal encoding task and the actual encoding process was verified by subsequent memory testing. Testing performance by an unexpected recognition test excludes the possibility of replication, as the

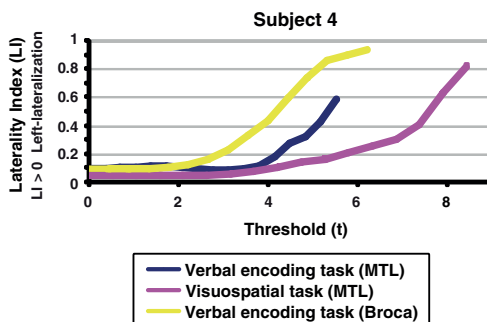


Fig. 4 The possibility to extract the three different laterality curves for a single individual, in this case subject 4, confirm the unambiguous lateralization pattern and facilitates the viewing of imaging data. Colour denotes task performed and the region of interest is written within brackets

purpose is to test for incidental learning. The visuospatial part of the paradigm has no performance measurement making it difficult to assess strategy and success rate. It is therefore not possible to exclude that a lateralization of visuospatial memory was a consequence of strategy. Subjects showing lateralization to the left (for example subjects 6 and 13; Fig. 2b) may have used a verbal strategy during performance in the MR camera. Difference in strategy could also explain the discrepancy between lateralization in the MTL and the anterior speech areas in the same individual. The confidence interval attached to the overall LI mean sometimes highlights the ambiguity of lateralization. In-depth interviews of subjects following testing may give further information about possible strategies, but the gold standard to attain more conclusive explanations to our hypothesis can only be provided by assessment of patients following temporal lobe resection. We are currently recruiting patients scheduled for this procedure for this very purpose.

We conclude that our new material-specific fMRI paradigm successfully studied an encoding process in the MTL. It was easily performed and feasible for clinical application. In addition to verbal memory activation, the verbal memory measure also provided information of language lateralization, an important component of verbal memory processing. We believe that data analyzed with the LI toolbox over anatomic areas of interest is superior to viewing lateralization index at a set threshold, particularly for single subject analysis purposes. Our comprehensive memory test enables a detailed analysis of verbal and visuospatial memory domains. The clinical usefulness and the predictive value for memory decline following temporal lobe resections remain to be seen.

Acknowledgements This research was financially supported by the University Hospital in Lund, Sweden, and by grant from the Swedish Research Council (projects no. 421-2005-1678). The authors thank the staff at the Department of Radiology at the University Hospital of Lund, Sweden, for their contribution to the research. They also thank Anthony Waites, Magnus Lindgren and Peter Höglund for their contributions to this paper.

Maria Strandberg was the recipient of the GlaxoSmith Kline Epilepsy Scholarship 2007.

References

- Abbott, D. F., Waites, A. B., Lillywhite, L., & Jackson, G. D. (2010). fMRI assessment of language lateralization: an objective approach. *Neuroimage*, *50*(4), 1446–1455.
- Ashburner, J., & Friston, K. J. (1999). Nonlinear spatial normalization using basis functions. *Human Brain Mapping*, *7*(4), 254–266.
- Ávila, C., Barrós-Loscertales, A., Mallo, R., Parcet, M.-A., Belloch, S., Campos, S., et al. (2006). Memory lateralization with 2 functional MR imaging tasks in patients with lesions in the temporal lobe. *AJNR. American Journal of Neuroradiology*, *27*, 498–503.
- Beisteiner, R., Drabek, K., Foki, T., Geibler, A., Gartus, A., Lehner-Baumgartner, E., et al. (2008). Does clinical memory fMRI provide a comprehensive map of medial temporal lobe structures? *Experimental Neurology*, *213*, 154–162.
- Binder, J. R., Sabsevitz, D. S., Swanson, S. J., Hammeke, T. A., Raghavan, M., & Mueller, W. M. (2008). Use of preoperative functional MRI to predict verbal memory decline after temporal lobe epilepsy surgery. *Epilepsia*, *49*(8), 1377–1394.
- Branco, D. M., Suarez, R. O., Whalen, S., O’Shea, J. P., Nelson, A. P., da Costa, J. C., et al. (2006). Functional MRI of memory in the hippocampus: laterality indices may be more meaningful if calculated from whole voxel distributions. *Neuroimage*, *32*, 592–602.
- Craik, F. I. M., & Lockhart, R. S. (1972). Levels of processing: a framework for memory research. *Journal of Verbal Learning and Verbal Behavior*, *11*, 671–684.
- Everts, R., Lidzba, K., Wilke, M., Kiefer, C., Mordasini, M., Schroth, G., et al. (2009). Strengthening of laterality of verbal and visuospatial functions during childhood and adolescence. *Human Brain Mapping*, *30*, 473–483.
- Fletcher, P. C., Stephenson, C. M., Carpenter, T. A., Donovan, T., & Bullmore, E. T. (2003). Regional brain activations predicting subsequent memory success: an event-related fMRI study of the influence of encoding tasks. *Cortex*, *39*, 1009–1026.
- Frings, L., Wagner, K., Unterrainer, J., Spreer, J., Halsband, U., & Schulze-Bonhage, A. (2006). Gender-related differences in lateralization of hippocampal activation and cognitive strategy. *NeuroReport*, *17*, 417–421.
- Friston, K. J., Ashburner, J., Frith, C., Poline, J. B., Heather, J. D., & Frackowiak, R. S. J. (1995). Spatial registration and normalization of images. *Human Brain Mapping*, *2*, 165–189.
- Grady, C. L., McIntosh, A. R., & Craik, F. I. M. (2005). Task-related activity in prefrontal cortex and its relation to recognition memory performance in young and old adults. *Neuropsychologia*, *43*(10), 1466–1481.
- Golby, A. J., Poldrack, R. A., Brewer, J. B., Spencer, D., Desmond, J. E., Aron, A. P., et al. (2001). Material-specific lateralization in the medial temporal lobe and prefrontal cortex during memory encoding. *Brain*, *124*, 1841–1854.
- Jansen, A., Menke, R., Sommer, J., Förster, A. F., Bruchmann, S., Hempleman, J., et al. (2006). The assessment of hemispheric lateralization in functional MRI—robustness and reproducibility. *Neuroimage*, *33*, 204–217.
- Jansen, A., Schlemeyer, C., Pfeleiderer, B., Sommer, J., Konrad, C., Zwitserlood, P., et al. (2009). Assessment of verbal memory by fMRI: lateralization and functional neuroanatomy. *Clinical Neurology and Neurosurgery*, *111*(1), 57–62.
- Jokeit, H., Okujava, M., & Woermann, F. G. (2001a). Memory fMRI lateralizes temporal lobe epilepsy. *Neurology*, *57*, 1786–1793.
- Jokeit, H., Okujava, M., & Woermann, F. G. (2001b). Carbamazepine reduces memory induced activation of mesial temporal lobe structures: a pharmacological fMRI-study. *BMC Neurology*, *1*, 6.
- Kurland, J., Cortes, C. R., Wilke, M., Sperling, A. J., Lott, S. N., Tagamets, M. A., et al. (2008). Neural mechanisms underlying learning following semantic mediation treatment in a case of phonologic alexia. *Brain Imaging and Behavior*, *2*, 147–162.
- Lidzba, K., Wilke, M., Staudt, M., Krägeloh-Mann, I., & Grodd, W. (2008). Reorganization of the cerebro-cerebellar network of language production in patients with congenital left-hemispheric brain lesions. *Brain and Language*, *106*, 204–210.
- Narayan, V. M., Kimberg, D. Y., Tang, K. Z., & Detre, J. A. (2005). Experimental design for functional MRI of scene memory encoding. *Epilepsy & Behavior*, *6*, 242–249.
- Oldfield, R. C. (1971). The assessment and analysis of handedness: the Edinburgh inventory. *Neuropsychologia*, *9*(1), 97–113.
- Otten, L. J., Henson, R. N., & Rugg, M. D. (2001). Depth of processing effects on neural correlates of memory encoding: relationship between findings from across- and within-task comparisons. *Brain*, *124*, 399–412.
- Petersson, K. M., Sandblom, J., Elfgrén, C., & Ingvar, M. (2003). Instruction-specific brain activations during episodic encoding: a generalized level of processing effect. *Neuroimage*, *20*, 1795–1810.
- Powell, H. W. R., Koepp, M. J., Symms, M. R., Boulby, P. A., Salek-Haddadi, A., Thompson, P. J., et al. (2005). Material-specific lateralization of memory encoding in the medial temporal lobe: blocked versus event-related design. *Neuroimage*, *27*, 231–239.
- Richardson, M. P., Strange, B. A., Duncan, J. S., & Dolan, R. J. (2006). Memory fMRI in left hippocampal sclerosis: optimizing the approach to predicting postsurgical memory. *Neurology*, *66*, 699–705.
- Roland, P. E., Eriksson, L., Stone-Elander, S., & Widén, L. (1987). Does mental activity change the oxidative metabolism of the brain? *The Journal of Neuroscience*, *7*(8), 2373–2389.
- Rorden, C., & Brett, M. (2000). Stereotaxic display of brain lesions. *Behavioural Neurology*, *12*, 191–200.
- Schacher, M., Haemmerle, B., Woermann, F. G., Okujava, M., Huber, D., Grunwald, T., et al. (2006). Amygdala fMRI lateralizes temporal lobe epilepsy. *Neurology*, *66*, 81–87.
- Seghier, M. (2008). Laterality index in functional MRI: methodological issues. *Magnetic Resonance Imaging*, *26*(5), 594–601.
- Spiers, H. J., Burgess, N., Maguire, E. A., Baxendale, S. A., Hartley, T., Thompson, P. J., et al. (2001). Unilateral temporal lobectomy patients show lateralized topographical and episodic memory deficits in a virtual town. *Brain*, *124*, 2476–2489.
- Squire, L. R., Stark, C. E. L., & Clark, R. E. (2004). The medial temporal lobe. *Annual Review of Neuroscience*, *27*, 279–306.
- Szaflarski, J. P., Holland, A. K., Schmithorst, V. J., & Byars, A. W. (2006). fMRI study of language lateralization in children and adults. *Human Brain Mapping*, *27*, 202–212.
- Weber, B., Kügler, F., & Elger, C. E. (2007). Comparison of implicit memory encoding paradigms for the activation of mediotemporal structures. *Epilepsy & Behavior*, *10*, 442–448.
- Wilke, M., & Lidzba, K. (2007). LI-tool: a new toolbox to assess lateralization in functional MR-data. *Journal of Neuroscience Methods*, *163*, 128–136.
- Wilke, M., & Schmithorst, V. J. (2006). A combined bootstrap/histogram analysis approach for computing a lateralization index from neuroimaging data. *Neuroimage*, *33*, 522–530.
- Worsley, K. J., Poline, J. B., Vandal, A. C., & Friston, K. J. (1995). Tests for distributed, nonfocal brain activations. *Neuroimage*, *2*, 183–194.

Paper III

Verbal encoding fMRI paradigm adds complementary information to cerebral language lateralization.

Maria Strandberg^a, MD

Peter Mannfolk^b, PhD

Lars Stenberg^b, MD, PhD

Kristina Källén^a, MD, PhD, Associate Professor

^a Department of Neurology, Department of Clinical Sciences, Lund, Skåne University Hospital, SE-221 85 Lund, Sweden

^b Diagnostic Radiology, Department of Clinical Sciences, Lund, Skåne University Hospital, SE-221 85 Lund, Sweden

Corresponding author:

Maria Strandberg
Department of Neurology
Lund University Hospital
221 85 Lund
Sweden
Telephone: +46 46 /172741
Fax: +46 46 17 19 18
E-mail: maria.strandberg@med.lu.se

As authors of this paper, we agree with this version of our paper and that it has not previously been published nor is it currently under consideration by any other journal. The study was performed without financial interest or financial benefit arising from this study. The experiments were carried out with the full understanding and the written consent of each subject, and with the approval of the local ethics committee.

Acknowledgements:

This research was financially supported by the University Hospital in Lund, Sweden. The authors thank the staff at the Department of Radiology at the University Hospital of Lund, Sweden, for their contribution to the research.

Abstract

Title: Verbal encoding fMRI paradigm adds complementary information to cerebral language lateralization.

Purpose: To explore two conceptually different fMRI paradigms' ability to lateralize language.

Methods: A verbal encoding paradigm and a word generation task were performed by six patients (four right-handed) with therapy-resistant temporal lobe epilepsy (TLE), and by ten healthy individuals (five right-handed). FMRI laterality indices (LI) and laterality curves for the anterior cerebral language regions were calculated. Typical lateralization was defined as left-hemisphere dominance and atypical as bilateral or right-hemisphere dominance.

Results: Both paradigms showed predominantly left-sided activation in the anterior language regions with typical contralateral cerebellar activity. Thirteen out of sixteen subjects showed concordant language lateralization results for both paradigms. Three subjects, all left-handed, showed discordant language lateralization results. Laterality curves added information for individual subjects with uncharacteristic results. The verbal encoding task showed overall more widespread activation compared to the word generation task.

Conclusion: Our results indicate valid language lateralization obtained by the fMRI verbal encoding paradigm for right-handed subjects. This offers the opportunity to simultaneously study two cognitive functions, language and verbal encoding, using one task. Atypical language representation in connection with left-handedness should be interpreted with caution irrespective of which paradigm is chosen.

Keywords: fMRI, TLE, handedness, lateralization index, language lateralization

Introduction

The spatial resolution of functional magnetic resonance imaging (fMRI) makes it possible to study cerebral language activation patterns. Language lateralization is probably the most investigated aspect in fMRI circuits and the relative contribution from each hemisphere is often reported as a lateralization index (LI). Accurate determination of language lateralization is essential prior to temporal lobe epilepsy (TLE) surgery aiming at the dominant hemisphere, as patients are at risk for decline in verbal memory and naming post-operatively. fMRI is currently the imaging method of choice, as it has shown 80-90% concordance compared to the invasive intracarotid amobarbital test (IAT) (*Binder et al., 1996; Aldenkamp et al., 2003*). A recent paper has even suggested that fMRI is more sensitive than IAT to right hemisphere processing (*Janecek et al., 2013*).

In addition to language deficits, epilepsy surgery can cause post-operative decline in other cognitive domains such as memory, and more specifically, in verbal memory (*Helmstaedter et al., 2007; Baxendale, 2008*). Binder et al. (*Binder et al., 2008*) have published very interesting results showing that fMRI language LIs in frontal areas have the strongest predictive value for verbal memory outcome following temporal lobe resection. The underlying hypothesis is that language processes and verbal encoding co-lateralize, a theory that is supported by other researchers (*Helmstaedter et al., 2008; Powell et al., 2008; Bonelli et al., 2011; Stewart et al., 2014*).

In 2011, we (*Strandberg et al., 2011*) published a study where healthy right-handed subjects performed a verbal encoding paradigm, which was subsequently used to study verbal memory. The task visualized levels of processing – deep and shallow encoding - for incidental learning and it elicited MTL activation during encoding (*Strandberg et al., 2011*). It was designed to be used as a clinically applicable fMRI test for assessment of verbal memory capacity in the medial temporal lobes (MTL) in an epilepsy surgery setting. The paradigm produced fMRI activation not only in areas essential for encoding processes, but also in anterior language areas. Fourteen of the fifteen right-handed healthy subjects showed left lateralized activity in this area. As verbal encoding involves the interpretation of verbal stimuli, this is not surprising. However, the extent of the activation was intriguing, and motivated further exploration of its mechanism and utility. Based on Binder's theory, we hypothesized that our verbal encoding paradigm could lateralize language similarly to a commonly used word generation task.

The word generation task, also known as “verbal fluency”, is often used in the evaluation of language laterality (*Gallagher et al., 2007; Pelletier et al., 2007; Fisher et al., 2008*). It has been shown to lateralize to a stronger degree compared to other paradigms (*Pillai and Zacà, 2011; Zacà et al., 2012*), and it has good concordance with IAT results (*Dym et al., 2011*). Nevertheless, researchers have suggested that the human language has two diverse dimensions that depend upon different brain areas and are based on different types of learning supported by different neuroanatomic networks

(*Ardila, 2012*) motivating further investigation of various methods to study language systems.

The aim of the current study was primarily to explore the concordance between a verbal encoding paradigm and a commonly used word generation paradigm in a group of subjects and TLE patients with mixed handedness. Secondly, we wanted to examine if the verbal encoding paradigm provide complementary lateralization information, possibly contributing to additional understanding of the cortical language and memory networks, at an individual level in a clinical setting.

Methods

Subjects

Six Swedish-speaking patients with therapy-resistant temporal lobe epilepsy (2 females; 2 left-handed; median age 33 yrs; range 24-58 yrs) and ten healthy Swedish-speaking volunteers (2 females; 5 left-handed; median age 38 yrs; range 25-62 yrs) without history of neurological or psychiatric illness were recruited for the study (Table 1). The patients were all therapy-refractory temporal lobe epilepsy patients under investigation for temporal lobe resection and already scheduled to perform the clinically used fMRI paradigm for language lateralization as part of their pre-surgical work-up (Table 2). An experienced neuroradiologist reviewed structural MRI scans, and no pathological changes were detected on the morphological images acquired during the fMRI scans for the healthy subjects. For patients, no *additional* pathology, other than reported with clinical data in Table 2, was found. Handedness for all included subjects was classified according to the Edinburgh Handedness Questionnaire (*Oldfield, 1971*).

The study was approved by the Lund University Ethics Committee, with all subjects giving their written informed consent.

FMRI-task experimental design

Word generation task

The subjects were shown different letters projected subsequently on a screen. Letters were shown during five blocks of 20 seconds each, where every active block was followed by a 20 second resting period. During the active period, subjects were asked to silently generate words beginning with the visualized letter until a cross appeared in the center of the screen. In the resting condition, participants were asked to fixate on the cross.

Verbal encoding task

During scanning, subjects were presented with 192 nouns. Each noun had two letters underlined, and subjects were asked to perform one of two alternating tasks. In the deep encoding task, subjects were asked to decide if the word was pleasant or not (e.g., BIKE). In the shallow encoding task, the subjects were asked whether the underlined letters were in alphabetical order or not (e.g., PADDLE).

The paradigm was based upon neuropsychological research exploring the encoding process. Stimulus material processed in an elaborate meaning-based manner, so called deep processing, has shown to be better remembered compared to when the same stimulus material is processed with an emphasis on perceptual features, so called shallow processing. This is the main effect of the encoding task, levels-of-processing (LOP-effect), a robust encoding effect in human memory (*Craik and Lockhart, 1972; Otten et al., 2001; Petersson et al., 2003*).

Subjects indicated their answer—yes or no—by pressing a button on a mouse pad. Answers were logged and served as confirmation of task compliance and basic behavioral data. The 192 words consisted of 96 words for deep encoding and 96 words for shallow encoding. Each word was presented for 4.25 sec followed by a 2 sec pause; they were randomly presented in blocks of eight subsequent deep and shallow encoding tasks, respectively (i.e., each block lasted 50 seconds). The words were presented in a total of three scan sessions, with eight blocks in each session. The scan time for each session was 6:54 min each, with a 1 min pause between each session.

E-prime software (Psychology Software Tools, Inc., Pittsburgh, USA) was used for the presentation and timing of the stimuli, and for the collection of response data. The font was equal for both scans.

MRI scanning

Magnetic resonance imaging was performed using either a 3T Siemens Magnetom Allegra MR unit (verbal encoding paradigm for subject 1-4) or a 3 T Philips Achieva MR unit (all remaining scans) with a standard quadrature head coil. Prior to the study, careful trials using the verbal encoding paradigm deemed this paradigm robust enough to produce similar activation with either unit, i.e. a non-camera-specific paradigm. A GRE-EPI pulse sequence (matrix size 64×64, TE=30 ms, TR=3000 ms, FoV=192 mm, 49 slices, slice thickness=3 mm, 0.9 mm slice gap for verbal fluency and 0.0 mm slice gap for verbal memory interleaved slice acquisition) was used for functional imaging. 3D T1-weighted and FLAIR (T2-weighted) sequences were used to obtain images for anatomical overlay of functional activation maps and to exclude pathology.

Pre-processing and statistical analysis

All data analysis was performed using MATLAB (Mathworks, Natick, MA). Preprocessing and statistical analysis was performed with the SPM5 software package (Wellcome Department of Cognitive Neurology, <http://www.fil.ion.ucl.ac.uk/spm>). Preprocessing included motion correction, where images were realigned to the first image to correct for movement-related variance, as well as slice time correction. Furthermore, normalization into standard Montreal Neurological Institute (MNI) space was performed using an EPI template (*Friston et al., 1995; Ashburner et al., 1999*). Finally, the images were then spatially smoothed with an 8-mm isotropic Gaussian kernel to fulfill the assumptions of Gaussian random field theory (*Worsley et al., 1995*).

Statistical analysis of all fMRI data was performed using the general linear model, yielding statistical parametric maps of task-related activation. Onset vectors for the verbal encoding paradigm were created from the logged data of each participant's recognition test corresponding to two possible event types (i.e. deep encoding and shallow encoding).

For the word generation task, a single onset vector (active state) was created from the onsets of the five blocks of word generation. The BOLD time course was modeled by convolving the onset vectors with the SPM5 canonical hemodynamic response function (HRF).

The results of this study were based on the analysis of the following contrasts:

- Word generation task: The active state (word generation) was contrasted against the resting state (fixating on a cross).
- Verbal encoding task: The deep encoding trials ("pleasant or not pleasant?") were contrasted against the shallow encoding trials ("correct alphabetical order or not?").

The resulting contrast images were entered into a second-level random-effects analysis. The statistical parametric maps were thresholded at $p < 0.001$, uncorrected for multiple comparisons. This threshold was chosen to reduce the occurrence of false negatives, and it is the threshold used in clinical practice in our department. It is also the threshold used in the original study (*Strandberg et al., 2011*).

Laterality assessment

Laterality indices were calculated using the LI-toolbox running within the SPM environment. A bootstrap algorithm was applied in order to calculate robust LIs at different thresholds. The algorithm is described in detail in the original article (*Wilke and Lidzba, 2007*), and has been applied previously in similar studies (*Bonelli et al., 2010; Strandberg et al., 2011; Labudda et al., 2012*). The result is a lateralization index between -1 and $+1$, where an overall LI mean greater than 0.1 was classified as left

lateralized and an overall LI mean less than 0.1 was classified as atypical (i.e., right-lateralized or with a bilateral activation pattern). This classification was based on a study published in 2006 (*Szaflarski et al., 2006; Yuan et al., 2006*). The limits were maintained to facilitate comparison to our previous study using the verbal encoding paradigm (*Strandberg et al., 2011*). The LI toolbox also produces laterality curves based on laterality indices for a range of consecutive thresholds without the necessity of a pre-defined cut-off. A single LI represents the curve, but the curve in itself visualizes the range of activation effects.

Prior to the LI calculation procedure, a mask for analysis of activation within regions of interest (ROI) was constructed. The ROI was drawn symmetrically; that is, it contained the same structures in both hemispheres. Symmetry with respect to the exact number of voxels included in the LI calculation was ensured by a mask weighting factor, which was applied to the ROI within the LI toolbox.

An experienced neuroradiologist drew the ROI, and it is routinely used in our department for clinical lateralization of language. The ROI was drawn on the MNI template and then applied to all subjects in the MNI space. It includes the inferior frontal gyrus, the main part of the middle frontal gyrus, and the dorsolateral pre-frontal cortex. This includes Broca's area and its homologue in the right hemisphere.

Results

All participants were able to complete the fMRI tasks during scanning. Due to severe motion artifacts noted before analysis of activation data, two scanning sessions for two of the healthy volunteers were repeated (word generation only).

Activation results

Table 3 shows the most important sites of overall activation for the two paradigms in the fourteen subjects with typical left-dominant language: nine right-handed and five left-handed.

For the word generation task, group activation showed a typical pattern of activation for language with activity primarily in the left hemisphere with expected contra-lateral cerebellar activation.

Whole-brain analysis at the group level for the verbal encoding paradigm showed strong activation in the left superior temporal gyrus and the left middle frontal gyrus. These brain regions are associated with frontal and temporal language areas. Contra-lateral activation was seen in the right cerebellum. The group activation was more widespread and bilateral for the verbal encoding paradigm, and more localized to traditional anterior language areas for the word generation task.

Lateralization indices (LI) and laterality curves

fMRI indices are shown in Table 1. For the verbal encoding paradigm, 12 participants showed predominantly left-sided activity (defined as $LI > 0.1$), and four participants showed atypical (predominantly right-sided or bilateral; defined as $LI < 0.1$). Concordance between the two paradigms was seen in 9 out of 9 right-handed subjects. Figure 1 shows a graphic illustration of concordance versus discordant language lateralization in all 16 participants, divided according to handedness and if the subjects were patients or not. Four subjects' (7, 9, 10 and 16) indices and bars (table 1; figure 1) evoke immediate attention. Subjects 7 and 16, both left-handed, showed discordance between LI for word generation (typical, left-sided dominance) and LI for verbal encoding (atypical, right-sided dominance).

Figure 2 shows the individual laterality curves for the two paradigms without further categorization, but with information about trend and range of activation effects. Subjects 9 and 10 had right-lateralized LI in the word generation task analysis, and bilateral activity without significant lateralization during the verbal encoding task. The LI curve for subject 9 - for the verbal encoding task - indicates equal use of both hemispheres with a slight trend toward the left hemisphere until very high thresholds where activation deviates towards the right hemisphere. If the whole curve is taken in account for index calculation results show a non-lateralizing index. The LI curve for subject 10 deviates toward left lateralization.

Discussion

The assessment of language lateralization in our study showed significant concordance between a standard word generation paradigm and a verbal encoding paradigm through ROI analysis in anterior language areas at a group level (13/16 subjects). All right-handed subjects were left lateralized (9/9) while language representation in connection with left-handedness showed concordant lateralization for 4/7 subjects. Laterality curves illustrated a variety of activation effects for verbal encoding and indicated a bilateral language representation for 1/7 left-handed subjects.

The combination of tasks in order to visualize different aspects of a cognitive process has previously been proposed, but in the context of the subject performing one task after another (*Ávila et al., 2006; Sanjuán et al., 2010; Zacà et al., 2012*). To assess two connected cognitive functions, language and memory, using a single fMRI paradigm is attractive not only because it demands less scanner time, but also because it potentially offers more information. Analysis of complex connections between higher cerebral functions, including general activation patterns, can probably contribute to further understanding of the brain networks. A *combined* fMRI task, *one* complex task demanding input from several cognitive abilities, can theoretically activate bilateral networks to a higher extent than two separate ones. Verbal encoding visualized by fMRI showed a widespread activation extending towards posterior as well as to frontal

language areas. However, a more pronounced component of network activation results in less distinct lateralization, evaluated by lateralization indices, which makes the word generation task more attractive for standard clinical purposes.

Difficulty in lateralizing language using the fMRI technique largely pertains to individuals with atypical handedness (*Szaflarski et al., 2006*). Furthermore, atypical language representation involves a wide range of patterns difficult to classify consistently across centers (*Chang et al., 2011; Van der Haegen et al., 2011*), partly explaining the commonly used, but very unspecific nomenclature: typical (left-sided) versus atypical (i.e. right-sided or bilateral representation).

Figure 3 illustrates two examples pertaining to the co-lateralization hypothesis of verbal memory and language where subject 16 serves as an example of network shift following long-standing therapy-resistant epilepsy. Subject 16, a young woman with refractory left-sided temporal lobe epilepsy, showed discordant data that merits further thought. Intra-cranial EEG recordings using electrodes (strip and depth electrodes) covering the temporal lobes bilaterally revealed initiation of seizures on the left side. Structural MRI indicated probable cortical dysplasia in the right lateral temporal gyrus.

Left TLE with frequent seizures affecting the dominant temporal lobe poses a risk for progressive decline in verbal memory function. However, instead of memory decline, repeated neuropsychological testing revealed intact verbal memory over time (2009, 2010, 2011 and 2014) in this patient. Verbal encoding and retention were normal and unaffected over time (measured by the Boston Naming Test and the Claeson-Dahl Verbal Learning Test (*Claeson et al., 1971*)). Within these psychometric tasks, she performed 0.6 standard deviations (SD) and 1 SD respectively above normal for list learning (immediate recall and delayed recall respectively). Using the visuospatial task (Rey Complex Figure Task), she performed consistently with -0.9 SD for immediate recall, -1 SD for delayed recall and 0.42 in a face recognition task. All values were deemed within the range of expected, normal capacity. This raised concerns regarding her language dominance being lateralized to the left as was indicated by her word generation task. Word generation LI indicated typical left-hemisphere dominance, whereas verbal encoding LI indicated atypical dominance (figure 1 & 2). A possible explanation for the LI discrepancy is that the left-sided epileptic focus had induced a more active verbal encoding process in the right temporal lobe, despite suspected structural pathology on the right side. Thus, the encoding LI may reveal this patient's possible atypical hemisphere dominance.

Figure 1 illustrates the general difficulties in lateralizing language in non-dexterous individuals, as some subjects have concordant, but ambiguous results, i.e., subject no's 9 and 10. Both subjects were left lateralized for word generation and by our definition subject 10 for verbal encoding as well, although by a very small margin. Their laterality curves for verbal encoding differed from each other. Subject 10's verbal encoding curve convincingly deviates towards left lateralization at high thresholds, thus rendering concordance with the clearly left lateralized curve for word generation. The verbal encoding LI curve for subject 9 indicates a bilateral activation pattern, which is, by our

definition atypical (atypical = bilateral), but not equal to the word generation curve (atypical = right lateralized (figure 2). Based on the curves subject 9 was judged not concordant.

A complicating, but not unforeseen, factor in our study was that patients were included regardless of handedness, whereas healthy subjects were included with knowledge of their handedness. TLE patients are predisposed to cortical re-organization, which inserts an uncertainty concerning expected hemisphere dominance. About 70% of healthy non-right-handed persons have left hemisphere dominance for language compared to 95% of healthy right-handed persons (*Szaflarski et al., 2002; Somers et al., 2011*). Optimally patients should have been included based on their true laterality of language established by IAT and/or language testing during direct cortical stimulation. As both investigations poses a risk for complications they are not routinely applied for dexterous handed patients. The key limitation in our study is the low number of study subjects. The study subjects (healthy and TLE patients) are few with a higher incidence of atypical handedness than expected in the normal population. The number of participants in the study limited the possibilities for statistical analysis. In order to study activation patterns at a group level, we did create one main group: subjects (healthy and TLE patients) with typical left-hemisphere dominance from visual assessment of word generation (all but subjects 8 and 9). Similar categorization has been done previously (*Van der Haegen et al., 2013*).

Our intention was to explore and evaluate the concordance between two paradigms aiming at language lateralization, without intent to replace one with the other. We conclude that overall concordance was 81% when all subjects were included and 100 % in dexterous-handed subjects illustrating the overlap between the two paradigms. The discordance in itself is informative and supports previous reports stating that subjects with greater likelihood of atypical language representation should be investigated more carefully, using more than one language paradigm (*Centeno et al., 2014*). The discordant individual patient LI data seen in the non-dexterous-handed group served as basis for a hypothetical discussion regarding cognitive network re-organization reflecting the nature of TLE as a network disease. Laterality curves potentially add complementary information to both paradigms, particularly for low numerical indices. The word generation paradigm is probably superior as a tool to lateralize language in fMRI trials. However, as the verbal encoding paradigm offers at least partial evaluation of two cognitive functions - language and memory - our results may add to the understanding of cortical networks if this approach is further investigated. Not only can memory be studied through language, but possibly also the other way around: language can be studied through memory. Future studies are needed to determine the clinical relevance and usefulness of this association.

Legends

Table 1. Demographic data and laterality indices for all subjects. Overall mean laterality indices for each subject (n=16; no 1-10 healthy controls, 11-16 TLE patients). A positive value means a left-lateralization and a negative value right-lateralization. LI greater than 0.1 were classified as left lateralized and LI less than 0.1 were classified as atypical (i.e. bilateral or right-lateralized activation).

Table 2. Additional clinical data for the TLE patients

Table 3. Functional neuroimaging results. Statistical contrast maps were thresholded at $p < 0.001$ uncorrected; $T = 3.8$. Coordinates correspond to selected activated clusters of interest, not all activated areas in the wholebrain analysis. The listed coordinates refer to peaks within larger clusters of activation. Anatomic structures of importance that correspond to clusters are listed in the text. Coordinates are given in MNI stereotaxic space. BA refers to Brodmann areas. L – Left hemisphere, R – right hemisphere.

Figure 1. Individual laterality indices for all subjects are shown in bars: blue bars correspond to activation from word generation, red bars from verbal encoding. Grey backgrounds encompass dexterous individuals and white background non-dexterous individuals.

Figure 2. The individual laterality curves for all subjects, each represented with their own colour: one for each paradigm. The curves for the word generation paradigm clearly show the left lateralization for all but two subjects. For the verbal encoding paradigm, the left-sided dominance is also obvious, with the exception of four subjects where the curves offer information that complements the single lateralization index. Range of activation effects can be studied for both paradigms.

Figure 3. The co-lateralization hypothesis between language and verbal memory domains – and its' pathology-induced plasticity - is illustrated by drawings (a, d) and exemplified with individual activation patterns (b, c, e, f).

Top row images are from a healthy right-handed individual (subject 4): (b) shows the activation from the word generation task, (c) from the verbal encoding paradigm. A typical left-sided language lateralisation is seen for both tasks. Memory domains presumably lateralize in accordance with the hypothesis of Binder (*Binder et al., 2008*): verbal memory to the dominant (left) and visuospatial to the non-dominant (right) hemisphere (a).

Bottom row images show subject 16 whose language representation - due to the fact that the patient is left-handed - is more bilaterally represented. Typical left-sided activation was seen from the word generation task (e), but bilateral activation from the verbal encoding task (f). Verbal memory is probably bilateral due to bilateral language representation induced by cerebral plasticity and reorganisation as a consequence of her frequent seizures from long-standing left temporal lobe epilepsy (hypothetical sketch (d)), all in accordance with the theory of Binder (*Binder et al., 2008*).

Table 1. Demographic data and laterality indices.

Subject	Sex/Age	Handedness	Word generation	Verbal encoding
1	F/62	Right	0.71	0.4
2	M/38	Right	0.49	0.39
3	M/50	Right	0.74	0.39
4	M/40	Right	0.82	0.77
5	M/38	Right	0.72	0.45
6	M/50	Left	0.69	0.67
7	M/31	Left	0.73	-0.44
8	F/25	Left	-0.5	-0.52
9	M/36	Left	-0.77	0.06
10	M/31	Left	0.79	0.13
11	M/58	Right	0.71	0.73
12	F/27	Right	0.77	0.51
13	M/37	Right	0.6	0.58
14	M/24	Right	0.56	0.35
15	M/44	Left	0.49	0.76
16	F/29	Left	0.7	-0.34

Overall mean laterality indices for each subject (n=16; no 1-10 healthy controls, 11-16 TLE patients) A positive value means a left-lateralization and a negative value right-lateralization. LI greater than 0.1 were classified as left lateralized and LI less than 0.1 were classified as atypical (i.e. bilateral or right-lateralized activation).

Table 2. Additional clinical data for the TLE patients

Nr	Age at disease onset	Age at fMRI	AED at time of fMRI*	Sz/EEG onset	Structural MRI pathology
11	46 yrs	49 yrs	VPA, LTG	Right Temporal Lobe	-
12	13 yrs	25 yrs	LTG	Left Temporal Lobe	-
13	32 yrs	35 yrs	VPA	Left Temporal Lobe	-
14	19 yrs	23 yrs	VPA, LTG	Left Temporal Lobe	Possible left cortical dysplasia/DNET temporal lobe
15	28 yrs	41 yrs	CBZ	Right Temporal Lobe	Right temporal lobe hippocampal sclerosis
16	13 yrs	27 yrs	VPA, LTG	Left Temporal Lobe	Possible cortical dysplasia right parahippocampal gyrus

* antiepileptic drugs during time of fMRI:s (VPA- valproic acid; LTG – lamotrigin; CBZ – carbamazepine)

Table 3. Functional neuroimaging results.

Word generation task					Verbal encoding task				
X	Y	Z	Anatomical structure	Z-score	X	Y	Z	Anatomical structure	Z-score
27	-63	-33	R Culmen	5.18	-39	15	-39	L BA 38	5.91
15	-69	-51	R Inferior semi-lunar lobule	5.07	39	-81	-42	R Pyramis	5.52
-33	-63	57	L BA 7	4.62	-6	18	66	L BA 6	5.13
-30	-66	45	L Superior parietal lobule	4.17	51	0	-36	R BA 20	4.83
39	27	-12	R Inferior frontal gyrus	4.58	-12	36	45	L Middle frontal gyrus	4.68
-6	18	45	L BA 32	4.55	-6	-51	21	L Posterior cingulated	4.62
0	27	39	L Frontal superior medial lobe	4.32	-48	-69	30	L BA 39	4.35
0	21	54	L Superior frontal gyrus	4.04	54	33	-6	R Inferior frontal gyrus	4.14
-3	-15	-21	Midbrain	4.51	24	-15	-21	R Parahippocampal gyrus	4.06
-42	18	-9	L Inferior frontal gyrus	4.20	-12	42	51	L Superior frontal gyrus	4.06

Statistical contrast maps were thresholded at $p < 0.001$ uncorrected; $T = 3.8$. Coordinates correspond to selected activated clusters of interest, not all activated areas in the wholebrain analysis. The listed coordinates refer to peaks in larger clusters of activation where anatomic structures of importance are listed in the text. Coordinates are given in MNI stereotaxic space. BA refer to Brodmann areas. L – Left hemisphere, R – right hemisphere.

Figure 1

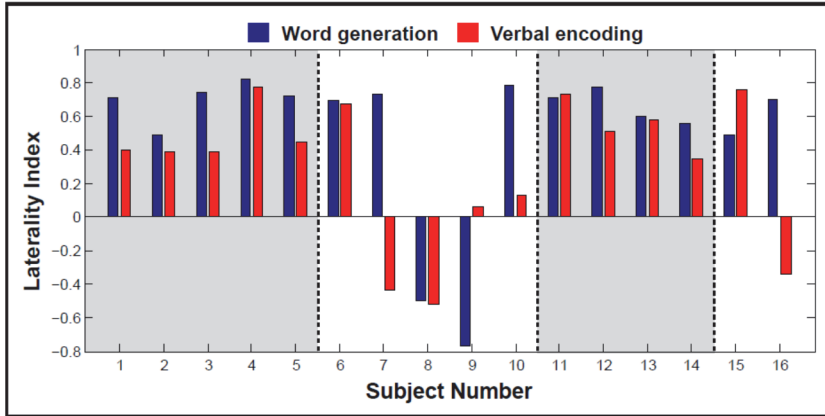


Figure 2

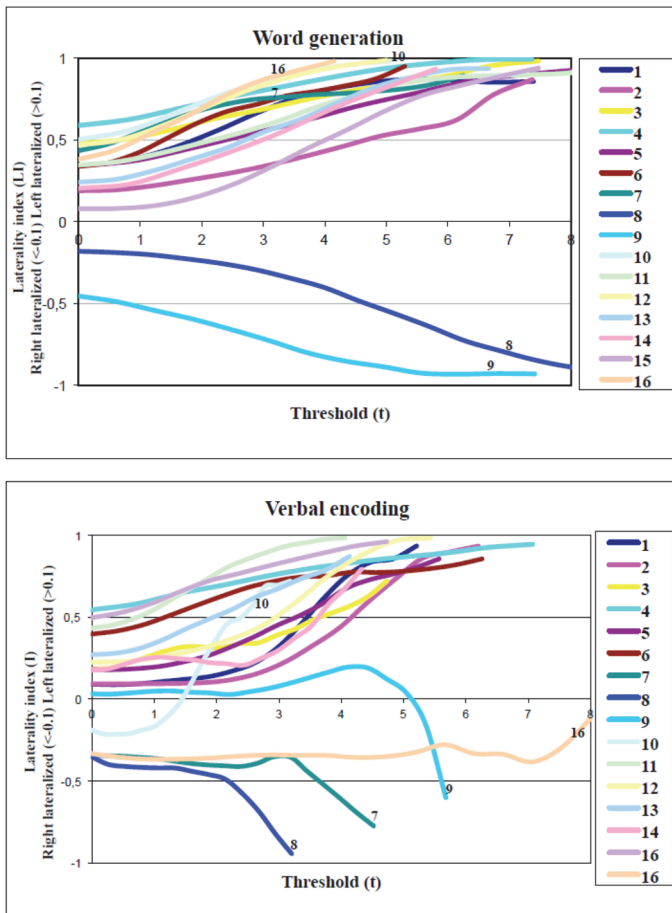
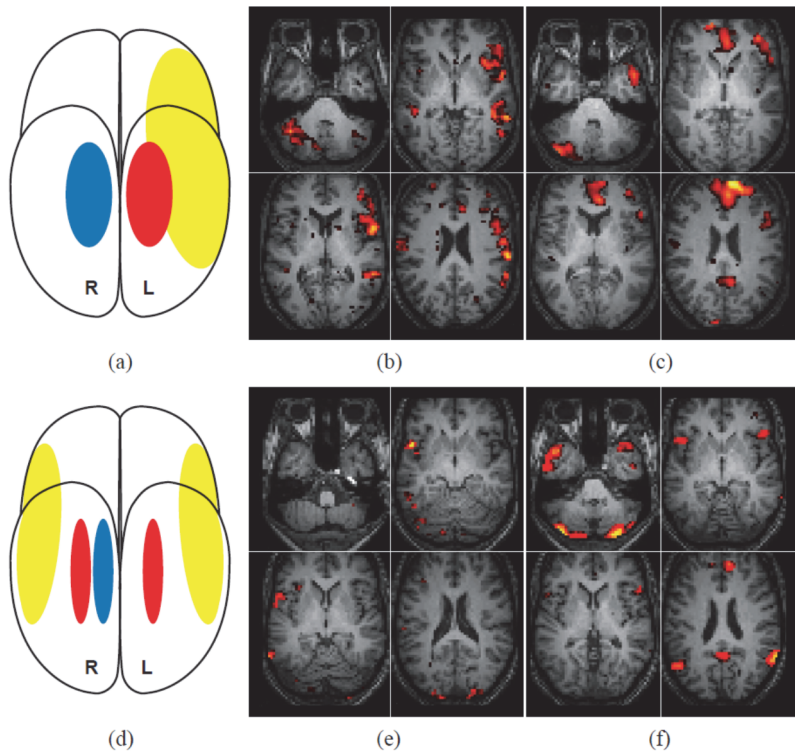


Figure 3



References:

- Aldenkamp, A, Boon P, Deblaere K, Achten E, Backes WH. Usefulness of language and memory testing during intracarotid amobarbital testing: Observations from an fMRI study. *Acta Neurol Scand* 2003; 108: 147–152.
- Ardila A. There are two different language systems in the brain. *Journal of Behavioral and Brain Science*, Vol. 1 No. 2, 2011, pp. 23-36.
- Ashburner J, Friston KJ. Nonlinear spatial normalization using basis functions. *Hum Brain Mapp* 1999; 7 (4): 254–66.
- Ávila C, Barrós-Loscertales A, Mallo R, Parcet M-A, Belloch S, Campos S, Feliu-Tatay R, González-Darder JM. Memory Lateralization with 2 functional MR Imaging Tasks in Patients with Lesions in the Temporal Lobe. *AJNR Am J Neuroradiol* 2006; 27: 498-503.
- Baxendale, Sallie. The impact of epilepsy surgery on cognition and behaviour. *Epilepsy & Behavior* 12 (2008) 592-599.

- Binder JR, Swanson SJ, Hammeke TA, Morris GL, Mueller WM, Fischer M, Benbadis S, Frost JA, Rao SM, Houghton VM. Determination of language dominance using functional MRI: A comparison with the Wada test. *Neurology* 1996; 46: 978-984.
- Binder JR, Sabsevitz DS, Swanson SJ, Hammeke TA, Raghavan M, Mueller WM. Use of preoperative functional MRI to predict verbal memory decline after temporal lobe epilepsy surgery. *Epilepsia* 2008; 49(8): 1377–1394.
- Bonelli SB, Powell RHW, Yogarajah M, Samson RS, Symms MR, Thompson PJ, Koepp MJ, Duncan JS. Imaging memory in temporal lobe epilepsy: predicting the effects of temporal lobe resection. *Brain* 2010; 133: 1186–1199.
- Bonelli SB, Powell R, Thompson PJ, Yogarajah M, Focke NK, Stretton J, Vollmar C, Symms MR, Price CJ, Duncan JS, Koepp MJ. Hippocampal activation correlates with visual confrontation naming: fMRI findings in controls and patients with temporal lobe epilepsy. *Epilepsy Res* 2011; 95: 246—254.
- Centeno M, Koepp MJ, Vollmar C, Stretton J, Sidhu M, Michalief C, Symms MR, Thompson PJ, Duncan JS. Language dominance assessment in a bilingual population: Validity of fMRI in the second language. *Epilepsia*. 2014 Sep 2. doi: 10.1111/epi.12757. [Epub ahead of print]
- Chang EF, Wang DD, Perry DW, Barbaro NM, Berger MS. Homotopic organization of essential language sites in right and bilateral cerebral hemispheric dominance. *J Neurosurg*. 2011 Apr; 114(4):893-902.
- Claeson L-E, Esbjörnsson E, Carté B-M, Wahlbin M. Manual to Claeson-Dahls learning test for clinical use (In Swedish). Stockholm: Skandinaviska Testförlaget; 1971.
- Craik FIM, Lockhart RS. Levels of processing: a framework for memory research. *J Verbal Learning Verbal Behav* 1972; 11, 671–684.
- Dym RJ, Burns J, Freeman K, Lipton ML. Is functional MR imaging assessment of hemispheric language dominance as good as the Wada test? *Radiology* 2011; 216:446–455.
- Fisher AE, Furlong PL, Seri S, Adjamian P, Witton C, Baldeweg T. Interhemispheric differences of spectral power in expressive language: A MEG study with clinical applications. *Int J Psychophysiol* 2008; 68: 111–122.
- Friston KJ, Ashburner J, Frith C, Poline JB, Heather JD, Frackowiak RSJ. Spatial registration and normalization of images. *Hum Brain Mapp* 1995; 2: 165–89.
- Gallagher A, Thériault M, Maclin E, Low K, Gratton G, Fabiani M. Language mapping using near-infrared spectroscopy (NIRS) in young epileptic patients. *Epileptic Disord* 2007; 9: 241–255.
- Helmstaedter C, Schramm J, Elger CE. 15 years epilepsy surgery in Bonn: cognitive and seizure outcome. *Epilepsia* 2007; 48:14–14.
- Helmstaedter C, Richter S, Roske S, Oltmanns F, Schramm J, Lehmann TN. Differential effects of temporal pole resection with amygdalohippocampectomy versus selective amygdalohippocampectomy on material-specific memory in patients with mesial temporal lobe epilepsy. *Epilepsia* 2008; 49:88–97.

- Janecek JK, Swanson SJ, Sabsevitz DS, Hammeke TA, Raghavan M, E Rozman M, Binder JR. Language lateralization by fMRI and Wada testing in 229 patients with epilepsy: rates and predictors of discordance. *Epilepsia* 2013; 54 (2): 314-22.
- Labudda K, Mertens M, Janszky J, Bien CG, Woermann FG. Atypical language lateralisation associated with right fronto-temporal grey matter increases — a combined fMRI and VBM study in left-sided mesial temporal lobe epilepsy patients. *NeuroImage* 2012; 59: 728–737.
- Pelletier I, Sauerwein HC, Lepore F, Saint-Amour D, Lassonde M. Non-invasive alternatives to the Wada test in the presurgical evaluation of language and memory functions in epilepsy patients. *Epileptic Disord* 2007; 9: 111–126.
- Petersson KM, Sandblom J, Elfgrén C, Ingvar M. Instruction-specific brain activations during episodic encoding: a generalized level of processing effect. *Neuroimage* 2003; 20: 1795-1810.
- Pillai JJ, Zaca D. Relative utility for hemispheric lateralization of different clinical fMRI activation tasks within a comprehensive language paradigm battery in brain tumor patients as assessed by both threshold-dependent and threshold-independent analysis methods. *NeuroImage* 2011; 54: S136–S145.
- Powell HWR, Parker GJM, Alexander DC, Symms MR, Boulby PA, Barker GJ, Thompson PJ, Koeppe MJ, Duncan JS. Imaging language pathways predicts postoperative naming deficits. *J Neurol Neurosurg Psychiatry* 2008; 79: 327–330.
- Oldfield RC. The assessment and analysis of handedness: the Edinburgh inventory. *Neuropsychologia* 1971; 9 (1), 97-113.
- Otten LJ, Henson RN, Rugg MD. Depth of processing effects on neural correlates of memory encoding: relationship between findings from across- and within-task comparisons. *Brain* 2001; 124: 399-412.
- Sanjuán A, Bustamante JC, Forn C, Ventura-Campos N, Barrós-Loscertales A, Martínez JC, Villanueva V, Ávila C. Comparison of two fMRI tasks for the evaluation of the expressive language function. *Neuroradiology* 2010; 52:407–415.
- Seghier ML, Kherif F, Josse G, Price CJ. Regional and Hemispheric Determinants of Language Laterality: Implications for Preoperative fMRI. *Human Brain Mapping* 2011; 32:1602–1614.
- Stewart CC, Swanson SJ, Sabsevitz DS, Rozman ME, Janecek JK, Binder JR. Predictors of language lateralization in temporal lobe epilepsy. *Neuropsychologia*. Vol 60, July 2014: 93–102.
- Strandberg M, Elfgrén C, Mannfolk P, Olsrud J, Stenberg L, Van Westen D, Larsson EM, Rorsman I, Källén K. fMRI memory assessment in healthy subjects: A new approach to view lateralization data at an individual level. *Brain imaging behav* (2011) 5:1-11.
- Somers M, Neggers SF, Dierken KM, Boks MO, Kahn RS, Sommer IE. The measurement of language lateralization with functional transcranial Doppler and functional MRI: a critical evaluation. *Front Hum Neurosci*. 2011 Mar 28; 5:31.

- Szaflarski JP, Binder JR, Possing ET, McKiernan KA, Ward BD, Hammeke TA. Language lateralization in left-handed and ambidextrous people fMRI data. *Neurology* 2002; 59: 238–244.
- Szaflarski JP, Holland SK, Schmithorst VJ, Byars AW. fMRI Study of Language Lateralization in Children and Adults. *Human Brain Mapping* 27:202–212(2006).
- Van der Haegen L, Cai Q, Brysbaert M. Colateralization of Broca's area and the visual word form area in left-handers: fMRI evidence. *Brain & Language* 122 (2012): 171–178.
- Van der Haegen L, Westerhausen R, Hugdahl K, Brysbaert M. Speech dominance is a better predictor of functional brain asymmetry than handedness: A combined fMRI word generation and behavioural dichotic listening study. *Neuropsychologia* 2013; 51 (1): 91-97.
- Wilke M, Lidzba K. LI-tool: A new toolbox to assess lateralization in functional MR-data. *J Neurosci Methods* 2007; 163: 128-136.
- Worsley KJ, Poline JB, Vandal AC, Friston KJ. Tests for distributed, nonfocal brain activations. *Neuroimage* 1995; 2: 183– 94.
- Yuan W, Szaflarski J.P. Schmithorst V.J. Schapiro M. Byars A.W. Strawsburg R.H. fMRI shows atypical language lateralization in pediatric epilepsy patients. *Epilepsia* 2006; 47:593–600.
- Zacà D, Nickerson JP, Deib G and Pillai JJ. Effectiveness of four different clinical fMRI paradigms for preoperative regional determination of language lateralization in patients with brain tumors. *Neuroradiology* 2012; 54:1015–1025.
- Zacà D, Jarso S, Pillai JJ. Role of Semantic Paradigms for Optimization of Language Mapping in Clinical fMRI Studies. *AJNR Am J Neuroradiol.* 2013 Oct; 34(10):1966-71.

Paper IV

An fMRI-based model for individual assessment of patients eligible for ATLR - a pilot study

Maria Strandberg^a, MD

Peter Mannfolk^b, PhD

Lars Stenberg^b, MD, PhD

Hanna Ljung^a, Psychologist

Kristina Källén^a, MD, PhD, Associate Professor

^a Department of Neurology, Department of Clinical Sciences, Lund, Skåne University Hospital, SE-221 85 Lund, Sweden

^b Diagnostic Radiology, Department of Clinical Sciences, Lund, Skåne University Hospital, SE-221 85 Lund, Sweden

Corresponding author:

Maria Strandberg

Department of Neurology

Lund University Hospital

221 85 Lund

Sweden

Telephone: +46 46 /172741

Fax: +46 46 17 19 18

E-mail: maria.strandberg@med.lu.se

As authors of this paper, we agree with this version of our paper and that it has not previously been published nor is it currently under consideration by any other journal. The study was performed without financial interest or financial benefit arising from this study. The experiments were carried out with the full understanding and the written consent of each subject, and with the approval of the local ethics committee.

Acknowledgements:

This research was financially supported by the University Hospital in Lund, Sweden. The authors thank the staff at the Department of Radiology at the University Hospital of Lund, Sweden, for their contribution to the research.

Abstract

Title: An fMRI-based model for individual assessment of patients eligible for ATR - a pilot study

Aim: To investigate if a pre-operative fMRI-task added predictive information with regards to post-surgical memory deficits.

Methods: Fourteen patients with therapy-resistant temporal lobe epilepsy (TLE) accepted for anterior temporal lobe resections were included. A clinical risk assessment score (RAS 0-3) was constructed from MRI, neuropsychological testing and hemisphere dominance. fMRI lateralization indices over frontal language and medial temporal regions were calculated for each patient using an fMRI verbal encoding task. Predictive value from clinical risk scoring and additional value from fMRI indices were correlated to post-surgical memory decline by calculating change in verbal encoding. Expected outcome was defined as patients with RAS 2-3 and significant verbal memory decline and patients with RAS 0-1 with intact post-operative verbal memory. Unexpected outcome was defined as patients with RAS 2-3 and intact verbal memory post-surgery and patients with RAS 0-1 that still suffered significant verbal memory decline following ATR.

Results: RAS for verbal memory decline exhibited a specificity of 67% and a sensitivity of 75%. Ten patients had an expected outcome and four patients had an unexpected outcome. Post-operative verbal memory decline was identified by fMRI due to bilateral language representation for two right TLE patients with pre-operative normal MRI and verbal memory (RAS 2). Two left TLE patients with pre-operative significant memory deficits and hippocampal pathology who suffered post-operative verbal memory decline were identified neither by clinical scoring nor fMRI.

Conclusion: We conclude that fMRI indices probably do add value to the pre-surgical work-up of epilepsy patients eligible for anterior temporal lobe resection. Right TLE patients with pre-operative normal MRI and verbal memory that seem to have an unexpected high risk for post-operative verbal memory decline can be detected by fMRI. Language patterns seem to be important for memory prediction in both left and right TLE.

Key words: TLE, verbal encoding, fMRI, lateralization index, verbal memory deficits

1. Introduction

Up to 30% of patients with temporal lobe epilepsy continue to suffer seizures despite advanced pharmacological treatment (*Schuele and Lüders, 2008*). Surgery is a therapeutic alternative, specifically resection of the anterior temporal lobe (ATLR), which is preceded by an extensive investigation, as the procedure is not without risk. The medial temporal lobe (MTL) structures are essential for memory and partial resection can cause cognitive deficits. Verbal and visuospatial memory decline are often seen deficits following TLE surgery (*Baxendale and Thompson, 2005*).

Current methods for assessing the risk of post-operative memory decline include structural MRI, neuropsychological assessment and language dominance assessment by the intracarotid amytal test (IAT, also known as the Wada test). IAT for language lateralization has in recent years been replaced by functional magnetic resonance imaging (fMRI), an advanced neuroimaging method relating to task-associated neurophysiological changes in the brain. Although fMRI has disadvantages when studying MTL structures (*Constable et al., 2000; Fransson et al., 2001*) several studies have published reports pointing to a predictive value for assessment of post-surgical memory outcome (*Rabin et al., 2004; Janszky et al., 2005; Richardson et al., 2006; Binder et al., 2008; Bonelli et al., 2010*). Most studies, however, present group results as the search for a predictive task at an individual level has not been without adversity.

The quest for a quantitative, prognostic memory task at an individual level continues and recent data point to the importance of testing both memory and language as they are closely linked (*Baldo et al., 2006; Binder et al., 2008 and 2009; Labudda et al., 2010*). Lateralized fMRI activation presented as lateralization indices, LIs, in anterior language areas has been shown to be the strongest predictor for verbal memory outcome following temporal lobe resection (*Binder et al., 2008*). In patients with pharmaco-resistant temporal lobe epilepsy material-specific re-organization can occur. Verbal skills are highly prioritized functions as left hemisphere dominant patients with left TLE often show a partial shift of verbal encoding to the right mesial structures, while verbal encoding in right, non-dominant hemisphere TLE patients with frequent seizures seems to remain unaffected and lateralized to the left temporal lobe (*Powell et al., 2007*).

Recent studies have increasingly used multivariate models and calculation of change scores to optimize predictions for memory decline post-ATLR. Such clinical parameters are neuropsychological test results, structural imaging findings, laterality of surgery, age of onset, disease duration, IQ, and hemisphere dominance (*Baxendale et al., 2006; Bonelli et al., 2010*). These quantitative predictions provide a much more realistic picture of the actual outcomes, which are not dichotomous, but vary along a continuum.

In this pilot study, an fMRI paradigm was used to examine TLE patients under investigation for resective temporal lobe surgery, with particular emphasis on individual assessment making minimal use of statistical models. The paradigm included an

incidental verbal encoding task and a visuospatial memory task. LIs were calculated both for anterior language areas and for relevant structures in the MTL. Our aim was to investigate the additive value from fMRI LIs to established clinical predictive factors, which are known to have an impact on verbal memory after temporal lobe resection.

2. Methods

2.1. Subjects

Twenty-four adult Swedish-speaking patients with normal IQ and pharmaco-resistant temporal lobe epilepsy (TLE) were included between November 2007 and August 2012. The Lund University Ethics Committee approved the study and all subjects gave their written informed consent. All patients were recruited from tertiary epilepsy surgery programmes in Sweden, mainly from the Skåne university hospital in Lund, but also from the university hospitals in Göteborg (4) and Uppsala (1).

All patients had undergone neurological examination, structural MRI, pre-operative neuropsychological testing and extra-cranial video-EEG-recordings. Three patients had additional intracranial video-EEG, including subdural and hippocampal deep electrodes. The decision to offer temporal lobe resection was made at a multidisciplinary management round and patients were included in the study after they were considered eligible for surgery.

Fourteen out of twenty-four patients performed the fMRI tasks before proceeding towards surgery: six patients for right and eight patients for left temporal lobe resection. Reasons for exclusion were not proceeding to operation (4), technical failure during scanning (3), lack of behavioural data supporting adequate task performance (2) and unrelated health issues (1).

All patients underwent ATR with the aim of removing the anterior 3–4 cm of the temporal lobe, including lateral (middle temporal gyrus, inferior temporal gyrus, polar superior temporal gyrus) and medial (fusiform gyrus, parahippocampus, amygdala and anterior hippocampus) structures. All surgically removed specimens were evaluated by skilled neuropathologists in the regional epilepsy surgery teams. Presurgical clinical data for each patient comprising sex, disease duration, age at disease onset, AED treatment, MRI lesions and lateralization of EEG seizure onset is presented in table 1.

2.2 Neuropsychological measures

2.2.1 Pre-operative testing

A series of memory tests were drawn from the protocol for the routine pre-surgical assessment. The results were corrected for age and education and aim to reflect aspects of memory including encoding, retention and recollection. The Claeson-Dahl Learning and Retention Test (*Claeson et al., 1971*) was used for examining verbal episodic memory. This test (CD list learning) enables assessment of learning and retention through a word list consisting of ten words which are orally presented and asked to be recalled after a delay of 15 seconds, over ten trials or until correctly recalled twice. Retrieval of words (CD delayed recall) was assessed after 30 minutes.

The Rey Complex Figure Test (RCFT) (*Lezak, 1983*) was applied for testing retention capacity of visuospatial material. The patient performed a copy trial of a complex figure, which is then removed. Prior to removal the patient was informed that recall of the copied figure would take place 30 minutes later. Retention of the visual-spatial figure was tested after a few minutes (immediate recall) and then at 30 minutes (delayed retention) by a copying task. The latter measurement was used to reflect non-verbal/visuospatial retention.

We thereby obtained three clinical neuropsychological variables:

- CD List learning
- CD Delayed recall
- Rey Complex Figure Test delayed retention

Pre-surgical test results for each patient are presented in table 1.

2.2.2 Post-operative testing and assessment

Each subject was re-tested with the same psychometric battery post-surgery (median 6 months, range 3-20 months). CD list learning was considered to have the strongest predictive value for post-surgical deterioration due to the fact that this parameter reflects the ability to establish new memories (*Baxendale, 2008; Andersson-Roswall et al., 2010*). A relative change, between pre- and post-surgical CD list learning scores, equal to or larger than 1.0 SD, was judged as significant in consistency with other studies of psychometric change (*Hermann et al., 1995; Kneebone et al., 2007*). A change equal to, or larger than, 0,5 standard deviations (SD) were judged a minor improvement or a minor deterioration (i.e. changes ranging from 0,5 to 0,9 SD). Minor deterioration in CD list learning in combination with a significant deterioration in immediate recall for CD list learning was considered as a significant decline in verbal memory.

2.3 Structural MRI scans: pre- and post-operatively

Structural MRI scans were performed, as a part of the clinical investigation, at a 3T scanner following a protocol particularly designed for epilepsy surgery candidates including high resolution anatomical T1 weighted MPRAGE and T2 weighted fluid attenuation (FLAIR) sequences. All scans were reviewed by experienced neuroradiologists. Follow-up MRI scans were performed after surgery (median 6 months, range 2-15,5 months).

To measure resected volume and remaining hippocampus volume, the resection cavity and the remaining hippocampus on the resected side were manually outlined on coronal MR-images reconstructed from 3D T1-sequences from a 3T scanner by an experienced neuroradiologist. Volumes were calculated by summing the areas of the regions of interest on each section and multiplying the total area by the slice thickness (3 mm). The anatomical landmarks were identified according to previously published anatomical MR-correlations (*Duvernoy HM, 1998*) and are equal to the ones clinically used at our department for hippocampus volumetric measurements. The posterior limit of the hippocampal tail was defined as the section where the entire length of the crus fornices was seen. This section was not included in the volumetric process.

2.4 fMRI-tasks – experimental design

The entire fMRI test comprised two different tasks: (A) a verbal encoding paradigm and (B) a visuospatial recall paradigm.

(A) The verbal memory paradigm: The verbal fMRI task used to study memory effects in healthy subjects is described in detail in previous publications (*Fletcher et al., 2003; Strandberg et al., 2011*). Two different encoding tasks were mixed, one for deep and one for shallow encoding. 192 nouns were presented during scanning and in each noun two letters were underlined. Subjects were asked to perform one of two tasks: decide if the word was pleasant or not (deep encoding) or if the underlined letters were in alphabetical order or not (shallow encoding).

(B) The visuospatial recall paradigm: The second paradigm was a mental navigation task originally designed for a PET study (*Roland et al., 1987*), later modified for fMRI use. The task has been frequently used in fMRI studies and is described in detail in previous publications (*Ávila et al., 2006; Strandberg et al., 2011*)

An unexpected recognition test followed the scanning as we aimed at testing for incidental learning. Neuropsychological testing of incidental verbal encoding has shown to have a high ecological validity, i.e. correlate significantly to memory in everyday life (*Helmstaedter et al., 1998*). On a computer screen the patients were consecutively presented with a random mix of the 192 nouns previously seen during scanning and an additional 96 words not seen before. They were asked to answer the following question: “have you seen this word during the scanning?” and answers were logged as subjects replied yes or no by pressing indicated mouse pad buttons. Logged

answers were categorized and controlled as previously described (*Strandberg et al., 2011*). The results served to ensure task compliance for the verbal encoding task. Patients who did not respond during the scanning or during the recognition task were excluded from the study.

2.5 Functional MRI scanning

Functional magnetic resonance imaging was performed using a 3T Philips Achieva MR unit with a standard quadrature head coil. A GRE-EPI pulse sequence (matrix size 64×64, TE = 30 ms, TR = 3000 ms, FoV = 192 mm, 49 slices, slice thickness = 3 mm, 0 mm slice gap, interleaved slice acquisition) was used for functional imaging. 3D T1-weighted and FLAIR (T2-weighted) sequences were used to obtain anatomical images for anatomical overlay of functional activation maps and to exclude pathology.

2.5.1 Preprocessing and BOLD data statistical analysis

All data analysis was performed using MATLAB (Mathworks, Natick, MA). Preprocessing and statistical analysis was performed with SPM5 software (Wellcome Department of Cognitive Neurology, <http://www.fil.ion.ucl.ac.uk/spm>). Preprocessing included motion correction, where images were realigned to the first image to correct for movement-related variance, as well as slice time correction. For normalization the SPM5 EPI template was used, which is based on a standard Montreal Neurological Institute (MNI) space (*Friston et al., 1995; Ashburner et al., 1999*). Finally, the images were then spatially smoothed with an 8-mm isotropic Gaussian kernel to fulfill the assumptions of Gaussian random field theory (*Worsley et al., 1995*).

Using the general linear model, statistical maps were computed for the verbal memory paradigm. Onset vectors were created from the logged data of each participant's recognition test corresponding to all the possible event types. For the visuospatial task a single onset vector (active state) was created from the onsets of the eight blocks of mental navigation. The BOLD time course was modeled by convolving the onset vectors with the SPM5 canonical hemodynamic response function (HRF).

The following contrasts were analyzed:

(A) For the verbal memory paradigm:

A. The comparison of the deep encoding trials (“pleasant or not pleasant?”) with the shallow encoding trials (“correct alphabetical order or not?”) irrespective of successful encoding.

(B) For the visuospatial paradigm;

B. The active state (mental navigation) was contrasted against the baseline state (counting odd numbers).

The resulting contrast images were entered into a second level random effects analysis. The statistical parametric maps were thresholded at $p < 0.001$, uncorrected for multiple

comparisons. The threshold was chosen to reduce the occurrence of false negatives, as used in clinical practice at our department, for fMRI language and motor tasks.

2.5.2 Laterality assessment

Laterality indices (LIs) were calculated using a toolbox running within the SPM environment (*Wilke and Lidzba, 2007*). Two masks for analysis of activation within regions of interest (ROI) were used.

The **Broca ROI** was identical to the ROI used in our department for clinical lateralization of language using a word generation task. It includes the inferior frontal gyrus, the main part of the middle frontal gyrus and the dorsolateral pre-frontal cortex. This includes the area of Broca and its homologue in the right hemisphere.

The **MTL ROI** encompassed the mesial temporal lobe structures that are relevant with respect to memory functions; hippocampus, parahippocampus, entorhinal cortex, perirhinal cortex and amygdala. The ROI was drawn using a standard single subject T1-weighted MR-image (ch2-template) in the MRICroN software (*Rorden et al., 2000*) by an experienced neuroradiologist.

The bootstrap algorithm included as an option in the toolbox was applied in order to calculate robust LIs at different thresholds. The algorithm was applied to masked statistical maps (t-maps) according to the previously defined ROIs obtained for the deep versus shallow contrast (the verbal paradigm, **A**) and the active versus baseline contrast (the visuospatial paradigm, **B**).

An overall LI mean greater than 0.1 was classified as left lateralized and an overall LI mean less than -0.1 was classified as right lateralized memory or language function. An overall mean LI between 0.1-(-0.1) was classified as bilateral (no lateralization), in accordance with previously used limits (*Szafarski et al., 2006; Yuan et al., 2006; Strandberg et al., 2011*).

2.6 Risk assessment score (RAS) and definition of outcome

A comprehensive risk assessment score for prediction of postoperative memory decline was created for each patient taking into account hemisphere dominance, MRI-pathology and baseline memory capacity. Patients with good pre-operative memory and language function are at higher risk for developing post-operative deficits, particularly if the dominant temporal lobe is resected (*Chelune et al., 1991; Helmstaedter and Elger, 1996; Baxendale, 2008*).

RAS parameters:

Hemisphere dominance was mainly based on handedness classified in accordance with the Edinburgh Handedness Questionnaire (*Oldfield, 1971*) strongly emphasizing the hand used for writing. In our study all but one patient (# 1) were dexterous for writing. During the course of the clinical investigation this patient performed a standard word

generation fMRI task for lateralization of language. Dominant resection received 1 point and non-dominant 0.

For structural MRI, any potential epileptogenic lesion in the MTL was included. MRI-positive (0 points) refers to patients with any structural pathology noted pre-operatively as opposed to MRI-negative, i.e. normal finding (1 point).

Baseline memory capacity was assessed with the CD list learning score. The limit for good baseline memory was set at -1 standard deviation (-1SD) as anything below that falls below the norm and it is also the clinical cut-off used at our centre. Good baseline memory received 1 point and poor baseline memory received 0 points.

Patients risk assessments are shown in table 2. Patients with 0-1 points were considered as having a **low risk** for post-operative memory decline and 2-3 points as having a **medium-high risk** for post-operative deficits in verbal memory.

Expected outcome was defined as:

RAS 2-3 followed by post-operative verbal memory decline

RAS 0-1 followed by no postoperative memory decline

Unexpected outcome was defined as:

RAS 2-3 followed by post-operative intact memory

RAS 0-1 followed by post-operative memory decline

2.6.1 Additional risk in relation to fMRI LI indices

fMRI LI scores were individually evaluated for additional risk for verbal memory deficit. Based on previous studies (*Powell et al., 2007; Banks et al., 2012; Willment & Golby, 2013*), we assumed that fMRI activation would show the following patterns:

For patients with left TLE, fMRI activity for language should be left lateralized in language regions and right lateralized for verbal encoding in the MTL.

For patients with right TLE, fMRI activity for both language and encoding should be left lateralized.

Deviation from the expected pattern served as a red alert.

The possible estimation variables were:

(0) No added risk: expected LIs for language and verbal encoding.

(+) Possible added risk: deviation of expected LI for verbal encoding in the MTL ROI.

(++) Added risk of verbal memory deficit: deviation of expected LI for language in the Broca ROI.

The basis for this grading was previous studies pointing to the important connection between language and encoding areas (*Binder et al., 2008 and 2009; Labudda et al.,*

2010), where language lateralization fMRI was shown to have an even stronger predictive value than encoding fMRI activity (*Binder et al., 2008*).

For the visuospatial task, we assumed that fMRI activity should lateralize to the contralateral side of the epileptogenic focus, i.e. to the right MTL for LTLE patients and to the left MTL for RTLE patients (*Jokeit et al., 2001*). As the task pertains to visuospatial recollection, not verbal encoding, it was not included in the risk assessment for fMRI indicating added risk for verbal memory decline.

2.6.2 Statistical analysis of psychometric and fMRI LI data

The Spearman correlation coefficient was calculated to test for correlations between the fMRI LI indices and psychometric outcome measurements. To investigate if the pre-operative assessment factors could be used to predict post-operative verbal memory decline, we performed multiple univariate logistic regressions and calculated odds ratio for all included parameters. We first calculated for all patients and then separately for the RTLE and LTLE group.

In order to connect the tasks with the co-lateralization hypothesis, we checked for correlations between the fMRI LIs in the respective regions of interest. This was done for the whole group and also for the RTLE and LTLE groups separately. Resected volume, remaining hippocampal volume, age at disease onset and disease duration were tested against psychometric outcome parameters.

2.7 Clinical outcome

The classification of clinical outcome with regards to seizures was previously described by *Edelvik et al (2013)*. In short: seizure freedom (with and without aura); 75% reduction in seizure frequency; 50%–74% reduction in seizure frequency; 0%–49% reduction in seizure frequency; and increased seizure frequency. Clinical follow-up time was median 54 months with a range of 5-80 months.

3. Results

3.1 Outcome data

Clinical outcome data, resected volume, remaining hippocampal volume and neuropathological data are shown in table 3. In summary, 10 patients were seizure free at the closing of this study; three experienced a 75% and one a 50-74% seizure reduction. The most common histopathological finding was hippocampal sclerosis (N=10). The median resected volume was 24 cm³ (range 8-47 cm³), which is comparable to previous reports (*Shamim et al., 2009*). The median remaining

hippocampal volume was 0,2 cm³ (range 0-2,4 cm³). There were no significant differences for volume resection or remaining hippocampal volume between RTLE and LTLE patients or when the patients were divided according to seizure outcome (seizure free (N=10) or not seizure-free (N=4)). Neither resection volume, remaining hippocampal volume or disease duration showed significant correlation to psychometric outcome parameters.

Table 3 also includes the neuropsychological change scores relating the difference between before and after surgery for each patient in each parameter (CD list learning/CD delayed recall/RCFT delayed recall). Three patients (#3, 4 and 5) in the RTLE group suffered a significant decline in verbal memory. In the LTLE group, five patients (#8, 9, 10, 11 and 13) suffered significant decline in verbal memory. For visuospatial recollection (RCFT), one patient (#1) in the RTLE group and one patient in the LTLE group suffered significant decline (#14).

3.2 Pre-op fMRI data

Preoperative assessment of fMRI LIs for: language lateralization (Broca ROI), verbal encoding (MTL ROI) and visuospatial memory (MTL ROI) are shown in table 2.

RTLE group: Three patients (# 1, 2 and 3) exhibited the predicted fMRI LI pattern (left lateralized language and verbal encoding). Two patients (# 4 and 5) fulfilled criteria for bilateral language representation; both had right-lateralized verbal encoding. Pat # 6 had right-lateralized language and bilateral verbal encoding.

All patients had, as expected, visuospatial memory lateralized to the left medial temporal lobe structures.

LTLE group: Five patients demonstrated the predicted fMRI LI pattern (left lateralized activity for language and right-lateralized activity for verbal encoding). Patients # 12 and 13 displayed left-hemisphere activation in the Broca ROI, but bilateral activation for verbal encoding in the MTL ROI. Patient 14 showed a highly unusual pattern for a right-handed individual with all lateralization indices pointing to the right hemisphere.

Two patients (#13 and 14) showed right-lateralized activity for visuospatial memory. Five patients exhibited left-lateralization - that is in their epileptogenic temporal lobe - for visuospatial memory.

3.3 Pre-op risk assessment for post-op memory deficit

Table 2 shows the risk assessment score (RAS) for postoperative verbal memory decline based on hemisphere dominance, MRI-pathology and baseline memory capacity. It also includes the three fMRI LI indices for each patient. As can be seen, three (# 4, 5 and 13) out of the four (including # 3) MRI-negative patients in this study exhibited unforeseen fMRI LI patterns that deviated from our initial predictions.

(0): Eight patients were judged to have no increased risk according to fMRI indices as they exhibited the predicted lateralization pattern without any indication of bilateral language.

(+): Two patients (#12, 13; both LTLE) were judged to have a low (+) added risk indicated by fMRI. Both of them exhibited bilateral verbal encoding activity in the MTL.

(++): Four patients (RTLE patients #4, 5 and 6 and LTLE #14) were judged to have a significant (++) added risk as indicated by fMRI. They all displayed bilateral or right-hemisphere activation in the Broca ROI and right-hemisphere or bilateral indices in the MTL ROI for verbal encoding.

3.4 Individual risk assessment score in relation to verbal memory outcome

Table 4 shows the individual patients, divided in left and right TLE groups, plotted according to risk assessment score and post-operative verbal memory change. For the whole group, RAS for verbal memory decline exhibited a specificity of 67% and a sensitivity of 75%, numbers comparable to previous studies (*Baxendale et al., 2006*). Ten patients had expected outcome (RAS 2-3 with verbal memory decline post-surgery or RAS 0-1 without verbal memory decline). Four patients had an unexpected outcome (#7, 8, 10, and 12) (RAS 2-3 and post-operative intact verbal memory or RAS 0-1, but still verbal memory decline after surgery). Post-operative verbal memory decline was identified by fMRI due to bilateral language representation for two right TLE patients (# 4 and 5) with pre-operative normal MRI and verbal memory (RAS 2). Two left TLE patients (# 8 and 10) with pre-operative significant memory deficits and hippocampal pathology who suffered post-operative verbal memory decline were identified neither by clinical scoring nor fMRI.

3.5 Post-operative neuropsychological data correlated to fMRI

For the whole group the only significant correlation was between fMRI visuospatial memory LI in the MTL ROI and RFCT change score ($r=0.586$; $p=0.035$) (Figure 1).

For the LTLE group there were two significant correlations (Figure 2):

- Between fMRI verbal encoding LI in the Broca ROI and CD change score ($r= -0.802$; $p=0.017$).
- Between fMRI visuospatial memory LI in the MTL ROI and RCTF change score ($r=0.829$; $p=0.021$).

For the RTLE group there was a significant correlation between fMRI verbal encoding LI in the MTL ROI and CD change score ($r=0.714$; $p=0.055$) (Figure 3).

None of the odds ratios were statistically significant.

3.6 Correlation between fMRI indices

The only significant correlation was seen in RTLE patients between fMRI verbal encoding LIs in the MTL ROI and fMRI verbal encoding LI in the Broca ROI ($r=0.771$; $p=0.036$). There was no significant correlation between MTL LI and Broca LI for the visuospatial task.

4. Discussion

Assessing and correctly predicting the risk for verbal memory decline is still an important and unresolved issue in epilepsy surgery investigations. In this study we investigated a risk score based on conventional clinical risk assessment together with fMRI laterality indices from a verbal encoding paradigm to improve prognostication of post-operative verbal memory decline at an individual level. Our most interesting finding pertains to patients eligible for R-TLR - with a medium-high risk assessment score - where atypical fMRI language patterns, especially bilateral language representation, raised alert.

Regarding our pre-fMRI-trial suppositions, we were intrigued by the number of bilateral LIs for language and verbal encoding in the RLTE group. These patients are not traditionally considered to be at risk for post-operative verbal memory decline although it has been described previously (*Sherman et al., 2011; Rosvall-Andersson et al., 2012*). Some studies have shown post-operative verbal memory deficits in 20-24% of non-dominant TLE patients (*Helmstaedter, 2003; Sherman et al., 2011*) and the prediction of risk patients in this group is probably neglected (*Helmstaedter, 2013*). A recent study established an equal risk for postoperative memory decline in both RTLE and LTLE patients with unilateral HS and intact verbal memory before surgery (*Baxendale et al., 2013*). The authors conclude that their findings did not support that intact memory was a function of migration to the contralateral structures in people with unilateral HS. Our results are in agreement with theirs and, furthermore, emphasize the importance of the networks between language areas and the MTL structures; particularly considering the impact hippocampal pathology can have on language patterns (*Weber et al., 2006*). Although language function is less investigated than memory in TLE patients, it has been shown that 17-33% of these patients have language deficits (*Bartha-Doering and Trinkka, 2014*) and that there is an association with hippocampal sclerosis (*Hermann et al., 1997; Oddo et al., 2003*).

In our study, three of the four patients that received an (++) added risk due to unanticipated fMRI LI indices were eligible for non-dominant resections. Two of them (#4 and 5) did suffer verbal memory decline post-surgery. In lieu of visible HS on MRI and poor pre-operative verbal memory, the fMRI indices for patients #4 and 5 add

valuable information. The fMRI pattern for patient # 6 is similar to that of patients 4 and 5, but she received a very low risk assessment score. Although her fMRI patterns indicated increased risk, her poor pre-operative memory likely decreased the absolute risk of further decline. We interpret the unpredicted LIs as an indication of atypical language representation coupled with an atypically organized verbal memory, increasing these patients' vulnerability to intervention in non-dominant MTL structures.

We also found a correlation between language (LI Broca) and verbal encoding LI in the MTL for the RTLE group, emphasizing the importance of visualizing connections between language and verbal encoding in the non-dominant hemisphere. The basis for the co-lateralization hypothesis is that the temporal lobe receives input from the ipsilateral cortex, thus creating the setting for verbal or nonverbal material specificity in the MTL. FMRI was recently suggested to be more sensitive to right-hemisphere processing than the IAT procedure (*Janecek et al., 2013*), hopefully benefitting right TLE patients.

Regarding the fMRI indices for language and verbal encoding in the LTLE group most data confirmed the expected risk for memory decline. However, the four patients that had unexpected verbal memory outcome according to our risk assessment score were all left hemisphere dominant. Two (# 8 and 10) of them had unexpected decline and two (#7 and 12) – although judged to be at high risk - did not show significant verbal memory decline by our definition. Traditional clinical parameters did not identify any of these cases, but in one patient (#12) the fMRI index for verbal encoding indicated pre-operative equal use of both MTLs.

In our study increased language lateralization in the BROCA ROI seemed to protect against post-operative decline of verbal encoding for LTLE patients. To comprehend this connection, the anatomic structures in our two different ROIs should be seen as an array of nodes in a collaborating network where increased lateralization can be viewed as a compensatory activation in the language area that post-operatively manifests as less change in CD change score. This reasoning is supported by the functional adequacy model which predicts that post-operative memory outcome will be inversely related to the level of preoperative functioning of the tissue to be resected (*Chelune et al., 1991; Chelune, 1995; Chelune and Najm, 2000*).

The functional adequacy model has received sustenance from fMRI studies aiming at prediction. Focus has been on the to-be-resected tissue (the anterior medial temporal lobe), but we suggest that "the functional adequacy tissue of importance" should include the collaborative network of the to-be-resected tissue as well, namely the language network of the anterior frontal lobe. This proposition becomes increasingly valid considering the growing interest for mTLE as a network disease with widespread network disruptions, and the idea that intrinsic connectivity reflects behavioral capacities (*McCormick et al., 2013*). A call for attention to and more extensive characterization of language capacity in several domains in epilepsy patients have also recently been made (*Bartha-Doering and Trinko, 2014*). Three (# 4, 5, 13) out of the

four (#3) MRI-negative patients that suffered significant verbal memory decline could be identified by unexpected fMRI patterns, suggesting that functional network changes precede structural changes that can be visualized by current structural MRI.

Out of the fourteen subjects, eleven patients showed left-lateralization for the visuospatial task making it one of the most consistent findings in our study. We did not include the visuospatial task in our pre-trial assumptions for several reasons, primarily because its' material-specificity was not our main focus. Also, the task can be easily verbalized and performed with either visuospatial recollection or internal verbalization. The hometown walk task has previously been shown to reliably activate MTL structures - bilaterally and symmetrically - in healthy subjects (*Jokeit et al., 2001; Ávila et al., 2006*). For TLE subjects, it has shown reduced activity ipsilateral to the epileptogenic side (*Janszky et al., 2005*), but a corresponding psychometric task is lacking. RCFT is regarded as a weak predictor of non-dominant temporal lobe function (*Kneebone et al., 2007*). Test results have not been able to differentiate between RTLE and LTLE groups (*McConley et al., 2008*).

Surprisingly, the only significant correlation was between fMRI visuospatial LI in the MTL and RFCT change score when looking at the whole group. This correlation was also seen separately in the LTLE group, but not the RTLE-group. Not knowing the strategy used to solve the task or even if the patients performed the task at all, it is very difficult to interpret what this correlation means. One possible interpretation is that the ability to use a verbal strategy - and verbal networks - to solve the visuospatial recollection task correlates to good outcome for post-operative figurative memory.

A limitation of our study was that a standard fMRI language lateralization was not generally performed in all patients eligible for TLR. Hemisphere dominance was assumed based on handedness rating scale results, family history of left-handedness and pre-surgical domain-specific neuropsychological deficits. Patient #14 revealed unusual fMRI indices for a right-handed person: all indices pointed towards dominance in the right hemisphere. The patient was ambidextrous for all but writing and eligible for "dominant" left ATLR. Post-resection the patient improved in list learning (immediate, but not delayed recall) and worsened in visuospatial recall, a somewhat uncharacteristic profile for a "dominant" resection patient. MRI and later histopathological examination verified HS, a finding that, as previously noted, is connected with atypical language patterns (*Weber et al., 2006*).

Our results are somewhat contradictory and should be regarded with great caution. First and foremost the low number of subjects, the main limitation of our study, make any result, even statistically significant correlations, preliminary at best. The number of participants also prevented us from using multivariate models, which produce notably better predictive information. The group heterogeneity, with even smaller subgroups, also prevented us from performing further activation pattern analysis, group analysis of t-maps or data-driven within-ROI analysis to look for activated regions with greater outcome correlations.

From our study we conclude that fMRI indices probably *do* add value to the pre-surgical work-up of epilepsy patients eligible for ATR. Conventional clinical predictive markers can be improved by non-invasive functional MRI of cognitive functions, thus improving prediction of post-operative decline and patient counseling. Language lateralization should be performed on all patients eligible for resection. Language patterns are important for both left and right TLE patients, as memory and language co-lateralize and bilateral language or right hemisphere dominance is common. Two out of three right TLE patients that suffered an unexpected high risk for post-operative verbal memory decline were identified by assessment of fMRI activity for language and verbal encoding. There is a need for further studies focusing on medial temporal lobe epilepsy as a network disease where the connections between the many functional areas and clinical correlates are explored.

Legends

Table 1. Pre-operative clinical data: sex, age at disease onset, disease duration, AEDs, EEG, MRI and pre-operative neuropsychological test results.

Table 2. Risk assessment score, and the estimation of added risk based on fMRI indices.

Table 3. Post-operative clinical data: seizure outcome, neuropsychological decline expressed as a change score, histological findings and resected volumes based on pre- and post-operative MRI comparison.

Table 4. LTLE and RTLE patients plotted according to RAS and verbal memory outcome.

Figure 1 shows all patients' laterality indices for the visuospatial task plotted against the change score for the figurative task, with a coefficient of determination $r^2=0.027$. A significant correlation (Spearman's Correlation coefficient $r = 0.586$, $p=0.035$) between the pre-op fMRI laterality for visual MTL memory and change in visual recollection capacity before and after temporal lobe resection is seen.

Figure 2. This figure shows the laterality indices for verbal encoding in the Broca (coefficient of determination $r^2=0.539$) and in the MTL ROI (coefficient of determination $r^2=0.131$). A significant, inverse correlation (Spearman's Correlation coefficient $r=-0.802$, $p=0.017$) was seen for activity in the Broca ROI during verbal encoding and subsequent CD change score (decline in verbal memory) for left TLE patients.

Figure 3. Laterality indices for verbal encoding in the Broca (coefficient of determination $r^2=0.158$) and in the MTL ROI (coefficient of determination $r^2=0.608$) respectively and their relation with CD change score are plotted for right TLE patients. A significant correlation between verbal encoding in the MTL and subsequent decline in verbal memory was seen (Spearman's Correlation coefficient $r=0.714$; $p=0.055$).

Table 1. Pre-operative clinical data: sex, age at disease onset, disease duration, AEDs, EEG, MRI and pre-operative neuropsychological test results.

Nr/Id/Sex	Age at disease onset	Disease duration (yrs)	AED at time of investigation	EEG sz onset	MRI pathology	List recall (CD)	Delayed recall (CD)	RCTF delayed recall
1/M	28	13	CBZ	R TL	R mesial sclerosis	-0,5sd	0,3 sd	-0,5sd
2/F	17	18	LTG, GBP	R TL	R occipital demarcated infarction; R hc atrophy	0,3sd	0,5 sd	-2,2sd
3/M	47	7	LTG, VPA	R TL	0	0,5sd	0,7sd	0,7sd
4/F	34	5	LEV, CBZ, PGB	R TL	0	1 sd	0,6 sd	-1,3sd
5/F	34	4	CBZ	R TL	0	-0,5sd	-0,2sd	-2,3sd
6/F	8	19	LTG	R TL	R mesial sclerosis	-1,6sd	-2,5 sd	-2,6sd
7/M	15	32	LEV	L TL	L TL suspect DNET	-0,7sd	-1,3 sd	0,5sd
8/M	19	4	VPA, LTG	L TL	L TL suspect DNET	-1,4sd	0,1 sd	-1,9sd
9/F	1	31	LTG, CLB	L TL	L mesial sclerosis	0,1sd	-2,1 sd	-1,1sd
10/F	19	12	PGB, CBZ	L TL	L mesial sclerosis	-3,3 sd	-2,7sd	--*
11/M	25	5	OXC	L TL	L TL low-grade astrocytoma	0,8sd	-4,5 sd	-1,6sd
12/F	10	20	LTG, VPA	L TL	L mesial sclerosis	-0,2 sd	-0,1 sd	0,0 sd
13/F	13	11	LTG	L TL	0	-0,8sd	-0,8 sd	-1,2sd
14/F	32	28	LEV, OXC	L TL	L mesial sclerosis	-2,2sd	-0,5sd	-1,3sd

*Not able to perform

CBZ carbamazepine; LTG lamotrigin; GBP gabapentin; VPA valproic acid; LEV levetiracetam; PGB pregabalin; CLB clobazam; OXC oxcarbazepine

Table 2. Risk assessment score, and the estimation of added risk based on fMRI indices.

Nr/Id	Hemisphere dominance	MRI pathology	Pre-op verbal memory score	Risk assessment score	Added risk indicated by fMRI	Verbal encoding LI Broca ROI	Verbal encoding LI MTL ROI	Visuospatial memory LI	MTL ROI
1*	0	0	1	1	0	0,75	0,86	0,15	
2	0	0	1	1	0	0,32	0,6	0,62	
3	0	1	1	2	0	0,74	0,25	0,14	
7	1	0	1	2	0	0,3	-0,41	0,4	
8	1	0	0	1	0	0,33	-0,58	0,52	
9	1	0	1	2	0	0,55	-0,66	0,33	
10	1	0	0	1	0	0,55	-0,5	0,53	
11	1	0	1	2	0	0,74	-0,27	0,003	
12	1	0	1	2	+	0,51	0,039	0,22	
13	1	1	1	3	+	0,54	0,042	-0,46	
4	0	1	1	2	++	0,056	-0,12	0,39	
5	0	1	1	2	++	-0,036	-0,26	0,15	
6	0	0	0	0	++	-0,15	-0,037	0,66	
14**	1	0	0	1	++	-0,48	-0,74	-0,36	
Hemisphere dominance (1=dominant; 0=non-dominant) MRI pathology (1=yes; 0=no) Pre-op list learning score (Lower than -1SD=0; higher than -1SD=1)				0-1 Low risk	0 Expected pattern	A positive value greater than 0.1 = left-lateralization.			
				2-3 Medium-high risk	+ MTL pattern unexpected	A negative value less than 0.1 = right-lateralization.			
					++ Language pattern unexpected	0.1-(-0.1) = bilateral activation pattern			

* Left-handed for writing, left hemisphere dominant according to word generation fMRI

** Right-handed for writing, but ambidextrous for all other activities.

Table 3. Post-operative clinical data: seizure outcome, neuropsychological decline expressed as a change score, histological findings and resected volumes based on pre-and post-operative MRI comparison.

Nr/Id	Seizure outcome	Change score (SD): CD list learning/CD delayed recall/RCTF delayed recall	Neuropathology	Resected volume (cm ³)	Remaining hippocampal volume (cm ³)
1	Not sz free	0,6/0,1/-1,7	Hc sclerosis + neuronal heterotypes	28	*
2	Not sz free	0,3/-0,5/0,6	Hc sclerosis	25	0,2
3	Sz free	-0,8/-2,1/0	Hc sclerosis	39	0,2
4	Sz free	-1,6/0/0,5	Hc sclerosis	24	0,3
5	Sz free	-0,5/-1,1/-0,7	Discrete disturbance of neuronal migration	47	0
6	Sz free	-0,4/0,8/-0,4	Hc sclerosis + gliosis	22	1,6
7	Not sz free	1,1/-0,7/0,7	Gliosis	8	1,9
8	Sz free	-1,2/-0,1/1,2	Neuronal heterotypes, glio-neurovascular dysplasia	25	0,1
9	Sz free	-1,5/-0,9/0,3	Hc sclerosis	22	0,1
10	Sz free	-1,7/-1,8/--	Hc sclerosis + neuronal heterotypes	19	0,2
11	Sz free	-2,5/3,1/-0,4	Astrocytoma grade I-II	27	2,4
12	Sz free	-0,4/0/1	Hc sclerosis	31	0
13	Not sz free	-2,6/-0,5/-0,4	Hc sclerosis	18	0,5
14	Sz free	0,9/-2,1/-1,7	Hc sclerosis	17	0,3

*Not possible to measure due to poor image quality

Table 4. LTLE and RTLE patients plotted according to RAS and verbal memory outcome.

	LTLE		RTLE	
	Verbal memory decline	No verbal memory decline	Verbal memory decline	No verbal memory decline
RAS 2-3 Medium-high risk	9, 11, 13	7, 12	3, 4, 5	-
RAS 0-1 Low risk	8, 10	14	-	1, 2, 6

Italics: Patients who received (+) as added risk according to fMRI indices.

Fat: Patients who received (++) as added risk according to fMRI indices.

Figure 1. All patients (n=13) LI for visuospatial encoding in the MTL plotted against change score for figurative recall.

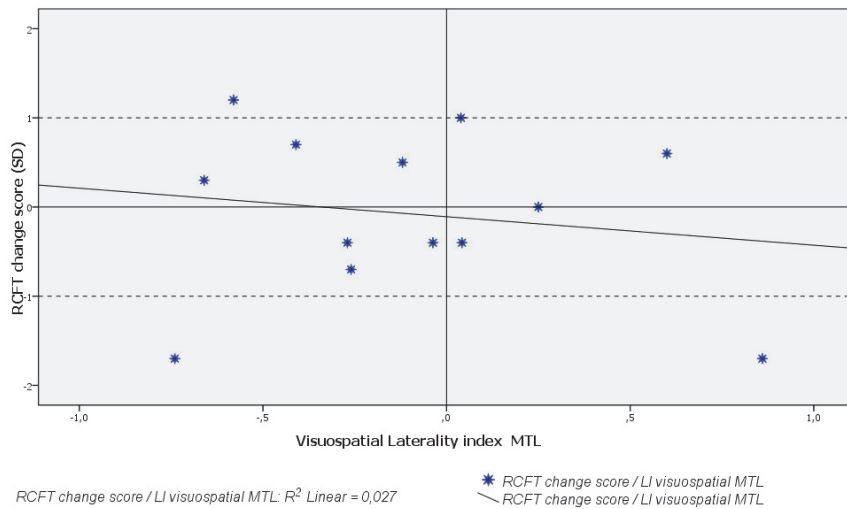


Figure 2. LTLE patients (n=8) verbal encoding LI in the MTL and Broca ROI plotted against CD change score.

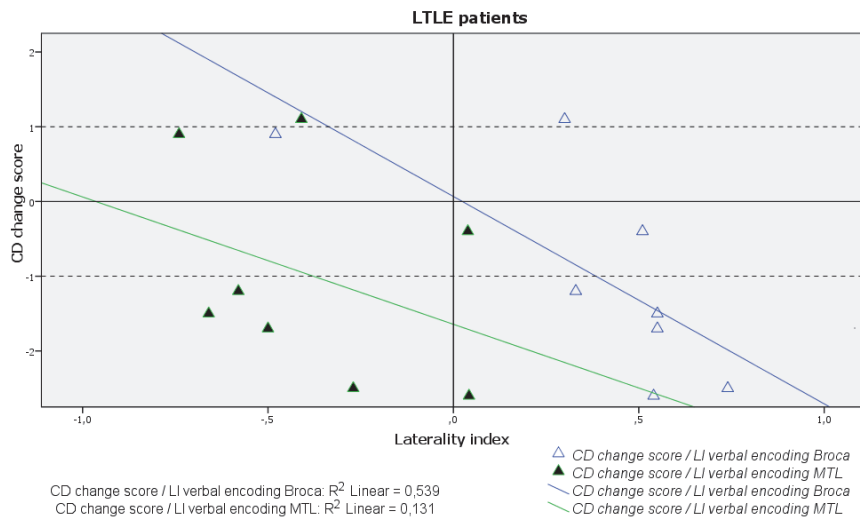
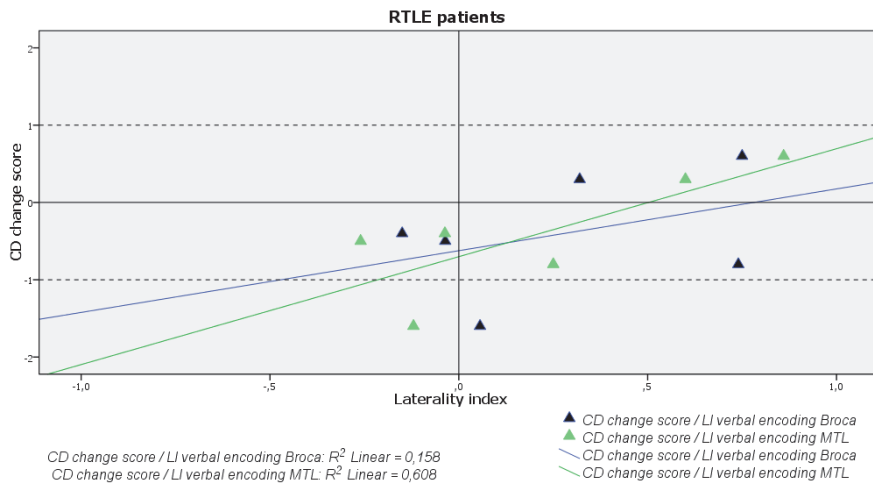


Figure 3. RTLE patients (n=6) verbal encoding LI in the MTL and Broca ROI plotted against CD change score.



References

- Andersson-Roswall, L., Engman, E., Samuelsson, H., Malmgren, K. (2010). Cognitive outcome 10 years after temporal lobe epilepsy surgery. *Neurology* 74(24): 1977-1985.
- Andersson-Roswall L, Malmgren K, Engman E, Samuelsson H. (2012). Verbal memory decline is less frequent at 10 years than at 2 years after temporal lobe surgery for epilepsy. *Epilepsy & Behavior*, Volume 24, Issue 4, Pages 462-467.
- Ashburner J, Friston K.J. (1999). Nonlinear spatial normalization using basis functions. *Human Brain Mapping* 7 (4), 254–66.
- Ávila C, Barrós-Loscertales A, Mallo R, Parcet M-A, Belloch S, Feliu-Tatay R, González-Darder JM. (2006). Memory Lateralization with 2 functional MR Imaging Tasks in Patients with Lesions in the Temporal Lobe. *AJNR Am J Neuroradiol*; 27: 498-503.
- Baldo, J.V., Schwartz, S., Wilkins, D., Dronkers, N.F. (2006). Role of frontal versus temporal cortex in verbal fluency as revealed by voxel-based lesion symptom mapping. *J. Int. Neuropsychol. Soc.* 12, 896-900.
- Banks SJ, Sziklas V, Sodums DJ, Jones-Gotham M. (2012). fMRI of verbal and nonverbal memory processes in healthy and epileptogenic medial temporal lobes. *Epilepsy & Behavior* 25: 42–49.
- Bartha-Doering L and Trinka E. The interictal language profile in adult epilepsy. *Epilepsia*:1–14, 2014
- Baxendale S, Thompson P. (2005). Defining meaningful postoperative change in epilepsy surgery patients: measuring the unmeasurable? *Epilepsy Behav.* 6:207–211

- Baxendale, S., Thompson, P., Harkness, W., Duncan, J. (2006). Predicting Memory Decline Following Epilepsy Surgery: A Multivariate Approach. *Epilepsia* 47(11): 1887-1894.
- Baxendale, Sallie. (2008) The impact of epilepsy surgery on cognition and behaviour. *Epilepsy & Behavior* 12: 592-599.
- Baxendale S, Thompson PJ, Sander JW. (2013). Neuropsychological outcomes in epilepsy surgery patients with unilateral hippocampal sclerosis and good preoperative memory function. *Epilepsia*, 54(9):e131–e134.
- Binder, J.R., Sabsevitz, D.S., Swanson, S.J., Hammeke, T.A., Raghavan, M., Mueller, W.M. (2008). Use of preoperative functional MRI to predict verbal memory decline after temporal lobe epilepsy surgery. *Epilepsia* 109, 57—69.
- Binder, J.R., Swanson, S.J., Sabsevitz, D.S., Hammeke, T.A., Raghavan, M., Mueller, W.M. (2009). A comparison of two fMRI methods for predicting verbal memory decline after left temporal lobectomy: language lateralization versus hippocampal activation asymmetry. *Epilepsia* 51, 618—626.
- Bonelli, S.B., Powell, R.H., Yogarajah, M., Samson, R.S., Symms, M.R., Thompson, P.J., Koeppe, M., Duncan, J.S. (2010). Imaging memory in temporal lobe epilepsy: predicting the effects of temporal lobe resection. *Brain* 133, 1186—1199.
- Claeson L-E, Esbjörnsson E, Carté B-M, Wahlbin M. (1971). Manual to Claeson-Dahls learning test for clinical use (In Swedish). Stockholm: Skandinaviska Testförlaget.
- Chelune GJ, Naugle RI, Lüders H, Awad IA. (1991). Prediction of cognitive change as a function of preoperative ability level among temporal lobectomy patients at six months follow-up. *Neurology*; 41:399–404.
- Chelune GJ (1995). Hippocampal adequacy versus functional reserve: predicting memory functions following temporal lobectomy. *Arch. Clin. Neuropsychol.* 10, 413–432.
- Chelune, GJ.; Najm, IM. Risk factors associated with postsurgical decrements in memory. In: Luders, HO.; Comair, Y., editors. *Epilepsy surgery*. 2nd edition. Lippincott; Philadelphia: 2000. p. 497-504.
- Constable RT, Carpentier A, Pugh K, Westerveld M, Oszunar Y, Spencer DD. (2000). Investigation of the hippocampal formation using a randomized event-related paradigm and z-shimmed functional MRI. *Neuroimage*; 12:55–62.
- Duvernoy HM. The human hippocampus: functional anatomy, vascularization and serial sections with MRI. 2 ed. Berlin: Springer Verlag, 1998.
- Edelvik A, Rydenhag B, Olsson I, Flink R, Källén K, Malmgren K. (2013). Long-term outcomes of epilepsy surgery in Sweden: a national prospective and longitudinal study. *Neurology*; Oct 1;81(14):1244-51.
- Fletcher P.C., Stephenson C.M., Carpenter T.A., Donovan T., Bullmore E.T. (2003). Regional brain activations predicting subsequent memory success: an event-related fMRI study of the influence of encoding tasks. *Cortex.* 39, 1009-26.
- Fransson P, Merboldt KD, Ingvar M, Petersson KM, Frahm J. (2001). Functional MRI with reduced susceptibility artifact: high-resolution mapping of episodic memory encoding. *Neuroreport*;12:1415–1420.

- Friston K.J., Ashburner J., Frith C., Poline J.B., Heather J.D., Frackowiak R.S.J. (1995). Spatial registration and normalization of images. *Human Brain Mapping* 2, 165–89.
- Helmstaedter C and Elger CE. (1996). Cognitive Consequences of Two-Thirds Anterior Temporal Lobectomy on Verbal Memory in 144 Patients: A Three-Month Follow-Up Study. *Epilepsia* Volume 37, Issue 2, pages 171–180, February.
- Helmstaedter C, Hauff M, and Elger CE. (1998). Ecological Validity of List-Learning Tests and Self-Reported Memory in Healthy Individuals and Those with Temporal Lobe Epilepsy. *Journal of Clinical and Experimental Neuropsychology*, Vol. 20, No. 3, pp. 365-375
- Helmstaedter C, Kurthen M, Lux S, Reuber M and Elger CE (2003). Chronic epilepsy and cognition: a longitudinal study in temporal lobe epilepsy. *Ann.Neurol.* 54, 425–432.
- Helmstaedter C. (2013). Cognitive outcome in different surgical approaches in temporal lobe epilepsy. *Epileptic disorders*. September, Volume 15, Issue 3, 221-239.
- Hermann BP, Seidenberg M, Haltiner A, Wyler AR. (1995). Relationship of age at onset, chronologic age, and adequacy of preoperative performance to verbal memory change after anterior temporal lobectomy. *Epilepsia*; 36: 137–45.
- Hermann BP, Seidenberg M, Schoenfeld J, et al. Neuropsychological characteristics of the syndrome of mesial temporal lobe epilepsy. *Arch Neurol* 1997;54: 369–376.
- Janecek JK, Swanson SJ, Sabsevitz DS, Hammeke TA, Raghavan M, E Rozman M, Binder JR. (2013). Language lateralization by fMRI and Wada testing in 229 patients with epilepsy: rates and predictors of discordance. *Epilepsia*; 54 (2): 314-22.
- Janzky J, Jokeit H, Kontopoulou K, Mertens M, Ebner A, Pohlmann-Eden B, Woermann FG. (2005). Functional MRI predicts memory performance after right mesiotemporal epilepsy surgery. *Epilepsia*. Feb; 46 (2):244-50.
- Jokeit H, Okujava M and Woermann FG. (2001). Memory fMRI lateralizes temporal lobe epilepsy. *Neurology*. November 27, vol. 57 no. 10 1786-1793.
- Kneebone A.C., Lee G.P., Wade L.T., Loring D.W. (2007). Rey Complex Figure: Figural and spatial memory before and after temporal lobectomy for intractable epilepsy. *Journal of the International Neuropsychological Society*.13:664-671.
- Labudda K, Mertens M, Aengenendt J, Ebner A, Woermann FG. (2010). Presurgical language fMRI activation correlates with postsurgical verbal memory decline in left-sided temporal lobe epilepsy. *Epilepsy Research*: 92, 258—261
- Lezak, M. D. (1983). *Neuropsychological assessment* (2nd ed.). New York: Oxford University Press.
- McConley R, Martin R, Palmer CA, Kuzniecky R, Knowlton R and Faught E (2008). Rey Osterrieth complex figure test spatial and figural scoring: relations to seizure focus and hippocampal pathology in patients with temporal lobe epilepsy. *Epilepsy Behav.* 13, 174–177.
- McCormick C, Quraan M, Cohn M, Valiante TA and McAndrews MP (2013). Default mode network connectivity indicates episodic memory capacity in mesial temporal lobe epilepsy. *Epilepsia* 54, 809–818

- Oddo S, Solis P, Consalvo D, et al. Mesial temporal lobe epilepsy and hippocampal sclerosis: cognitive function assessment in Hispanic patients. *Epilepsy Behav* 2003;4: 717–722.
- Oldfield R.C. (1971). The assessment and analysis of handedness: the Edinburgh inventory. *Neuropsychologia* 9 (1), 97-113.
- Powell, H.W., Parker,G.J., Alexander,D.C., Symms,M.R., Boulby,P. A., Wheeler-Kingshott, C.A., Barker GJ, Koepp MJ, Duncan JS. (2007). Abnormalities of language networks in temporal lobe epilepsy. *Neuroimage* 36, 209–221.
- Rabin ML, Narayan VM, Kimberg DY, Casasanto DJ, Glosser G, Tracy JI, French JA, Sperling MR, Detre JA. (2004). Functional MRI predicts post-surgical memory following temporal lobectomy. *Brain*; 127:2286–2298.
- Richardson M.P., Strange B.A., Duncan J.S., Dolan R.J. (2006). Memory fMRI in left hippocampal sclerosis: Optimizing the approach to predicting postsurgical memory. *Neurology*; 66; 699-705.
- Roland P.E., Eriksson L., Stone-Elander S., Widen L. (1987). Does Mental Activity Change the Oxidative Metabolism of the Brain? *J Neurosci* 7 (8), 2373-2389.
- Rorden C., Brett M. (2000). Stereotaxic display of brain lesions. *Behavioural Neurology*, 12, 191-200.
- Schuele SU, Lüders HO.(2008). Intractable epilepsy: management and therapeutic alternatives. *Lancet Neurol.* Jun;7 (6):514-24.
- Shamim S, Wiggs E, Heis J, Sato S, Liew Clarissa, Solomon J, Theodore WH. (2009) Temporal Lobectomy: Resection Volume, Neuropsychological Effects and Seizure Outcome. *Epilepsy Behav.* Oct; 16(2): 311–314.
- Sherman EM, Wiebe S, Fay-McClymont TB, Tellez-Zenteno J, Metcalfe A, Hernandez-Ronquillo L, Hader WJ, Jette N. (2011). Neuropsychological outcomes after epilepsy surgery: systematic review and pooled estimates. *Epilepsia*; 52(5): 857-869.
- Strandberg M, Elfgren C, Mannfolk P, Olsrud J, Stenberg L, Van Westen D, Larsson EM, Rorsman I, Källén K. (2011). fMRI memory assessment in healthy subjects: A new approach to view lateralization data at an individual level. *Brain imaging behave, Sep.*
- Szaflarski J.P., Holland A.K., Schmithorst V.J., Byars A.W. (2006). fMRI Study of Language Lateralization in Children and Adults. *Human Brain Mapping* 27, 202-212.
- Weber, B., Wellmer, J., Reuber, M., Mormann, F., Weis, S., Urbach, H., Ruhlmann, J., Elger, C.E., Fernandez, G., (2006). Left hippocampal pathology is associated with atypical language lateralization in patients with focal epilepsy. *Brain* 129, 346–351.
- Wilke M., Lidzba K. (2007). LI-tool: A new toolbox to assess lateralization in functional MR-data. *Journal of Neuroscience Methods* 163, 128-136.
- Willment KC, Golby A. (2013). Hemispheric lateralization interrupted: Material-specific memory deficits in temporal lobe epilepsy. *Front Hum Neurosci.* 7:546.
- Worsley K.J., Poline J.B., Vandal A.C., Friston K.J. (1995). Tests for distributed, nonfocal brain activations. *Neuroimage* 2, 183-94.

Yuan W, Szaflarski J.P. Schmithorst V.J. Schapiro M. Byars A.W. Strawsburg R.H. fMRI shows atypical language lateralization in pediatric epilepsy patients. (2006). *Epilepsia*; 47:593–600.

