



# LUND UNIVERSITY

## Soft Tissue Sarcoma Patterns multiplicity, heterogeneity and growth characteristics

Fernebro, Josefin

2007

[Link to publication](#)

*Citation for published version (APA):*

Fernebro, J. (2007). *Soft Tissue Sarcoma Patterns multiplicity, heterogeneity and growth characteristics*. [Doctoral Thesis (compilation), Breastcancer-genetics]. Department of Clinical Sciences, Lund University.

*Total number of authors:*

1

### General rights

Unless other specific re-use rights are stated the following general rights apply:

Copyright and moral rights for the publications made accessible in the public portal are retained by the authors and/or other copyright owners and it is a condition of accessing publications that users recognise and abide by the legal requirements associated with these rights.

- Users may download and print one copy of any publication from the public portal for the purpose of private study or research.
- You may not further distribute the material or use it for any profit-making activity or commercial gain
- You may freely distribute the URL identifying the publication in the public portal

Read more about Creative commons licenses: <https://creativecommons.org/licenses/>

### Take down policy

If you believe that this document breaches copyright please contact us providing details, and we will remove access to the work immediately and investigate your claim.

LUND UNIVERSITY

PO Box 117  
221 00 Lund  
+46 46-222 00 00

# **Soft Tissue Sarcoma Patterns multiplicity, heterogeneity, and growth characteristics**

**Josefin Fernebro**

Department of Oncology, Lund University, Lund, Sweden



## **Doctoral Dissertation**

by due permission of the Faculty of Medicine,  
Lund University, Sweden, to be publicly defended  
in the lecture hall, Barngatan 2, Lund University Hospital, Lund at 9.00  
a.m., Thursday May 24<sup>th</sup>, 2007

## **Faculty Opponent**

Professor Øyvind Bruland, Department of Oncology,  
the Norwegian Radium Hospital, Oslo, Norway

## **Supervisors**

Mef Nilbert and Jacob Engellau, Department of Oncology and  
Anders Rydholm, Department of Orthopedics,  
Lund University Hospital and Lund University.

Organization LUND UNIVERSITY		Document name DOCTORAL DISSERTATION	
Department of Oncology Lund University SE-221 85 Lund, Sweden		Date of issue May 24th, 2007	
Author(s) Josefin Fernebro		Sponsoring organization	
Title and subtitle Soft Tissue Sarcoma Patterns; multiplicity, heterogeneity, and growth characteristics			
<p>Abstract</p> <p>Soft tissue sarcomas (STS) represent a group of rare and heterogenous tumors that optimally should be diagnosed and treated within multidisciplinary teams. This thesis has studied various aspects – pathological, genetical, and clinical – of STS.</p> <p>In study I, we demonstrated that 20% of the patients in a population-based series of 818 STS developed second primary malignancies. An increased risk of developing a second malignancy was identified (SMR 1.3; 95% CI=1.0-1.5), with a particularly high risk of developing a second STS (SMR 17.6; 95% CI=8.1-33.5).</p> <p>Study II included 13 patients who had developed at least two primary STS and applied array-based comparative genomic hybridization to study the genetic profiles of these tumors. Cluster analysis and comparison between the genetic profiles suggested that 8 cases represented second primary STS, whereas 5 cases likely represented soft tissue metastases. In study III cDNA microarray was applied to 26 synovial sarcomas and identified differentially expressed genes in relation to gene fusion type. Among the discriminators were several genes that have previously been found to be up-regulated in SS, including AXL, ZIC2, SPAG7, AGRN, FOXC1, NCAM1. In study III we assessed the impact of targeting peripheral versus central tumor areas using tissue microarray-based staining for Ki-67 in leiomyosarcomas and demonstrated that the Ki-67 expression was higher in the tumor periphery in 18/25 tumors. These observations suggest that Ki-67 evaluation for prognostic purposes should be standardized regarding the part of the tumor investigated. In study V, peripheral tumor growth pattern was evaluated on preoperative MRI with correlations to microscopical growth pattern and prognosis. All tumours with diffuse infiltration on MRI also showed microscopical infiltration, whereas MRI failed to identify infiltration in one-third of the microscopically infiltrative tumours. Diffusely infiltrative growth on MRI also correlated with prognosis.</p> <p>In summary, we have demonstrated that patients with STS are at increased risk of developing second primary tumors, including STS, with genetic profiles supporting independent tumor origin. We have also demonstrated that the underlying gene fusion type in synovial sarcoma influence the gene expression profile. Finally, the tumor periphery seems to provide the best information; our studies suggest that evaluation of Ki-67 staining should be standardized, perhaps to the periphery, and that MRI-based classification of the peripheral tumor growth pattern may provide prognostic information.</p>			
Key words: Soft tissue sarcoma, multiple primary tumors, array comparative genomic hybridization, synovial sarcoma, cDNA microarray, leiomyosarcoma, Ki-67 expression, tumor growth pattern, MRI			
Classification system and/or index terms (if any):			
Supplementary bibliographical information:		Language English	
ISSN and key title: 1652-8220		ISBN 978-91-85559-66-4	
Recipient's notes		Number of pages	Price
		Security classification	

Distribution by (name and address)

I, the undersigned, being the copyright owner of the abstract of the above-mentioned dissertation, hereby grant to all reference sources permission to publish and disseminate the abstract of the above-mentioned dissertation.

Signature Josefin Fernebro

Date April 14, 2007

Department of Oncology,  
Lund University,  
Lund, Sweden

# **Soft Tissue Sarcoma Patterns**

**multiplicity, heterogeneity, and growth characteristics**

**Josefin Fernebro, MD**



**Thesis 2007**



## **Contact address**

---

Josefin Fernebro, MD  
Department of Oncology  
University Hospital  
SE-221 85 Lund, Sweden  
E-mail: josefin.fernebro@med.lu.se

ISBN 978-91-85559-66-4  
Lund University, Faculty of Medicine Doctoral Dissertation Series 2007:88  
Thesis layout: Ortonova AB, Lund  
Printed by Mediatryck  
Sweden 2007

# Contents

**Studies included in thesis and related publications, 2**

**Abbreviations and definitions, 3**

**Thesis at a glance, 4**

**Populärvetenskaplig sammanfattning, 5**

**Background and Purpose, 8**

*Epidemiology, 8*

*Carcinogens, 9*

*Treatment-induced STS, 9*

*Hereditary sarcoma, 9*

*Histopathology, 10*

*Tumor heterogeneity, 12*

*Cytogenetics, 13*

*Molecular pathways, 14*

*Clinical presentation, 17*

*Imaging, 17*

*Diagnostics, 17*

*Surgery, 18*

*Radiotherapy, 18*

*Chemotherapy, 18*

*Targeted therapy, 19*

*Prognostic factors and prognostic systems, 20*

**Materials, 21**

**Methods, 24**

*Risk assessment, 24*

*DNA extraction, 24*

*RNA extraction, 24*

*Array comparative genomic hybridization, 24*

*Expression microarray, 25*

*Tissue microarray, 27*

*Immunohistochemical staining, 28*

*Assessment of peripheral tumor growth pattern, 28*

**Results and Discussion, 30**

*Increased risk of malignancies in patients with STS, 30*

*Gene expression profiling in synovial sarcoma, 33*

*Tumor heterogeneity, 34*

*Peripheral tumor growth pattern, 36*

**Conclusions and Future questions, 38**

**Acknowledgements, 39**

**References, 40**

## Studies included in thesis and related publications

### Studies included in thesis

- I. Fernebro J, Bladström A, Rydholm A, Gustafson P, Olsson H, Engellau J, Nilbert M.  
Increased risk of malignancies in a population-based study of 818 soft-tissue sarcoma patients.  
*Br J Cancer* 2006; 95(8): 986-90.
- II. Fernebro J, Carneiro A, Rydholm A, Karlsson A, Borg Å, Nilbert M.  
Multiple soft tissue sarcomas: genetic profiling differentiates metastases and new primary tumors.  
In manuscript.
- III. Fernebro J, Francis P, Eden P, Borg A, Panagopoulos I, Mertens F, Vallon-Christersson J, Åkerman M, Rydholm A, Bauer HC, Mandahl N, Nilbert M.  
Gene expression profiles relate to SS18/SSX fusion type in synovial sarcoma.  
*Int J Cancer* 2006;118(5):1165-72.
- IV. Fernebro J, Engellau J, Persson A, Rydholm A, Nilbert M.  
Standardizing evaluation of sarcoma proliferation: higher Ki-67 expression in the tumor periphery than the center.  
*APMIS*, in press.
- V. Fernebro J, Wiklund M, Jonsson K, Bendahl P-O, Rydholm A, Nilbert M, Engellau J.  
Focus on the tumour periphery in the MRI evaluation of soft tissue sarcoma: infiltrative growth signifies poor prognosis.  
*Sarcoma*, 2006, e-published

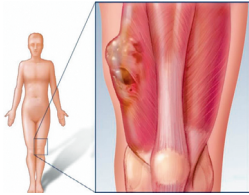
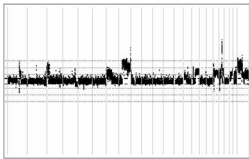
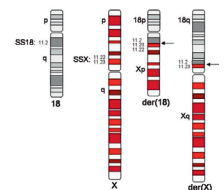
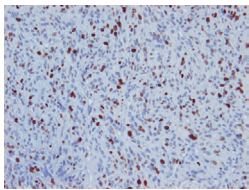
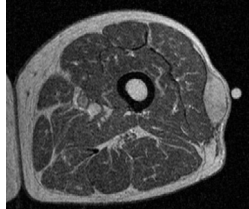
### Related publications

- VI. Nilbert M, Meza-Zapeda L, Francis P, Myklebost O, Fernebro J, Nilbert M.  
Lessons from genetic profiling in soft tissue sarcomas.  
*Acta Orthop Scand* 2004; 75: 35-50.
- VII. Francis P, Fernebro J, Eden P, Laurell A, Rydholm A, Domanski HA, Breslin T, Hegardt C, Borg A, Nilbert M.  
Intratumor versus intertumor heterogeneity in gene expression profiles of soft-tissue sarcomas.  
*Genes Chrom Cancer* 2005; 43(3): 302-8.
- VIII. Francis P, Namlos HM, Muller C, Eden P, Fernebro J, Berner J-M, Bjerkehagen B, Åkerman M, Bendahl P-O, Isinger A, Rydholm A, Myklebost O, Nilbert M.  
Diagnostic and prognostic gene expression signatures in 177 soft tissue sarcomas: hypoxia-induced transcription profile signifies metastatic potential.  
*BMC Genomics* 2007;8(1):73.

## Abbreviations and definitions

<b>aCGH</b>	Array comparative genomic hybridization	<b>Ki-67</b>	Proliferation antigen Ki-67
<b>BASE</b>	BioArray Software Environment, software used for analysis of microarray data	<b>KIT</b>	Gene mutated in most GIST
<b>COT-1 DNA</b>	DNA with rapidly annealing elements, used to suppress cross-hybridization to repetitive DNA	<b>MFH</b>	Malignant fibrous histiocytoma
<b>EGF</b>	Epidermal growth factor	<b>MMP</b>	Matrix metalloproteinases
<b>EORTC</b>	European organisation for research and treatment of cancer	<b>MPNST</b>	Malignant peripheral nerve sheath tumor
<b>FGF</b>	Fibroblast growth factor	<b>MRI</b>	Magnetic resonance imaging
<b>FISH</b>	Fluorescence in situ hybridization	<b>NCI</b>	National Cancer Institute
<b>FNA</b>	Fine needle aspiration	<b>PI3K</b>	Phosphoinositide-3 kinase
<b>FNCLCC</b>	Fédération Nationale des Centres de Lutte Contre le Cancer	<b>RAR</b>	Retinoic acid receptor
<b>GIST</b>	Gastrointestinal stromal tumor	<b>SIN</b>	Size, invasion, necrosis; prognostic system applied within the SSG
<b>Gy</b>	Gray, radiotherapy unit	<b>SMR</b>	Standard morbidity ratio
<b>HDAC</b>	Histone deacetylase inhibitors	<b>SS18</b>	Synovial sarcoma translocation gene on chromosome 18
<b>Hh</b>	Hedgehog	<b>SSG</b>	Scandinavian Sarcoma Group
<b>HER-2/neu</b>	Human epidermal growth factor receptor	<b>SSX1/2/4</b>	Synovial sarcoma X breakpoint genes 1/2/4
<b>HIF-1<math>\alpha</math></b>	Hypoxia inducible factor-1 $\alpha$	<b>STS</b>	Soft tissue sarcoma
<b>HNPCC</b>	Hereditary nonpolyposis colorectal cancer	<b>TMA</b>	Tissue microarray
<b>IGF</b>	Insulin growth factor	<b>TNF-<math>\alpha</math></b>	Tumor growth factor $\alpha$
		<b>UPS</b>	Undifferentiated pleomorphic sarcoma
		<b>VEGF</b>	Vascular endothelial growth factor
		<b>Wnt</b>	Wingless signaling transduction pathway

## Thesis at a glance

	Question	Method	Result		Conclusion
I	Are patients with STS at increased risk of developing second primary tumors?	Multiple primary tumors characterized and risk calculated in a population-based cohort of 818 STS patients	164 (20%) of the patients developed metachronous malignancies. Increased risk of a second malignancy, particularly a second STS		Patients with STS are at increased risk of second primary malignancies, including STS
II	Can differences in the genetic profiles be found in multiple STS from the same individual?	Array comparative genomic hybridization applied to 30 STS from 13 patients	Cluster analysis suggests 8 cases represent different primary tumors, whereas 5 cases likely represent soft tissue metastases		Independent STS may develop, although some cases represent soft tissue metastases
III	Do expression profiles in synovial sarcoma vary with genetic alterations or metastatic potential?	cDNA microarray applied to 26 synovial sarcomas. Gene expression analyzed in relation to genetics and clinical data	Differentially expressed genes identified in relation to gene fusion type, including e.g. <i>AXL</i> , <i>SPAG7</i> and <i>NCAM</i>		Gene fusion variant <i>SS18-SSX1</i> versus <i>SSX2</i> influence gene expression and weak metastasis signal identified
IV	Does proliferation assessed by Ki-67 immunostaining differ within a STS?	TMA and immunohistochemical staining for Ki-67 applied along the tumor diameter in 25 leiomyosarcomas	Ki-67 expression higher in the tumor periphery in 18/25 tumors. Different cut-off levels gave similar results		Ki-67 evaluation for prognostic purposes should be standardized and should probably focus on the tumor periphery
V	Can preoperative MRI be used for prognostication in STS?	Peripheral tumor-growth pattern evaluated on MRI and correlated to microscopy and prognosis in 78 STS	2/3 of the tumors with MRI infiltration also showed microscopic infiltration. Diffusely infiltrative growth on MRI predicts risk of metastases		MRI-based evaluation of peripheral tumor growth pattern may provide prognostic information and should be further evaluated

## Populärvetenskaplig sammanfattning

I Sverige diagnostiseras årligen drygt 300 mjukdelssarkom, vilket utgör ca 1% av alla maligniteter. Mjukdelssarkom är elakartade tumörer som uppkommer i stödjevävnader såsom muskler, fett och bindväv, vanligast i extremiteter och bålvägg. Sarkomdiagnostik och behandling bör för bästa resultat centraliseras med multidisciplinär handläggning av kirurg, röntgenolog, patolog, cytolog, klinisk genetiker och onkolog. Tumörerna är ofta stora, medianstorleken för en ytlig tumör är 4 cm och för en djup tumör 9 cm. Mjukdelssarkom är aggressiva; lokala tumörrecidiv uppkommer hos 10–20% och 1/3 av patienterna får fjärrmetastaser, de flesta av vilka avlider av sin sjukdom inom ett år.

Det finns mer än 30 olika histopatologiska undergrupper och även inom en och samma tumör finns ofta heterogenitet med varierande grader av pleomorfism och histopatologisk differentiering. Genetiskt kan mjukdelssarkom indelas i två huvudgrupper där den ena gruppen karakteriseras av återkommande, enkla förändringar i arvsmassan (t ex synoviala sarkom och myxoida liposarkom med balanserade kromosomtranslokationer) medan den andra gruppen präglas av komplexa genetiska förändringar (t ex högmaligna leiomyosarkom och pleomorfa liposarkom med multipla numeriska och strukturella förändringar).

Hos merparten av alla mjukdelssarkom är etiologin okänd. En liten del av tumörerna orsakas av ärftlighet och de mest kända ärftliga syndromen associerade med en ökad risk att utveckla mjukdelssarkom är neurofibromatos samt Li-Fraumeni syndromet. Båda dessa syndrom karakteriseras av medfödda DNA-förändringar (mutationer) som återfinns i kroppens alla celler och som ärvs från föräldrarna. Strålbehandling och cytostatikabehandling har också visats öka risken för sekundära mjukdelssarkom. Exposition för konserveringsmedel (klorfenoler) och herbicider (fenoxysyror) har i vissa studier visats ge en något ökad risk för

mjukdelssarkom. Endast en mycket liten del av mjukdelssarkom kan dock förklaras av de nämnda riskfaktorerna.

Den primära behandlingen av mjukdelssarkom är kirurgi som ofta kombineras med lokal strålbehandling och med cytostatikabehandling om tumören uppvisar högriskkriterier för fjärrspridning; t ex storlek >8 cm, nekros, kärlinväxt, och infiltrativt växtsätt.

### *Har patienter med mjukdelssarkom en ökad risk att utveckla annan cancer?*

Hos barn som behandlats för cancer har en ökad risk att drabbas av ny tumörsjukdom, häribland sarkom, påvisats. För att undersöka om vuxna sarkompatienter har ökad risk för nya maligna tumörer genomfördes en epidemiologisk studie baserad på det regionala sydsvenska cancerregistret.

Av 818 patienter med mjukdelssarkom fann vi att 20% hade utvecklat ytterligare en malign tumör (vanligast var cancer i bröst, tjocktarm och prostata) innan eller efter mjukdelstumören. Denna siffra är dubbelt så hög som hos cancerpatienter i allmänhet, av vilka 8–10% utvecklar ytterligare maligniteter. Riskberäkningarna visade att patienter med mjukdelssarkom har en signifikant ökad risk att utveckla en ny malignitet, med speciellt hög risk för ett andra sarkom.

### *Representerar flera mjukdelssarkom hos samma patient multipla primära tumörer eller ett ovanligt metastasmönster?*

Mot bakgrund av fyndet i studie I önskade vi undersöka huruvida multipla mjukdelssarkom utgör separata primärtumörer eller en ovanlig form av metastasering. Mjukdelssarkom metastaserar vanligen via blodbanan direkt till lungorna, men spridning till mjukdelar på andra ställen i kroppen har i sällsynta fall beskrivits.

För att undersöka detta studerades genomiska profiler (d v s ökad/miskad mängd DNA i form

av amplifieringar/deletioner) i 30 tumörer från 13 patienter med hjälp av array-comparative genomic hybridization (aCGH) metoden, och profiler från tumörer hos samma patient jämfördes. Hos 8 patienter hade tumörerna från samma individ fler olikheter än likheter, vilket talar för att de utgjorde multipla primära mjukdelssarkom hos samma person. Hos de resterande 5 patienterna var de sarkom patienten utvecklat genetiskt nästan identiska vilket talar för att dessa utgjorde metastasering till andra mjukdelar i kroppen.

### ***Kan genuttrycksprofiler skilja mellan synoviala sarkom med olika underliggande fusionsgener?***

De flesta synoviala sarkom karakteriseras av en genetisk avvikelse, en translokation med de två alternativa fusionsgenerna *SS18-SSX1* och *SS18-SSX2*. Kan genuttrycksprofilen i synoviala sarkom kopplas till den bakomliggande fusionsgenen eller till andra kliniska eller genetiska karakteristika?

I studie III kartlades genuttrycksprofilen i 26 synoviala sarkom med hjälp av cDNA-mikroarray teknik. Med denna teknik identifieras över/undertryckta gener med skillnader beroende på genfusion där bl a generna *AXL*, *ZIC2*, *SPAG7*, *AGRN*, *FOXCI*, *NCAM1* samt metallotioniner visade olika uttrycksmönster. Dessa resultat tyder på att genfusionstypen (*SS18-SSX1* eller *SS18-SSX2*) påverkar uttrycket av flera andra tumörassocierade gener. Dessutom indikerade studien en skillnad mellan genexpressionsprofilerna i metastaserande och icke-metastaserande synoviala sarkom innefattande bl a genen *TOP2A* som tidigare kopplats till prognos i synoviala sarkom.

### ***Skiljer sig proliferationen, mätt som Ki-67 uttryck, inom olika områden av mjukdelssarkom?***

Graden av tumörproliferation, vanligast bestämd med immunhistokemisk färgning för proliferationsmarkören Ki-67 eller genom mikroskopisk uppskattning av antal mitoser, har i upprepade studier visats vara av prognostiskt värde för mjukdelssarkom. Trots att markören övervägs för introduktion i kliniskt bruk saknas rekommendationer för hur analysen skall ske, t ex vilket område och hur stor del av tumören som skall analyseras

och vilket gränsvärde som skall användas.

I studie IV utvärderades uttrycket av Ki-67 i 25 leiomyosarkom. Vävnadsmikroarraymetoden med immunhistokemisk färgning av proteiner i tumör-cellerna användes för att undersöka om proliferationen är störst i tumörens periferi eller centrum. Multipla vävnadscylinrar togs längs tumörernas diameter och dessa färgades i sk vävnadsmikroarraysnitt med immunhistokemisk teknik för proliferationsmarkören Ki-67 samt för HIF-1 $\alpha$ , en markör som används för att bestämma graden av syrebrist (hypoxi) i tumören. I 18/25 tumörer var proliferationen högre i tumörens periferi jämfört med dess centrum, i 5 tumörer var proliferationen lika hög i centrum som i periferin, medan 2 tumörer hade högre proliferation centralt än perifert. HIF-1 $\alpha$  uttrycket korrelerade inte med proliferationen. Slutsatsen från denna studie är att analys av proliferationsmarkörer för kliniskt bruk i sarkomprognostik bör standardiseras med undersökning av perifer tumörområden.

### ***Kan magnetkameraundersökning identifiera invasivt växande mjukdelssarkom preoperativt?***

Nyligen har tumörens perifera växtsätt, analyserat i histopatologiska helvävnadssnitt, visats vara en stark prognostisk faktor; tumörer som växer infiltrativt in i omgivande vävnad har större risk för lokalrecidiv och metastasering. Skulle infiltrativt växande mjukdelssarkom kunna identifieras redan vid den diagnostiska magnetkameraundersökningen? Preoperativ identifiering av aggressiva tumörer med stor risk för spridning vore av värde för att överväga att ge dessa individer tilläggsbehandling i form av radioterapi eller cytostatikabehandling redan innan kirurgi.

I studie V jämfördes för 78 mjukdelssarkom bedömning av tumörens perifera växtsätt på histopatologiska storsnitt med bedömning av växtsättet på den rutinmässigt utförda diagnostiska, preoperativa magnetkameraundersökningen. Alla tumörer som med magnetkameraundersökning klassades som infiltrerande var också mikroskopiskt infiltrerande, men 1/3 av de tumörer som mikroskopiskt visade infiltration missades med magnetkameraundersökning. De tumörer som med hjälp av magnet-

kameraundersökning visade infiltration hade högre risk att sprida sig både lokalt och med fjärrmetastaser än de tumörer som inte visade infiltration i omgivande vävnad.

## Sammanfattning

Sammanfattningsvis har vi i studierna funnit

- att patienter med mjukdelssarkom har en överrisk att utveckla ny elakartad tumörsjukdom;
- att multipla mjukdelssarkom (t ex leiomyosarkom och malignt fibröst histiocyтом) med skilda genetiska profiler kan uppkomma hos samma individ, medan andra fall av uppfattade multipla sarkom (t ex liposarkom) kan utgöra ett ovanligt metastaseringsmönster. Denna kunskap har viktiga implikationer i kliniken eftersom beslut rörande terapival skiljer sig mellan metastaserande och icke metastaserande mjukdelssarkom;
- att den bakomliggande genetiska fusionsgenen, *SS18-SSX1* respektive *SS18-SSX2* i synoviala sarkom ger upphov till olika genuttrycksprofiler vilket talar för att den genetiska avvikelsen påverkar olika signalvägar;
- att en svag genexpressionssignal relaterad till metastasering kan identifieras i synoviala sarkom och att denna signal tycks vara kopplad till genen *TOP2A*;
- att tumörens proliferation, mätt som det immunhistokemiska uttrycket av Ki-67, är högst i tumörens periferi. Analys av proliferation, särskilt i klinisk rutinprognostik, bör därför standardiseras och sannolikt fokusera på tumörens periferi;
- att preoperativ magnetkameraundersökning urskiljer tumörer med histopatologiskt infiltrerande periferi, men också missar 1/3 av dessa. Framtida magnetkameraundersökningar bör dock standardiseras, och bland annat försöka bestämma tumörens växtsätt och skulle därmed kunna bidra med preoperativ prognostisk information, vilket i sin tur skulle möjliggöra tilläggsbehandling preoperativt för högriskindivider.



# Background and Purpose

Soft tissue sarcoma (STS) is a group of rare tumors with extensive heterogeneity within and between tumors with differences in histopathology, genetic make-up, response to treatment and prognosis. STS should therefore optimally be diagnosed and treated within sarcoma groups with expertise in pathology, genetics, imaging, surgery, and oncology. Several key issues remain to be improved and evaluated; etiology, heredity, diagnostic reproducibility, prognostics, treatment prediction, and development of more effective treatment regimes, including application of targeted therapies (table 1). This thesis includes studies on the epidemiology, tumor biology, genetic alterations, and imaging of STS with correlations to outcome. The work has been performed within the Lund Sarcoma Group with collaborations with the Karolinska University Hospital and the Scandinavian Sarcoma Group (SSG) and reflects multidisciplinary contributions. The specific aims of the different studies were to:

- characterize multiple primary malignancies in patients with STS and evaluate the risk of secondary tumors;
- investigate whether multiple STS that develop in the same individual have similar genetic profiles and hence if these are likely to represent multiple primary tumors or a rare form of metastatic disease;
- identify gene expression profiles related to histopathology, genetic alterations, and metastatic potential in synovial sarcoma;
- investigate the impact of central *versus* peripheral tumor sampling for analysis of proliferation in leiomyosarcomas;
- evaluate the prognostic role of preoperative Magnetic Resonance Imaging (MRI) in STS.

## Epidemiology

Malignant mesenchymal sarcomas account for

Table 1. Major clinical research questions in STS

<p><b>Etiology</b> (study I)</p> <p>The etiology of STS is in most cases unknown, although an increased incidence has been related to specific genetic syndromes, exposure to certain chemicals and radiotherapy. A better understanding hereof could contribute to preventive measures as well as novel therapeutic strategies.</p>
<p><b>Diagnostics</b> (study II)</p> <p>Histopathological tumor features is the basis for STS classification, often in combination with immunohistochemical stainings and cytogenetic/molecular genetic analysis. However, the reproducibility is sometimes poor with diagnostic reclassifications and discrepancies between different pathologists. Hence, refined diagnostic methods are needed.</p> <p>Second primary STS have been described in 1% of the STS, but it has been difficult to clarify whether these tumors represent multiple STS or rather represent a rare form of metastatic disease. Such a distinction would influence treatment decisions in these patients.</p>
<p><b>Heterogeneity</b> (study IV)</p> <p>STS are characterized by extensive inter-tumor as well as intra-tumor heterogeneity. The tumors are often large and display varying levels of pleomorphism and histopathological differentiation. Are analyses performed on a single tumor sample, e.g. a biopsy, representative of the whole tumor for diagnostic, predictive, and prognostic purposes?</p>
<p><b>Prognostics</b> (studies III and V)</p> <p>Different prognostic systems are currently in use for STS without general agreement on which high-risk factors should be applied e.g. for decisions on adjuvant therapies. Hence, there is a need for novel prognostic markers and validation of currently used factors. Also, treatment predictive markers need to be identified in order to design treatment based on clinical and/or biological factors predicting response.</p>
<p><b>Development of novel targeted therapies</b></p> <p>The value of systemic chemotherapy in most adult STS patients remains controversial and no highly effective therapy is available. The most commonly used agents, ifosfamide and doxorubicin show low response rates, 20-50%, and the prognosis remains poor for patients with metastatic STS. Hence, there is a call for novel therapies targeting the specific alterations driving sarcoma tumorigenesis.</p>

less than 1% of all malignancies with no obvious trends for a changing incidence. Although occasional STS, e.g. neurofibrosarcomas may develop in benign neurofibromas in patients with neurofibromatosis, STS are generally believed to develop *de novo* [62]. STS may occur everywhere but 4 out of 5 are located in the extremities and the trunk wall with half of the tumors in the thigh and one-tenth in the trunk wall. Most of the other tumors are retroperitoneal sarcomas (this thesis, however, concerns sarcomas of the extremities and the trunk wall). The median age at diagnosis is 65 years. There is a slight male predominance. The etiology in the majority of STS cases is unknown; most of these tumors arise without apparent causative factors. However, genetic and environmental factors, viral infections and immunodeficiency have been linked to an increased risk of STS.

## Carcinogens

An increased incidence of STS has been reported among individuals exposed to certain chemicals, e.g. phenoxy herbicides, chlorophenol, dioxin and vinyl chloride [35, 57, 80, 90, 91]. However, other studies have failed to demonstrate a link to STS [181, 213], and the contribution from occupational or other exposures to the development of STS is likely to be very small. In studies on the association between vinyl chloride exposure and the development of STS the increased cancer risk was limited to angiosarcomas of the liver [19, 129]. This applies also to Agent Orange, which was used during the Vietnam war. Whereas some case control studies have suggested an increased risk of STS among Vietnam war veterans, others have failed to demonstrate such a risk [1, 98, 99].

## Treatment-induced STS

Prior radiotherapy is a well known risk factor for the development of STS, and the risk is proportional to the radiation dose [62]. The median time interval for the development of a radiation-induced

tumor is 10 years [35]. Also chemotherapy has been suggested to increase the risk of STS [21, 30, 159]. Chronic lymphedema caused by mastectomy and axillary dissection due to breast cancer increases the risk of developing lymphangiosarcoma (Stewart-Treves syndrome) [35, 104, 114]. Survivors of childhood cancers such as retinoblastoma [17, 63, 105], leukemia [17], Wilms' tumor [17, 21], Hodgkin's lymphoma [16, 17] and sarcoma [30, 159, 165] have been shown to be at increased risk of STS [85, 140] (table 2). Data on adult patients treated for STS are scarce, but suggest an increased risk of a second STS [132].

## Hereditary sarcoma

STS development has been linked to several hereditary cancer syndromes [126], but heredity still has a minor contribution to the total number of STS (table 3). The most common such syndrome is neurofibromatosis type I due to mutations in the tumor suppressor gene *NF1* linked to an increased risk of neurofibrosarcomas [108, 126]. The Li-Fraumeni syndrome due to germline mutations in *TP53* has been associated with various forms of malignant tumors including breast cancer, lymphoma, brain tumors and STS [121, 127]. The premature aging syndromes Werner's syndrome due to mutations in *WRN* [69, 218] and Rothmund-Thomson syndrome with mutations in *RECQ4* [123] have been linked to an increased risk of sarcomas. Patients with Gardner's syndrome, a variant of familial adenomatous polyposis with *APC* gene mutations, carry an increased risk of STS, desmoid tumors and osteomas [149, 162]. Sarcomas have also been described in other hereditary cancer syndromes, including a rare manifestation within hereditary nonpolyposis colorectal cancer (HNPCC) with mutations in mismatch-repair genes [62, 87, 126, 130, 185]. An increased risk of STS has also been linked to melanoma syndrome kindreds within the familial atypical multiple-mole melanoma (FAMMM) syndrome with *CDKN2A* mutations [125].

Table 2. Studies demonstrating an increased risk of malignancy after pediatric malignancies

Primary diagnosis	Treatment <sup>a</sup>	Secondary tumor types reported	Reference
Retinoblastoma	RT <sup>b</sup>	STS, bone sarcoma, lung cancer, bladder cancer, brain cancer <sup>c</sup>	Fletcher et al., 2004
Retinoblastoma	RT	STS, bone sarcoma, melanoma, brain tumor, nasal cavity cancer <sup>c</sup>	Kleinerman et al., 2005 Kleinerman et al., 2007
Wilms' tumor	RT and CT	STS, bone sarcomas, leukemia, lymphoma, mixed carcinoma <sup>c</sup>	Breslow et al., 1995
Hodgkin lymphoma	RT and CT	Solid tumors, leukemia, lymphoma <sup>c</sup>	Beatty et al., 1995
STS	RT and CT	Leukemia, melanoma, breast cancer, bonesarcoma, STS <sup>c</sup>	Cohen et al., 2005
Ewing's sarcoma	CT	STS, leukemia, mixed carcinoma <sup>c</sup>	Paulussen et al., 2001
Osteosarcoma	CT	STS, melanoma, glioblastoma, chondrosarcoma, mixed carcinoma	Pratt et al., 1997
Ewing's sarcoma	CT and RT	Osteosarcoma, leukemia, melanoma, mixed carcinoma <sup>c</sup>	Bacci et al., 2005
Mixed malignancies	RT and CT	STS	Bisogno et al., 2004
Mixed malignancies	CT and RT	Bone sarcoma, STS, breast cancer, Hodgkin's lymphoma <sup>c</sup>	Neglia et al., 2001
Mixed malignancies	RT	STS, bone sarcoma <sup>c</sup>	Henderson et al., 2007

<sup>a</sup> Treatment: RT = radiotherapy, CT = chemotherapy.  
<sup>b</sup> Applies to a small proportion of the patients.  
<sup>c</sup> Significantly increased risk demonstrated.

Table 3. Syndrome associated soft tissue sarcoma

Hereditary syndrome	Inheritance <sup>a</sup> / gene	Sarcoma type	Associated tumors
Neurofibromatosis type I	AD / <i>NF1</i>	neurofibrosarcoma, MPNST	chronic myeloid leukemia, glioma
Li-Fraumeni	AD / <i>TP53</i>	STS	breast cancer, lymphoma, brain tumor
Rothmund-Thomson	Chrom 8 instability / <i>RECQ4</i>	STS, osteosarcoma	melanoma
Werner	AR / <i>WRN</i>	STS	meningioma, thyroid cancer, melanoma
FAMMM	AD / <i>CDKN2A</i>	STS	melanoma, pancreatic cancer
Lynch / HNPCC	AD / <i>MLH1</i> , <i>MSH2</i> , <i>MSH6</i>	STS	colorectal cancer, endometrial cancer <sup>b</sup>
Retinoblastoma	AD / <i>RB</i>	STS, osteosarcoma	CNS tumors, melanoma
Gardner	AD / <i>APC</i>	STS	colorectal cancer, desmoid tumors, osteomas

<sup>a</sup> Inheritance: AD = autosomal dominant, AR = autosomal recessive  
<sup>b</sup> also other tumor types occur at lower frequency

## Histopathology

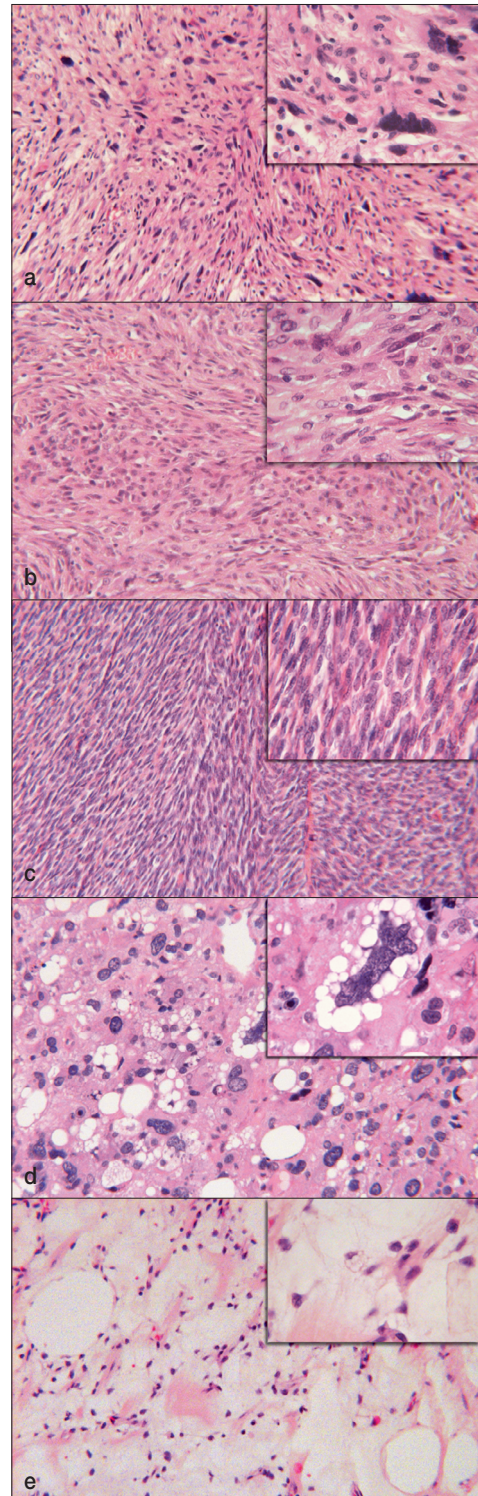
STS are believed to arise *de novo* from mesenchymal stem cells, the origin of which remains unclear, that reside in soft tissues such as muscle,

fat and connective tissue [62]. Conventional light microscopical evaluation is the basis for sarcoma classification, which is based on identification of a cell-lineage of differentiation and resemblance to a normal tissue type in the tumor (figure 1). There

**Figure 1.** Histopathological appearance of the most common STS subtypes.

- a. Malignant fibrous histiocytoma/undifferentiated pleomorphic sarcoma. This subgroup is likely to represent a variety of poorly differentiated tumors in which no other evident line of differentiation can be recognized. MFH-like sarcomas still represent the most common STS type in adults. These tumors are heterogenous in appearance and cellularity with extensive pleomorphism and rounded histiocyte-like cells. A storiform growth pattern and inflammatory cells within the tumor stroma are commonly observed.
- b. Leiomyosarcoma shows cells with smooth muscle features and accounts for 10–15% of STS, albeit for a larger proportion of the retroperitoneal sarcomas. The cells are orderly arranged with intersecting fascicles and show an eosinophilic cytoplasm and cigar-shaped elongated nuclei.
- c. Synovial sarcoma is both clinically, morphologically, and genetically distinct. Its origin is unknown and it has no relation to synovium. The tumors are divided into biphasic (with epithelial and spindle cell components), monophasic (with fascicles and sheets of uniform cells), and poorly differentiated. Synovial sarcomas account for 5–10% of STS. The tumors predominantly occur at younger age; 90% develop before age 50. Genetically, these tumors are characterized by the specific  $t(X;18)$ , which is found in more than 90% of the tumors, and which fuses *SS18* on chromosome 18 to *SSX1*, *SSX2* or *SSX4* on the X chromosome.
- d. Pleomorphic liposarcoma is a pleomorphic high-grade sarcoma with a variable number of pleomorphic lipoblasts. Other lines of differentiation are not found within this subtype, which accounts for 20% of pleomorphic STS.
- e. Myxoid liposarcoma is a tumor with round-oval mesenchymal cells and small signet-ring cell lipoblasts within a myxoid stroma. It accounts for one-third of liposarcomas or 10% of all STS. Genetically it is characterized by the specific  $t(12;16)$  that fuses *CHOP* (also called *DDIT3*) to *FUS* (also called *TLS*). *EWS* on chromosome 22 has also been demonstrated to be involved in a rare variant.

are, however, STS subtypes, e.g. clear cell sarcoma and epithelioid sarcoma, that do not show any similarities to normal tissue. In addition, a great proportion of STS are high-grade and poorly differentiated, which further complicates classification. About three-fourths of STS are histologically classified as high-grade sarcoma, with the most common subtypes being malignant fibrous histiocytoma (MFH)/undifferentiated pleomorphic sarcoma (UPS), leiomyosarcoma, liposarcoma, syno-

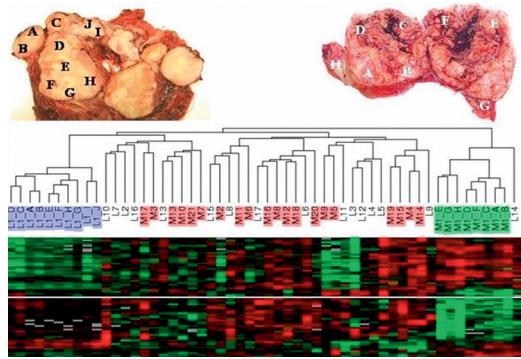




vial sarcoma and malignant peripheral nerve sheath tumors (MPNST) [62]. The incidence of different histologic subtypes varies with age with synovial sarcoma occurring also in young adults, whereas liposarcoma, leiomyosarcoma and MFH/UPS dominate in older patients [62]. The histopathological classification of the different subtypes of STS is difficult and subject to review and reclassification based on novel diagnostic subgroups, refined analyses using e.g. immunostaining, and identification of type-specific genetic alterations. Categorization of STS has thereby varied; during the 1980s about 50% of STS were diagnosed as MFH, whereas this subtype today is regarded a diagnosis of exclusion. Many of the STS previously diagnosed as MFH are now classified as myxofibrosarcomas, leiomyosarcomas and liposarcomas, and the others, unclassifiable tumors, are called UPS [59, 60, 62, 168]. Indeed, some investigators claim that UPS represent less than 5% of all STS [196]. The specificity of some of the genetic alterations may also affect the histopathologic diagnosis; a pleomorphic, undifferentiated STS carrying the  $t(X;18)$  would be classified as a synovial sarcoma. This refined classification may contribute to further advancements of targeted molecular therapies, the application of which will require detailed knowledge about the underlying biological alterations and a reproducible histotype classification.

## Tumor heterogeneity

Pleomorphic STS are typically large and often display great intratumor variations in macroscopic appearance. Also microscopically, these tumors reveal pronounced morphological heterogeneity with pleomorphism and intratumor variations in e.g. differentiation and proliferation. Engellau *et al.* assessed immunohistochemical heterogeneity for Ki-67 staining in pleomorphic STS. The results showed a median standard deviation of 2.5% between different tumor blocks from the same STS compared to 2.3% within a single tumor block, and based on this suggested that more than one tumor block should optimally be studied, in order to min-



**Figure 2.** Macroscopic pictures of one leiomyosarcoma and one pleomorphic myxofibrosarcoma from which multiple tumor pieces were obtained and analyzed together with 16 leiomyosarcomas and 20 malignant fibrous histiocytomas from which only a single piece was taken. In the hierarchical cluster analysis the pieces from the two multiple-piece tumors clustered together and also in relation to their location within the tumor. When the multiple pieces from the same tumors were compared to the single-piece leiomyosarcomas and malignant fibrous histiocytomas the mean variability was lower within a tumor than between tumors, but the maximal intratumor variability could indeed be larger than the minimal inter-tumor variability [65].

imize the influence of intratumor heterogeneity [53]. Morphologic heterogeneity in STS has also been studied in relation to S-phase fraction and in this context, pronounced intratumor heterogeneity has been demonstrated [95]. Since proliferation, most commonly assessed using immunostaining for Ki-67, may have a clinical prognostic impact, its reproducibility is central. Because of lack of standardized recommendations, we assessed the intratumor variability of Ki-67 expression in leiomyosarcomas in study IV.

Cytogenetic variability with intratumor heterogeneity and clonal evolution has also been demonstrated in STS, including MFH, leiomyosarcoma, liposarcoma, synovial sarcoma, and chondrosarcoma [154-157]. These studies suggest that partly different karyotypes are found in different tumor areas in three quarters of the STS subtypes, albeit most often in the form of related clones [157]. Francis *et al.* evaluated intratumor *versus* inter-tumor heterogeneity using multiple pieces from 2 MFH/myxofibrosarcomas. The multiple pieces from the 2 tumors clustered together (figure 2)

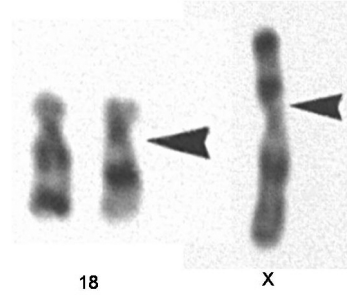
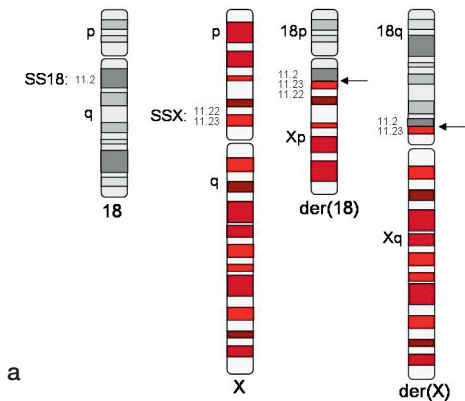
and also according to their original location within the tumor, which is in line with the cytogenetic observations of clonal evolution and genetic heterogeneity in STS [65]. These results suggest that expression profiling for diagnostic and prognostic purposes can reliably be performed from single tumor samples in STS, but intratumor heterogeneity may have a large impact on the results in small tumor series and may thereby limit the validity of the findings. This thus serves as a reminder to run large sample sets in order to reduce the impact of experimental and tumor-related heterogeneity to provide reproducible expression patterns.

## Cytogenetics

Currently, 1,169 of the 45,472 (2.6%) entries in the Mitelman database on chromosome alterations in cancer refer to STS, which reflects a vast cytogenetic knowledge about these rare tumors (<http://cgap.nci.nih.gov/Chromosomes/Mitelman>). Broadly, STS can, based on the genetic alterations, be divided into 2 major groups with complex and simple karyotypes, respectively [18, 84]. The majority of high-grade, often pleomorphic STS are characterized by highly complex, unbalanced karyotypes with multiple gains and losses and non-specific genetic alterations. About 1/3 of STS are characterized by simple karyotypes, often with recurrent, characteristic chromosomal rearrangements that are specific to the histological subtype and used in the diagnosis of these STS subtypes [18, 61, 190]. Current data suggest that such gene fusions are present in 20% of soft tissue tumors [135]. Several ancillary techniques have been developed to detect these chromosomal translocations and their respective chimeric genes, and thus facilitate the diagnosis of these tumors. The traditional method for demonstrating translocations is karyotyping of cultured tumor cells. Spectral karyotyping or fluorescence *in situ* hybridization (FISH) are sometimes used to characterize complex alterations or used for the validation of a specific gene fusion. The first chromosomal translocation characterized in STS was the t(11;22) fusing

the *EWS* and the *FLII* genes in more than 80% of Ewing sarcoma [200]. The *EWS* gene has then been shown to be involved in the t(12;22) found in more than 75% of clear cell sarcomas where it fuses to the *ATF1* gene [70], in the t(9;22) in extraskeletal myxoid chondrosarcoma with the *CHN* gene [22] and in the t(11;22) present in more than 75% of desmoplastic small round cell tumors where it is fused to the *WT1* gene [67]. The t(12;16) in which the *FUS* (also called *TLS*) gene on chromosome 16 fuses to the *CHOP* gene on chromosome 12 is the cytogenetic hallmark of myxoid liposarcoma and occur in more than 90% of these tumors. However, in about 5% of myxoid liposarcomas the *EWS* gene is involved in an alternative rearrangement with *CHOP* within the t(12;22) [128, 158, 202]. Other type-specific translocations in STS include the t(2;13) present in more than 75% of alveolar rhabdomyosarcomas, in which *PAX3* fuses to *FKHR* [183], the t(X;17) in more than 90% of alveolar soft part sarcomas, forming the *ASPL-TFE3* fusion [97], and the characteristic ring chromosome containing *COL1A1* and *PDGFB* in more than 75% of dermatofibrosarcoma protuberans [138, 160].

The t(X;18) or variants thereof are found in about 90% of synovial sarcoma and are suggested to represent the underlying cause of tumorigenesis, but secondary alterations including both numerical changes and unbalanced structural alterations are present in about 1/3 of the tumors and occur at increased frequency in recurrent and metastatic synovial sarcoma [122, 177, 201]. The t(X;18) fuses the 396 N-terminal amino acids of the *SS18* gene on chromosome 18 to the 78 C-terminal amino acids of one of the highly homologous *SSX* family genes [28, 38, 39] (figure 3). This translocation is specific to synovial sarcoma and has not been reported in other cancer types [45, 201]. The resulting chimeric fusion protein contains both transcriptional activating (from the *SS18* gene) and repressing (from the *SSX* genes) domains [45, 110] and is believed to control gene expression by association with chromatin remodelling. The SS18 protein is associated with the SWI/SNF complex and interacts directly with the epigenetic chromatin remodelling system, whereas the *SSX* proteins are associated with the



**Figure 3.** Schematic figure of the synovial sarcoma specific *SS18/SSX* translocation (a) and karyogram of chromosome 18 and X with arrows indicating the breakpoints (b).

polycomb complex [101, 161, 194]. Recently, the *SS18-SSX2* fusion protein also has been suggested to induce downstream target gene deregulation through epigenetic mechanisms [37]. A correlation between gene fusion type and clinical behaviour has been reported in synovial sarcoma; *SS18-SSX2* has been suggested to represent a favorable prognostic factor, whereas the *SS18-SSX1* fusion has been shown to correlate with shorter metastasis-free survival and a higher proliferation rate [102, 145]. However, the prognostic importance has been disputed and fusion type is not applied in clinical prognostication [72, 111].

Several of the above mentioned chromosomal translocations encompass transcription factor genes, and aberrant transcriptional regulation is thought to be a central mechanism in the development of STS. Fusion proteins like the *SS18-SSX* in synovial sarcoma, the *TLS-CHOP* in liposarcoma and the *EWS-ATF1* in clear cell sarcoma represent potential targets for tumor specific therapy because of their central involvement in tumorigenesis. However, in-depth characterization of these fusion genes and their downstream targets is needed in order to identify novel therapeutic targets [136]. The success of such approaches can be exemplified by gastrointestinal stromal tumors (GIST). Most GIST feature mutant *KIT* or *PDGFR* oncogenes and the mutations also correlate to prognosis and response to imatinib. Imatinib is a tyrosine kinase inhibitor with activity against *PDGFR* $\alpha$  and *PDGFR* $\beta$ , *KIT* and the Bcr-Abl fusion tyrosine

kinase [23, 46, 176]. *KIT* is expressed in about 90% of GISTs through a gain of function mutation and is highly specific to this tumor type. This discovery has significantly improved survival and quality of life for these patients [176].

## Molecular pathways

The first identified human tumor suppressor gene was the retinoblastoma (*RB1*) gene, which among others has been shown to be particularly important in STS. The *RB1* gene is a central cell cycle regulator and alterations of the gene itself or its pathway leads to abnormal cell proliferation [34]. A mutation in the *RB1* gene is inherited in the retinoblastoma syndrome, but also sporadic mutations and alterations of the *RB1* pathway have been shown to cause various sporadic tumors including osteosarcomas and STS [29, 41]. Studies have shown recurrent homozygous deletions of the region of chromosome 13 harbouring the *RB1* gene in mixed series of STS (Francis *et al.*, unpublished data) [29]. Also, alterations of the p53 pathway have been shown to be a central feature of STS with complex karyotypes including inactivation through *TP53* point mutations, homozygous deletion of *CDKN2A*, and *MDM2* amplification [18, 212]. In contrast, the prevalence of alterations of this pathway among STS with specific genetic alterations is relatively low, but has, when present, been suggested to correlate with poor prognosis [7,

8]. Whether alterations of the p53 pathway occur during the early stages of tumorigenesis or whether additional cooperating mutations are required is not yet known. Other tumor suppressor genes that are particularly important in STS include *CDKN2A* [153] and the *NF1* gene associated with neurofibromatosis type 1 [169].

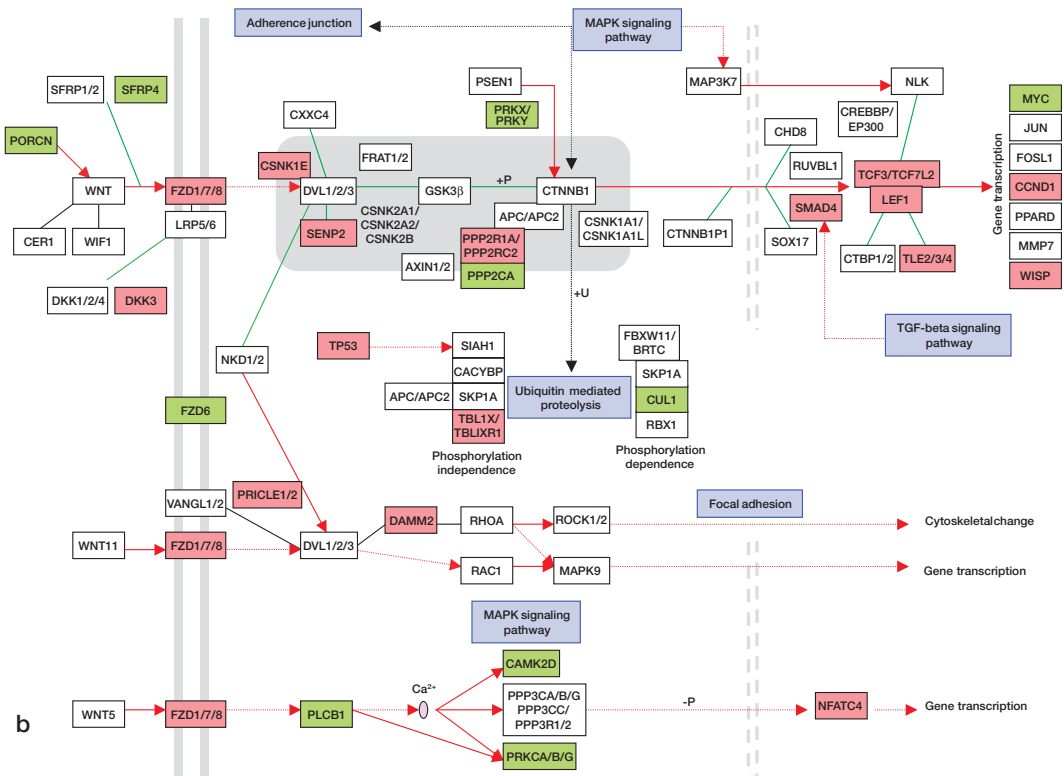
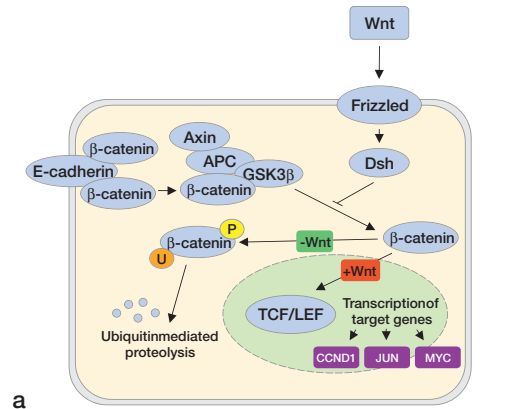
Oncogenes that have been implicated in the development of STS include *MDM2*, *MYC* and *HER-2/neu* and *RAS*-family members, and amplifications of these genes have been shown to correlate with an adverse outcome in STS patients [118]. Overexpression of *MDM2* promotes cell survival and leads to deregulated cell proliferation, and amplification of *MDM2* has been shown to be a particularly important mechanism leading to *TP53* inactivation in STS. The *MYC* oncogene is involved in cell cycle progression, apoptosis and cellular transformation, and has when amplified been suggested to play an important role in the development of certain STS [13], as well as being associated with poor prognosis in these patients [12]. Additionally, *MYC* represents one of the target genes of the Wntless (Wnt) signaling transduction pathway, which has been shown to be highly activated in synovial sarcoma [117, 143, 179]. Activating mutations of the *RAS* genes are among the most common genetic changes identified in human cancers and have also been reported in various STS subtypes, including MFH, liposarcomas [217], and leiomyosarcomas [86]. In most GIST, and also in some cases of Ewing sarcoma, the KIT receptor pathway has been shown to be activated either through activating mutations of *KIT* itself or *PDGFRA*, both leading to similar downstream activation of both *AKT* and *MAPK*. As mentioned previously, KIT is a tyrosine kinase receptor that successfully can be inhibited by the tyrosine kinase inhibitor imatinib [136].

Several studies have reported the application of high-throughput gene expression profiling in STS. Although individual gene lists differ in the various studies, consistent diagnostic expression signatures with upregulation of specific pathways have been identified in STS subtypes with simple genetic alterations e.g. synovial sarcoma, clear

cell sarcoma, GIST, and MPNST [3, 4, 10, 139, 179, 180]. More extensive genetic variation has been found among other more complex subtypes such as MFH/UPS, pleomorphic liposarcoma, and leiomyosarcoma [143, 179, 188]. From a diagnostic perspective, STS subtypes that cluster with distinct genetic profiles can be correctly classified using conventional cytogenetic methods and in most cases also with light microscopy. The expression data have, however, revealed novel genes and pathways including multiple downstream targets of the resultant chimeric transcription factors, which provide information about potentially differential diagnostic markers and serve as a basis for the understanding of key biological changes in STS development. In synovial sarcomas, gene expression profiling studies have revealed distinct and homogenous expression profiles that enable clear distinction of these tumors from other STS subtypes [3, 117, 139, 143, 179, 188]. The overexpressed genes have included members of the retinoic acid receptor pathway (RAR), the Wnt (figure 4) and the tumor growth factor receptor  $\beta$  (TGF- $\beta$ ) pathways, ephrins, genes related to the fibroblast growth factor (FGF) and the insulin growth factor (IGF) pathways, *CRABP1*, and the *SSX* genes [3, 117, 139, 143, 179]. Gene expression studies have also suggested a close relationship between synovial sarcomas and MPNST with upregulation of genes involved in neuroectodermal differentiation, which may suggest a neural crest origin of synovial sarcoma [3, 139]. Synovial sarcoma would be a good candidate for development of a new targeted therapy; the tumor type has a distinct underlying molecular biology with the SS18-SSX fusion protein, and several studies have shown that genes included in developmental pathways such as the Epidermal growth factor (EGF) and FGF receptor signaling pathways, the Hedgehog (Hh) and Notch signaling pathways, that could be possible targets for therapy, are highly overexpressed [3]. Moreover, synovial sarcoma have a high risk of metastatic development. In GIST, one of the strongest upregulated and discriminating genes, *KIT* has been shown to be both a genetic and a therapeutic target used in treatment of these patients.



**Figure 4.** Overview of the Wnt signal transduction pathway. The Wnt signaling pathway regulates several developmental processes, can lead to cancer formation and has been shown to be highly upregulated in synovial sarcomas. Wnt belongs to a family of glycoproteins that binds to frizzled transmembrane receptors inducing a signaling cascade that suppresses the activity of GSK-3 $\beta$  and thereby inhibits degradation of  $\beta$ -catenin causing accumulation of  $\beta$ -catenin in the cytoplasm and the nucleus. Once accumulated,  $\beta$ -catenin transmits Wnt signals to the nucleus through interaction with TCF/LEF transcription factors inducing transcription of certain target genes i.e. Cyclin-D1, *JUN* and *MYC* (a). In synovial sarcomas, upregulation of genes within red boxes, e.g. frizzled (*FZD1/7/8*), *LEF1* and cyclin-D1 is seen, whereas genes within green boxes have been shown to be down-regulated in synovial sarcomas when compared to other STS (b).



Studies that have applied conventional comparative genomic hybridization (CGH) as well as array-based CGH (aCGH) to soft tissue tumors have revealed recurrent alterations, including amplifications and deletions, and similarities between poorly

differentiated STS such as MFH/UPS, leiomyosarcomas and pleomorphic liposarcomas [25, 43, 112, 120, 152, 174, 210]. Specific chromosomal break-points in different high-grade STS have also been shown to correlate with adverse outcome in these

patients [27, 133, 134]. A 19p+ marker has been suggested to be associated with development of local recurrences and distant metastases in MFH [27], and gains of 1p31 and 7q32 have been associated with unfavorable prognosis in MFH [113]. Gains of 17q have been suggested to be associated with improved outcome with a lower risk of metastases in MFH patients [209], and a recent study has suggested a higher risk of metastases in STS patients with breakpoints in 1p1, and gain of 6p1 [134].

## Clinical presentation

Most STS of the extremities and the trunk wall present as a painless mass, often accidentally detected. The size at presentation is related to tumor depth and location with larger tumors (10–20 cm) in the deep proximal parts of the extremities and smaller tumors in superficial distal parts. Despite considerable tumor size, the general health of the patients usually remains good and because of the rarity of these malignancies they are commonly misinterpreted as benign conditions. STS are also vastly outnumbered by their benign counterparts – lipomas, fibrohistiocytic tumors, fibrous tumors, vascular tumors and peripheral nerve sheath tumors – at least by a factor of 100 [171, 172]. Suspicion of malignancy is important in soft tissue tumors since patients should optimally be referred before any surgery to a sarcoma center for centralized, multidisciplinary management. Based on epidemiological data, simple guidelines for referral have been established in Scandinavia. These guidelines suggest referring patients with deep-seated tumors irrespective of tumor size, superficial tumors larger than 5 cm and tumors otherwise suspected of malignancy (e.g. in children) based on 99% of benign soft tissue tumors being superficial and 95% being <5 cm in size [137, 171, 172]. Hereby, 1 in 10 tumors referred has been shown to be malignant and the vast majority of STS patients can undergo their primary STS treatment at a sarcoma center [15, 171]. This favorable referral pattern is unique for Scandinavia.

## Imaging

MRI is the imaging modality most frequently used for preoperative evaluation and surgical planning of soft tissue tumors [79, 106, 207]. MRI scans are mainly used to define the anatomical extension of the tumor, but are also used for guiding biopsies. Except for lipomas that show homogenous signals from their fat content, MRI can not be used for type-specific diagnostics. After treatment, MRI scans are used in monitoring local tumor changes, especially to evaluate the effects of preoperative chemotherapy and radiotherapy, and also for diagnosis of local recurrences. Dynamic, contrast-enhanced MRI has also been suggested to differentiate viable from non-viable (necrotic or avascular) tumors [182]. Hence, MRI could potentially provide preoperative prognostic information, which was tested in study V.

## Diagnostics

Fine needle aspiration (FNA) cytology is a simple and effective diagnostic method with minor risks of complications, such as local contamination of tumor cells, compared to an open biopsy. Despite limited sampling, FNA can correctly identify the sarcoma subtype in 75–95% of the cases and correctly determines malignancy grade (low/high) in 2/3 of the tumors [40, 44]. However, considerable experience is required in order to make a correct FNA-based diagnosis, and the results should be interpreted in conjunction with the findings from clinical examination and imaging. Core-needle biopsies are increasingly used since these allow morphological analysis and the harvest of more tumor tissue makes it easier to use ancillary techniques, e.g. cytogenetics or molecular genetics. The technique is safe and complications occur in less than 1% of the patients [47]. Open biopsy for precise diagnosis of histotype and grade is rarely (5–10% of the cases) used in Scandinavia since a diagnosis of “sarcoma” in most cases is sufficient for planning and performing surgery [35]. However, if use of preoperative chemotherapy or radio-

therapy is considered, needle/core biopsy may not be sufficient for treatment decision.

## Surgery

Surgery is the mainstay treatment in STS. Until the beginning of the 1980s the standard treatment for extremity STS was radical compartmental excisions, often as an amputation, in order to achieve local control [170]. However, when a multidisciplinary treatment approach was adopted, the rate of local recurrence could be held low without amputation, and consequently amputation rates have dropped drastically to about 5% [20, 170]. Surgical treatment of STS entails a fine balance between minimizing the risk of local tumor recurrence and preserving function. The type of surgical resection is determined by the anatomical location of the tumor, the involvement of nearby structures, the tumor size and depth, and the performance status of the patient. A STS should preferably be removed by a wide excision, which means an *en block* resection of the tumor mass including surrounding tissue. A marginal excision implies that part or all of the tumor (shelling out) is not surrounded by healthy tissue. An intralesional tumor resection removes only parts of the tumor with nearly a 100% risk for local tumor recurrence [56]. Despite improvements in local control, 10–20% of the tumors recur locally, but can in most cases still be controlled (except in retroperitoneal sarcoma). The prognostic impact of a local recurrence is controversial; whereas no increased risk of metastasis has been reported in some studies [78, 170, 192, 204], other investigators have demonstrated that a local recurrence *per se* is a risk factor for metastasis [119, 199], most likely because it signifies a highly aggressive tumor.

## Radiotherapy

To minimize the risk of local recurrence, surgery is often combined with postoperative radiotherapy, especially in deep-seated, high-grade tumors [163,

198, 215, 219]. Radiotherapy doses of 50–60 Gy with daily 2 Gy fractions are generally recommended, but for macroscopic residual tumors doses of >60 Gy are recommended [103, 219]. Radiotherapy can also be given preoperatively which allows lower doses [211] and smaller field sizes [141]. However, the benefit hereof is uncertain, but preoperative treatment is likely to give less long term side-effects, such as fibrosis and edema, because of a smaller remaining volume, but is also associated with an increased risk of postoperative wound complications [150]. Hence, decisions on radiotherapy should ideally take all of these factors, including the timing of surgery and radiotherapy, the size and anatomical site of the tumor as well as possible benefits and complications, into account, in order to maximize local tumor control with preserved function.

## Chemotherapy

Development of distant metastases remains a significant problem with high mortality [195]. Use of chemotherapy plays a major role in bone sarcoma, i.e. in osteosarcoma and Ewing sarcoma, where it has drastically improved 5-year survival from <10% with surgery alone to 60–70% when systemic chemotherapy is added. The value of systemic chemotherapy for most histological subtypes in adult STS patients remains controversial, except for rhabdomyosarcoma, particularly in younger patients. Decisions on systemic therapy depend on the estimated risk of adverse toxic effects in relation to the possible benefits of the treatment. The most commonly used regimens in patients with advanced STS are ifosfamide and doxorubicin [189] and even if both of these agents have been shown to be effective to some extent, the response rates are low, ranging from 20–50%, and the prognosis remains poor [5, 50, 58, 116, 178, 205, 208]. Hence, the value of adjuvant chemotherapy is debated, although several phase II trials and a recent US-based review have indicated a benefit [35]. Currently, patients with high-risk STS treated within the European organisation for research and

treatment of cancer (EORTC) are randomized to adjuvant therapy with a single agent doxorubicin versus doxorubicin in combination with ifosfamide (<http://www.sarkome.de/eortc/>). Both preoperative chemotherapy [71] and radiotherapy are used at many centers as part of a treatment plan for patients with primary STS [109]. The possible benefits of preoperative chemo-radiotherapy include early treatment of subclinical tumor spread and assessment of response, but its importance on survival in STS patients remains unknown.

The current treatment policy within the Scandinavian Sarcoma Group (SSG) includes adjuvant therapy for adult high-risk patients, below age 70–75 years, whose tumors display 2 of the 3 prognostic factors; large size (>8 cm), macroscopic and/or microscopic tumor necrosis, and vascular invasion [74, 75]. Recently, peripheral tumor growth pattern has been shown to correlate with prognosis and is therefore now added to the high-risk criteria [54]. The planned phase II trial, SSGXX, within the SSG classifies patients as high risk when the STS is histologically high-grade with either vascular invasion or 2 of the 3 factors; tumor necrosis, tumor size >8 cm and infiltrative tumor growth pattern. Patients whose tumors display such high-risk characteristics are treated with 6 cycles of doxorubicin and ifosfamide, and in all cases with deep-seated tumors radiotherapy is added.

## Targeted therapy

The treatment of STS most probably needs to take the specific STS subtype and its genetic/biological alterations into account. One of the challenges that remain is to identify the target genes that are deregulated by the specific fusion proteins and those associated with the subtypes characterized by complex karyotypes. Malignancies driven by a single genetic alteration such as a mutation or translocation provide the optimal model for advancements in the progress of targeted therapeutics. The prime example hereof is the development of imatinib in the treatment of GIST which drastically has improved outcome in these patients [42, 176].

Inherent difficulties in applying targeted therapies in STS may be that the tumor-type specific fusion proteins are not readily reached using e.g. surface antibodies. Tyrosine kinase inhibitors may also be preferable since several tyrosine kinases are deregulated in STS [203], i.e. KIT and the PDGF $\beta$  receptor in GIST [206]. Another example of a possible tyrosine kinase inhibitor target is dermatofibrosarcoma protuberans which is characterized by fusion of the *COL1A1* and the *PDGFB* genes leading to excess production of mature PDGF $\beta$  that stimulates growth through the PDGF receptor [186]. Successful growth inhibition of dermatofibrosarcoma protuberans tumors in mice and cell cultures has been demonstrated after treatment by a tyrosine kinase inhibitor targeting the PDGF receptor [187]. Ongoing phase II studies also evaluate imatinib in dermatofibrosarcoma protuberans [2]. Currently, there are several ongoing phase II studies evaluating the effect of multiple other approaches, including inhibition of angiogenesis and targeting of specific or multiple pathways using tyrosine kinase inhibitors in different STS including GIST, dermatofibrosarcoma, MPNST, and synovial sarcoma [11, 100, 136, 184].

Many other types of targeted therapies based on preclinical data and current gene expression data can be considered. The therapeutic role of antiangiogenic treatment in STS remains to be clarified since these large soft tissue tumors often show high interstitial pressure and hypoxia. Interestingly, hypoxia-related genes were among those signifying metastases in the gene expression profiling study on mixed STS performed by Francis *et al.* [66]. Multiple angiogenic inhibitors exist, but among those that could be further evaluated are the VEGF antibody bevacuzumab and the decoy receptor VEGF-trap. Recently, multityrosine kinase inhibitors inhibiting RAF, VEGFR, PDGFR and FLT3 have proven effective in renal cell cancer and are now being evaluated in STS. Also EGFR and ERBB/HER2, against which monoclonal antibodies as well as tyrosine kinase inhibitors have been developed, have been demonstrated to be overexpressed in STS. The PI3K pathway represents another interesting target

for therapeutic interventions in STS and mTOR inhibitors are thus among the agents that could be considered. Matrix metalloproteinases (MMP) and chromatin modifiers are among the proteins identified in gene expression studies of STS [66] and targeting of these using MMP inhibitors and histone deacetylase inhibitors (HDAC) could also be considered. In summary, there are interesting biological links between STS and several types of targeted therapies and novel clinical studies are therefore awaited within collaborative efforts because of the rarity of this tumor entity. Current knowledge, however, also suggests that identification of distinct diagnostic subsets in which deregulation of the molecule targeted can reproducibly be demonstrated, will be crucial for successfully developing targeted therapies in STS.

### Prognostic factors and prognostic systems

The overall 5-year survival of STS patients, including all malignancy grades, is 50–60% [136]. Metastases at diagnosis are found in less than 10% of the patients and among those who go on to develop metastases, 80% will be diagnosed within 2–3 years after treatment of the primary tumor [62, 74]. STS is a heterogenous group of tumors also when it comes to prognostic factors. Histologic malignancy grade is a major prognostic factor for development of metastasis [32, 74, 191, 220]. Malignancy grading is in part subjective and several grading systems based on different parameters are in use. Its impact also differs between different subtypes, e.g. malignancy grade does not seem to have a prognostic role in MPNST, clear cell sarcoma, and epithelioid sarcoma [32]. The two most widely used malignancy grading systems are the FNCLCC (French Fédération Nationale des Centres de Lutte Contre le Cancer) and the NCI (United States National Cancer Institute) systems [32, 33, 36, 73]. Both are based on III-tiered scales taking several histologic parameters such as mitotic rate, differentiation, pleomorphism, cellularity, necrosis, and histological type into account [32]. In Scandinavia, a IV-tiered histologic malignancy grade system based

on mitotic rate, cellularity, pleomorphism, nuclear atypia, and tumor necrosis is used [131].

Besides malignancy grade, tumor size is the most important prognostic factor in STS [31, 54, 74, 220]. Many studies have used dichotomization at different sizes [75] (the most commonly used being 5 cm), whereas others have applied a step-wise scale [31, 52, 166]. Necrosis is another strong prognostic factor for metastasis that is taken into account in most grading systems [54, 73]. However, there is a lack of consensus as to how this parameter should be evaluated and different cut-off levels have been applied [54, 220].

Microscopic intratumoral vascular invasion is also a validated, and strong prognostic factor in STS [54, 75]. Recently, Engellau *et al.* demonstrated that invasive peripheral tumor growth pattern is an independent prognostic factor and these data have recently also been validated in an independent tumor series (unpublished observations) [54]. However, neither vascular invasion nor peripheral tumor growth pattern is yet incorporated into commonly used prognostic systems [131], although vascular invasion has been included in the Size-Invasion-Necrosis (SIN) system [75], and tumor growth pattern has recently been added to the high risk criteria applied in Scandinavia [54]. Proliferation is another factor that has repeatedly been shown to represent a prognostic marker in sarcoma and is considered for inclusion in clinical prognostic systems [52, 83, 88, 94, 96, 144]. Various studies have applied mitotic rate, S-phase fraction, and immunohistochemical analysis of markers such as Ki-67, proliferating cell nuclear antigen (PCNA), and cyclin A as measures of proliferation [76, 93, 94, 96, 146]. However, Ki-67 remains the most thoroughly investigated marker and has repeatedly demonstrated a prognostic value in STS. There is, however, a lack of standardized evaluation hereof. We therefore assessed intratumor variability of Ki-67 expression in study IV. In conclusion, prognostic systems in STS are still in need of refinement with consensus regarding which parameters should be used, how they should be defined, and which cut-off levels should be applied.

# Materials

All patients included in the studies were diagnosed with a STS of the extremities or the trunk wall in the Southern Sweden Health Care Region (9 tumors from the Karolinska Hospital, Stockholm, were included in study III) between 1964 and 2006. The patient and tumor materials for the different studies are summarized in table 4. As part of clinical routine, the surgical specimen was brought fresh to the department of pathology, where representative tissue was selected and frozen at  $-80^{\circ}\text{C}$ . Frozen tumor tissue was used for DNA/RNA extractions in studies II and III, and formalin-fixed paraffin-embedded tumor tissue was used in studies II, IV, and V. Patient, treatment and outcome data are available from the Southern Sweden part of the National Cancer Registry, within the SSG registry, and within a clinical treatment registry (based on the Cancer Registry) at the Department of Orthopedics, Lund University Hospital. Ethical permission for the studies was granted from the Lund University ethics committee (LU 302-02) and all work was performed according to these ethical guidelines. All STS were diagnosed by sarcoma pathologists at the centers in Lund or in Stockholm and most of the tumors diagnosed after 1983 had also been reviewed by the SSG pathology review board [52, 74].

## Study I

All individuals in the Southern Swedish Health Care Region diagnosed with a primary STS of the extremities or trunk wall during 1964–2001 were included in the study. The patients were initially identified through the National Swedish Cancer Registry, and the inclusion was initiated in 1964 in order to compare data with the local sarcoma registry, which contained verified data on all cases. The National Swedish Cancer Registry is population-based and estimated to contain 99% of all malignant diagnoses. Since the focus of the study was STS of the extremities and the trunk wall, we excluded STS at other sites, e.g. head-neck, retroperitoneum, and urogenital sarcomas. Children (<16 years at diagnosis), syndrome-associated STS, dermal sarcomas, and radiation-induced STS were excluded. Hereafter, 818 individuals remained for analysis, 88 of whom had been treated with postoperative chemotherapy (study I, table 1). The Southern Sweden part of the Cancer Registry was used to identify all other primary malignancies that developed in this cohort. The histopathological reports regarding the other malignancies were collected from 169 cases, whereas data in 34 cases relied on information from the Cancer Registry. 23 patients had been treated with radiotherapy and these radiation fields were re-evaluated regarding

Table 4. Summary of materials in the different studies

Study	I	II	III	IV	V
Years of diagnosis	1964–2001	1988–2006	1986–1999	1989–2000	1989–2000
Number of patients/tumors	818/818	13/30	24/26	25/25	78/78
Histologic diagnoses	mixed	mixed	synovial sarcoma	leiomyosarcoma	mixed
Median age (range)	66 (16–98)	77 (28–83)	44 (11–84)	68 (40–92)	68 (23–87)
Men:women	440:378	6:7	15:11	17:8	36:42
Malignancy grades <sup>a</sup>	129 I-II; 689 III-IV	2 II; 28 III-IV	all III-IV	all III-IV	12 I-II; 66 III-IV
<sup>a</sup> Based on a 4-tiered scale					



overlap with secondary tumors and 1 presumable radiation-induced skin cancer was excluded. STS that developed at another anatomical site before the development of any metastases were regarded as multiple primary STS, whereas STS that developed at the same location as the primary tumor or in patients with known metastases were regarded as local recurrences or metastases, respectively, and were thus not included in the analysis [6].

### *Study II*

Individuals in study I who had developed 2 or more STS at different anatomical sites before the development of any detectable metastases were included in study II, which was further extended with all adult patients ( $\geq 16$  years of age) in the Southern Swedish Health Care Region who developed multiple STS before any metastases. Hereby, we identified 20 patients who had developed at least 2 STS at different anatomical sites before the occurrence of metastases. Frozen tissue was available from 16 tumors, whereas paraffin-embedded material was used in the remaining 28 cases. 7 individuals were excluded because of poor DNA quality in at least 1 of the tumors. Hence, evaluable aCGH profiles were obtained from 30 tumors. These were derived from 13 patients with a mean age of 73 (28–83) years at the time of first STS diagnosis (study II, table 1). The second STS developed median 3 (1–7) years after the first STS. 2 different tumors were analyzed in 10 cases, 3 in 2, and 4 STS were analyzed in 1 patient. No neoadjuvant chemotherapy had been used, and only 1 patient was treated with postoperative chemotherapy after the first STS. Radiotherapy had been administered to 4 patients; postoperatively in 3 cases and preoperatively in 1, but none of the second primary STS developed within the irradiated field. Follow-up was complete for a minimum of 8 years for the survivors. During follow-up, lung metastases developed in 5/13 patients, median 50 (15–51) months after the primary tumor.

### *Study III*

In study III, 26 synovial sarcomas, including

19 primary tumors, 3 local recurrences, and 4 metastases were analyzed (study III, table I). All tumors had been cytogenetically characterized and confirmed to carry X;18 translocations, with the t(X;18) as the sole change in 5 tumors and as part of complex karyotypes including the t(X;18) in 17 tumors, whereas normal karyotypes were found in 4 tumors. 12 tumors had the *SS18-SSX1* gene fusion type, whereas 9 tumors were characterized by the *SS18-SSX2* gene fusion variant. Metastases developed in 18 patients, from 12 of whom the primary tumors were available for analysis. 3 of the patients had received pre-operative treatment; chemotherapy in 2 cases and radiotherapy in 1 case. Follow-up was complete and was minimum 9 years for the survivors.

### *Study IV*

In study IV, 25 leiomyosarcomas operated at the Lund University Hospital Musculoskeletal Tumor Center between 1989 and 2000 were included. High-grade (grades III and IV) tumors from which whole tumor sections were available were selected. The mean tumor size was 8 (3–16) cm. None of the patients had received preoperative radiotherapy or chemotherapy. Whole-tumor blocks, i.e. an approximately 1-cm thick section obtained from the largest tumor diameter, were retrieved and 1-mm core biopsies were obtained from the tumor diameter (study IV, figure 1). Median 8 (5–19) biopsies were obtained from the tumors and used to construct a tissue microarray (TMA).

### *Study V*

Patients were selected for study V based on availability of evaluable preoperative MRI scans and presence of whole-tumor sections for classification of the peripheral microscopical growth pattern. 78 adult patients with primary STS operated at the Musculoskeletal Tumor Center in Lund between 1989 and 2000 were included (study V, table 1). The tumors had been resected with a marginal or wide surgical margin and neoadjuvant chemotherapy or radiotherapy had not been administered. The 78 patients represent a subset of a series of 140 patients in whom the prognostic value of micro-

scopic infiltrative growth on whole-tumor sections previously has been reported [54]. 2/3 of the tumors were deep-seated, leiomyosarcoma was the most common histiotype, and 66/78 tumors were high-

grade (grades III and IV). None of the patients had metastases at diagnosis, but metastases developed during follow-up in 33/78 patients. Follow-up was complete for at least 5 years for the survivors.



## Methods

### **Risk assessment (study I)**

The risk of developing a second primary tumor after the STS was assessed by calculating Standardized Morbidity Ratios (SMR) by dividing the observed number of cancers with the expected number. This was performed for the whole cohort of 818 patients and for subgroups with respect to sex, age at STS diagnosis and after excluding the 77 individuals with another primary malignancy before the STS diagnosis (since death from these tumors could not be accounted for). The risk estimates were based on tumors that developed after the STS because of difficulties in compensating for death rates from prior malignancies. The cancer incidence within the Southern Swedish part of the Cancer Registry was used as a reference and the analysis was stratified by sex, calendar year, and 5-year age groups. The SMR and their 95% confidence intervals were calculated (study I, table 2).

### **DNA extraction (study II)**

In order to maximize the number of tumors analyzed, DNA was extracted both from frozen (when ever available) and from paraffin-embedded tissue. Genomic DNA was extracted from frozen tissue using the WizardR Genomic DNA Purification kit (Promega, Madison, WI) and overnight proteinase-K digestion treatment followed by phenol-chloroform purification as described in detail in study II. In tumors where DNA was extracted from paraffin-embedded tissue, a fresh 4- $\mu$ m section was first obtained, which was stained with hematoxylin & erythrosin for identification of representative tumor areas. Thereafter, a 1-mm tissue core was obtained and used for DNA extraction. The tissue cores were then pre-treated in xylene before proteinase-K treatment and phenol-chloroform purification. DNA concentration was measured using a

Nano drop (NanoDrop Technologies, Wilmington, DE) and DNA quality was checked using a Ready-To-Go RAPD analysis kit (Amersham Biosciences, Buckinghamshire, UK). Commercial genomic male DNA, derived from a pool of healthy individuals was used as a reference (Promega).

### **RNA extraction (study III)**

Total RNA was extracted from 80–120 mg of frozen tissue using the RNeasy Midi kit (Qiagen, Valencia, CA) and TRIzol reagent (Invitrogen, Carlsbad, CA) according to the manufacturer's instructions. The steps included: dismembration of the frozen tissue, thawing the tissue powder in TRIzol and extracting the RNA from DNA and proteins using Chloroform (Sigma, St Louis, USA) and centrifugation. The Agilent 2100 Bioanalyzer (Agilent technologies, Palo Alto, CA, US) was used to measure RNA quality requiring a 28S/18S ratio of >1.1, and concentration was checked using Nano drop (NanoDrop Technologies). As reference RNA the Stratagene Universal Human Reference RNA (Stratagene), composed of total RNA isolated from ten cell lines representing different human tissues with broad coverage, was used.

### **Array comparative genomic hybridization (study II)**

#### **BAC array platform**

The BAC array slides used in the studies were produced at the Swegene DNA Microarray Resource Center, Department of Oncology, Lund University. These contained totally 32,433 BAC clones from the 32k human genome high resolution BAC re-arrayed clone set, version 1.0 from the BACPAC Resource Center at Children's Hospital Oakland Research Institute (Oakland, CA, US) (<http://>

bacpac.chori.org/). The clones provide >99% coverage of the fingerprint map and current sequence assembly with a resolution of 100 kb.

### ***Labeling and hybridization***

CyDye coupling/labeling was carried out using a random labeling kit (Invitrogen Life Technologies) according to the manufacturer's recommendations. In short, 2 µg genomic tumor DNA and reference DNA were differentially labeled with fluorescent dyes; Cy3 for tumor tissue and Cy5 for reference DNA. After purification using filter based columns (the CyScribe GFX Purification Kit, Amersham Biosciences for fresh frozen tumor and the PureLink PCR Purification Kit, Invitrogen for paraffin-embedded tumors), the labeled DNA were pooled, mixed with COT-1 DNA to block repetitive DNA sequences, dehydrated and finally resuspended in a formamide-based buffer. The arrays were UV cross-linked at 500 mJ/cm<sup>2</sup> and hybridization was performed at 37°C for 72 hours. The incubation was performed under cover slips for the DNA isolated from the frozen tumor material whereas the MAUI hybridization system (Bio-Micro systems Inc., Salt Lake City, UT, US) was used for the DNA derived from paraffin-embedded tumors. Dye-swaps were used to minimize noise derived from the dyes wherever this was necessary. Scanning was performed using the Agilent microarray scanner (Agilent Technologies).

## **Expression microarray (*study III*)**

### ***cDNA microarray platform***

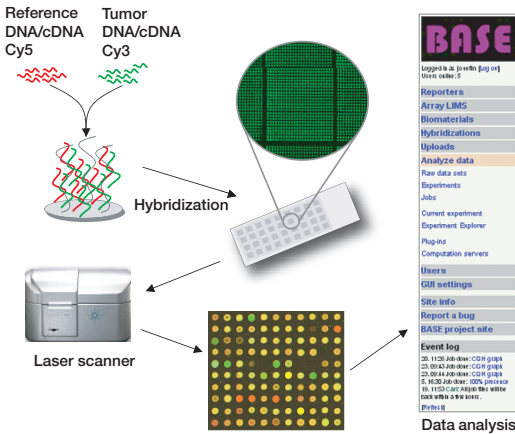
The cDNA microarrays and the BAC array slides used in the studies were produced at the Swegene DNA Microarray Resource Center, Department of Oncology, Lund University, Sweden. The cDNA microarrays were spotted with 27,648 spots containing sequence-verified IMAGE clones from the Research Genetics IMAGE clone library. Clone information was linked to gene names using build 164 of the Unigene database (<http://www.ncbi.nlm.nih.gov/UniGene>) and 17,517 unique Unigene clusters were represented on the array.

### ***cDNA synthesis, labeling, and hybridization***

cDNA synthesis and CyDye coupling was carried out using the CyScribe cDNA Post-labeling Kit (Amersham Biosciences) according to the manufacturer's recommendations. 35 µg tumor RNA and 25 µg reference RNA was annealed with Anchored oligo(dT) primer (from kit) and an extension reaction was performed catalyzed by the enzyme CyScript™ Reverse Transcriptase. During the reaction, amino allyl-dUTP (AA-dUTP) was incorporated into the cDNA. After degradation of remaining RNA templates through alkaline hydrolysis treatment (with NaOH), the amino allyl-modified first strand cDNA was purified, using ethanol precipitation, and coupled with an excess of reactive CyDye™ NHS-esters (Amersham Biosciences). The tumor and reference cDNA were coupled separately, tumor to Cy3 and reference to Cy5. In order to maximize hybridization signal and minimize non-specific background, the probes were purified using GFX purification columns (CyScribe GFX Purification Kit, Amersham Biosciences). The differentially labeled cDNA were then pooled and blocking reagents (human COT-1 DNA®, Poly dA and Yeast tRNA) were added in order to reduce non-specific hybridization. Hybridization was performed manually using the Pronto!™ Universal Hybridization Kit (Corning Life Sciences, Corning, NY, US) in 42°C for 18–20 hours, according to the manufacturer's instructions. The slides were then dried and scanned using the Agilent DNA Microarray Scanner (Agilent Technologies) (figure 5).

### ***Data analysis (*studies II and III*)***

The cDNA and BAC array slides were scanned using an Agilent DNA Microarray Scanner (Agilent Technologies) at 5 and 10 micron resolution respectively. Image analysis and data extraction were carried out using GenePix™ Pro 4.1.1.4 version (Axon Instruments Inc., Foster City, CA, US) and the quantified data matrix was then uploaded into the web-based BioArray Software Environment (BASE; <http://base.onk.lu.se/int/>) [173] where all data management and analysis were carried out. The background correction and intensities of Cy3



**Figure 5.** Overview of the steps within the aCGH and cDNA methods. Genomic tumor DNA/cDNA and reference DNA/cDNA are differentially labeled with fluorescent dyes; Cy3 and Cy5 respectively (cDNA is first synthesized from total RNA in a reverse transcriptase based reaction). After purification, pooling and blocking of repetitive sequences, the DNA/cDNA is applied to a spotted array and hybridized for 48–72 hours. The slides are washed to remove non-specific hybridization and scanned using an Agilent DNA microarray scanner, which creates two separate high-resolution images, one for each CyDye. These images are then overlaid and visualized as a pseudocolored image that is analyzed in GenePix Pro software. The raw data result files are finally uploaded into a data analysis software, such as BASE, for data-processing and analysis.

and Cy5 were calculated using the median feature and median local background intensities of the uploaded files, and the intensity ratios were calculated using the background corrected spot intensities by calculating the 2-logarithm of the ratio of tumor intensity to reference intensity.

A preliminary filtering, based on the flagging in the image analysis, was applied, and spots flagged as “bad” or had a spot diameter smaller than 55  $\mu\text{m}$  were filtered away from further analysis. In study II, all spots were required to have a signal to noise ratio  $>3$  in both the tumor and the reference channel. To normalize data within individual arrays, the intensity dependent LOWESS algorithm was used [216]. In study III, a weighted approach was adopted to account for varying spot qualities, which gradually reduces the importance of a spot as its quality goes down, essentially as has been described previously [24]. In study II,

a moving average smoothing algorithm with a 250 kbp sliding window was then applied, and to identify regions of gains and losses a BASE-adapted CGH-plotter software was used [9]. A region of gain/loss was defined as a  $\log_2$  ratio  $\pm 0.2$ . Amplifications were defined as clones with a  $\log_2$  ratio  $\geq 0.5$ , whereas high-level amplifications were defined as a  $\log_2$  ratio  $\geq 1.5$ . Homozygous deletions were suspected when the  $\log_2$  ratio was  $\leq -1.5$ . In order to reduce the noise, in the CGH-plotter each clone was assigned a calculated level  $\log_2$  ratio value, corresponding to the level that the clone belongs to. The data derived from the CGH-plotter was then used in a hierarchical cluster analysis (see below). The CGH-plotter was also used to generate a ternary scale, where all clones were designated gained, lost, or unchanged. These values were used to calculate the percentage of altered clones in each assay and the mean number of altered clones in tumor subgroups. A Pearson correlation estimate was used to determine the correlation between tumors within the same individual, based on altered clones.

In study III, a weighted approach was used to rank all genes based on their ability to discriminate between the different tumor subgroups. Each gene was assigned a discriminative weight, a Golub-score [68], by calculating the mean and the standard deviation of each particular gene across all of the samples (using the relative expression ratios of each gene in the subclasses). A genes weight then reflects the difference in expression of that gene between the groups relative to the standard deviation within the group and hence; a high Golub-score implicates minor variation in gene expression within the group, but large variation between the subgroups. In order to assess the discriminating power of the score to differentiate the groups, a random permutation test with 1,000 permutations was performed.

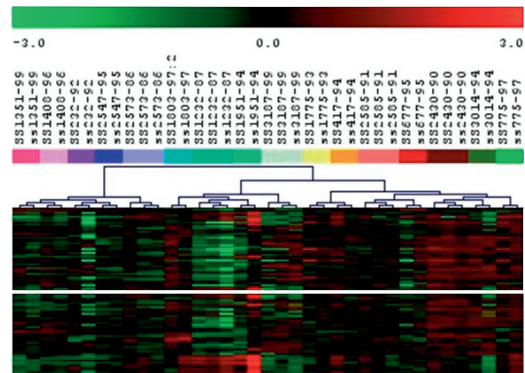
### *Hierarchical cluster analysis*

Unsupervised hierarchical cluster analysis, using the Pearson correlation distance metric and the average linkage method, was applied to the data derived from the CGH-plotter in study II and to all

~3,500 genes surviving the pre-processing filters in study III (the TMeV application from the TM<sub>4</sub> microarray software suite was used; <http://www.tm4.org/mev.html>) [175]. Hereby, a pair-wise comparison of the expression patterns across all genes and tumors was performed, that groups the groups the tumors and genes together, based on their similarities, into hierarchical trees [51]. The analysis also creates a “heat-map”, a two-dimensional plot that indicates expression levels of each gene in each tumor sample. In study III, a hierarchical cluster analysis was also applied to the genes with the best discriminating power (between tumors belonging to different biological supgroups; gene fusion types and metastatic potential) revealed in the weighted approach mentioned above, hence creating a supervised hierarchical cluster tree.

### Reproducibility

Numerous studies have demonstrated the usefulness of gene expression profiling techniques in the study of STS, and such applications have provided extended insight into the genetic complexity of these tumors [117, 142, 143, 179]. However, gene expression profiling allows analysis of thousands of genes simultaneously and the vast amount of information that is generated has to be interpreted in the correct context and validated by complementary techniques and/or other research groups. The complexity of the technique creates several challenges when it comes to experimental design, use of different platforms, technical implementation, management of and interpretation and validation of the data. Several studies that have applied gene expression analysis to STS have reported similar results and diagnostic subgroups have been confirmed [66, 117, 143, 179]. Additionally, useful diagnostic markers correctly identifying certain subgroups including e.g. GIST and synovial sarcoma have been provided through gene expression profiling studies. Also pathway signatures, such as the Wnt signaling pathway in synovial sarcoma have been a consistent finding in several studies [66, 117, 143, 179]. Hence, application of gene expression profiling in STS has confirmed previous findings from ancillary techniques, and has in

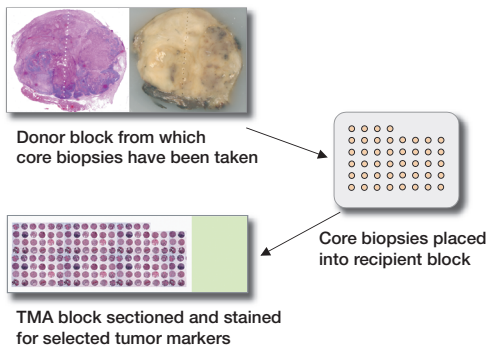


**Figure 6.** Cluster analysis showing tumor samples hybridized in duplicates and triplicates, with at least one year in between the experiments using two different protocols, on a hybe-station and manually. The duplicates and triplicates all clustered together. The analysis was performed using the TMeV application of the TM<sub>4</sub> microarray software suit [175] and the Pearson correlation distance metric was used.

addition vastly extended the knowledge and understanding about these genetically complex tumors. The majority of the tumors investigated in study III were hybridized in duplicates, and in some cases in triplicates. Different protocols were used, and about half of the tumors were hybridized manually whereas a hybridization-station was used in the remaining cases. Nevertheless, similar results were obtained with different protocols and when an unsupervised hierarchical cluster analysis was applied to the tumors, all duplicates and triplicates clustered closely together (figure 6).

### Tissue microarray (study IV)

TMA blocks were established from 1-mm diameter core biopsies obtained from throughout the tumor diameter using a manual arrayer (Beecher Instruments, Silver Spring, MD, US) (figure 7). Hereby, median 8 (5–19) biopsies were obtained from each of the 25 leiomyosarcomas. The 2 most peripheral core sections from each side of the tumor diameter (which corresponded to a fraction of 0.1–0.4 of the tumor diameter) were considered to represent the tumor periphery, whereas the central 1–3 biopsies



**Figure 7.** In study IV multiple 1-mm tissue cores were obtained throughout the tumor diameter from leiomyosarcomas. Hereafter a whole-tumor section was stained with hematoxylin & erythrosin in order to demonstrate from where the samples were obtained. The cores were brought into a TMA, which was sectioned and stained (with antibodies against Ki-67 and HIF-1 $\alpha$ ).

(depending on tumor size) were considered to represent the center.

### Immunohistochemical staining (study IV)

Fresh 5- $\mu$ m sections from the TMA blocks were mounted on glass slides (Dako ChemMate capillary gap microscope slides, Dako) and used for immunostaining. After deparaffinisation in xylene and rehydration in ethanol, the sections were microwave pre-treated in 10 mM citrate buffer (pH 6.0) to achieve antigen retrieval. Staining was performed using an automated immunostainer (TechMate 500Plus, Dako) with Dako ChemMate Kit peroxidase/3,3'-diaminobenzidine. The tumors were stained for the proliferation marker Ki-67 and the hypoxia marker, hypoxia inducible factor 1 $\alpha$  (HIF-1 $\alpha$ ). For Ki-67 the MIB-1 (Monoclonal Mouse antihuman Ki-67 antigen, Dako) antibody was used at 1:500 dilution and the percentage (<5, 10, 20, 30, 40, and >50%) of staining tumor cell nuclei was determined for each core section. Both the maximum and the mean Ki-67 staining in the peripheral 2 and the central 1 to 3 core sections were calculated. HIF-1 $\alpha$  staining was performed using the HIF-1 $\alpha$  antibody (Novus Biologicals, Inc, Littleton, CO, US) at 1:400 dilution and the

stainings were classified as weak or strong. Evaluation disregarded necrotic core sections and all slides were evaluated by the authors (J.F. and M.N.) and consensus was reached.

### Assessment of peripheral tumor growth pattern (study V)

#### Microscopic infiltration

The microscopic evaluation of the peripheral tumor growth pattern was based on whole-tumor sections and is part of a previously published study [54]. In short, a whole-tumor section (of approximately 1-cm thickness) was obtained from the maximum tumor diameter. This handling ensures equal fixation also of central tumor areas and after dehydration the section is paraffin-embedded. The microscopical assessment was performed on a 4- $\mu$ m hematoxylin & erythrosin stained section and classified the growth pattern as pushing (where no sign of infiltrative growth were present), focally infiltrative (infiltration in <25% of the tumor rim), and diffusely infiltrative (>25% of the tumor rim involved). Since no differences in outcome were found between the 2 infiltrating groups in the previous study [54], both infiltrating patterns were combined and the analysis thus considered growth patterns classified pushing *versus* infiltrating.

#### Infiltration classified on MRI

Preoperative MRI examinations in study V were retrospectively evaluated in consensus by 2 musculoskeletal radiologists (M.W. and K.J.) who were blinded to the microscopic classification and the outcome data. Standard MRI scans, most of which were performed at local hospitals before referring the patient to the musculoskeletal tumor center were used and included axial and coronal sections, and in some cases also sagittal sections. Hence, different MRI equipment including low-Tesla units as well as 1.5-Tesla units had been used. The sequences were T1 and T2-weighted, coronal short TI inversion recovery (STIR) sequence, and a static T1-weighted fat saturated sequence after intravenous contrast medium injection, most often

gadolinium diethylene triamine pentaacetic acid (DTPA). The assessment of peripheral growth pattern was based on the largest midsection of the tumor. Well-defined tumors without peripheral extensions into the surrounding tissue were clas-

sified as pushing. Tumors with irregular surfaces with spicula-like extensions into the surrounding tissue were classified as infiltrative; focal if <25% of the tumor circumference was involved and otherwise diffuse.



## Results and Discussion

### Increased risk of malignancies in patients with STS (*studies I–II*)

#### *Primary tumors preceding or following the STS*

In study I, additional primary malignancies, preceding or following a STS, developed in 164 (20%) patients, 131 of whom developed 1 additional malignancy, 27 developed 2, and 6 patients developed at least 3 malignancies. These malignancies developed median 10 (0–32) years before and median 4 (0–35) years after the sarcoma diagnosis. Data from the Swedish Cancer Registry suggest that 2 or more primary malignancies develop in 8–10% of all cancer patients, whereas 3 or more malignancies are found in less than 1% of the patients (Swedish board of health and welfare; <http://www.sos.se/sosmenye.htm>). Previous center-based studies have suggested that 7–10% of adult STS patients develop multiple primary malignancies (before or after the sarcoma diagnosis) [81, 132, 193]. Hence, our study suggests that STS patients develop secondary malignancies at a rate twice that in the Cancer Registry and also at a higher rate than previously reported in adult STS patients.

#### *Does the risk vary between different STS subtypes?*

The frequency of multiple primary malignancies varied between the different STS subtypes; second primary malignancies developed in 30% of patients with MFH, 22% with leiomyosarcomas, 23% with liposarcomas, 10% with synovial sarcomas, 54% with MPNST, and in 22% of the patients with STS of other subtypes. The subtype-variation may be influenced by survival differences for the different histopathological subtypes. The low rate detected in synovial sarcoma is in line with the results from Tateishi *et al.* (2005) and may reflect the adverse outcome for these patients. Two previous studies have suggested that the risk of multiple primary malignancies is particularly high among

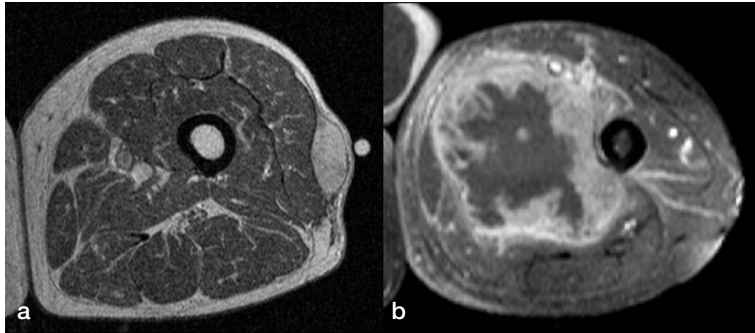
STS patients with MFH/myxofibrosarcoma [132, 193]. In our series, multiple primary tumors most frequently occurred in patients diagnosed with MPNST and MFH. Patients with neurofibromatosis type I are at increased risk of several malignancies, including MPNST, chronic myelogenous leukaemia, and glioma [108, 124]. Since patients with known neurofibromatosis type I were excluded from the study and none of these characteristic/syndrome-related tumor types were observed among the patients diagnosed with MPNST, this is not likely to explain the present observation. In the 19 patients who were diagnosed with MPNST, the most common second tumor types were breast cancer followed by prostate cancer, STS, and tumors of the urinary tract.

#### *Other primary tumors*

Among the primary malignancies that developed prior to the STS (90 tumors in 77 patients) the most common cancer types were breast cancer, prostate cancer, and malignant melanoma. Among the tumors that developed after a STS, the most common types were prostate cancer and colorectal cancer. Merimsky *et al.* (2001) identified renal cell cancer as the most common second tumor type in their study of a mixed STS cohort (including 375 patients), but did not analyze an increased risk hereof [132].

#### *Risk assessment*

During follow-up (6,910 person years for the whole cohort), 113 malignancies developed compared to the expected number of 90, which corresponds to a SMR for all malignancies of 1.3 (95% CI = 1.0–1.5;  $p = 0.02$ ) (study I, table 2). The only specific tumor type that developed at increased risk was STS with a SMR of 18 (95% CI = 8–34;  $p < 0.001$ ). Similar results were obtained also when the 77 individuals with another malignancy prior to the STS were excluded from the analysis, with



**Figure 8.** MRI images of two tumors in study II that developed closest to each other. Based on the genomic profiles these two leiomyosarcomas are suggested to represent two primary STS; a subcutaneous tumor of the left lateral thigh at age 83 (a) and an intramuscular tumor of the left medial thigh at age 87 (b).

a SMR for all malignant tumors of 1.3 (95% CI = 1.0–1.5;  $p = 0.03$ ) and a specifically increased risk of STS with SMR = 17 (95% CI = 7–34).

### *Multiple primary STS*

A second STS at another anatomical location developed in 7 patients mean 4 (2–5) years after the primary diagnosis, and 2 of these patients developed a third subsequent STS (study I, table 3). Of these 9 tumors, 3 were of another histopathologic subtype than the primary tumor. None of the patients had any detectable metastases at the time of diagnosis of the second STS and only 2/7 individuals developed subsequent lung metastases after 47 and 50 months respectively (figure 8). However, it is difficult to determine whether multiple STS that develop in the same individual represent multiple primary tumors or a rare pattern of soft tissue metastases. In order to identify the background of this phenomenon, we applied aCGH to 30 STS from 13 patients in study II. 5 of the patients with multiple STS identified in study I were included in the series, which was extended with an additional 8 patients who had developed at least 2 STS at different anatomical locations.

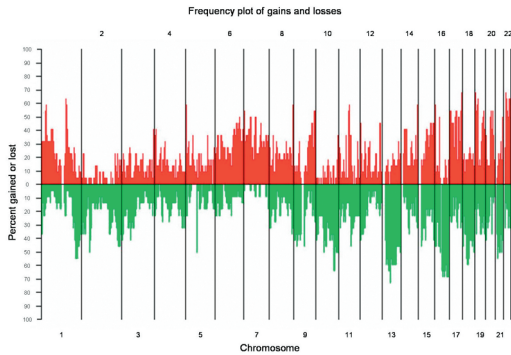
### *What is the cause of multiple STS?*

Several causes, including e.g. heredity, exposure, and treatment-related factors may underly development of multiple primary malignancies [107]. Although several rare genetic syndromes have been

linked to sarcoma development (table 3), heredity is likely to have a minor contribution to STS [126]. The greatest contribution comes from neurofibromatosis, but in the present study known cases of neurofibromatosis (from histopathological reports and clinical files) were excluded. Other syndromes, e.g. Li-Fraumeni, Werner syndrome, Rothmund-Thomson, HNPCC, and FAMMM are rare and thus unlikely to have an impact on the overall risk. STS linked to these syndromes have displayed various histopathologies – synovial sarcoma, liposarcoma and MFH, and no distinctive tumor biology has yet been recognized. Although no specific tumor type other than STS occurred at significantly increased risk in study I, 12 malignant melanomas, 4 pancreatic cancers, 11 endometrial cancers, and 21 colorectal cancers occurred. Hence, we cannot exclude that occasional cases may be linked to FAMMM or HNPCC and suggest that associated tumor types within the families should be taken into consideration, when obtaining a family history of cancer. The impact of previous radiotherapy and chemotherapy is likely to be minor since STS that developed within irradiated fields were excluded from the study, and since chemotherapy had only been administered to 4 patients.

The observation of an increased risk of a second primary sarcoma in STS patients provided the basis for study II in which aCGH was used to characterize and compare the genomic profiles of metachronous STS. Among the 30 STS, recurrent amplifi-

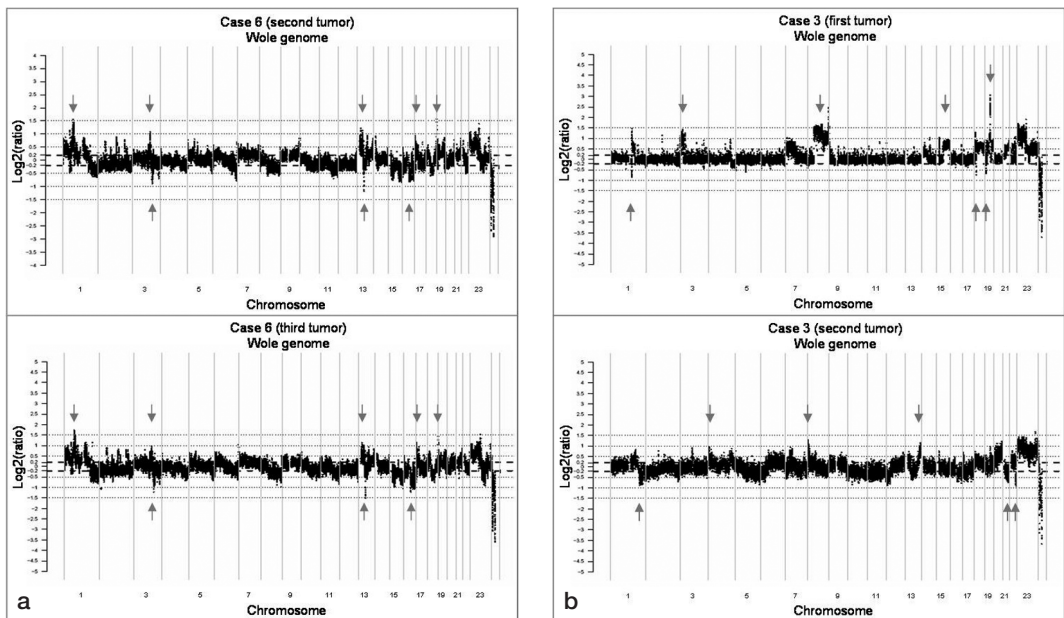




**Figure 9.** A frequency plot summarizing the gains and losses observed in the 22 tumors that were interpreted as separate primary STS within study II.

cations and deletions were identified, 7 of which occurred in >60% of the tumors, including deletion of 10q24.3-25.2, 13q12.1-12.2, 13q21.1-21.2, 16q13-23.2, 18q12.2-12.3 and amplification of 1q21.3-23.1 and 19p13.3 (figure 9). When an unsupervised cluster analysis was performed on the 30 tumors, tumor pairs from 5 cases clustered closely

together, suggesting that these represent soft tissue metastases, whereas tumors from the remaining 8 cases were scattered in the cluster, indicating that these represent multiple primary STS (study II, figure 1). Also when the genomic profiles from the tumors in each case were compared, the plots in the 5 cases that clustered together were strikingly similar, whereas the differences outnumbered the similarities in the plots of the 8 tumor pairs that did not cluster together (figure 10). In STS patients, about 80% of the metastases develop within the first 2–3 years following the primary tumor. The time interval between development of the first and subsequent STS among the 13 patients in study II, was median 1 (1–7) year in the group assumed to represent soft tissue metastases and 4 (1–5) years in the remaining 8 cases, further supporting development of multiple primary STS in the latter group. Knowledge of primary or metastatic tumor origin in patients with multiple STS is important for prognostication and therapeutic decisions.



**Figure 10.** Whole genome plots showing similarities in gene copy number changes in two liposarcomas that developed in the same patient (a) and differences in gene copy number changes in two malignant fibrous histiocytes that were diagnosed in another patient (b) (similarities and differences indicated by arrows). These tumors are hereby suggested to represent soft tissue metastases (a) or separate primary STS (b).

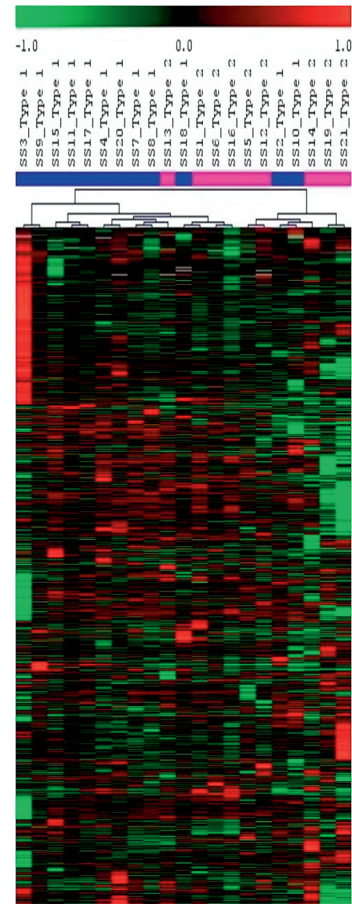
## Gene expression profiling in synovial sarcoma (study III)

### *Distinct gene expression profiles*

Synovial sarcomas are readily discerned from other sarcoma types in gene expression profiling studies. Members of the RAR pathway, the Wnt (figure 4) and TGF- $\beta$  pathways, ephrins, genes related to the FGF and the IGF pathways, *CRABP1*, and the *SSX* genes are among those overexpressed [3, 117, 139, 143, 179]. Among the 26 synovial sarcomas in study III unsupervised hierarchical cluster analysis based on the ~3,500 genes that passed the preprocessing filters did not reveal any distinct clusters related to histotype (monophasic *versus* biphasic), gene fusion type (*SS18-SSX1 versus SS18-SSX2*), karyotype (X;18-translocation as the sole change *versus* as part of a complex karyotype), or development of metastases (figure 11). Results from a recent study from our group on diagnostic and prognostic gene expression profiling in 177 STS, including the 26 synovial sarcomas from study III, showed findings that were in line with the results from previous studies with 4,000 genes differentially expressed in synovial sarcoma compared to other STS subtypes [66]. Several of the genes found to be upregulated in synovial sarcoma were part of central developmental pathways. The genes included *ERBB2*, *FGFR1*, *FGFR3*, *FGF18* and *FRAG1* from the EGF and FGF receptor signaling pathways, members of the Hh signaling pathway like *PTCH*, *SMO*, *BMP7*, *FOXM1* and *CSNK1E*, RAR pathway genes like *RARA*, *RARG*, *MDK*, *MEIS1* and *PRAME*, and genes involved in Notch receptor signaling like *NOTCH1*, *JAG1* and the transducin-like enhancer of split genes. In several previous studies, synovial sarcoma have shown gene expression signatures similar to those of MPNST, potentially indicating a neural crest origin of synovial sarcoma [3, 10, 66, 139].

### *Expression signature related to genetic alterations*

When Golub-scores were estimated and genes were ranked according to their discriminative power in relation to gene fusion type (12 tumors with *SS18-SSX1 versus* 9 tumors with *SS18-SSX2*), the 100



**Figure 11.** Unsupervised cluster analysis of the synovial sarcomas in study III. 12 tumors had the *SS18-SSX1* gene fusion type and 9 tumors had the *SS18-SSX2* fusion. The cluster was based on ~3,500 genes and the Pearson correlation distance metric was used. It was performed using the TMeV application of the TM<sub>4</sub> microarray software suit [175].

most influential genes were extracted (the false-discovery rate remained fairly constant around 40% from approximately 30 to 100 genes) (study III, figures 1 and 3). Among the discriminating genes, 81 were upregulated in tumors with the *SS18-SSX1* fusion type including multiple metallothioneins, histones and G protein-coupled receptors. In addition, a number of genes that have been implicated in oncogenesis, i.e. *TCF7*, *IGFBP3*, *AXL*, *RALGDS* and *CDC2L1*, and genes belonging to pathways previously linked to synovial sarcoma i.e. *AXL*, *ZIC2*,

*SPAG7* and *AGRN* were upregulated in tumors with *SS18-SSX1*. Patients with synovial sarcoma carrying the *SS18-SSX1* fusion have been suggested to be at increased risk of developing metastases, with a worse overall prognosis [102, 145]. Among the tumors with the *SS18-SSX1* fusion variant, histones and genes within histone metabolic pathways were highly expressed indicating a higher proliferative activity in these tumors, and interestingly high proliferation and also expression of cyclin A has previously been linked to synovial sarcoma with the *SS18-SSX1* fusion [145, 164, 214]. Additionally, in the recent gene expression study on 177 STS, EASE analysis identified chromatin-remodeling genes including several histones and SMAR genes as constituting one of the largest functional groups upregulated in the SS as compared to other STS subtypes [66]. Also, metallothioneins that were highly expressed in tumors with the *SS18-SSX1* fusion type have previously been suggested to be of prognostic value in STS [48, 49]. Among the 19 genes that were upregulated in tumors with the *SS18-SSX2* fusion type, were *NCAM1* and *FOXCI*, which previously have been shown to be linked to synovial sarcoma. In order to functionally classify the genes and to facilitate biological interpretation of them, these genes were further analysed using EASE (Expression Analysis Systematic Explorer) (<http://david.niaid.nih.gov/david/ease.htm>) [92]. Herein, several metallothioneins, histones and transcription factors appeared among the top-upregulated genes related to gene fusion type.

The findings in study III thus suggest that gene fusion type affects gene expression and identifies transcription factors, growth factor receptors and metallothioneins as discriminators, which may provide important information about the histopathologic and prognostic differences that have been associated with gene fusion type.

#### ***Subclusters related to tumor morphology***

Studies of gene expression in synovial sarcoma have revealed subclusters based on tumor morphology – monophasic *versus* biphasic [3, 139]. Based on the expression pattern of 1,405 genes, Nagayama *et al.* identified two subclasses; bipha-

sic tumors clustered together, whereas monophasic tumors were divided into two subsets; one of which clustered together with the biphasic tumors and the other formed a separate cluster [139]. Among the discriminating genes reported were *JUN*, *TIEG*, and annexin A4. Allander *et al.* used 21 genes to obtain a separation between biphasic and monophasic tumors with keratin-encoding genes being the most frequently upregulated in biphasic tumors, which would agree with an epithelial component being present in these tumors [3]. We did not, however, find any distinct gene expression patterns in relation to tumor morphology, but our study only contained 6 biphasic tumors from a tumor type with inherent heterogeneity.

#### ***Can a metastatic signature be identified?***

Since synovial sarcoma patients are at high risk (50%) of metastases, development of a molecular prognosticator would be valuable for decisions on adjuvant chemotherapy. Differentially expressed genes were identified when the 12 tumors that metastasized were compared to 7 primary tumors that did not. The series is small and the false discovery-rate is high, which precludes definite results. However, the identification of biological relevant genes, including *STXBP6*, survivin (*BIRC5*), and *TOP2A* is interesting since some of these have been demonstrated to correlate with prognosis in synovial sarcoma and have been linked to metastatic potential (study III, figure 2) [115, 151, 167].

### **Tumor heterogeneity (study IV)**

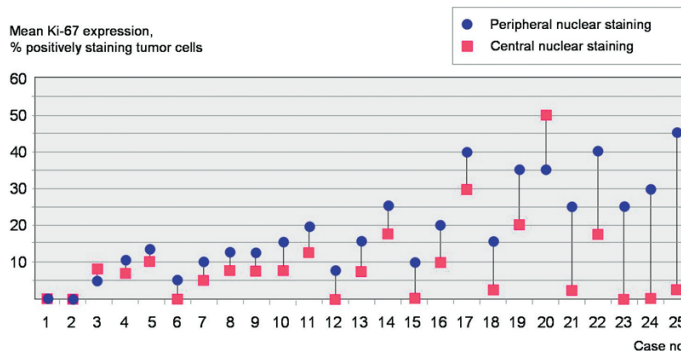
#### ***Proliferation as a prognostic marker***

Besides the currently used morphological parameters, e.g. necrosis and vascular invasion, proliferation represents a biologic marker that has repeatedly been linked to an adverse prognosis in STS [26, 55, 83]. Assessment of proliferation, which often uses immunohistochemical staining for Ki-67, is considered for inclusion into clinical prognostic systems. However, different methods and cut-off levels for assessment of proliferation have been used and its importance may also differ between different STS

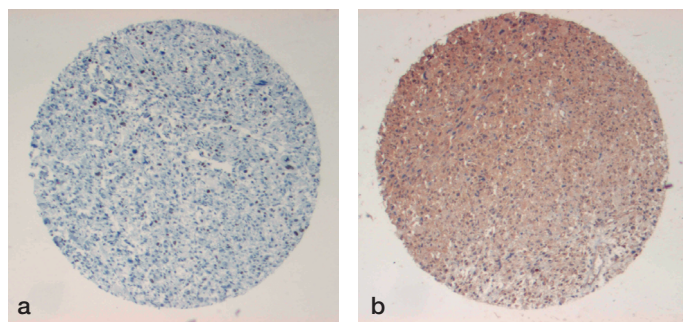
subtypes. In previous studies, the most commonly used cut-off levels for Ki-67 positivity range between 10% and 30% staining tumor nuclei, and different or unspecified tumor areas have been analyzed [82, 89, 94, 96]. The lack of consensus on how to determine proliferation in STS limits its use as a prognostic factor in the clinical setting.

### *Intratumor Ki-67 variability*

Sarcomas are often large and histologically heterogeneous; the mean tumor size is 5 cm for superficial tumors and 9 cm for deep-seated tumors [74]. In study IV, we choose one of the major types of highly malignant and pleomorphic STS types, leiomyosarcoma, to assess the variability of the most commonly used proliferation marker, Ki-67. TMA was applied to obtain tissue core biopsies from throughout the tumor diameter (figure 7). The leiomyosarcomas in study III were chosen based on availability of whole-tumor sections from which TMA-based core sections could be obtained from throughout the tumor diameter. 94% of the totally 229 TMA core biopsies were evaluable and identified higher Ki-67 staining in the tumor periphery in 18/25 tumors if the maximal staining was considered and in 21/25 if the mean Ki-67 expression was considered (figure 12 and study IV, figure 2). Irrespective of whether 10%, 20% or 30% staining tumor nuclei were used as cut-off, an additional 20–40% of the tumors were classified as positive if the periphery rather than the tumor center were used for evaluation (study IV, table 1). A higher Ki-67 staining in the tumor periphery than in the center was observed also when these cut-off levels and the mean staining intensities were considered (rather than the maximum staining) (figure 12). The differ-



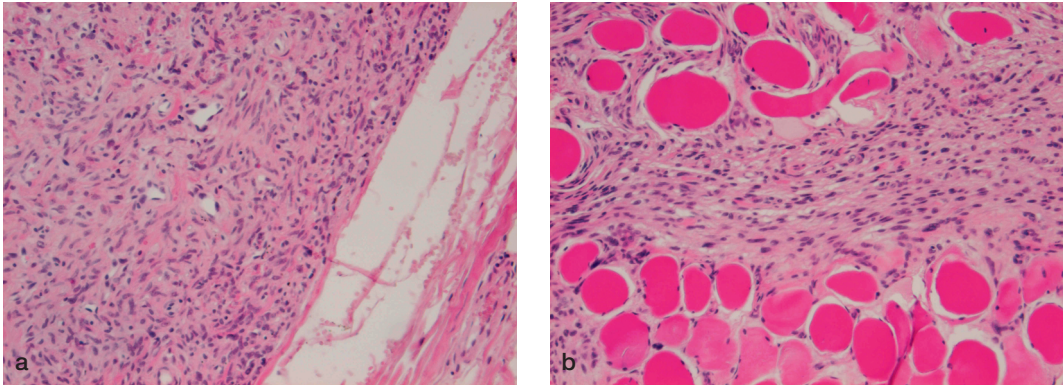
**Figure 12.** Mean peripheral Ki-67 staining in the tumor periphery compared to the tumor center for 25 leiomyosarcomas (1–25) in study IV (in the publication the maximal staining is depicted). Blue circles represent the tumor periphery and pink squares represent the tumor center.



**Figure 13.** Tissue microarray sections showing positive stainings for Ki-67 (a) and HIF-1 $\alpha$  (b).

ences could not be related to tumor size. Hypoxia has been linked to proliferation through e.g. increased glucose metabolism with the highest proliferative rates in the poorest oxygenated tumors and with an adverse prognosis for hypoxic tumors [14, 64, 147, 148]. Necrotic tumor areas were not evaluated, but in order to clarify a potential impact of hypoxia we used HIF-1 $\alpha$  staining. No relation between Ki-67 and HIF-1 $\alpha$  expression was identified and only 4 tumors showed an increased HIF-1 $\alpha$  expression in the tumor periphery. When the 8 tumors with >10% differences in Ki-67 expression between the tumor center and the periphery were considered, only one showed an increased hypoxia-related expression pattern in the tumor periphery (figure 13). The demonstration that highly proliferative tumor subclones predominantly exist in the tumor periphery suggests





**Figure 14.** Peripheral tumor growth patterns on histopathology in STS showing pushing growth (a) and infiltrating growth with tumor cells growing between the surrounding muscle cells (b).

that assessment of proliferation in STS should be standardized and perhaps focus on the tumor periphery, when introduced as a prognostic factor for decisions on adjuvant treatment.

### **Peripheral tumor growth pattern (study V)** ***Can preoperative MRI provide prognostic information?***

Different peripheral growth patterns in soft tissue tumors were recognized already in the 1980s by Enneking who described encapsulated benign tumors and infiltrative malignant tumors [56]. Engellau *et al.* have recently demonstrated the prognostic impact of an infiltrative peripheral tumor growth pattern (figure 14) [54]. This prognostic marker has the drawback of being analyzed in the operative specimen, which precludes its use in preoperative prognostication. We performed study V as a pilot investigation into whether preoperative MRI can be used to identify infiltrative STS and thus provide pretreatment prognostic data. Dynamic, contrast-enhanced MRI has been suggested to differentiate viable from non-viable (necrotic or avascular) tumor areas, and could therefore potentially be valuable for preoperative prognostication [182]. The possibility to obtain this information before surgery would allow individualized treatment with addition of neoadjuvant

therapies, i.e. radiotherapy or chemotherapy, for high-risk tumors. The overall prognostic value of preoperative MRI, however, is largely unknown.

### ***MRI growth pattern correlated to microscopic growth pattern***

The MRI-based growth pattern showed no obvious association with tumor size, depth, or grade; indeed a pushing growth pattern was identified in 2/3 of the large (>5 cm) tumors and in 1/3 of the grade IV tumors. Study V was based on a subset of patients (based on the availability of MRI scans) from the study that first suggested a prognostic role from peripheral tumor growth pattern [54]. Among the 78 tumors, 22 were classified as pushing on histopathology and all of these tumors were also classified as pushing or focally infiltrative on MRI. Among the 56 microscopically infiltrative tumors, MRI identified 20 as pushing, 17 as focally infiltrative, and 19 as diffusely infiltrative (study V, table 2). Hence, MRI failed to correctly classify 1/3 of the tumors that showed an infiltrative growth pattern on histopathology.

Metastases developed in 12/19 (rate 0.6) diffusely infiltrative tumors compared to 21/59 (rate 0.4) of the tumors with a pushing or focally infiltrative growth pattern on MRI ( $p = 0.03$ ). The former group had a HR of 2.5 for the risk of development of metastases (95% CI = 1.2–5.1;  $p = 0.01$ ) (study V, figure 2). Local tumor recurrences developed at

a rate of 0.3 in diffusely infiltrative tumors compared to 0.1 in tumors with a pushing or focally infiltrative growth pattern on MRI ( $p = 0.04$ ). In the analysis of local recurrence-free survival, infiltrative growth on MRI showed a HR of 3.7 (95% CI = 1.2–11;  $p = 0.02$ ).

These results demonstrate that STS with diffuse infiltrative growth on MRI have a higher risk of local recurrence as well as metastases. However, almost one third of the histopathologically pushing tumors had focal infiltration on MRI and one third of the histopathologically infiltrative tumors had pushing growth on MRI. Only diffuse infiltration on MRI was of prognostic importance (study V, figure 2). Difficulties in determining infiltration on MRI probably account for the discrepancies between the findings reported by Engellau [54] and identified herein. We suggest that tumors with diffuse infiltration around the tumor border are more likely to be correctly identified as infiltrative on MRI, whereas focal infiltration on MRI may be false positive. Based on these results, we suggest that preoperative MRI should, within a standardized protocol, classify the peripheral tumor growth pattern and evaluate the prognostic importance hereof in a prospective study, perhaps using high-resolution MRI.

### *Microscopic and MRI based necrosis*

Macroscopic as well as microscopic necrosis within a STS is a well-known and strong prognostic factor for the occurrence of metastasis [75, 197]. Suspected necrosis was on MRI identified in 77% of the evaluable STS in study V (data not included in the article), among which 67% also had histopathologically verified necrosis. Hence, MRI identified necrosis in 18 tumors that did not show evidence of necrosis on the whole-tumor sections. The agreement between necrosis assessed by MRI and histopathology was moderate (72%, kappa = 0.44) and only the histopathological classification of necrosis showed significant correlation to outcome. Necrosis identified on whole-tumor sections correlated to metastasis-free survival with a

HR of 3.4. Metastases occurred somewhat more frequently (44% *versus* 31%) in patients whose tumors had necrosis on MRI and a weak trend (HR = 1.8, 95% CI = 0.68–4.7;  $p = 0.2$ ) for metastasis-free survival was observed. However, no significant correlation between necrosis on MRI and metastasis or local recurrence was found. This may reflect false positive identification of necrosis on MRI because of difficulties in distinguishing necrosis from intratumoral bleeding. Indeed, among the 54 tumors with necrosis on MRI, 9 had bleeding but not necrosis on histopathology (data not shown). A previous study on 51 STS patients suggested a correlation between CT-based findings of tumor necrosis and development of metastasis [77], but the difficulties in distinguishing between bleeding and necrosis also apply to CT-based examinations and we have no explanation for the discrepancy regarding the CT/MRI-based prognostic value of necrosis in these two series.

### *The impact of the reactive zone*

In addition, a so-called reactive zone with edema and a mixture of normal tissue, granulation tissue, and sometimes also tumor cells, has been described in the infiltrative tumors, but whether this phenomenon correlates with the peritumoral tumor edema often observed on MRI is unknown. Therefore, peritumoral edema was retrospectively assessed in study V (not included in article). Edema based on MRI was identified in 45/67 (67%) evaluable tumors, and was classified as focal in 32 tumors and diffuse in 13 tumors (data not shown). MRI-based edema (focal and diffuse *versus* none) was associated to the presence of inflammatory cells in the whole-tumor sections ( $p = 0.01$ ) and with infiltrative growth-pattern on histopathology with a weak association. Of the tumors with edema on MRI 35/45 (78%) showed infiltrative growth as compared to 15/22 68% of the tumors without edema ( $p = 0.4$ ). Regarding the prognostic importance of edema, MRI-based peritumoral edema did not correlate with the development of metastases and hence, could not predict outcome in our series.

## Conclusions and Further questions

*(further questions italicized)*

Patients with STS are at increased risk of developing second primary malignancies, with a specifically high risk of a second STS. In the small subset of patients who were diagnosed with a second STS before any lung or lymph node metastases aCGH analysis demonstrated different genetic profiles in the majority of the cases. This indicates that double primary STS may occur, which has implications for treatment.

*Is the increased risk of a second malignancy identified in study I linked to an increased death rate? Can novel hereditary syndromes linked to STS be recognized? Such questions should preferentially be studied within extended, population-based, series.*

Gene expression analysis of synovial sarcoma identified genes discriminating tumors with the different gene fusion variants *SS18-SSX1* and *SS18-SSX2*. Hence, these fusions are likely to have different downstream effects. A signal suggesting metastatic potential was also suggested and was characterized by overexpression of e.g. *TOP2A*.

*The gene expression data currently available in STS clearly distinguish STS subsets with specific genetic alterations e.g. GIST and synovial sarcoma, and have herein identified multiple up/downregulated genes. Regarding the genetically complex, often pleomorphic STS types, distinctive expression profiles have not been identified. Further evaluation and identification of the signaling pathways involved in STS could provide knowledge related to diagnosis, prognosis and development of targeted therapies. The first genetic profiling data using aCGH confirm genetic complexity in STS, but also identify recurrent alterations. These studies, together with cytogenetically based gain/loss*

*data, suggest that genetic alterations may be of prognostic value. Based on current data, various genetic signature are emerging within STS, but these need to be validated and further evaluated using e.g. FISH and immunostaining, which can be applied in clinical routine.*

Proliferation has repeatedly been linked to prognosis in STS and is considered for clinical prognostic applications. However, there is a lack of consensus as to how to determine proliferation. We demonstrated higher Ki-67 immunostaining in the tumor periphery in most leiomyosarcomas, which supports the need for standardized determination.

*Ki-67 determination needs to be standardized and its role in different histopathological subsets as well as the impact of variability should be evaluated in extended type-specific STS series.*

MRI is routinely used for preoperative evaluation of STS patients, but its prognostic potential is unknown. If applicable, it would allow preoperative selection of patients whose tumors display high-risk characteristics for neoadjuvant treatment. STS with diffuse peripheral tumor infiltration on MRI were associated with a high risk for local recurrence and metastasis, but MRI also failed to identify 1/3 of the tumors with infiltration identified using morphology.

*The MRI study performed constitutes a pilot study indicating that high-risk STS may be recognized preoperatively through demonstration of an infiltrative growth pattern. These data should be prospectively validated in larger materials according to standardized protocols and use of modern MRI technology.*

## Acknowledgements

The work described in this thesis has been performed at the Department of Oncology, Institute of Clinical Sciences, Lund University – thank you for giving me the opportunity to work in such a stimulating environment!

Sarcoma diagnostics, treatment and research, however, involves multidisciplinary contributions and I would like to express my sincere gratitude to the Lund sarcoma group and to the SSG for facilitating research and for teaching me the importance and benefits of a multidisciplinary approach!

I would especially like to thank:

My supervisor, *Mef Nilbert* for support, encouragement and inspiration. Thank you for introducing me to research and for sharing your vast knowledge so generously;

My co-supervisors, *Anders Rydholm* and *Jacob Engellau* for help, advice and excellent clinical guidance;

All co-authors and collaborators at the Departments of Orthopedics, Pathology, Radiology, Cancer Epidemiology, and Clinical Genetics. Thank you for your contributions, help, and criticism;

All personnel at the Kamprad Laboratory and at the Genomics Facility, Department of Oncology, for creating a pleasant and stimulating working atmosphere – in particularly *Eva Rambech* for teaching me practical lab skills, *Pär-Ola Bendahl*

for excellent statistical advice and support, and *Kristina Lövgren* for help with the immunostainings;

The SSG registry for great and efficient help with various tasks;

*Pelle Gustafson*, for introducing me to clinical orthopedics and sarcoma treatment;

*Måns Åkerman* and *Henryk Domanski* for pathological review;

All my fellow PhD students for encouraging discussions and in particular, *Princy Francis*, my room-mate and fellow PhD student, for support in our joint struggle with bioinformatics and clinical follow-up data, for laughter and deep friendship;

All my dear friends, thank you!

My *family*, for your understanding and endless support. My parents *Lars* and *Eva* for generous help and for making this possible, and my sister *Jenny*, for always being there for me;

*Fredrik* for always supporting and believing in me.

This work has been supported by the Swedish Cancer Society, the Swedish Research Council, the Wallenberg Foundation through the Genomics Facility at Lund University, the Gunnar Nilsson Cancer Fund, the John and Augusta Persson Fund, the Berta Kamprad Cancer Fund, and the Region Skåne Fund.



## References

1. The association of selected cancers with service in the US military in Vietnam. II. Soft-tissue and other sarcomas. The Selected Cancers Cooperative Study Group. *Arch Intern Med* 150: 2485-2492, 1990.
2. Abrams TA, and Schuetz SM. Targeted therapy for dermatofibrosarcoma protuberans. *Curr Oncol Rep* 8: 291-296, 2006.
3. Allander SV, Illei PB, Chen Y, et al. Expression profiling of synovial sarcoma by cDNA microarrays: association of ERBB2, IGFBP2, and ELF3 with epithelial differentiation. *Am J Pathol* 161: 1587-1595, 2002.
4. Allander SV, Nupponen NN, Ringner M, et al. Gastrointestinal stromal tumors with KIT mutations exhibit a remarkably homogeneous gene expression profile. *Cancer Res* 61: 8624-8628, 2001.
5. Antman K, Crowley J, Balcerzak SP, et al. An intergroup phase III randomized study of doxorubicin and dacarbazine with or without ifosfamide and mesna in advanced soft tissue and bone sarcomas. *J Clin Oncol* 11: 1276-1285, 1993.
6. Antonescu CR, Elahi A, Healey JH, et al. Monoclonality of multifocal myxoid liposarcoma: confirmation by analysis of TLS-CHOP or EWS-CHOP rearrangements. *Clin Cancer Res* 6: 2788-2793, 2000.
7. Antonescu CR, Leung DH, Dudas M, et al. Alterations of cell cycle regulators in localized synovial sarcoma: A multifactorial study with prognostic implications. *Am J Pathol* 156: 977-983, 2000.
8. Antonescu CR, Tschernyavsky SJ, Decuseara R, et al. Prognostic impact of P53 status, TLS-CHOP fusion transcript structure, and histological grade in myxoid liposarcoma: a molecular and clinicopathologic study of 82 cases. *Clin Cancer Res* 7: 3977-3987, 2001.
9. Autio R, Hautaniemi S, Kauraniemi P, et al. CGH-Plotter: MATLAB toolbox for CGH-data analysis. *Bioinformatics* 19: 1714-1715, 2003.
10. Baird K, Davis S, Antonescu CR, et al. Gene expression profiling of human sarcomas: insights into sarcoma biology. *Cancer Res* 65: 9226-9235, 2005.
11. Balasubramanian L, and Evens AM. Targeting angiogenesis for the treatment of sarcoma. *Curr Opin Oncol* 18: 354-359, 2006.
12. Barrios C, Castresana JS, and Kreicbergs A. Clinicopathologic correlations and short-term prognosis in musculoskeletal sarcoma with c-myc oncogene amplification. *Am J Clin Oncol* 17: 273-276, 1994.
13. Barrios C, Castresana JS, Ruiz J, and Kreicbergs A. Amplification of the c-myc proto-oncogene in soft tissue sarcomas. *Oncology* 51: 13-17, 1994.
14. Bastiaannet E, Groen H, Jager PL, et al. The value of FDG-PET in the detection, grading and response to therapy of soft tissue and bone sarcomas; a systematic review and meta-analysis. *Cancer Treat Rev* 30: 83-101, 2004.
15. Bauer HC, Trovik CS, Alvegard TA, et al. Monitoring referral and treatment in soft tissue sarcoma: study based on 1,851 patients from the Scandinavian Sarcoma Group Register. *Acta Orthop Scand* 72: 150-159, 2001.
16. Beaty O, 3rd, Hudson MM, Greenwald C, et al. Subsequent malignancies in children and adolescents after treatment for Hodgkin's disease. *J Clin Oncol* 13: 603-609, 1995.
17. Bisogno G, Sotti G, Nowicki Y, et al. Soft tissue sarcoma as a second malignant neoplasm in the pediatric age group. *Cancer* 100: 1758-1765, 2004.
18. Borden EC, Baker LH, Bell RS, et al. Soft tissue sarcomas of adults: state of the translational science. *Clin Cancer Res* 9: 1941-1956, 2003.
19. Bosetti C, La Vecchia C, Lipworth L, and McLaughlin JK. Occupational exposure to vinyl chloride and cancer risk: a review of the epidemiologic literature. *Eur J Cancer Prev* 12: 427-430, 2003.
20. Brennan MF, Casper ES, Harrison LB, et al. The role of multimodality therapy in soft-tissue sarcoma. *Ann Surg* 214: 328-336; discussion 336-328, 1991.
21. Breslow NE, Takashima JR, Whitton JA, et al. Second malignant neoplasms following treatment for Wilm's tumor: a report from the National Wilms' Tumor Study Group. *J Clin Oncol* 13: 1851-1859, 1995.
22. Brody RI, Ueda T, Hamelin A, et al. Molecular analysis of the fusion of EWS to an orphan nuclear receptor gene in extraskeletal myxoid chondrosarcoma. *Am J Pathol* 150: 1049-1058, 1997.
23. Buchdunger E, Cioffi CL, Law N, et al. Abl protein-tyrosine kinase inhibitor STI571 inhibits in vitro signal transduction mediated by c-kit and platelet-derived growth factor receptors. *J Pharmacol Exp Ther* 295: 139-145, 2000.
24. Chen Y, Kamat V, Dougherty ER, et al. Ratio statistics of gene expression levels and applications to microarray data analysis. *Bioinformatics* 18: 1207-1215, 2002.
25. Cho YL, Bae S, Koo MS, et al. Array comparative genomic hybridization analysis of uterine leiomyosarcoma. *Gynecol Oncol* 99: 545-551, 2005.
26. Choong PF, Akerman M, Willen H, et al. Prognostic value of Ki-67 expression in 182 soft tissue sarcomas. Proliferation--a marker of metastasis? *Apmis* 102: 915-924, 1994.

27. Choong PF, Mandahl N, Mertens F, et al. 19p+ marker chromosome correlates with relapse in malignant fibrous histiocytoma. *Genes Chromosomes Cancer* 16: 88-93, 1996.
28. Clark J, Rocques PJ, Crew AJ, et al. Identification of novel genes, SYT and SSX, involved in the t(X;18)(p11.2;q11.2) translocation found in human synovial sarcoma. *Nat Genet* 7: 502-508, 1994.
29. Cohen JA, and Geradts J. Loss of RB and MTS1/CDKN2 (p16) expression in human sarcomas. *Hum Pathol* 28: 893-898, 1997.
30. Cohen RJ, Curtis RE, Inskip PD, and Fraumeni JF, Jr. The risk of developing second cancers among survivors of childhood soft tissue sarcoma. *Cancer* 103: 2391-2396, 2005.
31. Coindre JM, Terrier P, Bui NB, et al. Prognostic factors in adult patients with locally controlled soft tissue sarcoma. A study of 546 patients from the French Federation of Cancer Centers Sarcoma Group. *J Clin Oncol* 14: 869-877, 1996.
32. Coindre JM, Terrier P, Guillou L, et al. Predictive value of grade for metastasis development in the main histologic types of adult soft tissue sarcomas: a study of 1240 patients from the French Federation of Cancer Centers Sarcoma Group. *Cancer* 91: 1914-1926, 2001.
33. Coindre JM, Trojani M, Contesso G, et al. Reproducibility of a histopathologic grading system for adult soft tissue sarcoma. *Cancer* 58: 306-309, 1986.
34. Cordon-Cardo C. Mutations of cell cycle regulators. Biological and clinical implications for human neoplasia. *Am J Pathol* 147: 545-560, 1995.
35. Cormier JN, and Pollock RE. Soft tissue sarcomas. *CA Cancer J Clin* 54: 94-109, 2004.
36. Costa J, Wesley RA, Glatstein E, and Rosenberg SA. The grading of soft tissue sarcomas. Results of a clinicohistopathologic correlation in a series of 163 cases. *Cancer* 53: 530-541, 1984.
37. de Bruijn DR, Allander SV, van Dijk AH, et al. The Synovial Sarcoma-Associated SS18-SSX2 Fusion Protein Induces Epigenetic Gene (De)Regulation. *Cancer Res* 66: 9474-9482, 2006.
38. de Leeuw B, Balemans M, Olde Weghuis D, and Geurts van Kessel A. Identification of two alternative fusion genes, SYT-SSX1 and SYT-SSX2, in t(X;18)(p11.2;q11.2)-positive synovial sarcomas. *Hum Mol Genet* 4: 1097-1099, 1995.
39. de Leeuw B, Balemans M, Weghuis DO, et al. Molecular cloning of the synovial sarcoma-specific translocation (X;18)(p11.2;q11.2) breakpoint. *Hum Mol Genet* 3: 745-749, 1994.
40. de Saint Aubain Somerhausen N, and Fletcher CD. Soft-tissue sarcomas: an update. *Eur J Surg Oncol* 25: 215-220, 1999.
41. Dei Tos AP, Maestro R, Doglioni C, et al. Tumor suppressor genes and related molecules in leiomyosarcoma. *Am J Pathol* 148: 1037-1045, 1996.
42. Demetri GD, von Mehren M, Blanke CD, et al. Efficacy and safety of imatinib mesylate in advanced gastrointestinal stromal tumors. *N Engl J Med* 347: 472-480, 2002.
43. Derre J, Lagace R, Nicolas A, et al. Leiomyosarcomas and most malignant fibrous histiocytomas share very similar comparative genomic hybridization imbalances: an analysis of a series of 27 leiomyosarcomas. *Lab Invest* 81: 211-215, 2001.
44. Domanski HA, Akerman M, Carlen B, et al. Core-needle biopsy performed by the cytopathologist: a technique to complement fine-needle aspiration of soft tissue and bone lesions. *Cancer* 105: 229-239, 2005.
45. dos Santos NR, de Bruijn DR, and van Kessel AG. Molecular mechanisms underlying human synovial sarcoma development. *Genes Chromosomes Cancer* 30: 1-14, 2001.
46. Druker BJ, Sawyers CL, Kantarjian H, et al. Activity of a specific inhibitor of the BCR-ABL tyrosine kinase in the blast crisis of chronic myeloid leukemia and acute lymphoblastic leukemia with the Philadelphia chromosome. *N Engl J Med* 344: 1038-1042, 2001.
47. Dupuy DE, Rosenberg AE, Punyaratbandhu T, et al. Accuracy of CT-guided needle biopsy of musculoskeletal neoplasms. *AJR Am J Roentgenol* 171: 759-762, 1998.
48. Dziegiel P, Salwa-Zurawska W, Zurawski J, et al. Prognostic significance of augmented metallothionein (MT) expression correlated with Ki-67 antigen expression in selected soft tissue sarcomas. *Histol Histopathol* 20: 83-89, 2005.
49. Dziegiel P, Suder E, Surowiak P, et al. Expression of metallothionein in synovial sarcoma cells. *Appl Immunohistochem Mol Morphol* 10: 357-362, 2002.
50. Edmonson JH, Ryan LM, Blum RH, et al. Randomized comparison of doxorubicin alone versus ifosfamide plus doxorubicin or mitomycin, doxorubicin, and cisplatin against advanced soft tissue sarcomas. *J Clin Oncol* 11: 1269-1275, 1993.
51. Eisen MB, Spellman PT, Brown PO, and Botstein D. Cluster analysis and display of genome-wide expression patterns. *Proc Natl Acad Sci U S A* 95: 14863-14868, 1998.
52. Engellau J. Prognostic factors in soft tissue sarcoma. Tissue microarray for immunostaining, the importance of whole-tumor sections and time-dependence. *Acta Orthop Scand Suppl* 75: 2 p preceding table of contents-52, backcover, 2004.
53. Engellau J, Akerman M, Anderson H, et al. Tissue microarray technique in soft tissue sarcoma: immunohistochemical Ki-67 expression in malignant fibrous histiocytoma. *Appl Immunohistochem Mol Morphol* 9: 358-363, 2001.

54. Engellau J, Bendahl PO, Persson A, et al. Improved prognostication in soft tissue sarcoma: independent information from vascular invasion, necrosis, growth pattern, and immunostaining using whole-tumor sections and tissue microarrays. *Hum Pathol* 36: 994-1002, 2005.
55. Engellau J, Persson A, Bendahl PO, et al. Expression profiling using tissue microarray in 211 malignant fibrous histiocytomas confirms the prognostic value of Ki-67. *Virchows Arch* 445: 224-230, 2004.
56. Enneking WF, Spanier SS, and Goodman MA. A system for the surgical staging of musculoskeletal sarcoma. *Clin Orthop Relat Res* 106-120, 1980.
57. Eriksson M, Hardell L, and Adami HO. Exposure to dioxins as a risk factor for soft tissue sarcoma: a population-based case-control study. *J Natl Cancer Inst* 82: 486-490, 1990.
58. Ferrari A, Gronchi A, Casanova M, et al. Synovial sarcoma: a retrospective analysis of 271 patients of all ages treated at a single institution. *Cancer* 101: 627-634, 2004.
59. Fletcher CD. Pleomorphic malignant fibrous histiocytoma: fact or fiction? A critical reappraisal based on 159 tumors diagnosed as pleomorphic sarcoma. *Am J Surg Pathol* 16: 213-228, 1992.
60. Fletcher CD, Gustafson P, Rydholm A, et al. Clinicopathologic re-evaluation of 100 malignant fibrous histiocytomas: prognostic relevance of subclassification. *J Clin Oncol* 19: 3045-3050, 2001.
61. Fletcher JA, Kozakewich HP, Hoffer FA, et al. Diagnostic relevance of clonal cytogenetic aberrations in malignant soft-tissue tumors. *N Engl J Med* 324: 436-442, 1991.
62. Fletcher CDM, Unni KK, Mertens FE. (2002) Pathology and Genetics of Tumours of Soft Tissue and Bone. World Health Organisation Classification of Tumours, ed. C.D.M. Fletcher, K.K. Unni, and F. Mertens. Lyon: IARC Press.
63. Fletcher O, Easton D, Anderson K, et al. Lifetime risks of common cancers among retinoblastoma survivors. *J Natl Cancer Inst* 96: 357-363, 2004.
64. Folpe AL, Lyles RH, Sprouse JT, et al. (F-18) fluorodeoxyglucose positron emission tomography as a predictor of pathologic grade and other prognostic variables in bone and soft tissue sarcoma. *Clin Cancer Res* 6: 1279-1287, 2000.
65. Francis P, fernebro J, Eden P, et al. Intratumor versus intertumor heterogeneity in gene expression profiles of soft-tissue sarcomas. *Genes Chromosomes Cancer* 43: 302-308, 2005.
66. Francis P, Namlos HM, Muller C, et al. Diagnostic and prognostic gene expression signatures in 177 soft tissue sarcomas: hypoxia-induced transcription profile signifies metastatic potential. *BMC Genomics* 8: 73, 2007.
67. Gerald WL, and Haber DA. The EWS-WT1 gene fusion in desmoplastic small round cell tumor. *Semin Cancer Biol* 15: 197-205, 2005.
68. Golub TR, Slonim DK, Tamayo P, et al. Molecular classification of cancer: class discovery and class prediction by gene expression monitoring. *Science* 286: 531-537, 1999.
69. Goto M, Miller RW, Ishikawa Y, and Sugano H. Excess of rare cancers in Werner syndrome (adult progeria). *Cancer Epidemiol Biomarkers Prev* 5: 239-246, 1996.
70. Granville L, Hicks J, Popek E, et al. Visceral clear cell sarcoma of soft tissue with confirmation by EWS-ATF1 fusion detection. *Ultrastruct Pathol* 30: 111-118, 2006.
71. Grobmyer SR, Maki RG, Demetri GD, et al. Neo-adjuvant chemotherapy for primary high-grade extremity soft tissue sarcoma. *Ann Oncol* 15: 1667-1672, 2004.
72. Guillou L, Benhattar J, Bonichon F, et al. Histologic grade, but not SYT-SSX fusion type, is an important prognostic factor in patients with synovial sarcoma: a multicenter, retrospective analysis. *J Clin Oncol* 22: 4040-4050, 2004.
73. Guillou L, Coindre JM, Bonichon F, et al. Comparative study of the National Cancer Institute and French Federation of Cancer Centers Sarcoma Group grading systems in a population of 410 adult patients with soft tissue sarcoma. *J Clin Oncol* 15: 350-362, 1997.
74. Gustafson P. Soft tissue sarcoma. Epidemiology and prognosis in 508 patients. *Acta Orthop Scand Suppl* 259: 1-31, 1994.
75. Gustafson P, Akerman M, Alvegard TA, et al. Prognostic information in soft tissue sarcoma using tumour size, vascular invasion and microscopic tumour necrosis-the SIN-system. *Eur J Cancer* 39: 1568-1576, 2003.
76. Gustafson P, Baldetorp B, Ferno M, and Akerman M. Prognostic implications of various models for calculation of S-phase fraction in 259 patients with soft tissue sarcoma. *Br J Cancer* 79: 1205-1209, 1999.
77. Gustafson P, Herrlin K, Biling L, et al. Necrosis observed on CT enhancement is of prognostic value in soft tissue sarcoma. *Acta Radiol* 33: 474-476, 1992.
78. Gustafson P, Rooser B, and Rydholm A. Is local recurrence of minor importance for metastases in soft tissue sarcoma? *Cancer* 67: 2083-2086, 1991.
79. Hanna SL, and Fletcher BD. MR imaging of malignant soft-tissue tumors. *Magn Reson Imaging Clin N Am* 3: 629-650, 1995.
80. Hardell L, and Eriksson M. The association between soft tissue sarcomas and exposure to phenoxyacetic acids. A new case-referent study. *Cancer* 62: 652-656, 1988.
81. Hartley AL, Blair V, Harris M, et al. Multiple primary tumours in a population-based series of patients with histopathologically peer-reviewed sarcomas. *Br J Cancer* 68: 1243-1246, 1993.
82. Hasegawa T, Yamamoto S, Nojima T, et al. Validity and reproducibility of histologic diagnosis and grading for adult soft-tissue sarcomas. *Hum Pathol* 33: 111-115, 2002.

83. Hasegawa T, Yamamoto S, Yokoyama R, et al. Prognostic significance of grading and staging systems using MIB-1 score in adult patients with soft tissue sarcoma of the extremities and trunk. *Cancer* 95: 843-851, 2002.
84. Helman LJ, and Meltzer P. Mechanisms of sarcoma development. *Nat Rev Cancer* 3: 685-694, 2003.
85. Henderson TO, Whitton J, Stovall M, et al. Secondary sarcomas in childhood cancer survivors: a report from the Childhood Cancer Survivor Study. *J Natl Cancer Inst* 99: 300-308, 2007.
86. Hill MA, Gong C, Casey TJ, et al. Detection of K-ras mutations in resected primary leiomyosarcoma. *Cancer Epidemiol Biomarkers Prev* 6: 1095-1100, 1997.
87. Hirata K, Kanemitsu S, Nakayama Y, et al. A Novel Germ-line Mutation of MSH2 in a Hereditary Nonpolyposis Colorectal Cancer Patient with Liposarcoma. *Am J Gastroenterol* 101: 193-196, 2006.
88. Hoos A, Stojadinovic A, Mastorides S, et al. High Ki-67 proliferative index predicts disease specific survival in patients with high-risk soft tissue sarcomas. *Cancer* 92: 869-874, 2001.
89. Hoos A, Urist MJ, Stojadinovic A, et al. Validation of tissue microarrays for immunohistochemical profiling of cancer specimens using the example of human fibroblastic tumors. *Am J Pathol* 158: 1245-1251, 2001.
90. Hoppin JA, Tolbert PE, Flanders WD, et al. Occupational risk factors for sarcoma subtypes. *Epidemiology* 10: 300-306, 1999.
91. Hoppin JA, Tolbert PE, Herrick RF, et al. Occupational chlorophenol exposure and soft tissue sarcoma risk among men aged 30-60 years. *Am J Epidemiol* 148: 693-703, 1998.
92. Hosack DA, Dennis G, Jr., Sherman BT, et al. Identifying biological themes within lists of genes with EASE. *Genome Biol* 4: R70, 2003.
93. Huuhtanen RL, Blomqvist CP, Bohling TO, et al. Expression of cyclin A in soft tissue sarcomas correlates with tumor aggressiveness. *Cancer Res* 59: 2885-2890, 1999.
94. Huuhtanen RL, Blomqvist CP, Wiklund TA, et al. Comparison of the Ki-67 score and S-phase fraction as prognostic variables in soft-tissue sarcoma. *Br J Cancer* 79: 945-951, 1999.
95. Huuhtanen RL, Blomqvist CP, Wiklund TA, et al. S-phase fraction of 155 soft tissue sarcomas: correlation with clinical outcome. *Cancer* 77: 1815-1822, 1996.
96. Jensen V, Sorensen FB, Bentzen SM, et al. Proliferative activity (MIB-1 index) is an independent prognostic parameter in patients with high-grade soft tissue sarcomas of subtypes other than malignant fibrous histiocytomas: a retrospective immunohistological study including 216 soft tissue sarcomas. *Histopathology* 32: 536-546, 1998.
97. Joyama S, Ueda T, Shimizu K, et al. Chromosome rearrangement at 17q25 and xp11.2 in alveolar soft-part sarcoma: A case report and review of the literature. *Cancer* 86: 1246-1250, 1999.
98. Kang H, Enzinger FM, Breslin P, et al. Soft tissue sarcoma and military service in Vietnam: a case-control study. *J Natl Cancer Inst* 79: 693-699, 1987.
99. Kang HK, Weatherbee L, Breslin PP, et al. Soft tissue sarcomas and military service in Vietnam: a case comparison group analysis of hospital patients. *J Occup Med* 28: 1215-1218, 1986.
100. Kasper B, Gil T, D'Hondt V, et al. Novel treatment strategies for soft tissue sarcoma. *Crit Rev Oncol Hematol* 62: 9-15, 2007.
101. Kato H, Tjernberg A, Zhang W, et al. SYT associates with human SNF/SWI complexes and the C-terminal region of its fusion partner SSX1 targets histones. *J Biol Chem* 277: 5498-5505, 2002.
102. Kawai A, Woodruff J, Healey JH, et al. SYT-SSX gene fusion as a determinant of morphology and prognosis in synovial sarcoma. *N Engl J Med* 338: 153-160, 1998.
103. Kepka L, DeLaney TF, Suit HD, and Goldberg SI. Results of radiation therapy for unresected soft-tissue sarcomas. *Int J Radiat Oncol Biol Phys* 63: 852-859, 2005.
104. Kiricuta IC, and Dammrich J. Lymphangiosarcoma of arm after chronic lymphedema: a rare long-term complication after radical mastectomy in breast cancer patients. Case report and overview. *Strahlenther Onkol* 169: 291-295, 1993.
105. Kleinerman RA, Tucker MA, Tarone RE, et al. Risk of new cancers after radiotherapy in long-term survivors of retinoblastoma: an extended follow-up. *J Clin Oncol* 23: 2272-2279, 2005.
106. Knapp EL, Kransdorf MJ, and Letson GD. Diagnostic imaging update: soft tissue sarcomas. *Cancer Control* 12: 22-26, 2005.
107. Kony SJ, de Vathaire F, Chompret A, et al. Radiation and genetic factors in the risk of second malignant neoplasms after a first cancer in childhood. *Lancet* 350: 91-95, 1997.
108. Korf BR. Malignancy in neurofibromatosis type 1. *Oncologist* 5: 477-485, 2000.
109. Kraybill WG, Harris J, Spiro IJ, et al. Phase II study of neoadjuvant chemotherapy and radiation therapy in the management of high-risk, high-grade, soft tissue sarcomas of the extremities and body wall: Radiation Therapy Oncology Group Trial 9514. *J Clin Oncol* 24: 619-625, 2006.
110. Ladanyi M. Fusions of the SYT and SSX genes in synovial sarcoma. *Oncogene* 20: 5755-5762, 2001.
111. Ladanyi M, Antonescu CR, Leung DH, et al. Impact of SYT-SSX fusion type on the clinical behavior of synovial sarcoma: a multi-institutional retrospective study of 243 patients. *Cancer Res* 62: 135-140, 2002.

112. Larramendy ML, Kaur S, Svarvar C, et al. Gene copy number profiling of soft-tissue leiomyosarcomas by array-comparative genomic hybridization. *Cancer Genet Cytogenet* 169: 94-101, 2006.
113. Larramendy ML, Tarkkanen M, Blomqvist C, et al. Comparative genomic hybridization of malignant fibrous histiocytoma reveals a novel prognostic marker. *Am J Pathol* 151: 1153-1161, 1997.
114. Lasa MV, Mateo P, Bascon N, et al. Lymphangiosarcoma in a chronic lymphedematous limb: a case report. *Tumori* 81: 381-382, 1995.
115. LaTulippe E, Satagopan J, Smith A, et al. Comprehensive gene expression analysis of prostate cancer reveals distinct transcriptional programs associated with metastatic disease. *Cancer Res* 62: 4499-4506, 2002.
116. Le Cesne A, Judson I, Crowther D, et al. Randomized phase III study comparing conventional-dose doxorubicin plus ifosfamide versus high-dose doxorubicin plus ifosfamide plus recombinant human granulocyte-macrophage colony-stimulating factor in advanced soft tissue sarcomas: A trial of the European Organization for Research and Treatment of Cancer/Soft Tissue and Bone Sarcoma Group. *J Clin Oncol* 18: 2676-2684, 2000.
117. Lee YF, John M, Edwards S, et al. Molecular classification of synovial sarcomas, leiomyosarcomas and malignant fibrous histiocytomas by gene expression profiling. *Br J Cancer* 88: 510-515, 2003.
118. Levine EA. Prognostic factors in soft tissue sarcoma. *Semin Surg Oncol* 17: 23-32, 1999.
119. Lewis JJ, Leung D, Heslin M, et al. Association of local recurrence with subsequent survival in extremity soft tissue sarcoma. *J Clin Oncol* 15: 646-652, 1997.
120. Levy B, Mukherjee T, and Hirschhorn K. Molecular cytogenetic analysis of uterine leiomyoma and leiomyosarcoma by comparative genomic hybridization. *Cancer Genet Cytogenet* 121: 1-8, 2000.
121. Li FP, and Fraumeni JF, Jr. Soft-tissue sarcomas, breast cancer, and other neoplasms. A familial syndrome? *Ann Intern Med* 71: 747-752, 1969.
122. Limon J, Dal Cin P, and Sandberg AA. Translocations involving the X chromosome in solid tumors: presentation of two sarcomas with t(X;18)(q13;p11). *Cancer Genet Cytogenet* 23: 87-91, 1986.
123. Lindor NM, Furuichi Y, Kitao S, et al. Rothmund-Thomson syndrome due to RECQ4 helicase mutations: report and clinical and molecular comparisons with Bloom syndrome and Werner syndrome. *Am J Med Genet* 90: 223-228, 2000.
124. Listernick R, Charrow J, and Gutmann DH. Intracranial gliomas in neurofibromatosis type 1. *Am J Med Genet* 89: 38-44, 1999.
125. Lynch HT, Brand RE, Hogg D, et al. Phenotypic variation in eight extended CDKN2A germline mutation familial atypical multiple mole melanoma-pancreatic carcinoma-prone families: the familial atypical mole melanoma-pancreatic carcinoma syndrome. *Cancer* 94: 84-96, 2002.
126. Lynch HT, Deters CA, Hogg D, et al. Familial sarcoma: challenging pedigrees. *Cancer* 98: 1947-1957, 2003.
127. Malkin D. p53 and the Li-Fraumeni syndrome. *Cancer Genet Cytogenet* 66: 83-92, 1993.
128. Matsui Y, Ueda T, Kubo T, et al. A novel type of EWS-CHOP fusion gene in myxoid liposarcoma. *Biochem Biophys Res Commun* 348: 437-440, 2006.
129. McLaughlin JK, and Lipworth L. A critical review of the epidemiologic literature on health effects of occupational exposure to vinyl chloride. *J Epidemiol Biostat* 4: 253-275, 1999.
130. Medina Arana V, Barrios del Pino Y, Garcia-Castro C, et al. Highly aggressive leiomyosarcoma associated with Lynch II syndrome: increasing the range of extracolonic cancers related with hereditary non-polyposis colonic cancer. *Ann Oncol* 13: 807-808, 2002.
131. Meis-Kindblom JM, Bjerkehage B, Bohling T, et al. Morphologic review of 1000 soft tissue sarcomas from the Scandinavian Sarcoma Group (SSG) Register. The peer-review committee experience. *Acta Orthop Scand Suppl* 285: 18-26, 1999.
132. Merimsky O, Kollender Y, Issakov J, et al. Multiple primary malignancies in association with soft tissue sarcomas. *Cancer* 91: 1363-1371, 2001.
133. Mertens F, Stromberg U, Mandahl N, et al. Prognostically important chromosomal aberrations in soft tissue sarcomas: a report of the Chromosomes and Morphology (CHAMP) Study Group. *Cancer Res* 62: 3980-3984, 2002.
134. Mertens F, Stromberg U, Rydholm A, et al. Prognostic significance of chromosome aberrations in high-grade soft tissue sarcomas. *J Clin Oncol* 24: 315-320, 2006.
135. Mitelman F, Johansson B, and Mertens F. The impact of translocations and gene fusions on cancer causation. *Nat Rev Cancer* 7: 233-245, 2007.
136. Mocellin S, Rossi CR, Brandes A, and Nitti D. Adult soft tissue sarcomas: conventional therapies and molecularly targeted approaches. *Cancer Treat Rev* 32: 9-27, 2006.
137. Myhre-Jensen O. A consecutive 7-year series of 1331 benign soft tissue tumours. Clinicopathologic data. Comparison with sarcomas. *Acta Orthop Scand* 52: 287-293, 1981.
138. Naeem R, Lux ML, Huang SF, et al. Ring chromosomes in dermatofibrosarcoma protuberans are composed of interspersed sequences from chromosomes 17 and 22. *Am J Pathol* 147: 1553-1558, 1995.
139. Nagayama S, Katagiri T, Tsunoda T, et al. Genome-wide analysis of gene expression in synovial sarcomas using a cDNA microarray. *Cancer Res* 62: 5859-5866, 2002.
140. Neglia JP, Friedman DL, Yasui Y, et al. Second malignant neoplasms in five-year survivors of childhood cancer: childhood cancer survivor study. *J Natl Cancer Inst* 93: 618-629, 2001.



141. Nielsen OS, Cummings B, O'Sullivan B, et al. Preoperative and postoperative irradiation of soft tissue sarcomas: effect of radiation field size. *Int J Radiat Oncol Biol Phys* 21: 1595-1599, 1991.
142. Nielsen TO. Microarray analysis of sarcomas. *Adv Anat Pathol* 13: 166-173, 2006.
143. Nielsen TO, West RB, Linn SC, et al. Molecular characterisation of soft tissue tumours: a gene expression study. *Lancet* 359: 1301-1307, 2002.
144. Nilsson B, Bumming P, Meis-Kindblom JM, et al. Gastrointestinal stromal tumors: the incidence, prevalence, clinical course, and prognostication in the preimatinib mesylate era—a population-based study in western Sweden. *Cancer* 103: 821-829, 2005.
145. Nilsson G, Skytting B, Xie Y, et al. The SYT-SSX1 variant of synovial sarcoma is associated with a high rate of tumor cell proliferation and poor clinical outcome. *Cancer Res* 59: 3180-3184, 1999.
146. Noguchi T, Dobashi Y, Minehara H, et al. Involvement of cyclins in cell proliferation and their clinical implications in soft tissue smooth muscle tumors. *Am J Pathol* 156: 2135-2147, 2000.
147. Nordsmark M, Alsner J, Keller J, et al. Hypoxia in human soft tissue sarcomas: adverse impact on survival and no association with p53 mutations. *Br J Cancer* 84: 1070-1075, 2001.
148. Nordsmark M, Hoyer M, Keller J, et al. The relationship between tumor oxygenation and cell proliferation in human soft tissue sarcomas. *Int J Radiat Oncol Biol Phys* 35: 701-708, 1996.
149. Nunez Nunez R, Galan Gomez E, Moreno Hurtado C, et al. [Familial adenomatous polyposis: Gardner's syndrome]. *Cir Pediatr* 19: 111-114, 2006.
150. O'Sullivan B, Davis AM, Turcotte R, et al. Preoperative versus postoperative radiotherapy in soft-tissue sarcoma of the limbs: a randomised trial. *Lancet* 359: 2235-2241, 2002.
151. Oda Y, Ohishi Y, Saito T, et al. Nuclear expression of Y-box-binding protein-1 correlates with P-glycoprotein and topoisomerase II alpha expression, and with poor prognosis in synovial sarcoma. *J Pathol* 199: 251-258, 2003.
152. Ohguri T, Hisaoka M, Kawauchi S, et al. Cytogenetic analysis of myxoid liposarcoma and myxofibrosarcoma by array-based comparative genomic hybridisation. *J Clin Pathol* 59: 978-983, 2006.
153. Orlow I, Drobnjak M, Zhang ZF, et al. Alterations of INK4A and INK4B genes in adult soft tissue sarcomas: effect on survival. *J Natl Cancer Inst* 91: 73-79, 1999.
154. Orndal C, Mandahl N, Rydholm A, et al. Chromosomal evolution and tumor progression in a myxoid liposarcoma. *Acta Orthop Scand* 61: 99-105, 1990.
155. Orndal C, Mandahl N, Rydholm A, et al. Chromosome aberrations and cytogenetic intratumor heterogeneity in chondrosarcomas. *J Cancer Res Clin Oncol* 120: 51-56, 1993.
156. Orndal C, Mandahl N, Willen H, et al. Cytogenetic evolution in primary tumors, local recurrences, and pulmonary metastases of two soft tissue sarcomas. *Clin Exp Metastasis* 11: 401-408, 1993.
157. Orndal C, Rydholm A, Willen H, et al. Cytogenetic intratumor heterogeneity in soft tissue tumors. *Cancer Genet Cytogenet* 78: 127-137, 1994.
158. Panagopoulos I, Lassen C, Isaksson M, et al. Characteristic sequence motifs at the breakpoints of the hybrid genes FUS/CHOP, EWS/CHOP and FUS/ERG in myxoid liposarcoma and acute myeloid leukemia. *Oncogene* 15: 1357-1362, 1997.
159. Paulussen M, Ahrens S, Lehnert M, et al. Second malignancies after ewing tumor treatment in 690 patients from a cooperative German/Austrian/Dutch study. *Ann Oncol* 12: 1619-1630, 2001.
160. Pedeutour F, Simon MP, Minoletti F, et al. Ring 22 chromosomes in dermatofibrosarcoma protuberans are low-level amplifiers of chromosome 17 and 22 sequences. *Cancer Res* 55: 2400-2403, 1995.
161. Perani M, Ingram CJ, Cooper CS, et al. Conserved SNH domain of the proto-oncoprotein SYT interacts with components of the human chromatin remodeling complexes, while the QPGY repeat domain forms homo-oligomers. *Oncogene* 22: 8156-8167, 2003.
162. Perniciaro C. Gardner's syndrome. *Dermatol Clin* 13: 51-56, 1995.
163. Pisters PW, Harrison LB, Leung DH, et al. Long-term results of a prospective randomized trial of adjuvant brachytherapy in soft tissue sarcoma. *J Clin Oncol* 14: 859-868, 1996.
164. Polo SE, and Almouzni G. Histone metabolic pathways and chromatin assembly factors as proliferation markers. *Cancer Lett* 220: 1-9, 2005.
165. Pratt CB, Meyer WH, Luo X, et al. Second malignant neoplasms occurring in survivors of osteosarcoma. *Cancer* 80: 960-965, 1997.
166. Ramanathan RC, A'Hern R, Fisher C, and Thomas JM. Modified staging system for extremity soft tissue sarcomas. *Ann Surg Oncol* 6: 57-69, 1999.
167. Ramaswamy S, Ross KN, Lander ES, and Golub TR. A molecular signature of metastasis in primary solid tumors. *Nat Genet* 33: 49-54, 2003.
168. Randall RL, Albritton KH, Ferney BJ, and Layfield L. Malignant fibrous histiocytoma of soft tissue: an abandoned diagnosis. *Am J Orthop* 33: 602-608, 2004.
169. Rasmussen SA, and Friedman JM. NF1 gene and neurofibromatosis 1. *Am J Epidemiol* 151: 33-40, 2000.
170. Rosenberg SA, Tepper J, Glatstein E, et al. The treatment of soft-tissue sarcomas of the extremities: prospective randomized evaluations of (1) limb-sparing surgery plus radiation therapy compared with amputation and (2) the role of adjuvant chemotherapy. *Ann Surg* 196: 305-315, 1982.
171. Rydholm A. Management of patients with soft-tissue tumors. Strategy developed at a regional oncology center. *Acta Orthop Scand Suppl* 203: 13-77, 1983.



172. Rydholm A, and Berg NO. Size, site and clinical incidence of lipoma. Factors in the differential diagnosis of lipoma and sarcoma. *Acta Orthop Scand* 54: 929-934, 1983.
173. Saal LH, Troein C, Vallon-Christersson J, et al. Bio-Array Software Environment (BASE): a platform for comprehensive management and analysis of microarray data. *Genome Biol* 3: SOFTWARE0003, 2002.
174. Sabah M, Cummins R, Leader M, and Kay E. Leiomyosarcoma and malignant fibrous histiocytoma share similar allelic imbalance pattern at 9p. *Virchows Arch* 446: 251-258, 2005.
175. Saeed AI, Sharov V, White J, et al. TM4: a free, open-source system for microarray data management and analysis. *Biotechniques* 34: 374-378, 2003.
176. Sanborn RE, and Blanke CD. Gastrointestinal stromal tumors and the evolution of targeted therapy. *Clin Adv Hematol Oncol* 3: 647-657, 2005.
177. Sandberg AA, and Bridge JA. Updates on the cytogenetics and molecular genetics of bone and soft tissue tumors. Synovial sarcoma. *Cancer Genet Cytogenet* 133: 1-23, 2002.
178. Schutte J, Mouridsen HT, Stewart W, et al. Ifosfamide plus doxorubicin in previously untreated patients with advanced soft tissue sarcoma. The EORTC Soft Tissue and Bone Sarcoma Group. *Eur J Cancer* 26: 558-561, 1990.
179. Segal NH, Pavlidis P, Antonescu CR, et al. Classification and subtype prediction of adult soft tissue sarcoma by functional genomics. *Am J Pathol* 163: 691-700, 2003.
180. Segal NH, Pavlidis P, Noble WS, et al. Classification of clear-cell sarcoma as a subtype of melanoma by genomic profiling. *J Clin Oncol* 21: 1775-1781, 2003.
181. Serraino D, Franceschi S, La Vecchia C, and Carbone A. Occupation and soft-tissue sarcoma in northeastern Italy. *Cancer Causes Control* 3: 25-30, 1992.
182. Shapeero LG, Vanel D, Verstraete KL, and Bloem JL. Fast magnetic resonance imaging with contrast for soft tissue sarcoma viability. *Clin Orthop Relat Res* 212-227, 2002.
183. Shapiro DN, Sublett JE, Li B, et al. Fusion of PAX3 to a member of the forkhead family of transcription factors in human alveolar rhabdomyosarcoma. *Cancer Res* 53: 5108-5112, 1993.
184. Shih T, and Lindley C. Bevacizumab: an angiogenesis inhibitor for the treatment of solid malignancies. *Clin Ther* 28: 1779-1802, 2006.
185. Sijmons R, Hofstra R, Hollema H, et al. Inclusion of malignant fibrous histiocytoma in the tumour spectrum associated with hereditary non-polyposis colorectal cancer. *Genes Chromosomes Cancer* 29: 353-355, 2000.
186. Simon MP, Pedetour F, Sirvent N, et al. Dereglulation of the platelet-derived growth factor B-chain gene via fusion with collagen gene COL1A1 in dermatofibrosarcoma protuberans and giant-cell fibroblastoma. *Nat Genet* 15: 95-98, 1997.
187. Sjoblom T, Shimizu A, O'Brien KP, et al. Growth inhibition of dermatofibrosarcoma protuberans tumors by the platelet-derived growth factor receptor antagonist ST1571 through induction of apoptosis. *Cancer Res* 61: 5778-5783, 2001.
188. Skubitz KM, and Skubitz AP. Characterization of sarcomas by means of gene expression. *J Lab Clin Med* 144: 78-91, 2004.
189. Spira AI, and Ettinger DS. The use of chemotherapy in soft-tissue sarcomas. *Oncologist* 7: 348-359, 2002.
190. Sreekantaiah C, Ladanyi M, Rodriguez E, and Chaganti RS. Chromosomal aberrations in soft tissue tumors. Relevance to diagnosis, classification, and molecular mechanisms. *Am J Pathol* 144: 1121-1134, 1994.
191. Stojadinovic A, Leung DH, Allen P, et al. Primary adult soft tissue sarcoma: time-dependent influence of prognostic variables. *J Clin Oncol* 20: 4344-4352, 2002.
192. Tanabe KK, Pollock RE, Ellis LM, et al. Influence of surgical margins on outcome in patients with preoperatively irradiated extremity soft tissue sarcomas. *Cancer* 73: 1652-1659, 1994.
193. Tateishi U, Hasegawa T, Yamamoto S, et al. Incidence of multiple primary malignancies in a cohort of adult patients with soft tissue sarcoma. *Jpn J Clin Oncol* 35: 444-452, 2005.
194. Thaete C, Brett D, Monaghan P, et al. Functional domains of the SYT and SYT-SSX synovial sarcoma translocation proteins and co-localization with the SNF protein BRM in the nucleus. *Hum Mol Genet* 8: 585-591, 1999.
195. Torres MA, Ballo MT, Butler CE, et al. Management of locally recurrent soft-tissue sarcoma after prior surgery and radiation therapy. *Int J Radiat Oncol Biol Phys* 2007.
196. Tos AP. Classification of pleomorphic sarcomas: where are we now? *Histopathology* 48: 51-62, 2006.
197. Trojani M, Contesso G, Coindre JM, et al. Soft-tissue sarcomas of adults; study of pathological prognostic variables and definition of a histopathological grading system. *Int J Cancer* 33: 37-42, 1984.
198. Trovik CS. Local recurrence of soft tissue sarcoma. A Scandinavian Sarcoma Group Project. *Acta Orthop Scand Suppl* 72: 1-31, 2001.
199. Trovik CS, Bauer HC, Alvegard TA, et al. Surgical margins, local recurrence and metastasis in soft tissue sarcomas: 559 surgically-treated patients from the Scandinavian Sarcoma Group Register. *Eur J Cancer* 36: 710-716, 2000.
200. Turc-Carel C, Aurias A, Mugneret F, et al. Chromosomes in Ewing's sarcoma. I. An evaluation of 85 cases of remarkable consistency of t(11;22)(q24;q12). *Cancer Genet Cytogenet* 32: 229-238, 1988.
201. Turc-Carel C, Dal Cin P, Limon J, et al. Involvement of chromosome X in primary cytogenetic change in human neoplasia: nonrandom translocation in synovial sarcoma. *Proc Natl Acad Sci U S A* 84: 1981-1985, 1987.

202. Turc-Carel C, Limon J, Dal Cin P, et al. Cytogenetic studies of adipose tissue tumors. II. Recurrent reciprocal translocation t(12;16)(q13;p11) in myxoid liposarcomas. *Cancer Genet Cytogenet* 23: 291-299, 1986.
203. Tuveson DA, and Fletcher JA. Signal transduction pathways in sarcoma as targets for therapeutic intervention. *Curr Opin Oncol* 13: 249-255, 2001.
204. Ueda T, Yoshikawa H, Mori S, et al. Influence of local recurrence on the prognosis of soft-tissue sarcomas. *J Bone Joint Surg Br* 79: 553-557, 1997.
205. Van Glabbeke M, van Oosterom AT, Oosterhuis JW, et al. Prognostic factors for the outcome of chemotherapy in advanced soft tissue sarcoma: an analysis of 2,185 patients treated with anthracycline-containing first-line regimens--a European Organization for Research and Treatment of Cancer Soft Tissue and Bone Sarcoma Group Study. *J Clin Oncol* 17: 150-157, 1999.
206. van Oosterom AT, Judson I, Verweij J, et al. Safety and efficacy of imatinib (STI571) in metastatic gastrointestinal stromal tumours: a phase I study. *Lancet* 358: 1421-1423, 2001.
207. Varma DG. Imaging of soft-tissue sarcomas. *Curr Oncol Rep* 2: 487-490, 2000.
208. Weitz J, Antonescu CR, and Brennan MF. Localized extremity soft tissue sarcoma: improved knowledge with unchanged survival over time. *J Clin Oncol* 21: 2719-2725, 2003.
209. Weng WH, Ahlen J, Lui WO, et al. Gain of 17q in malignant fibrous histiocytoma is associated with a longer disease-free survival and a low risk of developing distant metastasis. *Br J Cancer* 89: 720-726, 2003.
210. Weng WH, Wejde J, Ahlen J, et al. Characterization of large chromosome markers in a malignant fibrous histiocytoma by spectral karyotyping, comparative genomic hybridization (CGH), and array CGH. *Cancer Genet Cytogenet* 150: 27-32, 2004.
211. Wilson AN, Davis A, Bell RS, et al. Local control of soft tissue sarcoma of the extremity: the experience of a multidisciplinary sarcoma group with definitive surgery and radiotherapy. *Eur J Cancer* 30A: 746-751, 1994.
212. Vogelstein B, and Kinzler KW. p53 function and dysfunction. *Cell* 70: 523-526, 1992.
213. Woods JS, Polissar L, Severson RK, et al. Soft tissue sarcoma and non-Hodgkin's lymphoma in relation to phenoxyherbicide and chlorinated phenol exposure in western Washington. *J Natl Cancer Inst* 78: 899-910, 1987.
214. Xie Y, Skytting B, Nilsson G, et al. The SYT-SSX1 fusion type of synovial sarcoma is associated with increased expression of cyclin A and D1. A link between t(X;18)(p11.2; q11.2) and the cell cycle machinery. *Oncogene* 21: 5791-5796, 2002.
215. Yang JC, Chang AE, Baker AR, et al. Randomized prospective study of the benefit of adjuvant radiation therapy in the treatment of soft tissue sarcomas of the extremity. *J Clin Oncol* 16: 197-203, 1998.
216. Yang YH, Dudoit S, Luu P, et al. Normalization for cDNA microarray data: a robust composite method addressing single and multiple slide systematic variation. *Nucleic Acids Res* 30: e15, 2002.
217. Yoo J, Robinson RA, and Lee JY. H-ras and K-ras gene mutations in primary human soft tissue sarcoma: concomitant mutations of the ras genes. *Mod Pathol* 12: 775-780, 1999.
218. Yu CE, Oshima J, Fu YH, et al. Positional cloning of the Werner's syndrome gene. *Science* 272: 258-262, 1996.
219. Zagars GK, and Ballo MT. Significance of dose in postoperative radiotherapy for soft tissue sarcoma. *Int J Radiat Oncol Biol Phys* 56: 473-481, 2003.
220. Zagars GK, Ballo MT, Pisters PW, et al. Prognostic factors for patients with localized soft-tissue sarcoma treated with conservation surgery and radiation therapy: an analysis of 225 patients. *Cancer* 97: 2530-2543, 2003.

