



# LUND UNIVERSITY

## Excellent long-term results of the Müller acetabular reinforcement ring in primary total hip arthroplasty.

Sirka, Aurimas; Clauss, Martin; Tarasevicius, Sarunas; Wingstrand, Hans; Stucinskas, Justinas; Robertsson, Otto; Emil Ochsner, Peter; Ilchmann, Thomas

*Published in:*  
Acta Orthopaedica

*DOI:*  
[10.3109/17453674.2015.1103607](https://doi.org/10.3109/17453674.2015.1103607)

2016

[Link to publication](#)

### *Citation for published version (APA):*

Sirka, A., Clauss, M., Tarasevicius, S., Wingstrand, H., Stucinskas, J., Robertsson, O., Emil Ochsner, P., & Ilchmann, T. (2016). Excellent long-term results of the Müller acetabular reinforcement ring in primary total hip arthroplasty. *Acta Orthopaedica*, 87. <https://doi.org/10.3109/17453674.2015.1103607>

*Total number of authors:*  
8

### **General rights**

Unless other specific re-use rights are stated the following general rights apply:  
Copyright and moral rights for the publications made accessible in the public portal are retained by the authors and/or other copyright owners and it is a condition of accessing publications that users recognise and abide by the legal requirements associated with these rights.

- Users may download and print one copy of any publication from the public portal for the purpose of private study or research.
- You may not further distribute the material or use it for any profit-making activity or commercial gain
- You may freely distribute the URL identifying the publication in the public portal


Read more about Creative commons licenses: <https://creativecommons.org/licenses/>

### **Take down policy**

If you believe that this document breaches copyright please contact us providing details, and we will remove access to the work immediately and investigate your claim.

LUND UNIVERSITY

PO Box 117  
221 00 Lund  
+46 46-222 00 00



## Excellent long-term results of the Müller acetabular reinforcement ring in primary total hip arthroplasty

Aurimas Sirka, Martin Clauss, Sarunas Tarasevicius, Hans Wingstrand, Justinas Stucinskas, Otto Robertsson, Peter Emil Ochsner & Thomas Ilchmann

**To cite this article:** Aurimas Sirka, Martin Clauss, Sarunas Tarasevicius, Hans Wingstrand, Justinas Stucinskas, Otto Robertsson, Peter Emil Ochsner & Thomas Ilchmann (2015): Excellent long-term results of the Müller acetabular reinforcement ring in primary total hip arthroplasty, Acta Orthopaedica, DOI: [10.3109/17453674.2015.1103607](https://doi.org/10.3109/17453674.2015.1103607)

**To link to this article:** <http://dx.doi.org/10.3109/17453674.2015.1103607>



© 2015 The Author(s). Published by Taylor & Francis on behalf of the Nordic Orthopedic Federation.



Published online: 16 Oct 2015.



Submit your article to this journal [↗](#)



Article views: 240



View related articles [↗](#)



View Crossmark data [↗](#)

# Excellent long-term results of the Müller acetabular reinforcement ring in primary total hip arthroplasty

A prospective study on radiology and survival of 321 hips with a mean follow-up of 11 years

Aurimas SIRKA<sup>1,3</sup>, Martin CLAUSS<sup>1</sup>, Sarunas TARASEVICIUS<sup>2</sup>, Hans WINGSTRAND<sup>3</sup>, Justinas STUCINSKAS<sup>1,2</sup>, Otto ROBERTSSON<sup>3</sup>, Peter Emil OCHSNER<sup>1</sup>, and Thomas ILCHMANN<sup>1,4</sup>

<sup>1</sup> Department of Orthopedics and Trauma Surgery, Kantonsspital Baselland, Liestal, Switzerland; <sup>2</sup> Department of Orthopedics, Lithuanian University of Health Sciences, Kaunas, Lithuania; <sup>3</sup> Department of Orthopedics, Lund University and Lund University Hospital, Lund, Sweden; <sup>4</sup> Department of Orthopedics, Hirslanden Klinik Birshof, Münchenstein, Switzerland.

Correspondence: aurimas.sirka@ismuni.it

Submitted 2015-03-19. Accepted 2015-08-18

**Background and purpose** — The original Müller acetabular reinforcement ring (ARR) shows favorable medium-term results for acetabular reconstruction in total hip arthroplasty, where it is used when the acetabular bone stock is deficient. However, there are no data regarding long-term survival of the device. We therefore investigated long-term survival and analyzed radiological modes of failure.

**Patients and methods** — Between 1984 and 2002, 321 consecutive primary arthroplasties using an ARR were performed in 291 patients. The mean follow-up time was 11 (0–25) years, and 24 hips were lost to follow-up. For survival analysis, we investigated 321 hips and the end of the follow-up was the date of revision, date of death, or the last patient contact date with implant still in situ. Radiological assessment was performed for 160 hips with a minimum of 10 years of follow-up and with radiographs of sufficient quality. It included evaluation of osteolysis, migration, and loosening.

**Results** — 12 ARR THAs were revised: 1 isolated ARR revision for aseptic loosening, 4 revisions of the ARR and the stem for aseptic loosening, 6 for infection, and 1 for recurrent dislocation. The cumulative revision rate for all components, for any reason, at 20 years was 15% (95% CI: 10–22), while for the ARR only it was 7% (95% CI: 4–12) for any reason and 3.4% (95% CI: 1–9) for aseptic loosening. 21 (13%) of 160 ARR THAs examined had radiological changes: 7 had osteolysis but were not loose, and 14 were radiologically loose but were not painful and not revised.

**Interpretation** — Our data suggest that the long-term survival of the ARR is excellent.

During total hip arthroplasty (THA), fixation of the acetabular component can be a problem when acetabular bone stock shows quantitative or qualitative bone loss (Schatzker et al. 1984, Haentjens et al. 1986, Rosson et al. 1992, Panski and Tauber 1997, Stockl et al. 1997). The acetabular reinforcement ring (ARR) was originally developed for acetabular revisions with small defects. Following this rationale, we used it from 1984 onwards in complex primary hip replacements when acetabular bone quality was poor (Gill et al. 1998), and even occasionally in standard hip replacement. Despite the fact that the ARR has been used for the past 3 to 4 decades, especially in central Europe (Schatzker et al. 1984, Haentjens et al. 1986, Rosson et al. 1992, Gill et al. 1998, Schlegel et al. 2006), there are no data on long-term results. To our knowledge, no other previous study has investigated long-term implant survival data for the use of the ARR in primary THA (Aebi et al. 1989, Gill et al. 1998, Korovessis et al. 1999, Schlegel et al. 2006).

The aim of this study was to assimilate and present long-term data and radiological results.

## Patients and methods

Between 1984 and 2002, 1,816 primary THAs were performed at Kantonsspital Baselland, Liestal, and followed prospectively using the in-house register, with a clinical and radiological examination every 5 years. About one-sixth (321) of all hips were treated with the ARR as the acetabular component. The indication for ARR use was bone deficiency, especially of the acetabular roof.



Figure 1. The ARR (view inside the ring). In the present study, ARRs made of steel and ARRs made of titanium were used. The shape remained the same.

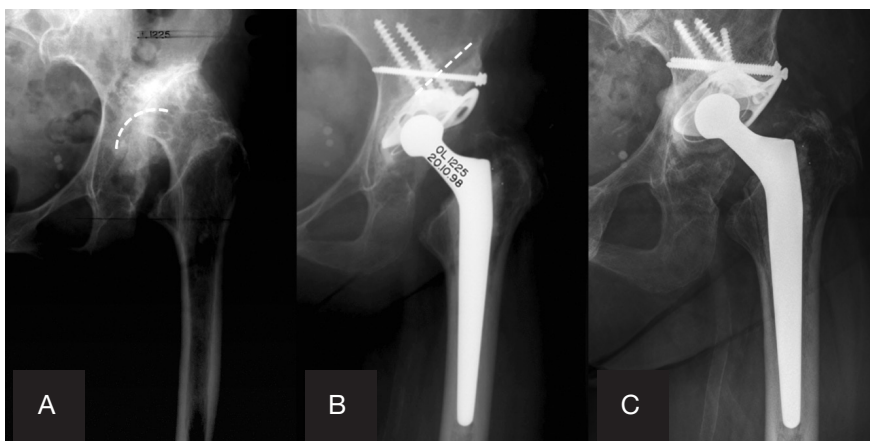


Figure 2. 70-year old female with hip dysplasia (Crowe 4). A. Preoperative radiograph. Dotted line: reaming for the ARR. B. 1 year postoperatively. Dotted line shows border between acetabular bone stock and shelf graft with a bone block out of the femoral head. Horizontal screws to fix shelf graft, oblique screws to fix ARR. C. 15 years postoperatively. Unchanged integration of ARR without any screws broken or radiolucent line. Integrated shelf graft. The patient died shortly afterwards. Technical note: in dysplastic acetabula, a segment of the resected femoral head is fixed with horizontal screws to complete the acetabular edge. The ARR is placed closely lateral to the teardrop figure. It is fixed tightly on the bone stock with 2–4 cancellous screws directed towards the center of the iliosacral joint. Remaining cavities are filled with autologous bone.

The implant used in all operations was the original ARR (formerly Protek, now Zimmer, Winterthur, Switzerland). The ring covered four-fifths of a hemisphere and the shape remained unchanged during the whole study period (Figure 1) (Ochsner 2003). The first implants were made of steel, but since January 1987 they have been made of titanium with 3 different surface roughnesses (Table 1). 286 all-polyethylene cups (Müller low-profile) and 35 PE cups with metal bearing

surface (Zimmer Metasul) were cemented inside the ring. The preferred head sizes were 28 mm and 32 mm. In cases where the acetabulum was small, as in hip dysplasia, 22-mm heads were used (Table 1). The preferred stem system used was a variant of the cemented Müller straight stem (Müller and Virtec) and in the case of hip dysplasia, a cemented monobloc stem was used (CDH, Protek, Zimmer) (Table 1). Until 1995, Sulfix-6 (Sulzer) bone cement was used, from 1995 until 1997 Sulfix-60 (Sulzer) was used, and from 1997 onwards Palacos R was used (Heraeus, Weinheim, Germany).

All patients were operated in a standardized manner with a lateral transgluteal approach in supine position. The ARR was inserted into the acetabulum, aiming for a press-fit. In addition, it was fixed using 2–5 cancellous bone screws oriented in the direction of the iliosacral joint (Figure 2). Steel screws were used for the ARRs made of steel and titanium screws were used for the ARRs made of titanium.

For survival analysis, we investigated all 321 THAs with ARR implanted in 291 patients. All revisions were documented, including their indications. Of 291 patients (321 hips) included in the survival analysis, there were 104 males and 187 females with a mean age of 67 (31–93) (SD 12) years. The indications were osteoarthritis (OA) in 53% (172 hips). The remaining 47% had a diagnosis that might affect the fixation of the cup: hip dysplasia in 16% (51 hips, 25 of them Crowe type-1, 17 type-2, 3 type-3, and 6 type-4), avascular necrosis in 11% (34 hips), fracture in 6% (19 hips), rheumatoid arthritis in 4% (14 hips), acetabular protrusion in 3% (9 hips), tumour in 2% (7 hips), posttraumatic arthritis in 2% (7 hips), epiphyseolysis in 1% (4 hips), Perthes' disease in 1% (3 hips), and Paget's disease (1 hip). The average length of

Table 1. Implant specifications

Implant specifications	n
<b>ARR material</b>	
steel	10
titanium, smooth-blasted	154
titanium, rough-blasted, first generation	61
titanium, rough-blasted, second generation	96
<b>Head material and diameter, mm</b>	
steel 32	5
28	4
22	27
CoCr 32	21
28	39
22	29
ceramic 32	49
28	147
<b>Stem type</b>	
Müller straight stem	123
Müller CDH stem	56
Müller SL cemented	66
Müller SL straight stem uncemented	10
Virtec straight stem	62
Spotorno straight stem, CLS	3
Wagner SL1 revision stem	1

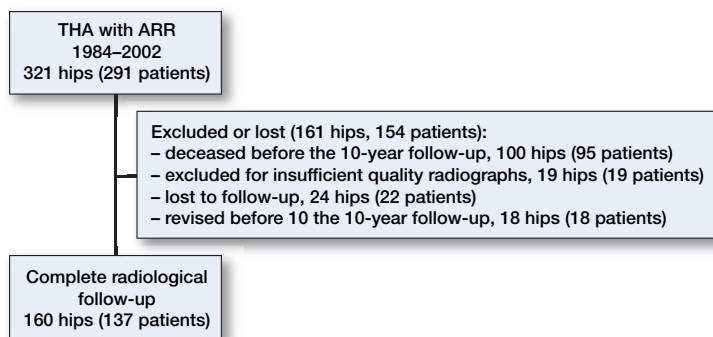


Figure 3. Flow chart of patients included in the radiological analysis.

follow-up for survival analysis was 11 (0–25) (SD 6.1) years. For survival analysis, failure was defined as revision of any component for any reason. 180 of 291 patients (56%) died during follow-up, for reasons unrelated to surgery. Patients' death date was obtained from a regional death register database. Of the 111 patients who were still alive in 2012, 70 had scheduled follow-up. The remaining 41 were contacted by telephone and none of these patients had been revised since the last in-house clinical check-up. The end of the follow-up was the date of death or the last date of patient contact with implant still in situ. 22 patients (with 24 THAs) could not be reached; their mean follow-up time was 4.7 (0.1–9.3) years and the end of follow-up in these patients was defined as the date of the last in-house radiographic examination (Figure 3).

137 patients (160 hips) had a radiographic follow-up of at least 10 years and were included in the long-term (> 10-year) radiographic analysis. Standardized anterior-posterior pelvic view radiographs were taken and investigated by one of the authors (AS) to determine signs of loosening and osteolysis on both the acetabular side and the femoral side. A Müller ARR was classified as loose if there was screw breakage, if a complete progressive radiolucent line around the screws was visible, or if migration of more than 2 mm was observed (Siebenrock et al. 2005). Osteolysis around the Müller ARR was defined as the radiographic appearance of any focal area of bone resorption greater or equal to 2 mm that was not evident on the radiograph obtained immediately after surgery (Zicat et al. 1995). On the acetabular side, radiolucent lines and/or signs of osteolysis were assessed in the 3 zones and the date of the first radiographic appearance was noted (DeLee et al. 1976). Migration was measured as the vertical displacement of the center of the cup relative to the inter-teardrop line, and medial migration was measured as the horizontal displacement of the cup center relative to the ipsilateral teardrop line (Nunn et al. 1989).

Radiolucent lines around the femoral component were assessed in the 7 Gruen zones and defined as being osteolysis or not. Newly developed endosteal bone loss with a diameter of greater than 3 mm, either with scalloping or with a bead-shaped lucency at the cement-bone interface, was defined as being osteolysis (Joshi et al. 1998). Radiographic loosening of

Table 2. Overall reasons for revision

Reason for revision (n = 28)	n
Aseptic loosening with revision of ARR:	
ARR and stem	4
isolated ARR	1
Infection (both components)	6
Recurrent dislocation (both components)	1
Stem and PE without revision of ARR	7
Stem only	9

PE: polyethylene.

the femoral component was defined as extension of the osteolytic zones to more than 50% of the cement-bone interface in at least 4 of the 7 zones.

All radiographs were analyzed using DICOM software (Agfa IMPAX v6.5.3.117; Agfa HealthCare, Mortsel, Belgium). Radiographic measurements were performed using IMAGIC IMS software (Imagic Company, Glattbrugg, Switzerland). Measurements were calibrated with the known true femoral head size.

### Statistics

Of the 291 patients, 30 had bilateral surgeries. Both hips were included, as it has been shown that bilaterality is not an important issue when estimating survival after hip and knee arthroplasty (Robertsson and Ranstam 2003, Lie et al. 2004). Kaplan-Meier survivorship analysis was performed to determine the cumulative revision rate (CRR) of the ARR for aseptic loosening, of the ARR for any reason, and of any component for any reason as endpoint. The time to revision was calculated as the time between the date of implantation and the date of revision. Patients without any revision were censored at the date of last contact or death. Greenwood's formula was used to determine 95% confidence intervals (CIs) around the survivorship curves. Any p-value less than 0.05 was considered significant. We used SPSS software version 21.0 for the calculations.

### Results

At final follow-up, 28 hips had been revised (Table 2). Concerning ARR survival, there were 5 ARRs (1.6%) that had been revised for aseptic loosening after 10, 10, 11, 16, and 25 years (mean 15 years). The diagnosis for these 5 cases was OA in 4 cases and DDH (Crowe 2) in 1. 1 was made of steel, 2 were made of smooth-blasted titanium, and 2 were made of rough-blasted titanium. 1 had a Metasul insert. At 20 years, the CRR for aseptic loosening of the ARR was 3.4% (CI: 1–9). 6 ARRs were revised for infection after a mean of 6 (2–15) years and 1 was revised for recurrent dislocation after 7 years. In total, 12 ARRs were revised for any reason; at 20

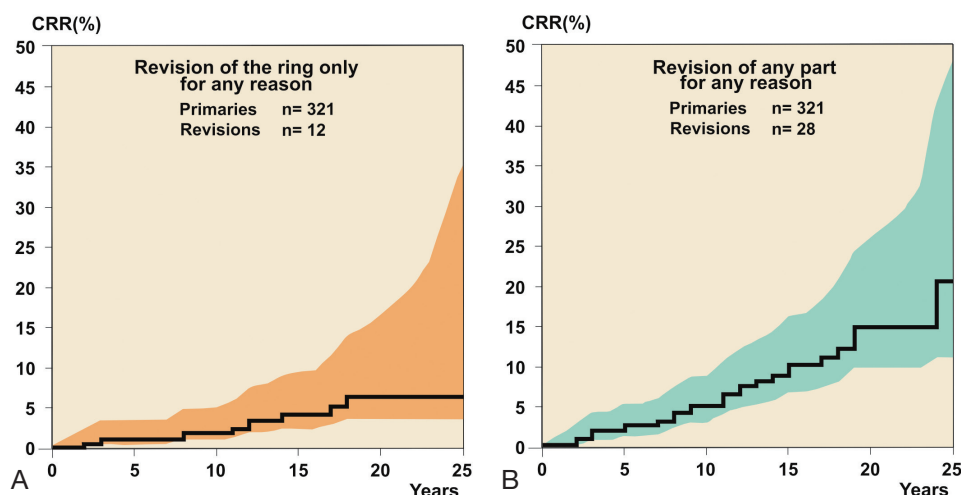


Figure 4. A. Cumulative revision rate (CRR) of the ARR with revision for any reason as endpoint. 12 ARRs had been revised, 5 of them for aseptic loosening. At 20 years, the CRR for the ARR with revision for any reason was 7% (95% CI: 4–12). B. Cumulative revision rate (CRR) of all hips with revision of the cup and/or stem for any reason as endpoint. At 20 years, the CRR was 15% (95% CI: 10–22).

years, the overall CRR of the ARR for any reason was 7% (CI: 4–12) (Table 2 and Figure 4).

A worst-case scenario was calculated for the 24 hips that were lost to follow-up, assuming that the ring had been revised 1 month after the last contact. Inclusion of these together with any other reasons for revision of the ARR resulted in a CRR at 20 years of 15% (CI: 10–22).

In 7 cases, the PE insert was changed during stem revision (at a mean of 8 (1–21) years) because of incompatible head size. The ARR remained in place and none of these THAs had radiological changes. 9 hips had an isolated stem revision. In total, 28 hips were revised after a mean of 10 (1–25) years. The CRR for all components, for any reason, at 20 years was 15% (CI: 10–22) (Figure 4).

For detailed long-term (> 10-year) radiographic analysis, we investigated 160 hips (in 137 patients) with an average follow-up period of 14 (10–25) (SD 3.6) years (Figure 1). After more than 10 years of follow-up, there were 10 further revisions. 4 of these were ARR revisions: 1 was an isolated ARR revision for aseptic loosening, 1 was a revision for aseptic loosening of ARR and stem, and 2 were ARR and stem revisions for late infection.

By the end of the study period (2012), none of the THAs that were excluded due to insufficient quality of radiographs or loss to radiological follow-up had been revised.

139 (87%) of the 160 ARRs had no signs of loosening, and 7 had osteolysis but were not loose. 14 ARRs were radiologically loose, 4 of which had been revised, as mentioned above (2 for aseptic loosening: 1 of them had osteolysis around the screws and lateral migration of more than 2 mm and the other 1 had progressive osteolysis around the screws; and 2 for infection: 1 of them was radiologically loose with 3 of 5 screws broken and extensive osteolysis medially and superi-

orly, and the other had osteolysis around the screws. The remaining 10 radiologically loose ARRs were not revised: 5 of these had at least 1 broken screw and no other changes, 2 had 1 broken screw and migration, 2 had 1 broken screw and radiolucent lines medially and superiorly, and 1 had migration alone without any screw being broken.

9 stems out of 160 were classified as radiologically loose, and 8 of them were revised.

## Discussion

For the ARR, the survival concerning fixation was excellent with a CRR of 3.4% with aseptic loosening

as endpoint and of 7% with revision for any reason at 20 years as endpoint. Even for the whole hip system used, the long-term survival must be considered good. Compared to the published survival data of successful acetabular component systems used in unselected primary THA, our data show a low revision rate in the long-term (Table 3).

Only half of the patients were treated because of primary OA, and a high percentage of the patients were complex cases with acetabular bone stock deficiency—which affects survival of the cup negatively (Gill et al. 1998). The definition of “complex” is somewhat arbitrary, but the atypical distribution of diagnoses in the our patient population shows that the ARR was being used in the more complex cases. All complex cases were treated by one of the authors (PEO), and no additional complex cases were operated with a standard implant. About one-sixth of all THR patients were treated with an ARR. About half of the 321 THAs performed with ARR would have

Table 3. Selected registry data on survivorship of acetabular components in comparison to the present study

Reference Acetabular component	Year	n	FU years	Surv <sup>a</sup> %
Swedish Arthroplasty Register Cemented (Lubinus)	1992–2011	80,401	20	90
Norwegian Arthroplasty Register Cemented (Charnley)	1987–2010	42,638	23	93
Swedish Arthroplasty Register Uncemented (Trilogy HA)	1992–2011	1,266	15	88
Present study ARR + PE <sup>b</sup>	1984–2002	321	20	93

<sup>a</sup> Survival of acetabular component, %

<sup>b</sup> PE: polyethylene.

been suitable for a standard cup, with favorable results also. However, the ARR was popular at that time and the surgeons relied on the more complex implant, even though it may not have been indicated.

Taking the unfavorable selection of more complex patients into account, our reported CRR is even more remarkable. We could not analyze risk factors for subgroups of diagnoses, as only 5 of the 321 using ARR were revised for aseptic loosening—4 of 172 hips with OA as diagnosis and 1 of 51 hips with DDH as diagnosis. As we used the ARR in many standard cases too, this led to greater experience in handling of the implant, which may have contributed to the excellent survival, even in the more complex patients.

Our findings are in line with previously reported data on excellent medium-term survival of THAs with ARR. Aebi et al. (1989) reported a revision rate of 0.7% for aseptic loosening of the ARR in primary hip replacement at a mean follow-up of 8 years. Similarly, Gill et al. (1998) used the ARR in 123 cases of hip dysplasia; 11 had a dislocated hip (Crowe IV), and in these complex cases only 2 ARRs were revised for aseptic loosening after a mean follow-up of 9 years. This demonstrates that the implant is reliable—even in the long-term—in patients with extensive loss of acetabular bone stock and/or hip dysplasia.

In survival analysis, a limitation of the study was that we only analyzed revision rates. This might be considered to be bias, since there is a lower tendency to revise complex cases. However, of 160 radiologically analyzed ARRs after a mean of 14 years, there were only 10 unrevised ARRs that were radiologically loose, and 5 of them had isolated screw breakage. In addition, 7 ARRs had osteolysis. All patients had scheduled follow-up examinations, but our data on clinical results were incomplete and are therefore not presented. However, even without detailed clinical evaluation, those patients were examined in the outpatient department and it can be assumed that those who were suitable for revision were revised.

Another limitation may be that patients who died might have been revised elsewhere before their death. But this is rather improbable, as most of the patients were local people who preferred to be treated at the local hospital, especially when becoming older.

Most of the patients who were lost to follow-up were people living elsewhere who could not be traced. It is improbable that these patients would have been revised elsewhere, as they wanted the primary operation at our hospital and would presumably have come there for revision also. As there is no national death register in Switzerland, it is probable that some of these patients died elsewhere and therefore could not be traced. Even in the worst-case scenario, taking all hips that were lost to follow-up as having been revised for any reason, the CRR of the ARR at 20 years would be 15%, which can be considered to be good.

Even if radiological changes are taken as pending failure, the CRR remains favorable. Furthermore, radiological data

cannot be obtained from national registers, so pending failure cannot be quantified and compared.

10 ARRs were classified as being radiologically loose; 5 of them only had broken screws. The screws are angularly stable due to locking of the screw heads with cement (Laflamme et al. 2008). Screws may be under tension when being inserted: micromotion of a well-fixed shell can cause oscillating forces on the screw through the locking mechanism and lead to breakage, which in return may be wrongly classified as loosening. Furthermore, some ARRs with signs of radiological loosening may have been asymptomatic, as the ring and the screws create a complex implant-bone interface and serve as a load-distribution device preventing clinical symptoms.

In 7 hips, the polyethylene insert of the ARR had to be changed during stem revision because the bearing surfaces were not compatible. None of the ARRs had to be considered as being loose and the insert exchange can be compared with a liner exchange in modular cups.

A limitation of our study may have been that 4 generations of the Müller ARR were combined with different bearing surfaces and a variety of stems. However, revisions were evenly distributed among the ARRs of different material and with different surfaces—as well as the various combinations of the different inserts used. We could not investigate whether any of the particular types of ARRs or bearings affected the overall survival, due to the limited number of revised cases.

We conclude that THA with ARR is a reliable procedure in the long term. This was demonstrated for standard cases and in complex situations with deficient acetabular bone stock, as in patients who suffered from hip dysplasia. When there is a questionable or difficult acetabular situation, the use of the ARR can be recommended.

We thank Mrs S. Häfliger for organizing the follow-up of all our patients during the last 30 years.

AS: data analysis, radiological analysis, and writing of first draft. MC: data analysis and writing of manuscript. ST: planning of study, data analysis, and writing of manuscript. HW: data analysis and writing of manuscript. OR: statistical analysis and writing of manuscript. PEO: implementation of register and writing of manuscript. TI: idea, design, and planning of study, data analysis, and writing of manuscript.

No competing interests declared.

Aebi M, Richner L, Ganz R. Long-term results of primary hip total prosthesis with acetabulum reinforcement ring. *Orthopade* 1989; 18(6): 504-10.

DeLee J G, Charnley J. Radiological demarcation of cemented sockets in total hip replacement. *Clin Orthop Relat Res* 1976; 121: 20-32.

Gill T J, Sledge J B, Müller M E. Total hip arthroplasty with use of an acetabular reinforcement ring in patients who have congenital dysplasia of the hip. Results at five to fifteen years. *J Bone Joint Surg Am* 1998; 80(7): 969-79.

- Haentjens P, Handelberg F, Casteleyn P P, Opdecam P. The Müller acetabular support ring. A preliminary review of indications and clinical results. *Int Orthop* 1986; 10: 223-30.
- Joshi R P, Eftekhari N S, McMahon D J, et al. Osteolysis after Charnley primary low-friction arthroplasty. A comparison of two matched paired groups. *J Bone Joint Surg (Br)* 1998; 80-B: 585-90.
- Korovessis P, Stamatakis M, Baikousis A, Katonis P, Petsinis G. Mueller roof reinforcement rings. Medium-term results. *Clin Orthop Relat Res* 1999; (362): 125-37.
- Laflamme G Y, Alami G B, Zhim F. Cement as a locking mechanism for screw heads in acetabular revision shells - a biomechanical analysis. *Hip Int* 2008; 18(1): 29-34.
- Lie S A, Engesaeter L B, Havelin L I, Gjessing H K, Vollset S E. Dependency issues in survival analyses of 55,782 primary hip replacements from 47,355 patients. *Stat Med* 2004; 23 (20): 3227-40.
- Norwegian Arthroplasty Register, Annual Report 2010: 30-31.
- Nunn D, Freeman M A, Hill P F, Evans S J. The measurement of migration of the acetabular component of hip prostheses. *J Bone Joint Surg Br* 1989; 71(4): 629-31.
- Ochsner P E. Total hip replacement. In: (Ochsner P E, ed.) *Total hip replacement*. Springer, Berlin, 2003.
- Panski A, Tauber C. Acetabular supporting ring in total hip replacement. *Arch Orthop Trauma Surg* 1997; 116: 233-5.
- Robertsson O, Ranstam J. No bias of ignored bilaterality when analysing the revision risk of knee prostheses: analysis of a population based sample of 44,590 patients with 55,298 knee prostheses from the national Swedish Knee Arthroplasty Register. *BMC Musculoskelet Disord* 2003; 4: 1.
- Rosson J, Schatzker J. The use of reinforcement rings to reconstruct deficient acetabula. *J Bone Joint Surg (Br)* 1992; 74: 716-20.
- Schatzker J, Glynn M K, Ritter D. A preliminary review of the Muller acetabular and Burch-Schneider antiprotusio support rings. *Arch Orthop Trauma Surg* 1984; 103: 5-12.
- Schlegel U J, Bitsch R G, Pritsch M, Clauss M, Mau H, Breusch S J. Mueller reinforcement rings in acetabular revision: outcome in 164 hips followed for 2-17 years. *Acta Orthop* 2006; 77(2): 234-41.
- Siebenrock K A, Tannast M, Kim S, Morgenstern W, Ganz R. Acetabular reconstruction using a roof reinforcement ring with hook for total hip arthroplasty in developmental dysplasia of the hip-osteoarthritis. Minimum 10-year follow-up results. *J Arthroplasty* 2005; 20(4): 492-8.
- Stockl B, Beerkotte J, Krismmer M, Fischer M, Bauer R. Results of the Muller acetabular reinforcement ring in revision arthroplasty. *Arch Orthop Trauma Surg* 1997; 116: 55-9.
- Swedish Hip Arthroplasty Register, Annual Report 2011: 75-77.
- Zicat B, Engh C A, Gokcen E. Patterns of osteolysis around total hip components inserted with and without cement. *J Bone Joint Surg Am* 1995; 77: 432-9.