



# LUND UNIVERSITY

## Scaphoid fractures. Treatment and outcome

Clementson, Martin

2017

*Document Version:*

Publisher's PDF, also known as Version of record

[Link to publication](#)

*Citation for published version (APA):*

Clementson, M. (2017). *Scaphoid fractures. Treatment and outcome*. [Doctoral Thesis (compilation), Department of Translational Medicine]. Lund University: Faculty of Medicine.

*Total number of authors:*

1

### General rights

Unless other specific re-use rights are stated the following general rights apply:

Copyright and moral rights for the publications made accessible in the public portal are retained by the authors and/or other copyright owners and it is a condition of accessing publications that users recognise and abide by the legal requirements associated with these rights.

- Users may download and print one copy of any publication from the public portal for the purpose of private study or research.
- You may not further distribute the material or use it for any profit-making activity or commercial gain
- You may freely distribute the URL identifying the publication in the public portal

Read more about Creative commons licenses: <https://creativecommons.org/licenses/>

### Take down policy

If you believe that this document breaches copyright please contact us providing details, and we will remove access to the work immediately and investigate your claim.

LUND UNIVERSITY

PO Box 117  
221 00 Lund  
+46 46-222 00 00



# Scaphoid fractures

## Treatment and outcome

---

MARTIN CLEMENTSON | FACULTY OF MEDICINE | LUND UNIVERSITY





# Scaphoid fractures

## Treatment and outcome

Martin Clementson



**LUND**  
UNIVERSITY

DOCTORAL DISSERTATION

by due permission of the Faculty of Medicine, Lund University, Sweden.

To be defended at Medicinskt forskningscenter,  
lilla aulan, SUS, Malmö.

January 20th 2017, 9 a.m.

Faculty opponent

Professor Lars Adolfsson  
Linköping University, Sweden

Organization LUND UNIVERSITY Faculty of Medicine Author(s) Martin Clementson	Document name DOCTORAL DISSERTATION
	Date of issue 2017-01-20
	Sponsoring organization
Title and subtitle Scaphoid fractures – Treatment and outcome	
Abstract <p>The scaphoid is the most commonly fractured carpal bone accounting for 2% of all fractures in the body. Scaphoid fractures are difficult both to diagnose and to treat. The aim of this thesis was to assess functional and radiological outcome after different treatments for patients with post-traumatic radial sided wrist pain with or without a scaphoid fracture. In 2004-2008 all patients attending the emergency department at Skåne University Hospital - Malmö with posttraumatic radial sided wrist pain were screened for scaphoid fractures with conventional radiographs and MRI. For patients where a scaphoid fracture was found, also CT was performed. Depending upon the findings the patients were then allocated into different study arms, some being randomized controlled trials. A total of 526 patients completed the screening. In paper 1 we compared clinical and radiological outcomes for non- or minimally displaced scaphoid waist fractures in patients aged between 18 to 65 years randomized to either conservative treatment with cast (n=24) or arthroscopy-assisted screw fixation (n=14). They were followed with CT and clinical examination at 6, 10, 14, 26, 52 weeks and after 6 (4-8) years. We found that surgically treated patients had better subjective hand function (DASH) at 10 and 14 weeks, but conservative treated patients had better range of wrist motion at 26 weeks. There were no other differences at any time point. At final follow up after 6 years radiological signs of arthritis was more frequent in the surgical group (3/14 vs. 2/21). In paper 2 we assessed union of scaphoid waist fractures in 65 patients between 16-65 years of age, with a randomized subgroup of 38 patients with non- or minimally displaced fractures. Union was assessed with CT scan with reconstructions in the long axis of the scaphoid. 27/30 (90%) of non-displaced fractures were united at 6 weeks. There was no difference in time to union between surgically or conservatively treated fractures. In paper 3 we compared clinical outcome in 43 patients with wrist sprains randomized to either immediate mobilization or to two weeks immobilization in a cast. Patients treated with cast showed a transient reduction in wrist movement at 2 weeks, and reported lower hand function (DASH) at 2 and 6 weeks. In paper 4, 40 patients with distal scaphoid fractures were re-examined after median 10 (8-11) years with CT scan and clinical examination. 7 wrists showed arthritis in the STT joint, none of which had any clinical relevance. Clinical outcomes and subjective function score (DASH) was good.</p>	
Key words Scaphoid fracture, Randomized controlled trial, Outcome, Arthritis, Distal scaphoid fracture	
Classification system and/or index terms (if any)	
Supplementary bibliographical information	Language
ISSN and key title: 1652-8220 Lund University, Faculty of Medicine Doctoral Dissertation Series 2017:6	ISBN: 978-91-7619-387-7
Recipient's notes	Number of pages: 85
	Security classification

I, the undersigned, being the copyright owner of the abstract of the above-mentioned dissertation, hereby grant to all reference sources permission to publish and disseminate the abstract of the above-mentioned dissertation.

Signature 

Date 2017-12-09

# Scaphoid fractures

## Treatment and outcome

Martin Clementson



**LUND**  
UNIVERSITY



Illustration on back cover: Fredrik Tersmeden

Copyright Martin Clementson

Faculty of Medicine

Department of Translational Medicine

ISBN 978-91-7619-387-7

ISSN 1652-8220

Lund University, Faculty of Medicine Doctoral Dissertation Series 2017:6

Printed in Sweden by Media-Tryck, Lund University

Lund 2017



MADE IN  SWEDEN

Christine

Hugo

Emil



# Contents

List of papers.....	9
Abbreviations .....	10
Thesis at a glance.....	11
Background.....	13
Anatomy .....	15
Epidemiology .....	18
Fracture mechanism .....	19
Clinical diagnostics. ....	19
Imaging.....	21
Classification.....	23
Treatment .....	24
Healing.....	27
Functional outcome after fracture .....	29
Complications after a scaphoid fracture.....	30
The Malmö scaphoid study .....	32
Aims of this thesis .....	33
Methods.....	35
Patients .....	36
Imaging.....	37
Treatment .....	41
Clinical examination and functional outcome .....	42
Subjective outcome .....	43
Statistics.....	43
Ethics.....	44
Results.....	45
Summary of results.....	46
Discussion.....	53
Diagnostics .....	54

Treatment and outcome .....	57
Strength and limitations.....	65
Conclusions .....	67
Future work .....	70
Populärvetenskaplig sammanfattning .....	71
Acknowledgements .....	73
References .....	75
Appendix .....	85

PEANUTS. The scaphoid bone, *os scaphoideum*, is said to look like a small boat. The Greek word *skaphe* means something that has been hollowed out, and the suffix *-oid* means that it has a resemblance to something. But the scaphoid bone resembles a peanut much more than a boat, both in size and shape. Thus, a more appropriate name would be the peanut bone, *os arachisoideum*.

However, dealing with injuries in the scaphoid bone is definitely not peanuts...



**Figure 1.** | *Os Arachisoideum*

publicdomainpictures.net

# List of papers

This thesis is based on the following papers:

1. **Conservative treatment versus arthroscopic-assisted screw fixation of scaphoid waist fractures-A randomized trial with minimum 4-year follow-up.**  
Clementson M, Jorgsholm P, Besjakov J, Thomsen N, Bjorkman A.  
J Hand Surg Am. 2015;40:1341-1348.
2. **Union of scaphoid waist fractures assessed by CT scan.**  
Clementson M, Jorgsholm P, Besjakov J, Bjorkman A, Thomsen N.  
J Wrist Surg. 2015;4:49-55.
3. **Is early mobilization better than immobilization in the treatment of wrist sprains?**  
Clementson M, Thomsen N, Jorgsholm P, Besjakov J, Bjorkman A.  
J Plast Surg Hand Surg. 2016;50:156-160.
4. **Long-term outcomes after distal scaphoid fractures. A 10-year follow-up.**  
Clementson M, Thomsen N, Besjakov J, Jorgsholm P, Bjorkman A.  
Manuscript submitted for peer-review.

Permission to reprint the articles has been granted by the publishers.

# Abbreviations

ASB	Anatomical snuffbox, fossa Tabatière
CSS	Clinical scaphoid score
CT	Computed tomography
DASH	Disabilities of the arm, shoulder, and hand
DISI	Dorsal intercalated segment instability
MRI	Magnetic resonance imaging
PA	Posteroanterior
PLIND	Perilunate injuries, not dislocated
PRWE	Patient-rated wrist evaluation
ROM	Range of motion
RSC	Radioscaphocapitate
SL	Scapholunate
SLAC	Scapholunate advanced collapse
SNAC	Scaphoid non-union advanced collapse
STIR	Short tau inversion recovery
STT	Scaphotrapeziotrapezoid
VAS	Visual-analogue scale

# Thesis at a glance.

## Paper 1

*Conservative treatment versus arthroscopic-assisted screw fixation of scaphoid waist fractures – A randomized trial with minimum 4-year follow-up*

**Aim:** To compare clinical and radiological outcomes for non- or minimally displaced scaphoid waist fractures randomized to either conservative treatment with cast or arthroscopy-assisted screw fixation.

**Method:** Consecutive patients between 18 to 65 years of age with non- or minimally displaced scaphoid waist fractures were included. 24 patients were conservatively treated with below elbow cast, and 14 patients were treated with arthroscopy-assisted screw fixation. They were followed with CT and clinical examination at 6, 10, 14, 26 and 52 weeks, and after 6 (4-8) years.

**Results:** Surgically treated patients had better subjective hand function (DASH) at 10 and 14 weeks. Conservative treated patients had better range of wrist motion at 26 weeks. There was no other difference at any time point.

At final follow up arthritis was more frequent in the surgical group (3/14 vs. 2/21) but numbers are too low to allow any generalization.

**Conclusion:** Operative treatment may provide an improved functional outcome in the short term but at the price of a possible increased risk of arthritis in the long term.

## Paper 2

*Union of scaphoid waist fractures assessed by CT scan*

**Aim:** To assess union of scaphoid waist fractures on CT scans at six weeks, and to compare time to union between conservative treatment and arthroscopic-assisted screw fixation.

**Method:** 65 consecutive patients between 16-65 years of age with scaphoid waist fractures regardless of dislocation were included. A subgroup of 38 patients with non- or minimally displaced fractures were randomized to either conservative treatment or arthroscopy-assisted screw fixation. Union was assessed with CT scan with reconstructions in the long axis of the scaphoid at 6 weeks.

**Results:** 27/30 (90%) non-displaced fractures were united at 6 weeks. There was no difference in time to union between surgically or conservatively treated fractures.

**Conclusion:**

Majority of non-displaced fractures are sufficiently treated with 6 weeks in a cast. Screw fixation does not reduce time to union in non-displaced fractures.

## Paper 3

*Is early mobilization better than immobilization in the treatment of wrist sprains?*

**Aim:** To compare clinical outcome in patients with wrist sprains randomized to either immediate mobilization or to two weeks immobilization in a cast.

**Method:** 43 consecutive patients >18 years of age with post-traumatic radial sided wrist pain where radiographs and MRI could not detect any fracture or SL ligament injury were included. They were randomized to either two weeks in a dorsal wrist cast or immediate mobilization, and were followed at 2, 4 and 6 weeks.

**Results:** Patients treated with cast showed a transient reduction in wrist movement at 2 weeks, and reported lower hand function (DASH) at 2 and 4 weeks.

**Conclusion:**

Patients with posttraumatic radial sided wrist pain where MRI does not demonstrate fracture or SL ligament injury do not benefit from immobilization and can be treated with early mobilization.

## Paper 4

*Long-term outcomes after distal scaphoid fractures. A 10-year follow-up.*

**Aim:** To assess the long-term clinical and radiological outcome after distal scaphoid fractures especially in relation to development of osteoarthritis in the scapho-trapezium-trapezoid joint.

**Method:** 40 consecutive patients with 41 distal scaphoid fractures were reexamined after median 10 (8-11) years with CT scan and clinical examination.

**Results:** 26/41 fractures were avulsion-fractures (Prosser Type I). Patients with avulsion-fractures were younger than patients with other types of distal fractures. One avulsion-fracture was not united. Seven wrists showed arthritis in the scapho-trapezium-trapezoid joint, none of which had any clinical relevance. Clinical outcomes and subjective function score (DASH) was good.

**Conclusion:** From a 10-year perspective, the consequences of a distal scaphoid fracture are minor regarding hand function and the risk of developing symptomatic posttraumatic scapho-trapezium-trapezoid joint arthritis.



# Background

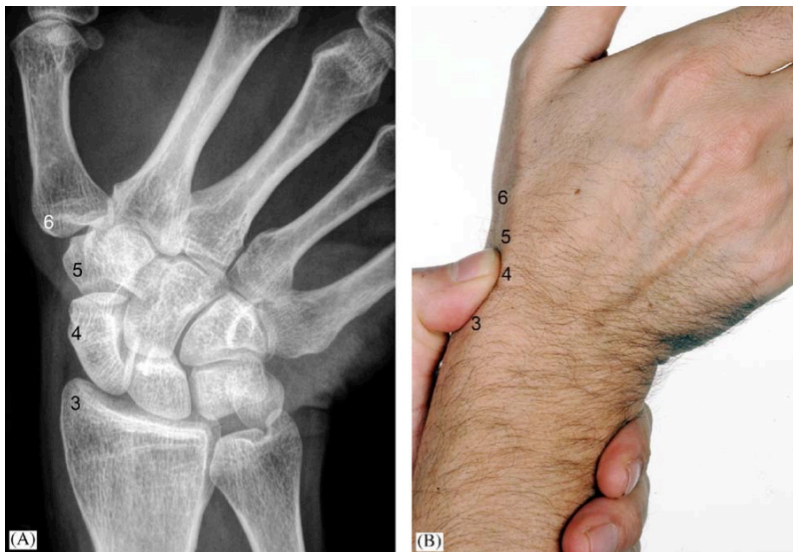
The scaphoid is the most commonly fractured carpal bone. It accounts for 60% of carpal fractures, 11% of hand fractures, and 2% of all fractures in the body.<sup>1</sup> There are several reasons for the diagnosis and treatment of scaphoid fractures being a continuous challenge:

- 25% of scaphoid fractures cannot be diagnosed on radiographs taken at the time of injury.<sup>2</sup> This increases the risk of delayed treatment or of lack of relevant treatment, which in turn increases the risk of non-union and long-term complications.<sup>3,4</sup>
- 10% of scaphoid fractures do not heal despite adequate treatment.<sup>5</sup> This is especially true for dislocated and unstable fractures, where the non-union rates have been reported to be as high as 55% in conservatively treated fractures.<sup>6</sup> The scaphoid bone and the ligament attaching it to adjacent carpal bones have a pivotal role in the biomechanics of the wrist. Disruption of this function, as in the case of a non-union, will eventually lead to a scaphoid non-union advanced collapse (SNAC).<sup>7-9</sup>
- The true incidence of scaphoid fracture in patients with acute wrist injury presenting with clinical signs suggestive of a scaphoid fracture has been reported to range from 15 to 42%.<sup>10,11</sup> Since the sensitivity of radiographs is low, patients with clinical signs of fracture and normal radiographs are placed in a cast for 10 - 14 days, after which repeated radiographs are taken. This means that many patients will be unnecessarily immobilized in a cast without having a fracture.
- Determining when a fracture is united is difficult based on clinical investigation and plain radiographs only.<sup>12</sup> Therefore, with the risk of non-union in mind, immobilization is often continued for as long as 10-14 weeks.<sup>13-15</sup> As a consequence, many patients are treated in a cast for a longer period of time than necessary. This could negatively affect their functional outcome quite apart from having a socio-economic impact due to prolongation of sick leave.

# Anatomy

The scaphoid is one of eight carpal bones of the wrist. It has an average length of 29 mm in men and 25 mm in women, and lies at an angle of  $45^\circ$  to the long axis of the radius in both the anteroposterior and lateral planes.<sup>16</sup> Its different parts are easily accessible for palpation. With the wrist in slight radial deviation, the distal part and the tubercle are found as a volar eminence just distal to the wrist crease in the elongation from the flexor carpi radialis tendon. With the wrist in ulnar deviation, the middle part, the waist, is palpated in the radial anatomical snuffbox. *Figure 2*. Finally, it is possible to palpate the proximal pole of the scaphoid with the wrist in flexion, just distal to Lister's tubercle.

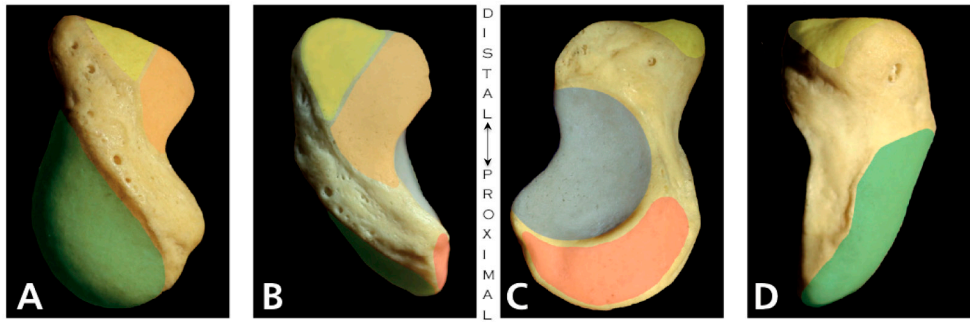
80% of the surface of the scaphoid is covered with cartilage. It has four articulate surfaces; to the radius, to the lunate, to the capitate and to the combined articulation of the trapezium and trapezoid. *Figure 3*.



**Figure 2.** Anatomical landmarks around the scaphoid.

Palpating the scaphoid bone with the thumb pressing down in the anatomical snuffbox. 3 - radial styloid, 4 - scaphoid waist, 5 – trapezoid, 6 – first metacarpal.

From Reddy et al., 2005.<sup>22</sup> Permission granted from publisher.



**Figure 3. | Articulations of the scaphoid bone.**

Radial (A), dorsal (B), ulnar (C) and volar (D) views of the right scaphoid. Articulations are green for distal radius, yellow for trapezium, orange for trapezoid, blue for capitate and red for lunate.

Note the vascular foramina on the dorsal ridge and the tubercle.

From Buijze et al, 2011.<sup>19</sup>

Permission granted from publisher.

While no tendons are directly attached to the scaphoid, together with the pisiform it is the only carpal bone that is dynamically influenced by extrinsic musculotendinous structures. The scaphoid is stabilized by attachment of the flexor carpi radialis tendon sheet to the scaphoid tubercle on the palmar side, and by the buttress effect of the extensor carpi radialis longus and brevis tendons on the dorsal side.<sup>17</sup>

The scaphoid is tethered proximally to the lunate via the scapholunate (SL) ligament complex and distally via the scapho-trapezio-trapezoidal (STT) ligament complex. The SL ligament is C-shaped with the dorsal part being thicker than the volar, and with a thin proximal fibrocartilage membrane in-between. The dorsal part courses from the dorsal horn of the lunate to the dorso-ulnar region of the proximal pole of the scaphoid, and the volar part courses obliquely between the volar pole of the lunate and the proximal pole of the scaphoid. Although the dorsal portion of the SL ligament is the strongest, all parts contribute to the rotational stability of the scapholunate joint.<sup>18</sup>

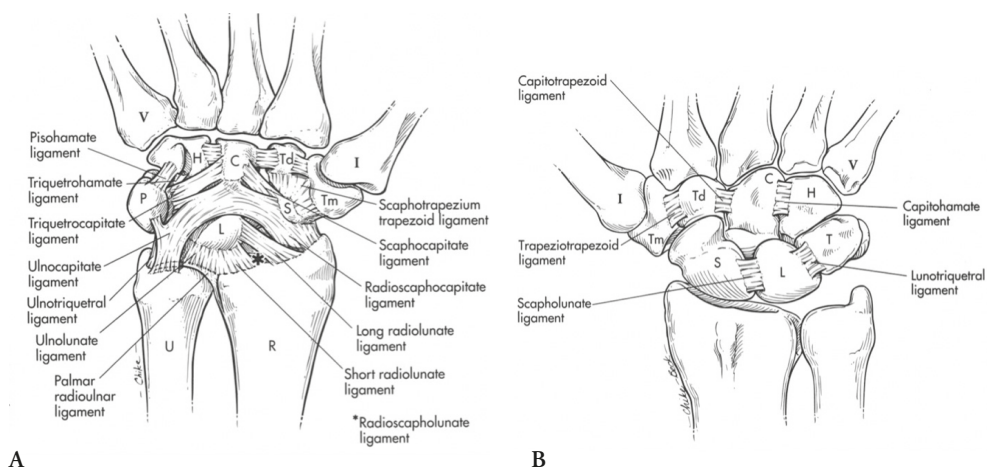
Compared to the SL ligament complex, the STT ligament complex shows more anatomical variations. The strongest part of the STT ligament complex is the scapho-trapezium ligament, which originates from the radiovolar aspect of the distal pole of the scaphoid and fans out in a V-shape to the proximal volar part of the trapezium. In the ulnar part of the STT ligament complex is the smaller scaphotrapezoid ligament. These two ligaments, the scaphotrapezium and scaphotrapezoid, form the volar part of the STT joint capsule and function as a stabilizer of the scaphoid to avoid excessive scaphoid flexion.<sup>19</sup> The radio-scapho-capitate (RSC) ligament originates from the radial styloid, passes volar to the scaphoid with attachments onto the radial aspect of the scaphoid waist and at the tubercle, and finally it inserts on the volar surface of the head

of the capitate. Together with the ulnocapitate ligament, the RSC ligament forms the arcuate ligament, which is an important stabilizer of the mid-carpal joint. The RSC acts as a pivot for scaphoid rotation and can also act as a fulcrum over which the bone may fracture.<sup>2, 19</sup>

The biomechanics of the scaphoid provides an important link between the proximal and distal carpal rows, where the integrity of the bone and its ligaments is fundamental to the entire carpal stability.<sup>20</sup> *Figure 4.*

## Vascular anatomy

Blood vessels originating from the dorsal carpal branch of the radial artery enter the scaphoid through capsular insertions on the dorsal ridge. They account for 70–80% of the scaphoid’s interosseous vascularity and the supply to the proximal pole. However, the proximal pole gets some additional blood from the radioscapoid (Testut) ligament. On the volar side, vessels from the superficial palmar branch of the radial artery enter the scaphoid in the area of the tubercle and mainly provide a vascular supply to the distal pole.<sup>21</sup>

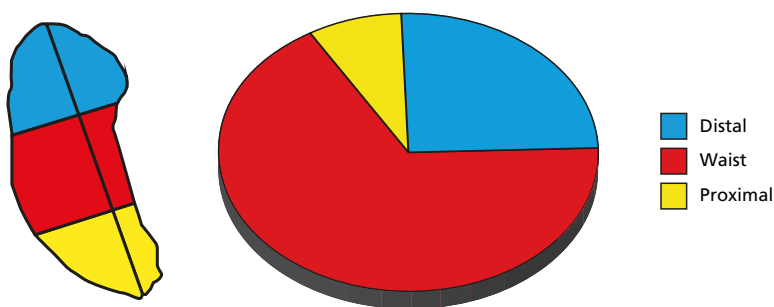


**Figure 4. | Wrist ligaments.**

Volar ligaments (A) and dorsal intrinsic ligaments (B) of the wrist.

From Berger, 2010.<sup>23</sup>

By permission of Mayo Foundation for Medical Education and Research. All rights reserved.



**Figure 5. | Distribution of scaphoid fractures.**

Distribution of fractures according to the equal third classification.

## Epidemiology

The incidence of scaphoid fractures has been reported to be between 12 and 29 per 100,000 in an urban population in the UK,<sup>24, 25</sup> and as high as 43 per 100,000 in Bergen, Norway.<sup>1</sup> There is a peak in age-specific risk between 10 and 30 years and a strong male predominance (83%).<sup>25, 26</sup>

Furthermore, there appears to be a higher incidence in patients of lower socioeconomic status, and also a seasonal difference—with more fractures in June and less in December.<sup>25</sup> Sport injuries accounts for one-third of fractures. A quarter of them occur at work, and a quarter occur at home.<sup>27</sup>

In adults, fractures at the scaphoid waist are the most common, accounting for approximately two-thirds (64–66%) of all scaphoid fractures. A quarter (25–31%) are located in the distal third and one-twelfth (5–10%) occur in the proximal third.<sup>11, 25, 26, 28</sup>

*Figure 5.* In a paediatric population, the rate of distal fractures is higher and this has been reported to be the most common fracture type in children under 13 years of age.<sup>29-31</sup>

# Fracture mechanism

A scaphoid fracture is most often caused by a fall onto an outstretched hand, or by a similar trauma mechanism, resulting in a hyperextension of the wrist.<sup>28, 32</sup> Experimental studies have shown that the combined load from hyperextension and radial deviation of the wrist most likely results in a waist fracture.<sup>33</sup> The crank-handle injury is also common, but today this injury is more likely to arise from a force directed into the palm of the hand by a bicycle handlebar or a hockey stick. This type of injury most often results in a waist fracture, often with a transverse pattern.<sup>28</sup> Forceful axial loading through the second metacarpal, as in a punch, can cause a shear fracture through the waist of the scaphoid,<sup>34</sup> while a direct blow to the scaphoid tubercle may result in a distal fracture.<sup>35</sup> An impact to an unloaded, fully extended wrist (goalkeeper injury) often results in a proximal pole fracture.<sup>36</sup>

High-energy trauma may result in a carpal dislocation in which a scaphoid injury can be part of a perilunate greater or lesser arc injury.<sup>37</sup> Such injury patterns can be seen without dislocation (perilunate injuries, not dislocated, PLIND), which are probably injuries that have been dislocated but have been spontaneously reduced.<sup>38</sup>

## Clinical diagnostics.

Patients who present with posttraumatic pain on the radial side of the carpus should be suspected of having a scaphoid fracture. After retrieving a full anamnesis including patient-related factors such as occupancy, previous injuries to the wrist, smoking habits, and trauma mechanism, a thorough examination must be performed.

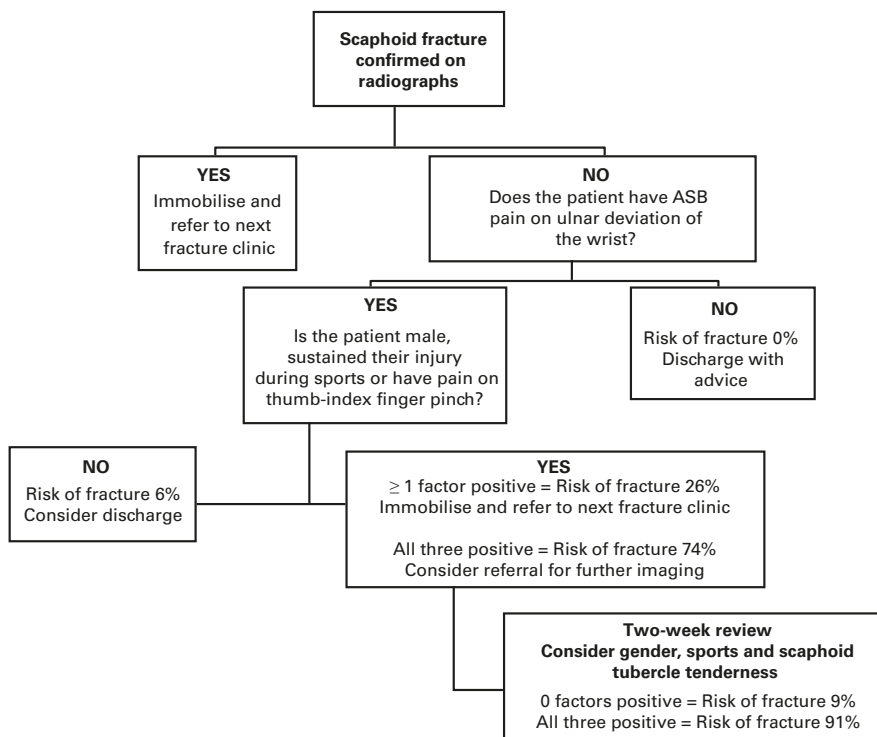
When assessing whether or not a patient has a fracture, it is important that the clinical tests are sensitive, as a missed fracture involves a higher risk of non-union and subsequent degenerative arthritis of the wrist. It is also important that the tests are specific for scaphoid pathology. Since the diagnostic accuracy of plain radiographs is limited, the examining surgeon must decide if a patient who has radiographs with no signs of fracture, but persistent radial-sided carpal pain, should be referred for second-line radiological examination. The classic routine for establishing a diagnosis is repeated clinical and radiological examination after two weeks of cast immobilization. If the specificity of the clinical tests is low, such patients will be overtreated—as they are immobilized without having a fracture. Modern imaging techniques such as MRI and CT can shorten the time for accurate diagnosis, but in many hospitals the possibilities of using MRI and CT for assessment of suspected scaphoid fractures are limited. Thus, it is important that patients are carefully selected for these second-line investigations.



There are three commonly used clinical tests for assessment of a patient for a scaphoid fracture: tenderness in the anatomical snuffbox (ASB), tenderness on the scaphoid tubercle, and tenderness with longitudinal compression of the first metacarpal.<sup>39</sup> Each of these tests has good sensitivity (100%) but low specificity (9–48%). However, a combination of these three tests improves the specificity to 74%.<sup>10</sup>

A “Clinical Scaphoid Score” (CSS) has been proposed.<sup>39</sup> It weights tenderness in the ASB with three points, tenderness on the tubercle with two points, and tenderness upon longitudinal compression with one point. A CSS score of less than 4 is believed to have a negative predictive value of 96%, which would make a scaphoid fracture unlikely.

Duckworth et al. identified several factors that were independent predictors of a fracture and they combined clinical tests, gender, and trauma mechanism into a diagnostic algorithm. *Figure 6*. With this protocol, the number of false-positive patients was reduced to 9%.<sup>40</sup>



**Figure 6. | Clinical test for scaphoid fractures.**

A suggested algorithm for diagnosing scaphoid fractures within 72 h of injury.

From Duckworth et al, 2012.<sup>40</sup>

Permission granted from publisher.

When examining the injured wrist, the surgeon should remember that the absence of a scaphoid fracture does not exclude the presence of other injuries around the carpus, as seen in the MRI study by Bergh et al.<sup>41</sup> Ligament injuries, such as an SL ligament tear, are notoriously difficult to diagnose even with modern MRI protocols, which is why a complete examination of the wrist must be performed.<sup>42</sup>

# Imaging

## Radiographs

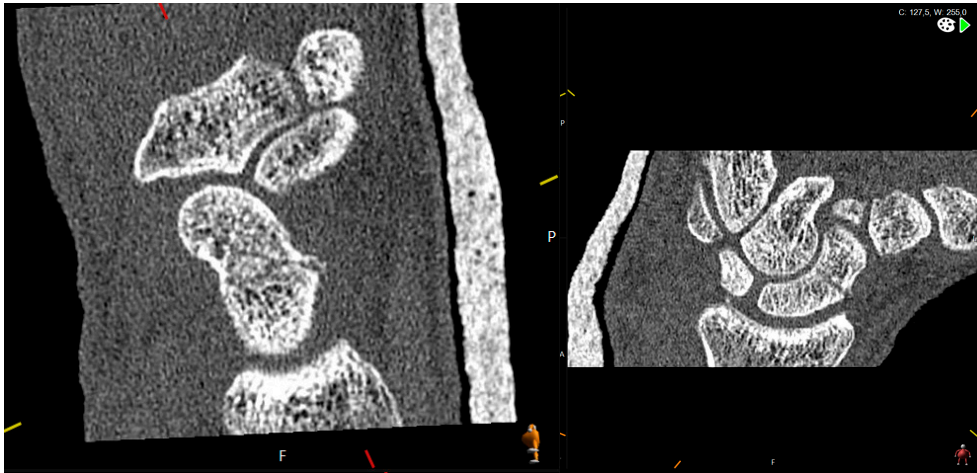Conventional radiographs are the first line of investigation of patients with posttraumatic radial-sided wrist pain. Posteroanterior and lateral projections of the wrist combined with four additional projections of the scaphoid bone are usually recommended. The American College of Radiology suggests: posteroanterior (PA), lateral, PA with ulnar deviation, and semi-pronated oblique (writing position).<sup>43</sup>

Initial radiography has high specificity but low sensitivity, being 70% in our material.<sup>11</sup> The minimal or non-displaced scaphoid fractures are especially difficult to diagnose on radiographs, as they require the X-ray beam to be parallel to the fracture line. Traditionally, in patients with negative findings on the initial radiographs and in whom suspicion of a scaphoid fracture remains, repeated radiographic investigation is done after two weeks.<sup>44</sup> The sensitivity of this investigation has been reported to be 91%.<sup>45</sup> Of patients with suspected scaphoid fractures and negative radiographs only 4-20% are found to have a fracture.<sup>40, 46</sup>

## CT.

Computed tomography (CT) is a technique for assembling multiple radiographic images taken from different angles with a rotating X-ray beam into a cross-sectional, tomographic image. Multi-slice CT is a method of obtaining several cross sections (slices) in the same rotation, making it possible to use the X-ray beam more efficiently and to make thinner sections with higher resolution and faster scanning times, while ideally giving less movement artefacts.<sup>47</sup> With modern computer technique, the large amount of data from a CT scan can be post-processed, making it possible to reconstruct and provide high-resolution images in any 3D plane. This makes CT superior for evaluation of fracture displacement and union.<sup>48</sup> *Figure 7.*

The overall sensitivity of CT in detecting a scaphoid fracture is somewhere between 85% and 95%.<sup>11, 45</sup>



**Figure 7. | Reconstruction of CT images.**

Reconstruction of CT images in the long axis of the scaphoid demonstrating a non-displaced waist fracture.

A CT examination exposes the patient to ionizing radiation. Scanning of the wrist with the patient lying prone with the hands above the head, in a so-called “superman position”, while carefully blending in the area to be examined gives very low scattering of the radiation and low total body exposure. An examination of the wrist with a modern 320-slice scanner exposes the patient to 0.009 mSv. For comparison, 0.01 mSv is equivalent to one day of background radiation and is considered to be negligible.<sup>49</sup>

A new technique is being introduced: cone-beam CT. It is a further development of making use of the cone shape of the X-ray beam and can produce high-resolution images with a much smaller and cheaper device, and also with a lower dose of radiation. Its place in the diagnostic algorithm for suspected scaphoid fractures is still to be demonstrated, but its sensitivity in detecting scaphoid fractures in the acute setting is still inferior to that of MRI.<sup>50</sup>

## MRI

Magnetic resonance imaging (MRI) has the advantage of not using ionizing radiation. Instead, it is the behaviour of the hydrogen atoms in the tissues that creates the signals that are converted into images. Hydrogen is of interest because of its abundance in water and fat. In an MR scanner, there is a strong longitudinal magnetic field running through the patient that influences all substances in the body. Inside the magnetic field, the movement (spin) of the hydrogen atom is aligned in one direction. An excitation radio frequency (RF) pulse is applied, exciting the electron. When the RF pulse is

terminated, the electron returns to its original state and in so doing emits a signal, an echo. The repetition time (TR) is the time between successive excitations and the echo time (TE) is the interval between the excitation pulse and measurement of the signal.

An MRI sequence is an order of RF and gradient pulses designed to acquire data to form an image. The tissues' different proportions of water and fat distinguish them from each other. The T1-weighted image is one of the basic pulse sequences in MRI; it has a short TE and TR. Fat appears bright on T1-weighted images and water appears dark. On T2-weighted images (long TE and TR), fat and water appear bright. STIR (short tau inversion recovery) is an extreme T2-weighted image in which the fat signal is suppressed to reveal fluid such as in oedemas.

A fracture is characterized as a bright signal on the STIR sequence with a corresponding dark signal on the T1.<sup>51</sup>

The sensitivity and specificity in detecting scaphoid fractures is high—almost 100%,<sup>52</sup> which is why it is the method of choice for detection of occult fractures in the acute setting.<sup>43</sup> MRI also has the advantage of enabling diagnosis of soft tissue injuries.<sup>41</sup> However, MRI cannot be used for fracture classification or for assessment of fracture dislocation. Nor can it be used for assessment of healing, since a signal on MRI is seen in the bone for a long time after the fracture is united.<sup>53</sup>

MRI has the drawback of being expensive and time-consuming, and therefore has limited availability.

## Bone scan/ SPECT/ ultrasound

Other methods for examining scaphoid fractures have been used, such as bone scan, SPECT, and ultrasound. However, they have limited value in contemporary diagnostics.

# Classification

There are many suggested systems for classification of scaphoid fractures. They classify the fracture based on location, fracture plane orientation, or fracture stability/displacement in different combinations, and they are all based on radiographs.<sup>54</sup>

In many studies, fractures are divided by the “equal third” classification into proximal, waist (middle third), or distal fractures. This is a categorization without any claim to describe the severity or orientation of the fracture. In clinical routine, the most common classification systems are the Herbert, followed by the Rouse and the Mayo classifications,<sup>54</sup> *Figure 8*;

Herbert and Fischer presented a classification based on stability.<sup>55</sup> All bicortical fractures except of the tubercle were considered unstable.

Rousse suggested a classification of waist fractures based on orientation of the fracture plane.<sup>44</sup> Horizontal oblique and transverse fractures were considered to be more stable while vertical oblique fractures were susceptible to shear forces and had a higher risk of being unstable, and an increased risk of developing non-union.

Cooney and co-workers at the Mayo clinic<sup>56</sup> developed a classification mainly based on fracture location. They also acknowledged that different parts of the scaphoid have different prognoses regarding time to union and risk of non-union. It is a classification into thirds with extra categories specifying intra- and extra-articular distal fractures.

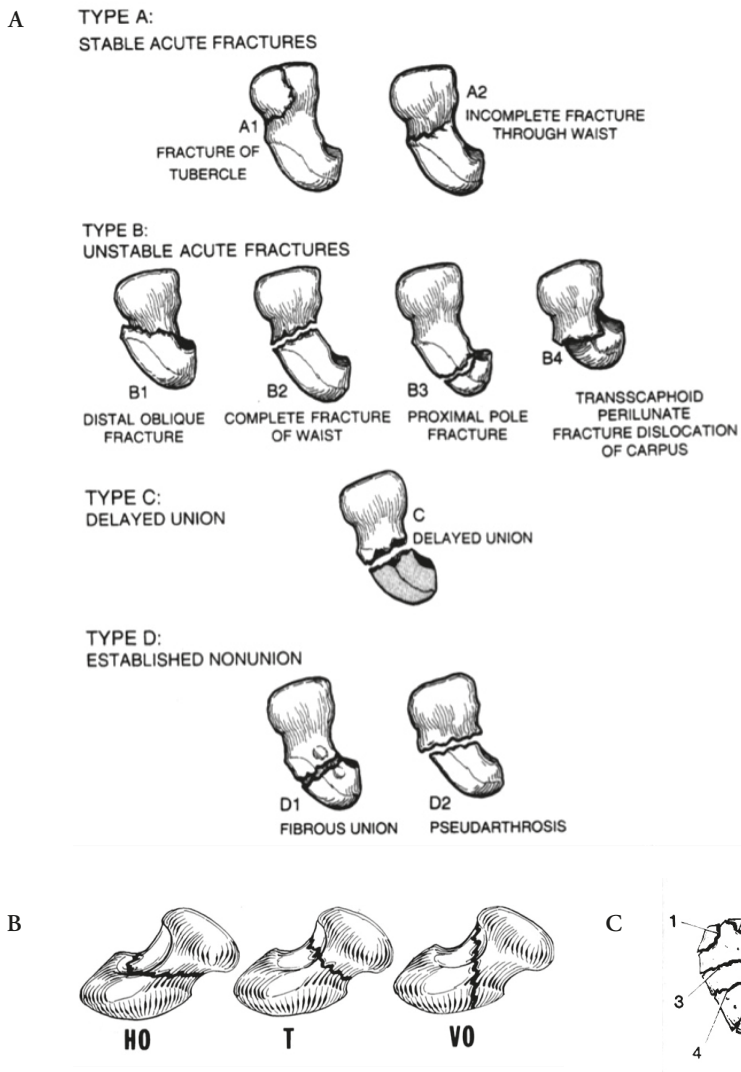
A classification for articular distal fractures only has been presented by Prosser et al.<sup>57</sup> *See the Methods section for details.*

# Treatment

## Conservative treatment

Most scaphoid fractures that are considered to be stable and non- or minimally displaced can be treated conservatively with immobilization.<sup>5</sup> There are many suggestions as to how the injured wrist should be immobilized; with an above-elbow cast, with a below-elbow cast, with hand in extension, with hand in flexion, with or without including the thumb, and so on. A meta-analysis of published methods could not find any evidence for one immobilization method being superior to any other,<sup>59</sup> but there appears to be a general consensus for recommendation of a below-elbow cast.<sup>2, 5, 60</sup> Furthermore, there is some new evidence to suggest that the thumb does not need to be immobilized at all in non-displaced fractures.<sup>60</sup> However, some patients actually prefer a cast with the thumb immobilized, and some caution is recommended in leaving the thumb free in patients with joint laxity or low compliance.<sup>5</sup>

The immobilization time in conservatively treated patients varies depending on many different factors such as fracture characteristics and patient-related factors (such as smoking, medications, age, and compliance), and also on how the treating surgeon evaluates fracture union (see section below). For non-displaced scaphoid waist fractures, the immobilization time is generally 6–12 weeks.<sup>13, 14, 61</sup> Fractures in the proximal part of the scaphoid are considered to heal slowly, and if they are treated conservatively, fixation times are often more than 12 weeks.<sup>28, 62</sup> There is general agreement that distal fractures require shorter immobilization in a cast, around 4–8 weeks,<sup>2, 28, 30, 62, 63</sup> and it has even been suggested that it is possible to treat avulsion fractures in a removable splint.<sup>5</sup>



**Figure 8. | Classification of scaphoid fractures.**

The most often used systems for classification of scaphoid fractures.

A - Herbert and Fischer. Type A and B are acute fractures.

B – Russe. Horizontal oblique (HO), transverse (T) and vertical oblique (VO).

C – Mayo. Extra articular fracture of the tuberosity (1), distal intra articular fracture (2), distal third fracture (3), waist fracture (4) and proximal fracture (5).

From Shin A, Marco R, 2010.<sup>58</sup>

By permission of Mayo Foundation for Medical Education and Research. All rights reserved.

## Surgical treatment

Surgical management is recommended in most proximal pole fractures and in waist fractures dislocated > 1 mm, because they take a longer time to unite and have a higher risk of non-union.<sup>56, 64</sup>

A wide range of different types of fixations have been used for scaphoid fractures, including pins, plates, and screws.<sup>65, 66</sup> The introduction of the headless compression screw with its two threaded sections of different pitch by Herbert and Fischer in 1984 changed the way in which scaphoid fractures were treated.<sup>55</sup> Since then, the original screw design has been subject to many improvements such as making it cannulated, which allows it to be inserted percutaneously.

### Open reduction and internal fixation (ORIF)

Historically, an open—often volar—approach was used to expose the scaphoid and stabilize the fracture. Over time, a more minimally invasive technique has evolved, but for more displaced or comminuted fractures many surgeons still use an open, most often volar (but in certain patients, dorsal) approach.

### Minimal invasive surgery

Minimally invasive techniques, both volar and dorsal, have also made screw fixation increasingly popular for non-displaced or minimally displaced fractures.<sup>67</sup> The proposed benefits of surgical fixation of a non-displaced fracture are shorter time to healing and the possibility of earlier mobilization, enabling faster return to work or sport.<sup>14, 61</sup> Dislocated fractures can also be treated with minimally invasive techniques, whereby wires inserted through the skin into the fragments of the fracture can aid in repositioning of the fracture.

### Dorsal minimally invasive approach

The dorsal approach is suitable for proximal fractures, but it is also popular for waist fractures.<sup>2</sup> With a short incision, the joint capsule is opened just ulnar to the tendons from the second and third extensor compartments. The wrist is flexed and the proximal pole of the scaphoid and the SL ligament can be inspected. A cannulated screw is inserted over a guide wire central to the long axis of the scaphoid at the proximal pole, a few mm radial to the membranous portion of the SL ligament.

### Arthroscopic assisted screw fixation

The dorsal fixation can be performed percutaneously, or with the assistance of arthroscopy.<sup>68</sup> The technique is as for the dorsal mini approach, but using the arthroscope in the 4–5 portal allows direct vision of the guide wire and screw, which is inserted through the 3–4 portal. The simultaneous arthroscopy gives the advantage of direct supervision of fracture reduction, placement, and countersinking of the screw, as well as the possibility of assessing any concomitant ligament injuries. *Figure 9.*



### **Volar minimally invasive approach**

Many have favoured a volar approach for waist fractures, where the screw is inserted in a retrograde manner.<sup>14, 61</sup> The advantage of this technique is that the tubercle is easily palpable, and thus a guide wire is fairly easy to place. Furthermore, placing of the screw from the volar side means that the joint capsule and the cartilage in the proximal scaphoid is not damaged. A small incision is made just distal to the tubercle. The wrist is extended and the ulnar deviated to extend and reduce the fracture and enable an entry point, which is visualized, with the help of an image intensifier, in the volar border of the STT joint.

### **Complications after surgery**

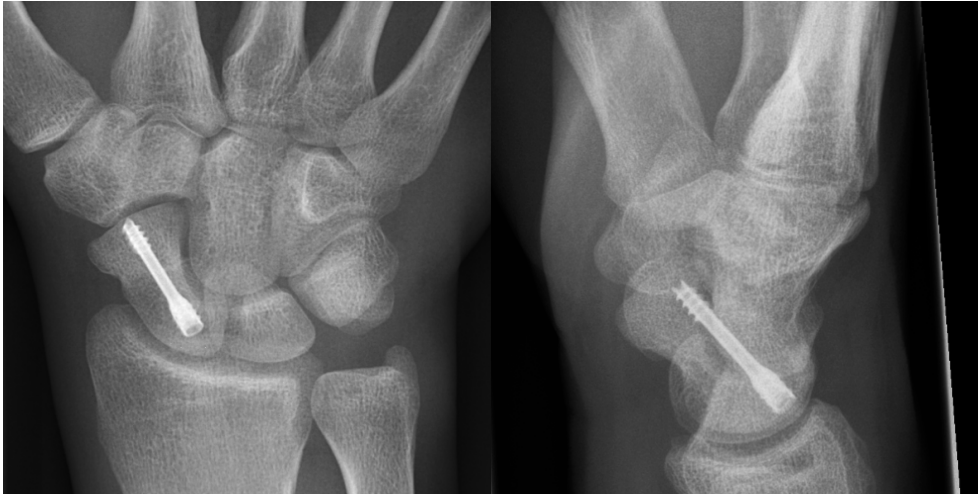A drawback of surgery is the risk of post-surgical complications, mainly problems such as wound infection or hypertrophic or hypersensitive scarring. Furthermore, the insertion of the screw will damage the cartilage in the proximal pole (dorsal screw fixation) or the STT joint (volar screw fixation). This could theoretically increase the risk of development of arthritis in these joints. In addition, the surgical procedure is technically demanding. Complications related to the technique, such as malposition of the screw, and to hardware failure, such as guide wire breakage, occur even with an experienced surgeon.<sup>2, 61, 69</sup>

## **Healing**

### **How should fracture union be defined?**

Since the scaphoid is mainly covered by cartilage and has little periosteum, the fracture heals with direct primary bone healing and no real callus formation. Russe suggested that a fracture was united if there was sclerosis at the fracture site or bone trabeculae crossing the fracture line visible on radiographs.<sup>44</sup> Both of these parameters have been shown to be unreliable and not reproducible.<sup>12</sup> Union can be even more difficult to define when surgery has been performed. If a fracture is reduced and fixated with a compression screw, then on a radiograph there will appear to be trabeculae crossing the fracture line immediately after surgery.

CT with reconstructions in the long axis of the scaphoid is more reliable for confirmation of fracture union.<sup>70, 71</sup> Singh et al. described a method by which the rate of bone contact with apparent trabecular crossing on five consecutive sagittal and coronal sections could be graded as 0–24%, 25–49%, 50–74%, and 75–99%. These estimates were added together to produce an estimate of the extent of union.<sup>72</sup> If union is > 50%, the fracture can be considered to be functionally healed.<sup>73</sup> Although better than esti-



**Figure 9. | Screw fixation of scaphoid fracture.**

Radiograph of a screw fixated scaphoid fracture.

mates based on radiographs, it is still difficult—even with CT including reconstructions in the long axis of the scaphoid—to assess union after surgery where there is compression over the fracture site.

## Time to union

Measurement of time to union requires a clear definition of union, a reliable technique to assess union, and a continuous determination of the state of union.<sup>5</sup> Healing of a fracture is a continuous process whereby bone matrix is developed and mineralized. At some stage in this process, the fracture is stable enough to allow mobilization. The state of union is usually examined at predefined intervals after a trauma or an intervention, such as surgical fracture fixation. This means that if union is confirmed at ten weeks, it actually means that the fracture was united when it was assessed at ten weeks, not that it took ten weeks to heal. To quote Dias: *“If the state of union of the scaphoid fracture cannot be established on radiographic evidence, determining the ‘time to union’ must be a particularly flawed measurement. It depends on the subjective interpretation of unreliable radiographic appearances at an arbitrary interval after surgery. [ ] The reporting of the ‘time to union’ should therefore be discouraged.”*<sup>5</sup> With this in mind, we still need to know the extent to which union is achieved at different time points.

After conservative treatment of scaphoid fractures where dislocated and proximal fractures had been excluded, Buijze et al. reported an overall union rate of 88% using CT at 10 weeks.<sup>60</sup> In a randomized trial using radiographs for assessment, Adolfsson reported similar values at 10 weeks where 85% in a conservatively treated group and 87% in an operated group were considered united.<sup>61</sup>

In a retrospective study, Grewal et al. investigated time to union using CT, but not at standard intervals. They found union of waist fractures after 65 days, union of distal pole fractures at 53 days, and union of proximal pole fractures at 113 days. They also found that fracture comminution and translation prolonged the time to union.<sup>62</sup> Furthermore, in a group of patients with undislocated scaphoid waist fractures, Geoghegan et al. mobilized 25 patients as early as 4 weeks when the CT scan indicated union, and all proceeded to union.<sup>73</sup>

## Functional outcome after fracture

### Assessment of outcome

When assessing how an injury in the upper extremities affects function, different standardized self-administered questionnaires are used. One of the most frequently used is the disabilities of the arm, shoulder, and hand (DASH) questionnaire. It is a region-specific 30-item questionnaire addressing both pain and function. It was developed by the American Academy of Orthopaedic Surgeons,<sup>74</sup> and the Swedish validated version was presented by Atroshi et al.<sup>75</sup> Answers are calculated on a score ranging from 0 (no impairment) to 100 (severe impairment). The normal value in an adult population is around 13, but it varies with gender and age.<sup>76</sup> A short form of DASH, the quick-DASH, consists of only 11 questions and has been shown to be interchangeable with the 30-item version.<sup>77</sup>

The patient-rated wrist evaluation outcome questionnaire (PRWE) is a wrist-specific evaluation tool that has also been translated to Swedish and validated in Sweden.<sup>78</sup> This is a set of 15 items in three subscales: Pain, Specific Activities, and Usual Activities. Pain and activity give equal weight, and result in a score from 0 (best) to 100 (worst).

For reporting of pain, a visual-analogue scale (VAS) is often used. The patient indicates his/her experience of pain on a line representing no pain to worst imaginable pain, and this is converted to a value from 0 to 10.

### Outcome after fracture

In a recent study on conservative treatment of non-displaced waist fractures, Buijze et al. reported good functional outcome 10 weeks after the trauma. Patients reported no remaining effect on wrist movement or grip strength, and had a mean DASH score of 5 and a mean VAS score of 1.<sup>60</sup> This contradicts some earlier findings by McQueen et al., in which conservatively treated patients with waist fractures were shown to have reduced wrist mobility and strength up to 26 weeks after a fracture.<sup>14</sup> Furthermore, two years after a fracture Dias et al. found that 20 % of patients still had some pain and

tenderness.<sup>79</sup> Meta-analysis of studies comparing conservative and surgical treatment of non-displaced waist fractures found a favourable result for operative treatment over conservative treatment regarding function score up to 3 months and for grip strength up to one year.<sup>80</sup>

The risk of persistent symptoms after a scaphoid fracture has united appears to be minor. Randomized studies on non-surgically and surgically treated waist fractures with a follow-up time of 7–12 years have shown no difference in persistent symptoms between treatments, with DASH or PRWE values from 0 to 8 and few patients reporting pain or reduction of mobility or strength in the injured hand.<sup>81-83</sup>

## Complications after a scaphoid fracture

### Non-unions

Non-union is a state in which a fracture has not united and where the fracture is considered not to have the possibility of uniting. There is no consensus on an exact time point at which an un-united fracture transforms into a non-union, but 12–26 weeks is usually set as a cut-off.<sup>59, 84</sup>

The number of acute scaphoid fractures that unite with conservative treatment has varied in different studies, but a proportion of 88–95% has been reported.<sup>5</sup> However, if only non-displaced waist fractures are included, the rate of union approaches 100%.<sup>59, 60</sup> For waist fractures with a displacement of more than 1 mm, the risk of non-union increases up to 50%.<sup>6, 62</sup> Angulation of the fracture has also been reported to predispose for a higher risk for non-union.<sup>62</sup>

Fractures in the proximal pole are considered to have a high risk of non-union, as much as 31%, but the published studies have had a limited number of cases in their series.<sup>62, 85</sup>

On the other hand, fractures in the distal pole are thought to be more benign, and many studies have found near 100% union.<sup>28, 30, 62</sup> Non-unions are considered to be rare, and they are reported to account for only 4% of all scaphoid non-unions that require surgery.<sup>86</sup>

A 40% risk of non-union has been reported in patients where there has been a delay of more than four weeks from injury to treatment.<sup>3</sup> This is however questioned by a recent study from Grewal et al. in which they show that 96% of scaphoid fractures diagnosed between 6 weeks to 6 month after trauma healed with conservative treatment.<sup>87</sup>

## Posttraumatic arthritis

### Classification of arthritis

There is no consensus on how to define and stage arthritis in the scaphoid articulations. Previous studies have mainly done the evaluation based on different combinations of joint narrowing, periarticular sclerosis, and osteophyte formation. Although similar, these studies cannot be directly compared. A few standardized classifications have been proposed for STT arthritis,<sup>88, 89</sup> but none of these have been used in follow-up studies to assess arthritis after scaphoid fractures. Most previous studies have used radiographs to assess arthritis. However, CT has been shown to be superior to radiography when assessing arthritis in the CMC-I joint,<sup>90</sup> and this is most likely the case also for assessment of arthritis in the STT and radioscapoid joints.

### Arthritis following united fractures

After a successfully united scaphoid fracture, some posttraumatic arthritis can be observed. Long-term studies using radiographs at follow-up have shown radiocarpal arthritis following united, conservatively treated scaphoid fractures in 2–5% of patients after 7–36 years.<sup>91, 92</sup> The risk of arthritis seems to be higher for patients who have received surgical treatment. Using CT for assessment, arthritis in the radiocarpal joint has been reported for 10–30% of conservatively treated patients and 18–39% of operatively treated patients. In the STT joint, arthritis was found in 3–25% of conservatively treated patients and in 38–65% of operatively treated patients.<sup>81, 82</sup>

### Arthritis following non-unions.

The natural course of a scaphoid non-union is not known. However, several studies have shown that all non-unions develop radiological signs of arthritis.<sup>8, 93, 94</sup> The validity of these studies has been questioned because they were all based on patients with clinical symptoms.<sup>95</sup> D ppe et al found that 4 of 9 patients with non-union had not developed arthritis after more than 30 years.<sup>91</sup> On the other hand, Lindstr m and Nystr m reported a small series of 33 patients who were diagnosed with asymptomatic non-union, where follow-up after at least 12 years showed that all had developed radiological arthritis and that 85% had become symptomatic.<sup>9</sup>

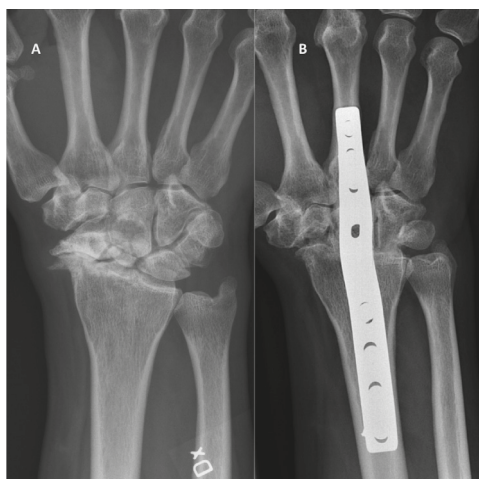The risk of non-union and its possible consequences is the reason for scaphoid fractures being considered to be so important to diagnose and treat correctly. An established non-union with carpal collapse and progressive arthritis will most often result in pain and impaired wrist function. Surgical salvage procedures may address the problem of wrist pain, but may further restrict wrist function. *Figure 10.*

# The Malmö scaphoid study

To address both epidemiological and therapeutically questions concerning scaphoid fractures and associated injuries, the Malmö scaphoid study was designed. During the years 2004 to 2008, all patients with posttraumatic radial-sided wrist pain who attended the emergency ward of Skåne University Hospital were screened with an extensive imaging protocol and were sorted into several study arms according to symptoms and signs. Data from that study formed the basis of two doctoral dissertations: that of Dr Peter Jørgsholm and the present one.

In the thesis *"Scaphoid Fractures. Epidemiology, diagnosis and treatment"*, (Jørgsholm 2015) the focus was on epidemiology and diagnostic methodology, with the following conclusions:

- Radiographs and CT are less sensitive in diagnosing carpal fractures than MRI in adults.
- MRI showed a high incidence of carpal fractures in both adults and children with posttraumatic radial-sided wrist pain.
- MRI revealed many concomitant carpal fractures, and the most common combination in both adults and children was that of a scaphoid and a capitate fracture.
- Scapholunate ligament injury is common in patients with scaphoid waist fractures.
- Radiographic scaphoid comminution is associated with fracture instability.



**Figure 10. | What we want to avoid.**

Radiographs showing the late consequences of a scaphoid fracture - a SNAC wrist (A) and same wrist after arthrodesis (B).

# Aims of this thesis

Focus in the present part of the Malmö Scaphoid Study has been functional and radiological outcome after treatment of patients with post-traumatic radial sided wrist pain with or without a scaphoid fracture.

## Specific aims:

- To compare functional and radiological outcome, in the short and medium term, of non-displaced or minimally displaced scaphoid waist fractures randomized either to conservative treatment in a cast or to arthroscopy-assisted screw fixation.
- To assess union of scaphoid waist fractures on CT scan at six weeks.
- To compare fracture union at specified intervals after conservative treatment and arthroscopy-assisted screw fixation.
- To compare clinical outcome in patients with wrist sprains randomized to either immediate mobilization or to two weeks of immobilization in a cast.
- To assess the long-term clinical outcome after distal scaphoid fractures.
- To assess the development of radiological osteoarthritis in the scapho-trapezium-trapezoid (STT) joint following distal scaphoid fractures.

*"Du ser att jag är en djefla man , som kan göra många konster."*

– August Strindberg, 1885



# Methods

# Patients

## The Malmö scaphoid study

During the time period when patients were included in the Malmö scaphoid study, Skåne University Hospital, Malmö, Sweden, served a population of approximately 350,000 inhabitants (2007).<sup>96-98</sup> In 2004–2008 all patients who attended our emergency department with posttraumatic radial-sided wrist pain were screened for scaphoid fractures using both conventional radiography and MRI. For patients in whom a scaphoid fracture was found, a CT was performed in addition. Depending upon the findings from these investigations, patients were allocated to different study arms, some being prospective and others randomized controlled trials. The randomized study arms ran from March 2004 to February 2007, but screening and some prospective study arms were prolonged to February 2008. In the period from March 2004 to February 2007, 425 patients completed the screening. From March 2007 to February 2008, 101 additional patients were screened, making a total of 526 patients.

## Paper 1

*Conservative treatment versus arthroscopic-assisted screw fixation of scaphoid waist fractures. -A randomized trial with minimum 4-year follow-up.*

Patients were included from March 2004 to February 2007. Inclusion criteria were age between 18 and 65 years and having a non-displaced or minimally displaced (< 1 mm displacement and < 15° volar angulation) scaphoid waist fracture, sustained within 14 days of inclusion in the study. 45 consecutive patients were randomized with a closed envelope system to either conservative treatment in a below-elbow cast or arthroscopically assisted screw fixation. They were followed at 6, 10, 14, 26, and 52 weeks with clinical examination, DASH questionnaire, and a CT scan at each visit. From 2011 to 2012, all patients were invited for an extended follow-up with clinical evaluation and CT scan.

## Paper 2

*Union of scaphoid waist fractures assessed by CT scan.*

CT scans of all patients with a scaphoid waist fracture diagnosed between March 2004 and February 2008 were re-evaluated regardless of the degree of dislocation. Inclusion criteria were age between 16 and 65 years, having been treated < 14 days after injury, and (in addition to the initial CT) having had a CT performed after 6 weeks. 65 patients met all three criteria and were included; 39 had received conservative treatment and 26 had been surgically treated.

Of the 65 patients, 38 patients with non-displaced or minimally displaced fractures were part of a randomized trial (paper 1): 23 had been conservatively treated and 15 had been surgically treated. The randomized patients were followed with CT scans at 10, 14, 36, and 52 weeks.

### Paper 3

*Is early mobilization better than immobilization in the treatment of wrist sprains?*

Patients were included from March 2004 to February 2007. The inclusion criteria were age > 18 years, having had a maximum of 14 days between injury and examination, and having no signs of any wrist fracture or obvious ligament injury, either on the radiographs or on the MRI. Two hundred and ninety-six patients were examined and 104 wrists fulfilled the inclusion criteria. Forty-three patients with unilateral injury agreed to participate in the study and they were randomized using a closed envelope system to 2 weeks of immobilization in a dorsal wrist cast or to immediate mobilization. They were followed clinically at 2, 4, and 6 weeks.

### Paper 4

*Long-term outcomes after distal scaphoid fractures. A 10-year follow-up.*

In 2015, we re-evaluated the images of patients with a fracture in the distal third of the scaphoid who were included from March 2004 to February 2008. The inclusion criterion was having had a distal fracture, but the time from injury to diagnosis and the age of the patient were of no concern. Fifty-five patients were identified. Six patients were excluded; one had died, one had dementia, three had other disorders, and one had moved abroad. Forty-nine patients with distal fractures were invited for an extended follow-up. Nine patients declined or could not be reached, so 40 patients with 41 fractures were assessed in 2016.

## Imaging

All patients had conventional radiographs taken initially (AXIOM Aristos FX; Siemens AG, Forchheim, Germany) when they attended the emergency department. Standard posteroanterior and lateral wrist views were taken, and also four views of the scaphoid (posteroanterior with ulnar deviation and with the X-ray beam centred over the anatomical snuffbox angled 10° cranially, 10° caudally, 20° ulnarly, and 20° radially). A fracture was defined as a break in the continuity of the bone.

Regardless of findings on the initial radiographs, all patients had an MRI within three working days. The MRI was done in a 0.23 Tesla, low-field MRI unit (PROVIEW; Marconi Medical Systems, Vantaa, Finland) that was dedicated to the study. The hand to be examined was placed and secured in an MRI wrist coil and examined with the following study protocol: coronal short tau inversion recovery (STIR), 3 mm slice thickness; coronal T1 field echo three-dimensional (FE3D), 2 mm slice thickness; axial T1 fast spin-echo (FSE), 3.5 mm slice thickness; sagittal T1 field echo three-dimensional (FE3D), 2 mm slice thickness. MRI was considered positive for a fracture when a cortical and trabecular fracture were present, causing intramedullary hyperintensity on the STIR and also intramedullary hypointensity on T1-weighted images extending to the cortices.<sup>51</sup>

If a scaphoid fracture was found, a CT was immediately performed using a 16-slice CT scanner (Somatotom Sensation 16; Siemens AG, Forchheim, Germany). The patient was placed prone with the hand to be examined above the head (superman position). A scout view was obtained before the scan. Axial sections of 0.6-mm-thick slices were obtained, enabling 1- or 2-mm-thick reconstructions in the coronal and sagittal planes defined by the long axis of the scaphoid. The same protocol was used for the follow-ups during the first year. On CT, a fracture was defined as the presence of a sharp lucent line within the trabecular bone and a breakage in the continuity of the cortex.<sup>99</sup> For the extended follow-up in paper 1, a 64-slice CT scanner was used (Somatom Sensation 64; Siemens AG, Forchheim, Germany). In paper 4, bilateral wrist CT scans were obtained with a 320-slice CT scanner (Aquilion One, Toshiba Medical Systems Corporation, Tochigi-Ken, Japan) at the extended follow-up. In both the 64-slice scanner and the 320-slice scanner, patients were positioned prone with one or both hands above the head (superman position). Axial 0.5-mm-thick sections were obtained with 1-mm-thick reconstructions in the coronal and sagittal planes defined by the long axis of the scaphoid.

The radiation dose from the initial CT investigations was approximately 0.02 mSv, and at follow-up in paper 4 it was 0.009 mSv. A dose of 0.01 mSv is equivalent to one day of background radiation and a dose below 0.1 mSv is considered to be of no medical importance.<sup>49</sup>

## Assessment of images

Fractures were categorized as proximal, middle, or distal, based on which third of the bone the major part (> 50%) of the fracture line was situated in. The allocation of fractures was done based on the oblique radiographic view, in which the scaphoid bone is visualized over its entire length, combined with information from MRI and reconstruction of CT images. The same senior expert radiologist evaluated all examinations (Dr Jack Besjakov).

### Paper 1.

Fractures were classified according to Herbert and Fisher,<sup>55</sup> and we also specified whether they were comminuted, typically represented by a separate cortical or corticospongyous fragment on the radial side of the scaphoid.

At the extended follow-up, arthritis in the radioscapoid joint was assessed on CT scans with reconstructions in the long axis of the scaphoid. Joint space was measured at the narrowest point and compared to approximately the same spot and projections on the primary CT. Arthritis was defined as a reduction in joint space by > 50%. A consensus reading of all images was done by a senior expert radiologist (Dr Jack Besjakov) and one of the senior authors (Dr Niels Thomsen or Dr Anders Björkman).

## Paper 2

Patients with a scaphoid waist fracture who had CT scans at the time of injury and after 6 weeks were included. A senior expert radiologist (Dr Jack Besjakov) and the senior author (Dr Niels Thomsen) together re-evaluated all images in a consensus manner. Fracture gap and translation (step-off) were assessed on the coronal and sagittal images from the initial CT scan. The maximum displacement noted on the initial CT scan was used to categorize the fracture as: minimally displaced ( $\leq 0.5$  mm), moderately displaced (ca. 1 mm), or severely displaced ( $\geq 1.5$  mm).<sup>100</sup>

The degree of fracture union was calculated using the sagittal CT reconstructions as described by Singh et al.<sup>72</sup> The percentage of bone contact over the fracture cross section at follow-up was graded as 0-24%, 25-49%, 50-74%, 75-99%, or 100%. The grading was estimated by using average measurements from four consecutive sagittal and coronal cuts from the CT scan. Ultimately, we assessed whether the fracture had united, which was defined as not just bone contact but as a continuous trabecular pattern over more than 50% of the cross section of the fracture.<sup>73, 100</sup> The reference standard to confirm fracture union was based on an additional CT scan at least 6 months after treatment.<sup>101</sup>

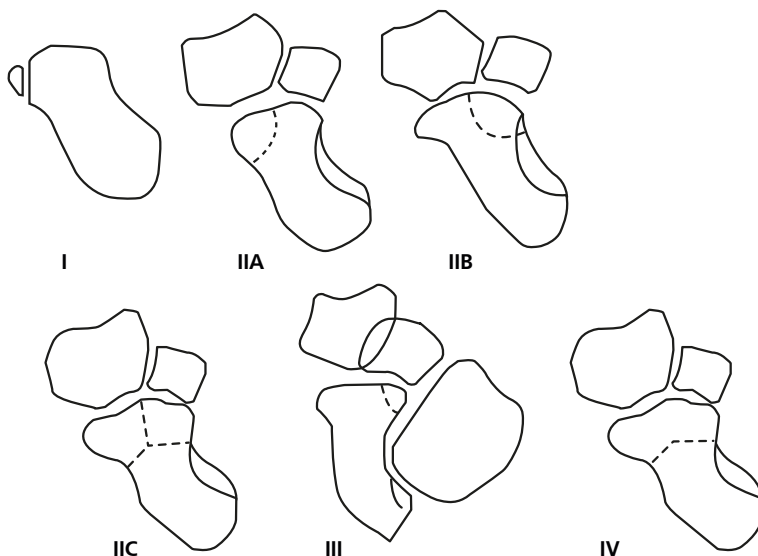
## Paper 3.

Patients had to be negative regarding any fracture on both radiographs and MRI. However, signs of bone bruising, bleedings, or oedema on the MRI were accepted. Importantly, the examinations should not show any sign of SL ligament injury on radiographs, defined as an increased SL distance ( $\geq 5$  mm) or an increased SL angle ( $\geq 60^\circ$ ), or a visible disruption of the SL ligament on MRI.

## Paper 4

Fractures in the distal third of the scaphoid that were visible on MRI were included. Sagittal and coronal reconstructions in the longitudinal axis of the scaphoid on the primary CT were used to classify the fractures according to a modified version of the classification described by Prosser et al.<sup>57</sup> Prosser's original classification was based on how the fractures appeared on radiographs. Since we had CT scans of all patients, we were able to improve the accuracy in the definitions of fracture types by specifying where in the STT-joint the fractureline should emerge in the different types. During the initial classification of the patients we discovered two patients with transverse extra-articular fractures in the distal third of the scaphoid that did not fit into the classification. The fracture type is however described in the Mayo classification as a class 3 fracture and in the AO system as a 72-A3 fracture. We decided to include this as a type IV in the Prosser classification.<sup>102, 103</sup> *Figure 11.*

Arthritic changes in the STT joint were assessed on sagittal reconstructions in the longitudinal axis of the scaphoid. The distance over the STT joint was measured at its narrowest point and compared to the same distance on the contralateral hand.



**Figure 11. | Classification of distal scaphoid fractures.**

Modified from Prosser et al. A type IV, extra articular transverse fractures, has been added to the original system.

Type I – extra-articular avulsion fracture.

Type IIA – radial fragment with fracture line within the trapezium articulation.

Type IIB – ulnar fragment with fracture line within the trapezium articulation.

Type IIC – Y-fracture, combination of IIA & IIB.

Type III – fracture line within the trapezoidal articulation.

Type IV – Extra-articular transverse distal fracture

From Prosser et al. 1988.<sup>57</sup>

Permission granted from publisher.

The joint space was classified into four categories: no apparent reduction, slight reduction (< 50%), reduction > 50%, and complete attrition between joint surfaces. Periarticular arthritic changes were recorded in terms of subcortical sclerosis, osteophytes, or cysts. These findings were summarized into a modified version of White's classification system.<sup>89</sup> *Table 1.*

Finally, posttraumatic changes such as step-off in the cortex or malunions were recorded.

All images, both at injury and at follow-up, were evaluated by the same senior radiologist (Dr Jack Besjakov).

**Table 1. | Classification of STT-arthritis.**

System used for classification of STT-arthritis based on CT in paper 4 in comparison with system described by White et al.<sup>89</sup> based on radiographs.

Stage	Definition in paper 4. CT	Definition by White. Radiographs
0	Joint space <50% reduction* and no arthritic changes†	
1	Joint space <50% reduction + arthritic changes, or joint space >50% reduction +/- subcortical sclerosis.	Narrowing of joint space +/- subcortical sclerosis
2	Joint space >50% reduction + arthritic changes.	Narrowing of joint space + more than one of arthritic changes
3	Joint attrition with bone to bone contact.	Complete narrowing of joint

\* joint space in comparison with contralateral STT-joint

† subcortical sclerosis, osteophytes or cysts

## Treatment

### Conservative treatment.

Conservative treatment of scaphoid fractures consisted of a below-elbow cast incorporating the thumb up to the interphalangeal joint. For waist fractures in papers 1 and 2, the first control was after 6 weeks. The cast was removed when there were signs of radiological union.

In paper 4, distal fractures were treated for four weeks. If clinical symptoms persisted, the immobilization period was prolonged for two additional weeks.

In paper 3, immobilized patients had a standard dorsal wrist cast for two weeks.

### Arthroscopic-assisted percutaneous screw fixation.

Surgery was performed under axillary block or general anaesthesia with a 1.9-mm or 2.7-mm arthroscope (Smith & Nephew, Andover, MA, USA) using standard 3–4, 4–5, mid-carpal radial, and mid-carpal ulnar portals. Arthroscopically assisted fracture fixation was done with a cannulated compression screw (3.0-mm HBS; KLS Martin Group, Mühlheim, Germany, or 3.2-mm TwinFix; Stryker, Kalamazoo, MI, USA) inserted percutaneously in the dorsal to volar direction through the 3–4 portal. Repositioning and screw placement were assessed both arthroscopically in radiocarpal and mid-carpal

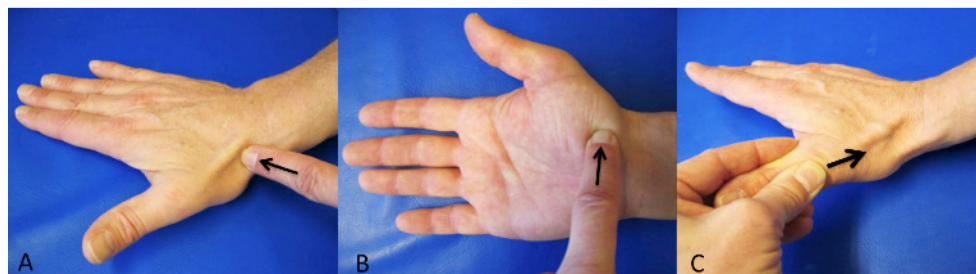
joints and radiologically using a fluoroscan image intensifier. All patients were operated by one of the senior authors (Dr Peter Jørgsholm, Dr Niels Thomsen, or Dr Anders Björkman), who have several years of experience in wrist arthroscopy. Postoperatively, the patients were immobilized in a cast for 2 weeks, after which physiotherapy was initiated. They were instructed to avoid heavy loading of the hand and wrist for 6 weeks.

Arthroscopy revealed several patients with concomitant SL ligament injury.<sup>104</sup> Complete lesions (Geissler grade IV)<sup>105</sup> were treated with additional pinning of the SL interval and were excluded from paper 1.

## Clinical examination and functional outcome

At inclusion, patients underwent three clinical tests: tenderness in the anatomical snuffbox (fossa Tabatière), scaphoid tubercle tenderness, and pain on longitudinal compression of the thumb. *Figure 12*. If one of the tests was positive, the patient was referred for further radiographic investigation of the wrist. After imaging, the patients attended the Department of Hand Surgery where they were invited to participate in the Malmö scaphoid study. All patients were re-examined by a hand surgeon.

The patients included in the randomized treatment study in papers 1 and 3 were re-examined at specified intervals during the first year. A hand surgeon performed the same tests as at inclusion, and clinical outcome assessments were done by two experienced hand therapists. Range of motion was measured in a standardized fashion with a goniometer. Grip strength was measured with an Exacta hydraulic hand dynamometer (North Coast Medical, Gilroy, CA, USA), and pinch strength with a pinch gauge (B&L Engineering, Santa Ana, CA, USA). Strength was calculated as the mean of three measurements. Outcome was reported as a percentage of the measurements in the contralateral hand in papers 1 and 3, and as absolute values in paper 4.



**Figure 12.** | Clinical tests for scaphoid fracture.

A, Anatomical snuffbox tenderness. B, scaphoid tubercle tenderness. C, pain on longitudinal compression of the thumb.



At the extended follow-up in papers 1 and 4, patients were also tested for SL ligament stability using the Watson shift test.<sup>106</sup> A painful clunk and subluxation when performing the test were considered positive for instability. Both wrists were examined and compared. In paper 4, pain upon radial and ulnar deviation was also recorded.

## Subjective outcome

Pain was evaluated using a VAS graded from 0 (no pain) to 10 (worst imaginable pain). Patients completed the Swedish version of the DASH questionnaire.<sup>75</sup> At the final follow-up in paper 4, the abbreviated version, quick-DASH, was used.

In paper 4, patients also completed the validated Swedish version of the PRWE questionnaire.<sup>78</sup> *Appendix 1 and 2.*

In papers 1 and 4, patients were asked to rate their satisfaction with their treatment outcome and wrist function on an arbitrary 5-grade scale: “Completely satisfied”, “Very satisfied”, “Satisfied”, “Unsatisfied”, “Very unsatisfied”.<sup>107</sup>

## Statistics

Medians (with range) are given for ordinal variables and also for ratio variables, where numbers of cases were small and even the distribution of the data was not certain. Differences between medians were tested with the non-parametric Mann-Whitney U-test.

Mean values were calculated for ratio variables with normal distribution, and differences between means were tested with Student’s t-test.

Dicotomous variables were tested using the Chi<sup>2</sup> test or Fisher’s exact test.

Linear association between the degree of fracture dislocation and fracture union was tested using the linear-by-linear association test.

Inter-observer agreement for fracture classification and staging of arthritis in paper 4 was calculated based on an independent assessment of all CT scans by two of the authors (JB and MC). A *Kappa* value of 1 corresponds to perfect agreement, and a value of 0 corresponds to pure chance. Generally, agreement between readers is categorized as:  $\leq 0.20$ , bad; 0.21–0.40, poor; 0.41–0.60, fair; 0.61–0.80, good; and 0.81–1.0, very good.<sup>108</sup>

Statistical calculations were done with SPSS 20.0 (SPSS Inc., Chicago, IL, USA).

Confidence intervals were set to 95% and any *p*-values  $< 0.05$  were considered statistically significant.

# Ethics

The regional ethics committee of Lund University approved the Malmö scaphoid study (LU 459-03). The long-term follow-up in paper 4 was also approved in an addendum (LU 2015/787). Informed written consent was obtained from all participating patients and, if the participant was under 18 years of age, also from the parents.

The studies were also approved by the regional committee for radiation safety.

# Results

# Summary of results

## Paper 1

Forty-five consecutive patients were randomized to either conservative treatment in a below-elbow cast ( $n = 24$ ; median age 29 [18–62] years; 4 females), or to arthroscopy-assisted screw fixation ( $n = 21$ ). None of the initial radiographic or clinical examinations indicated the presence of intrinsic ligament injury, but we found six patients with complete SL ligament tears (Geisler 4). We chose to treat them with additional K-wire pinning and they were excluded from paper 1, but were followed as initially planned and are reported separately below. One other patient in the surgical group declined further participation after randomization, which is why the surgically treated group consisted of 14 patients (median age 30 [18–63] years; 3 females). At the extended follow-up in 2011–2012, 21 patients in the conservative group and 14 in the surgical group were available for follow-up.

Arthroscopic-assisted screw fixation in the patients in the surgical treatment group was performed at a median time of 10 (4–17) days after injury.

At 10 weeks, there was no difference in range of motion (ROM) between surgically and conservatively treated patients (80% vs. 63%,  $p = 0.28$ ). However, at 26 weeks ROM was significantly better in the conservatively treated patients (88% vs. 97%,  $p = 0.004$ ). At this measuring point, the conservatively treated patients had almost reached normal values. Grip and pinch strength showed no significant differences between the two groups at any measuring point. *Figure 13.*

DASH score at 6 and 10 weeks showed significantly higher disability in the conservatively treated group than in the operated group ( $p = 0.001$  and  $p = 0.025$ , respectively). At later measuring points, there was no significant difference. *Figure 14.*

At the long-term follow-up at median 6 (4–8) years, we could not find any significant differences in any clinical outcome parameter between the two treatment groups.

At the 6-year follow-up, radiographic signs of arthritis in the radioscapoid joint were more frequent in the surgically treated group (3 out of 14 patients) than in the conservative group (2 out of 21) ( $p = 0.37$ ). Two of these five patients reported minor radial-side wrist pain and discomfort after wrist loading. One had undergone surgical treatment, and the other—who had been treated conservatively—had developed avascular necrosis in the proximal pole of the scaphoid.

A positive Watson shift test was found in 1 of 14 of the surgically treated patients as compared to 5 of 21 patients in the conservatively treated group. However, none of these six patients showed radiographic signs of arthritis, scapholunate dissociation, or dorsal intercalated segmental instability on CT scan.

### Six patients with complete SL tear

Six patients in the surgically treated group had complete Geissler 4 tears in the SL ligament and were excluded from paper 1. Four patients received both screw fixation and K-wire pinning of the SL interval, and two received K-wire pinning of both the SL interval and the scaphoid fracture. Median age was 48 (19–65) years, and there were two females. Median time to fracture healing was 6 (6–14) weeks. Three patients showed arthritis in the RS joint at final follow-up, after median 6 (5–7) years. Two of these were asymptomatic, but one had some pain in the wrist. Median ROM and median DASH score are shown in *Figures 13 and 14*.

*Erratum:* In the published article in table 2, page 1345, patient no. 26 in column 9 “Arthritis in RS joint” - is stated: “Yes”, should be: “No”.

### Paper 2

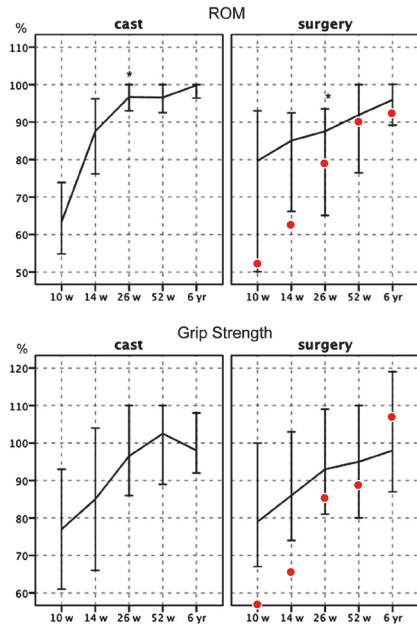
Sixty-five patients were included; 39 had received conservative treatment (median age 28 [17–62] years; 5 females) and 26 had been surgically treated (median age 31 [16–63] years; 4 females). A subgroup of 38 patients with non-displaced or minimally displaced fractures was part of a randomized trial (paper 1), with 23 being conservatively treated and 15 being surgically treated.

The 6-week CT scan demonstrated that 27 of 30 (90%) of the non-displaced or minimally displaced fractures in the conservatively treated group had united. The number of patients with moderate or severe fracture displacement that was treated conservatively was too small to provide valid frequencies on fracture union in these subgroups. Of the five fractures with uncertain union at six weeks, four were classified as healed after 10 weeks, and one after 14 weeks.

In the operatively treated group, the union rate at six weeks for non-displaced or minimally displaced fractures was nine out of 11 (82%), and it was four out of 10 (40%) for the severely displaced fractures. The numbers in the moderate and severe displacement groups were too small to be able to make any conclusions regarding any association between fracture displacement and fracture union ( $p = 0.06$ ). Of the eight fractures with uncertain union at six weeks, four were classified as united at 10 weeks, one at six months, two at 12 months, and one had developed into a non-union. All fractures with prolonged time to union ( $> 14$  weeks) were classified as severely displaced.

Fracture comminution indicated by a separate cortical or corticospongious fragment on the radial side of the scaphoid was common, even for the non-displaced or minimally displaced scaphoid fractures: 14 out of 41 (34%).

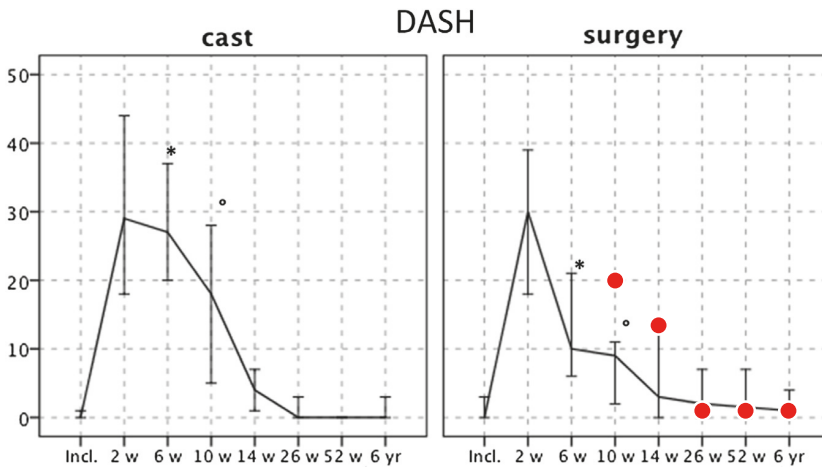
In the subgroup of patients with non-displaced or minimally displaced fractures randomized for conservative treatment or arthroscopy-assisted screw fixation, we found that 19 of 23 (83%) of the conservatively treated fractures had united at 6 weeks, 22 of



**Figure 13. | Clinical outcome paper 1.**

Range of motion (flexion + extension) and grip strength expressed as a percentage of the contralateral hand. Lines represent median value and whiskers represent confidence interval. \* - Significant difference ( $p=0,004$ ).

Red dots – median values for patients excluded for concomitant SL ligament ruptures.

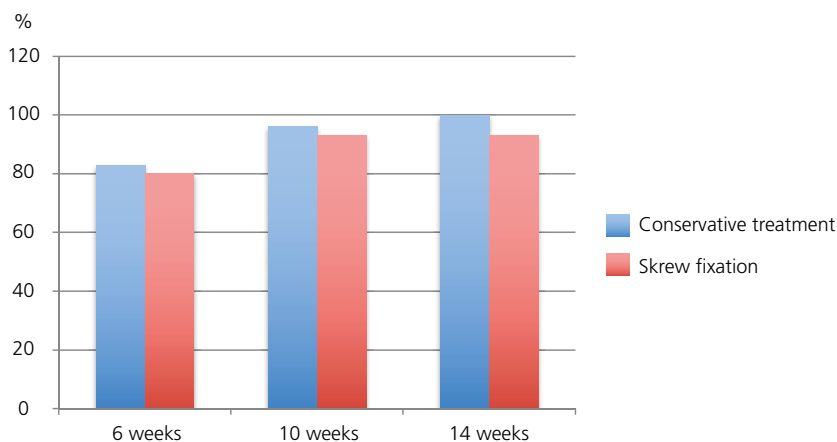


**Figure 14. | Subjective outcome paper 1.**

DASH score at each measure point. Lines represent median value and whiskers represent confidence interval. \* - Significant difference ( $p=0,001$ ). ° - Significant difference ( $p=0,025$ ).

Red dots – median values for patients excluded for concomitant SL ligament ruptures.

23 (96%) had united after 10 weeks, and 100% had united by 14 weeks. All four fractures that united later than 6 weeks were comminuted. In the operated group, 12 of 15 (80%) had united at 6 weeks, increasing to 14 of 15 (94%) after 10 weeks. One fracture did not unite until 1 year after surgery. There were no significant differences in union rate between the two treatment groups at any measuring point ( $p = 1.00$ ). *Figure 15.*



**Figure 15. | Union of randomized patients, paper 2.**

Percentage of randomized fractures considered united at each time point. Conservative treatment n=23, skew fixation n=15.

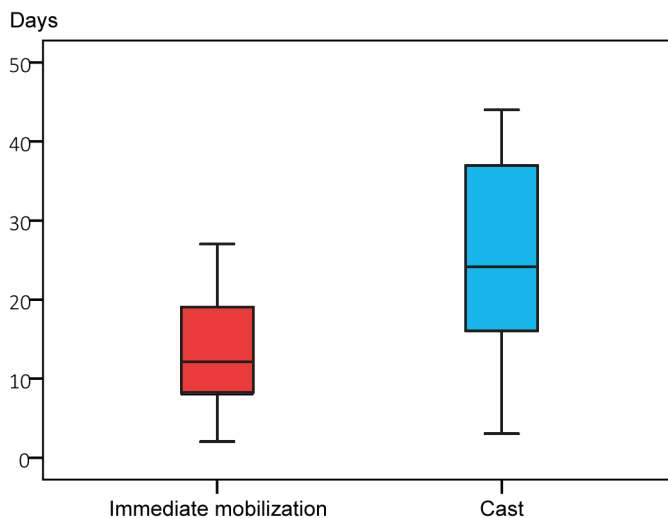
### Paper 3

Of the 104 patients/wrists that met the inclusion criteria, only 43 patients with unilateral injury agreed to participate further and they were randomized to 2 weeks of immobilization in a dorsal wrist cast (n = 21; median age 31 [18–57] years; 12 females) or immediate mobilization (n = 22; median age 31 [18–64] years; 12 females).

At 2 weeks, the patients treated with immobilization in a cast showed a reduced median ROM (77% vs. 96%;  $p = 0.011$ ) and a higher median DASH score (37 vs. 18;  $p = 0.009$ ) than the group that was mobilized immediately. The two treatment groups showed no significant difference in grip and pinch strength or pain score (VAS). Median pain score (VAS) was 0 (range: cast, 0–2; mobilization, 0–5) in both groups.

At 4 weeks, median DASH score was still significantly higher in patients who were treated with cast immobilization (14 vs. 4;  $p = 0.010$ ), but there was no longer a significant difference in ROM.

At 6 weeks, we could not find any significant difference between the two groups in any variable.



**Figure 16. | Sick leave, paper 3.**

Sick leave in patients with wrist sprains in the two treatment groups. Immediate mobilization n=15, cast immobilization n=11.

Boxplots showing medians and 25%–75% quartiles, whiskers show range. Statistical outliers are not shown.

Twenty-six of 43 patients (11 treated with cast immobilization and 15 treated with immediate mobilization) required sick leave because of the injury. Median time off work for the cast-immobilized patients was 27 (3–159) days, and for those treated with immediate mobilization it was 14 (2–105) days ( $p = 0.077$ ). *Figure 16*. We did not find any significant difference in sick leave between manual and non-manual workers.

## Paper 4.

Forty-nine patients with a distal scaphoid fracture were invited for an extended follow-up. Nine patients declined or could not be reached, so 40 patients with 41 fractures were followed up in 2016. Median age at injury was 19 (9–65) years, and there were 12 females.

Median time from injury to follow-up was 10 (8–11) years.

According to our modified Prosser classification system, there were 26 type-I fractures, 12 type-IIA, one type-IIC, and two type-IV fractures. Patients with a type-I fracture were significantly younger (median 15 [9–65] years) than those with type-II to type-IV fractures combined (median 26 [17–57] years) ( $p = 0.02$ ).

Five out of the 12 type-IIA fractures were dislocated: 4 of them between 0.6 and 1.0 mm, and one patient had a dislocation of 1.4 mm.



At follow-up, we found a non-union in a 30-year-old male who had a type-I fracture. Two of the 12 type-IIA fractures showed malunion with a gap of > 1 mm in the joint surface. Both the non-union and the malunions were asymptomatic and there were no arthritic changes in the STT joints.

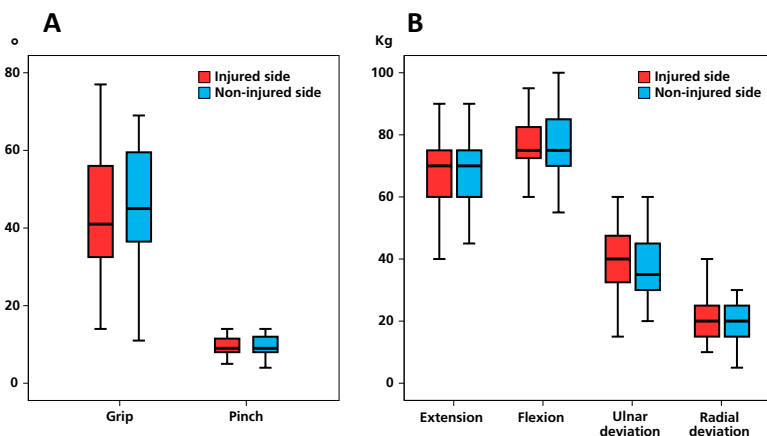
Arthritis in the STT joint was found after five type-I and two type-IIA fractures. Four were diagnosed as stage 1, and three as stage 2 arthritis. All the wrists with stage 1 arthritis initially had a type-I fracture.

None of the 41 wrists showed any sign of dorsal intercalated segmental instability (DISI).

At clinical examination, 16 out of 41 wrists were more tender in the anatomical snuff-box than on the contralateral side. This symptom was not associated with fracture type or presence of arthritis. Four out of the 41 wrists had a positive Watson's shift test.

Wrist range of motion, grip, and pinch strength were not significantly different between the injured side and the non-injured side. *Figure 17.*

Median VAS for pain was 0 (0–5) at rest. Median DASH score was 2 (0–36). Median PRWE value was 0 (0–55). On the arbitrary wrist-function satisfaction score, 28 of the 41 wrists were rated as “completely satisfied”, 8 as “very satisfied”, 1 as “fairly satisfied”, 3 as “not satisfied” and 1 as “very dissatisfied”. The four dissatisfied patients were also the ones who reported the highest DASH and PRWE scores. They all had other conditions that might explain their reduced wrist function.



**Figure 17. | Clinical outcome, paper 4.**

A. Wrist motion in injured and contralateral wrists.

B. Grip and pinch strength in injured and contralateral wrists.

Boxplots showing medians and 25%–75% quartiles, whiskers show range. Statistical outliers are not shown.

Of the 7 patients with arthritis (apparent on the CT scan), 6 were free of pain and rated themselves as being “completely satisfied” or “very satisfied”. The last patient, who was very dissatisfied, had a type-I fracture and showed grade-1 arthritis at follow-up. We found tenderness on palpation in the anatomical snuffbox, but no other wrist symptoms. Importantly, the functional disability in the hand was due to a recent, traumatic, complete radial nerve lesion in the upper arm.

# Discussion

# Diagnostics

## Clinical examination

Pain in the radial side of the wrist following a trauma should always evoke the suspicion of a scaphoid fracture. In our cohort, the orthopaedic surgeon who was on call in the emergency ward, usually a resident, examined the patients. These orthopaedic surgeons were instructed to conduct three clinical tests to assess a patient for a scaphoid fracture: pain in the anatomical snuffbox, on the scaphoid tubercle, and/or upon longitudinal compression of the thumb. If any of these were found positive, the patient should be enrolled in the prospective image screening. The wide indication for inclusion in our protocol should have minimized the risk of a false-negative clinical examination, thereby missing a scaphoid fracture. Still, we had an acceptable specificity, as we found a scaphoid fracture in 42% of adults and 53% of paediatric patients. This is more than the 28% reported by Duckworth et al.<sup>40</sup> The reason for this could be the level of expertise of the doctors on call, and also the fact that we performed MRI on all patients.

A trauma to the wrist is a common reason for attending the emergency ward. Selecting which patients should be referred to the first line of radiological examination and also which patients with normal radiographs should be subjected to second-line investigations is a challenging task for the doctor on call. Thus, the clinical tests must have a high specificity and sensitivity in identifying patients with indications for radiological investigation, but at the same time the services from the radiology department should be used wisely. After the Malmö scaphoid study, other studies have been presented on diagnostic algorithms that might further enhance the diagnostic accuracy. The clinical scaphoid score (CSS) described by Bergh et al. has a negative predictive value of 96% in patients with negative radiographs,<sup>39</sup> and Duckworth et al. demonstrated that patients with pain in the anatomical snuffbox on ulnar deviation (especially males), trauma during sports, or pain on pinching the thumb and index finger, should be referred further for radiological investigation. These authors also showed that patients with no pain in the anatomical snuffbox upon ulnar deviation of the wrist could be safely discharged.<sup>40</sup>

*Figure 6.* Further studies are needed to evaluate these diagnostic algorithms in clinical settings.

## First-line investigation with radiographs

The American College of Radiology recommended in 2013 that patients with clinically suspected scaphoid fractures should be examined with two wrist projections and four scaphoid projections: postero-anterior (PA), lateral, PA with ulnar deviation, and semi-pronated oblique (writing position).<sup>43</sup> In the Malmö scaphoid study, a slightly different protocol was used: PA with ulnar deviation and the X-ray beam centred over the anatomical snuffbox angled 10°cranially, 10° caudally, 20° ulnarly, and 20° radially.

With this protocol, we achieved a sensitivity of 70% for detection of scaphoid fractures, which is less than the  $\approx 80\%$  found in earlier studies.<sup>10, 43</sup> The difference in sensitivity can be explained by the fact that we examined all the patients with MRI, not only those with negative radiographs. We therefore detected a higher number of occult scaphoid fractures, many of which also had other concomitant fractures.

## MRI for second-line investigation

Traditionally, patients with a suspected scaphoid fracture and negative radiographs have been treated in a cast for 10–14 days, after which a second radiograph is taken.<sup>44</sup> This practice is still common in many clinics.<sup>109</sup> However, MRI as soon as possible after the trauma is proposed to be the modality most suited for detection of occult scaphoid fractures.<sup>43</sup> In addition MRI in patients with posttraumatic radial-sided pain and negative radiographs can reveal other pathologies such as bone bruising, bleedings, and oedema.<sup>11, 41</sup> These diagnoses might not always warrant any specific treatment, but can explain symptoms such as pain from the wrist.

Previous reports from the Malmö scaphoid study cohort showed that other carpal fractures, especially capitate fractures, are not uncommon in patients who are suspected of having a scaphoid fracture. These fractures are difficult to diagnose even with CT, which is why MRI is preferable.<sup>11</sup> In the Malmö scaphoid study, 65% of patients with posttraumatic radial-sided wrist pain had a fracture. Some of the patients who did not have a fracture had smaller ligament bleedings and bone bruises that might benefit from immobilization. In paper 3, we assessed whether these patients, in which MRI were negative regarding fracture, benefit from immobilization or early mobilization and found that the mobilized patients did better in terms of mobility and had a better subjective functional scoring (DASH). This suggests that an early MRI with an early diagnose may be beneficial for patients with posttraumatic radial-sided wrist pain and normal radiographs.

## CT for classification

In this thesis, all the patients who had a scaphoid fracture also had a CT performed for fracture classification. With MRI as the golden standard for detection of scaphoid fractures, CT had a sensitivity of detection of scaphoid fractures of 95%.<sup>11</sup> CT has proven to be superior to radiography in ruling out a fracture displacement.<sup>110</sup> This matters, as in paper 2 we found that fractures with a dislocation of 1.5 mm or more on CT were united to a lesser extent than non-displaced or minimally displaced fractures after six weeks of immobilization. This finding was not statistically significant, but it is in accordance with the findings of Grewal et al. who showed that dislocated fractures have a longer time to union and also a higher rate of non-union.<sup>62</sup> In our study—as well as in other studies on non-displaced waist fractures classified with CT—the union rate with conservative treatment approaches 90–100%.<sup>60, 62</sup> Hence, a reliable and precise

classification of scaphoid fractures is imperative in order to predict the prognosis of the fracture and to decide which treatment should be given. As radiographs are insufficient to provide this information, it has been suggested that a CT should be performed on all diagnosed scaphoid fractures and on all suspected fractures, preceding MRI as a second line of investigation, and that MRI should be reserved for patients with suspected scaphoid fractures and a negative CT.<sup>111</sup>

## Classification of distal scaphoid fractures.

In paper 4, we investigated the outcome after distal scaphoid fracture. Theoretically, different fracture patterns can result in a different risk of developing arthritis and non-union. Thus, an exact characterization of the fracture is necessary in a study focusing on describing outcome after a fracture. We chose to use the classification described by Prosser et al., as it is quite detailed and is also the one used most often for distal fractures.<sup>54, 57</sup> *Figure 11*. Prosser's classification is based on radiographs, and the authors stated in the original article that type I and IIA are not always easy to differentiate. We used CT with reconstructions in the long axis of the scaphoid, and we could therefore localize the fracture line more precisely and distinguish more exactly between the types described. The inter-observer analysis of this CT-based classification showed good agreement between the two readers ( $k = 0.78$ ), thus strengthening the reliability of this system.

## Fracture union determined by CT

When we discuss union, we often mean two things: (1) Fracture healing is a continuous process and at some stage in this process of developing matrix and mineralization the fracture is stable enough to allow mobilization. (2) A state in which there is complete consolidation of the fracture with no remaining fracture line. Neither of these conditions can be reliably estimated using plain radiographs, at least within a year of fracture,<sup>5</sup> which is why the role of radiographs in assessment of union is questionable. Using CT, this assessment is more reliable.<sup>70, 71</sup> In paper 2, we investigated the rate of union in fractures after 6 weeks using the method described by Singh et al.<sup>72</sup> This method has been used in several articles on scaphoid union.<sup>60, 62, 73</sup> It was not just bone contact that was evaluated: for the fracture to be considered functionally stable, there had to be a continuous trabecular pattern over more than 50% of the cross section of the fracture. There were some difficulties, however. In the ideal case, the degree of union should be assessed in all slices covering the scaphoid. With a modern CT scanner, one can get more than 15 slices in the long axis of the scaphoid. Furthermore, it is difficult to assess the precise union in a slice, so most previous studies have used intervals instead of exact numbers. It is our experience that intervals are more appropriate, and that the most important assessment is whether the union rate is above or below 50%.

## CT and radiation load

One argument against using CT for classification and evaluation of fracture union has been the radiation load that the patient is exposed to. However, with modern multi-slice scanners the effective dose in a wrist examination in superman position is < 0.01 mSv. Even if a patient is examined repeatedly for assessment of union, the total dose is well below 0.1 mSv and is therefore of no medical importance.<sup>49</sup>

# Treatment and outcome

## Wrist sprains.

A sprain has been defined as a partial ligament tear with normal radiographs.<sup>112</sup> With the introduction of MRI, this definition is difficult to hold on to. MRI in patients with posttraumatic radial-sided wrist pain often allows diagnosis of a wide range of different injuries, mainly in ligaments and soft tissue, as seen in earlier reports from the present cohort as well as in the study by Bergh et al.<sup>11, 41</sup> Note that patients in our cohort were included for just radial-sided wrist pain, not ulnar-sided wrist pain. Ulnar-sided problems and sprains are not discussed further here.

The precise diagnostic performance of MRI also poses a challenge for the treating doctor, and several questions should be asked. For example, are the findings on the MRI significant for the symptoms? In cases where several different pathologies are detected, which pathology is the one giving the symptoms? Lastly, does the patient benefit from treating it/them?

In paper 3, we found no benefit of immobilizing patients in whom MRI had precluded a fracture and in whom we did not suspect an SL ligament injury (either on MRI or on clinical investigation), and we included patients with changes such as bone bruising, ligament bleeding, and oedema. Patients who were mobilized immediately had better wrist range of movement and lower DASH score at two weeks, when the immobilized patients had their cast removed. Interestingly, both groups reported the same level of pain. The DASH score was also lower at 4 weeks. This is in accordance with previous studies comparing clinical outcome after immobilization with clinical outcome after early mobilization of wrists where MRI did not show any fracture.<sup>113-115</sup> The difference in range of motion was transient, and at six weeks there were no significant differences between the groups.

Previous studies have shown a reduced time off work in patients who have early mobilization.<sup>113, 114</sup> In our material, there was a trend towards this—as the immobilized patients in need of sick leave had twice as many days off work as those who were mobilized im-

mediately, but the difference was not statistically significant ( $p = 0.077$ ). As discussed also by Patel et al., who had similar findings, we probably had too few patients to be able to show that this difference was significant.<sup>115</sup> Studies on sick leave are, however, difficult to compare because of the differences in health insurance systems in different countries. From a socioeconomic point of view, an acute MRI in patients with a clinically suspected scaphoid fracture and normal radiographs has been suggested to be both justified and cost-effective.<sup>113, 115</sup>

When using MRI in the acute setting to identify patients with wrist sprains that could be mobilized directly, it is important to understand that MRI will detect fractures, bone bruises, and some ligament injuries, but several researches have pointed out that MRI is not reliable in ruling out an SL ligament injury.<sup>42, 116</sup> In our cohort, we had one patient with persistent pain in the area of the SL ligament but no instability. It has been suggested that 5–40% of sprained wrists have some degree of SL ligament injury,<sup>116, 117</sup> and Adolphsson and Povlsen found a complete SL ligament tear with arthroscopy in 7 of 43 wrists in patients with persistent pain but negative radiographs.<sup>118</sup> Bearing this in mind, patients with suspected scaphoid fracture and negative MRI should be examined by a physician with experience in examining wrists. If there is no suspicion of SL ligament injury, the patient can be dismissed. Otherwise, further immobilization and follow-up or diagnostic arthroscopy should be considered.

## Distal scaphoid fractures

In the cohort presented in paper 4, the distribution of fracture types was similar to that previously described.<sup>28, 30, 57</sup> Type-I fractures were the most common, followed by type-IIA fractures. Patients with type-I fractures were younger than patients with all other types taken together. It has been suggested that, even though ossification of the scaphoid progresses from distal to proximal and the distal pole is therefore ossified in these patients, the ligament insertion is still relatively stronger than the bone—which results in a fracture and not a ligament injury.<sup>31, 35</sup>

Non-union in distal scaphoid fractures is rare and often asymptomatic.<sup>57, 119</sup> Our group and also Prosser et al. found one patient each with a non-united type-I fracture, which in our case was completely asymptomatic even after ten years. Mody et al. reported four patients with non-union of the tuberosity, two of which were symptomatic.<sup>119</sup> From these few cases reported in the literature, it appears that non-union of a type-I fracture does not preclude the possibility of a satisfactory clinical result. Immobilization for 6–8 weeks in a cast, as recommended by Lee in Green's Operative Hand Surgery,<sup>2</sup> is perhaps unnecessary for this type of fracture and clinical symptoms rather than radiological union can dictate the period of immobilization. For the intra-articular fractures, a non-union might have a greater effect. Oron et al. reported a series of eight non-unions, all type-IIC fractures with concomitant DISI pattern. They stated that the comminuted fracture and the instability pattern indicated that there had been severe forces involved



in the trauma. In our series, we found one type-IIC fracture, and Prosser et al. reported two cases. All healed with 3–6 weeks in a cast. It is impossible to make generalizations from these small series, but it seems reasonable to follow intra-articular fractures in the distal scaphoid until radiological union, starting with a CT scan at 4–6 weeks.

Distal scaphoid fractures, and intra-articular fractures in particular, carry a theoretical risk of developing posttraumatic arthritis. We examined the patients in our cohort with CT after 10 years and used a modified White's classification system to grade the findings. CT allowed us a more precise assessment of joint space narrowing, as well as providing information on periarticular arthritic changes. The inter-observer analysis between two independent readers showed good agreement, which supports the reliability of the system. We found radiological signs of arthritis in the STT joint in 7 of 41 wrists. Only two of our five patients with a dislocated type-II fracture, and neither of the two patients with malunion, developed signs of arthritis. We are not aware of any other publications that have described the frequency of arthritis after distal scaphoid fractures. But similar frequencies were found after conservative treatment of waist fractures, where Saeden et al. reported STT arthritis in 4 of 16 patients at 12-year follow-up,<sup>81</sup> and Dias et al. found STT arthritis in 5 of 31 patients after 7 years.<sup>83</sup>

STT arthritis is considered to be the second most common site of degenerative changes in the wrist, although its true incidence is not known.<sup>120-122</sup> In our cohort, as in the other studies, the numbers were too small to be able to detect any association between the fracture and the arthritis observed. It appears that any possible risk of arthritis after distal scaphoid fracture must be low, since 34 of 41 wrists did not develop arthritis in 10 years.

Previous studies have suggested that the majority of patients with radiological STT arthritis are asymptomatic.<sup>123</sup> In accordance with this, six out of our seven patients with STT arthritis were completely free from pain and were satisfied with the functioning of their wrist. It appears that the presence of posttraumatic arthritis on a CT scan does not rule out a good clinical result in the time frame investigated here.

We could not find any long-term effect of a distal scaphoid fracture on the range of movement, or grip and pinch strength of the wrist. We cannot explain why many patients had tenderness in the anatomical snuffbox and not at the scaphoid tubercle, which would be more expected given the location of the fracture. However, the tenderness was not related to fracture type or the presence of arthritis in the STT joint.

The majority of patients rated their wrist function as being completely or very satisfactory, and reported low DASH and PRWE scores. Good functional outcome has been reported previously in paediatric patients 70 months after a scaphoid fracture, 80% of which were located in the distal third. In that group, 34 of 40 patients had DASH scores of < 5.<sup>31</sup>

## Scaphoid waist fractures

### Non-displaced or minimally displaced waist fractures

#### *Time to union/non-union*

We found that 90% of conservatively treated non-displaced or minimally displaced waist fractures united within six weeks. If we excluded comminuted fractures, the union rate was already 100% at this time point. This is a higher rate and at an earlier time point than the 88% at 10 weeks reported by Buijze et al. using similar criteria for union.<sup>60</sup> Grewal et al. found a time to union of 65 days for waist fractures.<sup>62</sup> They also found that fracture comminution increased the time to union. However, they did not assess union at specified intervals and they converted their findings at the time points investigated to number of days to union, which is questionable. Geoghegan et al. tested mobilization of 25 patients already at 4 weeks if the CT scan indicated union, and all united.<sup>73</sup> Taken together, the general findings suggest that a CT-verified non-displaced and non-comminuted waist fracture is a benign injury with a good prognosis. If CT at 4–6 weeks indicates union with bone contact and bridging trabecular pattern across > 50% of the fracture line, the patient can be mobilized.

When we compared the patients in the subgroup randomized to either conservative treatment or arthroscopy-assisted screw fixation, we could not detect any difference in union rate at six weeks, or at any other measuring point. No other studies that we know of have used CT at standardized intervals for this comparison. Meta-analyses of studies evaluating the difference between non-surgically and surgically treated waist fractures showed an advantage of surgical treatment regarding time to union.<sup>67, 80</sup> However, since the studies included in the meta-analyses were based on radiographs, not CT, both at inclusion and for determination of union, the value of this comparison is doubtful.

Regarding non-union, we could not detect any significant difference between conservatively treated and surgically treated patients. All healed within 14 weeks, except one surgically treated patient who was first considered united at the 52-week follow-up. Other studies of non-surgically treated patients where fractures have been classified as minimally displaced, with CT at inclusion or at first follow-up—have also shown 98–100% union.<sup>60, 73</sup> However, Grewal et al. reported a risk of non-union of 13% in minimally displaced fractures (< 1 mm dislocation).<sup>62</sup> A meta-analysis of the risk of non-union has shown a favourable odds ratio for surgical treatment over non-surgical treatment.<sup>80</sup> But the studies included in the meta-analysis had based their evaluation on radiographs at inclusion, and some had also included dislocated fractures,<sup>14</sup> which is why the results cannot be directly compared to those in our study.

#### *Functional outcome*

Faster improvement of wrist motion and grip strength and also improved self-reported hand function are often arguments used for surgical treatment of non-displaced

scaphoid waist fractures.<sup>84</sup> A recent meta-analysis has indicated that this could be true for function scores up to 12 weeks and for grip strength up to one year, but not for wrist motion.<sup>80</sup> In accordance with this, we found a significantly better self-reported function in the surgically treated patients using DASH score at 6 and 10 weeks. This probably reflects the fact that many of the conservatively treated patients still had their casts on at these time points. A DASH score of around 13 has been proposed to represent a normal functional score in a general population.<sup>76</sup> If so, the surgically treated patients had already reached this level at six weeks. In contrast to previously mentioned studies, we could not detect any difference in grip strength between the groups, not even at the early time points. When comparing grip strength after volar screw fixation, patients treated with arthroscopy-assisted dorsal screw fixation regained their strength somewhat more slowly, but there were large variations within the groups.<sup>14</sup>

In our cohort, conservatively treated patients showed slightly less wrist range of motion at 10 weeks, but at 26 weeks they had regained almost full range of motion compared to the contralateral hand, and they had a significantly better range of movement than the surgically treated patients. The question that arises is not why the conservatively treated patients did well, but rather why the arthroscopically treated patients did not do better. The arthroscopy-assisted screw-fixed patients in our cohort return slower to normal range of motion than what has been reported in patients treated with percutaneous volar screw fixation.<sup>14</sup> One argument for an arthroscopic approach is that it is ligament preserving and less traumatic than open surgery. However, comparison of our results with those of McQueen et al. indicates that the dorsal approach to the scaphoid through the dorsal radiocarpal joint capsule has more effect on wrist function than a volar approach through the STT joint. Direct comparison between the studies is not possible due to differences in inclusion and in methodology for determining union. A study that focuses on comparison of the different surgical approaches is needed.

In long-term follow-up, both conservatively treated and surgically treated patients do well. Patients in our cohort showed normal wrist motion, normal grip and pinch strength, and low values for DASH score six years after the injury. We could not detect any significant differences between conservatively treated and surgically treated patients. This is in line with previous studies and meta-analyses.<sup>80-83</sup> Even though most patients have normal function in their injured wrist, some do report minor persistent symptoms. In a 12-year follow-up study of waist fractures, Saeden et al. reported that 8 of 26 conservatively treated patients and 5 of 25 surgically treated patients sometimes felt pain or discomfort.<sup>81</sup> After a median follow-up of 10 years, Vinnars et al. found that 8 of 35 conservatively treated patients and 15 of 40 operatively treated patients stated that their wrist did not function as well as before the injury. One patient who was treated conservatively and three who were treated operatively stated that there were activities that they could not perform due to the injured wrist.<sup>82</sup> These findings are more qualitative in nature, and reflect small functional symptoms that do not always show up in reports based on standardized questionnaires.

### *Arthritis and complications*

Lindström and Nyström retrospectively studied a cohort of 229 patients with scaphoid waist fractures that had healed with conservative treatment. Their study included undislocated fractures as well as displaced and comminuted fractures. After at least seven years, they found radiocarpal arthritis in 5.2%, all of whom had some symptoms.<sup>92</sup> Düppe et al. found radiocarpal arthritis in 2% of united scaphoid fractures after 36 years.<sup>91</sup> Dias et al. followed 59 surgically or conservatively treated patients with waist fractures for a mean of 93 months, and found radiological signs of arthritis in the radiocarpal joint in 10% and in the scapho-trapezial joint in 14%. The patients with arthritis were older, and the authors noted that it was more common for patients with an abnormal scapholunate angle to develop arthritis.<sup>83</sup> Higher frequencies of arthritis have been reported in both conservatively and operatively treated patients in studies using CT at the follow-up. Saeden et al. followed 62 patients for 12 years and found radiocarpal arthritis (relative to the contralateral wrist) in 31% of conservatively treated patients and in 39% of surgically treated patients, and scaphotrapezial arthritis in 25% and 61%, respectively.<sup>81</sup> Vinnars et al. examined 62 patients after median 10 years and found radiocarpal arthritis in 10% of conservatively treated patients and in 18% of surgically treated patients, and scaphotrapezial arthritis in 3% and 38%, respectively. Neither Saeden nor Vinnars could find any association between scaphotrapezial arthritis and clinical symptoms.

We found radiocarpal arthritis in 2 of 21 conservatively treated patients (10%) and in 3 of 14 patients treated with arthroscopy-assisted screw fixation. This difference was not statistically significant, and we could not relate arthritis to any other outcome parameter such as pain, DASH, or satisfaction score. The definition of arthritis is not homogenous through the different studies,<sup>81-83</sup> and comparison is therefore difficult, but we found a lower number of patients with arthritis compared to Saeden et al. but a proportion equal to that presented by Dias et al. and Vinnars et al. This is interesting, since we used different surgical approaches. Saeden used an open volar approach and Vinnars used an open or mini open volar approach, both inserting the screw retrograde. We inserted the screw antegrade through the proximal pole, and still did not see a higher rate of arthritis in the radiocarpal joint. The effect of passing a screw through the STT joint is also unclear, since Geurts et al. did not find any STT arthritis on radiographs after six years following retrograde screw placement through the trapezium.<sup>124</sup> Since we were mainly interested in the consequences of inserting a screw through the proximal pole, we did not investigate the STT joint, which could have been interesting in comparison to studies using a volar approach. The shorter follow-up time, a median of 6 years in our cohort and that of Geurts in comparison to Saeden's or Vinnars' 10–12 years, may explain why we did not find a higher rate of arthritis. A new follow-up of our cohort in ten years would give more information. The volar approach might be preferable to the dorsal one, even though the rate of arthritis in the STT joint appears to be high following this procedure, since the consequences of a severe arthritis in the STT joint are better tolerated than those of a severe arthritis in the radiocarpal joint.<sup>125</sup>

Not all arthritic changes can be related to surgical factors, as arthritis is also found in conservatively treated patients. This could sometimes be related to malunion,<sup>83</sup> but it might also be that apart from creating a fracture, the trauma causes cartilage damage that predisposes to arthritis. The studies using CT with a follow-up of 6–12 years have shown a higher rate of arthritis than has been found after 36 years using radiography.<sup>91</sup> Perhaps minor arthritic changes discovered using CT never progress into more severe arthritis that is detectable on radiographs. There is a need for further studies on long-term radiological outcome after scaphoid fractures.

Regarding complications of treatment of scaphoid waist fractures, we reported removal of the screw in two surgically treated patients and an avascular necrosis in the proximal pole in one conservatively treated patient. Many studies have reported a few complications, such as hardware failure during surgery, screw misplacement, or complex regional pain syndrome – with predominance in surgically treated groups.<sup>14, 61, 81, 126</sup> One meta-analysis found an advantage of conservative treatment over surgical treatment regarding rate of complications,<sup>69</sup> but others have not found any statistically significant differences.<sup>67, 80</sup> This could be due to differences in methodology when performing meta-analyses, but the definition of what is considered to be a complication also differs between studies.

Even though complications are rare after surgery, it may still pose an unnecessary risk in most circumstances – considering that surgery only appears to be of minor benefit.

### **Displaced or comminuted waist fractures**

Generally, a scaphoid waist fracture with a displacement of > 1 mm has been considered to be unstable, and an indication for surgical fixation.<sup>56</sup> We found that fractures with a displacement of < 1.5 mm healed within 6–10 weeks of conservative treatment. Grewal reported a markedly increased risk of non-union in fractures with > 1.5 mm of displacement.<sup>62</sup> On the other hand, Amirfeyz et al. reported that fractures with a gap size of ≤ 2 mm all healed with conservative treatment, and they suggested that a gap of ≥ 3 mm should be an indication for screw fixation.<sup>127</sup>

A correlation has been shown between comminution and arthroscopically determined fracture instability.<sup>128</sup> We found that all of the conservatively treated non-displaced or minimally displaced waist fractures that were not united at 6 weeks were comminuted. This result is supported also by Grewal et al., who found that comminution is a contributory factor regarding prolonged time to union.<sup>62</sup> Thus, apart from displacement, comminution should also be taken into account when deciding on whether a fracture should be treated surgically or conservatively.

### **Scaphoid fractures and SL ligament injuries**

In the patients with non-displaced or minimally displaced waist fractures who were randomized for arthroscopy-assisted screw fixation, we found six who (apart from their fracture) also had a complete SL ligament tear of Geissler grade 4. They had additional

K-wire pinning of the SL interval for six weeks, and were excluded from the study. However, even though they were excluded from the randomized study, they participated in the follow-up and are reported in the Results section of this thesis. They showed a slower recovery of mobility and grip strength, and initially had higher DASH scores than the other surgically treated patients. Furthermore, three of the six showed signs of arthritis in the radioscaphoid joint at final follow-up. In the Malmö scaphoid study, we found a total proportion of 24% concomitant complete SL ligament injuries.<sup>104</sup> The combination of a scaphoid fracture and an SL ligament tear has been described earlier,<sup>129, 130</sup> and can be part of a PLIND injury.<sup>38</sup> These fractures are highly unstable, and—hypothetically—they have an increased risk of non-union. However, we must assume that given this incidence, a corresponding number of patients who were treated conservatively, not only in our study but also in all studies on conservative treatment, would also have had complete SL ligament tears. In our cohort, we found 5 of 21 patients with a positive Watson shift test in the conservatively treated group as compared to 1 of 14 in the surgically treated group, but none of whom showed any SL dissociation, DISI, or arthritis on CT. In addition, distal radius fractures with concomitant SL ligament injury (Geissler grade 3) followed for 13–15 years did not show any signs of static SL dissociation or SLAC wrist development.<sup>131</sup> As non-unions and SLAC wrists are not as common as the 24% rate of SL ligament tears found in scaphoid waist fractures, we must assume that the SL injuries that we observed usually healed while treating the fracture conservatively. If a fracture is treated with minimally invasive surgery and planned for early mobilization, it may be an advantage to assess the integrity of the SL ligament arthroscopically. However, postoperative SL instability has not been reported to be a problem following minimally invasive screw fixation. If we compare the results of the six patients with SL injury who were excluded from paper 1 with those of the conservatively treated patients, the six patients did not benefit from our treatment. This indicates the need for further studies that focus on the natural history, and on the indications for surgical repair, of a torn SL ligament in combination with a scaphoid fracture.

# Strength and limitations

The main strength of the work in this thesis was the large number of patients in the original cohort and the prospective design. The study cohort was not selected, as treatment of hand trauma cases in the geographic area around Malmö is centred at Skåne University Hospital in Malmö. We cannot exclude the possibility that a few cases were examined and treated at other healthcare providers, but the vast majority of patients were treated at our hospital. An additional strength was that all the patients were examined with radiography and MRI, and that CT was used for fracture classification and on all follow-up occasions. Taken together, the diagnostic work-up was very extensive. A further strength was that we managed to follow the majority of participants, and we had over 80% participation at our long-term evaluations.

There were also some limitations. Firstly, even though we had a large initial cohort, when fractures and injuries were subcategorized further, the groups become small. We only had a handful of patients in some interesting subgroups, so it was not possible to make any generalizations. Secondly, at the initial examinations we used a low-field MRI scanner and a first-generation multi-slice CT scanner. It is reasonable to assume that modern MR and CT scanners offer higher specificity, but the sensitivity in detecting a fracture was already high using the low-field MRI scanner.

*"The more I see, the less I know for sure."*

– John Lennon



# Conclusions



**More peanuts.**

Modified from Schulz. ©Peanuts Worldwide LLC

- Arthroscopy-assisted screw fixation of non-displaced waist fractures may provide an improved functional outcome in the short term but at the price of a possible increased risk of arthritis in the long term.
- The majority of non-displaced fractures are sufficiently treated with 6 weeks in a cast.
- Screw fixation does not reduce time to union in non-displaced fractures.
- Patients with posttraumatic radial-sided wrist pain where MRI does not demonstrate fracture or SL ligament injury do not benefit from immobilization and can be treated with early mobilization.
- From a 10-year perspective, the consequences of a distal scaphoid fracture are minor regarding hand function and the risk of developing symptomatic post-traumatic STT arthritis.

# Future work

- The time in a cast that is needed for sufficient union of distal scaphoid fractures to allow mobilization is still only known in vague terms. Since these fractures are rare, a prospective study of adequate power would have to have a multi-centre design.
- The natural history after scaphoid fracture treatment is still only poorly known. We have found increased rates of radiological arthritis in the radiocarpal and STT joints after scaphoid fractures, especially after operative treatment, but since most patients are asymptomatic the relevance of these findings is unclear. Which patients will develop a progressive arthritis and which will develop symptoms? Larger long-term studies are needed to investigate what happens to the patients with posttraumatic arthritis.
- Many surgical procedures for stabilization of scaphoid waist fractures have been described, but no procedure has been tested against any other. Is there a difference in using a volar approach or a dorsal approach to the scaphoid? This must be tested in a randomized controlled trial.
- SL ligament ruptures observed in association with scaphoid fractures are a challenge. How can we diagnose these injuries clinically, which imaging modality is best, and what role does wrist arthroscopy have in the diagnostic work-up of these patients? What is the natural history of this injury? How do we know which ones need specific treatment? What treatment is optimal? These questions are very important, and should be addressed in large randomized studies.

# Populärvetenskaplig sammanfattning

Båtbenet, os Scafoideum, påminner både till storlek och form om en oskalad jordnöt och är ett av åtta ben i handloven. Båtbensfrakturer uppkommer ofta vid fall på sträckt handled och drabbar oftast unga män, ofta under sport. Båtbenet är det handlovsben som oftast bryts och i Sverige bryter ungefär 3 000 personer/år båtbenet. Detta motsvarar ca 2% av alla benbrott i kroppen.

Båtbenet är ett viktigt ben för handledsfunktionen. Ett oläkt brott kan leda till kollaps av handleden med progredierande förlust av ledbrosk och uttalad smärta. Vid misstanke om båtbensbrott undersöks handleden, och framför allt ömhet i den “anatomiska snusgropen” på tumsidan av handleden kan tala för ett brott. Båtbensbrott kan vara mycket svåra att upptäcka på vanlig röntgen. På grund av rädsla att missa båtbensfraktur, och för att lindra smärta, gipsas alla patienter med misstänkt båtbensfraktur, även om de har en normal röntgen. Man röntgar sedan om dem efter ca två veckor för att se om man då kan påvisa en fraktur. Utökad undersökning av misstänkta båtbensbrott med magnetresonanstomografi (MRI) redan i akutskedet möjliggör att en fraktur kan identifieras tidigt och att rätt behandling kan ges till patienten. Dessutom framkommer ofta andra associerade skador i karpalben och ledband hos patienter med en båtbensfraktur. Dessa skador är oftast svåra eller omöjliga att diagnosticera med vanlig röntgenteknik.

Vid ett okomplicerat båtbensbrott är rutinbehandlingen handledsgips i 6–12 veckor, och ungefär 90% av fallen läker med denna behandling. Operation med titthålsteknik har föreslagits ge ett snabbare läkningsförlopp och ökad andel läkta frakturer. En annan fördel är att patienten ofta kan börja använda handen redan efter 2 veckor, varför sjukskrivningstiden blir avsevärt kortare än vid nuvarande rutinbehandling. Operation medför dock ett ingrepp i handleden och det finns risk för komplikationer till följd av ingreppet.

För att studera ett flertal aspekter kring båtbensbrott genomfördes “Malmö Scaphoid Study” mellan 2004 och 2008. Alla patienter som sökte ortopedens akutmottagning i Malmö med misstänkt båtbensfraktur tillfrågades om att delta i en omfattande studie. Alla patienter undersöktes med en klinisk undersökning på ett systematiskt sätt samt genomgick både vanlig röntgen och MRI. De patienter som hade en båtbensfraktur genomgick även en skiktröntgen, CT. Totalt inkluderades 526 patienter, vilka sedan fördelats på ett flertal olika studier beroende på typ av skada. Denna avhandling redogör för fyra studier med utgångspunkt i detta material.

I första studien följde vi patienter med ringa felställda frakturer i mellersta tredjedelen av båtbenet, sk. midjefrakturer, som slumpvis behandlats med antingen gips eller med operation då man med titthålsteknik fixerade frakturen med en skruv. Vi kunde konstatera att de som opererats angav lägre grad av funktionsnedsättning vid de första mätningarna, men att de var stelare i sina handleder något längre. Vid ett och sex-års

kontrollerna var det ingen skillnad mellan grupperna i något avseende. Vi kunde se en tendens till ökad ledsvikt med sänkt broskhöjd hos de opererade patienterna, men kunde inte ställa det i relation till några besvär.

I andra studien visar vi att man med hjälp av skiktröntgen kan påvisa övertygande läkning i 90% av midjefrakturen utan felställning redan efter sex veckor. Läkningsskontroller med skiktröntgen i stället för med konventionell röntgen kan därför möjliggöra att ett stort antal patienter med båtbensbrott kan avgipsas redan efter denna tid. Vi undersöker även läkningen i en undergrupp av patienter med ringa dislocerade midjefrakturen som slumpvis behandlats med antingen gips eller med titthålsassisterad skruvfixation utan att kunna påvisa någon skillnad.

I tredje studien undersöker vi om patienter med smärta i handloven efter en skada men där MRI inte kunnat påvisa en fraktur har fördel av ett gips i två veckor eller att omedelbart rörelseträna. Vi fann att patienter som rörelsetränade hade bättre rörlighet men inte mer smärtor än de som varit gipsade de första veckorna. Patienter som inte funnits ha fraktur och där en klinisk undersökning inte ger misstanke om någon allvarigare ledbandsskada kan därför omedelbart rörelseträna.

I fjärde studien undersöker vi naturalförloppet av frakturer i den yttersta tredjedelen av båtbenet. Vi finner att tio år efter en sådan fraktur har patienterna ringa besvär. Några fall av ledsvikt in i leden mot det månghörniga benet identifierades men kunde inte knytas till några upplevda besvär.

# Acknowledgements

This thesis is a result of many peoples hard work, and of the contribution of 526 patients. It has been supported by grants from the Swedish Research Council (Medicine) and funds from Region Skåne.

I wish to thank:

*Anders Björkman and Niels Thomsen*

My supervisors. For tremendous patience in guiding me through this work. For their knowledge and sense for direction. For fun and creative meetings where plans have been made and manuscripts have been scrutinized.

*Peter Jørgsholm*

For his work with the Malmö scaphoid study and for paving the road on which I have tread. For being one of my senior colleagues who convinced me to switch from orthopaedics to hand surgery. For this I am ever grateful.

*Jack Besjakov*

Always enthusiastic and helpful. For all your work with evaluating thousands of images.

*Lars Dahlin*

Professor, co-supervisor and a very friendly colleague. For your support in all aspects, and for fun collaboration with the med-students.

*Sven Olof Abrahamsson*

My first boss at the department of Hand Surgery. For inviting me to the clinic and to the speciality of Hand Surgery. For ordering me to take on this project, an offer I couldn't refuse.

*Charlotte Jeppsson*

My present boss at the department. For supporting this work and for making the department of Hand Surgery a great place to work.

*Tina Folker*

For invaluable support in the practical matters.

*Helen Wilhelmsson*

For keeping track of me and the numbers.

*Anette Persson*

For help with running the Malmö Scaphoid Study.

*Fredrik Järnkrants and Marianne Neving*

For the work with patient follow-up and clinical scoring.

*All assistants at CT lab 107, Bild och Funktion*

For happily letting me intrude with my wrist examinations.

*Colleagues at the Departement of Hand Surgery*

It is a great place to work in thanks to you! I'm proud to be a part of this department.

*Stefan Andersson*

Best friend. For invaluable support in the practical making of this book. And for drinking all that beer with me.

*Fredrik Tersmeden*

Dear friend. For the songs and laughs and for the illustration in this book.

*Parents and family*

For all the love you give and all the things you've taught me. For your endless support.

*Lottie and Bruno*

For kindness and happy dinners.

*Hugo and Emil*

My loved sons. For always interrupting me with things more important in life. You are my greatest gifts.

*Christine*

My companion in love and life. We made it, now the fun starts!

Additional thanks:

*Lomma Vindsurfingklubb.*

*Charvel guitars and ENGL amplifiers.*

*Headspace.com.*



Habo Ljung, December 3, NW, 18 knots.



# References

# References

1. Hove LM. Epidemiology of scaphoid fractures in Bergen, Norway. *Scand J Plast Surg Hand Surg*. 1999;33:423-426.
2. Lee S. Fractures of the Carpal Bones. In: Wolfe SW HR, Pederson WC, Kozin SH, Cohen MS, ed. *Green's Operative Hand Surgery*. 7th ed. Philadelphia: Elsevier; 2017.
3. Langhoff O, Andersen JL. Consequences of late immobilization of scaphoid fractures. *J Hand Surg Br*. 1988;13:77-79.
4. Wong K, von Schroeder HP. Delays and poor management of scaphoid fractures: factors contributing to nonunion. *J Hand Surg Am*. 2011;36:1471-1474.
5. Dias J. Nonoperative Treatment of Scaphoid Fractures. In: Slutsky DJ, Slade III J, ed. *The Scaphoid*. New York: Thieme; 2011.
6. Szabo RM, Manske D. Displaced fractures of the scaphoid. *Clin Orthop Relat Res*. 1988;30-38.
7. Bain GI, McGuire DT. Decision making for partial carpal fusions. *J Wrist Surg*. 2012;1:103-114.
8. Vender MI, Watson HK, Wiener BD, Black DM. Degenerative change in symptomatic scaphoid nonunion. *J Hand Surg Am*. 1987;12:514-519.
9. Lindstrom G, Nystrom A. Natural history of scaphoid non-union, with special reference to "asymptomatic" cases. *J Hand Surg Br*. 1992;17:697-700.
10. Parvizi J, Wayman J, Kelly P, Moran CG. Combining the clinical signs improves diagnosis of scaphoid fractures. A prospective study with follow-up. *J Hand Surg Br*. 1998;23:324-327.
11. Jorgsholm P, Thomsen NO, Besjakov J, Abrahamsson SO, Bjorkman A. The benefit of magnetic resonance imaging for patients with posttraumatic radial wrist tenderness. *J Hand Surg Am*. 2013;38:29-33.
12. Dias JJ, Taylor M, Thompson J, Brenkel IJ, Gregg PJ. Radiographic signs of union of scaphoid fractures. An analysis of inter-observer agreement and reproducibility. *J Bone Joint Surg Br*. 1988;70:299-301.
13. Bond CD, Shin AY, McBride MT, Dao KD. Percutaneous screw fixation or cast immobilization for nondisplaced scaphoid fractures. *J Bone Joint Surg Am*. 2001;83-A:483-488.
14. McQueen MM, Gelbke MK, Wakefield A, Will EM, Gaebler C. Percutaneous screw fixation versus conservative treatment for fractures of the waist of the scaphoid: a prospective randomised study. *J Bone Joint Surg Br*. 2008;90:66-71.
15. Arora R, Gschwentner M, Krappinger D, Lutz M, Blauth M, Gabl M. Fixation of nondisplaced scaphoid fractures: making treatment cost effective. Prospective controlled trial. *Arch Orthop Trauma Surg*. 2007;127:39-46.

16. Cooney WP LR, Dobyns JH. Fractures and dislocations of the wrist. In: Rockwood CA GD, Bcholz RW, ed. *Rockwood and Green's Fractures in Adults*. 4th ed. Philadelphia: Lippincott-Raven Publishers; 1996.
17. Watts AC, McLean JM, Fogg Q, Bain GI. Scaphoid Anatomy. In: Slutsky DJ, Slade III J, ed. *The Scaphoid*. New York: Thieme; 2011.
18. Berger RA, Imeada T, Berglund L, An KN. Constraint and material properties of the subregions of the scapholunate interosseous ligament. *J Hand Surg Am*. 1999;24:953-962.
19. Buijze GA, Lozano-Calderon SA, Strackee SD, Blankevoort L, Jupiter JB. Osseous and ligamentous scaphoid anatomy: Part I. A systematic literature review highlighting controversies. *J Hand Surg Am*. 2011;36:1926-1935.
20. Berger RA, Garcia-Elias M. General anatomy of the wrist. In: An KN, Berger R, Cooney WP, ed. *Biomechanics of the Wrist Joint*. New York: Springer-Verlag; 1991.
21. Gelberman RH, Menon J. The vascularity of the scaphoid bone. *J Hand Surg Am*. 1980;5:508-513.
22. Reddy R, Compson J. Examination of the wrist- surface anatomy of the carpal bones. *Current Orthopaedics*. 2005;19:171-179.
23. Berger R. Wrist anatomy. In: Cooney III, ed. *The Wrist*. 2nd ed: Lippincott Williams & Wilkins; 2010.
24. Duckworth AD, Jenkins PJ, Aitken SA, Clement ND, Court-Brown CM, McQueen MM. Scaphoid fracture epidemiology. *J Trauma Acute Care Surg*. 2012;72:E41-45.
25. Garala K, Taub NA, Dias JJ. The epidemiology of fractures of the scaphoid: impact of age, gender, deprivation and seasonality. *The bone & joint journal*. 2016;98-B:654-659.
26. Brondum V, Larsen CF, Skov O. Fracture of the carpal scaphoid: frequency and distribution in a well-defined population. *Europ J Radiology*. 1992;15:118-122.
27. Van Tassel DC, Owens BD, Wolf JM. Incidence estimates and demographics of scaphoid fracture in the U.S. population. *J Hand Surg Am*. 2010;35:1242-1245.
28. Leslie IJ, Dickson RA. The fractured carpal scaphoid. Natural history and factors influencing outcome. *J Bone Joint Surg Br*. 1981;63-B:225-230.
29. Jorgsholm P, Thomsen N, Besjakov J, Abrahamsson S, Bjorkman A. MRI shows a high incidence of carpal fractures in children with posttraumatic radial-sided wrist tenderness. *Acta orthopaedica*. 2016;87:533-537.
30. Vahvanen V, Westerlund M. Fracture of the carpal scaphoid in children. A clinical and roentgenological study of 108 cases. *Acta Orthop Scand*. 1980;51:909-913.
31. Ahmed I, Ashton F, Tay WK, Porter D. The pediatric fracture of the scaphoid in patients aged 13 years and under: an epidemiological study. *J Pediatric Orthop*. 2014;34:150-154.
32. Kozin SH. Incidence, mechanism, and natural history of scaphoid fractures. *Hand Clin*. 2001;17:515-524.

33. Weber ER, Chao EY. An experimental approach to the mechanism of scaphoid waist fractures. *J Hand Surg Am.* 1978;3:142-148.
34. Horii E, Nakamura R, Watanabe K, Tsunoda K. Scaphoid fracture as a “puncher’s fracture”. *J Orthop Trauma.* 1994;8:107-110.
35. Cockshott WP. Distal avulsion fractures of the scaphoid. *British J Radiology.* 1980;53:1037-1040.
36. Green JR, Jr., Rayan GM. Scaphoid fractures in soccer goalkeepers. *J Oklahoma State Medical Ass.* 1997;90:45-47.
37. Mayfield JK, Johnson RP, Kilcoyne RK. Carpal dislocations: pathomechanics and progressive perilunar instability. *J Hand Surg Am.* 1980;5:226-241.
38. Herzberg G. Perilunate Injuries, Not Dislocated (PLIND). *J Wrist Surg.* 2013;2:337-345.
39. Bergh TH, Lindau T, Soldal LA, et al. Clinical scaphoid score (CSS) to identify scaphoid fracture with MRI in patients with normal x-ray after a wrist trauma. *Emergency medicine journal : EMJ.* 2014;31:659-664.
40. Duckworth AD, Buijze GA, Moran M, et al. Predictors of fracture following suspected injury to the scaphoid. *J Bone Joint Surg Br.* 2012;94:961-968.
41. Bergh TH, Lindau T, Bernardshaw SV, et al. A new definition of wrist sprain necessary after findings in a prospective MRI study. *Injury.* 2012;43:1732-1742.
42. Andersson JK, Andernord D, Karlsson J, Friden J. Efficacy of Magnetic Resonance Imaging and Clinical Tests in Diagnostics of Wrist Ligament Injuries: A Systematic Review. *Arthroscopy.* 2015;31:2014-2020 e2012.
43. American College of Radiology. Appropriateness Criteria. Acute Hand and Wrist Trauma. 2013. Cited 2016: <https://acsearch.acr.org/docs/69418/Narrative/>
44. Russe O. Fracture of the carpal navicular. Diagnosis, non-operative treatment, and operative treatment. *J Bone Joint Surg. Am.* 1960;42-A:759-768.
45. Yin Z-G, Zhang J-B, Kan S-L, Wang X-G. Diagnosing suspected scaphoid fractures: a systematic review and meta-analysis. *Clinical Orthop Rel Research.* 2010;468:723-734.
46. Jenkins PJ, Slade K, Huntley JS, Robinson CM. A comparative analysis of the accuracy, diagnostic uncertainty and cost of imaging modalities in suspected scaphoid fractures. *Injury.* 2008;39:768-774.
47. Goldman L. Principles of CT: Multislice CT. *J Nucl Med Technol.* 2008;36:57-68.
48. Bain GI. Clinical Utilisation of Computed Tomography of the Scaphoid. *Hand surgery.* 1999;4:3-9.
49. ICRP. Radiological protection in biomedical research. *Ann. ICRP.* 1992;22(3).
50. Edlund R, Skorpil M, Lapidus G, Backlund J. Cone-Beam CT in diagnosis of scaphoid fractures. *Skeletal radiology.* 2016;45:197-204.
51. Breitenseher MJ, Metz VM, Gilula LA, et al. Radiographically occult scaphoid fractures: value of MR imaging in detection. *Radiology.* 1997;203:245-250.

52. Yin ZG, Zhang JB, Kan SL, Wang XG. Diagnostic accuracy of imaging modalities for suspected scaphoid fractures: meta-analysis combined with latent class analysis. *J Bone Joint Surg Br*. 2012;94:1077-1085.
53. Hackney LA, Dodds SD. Assessment of scaphoid fracture healing. *Current Reviews Musculoskeletal Med*. 2011;4:16-22.
54. Ten Berg PW, Drijkoningen T, Strackee SD, Buijze GA. Classifications of Acute Scaphoid Fractures: A Systematic Literature Review. *J Wrist Surg*. 2016;5:152-159.
55. Herbert TJ, Fisher WE. Management of the fractured scaphoid using a new bone screw. *J Bone Joint Surg Br*. 1984;66:114-123.
56. Cooney WP, Dobyns JH, Linscheid RL. Fractures of the scaphoid: a rational approach to management. *Clin Orthop Relat Res*. 1980:90-97.
57. Prosser AJ, Brenkel IJ, Irvine GB. Articular fractures of the distal scaphoid. *J Hand Surg Br*. 1988;13:87-91.
58. Shin A, Rizzo M. Acute Scaphoid Fractures. In: Cooney III, ed. *The Wrist*. 2nd ed: Lippincott Williams & Wilkins; 2010.
59. Doornberg JN, Buijze GA, Ham SJ, Ring D, Bhandari M, Poolman RW. Nonoperative treatment for acute scaphoid fractures: a systematic review and meta-analysis of randomized controlled trials. *J Trauma*. 2011;71:1073-1081.
60. Buijze GA, Goslings JC, Rhemrev SJ, et al. Cast immobilization with and without immobilization of the thumb for nondisplaced and minimally displaced scaphoid waist fractures: a multicenter, randomized, controlled trial. *J Hand Surg Am*. 2014;39:621-627.
61. Adolfsson L, Lindau T, Arner M. Acutrak screw fixation versus cast immobilisation for undisplaced scaphoid waist fractures. *J Hand Surg Br*. 2001;26:192-195.
62. Grewal R, Suh N, Macdermid JC. Use of computed tomography to predict union and time to union in acute scaphoid fractures treated nonoperatively. *J Hand Surg Am*. 2013;38:872-877.
63. Langhoff O, Andersen JL, Grøn P. Fractures in the distal third of the scaphoid bone. *Ugeskrift læger*. 1987;149:3041-3042.
64. Singh HP, Taub N, Dias JJ. Management of displaced fractures of the waist of the scaphoid: meta-analyses of comparative studies. *Injury*. 2012;43:933-939.
65. McLaughlin H. Fracture of the carpal navicular (scaphoid) bone; some observations based on treatment by open reduction and internal fixation. *J Bone Joint Surg Am*. 1954;36-A:765-774.
66. Bain GI, Turow A, Phadnis J. Dorsal Plating of Unstable Scaphoid Fractures and Nonunions. *Tech Hand & Upper Extrem Surgery*. 2015;19:95-100.
67. Buijze GA, Doornberg JN, Ham JS, Ring D, Bhandari M, Poolman RW. Surgical compared with conservative treatment for acute nondisplaced or minimally displaced scaphoid fractures: a systematic review and meta-analysis of randomized controlled trials. *J Bone Joint Surg. Am*. 2010;92:1534-1544.

68. Slade JF, Gillon T. Retrospective review of 234 scaphoid fractures and nonunions treated with arthroscopy for union and complications. *Scand J Surg.* 2008;97:280-289.
69. Ibrahim T, Qureshi A, Sutton AJ, Dias JJ. Surgical versus nonsurgical treatment of acute minimally displaced and undisplaced scaphoid waist fractures: pairwise and network meta-analyses of randomized controlled trials. *J Hand Surg Am.* 2011;36:1759-1768 e1751.
70. Bain GI, Smith ML, Watts AC. Scaphoid Imaging. In: Slutsky DJ, Slade III JF, ed. *The Scaphoid.* New York: Thieme Medical Publishers, Inc.; 2011:22-30.
71. Buijze GA, Wijffels MM, Guitton TG, et al. Interobserver reliability of computed tomography to diagnose scaphoid waist fracture union. *J Hand Surg Am.* 2012;37:250-254.
72. Singh HP, Forward D, Davis TRC, Dawson JS, Oni Ja, Downing ND. Partial union of acute scaphoid fractures. *J Hand Surg Br.* 2005;30:440-445.
73. Geoghegan JM, Woodruff MJ, Bhatia R, et al. Undisplaced scaphoid waist fractures: is 4 weeks' immobilisation in a below-elbow cast sufficient if a week 4 CT scan suggests fracture union? *J Hand Surg Eur Vol.* 2009;34:631-637.
74. Hudak PL, Amadio PC, Bombardier C. Development of an upper extremity outcome measure: the DASH (disabilities of the arm, shoulder and hand). The Upper Extremity Collaborative Group (UECG). *Am J Industrial Medicine.* 1996;29:602-608.
75. Atroshi I, Gummesson C, Andersson B, Dahlgren E, Johansson a. The disabilities of the arm, shoulder and hand (DASH) outcome questionnaire: reliability and validity of the Swedish version evaluated in 176 patients. *Acta Orthop Scandinavica.* 2000;71:613-618.
76. Aasheim T, Finsen V. The DASH and the QuickDASH instruments. Normative values in the general population in Norway. *J Hand Surg Eur Vol.* 2014;39:140-144.
77. Gummesson C, Ward MM, Atroshi I. The shortened disabilities of the arm, shoulder and hand questionnaire (QuickDASH): validity and reliability based on responses within the full-length DASH. *BMC musculoskeletal disorders.* 2006;7:44.
78. Wilcke MT, Abbaszadegan H, Adolphson PY. Evaluation of a Swedish version of the patient-rated wrist evaluation outcome questionnaire: good responsiveness, validity, and reliability, in 99 patients recovering from a fracture of the distal radius. *Scand J Plast Surg Hand Surg.* 2009;43:94-101.
79. Dias JJ, Brenkel IJ, Finlay DB. Patterns of union in fractures of the waist of the scaphoid. *J Bone Joint Surg Br.* 1989;71:307-310.
80. Shen L, Tang J, Luo C, Xie X, An Z, Zhang C. Comparison of operative and non-operative treatment of acute undisplaced or minimally-displaced scaphoid fractures: a meta-analysis of randomized controlled trials. *PloS one.* 2015;10:e0125247.
81. Saeden B, Tornkvist H, Ponzer S, Hoglund M. Fracture of the carpal scaphoid. A prospective, randomised 12-year follow-up comparing operative and conservative treatment. *J Bone Joint Surg Br.* 2001;83:230-234.

82. Vinnars B, Pietreanu M, Bodestedt A, Ekenstam F, Gerdin B. Nonoperative compared with operative treatment of acute scaphoid fractures. A randomized clinical trial. *J Bone Joint Surg Am.* 2008;90:1176-1185.
83. Dias JJ, Dhukaram V, Abhinav A, Bhowal B, Wildin CJ. Clinical and radiological outcome of cast immobilisation versus surgical treatment of acute scaphoid fractures at a mean follow-up of 93 months. *J Bone Joint Surg Br.* 2008;90:899-905.
84. Dias JJ, Wildin CJ, Bhowal B, Thompson JR. Should acute scaphoid fractures be fixed? A randomized controlled trial. *J Bone Joint Surg Am.* 2005;87:2160-2168.
85. Clay NR, Dias JJ, Costigan PS, Gregg PJ, Barton NJ. Need the thumb be immobilised in scaphoid fractures? A randomised prospective trial. *J Bone Joint Surg Br.* 1991;73:828-832.
86. Oron A, Gupta A, Thirkannad S. Nonunion of the scaphoid distal pole. *Hand Surgery.* 2013;18:35-39.
87. Grewal R, Suh N, MacDermid JC. The Missed Scaphoid Fracture-Outcomes of Delayed Cast Treatment. *J Wrist Surg.* 2015;4:278-283.
88. Crosby EB, Linscheid RL, Dobyns JH. Scaphotrapezial trapezoidal arthrosis. *J Hand Surg Am.* 1978;3:223-234.
89. White L, Clavijo J, Gilula LA, Wollstein R. Classification system for isolated arthritis of the scaphotrapeziotrapezoidal joint. *Scand J Plast Surg Hand Surg.* 2010;44:112-117.
90. Saltzherr MS, van Neck JW, Muradin GS, et al. Computed tomography for the detection of thumb base osteoarthritis: comparison with digital radiography. *Skeletal radiology.* 2013;42:715-721.
91. Duppe H, Johnell O, Lundborg G, Karlsson M, Redlund-Johnell I. Long-term results of fracture of the scaphoid. A follow-up study of more than thirty years. *J Bone Joint Surg Am.* 1994;76:249-252.
92. Lindstrom G, Nystrom A. Incidence of post-traumatic arthrosis after primary healing of scaphoid fractures: a clinical and radiological study. *J Hand Surg Br.* 1990;15:11-13.
93. Inoue G, Sakuma M. The natural history of scaphoid non-union. Radiographical and clinical analysis in 102 cases. *Arch Orthop Trauma Surg.* 1996;115:1-4.
94. Ruby LK, Stinson J, Belsky MR. The natural history of scaphoid non-union. A review of fifty-five cases. *J Bone Joint Surg Am.* 1985;67:428-432.
95. Kerluke L, McCabe SJ. Nonunion of the scaphoid: a critical analysis of recent natural history studies. *J Hand Surg Am.* 1993;18:1-3.
96. Malmö Stad; 2016. Cited 2016. <http://malmo.se/Kommun--politik/Statistik/Befolkning.html>
97. Trelleborg Kommun; 2016. Cited 2016. <http://www.trelleborg.se/sv/kommun-politik/kommunfakta/kommunstatistik/befolkning/>



98. Vellinge Kommun; 2016. Cited 2016. <http://vellinge.se/kommun-politik/kommunfakta/befolkning/#2>
99. Memarsadeghi M, Breitenseher MJ, Schaefer-Prokop C, et al. Occult scaphoid fractures: comparison of multidetector CT and MR imaging--initial experience. *Radiology*. 2006;240:169-176.
100. Bhat M, McCarthy M, Davis TR, Oni JA, Dawson S. MRI and plain radiography in the assessment of displaced fractures of the waist of the carpal scaphoid. *J Bone Joint Surg Br*. 2004;86:705-713.
101. Dias JJ. Definition of union after acute fracture and surgery for fracture nonunion of the scaphoid. *J Hand Surg*. 2001;26:321-325.
102. Cooney WP, Linscheid RL, Dobyns JH, eds. *The Wrist. Diagnosis and Operative Treatment*. 1st ed. St. Louis, MO: Mosby; 1998.
103. Marsh JL, Slongo TF, Agel J, et al. Fracture and dislocation classification compendium - 2007: Orthopaedic Trauma Association classification, database and outcomes committee. *J Orthop Trauma*. 2007;21:S1-133.
104. Jorgsholm P, Thomsen NO, Bjorkman A, Besjakov J, Abrahamsson SO. The incidence of intrinsic and extrinsic ligament injuries in scaphoid waist fractures. *J Hand Surg Am*. 2010;35:368-374.
105. Geissler WB, Freeland AE, Savoie FH, McIntyre LW, Whipple TL. Intracarpal soft-tissue lesions associated with an intra-articular fracture of the distal end of the radius. *J Bone Joint Surg Am*. 1996;78:357-365.
106. Watson HK, Ashmead Dt, Makhlof MV. Examination of the scaphoid. *J Hand Surg Am*. 1988;13:657-660.
107. Atroshi I, Johnsson R, Sprinchorn A. Self-administered outcome instrument in carpal tunnel syndrome. Reliability, validity and responsiveness evaluated in 102 patients. *Acta Orthop Scand*. 1998;69:82-88.
108. Landis JR, Koch GG. The measurement of observer agreement for categorical data. *Biometrics*. 1977;33:159-174.
109. Groves AM, Kayani I, Syed R, et al. An international survey of hospital practice in the imaging of acute scaphoid trauma. *Am J Roentgenology*. 2006;187:1453-1456.
110. Lozano-Calderon S, Blazar P, Zurakowski D, Lee SG, Ring D. Diagnosis of scaphoid fracture displacement with radiography and computed tomography. *J Bone Joint Surg Am*. 2006;88:2695-2703.
111. Schmitt R, Rosenthal H, Deutsche Gesellschaft fur U. Imaging of Scaphoid Fractures According to the New S3 Guidelines. *RoFo : Fortschritte auf dem Gebiete der Rontgenstrahlen und der Nuklearmedizin*. 2016;188:459-469.
112. Gilula L, Mann F, Dobyns J, Yin Y. Wrist Terminology as Defined by the International Wrist Investigators' Workshop. *J Bone & Joint Surgery*. 2002;84:1-66.
113. Hansen TB, Petersen RB, Barckman J, Uhre P, Larsen K. Cost-effectiveness of MRI in managing suspected scaphoid fractures. *J Hand Surg Eur Vol*. 2009;34:627-630.



114. Bergh TH, Steen K, Lindau T, et al. Costs analysis and comparison of usefulness of acute MRI and 2 weeks of cast immobilization for clinically suspected scaphoid fractures. *Acta Orthopaedica*. 2014;1-7.
115. Patel NK, Davies N, Mirza Z, Watson M. Cost and clinical effectiveness of MRI in occult scaphoid fractures: a randomised controlled trial. *Emergency Medicine J*. 2013;30:202-207.
116. Prosser R, Harvey L, Lastayo P, Hargreaves I, Scougall P, Herbert RD. Provocative wrist tests and MRI are of limited diagnostic value for suspected wrist ligament injuries: a cross-sectional study. *J Physiotherapy*. 2011;57:247-253.
117. Jones WA. Beware the sprained wrist. The incidence and diagnosis of scapholunate instability. *J Bone Joint Surg Br*. 1988;70:293-297.
118. Adolfsson L, Povlsen B. Arthroscopic findings in wrists with severe post-traumatic pain despite normal standard radiographs. *J Hand Surg*. 2004;29:208-213.
119. Mody BS, Belliappa PP, Dias JJ, Barton NJ. Nonunion of fractures of the scaphoid tuberosity. *J Bone Joint Surg Br*. 1993;75:423-425.
120. Bhatia A, Pisoh T, Touam C, Oberlin C. Incidence and distribution of scaphotrapezotrapezoidal arthritis in 73 fresh cadaveric wrists. *Ann Hand Upper Limb Surg*. 1996;15:220-225.
121. Watson HK, Ballet FL. The SLAC wrist: scapholunate advanced collapse pattern of degenerative arthritis. *J Hand Surg Am*. 1984;9:358-365.
122. Brown GD, 3rd, Roh MS, Strauch RJ, Rosenwasser MP, Ateshian GA, Mow VC. Radiography and visual pathology of the osteoarthritic scaphotrapezio-trapezoidal joint, and its relationship to trapeziometacarpal osteoarthritis. *J Hand Surg Am*. 2003;28:739-743.
123. Wollstein R, Watson HK. Scaphotrapeziotrapezoid arthrodesis for arthritis. *Hand Clin*. 2005;21:539-543, vi.
124. Geurts G, van Riet R, Meermans G, Verstreken F. Incidence of scaphotrapezoidal arthritis following volar percutaneous fixation of nondisplaced scaphoid waist fractures using a transtrapezoidal approach. *J Hand Surg Am*. 2011;36:1753-1758.
125. Patel N, Russo G, Rodner C. Osteoarthritis of the Wrist. In: Chen Q, ed. *Osteoarthritis- Diagnosis, Treatment and Surgery*: Intech; 2012:171-202.
126. Vinnars B, Ekenstam FA, Gerdin B. Comparison of direct and indirect costs of internal fixation and cast treatment in acute scaphoid fractures: a randomized trial involving 52 patients. *Acta Orthopaedica*. 2007;78:672-679.
127. Amirfeyz R, Bebbington A, Downing ND, Oni JA, Davis TR. Displaced scaphoid waist fractures: the use of a week 4 CT scan to predict the likelihood of union with nonoperative treatment. *J Hand Surg Eur Vol*. 2011;36:498-502.
128. Buijze GA, Jorgsholm P, Thomsen NO, Bjorkman A, Besjakov J, Ring D. Factors associated with arthroscopically determined scaphoid fracture displacement and instability. *J Hand Surg Am*. 2012;37:1405-1410.

129. Thomsen L, Falcone MO. Lesions of the scapholunate ligament associated with minimally displaced or non-displaced fractures of the scaphoid waist. Which incidence? *Chirurgie de la main*. 2012;31:234-238.
130. Caloia MF, Gallino RN, Caloia H, Rivarola H. Incidence of ligamentous and other injuries associated with scaphoid fractures during arthroscopically assisted reduction and percutaneous fixation. *Arthroscopy*. 2008;24:754-759.
131. Mrkonjic A, Lindau T, Geijer M, Tagil M. Arthroscopically diagnosed scapholunate ligament injuries associated with distal radial fractures: a 13- to 15-year follow-up. *J Hand Surg Am*. 2015;40:1077-1082.

# Appendix 1



Denna enkät berör Dina symtom och Din förmåga att utföra vissa aktiviteter.

Svara på **varje fråga**, baserat på hur Du har mått **den senaste veckan**, genom att kryssa för ett svarsalternativ för varje fråga.

Om det är någon aktivitet Du inte har utfört den senaste veckan får Du kryssa för det svar som Du bedömer **stämmer bäst** om Du hade utfört aktiviteten.

Det har ingen betydelse vilken arm eller hand Du använder för att utföra aktiviteten. Svara baserat på Din förmåga oavsett hur Du utför uppgiften.

	Ingen svårighet	Viss svårighet	Måttlig svårighet	Stor svårighet	Omöjligt att göra
1. Öppna en ny burk, eller hårt sittande lock	<input type="checkbox"/>	<input type="checkbox"/>	<input type="checkbox"/>	<input type="checkbox"/>	<input type="checkbox"/>
2. Skriva	<input type="checkbox"/>	<input type="checkbox"/>	<input type="checkbox"/>	<input type="checkbox"/>	<input type="checkbox"/>
3. Vrida om en nyckel	<input type="checkbox"/>	<input type="checkbox"/>	<input type="checkbox"/>	<input type="checkbox"/>	<input type="checkbox"/>
4. Förbereda en måltid	<input type="checkbox"/>	<input type="checkbox"/>	<input type="checkbox"/>	<input type="checkbox"/>	<input type="checkbox"/>
5. Öppna en tung dörr	<input type="checkbox"/>	<input type="checkbox"/>	<input type="checkbox"/>	<input type="checkbox"/>	<input type="checkbox"/>
6. Lägga upp något på en hylla över Ditt huvud	<input type="checkbox"/>	<input type="checkbox"/>	<input type="checkbox"/>	<input type="checkbox"/>	<input type="checkbox"/>
7. Utföra tunga hushållssysslor (t ex tvätta golv och väggar, putsa fönster, hänga tvätt)	<input type="checkbox"/>	<input type="checkbox"/>	<input type="checkbox"/>	<input type="checkbox"/>	<input type="checkbox"/>
8. Trädgårdsarbete	<input type="checkbox"/>	<input type="checkbox"/>	<input type="checkbox"/>	<input type="checkbox"/>	<input type="checkbox"/>
9. Bädda sängen	<input type="checkbox"/>	<input type="checkbox"/>	<input type="checkbox"/>	<input type="checkbox"/>	<input type="checkbox"/>
10. Bära matkassar eller portfölj	<input type="checkbox"/>	<input type="checkbox"/>	<input type="checkbox"/>	<input type="checkbox"/>	<input type="checkbox"/>
11. Bära tunga saker (över fem kilo)	<input type="checkbox"/>	<input type="checkbox"/>	<input type="checkbox"/>	<input type="checkbox"/>	<input type="checkbox"/>
12. Byta en glödlampa ovanför Ditt huvud	<input type="checkbox"/>	<input type="checkbox"/>	<input type="checkbox"/>	<input type="checkbox"/>	<input type="checkbox"/>
13. Tvätta eller fona håret	<input type="checkbox"/>	<input type="checkbox"/>	<input type="checkbox"/>	<input type="checkbox"/>	<input type="checkbox"/>
14. Tvätta Din rygg	<input type="checkbox"/>	<input type="checkbox"/>	<input type="checkbox"/>	<input type="checkbox"/>	<input type="checkbox"/>
15. Ta på en tröja	<input type="checkbox"/>	<input type="checkbox"/>	<input type="checkbox"/>	<input type="checkbox"/>	<input type="checkbox"/>
16. Använda en kniv för att skära upp maten	<input type="checkbox"/>	<input type="checkbox"/>	<input type="checkbox"/>	<input type="checkbox"/>	<input type="checkbox"/>
17. Fritidsaktiviteter som kräver liten ansträngning (t ex spela kort, sticka, boule)	<input type="checkbox"/>	<input type="checkbox"/>	<input type="checkbox"/>	<input type="checkbox"/>	<input type="checkbox"/>
18. Fritidsaktiviteter som tar upp viss kraft eller stöt genom arm, axel eller hand (t ex spela golf, använda hammare, spela tennis, skytte, bowling)	<input type="checkbox"/>	<input type="checkbox"/>	<input type="checkbox"/>	<input type="checkbox"/>	<input type="checkbox"/>
19. Fritidsaktiviteter där Du rör på armen fritt (t ex spela badminton, simma, gympa)	<input type="checkbox"/>	<input type="checkbox"/>	<input type="checkbox"/>	<input type="checkbox"/>	<input type="checkbox"/>
20. Färdas från en plats till en annan	<input type="checkbox"/>	<input type="checkbox"/>	<input type="checkbox"/>	<input type="checkbox"/>	<input type="checkbox"/>
21. Sexuella aktiviteter	<input type="checkbox"/>	<input type="checkbox"/>	<input type="checkbox"/>	<input type="checkbox"/>	<input type="checkbox"/>

22. Under **de senaste sju dagarna**, i vilken utsträckning har Dina arm-, axel- eller handproblem störst Ditt vanliga umgänge med anhöriga, vänner, grannar eller andra?

Inte alls       Lite       Måttligt       Mycket       Väldigt mycket

23. Under **de senaste sju dagarna**, i vilken utsträckning har Dina arm-, axel- eller handproblem störst Ditt vanliga arbete eller andra dagliga aktiviteter?

Inte alls       Lite       Måttligt       Mycket       Väldigt mycket

Ange svårighetsgraden på Dina symptom **de senaste sju dagarna**:

	Ingen	Lätt	Måttlig	Svår	Mycket svår
24. Värk/smärta i arm, axel eller hand	<input type="checkbox"/>	<input type="checkbox"/>	<input type="checkbox"/>	<input type="checkbox"/>	<input type="checkbox"/>
25. Värk/smärta i arm, axel eller hand i samband med aktivitet	<input type="checkbox"/>	<input type="checkbox"/>	<input type="checkbox"/>	<input type="checkbox"/>	<input type="checkbox"/>
26. Stickningar (sockerdricks känsla) i arm, axel eller hand	<input type="checkbox"/>	<input type="checkbox"/>	<input type="checkbox"/>	<input type="checkbox"/>	<input type="checkbox"/>
27. Svaghet i arm, axel eller hand	<input type="checkbox"/>	<input type="checkbox"/>	<input type="checkbox"/>	<input type="checkbox"/>	<input type="checkbox"/>
28. Stelhet i arm, axel eller hand	<input type="checkbox"/>	<input type="checkbox"/>	<input type="checkbox"/>	<input type="checkbox"/>	<input type="checkbox"/>

29. Har Du haft svårt att sova, under **de senaste sju dagarna**, på grund av värk/smärta i arm, axel eller hand?

Inte alls     Viss svårighet     Måttlig svårighet     Stor svårighet     Mycket stor svårighet

30. Jag känner mig mindre kapabel, har sämre självförtroende eller känner mig mindre behövd på grund av mina arm-, axel- eller handproblem.

Instämmer absolut inte     Instämmer inte     Vet inte     Instämmer     Instämmer absolut

Följande frågor rör hur mycket Dina arm-, axel- eller handproblem påverkat Din förmåga att arbeta (inklusive hushållsarbete om detta är Ditt huvudsakliga arbete).

Arbetar Du?  Ja  Nej

Om Du inte arbetar kan Du hoppa över de följande fyra frågorna

Ange här Ditt arbete

Kryssa för det påstående som bäst stämmer in på Din kroppsliga förmåga **de senaste sju dagarna**.

Hade Du någon svårighet att:	Ingen svårighet	Viss svårighet	Måttlig svårighet	Stor svårighet	Omöjligt
1. använda Din vanliga teknik för att arbeta?	<input type="checkbox"/>	<input type="checkbox"/>	<input type="checkbox"/>	<input type="checkbox"/>	<input type="checkbox"/>
2. utföra Ditt ordinarie arbete på grund av värk/smärta i arm, axel eller hand?	<input type="checkbox"/>	<input type="checkbox"/>	<input type="checkbox"/>	<input type="checkbox"/>	<input type="checkbox"/>
3. utföra Ditt arbete så bra som Du skulle vilja?	<input type="checkbox"/>	<input type="checkbox"/>	<input type="checkbox"/>	<input type="checkbox"/>	<input type="checkbox"/>
4. utföra Ditt arbete på den tid Du brukar använda?	<input type="checkbox"/>	<input type="checkbox"/>	<input type="checkbox"/>	<input type="checkbox"/>	<input type="checkbox"/>

Följande frågor rör hur mycket Dina arm-, axel- eller handproblem påverkat Din förmåga att spela musikinstrument och/eller utöva idrott.

Spelar Du något musikinstrument eller utövar någon idrott?  Ja  Nej

Om Du inte spelar något musikinstrument eller utövar någon idrott kan Du hoppa över resterande frågor

Om Du spelar mer än ett musikinstrument eller utövar mer än en idrott ska Du svara med avseende på den aktivitet som är viktigast för Dig.

Ange här det musikinstrument eller den idrott som är viktigast för Dig

Kryssa för det påstående som bäst stämmer in på Din kroppsliga förmåga **de senaste sju dagarna**.

Hade Du någon svårighet att:	Ingen svårighet	Viss svårighet	Måttlig svårighet	Stor svårighet	Omöjligt
1. använda Din vanliga teknik för att spela instrument/idrotta?	<input type="checkbox"/>	<input type="checkbox"/>	<input type="checkbox"/>	<input type="checkbox"/>	<input type="checkbox"/>
2. spela instrument/idrotta på grund av värk/smärta i arm, axel eller hand?	<input type="checkbox"/>	<input type="checkbox"/>	<input type="checkbox"/>	<input type="checkbox"/>	<input type="checkbox"/>
3. spela instrument/idrotta så bra som Du skulle vilja?	<input type="checkbox"/>	<input type="checkbox"/>	<input type="checkbox"/>	<input type="checkbox"/>	<input type="checkbox"/>
4. använda lika mycket tid som vanligt för att spela instrument/idrotta?	<input type="checkbox"/>	<input type="checkbox"/>	<input type="checkbox"/>	<input type="checkbox"/>	<input type="checkbox"/>





## Appendix 2



## PATIENTUPPLEVD HANDELSFUNKTION

Namn \_\_\_\_\_

Datum \_\_\_\_\_

Nedanstående frågor ska hjälpa oss att förstå hur mycket besvär du har haft av din handled. Du ska ange dina genomsnittliga handledsbesvär den senaste veckan på en skala från 0 till 10. Vår vänlig och besvara **ALLA** frågor. Om du inte utförde en viss aktivitet, vänligen **UPPSKATTA** den grad av smärta eller svårighet som Du tror hade uppstått. Om Du **ALDRIG** har utfört en viss aktivitet kan du lämna raden obesvarad.

### 1. SMÄRTA

Ange Din genomsnittliga handledssmärta den gångna veckan och ringa in siffran som bäst motsvarar smärtan på en skala från 0 till 10. Noll (0) betyder ingen smärta och tio (10) betyder att Du har haft den värsta tänkbara smärtan eller att du inte kunde utföra aktiviteten på grund av smärta.

Exempel:	Skala	0	1	2	3	4	5	6	7	8	9	10
		<b>Ingen smärta</b>										<b>Värsta tänkbara smärta</b>
<b>UPPSKATTA DIN SMÄRTA:</b>												
I vila		0	1	2	3	4	5	6	7	8	9	10
När du utför en uppgift med upprepade handledsrörelser, t ex skruva		0	1	2	3	4	5	6	7	8	9	10
När du lyfter ett tungt föremål		0	1	2	3	4	5	6	7	8	9	10
När smärtan är som värst		0	1	2	3	4	5	6	7	8	9	10
Hur ofta har du haft ont i handleden den senaste veckan?		0	1	2	3	4	5	6	7	8	9	10
		<b>Aldrig</b>										<b>Alltid</b>
		Var god vänd										

### 2. FUNKTION

#### A. SPECIELLA AKTIVITETER

Ange graden av svårighet som Du har haft den senaste veckan att utföra nedanstående aktiviteter genom att ringa in siffran som beskriver svårigheten på en skala från 0 till 10. En nolla (0) betyder att Du inte har haft någon svårighet och tio (10) betyder att Du har haft så stor svårighet att Du inte kunde utföra aktiviteten alls.

Exempel:	Skala	0	1	2	3	4	5	6	7	8	9	10
		<b>Ingen svårighet</b>										<b>Omöjligt att utföra</b>
Öppna en ny burk, eller hårt sittande lock med den påverkade handen		0	1	2	3	4	5	6	7	8	9	10
Skära kött med kniv med den påverkade handen		0	1	2	3	4	5	6	7	8	9	10
Knäppa skjortknappar med den påverkade handen		0	1	2	3	4	5	6	7	8	9	10
Använda den påverkade handen för att skjuta ifrån och resa mig upp från en stol		0	1	2	3	4	5	6	7	8	9	10
Bära ett 5 kilos föremål med den påverkade handen		0	1	2	3	4	5	6	7	8	9	10
Använda toalettpapper med den påverkade handen		0	1	2	3	4	5	6	7	8	9	10

## B. VARDAGLIGA AKTIVITETER

Uppskatta graden av svårighet du har upplevt när du har utfört vardagliga sysslor inom nedan listade områden under den gångna veckan genom att ringa in siffran som bäst beskriver din svårighet på en skala från 0 till 10. Med vardagliga sysslor menas sysslor som du utförde innan du fick problem med handleden. En nolla (0) betyder att du inte har upplevt någon svårighet och tio (10) betyder att det har varit så svårt att du inte har kunnat utföra någon av dina vanliga sysslor inom detta område.

Personlig vård (klä på sig, tvätta sig)	0	1	2	3	4	5	6	7	8	9	10
Hushållsarbete (tvätta, diska)	0	1	2	3	4	5	6	7	8	9	10
Arbete (ditt yrke eller vardagliga sysslor)	0	1	2	3	4	5	6	7	8	9	10
Fritidsaktivitet, hobby	0	1	2	3	4	5	6	7	8	9	10

## Supplement II

### PATIENT-RATED WRIST EVALUATION

Name \_\_\_\_\_

Date \_\_\_\_\_

*The questions below will help us understand how much difficulty you have had with your wrist in the past week. You will be describing your **average** wrist symptoms **over the past week** on a scale of 0–10. **Please provide an answer for ALL questions. If you did not perform any activity, please ESTIMATE the pain or difficulty you would expect. If you have never performed the activity, you may leave it blank.***

#### 1. PAIN

*Rate the average amount of pain in your wrist over the past week by circling the number that best describes your pain on a scale from 0–10. A zero (0) means that you did not have any pain and a ten (10) means that you had the worst pain you have ever experienced or that you could not do the activity because of pain.*

Sample scale	0	1	2	3	4	5	6	7	8	9	10
	No Pain										Worst Ever
RATE YOUR PAIN:											
At rest	0	1	2	3	4	5	6	7	8	9	10
When doing a task with a repeated wrist movement	0	1	2	3	4	5	6	7	8	9	10
When lifting a heavy object	0	1	2	3	4	5	6	7	8	9	10
When it is at its worst	0	1	2	3	4	5	6	7	8	9	10
How often do you have pain?	0	1	2	3	4	5	6	7	8	9	10
	Never										Always

#### 2. FUNCTION

##### A. SPECIFIC ACTIVITIES

*Rate the **amount of difficulty** you experienced performing each of the items listed below – over the past week by circling the number that describes your difficulty on a scale of 0–10. A zero (0) means you did not experience any difficulty and a ten (10) means it was so difficult you were unable to do it at all.*

Sample scale	0	1	2	3	4	5	6	7	8	9	10
	No Difficulty										Unable To Do
Turn a door knob using my affected hand	0	1	2	3	4	5	6	7	8	9	10
Cut meat using a knife in my affected hand	0	1	2	3	4	5	6	7	8	9	10

Fasten buttons on my shirt	0	1	2	3	4	5	6	7	8	9	10
Use my affected hand to push up from a chair	0	1	2	3	4	5	6	7	8	9	10
Carry a 10 lb object in my affected hand	0	1	2	3	4	5	6	7	8	9	10
Use bathroom tissue with my affected hand	0	1	2	3	4	5	6	7	8	9	10

## B. USUAL ACTIVITIES

Rate the **amount of difficulty** you experienced performing your usual activities in each of the areas listed below over the past week by circling the number that best describes your difficulty on a scale of 0–10. By “usual activities”, we mean the activities you performed before you started having a problem with your wrist. A zero (0) means that you did not experience any difficulty and a ten (10) means it was so difficult you were unable to do any of your usual activities.

Personal care activities (dressing, washing)	0	1	2	3	4	5	6	7	8	9	10
Household work (cleaning, maintenance)	0	1	2	3	4	5	6	7	8	9	10
Work (your job or usual everyday work)	0	1	2	3	4	5	6	7	8	9	10
Recreational activities	0	1	2	3	4	5	6	7	8	9	10



Martin Clementson, illustration by Fredrik Tersmeden.

## Scaphoid fractures

---

Fractures of the scaphoid bone of the carpus are infamous for being difficult both to diagnose and to treat. This doctoral dissertation aims to add further knowledge to the research field of scaphoid fractures, and to further improve the treatment and outcome for our patients.

