



LUND UNIVERSITY

Placental ischemia and changes in umbilical and uteroplacental arterial and venous hemodynamics.

Thuring, Ann; Marsal, Karel; Laurini, Ricardo

Published in:

Journal of Maternal-Fetal & Neonatal Medicine

DOI:

[10.3109/14767058.2011.594466](https://doi.org/10.3109/14767058.2011.594466)

2012

[Link to publication](#)

Citation for published version (APA):

Thuring, A., Marsal, K., & Laurini, R. (2012). Placental ischemia and changes in umbilical and uteroplacental arterial and venous hemodynamics. *Journal of Maternal-Fetal & Neonatal Medicine*, 25, 750-755.
<https://doi.org/10.3109/14767058.2011.594466>

Total number of authors:

3

General rights

Unless other specific re-use rights are stated the following general rights apply:

Copyright and moral rights for the publications made accessible in the public portal are retained by the authors and/or other copyright owners and it is a condition of accessing publications that users recognise and abide by the legal requirements associated with these rights.

- Users may download and print one copy of any publication from the public portal for the purpose of private study or research.
- You may not further distribute the material or use it for any profit-making activity or commercial gain
- You may freely distribute the URL identifying the publication in the public portal

Read more about Creative commons licenses: <https://creativecommons.org/licenses/>

Take down policy

If you believe that this document breaches copyright please contact us providing details, and we will remove access to the work immediately and investigate your claim.

LUND UNIVERSITY

PO Box 117
221 00 Lund
+46 46-222 00 00

Placental ischemia and changes in umbilical and uteroplacental arterial and venous hemodynamics

Ann Thuring, Karel Maršál, Ricardo Laurini

Department of Obstetrics and Gynecology, Clinical Sciences Lund,
Lund University, Sweden

Short title: Placental ischemia and hemodynamics

Keywords: Placenta, Doppler ultrasound, pregnancy, umbilical circulation,
uteroplacental circulation

Address for correspondence:

Ann Thuring, Biomedical Scientist

Department of Obstetrics and Gynecology

Lund University Hospital

S-22185 Lund, Sweden

Phone: +46 46 172761

e-mail: Ann.Thuring@med.lu.se

Abstract*Objective*

To relate Doppler velocimetry findings in fetoplacental and uteroplacental circulation to placental histomorphology.

Material and Methods

In 14 uncomplicated and 31 high-risk pregnancies Doppler velocimetry was performed in umbilical artery and vein, and in maternal uterine veins and arteries during the second half of gestation. Histopathology of the placentas was examined especially for signs of ischemia and inflammation.

Results

All fetuses in uncomplicated pregnancies had normal flow velocity waveforms in umbilical artery; in the high risk group 18 fetuses had abnormal flow (increased PI or absent/reverse end-diastolic flow). The latter group had more often high ischemic score and infarctions in the placenta than found in pregnancies with normal umbilical artery flow ($p<0.001$ and $p=0.02$, respectively). Similarly, the abnormal uterine artery flow pattern (uterine artery score 3-4) occurred more often with high ischemic score and placenta infarctions ($p<0.001$ and $p<0.001$, respectively). No significant associations were found between the uterine venous flow type and placental ischemia.

Conclusion

Placental ischemic morphological changes were associated with Doppler ultrasound signs of increased resistance to arterial blood flow both on the fetal and maternal sides of the placenta. No significant relation to the uterine venous flow velocities was found.

Introduction

A normal development of placenta in early pregnancy is dependent on an adequate invasion of trophoblast cells into decidual and myometrial segments of spiral arteries. Several studies have shown that deficient trophoblast invasion is associated with increased placental vascular resistance in the fetoplacental and uteroplacental circulation and development of preeclampsia and/or intrauterine growth restriction (IUGR) [1,2]. The increased resistance to flow in the umbilical and uterine arteries can be detected with Doppler ultrasound that is used as a part of a clinical protocol in surveillance of high risk pregnancies [3,4]. However, the results of Doppler velocimetry have not always been predictive of placental pathology [5,6]. This is probably due to the fact, that human placenta has vast compensatory capacity and/or that there are very few well-designed studies correlating a comprehensive morphological placenta examinations to antenatal hemodynamic findings obtained with Doppler ultrasound.

At the histopathological placenta examination in cases of placental abruption, we observed signs of venous congestion on the maternal side of placenta. This raised the question of potential clinical significance of an abnormal placental-maternal venous return and likelihood that uteroplacental venous flow could facilitate the detection of early changes in intraplacental circulation. Recently, we established the feasibility of assessing uterine venous flow velocities and demonstrated that pulsating blood flow velocity in uterine veins was associated with abnormal Doppler findings in the uterine artery [7].

The aim of the present study was to relate the Doppler velocimetry findings in uterine veins and arteries and in umbilical artery to placental morphology in uncomplicated and

high-risk pregnancies, respectively. In addition to conventional histopathological examination of placenta, special attention was paid to the degree of ischemic pathology and inflammatory infiltration of decidua basalis.

Material and Methods

The study comprised 45 singleton pregnancies; 14 of pregnancies were uncomplicated and 31 were high-risk pregnancies. The demographic data and the outcome of pregnancies are presented in Table I. The 14 uncomplicated pregnancies were recruited at routine ultrasound examinations in the second half of gestation. The 31 high-risk pregnancies were referred for Doppler examination of fetal and maternal circulation as a part of clinical surveillance; 14 were referred because of suspected IUGR, 8 because of preeclampsia and 5 patients had both preeclampsia and IUGR. In the remaining 4 cases, the indication for Doppler velocimetry were pregnancy induced hypertension, premature preterm rupture of membranes, hepatitis C, and diabetes mellitus, respectively.

The ultrasound examinations were performed transabdominally with a Philips HDI 5000 system using a 5-2 MHz transducer (Philips Medical Systems, Bothell, WA). All examinations were done by one of the authors (AT) on women reclining in a standard hospital bed. The Doppler signals were recorded during periods of fetal apnea and quiescence, and during short voluntary maternal apnea. The blood velocity signals of umbilical artery and vein were recorded from the free-floating part of the umbilical cord. The Doppler signals from maternal uterine arteries were recorded from the sample volume placed over the uterine artery just above its crossing with iliac vessels on both

sides of uterus. The uterine veins were identified close to the uterine artery using colour Doppler as described previously [7].

Pulsatility index (PI) was calculated from at least ten uniform waveforms in the flow velocity spectrum of umbilical artery and of both uterine arteries. The waveform patterns in the umbilical artery were also described semiquantitatively according to blood flow classes (BFC) [8]: BFC normal, PI within normal limits of the reference [9] and positive diastolic flow; BFC I, $PI > \text{mean} + 2SD$ and $\leq \text{mean} + 3SD$, and positive diastolic flow; BFC II, $PI > \text{mean} + 3SD$ and positive diastolic flow; BFC IIIA, absent end-diastolic flow velocity; BFC IIIB, reverse end-diastolic flow velocity. The flow in the umbilical vein was considered normal if continuous non-pulsatile. The uterine artery blood velocity spectrum was also evaluated semiquantitatively according to the uterine artery score (UAS) [4]: UAS 0, PI within normal limits [10] and no early diastolic notch in both uterine arteries; UAS 1-3, one up to three abnormal findings, i.e., either $PI > 1.20$ or notch established visually; UAS 4, $PI \geq 1.20$ and early diastolic notch bilaterally. The uterine venous flow pattern was described in three flow velocity types [7]: type I, continuous non-pulsatile flow; type II, pulsatile flow with a “notch” down to the zero line; type III, pulsatile pattern with absent flow during a part of the heart cycle.

After delivery, the placentas were weighed and then left to drain at room temperature for 4 to 6 h followed by fixation in 10 % formalin. The weight of the fixated placentas was assessed after dissection of the umbilical cord, membranes and coagula, when present. Tissue sampling for histological examination was based on a minimum of 6 paraffin blocks including 8 standard samples of tissue: umbilical cord (two); membrane roll (one); umbilical cord insertion (one); cotyledons with normal appearance including

maternal lakes (two); decidua basalis (opening of spiral arteries) (two). In addition, a variable number of samples from gross lesions were examined (up to 12 paraffin blocks per placenta). Tissue samples were embedded in paraffin and stained with hematoxylin-eosin.

All sections were examined by one of the authors (RL) and the findings were classified for conventional pathology with special emphasis on occurrence of mural thrombosis, hemorrhagic endovasculitis, avascular villi, sclerosing endarteritis, ischemia (increased syncytial knotting), ischemic villitis (microinfarctions), infarctions, perivillous fibrin deposition (focal or massive), villitis of unknown etiology, decidual (i.e., uteroplacental) vasculopathy (inadequate trophoblast infiltration, acute atherosclerosis, and thrombosis in decidual vessels). Fetoplacental thrombotic vasculopathy included mural thrombosis, hemorrhagic endovasculitis, and avascular villi. The presence of inflammatory cells (**mostly** lymphocytes and occasional plasma cells) in the decidua basalis indicated chronic deciduitis that was quantified in four grades: grade D0 (no cells), grade D1 (occasional cells), grade D2 (several foci with cells), grade D3 (diffuse infiltration) (Fig 1).

The degree of ischemic pathology was defined using the recently described placenta ischemic score (IS) [11]. The IS represents the sum of ischemic lesions (ischemia, ischemic villitis, and infarction) observed on histological examination - one point for the presence of each lesion in respective section, several similar lesions observed in the same section being counted as one. An abnormal IS was defined as ≥ 1 . In addition we calculated an ischemic score index (ISI) - IS divided by the number of available sections

with parenchyma. The section from the insertion was considered only when represented by a complete transplacental section.

The use of Doppler ultrasound in pregnancy was approved by the Regional Research Ethics Committee and the women participated in the study after giving their informed consent.

Mann-Whitney test and Fisher's exact test were used for statistical analysis as appropriate. MedCalc version 9.1.0.1. statistical package (MedCalc Software, Mariakerke, Belgium) was used for calculations.

Results

The placenta weight was significantly higher in the group of uncomplicated pregnancies than in the group of high-risk pregnancies ($p < 0.001$) (Table II). Placenta infarctions and high IS (2-9) were significantly more often found among high-risk pregnancies ($p < 0.01$ and $p < 0.001$, respectively) that also had higher median ISI ($p < 0.001$). The distribution of deciduitis grades was similar in both groups ($p = 0.07$) (Table II).

In all uncomplicated pregnancies the blood velocity waveforms in umbilical artery were normal (BFC normal) and the flow in umbilical vein was normal non-pulsatile. In the high risk group, 13 patients had normal umbilical artery BFC, 2 had BFC I, 4 BFC II, 9 BFC IIIA, and 3 BFC IIIB. Two patients with BFC II and 6 with BFC III had pulsations in the umbilical venous flow. The findings of high UAS were more common in the group of high-risk pregnancies (two patients with UAS 1, three with UAS 2, four with

UAS 3, and 15 patients with UAS 4) than in the group with uncomplicated pregnancies (UAS 1 in one and UAS 2 in two women).

The distribution of Doppler velocimetry findings according to the results of placenta histomorphology in total material is presented in Table III. No statistically significant differences were found between the various uterine venous flow types with regard to the IS ($p = 0.17$), ISI ($p = 0.21$), presence of infarctions ($p = 0.14$) and degree of deciduitis ($p = 1.00$). Abnormal umbilical artery flow velocity waveforms (BFC I-III) were significantly more often found in cases with infarctions or with high IS ($p=0.02$ and $p<0.001$, respectively) than in cases without signs of placental ischemia. The median ISI was higher in cases with BFC I-III than in those with BFC normal ($p<0.001$). Similar differences were found for the uterine artery Doppler findings: there was association between the high UAS (3-4) and infarctions ($p<0.001$), and between high UAS and high IS ($p<0.001$). The median ISI was higher in cases with UAS 3-4 than in those with UAS 0-2 ($p<0.001$).

Discussion

In recent years, developments in Doppler ultrasound technology substantially improved the possibilities to detect and visualize low velocity flows also in small vessels. The sensitivity of colour Doppler has increased and it is now possible to find and record Doppler flow signals of maternal veins including the uterine veins [7]. Previously, we showed that abnormal flow velocity patterns in uterine veins (types II and III) were associated with abnormal Doppler findings in the uterine artery (UAS 2-4) [7].

Therefore, we have expected to find an association between histomorphological findings indicating placenta ischemia and abnormal uterine venous blood flow type. However, the present findings failed to confirm it. There are limiting factors that might have at least partly contributed to this. The ultrasound method might still not be at the necessary technical level in order to detect discrete changes in the venous return from placenta that includes a very special vascular anatomy comprising both chorio-decidual sinuses and draining uterine veins [12]. Another factor might be the size and composition of the present clinical material.

In agreement with our previous studies [11,13], we have found a strong association between the Doppler findings indicating high resistance to arterial flow on both sides of placenta (BFC I-III and UAS 3-4) and placental ischemic changes expressed as the presence of infarctions and high ischemic score (Table III). The increased inflammatory response that characterises both placental ischemic changes and deciduitis can have contributed to these hemodynamic changes.

In the present study, chronic deciduitis (grades D2 and D3) was seen only in the high-risk pregnancies with the exception of one case. Our findings regarding deciduitis are very similar to those reported by others when describing chronic deciduitis in the placental basal plate [14]. Moreover, the diffuse decidual leukocytoclastic necrosis of decida basalis, a placental lesion associated with preeclampsia, preterm birth and IUGR, also shows a significant association to chronic deciduitis [15]. In addition, chronic deciduitis has been shown to have a weak but significant association to periventricular leukomalacia in the infants [16].

An increased maternal systemic inflammatory response has been shown in preeclamptic pregnancies where placenta inflammation plays a central role [17]. Based on our findings, we hypothesise that the hemodynamic changes shown by Doppler velocimetry might be a result of an abnormally increased placenta inflammation secondary to the inflammatory process that accompanies placental ischemia, in particular the infarctions with extensive polymorphonuclear infiltration around necrotic areas and with increase in inflammation of decidua basalis. Such augmented inflammatory activity will result in an amplified production of inflammatory cytokines and tumor necrosis factor (TNF) that can directly affect the uterine circulation. In addition, the inflammatory process can also activate leukocytes, especially granulocytes that can stimulate endothelial cells of the uterine vessels and promote anchoring of inflammatory leukocytes with resulting endothelial cell damage [18]. Such process would be then an integral part of the excessive inflammatory response. There is evidence that leukocytes in uterine circulation are significantly activated and uterine venous blood shows higher concentration of TNF α in preeclampsia [19,20].

Thus, independent of its possible etiology, chronic deciduitis indicates an increased inflammatory response that strengthens the role of inflammation in placental pathology. Recent work showed that the maternal levels of inflammatory cytokines are related to the degree of inflammatory infiltration in placental tissue samples [21]. The cytokine and chemokine levels in the group with signs of inflammation were generally higher than in controls but lower than in cases with histological chorioamnionitis group [21].

The above described inflammatory processes in the placenta leading to systemic inflammatory response in maternal circulation might contribute to the chronically

increasing placental resistance to flow in IUGR and preeclampsia. This seems to be indirectly supported by the experimental work on pregnant sheep with intact placenta where embolization of a very large proportion of placenta was necessary to increase the umbilical artery resistance detectable by Doppler ultrasound [22].

In summary, our study showed placental ischemic morphological changes to be associated with Doppler ultrasound signs of increased resistance to arterial blood flow both on the fetal and maternal sides of the placenta. No significant relation to the uterine or umbilical venous flow velocities was found.

Acknowledgements

The expert technical help by Sidsel Laurini in processing placenta samples is gratefully acknowledged. The study was supported by grants to Researchers in the Public Health Service from the Swedish Government.

Declaration of interest

The authors report no declaration of interest.

References

1. Brosens I, Robertson WB, Dixon HG. The role of the spiral arteries in the pathogenesis of preeclampsia. *Obstet Gynecol Annual* 1972;1:117-191.
2. Khong TY, De Wolf F, Robertson WB. Inadequate maternal vascular response to placentation in pregnancies complicated by preeclampsia and by small-for-gestational age infants. *Br J Obstet Gynaecol* 1986;93:1049-1059.
3. Westergaard HB, Langhoff-Roos J, Lingman G, Maršál K, Kreiner S. A critical appraisal of the use of umbilical artery Doppler ultrasound in high-risk pregnancies: use of meta-analyses in evidence-based obstetrics. *Ultrasound Obstet Gynecol* 2001;17:466-476.
4. Hernandez-Andrade E, Brodzki J, Lingman G, Gudmundsson S, Molin J, Maršál K. Uterine artery score and perinatal outcome. *Ultrasound Obstet Gynecol* 2002;19:438–442.
5. Kingdom JCP, Burrell SJ, Kaufmann P. Pathology and clinical implications of abnormal umbilical artery Doppler waveforms. *Ultrasound Obstet Gynecol* 1997;9:271-286.
6. Olofsson P, Laurini RN, Lingman G, Maršál K. Feto-maternal circulatory changes related to placenta morphology in diabetes mellitus. *Echocardiography* 1990;7:613-618.
7. Thuring A, Laurini R, Maršál K. Uterine venous blood flow in normal and complicated pregnancies: a methodological study. *Ultrasound Obstet Gynecol* 2010;35:462-467.
8. Gudmundsson S, Maršál K. Blood velocity waveforms in the fetal aorta and umbilical artery as predictors of fetal outcome – A comparison. *Am J Perinatol* 1991;8:1-6.

9. Gudmundsson S, Maršál K. Umbilical artery and uteroplacental blood flow velocity waveforms in normal pregnancy – A cross-sectional study. *Acta Obstet Gynaecol Scand* 1988;67:347-354.
10. Hofstaetter C, Dubiel M, Gudmundsson S, Maršál K. Uterine artery color Doppler assisted velocimetry and perinatal outcome. *Acta Obstet Gynaecol Scand* 1996;75:612-619.
11. Brodzki J, Länne T, Laurini R, Strevens H, Wide-Svensson D, Maršál K. Vascular mechanical properties and endothelial function in pre-eclampsia with special reference to bilateral uterine artery notch. *Acta Obstet Gynecol* 2008;87:154-162.
12. Turner R, Carroll BA. Ultrasound appearance of decidual reaction in the uterus during normal pregnancy. *AJR* 1979;133:493-496.
13. Laurini R, Laurin J, Maršál K. Placental histology and fetal blood flow in intrauterine growth retardation. *Acta Obstet Gynecol Scand* 1994;73:529-534.
14. Yee Khong T, Bendon RW, Qureshi F, Redline RW, Gould S, Stallmach T, Lipsett J, Staples A. Chronic deciduitis in the placental basal plate: definition and interobserver reliability. *Hum Pathol* 2000;31:292-295.
15. Goldenberg RL, Faye-Petersen O, Andrews WW, Goepfert AR, Cliver SP, Hauth JC. The Alabama Preterm Birth Study: diffuse decidual leukocytoclastic necrosis of the decidua basalis, a placental lesion associated with preeclampsia, indicated preterm birth and decreased fetal growth. *J Mat Fet Neonat Med* 2007;20:391-395. .
16. Maleki Z, Bailis AJ, Argani CH, Askin FB and Graham E. Periventricular leukomalacia and placental histopathologic abnormalities. *Obstet Gynecol* 2009;114:1115-1120.

17. Redman CWG, Sargent IL. Pre-eclampsia, the placenta and the maternal systemic inflammatory response-a review. *Placenta* 2003;24(Suppl 1):S21-27.
18. Wang JH, Redmond HP, Watson RW, Duggan S, McCarthy J, Barry M, Bouchier Hayes D. Mechanisms involved in the induction of human endothelial cell necrosis. *Cell Immunol* 1996;168:91-99.
19. Benyo DF, Smarason A, Redman CWG, Sims C, Conrad KP. Expression of inflammatory cytokines in placentas from women with preeclampsia. *J Clin Endocrinol Metab* 2001;86:2505-2512.
20. Mellembakken JR, Aukrust P, Olafsen MK, Ueland T, Hestdal K, Videm V. Activation of leukocytes during the uteroplacental passage in preeclampsia. *Hypertension* 2002;39:155-160.
21. Holst R-M, Laurini R, Jacobsson B, Samuelsson E, Sävman K, Doverhag C, Wennerholm U-B, Hagberg H. Expression of cytokines and chemokines in cervical and amniotic fluid: Relationship to histological chorioamnionitis. *J Mat Fet Neonat Med* 2007;20:885-893.
22. Trudinger BJ, Stevens D, Connelly A, Hales JRS, Alexander G, Bradly L, Fawcett A, Thompson RS. Umbilical artery flow velocity waveforms and placental resistance: the effect of embolization of the umbilical circulation. *Am J Obstet Gynecol* 1987;157:1443-1448.
23. Marsál K, Persson PH, Larsen T, Lilja H, Selbing A, Sultan B. Intrauterine growth curves based on ultrasonically estimated foetal weights. *Acta Paediatr* 1996;85:843-848.

Legends

Fig. 1 Grades of chronic deciduitis. Histological sections from decidua basalis showing grade D0 without inflammatory cells (fig. 1A), grade D1 with occasional inflammatory cells (fig. 1B), grade D2 characterized by several foci of inflammatory cells (fig. 1C), and grade D3 with diffuse infiltration by inflammatory cells (fig. 1D). Samples stained with hematoxylin-eosin; magnification 400x.

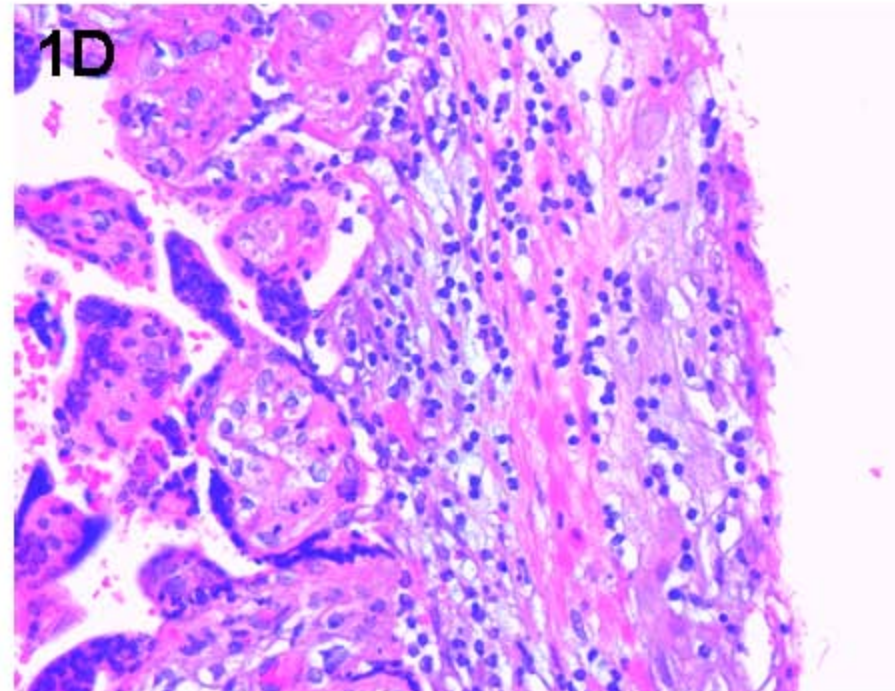
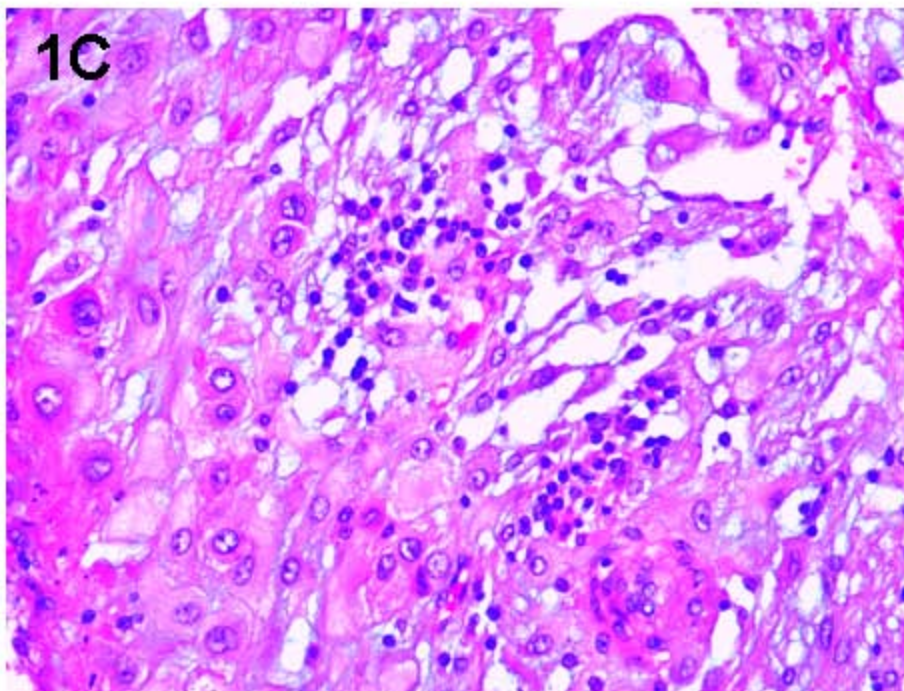
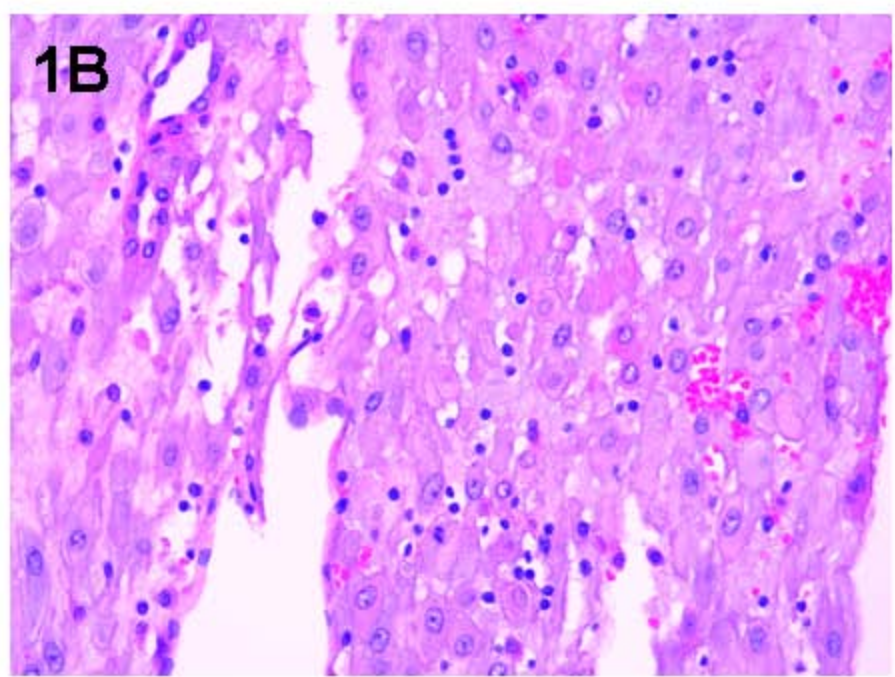
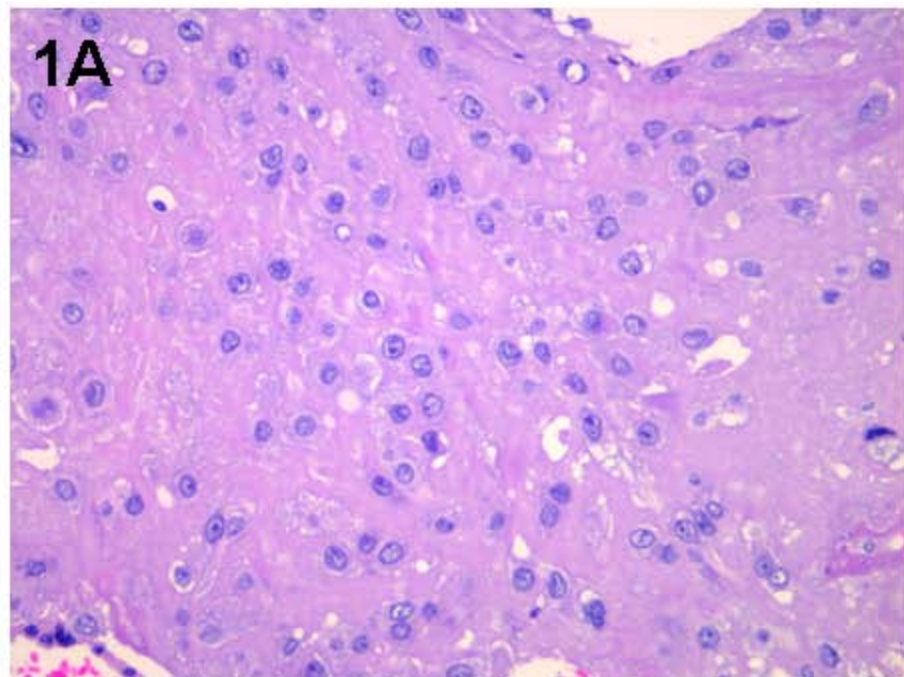


Table I. Demographic data

	Uncomplicated pregnancies	High-risk pregnancies
n	14	31
<i>Mothers / pregnancies</i>		
Age (years; median (range))	32 (24-42)	29 (20-42)
Nulliparae (n [%])	5 [36%]	20 [66%]
Body Mass Index* (kg/m ² ; mean ± SD)	27.7 ± 4.3	28.1 ± 5.1
≤ 30 kg/m ² (n)	10	18
31-34 kg/m ² (n)	2	3
> 35 kg/m ² (n)	1	1
Gestational age (weeks + days; median (range))		
- at examination	32+3 (24+2 – 39+3)	29+0 (23+0 – 37+3)
- at delivery	39+6 (38+0 – 41+0)	29+1 (23+4 – 39+4)
Delivery mode (n [%])		
- vaginal spontaneous	13 [93 %]	8 [26 %]
- cesarean section	1 [7 %]	23 [74 %]
- elective	1	6
- emergency	0	17

Newborns

Female gender (n [%])	7 [50 %]	17 [55 %]
Birth weight (g; median (range))	3590 (2670 – 4220)	1113 (320 – 3425)
Birth weight deviation ** (%; (range))	1.5 (-19 - +25)	-29.3 (-59 - +9)
Small-for-gestational age (n [%])	0	21[68 %]
Large-for-gestational age (n [%])	1 [7 %]	0
Apgar score 5 min < 7 (n [%])	0	1 [2 %]***
pH umbilical artery (mean ± SD)	7.26 ± 0.09 [§]	7.28 ± 0.06 ^{§§}

* missing in 10 cases; ** deviation from the expected birth weight according to the Swedish growth standard²³; *** 3 cases of intrauterine death excluded; § missing in 1 case, §§ missing in 6 cases

Table II. Placenta morphology.

	Uncomplicated pregnancies	High-risk pregnancies	Significance of difference
n	14	31	
Placenta weight (g; median (range)) at delivery	560 (480 – 770)	330 (90 – 630)	p < 0.001
Placenta weight (g; median (range)) at morphological examination	417(325 – 527)	208 (77- 486)	p < 0.001
Ischemic score (IS) (n)			
0-1	13	9	p < 0.001*
2-6	1	16	
7-9	0	6	
(median (range))	0 (0-2)	4.5 (0-9)	
Ischemic score index (ISI) (median (range))	0 (0-0.4)	0.86 (0-1.75)	p < 0.001
Deciduitis (n)			
0	9	19	p = 0.07**
1	4	1	
2	1	6	
3	0	5	
Infarctions (n)			
0 %	14	16	p < 0.01***
1% - 9%	0	7	
10% - 40%	0	8	

* IS 0-1 vs IS 2-9

** Deciduitis 0-1 vs 2-3

*** Infarctions 0% vs 1-40%

Table III. Doppler velocimetry of umbilical and uterine circulation according to placental morphology.

	Umbilical artery blood flow class		Uterine artery score		Uterine venous flow type	
	normal	I - III	0 -2	3 - 4	I	II - III
Ischemic score 0-1	19	3	20	1	19	3
2-9	8	15	5	19	15	8
Significance of difference	p < 0.001		p < 0.001		p = 0.17	
Ischemic score index median (range)	0 (0-1.5)	0.88 (0-1.75)	0 (0-1.20)	0.88 (0-1.75)	0 (0-1.75)	0.41 (0-1.5)
Significance of difference	p < 0.001		p < 0.001		p = 0.21	
Deciduitis 0-1	19	14	20	13	25	8
2-3	8	4	6	6	9	3
Significance of difference	p = 0.74		p = 0.73		p = 1.00	
Infarctions no	22	8	25	5	25	5
yes	5	10	1	14	9	6
Significance of difference	p = 0.02		p < 0.001		p = 0.14	

Results presented as numbers or median (range).