



# LUND UNIVERSITY

## Adolescent Idiopathic Scoliosis. The Role of Low Dose Computed Tomography.

Abul-Kasim, Kasim

2009

[Link to publication](#)

*Citation for published version (APA):*

Abul-Kasim, K. (2009). *Adolescent Idiopathic Scoliosis. The Role of Low Dose Computed Tomography*. [Doctoral Thesis (compilation), Department of Translational Medicine]. Department of Radiology, Lund University.

*Total number of authors:*

1

### General rights

Unless other specific re-use rights are stated the following general rights apply:

Copyright and moral rights for the publications made accessible in the public portal are retained by the authors and/or other copyright owners and it is a condition of accessing publications that users recognise and abide by the legal requirements associated with these rights.

- Users may download and print one copy of any publication from the public portal for the purpose of private study or research.
- You may not further distribute the material or use it for any profit-making activity or commercial gain
- You may freely distribute the URL identifying the publication in the public portal

Read more about Creative commons licenses: <https://creativecommons.org/licenses/>

### Take down policy

If you believe that this document breaches copyright please contact us providing details, and we will remove access to the work immediately and investigate your claim.

LUND UNIVERSITY

PO Box 117  
221 00 Lund  
+46 46-222 00 00

# **Adolescent Idiopathic Scoliosis.**

## **The Role of Low Dose Computed Tomography**

Kasim Abul-Kasim



**LUND UNIVERSITY**

AKADEMISK AVHANDLING

som med vederbörligt tillstånd av Medicinska fakulteten vid Lunds universitet för avläggande  
av doktorsexamen i medicinsk vetenskap kommer att offentligen försvaras i

Lilla aulan, MFC, ing 59, Universitetssjukhuset MAS, Malmö,

tisdagen den 12 maj 2009, kl 09.15

Fakultetsopponent:

Docent Håkan Geijer, Örebro

Organization LUND UNIVERSITY Clinical Sciences, Malmö Medical Radiology	Document name DOCTORAL DISSERTATION	
	Date of issue May 12, 2009	
	Sponsoring organization	
Author(s) Kasim Abul-Kasim		
Title and subtitle Adolescent idiopathic scoliosis. The role of low dose computed tomography.		
<p><b>Abstract</b></p> <p>Continuous implementation of new operative methods for correction and stabilization of spinal deformities in young patients with AIS demands a detailed morphological analysis of the vertebral column. CT spine according to protocols available in daily clinical practice means a high radiation dose to these young individuals. All examinations included in this thesis were performed on a 16-slice CT scanner. Examination of the chest phantom in <b>paper I</b> showed that the radiation dose of the spine (including 15 vertebrae) was 20 times lower than that of routinely used protocols for CT examination of the spine in children (0.38 mSv vs 7.76 mSv). In <b>paper II</b> the radiation dose and the impact of dose reduction on image quality were evaluated in 113 consecutive examinations with low-dose spine CT and compared with that of 127 CTs after trauma and 15 CTs performed according to a previously used ANV/KASS-protocol of a limited part of the vertebral column. The effective dose of the low-dose spine CT (0.01 mSv/cm scan length) was 20 times lower than that of the standard CT for trauma (0.20 mSv/cm scan length). The absorbed doses to the breasts, genital organs, and thyroid gland in the low-dose spine CT was 8, 265, and 22 times lower than the corresponding doses in CT for trauma. This significant dose reduction conveyed no impact on image quality with regard to answering the clinical questions at issue for the preoperative CTs and for the CT-examinations after posterior corrective surgery. In <b>paper III</b> the low-dose CT showed to be a reliable method in the evaluation of screw placement in patients with AIS after posterior scoliosis surgery with titanium implants, using the new grading system for screw misplacement. Our proposed grading system for screw misplacement has shown to be feasible, practical, and easy to perform and is in line with the general agreement about the harmlessness of misplacement with minor pedicle breach. In <b>paper IV</b> the evaluation of the clinical and radiological outcome of 49 patients with AIS operated on with titanium "all-pedicle screw construct" showed an overall misplacement rate of 17 %. No evidence of neurovascular complications was reported. In parity with most of the reports in the literature the lateral- and medial cortical perforation were the most common types of screw misplacement (8 % and 6.1 % respectively).</p> <p><b>Key words:</b>          low-dose spine CT, adolescent idiopathic scoliosis, phantom, effective dose, image quality, titanium screws, screw misplacement, neurovascular complication, outcome.</p> <p>Classification system and/or index terms (if any):</p>		
Supplementary bibliographic information:	Language: English	
ISSN and key title: 1652-8220, Low-dose CT in AIS	ISBN 978-91-86253-29-5	
Recipient's notes	Number of pages 156	Price
Security classification		

Distribution by (name and address) **Kasim Abul-Kasim, Department of Radiology, Malmö University Hospital, Malmö, Sweden**

I, the undersigned, being the copyright owner of the abstract of the above-mentioned dissertation, hereby grant to all reference sources permission to publish and disseminate the abstract of the above-mentioned dissertation.

Signature K. Abul Kasim Date 2009-03-19

# **Adolescent Idiopathic Scoliosis.**

## **The Role of Low Dose Computed Tomography**

Kasim Abul-Kasim



Faculty of Medicine, University of Lund  
Department of Radiology  
Malmö University Hospital, Malmö

2009



ISSN 1652-8220

ISBN 978-91-86253-29-5

Lund University, Faculty of Medicine Dissertation series 2009:42

Cover by

Printed by Media Tryck in Lund, Sweden 2009

©Kasim Abul-Kasim 2009

To Saly, Lina and Linda

"Constant development is the law of life, and a man who always tries to maintain his dogmas in order to appear consistent drives himself into a false position."

*Mahatma Gandhi*



## Contents

Abbreviations	6
Glossary of terms	8
List of papers	10
Summary of papers	11
Introduction	15
Aims of the thesis	31
Materials and methods	33
Results	47
General discussion	59
Conclusions and summary of results	75
Recommendations	75
Summary in Swedish (populärvetenskaplig sammanfattning)	76
Appendices	79
Acknowledgements	89
References	91
Paper I	103
Paper II	115
Paper III	127
Paper IV	141

## Abbreviations

ACP	Anterior cortical perforation
AIS	Adolescent idiopathic scoliosis
ANV	Apical neutral vertebra
AP	Anteroposterior
CI	Confidence interval, often as 95 % CI
CSL	Central sacral line
CT	Computed tomography
CTDI <sub>vol</sub>	Computed tomography dose index volume
3D	3-dimensional
DLP	Dose length product
DRN	Diagnostic reference level (diagnostisk referensnivå)
DRS	Dose reduction system
DVR	Direct vertebral rotation
dx	Dexter, right
E	Effective dose
EC RDLs	European commission reference dose levels
EPP	Endplate perforation
FP	Foraminal perforation
ICC	Intraclass correlation coefficient
IQR	Image quality reference
KASS-protocol	Kaneda Anterior Spinal Surgery-protocol (KASS-protocol)
K	Cohen's kappa (kappa value)
kV	Kilovolt (tube voltage)
L	Lumbar
LCP	Lateral cortical perforation
mA	Milliampere (tube current)
mAs	Milliampere second (tube charge)
MCP	Medial cortical perforation
MEP	Motor evoked potential
mGy	Milligray
MPR	Multiplanar reconstruction
MRI	Magnetic resonance imaging
MSCT	Multislice computed tomography, also called multidetector computed tomography (MDCT)
mSv	Millisievert
n	Number
PA	Posteroanterior
PACS	Picture archiving and communication system
PRU	Pedicle rib unit

ROI	Region of interest
SD	Standard deviation
SI	International system of units
sin	Sinister, left
SNR	Signal-to-noise ratio
SPSS	Statistical Package for the Social Sciences
SSI FS	Swedish Radiation Protection Authority regulations (Statens strålskyddsinstitutets föreskrifter)
T	Thoracic
TSA	Transverse screw angle
VRT	Volume rendering technique

## Glossary of Terms

Absorbed dose	The measure of the energy deposited in a medium by ionizing radiation, also known as total ionizing dose (TID). It has the unit of gray (Gy).
Apical vertebra	The vertebra that is most deviated laterally from the vertical axis that passes through the central sacral line.
Central sacral line	The vertical line in a frontal radiograph that passes through the center of the sacrum (identified by suitable landmarks preferably on the first sacral segment).
Cobb angle	The angle formed at the intersection of a line drawn along the upper end vertebra and a line drawn along the lower end vertebra or the angle formed at the intersection of the lines perpendicular to these lines.
Effective dose	Is an estimate of the stochastic effect that a non-uniform radiation dose has on a human, given in Sievert (Sv).
Equivalent dose	The measure of the radiation dose to the tissue exposed to ionizing radiation, given in Sievert (Sv).
Feed	The table movement per rotation.
Increment	The distance that the table is advanced per rotation of the x-ray tube.
Ionizing radiation	Consists of subatomic particles or electromagnetic waves that are energetic enough to detach electrons from atoms or molecules resulting in their ionization.
Kilovolt (kV)	The unit of tube voltage. SI derived unit of electric potential difference.
Lower end vertebra (inferior end vertebra)	The first vertebra in the caudad direction from a curve apex, whose inferior surface is tilted maximally towards the concavity of the curve.
Milliamperere (mA)	The SI unit of tube current. $1 \text{ mA} = 10^{-3} \text{ A}$ .
Milligray (mGy)	The SI unit of the absorbed radiation dose. $1 \text{ mGy} = 10^{-3} \text{ Gy}$ .
Millisievert (mSv)	SI unit of dose equivalent. $1 \text{ mSv} = 10^{-3} \text{ Sv}$ .
Neutral vertebra	The vertebra without axial rotation.
Pitch	The table movement per rotation (feed) /slice thickness. This term used only in single slice CT.
Pitch factor	The table movement per rotation (feed) /the sum of slice collimation of all detectors. This term used in multidetector CT.
Reconstruction increment	The distance between the positions of neighboring image planes. It is an expression of the degree of overlapping between the reconstructed images.

Rotation time	The time needed for the gantry to rotate 360°.
Transverse screw angle	The angle between a line drawn through the middle of the vertebral body and a line drawn through the middle of the pedicle (in axial projection).
Tube collimation	Beam adjustment.
Upper end vertebra. (superior end vertebra)	The first vertebra in the cephalad direction from a curve apex, whose superior surface is tilted maximally towards the concavity of the curve.
Vertebral rotation	Transverse plane angulation of a vertebra.



**Paper I**

Radiation dose optimization in CT planning of corrective scoliosis surgery. A phantom study.

Abul-Kasim K, Gunnarsson M, Maly P, Ohlin A, Sundgren PC

*The Neuroradiology Journal* 2008;21:374–382

**Paper II**

Low-dose helical computed tomography (CT) in the perioperative workup of adolescent idiopathic scoliosis.

Abul-Kasim K, Overgaard A, Maly P, Ohlin A, Gunnarsson M, Sundgren PC

*Eur Radiol* 2009;19:610-618. *Epub* 2008 Sep 23.

**Paper III**

Reliability of low radiation dose CT in the assessment of screw placement after posterior scoliosis surgery, evaluated with a new grading system.

Abul-Kasim K, Strömbeck A, Ohlin A, Maly P, Sundgren PC

*Spine*. In press. Scheduled for publication 2009 May 1.

**Paper IV**

Radiological and clinical outcome of screw placement in idiopathic scoliosis using computed tomography with low radiation dose.

Abul-Kasim K, Ohlin A, Strömbeck A, Maly P, Sundgren PC

*Spine*. Submitted 2009; Jan 5.

*The published papers are reprinted with kind permission of the publisher.*

### Paper I

**Background:** Continuous implementation of new operative methods for correction of spinal deformities demands a detailed morphological analysis of the vertebral column. CT spine according to protocols available in daily clinical practice means high radiation dose to these young individuals, predominantly girls.

**Purpose:** To explore the possibility of obtaining a helical CT scan of the whole region of interest of the vertebral column, optimally reduce the radiation dose, compare the radiation dose of the low dose helical CT with that of some of the CT protocols used in clinical practice and, finally, assess the impact of such a dose reduction on the image quality.

**Material and methods:** A chest phantom was examined on a 16-slice CT scanner. Six scans were performed with different radiation doses. The radiation doses of all scans were estimated. The image quality was evaluated subjectively and objectively by two independent radiologists. The absorbed doses to the breasts and the genital organs were also calculated. The radiation doses of the adult phantom used in this study were corrected to phantoms corresponding to different age groups.

**Results:** The lowest radiation dose which had no impact on image quality with regard to the information required for surgical planning of patients with scoliosis was 20 times lower than that of routinely used protocols for CT examination of the spine in children (0.38 mSv vs 7.76 mSv).

**Conclusion:** Patients with scoliosis planned for corrective surgery can be examined with low dose helical CT scan. The dose reduction systems available in modern CT scanners contributed to dose reduction and should be used.

### Paper II

**Background:** Scoliosis primarily affects young individuals and new surgical corrective methods with posterior pedicle screws require detailed pre- and postoperative CT-evaluation of the thoracic and lumbar spine as there is a risk for neurovascular complications with pedicle screw insertion, especially in thoracic vertebrae.

**Purpose:** To estimate the radiation dose in patients with AIS examined with low-dose spine CT and compare the radiation dose with that received by patients undergoing standard CT for trauma of the same region of interest. The second aim of the study was to evaluate the impact of dose reduction on image quality.

**Material and methods:** Radiation doses in 113 consecutive examinations with low-dose spine CT were compared with those of 127 CTs after trauma and 15 CTs performed according to a protocol previously used in our institution (ANV-protocol/KASS-protocol); Appendix 1. Image quality was evaluated subjectively and objectively. The interobserver and the intraobserver agreement in measurements of pedicular width, measurements of vertebral rotation, and assessment of hardware status were the indicators used in the evaluation of image quality. Signal-to-noise ratio was also estimated for haphazardly chosen examinations included in the analysis.

**Results:** The effective dose of the low-dose spine CT (0.01 mSv/cm scan length) was 20 times lower than that of the standard CT for trauma (0.20 mSv/ cm scan length). The effective dose for the whole scan in the low-dose spine CT was 35 times lower than that of the standard CT for trauma ( $0.37 \pm 0.10$  mSv versus  $13.09 \pm 3.19$ ). The absorbed doses to the breasts, genital organs, and thyroid gland in the low-dose spine CT was 8, 265, and 22 times, respectively, lower than the corresponding doses in CT for trauma. This significant dose reduction conveyed no impact on image quality with regard to answering the clinical questions at issue.

**Conclusion:** Using low-dose spine CT in young individuals with AIS allows a detailed evaluation that is necessary for the preoperative planning and the postoperative evaluation of patients undergoing posterior corrective surgery using titanium implants.

### Paper III

**Background:** The use of “all-pedicle screw construct” in the posterior scoliosis surgery continues to gain increasing popularity since its introduction in 1994 although its use in the thoracic spine carries a potential risk for neurovascular complications. CT is the method widely used to evaluate the screw placement.

**Purpose:** To evaluate the reliability of CT with low radiation dose in the assessment of screw placement in patients with AIS operated upon with titanium “all-pedicle screw construct”.

**Materials and methods:** This is a retrospective analysis of 46 consecutive low-dose spine CTs in patients with AIS after posterior corrective surgery. Status of 809 titanium screws (642 thoracic and 167 lumbar) was evaluated. The degree of interobserver and intraobserver agreement about implant status was used as an indicator of the reliability of the low-dose spine CT in the assessment of accuracy of pedicle screw insertion. A new grading system has been developed for this purpose. Five types of misplacements have been evaluated: lateral-, medial-, and anterior cortical perforations, endplate perforation, and foraminal perforation.

**Results:** The analysis has shown a substantial interobserver and intraobserver agreement (kappa value of 0.69 and 0.76 respectively) in differentiating pedicle screws with acceptable placement from screws with partial or total cortical perforation. None of the examinations was subjectively classified as unreliable. The degree of interobserver and intraobserver agreement in evaluating medial and lateral cortical perforation was substantial. However, the interobserver agreement in the evaluation of anterior cortical perforation and foraminal perforation was only fair.

**Conclusion:** This study has shown that low-dose spine CT is a reliable method in evaluating screw placement in patients with AIS after posterior scoliosis surgery with titanium implants, using our new grading system. The new grading system of screw misplacement was feasible, practical, easy to perform and in line with the general agreement about the harmlessness of misplacement with minor pedicle breach. The reliability of low-dose spine CT in the evaluation of lateral cortical perforation, medial cortical perforation and endplate perforation was substantial whereas the reliability in the evaluation of anterior cortical- and foraminal perforations was fair but believed to be improved by increasing experience of the reading radiologist. To avoid exposing these young individuals to unnecessarily high radiation doses, the postoperative assessment of titanium screw placement should be performed with dedicated CT using low radiation dose.

## **Paper IV**

**Background:** CT is the method of choice in the assessment of screw placement. To our knowledge there is no study reporting the use of low-dose spine CT in such assessment.

**Purpose:** To assess pedicle screw placement in patients with AIS using CT with low radiation dose, and to evaluate the clinical outcome in patients with misplaced pedicle screws.

**Materials and methods:** Forty-nine consecutive postoperative low-dose CTs (873 screws; 79 % thoracic) of patients with AIS after posterior surgical correction and stabilization using titanium “all-pedicle screw construct”, were retrospectively analyzed. A new grading system was developed to distinguish between five types of misplacement: lateral-, medial- and anterior cortical perforations as well as endplate perforation and foraminal perforation. The grading system is based on whether the cortical violation by pedicle screws is partial or total rather than on mm-basis.

**Results:** The overall rate of pedicle screw misplacement was 17% (n=149), 8% of the screws were laterally placed and 6.1 % were medially placed. The rates of anterior cortical-, endplate- and foraminal perforations were 1.5%, 0.9%, and 0.5 %, respectively. Lateral cortical perforation was more frequent in the thoracic spine (P=0.005). Other types of misplacement including medial cortical perforation were more frequent on the left and the concave side of the scoliotic curves (P=0.002 and 0.003). No neurovascular complications were reported.

**Conclusion:** In the absence of neurovascular complications spinal canal encroachment of up to 5 mm on the concavity and up to 7 mm on the convexity of scoliotic apex can be tolerated. The low-dose CT used for the evaluation of pedicle screw placement means exposing young individuals with AIS to a significantly lower radiation dose than do the other protocols used in daily clinical practice.

## Introduction

Scoliosis is a 3-dimensional spinal deformity including a lateral curvature of the spine in the frontal plane, vertebral rotation in the axial plane and often lordosis (hypokyphosis) in the sagittal plane. In the absence of any congenital spinal anomaly or associated neurological or musculoskeletal abnormalities, the scoliosis is regarded as idiopathic [1]. Idiopathic scoliosis is traditionally divided into three categories, dependant on the age of onset [2]: infantile, juvenile and adolescent. As a considerable transgression between these groups occur, it is unclear if the juvenile scoliosis really exists [2]. Adolescent idiopathic scoliosis (AIS) is the type of idiopathic scoliosis with onset after the age of 10 years and with maximal progression at the pubertal age. AIS is the most common type of scoliosis and is the subject of this thesis.

### Etiology and pathogenesis of AIS

The etiology and pathogenesis of AIS are unclear and still a matter of debate despite an extensive and cumulative clinical experience that approaches 5000 years. However, a general agreement exists about the multifactorial nature of the disorder.

#### *Genetic factors:*

Several studies dealing with the etiology of AIS have shown certain role of genetic factors in the development of scoliosis as well as in the curve progression. However, no specific mode of inheritance has been identified. The following are some examples of the numerous reports on the role of genetics in the pathogenesis of AIS:

1. Evidence of linkage has been suggested between the familial idiopathic scoliosis and specific regions on chromosome 6, 9, 16, 17, and 19 [3-5].
2. Reports of familial idiopathic scoliosis postulated that the disorder might be caused by a dominantly inherited single gene or by multiple gene disorder [6].
3. Autosomal or multiple gene inheritance was also suggested [7].
4. Female predominance might be an expression of an x-linked dominant inheritance. Cowell et al concluded that AIS was inherited as an x-linked dominant mode with variable expressivity and incomplete penetrance [8].

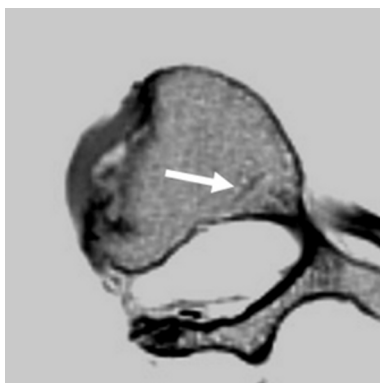
5. Justice et al suggested an x-linked dominant inheritance of familial idiopathic scoliosis [9].
6. Genetic tall stature is an inherited phenomenon and reports have suggested that genetic tall stature is associated with high prevalence of AIS [1] as well as high progression potentials [10, 11].
7. Gene fragility: Children to mothers older than 27 years showed in one study to have a higher risk of development of AIS [12].

### *Spinal growth:*

The pattern of growth of the spine has been studied thoroughly in animal models and in animated reconstructed models. Some studies have suggested imbalance between spinal growth and the body growth whereas other studies have suggested imbalance between the growth of different elements of the vertebral column. Asymmetrical loading of the epiphysial plates results in wedging of the vertebrae and asymmetrical growth [13]. Asymmetrical mechanical forces showed to be associated with elevated synthetic activity in the convex side of scoliotic curves [14] and disorganized chondrocytes [15].

The age of closure of the neurocentral junction is not well defined. However, persistent growth of the neurocentral junction after the age of 10 might result in asymmetrical growth and, may consequently, play a role in the development and progression of scoliosis [16, 17] (Figure 1).

Some flattening of the normal thoracic kyphosis occurs during the adolescence. This is believed to depend on an imbalance between the growth of the anterior and posterior column with relative anterior column overgrowth. As girls mature earlier than boys and as girls usually go through the adolescent growth spurt when the thoracic kyphosis is at its minimum, they tend to develop



**Figure 1:** Persistent growth of the neurocentral junction (arrow) on the left side might contribute to development of scoliosis with the right side being the convex side.

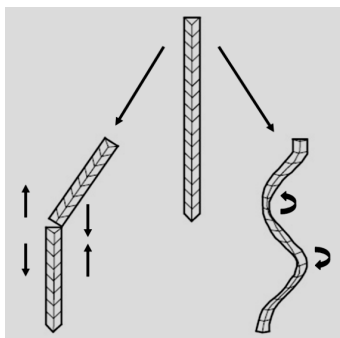
AIS more frequently than boys [18-20]. Several studies have shown that children with AIS are taller compared with their peers [21, 22] which possibly partly depends on the hypokyphosis.

The role of the intervertebral discs in the development of AIS is contradictory. Some authors believe that disc changes occur earlier than vertebral changes, with shift of nucleus pulposus to the convexity of the curve [23] whereas others believe that disc changes in scoliosis are secondary rather than causative [24].

#### *Biplanar spinal asymmetry:*

An important aspect in the pathogenesis of scoliosis is the development of the concept of biplanar spinal asymmetry [19]. The sagittal plane deformity which often was believed to be kyphosis depends on the fact that the viewing at the sagittal plane was in fact viewing of the sagittal plane of the patient and not of the apical vertebra. The vertebral rotation has also contributed to the misunderstanding of the sagittal spinal deformity. A true lateral radiograph of the apical vertebra which is in fact an oblique projection to the routine lateral radiograph, shows a real lordosis or hypokyphosis in association with scoliosis [19], a finding that was experimentally confirmed in rabbit models [25].

Simulating the vertebral column with a beam might make the understanding of the biplanar spinal asymmetry easier. For a beam to fail there are two possible ways: (1) Simple collapse due to structural failure with compression on one side and tension on the other side. This represents the kyphotic deformity (Figure 2). (2) When the beam buckling incorporates true rotation as well the resulting deformity occurs at more than one plane with consequent development of bending in the frontal plane. This represents the mechanism of scoliosis development (Figure 2). Simulating a pipe, the spine can be deformed in one plane or three planes but never in two planes. The normal spine has always a lordosis or kyphosis



**Figure 2** shows the principal idea of the multiplanar nature of scoliosis. The beam in the middle is the normal straight beam. On the left the beam failure following compression, represents the development of kyphosis. On the right the beam buckling deformity incorporates rotation representing the development of scoliosis . Data compiled from [1].

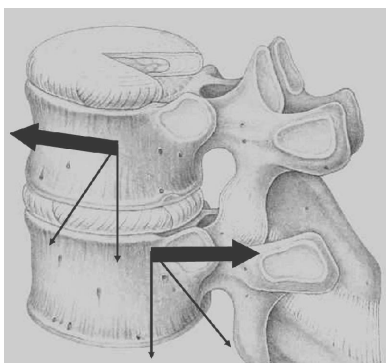


and by adding a lateral curvature when scoliosis developed, a deformity in the third plane (rotation in axial plane) occurs automatically [26].

#### *Upright posture:*

In contradistinction to other vertebrates (quadrupeds and bipeds ambulate with flexed hips and knees) human beings ambulate with erect posture. The upright posture seems to be a prerequisite for scoliosis to develop. This has been supported by the development of scoliosis in rats that were surgically converted to bipedal and subjected to pinealectomy whereas similarly pinealectomized quadrupedal rats did not develop scoliosis [27, 28]. This highlighted also a possible role of melatonin in the development of AIS.

In vertebrates ambulating with flexed hips and knees the spine is loaded by axial compression with the shearing load, e.g. from gravity, directed mainly anteriorly (carried by vertebral bodies and intervertebral discs) [29] (Figure 3). In humans it has been shown that there is an additional shearing load directed posteriorly especially in the thoracic region [30] (Figure 3). The facet joints counteract ventrally directed shearing loads and play an important role in providing rotational stability to the spine [31]. These joints render less effective in this function when they are exposed to posteriorly directed shearing loads with subsequent development of vertebral rotation or increase of a preexisting vertebral rotation, often right-sided [32]. This preexisting vertebral rotation might explain the predominance of right-sided thoracic curves in patients with AIS whereas patients with total situs inversus who develop scoliosis often have their rotational deformity in the mid- and lower thoracic vertebrae to the left [33]. Study on postural function in siblings to scoliotic children showed that postural aberration



**Figure 3** shows that vertebra in human being can be subjected to anterior as well posterior shearing load. Data compiled from [5, 30].

might play a role in the pathogenesis of AIS as siblings had a postural sway that was less than the sway measured in scoliotic patients [34].

### *Neurological origin:*

The suspicion of neuromuscular factors playing some role in the pathogenesis of idiopathic scoliosis has been repudiated [35]. Discrepancy between the spinal cord growth and vertebral growth has been postulated to play some role in the pathogenesis of AIS. It was hypothesized that a short spinal cord acts as a functional tethering of the posterior column with subsequent overgrowth of the anterior column (vertebral bodies), resulting in rotation of the spine around the spinal cord-axis [36, 37]. However, absence of clinical evidence of tethering and the rarity of development of neurological deficit following scoliosis surgery make this suggestion contradictory. Experimentally induced scoliosis by injection of Poliomyelitis vaccine [38] has also raised some suspicion to a possible neurological origin of scoliosis. Association with central nervous system abnormalities, in particular abnormalities of the vestibular apparatus have also been postulated as a causative or associated factor in the pathogenesis of idiopathic scoliosis [39, 40]. Dysfunction of the autonomic nervous system has been postulated to play a certain role in the pathogenesis of AIS [41].

### *Other etiological factors:*

1. Hormonal: Evidence of increased growth hormone activity in girls with adolescent idiopathic scoliosis was proposed [42]. The scoliotic girls showed to have an above-average height 2 years before the onset of the pubertal growth spurt. However, their values were only slightly higher than the reference mean values at maturity because they displayed an early pubertal maturation as well as a low pubertal gain in height.
2. The symmetrical length of the ribs plays an important role in maintaining spinal stability as scoliosis has been induced in animals that underwent surgical elongation or resection of parts of their ribs [43, 44]. A concept for the pathogenesis of AIS in patients with right thoracic curves were proposed by Sevastik et al claiming that increased longitudinal growth of the left periapical ribs triggers the thoracic curve simultaneously in the three cardinal planes [45].
3. Patients with AIS were shown to have lower bone mineral density than normal controls [46]. Osteoporosis is believed to play a role in curve progression.
4. Muscle disorder and platelet abnormalities have been suggested to play a role in the pathogenesis of AIS as patients with progressive scoliosis showed to

have high levels of platelet calmodulin, a calcium-binding receptor protein. Platelet calmodulin resembles the contractile protein of skeletal muscles and muscle abnormalities have been postulated to play a causative role in the pathogenesis of AIS. Scoliosis correction has been shown to result in reduction of platelet calmodulin [47, 48].

5. Abnormal proteoglycans [49], abnormal collagen [50, 51], abnormal fibrillin metabolism [52], and an aberrant muscle physiology [53] have been postulated to play a role in AIS.

## Epidemiology

The screening of school children for scoliosis began in Delaware in 1965 [54]. Clinical examination, photography, plain radiography or reviews of miniature chest radiograph have been used to determine the incidence and prevalence of scoliosis [55-57]. Up to 15% of school children between the age of 10 and 14 years subjected for screening showed to have scoliosis exceeding 5°. However, the incidence of scoliosis varies widely depending on the criteria used for definition of the deformity, the population age included in the screening and the screening method [39]. The prevalence of scoliosis with curve greater than 10° was estimated to be 2 % (range 1.9–3 %) while for curves between 5° and 10° the incidence varies from 4 % [1] to 13.6 % [58]. The prevalence of scoliosis with Cobb angle exceeding 20° is estimated to be about 0.2% [1, 2]. In 1982 Willner et al reported the results of screening of school children in Malmö, Sweden [59]. Between 1971 and 1980, 17181 children were screened for scoliosis once a year between the ages of 7 and 16 years. Prevalence of scoliosis measuring  $\geq 5^\circ$  was 2.8 % (4.3 % among girls and 1.2 % among boys). With 10° as the lower limit, the scoliosis prevalence was 3.2 % in girls and 0.5 % in boys. The prevalence of scoliosis exceeding 19° was 1.1 % in girls and 0.14 % in boys.

In school age children the female to male ratio is in the order of 1.4:1 with ratio increased markedly to 10:1 when it comes to scoliosis achieving clinical significance with curves greater than 20°–30° [1, 2]. It is well known that the maximal curve progression occurs at the time of growth spurt. The discrepancy between the prevalence of clinically significant idiopathic scoliosis in girls and boys indicates that the curve in boys has a significant regression potential and the boys are thus considered to be relatively protected. In adolescents who do not show evidence of curve progression the prevalence of scoliosis is only slightly higher in girls, (Table 1).

## Clinical presentation

Most of the patients are discovered in primary care and followed up by school nurses and physicians. Scoliosis is typically a non-painful condition. However, in a series of 2400 patients 23 % had pain of which 9 % were shown to have underlying pathology [60]. Patients with scoliosis used to be examined in standing position as well as in forward bending. Rib or loin hump and shoulder deformity are the best indicators of the scoliotic deformity. In many cases the deformity component that brings these patients to clinical presentation is the rotational prominence.

The scoliosis is categorized according to the position of the apex into thoracic, thoracolumbar or lumbar as well as according to the direction of the frontal-plane convexity into right or left. The most common type of deformity is a right-sided thoracic curve. More than 90% of the single thoracic curves are right-sided, 80% of the thoracolumbar curves are right-sided, more than 70% of the single lumbar curves are left-sided, and 90% of the double major curves are right thoracic and left lumbar [39]. The two most common types of scoliosis classifications are King classification and Lenke classification which are described in Appendix 2.

## Radiological workup

### *Plain radiography:*

Patients with AIS are usually examined initially with lateral and posteroanterior (PA) standing radiographs. In the subsequent follow-up single PA radiographs are usually obtained to measure the degree of the scoliotic curve. The most common technique used to measure the degree of the scoliotic curve is the Cobb technique [61, 62]. On a standing frontal radiograph lines are drawn tangentially to the superior endplate of the upper end vertebra and the inferior endplate of the lower end vertebra, which are the most tilted vertebrae in the coronal plane. The Cobb angle is the angle formed at the intersection of these lines or the angle formed at the intersection of the lines perpendicular to these lines. Ferguson technique [63] is

Age (year)	Prevalence of scoliosis	
	Female	Male
10	7.2	3.7
11	6.4	4.3
12	5.4	3.0
13	13.0	6.1
14	8.9	7.2
Total	7.7	4.6

**Table 1:** Prevalence of idiopathic scoliosis (curves of  $> 5^\circ$ ) in boys and girls aged 10-14 year. Data compiled from [1]

another method of determining the degree of scoliotic deformity. A line is drawn from the center of the apical vertebra to the center of the upper end vertebra. Another line is drawn from the center of the apical vertebra to the center of the lower end vertebra. The angle between these lines represents the Ferguson angle which is the measure of the degree of severity of the scoliotic deformity in frontal plane.

Measurements of vertebral rotation at the scoliotic apex have been performed with plain radiography using different methods. The most commonly used method for this purpose is Perdriolle's method [64], which is performed by aligning a torsionmeter with the lateral border of the vertebral body at scoliotic apex. The vertebral rotation is the angle between that line and the line bisecting the pedicle contour on the convex side of the scoliotic curve. However, the major limitations of this method are that it enables measurement of vertebral rotation only at the scoliotic apex and in rotation deformity  $\leq 40^\circ$  [1].

#### *Computed tomography:*

The continuous development and improvement of the corrective methods and implementation of new implants in particular the concept of "all-pedicle screw construct" introduced by Suk 1994 [65], make it necessary to obtain a detailed anatomical map of the thoracic and lumbar spine, enabling measurement of the degree of vertebral rotation before surgery, pedicular width before surgery and the degree of derotation achieved by surgery. As pedicle screw insertion in spinal fixation is associated with 1.3 % risk for neurovascular complication [66] screw placement should be assessed after surgery. CT has increasingly been used in the workup of patients with AIS before and after posterior scoliosis surgery as such information cannot be obtained from plain radiographs. Moreover CT is a more accurate method in the evaluation of screw placement than plain radiography [67-69]. Two series using CT in the assessment of screw placement showed 10 times as many violations of pedicular cortex as did plain radiography [70, 71].

By enabling measurement of the degree of vertebral rotation before surgery CT helps to determine the transverse screw angle (TSA) which is the angle between a line drawn through the middle of the vertebral body and the line drawn through the middle of the pedicle (in axial projection). The TSA finally determines the screw tract; therefore a preoperative measurement of the degree of vertebral rotation provides the information necessary for correct insertion of the pedicle screws at different vertebral levels. Besides helping the surgeon with correct screw insertion, knowledge of the degree of vertebral rotation is an indicator of curve

progression and subsequently a predictive factor for the overall prognosis of this spinal deformity [64, 72]. Furthermore, the spinal surgeon needs information about the pedicular width often of up to 15 vertebral levels, in order to plan the suitable size of screws at various vertebral levels. CT has also the advantage of providing better information about the morphology of spine and thereby enables the detection of possible underlying pathology such as vertebral anomalies, spinal dysraphism, dural ectasia etc. However, such information can be obtained using magnetic resonance imaging (MRI).

The role of MRI in the investigation of scoliosis especially in the presence of suspected spinal cord abnormalities and in atypical scoliosis has been extensively reviewed [73-76]. Some of the drawbacks of MRI are its lesser availability, longer examination time, longer interpretation time and higher cost. Yet an important issue in the postoperative follow up of patients who underwent posterior correction and stabilization using “all-pedicle screw construct” is the assessment of the accuracy of pedicle screw placement. The extensive susceptibility artifacts caused by the implants might make the assessment of hardware status after surgery impossible with MRI. Furthermore the measurement of the degree of vertebral rotation is performed on the axial images and thus, in the MRI, demands repeated axial sequences to cover the whole region of interest, which further lengthens the MRI examination time. Of course the major drawback of CT is the exposure to ionizing radiation.

#### *The role of CT in the postoperative assessment:*

As mentioned above scoliosis surgery has undergone rapid and continuous development with the introduction of new operative techniques and new implants. The extensive instrumentation with pedicle screws including thoracic vertebrae, nowadays known as “all-pedicle screw construct” [65] is considered revolutionary. However, the use of pedicle screws, in particular in the thoracic region, is potentially dangerous because of the risk for neurovascular complications when screws are misplaced. Thus a reliable postoperative assessment of pedicle screw placement becomes increasingly necessary. Plain radiography and CT have been used for this purpose. Plain radiography has its limitations [77-79] and in two series it was shown that CT was superior to plain radiography in the evaluation of screw placement [70, 71]. Several studies have also shown that CT is an accurate tool in the assessment of pedicle screws [68, 80]. Assessment of pedicle screw placement with CT has been extensively studied in cadaver spines [69, 80-82]. These studies have shown that CT is a suitable tool in the assessment of pedicle

screw placement that is why CT today has become widely used in the postoperative evaluation of spinal fixation with pedicle screws. In most of the reports of assessment of pedicle screw placement with CT, there is little knowledge, if any, about the radiation dose received during such examinations which often include the majority of the thoracic and lumbar spine. Besides providing the opportunity of safe and reliable assessment of hardware status after surgery, CT of the spine enables measurement of the degree of vertebral derotation achieved by surgery.

### Natural history, curve progression and treatment of AIS

Treatment of AIS is closely related to the risk of curve progression. In general, AIS curves progress in two ways: (1) during the rapid growth period in the adolescence, and (2) into adulthood if the curve is relatively large [83]. Since scoliotic deformity increases during the rapid pubertal growth, the potential for growth is evaluated taking into consideration the patient's age, menstrual status in female patients and the radiographic parameters. In general, girls grow until 14 years of age, while boys grow until 16 years of age. Girls grow very rapidly until their first menstrual period, and then their growth generally slows down. However, they continue to grow until 2 years after their first menstrual period. Radiographs of the spine and pelvis are also used to determine growth. The Risser grading system is often used to determine a child's skeletal maturity (how much growth is left) on the pelvis, which correlates with spinal growth [84]. The Risser grading system rates the skeletal maturity of a child on a scale of 0–5. Patients with Risser scale 4–5 have stopped growing. Large curves are also more likely to progress or worsen. Curves greater than 45° in patients who are growing, or curves greater than 50° in patients who have arrested growth will continue to progress slowly over time. Osteopenia [46] and platelet abnormalities [47] have been suggested to have some prognostic value. Measurements of rib vertebral angle difference (RVAD: is the difference between the rib vertebral angle on the concave and convex sides of the curve) at the scoliotic apex have showed that 80 % of patients with RVAD exceeding 20° continued to progress [85]. The probability of progression of scoliotic curve with different degrees of severity and in different age groups is shown in Table 2.

Treatment of adolescent idiopathic scoliosis falls into three main categories: observation, bracing, and surgery. Patients who are still growing and with curves less than 25° as well as patients who have completed their growth and with curves less than 50° are usually treated by observation and regular follow-up of their

Cobb angle	The probability of curve progression			<b>Table 2:</b> The probability of curve progression. The given degree of scoliosis represents the degree of deformity at presentation. Data compiled from [26].
	10-12 years	13 years	15-16 years	
<19°	25 %	10 %	0 %	
20-29°	60 %	40 %	10 %	
30-59°	90 %	70 %	30 %	
>60°	100 %	90 %	70 %	

Coob angle [83]. Bracing is usually used for patients with curves that measure between 25° and 40° during their growth phase with the aim to prevent curve progression. Even if slight curve progression occurs despite wearing the brace, surgical treatment is not necessary as long as the curve remains below 45° at the end of growth [83].

### Surgical treatment of scoliosis: historical perspective and treatment alternatives

Ancient Hindu religious literature from about 3500-1800 BC and Hippocrates (400 BC) [86] described scoliosis treatment which was focused primarily on spinal manipulation and traction. Similar procedures were described in Arabic and Chinese literature [87]. Another important tool in the treatment of scoliosis was the plaster body jacket (i.e. body cast). The American orthopedic surgeon Lewis Sayre popularized its use in the mid 1800s [88]. Posterior spinal fusion was performed in the early 1900s. Russell Hibbs performed his first fusion operation for tuberculous spinal deformity in 1911 and in 1914 he applied this technique in the treatment of patients with scoliosis [89]. The technique is very similar to the non-instrumented fusion used today. Hibbs approach focused on achieving maximum deformity correction via a variety of plaster jackets before surgery. By 1941, such spinal fusion operations for idiopathic scoliosis were common enough that Shands et al [90] could report assessment of more than 400 cases operated with Hibbs-type fusion. Supplemental bone grafts (often from the tibia) was used by most of the surgeons.

Dr. Paul Harrington in Houston, Texas, began in 1953 to develop his instrumentation and in 1958 he put forward what is today known as the Harrington rod system [91]. Dr. Eduardo Luque developed a similar rod system in 1976. The Luque rod system consisted of long, L-shaped, flexible and contourable cylindrical rods. The rods were affixed to the spine by using sublaminar wires at multiple segments along its length [92]. Cotrel-Dubousset instrumentation was introduced in 1984 used rods and hooks at either side in a cross-linked pattern to realign the



spine and redistribute the biomechanical stress [93]. In 1980s Roy-Camille used pedicle screws together with plate in spinal fixation [94, 95]. Dwyer was the first to perform anterior correction of scoliosis in 1964 using screws and wires [96]. In 1975 Zielke introduced ventral derotation spinal fusion with vertebral screws, threaded pins, and nuts. The derotation maneuver was intended to prevent the instruments from causing kyphotic deformation in the sagittal plane [87, 97]. In 1991 Kaneda developed a system for the anterior corrective surgery based on the same principle but sturdier than its predecessor [98]. A newer and more rigid construct in spinal surgery was established by the use of pedicle screw-assisted instrumentation, originally described by Michele and Krueger in 1949 [99]. In European countries Roy-Camille has played a significant role in pioneering and popularizing the use of pedicle screws with clinical success, especially in the treatment of spinal injuries [100]. Luque introduced the use of pedicle screws in scoliotic surgery in 1986 [101]. During the late 1980s Suk gradually extended the use of the pedicle screws in scoliotic correction and stabilization. The so called “all-pedicle screw construct” or “pedicle screw-only construct”, which has been introduced by Suk in 1994, has successively gained an increasing popularity in scoliotic surgery and is nowadays widely used in the posterior correction and stabilization of scoliosis [65, 102].

The major goal of the surgical treatment of scoliosis is to stop further progression of the scoliotic deformity and when possible to establish an adequate correction and solid fusion. Modern instrumentation enables good correction of the deformity in coronal plane. Whether this instrumentation achieves reasonable derotation is a matter of debate as reports have shown that derotation in the instrumented portions of the spine possibly occurred at the expense of creation of new rotation in the non-instrumented portion of the spine [103]. However, Suk has reported a 59 % reduction of vertebral rotation following segmental pedicle screw fixation [102]. Lenke et al have shown that modern instrumentation achieved little or no correction of rib hump in patients with scoliosis [104].

## The issue of ionizing radiation

Medical sources of ionizing radiation have increased in the last years. Although the radiation exposure in diagnostic imaging is much less than that in radiation therapy, the increasing use of CT has contributed to the increase of the radiation load to the general population. In the beginning of the 1990s CT constituted about 2-3% of all radiological examinations [105] and contributed to about 20-30% of the total radiation load from medical use of ionizing radiation [106]. Later reports have increased the latter figure to about 50% [107, 108]. In Sweden the number of CT-examinations per/1000 inhabitant has increased more than 3 times between 1991 and 2005 (22 in 1991, 39 in 1995 and 72 in 2005) [109]. CT contributed to 58 % of the total radiation dose to the patients in 2005 [109].

Performing a whole spine CT examination according to protocols available in daily clinical practice, that are aimed for morphological evaluation of the spine, workup of trauma, and investigation of different spinal pathology means exposing these young individuals to high radiation doses. Especially vulnerable organs are breasts, genital organs, thyroid glands, and erythropoietic bone marrow.

The biological effects of ionizing radiation on living cells may result in one of the following: (a) cells experience DNA damage but are able to detect and repair that damage, (b) cells experience DNA damage but are unable to repair the damage and go through the process of programmed cell death (apoptosis), or (c) cells experience a non-lethal DNA mutation that is passed on to subsequent cell divisions. This mutation may contribute to the induction of cancer. Whether or not radiation doses at levels delivered by CT produce cancer remains a controversial topic. However, an agreement seems to exist about the fact that radiation exposure is a greater concern in the pediatric population. There is strong support for a linear, non-threshold model of radiation dose in which any radiation dose is thought to increase the risk of developing cancer [110]. On the other hand, others believe in the concept of hormesis and argue that low doses of radiation are harmless or may actually be therapeutic (e.g. stimulate the immune system) [111]. Malignant neoplasias associated with high dose exposure include leukemia, thyroid, breast, bladder, colon, liver, lung, esophagus, ovarian, stomach cancers, and multiple myeloma [112].

It has been estimated that a dose of 0.01 Gy (10 mGy) to the breast of a woman younger than 35 years of age increases her risk to develop breast cancer by approximately 14% over the expected spontaneous rate for the general population [113]. Brenner et al [114] estimated a lifetime cancer mortality risk attributed to a single CT (with relatively high dose) to be 0.18 % for an abdomen-pelvis CT and

0.07% for a head CT performed in a 1-year-old child. The estimated risk for radiation-induced lethal cancer in a normal population amounts to 5 % per Sievert (Sv) [115]. However, this risk has an inverse relation to the patient's age with higher risk in younger individuals. The risk for patients aged 10-30 years, which is usually the age of presentation and follow-up of patients with AIS amounts to 8-10 % per Sievert [115]. In the United States, 600 000 abdominal- and head CT examinations are performed annually in children under the age of 15 years. A rough estimate is that 500 of these individuals might ultimately die from cancer attributable to the CT radiation [114]. In scoliosis the risk of development of breast cancer is well studied and in one study breast cancer was reported in 11 out of 1030 women with scoliosis followed for 26 years [116]. In another study 77 breast cancer deaths were reported among 5466 patients with scoliosis subjected to an average of 24.7 diagnostic radiographs. The risk of developing a lethal cancer showed to increase significantly with increasing the number of radiographs and with the cumulative radiation dose [117].

### Image quality in CT

While image quality has always been a concern for the physicists, clinically adequate image quality nowadays is an acceptable concept (for physicists and radiologists) especially to pediatric patients. Beside the radiation dose there are other determinants of image quality in CT namely: image noise, slice thickness, high contrast resolution, low contrast resolution, clinical question at issue and the evaluating observer.

*Image noise:* Is the standard deviation of voxel values in a homogenous (typically water) phantom. Image noise is influenced by a large number of parameters: Tube voltage, tube current, scan time, slice collimation, reconstructed slice thickness, reconstruction algorithm or filter, pitch factor, helical interpolation algorithm as well as detector efficiency.

*Slice thickness:* The reconstructed slice thickness is influenced by slice collimation, detector width, pitch factor and helical interpolation algorithm. Unlike single detector CT, the slice thickness in multidetector-CT is independent of table speed (feed) because of the ability to interpolate data collected from multiple detectors and because of availability of different interpolation algorithms [118].

*Spatial resolution (high contrast resolution):* Is a measure of the smallest area identifiable on an image as a discrete separate unit. High contrast spatial resolution is influenced by: pixel size, mathematical reconstruction filter (kernel) and the geometric resolution limits of the CT-system e.g. detector width and ray sampling.

*Low contrast resolution:* In CT the low contrast resolution is often determined using objects having a very small difference from the background (typically from 4-10 HU difference). In this case, because the signal (the difference between object and background) is so small, noise is a significant factor. Low contrast resolution is influenced by the same factors that affect the image noise as well as by window and centre settings. In addition monitor or film calibration has some influence on the low contrast resolution.

*Clinical question at issue:* The images produced by any radiological examination should be adequate to show or to rule out pathology in question. ALARA principle (as low as reasonably achievable) which is a well known principle in plain radiography also is applicable in CT. Working with this principle every individual CT-examination should be designed and the radiation exposure parameters should be adjusted to produce images of adequate diagnostic quality.

*The evaluating observer:* The subjective evaluation of image quality depends on individual preferences, which in turn depends on the experience of the reader (i.e. training) in addition to institutional, national, and medical organizational guidelines [119].

## Optimization and implementation of low-dose CT in the perioperative workup of AIS

The major aim of the optimization of image quality in CT for patients with AIS examined perioperatively was to provide the clinician with information important for the planning of surgery and for quality control of the outcome of scoliosis surgery. The optimization process has meant tradeoffs between image quality and radiation doses. The present availability of multislice scanners (MSCT/MDCT) and the possibility of reducing and individually adjusting the radiation dose by using different dose reduction modulations make it possible to reduce the radiation doses and to tailor a low radiation dose protocol which provides 3D-information of relevant segments of the thoracic and lumbar spine. In the here used CT-system (Siemens AG, Forchheim, Germany) the dose reduction system (DRS) called CareDose 4D, enables angular and longitudinal tube current modulation [120], with the aim to automatically adapt the tube current to the patient's anatomical configuration and the patient's size together with an on-line controlled tube current modulation for each tube rotation [121].

Before implementing the CT as routine method in the perioperative workup of scoliosis, optimization of radiation dose should be considered mandatory. For this purpose a phantom study has been conducted in our institution using an

anthropomorphic phantom (**paper I**). Afterwards the evaluation of the radiation doses and the image quality was performed in different patient groups before and after surgery (**paper II**). Similarly the impact of dose reduction on image quality has been studied in the postoperative examinations as it is well known that surgical metal implants cause disturbing artifacts and possibly make the postoperative assessment of screw placement impossible. A reliability analysis has been conducted to assess the reliability of low-dose CT in such assessments (**paper III**). When the method was considered as reliable, the low-dose CT was then used to assess the accuracy of pedicle screw insertion (**paper IV**).

To my knowledge, there have been no in vivo studies using low-dose spine CT in the preoperative planning of corrective scoliosis surgery (**paper II**), nor studies evaluating the interobserver and intraobserver reliability of low-dose spine CT in the assessment of pedicle screw placement (**paper III**). The use of low-dose spine CT in the assessment of the radiological outcome of screw placement after posterior scoliosis surgery using the titanium-alloy “all pedicle screw construct” (**paper IV**) is also the first report of its kind in the literature.

### **Paper I**

- To compare the radiation dose of low-dose CT of spine with that of some of the CT protocols that are routinely used in clinical practice, before implementing this low-dose CT in clinical routine.
- To assess the impact of this optimal dose reduction on image quality.
- To optimize the level of the radiation dose that still allows safe and reliable assessment of the required parameters such as the measurement of pedicular width.

### **Paper II**

- To measure the radiation dose of the low-dose spine CT in patients with AIS and compare it with that of standard CT for trauma (a protocol used for the chest and abdomen examination after trauma) as well as with that of the CT protocol previously used for the examination of patients with AIS (ANV-protocol).
- To find out if the radiation dose could be held as low as that in the phantom study.
- To evaluate the impact of the dose reduction on image quality and reliability of these images with respect to answering the clinical questions at issue.

### **Paper III**

- To evaluate the image quality of the low-dose spine CT in patients with AIS subjected to posterior corrective surgery using a titanium-alloy “all-pedicle screw construct” for correction and stabilization.
- To analyze the reliability of these images to assess the screw placement using a new grading system.

### **Paper IV**

- To assess the pedicle screw placement in patients with AIS operated upon with posterior correction and stabilisation, using the low-dose spine CT.
- To comprehensively evaluate the relationship of misplaced screws to the surrounding structures.
- To evaluate the clinical outcome in patients with misplaced pedicle screws.



## Materials and methods

All CT-examinations included in this thesis were performed on a 16-slice CT-scanner (SOMATOM Sensation 16, Siemens AG Forchheim Germany). The examinations in **paper II-IV** were performed according to the low-dose CT-protocol. The examination protocol was decided to be that recommended in the phantom study (**paper I**) with the following scan parameters: Slice collimation 16x0.75 mm, rotation time 0.75 s, pitch 1.5, tube voltage 80 kV and quality reference for the effective tube current-time product 25 mAs. Axial images, 3 mm and 1 mm thick with skeletal and soft tissue algorithm, were available for the analysis. The slice collimation of 0.75 mm allows obtaining 2 mm thick coronal and sagittal reformatted images. 3D-reconstruction was also a possible and available post-processing option that was often performed after the preoperative examinations. The Dose reduction system (DRS) (CareDose 4D, Siemens AG, Forchheim, Germany) available in the scanner was automatically activated in all examination included in the studies (**paper II-IV**). This type of DRS is an automatic exposure control based on axial as well as angular tube current modulation [121].

### Paper I

#### *The study phantom:*

An anthropomorphic adult chest phantom (PBU-X-21; Kyoto Kagaku CO, Ltd, Kyoto, Japan) was used for the purpose of radiation dose optimization, Figure 4. The phantom consists of substitute materials for human soft tissues such as muscles whereas the bones are simulated by epoxy resins and calcium hydroxyapatite to achieve changes in contrast in the phantom images similar to those in the human body.



**Figure 4:** The study phantom.



The phantom was examined with stepwise reduction of the radiation dose, primarily by manipulating the different scan parameters. The scans parameters of different scans reported in this study are shown in Table 3. However, several scan settings were tested during the optimization process. See Appendix 3 and 4.

#### *Scan parameters:*

**Scan 1:** CT spine protocol recommended by the manufacturer for investigation of different spinal pathology in adults [122].

**Scan 2:** CT spine protocol recommended by the manufacturer for investigation of different spinal pathologies in children, with a fixed tube voltage of 120 Kv and a tube current-time product depending on the body weight. In this study the tube current-time product was 140 mAs (130 mAs recommended by the manufacturer for patients with body weight of 35-44 kg) [122].

**Scan 3:** “Apical Neutral Vertebra” CT-protocol (ANV-protocol). Before the era of multislice-CT this protocol, also called KASS-protocol, had been used in our institution to measure the degree of vertebral rotation prior to the planned corrective surgery and to measure the degree and derotation after surgery. It consists of four sequential slices of the apical vertebra (at the scoliotic apex), four slices at the upper end vertebra and four slices at the lower end vertebra (appendix 1). Only 1.2 cm of each of the three vertebral bodies has been scanned.

	Slice collimation, mm	Rotation time, sec	Pitch factor	Tube voltage, Kv	Effective tube current-time product, effective mAs
Scan 1	16x0.75*	0.75	0.75	120	300
Scan 2	16x0.75*	0.75	0.75	120	140
Scan 3	12x1.5	1	1	120	60
Scan 4	16x0.75	0.75	1.5	80	25
Scan 5	<b>16x0.75</b>	<b>0.75</b>	<b>1.5</b>	<b>80</b>	<b>25/19</b>
Scan 6	16x0.75	0.5	1.5	80	17

**Table 3:** Scan parameters of all scans reported in the phantom study (**Paper I**). The values written in bold represent the scan parameters of the low-dose CT protocol. The tube current-time product shown in column 6 (scan 5, taking advantage of DRS) is expressed as IQR mAs/eff mAs, respectively. IQR mAs is the image quality reference mAs whereas eff mAs is the effective mAs. (\*) Minor modification from the manufacturer protocol (16x1.5 mm recommended by Siemens). The pitch factor is however almost the same as the manufacturer’s recommendation.

**Scan 4:** The low-dose helical CT protocol before applying the DRS.

**Scan 5:** The low-dose helical CT protocol taking advantage of the DRS (*the here proposed low-dose CT protocol*).

**Scan 6:** Helical CT protocol with the maximum possible reduction of tube voltage and tube current in our CT system.

For all helical scans, i.e. except scans 3, the scan length was 36.5 cm. The number of vertebrae included in these scans was 15.

#### *Estimation of the radiation dose:*

1. **Calculation of the effective dose:** The effective mAs value was recorded for scan 5, i.e. scan with activated DRS. The volume CTDI ( $CTDI_{vol}$ ) which is a derivative of the computed tomography dose index (CTDI) and the dose length product (DLP) were recorded for every individual scan included in this study. The effective dose (E) was determined. The effective dose is calculated from values of DLP for an examination using appropriate conversion factors and according to the following equation:

$$E = E_{DLP} \cdot DLP \text{ (mSv)}$$

where  $E_{DLP}$  is the region-specific conversion factor. General values of the conversion factor appropriate to different anatomical regions of the patient (head, neck, chest, abdomen, pelvis) were taken from the European commission 2004 CT Quality Criteria, Appendix A-MSCT Dosimetry [108], Table 4. The conversion factor used in this study was 0.018 (average of 0.019 for the chest and 0.017 for the abdomen).

2. **The effective doses** obtained from calculation of the data from this phantom study were compared with the effective doses calculated by using the Monte Carlo simulation program WINDOSE 3.0 (Scanditronix Wellhöfer, GmbH; Germany).

3. **The absorbed dose to the breasts and genital organs** were calculated using the Monte Carlo simulation program WINDOSE 3.0.

Body region	Conversion factor
Head	0.0023
Neck	0.0054
Chest	0.019
Abdomen	0.017
Pelvis	0.017
Legs	0.0008

**Table 4:** Conversion factor used for calculation of the effective dose (European commission 2004 CT Quality Criteria, Appendix A-MSCT Dosimetry) [108].

4. **Normalization of the radiation dose** obtained from this adult phantom to phantom of four different age groups was performed using the data from the National Radiological Protection Board (NRPB) SP250 [123].

#### *Evaluation of image quality:*

1. **Measurement of the signal-to-noise ratio (SNR):** SNR was estimated at the same level of the vertebral column (L1) for every single scan, using 1 cm large region of interest (ROI).

2. **Subjective evaluation of image quality** was performed by two readers. All scans were read independently by two senior radiologists who were blinded to scan parameters, with the aim to evaluate: (a) the ability of the images to visualize the vertebral pedicles at different segments of the vertebral column and (b) the possibility of measuring the width of the pedicles. The readers were asked to grade the degree of evaluation reliability in every single scan as: reliable, relatively reliable, or unreliable.

3. **Objective evaluation of the impact of dose reduction on image quality:** Axial 3 mm thick reformatted images from scan 1 (the highest radiation dose tested), from scan 5 (the here proposed low-dose CT protocol) and from scan 6 (the lowest possible radiation dose in our CT system) were blinded to all information related to scan parameters and sent to the Picture Archiving and Communication System (PACS, Agfa IMPAX). The objective evaluation of the impact of dose reduction on image quality has been limited to the measurement of the pedicular width. Two independent observers have performed measurements of pedicular width of 28 pedicles (14 vertebrae in each of these 3 scans; a total of 84 pedicular width measurements per observer and occasion). The same measurements were performed by one observer at two different occasions with one-week interval.

## **Paper II**

### *Patients:*

To the date of analysis 81 patients with AIS had been examined with a low-dose spine CT. Seventy-one patients (88%) have given their consent to have their images retrospectively evaluated and were included in this analysis of a total of 113 consecutive low-dose spine CT. The remaining 10 patients did not reply to the send letter including information about the study and a request to approve the retrospective analysis of their images. Out of 71 patients included in the analysis, 42 had been examined both pre- and postoperatively while the remaining 29

patients had been examined either preoperatively or postoperatively with this low-dose spine CT. Fifty-four patients (76%) were female and 17 patients (24%) were male. The mean and the median value of patient's age were 17 and 16 years respectively (range 12-32 years).

The examinations included in this analysis have been categorized into the following groups, in order to enable comparison between these groups:

Group 1: All examinations with low-dose spine CT (n=113).

Group 2: Preoperative examinations with low-dose spine CT (n=50).

Group 3: Postoperative examinations with low-dose spine CT (CT scan after posterior surgical correction, n=46).

Group 4: Postoperative examinations with low-dose spine CT (CT scan after anterior surgical correction, n=17).

Group 5: CT scan according to the so called ANV-protocol (n=15).

Group 6: Trauma CT of patients in the same age group as patients with AIS (n=127)

#### *Evaluation of the radiation dose:*

All trauma CT performed in our institution during 2007 on patients of the same age group as the patients with AIS, were evaluated with regard to the radiation dose. A total of 127 trauma CT performed in the age group of 13-32 years, were evaluated. The scan parameters for the trauma CT are shown in Table 6. Further comparison was done with the radiation dose of the CT scan according to the previously used ANV-protocol that provided only four sequential images at three vertebral levels. A total of 15 randomly chosen CT examinations according to ANV-protocol were evaluated. The scan parameters for the CT according to ANV protocol were those used in phantom study (Tables 3 and 6). The dosimetric evaluation was the same as that in the phantom study.

#### *Evaluation of the impact of dose reduction on image quality:*

The impact of dose reduction on image quality in examinations according to low-dose spine CT was evaluated objectively and subjectively. For comparison the evaluation of image quality of 15 randomly chosen CT-examinations according to ANV-protocol was performed. In contrary to trauma CT, this latter group of examinations has the advantage that it includes patients with scoliosis of the same age group, enabling a comparable evaluation of different indicators of image quality e.g. vertebral rotation.

**(A) Subjective evaluation of image quality:** All examinations were read independently by one senior radiologist at one occasion and by another senior radiologist at two different occasions (with a 6-week interval) with the aim to evaluate the reliability of the images to:

(i) Identify and clearly delineate the vertebral bodies and the pedicles at different segments of the vertebral column.

(ii) Measure the width of the pedicles.

(iii) Measure the degree of vertebral rotation.

The readers were asked to grade the degree of reliability in each single examination as: reliable, relatively reliable, or unreliable.

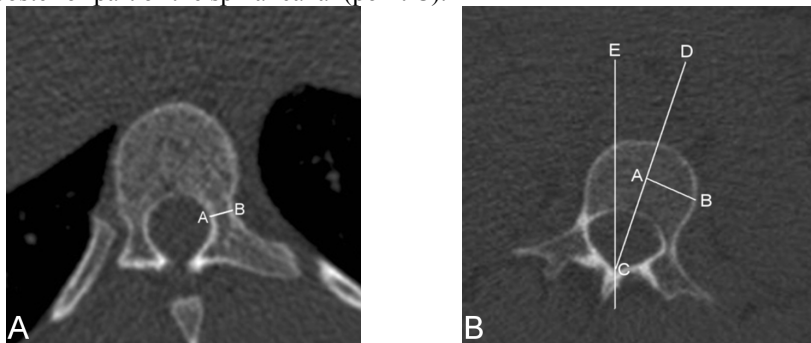
**(B) Objective evaluation of image quality:** The following parameters were measured/evaluated:

(i) *Measurement of pedicular width:* The width of both pedicles at the scoliotic apex was measured (Figure 5A). A total of 226 pedicular width measurements were performed on examinations with low-dose spine CT and 30 such measurements on CT examinations according to ANV-protocol.

(ii) *Measurement of degree of vertebral rotation:* Vertebral rotation was measured at the apical-, the upper end- and the lower end vertebrae. In patients with S-formed scoliosis five measurements were done: two at the apical vertebrae, one at the upper end vertebra, one at the lower end vertebra, and one at the neutral vertebra. The level of these vertebrae were predetermined on previously obtained plain radiographs taken in standing position, which were performed for measurement of Cobb angle as part of the routine radiological workup. The vertebral rotation was measured according to the method developed by Aaro and Dahlborn [67], (Figure 5B). A total of 367 measurements of the degree of vertebral rotation were performed on low-dose spine CTs (3 per examination in 99 CTs and 5 per examination in 14 CTs where the patients had S-formed scoliosis with double curve) and 45 such measurements were performed on the 15 CT examinations according to ANV-protocol.

(iii) *Evaluation of hardware status:* The subjects of this analysis were patients operated on with posterior surgical correction and fixation with “all-pedicle screw construct” (group 3; 46 examinations). The status of a total of 809 pedicle screws was evaluated. The readers were asked to grade the screw placement as *normal placement* when the screw was enclosed within the pedicle or minimally violated the pedicular cortex; or *misplacement* when more than half of the screw diameter violated the pedicular cortex.

**Figure 5:** Figure A-B: Axial images obtained with a low-dose spine CT. In Figure A, the pedicular width is defined as the distance between point A and B. In Figure B, A–B represents the line between the outer cortex and the middle of the vertebral body. C–D is the line drawn through the middle of the vertebral body to the middle of the most posterior part of the spinal canal and C–E is the line drawn through the sagittal plane. The degree of vertebral rotation is defined as the angle where the lines C–D and C–E meet at the most posterior part of the spinal canal (point C).



(iv) *Measurement of signal-to-noise ratio (SNR):* SNR was measured on 200 haphazardly chosen images in 35 haphazardly chosen examinations with low-dose spine CT. Fifty such measurements were done on CT according to ANV-protocol and 100 measurements on images from trauma CT.

### Paper III

#### *Patients:*

This is a retrospective analysis of low-dose CT of 46 patients with AIS who have undergone posterior corrective surgery. Thirty-six patients (78%) were female and ten patients (22%) were male with a mean and median age of 16.9 and 16 years respectively at the time of surgery (range 12-32 years). The patient who was 32 years old at the time of surgery had the disease onset at the pubertal age. A total of 809 pedicle screws were analyzed, 642 screws (79%) were inserted in the thoracic spine and 167 screws (21%) were inserted in the lumbar spine.

#### *CT-examinations:*

The scan parameters of all CT-examinations were those recommended by a previous phantom study (**paper I**) [124] and also used in the patient study (**paper II**) [125].

### *New grading system for assessment of screw placement:*

In our institution we developed a new grading system (Figure 6) for the evaluation of screw placement, where the relationship of every individual screw to the corresponding pedicle, vertebral body, endplate, and neural foramen was evaluated with regard to:

#### **1. Medial cortical perforation (MCP):**

- a. Grade 0 when the pedicle screw passes totally within the pedicle medullary canal or with minimal breach of medial pedicular cortex ( $< 1/2$  of the screw diameter passes medial to the medial pedicular cortex).
- b. Grade 1 when the screw is partially medialised ( $> 1/2$  of the screw diameter passes medial to the medial pedicular cortex).
- c. Grade 2 when the screw is totally medialised (screw passes totally medial to the medial pedicular cortex).

#### **2. Lateral cortical perforation (LCP):**

- a. Grade 0 when the pedicle screw passes totally within the pedicle medullary canal or with minimal breach of the lateral pedicular cortex ( $< 1/2$  of the screw diameter passes lateral to the lateral pedicular cortex).
- b. Grade 1 when the screw is partially lateralised ( $> 1/2$  of the screw diameter passes lateral to the lateral pedicular cortex).
- c. Grade 2 when the screw is totally lateralised (screw passes totally lateral to the lateral pedicular cortex).

#### **3. Anterior cortical perforation (ACP):**

- a. Grade 0 when the screw is contained within the vertebral body.
- b. Grade 1 when the screw tip penetrates the anterior cortex of the corresponding vertebral body. The degree of penetration is reported in mm and the relationship to the surrounding structures is reported.

#### **4. Endplate perforation (EPP):**

- a. Grade 0 when the screw tip is contained within the vertebral body.
- b. Grade 1 when the screw tip penetrates the upper or the lower endplate into the adjacent disc space.

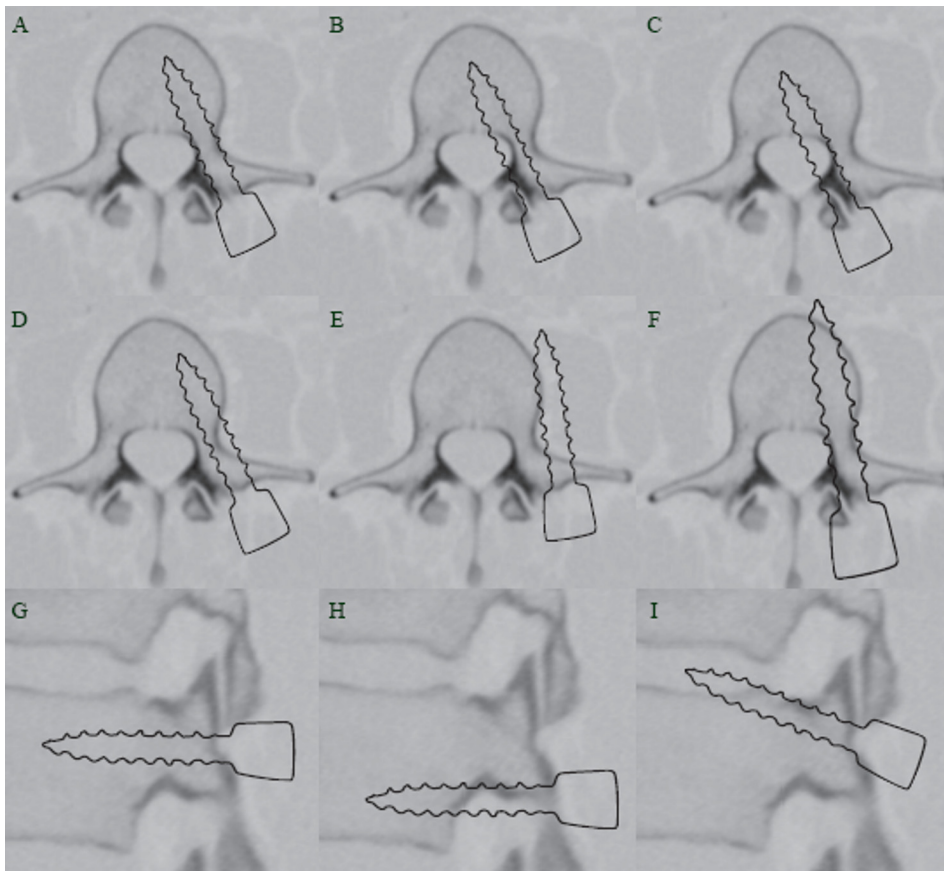
#### **5. Foraminal perforation (FP):**

- a. Grade 0 when the screw passes through the pedicle.
- b. Grade 1 when the screw penetrates the pedicle border into the overlying or underlying neural foramen.

All examinations included in the analysis were read independently by two senior radiologists and one of them repeated the evaluation at another occasion with a 6-

week interval. Subjective and objective analyses of image quality were performed with the two observers being asked to:

1. Grade the overall reliability of the images in every single scan as: reliable, relatively reliable, or unreliable.
2. Evaluate the placement of the pedicle screws. The observers were asked to classify the screw placement into acceptable placement, or misplacement regardless the type of misplacement.
3. Explore the reliability of the low-dose CT to differentiate between screws with acceptable placement, screws with partial cortical perforation, and screws with total cortical perforation. Screws with grade 1 MCP and grade 1 LCP were



**Figure 6:** Different types of misplacement according to the here proposed grading system. (A–F) axial images and (G–I) sagittal images. A: Acceptably placed pedicle screw. B: MCP grade 1. C: MCP grade 2. D: LCP grade 1. E: LCP grade 2. F: ACP. G: Acceptably placed pedicle screw on a sagittal image with no FR or EPP. H: FP. Perforation into the underlying neural foramen. I: EPP. Perforation through the upper endplate.



regarded as screws with partial cortical perforation. Screws with grade 2 MCP, grade 2 LCP as well as screws with ACP, EPP and FP were regarded as screws with total cortical perforation.

4. Perform a detailed analysis of reliability of low-dose CT in grading of all types of misplacement according to the new grading system.

## **Paper IV**

### *Patients:*

To the date of analysis a total of 49 patients with AIS who had undergone posterior corrective surgery and stabilization with titanium “all-pedicle screw construct” have given their consent to be included in this retrospective analysis. The CT examinations were performed with low-dose spine CT 6 weeks after surgery. Thirty-eight patients (78%) were female and 11 patients (22%) were male. The mean and the median value of patient age were  $16.8 \pm 4.2$  (mean  $\pm$ SD) and 16 years.

### *CT-examinations:*

All CT-examinations were performed according to the protocol recommended by the phantom study (**paper I**) [124] and used in the patient study (**paper II**) [125]. To minimize the streak artifacts from the implants reformatted 1-mm thick axial images with soft tissue algorithm and 2-mm thick coronal and sagittal reformatted images with the same soft tissue algorithm have been used for the analysis. Images with skeletal algorithm were also available to the readers.

### *Assessment of screw placement:*

The placement of 873 screws was assessed using our new grading system described in methods in **paper III**. All examinations included in the analysis were read independently by two senior radiologists (KAK, AS) of whom one (KAK) performed the analysis at two different occasions with a 6-week interval. Because the evaluations were done by two different readers and totally at three different occasions, three possible types of interpretation of the screw position status occurred: (1) Screws where both readers totally agreed upon their position, i.e. the placement status was evaluated exactly the same at all three occasions, (2) screws where the two readers agreed upon their position at least on two occasions, and (3) screws where the two readers disagreed about their position. Screws of the latter group were subjected to a joint evaluation by both readers to reach a consensus

about the status of the screw placement. Status of those screws in which no agreement could be reached at the joint evaluation was regarded as questionable.

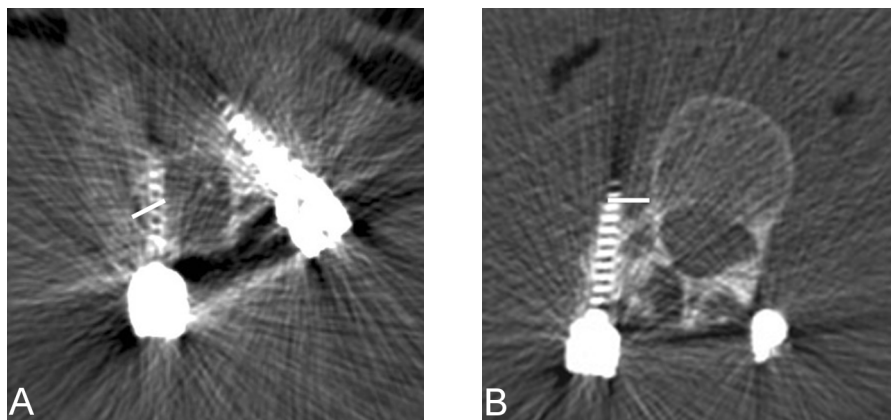
A detailed analysis of the misplaced screws was performed and the relationship of every individual screw to the following structures was studied:

- (a) Concavity or convexity of the scoliotic curve.
- (b) Apex of the curve.
- (c) Surrounding bony structures: lateral and medial pedicular cortex, vertebral body as well as pedicle rib unit (PRU). See Appendix 5.
- (d) Aorta.

The degree of encroachment in the spinal canal was measured in millimeters in case of medially placed pedicle screws. The encroachment was defined as the distance between medial pedicular cortex and the medial border of the medially placed screw (Figure 7A). The distance between the laterally placed pedicle screws and the lateral border of vertebral body was also measured and reported in millimeters (Figure 7B).

#### *Analysis of clinical outcome:*

An outcome-based analysis of the screw placement was performed and the medical records of all patients with total perforation of pedicular cortex were scrutinized. The intraoperative course of events, the medical status in the



**Figure 7:** (A) CT-axial image showing the way of measurement of the degree of encroachment of a medially placed pedicle screw. (B) CT-axial image of another patient with LCP grade 2 with paravertebral passage of pedicle screw which was supposed to pass through the right pedicle of L2. The image shows the way of measurement of the degree of the paravertebral location of the screw.

immediate postoperative period as well as at the out-patient follow-up 8 weeks after surgery was evaluated with respect to the occurrence of symptoms and signs of neurovascular complication that could be related to screw misplacement. At the 8-week follow-up visit all patients were asked about any history of new neurological symptoms related to spinal cord or nerve root compromise with specific questions about the occurrence of pain (local or radicular), numbness, paraesthesia, extremity weakness, muscle spasm, sensory loss, as well as bowel and bladder problems. Muscle strength, gait, tendon reflexes and Babinski sign were examined. Sensory modalities for pain, fine touch, pressure, vibration sense and position sense were also tested. Evidence of myelopathy with increased reflexes, abnormal clonus and Babinski sign were specifically sought for.

### Operative technique:

All operations were performed according to a standardized technique through a posterior exposure. The entry points for screws were determined after identification of the bony landmarks. At each assumed entry point, a 3 cm long titanium bone marker with a diameter of 1 mm, was inserted approximately 3 mm deep. By means of a C-arm fluoroscopy in the AP view, the position as well as the degree of rotation was estimated. The position was considered as acceptable when having the marker as the bull's eye on the screen in the middle of the circle of the pedicle. An assistant made notes on the observations of position and the degree of angulation of each marker. When preparing the screw canal the assistant read, at each level, the previously estimated trajectory. The screw canal was prepared with a hand-driven drill, which was introduced stepwise having a constant feeling of bone resistance at the bottom. After drilling, a probe or "feeler" was used to palpate the bottom and borders of the screw canal. Thereafter, self-tapping transpedicular screws were sequentially introduced. After completion of screw insertion, a check of screw position was undertaken by means of the C-arm fluoroscopy in oblique views. Curve correction was performed by simple rod derotation as well as direct vertebral rotation (DVR) [126] when having only the concave rod in place. Prior to rod insertion, the facet joints were destructed, and before inserting the stabilizing convex rod, all posterior bony elements were decorticated. Only local bone grafts were used. All operations were performed under spinal cord monitoring by means of motor evoked potential (MEP).

## Statistical analysis

Statistical analysis was performed by means of SPSS (Originally, Statistical Package for the Social Sciences) version 15. In **paper I** twenty four paired sample t-tests were performed to explore the interobserver and intraobserver variations in measurements of pedicular width done on scan 1, 5 and 6 (Appendix 6). The level of statistical significance was set to  $\leq 0.01$ . The mean value for differences in measurements of pedicular width was expressed as the systematic error while the standard deviation of the aforementioned values was expressed as the random error. Regarding the subjective evaluation of dose reduction on image quality and objective evaluation of the screw placement in **paper II**, the degree of interobserver and intraobserver agreement has been evaluated by cross tabulation and calculation of kappa coefficient (Cohen's kappa, K value). To explore the interobserver and intraobserver variations in measurements of pedicular width and degree of vertebral rotation, paired sample t-tests were performed and the systematic and the random errors were estimated. Furthermore a reliability analysis was performed by calculating a two-way mixed model of intraclass correlation coefficient (ICC). Interpretation of the kappa coefficient was done according to the one proposed by Landis and Kock [127, 128] shown in Table 5. The interpretation of ICC was similar to that of kappa coefficient [129]. The degree of interobserver and intraobserver agreement in the assessment of accuracy of pedicle screw placement in **paper III** has been estimated by calculation of kappa coefficient (K values). In **paper IV** Chi-square test was performed to test the association between the screw misplacement with the following variables: (1) level of misplacement (thoracic or lumbar), (2) side of misplacement (right or left), (3) curve concavity or convexity, and (d) scoliotic apex. Statistical significance was set to  $< 0.05$ .

K values	Degree of agreement
<0	Poor
0-0.20	Slight
0.21-0.40	Fair
0.41-0.60	Moderate
0.61-0.80	Substantial
0.81-1.00	Almost perfect

**Table 5.** The interpretation of the kappa (K) value [127, 128].

## **Ethical considerations**

The results of our phantom study (**paper I**) were presented to the regional radiation protection committee which then approved the use of low-dose spine CT in clinical practice instead of the previously used CT scan according to ANV-protocol. The regional ethical committee approval to conduct the retrospective analysis of **paper II-IV** was obtained. The patients were provided with written general information about the study and their written consents were a prerequisite for inclusion in the analysis.

## Results

### Estimation of radiation doses

The results of measurements of  $CTDI_{vol}$ , DLP and the effective doses for scans 1-6 (phantom study) are shown in Table 2, Paper I [124]. The effective dose of the low-dose CT scan taking advantage of the DRS (Scan 5) was 0.38 mSv which was 44 times lower than that of scan 1 (16.6 mSv), 20 times lower than that of scan 2 (7.76 mSv) and 12% lower than that of the scan 3 i.e. ANV-protocol (0.43 mSv). Applying the DRS has lowered the effective dose by 19% (from 0.47 mSv in scan 4 to 0.38 mSv in scan 5). The calculated absorbed dose to the breasts and the genital organs in the CT protocol recommended by the manufacturer for investigation of spinal disease in children (scan 2) was 23 times and 32 times, respectively, higher than that of the low dose CT protocol (scan 5).

The radiation doses of the low-dose spine CT in patient study, trauma CT, and CT according to the ANV-protocol are shown in (Table 6). The mean value for the effective dose of the low-dose spine CT was  $0.37 \pm 0.10$  mSv (mean  $\pm$  SD) which

	Low-dose spine CT	Trauma CT	Sequential scan ANV-protocol
Slice collimation, mm	16x0.75	16x0.75	12x1.5
Rotation time, second	0.75	0.5	1
Pitch	1.5	1	1
Tube voltage, Kv	80	120	120
Effective tube current-time product, mAs	25	165	60
Effective mAs	$20.20 \pm 2.60$	$129 \pm 30$	$60 \pm 2.3$
$CTDI_{vol}$ , mGy	$0.53 \pm 0.06$	$10.12 \pm 2.31$	$13 \pm 0.17$
DLP, mGy.cm	$20.75 \pm 5.38$	$714 \pm 178$	24
Effective dose, mSv	$0.37 \pm 0.10$	$13.09 \pm 3.19$	0.43
Scan length, cm	$35.93 \pm 8.94$	$66.37 \pm 8.49$	3.6 totally, 1.2 per vertebra
Effective dose/cm scan length, mSv	0.01	0.20	0.12
Absorbed dose to the breasts, mGy	$0.47 \pm 0.31$	$3.99 \pm 6.67$	$1.30 \pm 0.31$
Absorbed dose to genital organs, mGy	$0.02 \pm 0.05$	$5.33 \pm 6.20$	$0.03 \pm 0.05$
Absorbed dose to thyroid glands, mGy	$0.39 \pm 0.34$	$8.65 \pm 7.03$	$0.18 \pm 0.34$
Signal to noise ratio (SNR)	1.03	2.53	1.80

**Table 6:** Scan parameters and the estimated radiation doses in patient study (Table 1, paper II).

was 35 times lower than that received by the patients examined with trauma CT ( $13.09 \pm 3.19$  mSv) and 14% lower than that received by the patients examined with CT according to the ANV-protocol (0.43 mSv). The effective dose per cm scan length was 0.01 mSv in the low-dose spine CT which was 20 and 12 times, lower than that of trauma CT and CT scan according to the ANV-protocol, respectively. The radiation dose of low-dose spine CT in this patient material has been kept as low as that recorded in our phantom study (0.38 mSv at scan length of 36.5 cm). The number of vertebrae included in the low-dose spine CT was almost 15 vertebrae [ $14.8 \pm 3.7$  (mean  $\pm$  SD)] and the scan length was almost 36 cm [ $35.93 \pm 8.94$  (mean  $\pm$  SD)]. The absorbed doses to the breasts, genital organs and thyroid gland in the low-dose spine CT was 8 times, 265 times, and 22 times, respectively, lower than the corresponding doses in trauma CT and 2.7 and 1.5 times, respectively, lower than the absorbed doses to the breast and genital organs in CT scan according to the ANV-protocol.

## Evaluation of image quality

**1. SNR values:** The results of the SNR calculations in phantom study (**paper I**) are shown in Table 2, Paper I [124] and in patient study in Table 6. Although the SNR value of the low-dose CT protocol (phantom, scan 5) was 35 times lower than that of the scan with the highest radiation dose (phantom, scan 1) and 2.5 times lower than trauma CT in patient study (**Paper II**), no negative influence on the reliability of the low-dose CT in the evaluation of the parameters tested during the subjective and the objective evaluation of the image quality.

**2. Subjective evaluation of image quality:** In phantom study the readers classified all images of scans 1-5 including those of the low-dose CT protocol as reliable. The overall image quality of scan 6 has been classified as unreliable in the lower five vertebral levels and relatively reliable in the upper 10 vertebral levels. Due to this difference in overall image quality of scan 6, the statistical test (paired sample t-test) has also been performed separately for the lower 5 vertebral levels (i.e. 10 pedicles of 28). In **paper II** the two readers agreed about the degree of reliability of the images in 106 out of 113 examinations (74 were considered as reliable, 25 as relatively reliable, and 7 as unreliable), Table 7. All 7 examinations which were considered as unreliable belong to patients who underwent anterior corrective surgery with insertion of stainless steel implants; the remaining 10 examinations in this group were considered as relatively reliable. The interobserver and intraobserver agreement were almost perfect in groups 1, 2 and

**Table 7:** The results of the subjective evaluation of image quality of all 113 examinations included in the analysis (**Table 3, paper II**).

		Observer 1/ Occasion 1			Total
		Reliable	Relatively reliable	Unreliable	
<b>Observer 2</b>	Reliable	74	0	0	74
	Relatively reliable	5	25	2	32
	Unreliable	0	0	7	7
	Total	79	25	9	113
	K- value				<b>0.87</b>
		Observer 1/ Occasion 2			Total
		Reliable	Relatively reliable	Unreliable	
<b>Observer 1/ Occasion 1</b>	Reliable	78	1	0	79
	Relatively reliable	3	20	2	25
	Unreliable	0	2	7	9
	Total	81	23	9	113
	K- value				<b>0.84</b>

in group 5. The interobserver and intraobserver agreement were substantial in group 3 while the intraobserver agreement in group 4 was moderate (K- value 0.53), (Table 8).

**3. Objective evaluation of image quality:** The objective evaluation of the impact of dose reduction on image quality scans 1, scan 5 and scan 6 (**phantom study, paper I**) is shown in Table 3, Paper I [124] which shows only the statistically significant results of the paired sample t-tests. Five of the 24 performed paired sample t-tests resulted in statistically significant differences in pedicular width measurements. The scan 6 (with lowest possible dose in our CT system) was included in all of these 5 paired tests, out of which 3 pairs concerned differences in pedicular width measurements in the lower 5 vertebral levels.

	Interobserver agreement			Intraobserver agreement		
	Kappa	95% CI		Kappa	95% CI	
		Lower limit	Upper limit		Lower limit	Upper limit
Group 1	0.87	0.77	0.96	0.84	0.74	0.94
Group 2	1	1	1	1	1	1
Group 3	0.77	0.59	0.96	0.79	0.60	0.98
Group 4	0.77	0.47	1.06	0.53	0.12	0.93
Group 5	0.83	0.49	1.15	0.85	0.57	1.13

**Table 8:** The degree of interobserver and intraobserver agreement in the subjective evaluation of image quality using Kappa coefficient for all low-dose CT examinations included in the analysis (group 1), the preoperative group (group 2), examinations of patients after posterior and anterior corrective surgery (group 3, and 4 respectively), and CT-examinations according to ANV-protocol (group 5), (**Table 4, Paper II**).



In **paper II** the objective evaluation of the image quality included:

(i) *Measurement of pedicular width*: The results are shown in Table 5, Paper II [125]. The reliability analysis showed almost perfect ICC in examinations with low-dose spine CT and in CT-examinations performed according to the ANV-protocol. The interobserver and intraobserver ICC was almost perfect in all groups except in that of group 4 (after anterior corrective surgery) where the interobserver ICC was moderate (ICC=0.508). The SD of interobserver difference between measurements of pedicular width was 0.61 mm in the examinations with low-dose spine CT compared with 0.32 mm in examinations according to the ANV-protocol. Corresponding values for SD of intraobserver differences were 0.42 vs 0.37 mm.

(ii) *Measurement of degree of vertebral rotation*: The mean values of degree of vertebral rotation was 10.7°, 10.4°, and 10.3° measured by observer 2 and observer 1 at three different occasions, respectively. This includes measurements at the apical vertebra, at the upper end vertebra, and at the lower end vertebra. The results of the reliability analysis are shown in Table 5, Paper II [125]. The reliability analysis showed almost perfect ICC in examinations with low-dose spine CT and those performed according to the ANV-protocol (group 1, and 5) as well as in the remaining groups. The SD of interobserver differences between measurements of degree of vertebral rotation was 1.88° in the examinations with low-dose CT-spine compared with 1.80° in examinations according to the ANV-protocol. Corresponding values for SD of intraobserver differences were 1.77° vs 1.82°. Only in group 4 the SD of the interobserver differences between measurements of degree of vertebral rotation exceeded 2°. In the remaining groups the SD of differences varied between 1.74° and 1.91°.

(iii) *Evaluation of the hardware status*: The interobserver agreement in the subjective evaluation of screw placement was substantial ( $\kappa=0.78$ ; 95% confidence interval 0.72–0.84) whereas the intraobserver agreement was almost perfect ( $\kappa=0.84$ ; 95% confidence interval 0.79–0.89).

Figure 2 (a-f), Paper II [125] shows examples of images generated by low-dose CT in patients study (**paper II**).

## Reliability of low-dose CT in the assessment of screw placement after posterior corrective scoliosis surgery

(1) Subjective evaluation of the overall reliability of images in the assessment of screw placement: None of the 46 CT-examinations included in the analysis was regarded as unreliable by any observer at any occasion (Table 9, evaluation 1 and

2). See also Table 2, Paper III [130].

(2) Evaluation of placement of the pedicle screws regardless the type of misplacement: the two observers agreed about the status of screw placement in 758 of 809 screws analyzed (Table 9, evaluation 3 and 4). See also Table 3, Paper III [130].

(3) The results of the interobserver- and intraobserver agreement in differentiating between screws with acceptable placement, screws with partial cortical perforation, and those with total cortical perforation are shown in Table 9, evaluation 5 and 6. See also Table 4, Paper III [130].

(4) The results of detailed analysis of all types of screw misplacement: With respect to the two most common types of misplacement, namely lateral and medial cortical perforations of the pedicles, the interobserver and intraobserver agreements were substantial, Table 10. The same applies to the interobserver- and intraobserver agreement regarding endplate perforation as well as the intraobserver agreement in anterior cortical penetration and foraminal perforation. The interobserver agreements in anterior cortical perforation and foraminal perforation were fair ( $\kappa = 0.39$  and  $0.40$  respectively).

Evaluation	Table number Paper III	The number the observer agreed about their status	(%)	Degree of agreement		
				95 % CI		
				K-value	Lower bound	Upper bound
1	2	41/46	89 %	0.77	0.59	0.96
2	2	42/46	91 %	0.79	0.60	0.98
3	3	758/809	94 %	0.78	0.72	0.84
4	3	772/809	95 %	0.84	0.79	0.89
5	4	734/809	91 %	0.69	0.63	0.75
6	4	752/809	93 %	0.76	0.71	0.81

**Table 9** shows a summary of interobserver and intraobserver agreement in the evaluation of screw placement using low-dose CT. Data compiled from Table 2,3, and 4 (**Paper III**) [130]

\*Evaluation 1 and 2: Interobserver and intraobserver agreement in subjective evaluation of CT-examinations.

\*Evaluation 3 and 4: Interobserver and intraobserver agreement in evaluating screw placement regardless the type of misplacement

\*Evaluation 5 and 6: Interobserver and intraobserver agreement in differentiation between the screws with acceptable placement (0), the screws with partial cortical perforation (1), and screws with total cortical perforation (2)

**Table 10:** The interobserver- and intraobserver agreement in different types of screw misplacement, (**Table 5, Paper III**).

	Interobserver agreement			Intraobserver agreement		
	Kappa	95% CI		Kappa	95% CI	
		Lower limit	Upper limit		Lower limit	Upper limit
MCP	0.68	0.58	0.78	0.77	0.69	0.86
LCP	0.72	0.64	0.79	0.76	0.69	0.84
ACP	0.39	0.08	0.71	0.62	0.34	0.90
EPP	0.77	0.56	0.99	0.87	0.70	1.05
FP	0.40	-0.15	0.94	0.66	0.23	1.10

## Clinical and radiological evaluation of screw placement

### *Types of scoliotic curves and distribution of pedicle screws:*

The right convex thoracic curve was the most frequent deformity (34 out of 49 patients, 69 % of study population, **Paper IV**) followed by the S-formed double curves with right convex thoracic- and left convex lumbar curve which was encountered in 10 patients (20 %). The remaining had left convex thoracic curve (n=2) and left convex lumbar curve (n=3). Three of the scoliotic apices were at the level of L2, two at the level of T12, and one at the level of T5. The remaining curves (88 %) had their apex at T8 or T9. In cases of double curves, the caudal curve had its apex at L1 or L2.

The total number of screws analyzed was 873; 79% of all screws were inserted in the thoracic spines; 31 % of the screws were inserted in the vertebral levels around the scoliotic apex (T7-T10). The distribution of the pedicle screw insertion is shown in Figure 2 paper IV [131].

### *Radiological assessment of screw placement:*

The overall rate of misplacement was 17 % while the acceptably placed screws amounted to 82.7 %. The status of three screws (0.3 %) was questionable. The rates of lateral cortical perforation, medial cortical perforation, anterior cortical perforation, endplate perforation, and foraminal perforation were 8 %, 6.1 %, 1.5 %, 0.9 %, and 0.5 %, respectively; Table 11. Of the misplaced screws 84% were thoracic, 59 % were inserted in pedicles on the left hand side, 56 % were inserted in pedicles on the concave side of the scoliotic curves, and 31% were inserted at or around the scoliotic apex. Of the 54 screws with MCP 40 (74 %) were on the left side (P=0.005), Table 12. The associations between MCP and the level of misplacement (thoracic or lumbar), concavity of the curve and the apex of the curve were statistically non-significant. Of 70 screws with LCP 65 (93 %) were thoracic (P= 0.005). Regarding the side and relation to scoliotic curves, screws

**Table 11:** The results of the radiological assessment of pedicle screw placement. Percent between parentheses, **(Table 1, Paper IV).**

T: thoracic, L: lumbar, Dx: right, Sin: left, Cc: pedicle screws inserted on the concave side of the curve. Cx: pedicle screws inserted on the convex side of the curve. Apex: pedicle screws inserted at the scoliotic apex. None-apex: pedicle screws inserted at levels other than apex.

	Total	T	L	Dx	Sin	Cc	Cx	Apex	None-apex
MCP	54 (6.1)	44 (81)	10 (19)	14 (26)	40 (74)	33 (61)	21 (839)	15 (28)	39 (72)
LCP	70 (8)	65 (93)	5 (7)	38 (54)	32 (46)	30 (43)	40 (57)	26 (37)	44 (63)
ACP	13 (1.5)	13 (100)	0	3 (23)	10 (77)	10 (77)	3 (23)	2 (15)	11 (85)
EPP	8 (0.9)	1 (12)	7 (88)	6 (75)	2 (25)	6 (75)	2 (25)	2 (25)	6 (75)
FP	4 (0.5)	2 (50)	2 (50)	0	4 (100)	4 (100)	0	2 (50)	2 (50)
Misplacement: Total	149 (17)	125 (84)	24 (16)	61 (41)	88 (59)	83 (56)	66 (44)	47 (31)	102 (69)
Normal placement	721 (82.7)	560 (78)	161 (22)	253 (35)	468 (65)	444 (62)	277 (38)	209 (29)	512 (71)
Questionable	3 (0.3)	3 (100)	0	2 (67)	1 (33)	1 (33)	2 (67)	0	3 (100)
Total (all screws)	873 (100)	688 (79)	185 (21)	316 (36)	557 (64)	528 (61)	345 (39)	256 (29)	617 (71)

with LCP were slightly more frequent on the right side and on the convexity of scoliotic curves (54 % and 57 % respectively) whereas other types of screw misplacement were showed to be 2.5 times and 2 times as frequent on the left side and the concavity of scoliotic curves, respectively ( $P=0.002$  and  $0.003$  respectively), Table 12.

#### *Detailed analysis of the screw placement:*

**(1) Screws with medial cortical misplacement:** Regarding medially placed screws, 35 of 37 partially medialised screws (grade 1 MCP) anchored in their vertebral bodies, Table 13. The degree of encroachment was measured in mm in cases where the screws totally perforated the medial pedicular cortex (grade 2 MCP). This was shown to vary from 3-5 mm ( $n=14$  of 17) to 6-7 mm ( $n=3$ ). All screws but one with encroachment of 3-5 mm abutted the medial pedicular cortex and anchored in the respective vertebral body. Three screws with 6-7 mm encroachment had 2-3 mm interval to the medial pedicular cortex. The tip of two of these screws did not anchor in the respective vertebral bodies but ended in the anterior part of the spinal canal or touched the posterior cortex of the vertebral

**Table 12:** The results of Chi-square test of the association between misplacements in general, MCP and LCP with different predictors in the first column. Statistical significance is marked with fat style, (**Table 2, Paper IV**).

	Misplacement, All types		P- value	Misplacement		P- value	Misplacement		P- value
	Yes	No		MCP	Other		LCP	Other	
Thoracic	125	560		44	81		65	60	
Lumbar	24	161	0.091	10	14	0.546	5	19	<b>0.005</b>
Right	61	253		14	47		38	23	
Left	88	468	0.176	40	48	<b>0.005</b>	32	56	<b>0.002</b>
Concave	83	444		33	50		30	53	
Convex	66	277	0.181	21	45	0.317	40	26	<b>0.003</b>
Apex	47	209		15	32		26	21	
Non-apex	102	512	0.533	39	63	0.456	44	58	0.166

bodies. No electrophysiological abnormalities were reported during the insertion of these misplaced screws and no neurological deficit was reported in the immediate postoperative period or in the outpatient follow up 8 weeks after the surgery. The evaluation did not show any pedicle fracture or other evidence of screw migration during the process of deformity correction.

Remarks	Total	Level		Side		Relation to curve		Relation to apex	
		T	L	Dx	Sin	Cc	Cx	Apex	None
• Anchors in vertebral body	35	29	6	10	8	21	14	9	26
• Anchors to vertebral body with 5 mm of the screw tip	2	1	1	0	2	1	1	1	1
<b>Total</b>	37	30	7	10	27	22	15	10	27
• 3-4 mm encroachment, abuts medial pedicular cortex and anchors in vertebral body	9	8	1	1	8	9	0	0	9
• 4 mm encroachment, screw tip in the spinal canal	1	1	0	1	0	0	1	1	0
• 5 mm encroachment, abuts medial pedicular cortex and anchors in vertebral body	4	3	1	2	2	1	3	3	1
• 6 mm encroachment, anchors in vertebral body	1	1	0	0	1	1	0	0	1
• 7 mm encroachment, screw tip in the spinal canal	2	1	1	0	2	0	2	1	1
<b>Total</b>	17	14	3	4	13	11	6	5	12

**Table 13:** The detailed analysis of screws with medial cortical perforation, showing the relationship of every individual misplaced screw to the surrounding bony structures, the scoliotic curve, and the scoliotic apex. Data compiled from **Table 3 Paper IV**.

T: thoracic, L: lumbar, Dx: right, Sin: left, Cc: pedicle screws inserted on the concave side of the curve. Cx: pedicle screws inserted on the convex side of the curve. Apex: pedicle screws inserted at the scoliotic apex. None-apex: pedicle screws inserted at levels other than apex.

**(2) Screws with lateral cortical misplacement:** Among the 30 screws which were partially lateralised (grade 1 LCP) 22 anchored in the respective vertebral bodies while 8 screws passed laterally through the vertebral bodies and abutted their inner cortex resulting in suboptimal hold in the vertebral bodies, Table 14. The majority of screws placed totally lateral to the pedicles (n= 25 of 40) abutted the outer pedicular cortex of the vertebral body but did not anchor in the respective vertebral bodies. Seven screws passed through the PRU with the screw tip in the PRU. Five screws had paravertebral passage (4 on the right side) with an interval of 1-6 mm to the lateral border of vertebral column, of which one screw made a slight impression in the adjacent pleura on the right side. There were no respiratory complaints after the surgery, and no pleural thickening was reported in the radiological follow-up with low-dose spine CT.

**(3) Screws with other types of misplacement:** The total number of screws with anterior cortical perforation was 13, of which 5 were associated with lateral cortical perforation, Table 15. The average perforation of anterior cortex was 2.3 mm (range 1-6 mm). All reported cases of endplate perforation (n=8) occurred into the upper endplates while the foraminal perforation (n=4) occurred equally into the overlying and the underlying neural foramen, Table 15.

Remarks	Total	Level		Side		Relation to curve		Relation to apex	
		T	L	Dx	Sin	Cc	Cx	Apex	None
• Anchors in vertebral body	22	19	3	8	14	15	7	9	13
• Passes laterally in the vertebral body and abuts their inner cortex	8	8	0	5	3	3	5	5	3
<b>Total</b>	30	27	3	13	17	18	12	14	16
• Anchors in vertebral body	2	2	0	0	2	1	1	1	1
• Abuts lateral pedicular cortex and vertebral body. Does not anchor in the vertebral body	25	24	1	15	10	9	16	7	18
• Passes through pedicle rib unit (PRU) with screw tip in the PRU	7	7	0	6	1	1	6	2	5
• Passes through pedicle rib unit (PRU) with screw anterior to PRU	1	1	0	0	1	1	0	1	0
• Paravertebral passage	5	4	1	4	1	0	5	1	4
<b>Total</b>	40	38	2	25	15	12	28	12	28

**Table 14:** The detailed analysis of screws with lateral cortical perforation, showing the relationship of every individual misplaced screw to the surrounding structures, the scoliotic curve and the scoliotic apex. Data compiled from **Table 3 Paper IV**.

T: thoracic, L: lumbar, Dx: right, Sin: left, Cc: pedicle screws inserted on the concave side of the curve. Cx: pedicle screws inserted on the convex side of the curve. Apex: pedicle screws inserted at the scoliotic apex. None-apex: pedicle screws inserted at levels other than apex

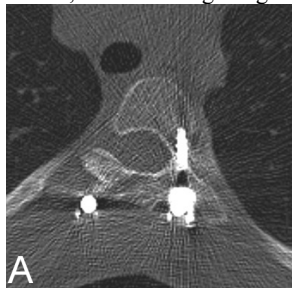
Figure 8 shows CT-images of different types of screw misplacement and their relation to the surrounding structures. Vicinity of the screw tip to aorta (Figure 8F) was found in 15 screws (10 patients) of which 6 screws were placed with ACP and 9 with LCP. The average distance between the screw tip and the dorsal or the lateral wall of aorta was 2.9 mm (range 1-4 mm).

Type of misplacement	Remarks	Total	Level		Side		Relation to curve		Relation to apex	
			T	L	Dx	Sin	Cc	Cx	Apex	None
ACP	Pure ACP	8	8	0	2	6	6	2	0	11
	Associated with LCP	5	5	0	1	4	4	1	2	0
	<b>Total</b>	13	13	0	3	10	10	3	2	11
EPP	Upper endplate	8	1	7	6	2	6	2	2	6
	Lower endplate	0	0	0	0	0	0	0	0	0
	<b>Total</b>	8	1	7	6	2	6	2	2	6
FP	Overlying foramen	2	0	2	0	2	2	0	0	2
	Underlying foramen	2	2	0	0	2	2	0	2	0
	<b>Total</b>	4	2	2	0	4	4	0	2	2

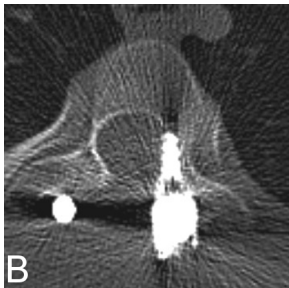
**Table 15 :** The detailed analysis of screws with remaining types of misplacement, showing the relationship of every individual misplaced screw to the surrounding structures, the scoliotic curve, and the scoliotic apex. Data compiled from **Table 3 Paper IV**.

T: thoracic, L: lumbar, Dx: right, Sin: left, Cc: pedicle screws inserted on the concave side of the curve. Cx: pedicle screws inserted on the convex side of the curve. Apex: pedicle screws inserted at the scoliotic apex. None-apex: pedicle screws inserted at levels other than apex.

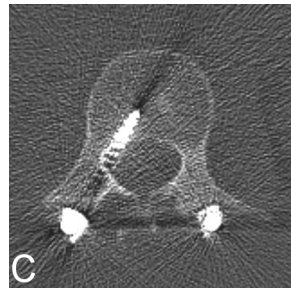
**Figure 8:** Examples of different types of screw (mis)placement. Image G is sagittal and image H is coronal; the remaining images are axial.



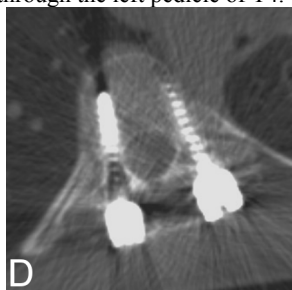
(A) Acceptably placed screw through the left pedicle of T4.



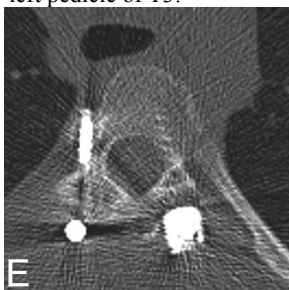
(B) MCP grade 1 through the left pedicle of T3.



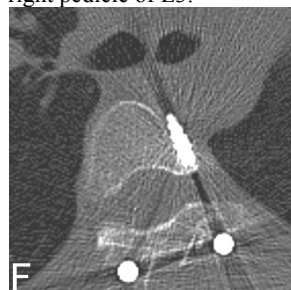
(C) MCP grade 2 through the right pedicle of L3.



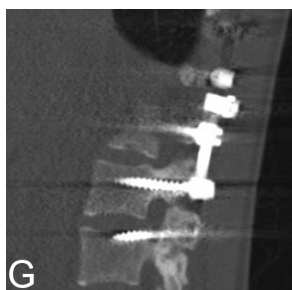
(D) LCP grade 1 through the left pedicle of T9. Acceptably placed screw on the right side.



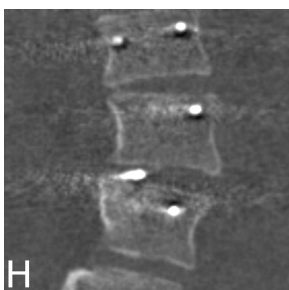
(E) LCP grade 2 through the right pedicle of T5. The screw does not anchor in the vertebral body



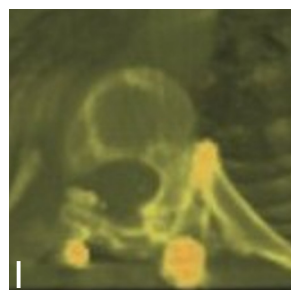(F) ACP through the anterior cortex of T5 on the left side. Note the vicinity of screw tip to aorta.



(G) The upper screw is acceptably placed through the pedicle of L2 with no penetration into the neural foramen or the vertebral endplate while the lower screw passes through the overlying neural foramen (FP).



(H) EPP through the upper endplate of L3 on the right side.



(I) Axial image with volume rendering technique (VRT) showing grade 2 LCP with screw passage through the pedicle rib unit. The screw was supposed to pass through the left pedicle of T7.





## General discussion

The studies included in this thesis have shown that the radiation dose of the helical CT-examination of the spine could be markedly reduced before any negative impact on image quality would be noticed. The low-dose CT has been shown to be a reliable method in the evaluation of the different parameters important for the preoperative workup of patients with AIS (e.g. measurement of the pedicular width and the degree of vertebral rotation) as well as in the evaluation of hardware status after surgery. The grading system proposed here for the evaluation of screw placement has been shown to be practical and makes the evaluation of screw insertion in the posterior corrective scoliosis surgery easier.

### Radiation dose and radiation protection

Adolescent idiopathic scoliosis affects young individuals, predominantly females. The maximal curve progression occurs during the pubertal growth spurt. These patients are often the object of repeated radiological examinations during the follow-up of scoliosis as well as in conjunction with the treatment. Thus the optimization of the radiation dose in the workup of AIS is mandatory.

It has been thought that approximately of 15 % of all radiation exposure comes from the medical radiation (5 % from conventional radiography and 10% from CT). More than 60 million CT-examinations were performed in the United States in 2005 [132], which means that every individual U.S. citizen would be exposed to one CT-examination in the course of 5 years. Thus the contribution of CT to the total radiation dose is certainly underestimated. At the April 2006 National Council on Radiation Protection and Measurement Annual Meeting in Washington, D.C., preliminary data suggested that the contribution of CT to total radiation dose exposure could be approximately 50% [133]. The major contributing factors to this increase are the increasing availability of the CT scan as well as the increasing number of new indications and the introduction of new modalities (e.g. CT angiography, high resolution studies, “multiple phase examinations”, perfusion studies, etc). In Sweden 651 885 CT-examinations were performed in 2005 of which 17 453 CT-examinations were of children [109]. Appendix 7 shows a summary of some relevant data collected from SSI-report given by the Swedish Radiation Protection Authority 2008. The annual per capita effective dose for the UK in 2001-2002 was estimated to be 0.38 mSv [134] and for the Dutch population in 1998 to 0.59 mSv [135]. In Germany an overview of

MSCT examinations conducted in 2001 has shown that the average effective dose to patients changed from 7.4 mSv at single-slice to 5.5 mSv and 8.1 mSv at dual- and quad-slice scanners, respectively [136]. Table 16 shows some examples of the radiation doses of different types of radiological examinations of the spine or chest and abdomen (including the same region of interest and exposing the same radiosensitive organs for ionizing radiation as those for patients included in our study) reported in the literature. To the best of my knowledge there is no single report in the literature showing such markedly reduced radiation doses in CT as in our study. However, Geijer et al [137] recently reported a marked reduction in the radiation dose of plain radiograph of the lumbar spine, reduced to as low as 0.24 mSv, primarily by increasing the system speed and decreasing the tube voltage. Studies have been done normalizing the effective dose to phantom age and to different body regions [123]. An inverse trend was observed between normalized effective dose and phantom age. The effective dose normalized to age for chest examinations using Siemens DRH-scanner increased from 6 mSv in the adult phantom to only 6.3 mSv in the phantom corresponding a 15 year old child [123], Table 17. The difference increased even more in phantoms corresponding to newborns and a 1-year-old child. However, these age groups are seldom the object for corrective surgery and, consequently, rarely subjected to CT examination of

**Table 16:** Shows examples of the literature reports on radiation doses on plain radiography of spine, CT of spine and CT of chest and abdomen i.e. CT-examinations covering the same region of interest as CT of the spine. The fourth column shows the estimated risk for induction of lethal cancer per 10 000 normal population. Data of risk for induction of lethal cancer compiled from [115, 138].

References	Region of interest	Effective dose, mSv	Risk for induction of lethal cancer
Wintermark [139]	Plain radiography, spine	6.36	3.2
Almén [115]	Plain radiography, lumbar spine	1.8	0.9
Wintermark [139]	CT chest and abdomen	19.42	9.7
Nishizawa [140]	CT-chest	9.4-28	4.7-14
Nishizawa [140]	CT-abdomen and pelvis	13-28	6.5-14
Tsapaki [141]	CT-chest and abdomen	18	9
Abul-Kasim [125]	CT-trauma	13	6.5
Heggie [142]	CT-lumbar spine	6.9	3.5
Mulkens [120]	CT-lumbar spine	6.69	3.3
Abul-Kasim [125]	Low-dose CT	0.37	0.18
Åkerblom [143]	Background radiation	1-4	

the spine as the median age of patients at or just prior to surgery is estimated to be 14-15 years [144].

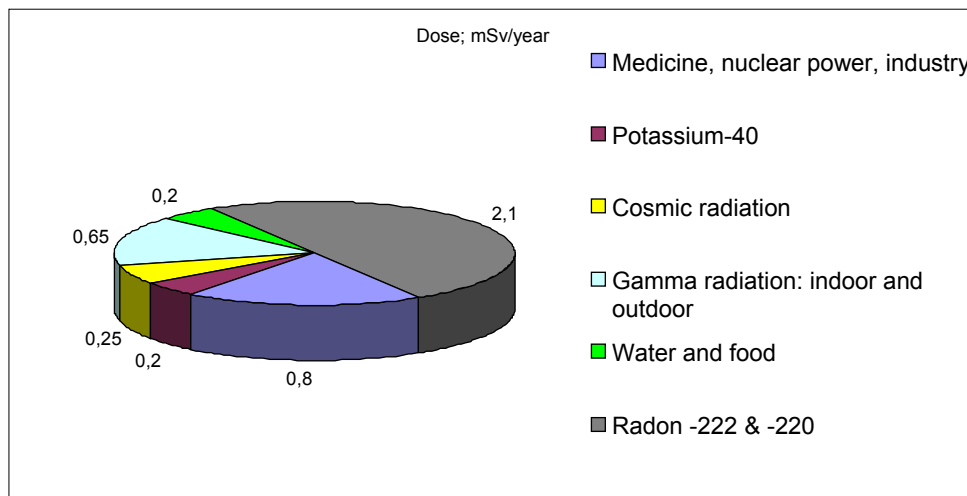
The Swedish SSI has set a diagnostic reference level (DRN) [145] for different radiological examinations. The DRN for the effective dose for CT-lumbar spine and for CT-chest and abdomen in patients aged 10-30 years was set to 9 mSv and 24 mSv, respectively. In our studies the mean value of the effective dose in low-dose CT was 0.37 mSv (**Paper II**), which is 24 and 65 times lower than the DRN. In Sweden the mean value for CTDI<sub>vol</sub>, DLP and the effective dose for CT-lumbar spine in the period 1999-2006 were 38 mGy, 510 mGy.cm, and 8.7 mSv respectively [146] while the mean values for CTDI<sub>vol</sub>, DLP, and the effective dose for CT-chest and abdomen during the same period were 22 mGy, 1057 mGy.cm, and 18.7 mSv respectively [146]. The corresponding values for low-dose CT used in our patient study (**paper II**) were 0.53 mGy, 20.75 mGy.cm, and 0.37 mSv. In up to 24 % of CT-spine performed in Sweden during the period 1999-2006 the DLP-values exceeded the DRN [146].

In the view of the above facts the results of **paper I and II** show considerable reduction of the radiation doses of spine CT without any negative influence on image quality with regard to the ability to answer the clinical questions. Performing one preoperative and one postoperative low-dose spine CT between Th2-L4 means a total effective radiation dose of 0.74 mSv. This can be compared with the exposure to the natural radioactivity from different sources including background radiation: cosmic radiation, radon houses, industry, nuclear reactors etc, which varies from place to place with values ranging from 1 to 2 mSv but can in some instances amount up to 4 mSv per year [143], Figure 9.

Scan number in our phantom study	Adults	15 years	10 years	5 years	1 year
Scan 1	18.6	18.6-20.46	20.46-27.9	22.32-29.76	24.18-37.2
Scan 2	8.6	8.6-9.46	9.46-12.9	10.32-13.76	11.18-17.2
Scan 3	0.49	0.49-0.54	0.54-0.73	0.59-0.78	0.64-0.98
Scan 4	0.45	0.45-0.5	0.5-0.67	0.54-0.72	0.58-0.9
<b>Scan 5</b>	<b>0.34</b>	<b>0.34-0.37</b>	<b>0.37-0.51</b>	<b>0.41-0.54</b>	<b>0.44-0.68</b>
Scan 6	0.30	0.30-0.33	0.33-0.45	0.36-0.48	0.39-0.6

**Table 17:** The effective dose (mSv) in the adult phantom and the normalized effective dose (mSv) to the phantoms of four different age groups using the data from the National Radiological Protection Board (NRPB) SP250. The ranges in the age groups other than the adult represent the minimum and maximum relative dose. In our low-dose CT-protocol the normalized dose in phantom corresponding to the age-group 15 years is quite the same as that of the adults (0.34-0.37 mSv, and 0.34 mSv respectively).

**Figure 9:** Diagram showing the distribution of different sources of background radiation in Sweden. In certain regions the annual background radiation amounts to 4.2 mSv. Data compiled from [143].



The dose of 2 examinations according to the low-dose spine CT corresponds thus to only 18-74 % of the annual exposure of the natural radioactivity. Furthermore this significant reduction of the radiation dose may hopefully contribute to reduction of the risk for induction of lethal cancer (Table 16).

A current concept has recently proposed three ways to reduce the overall radiation dose from CT [147]. These include: (1) reduction of the number of CT studies that are prescribed, (2) replacing the CT examinations with other modalities e.g. MRI, and (3) taking advantage of the dose reduction system available in some scanners in accordance to our recommendation. However, we believe that attempts to reduce the radiation dose in CT examinations and efforts to create low-dose CT protocols adapted to answer different clinical questions have to be added as the fourth way to reduce the overall radiation dose from CT-examinations.

Because of the increasing alertness about the hazard of ionizing radiation in the last years, recent data suggests that the radiation practice patterns are, in fact, changing. Data presented at the society for pediatric radiology annual meeting in April 2007 represented a 5-year-interval survey of pediatric body MDCT use by the member of the society. Approximately 40% of the respondents indicated using a peak voltage of <110 in 2006 versus <5% of the respondents in 2001 [148]. In addition, the mean tube current for CT in the 0-to-4-year age group has been

decreased from >120 mA to approximately 70 mA in abdomen CT, and from approximately 110 mA to 50 mA in chest CT. In Sweden the SSI-report 2008 showed a 22 % and 8 % reduction, respectively, of CTDI<sub>vol</sub> and DLP for CT-lumbar spine between 1999 and 2006 [146].

## Measures to reduce the radiation dose in CT

### *Optimization of scan parameters:*

The principal parameters that contribute to the radiation dose are tube current (mA), peak voltage (kV), gantry cycle time, and pitch. The relationship between peak voltage and radiation dose is non-linear while the relationship between the remaining parameters and the radiation dose is linear. The initial approach to optimizing the radiation dose is to determine what information is required from the CT-examination and the minimum level of contrast to noise ratio that is acceptable for diagnostic purposes. If lesser contrast is required and greater noise can be tolerated, then a lower tube current should be used.

When all other parameters are held constant increasing the peak voltage from 120 to 140 (17%) results in a 37.5% increase in the CTDI<sub>vol</sub> for a head phantom and 39% for a body phantom [149]. However, decreasing the peak voltage often reduces x-ray penetration, and requires a significant increase in mA to counterbalance this reduction, resulting in an overall increased radiation dose. In specific applications such as perfusion CT and pulmonary angiography CT, a tube voltage of 80 kV is typically combined with low tube current. This combination affords increased contrast (closer to the K-edge for iodine), whereas the radiation dose is reduced [150].

Decreasing tube current by 50% will essentially decrease radiation dose by 50% [151] and result in increased image noise. Studies suggest that higher mAs values are generally used in CT than those that are actually required to achieve diagnostic images [152].

Decreasing gantry rotation time decreases the radiation dose in a linear fashion [153]. The faster the gantry rotation, the lower the dose; reduction of the gantry rotation time by half leads to the same degree of dose reduction as reducing the tube current by half. This can be advantageous also when a quicker acquisition is needed, for instance in unstable patients [154].

A higher pitch results in a decreased amount of time that an anatomic part is exposed to radiation. By increasing the pitch, the dose to the patient is decreased. However, volume averaging is increased due to an increase in effective section thickness, and spatial resolution along the z-axis is slightly decreased [155]. This

might jeopardize the possibility to obtain good coronal and sagittal reconstructions especially at a pitch factor approaching 2. Increasing the pitch from 1.0 to 1.5 will reduce the patient dose by 33% [156].

On multidetector CT scanners and in the era of PACS, the collimation should be set to acquire images as thin as one may be interested of (now or later) [155]. Typically, thin collimation (0.625-0.75 mm) and thin (and overlapped) reconstructions (0.625-0.75 mm) are used for those techniques that require high spatial detail, such as intracranial CTA or CT of the cervical spine, where the highest spatial resolution is sought to detect small aneurysms or subtle fractures. At the other end of the spectrum, thin collimation (0.625 mm) and thicker reconstruction (and again overlapped) images (2.5–3 mm) may be best used for CT-studies of the lumbar spine. In our study we used a collimation of 0.75 mm and a reconstruction thickness of 1 and 3 mm. The strategy of “acquire thin and view thick” [155] is very dose-efficient because the source images will be noisy, but the thick images used for review will not. Furthermore, the source images with higher spatial resolution will be available if required to interpret an unresolved finding on the thick review images and as the source images for 2D and 3D reformats.

#### *Use of in-plane shielding:*

In-plane shielding of radiosensitive tissues such as the female breast may reduce the dose to this radiosensitive organ. Parker et al [157] suggested that an externally applied custom designed tungsten-antimony composite shield can potentially reduce the dose incurred during CT pulmonary angiography by 43-73%. Similarly, bismuth breast shields have been shown to reduce breast dose by 29% in pediatric patients [158].

#### *Dose modulation:*

Three types of automatic tube current modulation exist: angular (x- and y-axis), longitudinal (z-axis), and combined (x-, y-, and z-axis) modulation. With angular modulation, relatively higher tube current is delivered through the thicker region of the body (mediolateral abdomen) as compared with the thinner dimension (e.g. anteroposterior abdomen). With longitudinal modulation, tube current is altered along the craniocaudal dimension of the patient, delivering lower tube current through structures with lower attenuation (e.g. the lungs) and relatively higher tube currents through structures with higher attenuation (e.g. the shoulders). This type of modulation is based on the density of tissues seen on the topogram. The

technical basis that determines the type of tube current modulation varies by manufacturer. In our study the CT-manufacturer's dose reduction system (CareDose 4D, Siemens AG, Forchheim, Germany) was used. This automatic tube current modulation system includes both angular modulation and longitudinal modulation [120], with the aim to automatically adapt the tube current to the patient's anatomic configuration and size together with an on-line controlled tube current modulation for each tube rotation [121].

#### *Noise reduction filters:*

Noise-reducing reconstruction algorithms are another approach being explored by manufacturers for potential dose reduction and image quality improvement, often referred to as "adaptive filters". These filters vary according to the scanner manufacturer and operate either in the raw data domain or use postprocessing methods to reduce noise whilst maintaining the resolution in specific regions of the image, thereby offering the potential to use a lower tube current [159, 160]. Such filters reduce image noise on low-radiation-dose chest CT with some compromise in image sharpness and contrast [160]. Soft tissue or smooth reconstruction filters have shown to overcome the streak artifacts from metal hardware [161] and are used in our studies.

#### *Other measures that might contribute to the reduction of the radiation dose to the patients:*

1. Avoiding the multiphase scanning.
2. Limiting the range of coverage by reducing the field of view to include only the region of interest.
3. Developing CT protocols that are based on the patient's size, especially in the pediatric population.
4. Avoiding overlapping scans.
5. Lowering radiation dose at repeated control CT.
6. Minimizing scan lengths as much as possible.
7. Providing adequate education of CT users with regard to the effect of scan parameter settings on the radiation dose and the image quality.

#### **Measures to reduce the radiation dose in our studies**

In our studies the tube voltage and tube current are reduced to the maximum levels allowed by our CT-system taking advantage of the automatic tube current modulation (CareDose, 4D). Further reduction of mAs was only possible without



the automatic tube current modulation. Furthermore, such a reduction (scan 6, **paper I**) proved to impose significant impact on image quality. Although the reduction of tube voltage has the disadvantage of negatively influence the penetration and consequently lower the image contrast we decided to decrease the tube voltage to the minimum level allowed by our CT-system as the subjective and objective evaluation of images of the low-dose CT did not show any significant impact on image quality with regard to answering the clinical questions at issue. Keeping the tube voltage at 120 kV and reducing the quality mAs to the minimum of 25 mAS could have resulted in almost 4-fold increase in the effective dose as scan setting of this amplitude would result in CTDI<sub>vol</sub> of 1.95 mSv compared with that of the low-dose CT (0.53 mSv).

The pitch factor has been increased in our study from 1 to 1.5. Further increase in pitch to 2 could have decreased the radiation dose with about 20-25 % as an increase in pitch factor of this magnitude shortens the scan time with 20-25 %. We decided not to further increase the pitch factor as this would result in increased noise (further decrease of the SNR) and jeopardize the possibility to obtain reasonable coronal and sagittal reformatted images. Also further reduction in rotation time was possible (from 0.75 sec to 0.5 sec) and could have shortened scan time and subsequently the radiation dose but, similarly, it could have resulted in further increase in the image noise as data in MDCT are collected simultaneously at multiple z-axis locations (multiple detector rows). The interpolation process in MDCT can thus utilize data from the detector row nearest to the requested z-axis image location, regardless of which row those data come from [162]. Using a modified 360° interpolation approach, there are redundant data points (i.e. data passing through the same z-axis position) from different detectors as they rotate about the patient. The frequency of these redundancies is determined by the pitch values [162], with greater utilization of these redundant data at lower pitch values and longer rotation time and vice versa. To make use of all the photons applied to the patient, MDCT interpolation algorithms make use of the redundant data by averaging redundant projection values, which effectively decreases image noise. When the pitch is markedly increased or the rotation time is markedly decreased, there are more gaps in the data with fewer redundant points to average, i.e. the possibility to utilize this unique function of interpolation process diminishes and image noise will not be sufficiently reduced. This is the reason why the pitch factor and the rotation time were not further changed in our study.

Continuous education of our radiographers about the measures to keep the patient's radiation doses as low as possible and about the hazards of unnecessary radiation exposure are important tool to decrease the overall radiation dose from CT. Limiting the scan length only to the region of interest, reduction of FOV and the use of noise reduction filter are other measures that resulted in keeping the radiation dose in the study cohort (**paper II**) as low as that obtained in the phantom study (**paper I**) and an image quality that is fully acceptable for the purpose.

Appendix 8 shows the detailed scan- and reconstruction parameters of low-dose CT used today in clinical practice.

### Influence of dose reduction on image quality

During our subjective evaluation of image quality we decided to perform a visual grading analysis (VGA) [163, 164] separately for every scan setting, using the vertebral body and pedicular contour as anatomical landmark rather than comparing images of different scan settings, i.e. performing absolute grading (no reference images). By performing a subjective and objective evaluation of image quality in the phantom study (**paper I**) we came to the conclusion that the parameters of the low dose helical CT protocol (Table 3) are to be considered as a cut-off value to which the scan parameters can be reduced (with resultant decrease in the effective dose) with no significant impact on image quality required for planning of scoliosis surgery. The subjective and the objective evaluation of image quality of scan 1 (according CT protocol recommended by the manufacturer of our CT-scanner) and scan 5 (according to the low-dose CT protocol) was reliable with respect to identification of the pedicles, and measuring their width. The interobserver and intraobserver random errors in measuring the pedicular width varied between 1.1 mm and 1.6 mm in scan 6 (lowest possible parameter reduction in our CT-system), Table 3 ; Paper I. Beside statistical significance, differences exceeding 1 mm make the results also significant from the clinical point of view as they significantly influence the choice of appropriate screw size.

In **paper II** the images of low-dose spine CT were considered reliable with respect to measurements of pedicular width, vertebral rotation and assessment of hardware status. This concerns images of all groups i.e. all examinations included in the analysis (group 1, n=113) as well as the preoperative examinations (group 2), the postoperative examinations after posterior corrective scoliosis surgery (group 3), and images according to ANV-protocol (group 5). The only exception was the low-dose CT-examinations performed after anterior corrective surgery

(group 4) where the subjective evaluation showed that 7 out of 17 CT-examinations were unreliable.

The SD of interobserver- and intraobserver differences between measurements of pedicular width were less than 1 mm (varied between 0.3 and 0.6 mm) in all groups except for group 4 (examinations performed after anterior corrective surgery) where the SD was 1.3 mm (Table 5, Paper II) [125]. Except for the latter figure, the SD of 0.3–0.6 mm has to be considered as clinically insignificant as differences of such magnitude at least partly are the inborn error of the measurement programs in any PACS.

The SD of interobserver- and intraobserver differences between measurements of the degree of vertebral rotation varied from 1.74° to 1.91° in group 1, 2, 3, and 5 (Table 5, Paper II) [125]. The measurements of the degree of vertebral rotation with CT scan performed with different methods [67, 165-167] and the comparison between the reliability of some of these methods have been studied previously [168, 169]. The SD of differences in our study (**Paper II**) are in accordance with the results from these previous studies [67, 169] and supports the assumption that low-dose spine CT has to be considered as a suitable and reliable method in measuring the degree of vertebral rotation. **Paper II** has thus shown that the reduction of radiation dose of such a large magnitude did not convey any negative impact on image quality with regard to answering the clinical questions necessary for the preoperative planning of patients with AIS. However, the low-dose spine CT does not seem to be a suitable method in the postoperative work-up of patients after anterior corrective scoliosis surgery because all CT-examinations (n=7) which were classified as unreliable in the subjective evaluation of image quality belong to this group of examinations, and the SD of interobserver- and intraobserver differences between measurements of degree of vertebral rotation as well as pedicular width exceeded 2° and 1 mm respectively. We believe that this depend on the fact that the construct (stainless steel) used in the anterior corrective surgery give rise to very disturbing metal artifacts and make the evaluation of this type of hardware unreliable with the low-dose CT.

One of the limitation of the phantom study (**paper I**) was that the study phantom was an adult phantom. However, when normalizing the effective dose to phantom age (Table 17), no significant increase in the effective dose could be recorded in the low dose CT-protocol in the patient group which is predominantly the subject of scoliosis surgery, namely 15-year-old phantom. The other limitations were inability to assess the degree of vertebral rotation and the impact

of artifacts from metal implants on the ability to assess the hardware status postoperatively, which otherwise could be clarified in **paper II**.

Even in other body parts a marked dose reduction can be achieved before any negative impact on image quality that would jeopardize the diagnostic accuracy can be noticed. The use of tube current modulation in low-dose abdomen CT (with tube voltage of 120 kV and tube current time product of 25–100 mAs) has been reported to result in both a sensitivity and negative predictive value of 93% in patients with “acute abdomen” [170]. Definite criteria for optimal image quality do not exist and are a matter of debate. Image quality depends on individual preferences, which in turn depend on the experience (i.e. training) in addition to institutional, national, and medical organizational guidelines [119].

### Reliability analysis of low-dose CT in the assessment of screw placement

**Paper III** showed that low-dose CT is a reliable method in the assessment of pedicle screw placement in patients with AIS, who have undergone posterior correction of scoliotic deformity and stabilization with titanium “all-pedicle screw construct”. This paper showed a high degree of interobserver- and intraobserver agreement with regard to the stepwise evaluation of the reliability of low-dose CT in differentiation between the acceptably placed screws and the misplaced screws and between screws with partial- and those with total cortical violation as well as in the assessment of different types of misplacement. However, the interobserver agreement in the assessment of anterior cortical perforation and foraminal perforation was fair (K-value 0.39 and 0.40 respectively) whereas the corresponding values for intraobserver agreement were substantial (K-value 0.62 and 0.66 respectively). We believe that this difference depends on the fact that the reader who did the assessment twice was the radiologist who is primarily involved in the optimization process of the here proposed low-dose spine CT and who is usually involved in the daily radiological assessment of these examinations. The radiologists in general are more familiar with lateral- and medial cortical perforations. Foraminal perforation, which we included in our new grading system, is a rather rare and a previously less frequently analyzed and reported type of misplacement. The above mentioned facts might have contributed to this difference in the degree of agreement in the assessment of anterior cortical perforation and foraminal perforation. The substantial intraobserver agreement compared with the fair interobserver agreement in assessment of anterior cortical perforation and foraminal perforation indicates that the reliability of low-dose CT

spine is high if the evaluating radiologist is dealing with the assessment of such examinations in the daily clinical practice and is more familiar with assessment of screw misplacement. Although the interobserver agreement in the assessment of anterior cortical perforation and foraminal perforation was fair, the risk to benefit ratio of using the low-dose CT instead of standard dose CT (20-35 fold lower radiation dose compared with trauma CT of the same region of interest) [125] should validate our recommendation to use the low-dose CT and the here proposed grading system in the assessment of screw placement.

### The new grading system for assessment of screw misplacement

In the literature the rate of the reported screw misplacement in the thoracic region varies from 20% to 50% [78, 171, 172]. The rate of neurovascular complications ranges from 0 to 1% [173, 174]. According to the report of the scoliosis research society morbidity and mortality committee 2006 the overall neurological complication rate after spinal fusion for adult scoliosis was estimated to 1.3% [66]. However, there have been reports of serious resolving or permanent complications sometimes necessitating surgical revision or removal [172, 175-177].

The reasons why we decided to propose a new grading system in the evaluation of screw placement were: (1) In almost all reports no neurovascular complications have been reported when pedicle breach was  $\leq 2$  mm and a potential for neurological complication was believed to exist only when the medial wall perforation exceed 4 mm [172, 178, 179]. (2) Most of the reports on screw misplacement are based on measuring the degree of misplacement in mm. (3) A literature review and a recently published meta-analysis [180] showed that up to 35 methods have been used for the assessment of different types of misplacement of pedicular screws. Most of the reports focused on the two most common types of misplacements (medial- and lateral cortical perforation) [180] with a few of them reporting the other types of screw misplacements that are proposed in **paper III**.

The screws used in the spinal fixation in patients with AIS vary in diameter between 4 and 8 mm (often 4-5 mm in the thoracic pedicles, and 5-7 mm in the lumbar pedicles). Using our grading system a cortical perforation of less than half the screw diameter is included in grade 0 placement i.e.  $< 2$ -2.5 mm cortical perforation of screws with 4-5 mm diameter used in the thoracic spine. This is in accordance with the conclusion of most studies, namely that the pedicle perforation of  $\leq 2$  mm is harmless and can thus be classified as a normal and acceptable placement. The different grades of misplacement in our grading system take into account the relation between the magnitude of misplacement and the

screw diameter. Thus grade 1 lateral- or medial misplacement includes screws with more than half the screw diameter outside the pedicle wall. In practice grade 1 medial- and lateral cortical misplacement include 4 mm sized screws with perforation of more than 2 mm, 5 mm sized screws with perforation of more than 2.5 mm, 6 mm sized screws with perforation of more than 3 mm etc.

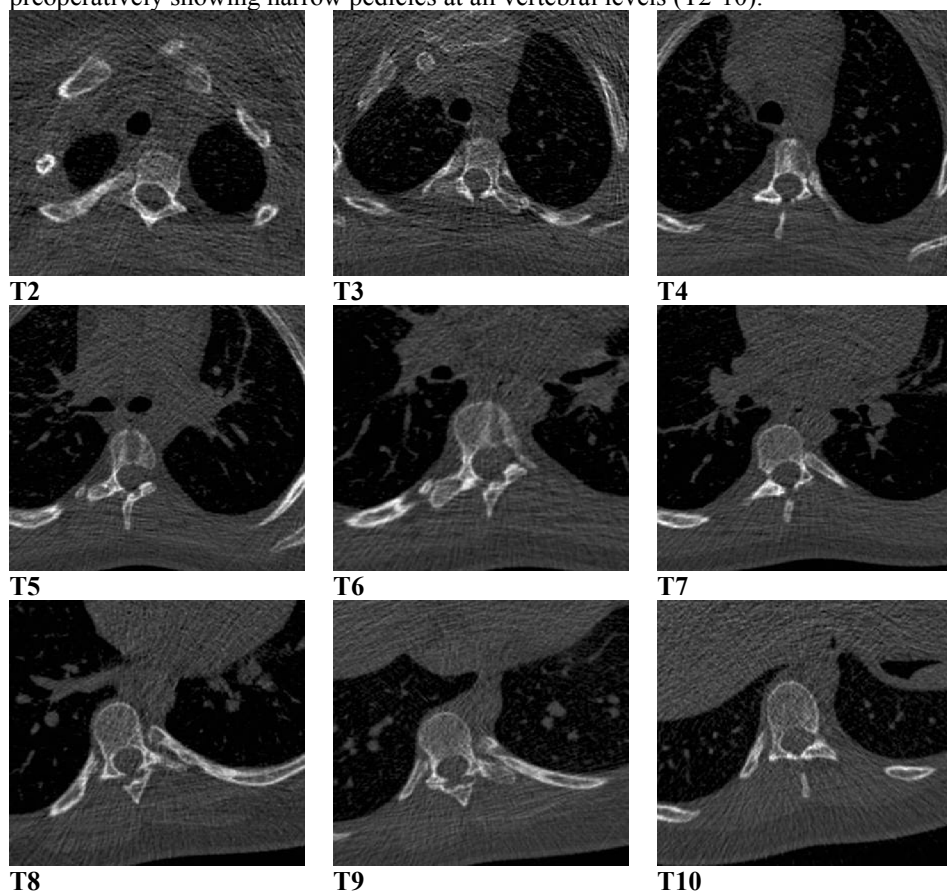
Analysis of data (posthoc) from a previous study (**paper II**) of measurement of thoracic pedicle width at the level Th7-Th9 (data on pedicular width not presented in that paper) has shown that 38 % of the pedicles had a width of  $\leq 4$  mm and 71 % of the pedicles had a width of  $\leq 5$  mm. Therefore, using a pedicle screw of 4–5 mm in the thoracic spine means that 38–71 % of screw placements are inclined for cortical violation of 1–2 mm irrespectively of the skillfulness of the surgeon. In clinical practice the pedicular width at the upper thoracic spines is not unusually  $\leq 3$  mm (Figure 10) and in one report the pedicular width at the level of T4 was found to be 2.6 mm [181]. Placing a 4 or 5 mm sized screw through pedicles with 2.6 mm diameter means a misplacement of at least 1.4–2.4 mm. In practice this means that all screws inserted through these pedicles should be classified as misplaced if the grading of misplacement is based on cortical violation measured in mm. Instead, our grading system was based on the degree of the cortical violation (partial or total).

Taking these facts into consideration, our new grading system is to be considered more practical, feasible and easier to perform than many of the previously used grading systems using perforations of  $< 2$ , 2-4 and  $> 4$  mm as the basis for their grading.

### Misplacement rate: A literature review

As mentioned before there seems to be a general agreement that minor misplacement and minor cortical violation ( $\leq 2$  mm) is harmless, not associated with neurovascular complication, and in most of the cases does not require implant removal or revision [78, 178, 179]. A consensus of a so called “safe zone” of 4 mm has been reached with regard to the medial cortical perforation [171, 182]. A medial cortical perforation of 5 mm and a lateral cortical perforation of 6 mm have been tolerated in one study [178] where the authors hypothesize a definite safe zone (perforation  $< 2$  mm), a probable safe zone (perforation 2-4 mm), and a questionable safe zone (perforation 4-8 mm) of medial cortical perforation. However, pedicle breach might negatively affect the biomechanical strength of the pedicle screws even if some studies have shown that screws with minimal pedicle

**Figure 10:** Axial CT-images of a patient with AIS examined with low-dose CT preoperatively showing narrow pedicles at all vertebral levels (T2-10).



perforation might have better biomechanical strength than those purely enclosed within the medullary canal of the pedicles [183]. Other authors have expressed lower tolerance to pedicle wall violation after their report of about 23 % medial canal encroachment of an average 5 mm in 90 pedicle screws inserted in five fresh-frozen cadavers [184]. Furthermore, medially placed screws inserted at the concave side of the scoliotic curve, especially at the apex, with medial canal encroachment exceeding 4 mm, carry a higher risk of spinal cord injury, as the dural sac and, consequently, the spinal cord shift to the concave side at the scoliotic apex [185].

A literature review of some of the reports of misplacement of pedicle screw based on CT evaluation [71, 78, 171, 172, 178, 182, 186-197] is shown in Table

18. The most commonly reported types of misplacements are the lateral and medial placements. The overall rate of misplacement reported in **paper IV** was 17%. The misplacement rate reported in the literature varies widely from 2.7 % to 50.7 %. Three of the studies dealing exclusively with assessment of pedicular screw placement in scoliosis showed a misplacement rate of 5.7, 18.5%, and 25% [171, 186, 195], while a fourth study that partly included assessment of screw placement following scoliosis surgery showed a misplacement rate of 50.7 %

References	Patient (n)	Screw (n)	Region	Misplacement (%)	Medial, % of total	Lateral, % of total	NVC (n)
Laine [71]	30	152	L	21			1, root lesion
Belmont [78]	40	279	T	43	14	29	0
Liljenqvist* [171]	32	120	T	25	8.3	14.2	0
Uppendra* [172]	24	138	T	50.7	24.6	24.7	2
Uppendra [172]	34	176	T	50	31.8	11.4	0
Kim [178]	557	49	T	6.2	1.8	4.7	0
Gertzbein [182]	40	71	T	30	25.5	4	2, resolved
Silvestre* [186]	25	311	T	5.7	1	3.8	0
Heary [187]	27	185	T	13.5	1.6	11.3	
Lekovic [188]	37	277	T	18	2.2	13	0
Smorgick [189]	25	112	T	12.5			0
Schwarzenbach [190]	29	150	L	2.7		2	6; 5 resolved
Schizas [191]	15	60	L	23.3	11.6	11.6	1, S1-root
Wiesner [192]	51	408	L2-S1	6.6	4.6	1.5	1, L4-root
Sapkas [193]	35	220	T-L	3.63			0
Lehman [194]	60	1023	T1-L4	10.5	8.6	1.9	0
Halm* [195]	25	178	T5-L4	18.5	4.5	12.4	0
Güven [196]	75	379	T8-S2	10	3	5	1, root lesion
Odgers [197]	65	238	T11-L5	10.9	7.6	2.5	2
<b>(paper IV)*</b> [131]	49	873	T1-L5	17	6.1	8	0

**Table 18:** Literature review of some of the reported screw misplacements assessed with postoperative CT. References marked with\* represent studies dealing with assessment of screw placement following scoliosis correction and stabilization.

n: Number, NVC: Neurovascular complications, T: Thoracic, L: Lumbar



among the scoliotic group [172]. By excluding misplacement with pedicular violation of less than 2 mm, the misplacement rate in the latter study decreases to almost 32%. The lowest misplacement rate was reported in a study including 115 patients after posterior scoliosis surgery [186]. These patients were primarily examined with plain radiographs. CT was performed only in 25 patients when the screw position was regarded as questionable. Misplacement rates in plain radiographs versus CT of that study were 1.7 % and 5.7 %, respectively. As other reports [70, 71] showed that CT revealed up to 10 times as many pedicle violations as did plain radiography, the misplacement rate of the above mentioned study [186] is likely underestimated. A misplacement rate of 2.7 % has been reported from a study dealing with screw placement in the lumbar region [190].

### Outcome-based classification of the different types of screw misplacement

**In paper IV** including assessment of screw placement in 873 screws, 149 (17 %) were misplaced. None of these patients with screw misplacement showed evidence of neurovascular complication. From the clinical point of view the medially placed screws and screws whose tip lies in the vicinity of aorta represent the most critical and feared types of misplacement, which should be studied in detail because of an attendant risk for neurovascular complications. Screws with foraminal perforation carry a potential risk for nerve root injury. In our opinion the endplate penetration has to be considered the least injurious of all types of screw misplacement discussed here as we are dealing with a surgical procedure the primary aim of which is spinal fusion. In our opinion pedicle screws with anterior cortical perforation with the screw tip in the vicinity of aorta need to be followed up with a suitable imaging modality, for example CT-angiography, to exclude development of pseudoaneurysm.

With regard to spinal canal encroachment the detailed analysis of the misplaced screws included in **paper IV** revealed a spinal canal encroachment of 5 mm (almost a total screw diameter) at the concave side and up to 7 mm at the convex side of the scoliotic apex with no evidence of neurological deficit. An encroachment of this magnitude may be tolerated providing that neither electrophysiological abnormality is reported during the screw insertion nor neurological deficit occurs after surgery.

## Conclusions and summary of results

- The phantom study has shown that it would be possible to reduce the radiation dose in helical CT examination of the spine without any significant impact on image quality.
- The low-dose spine CT has shown to be a suitable method to implement in the pre- and the postoperative workup of young patients with adolescent idiopathic scoliosis.
- The results of this thesis emphasize the importance of tailoring different CT protocols with different radiation doses adapted to answer the clinical question at issue.
- Using the here proposed grading system, the low-dose spine CT was shown to be a reliable method in the assessment of the accuracy of pedicle screw placement in patients with AIS after posterior corrective surgery using titanium “all pedicle screw construct”.
- Lateral cortical perforation was the most common type of misplacement, followed by medial cortical perforation.
- In the absence of evidence of neurovascular complications, a medial cortical perforation of up to 5 mm on the concave side and 7 mm on the convex side of the scoliotic apex may be tolerated.

## Recommendations

- We recommend using the low-dose spine CT in the perioperative workup of patients with AIS.
- We recommend using our grading system in the assessment of screw placement in the daily clinical practice instead of other grading systems where the degree of screw misplacement is measured in mm.
- The dose reduction system of the CT scanner, if available, should be used.
- When assessing the effective dose the absorbed doses to different organs (e.g. breasts, genital organs and thyroid glands) should be taken into consideration.
- Beside lateral-, medial- and anterior cortical perforations, endplate perforation and foraminal perforation should also be considered when evaluating screw placement.
- Screws with their tip in the vicinity of aorta warrant follow-up (e.g. CT angiography) to exclude vascular complication.

## Sammanfattning på svenska

Skolios är en tredimensionell deformitet med lateral deviation (sidoböjning) av ryggraden i frontalplanet, lordos (hypokyfos) eller kyfos i sagittalplanet och rotation i axialplanet. Den vanligaste formen av skolios är idiopatisk skolios som drabbar unga individer med övervikt för flickor och med maximal ökning av skoliosgraden under tillväxtspurt. Majoriteten av kirurgikrävande skolioser drabbar flickor i pubertetsåldern. De som blir föremål för operation är i de flesta fall i 12-17 års åldern. Dessa patienter brukar följas upp med slätröntgen för att mäta graden av deformiteten. Patienter har på Diagnostiskt centrum för bild- och funktionsmedicin-UMAS, inför planerad skoliosoperation sedan 1998, undersökts med CT (skiktröntgen/datortomografi) enligt ett så kallat Apical Neutral Vertebrae-protokoll (ANV protokoll) eller Kaneda Anterior Spinal Surgery-protokoll (KASS-protokoll). Detta innebär att kotpelaren undersöks med ett begränsat antal snitt över tre kotor, nämligen, i mitten på kotan i skoliosens apex samt i mitten på kotan i skoliosens övre respektive nedre begränsning.

Skolioskirurgin har på senare år utvecklats snabbt med införande av flera nya operationsmetoder. Idag utförs oftast skolioskorrektion och fixation av delar av ryggen med två långa stag och transpedikulära skruvar (skruvar genom kotornas bågar på flera nivåer, inte sällan insättes upp till 20-25 skruvar). Detta kräver kännedom om bågarnas bredd och om graden av rotationsfelställning för att dels kunna välja lämplig skruvstorlek, dels kunna introducera skruven genom pedikeln i korrekt vinkel och på så sätt undvika skruvpassage genom exempelvis ryggmärgskanalen. Vidare är den opererande kirurgen angelägen om att få en postoperativ bild av läget av de inopererade skruvarna och dess relation till ryggmärgskanalen och till omgivningen t ex till aorta. För att besvara samtliga ovannämnda kliniska frågeställningar krävs en spiral CT-undersökning av stora delar av kotpelaren eftersom CT-undersökning enligt det förstnämnda protokollet (KASS/ANV) genererar endast enstaka bilder på delar av tre kotor och således tillåter endast mätning av rotationsgraden på dessa nivåer. En spiral CT-undersökning (före och efter operation, d.v.s. 2 CT undersökningar) med de för närvarande rutinemässiga protokoll vilka används för undersökning av ryggen vid t ex trauma innebär en betydande strålbeklastning.

Avhandlingen består av fyra delarbeten med följande huvudsyften: (1) Optimering av stråldosen vid CT av bröst- och ländrygg hos patienter med

adolescent idiopatisk skolios. (2) Beräkning av stråldosen och inverkan av dosreduktionen på bildkvaliteten vid lågdos CT av ryggen hos patienter med adolescent idiopatisk skolios. (3) Utvärdering av tillförlitligheten av lågdos CT i den pre- och postoperativa utredningen av patienter med adolescent idiopatisk skolios. (4) Klinisk och radiologisk utvärdering av skruvlägen efter bakre skolioskirurgi.

Innan vi ändrade, på ryggkirurgernas önskemål/begäran, vår rutin att, i stället för den gamla CT-undersökningen enligt KASS/ANV protokoll, undersöka ryggen med en lång spiral CT med låg stråldos har vi på Diagnostiskt centrum för bild- och funktionsmedicin-UMAS undersökt möjligheten att maximalt reducera stråldosen och ändå erhålla tillförlitliga bilder med just den relevanta information som klinikerna behöver. Därför har vi först utfört en fantomstudie där fantomen av konstgjort material konstruerat på ett sätt som liknar en människokropp avseende genomsläpplighet av röntgenstrålar, har undersökts med successivt reducerad stråldos. Resultatet av denna studie (**arbete I**) visade att en CT-undersökning av ett c:a 36 cm långt segment av kotpelaren (inkluderande 15 kotor) enligt "lågdosprotokollet" resulterade i en stråldos som var 35 gånger lägre än stråldosen vid CT av thorax och buk efter trauma (20 gånger omräknat i förhållande till scanlängden: 0,01 mSv/cm mot 0,20 mSv/cm) utan någon negativ inverkan på bildkvaliteten. Att ersätta den gamla metoden enligt s k KASS/ANV- protokoll med lågdos CT av ryggen har därefter godkänts av regionala strålskyddskommittén. Den retrospektiva genomgången av patientmaterialet har godkänts av den regionala etiska kommittén.

I **arbete II** har vi beräknat stråldosen och utvärderat inverkan av den betydligt lägre stråldosen på bildkvaliteten genom en subjektiv och en objektiv bedömning av 113 CT undersökningar utförda med lågdos-CT. För jämförelse hade vi 15 slumpmässigt valda CT-undersökningar enligt KASS/ANV- protokoll och 127 CT-trauma undersökningar. Graden av överensstämmelse mellan de 2 granskande radiologer som utförde mätningarna av pedikelvidden, graden av rotationen och en översiktlig bedömning av läget av osteosyntesmaterialet har använts som indikator för bildkvaliteten. Stråldosen vid lågdos-CT var 20 respektive 12 gånger lägre per cm bestrålat område jämfört med CT enligt CT-trauma och KASS/ANV-protokoll. Lågdos-CT har bedömts som en tillförlitlig metod eftersom det rädde mycket god överensstämmelse mellan de två granskande radiologerna beträffande den subjektiva och den objektiva utvärderingen av bildkvaliteten för både de pre- och postoperativa undersökningarna efter bakre skolioskirurgi. Bilderna efter främre skolioskirurgi har bedömts som icke-tillförlitliga i 7 av 17 CT-

undersökningar beroende på att dessa operationer innebar insättning av rostfritt stål som ger upphov till betydande artefakter vid CT-undersökningar.

I **arbete III** har vi utvärderat tillförlitligheten av lågdos-CT vid bedömning av skruvlägen hos 46 patienter som genomgått bakre skolioskirurgi utförd med titanskruvar och stag. Läget av 809 skruvar har bedömts avseende deras relation till respektive pedikel, ryggmärgskanalen, nervrotskanalen och kotornas ändplattor samt omgivande strukturer. För detta ändamål har vi utvecklat ett nytt klassifikationssystem för bedömning av läget av de inopererade skruvarna. Detta arbete har visat att lågdos-CT är en tillförlitlig metod för bedömning huruvida skruvarna är acceptabelt placerade eller ej, skilja mellan dem som är acceptabelt placerade och dem som är partiellt eller totalt utanför pedikelgränsen (kappa-värde för interobserver och intraobserver överensstämmelse på 0,69 respektive 0,70) liksom i bedömning av olika typer av ”icke-optimalt insatta pedikelskruvar”.

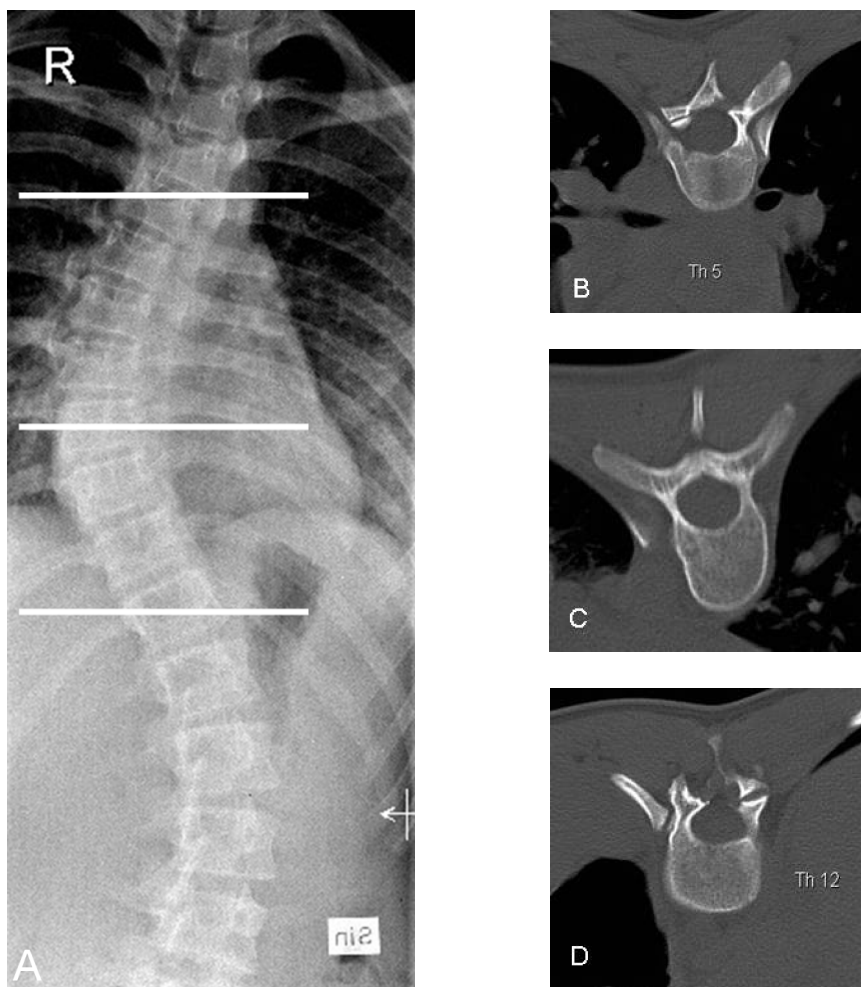
Den kliniska och radiologiska utgången efter bakre skolioskirurgi hos 49 patienter (873 skruvar) har utvärderats i **arbete IV**. 79 % av skruvarna var inopererade i bröstryggen och 31 % i höjd med och kring skoliosens apex. Av 873 skruvar var 149 (17 %) placerade suboptimalt varav 8 % lateraliserade, 6,1 % medialiserade, 1,5 % med skruvspetsen perforerande kotans främre kant, 0,9 % med skruvspetsen perforerande kotans ena ändplatta och 0,5 % passerande genom nervrotskanalen. Ingen av dessa patienter visade tecken på neurovaskulär skada vare sig under operationen (utförd under ryggmärgsövervakning) eller vid den posteroperativa kontrollen 8 veckor efter operationen. De lateraliserade skruvarna var vanligare i bröstryggen än i ländryggen. Övriga typer av ”icke-optimalt insatta pedikelskruvar” var dubbelt så vanliga på vänster sida som ofta är skoliosens konkav sida där anatomiska måtten ofta är mindre än på den konvexa sidan. Omfattningen av felaktigt placerade skruvar ligger i paritet med tidigare resultat rapporterade i litteraturen.

Sammanfattningsvis har denna avhandling visat att lågdos CT är en tillförlitlig metod för den pre- och den postoperativa utredningen av patienter med adolescent idiopatisk skolios och medför en betydande reduktion av stråldosen vilket förhoppningsvis leder till en betydande minskning av risken att utveckla cancer senare i livet.

## Appendices

*ANV-protocol (KASS-protocol):*

**Figure 11:** (A) PA-radiography of a patient with AIS with right sided thoracic curve with apex at T9. (B-D) Axial CT-images obtained according to the previously used ANV-protocol. (B) Axial image at the level T5 (upper end vertebra). (C) Axial image at the level of T9 (Apical vertebra) and (D) Axial image at the level T12 (lower end vertebra).



## Classification of scoliosis:

### *King classification of scoliosis* [198]:

*King type I:* S-shaped curve crossing the midline of the thoracic and lumbar curves. The lumbar curve is larger and more rigid than the thoracic curve. The flexibility index in the bending radiographs is negative.

*King type II:* S-shaped curve where both the thoracic major curve and the lumbar minor curve cross over the midline. The thoracic curve is larger than the lumbar curve.

*King type III:* Thoracic curve where the lumbar curve does not cross the midline.

*King type IV:* Long thoracic curve where the 5th lumbar vertebra is centred over the sacrum, but the 4th lumbar vertebra is already angled in the direction of the curve.

*King type V:* Double thoracic curve where the 1st thoracic vertebra angles into the convexity of the upper curve.

### *Lenke classification of scoliosis* [199, 200]:

- *Curve type.*

**Table 19:** Curve type in Lenke classification

	Name	Proximal T	Main T	TL or L
1	Main T	Non-structural	Structural (M)	Non-structural
2	Double T	Structural	Structural (M)	Non-structural
3	Double major	Non-structural	Structural (M)	Structural
4	Triple major	Structural	Structural (M)	Structural (M)
5	TL/L	Non-structural	Non-structural	Structural (M)
6	TL/L-Main T	Non-structural	Structural	Structural (M)

T: Thoracic, L: Lumbar, TL: Thoracolumbar, M: Major

- *Lumbar spine modifier:*

(a) When the central sacral line (CSL) passes between the pedicles of the apical vertebra.

(b) When CSL touches the concave-side pedicle of the apical vertebra.

(c) When the CSL passes totally medial to the apical vertebra.



- *Thoracic sagittal modifier:*

(-): Hypokyphosis when kyphosis angle T2-T12  $< 10^{\circ}$ .

N: Normal when kyphosis angle T2-T12  $10^{\circ}$ – $40^{\circ}$ .

(+): Hyperkyphosis when kyphosis angle T2-T12  $> 40^{\circ}$ .

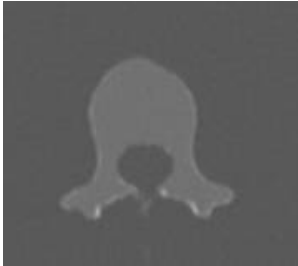*Definitions:*

- Major curve: Largest Cobb measurement. Always structural.
- Minor curve: Structural if the following criteria are fulfilled:
  - (a) Proximal thoracic: Cobb  $\geq 25^{\circ}$  and T2-T5 kyphosis  $\geq 20^{\circ}$ .
  - (b) Main thoracic: Cobb  $\geq 25^{\circ}$  and T10-L2 kyphosis  $\geq 20^{\circ}$ .
  - (c) Thoracolumbar/lumbar: Cobb  $\geq 25^{\circ}$  and T10-L2 kyphosis  $\geq 20^{\circ}$ .
- Scoliosis level:
  - (a) Thoracic: Apex at between T2 and disc level T11-12.
  - (b) Thoracolumbar: Apex at T12-L1.
  - (c) Thoracolumbar/lumbar: Apex between disc level L1-2 and L4.

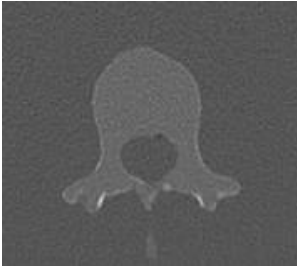**Table 20:** Scan parameters and radiation doses of the different scan settings of the original work of paper I. In scan 3, 4, 9, 10, and 11 the given effective mAs are expressed as image quality reference mAs/effective mAs. Scans parameters written in bold are those reported in the published **Paper I, Table 1–2**

	Slice collimation, mm	Rotation time, sec	Tube voltage, Kv	Effective mAs	CTDI <sub>vol</sub> , mGy	DLP mGy.cm	Effective dose, mSv
<b>1</b>	<b>16x0.75</b>	<b>0.75</b>	<b>120</b>	<b>300</b>	<b>23.40</b>	<b>920</b>	<b>16.60</b>
<b>2</b>	<b>16x0.75</b>	<b>0.75</b>	<b>120</b>	<b>140</b>	<b>10.92</b>	<b>431</b>	<b>7.76</b>
3	16x0.75	0.75	120	300/150	11.70	459	8.00
4	16x0.75	0.75	120	140/68	5.30	208	3.30
<b>5</b>	<b>12x1.5</b>	<b>1</b>	<b>120</b>	<b>60</b>	<b>4.32</b>	<b>24</b>	<b>0.43</b>
6	16x0.75	0.75	80	35	0.91	37	0.59
<b>7</b>	<b>16x0.75</b>	<b>0.75</b>	<b>80</b>	<b>25</b>	<b>0.65</b>	<b>26</b>	<b>0.47</b>
8	16x0.75	0.75	100	20	1.00	41	0.66
9	16x0.75	0.75	80	35/23	0.60	24	0.38
<b>10</b>	<b>16x0.75</b>	<b>0.75</b>	<b>80</b>	<b>25/19</b>	<b>0.51</b>	<b>21</b>	<b>0.38</b>
11	16x0.75	0.75	100	20/15	0.78	31	0.50
<b>12</b>	<b>16x0.75</b>	<b>0.5</b>	<b>80</b>	<b>17</b>	<b>0.44</b>	<b>19</b>	<b>0.34</b>

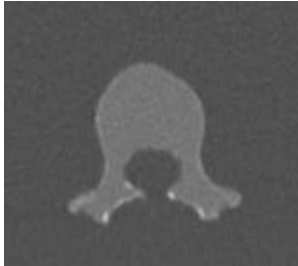
**Figure 12:** Axial images of different scan settings of the original work of **Paper I**. mAs values in images C, D, I, J and K are given as image quality reference mAs /effective mAs.



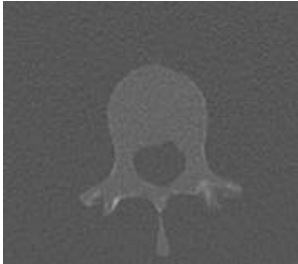
**A: 120 kV; 300 mAs**



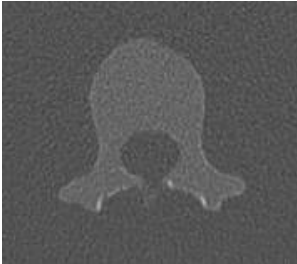**B:120 kV; 140 mAs**



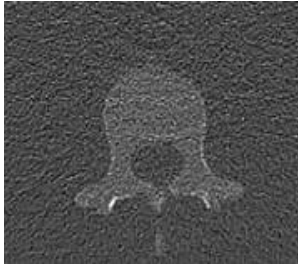
**C:120 kV; 300/150 mAs**



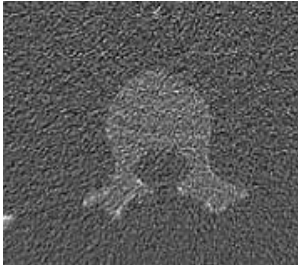
**D:120 kV; 140/68 mAs**



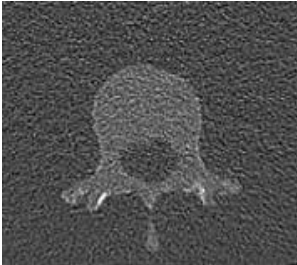
**E:ANV:120 kV;60 mAs**



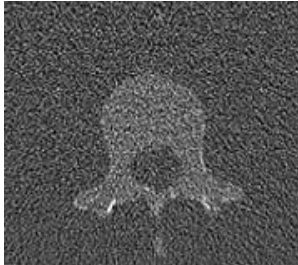
**F: 80 kV; 35 mAs**



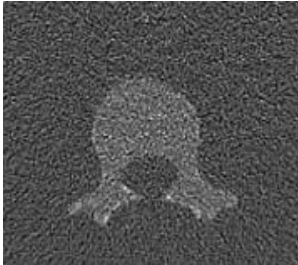
**G: 80 kV; 25 mAs**



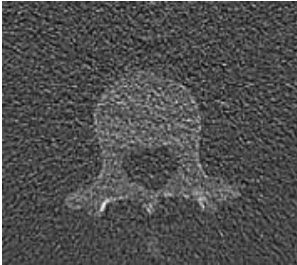
**H:100 kV; 20 mAs**



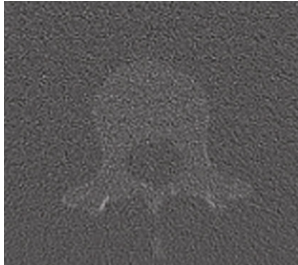
**I:80 kV; 35/23 mAs**



**J:80 kV; 25/19 mAs**

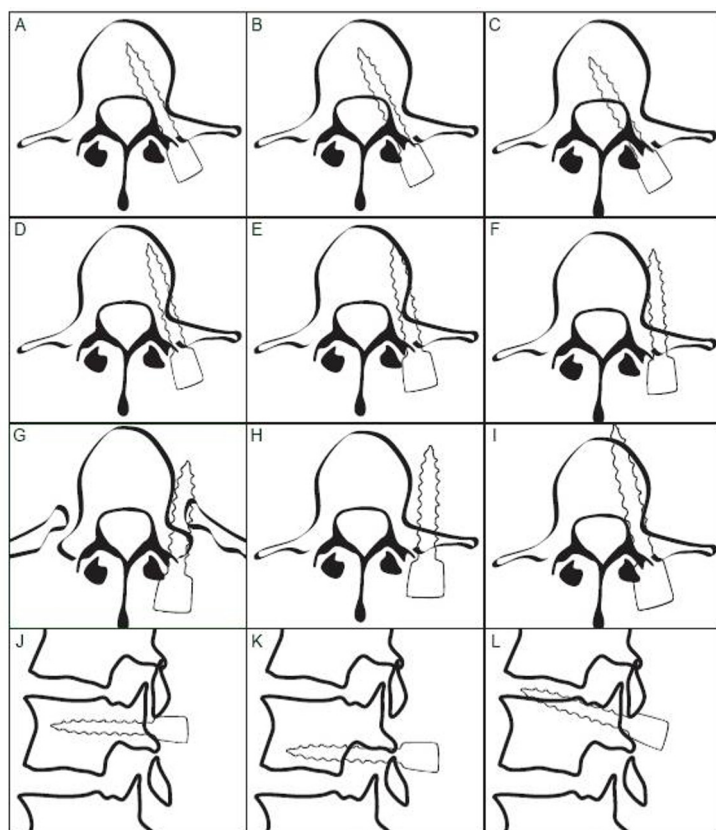


**K:100 kV; 20/15 mAs**



**L:80 kV; 17 mAs**

**Figure 13:** The types of screw placement according to the new grading system and examples of the relationship between different misplaced screws and the surrounding structures. (A) Normally placed screw. (B) MCP grade 1. Screw anchors in the vertebral body. (C) MCP grade 2. Screw anchors in the vertebral body. (D) LCP grade 1. Screw anchors in the vertebral body. (E) LCP grade 1. Screw passes within the vertebral body and abuts its inner cortex. (F) LCP grade 2. Screw abuts outer cortex of the vertebral body and does not anchor in the vertebral body. (G) LCP grade 2. Screw passes through the PRU and does not anchor in the vertebral body. (H) LCP grade 2. Screw with paravertebral passage. (I) ACP. (J) Normally placed screw on sagittal plane. (K) FP. Perforation of underlying neural foramen. (L) EPP: Perforation of upper endplate.



## Appendix 6

**Table 21** shows the 24 paired sample t-tests performed to explore the inter- and intraobserver variations in measurements of pedicular width in scan 1, 5 and 6 with all possible combinations of comparison. Pairs written in bold are those with statistically significant differences in pedicular width measurements and are those shown in Table 3, Paper 1.

Whole phantom	Scan 1: Observer 1, occasion 2	Scan 5, Observer 1, occasion 2
Whole phantom	Scan 1: Observer 1, occasion 1	Scan 5, Observer 1, occasion 1
Whole phantom	Scan 1: Observer 2	Scan 5, Observer 2
Whole phantom	Scan 1: Observer 1, occasion 1	Scan 6, Observer 1, occasion 1
Whole phantom	Scan 1: Observer 1, occasion 1	Scan 1, Observer 2
Whole phantom	Scan 1: Observer 1, occasion 1	Scan 1, Observer 1, occasion 2
Whole phantom	Scan 5: Observer 1, occasion 1	Scan 5, Observer 2
Whole phantom	Scan 5: Observer 1, occasion 1	Scan 5, Observer 1, occasion 2
<b>Whole phantom</b>	<b>Scan 6: Observer 1, occasion 1</b>	<b>Scan 6, Observer 2</b>
Whole phantom	Scan 6: Observer 1, occasion 1	Scan 6, Observer 1, occasion 2
Whole phantom	Scan 1: Observer 1, occasion 2	Scan 6, Observer 1, occasion 2
<b>Whole phantom</b>	<b>Scan 1: Observer 2</b>	<b>Scan 6, Observer 2</b>
Last five vertebral bodies	Scan 1: Observer 1, occasion 2	Scan 5, Observer 1, occasion 2
Last five vertebral bodies	Scan 1: Observer 1, occasion 1	Scan 5, Observer 1, occasion 1
Last five vertebral bodies	Scan 1: Observer 2	Scan 6, Observer 2
<b>Last five vertebral bodies</b>	<b>Scan 1: Observer 1, occasion 1</b>	<b>Scan 6, Observer 1, occasion 1</b>
Last five vertebral bodies	Scan 1: Observer 1, occasion 1	Scan 1, Observer 2
Last five vertebral bodies	Scan 1: Observer 1, occasion 1	Scan 1, Observer 1, occasion 2
Last five vertebral bodies	Scan 5: Observer 1, occasion 1	Scan 5, Observer 2
Last five vertebral bodies	Scan 5: Observer 1, occasion 1	Scan 5, Observer 1, occasion 2
<b>Last five vertebral bodies</b>	<b>Scan 6: Observer 1, occasion 1</b>	<b>Scan 6, Observer 2</b>
<b>Last five vertebral bodies</b>	<b>Scan 1: Observer 1, occasion 2</b>	<b>Scan 6, Observer 1, occasion 2</b>
Last five vertebral bodies	Scan 1: Observer 2	Scan 5, Observer 2
Last five vertebral bodies	Scan 6: Observer 1, occasion 1	Scan 6, Observer 1, occasion 2

**Table 22:** Summary of SSI-report 2008:03 on the radiological examinations performed in Sweden 2005 [109].

	Whole Sweden	Southern Sweden	Highest in Sweden
Population	9 046 752	1 659 837	1 947 433, Stockholm
Number of children: 0-15 y	1 637 400	295 019	367 105, Stockholm
CT-scanner	161	27	33, Western Sweden and Uppsala/Örebro
CT-examinations	651 885	118 861	143 210, Stockholm
CT-examination/1000 inhabitant	72	72	79, northern Sweden
CT-examination/scanner	4049	4402	4774, Stockholm
Number of children examined with CT	17 453	2 604	4089, Stockholm
Number of children examined with CT/1000 children	11	9	12, southern eastern Sweden
Percent of children examined with CT	2.7	2.2	3.1, western Sweden
CT spine 2005	12 229 (2 % of all CT)		

**Table 23:** Detailed scan- and reconstruction parameters of low-dose CT used today in clinical practice.

Scan parameters:			
Tube Voltage	80 kV		
Image quality reference for tube current time product	25 mAs		
Increment	16 X 0.75 mm		
Pitch	1.5		
Rotation time	0.75 s		
Scan time	8.08 s		
Direction	Craniocaudal		
CTDI <sub>vol</sub>	0.65 mGy		
4D (care dose)	Yes		
Reconstruction parameters:			
	<i>First reconstruction</i>	<i>Second reconstruction</i>	<i>Third reconstruction</i>
FOV	180	180	180
Kernel	B70 very sharp	B30 medium	B30s medium
Slice	3 mm	1 mm	0.75 mm
Recon increment	3 mm	0.6 mm	0.6 mm
Window	skeletal	skeletal	skeletal
Reformation	No	MPR	3D (InSpace)

## Acknowledgements

This project of thesis could not have been initiated nor completed without the help and the support of many fantastic persons in my professional and my private life. To them all I would like to express my sincere gratitude.

*Pia Sundgren*, my head supervisor, for excellent and constructive tutorship, for continuous feedback, for your support and help, and for your never ending enthusiasm.

*Acke Ohlin*, my co-supervisor, for your excellent supervising, for your enthusiasm, for your constructive criticism, for being available all the time, and for your friendship.

*Pavel Maly*, my spiritual tutor, for your fantastic help and encouragement throughout my academic work, for your feedback, for your co-authorship, and for your help and support.

*Anita Strömbeck and Angelica Overgaard* for your skillful work during the analysis of this project, for your co-authorship, and for your support.

*Mikael Gunnarsson* for your excellent help and contribution in the development of the method of this project, and for your co-authorship.

*Olle Ekberg*, the professor of my institution, and *Peter Leander*, the head of my department, for your enthusiasm and support and for providing me with optimal working and research environment.

*My colleagues* at the Radiology department especially my colleagues at the Neuroradiology section and Thoracic section for your support and friendship.

*The Staff* at the Neuroradiology section for your friendly treatment and support.

*Eva prahl*, Radiology department, for your great work in correcting and editing, for your help in the final stage of layout and design of the thesis, and for being available and willing to help all the time.

*Jan Åke Nilsson*, Department of Orthopedic Surgery, for your excellent statistical advices.

*Maria Nilsson and Helena Karlsson* for your great administrative help.

*Sandra Diaz* for your help, advice and support at the final stage of my thesis.

*My parents-in-law* for your help and encouragement, and for being available for me and for my family.

*Abraham*, my brother for your love and support.

*Saly, Lina and Linda*, my family for your never ending support, for your patience, and for your love, trust and belief in me.





## References

1. Leatherman KD. *The Management of Spinal Deformities*. London: Wright, 1988
2. Dickson RA, Stamper P, Sharp AM, Harker P. School screening for scoliosis: cohort study of clinical course. *Br Med J* 1980;281:265-267
3. Miller NH, Justice CM, Marosy B, et al. Identification of candidate regions for familial idiopathic scoliosis. *Spine* 2005;30:1181-1187
4. Chan V, Fong GC, Luk KD, et al. A genetic locus for adolescent idiopathic scoliosis linked to chromosome 19p13.3. *Am J Hum Genet* 2002;71:401-406
5. Kouwenhoven JW, Castelein RM. The pathogenesis of adolescent idiopathic scoliosis: review of the literature. *Spine* 2008;33:2898-2908
6. Wynne-Davies R. Familial (idiopathic) scoliosis. A family survey. *J Bone Joint Surg Br* 1968;50:24-30
7. Robin GC, Cohen T. Familial scoliosis. A clinical report. *J Bone Joint Surg Br* 1975;57:146-148
8. Cowell HR, Hall JN, MacEwen GD. Genetic aspects of idiopathic scoliosis. A Nicholas Andry Award essay, 1970. *Clin Orthop Relat Res* 1972;86:121-131
9. Justice CM, Miller NH, Marosy B, Zhang J, Wilson AF. Familial idiopathic scoliosis: evidence of an X-linked susceptibility locus. *Spine* 2003;28:589-594
10. Dickson RA, Sevitt EA. Growth and idiopathic scoliosis. A longitudinal cohort study. *J Bone Joint Surg Br* 1982;64B:385
11. Drummond DS, Rogala EJ. Growth and maturation of adolescents with idiopathic scoliosis. *Spine* 1980;5:507-511
12. Karol LA, Johnston CE, 2nd, Browne RH, Madison M. Progression of the curve in boys who have idiopathic scoliosis. *J Bone Joint Surg Am* 1993;75:1804-1810
13. Stokes IA, Burwell RG, Dangerfield PH. Biomechanical spinal growth modulation and progressive adolescent scoliosis--a test of the 'vicious cycle' pathogenetic hypothesis: summary of an electronic focus group debate of the IBSE. *Scoliosis* 2006;1:16
14. Antoniou J, Arlet V, Goswami T, Aebi M, Alini M. Elevated synthetic activity in the convex side of scoliotic intervertebral discs and endplates compared with normal tissues. *Spine* 2001;26:E198-206
15. Bylski-Austrow DI, Wall EJ, Kolata RJ. *Endoscopic nonfusion spinal hemiepiphysiodesis: preliminary studies in a porcine model*. Ohmsha: IOS Press, Inc, 1999
16. Taylor JR. Scoliosis and growth. Patterns of asymmetry in normal vertebral growth. *Acta Orthop Scand* 1983;54:596-602
17. Knutsson F. A contribution to the discussion of the biological cause of idiopathic scoliosis. *Acta Orthop Scand* 1963;33:98-104
18. Dickson RA. The aetiology of spinal deformities. *Lancet* 1988;1:1151-1155
19. Dickson RA, Lawton JO, Archer IA, Butt WP. The pathogenesis of idiopathic scoliosis. Biplanar spinal asymmetry. *J Bone Joint Surg Br* 1984;66:8-15
20. Deacon P, Flood BM, Dickson RA. Idiopathic scoliosis in three dimensions. A radiographic and morphometric analysis. *J Bone Joint Surg Br* 1984;66:509-512

21. Cheung CS, Lee WT, Tse YK. Abnormal peri-pubertal anthropometric measurements and growth pattern in adolescent idiopathic scoliosis: a study of 598 patients. *Spine* 2003;28:2152-2157
22. Nissinen M, Heliovaara M, Seitsamo J, Poussa M. Trunk asymmetry, posture, growth, and risk of scoliosis. A three-year follow-up of Finnish prepubertal school children. *Spine* 1993;18:8-13
23. Bick EM, Barash ES, Lehman L. Congenital scoliosis without vertebral anomaly; the vertebral histology of two cases. *Clin Orthop* 1958;12:285-290
24. Zaleske DJ, Ehrlich MG, Hall JE. Association of glycosaminoglycan depletion and degradative enzyme activity in scoliosis. *Clin Orthop Relat Res* 1980;177-181
25. Lawton JO, Dickson RA. The experimental basis of idiopathic scoliosis. *Clin Orthop Relat Res* 1986;9-17
26. D ppe H, Ohlin A. *Danielsson och Willners Barnortopedi. Adolescent idiopatisk skolios*. Lund: Studentlitteratur AB, 2007
27. Machida M, Saito M, Dubousset J, Yamada T, Kimura J, Shibasaki K. Pathological mechanism of idiopathic scoliosis: experimental scoliosis in pinealectomized rats. *Eur Spine J* 2005;14:843-848
28. Machida M, Murai I, Miyashita Y, Dubousset J, Yamada T, Kimura J. Pathogenesis of idiopathic scoliosis. Experimental study in rats. *Spine* 1999;24:1985-1989
29. Smit TH. The use of a quadruped as an in vivo model for the study of the spine - biomechanical considerations. *Eur Spine J* 2002;11:137-144
30. Castelein RM, van Dieen JH, Smit TH. The role of dorsal shear forces in the pathogenesis of adolescent idiopathic scoliosis--a hypothesis. *Med Hypotheses* 2005;65:501-508
31. Oda I, Abumi K, Cunningham BW, Kaneda K, McAfee PC. An in vitro human cadaveric study investigating the biomechanical properties of the thoracic spine. *Spine* 2002;27:E64-70
32. Kouwenhoven JW, Smit TH, van der Veen AJ, Kingma I, van Dieen JH, Castelein RM. Effects of dorsal versus ventral shear loads on the rotational stability of the thoracic spine: a biomechanical porcine and human cadaveric study. *Spine* 2007;32:2545-2550
33. Kouwenhoven JW, Bartels LW, Vincken KL, et al. The relation between organ anatomy and pre-existent vertebral rotation in the normal spine: magnetic resonance imaging study in humans with situs inversus totalis. *Spine* 2007;32:1123-1128
34. Lidstrom J, Friberg S, Lindstrom L, Sahlstrand T. Postural control in siblings to scoliosis patients and scoliosis patients. *Spine* 1988;13:1070-1074
35. Robb JE, Conner AN, Stephenson JB. Normal electroencephalograms in idiopathic scoliosis. *Acta Orthop Scand* 1986;57:220-221
36. Porter RW. Can a short spinal cord produce scoliosis? *Eur Spine J* 2001;10:2-9
37. Porter RW. The pathogenesis of idiopathic scoliosis: uncoupled neuro-osseous growth? *Eur Spine J* 2001;10:473-481
38. Pincott JR, Taffs LF. Experimental scoliosis in primates: a neurological cause. *J Bone Joint Surg Br* 1982;64:503-507
39. Rinsky LA, Gamble JG. Adolescent idiopathic scoliosis. *West J Med* 1988;148:182-191

40. Sahlstrand T, Petruson B. A study of labyrinthine function in patients with adolescent idiopathic scoliosis. I. An electro-nystagmographic study. *Acta Orthop Scand* 1979;50:759-769
41. Sevastik JA. Dysfunction of the autonomic nerve system (ANS) in the aetiopathogenesis of adolescent idiopathic scoliosis. *Stud Health Technol Inform* 2002;88:20-23
42. Hagglund G, Karlberg J, Willner S. Growth in girls with adolescent idiopathic scoliosis. *Spine* 1992;17:108-111
43. Agadir M, Sevastik B, Sevastik JA, Persson A, Isberg B. Induction of scoliosis in the growing rabbit by unilateral rib-growth stimulation. *Spine* 1988;13:1065-1069
44. Michelsson JE. The development of spinal deformity in experimental scoliosis. *Acta Orthop Scand Suppl* 1965:Suppl 81:81-91
45. Sevastik J, Burwell RG, Dangerfield PH. A new concept for the etiopathogenesis of the thoracospinal deformity of idiopathic scoliosis: summary of an electronic focus group debate of the IBSE. *Eur Spine J* 2003;12:440-450
46. Cheng JC, Guo X. Osteopenia in adolescent idiopathic scoliosis. A primary problem or secondary to the spinal deformity? *Spine* 1997;22:1716-1721
47. Kindsfater K, Lowe T, Lawellin D, Weinstein D, Akmakjian J. Levels of platelet calmodulin for the prediction of progression and severity of adolescent idiopathic scoliosis. *J Bone Joint Surg Am* 1994;76:1186-1192
48. Lowe T, Lawellin D, Smith D, et al. Platelet calmodulin levels in adolescent idiopathic scoliosis: do the levels correlate with curve progression and severity? *Spine* 2002;27:768-775
49. Pedrini VA, Ponseti IV, Dohrman SC. Glycosaminoglycans of intervertebral disc in idiopathic scoliosis. *J Lab Clin Med* 1973;82:938-950
50. Francis MJ, Sanderson MC, Smith R. Skin collagen in idiopathic adolescent scoliosis and Marfan's syndrome. *Clin Sci Mol Med* 1976;51:467-474
51. Uden A, Nilsson IM, Willner S. Bleeding time and scoliosis. *Acta Orthop Scand* 1982;53:73-77
52. Hadley-Miller N, Mims B, Milewicz DM. The potential role of the elastic fiber system in adolescent idiopathic scoliosis. *J Bone Joint Surg Am* 1994;76:1193-1206
53. Yarom R, Wolf E, Robin GC. Deltoid pathology in idiopathic scoliosis. *Spine* 1982;7:463-470
54. Cronis S, Russell AY. Orthopedic screening of children in Delaware public schools. *Del Med J* 1965;37:89-92
55. Kane WJ, Moe JH. A scoliosis-prevalence survey in Minnesota. *Clin Orthop Relat Res* 1970;69:216-218
56. Adler NS, Csongradi J, Bleck EE. School screening for scoliosis. One experience in California using clinical examination and moire photography. *West J Med* 1984;141:631-633
57. Shands AR, H.B. E. The incidence of scoliosis in the State of Delaware. A study of 50,000 minifilms of the chest made during a survey for tuberculosis. *J Bone Joint Surg [Am]* 1955;37:1232-1249
58. Brooks HL, Azen SP, Gerberg E, Brooks R, Chan L. Scoliosis: A prospective epidemiological study. *J Bone Joint Surg Am* 1975;57:968-972
59. Willner S, Uden A. A prospective prevalence study of scoliosis in Southern Sweden. *Acta Orthop Scand* 1982;53:233-237

60. Ramirez N, Johnston CE, Browne RH. The prevalence of back pain in children who have idiopathic scoliosis. *J Bone Joint Surg Am* 1997;79:364-368
61. Cobb JR. Outline for the study of scoliosis. In: *American Academy of Orthopaedic Surgeons Instructional Course Lectures* 1948:261
62. Whittle MW, Evans M. Instrument for measuring the Cobb angle in scoliosis. *Lancet* 1979;1:414
63. Ferguson A. The study and treatment of scoliosis. *South Med J* 1930;23:116-120
64. Perdriolle R, Vidal J. Thoracic idiopathic scoliosis curve evolution and prognosis. *Spine* 1985;10:785-791
65. Suk SI, Lee CK, Min HJ, Cho KH, Oh JH. Comparison of Cotrel-Dubousset pedicle screws and hooks in the treatment of idiopathic scoliosis. *Int Orthop* 1994;18:341-346
66. Coe JD, Shaffrey CI, Alert V, Berven SH. Complications in Spinal Fusion for Adult Scoliosis. A Report of the Scoliosis Research Society Morbidity and Mortality Committee. Abstract from the 2006 SRS Annual Meeting. Available online via: <http://www.spineuniverse.com/displayarticle.php/article2074.html>
67. Aaro S, Dahlborn M, Svensson L. Estimation of vertebral rotation in structural scoliosis by computer tomography. *Acta Radiol Diagn (Stockh)* 1978;19:990-992
68. Berlemann U, Heini P, Muller U, Stoupis C, Schwarzenbach O. Reliability of pedicle screw assessment utilizing plain radiographs versus CT reconstruction. *Eur Spine J* 1997;6:406-410
69. Learch TJ, Massie JB, Pathria MN, Ahlgren BA, Garfin SR. Assessment of pedicle screw placement utilizing conventional radiography and computed tomography: a proposed systematic approach to improve accuracy of interpretation. *Spine* 2004;29:767-773
70. Farber GL, Place HM, Mazur RA, Jones DE, Damiano TR. Accuracy of pedicle screw placement in lumbar fusions by plain radiographs and computed tomography. *Spine* 1995;20:1494-1499
71. Laine T, Makitalo K, Schlenszka D, Tallroth K, Poussa M, Alho A. Accuracy of pedicle screw insertion: a prospective CT study in 30 low back patients. *Eur Spine J* 1997;6:402-405
72. Weinstein SL, Ponseti IV. Curve progression in idiopathic scoliosis. *J Bone Joint Surg Am* 1983;65:447-455
73. Maiocco B, Deeney VF, Coulon R, Parks PF, Jr. Adolescent idiopathic scoliosis and the presence of spinal cord abnormalities. Preoperative magnetic resonance imaging analysis. *Spine* 1997;22:2537-2541
74. Benli IT, Un A, Karaaslan S, Cinemre O, Gurses L, Hekimoglu B. [Neural axis abnormalities detected by preoperative magnetic resonance imaging in patients with type III idiopathic scoliosis]. *Acta Orthop Traumatol Turc* 2002;36:354-361
75. Winter RB, Lonstein JE, Heithoff KB, Kirkham JA. Magnetic resonance imaging evaluation of the adolescent patient with idiopathic scoliosis before spinal instrumentation and fusion. A prospective, double-blinded study of 140 patients. *Spine* 1997;22:855-858
76. Barnes PD, Brody JD, Jaramillo D, Akbar JU, Emans JB. Atypical idiopathic scoliosis: MR imaging evaluation. *Radiology* 1993;186:247-253
77. Whitecloud TS, Skalley TC, Cook SD, Morgan EL. Roentgenographic measurement of pedicle screw penetration. *Clin Orthop Relat Res* 1989:57-68
78. Belmont PJ, Jr., Klemme WR, Dhawan A, Polly DW, Jr. In vivo accuracy of thoracic pedicle screws. *Spine* 2001;26:2340-2346

79. Weinstein JN, Spratt KF, Spengler Dea. Spinal pedicle fixation: reliability and validity of roentgenogram-based assessment and surgical factors on successful screw placement. *Spine* 1991;5:576-579
80. Rao G, Brodke DS, Rondina M, Bacchus K, Dailey AT. Inter- and intraobserver reliability of computed tomography in assessment of thoracic pedicle screw placement. *Spine* 2003;28:2527-2530
81. Yoo JU, Ghanayem A, Petersilge C, Lewin J. Accuracy of using computed tomography to identify pedicle screw placement in cadaveric human lumbar spine. *Spine* 1997;22:2668-2671
82. Krag MH, Weaver DL, Beynnon BD, Haugh LD. Morphometry of the thoracic and lumbar spine related to transpedicular screw placement for surgical spinal fixation. *Spine* 1988;13:27-32
83. Treatment of Adolescent idiopathic scoliosis. Scoliosis Research Society, 2009. Available online: <http://www.srs.org/patients/adolescent/idiopathic/treatment.php>
84. Risser JC, Ferguson AB. Scoliosis: its prognosis. *J Bone Joint Surg* 1936;18:667-670
85. Mehta MH. The rib-vertebra angle in the early diagnosis between resolving and progressive infantile scoliosis. *J Bone Joint Surg Br* 1972;54:230-243
86. Marketos SG, Skiadas P. Hippocrates. The father of spine surgery. *Spine* 1999;24:1381-1387
87. Knoeller SM, Seifried C. Historical perspective: history of spinal surgery. *Spine* 2000;25:2838-2843
88. LeVay D. *The History of Orthopaedics: An Account of the Study and Practice of Orthopaedics from the Earliest Times to the Modern Era*. Park Ridge, NJ: Parthenon Publishing, 1990
89. Hibbs R. A report of fifty-nine cases of scoliosis treated by the fusion operation. *J Bone Joint Surg* 1924;6:3
90. Shands AR, Barr JS, Colonna PC. End-Result Study of the Treatment of Idiopathic Scoliosis: Report of the Research Committee of the American Orthopaedic Association. *J Bone Joint Surg* 1941;23:963-977
91. Harrington PR. Treatment of scoliosis: correction and internal fixation by spine instrumentation. June 1962. *J Bone Joint Surg Am* 2002;84-A:316
92. Luque ER. The anatomic basis and development of segmental spinal instrumentation. *Spine* 1982;7:256-259
93. Cotrel Y, Dubousset J, Guillaumat M. New universal instrumentation in spinal surgery. *Clin Orthop Relat Res* 1988;227:10-23
94. Roy-Camille R, Saillant G, Mazel C. Internal fixation of the lumbar spine with pedicle screw plating. *Clin Orthop Relat Res* 1986:7-17
95. Roy-Camille R. [Current trends in surgery of the spine]. *Int Orthop* 1989;13:81-87
96. Dwyer AF, Schafer MF. Anterior approach to scoliosis. Results of treatment in fifty-one cases. *J Bone Joint Surg Br* 1974;56:218-224
97. Zielke K, Stunkat R, Duquesne Jea. Ventrale derotations spondylodese. *Orthop Praxis* 1975;11:562-565
98. Kaneda K. *Anterior approach and Kaneda instrumentation for lesions of the thoracic and lumbar spine*. Philadelphia: J.B. Lippincott & Co, 1991
99. Albert TJ, Jones AM, Balderston RA. *Spinal instrumentation*, Third ed. Philadelphia: WB Saunders, 1992

100. Roy-Camille R, Roy-Camille M, Demeulenaere C. [Osteosynthesis of dorsal, lumbar, and lumbosacral spine with metallic plates screwed into vertebral pedicles and articular apophyses]. *Presse Med* 1970;78:1447-1448
101. Luque ER. Interpeduncular segmental fixation. *Clin Orthop Relat Res* 1986;54-57
102. Suk SI, Lee CK, Kim WJ, Chung YJ, Park YB. Segmental pedicle screw fixation in the treatment of thoracic idiopathic scoliosis. *Spine* 1995;20:1399-1405
103. Rajasekaran S, Dorgan JC, Taylor JF, Dangerfield PH. Eighteen-level analysis of vertebral rotation following Harrington-Luque instrumentation in idiopathic scoliosis. *J Bone Joint Surg Am* 1994;76:104-109
104. Lenke LG, Bridwell KH, Baldus C, Blanke K, Schoenecker PL. Cotrel-Dubousset instrumentation for adolescent idiopathic scoliosis. *J Bone Joint Surg Am* 1992;74:1056-1067
105. Rehani MM, Berry M. Radiation doses in computed tomography. The increasing doses of radiation need to be controlled. *BMJ* 2000;320:593-594
106. Shrimpton PC, Jones DG, Hillier MC. Survey of CT practice in the UK, Part 2: Dosimetric aspects. In: London: HMSO, 1991
107. Royal College of Radiologists. *Making the best use of department of clinical radiology: guidelines for doctors*. 4th ed, London, 1998
108. Bongartz G, Golding SJ, Jurik AG, et al. European Guidelines for Multislice Computed Tomography. 2004 CT Quality Criteria. Appendix A: MSCT Dosimetry. In: Funded by the European Commission. , 2004. Contract number FIGM-CT2000-20078-CT-TIP. March 2004. Available online via: [http://www.msct.eu/CT\\_Quality\\_Criteria.htm#Download%20the%202004%20CT%20Quality%20Criteria](http://www.msct.eu/CT_Quality_Criteria.htm#Download%20the%202004%20CT%20Quality%20Criteria)
109. Almén A, Richter S, Leitz W. Radiological examinations in Sweden during 2005. SSI report 2008:03. Swedish Radiation Protection Authority. In Swedish. Available online via [www.ssi.se](http://www.ssi.se).
110. Pierce DA, Preston DL. Radiation-related cancer risks at low doses among atomic bomb survivors. *Radiat Res* 2000;154:178-186
111. Cohen BL. Cancer risk from low-level radiation. *AJR Am J Roentgenol* 2002;179:1137-1143
112. A Nested Case-Control Study of Leukemia and Ionizing Radiation at the Portsmouth Naval Shipyard. National Institute for Occupational Safety and Health. NIOSH Publication No. 2005-104. 2005. Available online via <http://www.cdc.gov/niosh/docs/2005-104/pdfs/2005-104.pdf>.
113. Remy-Jardin M, Remy J. Spiral CT angiography of the pulmonary circulation. *Radiology* 1999;212:615-636
114. Brenner D, Elliston C, Hall E, Berdon W. Estimated risks of radiation-induced fatal cancer from pediatric CT. *AJR Am J Roentgenol* 2001;176:289-296
115. Almén A, Leitz W, Nyman U. Appendix III: Stråldoser och riskuppskattning vid radiologisk diagnostik. *Blodpropp - Förebyggande, Diagnostik och Behandling av Venös Tromboembolism, Volym III*:537-546. Available online via: <http://www.arwen.se/radiologi/VTE/Volym%203/Appendix%20III%20Straldoser%20och%20riskuppskattning%20vid%20radiologisk%20diagnostik.pdf>
116. Hoffman DA, Lonstein JE, Morin MM, Visscher W, Harris BS, 3rd, Boice JD, Jr. Breast cancer in women with scoliosis exposed to multiple diagnostic x rays. *J Natl Cancer Inst* 1989;81:1307-1312

117. Morin Doody M, Lonstein JE, Stovall M, Hacker DG, Luckyanov N, Land CE. Breast cancer mortality after diagnostic radiography: findings from the U.S. Scoliosis Cohort Study. *Spine* 2000;25:2052-2063
118. McCollough CH, Zink FE. Performance evaluation of a multi-slice CT system. *Med Phys* 1999;26:2223-2230
119. Frush DP. Radiation dose and image quality for pediatric CT: Clinical considerations. *Categorical Course in Physics presented at the Radiological Society of North America*. Chicago, IL, 2006
120. Mulkens TH, Bellinck P, Baeyaert M, et al. Use of an automatic exposure control mechanism for dose optimization in multi-detector row CT examinations: clinical evaluation. *Radiology* 2005;237:213-223
121. Application Guide. SIEMENS, SOMATOM Sensation 64 In: Siemens AG Medical Solution, Computed Tomography 2004:29-32
122. Application Guide. SIEMENS, SOMATOM Sensation 16 In: Siemens AG Medical Solution, Computed Tomography, 2003:62-63 and 140-141
123. Khursheed A, Hillier MC, Shrimpton PC, Wall BF. Influence of patient age on normalized effective doses calculated for CT examinations. *Br J Radiol* 2002;75:819-830
124. Abul-Kasim K, Gunnarsson M, Maly P, Ohlin A, Sundgren P. Radiation dose optimization in CT planning of corrective scoliosis surgery. A phantom study. *The Neuroradiology Journal* 2008;21:374-382
125. Abul-Kasim K, Overgaard A, Maly P, Ohlin A, Gunnarsson M, Sundgren PC. Low-dose helical computed tomography (CT) in the perioperative workup of adolescent idiopathic scoliosis. *Eur Radiol* 2009;19:610-618
126. Lee SM, Suk SI, Chung ER. Direct Vertebral Rotation: A New Technique of Three-Dimensional Deformity Correction With Segmental Pedicle Screw Fixation in Adolescent Idiopathic Scoliosis. *Spine* 2004;29:343-349
127. Landis JR, Koch GG. The measurement of observer agreement for categorical data. *Biometrics* 1977;33:159-174
128. Landis JR, Koch GG. An application of hierarchical kappa-type statistics in the assessment of majority agreement among multiple observers. *Biometrics* 1977;33:363-374
129. Garson GD. Reliability analysis. In 2008. Available online via: <http://www2.chass.ncsu.edu/garson/pa765/reliab.htm>
130. Abul-Kasim K, Strömbeck A, Ohlin A, Maly P, Sundgren PC. Reliability of low radiation dose CT in the assessment of screw placement after posterior scoliosis surgery, evaluated with a new grading system. Accepted for publication in *Spine*. Scheduled for publication 2009, May 1.
131. Abul-Kasim K, Ohlin A, Strömbeck A, Maly P, Sundgren PC. Radiological and clinical outcome of screw placement in idiopathic scoliosis using computed tomography with low radiation dose. Submitted to *Spine* 2009, January 5.
132. Levatter RE, Brenner DJ, Elliston CD. Radiation risk of body CT: What to tell our patients and other questions [Letter to the Editor]. *Radiology* 2005;234:968-970
133. U.S. exposure to medical radiation soars, ACR issues new white paper on dosage. Diagnostic Imaging Intelligence Report, June 2007. Available online via: [http://www.g2reports.com/issues/DIIR/2007\\_6/1612608-1.html](http://www.g2reports.com/issues/DIIR/2007_6/1612608-1.html)
134. Hart D, Wall BF. UK population dose from medical X-ray examinations. *Eur J Radiol* 2004;50:285-291



135. Brugmans MJ, Buijs WC, Geleijns J, Lembrechts J. Population exposure to diagnostic use of ionizing radiation in The Netherlands. *Health Phys* 2002;82:500-509
136. Brix G, Nagel HD, Stamm G, et al. Radiation exposure in multi-slice versus single-slice spiral CT: results of a nationwide survey. *Eur Radiol* 2003;13:1979-1991
137. Geijer H, Norrman E, Persliden J. Optimizing the tube potential for lumbar spine radiography with a flat-panel digital detector. *Br J Radiol* 2009;82:62-68
138. Publication 60. Recommendations of the International Commission on Radiological Protection. Annals of the ICRP. 1990, Vol 21, No 1-3.
139. Wintermark M, Mouhsine E, Theumann N, et al. Thoracolumbar spine fractures in patients who have sustained severe trauma: depiction with multi-detector row CT. *Radiology* 2003;227:681-689
140. Nishizawa K, Matsumoto M, Iwai K, Tonari A, Yoshida T, Takayama M. Dose evaluation and effective dose estimation from multi detector CT. *Igaku Butsuri* 2002;22:152-158
141. Tsapaki V, Kottou S, Papadimitriou D. Application of European Commission reference dose levels in CT examinations in Crete, Greece. *Br J Radiol* 2001;74:836-840
142. Heggie JC, Kay JK, Lee WK. Importance in optimization of multi-slice computed tomography scan protocols. *Australas Radiol* 2006;50:278-285
143. Åkerblom G, Falk R, Lindgren J, Mjönes L, Östergren I, Söderman A-Lea. Natural radioactivity in Sweden, exposure to internal radiation. Radiological Protection in Transition. Proceedings of the XIV Regular Meeting of the Nordic Society for Radiation Protection. Given as SSI-report SSI 2005:15. Available online via [www.ssi.se](http://www.ssi.se).
144. Franic M, Kovac V. Anterior instrumentation for correction of adolescent thoracic idiopathic scoliosis: historic prospective study. *Croat Med J* 2006;47:239-245
145. Statens strålskyddsinstitutets föreskrifter och allmänna råd om diagnostiska standarddoser och referensnivåer inom diagnostisk röntgendiagnostik. SSI FS 2002:02. Available online via [www.ssi.se](http://www.ssi.se).
146. Leitz W, Almén A. The patients radiation doses in diagnostic radiology in Sweden 1999-2006. SSI report 2008:02. Swedish Radiation Protection Authority. In Swedish. Available online via [www.ssi.se](http://www.ssi.se).
147. Brenner DJ, Hall EJ. Computed tomography--an increasing source of radiation exposure. *N Engl J Med* 2007;357:2277-2284
148. Coursey CA, Frush DP. CT and Radiation: What Radiologists Should Know. Techniques for Decreasing Radiation Dose. *Appl Radiol* 2008;37:22-29. Available online via: [http://www.medscape.com/viewarticle/572551\\_1](http://www.medscape.com/viewarticle/572551_1)
149. McNitt-Gray MF. AAPM/RSNA Physics Tutorial for Residents: Topics in CT. Radiation dose in CT. *Radiographics* 2002;22:1541-1553
150. Wintermark M, Maeder P, Verdun FR, et al. Using 80 kVp versus 120 kVp in perfusion CT measurement of regional cerebral blood flow. *AJNR Am J Neuroradiol* 2000;21:1881-1884
151. Frush DP, Donnelly LF, Rosen NS. Computed tomography and radiation risks: what pediatric health care providers should know. *Pediatrics* 2003;112:951-957
152. Frush DP, Slack CC, Hollingsworth CL, et al. Computer-simulated radiation dose reduction for abdominal multidetector CT of pediatric patients. *AJR Am J Roentgenol* 2002;179:1107-1113

153. Smergel E, Benson D. Radiation dose on pediatric CT: losing track of time. *AJR Am J Roentgenol* 2002;178:507-508
154. Hamberg LM, Rhea JT, Hunter GJ, Thrall JH. Multi-detector row CT: radiation dose characteristics. *Radiology* 2003;226:762-772
155. Smith AB, Dillon WP, Gould R, Wintermark M. Radiation dose-reduction strategies for neuroradiology CT protocols. *AJNR Am J Neuroradiol* 2007;28:1628-1632
156. Huda W, Slone R. *Review of Radiologic Physics*. 2nd ed. Baltimore MD: Lippincott Williams & Wilkins, 2003
157. Parker M, Chung J, Fatouros P, Hoots J, Kelleher N, Benedict S. Reduction of Radiation Dose to the Female Breast: Preliminary Data with a Custom-Designed Tungsten-Antimony Composite Breast Shield. *The Journal of Applied Research* 2006;6:230-239
158. Fricke BL, Donnelly LF, Frush DP, et al. In-plane bismuth breast shields for pediatric CT: effects on radiation dose and image quality using experimental and clinical data. *AJR Am J Roentgenol* 2003;180:407-411
159. Kachelriess M, Watzke O, Kalender WA. Generalized multi-dimensional adaptive filtering for conventional and spiral single-slice, multi-slice, and cone-beam CT. *Med Phys* 2001;28:475-490
160. Kalra MK, Wittram C, Maher MM, et al. Can noise reduction filters improve low-radiation-dose chest CT images? Pilot study. *Radiology* 2003;228:257-264
161. Vande Berg B, Malghem J, Maldague B, Lecouvet F. Multi-detector CT imaging in the postoperative orthopedic patient with metal hardware. *Eur J Radiol* 2006;60:470-479
162. Primak AN, McCollough CH, Bruesewitz MR, Zhang J, Fletcher JG. Relationship between noise, dose, and pitch in cardiac multi-detector row CT. *Radiographics* 2006;26:1785-1794
163. Månsson LG. Methods for the evaluation of image quality: A review. *Radiat Prot Dosimetry* 2000;90:89-99
164. Vucich JJ, Goodenough DJ, Lewicki A, Briefel E, Weaver KE. *Use of Anatomical Criteria in Screen/Film Selection for Portable Chest X-ray Procedures*. In: *Optimization of Chest Radiography*: J. Cameron, HHS Publication (FDA), 1980
165. Ho E, Upadhyay SS, Chan FL, Hsu LC, Leong JC. New methods of measuring vertebral rotation from computed tomographic scans. *Spine* 1993;18:1173-1177
166. Krismer M, Sterzinger W, Haid C, Frischhut B, Bauer R. Axial rotation measurement of scoliotic vertebrae by means of computed tomography scans. *Spine* 1996;21:576-581
167. Gocen S, Havitcioglu H, Alici E. A new method to measure vertebral rotation from CT scans. *Eur Spine J* 1999;8:261-265
168. Krismer M, Chen AM, Steinlechner M, Haid C, Lener M, Wimmer C. Measurement of vertebral rotation: a comparison of two methods based on CT scans. *J Spinal Disord* 1999;12:126-130
169. Gocen S, Aksu MG, Baktiroglu L, Ozcan O. Evaluation of computed tomographic methods to measure vertebral rotation in adolescent idiopathic scoliosis: an intraobserver and interobserver analysis. *J Spinal Disord* 1998;11:210-214
170. Udayasankar UK, Li J, Kalra MKea. Ultra-low-dose MDCT of abdomen and pelvis in patients with acute nonspecific abdominal pain: Impact on patient care and management. *Am J Roentgenol* 2007;188:A27-A29

171. Liljenqvist UR, Halm HF, Link TM. Pedicle screw instrumentation of the thoracic spine in idiopathic scoliosis. *Spine* 1997;22:2239-2245
172. Upendra BN, Meena D, Chowdhury B, Ahmad A, Jayaswal A. Outcome-based classification for assessment of thoracic pedicular screw placement. *Spine* 2008;33:384-390
173. Suk SI, Kim WJ, Lee SM, Kim JH, Chung ER. Thoracic pedicle screw fixation in spinal deformities: are they really safe? *Spine* 2001;26:2049-2057
174. Yalcin S, Guven O. Reversible anterior cord syndrome due to penetration of the spinal canal by pedicular screws. *Paraplegia* 1995;33:423-425
175. Papin P, Arlet V, Marchesi Dea. Unusual presentation of spinal cord compression related to misplaced pedicle screws in thoracic scoliosis. *Eur Spine J* 1999;8:156-160
176. Choi JB, Han JO, Jeong JW. False aneurysm of the thoracic aorta associated with an aorto-chest wall fistula after spinal instrumentation. *J Trauma* 2001;50:140-143
177. Minor ME, Morrissey NJ, Peress R, et al. Endovascular treatment of an iatrogenic thoracic aortic injury after spinal instrumentation: case report. *J Vasc Surg* 2004;39:893-896
178. Kim YJ, Lenke LG, Bridwell KH, Cho YS, Riew KD. Free hand pedicle screw placement in the thoracic spine: is it safe? 2004;29:333-342
179. Liljenqvist U, Lepsien U, Hackenberg L, Niemeyer T, Halm H. Comparative analysis of pedicle screw and hook instrumentation in posterior correction and fusion of idiopathic thoracic scoliosis. *Eur Spine J* 2002;11:336-343
180. Kosmopoulos V, Schizas C. Pedicle screw placement accuracy: a meta-analysis. *Spine* 2007;32:E111-120
181. Parent S, Labelle HL, Skalli Wea. Thoracic Pedicles Morphometry in Vertebrae from Scoliotic Spines. In: *Abstract from the SRS 2002 Annual Meeting*, 2002. Available online via: <http://www.spineuniverse.com/displayarticle.php/article2290.html>
182. Gertzbein SD, Robbins SE. Accuracy of pedicular screw placement in vivo. *Spine* 1990;15:11-14
183. Reichle E, Morlock M, Sellenschloh K, Eggers C. [Definition of pedicle malposition. Primary stability and loosening characteristics of pedicle screws in relation to position: spongy anchoring, cortical anchoring, perforation and malposition]. *Orthopade* 2002;31:402-405
184. Vaccaro AR, Rizzolo SJ, Balderston RA, et al. Placement of pedicle screws in the thoracic spine. Part II: An anatomical and radiographic assessment. *J Bone Joint Surg Am* 1995;77:1200-1206
185. Rauschnig W. Anterior surgery of the thoracolumbar junction and the lumbar spine. Anatomy, complications and safeguards. In: *Anterior spine surgery: Standards and New Techniques*. Berlin, Germany, 1995
186. Di Silvestre M, Parisini P, Lolli F, Bakaloudis G. Complications of thoracic pedicle screws in scoliosis treatment. *Spine* 2007;32:1655-1661
187. Heary RF, Bono CM, Black M. Thoracic pedicle screws: postoperative computerized tomography scanning assessment. *J Neurosurg* 2004;100:325-331
188. Lekovic GP, Potts EA, Karahalios DG, Hall G. A comparison of two techniques in image-guided thoracic pedicle screw placement: a retrospective study of 37 patients and 277 pedicle screws. *J Neurosurg Spine* 2007;7:393-398

189. Smorgick Y, Millgram MA, Anekstein Y, Floman Y, Mirovsky Y. Accuracy and safety of thoracic pedicle screw placement in spinal deformities. *J Spinal Disord Tech* 2005;18:522-526
190. Schwarzenbach O, Berlemann U, Jost B, et al. Accuracy of computer-assisted pedicle screw placement. An in vivo computed tomography analysis. *Spine* 1997;22:452-458
191. Schizas C, Michel J, Kosmopoulos V, Theumann N. Computer tomography assessment of pedicle screw insertion in percutaneous posterior transpedicular stabilization. *Eur Spine J* 2007;16:613-617
192. Wiesner L, Kothe R, Schulitz KP, Ruther W. Clinical evaluation and computed tomography scan analysis of screw tracts after percutaneous insertion of pedicle screws in the lumbar spine. *Spine* 2000;25:615-621
193. Sapkas GS, Papadakis SA, Stathakopoulos DP, Papagelopoulos PJ, Badekas AC, Kaiser JH. Evaluation of pedicle screw position in thoracic and lumbar spine fixation using plain radiographs and computed tomography. A prospective study of 35 patients. *Spine* 1999;24:1926-1929
194. Lehman RA, Jr., Lenke LG, Keeler KA, Kim YJ, Cheh G. Computed tomography evaluation of pedicle screws placed in the pediatric deformed spine over an 8-year period. *Spine* 2007;32:2679-2684
195. Halm H, Liljeqvist U, Link T, Jerosch J, Winkelmann W. [Computerized tomography monitoring of the position of pedicle screws in scoliosis surgery]. *Z Orthop Ihre Grenzgeb* 1996;134:492-497
196. Guven O, Yalcin S, Karahan M, Sevinc TT. Postoperative evaluation of transpedicular screws with computed tomography. *Orthop Rev* 1994;23:511-516
197. Odgers CJt, Vaccaro AR, Pollack ME, Cotler JM. Accuracy of pedicle screw placement with the assistance of lateral plain radiography. *J Spinal Disord* 1996;9:334-338
198. Harms J. King-Lenke classification in scoliosis. In: *Spine Surgery Information Portal*. Available online via: <http://harms-spinesurgery.com/src/plugin.php?m=harms.SKO03P&t=pdf>
199. Lenke L. The Lenke classification system for scoliosis. Available online via: <http://www.spinal-deformity-surgeon.com/classification.html>.
200. Lenke LG, Betz RR, Harms J, et al. Adolescent idiopathic scoliosis: a new classification to determine extent of spinal arthrodesis. *J Bone Joint Surg Am* 2001;83-A:1169-1181



# Paper I





# Radiation Dose Optimization in CT Planning of Corrective Scoliosis Surgery.

## A Phantom Study

K. ABUL-KASIM\*, M. GUNNARSSON\*\*, P. MALY\*, A. OHLIN\*\*\*, P. SUNDGREN\*\*\*\*

\* Department of Radiology, Section of Neuroradiology; \*\* Department of Radiation Physics; \*\*\*Department of Orthopedic Surgery, University of Lund, Malmö University Hospital; Sweden

\*\*\*\* Department of Radiology, University of Michigan Health System; Ann Arbor USA.

**Key words:** scoliosis, low dose helical CT, effective dose, dose reduction system (DRS)

**SUMMARY** – *The aim of the study was to explore the possibility of obtaining a helical CT scan of a long segment of vertebral column, optimally reduce the radiation dose, compare the radiation dose of the low dose helical CT with that of some of the CT protocols used in clinical practice and finally assess the impact of such a dose reduction on the image quality. A chest phantom was examined with a 16-slice CT scanner. Six scans were performed with different radiation doses. The lowest radiation dose which had no impact on image quality with regard to the information required for surgical planning of patients with scoliosis, was 20 times lower than that of routinely used protocol for CT examination of the spine in children (0.38 mSv vs 7.76 mSv). Patients with scoliosis planned for corrective spinal surgery can be examined with low dose helical CT scan. The dose reduction systems (DRS) available in modern CT scanners contribute to dose reduction and should be used.*

### Introduction

Adolescent idiopathic scoliosis (AIS) most often affects adolescent girls. The prevalence of AIS exceeding a Cobb angle of 20 degrees is estimated to be in the range of 0.2 %<sup>1</sup>. These patients are usually examined initially with lateral and posteroanterior (PA) radiograph. Subsequently the Cobb angle is measured on a single PA radiograph.

The continuous development and improvement of the corrective methods and implementation of new implants make it necessary to obtain a detailed anatomical map of an often large region of interest both before and after corrective spinal surgery. Preoperatively the surgeon needs a precise estimation of the degree of vertebral rotation in order to plan the correct insertion of transpedicular screws at different levels. Furthermore he/she needs information about the width as well as length of the pedicles, not seldom of up to 15 vertebral levels, in order to plan the suitable diameter of screws at various vertebral levels. As such in-

formation cannot be obtained from plain radiograph<sup>2</sup>; a CT examination of a large segment of the vertebral column is required. Performing such a CT examination of spine, according to CT protocols available in daily clinical practice that are aimed for morphological evaluation of the spine and investigation of different spinal pathology means exposing these young individuals to high radiation dose.

The present availability of multislice scanners and the possibility of reducing and individually adjusting the radiation dose by using the manufacturer's dose reduction system (DRS) (CareDose 4D, Siemens AG, Forchheim, Germany) have enabled us to tailor a very low radiation dose protocol which provides 3D information of relevant segments of the thoracic and lumbar spine. This tube current modulation system includes both angular modulation and z-axis modulation<sup>3</sup> with the aim to automatically adapt the tube current to the patient's anatomic configuration and size together with an on-line controlled tube current modulation for each tube rotation<sup>4</sup>. The major aim of this



phantom study was to compare the radiation dose of the here proposed low dose 3D helical CT protocol with that of some of the CT protocols that are routinely used in clinical practice, before implementing this low dose CT protocol in clinical routine.

The other aims of this phantom study were to assess the impact of this optimal dose reduction on image quality and to find the dose level that still allows safe and reliable assessment of the required parameters such as measurement of pedicular width.

## Materials and Methods

The anthropomorphic adult chest phantom (PBU-X-21; Kyoto Kagaku CO, Ltd, Kyoto, Japan) was used in this study (figure 1). It contains substitute materials for human soft tissues such as muscles and blood vessels. Bones are simulated by epoxy resins and calcium hydroxyapatite to achieve changes in contrast in the phantom images as in an actual human body.

The examinations were performed on a 16-slice CT scanner (SOMATOM Sensation 16, Siemens AG, Forchheim, Germany).

Following scout view, the phantom was examined with the following scans (table 1 shows scan parameters of every individual scan):

*Scan 1:* CT spine protocol recommended by the manufacturer for investigation of different spinal pathology in adults<sup>5</sup>.

*Scan 2:* CT spine protocol recommended by the manufacturer for investigation of different spinal pathology in children with fixed tube voltage of 120 Kv and tube current-time product depending on the body weight. In this study the tube current-time product was 140 mAs (130 mAs recommended by manufacturer for patients with body weight of 35-44 kg)<sup>5</sup>.

*Scan 3:* "Apical Neutral Vertebra" CT protocol (ANV-protocol). This protocol had been used in our institution to measure the degree of vertebral rotation prior to the planned corrective surgery and to measure the degree and derotation after surgery. It consists of four sequential slices of the apical vertebra (at the scoliotic apex), at the superior and the inferior end vertebra at either end of scoliotic curvature.

*Scan 4:* The low dose 3D helical CT protocol before applying the DRS.

*Scan 5:* The low dose 3D helical CT protocol taking advantage the DRS (*the here proposed low dose CT protocol*).

*Scan 6:* 3D helical CT protocol with the lowest possible radiation dose in our CT system.

For all helical scans, i.e. except scan number 3, the scan length was 36.5 cm. The number of vertebrae included in these scans was 15. Reconstructed slice thickness was 3 mm with increment of 3 mm. Scan number 2 (ANV-protocol) consisted of four sequential slices at the middle of each of the three vertebral bodies imaged (only 1.2 cm of each of the three vertebral bodies has been scanned).

The signal-to-noise ratio (SNR) expressed as the ratio of the mean pixel value (MPV) to the standard deviation (SD) of the pixel values, was estimated at the same level of the vertebral column (L1) for every single scan, using a one cm large region of interest (ROI).

A subjective evaluation of image quality was performed by two readers. All scans were read independently by two senior radiologists who were blinded to scan parameters with the aim of evaluating: (a) the ability of the scan to visualize the vertebral pedicles at different segments of the vertebral column and (b) the possibility of measuring the width of the pedicles. The readers were asked to grade the degree of evaluation reliability in every single scan as: (A) unreliable, (B) relatively reliable or (C) reliable.

For quantitative evaluation of the impact of dose reduction on image quality, 3 mm thick reformatted images from scan 1 (the highest radiation dose tested), from scan 5 (the here proposed low-dose CT protocol) and from scan 6 (the lowest possible radiation dose in our CT system) were blinded to all information related to scan parameters and sent to the Picture Archiving and Communication System (PACS, Agfa IMPAX). Since there was no vertebral rotation in the study phantom, the quantitative evaluation of the impact of dose reduction on image quality was limited to the measurement of the pedicular width. Two independent observers performed measurements of pedicular width of 28 pedicles in every scan (a total of 84 pedicular width measurements per observer and occasion). The same measurements were performed by one observer on two different occasions with a one week interval.

Statistical analysis was performed in SPSS 15. Twenty four paired sample T-tests were performed to explore the inter- and intraobserver variations between measurements done on scans 1, 5 and 6 as well as between measurements done within the same scan by two different observers and by the same observer at two

different occasions. The level significance was decided to be  $P \leq 0.01$ . The mean value for differences in measurements of pedicular width was expressed as the systematic error while the standard deviation of the aforementioned values was expressed as the random error.

### MSCT Dosimetry

The effective mAs concept was introduced with the (SOMATOM Sensation 16, Siemens AG, Forchheim, Germany) MSCT. The effective mAs take into account the influence of pitch on both the image quality and the radiation dose and is defined as tube current-time product/pitch factor<sup>4</sup>. The effective mAs value was recorded for scan 5 i.e. scan with activated DRS (table 1).

$$E = E_{DLP} \cdot DLP \text{ (mSv)}$$

Where  $E_{DLP}$  is the region-specific, DLP normalized effective dose (mSv/mGy.cm). General values of the conversion factor,  $E_{DLP}$ , appropriate to different anatomical regions of the patient (head, neck, chest, abdomen, pelvis) were taken from European commission 2004 CT Quality Criteria, Appendix A-MSCT Dosimetry<sup>6</sup>. This phantom study included the thoracic and abdominal regions and the conversion factor used was 0.018 (average of 0.019 for the chest and 0.017 for the abdomen).

The effective doses obtained from calculation of the data from this phantom study were compared with the effective doses which were calculated by using Monte Carlo simulation program WINDOSE 3.0 (Scanditronix Wellhöfer, GmbH; Germany).

**Table 1** Scan parameters of all scans in the phantom study. The values marked in bold represent the scan parameters of the here proposed low dose CT protocol. Effective tube current-time product shown in column 6 is expressed as IQR mAs and effective mAs, respectively, in scan 5 taking advantage of DRS. (IQR mAs is the Image Quality Reference mAs). (\*) Minor modification from the manufacturer's protocol (16x1.5 mm recommended by Siemens). The pitch is however the same as manufacturer's recommendation.

	<i>Slice collimation, mm</i>	<i>Rotation time, sec</i>	<i>Pitch</i>	<i>Tube voltage, Kv</i>	<i>Effective tube current-time product, effective mAs</i>
Scan 1	16x0.75*	0.75	0.75	120	300
Scan 2	16x0.75*	0.75	0.75	120	140
Scan 3	12x1.5	1	1	120	60
Scan 4	16x0.75	0.75	1.5	80	25
Scan 5	16x0.75	0.75	1.5	80	<b>IQR mAs 25</b> <b>Effective mAs 19</b>
Scan 6	16x0.75	0.50	1.5	80	17

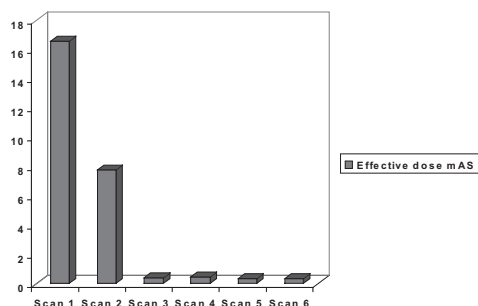
The volume CTDI ( $CTDI_{vol}$ ) which is a derivative of the computed tomography dose index (CTDI) and the dose length product (DLP) was recorded for every scan included in this study. To allow comparisons with other type of radiological examinations, the effective dose (E) was determined.

The effective dose may be derived from values of DLP for an examination using appropriate conversion factors and the following equation:

### Results

The results of measurements of  $CTDI_{vol}$ , DLP and the effective doses for scans 1 to 6 are shown in table 2 (columns 2-5). The effective doses of all scans are also shown in figure 2.

The effective dose (table 2, column 4) of the here proposed low-dose 3D helical scan taking advantage of the DRS (Scan 5) was 0.38 mSv which is 44 times lower than that of scan 1 (16.6 mSv), 20 times lower than that of scan 2



↑ Figure 2 The effective radiation dose for all scan settings (scans 1-6).

← Figure 1 The adult phantom used in this study was constructed to contain about 15 vertebral bodies, ribs, two lungs, trachea and soft tissue in the abdomen and in the thoracic and abdominal walls.

**Table 2** Results of all scans in the phantom study show the CTDIvol, DLP, mean effective dose, the absorbed dose to the breast and the genital organs as well as image quality (SNR). (\*) refers to the estimated effective dose, the absorbed doses to the breast and to the genital organs according to Monte Carlo calculations WINDOSE 3.0. The values marked in bold represent the CTDIvol, DLP, effective dose and the lowest absorbed dose to the breasts and the genital organs in the here proposed low dose CT protocol.

	CTDI <sub>vol</sub> mGy	DLP mGy.cm	Effective dose, mSv	Effective dose, mSv*	Absorbed dose to the breasts, mGy*	Absorbed dose to the genital organs, mGy*	SNR= MPV/SD
Scan 1	23.40	920	16.60	18.6	33.3	1.9	167/5
Scan 2	10.92	431	7.76	8.6	15.5	0.9	168/38
Scan 3	4.32	3×8=24	0.43	0.1+ 0.19+ 0.2=0.49	1.31	0.028	166/64
Scan 4	0.65	26	0.47	0.45	0.86	0.037	176/174
Scan 5	<b>0.51</b>	<b>21</b>	<b>0.38</b>	<b>0.34</b>	<b>0.66</b>	<b>0.028</b>	<b>175/182</b>
Scan 6	0.44	19	0.34	0.30	0.55	0.025	160/347

(7.76 mSv) and 12% lower than that of the scan 3/ANV-protocol (0.43 mSv). The latter merely provides few sequential images at only three vertebral levels. Applying the DRS has lowered the effective dose by 19% (from 0.47 mSv in scan 4 to 0.38 mSv in scan 5).

According to the Monte Carlo calculation (table 2, column 5) the effective dose of the here proposed low dose CT protocol of the spine (scan 5) was 0.34 mSv which is 55 times lower than that delivered by scan 1 (18.6 mSv), 25

times lower than that delivered by scan 2 (8.6 mSv) and 30% lower than that of the ANV-protocol (0.49 mSv).

The calculated absorbed dose to the breasts and the genital organs are shown in table 2, columns 6 and 7, respectively. In the CT protocol recommended by the manufacturer for investigation of spinal disease in children (scan 2), the absorbed dose to the breasts and the genital organs was 23 times and 32 times, respectively, higher than that of the here proposed

low-dose CT protocol (scan 5). In the ANV-protocol (scan 3) the absorbed dose to the breasts was twice as high as the here proposed low-dose CT protocol (scan 5) while the absorbed dose to the genital organs was the same in both scans (0.028 mSv).

The readers classified all images of scans 1 to 5 including those of the here proposed low dose CT protocol (scan 5) as reliable with respect to identification of the pedicles, and measuring their width. The overall image quality of scan 6 was classified as unreliable in the lower five vertebral levels and relatively reliable in the upper ten vertebral levels. Due to this difference in overall image quality of scan 6, the statistical test (paired sample T-test) was also performed separately for the lower five vertebral levels (i.e. 10 pedicles out of 28).

The results of the SNR (MPV/SD) calculations are shown in table 2, column 8. The fact that the SNR value of the here proposed low dose CT protocol (scan 5) was 35 times lower than that of scan 1 (with the highest radiation dose) does not seem to affect the reliability of the evaluation of the parameters required. Some examples of images from different scans of this study are shown in figure 3A-D.

The quantitative evaluation of the impact of dose reduction on image quality in scans 1, 5 and 6 is shown in table 3, which shows only the statistically significant results of paired sample T-tests. Five of the 24 performed paired sample T-tests resulted in statistically significant differences in pedicular width measurements. Scan 6 (with lowest possible dose in our CT system) was involved in all five paired tests, out of which three pairs involved differences in pedicular width measurements in the lower five vertebral levels.

## Discussion

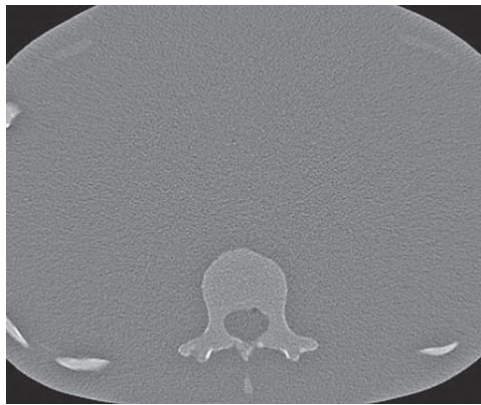This study has shown that it would be possible to examine a large segment of the vertebral column (15 vertebrae) with a long helical 3D CT scan while exposing the patient to a markedly lower radiation dose than would do the CT scan performed according to protocols used in daily clinical practice or the previously used CT scan with sequential images over a very limited part of the vertebral column according to the ANV-protocol (table 2 and figure 2). The latter CT protocol merely enabled measurement of the degree of vertebral rotation (preoperatively) and degree of vertebral derotation (post-

operatively) whereas the low-dose helical CT of a considerably larger area of vertebral column gives, in addition, the opportunity to study its morphology. The fact that some pedicles at the apex of the scoliotic curvature can be merely 2-3 mm wide and may have to be subsequently excluded from transpedicular screw insertion makes the reliability of the measurements of pedicular width crucial in the preoperative planning.

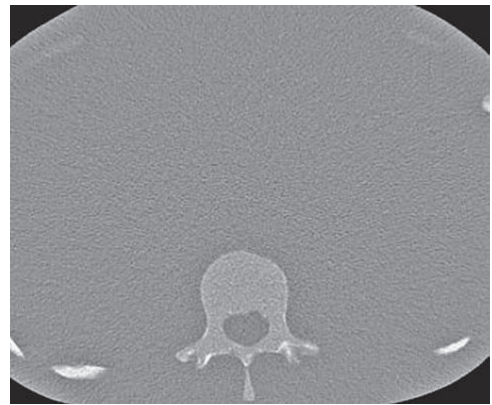Scan 6 (scan with the lowest possible dose in our CT system) is involved in all five paired comparisons with statistically significant differences in pedicular width measurements. This result is compatible with the two reader's subjective classification of images of scan 6 as relatively reliable and of those in the lower five vertebral levels as unreliable. In these five pairs involving scan 6, besides the statistical significance of the differences, the inter- and intraobserver random errors in measuring the pedicular width varied between 1.1 mm and 1.6 mm while the systematic error varied between 1.2 mm and 2.4 mm. The magnitude of the differences exceeding 1 mm also makes the results significant from the clinical point of view as they have a significant influence on the choice of appropriate screw diameter. Unlike the comparisons involving scan 6, none of the comparisons between scan 5 and scan 1 with respect to the inter- and intraobserver random error and the systematic error in measuring the pedicular width resulted in significant differences and were always less than 1 mm (not shown in table 3 because these results were statistically non significant). Taking these statistical findings into consideration, the parameters of the here proposed low dose helical CT protocol (table 1) are to be considered a cut-off value to which the radiation dose can be reduced with no significant impact on image quality required for planning of scoliosis surgery.

In the beginning of 1990s CT constituted about 2-3% of all radiological examinations<sup>7</sup> and contributed to about 20-30% of the total radiation load from medical use of ionizing radiation<sup>8</sup>. Later reports increased the latter figure to about 50%<sup>6,9</sup>.

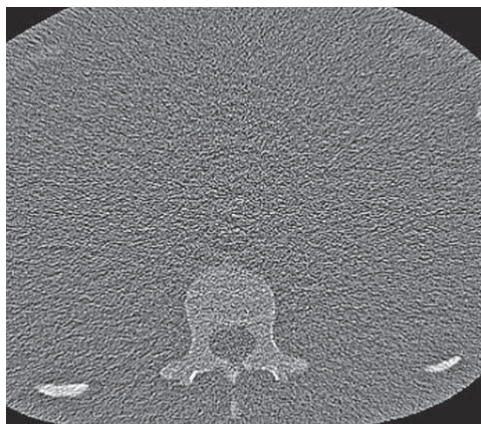
In Germany an overview of MSCT examinations conducted in 2001 showed that the average effective dose to patients had changed from 7.4 mSv at single-slice to 5.5 mSv and 8.1 mSv at dual- and quad-slice scanners, respectively<sup>10</sup>. The annual per capita effective dose for the UK in 2001-2002 was estimated to be 0.38 mSv<sup>11</sup> and for the Dutch population in 1998 to be 0.59



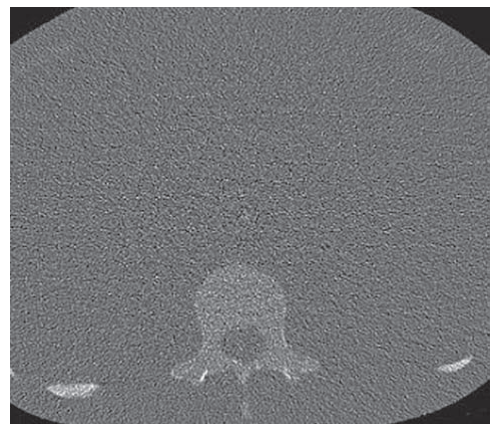
A



B



C



D

Figure 3 A-D Examples of axial images obtained at the same level of the spine, using different protocols. A) Scan 1 according to the protocol for CT-spine recommended by the manufacturer for investigation of different skeletal spinal pathology in children. B) Scan 3 according to ANV-protocol. C) Scan 5 with the low radiation dose according to the here proposed low dose helical CT protocol. D) Scan 6 with the lowest possible radiation dose in our CT system. Undoubtedly the best image quality is that of image A but the detail in image C allows reliable measurement of the width of the pedicles. The overall image quality in scan 6 (image D) is considered to be unreliable especially in the lumbar region. Note that the cortical delineation of the pedicles in image D, especially on the right side, is indistinct which make the measurements of pedicular width difficult, uncertain and unreliable.

mSv<sup>12</sup>. European Commission reference dose levels (EC RDLs) were applied to the routine CT examinations for a random sample of ten patients in the Euromedica medical center in Greece<sup>13</sup>. The mean value of the effective dose was 10.9 mSv for the chest and 7.1 mSv for the abdomen. Both the CTDI vol and the effective dose of the abdomen CT met the EC RDLs criteria<sup>13</sup>. Also the CTDI vol of the scans of the

chest met the EC RDLs dose criteria but the effective dose exceeded the recommended dose. That has been explained by high DLP-value (large irradiation volume length). According to this protocol that had the purpose of applying the EC RDLs criteria, the total effective dose was 18 mSv for the chest- and abdominal scans, a region that corresponds to the region examined in this study with the low dose heli-



**Table 3** The results of paired sample T-test on pedicular width measurements performed on scan 1, scan 5 and scan 6 by two observers as well as by one observer on two different occasions. Twenty four paired sample T-tests were performed. Only the statistically significant results are shown in this table. The statistically significant level was set at  $P \leq 0.01$

Differences in pedicular width measurements (mm)		Paired differences				Sig. (2-tailed)
		Mean (systematic error)	Std. Deviation (random error)	95% Confidence Interval of the Difference		
				Lower	Upper	
Pair 1	Scan 6, Observer 1, occasion 1 ---- Scan 6, Observer 2	-1,8	1,2	-2,3	-1,3	<0,001
Pair 2	Lower 5 vertebral levels: Scan 6, Observer 1, occasion 1, ---- Scan 6, Observer 2	-2,4	1,6	-3,5	-1,3	0,001
Pair 3	Scan 1, Observer 2 ---- Scan 6, Observer 2	-1,2	1,1	-1,7	-0,8	<0,001
Pair 4	Lower 5 vertebral levels: Scan 1, Observer 1, occasion 1, ---- Scan 6, Observer 1, occasion 1	1,7	1,6	0,5	2,8	0,009
Pair 5	Lower 5 vertebral levels: Scan 1, Observer 1, occasion 2 ---- Scan 6, Observer 1, occasion 2	1,6	1,1	0,9	2,4	0,001

cal CT. That dose is 49 times higher than that of the low dose helical CT protocol of this phantom study.

Even the recent reports using different dose reduction systems record significantly higher radiation doses than that of the here proposed low dose CT protocol. The mean effective dose for CT-lumbar spine after optimization was reported to be 6.9 mSv in one study<sup>14</sup>. The mean effective dose for the same region was reported to be 6.69 mSv after angular and z-axis modulation in another study<sup>3</sup>. These radiation doses are 18 times higher than that of the here proposed low dose helical CT which provides significantly longer scan including most of the thoracic and lumbar spine.

Studies have been done normalizing the effective dose to phantom age and to different body regions (head and neck, and different trunk regions including chest, abdomen, and pelvis). Phantoms corresponding to six age groups have been examined with three different CT scanners<sup>15</sup>. In all cases an inverse trend was observed between normalized effective dose and phantom age. The effective dose normalized to age for chest examinations using Siemens DRH-scanner increased from 6 mSv in adult phantom to only 6.3 mSv in phantom corresponding a 15 year old child<sup>15</sup>. The difference increased even more in phantoms corresponding to newborn and a one-year-old child resulting in normalized effective doses of 7.8 and 7.1

mSv respectively. In accordance with those results, table 4 in this study shows the effective dose to the adult phantom (according to Monte Carlo calculation) as well as the normalized effective dose to the phantoms corresponding to four different age groups, namely 15 years, ten years, five years, and one year. However, the last three age groups are seldom the object for corrective surgery and consequently rarely subjected to CT examination of the spine. The median age of patients at or just prior to surgery is estimated at 14 to 15 years<sup>16</sup>. As the effective dose to the phantom at the age group 15 years was only 1-1.1 times higher than that of the adult phantom (0.34-0.37 mSv versus 0.34 mSv), the results of this study are quite representative for the estimation of the radiation dose in CT-examinations of the spine in adult patients as well as in patients in pubertal age who are often the object for corrective surgery of scoliosis. In lower age groups, e.g. in phantoms corresponding one year old child, the effective dose can be as high as twice the adult dose. However the increase in the effective dose is markedly evident in examinations with originally high radiation dose such as that of scan 1 of this study. In the here proposed low-dose CT protocol the effective dose to a phantom corresponding one-year-old child has been estimated at 0.44-0.68 mSv – a value that still has to be considered a relatively low dose.

A current concept has recently proposed

**Table 4** The effective dose (mSv) in the adult phantom and the normalized effective dose (mSv) to the phantoms of four different age groups using the data from the National Radiological Protection Board (NRPB) SP250. The ranges in the age groups other than adult represent the minimum and maximum relative doses. The median age of patients at or just prior to surgery is estimated to be 14-15 years (16). In the here proposed low dose CT-protocol (scan 5), the normalized dose in this age group is almost the same as that of the adults (0.34-0.37 mSv, and 0.34 mSv respectively).

	<i>Adult</i>	<i>15 years</i>	<i>10 years</i>	<i>5 years</i>	<i>1 year</i>
Scan 1	18.6	18.6-20.46	20.46-27.9	22.32-29.76	24.18-37.2
Scan 2	8.6	8.6-9.46	9.46-12.9	10.32-13.76	11.18-17.2
Scan 3	0.49	0.49-0.54	0.54-0.73	0.59-0.78	0.64-0.98
Scan 4	0.45	0.45-0.5	0.5-0.67	0.54-0.72	0.58-0.9
Scan 5	0.34	0.34-0.37	0.37-0.51	0.41-0.54	0.44-0.68
Scan 6	0.30	0.30-0.33	0.33-0.45	0.36-0.48	0.39-0.6

three ways to reduce the overall radiation dose from CT<sup>17</sup>. These include a reduction of the number of CT studies prescribed as well as replacing CT examinations with other modalities e.g. MRI. The role of MRI in investigating intraspinal pathologies preoperatively is well known in clinical practice and has been extensively reviewed<sup>18-20</sup>. In accordance with our recommendation of taking advantage of the dose reduction system available in some scanners, the third proposed way to reduce the population dose from CT was to take advantage of the automatic exposure-control option. However we believe that serious attempts to reduce the radiation dose in CT examinations and efforts to create low dose CT protocols adapted to answer different clinical questions have to be added to the above mentioned methods to reduce the radiation dose from CT examinations.

Applying the here proposed low dose protocol to the CT examination of scoliotic patients who are predominantly thinner than the phantom of this study, will likely enable further reduction of the radiation dose when taking advantage of the dose reduction system of the scanner.

One limitation of this study is that it is a phantom study and the phantom used is an adult phantom. However when normalizing the effective dose to phantom age (table 4), no significant increase in the effective dose could be recorded in the here proposed low dose protocol. The second limitation was inability to assess the degree of vertebral rotation as this was not built into the phantom. Another limitation of this study is that the impact of artifacts from metal implants on the ability to measure the degree of vertebral derotation and the assessment of the hardware status after surgery could not be evaluated. To our knowl-

edge no phantoms with either vertebral torsion or inserted screws are commercially available to test.

Taking the above-mentioned facts in consideration, the medical community has to be concerned about the increasing total radiation load to the population due to the increasing availability of the CT scan and the increasing number of its upcoming new indications and modifications (e.g. CT angiography, high resolution studies, "multiple phase examinations", perfusion studies, etc.). Efforts should be continued to reduce the radiation dose of every single CT by tailoring CT examinations with their radiation doses individually adapted to the purpose of the investigation.

## Conclusion

This phantom study has shown that it would be possible to reduce the radiation dose in helical CT examination of the spine in patients planned for corrective surgery of spinal deformities without any significant impact on image quality. To test this possibility we intend to implement the protocol into the preoperative work up of this patient category instead of the ANV-sequential slice method used previously, provided that the radiation doses can be kept at this low level. The results of this study emphasize the importance of tailoring different CT protocols with different radiation doses adapted to answer the clinical question at issue. The dose reduction system of the CT scanner, if available, should be used. When assessing the effective dose the absorbed dose to different organs (e.g. genitals and breasts) should be taken into consideration

## Acknowledgement

The authors gratefully acknowledge Dr. Eufrozina Selariu, Department of Radiology, University of Lund, Malmö University Hospi-

tal, Sweden for her contribution in parts of the analysis. We would also like to acknowledge Jan Åke Nilsson, Department of Orthopedic Surgery, University of Lund, Malmö University Hospital for his statistical advice.

## References

- 1 Leatherman KD, Dickson RA: The Management of Spinal Deformities. Wright 1988.
- 2 Perdriolle R, Vidal J: Thoracic idiopathic scoliosis curve evolution and progression. *Spine* 10: 785-91, 1985.
- 3 Mulkens TH, Bellinck P, Baeyaert M et Al: Use of an automatic exposure control mechanism for dose optimization in multi-detector row CT examinations: clinical evaluation. *Radiology* 237: 213-23, 2005.
- 4 Siemens, Somatom Sensation 64: Application Guide. Siemens AG Medical Solution, Computed Tomography 2004: 29-32
- 5 Siemens, Somatom Sensation 16: Application Guide. Siemens AG Medical Solution, Computed Tomography 2003: 62-63, 140-141.
- 6 Bongartz G, Golding SJ, Jurik AG et al: European Guidelines for Multislice Computed Tomography. Funded by the European Commission. Contract number FIGM-CT2000-20078-CT-TIP 2004.
- 7 Rehani MM, Berry M: Radiation doses in computed tomography. The increasing doses of radiation need to be controlled. *BMJ* 320: 593-594, 2000.
- 8 Shrimpton PC, Jones DG, Hillier MC: Survey of CT practice in the UK, Part 2: Dosimetric aspects. London: HMSO 1991.
- 9 Royal College of Radiologists: Making the best use of department of clinical radiology: guidelines for doctors. 4<sup>th</sup> ed. London: Royal College of Radiologists 1998.
- 10 Brix G, Nagel HD, Stamm G et Al: Radiation exposure in multi-slice versus single-slice spiral CT: results of a nationwide survey. *Eur Radiol* 13: 1979-91, 2003.
- 11 Hart D, Wall BF: UK population dose from medical x-ray examinations. *Eur J Radiol* 50: 285-91, 2004.
- 12 Brugmans MJ, Buijs WC, Geleijns J et Al: Population exposure to diagnostic use of ionizing radiation in The Netherlands. *Health Phys* 82: 500-9, 2002.
- 13 Tsapaki V, Kottou S, Papadimitriou D: Application of European Commission reference dose levels in CT examinations in Crete, Greece. *Br J Radiol* 74: 836-40, 2001.
- 14 Heggie JC, Kay JK, Lee WK: Importance in optimization of multi-slice computed tomography scan protocols. *Australas Radiol* 50: 278-285, 2006.
- 15 Khursheed A, Hillier MC, Shrimpton PC et Al: Influence of patient age on normalized effective doses calculated for CT examinations. *Br J Radiol* 75: 819-30, 2002.
- 16 Franic M, Kovac V: Anterior instrumentation for correction of adolescent thoracic idiopathic scoliosis: historic prospective study. *Croat. Med J* 47: 239-45, 2006.
- 17 Brenner DJ, Hall EJ: Computed tomography--an increasing source of radiation exposure. *N Engl J Med* 357: 2277-84, 2007.
- 18 Redla S., Sikdar T, Saifuddin A: Magnetic resonance imaging of scoliosis. *Clinical Radiology* 56: 360-71, 2001.
- 19 Nokes SR, Murtagh FR, Jones JD et Al: Childhood Scoliosis: MR Imaging. *Radiology* 164: 791-97, 1987.
- 20 Barnes PD, Brody JD, Jaramillo D et Al: Atypical idiopathic scoliosis: MR imaging evaluation. *Radiology* 186: 247-253, 1993.

K. Abul-Kasim, MD  
Department of Radiology  
Section of Neuroradiology  
University of Lund  
Malmö University Hospital  
205 02 Malmö  
Sweden  
Tel.: +46 40 33 87 90  
Fax: +46 40 33 87 98  
E-mail: Kasim.Abul-Kasim@med.lu.se





## Paper II



Kasim Abul-Kasim  
Angelica Overgaard  
Pavel Maly  
Acke Ohlin  
Mikael Gunnarsson  
Pia C. Sundgren

## Low-dose helical computed tomography (CT) in the perioperative workup of adolescent idiopathic scoliosis

Received: 17 April 2008  
Accepted: 13 July 2008  
Published online: 23 September 2008  
© European Society of Radiology 2008

K. Abul-Kasim (✉) · A. Overgaard ·  
P. Maly  
Department of Radiology, Section of  
Neuroradiology, University of Lund,  
Malmö University Hospital,  
205 02 Malmö, Sweden  
e-mail: Kasim.Abul-Kasim@med.lu.se  
Tel.: +46-40-338790  
Fax: +46-40-338798

A. Ohlin  
Department of Orthopaedic Surgery,  
University of Lund,  
Malmö University Hospital,  
Malmö, Sweden

M. Gunnarsson  
Department of Radiation Physics,  
University of Lund,  
Malmö University Hospital,  
Malmö, Sweden

P. C. Sundgren  
Department of Radiology,  
Division of Neuroradiology,  
University of Michigan Health Systems,  
Ann Arbor, USA

**Abstract** The study aims were to estimate the radiation dose in patients examined with low dose spine CT and to compare it with that received by patients undergoing standard CT for trauma of the same region, as well as to evaluate the impact of dose reduction on image quality. Radiation doses in 113 consecutive low dose spine CTs

were compared with those in 127 CTs for trauma. The inter- and intraobserver agreement in measurements of pedicular width, measurements of vertebral rotation, and signal-to-noise ratio and assessment of hardware status were the indicators in the evaluation of image quality. The effective dose of the low dose spine CT (0.37 mSv) was 20 times lower than that of a standard CT for trauma (13.09 mSv). This dose reduction conveyed no impact on image quality. This low dose spine CT protocol allows detailed evaluation that is necessary for preoperative planning and postoperative evaluation.

**Keywords** Spine CT · Effective dose · Image quality · Vertebral rotation · Hardware status

### Background and aims

Scoliosis is a complex spinal deformity characterized by lateral curvature of the spine, which is always associated with vertebral rotation. The most common type of scoliosis is adolescent idiopathic scoliosis (AIS) in which the deformity progresses during the pubertal peak of growth after the age of 10 years. The prevalence of AIS with a Cobb angle exceeding 20 degrees is estimated to be in the range of 0.2% with a female-to-male ratio of 10:1 [1]. Patients with AIS are usually examined initially with lateral and posteroanterior (PA) radiographs. Subsequently, the Cobb angle is measured on a single PA radiograph.

Surgical treatment of scoliosis is most often performed in young individuals; therefore, radiation protection mea-

sures are of great importance. Preoperatively, the surgeon is interested in: (1) measurements of the degree of vertebral rotation, (2) looking for a possible underlying cause of scoliosis as well as for associated abnormalities, such as vertebral anomalies, dysraphism, dural ectasia, etc., and (3) measurements of pedicular width. This information allows the surgeon to choose a suitable size of screw for every individual pedicle and is of great help for correct placement of pedicle screws. Furthermore, the degree of vertebral rotation is an indicator of curve progression and subsequently a predictive factor for the prognosis [2–3]. Postoperatively, it is important to assess the degree of vertebral derotation achieved and to assess the hardware status. As this information cannot be provided by plain radiograph [2], CT of the spine has become increasingly

used in the workup of scoliosis. The role of magnetic resonance imaging (MRI) in the investigation of scoliosis, especially in the presence of suspected spinal cord abnormalities and in atypical scoliosis, has been extensively reviewed [4–7]. Some of the drawbacks of MRI are its lesser availability, the longer examination time, and the extensive susceptibility artifacts caused by the implants, which can make the measurement of the degree of vertebral derotation and assessment of screw placement after surgery impossible. Furthermore, the measurement of the degree of vertebral rotation is obtained from axial images and thus, in the MRI, demands repeated axial sequences to cover the whole region of interest and further lengthens the MRI examination time.

Before the era of multislice CT (MSCT), patients with scoliosis planned for surgery were examined with CT according to different protocols. At our institution these patients were previously examined according to a locally developed “apical neutral vertebra” CT protocol (ANV protocol). According to this protocol, the patients were examined with sequential CT that delivered four sequential slices at the middle of the apical vertebra and four sequential slices at the middle of a vertebra at either end of the scoliotic curvature. This made it possible to measure the degree of vertebral rotation only at these three levels.

At our institution a phantom study was conducted in order to establish a new method for investigation of patients with scoliosis using 3D helical MSCT with as low a radiation dose as possible and with no impact on image quality [8]. That phantom study has shown that the radiation dose of that low-dose spine CT was 20 times lower than that of the routinely used protocol for spine CT in children (0.38 mSv vs 7.76 mSv) [8].

The main aim of this study was to measure the radiation dose of this low-dose spine CT in patients with AIS and compare it with that of trauma CT (a protocol used for examination of the chest and abdomen after trauma) as well as with that of the previously used sequential CT according to the ANV protocol. The second aim was to find out if the radiation dose could be held as low as that in the above-mentioned phantom study. The third aim was to evaluate the impact of the dose reduction on image quality and reliability of these images to answer clinical questions at issue.

## Material and methods

To the date of analysis, a total of 137 consecutive CT examinations (81 patients with AIS) had been performed with a low-dose 3D helical MSCT of the spine, which, in this study, will be called “low-dose spine CT.” A total of 71 patients (88%) gave their consent to have their images retrospectively evaluated as part of this study and were included in this analysis of a total of 113 examinations. Of the 71 patients, 42 had been examined both pre- and

postoperatively, while the remaining 29 patients had been examined either preoperatively or postoperatively with this low-dose spine CT. Fifty-four patients (76%) were female, and 17 patients (24%) were male. The mean and the median values of patient age were 17 and 16 years, respectively (range 12–32 years). Fifty examinations (44%) were preoperative, and 63 examinations (56%) were postoperative examinations.

The examinations included in this analysis have been categorized into the following groups, in order to enable comparison among these groups:

### Group 1:

All examinations with low dose spine CT (n=113).

### Group 2:

Preoperative examinations with low dose spine CT (n=50).

### Group 3:

Low dose spine CT after posterior surgical correction (n=46).

### Group 4:

Low dose spine CT after anterior surgical correction (n=17).

### Group 5:

CT according to ANV-protocol (n=15).

### Group 6:

Trauma CT (n=127)

## Evaluation of the radiation dose

All examinations were performed at a 16-slice CT system (SOMATOM Sensation 16, Siemens, Germany). The examination protocol was that recommended in the phantom study [8]. At the beginning a scout view was obtained. In addition to 1- and 3-mm-thick axial images, 2-mm-thick coronal and sagittal reformatted images with 2-mm distance between images were also obtained. Three-dimensional reconstruction was also a possible and available post-processing option that was often performed after the preoperative examinations.

All trauma CTs performed in our institution during 2007 on patients of the same age group as the patients with AIS were evaluated with regard to the radiation dose. A total of 127 trauma CTs performed in the age group of 13–32 years were evaluated. The scan parameters of this trauma CT protocol are about the same as that of the CT protocol used in daily clinical practice for investigation of spinal pathology in this age group (the effective tube current-time product of 140–200 mAs depending on the patient's age), making the comparison of radiation dose with trauma CT reasonable. The dose reduction system (DRS) (CareDose 4D, Siemens, Forchheim, Germany) available in the CT system was automatically activated in low-dose spine CT and CT for trauma. This type of DRS is an

automatic exposure control based on axial as well as angular tube current modulation [9].

Further comparison was done with the radiation dose of the CT according to the above-mentioned ANV protocol. A total of 15 randomly chosen CT examinations according to the ANV protocol was evaluated. The scan parameters of the low-dose spine CT, trauma CT, and CT according to the ANV protocol are shown in Table 1.

*MSCT dosimetry*

The effective mAs concept has been introduced with the MSCT. The effective mAs value defined as tube current-time product/pitch factor [9] was recorded for every individual examination. The volume CTDI (CTDI<sub>vol</sub>) and the dose length product (DLP) were also recorded for every individual examination. The effective doses (E) were calculated using the following equation:

$$E = E_{DLP}DLP$$

where  $E_{DLP}$  is the region-specific. General values of the conversion factor,  $E_{DLP}$  appropriate to different anatomical regions of the patient (head, neck, chest, abdomen, and pelvis) were taken from the European Commission 2004 CT Quality Criteria, Appendix A-MSCT Dosimetry [10]. A conversion factor of 0.018 was used (average of 0.019 for the chest and 0.017 for the abdomen).

The absorbed dose to the breasts, genital organs, and thyroid gland was calculated using the Monte Carlo simulation program WINDOSE 3.0 (Scanditronix Wellhöfer).

Evaluation of the impact of dose reduction on image quality

The impact of dose reduction on image quality in examinations according to the low-dose CT-protocol was evaluated using the parameters mentioned below. For comparison, evaluation of image quality of 15 randomly chosen sequential CT examinations according to the previously used ANV protocol was performed. The latter group of examinations has the advantage that it includes patients with scoliosis of the same age group, which enables a comparable evaluation of different indicators of image quality, e.g., vertebral rotation, as opposed to comparison with CT examinations of patients who had no scoliotic deformity. All examinations were read independently by two senior radiologists; one of them repeated the same evaluations at 6-week interval. As indicators of image quality, the following evaluations were performed:

- (A) Subjective evaluation of image quality: The readers were asked to evaluate the reliability of the images to: (i) identify and clearly delineate the vertebral bodies and the pedicles, (ii) measure the width of the pedicles, and (iii) measure the degree of vertebral rotation. The readers were asked to grade the degree of reliability in each single examination as: reliable (0), relatively reliable (1), or unreliable (2).
- (B) Measurement of pedicular width: 3-mm-thick reformatted axial images with skeletal algorithm were used for this purpose. Figure 1a illustrates in which way the measurement of the pedicular width was performed. A total of 226 pedicular width measurements was performed on examinations with low-dose spine CT

**Table 1** The evaluation of radiation doses in the low-dose spine CT, trauma CT, and sequential CT according to the ANV protocol

Parameters	Low-dose spine CT	Trauma CT	Sequential scan ANV-protocol scan, n=3
Slice collimation, mm	16×0.75	16×0.75	12×1.5
Rotation time, s	0.75	0.5	1
Pitch	1.5	1	1
Tube voltage, Kv	80	120	120
Effective tube current-time product, mAs	25	165	60
Effective mAs	20.20±2.60	129±30	60±2.3
CTDI <sub>vol</sub> , mGy	0.53±0.06	10.12±2.31	13±0.17
DLP, mGy.cm	20.75±5.38	714±178	24
Effective dose, mSv	0.37±0.10	13.09±3.19	0.43
Scan length, cm	35.93±8.94	66.37±8.49	3.6 totally, 1.2 per vertebra
Effective dose/cm scan length, mSv	0.01	0.20	0.12
Absorbed dose to the breasts, mGy	0.47±0.31	3.99±6.67	1.30±0.31
Absorbed dose to genital organs, mGy	0.02±0.05	5.33±6.20	0.03±0.05
Absorbed dose to thyroid glands, mGy	0.39±0.34	8.65±7.03	0.18±0.34
Signal-to-noise ratio (SNR)	1.03	2.53	1.80

and 30 such measurements on CT examinations according to the ANV protocol.

- (C) Measurement of the degree of vertebral rotation: 3-mm-thick reformatted axial images with skeletal algorithm were used for this purpose. Vertebral rotation was measured at the apical, the upper end, and the lower end vertebrae. In patients with S-formed scoliosis, five measurements were done: two at the apical vertebrae, one at the upper end vertebra, and one at the lower end vertebra, as well as one at the neutral vertebra. Vertebral rotation is defined as transverse plane angulation of a vertebra [11]. Apical vertebra in a curve is the vertebra that is most deviated laterally from the vertical axis that passes through the central sacral line. The end vertebrae are the vertebrae that define the ends of a curve in frontal projection. Neutral vertebra is the vertebra without axial rotation (in reference to the most cephalad and caudal vertebrae that are not rotated in a curve) [11]. The levels of these vertebrae were predetermined on previously obtained plain radiographs taken in standing position, performed for measurement of the Cobb angle as part of the routine radiological workup. The vertebral rotation was measured according to the method developed by Aaro and Dahlborn [12] as illustrated in Fig. 1b. A total of 367 measurements of degree of vertebral rotation was performed on low-dose spine CT, and 45 such measurements were performed on the 15 CTs according to the ANV protocol.
- (D) Evaluation of hardware status: 1-mm-thick reformatted axial images with soft tissue algorithm have been used for this purpose. The subjects of this analysis were patients operated with posterior surgical correction (group 3; 46 examinations) and fixation with all-pedicle screw construct. The status of a total of 809 inserted pedicle screws was evaluated. The readers

were asked to grade the screw placement as *normal placement* (0) when the screw was enclosed within the pedicle or minimally violated the pedicular cortex, or *misplacement* (1) when more than half of the screw diameter violated the pedicular cortex.

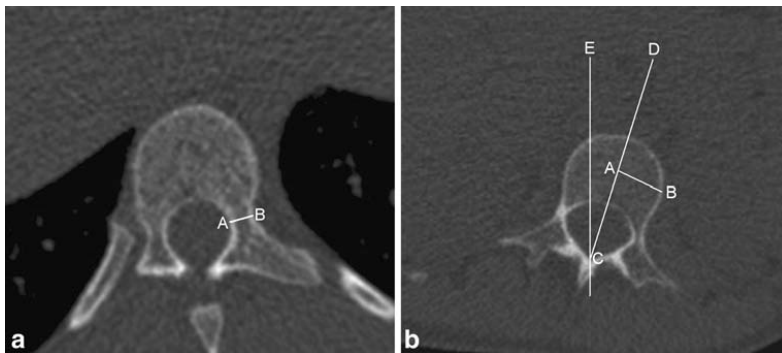
- (E) Measurement of the signal-to-noise ratio (SNR): SNR was measured on 200 haphazardly chosen images in 35 haphazardly chosen examinations with low-dose spine CT. Fifty such measurements were done on CT according to the ANV protocol and 100 measurements on images from trauma CT.

The results of the above-mentioned phantom study [8] were presented to the regional radiation protection committee, which then approved the use of the low-dose spine CT instead of the previously used ANV-protocol CT. The regional ethical committee approval to conduct this retrospective analysis was also obtained. The patients were provided with written information about this study.

#### Statistical analysis

Statistical analysis was performed by means of SPSS 15 (Statistical Package for Social Sciences, version 15). Regarding the subjective evaluation of image quality and evaluation of hardware status, the degree of interobserver and intraobserver agreement was evaluated by calculating the kappa coefficient (Cohen's kappa). Interpretation of the kappa coefficient (K values) was done according to the one proposed by Landis and Kock [13–15], shown in Table 2.

To explore the interobserver and intraobserver variations in measurements of pedicular width and degree of vertebral rotation, paired sample t-tests were performed, and the systematic and the random errors were estimated. The



**Fig. 1** (a-b) illustrates the method of measurement of the pedicular width (a) and vertebral rotation (b). (a-b) shows axial images obtained with a low-dose spine CT. In (a), the pedicular width is defined as the distance between point A and B. In (b), A-B represents the line between the outer cortex and the middle of the

vertebral body. The degree of vertebral rotation is defined as the angle where C-D and C-E meet at the most posterior part of the spinal canal. C-D is the line drawn through the middle of the vertebral body to the middle of the most posterior part of the spinal canal, and C-E is the line drawn through the sagittal plane

**Table 2** The interpretation of the kappa (K) value and ICC

K values	Degree of agreement
<0	Poor
0–0.20	Slight
0.21–0.40	Fair
0.41–0.60	Moderate
0.61–0.80	Substantial
0.81–1.00	Almost perfect

mean values of differences in measurements of pedicular width and vertebral rotation were expressed as systematic error, while the standard deviation (SD) of the aforementioned values was expressed as random error. Furthermore, a reliability analysis was performed by calculating a two-way mixed model of intraclass correlation coefficient (ICC). The ICC is interpreted similarly to the kappa coefficient [16].

## Results

### Radiation dose

The results of evaluation of radiation doses are shown in Table 1. The mean value of the effective dose of the low-dose spine CT was  $0.37 \pm 0.10$  mSv (mean  $\pm$  SD) (95% confidence interval of 0.35–0.39 mSv), which is 35 times lower than that received by the patients examined with trauma CT ( $13.09 \pm 3.19$  mSv, 95% confidence interval of 12.49–13.68 mSv) and 14% lower than that received by patients previously examined according to the ANV protocol (0.43 mSv). However, the craniocaudal length for trauma CT was considerably longer than that of the low-dose spine CT ( $66.37 \pm 8.49$  cm vs  $35.93 \pm 8.94$  cm), while the overall length of the ANV-protocol CT was considerably shorter (a total of 3.6 cm). The effective dose per cm length examined by CT was 0.01 mSv in the low-dose

spine CT, which is 20 and 12 times lower than that of trauma CT and ANV protocol CT (0.20 mSv and 0.12 mSv per cm, respectively). The radiation dose of low-dose spine CT in this patient material has been kept as low as that recorded in our phantom study (0.38 mSv for a craniocaudal CT length of 36.5 cm) [8]. The number of vertebrae included in the low-dose spine CT was  $14.8 \pm 3.7$  (mean  $\pm$  SD) vertebrae. This means in practice a long CT examination that includes the majority of the thoracic and lumbar vertebrae, often between Th2 and L4.

The absorbed doses to the breasts, genital organs, and thyroid gland in the low-dose spine CT were 8, 265, and 22 times, respectively, lower than the corresponding doses in trauma CT and 2.7 and 1.5 times (respectively) lower than the absorbed doses to the breast and genital organs in the CT scan according to the ANV protocol. The absorbed dose to the thyroid glands was 2.1 times higher in low-dose spine CT than that in CT scans according to the ANV protocol.

### Impact of dose reduction on image quality

- (1) *Subjective evaluation of image quality:* The two readers agreed about the degree of reliability of the images in 106 out of 113 examinations (74 were considered as reliable, 25 as relatively reliable, and 7 as unreliable) (Table 3). All seven examinations that were considered as unreliable belong to patients who underwent anterior corrective surgery (group 4), and the remaining ten examinations in this group were considered as relatively reliable. The interobserver and intraobserver agreement was almost perfect in group 1, group 2, and group 5 and substantial in group 3 (for the verbal interpretation of kappa values, see Table 2). The interobserver and intraobserver agreement in group 4 was substantial and moderate, respectively (Table 4).
- (2) *Measurement of pedicular width:* The results are shown in Table 5. The reliability analysis showed almost perfect ICC in examinations with low-dose

**Table 3** The results of the subjective evaluation of image quality of all 113 examinations included in the analysis

		Reliable (0)	Relatively reliable (1)	Unreliable (2)	Total
<b>Observer 1/occasion 1</b>					
<b>Observer 2</b>	Reliable (0)	74	0	0	74
	Relatively reliable (1)	5	25	2	32
	Unreliable (2)	0	0	7	7
	Total	79	25	9	113
<b>Observer 1/occasion 2</b>					
<b>Observer 1/occasion 1</b>	Reliable (0)	78	1	0	79
	Relatively reliable (1)	3	20	2	25
	Unreliable (2)	0	2	7	9
	Total	81	23	9	113



**Table 4** The degree of interobserver and intraobserver agreement in the subjective evaluation of image quality using kappa coefficient for all low-dose CT examinations included in the analysis (group 1), the preoperative group (group 2), examinations of patients after posterior and anterior corrective surgery (group 3 and 4, respectively), and CT examinations according to the ANV protocol (group 5)

	Interobserver agreement			Intraobserver agreement		
	Kappa	95% Confidence interval		Kappa	95% Confidence interval	
		Lower limit	Upper limit		Lower limit	Upper limit
Group 1 (n=113)	0.87	0.77	0.96	0.84	0.74	0.94
Group 2 (n=50)	1	1	1	1	1	1
Group 3 (n=46)	0.77	0.59	0.96	0.79	0.60	0.98
Group 4 (n=17)	0.77	0.47	1.06	0.53	0.12	0.93
Group 5 (n=15)	0.83	0.49	1.15	0.85	0.57	1.13

spine CT and those performed according to the ANV protocol (groups 1 and 5). The interobserver and intraobserver ICC was almost perfect in the other groups except in that of group 4 (after anterior corrective surgery) where the interobserver ICC was moderate. The SD of interobserver differences between measurements of pedicular width was 0.61 mm in the examinations with low-dose spine CT compared with 0.32 mm in examinations according to the ANV protocol. Corresponding values for SD of intraobserver differences were 0.42 vs. 0.37 mm.

- (3) *Measurement of the degree of vertebral rotation*: The mean value of the degree of vertebral rotation measured by the second reader (observer 2) was 10.7°, while those measured by the first reader (observer 1) were 10.4° and 10.3° at the first and the second occasion, respectively. The results of the reliability analysis are shown in Table 5. The reliability

analysis showed almost perfect ICC in examinations with low-dose spine CT and those performed according to the ANV protocol (group 1 and 5). Only in group 4, the SDs of the interobserver differences between measurements of the degree of vertebral rotation exceeded 2°. In the remaining groups, the SD of differences varied between 1.74° and 1.91°.

- (4) *Evaluation of the hardware status*: Observers 1 and 2 agreed about the status of placement of the pedicle screws in 758 out of 809 screws evaluated, resulting in a substantial interobserver agreement with  $\kappa=0.78$  (95% confidence interval 0.72–0.84). The evaluation of screw placement by observer 1 was the same at the two occasions in 772 out of 809 screws evaluated, resulting in an almost perfect intraobserver agreement with  $\kappa=0.84$  (95% confidence interval 0.79–0.89).
- (5) The results of measurements of SNR are shown in Table 1.

**Table 5** The reliability analysis using a two-way mixed model of intraclass correlation coefficient (ICC) as well as the mean and the standard deviation (SD) of the inter- and intraobserver differences in measuring the degree of vertebral rotation and pedicular width

Parameter	Group	Interobserver reliability					Intraobserver reliability				
		ICC	95%CI		Mean	SD	ICC	95%CI		Mean	SD
			Lower	Upper				Lower	Upper		
Pedicular width	1	0.872	0.836	0.900	0.13	0.61*	0.936	0.918	0.951	0.05	0.42
	2	0.971	0.957	0.980	−0.004	0.30	0.965	0.948	0.976	−0.04	0.33
	3	0.941	0.912	0.960	0.13	0.39*	0.919	0.880	0.946	0.10	0.44*
	4	0.508	0.210	0.720	0.51	1.30*	0.895	0.800	0.946	0.18	0.53
	5	0.975	0.948	0.988	0.01	0.32	0.965	0.928	0.983	0.53	0.37
Vertebral rotation	1	0.970	0.963	0.975	0.27	1.88*	0.972	0.966	0.978	0.08	1.77
	2	0.975	0.967	0.982	−0.01	1.77	0.975	0.967	0.982	0.20	1.74
	3	0.970	0.959	0.978	0.52	1.91*	0.974	0.964	0.981	−0.19	1.76
	4	0.963	0.891	0.963	0.43	2.08	0.945	0.905	0.968	0.48	1.80
	5	0.971	0.947	0.984	0.18	1.80	0.970	0.946	0.983	0.55	1.82

The units for the mean and SD of differences in measurements of the vertebral rotation and the pedicular width are in degree and millimeter, respectively. \*Statistically significant (P value < 0.05)

Figure 2 shows some examples of images with low-dose spine CT.

## Discussion

This study has shown that performing the here-proposed low-dose spine CT results in a significant dose reduction to these young individuals with AIS compared with the dose that would result from the use of standard CT protocols. The effective dose-per-centimeter scan length was 20 times lower than that of the trauma CT.

This study has shown a high degree of interobserver and intraobserver agreement in the evaluation of the impact of dose reduction on image quality. The here-used low-dose spine CT thus allows a wide range of morphological assessment, such as measurement of pedicular width, measurement of the degree of vertebral rotation preoperatively and postoperatively, as well as assessment of screw placement.

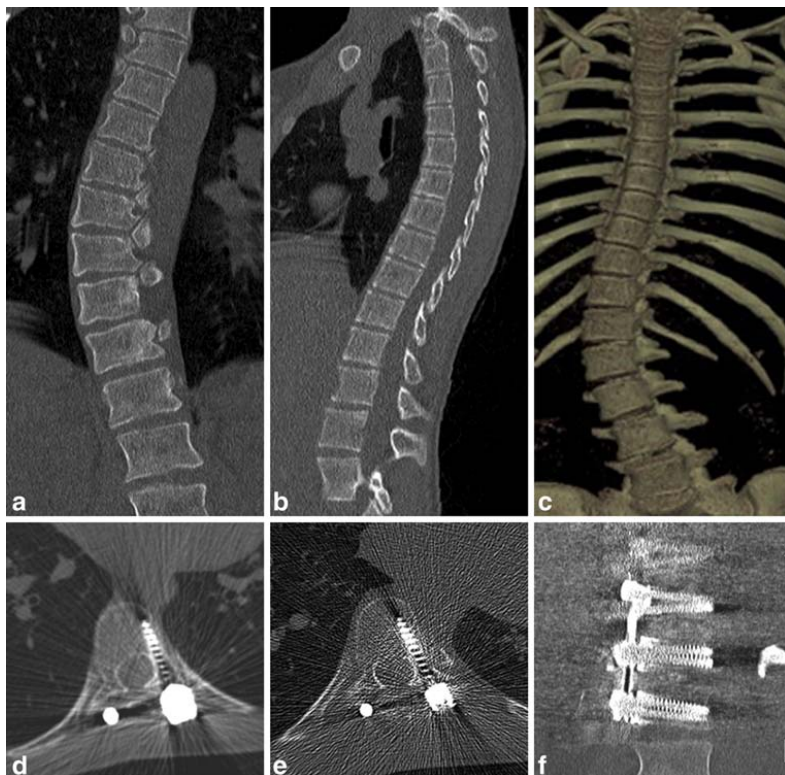
With regard to subjective evaluation of image quality and reliability of these images to answer the clinical questions at issue, there was a substantial - almost perfect -

interobserver and intraobserver agreement when evaluating the preoperative and the postoperative examinations with the exception of examinations performed after anterior corrective surgery (group 4). Similarly, there was an almost perfect interobserver and intraobserver ICC with regard to differences in measurement of pedicular width and the degree of vertebral rotation, again with the exception of those examinations performed after anterior corrective surgery.

The SD of interobserver and intraobserver differences between measurements of pedicular width varied between 0.3 and 0.6 mm in all groups except, again, for group 4 (after anterior corrective surgery), where the SD was 1.3 mm. Except for the latter figure, the SD of 0.3–0.6 mm (although three of them were statistically significant, Table 5) has to be considered as clinically insignificant as a differences of such magnitude at least partly are inborn error of the measurement programs in any Picture Archiving and Communication System (PACS).

The SD of interobserver and intraobserver differences between measurements of degree of vertebral rotation varied from 1.74° to 2.01° in all groups analyzed. The measurements of the degree of vertebral rotation with CT

**Fig. 2** (a-f) shows some examples of the images generated by the low-dose spine CT. (a-b) show coronal and sagittal reformatted images of two different patients with AIS before surgery. The image quality in the preoperative examinations allows a 3D reconstruction with volume-rendering technique (VRT) as shown in (c). These images allow a morphological analysis of the region of interest. (d-e) show axial images obtained from two different patients examined after posterior corrective surgery with titanium implants. Image quality in (d) was regarded as reliable by both readers and illustrates a normally placed pedicle screw. Image quality in (e) was regarded as relatively reliable. The image quality was good enough to illustrate that the screw is enclosed within the pedicle. (f) shows the coronal reformatted image of a patient after anterior corrective surgery with stainless steel implants consisting of rods at the scoliosis convexity side and two screws through every vertebral body at three levels. The images of this examination were regarded as unreliable by both readers



performed with different methods [12, 17–19] and the comparison between the reliability of some of these methods have been studied previously [20–21]. The original work of Aaro et al. was on film and not on digitalized images, and the SDs between the estimated angles were 1.55–2.28°, depending on the size of the film used [12]. In another series the SD of intraobserver differences in measurements according to the Aaro method was 1.76° [21]. The SD of differences in this study is thus in accordance with the results from these previous studies [12, 21] and supports the assumption that low-dose spine CT has to be considered as a reliable method in measuring the degree of vertebral rotation. The statistical significance of interobserver differences in two of the analyzed pairs (Table 5) may therefore have no clinical significance.

The substantial interobserver and intraobserver agreement regarding the placement of pedicle screws in patients after posterior corrective surgery with titanium implants suggests that the assessment of hardware status is reliable even in a low-dose spine CT. However, the low-dose spine CT does not seem to be a suitable method in the postoperative workup of patients after anterior corrective scoliosis surgery. One of the techniques used to overcome the streak artifacts from hardware is the use of soft tissue or smooth reconstruction filters [22], and this has been used in this study. The detailed analysis of the hardware status was not the subject of this study as the aim of this analysis was to use the interobserver and intraobserver agreement as an indicator of the image quality.

Although the SNRs of trauma CT and CT according to the ANV protocol were 2.5 and 1.8 times higher than that of low-dose spine CT, this did not seem to negatively influence the reliability of the images in the assessments of the parameters in question.

In a previous study the effective radiation doses at conventional radiography of the spine and thoracoabdominal multi-detector CT scan of patients involved in serious trauma were 6.36 mSv and 19.42 mSv, respectively [23], which are 16 and 47 times higher, respectively, than that of the here-proposed low-dose spine CT.

Effective doses of up to 9.4–28 mSv for the chest examination and 13–28 mSv for the abdomen-pelvis were obtained in another previous study [24]. Those effective doses are 55–137 times higher than that of the here-

proposed low-dose spine CT. Even in a recent study claiming dose reduction, effective doses were estimated to be 5.9 and 8.2 mSv for the CT examination of the chest and the abdomen, respectively, with a total of 14.1 mSv [25], which is also significantly higher (38 times higher) than the dose of the here-proposed low-dose spine CT of 0.37 mSv. In another report, the mean effective dose for the CT of the lumbar spine after angular and z-axis modulation was 6.69 mSv [26], which is 18 times higher than that of the here-proposed low-dose spine CT providing significantly longer craniocaudal CT examination, including major parts of the thoracic and lumbar spine.

CT examinations are an increasing source of radiation exposure to the population [27] and nowadays probably contribute to almost half of the collective dose from all X-ray examinations [28]. Therefore, every effort to reduce the total radiation load from medical use of ionizing radiation is important.

Performing one preoperative and one postoperative low-dose spine CT between Th2-L4 means a total effective radiation dose of 0.74 mSv. This can be compared with the exposure to natural radioactivity from different sources, including background radiation, radon in houses, industry, nuclear reactors, etc., which varies from place to place with values ranging from 1 to 2 mSv, but can in some instances amount to 4 mSv per year [29]. The dose of two examinations according to the low-dose spine CT corresponds thus to only 18–74% of the annual exposure to natural radioactivity.

## Conclusion

The here-proposed low-dose spine CT has been shown to be a suitable method to implement in the pre- and the postoperative investigation of young patients with AIS as this significant dose reduction did not convey any negative impact on image quality. It provides an informative 3D CT that can be used for various purposes in the perioperative workup of patients with scoliosis as well as in other patients in whom the skeletal components of the spine are the issue. This study emphasizes also the importance of tailoring CT protocols to obtain just the information necessary to answer the clinical question at issue.

## References

1. Leatherman KD, Dickson RA (1988) The management of spinal deformities. Wright, London
2. Perdiolle R, Vidal J (1985) Thoracic idiopathic scoliosis curve evolution and prognosis. *Spine* 10(9):785–791
3. Weinstein SL, Ponseti IV (1983) Curve progression in idiopathic scoliosis. *J Bone Joint Surg Am* 65(4):447–455
4. Maiocco B, Deeney VF, Coulon R, Parks PF Jr (1997) Adolescent idiopathic scoliosis and the presence of spinal cord abnormalities. Preoperative magnetic resonance imaging analysis. *Spine* 22(21):2537–2541
5. Benli IT, Un A, Karaaslan S, Cinemre O, Gurses L, Hekimoglu B (2002) Neural axis abnormalities detected by preoperative magnetic resonance imaging in patients with type III idiopathic scoliosis. *Acta Orthop Traumatol Turc* 36(4):354–361

6. Winter RB, Lonstein JE, Heithoff KB, Kirkham JA (1997) Magnetic resonance imaging evaluation of the adolescent patient with idiopathic scoliosis before spinal instrumentation and fusion. A prospective, double-blinded study of 140 patients. *Spine* 22(8):855–858
7. Barnes PD, Brody JD, Jaramillo D, Akbar JU, Emans JB (1993) Atypical idiopathic scoliosis: MR imaging evaluation. *Radiology* 186:247–253
8. Abul-Kasim K, Gunnarsson M, Maly P, Ohlin A, Sundgren PC (2008) Radiation dose optimization in CT planning of corrective scoliosis surgery. A phantom study. *Neuroradiol J* 21:374–382
9. SIEMENS. SOMATOM Sensation 64, Application Guide (2004) Siemens AG medical solution, computed tomography, pp 29–32
10. Bongartz G, Golding SJ, Jurik AG, Leonardi M, van Persijn van Meerten E, Rodriguez R, Schneider K, Calzado A, Geleijns J, Jessen KA, Panzer W, Shrimpton PC, Tosi G (2004) European guidelines for multislice computed tomography. Funded by the European Commission. Contract number FIGM-CT2000–20078-CT-TIP; March 2004
11. The Working Group on 3-D Classification (Chair Larry Lenke) and the Terminology Committee (March 2000). Scoliosis Research Society Terminology Committee and Working Group on Spinal Classification, Revised Glossary of Terms. Available via: <http://www.srs.org/professionals/glossary/glossary.php>. Accessed 17 April 2008
12. Aaro S, Dahlborn M, Svensson L (1978) Estimation of vertebral rotation in structural scoliosis by computer tomography. *Acta Radiol Diagn* 19 (6):990–992
13. Landis JR, Koch GG (1977) The measurement of observer agreement for categorical data. *Biometrics* 33(1):159–174
14. Landis JR, Koch GG (1977) An application of hierarchical kappa-type statistics in the assessment of majority agreement among multiple observers. *Biometrics* 33(2):363–374
15. Viera AJ, Garrett JM (2005) Understanding interobserver agreement: the kappa statistic. *Fam Med* 37(5):360–363
16. Garson GD (2008) Reliability analysis. Available via: <http://www2.chass.ncsu.edu/garson/pa765/reliab.htm>. Accessed 17 April 2008
17. Ho E, Upadhyay SS, Chan FL, Hsu LC, Leong JC (1993) New methods of measuring vertebral rotation from computed tomographic scans. *Spine* 18 (9):1173–1177
18. Krismar M, Sterzinger W, Haid C (1996) Axial rotation measurement of scoliotic vertebrae by means of CT scans. *Spine* 21(5):576–581
19. Göçen S, Havitcioğlu H, Alici E (1999) A new method to measure vertebral rotation from CT scan. *Eur Spine J* 8 (4):261–265
20. Krismar M, Chen AM, Steinlechner M, Haid C, Lener N, Wimmer C (1999) Measurement of vertebral rotation: a comparison of two methods based on CT scan. *J Spinal Disord* 12(2):126–130
21. Göçen S, Aksu MG, Baktiroğlu L, Özcan Ö (1998) Evaluation of computed tomographic methods to measure vertebral rotation in adolescent idiopathic scoliosis: an intraobserver and interobserver analysis. *J Spinal Disord* 11(3):210–214
22. Vande Berg B, Malghe J, Maldague B, Lecouvet F (2006) Multi-detector CT imaging in the postoperative orthopedic patient with metal hardware. *Eur J Radiol* 60(3):470–479
23. Wintermark M, Mouhsine E, Theumann N, Mordasini P, van Melle G, Leyvraz PF, Schnyder P (2003) Thoracolumbar spine fractures in patients who have sustained severe trauma: depiction with multi-detector row CT. *Radiology* 227(3):681–689
24. Nishizawa K, Matsumoto M, Iwai K, Tonari A, Yoshida T, Takayama M (2002) Dose evaluation and effective dose estimation from multi detector CT. *Igaku Butsuri* 22(3):152–158
25. Tsapaki V, Aldrich JE, Sharma R, Staniszevska MA, Krisanachinda A, Rehani M, Hufton A, Triantopoulou C, Maniatis PN, Papaïliou J, Prokop M (2006) Dose reduction in CT while maintaining diagnostic confidence: diagnostic reference levels at routine head, chest, and abdominal CT-IAEA-coordinated research project. *Radiology* 240(3):828–834
26. Mulkens TH, Bellinck P, Baeyaert M, Ghysen D, Van Dijk X, Mussen E, Venstermans C, Termote JL (2005) Use of an automatic exposure control mechanism for dose optimization in multi-detector row CT examinations: clinical evaluation. *Radiology* 237:213–223
27. Brenner DJ, Hall EJ (2007) Computed tomography—an increasing source of radiation exposure. *N Engl J Med* 357 (22):2277–2284
28. Royal College of Radiologists (1998) Making the best use of department of clinical radiology: Guidelines for doctors, 4th edn. Royal College of Radiologists, London
29. Åkerblom G, Falk R, Lindgren J, Mjönes L, Östergren I, Söderman A-L et al (2005) Natural radioactivity in Sweden, exposure to internal radiation. Radiological protection in transition, Proceedings of the XIV Regular Meeting of the Nordic Society for Radiation Protection. NSFS. Rättvik, Sweden, 27–31 August 2005. pp 211–214. Given as SSI-report SSI 2005:15



## Paper III



# Reliability of low radiation dose CT in the assessment of screw placement after posterior scoliosis surgery, evaluated with a new grading system

Kasim Abul-Kasim, MD<sup>\*</sup>; Anita Strömbeck, MD<sup>\*</sup>; Acke Ohlin, MD, Ph D<sup>†</sup>; Pavel Maly, MD, Ph D<sup>\*</sup>; Pia C. Sundgren, MD, Ph D<sup>‡</sup>

**Corresponding author:** Kasim Abul-Kasim. Faculty of Medicine, University of Lund, Department of Radiology, Section of Neuroradiology, Malmö University Hospital, 205 02 Malmö, Sweden

PHONE +46 40 33 87 90, FAX +46 40 33 87 98, E-MAIL [Kasim.AbulKasim@med.lu.se](mailto:Kasim.AbulKasim@med.lu.se)

<sup>\*</sup>Dept. of Radiology, Section of Neuroradiology, University of Lund, Malmö University Hospital, Sweden.

<sup>†</sup>Dept. of Orthopaedic Surgery, University of Lund, Malmö University Hospital, Sweden.

<sup>‡</sup>Dept. of Radiology, University of Michigan Health Systems, Ann Arbor, USA.

## Abstract

**Study design.** A retrospective study.

**Objectives.** To evaluate the reliability of Computed Tomography (CT) with low radiation dose in the assessment of implant status in patients with adolescent idiopathic scoliosis (AIS).

**Summary of background data.** The use of all-pedicle screw construct in the posterior scoliosis surgery continues to gain increasing popularity since their introduction 1994 although their use in the thoracic spine carries a potential risk for neurovascular complications. CT is the method widely used to evaluate screw placement.

**Materials and methods.** Retrospective analysis of 46 consecutive low-dose spine CT in patients with AIS after posterior corrective surgery. Status of 809 titanium screws (642 thoracic) was evaluated. The degree of *interobserver* and *intraobserver* agreement about implant status was used as an indicator of the reliability of the low-dose spine CT in the assessment of accuracy of pedicle screw insertion. A new grading system has been developed for this purpose. Five types of misplacements have been evaluated: lateral, medial, and anterior cortical perforations, endplate perforation, and foraminal perforation.

**Results.** The analysis has shown a substantial *interobserver* and *intraobserver* agreement (kappa value of 0.69 and 0.76 respectively) in differentiating pedicle screws with acceptable placement from screws with partial or total cortical perforation. None of the examinations was subjectively classified as unreliable.

**Conclusion.** The study has shown that low-dose spine CT is a reliable method in evaluating screw placement in patients with AIS after posterior scoliosis surgery with titanium implants, using the here proposed grading system. The new grading system of screw misplacement was feasible and in line with the general agreement about the harmlessness of misplacement with minor pedicle breach. The reliability of low-dose spine CT in evaluation of lateral-, medial cortical perforations and endplate perforation was substantial whereas the reliability in evaluation of anterior cortical- and foraminal perforations was fair but believed to be improved by increasing experience of the reading radiologist. To avoid exposing these young individuals to unnecessarily high radiation doses, the postoperative assessment of titanium screw placement should be performed with dedicated CT using low radiation dose.

■ **Key words:** Titanium screws, interobserver agreement, misplacement, medial cortical perforation, endplate perforation, foraminal perforation.

**In Press. Scheduled for publication in Volume 34, Number 9 "Spine" may 2009.**

Spinal fixation with pedicle screws, initially combined with posterior plates,

was used in fixation of spinal fractures already in 1970s<sup>1</sup>. In the surgical correction and stabilization of scoliotic deformities



the instrumentation with pedicle screws has become increasingly popular since this technique was introduced in 1986<sup>2</sup> and further improved by the introduction of what is nowadays known as “all-pedicle screw construct”, in 1994<sup>3</sup>. As this procedure, in particular in the thoracic region, is potentially dangerous due to the risk of neurovascular complications when screws are misplaced, a reliable postoperative assessment of pedicle screw placement is necessary. Plain radiography and computed tomography (CT) have been used for postoperative assessment. However, because plain radiography has its limitations<sup>4,6</sup>, and because studies have shown that CT is more accurate in demonstrating screw misplacement than plain radiography<sup>7-8</sup> as well as being a more accurate and reliable tool in the assessment of pedicle screws<sup>9-13</sup>, CT has become more widely used in the postoperative evaluation of spinal fixation with pedicle screws. However in most of the previous reports assessing pedicle screw placement with CT, the information about radiation dose received during such examinations is limited or missing. As AIS affects young individuals, predominantly females, the use of CT in the postoperative workup according to protocols that are used in the daily clinical practice means exposing these young individuals to very high radiation doses. Breasts, erythropoietic bone marrow, and to lesser extent thyroid glands and genital organs are included in the radiation field and, therefore, are subjected to a high radiation doses. Therefore the implementation of low radiation dose CT protocols has become a necessary measure with the growing demand to evaluate screw placement after corrective surgery. A low-dose CT protocol has previously been evaluated with regard to both the radiation dose and the impact of dose reduction on image quality and was shown to be a reliable method in the perioperative workup of patients with AIS<sup>14</sup>. That low-dose spine CT of young individuals including an

average of 15 vertebral levels (average scan length of 36 cm) resulted in an effective radiation dose of 0.37 mSv which was shown to be at least 20 times lower than the radiation dose received when using conventional CT-protocols including the same region of interest. A considerably lower absorbed dose to the breasts, genitals and thyroid gland were also received when using the low-dose CT protocol<sup>14</sup>.

Although the rate of screw misplacement in the thoracic pedicles amounts to 20-30%, the rate of neurovascular complications only ranges from 0 to 1%<sup>5,15-17</sup>. According to the Scoliosis Research Society Morbidity and Mortality Committee, the rate of neurological complications of spinal fusion for adult scoliosis is 1.3%<sup>18</sup>.

To our knowledge, the reliability of CT in the assessment of pedicle screw placement, in particular assessment utilizing CT with low radiation dose has not been evaluated in patient studies. The main aim of this study was to evaluate the image quality of the low-dose spine CT and the reliability of these images to assess the screw placement in patients with AIS, subjected to posterior surgery using a titanium all-pedicle screw construct for correction and stabilization. The subsequent aim was to categorise screw (mis)placement in a new grading system that would be feasible both for the evaluation in clinical practice and in the research (e.g. allowing evaluation of the interobserver- and intraobserver agreement).

## ■ Materials and methods:

The study includes a total of 46 patients with AIS who have undergone posterior corrective surgery. Thirty six patients (78%) were female and 10 patients (22%) were male with a mean and median age of 16.9 and 16 years respectively at the time of surgery (range 12-32 years). The patient who was 32 year old at the time of surgery had the disease onset at the pubertal age. A total of 809 pedicle screws were analyzed,

642 screws (79%) were inserted in the thoracic spine and 167 screws (21%) were inserted in the lumbar spine.

The insertion of screws was partially guided by means of a C-arm fluoroscopy in the anteroposterior-view. However the radiation exposure was intermittent and used only to check the positioning of 3-cm long and 1-mm wide titanium bone marker inserted at the entry points. Thereafter the insertion of the screws was performed using free-hand technique.

All examinations were performed on a 16-slice CT-scanner (SOMATOM Sensation 16, Siemens AG, Forchheim Germany) 6 weeks after surgery. The scan parameters were those recommended by a previous phantom study<sup>19</sup>: Slice collimation 16x0.75 mm, rotation time 0.75 second, pitch 1.5, tube voltage 80 kV, and quality reference for the effective tube current-time product 25 mAs. The dose reduction system (DRS) (CareDose 4D, Siemens AG, Forchheim, Germany) available in the scanner was automatically activated. Reconstructed slices with 3 mm

thickness and 3 mm increment were obtained. The slice collimation of 0.75 mm allowed obtaining 1 mm thick reformatted axial images (1 mm increment) with both soft tissue algorithm and skeletal algorithm as well as 2 mm thick coronal and sagittal reformatted images. In our institution we developed a new grading system for the evaluation of screw placement, where the relationship of every individual screw to the corresponding pedicle, vertebral body, endplate, and neural foramen were evaluated with regard to: (a) medial cortical perforation of the corresponding pedicle (MCP), (b) lateral cortical perforation of the corresponding pedicle (LCP), (c) anterior cortical perforation of vertebral body (ACP), (d) endplate perforation (EPP), and (e) foraminal perforation (FP), Table 1. Fig 1 illustrates different types of misplacement, according to our new grading system. All examinations included in the analysis were read independently by two observers (senior radiologists: KAK & AS) and one

**Table 1. The new grading system used for the assessment of screw placement.**

Medial cortical perforation of the pedicle (MCP):	Grade 0: Acceptable placement. Screw passes totally within the pedicle medullary canal or with minimal breach of medial pedicular cortex (< 1/2 of the screw diameter passes medial to medial pedicular cortex). Grade 1: Partially medialised screw (>1/2 of the screw diameter passes medial to medial pedicular cortex). Grade 2: Totally medialised screw (screw passes totally medial to medial pedicular cortex).
Lateral cortical perforation of the pedicle (LCP):	Grade 0: Acceptable placement. Screw passes totally within the pedicle medullary canal or with minimal breach of lateral pedicular cortex (< 1/2 of the screw diameter passes lateral to lateral pedicular cortex). Grade 1: Partially lateralised screw (>1/2 of the screw diameter passes lateral to lateral pedicular cortex). Grade 2: Totally lateralised screw (screw passes totally lateral to lateral pedicular cortex).
Anterior cortical perforation of the vertebral body (ACP):	Grade 0: Acceptable placement. The screw tip is contained within the vertebral body. Grade 1: Anterior cortical perforation. The screw tip penetrates the anterior cortex of the corresponding vertebral body. The degree of perforation is reported in mm.
Endplate perforation (EPP):	Grade 0: Acceptable placement. The screw tip is contained within the vertebral body. Grade 1: Endplate perforation. The screw tip penetrates the upper or lower endplate into the adjacent disc space.
Foraminal perforation (FP):	Grade 0: Acceptable placement. The screw tip does not penetrate the pedicle border into the overlying or underlying neural foramen. Grade 1: Foraminal perforation. The screw tip penetrates the pedicle border into the overlying or underlying neural foramen.

of them (KAK) repeated the evaluation at another occasion with 6-week interval. Subjective and objective analyses of image quality were performed with the two observers being asked to:

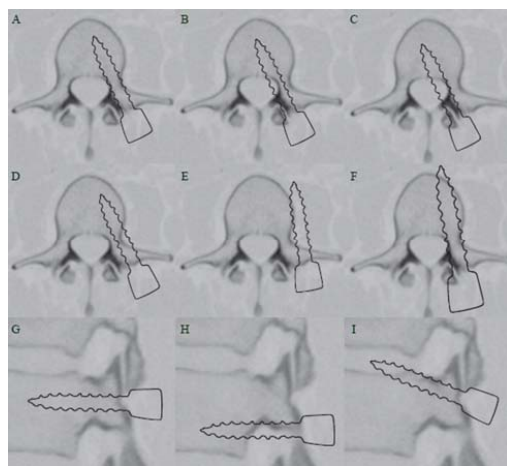
- a. Grade the overall reliability of the images in every single scan as: reliable (0), relatively reliable (1), or unreliable (2).
- b. Evaluate the placement of the pedicle screws. The observers were asked to classify the screw placement into acceptable placement (0), or misplacement (1) regardless the type of misplacement.
- c. Explore the reliability of the low-dose CT to differentiate between screws with acceptable placement (0), screws with partial cortical perforation (1), and screws with total cortical perforation (2). Screws with grade 1 MCP and grade 1 LCP were regarded as screws with partial cortical perforation. Screws with grade 2 MCP, grade 2 LCP as well as screws with ACP, EPP and FP were regarded as screws with total cortical perforation.
- d. Perform a detailed analysis of reliability of low-dose CT in grading of all types of misplacement according to the new grading system shown in Table 1.

## Ethical committee approval

The regional radiation protection committee approval to use this low-dose spine CT in the workup of patients with scoliosis was obtained. The regional ethical committee approval to conduct this retrospective analysis was also obtained. The patients were provided with written information about this study and their written consents were a prerequisite for inclusion in this analysis.

## Statistical analysis:

Statistical analysis was performed by means of SPSS 15 (Statistical Package for Social Sciences, version 15). The degree of *interobserver* and *intraobserver* agreement was evaluated by cross tabulation and calculation of kappa (K values). The interpretation of kappa values was done according to the one proposed by Landis and Kock<sup>20-21</sup>. A kappa of 1 indicates total agreement of the two readers in all cases analyzed. A kappa of 0.81-1.00 indicates almost perfect agreement, 0.61-0.80 indicates substantial agreement, 0.41-0.60 indicates moderate agreement, 0.21-0.40 indicates fair agreement while a kappa of <0 indicates poor agreement.



**Figure 1:** Different types of misplacement according to the here proposed grading system.

(A–F) axial images and (G–I) sagittal images. A: Acceptably placed screw. B: MCP grade 1. C: MCP grade 2. D: LCP grade 1. E: LCP grade 2. F: ACP. G: Acceptably placed screw on a sagittal image. No FR or EPP. H: FP. Perforation into the underlying neural foramen. I: EPP. Perforation through the upper endplate.

**Table 2. The results of the subjective analysis of image quality.**

		Observer 1/ Occasion 1			Total
		Reliable (0)	Relatively reliable (1)	Unreliable (2)	
<b>Observer 2</b>	Reliable (0)	26	0	0	26
	Relatively reliable (1)	5	15	0	20
	Unreliable (2)	0	0	0	0
	Total	31	15	0	46
		Observer 1/ Occasion 2			Total
		Reliable (0)	Relatively reliable (1)	Unreliable (2)	
<b>Observer 1 Occasion 1</b>	Reliable (0)	30	1	0	31
	Relatively reliable (1)	3	12	0	15
	Unreliable (2)	0	0	0	0
	Total	33	13	0	46

\* The numbers shown are the numbers of low dose CT examinations.

## ■ Results:

The results of subjective evaluation of the overall reliability of images are shown in Table 2. None of the 46 CT-examinations included in the analysis was regarded as unreliable by any observer at any occasion. The *interobserver* agreement was substantial with  $\kappa = 0.77$  (95% confidence interval 0.59-0.96). The *intraobserver* agreement was also substantial with  $\kappa = 0.79$  (95% confidence interval 0.60-0.98).

In the evaluation of placement of the pedicle screws regardless the type of misplacement if any (Table 3), the two observers agreed about the status of screw placement in 758 of 809 (94%) screws analyzed. They agreed that 645 screws were acceptably placed and 113 screws were misplaced, which resulted in substantial *interobserver* agreement with  $\kappa = 0.78$  (95% confidence interval 0.72–0.84). The observer who performed the analysis twice assessed at both occasions that 654 screws were acceptably placed and 118 screws were misplaced, which resulted in an almost perfect *intraobserver*

agreement with  $\kappa = 0.84$  (95% confidence interval 0.79–0.89).

The results of the *interobserver*- and *intraobserver* agreement in differentiating between screws with acceptable placement, screws with partial cortical perforation, and those with total cortical perforation are shown in Table 4. The two observers agreed about the type of screw placement in 734 screws, resulting in substantial *interobserver* agreement with  $\kappa = 0.69$  (95% confidence interval 0.63–0.75). The observer who evaluated the screw placement at two different occasions agreed about the type of screw placement in 752 screws, resulting in substantial *intraobserver* agreement with  $\kappa = 0.76$  (95% confidence interval 0.71–0.81). The results of detailed analysis of all types of misplacement are shown in Table 5. With respect to the two most common types of misplacement, namely lateral and medial cortical perforations of the pedicles, the *interobserver* and *intraobserver* agreements were substantial.

**Table 3. The results of the evaluation of the pedicle screw placement regardless the type of misplacement.**

		Observer 1/ Occasion 1		Total
		Acceptable placement (0)	Misplacement (1)	
<b>Observer 2</b>	Acceptable placement (0)	645	30	675
	Misplacement (1)	21	113	134
	Total	666	143	809
		Observer 1/ Occasion 2		Total
		Acceptable placement (0)	Misplacement (1)	
<b>Observer 1/ Occasion 1</b>	Acceptable placement (0)	654	12	666
	Misplacement (1)	25	118	143
	Total	679	130	809

\* The numbers shown are the number of the screws.

**Table 4. The interobserver- and intraobserver agreement in differentiation between the screws with acceptable placement (0), the screws with partial cortical perforation (1), and screws with total cortical perforation (2).**

		Observer 1/ Occasion 1			Total
		Acceptable placement	Partial cortical perforation	Total cortical perforation	
Observer 2	Acceptable placement	645	22	8	675
	Partial cortical perforation	17	33	10	60
	Total cortical perforation	4	14	56	74
	Total	666	69	74	809
		Observer 1/ Occasion 2			Total
		Acceptable placement	Partial cortical perforation	Total cortical perforation	
Observer 1/ Occasion 1	Acceptable placement	654	10	2	666
	Partial cortical perforation	19	36	14	69
	Total cortical perforation	6	6	62	74
	Total	679	52	78	809

The same applies to the *interobserver- and intraobserver* agreement regarding endplate perforation as well as the *intraobserver* agreement in anterior cortical penetration and foraminal perforation. The *interobserver* agreements in anterior cortical penetration and foraminal perforation were fair ( $\kappa = 0.39$  and  $0.40$  respectively).

Images of the low-dose spine CT, which demonstrate the different types of misplacement according to our new grading system, are shown in Fig 2 (A-H).

## ■ Discussion:

Using our new grading system, we found that CT with low radiation dose is a reliable method in the assessment of pedicle screw placement in patients with AIS who have undergone posterior correction of scoliotic deformity and stabilization with titanium all-pedicle screw construct. The results of this study are in accordance with previous reports

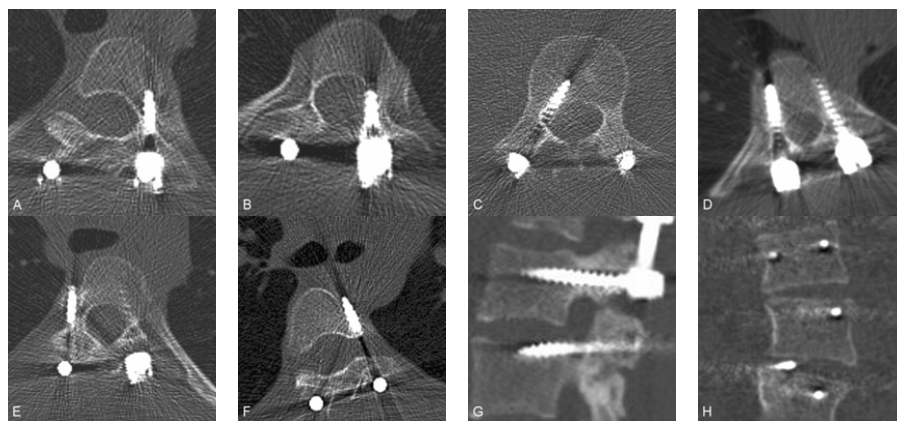
regarding reliability of CT in the postoperative assessment of screw placement, which previously has been extensively studied in cadaver and in patient series and has been shown to be higher than that of plain radiography<sup>7-9,11</sup>. There is at least one previous report showing plain radiography to be as accurate as CT in the evaluation of pedicle screw position<sup>22</sup>. When assessing thoracic pedicle screw placement with CT the rate of screw misplacement has shown to be as high as 20-30%<sup>5,17</sup> and in another study the misplacement rate was up to 50%<sup>15</sup>. This is in contrast to the markedly lower rate of misplacement shown in many studies using plain radiography as a routine method of assessment of pedicle screw placement. For example two large studies of thoracic (4604 screws evaluated) and lumbosacral (4790 screws evaluated) pedicle screw placement<sup>17,23</sup>, showed a misplacement rate of 1.5%, and 5.1%, respectively. The clear discrepancy between those results and the

**Table 5. The interobserver- and intraobserver agreement in different types of screw misplacement.**

	Interobserver agreement			Intraobserver agreement		
	Kappa	95% Confidence interval		Kappa	95% Confidence interval	
		Lower limit	Upper limit		Lower limit	Upper limit
Medial cortical perforation	0.68	0.58	0.78	0.77	0.69	0.86
Lateral cortical perforation	0.72	0.64	0.79	0.76	0.69	0.84
Anterior cortical perforation	0.39	0.08	0.71	0.62	0.34	0.90
Endplate perforation	0.77	0.56	0.99	0.87	0.70	1.05
Foraminal perforation	0.40	-0.15	0.94	0.66	0.23	1.10

above mentioned average figure of 20-30% misplacement rate detected by CT supports the fact that CT is superior to plain radiography in detecting screw misplacement. This has also been shown in studies directly comparing the two methods<sup>7-8</sup>. Nevertheless, as CT has the disadvantage of general exposure to higher radiation dose than plain radiography, it is important to state that the protocol used for low radiation dose CT of spine in this study delivered a very low radiation dose (0.37 mSv) which was markedly lower than the radiation dose reported in thoracolumbar plain radiography and CT after spinal trauma (26 mSv and 13 mSv respectively with the effective dose of plain radiograph twice as high as that of CT)<sup>24</sup>. Even optimized trauma CTs of the same region of interest using dose modulation system has shown to deliver an effective radiation dose 35 times higher than that of our low-dose spine CT (20 times higher radiation dose per cm scan length)<sup>14</sup>.

A previous study of 12 adult cadavers demonstrated *interobserver* and *intraobserver* reliability of CT in the assessment of titanium thoracic pedicle screw placement (with  $\kappa$  value of 0.53 and 0.63 respectively)<sup>10</sup>. The fact that we have shown higher degree of agreement despite the use of CT with low radiation dose probably depends on improvement of CT-technology and on the new grading system we have developed where we have omitted grading the rate of misplacement on mm-basis. Before establishing our grading system, a literature review was done to find out if there was any correlation between the grade of misplacement and the occurrence of neurovascular complications. It seems that a consensus of a so called “safe zone” of 4 mm has been reached with regard to the medial cortical perforation<sup>25-26</sup>. In most of the published reports a pedicle breach of  $\leq 2$  mm is regarded as harmless<sup>5,27-28</sup>.



**Figure 2:** CT images obtained from different patients examined with low dose CT of spine. (A) Axial image shows acceptably placed screw through the left pedicle of T4. (B) MCP grade 1 through the left pedicle of T3. (C) MCP grade 2 through the right pedicle of L3. (D) LCP grade 1 through the left pedicle of T9. Acceptably placed screw on the right side. (E) LCP grade 2 through the right pedicle of T5. The screw does not anchor in the vertebral body (F) ACP through the anterior cortex of T5 on the left side. Note the vicinity of screw tip to aorta. (G) Sagittal image shows that the upper screw is acceptably placed screw through the pedicle of L2 without any penetration into the neural foramina or the vertebral endplates while the lower screw passes (L3) through the overlying neural foramen (FP). (H) EPP through the upper endplate of L3 on the right side.

A medial cortical perforation of 5 mm and lateral cortical perforation of 6 mm have been tolerated in one study where the authors hypothesize a definite safe zone (perforation < 2 mm), probable safe zone (perforation 2-4 mm) and questionable safe zone (perforation 4-8 mm) of medial cortical perforation<sup>27</sup>. However pedicle breach might negatively affect the biomechanical strength of the pedicle screws even if some studies has shown that screws with minimal pedicle perforation might have better biomechanical strength than those purely enclosed in the medullary canal of the pedicles<sup>29</sup>.

The screws used in the spinal fixation vary in diameter between 4 and 8 mm (often 4-5 mm in the thoracic pedicles, and 5-7 mm in the lumbar pedicles) which means that adopting our classification of including screws with less than half the screw diameter (< 2-2.5 mm perforation in screws with 4-5 mm diameter used in the thoracic spine) in grade 0 placement is acceptable and in accordance with the conclusion of most studies, namely that the pedicle perforation of  $\leq 2$  mm is harmless and can thus be classified as a normal and acceptable placement. The different grades of misplacement in our grading system takes into account the relation between the magnitude of misplacement and the screw diameter. Thus grade 1 lateral- or medial misplacement includes screws with more than half screw diameter outside the pedicle wall. In practice grade 1 medial- and lateral cortical misplacement include 4 mm sized screws with perforation of more than 2 mm, 5 mm sized screws with perforation of more than 2.5 mm, 6 mm sized screws with perforation of more than 3 mm etc.

Analysis (posthoc) of data from previous study<sup>14</sup> of measurement of thoracic pedicle width at the level Th7-Th9 (data on pedicular width not presented in that study) has shown that 38 % of pedicles had a width of  $\leq 4$  mm and 71 % of pedicles had a width of  $\leq 5$  mm. Therefore, using a pedicle screw of 4-5 mm in the

thoracic spine means that 38–71 % of screw placements are inclined for cortical violation of 1-2 mm irrespectively of the skillfulness of the surgeon. From our experience the pedicular width at the upper thoracic spines is not seldom  $\leq 3$  mm and in one report the pedicular width at the level of T4 was found to be 2.6 mm<sup>30</sup>. Placing a 5 mm sized screw through pedicles with 2.6 mm diameter means a misplacement of at least 2.4 mm. In practice this means that all screws inserted through these pedicles should be classified as misplaced if the grading of misplacement is based on cortical violation measured in mm. However pedicle screws fixation in the pediatric population performed by properly trained spinal surgeons, can be performed safely to treat a variety of spinal disorders<sup>31</sup> as pedicular expansion may occur during the screw insertion.

The final reason for proposing our new grading system is the fact that none of the previously proposed grading system included all possible types of screw misplacement<sup>32</sup>. Our grading system also includes perforation into neural foramina and endplate perforations, which both are rarely presented and discussed in the literature although they can cause nerve root injuries and may accelerate disc degeneration, respectively<sup>33</sup>.

Taking these facts into consideration, our grading system is to be considered more practical, feasible and easier to perform than many of the previously used grading systems using perforations of < 2, 2-4 and > 4 mm as basis for their grading. In endplate perforation and in anterior cortical perforation the relation of screw tip to the endplate and vertebral anterior cortex respectively was the subject of analysis. That is the reason for classifying these types of misplacement and the foraminal perforation only into two grades – grade 0 and grade 1. The *interobserver* agreement in the assessment of anterior cortical perforation and foraminal perforation were fair (K-value 0.39 and

0.40 respectively) whereas the corresponding values for *intraobserver* agreement were substantial (K-value 0.62 and 0.66 respectively). We believe that this difference depends on the fact that observer 1 who did the assessment twice was the neuroradiologist who developed the protocol of low-dose spine CT and who is usually involved in the daily assessment of these examinations. The differences in K-value are more evident in anterior cortical perforation and foraminal perforation (Table 5). This depends partly also on the fact that the radiologists in general are more familiar with lateral- and medial cortical perforations whereas foraminal perforation, which we included in our new grading system, is rather rare and previously less frequently analyzed and reported type of misplacement. Thus the substantial *intraobserver* agreement compared with the fair *interobserver* agreement in assessment of anterior cortical perforation and foraminal perforation indicates that the reliability of low-dose CT spine is high if the evaluating radiologist is experienced and more familiar with assessment of screw misplacement. Although the *interobserver* agreement in the assessment of anterior cortical perforation and foraminal perforation were fair, the risk to benefit ratio of using the low-dose CT instead of standard dose CT (35 fold lower radiation dose)<sup>14</sup> should validate our recommendation to use the low-dose CT and the here proposed grading system in the assessment of screw placement.

In summary this study has shown that the low-dose spine CT is a reliable method in evaluating screw placement in patients with AIS after posterior correction and stabilization using titanium implants. The substantial *interobserver* and *intraobserver* agreement in the evaluation of screw placement suggest that simplifying the grading system reduces the influence of individual variations and avoids the inherent error of measurements in millimeter and submillimeter level when

these are performed in the Picture Archiving and Communication System (PACS). However, the reliability of low-dose spine CT is fair in evaluating the anterior cortical perforation and foraminal perforation. This reliability can be increased with increasing experience of the reader.

## ■ Conclusion

Using our proposed grading system for screw misplacement, the low-dose spine CT has shown to be reliable in this assessment of lateral-, medial cortical perforation as well as endplate perforation and the grading system was found to be feasible and practical. The reliability of low-dose CT in evaluation of the anterior cortical perforation and foraminal perforation can be increased if the reading radiologist is experienced and familiar with evaluation of screw placement. Based on the results of this study we recommend using CT with low radiation dose in the postoperative follow up of patients with AIS after posterior correction and stabilization with titanium implants instead of using other CT protocols with unnecessarily higher radiation doses to these young individuals.

### ■ Key points:

- Using the here proposed grading system, the low radiation dose spine CT is a reliable method to assess the accuracy of pedicle screw placement in patients with AIS after posterior corrective surgery using titanium implants.
- The here proposed grading system of screw misplacement has shown to be feasible and practical.
- Beside lateral, medial and anterior cortical perforations, endplate perforation and foraminal perforation should also be considered when evaluating screw placement.
- Postoperative CT-follow up of young patients with AIS should be done according to protocols with low radiation dose as the one proposed in this study.



## References:

1. Roy-Camille R, Saillant D, Mazel C. Internal fixation of lumbar spine with pedicle screw plating. *Clin Orthop* 1986;203:7–17.
2. Luque ER. Interpeduncular segmental fixation. *Clin Orthop* 1986;203:54–7.
3. Suk SI, Lee CK, Kim WJ, et al. Segmental pedicle screw fixation in the treatment of thoracic idiopathic scoliosis. *Spine* 1995;20:1399–405.
4. Whitecloud TS, Skalley T, Cook SD, et al. Roentgenographic measurement of pedicle screw penetration. *Clin Orthop* 1989;245:57–68.
5. Belmont PJ Jr, Klemme WR, Dhawan A, Polly DW Jr. In vivo accuracy of thoracic pedicle screws. *Spine* 2001;26:2340–6.
6. Weinstein JN, Spratt KF, Spengler D, et al. Spinal pedicle fixation: reliability and validity of roentgenogram-based assessment and surgical factors on successful screw placement. *Spine* 1991;5:576–9.
7. Farber GL, Place HM, Mazur RA, et al. Accuracy of pedicle screw placement in lumbar fusions by plain radiographs and computed tomography. *Spine* 1995;20:1494–9.
8. Laine T, Mäkitalo K, Schlenszka D, Tallroth K, Poussa M, Alho A. Accuracy of pedicle screw insertion: a prospective CT study in 30 low back patients. *Eur Spine J* 1997;6: 402–5.
9. Berlemann U, Heini P, Müller U, et al. Reliability of pedicle screw assessment utilizing plain radiographs versus CT reconstruction. *Eur Spine J* 1997;6:406–11.
10. Rao G, Brodke DS, Rondina M, et al. Inter- and intraobserver reliability of computed tomography in assessment of thoracic pedicle screw placement. *Spine* 2003;28:2527–30.
11. Yoo JU, Ghanayem A, Petersilge C, et al. Accuracy of using computed tomography to identify pedicle screw placement in cadaveric human lumbar spine. *Spine* 1997;22:2668–71.
12. Learch TJ, Massie JB, Pathria MN, et al. Assessment of pedicle screw placement utilizing conventional radiography and computed tomography: a proposed systematic approach to improve accuracy of interpretation. *Spine* 2004;29:767–73.
13. Krag MH, Weaver DL, Beynon BD, et al. Morphometry of the thoracic and lumbar spine related to transpedicular screw placement for surgical spinal fixation. *Spine* 1988;13:27–32.
14. Abul-Kasim K, Overgaard A, Maly P, Ohlin A, Gunnarsson M and Sundgren PC. Low dose helical computed tomography (CT) in the perioperative work up of adolescent idiopathic scoliosis. *Eur Radiol* 2009;19:610-18. Epub 2008, sept 23.
15. Upendra BN, Meena D, Chowdhury B, Ahmad A and Jayaswal A. Outcome-Based Classification for Assessment of Thoracic Pedicular Screw Placement. *Spine* 2008;33: 384–390.
16. Silvestre MD, Parisini P, Lolli F and Bakaloudis G. Complications of thoracic pedicle screws in scoliosis treatment. *Spine* 2007;32: 1655–1661.
17. Suk SI, Kim WJ, Lee SM, et al. Thoracic pedicle screw fixation in spinal deformities: are they really safe? *Spine* 2001;26:2049–57.
18. Coe JD. Complications in Spinal Fusion for Adult Scoliosis. A Report of the Scoliosis Research

- Society Morbidity and Mortality Committee. Abstract from the 2006 SRS Annual Meeting. Available via: <http://www.spineuniverse.com/displavarticle.php/article2074.html>. Accessed 17 april 2008.
19. Abul-Kasim, K, Gunnarsson M, Maly P, Ohlin A, and Sundgren PC. Radiation dose optimization in CT planning of corrective scoliosis surgery. A phantom study. *The Neuroradiology Journal* 2008; 21: 374-382.
  20. Landis JR, Koch GG. The measurement of observer agreement for categorical data. *Biometrics* 1977;33:159-74.
  21. Landis JR, Koch GG. An application of hierarchical kappa-type statistics in the assessment of majority agreement among multiple observers. *Biometrics* 1977;33:363-74.
  22. Sapkas GS, Papadakis SA, Stathakopoulos DP, et al. Evaluation of pedicle screw position in thoracic and lumbar spine fixation using plain radiographs and computed tomography. A prospective study of 35 patients. *Spine* 1999;24:1926-9.
  23. Lonstein JE, Denis F, Perra JH, Pinto MR, Smith MD, Winter RB. Complications associated with pedicle screws. *J Bone Joint Surg Am* 1999, 81:1519-28.
  24. Antevil JL, Sise MJ, Sack DI, Kidder B, Hopper A, Brown CV. Spiral computed tomography for the initial evaluation of spine trauma: A new standard of care? *J Trauma* 2006 Aug;61:382-7.
  25. Gertzbein SD, Robbins SE. Accuracy of pedicular screw placement in vivo. *Spine* 1990;15:11-4.
  26. Liljenqvist UR, Halm HF, Link TM. Pedicle screw instrumentation of the thoracic spine in idiopathic scoliosis. *Spine* 1997;22:2239-45.
  27. Kim YJ, Lenke LG, Bridwell KH, Cho YS, Riew KD. Free hand pedicle screw placement in the thoracic spine: is it safe? *Spine* 2004;29:333-42.
  28. Liljenqvist U, Lepsien U, Hackenberg L, et al. Comparative analysis of pedicle screw and hook instrumentation in posterior correction and fusion of idiopathic thoracic scoliosis. *Eur Spine J* 2002;11:336-43.
  29. Reichle E, Morlock M, Sellenschloh K, et al. Definition of pedicle malposition. Primary stability and loosening characteristics of pedicle screws in relation to position: spongy anchoring, cortical anchoring, perforation and malposition. *Orthopade* 2002;31:402-5.
  30. Parent S, Labelle HL, Skalli W et al. Thoracic Pedicles Morphometry in Vertebrae from Scoliotic Spines. Abstract from the SRS 2002 Annual Meeting. Available via: <http://www.spineuniverse.com/displavarticle.php/article2290.html>. Accessed 18 april 2008.
  31. Brown CA, Lenke LG, Bridwell KH, et al. Complications of pediatric thoracolumbar and lumbar pedicle screws. *Spine* 1998;23:1566-71.
  32. Kosmopoulos V, Schizas C. Pedicle screw placement accuracy: a meta-analysis. *Spine* 2007;32:E111-E120.
  33. Melrose J, Ghosh P, Taylor TKF, et al. A longitudinal study of the matrix changes induced in the intervertebral disc by surgical damage to the annulus fibrosus. *J Orthop Res* 1992;10:665-76.



## Paper IV



# Radiological and clinical outcome of screw placement in adolescent idiopathic scoliosis. Evaluation with low-dose computed tomography

Kasim Abul-Kasim, MD<sup>\*</sup>; Acke Ohlin, MD, Ph D<sup>†</sup>; Anita Strömbeck, MD<sup>\*</sup>; Pavel Maly, MD, Ph D<sup>\*</sup>; Pia C Sundgren, MD, Ph D

**Corresponding author:** Kasim Abul-Kasim. Faculty of Medicine, University of Lund, Department of Radiology, Section of Neuroradiology, Malmö University Hospital, 205 02 Malmö, Sweden

PHONE +46 40 33 87 90, FAX +46 40 33 87 98, E-MAIL [Kasim.AbulKasim@med.lu.se](mailto:Kasim.AbulKasim@med.lu.se)

<sup>\*</sup>Dept. of Radiology, Section of Neuroradiology, University of Lund, Malmö University Hospital, Sweden.

<sup>†</sup>Dept. of Orthopaedic Surgery, University of Lund, Malmö University Hospital, Sweden.

## Abstract:

**Study design.** A retrospective study.

**Objectives.** To assess pedicle screw placement in patients with adolescent idiopathic scoliosis (AIS), using computed tomography (CT) with low radiation dose and to evaluate the clinical outcome in patients with misplaced pedicle screws.

**Summary and background data.** CT is the method of choice in the assessment of screw placement. To our knowledge there is no study reporting the use of low-dose CT in such assessment.

**Materials and methods.** Forty-nine consecutive postoperative low-dose CT (873 screws; 79 % thoracic) of patients with AIS after posterior surgical correction and stabilization using titanium all-pedicle screw construct, were retrospectively analyzed. A new grading system was developed to distinguish between five types of misplacement: lateral, medial and anterior cortical perforations as well as endplate perforation and foraminal perforation. The grading system is based on whether the cortical violation is partial or total rather than on mm-basis.

**Results.** The overall rate of pedicle screw misplacement was 17% (n=149), 8% of which were laterally placed and 6.1 % were medially placed. The rates of anterior cortical-, endplate- and foraminal perforation were 1.5%, 0.9%, and 0.5 %, respectively. Lateral cortical perforation was more frequent in the thoracic spine (P= 0.005) whereas other types of misplacement including medial cortical perforation were more frequent on the left and the concave side of scoliotic curves (P=0.002 and 0.003). No neurovascular complications were reported.

**Conclusion.** In the absence of neurovascular complications can spinal canal encroachment of up to 5 mm on the concavity and up to 7 mm on the convexity of scoliotic apex likely be tolerated. The low-dose CT used for the evaluation of pedicle screw means exposing young individuals with AIS to a significantly lower radiation dose than do the other protocols used in daily clinical practice.

■ **Key words.** Screw misplacement; neurovascular complication; medial cortical perforation; lateral cortical perforation; anterior cortical perforation; endplate perforation; foraminal perforation.

**Submitted to "Spine" 2009, January 5.**

Posterior instrumentation with transpedicular screws only as anchors has gained increasing popularity in the correction and stabilization of scoliotic

deformities. Besides providing better stabilization, all-pedicle screw construct provides better correction of scoliosis.<sup>1-4</sup> Instrumentation using pedicle screw was originally described by Michele and

Krueger in 1949.<sup>5</sup> Harrington and Tullos were the first to use pedicle screws in the treatment of spondylolisthesis<sup>6</sup>, thereafter Roy-Camille et al reported extensive experience with the use of pedicle screws and plates in the spinal fixation after vertebral fractures.<sup>7</sup> The use of pedicle screws in the corrective surgery of scoliosis was introduced in 1986.<sup>8</sup> Extensive pedicle screw insertion in the correction and stabilization of the scoliosis including the thoracic spine, nowadays known as all-pedicle screw construct, was introduced by Suk et al 1994.<sup>9</sup> The safety and the complications of thoracic pedicle screw insertion have been extensively discussed, investigated, and reported. Among the most serious complications are neurovascular complications such as spinal cord injuries caused by medially placed screws and false aortic aneurysm caused by laterally placed screws. Other, not commonly, encountered complications such as nerve root injuries, pedicle fractures, dural injuries, infection and implant loosening have been reported.<sup>10-16</sup>

Assessment of misplacement of pedicle screws has been reported in many studies.<sup>10,17-20</sup> The best method of performing such an assessment is CT of the spine which has been shown to be reliable in the assessment of screw placement<sup>21</sup> and in one study showed 10 times as many pedicle violations as did plain radiography.<sup>22</sup> Because idiopathic scoliosis affect predominantly young individuals, radiation protections measures are mandatory. CT with low radiation dose has recently shown to be a reliable method in the assessment of pedicle screw placement with substantial interobserver and intraobserver agreement.<sup>23</sup>

Review of studies dealing with assessment of accuracy of pedicle screw insertion and clinical outcome of these operative procedures reveal a clear discrepancy between the rate of misplacement and the rate of actual complications in terms of symptoms and neurological deficit related to screw

misplacement. The rate of screw misplacement in the thoracic region varies from 20% to 50%.<sup>4,10-11,20,24-25</sup> The rate of neurovascular complications ranges from 0 to 1%.<sup>11,16</sup> However there has been reports of serious resolving or permanent complications sometimes necessitating surgical revision or removal.<sup>11-15,20,25</sup> In almost all reports no complications have been reported when pedicle breach was less than 2 mm and a potential for neurological complication was believed to exist only when medial wall perforation exceed 4 mm.<sup>20</sup> Regarding grading systems for assessment of different types of misplacement of pedicular screws, up to 35 methods have been used for this purpose.<sup>26</sup> In the view of the above mentioned facts a new grading system (in detailed described in Materials and Methods) has been developed<sup>23</sup> and used in this study.

Low-dose CT of spine has been recently introduced in the perioperative workup of AIS<sup>27</sup> and to our knowledge there is no report on assessment of the accuracy of pedicle screw insertion using this method. The aim of this study was to assess the pedicle screw placement in patients with AIS operated on with posterior correction and stabilisation, using a spine CT with low radiation dose. The other aims of this study were to study the relationship of misplaced screws to the surrounding structures and to evaluate the clinical outcome in patients with misplaced pedicle screws.

## ■ Materials and methods

To the date of analysis a total of 49 patients with AIS who had undergone posterior corrective surgery and stabilization with titanium all-pedicle screw construct have given their consent to be included in this retrospective analysis. The CT examinations were performed with low-dose spine CT 6 weeks after surgery. Thirty eight patients (78%) were female and 11 patients (22%) were male. The mean and the median value of patient age were  $16.8 \pm 4.2$  (mean  $\pm$ SD) and 16 years.

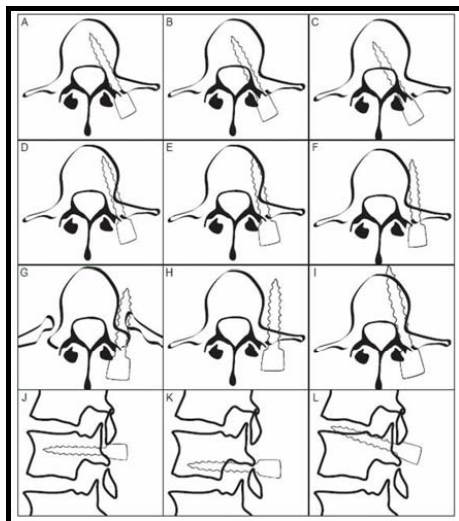
All examinations were performed on 16-slice CT-scanner (SOMATOM Sensation 16, Siemens AG Forchheim, Germany) with scan parameters recommended by a previously conducted phantom study<sup>28</sup> and used in patient series.<sup>27</sup> To minimize the streak artifacts from the implants reformatted 1-mm thick axial images with soft tissue algorithm and 2-mm thick coronal and sagittal reformatted images with the same soft tissue algorithm have been used for analysis. Images with skeletal algorithm as well as 3-dimensional images were also available to the readers.

The type of placement of every individual screw included in the analysis was assessed using our new grading system. The following types of misplacement were included in this grading system:

1. Medial cortical perforation (MCP). The placement is graded into grade 0 when the pedicle screw passes totally within the pedicle medullary canal or with minimal breach of medial pedicular cortex ( $<1/2$  the screw diameter passes medial to the medial pedicular cortex), grade 1 when the screw is partially medialised ( $>1/2$  the screw diameter passes medial to the medial pedicular cortex) and grade 2 when the screw is totally medialised (screw passes

totally medial to the medial pedicular cortex).

2. Lateral cortical perforation (LCP). The placement is graded into grade 0 when the pedicle screw passes totally within the pedicle medullary canal or with minimal breach of lateral pedicular cortex ( $<1/2$  the screw diameter passes lateral to the lateral pedicular cortex), grade 1 when the screw is partially lateralised ( $>1/2$  the screw diameter passes lateral to the lateral pedicular cortex) and grade 2 when the screw is totally lateralised (screw passes totally lateral to the lateral pedicular cortex).
3. Anterior cortical perforation of vertebral body (ACP). The placement is graded into grade 0 when the screw is contained within the vertebral body and grade 1 when the screw tip penetrates the anterior cortex of corresponding vertebral body. The degree of penetration is reported in mm and the relationship to the surrounding structures is reported and evaluated.
4. Endplate perforation (EPP). The placement is graded into grade 0 when the screw tip is contained within the vertebral body and grade 1 when the screw tip penetrates the upper or the lower endplate into the adjacent disc space.
5. Foraminal perforation (FP). The placement is graded into grade 0 when the screw passes



**Figure 1:** The types of screw placement according to the new grading system and examples of the relationship between different misplaced screws and the surrounding structures. (A) Normally placed screw. (B) Grade 1 MCP. Screw anchors in the vertebral body. (C) Grade 2 MCP. Screw anchors in the vertebral body. (D) Grade 1 LCP. Screw anchors in the vertebral body and abuts its inner cortex. (E) Grade 1 LCP. Screw abuts outer cortex of the vertebral body and does not anchor in the vertebral body. (F) Grade 2 LCP. Screw passes through the PRU and does not anchor in the vertebral body. (H) Grade 2 LCP. Screw with paravertebral passage. (I) ACP. (J) Normally placed screw on sagittal plane. (K) FP. Perforation of underlying neural foramen. (L) EPP: Perforation of upper endplate.



through the pedicle and grade 1 when the screw penetrates the pedicle border into the overlying or underlying neural foramen.

All examinations included in the analysis were read independently by two senior radiologists (KAK, AS) of whom one (observer 1, KAK) performed the analysis at two different occasions with 6-week interval. Because the evaluations were done by two different readers and at three different occasions, three possible types of screw position status occurred: (1) Screws where both readers totally agreed upon their position, i.e. the placement status was evaluated exactly the same at all three occasions, (2) screws where the two readers agreed upon their position at least on two occasions, and (3) screws where the two readers disagreed about their position. Screws of the latter group were subjected to a joint evaluation by both readers to reach a consensus about the status of the screw placement. Status of those screws in which no agreement could be reached at the joint evaluation was regarded as questionable.

A detailed analysis of the misplaced screws was performed and the relationship of every individual screw to the following structures was studied: (a) concavity or convexity of the scoliotic curve, (b) apex of the curve, (c) surrounding bony structures: lateral and medial pedicular cortex, vertebral body as well as pedicle rib unit (PRU), and (d) aorta. The degree of encroachment in the spinal canal was measured in mm in case of medially placed pedicle screws. The encroachment was defined as the distance between medial pedicular cortex and the medial border of the medially placed screw. The distance between the laterally placed pedicle screws and the lateral border of vertebral body was also measured in mm. Figure 1 illustrates the types of screw misplacement according to the new grading system as well as examples of different screw relationship to the surrounding structures.

Finally an outcome-based analysis of the screw placement was performed and

the medical records of all patients with total perforation of pedicular cortex were scrutinized. The intraoperative course of events, the medical status in the immediate postoperative period as well as at the out-patient follow up eight weeks after surgery were evaluated with respect to the occurrence of symptoms and signs of neurovascular complication that could be related to screw misplacement. At the 8-week follow-up visit all patients were asked about any history of new neurological symptom related to medullary or nerve root compromise with specific questions about the occurrence of pain (local or radicular), numbness, paraesthesia, extremity weakness, muscle spasm, sensory loss, as well as bowel and bladder changes. Muscle strength, gait, tendon reflexes and Babinski sign were examined. Sensory modalities for pain, fine touch, pressure, vibration sense and position sense were also tested. Evidence of myelopathy with increased reflexes, abnormal clonus and Babinski sign were specifically sought for.

Statistical analysis was performed by means of SPSS version 15. Chi-square test was performed to test the significance of association between the misplacement in general, medial cortical perforation and lateral cortical perforation with the following variables: (1) level of misplacement (thoracic or lumbar), (2) side of misplacement (right or left), (3) curve concavity or convexity, and (d) scoliotic apex. Statistical significance was set to  $< 0.05$ .

#### *Ethical committee approval*

The regional radiation protection committee approval to use this low-dose spine CT in the workup of patients with scoliosis was obtained. The regional ethical committee approval to conduct this retrospective analysis was also obtained. The patients were provided with written information about the study and all patients included in the analysis have given their written consent.

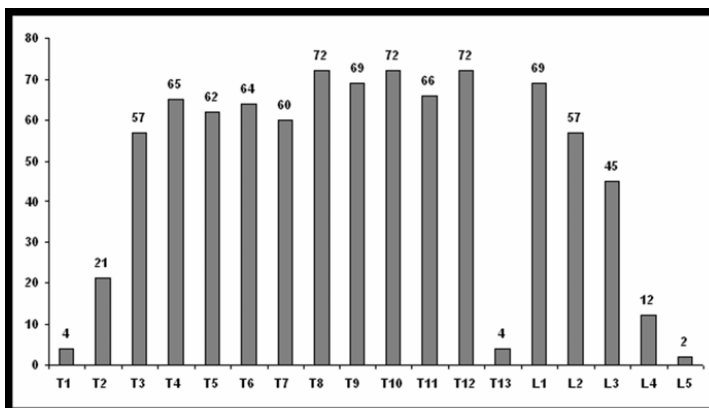
### *Operative technique:*

All operations were performed according to a standardized technique through a posterior exposure. The entry points for screws were determined after identification of the bony landmarks. At each assumed entry point, a 3 cm long titanium bone marker with a diameter of 1 mm, was inserted approximately 3 mm deep. By means of a C-arm fluoroscopy in the AP view, the position as well as the degree of rotation was estimated. The position was considered as acceptable when having the marker as the bull's eye on the screen. An assistant made notes on the observations of position or degree of angulation of each marker. When preparing the screw canal the assistant read, at each level, the previously estimated trajectory. The screw canal was prepared with a hand-driven drill, which was introduced stepwise having a constant feeling of bone resistance at the bottom. After drilling, a probe or "feeler" was used to palpate the bottom and borders of the screw canal. Thereafter, self-tapping transpedicular screws were sequentially introduced. After completion of screw insertion, a check of screw position was undertaken by means of the C-arm fluoroscopy in oblique views. Curve correction was performed by simple rod derotation as well as direct vertebral

rotation (DVR)<sup>29</sup> when having only the concave rod in place. Prior to rod insertion, the facet joints were destructed, and before inserting the stabilizing convex rod, all posterior bony elements were decorticated. Only local bone grafts were used. All operations were performed under spinal cord monitoring by means of motor evoked potential (MEP).

### ■ Results

Right convex thoracic curve was the most frequent deformity (34 patients, 69 % of study population) followed by S-formed double curves with right convex thoracic- and left convex lumbar curve which was encountered in 10 patients (20 %). The remaining had left convex thoracic curve (n=2) and left convex lumbar curve (n=3). Three of scoliotic apices were at the level of L2, 2 at the level of T12, and one at the level of T5. The remaining curves (88 %) had their apex at T8 or T9. In cases of double curves, the caudal curve had their apex at L1 or L2. The total numbers of screws analyzed were 873; 79% of all screws were inserted in the thoracic spines. 31 % of screws were inserted in the vertebral levels around scoliotic apex (T7-T10). The distribution of the pedicle screw insertion is shown in Figure 2.



**Figure 2:** Distribution of the pedicle screws insertion in different vertebral levels. T: thoracic, L: Lumbar.

**Table 1.** Results of the radiological assessment of pedicle screw placement.

	Total	T	L	Dx	Sin	Cc	Cx	Apex	None-apex
Medial placement	54 (6.1%)	44 (81%)	10 (19%)	14 (26%)	40 (74%)	33 (61%)	21 (39%)	15 (28%)	39 (72%)
Lateral placement	70 (8%)	65 (93%)	5 (7%)	38 (54%)	32 (46%)	30 (43%)	40 (57%)	26 (37%)	44 (63%)
Anterior cortical perforation	13 (1.5%)	13 (100%)	0 (0%)	3 (23%)	10 (77%)	10 (77%)	3 (23%)	2 (15%)	11 (85%)
Endplate perforation	8 (0.9%)	1 (12%)	7 (88%)	6 (75%)	2 (25%)	6 (75%)	2 (25%)	2 (25%)	6 (75%)
Foraminal perforation	4 (0.5%)	2 (50%)	2 (50%)	0 (0%)	4 (100%)	4 (100%)	0 (0%)	2 (50%)	2 (50%)
Misplacement: Total	149 (17%)	125 (84%)	24 (16%)	61 (41%)	88 (59%)	83 (56%)	66 (44%)	47 (31%)	102 (69%)
Normal placement	721 (82.7%)	560 (78%)	161 (22%)	253 (35%)	468 (65%)	444 (62%)	277 (38%)	209 (29%)	512 (71%)
Questionable	3 (0.3%)	3 (100%)	0 (0%)	2 (67%)	1 (33%)	1 (33%)	2 (67%)	0 (0%)	3 (100%)
Total (all screws included in analysis)	873 (100%)	688 (79%)	185 (21%)	316 (36%)	557 (64%)	528 (61%)	345 (39%)	256 (29%)	617 (71%)

T: thoracic, L: lumbar, Dx: right, Sin: left, Cc: pedicle screws inserted on the concave side of the curve. Cx: pedicle screws inserted on the convex side of the curve. Apex: pedicle screws inserted at the scoliotic apex. None-apex: pedicle screws inserted at levels other than apex.

The results of radiological assessment of screw placement are shown in Table 1. The overall rate of misplacement was 17 % while the acceptably placed screws amount to 82.7 %. Status of three screws (0.3 %) was questionable. The rates of lateral cortical perforation, medial cortical perforation, anterior cortical perforation, endplate perforation and foraminal perforation were 8 %, 6.1 %, 1.5 %, 0.9 %, and 0.5 % respectively. Of the misplaced screws 84% were thoracic, 59 % were inserted in pedicles on the left hand side, 56 % were inserted in pedicles on the concave side of the scoliotic curves, and 31% were inserted at or around the scoliotic apex. Of the 54 screws with MCP 40 (74 %) were on the left side ( $P = 0.005$ ),

Table 2. The association between MCP and the level of misplacement (thoracic or lumbar), concavity of the curve and the apex of the curve were statistically non-significant. Of 70 screws with LCP 65 (93 %) were thoracic ( $P = 0.005$ ). Regarding the side and relation to scoliotic curves, screws with LCP were slightly more frequent on the right side and on the convexity of scoliotic curves (54 % and 57 % respectively) whereas other types of screw misplacement were reported 2.5 times and twice as frequent on the left side and the concavity of scoliotic curves respectively ( $P = 0.002$  and  $0.003$  respectively), Table 2. The results of the detailed analysis of the screw placement are shown in Table 3.

**Table 2.** Results of Chi-square test between misplacements in general, MCP and LCP with different predictors in the first column. Statistical significance is marked with \*.

	Misplacement, all		P-value	Misplacement		P-value	Misplacement		P-value
	Yes	No		MCP	Other		LCP	Other	
Thoracic	125	560		44	81		65	60	
Lumbar	24	161	0.091	10	14	0.546	5	19	0.005*
Right	61	253		14	47		38	23	
Left	88	468	0.176	40	48	0.005*	32	56	0.002*
Concave	83	444		33	50		30	53	
Convex	66	277	0.181	21	45	0.317	40	26	0.003*
Apex	47	209		15	32		26	21	
Non-apex	102	512	0.533	39	63	0.456	44	58	0.166

Regarding medially placed screws, 35 of 37 partially medialised screws (grade 1 MCP) anchor in their vertebral bodies. The degree of encroachment was measured in mm in cases where the screws totally perforated the medial pedicular cortex (grade 2 MCP, Figure 3D). This was

shown to vary from 3-5 mm (n=14 of 17) to 6-7 mm (n=3). All screws but one with encroachment of 3-5 mm abut the medial pedicular cortex and anchor in the respective vertebral body. Three screws with 6-7 mm encroachment had 2-3 mm interval to the medial pedicular cortex.

**Table 3:** Detailed analysis of different types of misplacement, showing the relationship of every individual misplaced screw to the surrounding bony structures, the scoliotic curve and the scoliotic apex.

Misplacement	Remarks	Level			Side		Relation to curve		Relation to apex	
		Total	T	L	Dx	Sin	Cc	Cx	Apex	None
<b>Grade 1 MCP</b>	Anchor in vertebral body	35	29	6	10	8	21	14	9	26
	Anchor to vertebral body with 5 mm of the screw tip	2	1	1	0	2	1	1	1	1
	<b>Total</b>	37	30	7	10	27	22	15	10	27
<b>Grade 2 MCP</b>	3-4 mm encroachment, abuts medial pedicular cortex and anchor in vertebral body	9	8	1	1	8	9	0	0	9
	4 mm encroachment, screw tip in the spinal canal	1	1	0	1	0	0	1	1	0
	5 mm encroachment, abuts medial pedicular cortex and anchor in vertebral body	4	3	1	2	2	1	3	3	1
	6 mm encroachment, anchor in vertebral body	1	1	0	0	1	1	0	0	1
	7 mm encroachment, screw tip in the spinal canal	2	1	1	0	2	0	2	1	1
	<b>Total</b>	17	14	3	4	13	11	6	5	12
<b>Grade 1 LCP</b>	Anchor in vertebral body	22	19	3	8	14	15	7	9	13
	Passes laterally in the vertebral body and abuts their inner cortex	8	8	0	5	3	3	5	5	3
	<b>Total</b>	30	27	3	13	17	18	12	14	16
<b>Grade 2 LCP</b>	Anchor in vertebral body	2	2	0	0	2	1	1	1	1
	Abuts lateral pedicular cortex and vertebral body. Do not anchor in the vertebral body	25	24	1	15	10	9	16	7	18
	Passes through pedicle rib unit (PRU) with screw tip in the PRU	7	7	0	6	1	1	6	2	5
	Passes through pedicle rib unit (PRU) with screw anterior to PRU	1	1	0	0	1	1	0	1	0
	Paravertebral passage	5	4	1	4	1	0	5	1	4
	<b>Total</b>	40	38	2	25	15	12	28	12	28
<b>ACP</b>	Pure ACP	8	8	0	2	6	6	2	0	11
	Associated with LCP	5	5	0	1	4	4	1	2	0
	<b>Total</b>	13	13	0	3	10	10	3	2	11
<b>EPP</b>	Upper endplate	8	1	7	6	2	6	2	2	6
	Lower endplate	0	0	0	0	0	0	0	0	0
	<b>Total</b>	8	1	7	6	2	6	2	2	6
<b>FP</b>	Overlying foramen	2	0	2	0	2	2	0	0	2
	Underlying foramen	2	2	0	0	2	2	0	2	0
	<b>Total</b>	4	2	2	0	4	4	0	2	2
<b>Total number of all misplacements</b>		149	125	24	61	88	83	66	47	102

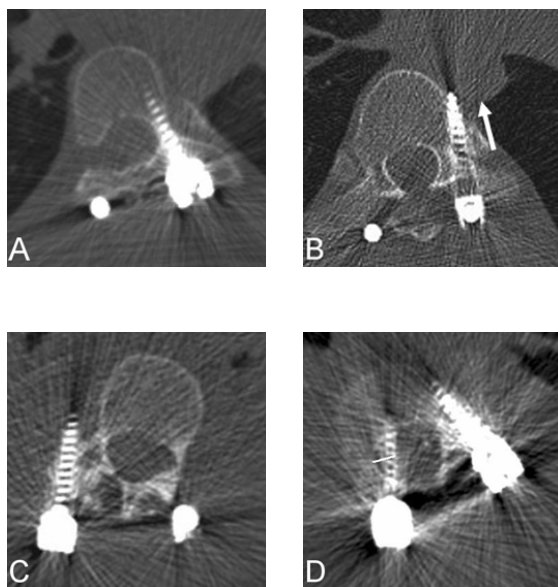
T: thoracic, L: lumbar, Dx: right, Sin: left, Cc: pedicle screws inserted on the concave side of the curve. Cx: pedicle screws inserted on the convex side of the curve. Apex: pedicle screws inserted at the scoliotic apex. None-apex: pedicle screws inserted at levels other than apex.

The tip of these screws did not anchor in the respective vertebral bodies but ended in the anterior part of the spinal canal or touched the posterior cortex of the vertebral bodies. No electrophysiological abnormalities were reported during the insertion of these misplaced screws and no neurological deficit was reported in the immediate postoperative period or in the outpatient follow up 8 weeks after the surgery.

Among the 30 screws which were partially lateralised (grade 1 LCP) 22 anchored in the respective vertebral bodies while 8 screws passed laterally through the vertebral bodies and abuted their inner cortex resulting in suboptimal hold in the vertebral bodies. The majority of screws placed totally lateral to pedicles (n= 25 of 40) abuted the outer pedicular cortex of the vertebral body but did not anchor in the respective vertebral bodies. Seven screws passed through PRU with screw tip in the PRU. Five screws had paravertebral passage (4 on the right side) with an interval of 1-6 mm to the lateral border of

vertebral column, of which one screw made a slight impression in the adjacent pleura on the right side. There were no respiratory complaints after the surgery, and no pleural thickening was reported in the radiological follow up with low-dose spine CT.

The total number of screws with anterior cortical perforation was 13, of which 5 were associated with lateral cortical perforation. The average perforation of anterior cortex was 2.3 mm (range 1-6 mm). All reported cases of endplate perforation (n=8) occurred into the upper endplates while the foraminal perforation (n=4) occurred equally into the overlying and the underlying neural foramen. Figure 3 shows CT-images of different types of screw misplacement and their relation to the surrounding structures. Vicinity of the screw tip to aorta was found in 15 screws (10 patients) of which 6 screws were placed with ACP and 9 with LCP. The average distance between the screw tip and the dorsal or the lateral wall of aorta was 2.9 mm (range 1-4 mm).



**Figure 3:** CT images showing some examples of screw placement and abnormal relationship of pedicle screws to the surrounding structures which were encountered during the detailed analysis of the screw placement. **A:** Axial image showing normally placed screw through the left sided pedicle of T7. **B:** Axial image showing LCP and ACP of pedicle screw through T8 on the left side with screw tip touches the right and posterior margin of aorta (arrow). **C:** Axial image showing grade 2 LCP with paravertebral passage of pedicle screw which supposed to pass through the right pedicle of L2. **D:** Axial image showing the way of measurement of the degree of encroachment of medially placed pedicle screws. The encroachment is the distance between the medial pedicular cortex and the medial border of the medially placed screw, given in millimeter.

## ■ Discussion

In this study placement of 873 pedicle screws has been evaluated postoperatively with spine CT using low radiation dose. This is the first report in the literature on the assessment of screw placement with low-dose spine CT. A newly developed grading system was used<sup>23</sup> for evaluation of five types of misplacements: medial cortical perforation, lateral cortical perforation, anterior cortical perforation, endplate perforation and foraminal perforation. The degree of perforation of pedicular cortex was not based on millimeter but on the evaluation of whether the cortical violation was partial or total.

Literature review of some of the reports of misplacement of pedicle screw based on CT evaluation<sup>4,10,17,20,24,30-42</sup> is shown in Table 4. The most commonly reported types of misplacements are the lateral and medial placements. The overall rate of misplacement reported in this study was 17%. The misplacement rate reported in the literature varies widely from 2.7 % to 50.7 %. Three of the studies dealing exclusively with assessment of pedicular screw placement in scoliosis showed a misplacement rate of 5.7, 18.5%, and 25%,<sup>10,40,4</sup> while a fourth study that partly included assessment of screw placement following scoliosis surgery showed a misplacement rate of 50.7 % among the scoliotic group.<sup>20</sup> By excluding misplacement with pedicular violation of less than 2 mm, the misplacement rate in the latter study decreases to almost 32%. Misplacement rate of 2.7 % has been reported from a study dealing with screw placement in the lumbar region.<sup>34</sup>

From the clinical point of view the medially placed screws and screws whose tip lies in the vicinity of aorta represent the most critical and feared types of misplacement which should be studied in detail because of an attendant risk for neurovascular complications. Gertzbein et al<sup>17</sup> suggested a so called “safe zone” where they suggested that a medial canal encroachment of up to 4 mm between T10

and L4 can be tolerated. They reported 2 cases of spontaneously resolving minor neurological complications in patients with canal encroachment of 4–8 mm. Kim et al<sup>33</sup> have also expressed a tolerant position in this issue suggesting a “definite safe zone” with medial encroachment of < 2 mm, a “probable safe zone” with medial encroachment of 2–4 mm, and “questionable safe zone” with medial encroachment of 4–8 mm if there were no abnormal electrophysiological findings during and after the screw insertion. However Vaccaro et al<sup>43</sup> have expressed lower tolerance to pedicle wall violation after their report of about 23 % medial canal encroachment of an average 5 mm in 90 pedicle screws inserted in five fresh-frozen cadavers. Furthermore medially placed screws inserted at the concave side of the scoliotic curve, especially at the apex, with medial canal encroachment exceeding 4 mm carry higher risk of spinal cord injury, as the dural sac and consequently spinal cord shift to the concave side at scoliotic apex.<sup>44</sup> In our study all medially placed screws with an encroachment of 3–4 mm were on the concave side but none of them was at scoliotic apex (Table 3). The one with 4 mm encroachment with screw tip anteriorly in the spinal canal was on the convex side of the scoliotic apex. One of the screws with encroachment of 5 mm was inserted at the concave side of scoliotic apex whereas one screw with encroachment of 6 mm was inserted at the concave side of an upper endvertebra. The two screws with 7 mm encroachment (both with screw tip in the spinal canal) were inserted at convex side of the scoliotic apex and a vertebra above apex respectively.

No study has discussed screw penetration into the vertebral endplates and discs<sup>45</sup>. Studies evaluating injection of substances into the disc and annular injuries have shown disc matrix changes suggestive of degeneration.<sup>45-46</sup> However, because it is unclear whether the presence

of screw tip in the disc space is injurious we found reporting this type of misplacement important for the purpose of future evaluation of occurrence of disk degeneration. Neither the screw tip penetration into the neural foramen has been discussed in literature although it carries a potential risk for nerve root injuries. Our study reported four screws (0.5 %) with foraminal perforation in four different patients of whom none showed evidence of nerve root injury. In our opinion the endplate penetration has to be considered the least injurious of all types of the screw misplacement discussed here as we are dealing with a surgical procedure whose primary aim is spinal fusion. In our opinion pedicle screws with anterior cortical perforation with the screw tip in the vicinity of aorta need to be followed up with a suitable imaging modality, for example CT-angiography, to exclude development of pseudoaneurysm.

The use of spine CT with low radiation dose in the assessment of screw placement in this study actually is the first report of this kind. This effort to reduce the total radiation load from medical use of ionizing radiation is one of the major advantages of this study, which hopefully contribute to reduce risk of cancer development in these young individuals. This low dose CT (effective dose of 0.37 mSv)<sup>27</sup> means a radiation dose that only correspond to 18-74 % of the annual exposure from the natural sources which amount to 1-4 mSv.<sup>47</sup>

## ■ Conclusion

This study of the radiological and clinical outcome of screw placement in patients with AIS after posterior corrective surgery showed that screw placement can be evaluated using low-dose spine CT with the advantage of exposing these young patients to markedly reduced radiation

**Table 4.** Literature review of some of the reported screw misplacements assessed with postoperative CT.

	Patient number	Screw number	Region	Misplacement %	Medial, % of total	Lateral, % of total	Neurovascular complications, number	Others remarks
Liljenqvist <sup>4</sup>	32	120	Thoracic	25	8.3	14.2	0	<b>Scoliosis</b>
Silvestre <sup>10</sup>	25	311	Thoracic	5.7	1	3.8	0	<b>Scoliosis</b>
Gertzbein <sup>17</sup>	40	71	Thoracic	30	25.5	4	2, resolved spontaneously	Reported MCP 6-7 mm
Upendra <sup>20</sup>	24	138	Thoracic	50.7	24.6	24.7	2	<b>Scoliosis</b>
Upendra <sup>20</sup>	34	176	Thoracic	50	31.8	11.4	0	Non-scoliosis
Belmont <sup>24</sup>	40	279	Thoracic	43	14	29	0	
Heary <sup>30</sup>	27	185	Thoracic	13.5	1.6	11.3		
Lekovic <sup>31</sup>	37	277	Thoracic	18	2.2	13	0	Guided insertion 1.8 % aortic abutment
Smorgick <sup>32</sup>	25	112	Thoracic	12.5			0	
Kim <sup>33</sup>	557	49	Thoracic	6.2	1.8	4.7	0	
Schwarzenbach <sup>34</sup>	29	150	Lumbar	2.7		2	6; 5 resolved spontaneously	
Laine <sup>35</sup>	30	152	Lumbar	21			1, root lesion	
Schizas <sup>36</sup>	15	60	Lumbar	23.3	11.6	11.6	1, S1-root	
Wiesner <sup>37</sup>	51	408	L2-S1	6.6	4.6	1.5	1, L4-root	
Sapkas <sup>38</sup>	35	220	T-L	3.63			0	
Lehman <sup>39</sup>	60	1023	T1-L4	10.5	8.6	1.9	0	
Halm <sup>40</sup>	25	178	T5-L4	18.5	4.5	12.4	0	<b>Scoliosis</b>
Güven <sup>41</sup>	75	379	T8-S2	10	3	5	1, root compression	
Odgers <sup>42</sup>	65	238	T11-L5	10.9	7.6	2.5	2	
This study	49	873	T1-L5	17	6.1	8	0	<b>Scoliosis</b>

dose. The overall rate of misplacement reported in this study was 17 %. None of these patients reported symptoms and signs related to neurovascular complications. A spinal canal encroachment of up to 5 mm (almost a total screw diameter) at the concave side and up to 7 mm at the convex side of the scoliotic apex can likely be tolerated providing that neither electrophysiological abnormality was reported during the insertion nor neurological deficit occurred after surgery. A special attention should be paid to pedicle screws with lateral and anterior cortical perforation and the relationship of screw tip to the surrounding structures should be studied in details. Assessment of screw position in relation to vertebral endplates and neural foramen should be included in the analysis of screw placement.

#### ■ Key points

- As in other previously reported studies, lateral cortical perforation is the commonest type of misplacement, followed by medial cortical perforation.
- Screw position in relation to vertebral endplates and neural foramen should be included in the analysis of screw placement.
- As previous reports showed that minimal cortical breach (< 2mm) is harmless with the regard to neurovascular complications, screw misplacement should not be graded on millimeter basis.
- In the absence of evidence of neurovascular complications, a medial cortical perforation of up to 5 mm on the concave side and 7 mm on the convex side of the scoliotic apex can be tolerated.
- Screws with their tip in the vicinity of aorta warrant follow up to exclude vascular complications.

## References

1. Liljenqvist U, Hackenberg L, Link T, et al. Pullout strength of pedicle screws versus pedicle and laminar

- hooks in the thoracic spine. *Acta Orthop Belg* 2001;67:157–63.
2. Kuklo TR, Lenke LG, O'Brien MF, et al. Accuracy and efficacy of thoracic pedicle screws in curve more than 90°. *Spine* 2005;20:222–6.
3. Liljenqvist U, Lepsien U, Hackenberg L, et al. Comparative analysis of pedicle screw and hook instrumentation in posterior correction and fusion of idiopathic thoracic scoliosis. *Eur Spine J* 2002;11:336–43.
4. Liljenqvist UR, Halm HF, Link TM. Pedicle screw instrumentation of the thoracic spine in idiopathic scoliosis. *Spine* 1997;22:2239–45.
5. Albert TJ, Jones AM, Balderston RA. Spinal instrumentation, in Rothman RH, Simeone FA (eds): *The Spine*, ed 3. Philadelphia:WB Saunders, Vol II, 1992:1777–1796.
6. Harrington PR, Tullos HS. Reduction of severe spondylolisthesis in children. *South Med J* 1969;62:1–7.
7. Roy-Camille R, Saillant G, Mazel C. Internal fixation of the lumbar spine with pedicle screw plating. *Clin Orthop* 1986;203:7–17.
8. Luque ER. Interpeduncular segmental fixation. *Clin Orthop* 1986;203:54–7.
9. Suk SI, Lee CK, Min HJ, et al. Comparison of Cotrel-Dubousset pedicle screws and hooks in the treatment of idiopathic scoliosis. *Int Orthop* 1994;18:341–6.
10. Silvestre MD, Parisini P, Lolli F, et al. Complications of thoracic pedicle screws in scoliosis treatment. *Spine* 2007;32:1655–1661.
11. Suk SI, Kim WJ, Lee SM, et al. Thoracic pedicle screw fixation in spinal deformities: are they really safe? *Spine* 2001;26:2049–57.
12. Papin P, Arlet V, Marchesi D, et al. Unusual presentation of spinal cord compression related to misplaced pedicle screws in thoracic scoliosis. *Eur Spine J* 1999;8:156–60.



13. Choi JB, Han JO, Jeong JW. False aneurysm of the thoracic aorta associated with an aorto-chest wall fistula after spinal instrumentation. *J Trauma* 2001;50:140–3.
14. Minor ME, Morrissey NJ, Peress R, et al. Endovascular treatment of an iatrogenic thoracic aortic injury after spinal instrumentation: case report. *J Vasc Surg* 2004;39:893–6.
15. Heini P, Scholl E, Wyler D, et al. Fatal cardiac tamponade associated with posterior spinal instrumentation. A case report. *Spine* 1998;23:2226–30.
16. Yalcin S, Guven O. Reversible anterior cord syndrome due to penetration of the spinal canal by pedicular screws. *Paraplegia* 1995;33:423–5.
17. Gertzbein SD, Robbins SE. Accuracy of pedicular screw placement in vivo. *Spine* 1990;15:11–4.
18. Amiot L-P, Lang K, Putzier M, et al. Comparative results between conventional and computer-assisted pedicle screw installation in the thoracic, lumbar and sacral spine. *Spine* 2000;25:606–14.
19. Xu R, Ebraheim NA, Ou Y, et al. Anatomic considerations of pedicle screw placement in the thoracic spine. Roy-Camille technique versus open-lamina technique. *Spine* 1998;23:1065–8.
20. Upendra BN, Meena D, Chowdhury B, et al. Outcome-Based Classification for Assessment of Thoracic Pedicular Screw Placement. *Spine* 2008;33:384–390.
21. Rao G, Brodke DS, Rondina M, et al. Inter- and intraobserver reliability of computed tomography in assessment of thoracic pedicle screw placement. *Spine* 2003;28:2527–30.
22. Farber GL, Place HM, Mazur RA, et al. Accuracy of pedicle screw placement in lumbar fusions by plain radiographs and computed tomography. *Spine* 1995;20:1494–9.
23. Abul-Kasim K, Strömbeck A, Ohlin A, Maly P, Sundgren PC. Reliability of low radiation dose CT in the assessment of screw placement after posterior scoliosis surgery, evaluated with a new grading system. *Spine* 2008. In press.
24. Belmont PJ Jr, Klemme WR, Dhawan A, et al. In vivo accuracy of thoracic pedicle screws. *Spine* 2001;26:2340–6.
25. Mulholland RC. Pedicle screw fixation in the spine [Editorial]. *J Bone Joint Surg Am* 1994;76:517.
26. Kosmopoulos V, Schizas C. Pedicle screw placement accuracy: a metaanalysis. *Spine* 2007;32:E111–E120.
27. Abul-Kasim K, Overgaard A, Maly P, et al. Low dose helical computed tomography (CT) in the perioperative work up of adolescent idiopathic scoliosis. *Eur Radiol* 2009; 19: 610–618. E-pub 2008, sept 23.
28. Abul-Kasim, K, Gunnarsson M, Maly P, et al. Radiation dose optimization in CT planning of corrective scoliosis surgery. A phantom study. *The Neuroradiology Journal* 2008;21:374–382.
29. Lee SM, Suk SI, Chung ER. Direct Vertebral Rotation: A New Technique of Three-Dimensional Deformity Correction With Segmental Pedicle Screw Fixation in Adolescent Idiopathic Scoliosis. *Spine* 2004;29:343–49.
30. Heary RF, Bono CM, Black M. Thoracic pedicle screws: postoperative computerized tomography scanning assessment. *J Neurosurg* 2004;100:325–31.
31. Lekovic GP, Potts EA, Karahalios DG, et al. A comparison of two techniques in image-guided thoracic pedicle screw placement: a retrospective study of 37 patients and 277 pedicle screws. *J Neurosurgspine* 2007;7:393–8.

32. Smorgick Y, Millgram MA, Anekstein Y, et al. Accuracy and safety of thoracic pedicle screw placement in spinal deformities. *J Spinal Disord Tech* 2005;18:522–6.
33. Kim YJ, Lenke LG, Bridwell KH, et al. Free hand pedicle screw placement in the thoracic spine: is it safe? *Spine* 2004; 29:333–42
34. Schwarzenbach O, Berlemann U, Jost B, et al. Accuracy of computerassisted pedicle screw placement. An in vivo computed tomography analysis. *Spine* 1997;22:452–8.
35. Laine T, Mäkitalo K, Schlenzka D, et al. Accuracy of pedicle screw insertion: a prospective CT study in 30 low back patients. *Eur Spine J* 1997;6: 402–5.
36. Schizas C, Michel J, Kosmopoulos V, et al. Computer tomography assessment of pedicle screw insertion in percutaneous posterior transpedicular stabilization. *Eur Spine J* 2007; 16:613–7.
37. Wiesner L, Kothe R, Schulitz KP, et al. Clinical evaluation and computed tomography scan analysis of screw tracts after percutaneous insertion of pedicle screws in the lumbar spine. *Spine* 2000;25:615–21.
38. Sapkas GS, Papadakis SA, Stathakopoulos DP, et al. Evaluation of pedicle screw position in thoracic and lumbar spine fixation using plain radiographs and computed tomography. A prospective study of 35 patients. *Spine* 1999;24:1926–9.
39. Lehman RA Jr, Lenke LG, Keeler KA, et al. Computed tomography evaluation of pedicle screws placed in the pediatric deformed spine over an 8-year period. *Spine* 2007;32:2679–84.
40. Halm H, Liljeqvist U, Link T, et al. Computerized tomography monitoring of the position of pedicle screws in scoliosis surgery. *Z Orthop Ihre Grenzgeb* 1996;134:492–7.
41. Güven O, Yalçın S, Karahan M, et al. Postoperative evaluation of transpedicular screws with computed tomography. *Orthop Rev* 1994;23:511–6.
42. Odgers CJ, Vaccaro AR, Pollack ME, et al. Accuracy of pedicle screw placement with the assistance of lateral plain radiography. *J Spinal Disord* 1996;9:334–8.
43. Vaccaro AR, Rizzolo SJ, Balderston RA, et al. Placement of pedicle screws in the thoracic spine. Part II: An anatomical and radiographic assessment. *J Bone Joint Surg Am* 1995;77:1200–6.
44. Rauschnig W. Anterior surgery of the thoracolumbar junction and the lumbar spine. Anatomy, complications and safeguards. Presented at the meeting Anterior spine surgery: Standards and New Techniques. Berlin, Germany, October 25-27, 1995.
45. Melrose J, Ghosh P, Taylor TKF, et al. A longitudinal study of the matrix changes induced in the intervertebral disc by surgical damage to the annulus fibrosus. *J Orthop Res* 1992;10:665–76.
46. Meter JJ, Polly DW Jr, Miller DW, et al. A method for radiographic evaluation of pedicle screw violation of the vertebral endplate. Technique. *Spine* 1996;1;21:1587–92.
47. Åkerblom G, Falk R, Lindgren J, Mjönes L, Östergren I, Söderman A-L et al. Natural radioactivity in Sweden, exposure to internal radiation. Radiological Protection in Transition, Proceedings of the XIV Regular Meeting of the Nordic Society for Radiation Protection. NSFS. Rättvik, Sweden, 27-31 August 2005. pp 211–214. Given as SSI-report SSI 2005:15.

