



LUND UNIVERSITY

Multimodal imaging in CABP4-related retinopathy

Schatz, Patrik; Elsayed, Maram E A Abdalla; Khan, Arif O.

Published in:
Ophthalmic Genetics

DOI:
[10.1080/13816810.2017.1289543](https://doi.org/10.1080/13816810.2017.1289543)

2017

Document Version:
Peer reviewed version (aka post-print)

[Link to publication](#)

Citation for published version (APA):
Schatz, P., Elsayed, M. E. A. A., & Khan, A. O. (2017). Multimodal imaging in CABP4-related retinopathy. *Ophthalmic Genetics*, 38(5), 459-464. <https://doi.org/10.1080/13816810.2017.1289543>

Total number of authors:
3

General rights

Unless other specific re-use rights are stated the following general rights apply:
Copyright and moral rights for the publications made accessible in the public portal are retained by the authors and/or other copyright owners and it is a condition of accessing publications that users recognise and abide by the legal requirements associated with these rights.

- Users may download and print one copy of any publication from the public portal for the purpose of private study or research.
- You may not further distribute the material or use it for any profit-making activity or commercial gain
- You may freely distribute the URL identifying the publication in the public portal

Read more about Creative commons licenses: <https://creativecommons.org/licenses/>

Take down policy

If you believe that this document breaches copyright please contact us providing details, and we will remove access to the work immediately and investigate your claim.

LUND UNIVERSITY

PO Box 117
221 00 Lund
+46 46-222 00 00

Multimodal imaging in *CABP4*-related retinopathy.

Running Head: Retinal structure in CABP4-related retinopathy.

Authors: Patrik Schatz MD PhD,^{1,2} Maram E A Abdalla Elsayed MD,³ Arif O. Khan MD⁴

Affiliations:

¹ Vitreoretinal Division, King Khaled Eye Specialist Hospital, Riyadh, Kingdom of Saudi Arabia.

² Department of Ophthalmology, Clinical Sciences, Scane County University Hospital, University of Lund, Sweden.

³ Jeddah Eye Hospital, Jeddah, Kingdom of Saudi Arabia.

⁴ Eye Institute, Cleveland Clinic Abu Dhabi, Abu Dhabi, United Arab Emirates

Corresponding author: Patrik Schatz, MD PhD, Vitreoretinal Division

King Khaled Eye Specialist Hospital, Al- Oruba Street, PO Box 7191 Riyadh 11462, Kingdom of Saudi Arabia. Telephone number: Tel +966 11 482 1234 ext. 3773 | Fax +966 11 4821234 ext.

3773. Email: patrik.schatz@med.lu.se

Word count: 1470

Number of tables: 1, figures: 4

Conflict of interest disclosures: None for each of the authors. Funding/support: Grants from the Cronqvist Foundation of the Swedish Society of Medicine, the Eye Foundation, the Foundation for the visually impaired in the Skane County and the Crownprincess Margareta's Board for the visually impaired.

ABSTRACT

Purpose: Multimodal imaging has not been document for *CABP4*-related retinopathy. In this study we describe optical coherence tomography (OCT) and fundus autofluorescence findings for 5 genetically-confirmed cases.

Methods: Retrospective case series.

Results: Four patients with the previously-described homozygous Saudi *CABP4* founder mutation c.81_82insA (p.Pro28ThrfsX44) and 1 patient with the homozygous mutation c.1A>G (p.Met1?) in *CABP4* were examined. The ages ranged between 9-16 years at last follow up, and the duration of follow up ranged from 2-12 years. Foveal thickness was reduced ranging between 175-212 micrometers. Wide field imaging including fundus autofluorescence was unremarkable. All patients presented with a negative electroretinogram, with a variable amount of cone and rod dysfunction. Over follow-up, there was no electroretinographic indication of any progressive retinal dysfunction.

Conclusions: Foveal thinning is a feature of *CABP4* retinopathy. Normal autofluorescence is consistent with inner retinal dysfunction and suggests the condition could be amenable to gene therapy. Retinal dysfunction was stable throughout follow-up.

Keywords: *CABP4*, Congenital stationary night blindness, optical coherence tomography.

Introduction

CABP4-related retinopathy, also termed congenital non-progressive cone-rod synaptic disorder (CRSD; MIM #610427), is caused by mutations in the gene encoding calcium-binding protein-4 (CABP4; MIM #608965) on chromosome 11q13. It is characterized by stable low vision, nystagmus, photophobia, a normal or near-normal fundus appearance, and no night blindness. Electroretinography shows an electronegative waveform response to scotopic bright flash, near-normal to subnormal rod function, and delayed and/or decreased to nonrecordable cone responses.[1-3] The underlying cause is a dysfunction of the photoreceptor-bipolar synapse, where CABP4 is specifically located on the side of the photoreceptor synaptic terminal. Together with CACNA1F and CACNA2D4, CABP4 plays an important role in the photoreceptor-bipolar cell synapse by allowing the continuous release of glutamate into the synapse. Mutations in the genes encoding these proteins may cause disturbed glutamate release resulting in synaptic dysfunction which manifests clinically as an electronegative electroretinogram, where the a-wave which emanates from the phototransduction is greater than the b-wave which results from activity in the bipolar and Muller cells. Phenotypically such mutations have been described to cause cone dystrophy, cone-rod dystrophy or incomplete congenital stationary night blindness.[1, 4-6]

Albeit rare with only about 10 cases described in the literature (summarized by Khan et al.[1]), *CABP4*-related retinopathy is unique in that it does not cause night blindness, in spite of the protein's function being closely related to other proteins implicated in incomplete congenital stationary night blindness, and that there is a negative electroretinogram, which is hallmark of the latter condition.

In this paper we for the first time present the results of multimodal imaging for *CABP4*-related retinopathy as well as longer-term follow-up of retinal function.

Methods

This study was approved by the institutional research ethics committee and adhered to the tenets of the Declaration of Helsinki. We reviewed the records of patients homozygous for *CABP4* mutations known to one of the authors (AOK). All had the Saudi founder mutation (c.81-82insA; p.Pro28ThrfsX44) except one [Patient 2 in Table 1, who was homozygous for the mutation c.1A>G (p.Met1?)], and all had been previously noted in the literature.[1,2]

Retinal structure was analyzed qualitatively and quantitatively with transfoveal horizontal spectral domain optical coherence tomography scans (Spectralis OCT, Heidelberg Engineering, Inc., Heidelberg, Germany). Measurement of foveal retinal thickness, which was defined as the shortest distance from the top of the retinal pigment epithelium line to the internal limiting membrane in the right eyes of patients, was obtained with calipers using the Heidelberg software. In addition, in 2 of the patients (Patients 2 and 5), the Spectralis macular raster consisting of 19 horizontal 6 millimeter line scans, was performed, in spite of nystagmus. This enabled automated software algorithm to display with numeric averages of the macular thickness measurements for each of the 9 map sectors as defined by the Early Treatment Diabetic Retinopathy Study (ETDRS). [7] Retinal thickness in patients was compared to that of controls from a previously published paper by us, [8] using identical protocols (caliper measurement and ETDRS map) in patients and controls. Wide field imaging including fundus autofluorescence was performed in all patients (Optos PLC, Dunfermline, UK). Four of the patients (all except Patient 2) had macular autofluorescence imaging with a fundus camera (Topcon TRC-50DX, Topcon Medical Systems, Inc., NJ, US).

Retinal function was evaluated with full-field electroretinography (ffERG, Nicolet Biomedical Instruments, Madison, Wisconsin, USA), in dark adapted and light adapted state according to ISCEV standards,[9] with a few modifications as follows. Retinal function was evaluated with full-field electroretinography (ffERG, Nicolet Biomedical Instruments, Madison,

Wisconsin, USA), in dark adapted and light adapted state according to ISCEV standards, with a few modifications as follows.[8] Full-field electroretinograms were recorded in a Nicolet analysis system (Nicolet Biomedical Instruments, Madison, Wisconsin, USA), after dark adaptation of subjects for 40 min, dilatation of the pupils with topical cyclopentolate 1% and metaoxedrine 2,5% and topical anaesthesia, with a Burian Allen bipolar contact lens and a ground electrode applied to the forehead. Responses were obtained stimulating with single full-field flash (30 ms) with blue light (0.81 cd-s/m²: rod response) and with white light (10.02 cd-s/m²: combined rod-cone response). In addition, the dark adapted cone response was measured after stimulation with dim red light (3.93 cd-s/m²). Photopic responses were obtained with a background illumination of 3.4 cd-s/m² in order to saturate the rods.

Results

OCT foveal thickness using caliper measurement at most recent follow-up showed foveal thinning (Table 1, Fig. 1). Foveal thickness ranged between 175-212 micrometers (range of normal: 215-245).[8] In addition, patients 2 and 5 displayed reduced averages of macular thickness measurements for each of the 9 ETDRS map sectors, including the central 1 millimeter sector, compared to controls (data not shown), except for a single value for the outer superior sector in Patient 2 [285 microns for patient 2, compared to median (300) and range (281-332) for controls for that sector]. Due to nystagmus in all patients, the quality of the scans did not allow thickness analysis of the various retinal sublayers. There seemed to be a thinning of the outer plexiform layer in for example Patient 3 with the homozygous Saudi founder mutation c.81_82insA (p.Pro28ThrfsX44), whereas it seemed to be more prominent in Patient 2 with the homozygous mutation c.1A>G (p.Met1?), in *CABP4* (Fig. 1). However this may have been due to variable reflectivity and thus visualization of Henle's fiber layer due to its birefringent optical properties and

oblique orientation, in the context of horizontal displacement of the OCT entry beam through the pupil, due to nystagmus. [10] Thus visualization of the Henle's fiber layer, which consists of the axons of the photoreceptors, could account for the apparent prominence of the outer plexiform layer. Fundus wide field and macular imaging demonstrated unremarkable fundi including normal distribution of autofluorescence (Fig. 1).

Retinal function was measured in all patients using full field electroretinography, and in 3 out of 5 patients, long-term follow-up of retinal function was possible, ranging over 5-12 years (Table 1). Dark adapted rod responses were present in 3 patients and were normal in 1 of these (Table 1). Dark adapted cone responses ("b1") were present in 2 of 5 patients, albeit reduced compared to normal (Table 1, Figs. 2-4). Light adapted cone responses and 30 Hz flicker responses were severely reduced in all patients, however the 30 Hz flicker implicit time was not delayed as seen in progressive retinal dystrophies (Table 1, Figs. 2-4). Furthermore, the cone and rod-cone a-waves, emanating from phototransduction activity proximal to the photoreceptor-bipolar synapse, were normal or near-normal. Retinal function was stable over time in all patients (Table 1, Figs. 2-4).

Discussion

In an animal mouse model of *CABP4*-related retinopathy, the outer plexiform layer was thinner in *Cabp4* ^{-/-} mice, with a reduction in the number of synaptic ribbons and photoreceptor terminals and there were ectopic synapses originating from rod bipolar and horizontal cells extending into the outer nuclear layer.[11] Here, we found thinning of foveal retinal thickness by optical coherence tomography, and in addition, our results strongly suggest macular retinal thinning also outside the fovea in all 9 ETDRS sectors. It is to be noted that the control group used for this study consisted of healthy myopic subjects (range 6–9, median 7.5 diopters of myopia) designed to

match myopic patients from a previous study, [8] and would thus be expected to have thinner-than normal retinas of emmetropic subjects. This further supports a generalized macular retinal thinning in *CABP4*-related retinopathy. However due to nystagmus the quality of the scans did not permit any quantitative analysis of retinal sublayer thickness.

Retinal function as measured with full field ERG was stable over time and there was no sign of progressive retinopathy. Consistently, all patients had severe reduction of light and dark adapted cone b waves, whereas the cone and rod-cone a-waves, emanating from phototransduction activity proximal to the photoreceptor-bipolar synapse, were normal or near-normal. Rod function was variably reduced and normal in 1 of the patients. One can speculate if *CABP4* may have a more prominent role in cone synapses than rod synapses in humans. Consistently, dark adapted *Cabp4*^{-/-} mice showed consistently lower ERG a- and b-waves compared to controls, whereas light adapted *Cabp4*^{-/-} mice showed smaller differences in the a-wave amplitudes than in the b-wave amplitudes, compared to controls.

Fundus imaging was unremarkable in all patients and there was a normal distribution of fundus autofluorescence. This is consistent with the condition being primarily a problem of inner retinal dysfunction and suggests it could be amenable to gene therapy.

In summary, retinal dysfunction was stable over long term follow-up in *CABP4*-related retinopathy. Foveal retinal thickness was reduced compared to normal, which may be due to primarily reduced thickness of the outer plexiform layer, as seen in *Cabp4*^{-/-} mice, and could result from a lack of the protein's function in the photoreceptor-bipolar synapse in this layer. Autofluorescence was unremarkable. These findings further our understanding of the condition.

ACKNOWLEDGEMENTS

a. Funding/support: Grants from the Cronqvist Foundation of the Swedish Society of Medicine, the Eye Foundation, the Foundation for the visually impaired in the Skane County and the Crownprincess Margareta's Board for the visually impaired.

b. Conflict of interest disclosures: None for each of the authors.

c. Contributions to Authors:

Design of the study (PS, AE, AK).

Conduct of the study (PS, AE, AK).

Collection, management, analysis, and interpretation of the data (PS, AE, AK).

Preparation, review and final approval of the manuscript (PS, AE, AK)

References

1. Khan, A. O., Alrashed, M., Alkuraya, F. S. Clinical characterisation of the CABP4-related retinal phenotype. *Brit. J. Ophthalmol.* 2013;97:262-265.
2. Khan, A. O. CABP4 mutations do not cause congenital stationary night blindness. (Letter) *Ophthalmology*. 2014;121:e15.3. Zeitz C, Robson AG, Audo I. Congenital stationary night blindness: an analysis and update of genotype-phenotype correlations and pathogenic mechanisms. *Prog Retin Eye Res.* 2015;45:58-110.
4. Zeitz C, Kloeckener-Gruissem B, Forster U, et al. Mutations in CABP4, the gene encoding the Ca²⁺-binding protein 4, cause autosomal recessive night blindness. *Am J Hum Genet.* 2006;79:657-667.
5. Aldahmesh MA1, Al-Owain M, Alqahtani F, Hazzaa S, Alkuraya FS. A null mutation in CABP4 causes Leber's congenital amaurosis-like phenotype. *Mol Vis.* 2010;16:207-212.
6. Littink KW, van Genderen MM, Collin RW, et al. A novel homozygous nonsense mutation in CABP4 causes congenital cone-rod synaptic disorder. *Invest Ophthalmol Vis Sci.* 2009;50:2344-2350.
7. Early Treatment Diabetic Retinopathy Study Research Group. ETDRS Report Number 7: Early Treatment Diabetic Retinopathy Study Design and Baseline Patient Characteristics. *Ophthalmology*. 1991;98:741–756.
8. Al Oreany AA, Al Hadlaq A, Schatz P. Congenital stationary night blindness with hypoplastic discs, negative electroretinogram and thinning of the inner nuclear layer. *Graefes Arch Clin Exp Ophthalmol.* 2016;254:1951-1956.
9. Marmor MF, Zrenner E. Standard for clinical electroretinography. *Doc Ophthalmol.* 1999; 97:143–156.

10. Lujan BJ1, Roorda A, Knighton RW, Carroll J. Revealing Henle's fiber layer using spectral domain optical coherence tomography. Invest Ophthalmol Vis Sci. 2011;18;52:1486-1492.11. Haeseleer F, Imanishi Y, Maeda T, et al. Essential role of Ca²⁺-binding protein 4, a Cav1.4 channel regulator, in photoreceptor synaptic function. Nat Neurosci. 2004;7:1079-1087.

Figure legends

Figure 1: Wide field imaging and optical coherence tomography findings in *CABP4*-related retinopathy.

Top panel: Right eye. Wide field imaging and fundus autofluorescence in Patient 3 with the homozygous Saudi founder mutation c.81_82insA (p.Pro28ThrfsX44) in *CABP4*. There is a normal distribution of autofluorescence.

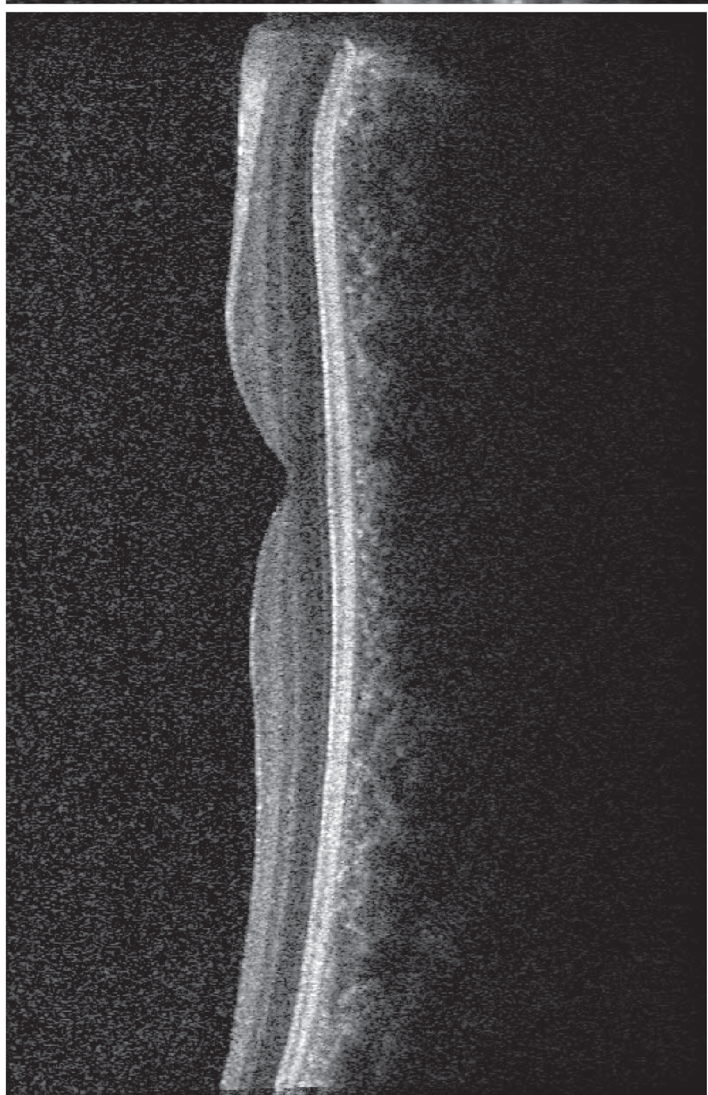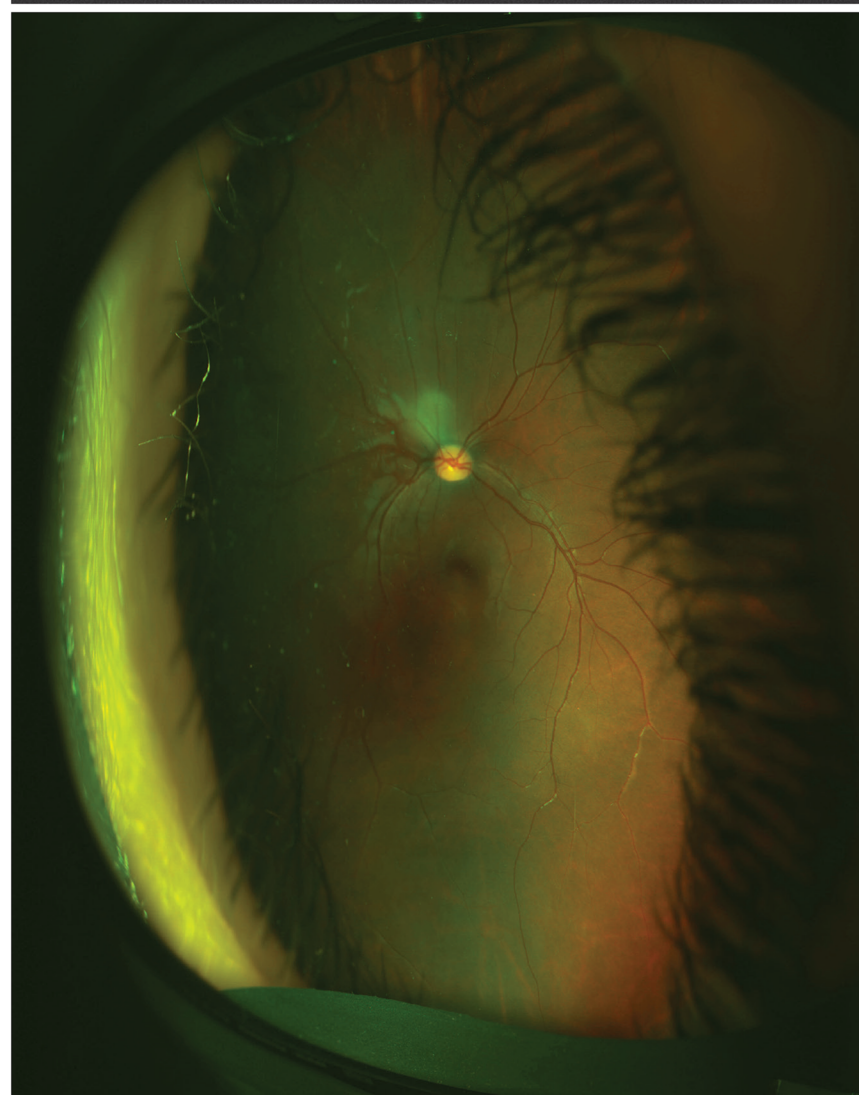
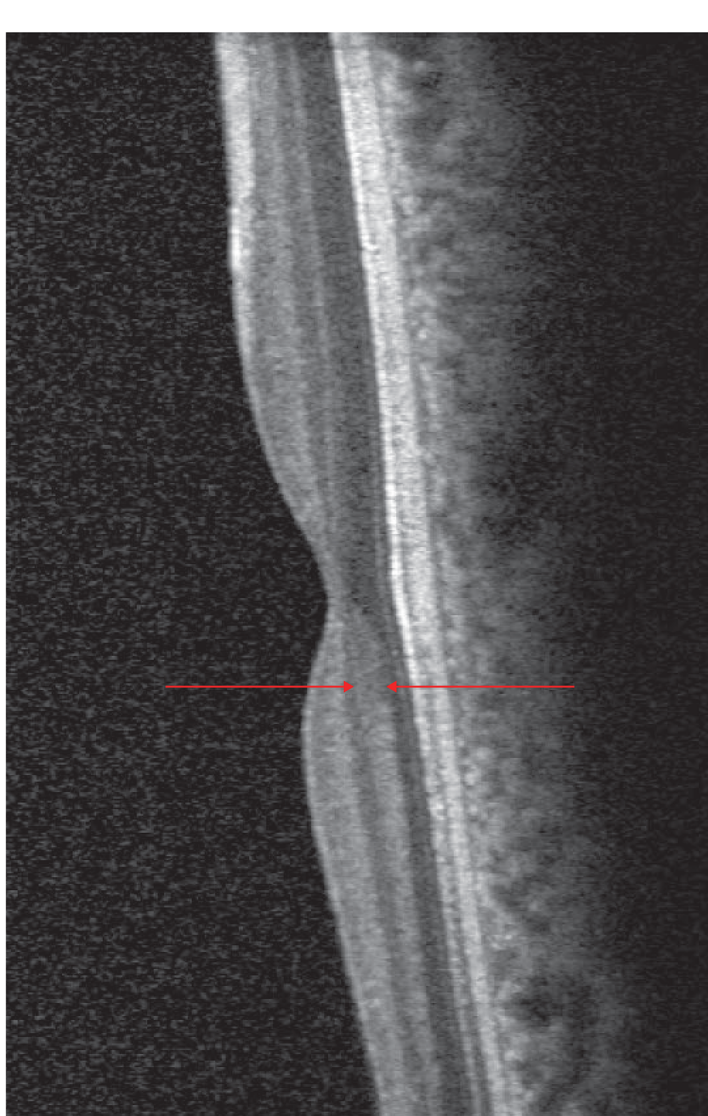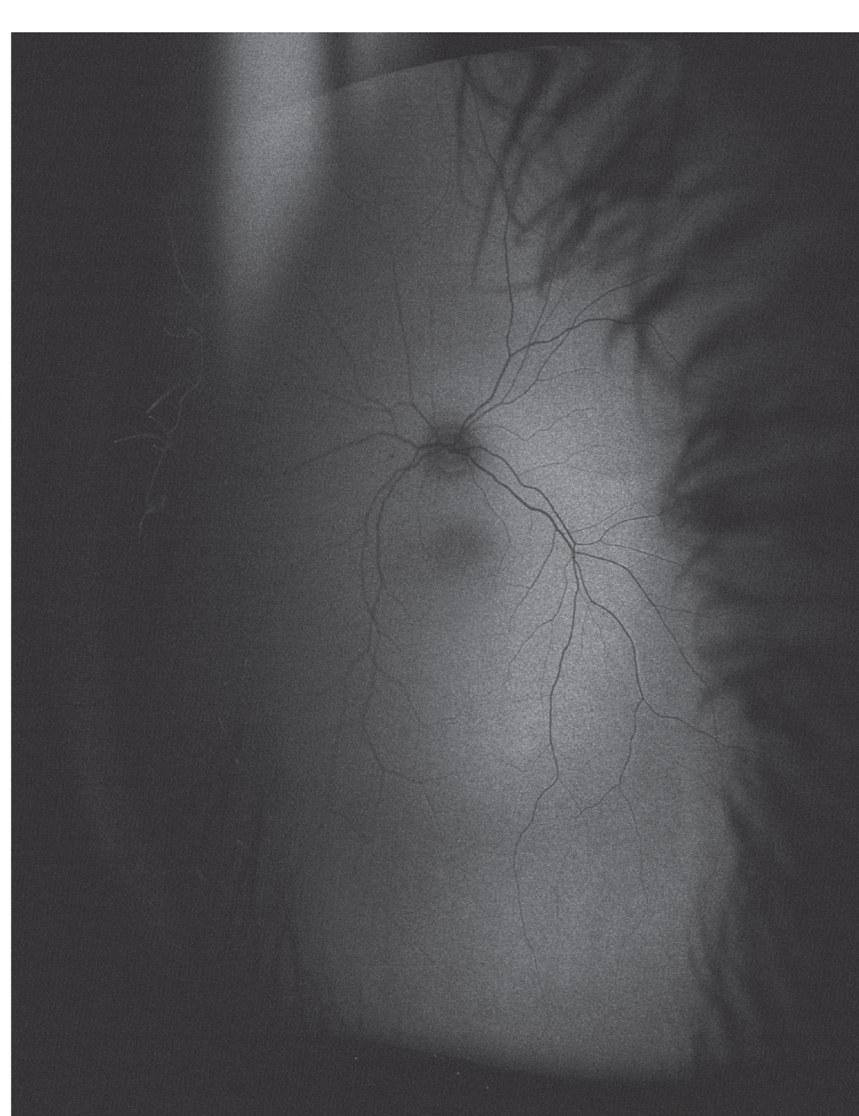Lower panel: Right eyes. Optical coherence tomography in Patient 3 (left column) with the homozygous Saudi founder mutation c.81_82insA (p.Pro28ThrfsX44) and in Patient 2 (right column) with the homozygous c.1A>G (p.Met1?) mutation in *CABP4*. The outer plexiform layer (between arrows) seems more prominent in Patient 2 than in Patient 3. However this may have been due to variable reflectivity and thus visualization of Henle's fiber layer due to its birefringent optical properties and oblique orientation, in the context of horizontal displacement of the OCT entry beam through the pupil, due to nystagmus, as described by Lujan et al. 2011. [10] Thus visualization of the Henle's fiber layer, which consists of the axons of the photoreceptors, could account for the apparent prominence of the outer plexiform layer.

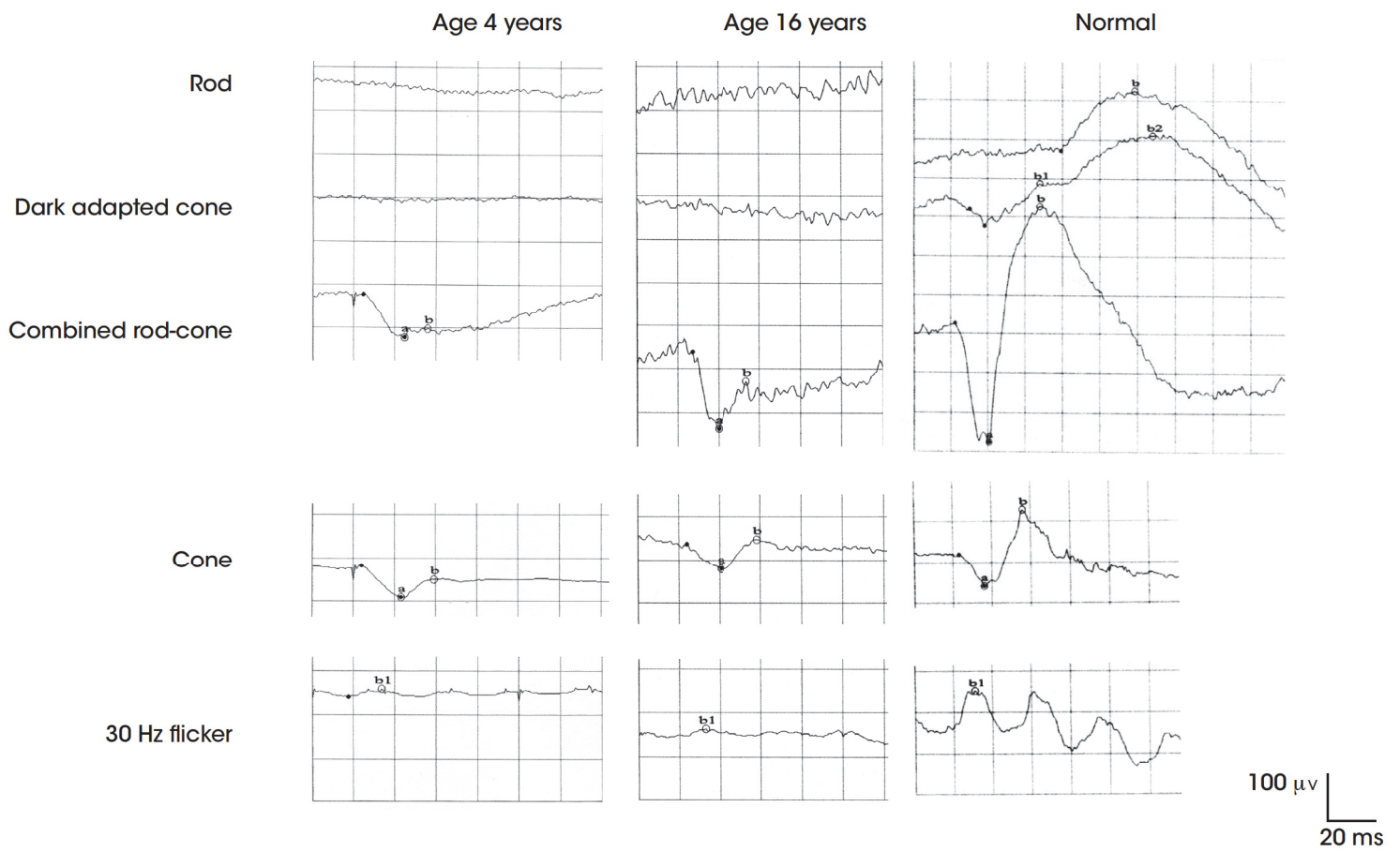
Figure 2: Right eye. Long term follow up of retinal dysfunction by full-field electroretinography in Patient 1 with the homozygous Saudi founder mutation c.81_82insA (p.Pro28ThrfsX44) in *CABP4*. No rod function can be measured. Note electronegative combined rod-cone response. Light

adapted cone responses are reduced. There is no sign of progressive retinal dysfunction over follow-up. A normal full-field electroretinogram is shown for comparison in the right column. ms=milliseconds. μ V=microvolts.

Figure 3: Right eye. Long term follow up of retinal dysfunction by full-field electroretinography in Patient 2 with the homozygous c.1A>G (p.Met1?) mutation in *CABP4*. There is a reduced but measurable rod response. Note electronegative combined rod-cone response. Light adapted cone responses are reduced. There is no sign of progressive retinal dysfunction over follow-up. ms=milliseconds. μ V=microvolts.

Figure 4: Right eye. Long term follow up of retinal dysfunction by full-field electroretinography in Patient 4 with the homozygous Saudi founder mutation c.81_82insA (p.Pro28ThrfsX44) in *CABP4*. There is a prominent rod response. Note electronegative combined rod-cone response. Light adapted cone responses are reduced. There is no sign of progressive retinal dysfunction over follow-up. ms=milliseconds. μ V=microvolts.

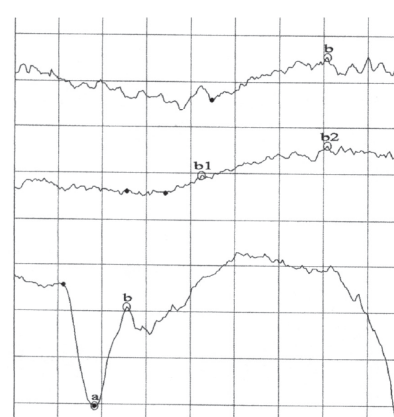
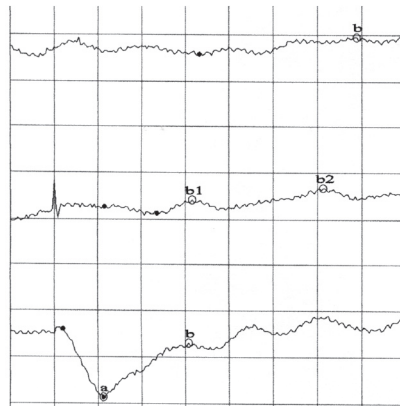





Age 3 years

Age 8 years


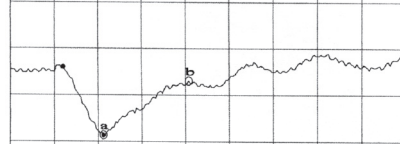
Rod





Dark adapted cone



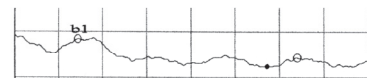
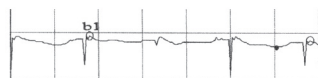
Combined rod-cone



Cone



30 Hz flicker



100 μ V
20 ms

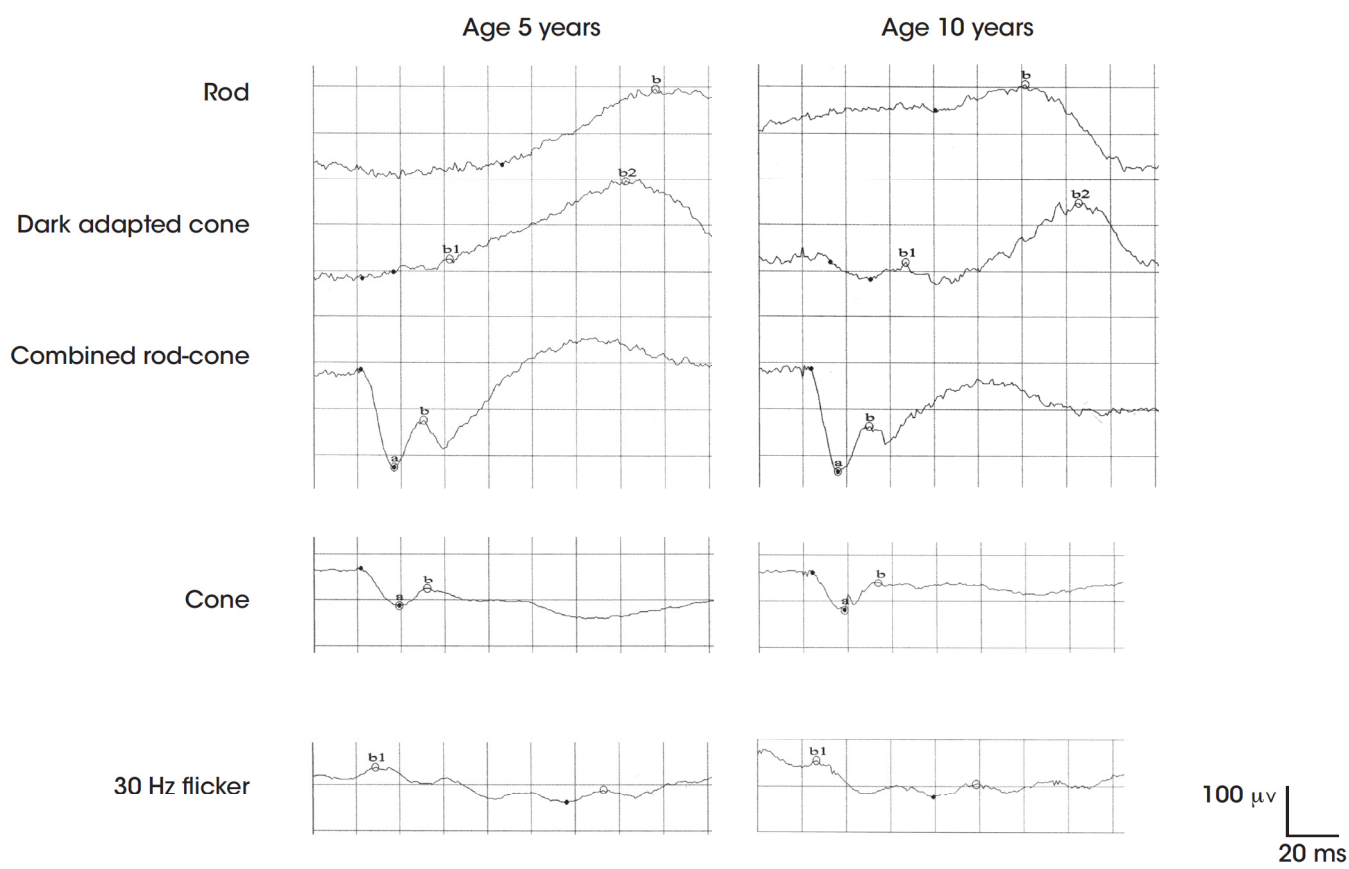


Table 1. Long term retinal function and foveal thickness in 5 patients with *CABP4*-related retinopathy. All patients were male.

Patient	Age	Gender	Binocular VA at first visit (age 1 st visit), binocular VA at follow-up	Refraction at follow-up (OD, OS)	OCT FT OD	Full-field electroretinography (ffERG) at presentation, ffERG at follow up (OD)													
						Rod		Rod-cone a wave		Rod-cone b wave		Cone a wave		Cone b wave		30 Hz flicker		Red b1	
						A	It	A	It	A	It	A	It	A	It	A	It	A	It
1	16	M	20/200 (4), 20/200	OU -1= 3x5	187	0	0	200, 158	17, 20	88, 97	32, 34	103, 59	21, 21	107, 71	38, 38	20, 13	34, 33	0	0
2	9	M	F&F (2), 20/80	-1.50=1.50x130, +1.00=1.00=85	212	34, 87	138, 122	135, 238	22, 17	105, 195	62, 31	70, 75	22, 18	70, 81	44, 37	17, 18	36, 29	27, 36	63, 65
3	11	M	20/100 (9), 20/200	+6= -2.5x16, +7= -4x167	175	106	117	322	18	201	31	79	19	46	33	33	27	0	0
4	10	M	20/300 (6), 20/300	2.75=1.75x105, 3=2x85	197	148, 51	136, 102	192, 202	17, 16	93, 89	30, 30	85, 74	19,1 9	40, 47	33, 32	30, 20	29, 30	25, 33	42, 47
5	9	M	20/80 (7), 20/70	OU-6=-2.5x0	204	0	0	159‡	19	72	31	54	19	28	26	42	26	0	0
Normal values (range)					215-245*	103-380	69-115	164-378	11-17	284-705	42-60	54-117	11-15	96-239	33-37	96-259	25-32	51-197	42-53

VA=Visual acuity, OCT FT=optical coherence tomography foveal thickness, OD=right eye, OS=left eye, OU=both eyes, A=Amplitude,
It=implicit time. F&F=Fixates and follows.

* Reference material for optical coherence tomography from Oreany et al.[8]

