



# LUND UNIVERSITY

## Frontotemporal dementia with a C9ORF72 expansion in a Swedish family: clinical and neuropathological characteristics.

Landqvist, Maria; Gustafson, Lars; Nilsson, Karin; Traynor, Bryan J; Renton, Alan E; Englund, Elisabet; Passant, Ulla

*Published in:*  
American Journal of Neurodegenerative Disease

2013

[Link to publication](#)

### *Citation for published version (APA):*

Landqvist, M., Gustafson, L., Nilsson, K., Traynor, B. J., Renton, A. E., Englund, E., & Passant, U. (2013). Frontotemporal dementia with a C9ORF72 expansion in a Swedish family: clinical and neuropathological characteristics. *American Journal of Neurodegenerative Disease*, 2(4), 276-286.  
<http://www.ncbi.nlm.nih.gov/pubmed/24319645?dopt=Abstract>

*Total number of authors:*  
7

### **General rights**

Unless other specific re-use rights are stated the following general rights apply:  
Copyright and moral rights for the publications made accessible in the public portal are retained by the authors and/or other copyright owners and it is a condition of accessing publications that users recognise and abide by the legal requirements associated with these rights.

- Users may download and print one copy of any publication from the public portal for the purpose of private study or research.
- You may not further distribute the material or use it for any profit-making activity or commercial gain
- You may freely distribute the URL identifying the publication in the public portal

Read more about Creative commons licenses: <https://creativecommons.org/licenses/>

### **Take down policy**

If you believe that this document breaches copyright please contact us providing details, and we will remove access to the work immediately and investigate your claim.

LUND UNIVERSITY

PO Box 117  
221 00 Lund  
+46 46-222 00 00

## Original Article

# Frontotemporal dementia with a *C9ORF72* expansion in a Swedish family: clinical and neuropathological characteristics

Maria Landqvist Waldö<sup>1</sup>, Lars Gustafson<sup>1</sup>, Karin Nilsson<sup>1</sup>, Bryan J Traynor<sup>3</sup>, Alan E Renton<sup>3</sup>, Elisabet Englund<sup>2</sup>, Ulla Passant<sup>1</sup>

<sup>1</sup>Section of Geriatric Psychiatry, Department of Clinical Sciences, Lund University, Klinikgatan 22, Lund SE-221 85, Sweden; <sup>2</sup>Section of Pathology, Department of Clinical Sciences, Lund University, Lund, SE-221 85, Sweden; <sup>3</sup>Laboratory of Neurogenetics, NIA, NIH, 35 Convent Drive, Room 1A-1000, Bethesda, MD 20892

Received September 27, 2013; Accepted November 5, 2013; Epub November 29, 2013; Published December 15, 2013

**Abstract:** Background: In 2011 the *C9ORF72* repeat expansion was identified as the most frequent genetic mutation underlying FTD and ALS. The main aim of this study was to investigate clinical characteristics in a large *C9ORF72*-positive FTD family, and to compare these with the neuropathological findings. Methods: The clinical records of 12 related FTD patients were thoroughly evaluated. The five neuropathologically examined cases were revised using additional TDP-43 immuno-stainings. Four cases were screened for the *C9ORF72* expansion. Results: All 12 patients fulfilled the criteria for bvFTD. Restlessness and social neglect were often among the first reported symptoms. Psychotic symptoms were reported in 8 patients. Somatic complaints were seen in 7 cases. All the neuropathologically examined cases were TDP-43 positive. Conclusions: The phenotype of this *C9ORF72* hexanucleotide expansion carrier family was bvFTD. The clinical symptom profile was strikingly homogenous. Psychotic symptoms and somatic complaints were observed in most of the cases.

**Keywords:** Genetics, FTD, longitudinal study, psychotic symptoms, TDP-43

## Background

The recently described hexanucleotide repeat expansion in the *C9ORF72* gene appears to be the most common genetic cause of familial frontotemporal dementia (FTD) and amyotrophic lateral sclerosis (ALS) [1-3], and has also been found in cases without known family history of dementia [4]. FTD is a heterogeneous group of neurodegenerative diseases affecting predominantly the frontal and temporal brain cortices [5]. Clinically, FTD is divided into three main subtypes: behavioural variant FTD (bvFTD), semantic dementia (SD) and progressive nonfluent aphasia (PNFA) [6]. The association between FTD and the progressive neurological disease ALS has been recognised for many years [7, 8].

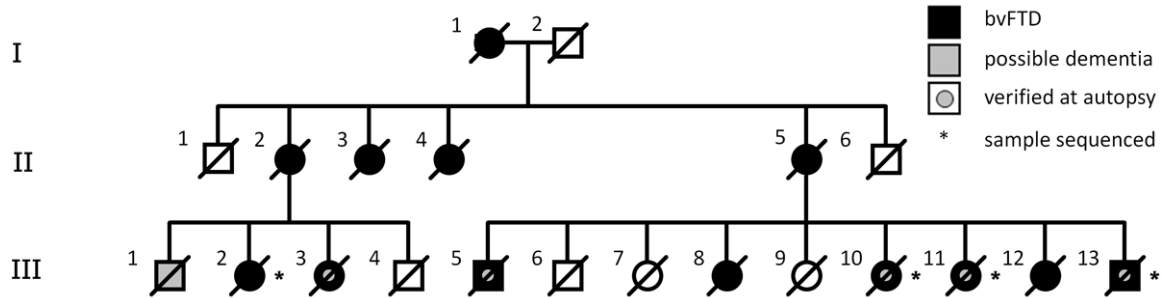
A positive family history has been reported in about 40% of FTD cases [9, 10], with an autosomal dominant inheritance pattern in at least

10% of patients [9]. In some families, a co-morbidity with ALS is seen. Genes previously described to carry FTD pathogenic mutations include progranulin (*GRN*) and microtubule-associated protein tau (*MAPT*) on chromosome 17, as well as *CHMP2B* on chromosome 3 [11]. Whereas a mutation in the gene encoding TDP-43 (*TARDBP*) on chromosome 1 most often causes ALS, in rare cases the phenotype is FTD [12, 13]. With the discovery of the *C9ORF72* expansion a strong genetic link between FTD and ALS was found [4, 14].

Since the discovery of the *C9ORF72* mutation in 2011 [1, 2], several studies of prevalence [4, 15] as well as clinical and neuropathological features in expansion carriers have been published [16-18].

In a recent large study pathogenic *C9ORF72* repeat expansions were observed in about 25% of European familial FTD and about 40% of

## FTD with a C9ORF72 expansion in a Swedish family



**Figure 1.** Pedigree of a Swedish family with frontotemporal dementia and a *C9ORF72* expansion.

familial ALS [4]. In sporadic cases the frequency was highest in Finland, and a Scandinavian origin has been suggested. A Finnish founder risk haplotype has previously been described and was found in the majority of *C9ORF72*-positive cases, which could support the theory of a common founder [4, 19]. There appears to be large prevalence differences between countries [15]. The prevalence in normal controls based on a large cohort from Great Britain was 0.15% [20].

The mean age at dementia onset in *C9ORF72* carriers seems to be around 57 years, albeit with large variability. Penetrance at age 58 is 50%, increasing to almost full penetrance by age 80 [4].

Several publications indicate great heterogeneity in clinical symptomatology associated with *C9ORF72* expansion, even within the same family [21-23].

Psychiatric symptoms, particularly psychotic symptoms, have been found as prominent features in patients carrying the *C9ORF72* expansion in several studies [17, 21, 23-25]. A possible neuroanatomical basis of neuropsychiatric symptoms in *C9ORF72* mutation carriers has been discussed. Involvement of the thalamus and cerebellum has been suggested to be associated with certain symptoms including hallucinations and delusions [21, 23].

Clinical phenotypes of *C9ORF72* expansion carriers mainly consist of bvFTD, ALS or FTD with motor neuron disease (FTD-MND). Also, cases that have presented with primary progressive aphasia (PPA) [18, 22], corticobasal and ataxia syndromes [26], Parkinsonism [27], or Alzheimer's disease [28] have been described.

Neuropathologically, *C9ORF72*-positive FTD cases exhibit TDP-43 positive inclusions consistent with Mackenzie pathology type A or B [23, 29, 30]. Also, p62-positive inclusions in the cerebellar granule cell layer seem to be specific for this mutation, and are present in most but not all cases [21-23].

A cut-off of 30 or more is commonly used to differentiate between pathogenic or non-pathogenic repeat numbers. There are indications, though, that also expansions between 20 and 30 may be pathogenic [31].

The main aim of the present study was to investigate clinical characteristics including demographic, psychiatric and neurological findings in a genetically characterised family with bvFTD and to compare these results with the neuropathological results.

### Materials and methods

We collected clinical and neuropathological data from a large family with a high prevalence of FTD from the southern part of Sweden (**Figure 1**). The family has been followed at the Department of Psychogeriatrics for over 40 years [32], and we had access to clinical records from 14 family members in three generations (12 with FTD and two at risk-individuals). Also, complementary information was available in public records such as parish records. 5 cases were neuropathologically verified and there was blood available from 4 family members (3 of the autopsy verified cases and 1 case where we only had clinical data). One case has previously been identified as a *C9ORF72* expansion carrier [33]. Members of this family have been followed longitudinally for research purposes, making it possible to thoroughly examine them during the course of disease by

repeated clinical evaluations. Neuropsychological assessments and neuroimaging have supported the diagnosis of FTD. Ethical approval for the longitudinal study in which the patients were included was given by the regional ethical review board in Lund.

### *Clinical evaluations*

We retrospectively analysed the clinical records of the 14 family members. All information was carefully read and evaluated by two experienced MDs (MLW, UP), by each observer individually and then once more by both observers together at a consensus meeting.

Demographic data and clinical features including neurological and neuropsychiatric symptoms were noted for each case. Several individuals were diagnosed before publication of the 1998 consensus document and thus all diagnoses were revised and diagnosed as bvFTD according to the Neary et al criteria [6].

The aim was to focus on symptoms not covered by the consensus criteria. Psychiatric features such as psychotic symptoms (hallucinations, delusions, paranoid ideations) and affective symptoms (mood, emotional lability, suicidal ideations, aggression, apathy, restlessness) at any time during the course of the disease were noted. Reported presenting symptoms, which we defined as the first symptoms observed by the family, were noted. Somatic complaints were recorded separately.

Neurological symptoms, including signs of Parkinsonism and motor neuron disease (MND) were evaluated. Symptoms considered as associated with Parkinsonism were rigidity, gait disturbances and tremor. Muscle weakness, loss of ability to walk, exaggerated reflexes, positive primitive reflexes, dysarthria and dysphagia were considered to be possible MND symptoms.

Language symptoms such as decreased speech output, word-finding difficulties, echolalia or perseverations were noted. Special focus was given to symptoms consistent with the earlier described PEMA syndrome (palilalia, echolalia, mutism and amimia) [34]. The patients were considered to suffer from the PEMA syndrome if notes were made about at least 3 out of 4 of the PEMA symptoms in clinical records.

The age at onset was defined as the first time relatives noted symptoms attributable to the disease. Due to large variations in disease duration the terms “early” versus “late” were used to describe when during the disease progression of each individual symptom were noted. In order to define “early” and “late”: if the duration was 16 years, the first 8 years were “early”, and if disease duration was 4 years, then the first 2 years were considered to be “early”.

### *Pathology*

Five cases were neuropathologically examined according to standardised clinical methods at the Pathology Department. The procedure included whole brain assessment with entire bi-hemispheric coronal sections covering all major regions for conventional staining, as described in a previous publication [35].

For comparisons of regionally accentuated pathology, the neocortical areas (frontal, temporal, parietal and occipital cortex) were analysed for severity of degeneration and graded as mild, moderate or severe according to the same definitions as previously published [36].

Particular attention was paid to potential hemispheric asymmetry, but also to pathology in the cerebellum, the thalamus, the hippocampus and regions related to motor function, such as cervical cord motor neurons and upper neurons within the motor cortex. Furthermore, the frontal white matter was assessed with a similar grading. Immunohistochemical staining of phosphorylated TDP-43 and FUS, p62 and phosphorylated tau were analysed. The cases were re-evaluated and revised for confirmation and comparison between the cases. For TDP-43-positive pathology, the pattern of positive inclusions was subtyped according to the Mackenzie system (type A-D) [29], and further semiquantitatively graded 1-4 for increasing severity.

### *Genetics*

Frozen blood samples from 4 individuals within the family (cases III:2, III:10, III:11, III:13) were thawed and DNA was extracted. Also, in two cases (III:3, III:5), DNA was extracted from paraffin-embedded brain material. We screened all samples for the C9ORF72 hexanucleotide

repeat expansion using the repeat-primed polymerase chain reaction (rpPCR) method previously described [2]. The result was defined as a mutation if this assay consistently showed the characteristic expansion pattern and more than 30 repeats in total.

### Results

#### *Clinical findings*

Demographic data is summarised in **Table 1**. The age at onset (43-70 years) and disease duration (2-21 years) was highly variable within this family. Median age at onset was 60 years and median duration was 10 years.

All cases fulfilled the Neary et al criteria at an early stage, but there were also other symptoms that were prominent in several family members, presented in **Table 1**.

Psychotic symptoms were seen in 8 of the patients, manifesting as hallucinations, delusions or paranoia. Affective symptoms were frequent, including depression, mood swings, elated mood, emotional lability, suicidal ideations, aggression and restlessness. Apathy, with or without depressed mood, was present in all cases at some time during disease duration, but not as a prominent symptom at an early stage. 4 patients expressed suicidal ideations or suicidal threats but no one committed suicide or made any suicide attempts.

Extreme restlessness in combination with social neglect, defined as loss of social awareness and insight in combination with neglect of self-care, activity of daily living and mismanagement of domestic activities were reported as presenting symptoms in all but one case.

Marked and often persistent pain (head, abdomen, legs) was reported in 7 out of 12 cases and was often present early during the disease or even before disease onset. The patients were subject to repeated medical evaluations due to these symptoms, but in the majority of cases no specific medical explanation for the complaints could be found.

Speech output gradually decreased in all cases, eventually resulting in mutism. In two cases logorrhoea was initially reported. No case had an onset with isolated language impairment. Palilalia, echolalia, mutism and

amimia (PEMA) were present in the majority of cases (**Table 1**).

Hyperphagia was reported in all, and dysphagia in all but one case at some time during the disease. All patients suffered from severe weight loss at the final stage of disease. Dysarthria was noted early in two cases. Motor features were present, to some extent, in all cases. Only one of the cases received the diagnosis MND while alive. When analysed in retrospect, however, symptoms attributable to MND pathology were seen in several individuals (**Table 1**).

Parkinsonism with rigidity, bradykinesia and gait disturbances, but not tremor, was noted in at least 4 cases, but in only one case this was seen at an early stage of disease. In that particular case symptoms started after the administration of antipsychotic medication and persisted after cessation of the medication. Antipsychotic drugs were administered to 7 patients, all of them reacting with pronounced side effects, in most cases Parkinsonism. Ataxia was not reported in any of the 12 cases.

#### *Short case reports*

I:1 According to relatives this woman developed dementia many years prior to death. She suffered from a stroke during her last year of life, and died at the age of 88.

I:2 The husband of I:1 died at age 49, according to parish registration cause of death was "cardiac paralysis".

II:2 The personality and behaviour of this woman changed markedly at the age of 57. She became restless, disinhibited and acted socially inappropriately, by paying visits to unknown people, laughing, telling jokes and confabulating. She also ignored self-care and domestic activities. Memory, recognition and spatial skills were preserved, however she developed speech disturbances with severe logorrhoea followed by reduced speech output. She made suicidal threats. Already after two years she could no longer be taken care of at home. When given antipsychotic drugs she developed extreme Parkinsonism and the negative side effects lasted for months, even after medication was withdrawn.

II:3 According to relatives this woman had a 10 year history of progressive dementia before

## FTD with a C9ORF72 expansion in a Swedish family

**Table 1.** Clinical features of a Swedish family with frontotemporal dementia and a C9ORF72 expansion

Case	Onset (y)	Dur (y)	Psychotic symptoms	Affective symptoms	Somatic complaints	PEMA	Dysarthria	Dysphagia	Motor features	Antipsychotic drugs	Reported presenting symptoms
II:2	57	12	Paranoid ideations, delusions	Elated/depressed mood, suicidal threats	No	Yes	No	Early	Early Parkinsonism, muscle atrophy, incontinence	Yes, pronounced rigidity, even after medication stopped	Social neglect <sup>a</sup> , restlessness
II:3	64	10	Tactile halluc.	Aggression	No	Yes	No	Late	Late Parkinsonism, falls, incontinence	Yes, rigidity	Social neglect, restlessness, memory problems
II:4	65	21	NA	Aggression	NA	No speech	NA	NA	Left hemiplegia, bilateral lower limb weakness	No	Restlessness, aggression
II:5	55	6	Aud. halluc., delusions	Emotional lability, elated/depressed mood, suicidal threats, aggression	Pain (legs)	Yes	No	Late	Muscle atrophy	No	Social neglect, restlessness, emotional lability/suicidal threats, psychotic symptoms
III:2	68	3	Visual halluc., delusions, paranoid ideations	Emotional lability, aggression	Pain (head, abdominal, legs)	Yes	Early	Early	MND, falls	No	Restlessness, paranoid ideations, aggression, motoric symptoms
III:3	50	5	<b>Delusions, visual/aud halluc.</b>	<b>Emotional lability, depressed mood</b>	<b>Pain (head, chest)</b>	<b>Yes</b>	<b>Early</b>	<b>Early</b>	<b>Exaggerated reflexes</b>	<b>Yes, lost ability to speak</b>	<b>Social neglect, restlessness, apathy, psychotic symptoms</b>
III:5	46	17	<b>Paranoid ideations</b>	<b>Elated/depressed mood, aggression, suicidal ideations</b>	<b>Pain (abdominal)</b>	<b>Yes</b>	<b>No</b>	<b>Late</b>	<b>Late Parkinsonism, incontinence</b>	<b>Yes, pronounced rigidity, salivation</b>	<b>Restlessness, inappropriate behaviour</b>
III:8	69	10	No	Emotional lability	No	Yes	No	Early	Bradykinesia, incontinence	No	Social neglect, restlessness, emotional lability
III:10	68	5	No	Aggression	No	Yes	No	Late	Exaggerated reflexes	Yes, pronounced tiredness	Social neglect, inappropriate relationships
III:11	52	18	<b>Paranoid ideations, delusions</b>	<b>Emotional lability, suicidal ideations</b>	<b>Pain (head, abdominal)</b>	<b>Yes</b>	<b>No</b>	<b>Early</b>	<b>Late Parkinsonism, falls</b>	<b>Yes, salivation</b>	<b>Social neglect, restlessness, anxiety, suicidal thoughts, paranoid ideations</b>
III:12	70	2	NA	Emotional lability	Pain (head, abdominal)	2/4 criteria	No	Late	Muscle atrophy, exaggerated reflexes, gait disturbance, falls	No	Apathy, anxiety
III:13	43	17	Visual/tactile halluc.	Emotional lability, aggression	Pain (head, abdominal)	Yes	Late	No	Incontinence	Yes, deterioration	Social neglect, restlessness, aggression, alcohol abuse

Abbreviations: PEMA=pallidum, echolalia, mutism and amimia; MND=motor neuron disease; aud.=auditory; halluc.=hallucinations; NA=not applicable, insufficient clinical data; Bold=neuropathologically verified cases. <sup>a</sup>The term social neglect is defined as loss of social awareness and insight in combination with neglect of self-care, ADLS and mismanagement of domestic activities.

**Table 2.** Brain pathology in neuropathologically verified cases

Case	Onset	Duration	Front cx	Temp cx	Pariet cx	Hipp	Nigra	Thalamus	Cerebellum	White matter, frontal	pTDP-43	Asymmetry	Weight (g)
III:3	50	5	++	+	+	0	++	0	0	0	2	R=L	1280
III:5	46	15	+++	++	++	+	+++	+++	+	++	4	R=L	1330
III:10	68	5	++	++	+	+	++	++	0	++	1	R>L	1130
III:11	52	18	+++ <sup>a</sup>	+++	+++	+++	+++	+++	++	+++	4	R>L	875
III:13	43	17	+++	++	+	++	++	++	+	++	3	R=L	1200

Abbreviations: Front cx=frontal cortex; Temp cx=temporal cortex; Pariet cx=parietal cortex; Nigra=substantia nigra; pTDP-43=phosphorylated tau DNA binding protein-43. R=right, L=left. <sup>a</sup>Extra severe degeneration, exceeding all other graded areas.



## FTD with a C9ORF72 expansion in a Swedish family

dying at age 74. She was admitted to the Department of Psychogeriatrics 4 years prior to death with severe agitation, restlessness and tactile hallucinations. Her speech was sparse with echolalia. Utilisation behaviour [37] was a prominent symptom. On low doses of antipsychotic drugs she displayed Parkinsonism and made no verbal contact. She often fell and during the last two years of life she was unable to walk. She died from heart failure.

II:4 This woman lived isolated in a cottage in the forest. It was reported that she had undergone a marked personality change during the last two decades of life. At the age of 85 she suffered from a stroke that left her hemiplegic on the left side. At that time it was noted she was mute.

II:5 At the age of 55 this mother of nine changed in personality. She became restless, neglected her home and family, showed an affective lability, stated suicidal threats and had auditory hallucinations. For a certain period of time she showed an elated mood with inappropriate singing and dancing. Speech output decreased and she showed perseverations. Utilisation behaviour and physical aggressiveness were noted.

III:2 This woman had a long history of diffuse somatic complaints (headache, vertigo), being subjected to repeated medical evaluations beginning at age 35. At the age of 68 her personality changed. She showed aggression and suspicions towards her husband, became restless and emotionally incontinent. She spent large amounts of money on unnecessary items with no thoughts of economic consequences. Visual hallucinations were present. She developed dysarthria, dysphagia and progressive muscle weakness, and was wheelchair ridden 2 years after onset. She died of pneumonia one year later.

III:3 This woman's husband reported a change in her personality when she was 50 years old. She became restless and unconcerned about herself and domestic activities, showed an affective lability and aggression. She reported visual hallucinations and started to confabulate. Her speech changed rapidly to stereotyped phrases and echolalia. Her ability to find words was severely impaired when given antipsychotic drugs. She died from aspiration of a large piece of food.

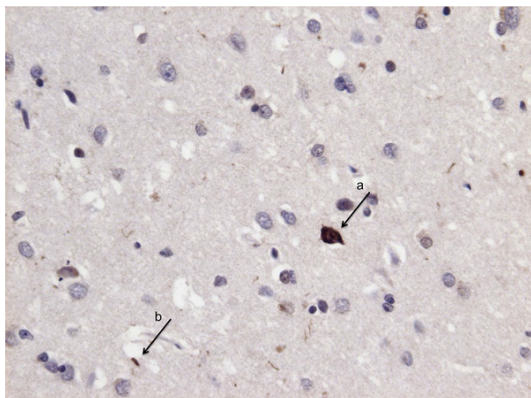
III:5 This man had several depressive episodes with suicidal thoughts but also paranoid ideas and suspiciousness starting in his mid-forties. He neglected his family. He continued to work for another 10 years after onset even after being diagnosed with cerebral atrophy. He showed a profound restlessness and often changed jobs. Disinhibition and compulsive behaviour were noticed. He was involved in several traffic accidents. He presented an array of somatic complaints mainly located to his abdomen and consulted many different physicians. No somatic reason for his complaints could be found. His spontaneous language gradually decreased and before reaching total mutism it consisted of only a limited number of stereotypical phrases. In contrast to the other affected family members he was still able to walk until he died after 17 years.

III:8 In her late sixties this woman changed in personality and neglected her home and family. She was restless and showed emotional lability. Her spontaneous speech gradually decreased. Clinical information about the last years of her life is limited.

III:10 The family of this woman reported a marked personality change at the age of 68, when she started to reply to contact advertisements and made several new acquaintances of inappropriate character. She became extremely restless. Early speech disturbances were noticed with severe logorrhoea followed by stereotyped phrases and reduced speech output. She died of pneumonia.

III:11 At the age of 52 this woman started to neglect her home and family. She was restless, anxious and preoccupied with somatic symptoms. According to relatives she mentioned suicidal thoughts and had paranoid ideas. Language impairment was seen early with stereotyped phrases and later dominated by echolalia. She was involved in several traffic incidents due to lack of judgement. During the last 7 years in life she was mute and bedridden.

III:12 In her early seventies this woman was severely demented. There is however limited information about the early stages of disease, but according to relatives she had gradually become restless and later apathetic. Her language deteriorated with perseverations and reduced output. She complained about pains in



**Figure 2.** Immunohistochemical Tar DNA-binding protein (TDP-43) staining from the anterior frontal lobe, showing features of TDP-43 type B pathology according to Mackenzie et al., including neuronal cytoplasmic inclusions (a) and few short dystrophic neurites (b).

head and abdomen. Motor features included a tendency to fall.

III:13 At the age of 43 this man changed in personality and behaviour. He became apathetic and no longer showed any interest in his family. He became quarrelsome with physical aggressiveness. His lack of insight and disinhibition led to shoplifting and impulsive economic transactions. Tactile and visual hallucinations with social consequences were present. His speech consisted of stereotyped phrases and echolalia. He complained about headache, abdominal and back pain.

#### *Brain pathology*

All five cases that were neuropathologically examined showed TDP-43 type B positive pathology with all cortical layers involved, few dystrophic neurites and few to moderate numbers of cellular inclusions (NCI) (**Figure 2**). A prominent feature, however, was that of intraneuronal granular positivities (not dense and delineated inclusions) in all cases - in those cases exhibiting most severe TDP pathology it was abundant. Staining with the p62 antibody revealed neuronal inclusions and fine granular positivities in the neocortex.

The severity of overall degeneration varied from mild to severe pathology, seemingly in parallel with the severity of TDP-43 pathology and with disease duration (**Table 2**). All cases had predominantly frontotemporal pathology, either

symmetric (3 cases) or predominantly right-sided (2 cases). The single case with marked brain atrophy (870 g) exhibited the most severe brain pathology and had the longest disease duration, whereas in four of the five cases, brain weight was within relatively normal limits (1130-1330 g), irrespective of disease severity, duration and age of onset. In the individual with brain weight of 1330 g, however, there was a final hypoxic oedema and congestion, probably contributing to the reported brain weight.

The substantia nigra exhibited neuronal loss and depigmentation in all cases, more severely in the two individuals displaying Parkinsonism.

The thalamus revealed neuronal loss and gliosis in four of the five cases. Among these, three showed psychotic symptoms. The patient without discernible thalamus changes displayed hallucinations and delusions.

Motor areas pertinent to MND features, such as cervical cord anterior motor neurons and the upper motor neurons of the postcentral neocortex, showed loss of or at least degeneration with atrophy of neurons in these regions. Due to dissimilar sampling over the years, only the postcentral motor cortex was represented in all cases, whereas cervical cord sections were available in only two of the cases.

#### *Genetic findings*

Cases III:2, III:10, III:11, III:13 all carried a pathogenic expansion in C9ORF72. The rpPCR analysis of DNA derived from paraffin-embedded material failed.

#### **Discussion**

In this study we provide a detailed analysis of the clinical features for 12 related individuals in a family with bvFTD and the C9ORF72 mutation, as well as describing the brain changes in 5 individuals. We highlight the degree of similarity and differences in clinical and neuropathological features in this large family with the newly discovered genetic abnormality. The particular approach of this longitudinal study is the description of a very thoroughly documented family with an autosomal dominant inheritance pattern. In contrast to other publications claiming great phenotypic heterogeneity even within families carrying the C9ORF72 expansion, we found that clinical presentations in this



family are strikingly similar, although age at onset and duration are highly variable.

Psychiatric symptoms including a profound restlessness, social neglect and affective symptoms were prominent features in this family, being among the earliest noted symptoms in the majority of cases. Psychotic symptoms have previously been described as a conspicuous feature in up to 50% of C9ORF72 carriers [21] and this is supported by the findings in our family. It has been suggested that thalamic and cerebellar projections could be related to the neuropsychiatric features associated with this mutation, including hallucinations and/or delusions [23]. However in our material, thalamic pathology was seen both in cases with and without psychotic symptoms.

None of our patients exhibited any positive effects from antipsychotic drugs. On the contrary, they all suffered from severe side effects that in some cases did not reverse after withdrawal of medication. This is in line with previous reports that FTD constitutes a group with marked vulnerability to pharmacological interventions [38]. All post mortem cases examined displayed degeneration of the substantia nigra. Thus, we cannot conclude to what extent the observed parkinsonian features are related to nigral degeneration or to pharmacologic side effects, or both.

The majority of patients exhibited somatic complaints such as pain, predominantly headache or abdominal pain, not supported by objective findings. It is difficult, though, to know the nature of these complaints, if there is a true organic background such as central pathology (i.e. involvement of the thalamus leading to altered pain experience) or unidentified changes in the peripheral neural system, or if they should be considered somatic delusions as discussed in earlier studies [21]. This matter needs to be studied in a larger case series. In a Brazilian kindred co-morbidity with inflammatory bowel disease was reported in 2 cases [39]. In our family several individuals complained about abdominal pain, and also had repeated medical examinations as a result. No patient was diagnosed with inflammatory bowel disease.

One speculative hypothesis on the high prevalence of FTD in this family (more than 50% of

generations 2 and 3) is the possibility that both parents in generation I may have been carriers of the C9ORF72 expansion. Genealogical research has shown that they both came from the same village. Another hypothesis may be that there are as yet unidentified modifying genes, resulting in a high vulnerability for this disease.

The prevailing opinion is that expansions of >30 repeats are pathological, but there is also one publication indicating that 20-30 repeats might also cause disease [31]. All four analysed cases in our family had >30 repeats. As this analysis included only a small number of cases it was not possible to make any conclusions regarding the exact number of repeats and, for example, demographic data. Thus the exact size of the expansions were not analysed by Southern blot. Other studies have not found any correlation between expansion size and age at onset or disease duration, but they have screened large cohorts for C9ORF72 expansions without looking at several related individuals [40].

Limitations of this study are the retrospective design with its inherent difficulty to assess reported symptoms based on clinical notes and that we did not have DNA and neuropathological data from all individuals. It is also possible that information about certain symptoms may not have been mentioned in the clinical records, thereby resulting in the underestimation of these. However, the affected family members had been followed thoroughly by repeated clinical evaluations and the disease course was very well documented in the majority of cases.

Summarising our findings, they demonstrate the importance of longitudinal follow up in familial neurodegenerative disease. Some individuals may progress extremely slowly and although the clinical picture is very similar between the family members some differences should not be neglected. Considering the variation in age at onset and disease duration there might be other factors than the C9ORF72 expansion yet to be revealed which contribute to the clinical picture and disease course.

### Acknowledgements

This study was supported by the Council of Region Skåne, Demensfonden, the Sjöbring

Foundation and the Trolle-Wachtmeister Foundation. The authors wish to thank Annette Persson for her contribution to the project.

#### Disclosure of conflict of interest

The authors declared no potential conflicts of interest with respect to the research, authorship, and/or publication of this article.

**Address correspondence to:** Dr. Maria Landqvist Waldö, Section of Geriatric Psychiatry, Department of Clinical Sciences, Lund University, Klinikgatan 22, Lund SE-221 85, Sweden. E-mail: maria.landqvist@med.lu.se

#### References

- [1] DeJesus-Hernandez M, Mackenzie IR, Boeve BF, Boxer AL, Baker M, Rutherford NJ, Nicholson AM, Finch NA, Flynn H, Adamson J, Kouri N, Wojtas A, Sengdy P, Hsiung GY, Karydas A, Seeley WW, Josephs KA, Coppola G, Geschwind DH, Wszolek ZK, Feldman H, Knopman DS, Petersen RC, Miller BL, Dickson DW, Boylan KB, Graff-Radford NR and Rademakers R. Expanded GGGGCC hexanucleotide repeat in noncoding region of C9ORF72 causes chromosome 9p-linked FTD and ALS. *Neuron* 2011; 72: 245-256.
- [2] Renton AE, Majounie E, Waite A, Simon-Sanchez J, Rollinson S, Gibbs JR, Schymick JC, Laaksovirta H, van Swieten JC, Myllykangas L, Kalimo H, Paetau A, Abramzon Y, Remes AM, Kaganovich A, Scholz SW, Duckworth J, Ding J, Harmer DW, Hernandez DG, Johnson JO, Mok K, Ryten M, Trabzuni D, Guerreiro RJ, Orrell RW, Neal J, Murray A, Pearson J, Jansen IE, Sondervan D, Seelaar H, Blake D, Young K, Halliwell N, Callister JB, Toulson G, Richardson A, Gerhard A, Snowden J, Mann D, Neary D, Nalls MA, Peuralinna T, Jansson L, Isoviiita VM, Kaivorinne AL, Holtta-Vuori M, Ikonen E, Sulkaava R, Benatar M, Wu J, Chio A, Restagno G, Borghero G, Sabatelli M, Heckerman D, Rogaeva E, Zinman L, Rothstein JD, Sendtner M, Drepper C, Eichler EE, Alkan C, Abdullaev Z, Pack SD, Dutra A, Pak E, Hardy J, Singleton A, Williams NM, Heutink P, Pickering-Brown S, Morris HR, Tienari PJ and Traynor BJ. A hexanucleotide repeat expansion in C9ORF72 is the cause of chromosome 9p21-linked ALS-FTD. *Neuron* 2011; 72: 257-268.
- [3] van Blitterswijk M, DeJesus-Hernandez M and Rademakers R. How do C9ORF72 repeat expansions cause amyotrophic lateral sclerosis and frontotemporal dementia: can we learn from other noncoding repeat expansion disorders? *Curr Opin Neurol* 2012; 25: 689-700.
- [4] Majounie E, Renton AE, Mok K, Dopfer EG, Waite A, Rollinson S, Chio A, Restagno G, Nicolaou N, Simon-Sanchez J, van Swieten JC, Abramzon Y, Johnson JO, Sendtner M, Pampillet R, Orrell RW, Mead S, Sidle KC, Houlden H, Rohrer JD, Morrison KE, Pall H, Talbot K, Ansgore O, Hernandez DG, Arepalli S, Sabatelli M, Mora G, Corbo M, Giannini F, Calvo A, Englund E, Borghero G, Floris GL, Remes AM, Laaksovirta H, McCluskey L, Trojanowski JQ, Van Deerlin VM, Schellenberg GD, Nalls MA, Drory VE, Lu CS, Yeh TH, Ishiura H, Takahashi Y, Tsuji S, Le Ber I, Brice A, Drepper C, Williams N, Kirby J, Shaw P, Hardy J, Tienari PJ, Heutink P, Morris HR, Pickering-Brown S and Traynor BJ. Frequency of the C9orf72 hexanucleotide repeat expansion in patients with amyotrophic lateral sclerosis and frontotemporal dementia: a cross-sectional study. *Lancet Neurol* 2012; 11: 323-330.
- [5] Clinical and neuropathological criteria for frontotemporal dementia. The Lund and Manchester Groups. *J Neurol Neurosurg Psychiatry* 1994; 57: 416-418.
- [6] Neary D, Snowden JS, Gustafson L, Passant U, Stuss D, Black S, Freedman M, Kertesz A, Robert PH, Albert M, Boone K, Miller BL, Cummings J and Benson DF. Frontotemporal lobar degeneration: a consensus on clinical diagnostic criteria. *Neurology* 1998; 51: 1546-1554.
- [7] Morita K, Kaiya H, Ikeda T and Namba M. Presenile dementia combined with amyotrophy: a review of 34 Japanese cases. *Arch Gerontol Geriatr* 1987; 6: 263-277.
- [8] Neary D, Snowden JS, Mann DM, Northen B, Goulding PJ and Macdermott N. Frontal lobe dementia and motor neuron disease. *J Neurol Neurosurg Psychiatry* 1990; 53: 23-32.
- [9] Rohrer JD, Guerreiro R, Vandrovцова J, Uphill J, Reiman D, Beck J, Isaacs AM, Authier A, Ferrari R, Fox NC, Mackenzie IR, Warren JD, de Silva R, Holton J, Revesz T, Hardy J, Mead S and Rossor MN. The heritability and genetics of frontotemporal lobar degeneration. *Neurology* 2009; 73: 1451-1456.
- [10] Rosso SM, Donker Kaat L, Baks T, Joosse M, de Koning I, Pijnenburg Y, de Jong D, Dooijes D, Kamphorst W, Ravid R, Niermeijer MF, Verheij F, Kremer HP, Scheltens P, van Duijn CM, Heutink P and van Swieten JC. Frontotemporal dementia in The Netherlands: patient characteristics and prevalence estimates from a population-based study. *Brain* 2003; 126: 2016-2022.
- [11] Sleegers K, Cruts M and Van Broeckhoven C. Molecular pathways of frontotemporal lobar

## FTD with a C9ORF72 expansion in a Swedish family

- degeneration. *Annu Rev Neurosci* 2010; 33: 71-88.
- [12] Rutherford NJ, Zhang YJ, Baker M, Gass JM, Finch NA, Xu YF, Stewart H, Kelley BJ, Kuntz K, Crook RJ, Sreedharan J, Vance C, Sorenson E, Lippa C, Bigio EH, Geschwind DH, Knopman DS, Mitsumoto H, Petersen RC, Cashman NR, Hutton M, Shaw CE, Boylan KB, Boeve B, Graff-Radford NR, Wszolek ZK, Caselli RJ, Dickson DW, Mackenzie IR, Petrucelli L and Rademakers R. Novel mutations in TARDBP (TDP-43) in patients with familial amyotrophic lateral sclerosis. *PLoS Genet* 2008; 4: e1000193.
- [13] Borroni B, Archetti S, Del Bo R, Papetti A, Burratti E, Bonvicini C, Agosti C, Cosseddu M, Turla M, Di Lorenzo D, Pietro Comi G, Gennarelli M and Padovani A. TARDBP mutations in frontotemporal lobar degeneration: frequency, clinical features, and disease course. *Rejuvenation Res* 2010; 13: 509-517.
- [14] Boxer AL, Mackenzie IR, Boeve BF, Baker M, Seeley WW, Crook R, Feldman H, Hsiung GY, Rutherford N, Laluz V, Whitwell J, Foti D, McDade E, Molano J, Karydas A, Wojtas A, Goldman J, Mirsky J, Sengdy P, Dearmond S, Miller BL and Rademakers R. Clinical, neuroimaging and neuropathological features of a new chromosome 9p-linked FTD-ALS family. *J Neurol Neurosurg Psychiatry* 2011; 82: 196-203.
- [15] van der Zee J, Gijssels I, Dillen L, Van Langenhove T, Theuns J, Engelborghs S, Philtjens S, Vandenbulcke M, Sleegers K, Sieben A, Baumer V, Maes G, Corsmit E, Borroni B, Padovani A, Archetti S, Pernecky R, Diehl-Schmid J, de Mendonca A, Miltenberger-Miltenyi G, Pereira S, Pimentel J, Nacmias B, Bagnoli S, Sorbi S, Graff C, Chiang HH, Westerlund M, Sanchez-Valle R, Llado A, Gelpi E, Santana I, Almeida MR, Santiago B, Frisoni G, Zanetti O, Bonvicini C, Synofzik M, Maetzler W, Vom Hagen JM, Schols L, Heneka MT, Jessen F, Matej R, Parobkova E, Kovacs GG, Strobel T, Sarafov S, Tournev I, Jordanova A, Danek A, Arzberger T, Fabrizio GM, Testi S, Salmon E, Santens P, Martin JJ, Cras P, Vandenberghe R, De Deyn PP, Cruts M, Van Broeckhoven C, Muller Vom Hagen J, Ramirez A, Kurzweil D, Sachtleben C, Mairer W, Fermo C, Antonell A, Molinuevo J, Kinhult Stahlbom A, Thonberg H, Nennesmo I, Borjesson-Hanson A, Bessi V, Piaceri I, Helena Ribeiro M, Rosario Almeida M, Oliveira C, Massano J, Garret C, Pires P, Danel A, Maria Fabrizio G, Ferrari S and Cavallaro T. A pan-European study of the C9orf72 repeat associated with FTL: geographic prevalence, genomic instability, and intermediate repeats. *Hum Mutat* 2013; 34: 363-373.
- [16] Whitwell JL, Weigand SD, Boeve BF, Senjem ML, Gunter JL, DeJesus-Hernandez M, Rutherford NJ, Baker M, Knopman DS, Wszolek ZK, Parisi JE, Dickson DW, Petersen RC, Rademakers R, Jack CR Jr and Josephs KA. Neuroimaging signatures of frontotemporal dementia genetics: C9ORF72, tau, progranulin and sporadics. *Brain* 2012; 135: 794-806.
- [17] Snowden JS, Rollinson S, Thompson JC, Harris JM, Stopford CL, Richardson AM, Jones M, Gerhard A, Davidson YS, Robinson A, Gibbons L, Hu Q, DuPlessis D, Neary D, Mann DM and Pickering-Brown SM. Distinct clinical and pathological characteristics of frontotemporal dementia associated with C9ORF72 mutations. *Brain* 2012; 135: 693-708.
- [18] Simon-Sanchez J, Dopfer EG, Cohn-Hokke PE, Hukema RK, Nicolaou N, Seelaar H, de Graaf JR, de Koning I, van Schoor NM, Deeg DJ, Smits M, Raaphorst J, van den Berg LH, Schelhaas HJ, De Die-Smulders CE, Majoor-Krakauer D, Rozemuller AJ, Willemsen R, Pijnenburg YA, Heutink P and van Swieten JC. The clinical and pathological phenotype of C9ORF72 hexanucleotide repeat expansions. *Brain* 2012; 135: 723-735.
- [19] Mok K, Traynor BJ, Schymick J, Tienari PJ, Laaksovirta H, Peuralinna T, Myllykangas L, Chio A, Shatunov A, Boeve BF, Boxer AL, DeJesus-Hernandez M, Mackenzie IR, Waite A, Williams N, Morris HR, Simon-Sanchez J, van Swieten JC, Heutink P, Restagno G, Mora G, Morrison KE, Shaw PJ, Rollinson PS, Al-Chalabi A, Rademakers R, Pickering-Brown S, Orrell RW, Nalls MA and Hardy J. Chromosome 9 ALS and FTD locus is probably derived from a single founder. *Neurobiol Aging* 2012; 33: 209, e3-8.
- [20] Beck J, Poulter M, Hensman D, Rohrer JD, Mahoney CJ, Adamson G, Campbell T, Uphill J, Borg A, Fratta P, Orrell RW, Malaspina A, Rowe J, Brown J, Hodges J, Sidle K, Polke JM, Houlden H, Schott JM, Fox NC, Rossor MN, Tabrizi SJ, Isaacs AM, Hardy J, Warren JD, Collinge J and Mead S. Large C9orf72 hexanucleotide repeat expansions are seen in multiple neurodegenerative syndromes and are more frequent than expected in the UK population. *Am J Hum Genet* 2013; 92: 345-353.
- [21] Takada LT and Sha SJ. Neuropsychiatric features of C9orf72-associated behavioral variant frontotemporal dementia and frontotemporal dementia with motor neuron disease. *Alzheimers Res Ther* 2012; 4: 38.
- [22] Hsiung GY, DeJesus-Hernandez M, Feldman HH, Sengdy P, Bouchard-Kerr P, Dwosh E, Butler R, Leung B, Fok A, Rutherford NJ, Baker M, Rademakers R and Mackenzie IR. Clinical and pathological features of familial frontotemporal dementia caused by C9ORF72 mutation on chromosome 9p. *Brain* 2012; 135: 709-722.

## FTD with a C9ORF72 expansion in a Swedish family

- [23] Mahoney CJ, Beck J, Rohrer JD, Lashley T, Mok K, Shakespeare T, Yeatman T, Warrington EK, Schott JM, Fox NC, Rossor MN, Hardy J, Collinge J, Revesz T, Mead S and Warren JD. Frontotemporal dementia with the C9ORF72 hexanucleotide repeat expansion: clinical, neuroanatomical and neuropathological features. *Brain* 2012; 135: 736-750.
- [24] Snowden JS, Harris J, Richardson A, Rollinson S, Thompson JC, Neary D, Mann DM and Pickering-Brown S. Frontotemporal dementia with amyotrophic lateral sclerosis: a clinical comparison of patients with and without repeat expansions in C9orf72. *Amyotroph Lateral Scler Frontotemporal Degener* 2013; 14: 172-176.
- [25] Dobson-Stone C, Hallupp M, Bartley L, Shepherd CE, Halliday GM, Schofield PR, Hodges JR and Kwok JB. C9ORF72 repeat expansion in clinical and neuropathologic frontotemporal dementia cohorts. *Neurology* 2012; 79: 995-1001.
- [26] Lindquist SG, Duno M, Batbayli M, Puschmann A, Braendgaard H, Mardosiene S, Svenstrup K, Pinborg LH, Vestergaard K, Hjermland LE, Stokholm J, Andersen BB, Johannsen P and Nielsen JE. Corticobasal and ataxia syndromes widen the spectrum of C9ORF72 hexanucleotide expansion disease. *Clin Genet* 2013; 83: 279-283.
- [27] O'Dowd S, Curtin D, Waite AJ, Roberts K, Pender N, Reid V, O'Connell M, Williams NM, Morris HR, Traynor BJ and Lynch T. C9ORF72 expansion in amyotrophic lateral sclerosis/frontotemporal dementia also causes Parkinsonism. *Mov Disord* 2012; 27: 1072-1074.
- [28] Wojtas A, Heggeli KA, Finch N, Baker M, DeJesus-Hernandez M, Younkin SG, Dickson DW, Graff-Radford NR and Rademakers R. C9ORF72 repeat expansions and other FTD gene mutations in a clinical AD patient series from Mayo Clinic. *Am J Neurodegener Dis* 2012; 1: 107-118.
- [29] Mackenzie IR, Neumann M, Baborie A, Sampathu DM, Du Plessis D, Jaros E, Perry RH, Trojanowski JQ, Mann DM and Lee VM. A harmonized classification system for FTLD-TDP pathology. *Acta Neuropathol* 2011; 122: 111-113.
- [30] Boeve BF, Boylan KB, Graff-Radford NR, DeJesus-Hernandez M, Knopman DS, Pedraza O, Vemuri P, Jones D, Lowe V, Murray ME, Dickson DW, Josephs KA, Rush BK, Machulda MM, Fields JA, Ferman TJ, Baker M, Rutherford NJ, Adamson J, Wszolek ZK, Adeli A, Savica R, Boot B, Kuntz KM, Gavriloava R, Reeves A, Whitwell J, Kantarci K, Jack CR Jr, Parisi JE, Lucas JA, Petersen RC and Rademakers R. Characterization of frontotemporal dementia and/or amyotrophic lateral sclerosis associated with the GGGGCC repeat expansion in C9ORF72. *Brain* 2012; 135: 765-783.
- [31] Gomez-Tortosa E, Gallego J, Guerrero-Lopez R, Marcos A, Gil-Neciga E, Sainz MJ, Diaz A, Franco-Macias E, Trujillo-Tiebas MJ, Ayuso C and Perez-Perez J. C9ORF72 hexanucleotide expansions of 20-22 repeats are associated with frontotemporal deterioration. *Neurology* 2013; 80: 366-370.
- [32] Passant U, Gustafson L and Brun A. Spectrum of frontal lobe dementia in a Swedish family. *Dementia* 1993; 4: 160-162.
- [33] Englund E, Gustafson L, Passant U, Majounie E, Renton AE, Traynor BJ, Rohrer JD, Mok K and Hardy J. Familial Lund frontotemporal dementia caused by C9ORF72 hexanucleotide expansion. *Neurobiol Aging* 2012; 33: 1850, e13-6.
- [34] Gustafson L. Clinical picture of frontal lobe degeneration of non-Alzheimer type. *Dementia* 1993; 4: 143-148.
- [35] Brunnstrom H and Englund E. Clinicopathological concordance in dementia diagnostics. *Dementia* 2009; 17: 664-670.
- [36] Landqvist Waldo M, Frizell Santillo A, Passant U, Zetterberg H, Rosengren L, Nilsson C and Englund E. Cerebrospinal fluid neurofilament light chain protein levels in subtypes of frontotemporal dementia. *BMC Neurol* 2013; 13: 54.
- [37] Lhermitte F. 'Utilization behaviour' and its relation to lesions of the frontal lobes. *Brain* 1983; 106: 237-255.
- [38] Kerssens CJ and Pijnenburg YA. Vulnerability to neuroleptic side effects in frontotemporal dementia. *Eur J Neurol* 2008; 15: 111-112.
- [39] Takada LT, Pimentel ML, DeJesus-Hernandez M, Fong JC, Yokoyama JS, Karydas A, Thibodeau MP, Rutherford NJ, Baker MC, Lomen-Hoerth C, Rademakers R and Miller BL. Frontotemporal dementia in a Brazilian kindred with the c9orf72 mutation. *Arch Neurol* 2012; 69: 1149-1153.
- [40] Rutherford NJ, Heckman MG, DeJesus-Hernandez M, Baker MC, Soto-Ortolaza AI, Rayaprolu S, Stewart H, Finger E, Volkening K, Seeley WW, Hatanpaa KJ, Lomen-Hoerth C, Kertesz A, Bigio EH, Lippa C, Knopman DS, Kretzschmar HA, Neumann M, Caselli RJ, White CL 3rd, Mackenzie IR, Petersen RC, Strong MJ, Miller BL, Boeve BF, Uitti RJ, Boylan KB, Wszolek ZK, Graff-Radford NR, Dickson DW, Ross OA and Rademakers R. Length of normal alleles of C9ORF72 GGGGCC repeat do not influence disease phenotype. *Neurobiol Aging* 2012; 33: 2950, e5-7.