



LUND UNIVERSITY

Sentinel lymph node biopsy in endometrial cancer

Geppert, Barbara

2018

Document Version:

Publisher's PDF, also known as Version of record

[Link to publication](#)

Citation for published version (APA):

Geppert, B. (2018). *Sentinel lymph node biopsy in endometrial cancer*. [Doctoral Thesis (compilation), Obstetrics and Gynaecology (Lund)]. Lund University: Faculty of Medicine.

Total number of authors:

1

General rights

Unless other specific re-use rights are stated the following general rights apply:

Copyright and moral rights for the publications made accessible in the public portal are retained by the authors and/or other copyright owners and it is a condition of accessing publications that users recognise and abide by the legal requirements associated with these rights.

- Users may download and print one copy of any publication from the public portal for the purpose of private study or research.
- You may not further distribute the material or use it for any profit-making activity or commercial gain
- You may freely distribute the URL identifying the publication in the public portal

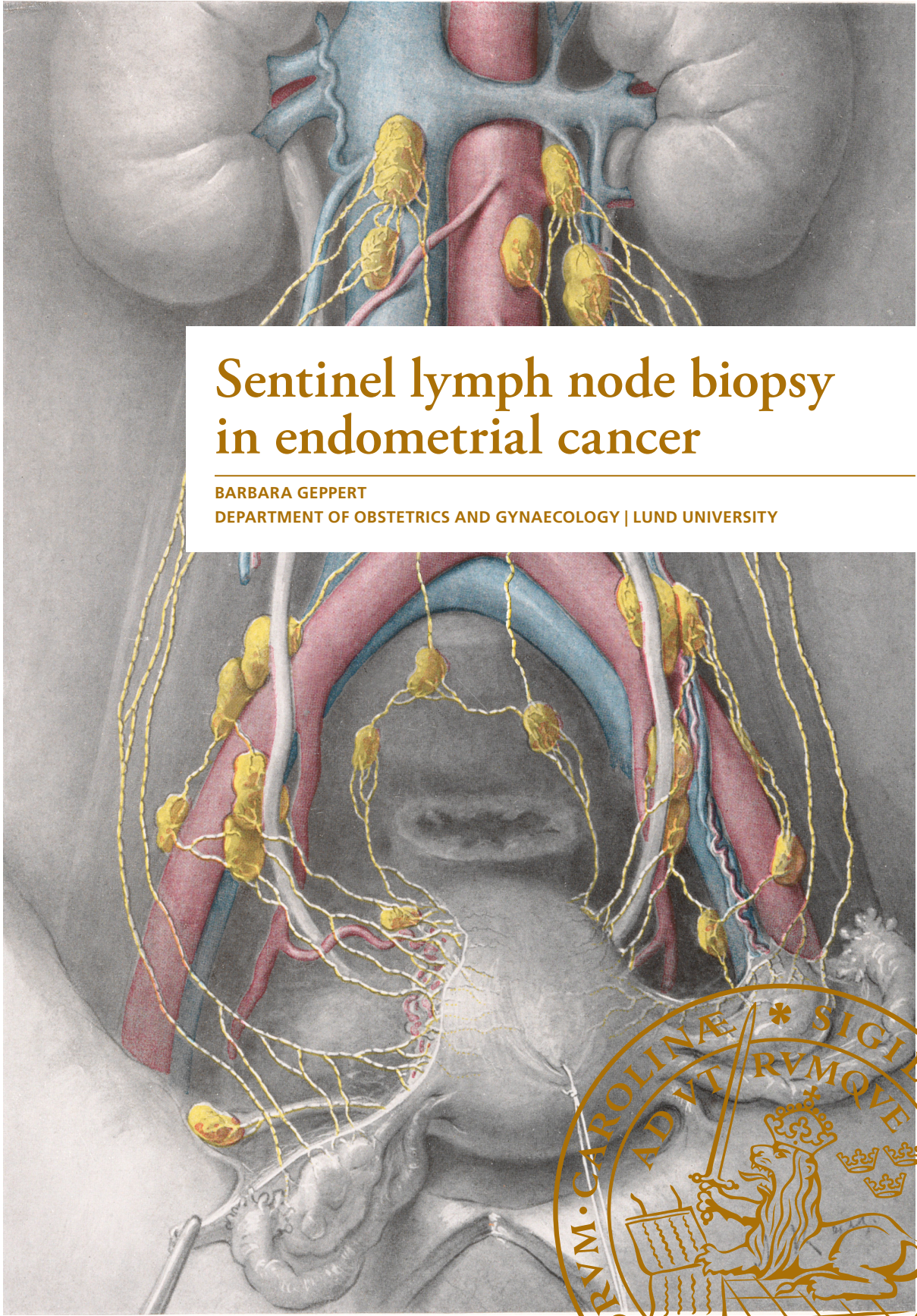
Read more about Creative commons licenses: <https://creativecommons.org/licenses/>

Take down policy

If you believe that this document breaches copyright please contact us providing details, and we will remove access to the work immediately and investigate your claim.

LUND UNIVERSITY

PO Box 117
221 00 Lund
+46 46-222 00 00



Sentinel lymph node biopsy in endometrial cancer

BARBARA GEPPERT

DEPARTMENT OF OBSTETRICS AND GYNAECOLOGY | LUND UNIVERSITY



Sentinel lymph node biopsy in endometrial cancer

Barbara Geppert



LUND
UNIVERSITY

DOCTORAL DISSERTATION

by due permission of the Faculty of Medicine, Lund University, Sweden.

To be defended at the Department of Obstetrics and Gynaecology.

Friday 19 January 2018 at 09:00.

Faculty opponent

Professor Philippe Morice, University Paris-Sud (Paris XI), France

Organization LUND UNIVERSITY	Document name DOCTORAL DISSERTATION	
	Date of disputation: January 19, 2018	
Barbara Geppert	Sponsoring organization: None	
Sentinel lymph node biopsy in endometrial cancer		
<p>The general objectives were to examine the feasibility of robot-assisted pelvic and para-aortic lymphadenectomy, and to develop and evaluate an algorithm for detecting sentinel lymph nodes in endometrial cancer.</p> <p>Aims: Study I: To evaluate the feasibility and lymphatic complications of robot-assisted infrarenal para-aortic and pelvic lymphadenectomy. Study II: To describe the anatomy of uterine lymphatic drainage following cervical or fundal tracer injection to enable standardization of a pelvic sentinel lymph node concept.</p> <p>Study III: To describe and evaluate an anatomically based surgical algorithm for detecting sentinel lymph nodes.</p> <p>Study IV: To assess the feasibility and safety of sentinel lymph node biopsy and to compare the rate of lymphatic complications with those of full pelvic and infrarenal para-aortic lymphadenectomy.</p> <p>Material and methods: Study I: Success rate, factors associated with nodal yield and lymphatic complications were analysed in 140 patients scheduled to receive robot-assisted lymphadenectomy. Studies II–IV: Patients with endometrial cancer scheduled to receive robot-assisted surgery were approached for inclusion in a sentinel lymph node study using indocyanine green (ICG). In low-risk patients, sentinel lymph node biopsy was performed before hysterectomy. In high-risk patients, sentinel lymph node biopsy was followed by a pelvic and infrarenal para-aortic lymphadenectomy. Study II: ICG was injected into the cervix (n = 60) or fundus uteri (n = 30) to depict uterine lymphatic drainage and compare positions of pelvic sentinel lymph nodes and lymph node metastases. Study III: An algorithm for sentinel lymph node identification in the two bilateral pelvic lymphatic pathways using cervical injection and reinjection of ICG was applied in 102 high-risk endometrial cancer patients. After sentinel lymph node removal, complete pelvic and para-aortic lymphadenectomy was performed. Study IV: The performance of sentinel lymph node biopsy alone in low-risk patients was compared with that of full lymphadenectomy in high-risk patients in 188 women. The effect of the extent of the lymphadenectomy on the complication rate was evaluated.</p> <p>Results: Study I: Infrarenal para-aortic lymphadenectomy was possible in 70% of patients. High body mass index and the surgeon's inexperience restricted para-aortic nodal staging. Study II: Independent of the injection site, two consistent lymphatic pathways with pelvic sentinel lymph nodes were detected: an upper paracervical pathway with draining medial external iliac and/or obturator lymph nodes and a lower pathway with draining presacral lymph nodes. The bilateral sentinel lymph node detection rates were 98% for cervical injection and 80% for fundal injection (p = 0.005). Study III: The anatomically based algorithm including tracer reinjection produced a bilateral detection rate of 96%. All 24 (23.5%) node-positive patients had at least one metastatic sentinel lymph node. Study IV: No intraoperative complications were associated with the sentinel lymph node biopsy as such. Sentinel lymph node biopsy alone reduced the risk of leg lymphoedema (1.3% vs 18.1% after pelvic and infrarenal para-aortic lymphadenectomy, respectively; p = 0.0003).</p> <p>Conclusions: An infrarenal robot-assisted para-aortic lymphadenectomy is feasible in most patients. The lymphatic anatomy comprises two bilateral pelvic pathways. Similarly positioned sentinel lymph nodes could be depicted independent of the tracer injection site, but cervical injection resulted in a higher technical success rate. The anatomically based algorithm for sentinel lymph node detection using cervical ICG injection showed a high detection rate and identified all patients with lymph node metastases. This thesis shows that sentinel lymph node biopsy is feasible and safe, and has a low risk of leg lymphoedema. Therefore, this thesis supports the implementation of sentinel lymph node biopsy in low-risk endometrial cancer patients.</p>		
Key words: endometrial cancer, sentinel lymph node biopsy, lymphadenectomy, lymphatic metastases, lymphatic system, lymphatic complications, indocyanine green, robotic surgery		
Classification system and/or index terms (if any)		
Supplementary bibliographical information	Language: English	
ISSN: 1652-8220; Key title: Lund University, Faculty of Medicine Doctoral Dissertation Series 2018:2	ISBN: 978-91-7619-570-3	
Recipient's notes	Number of pages 105	Price
	Security classification	

I, the undersigned, being the copyright owner of the abstract of the above-mentioned dissertation, hereby grant to all reference sources permission to publish and disseminate the abstract of the above-mentioned dissertation.

Signature 

Date 2017 12 01

Sentinel lymph node biopsy in endometrial cancer

Barbara Geppert



LUND
UNIVERSITY

Front cover illustration by Döderlein and Krönig, 1912, with kind permission of Thieme Medical publishers, Germany, modified by Jan Funke

Copyright Barbara Geppert

Faculty of Medicine
Department of Obstetrics and Gynaecology

ISBN 978-91-7619-570-3

ISSN 1652-8220

Printed in Sweden by Media-Tryck, Lund University
Lund 2017



*To my husband Daniel Nilsson
and my parents, Dr Adelheid and Dr Christian Geppert*

Contents

Thesis at a glance	9
Original studies	10
Populärvetenskaplig sammanfattning	11
Populärwissenschaftliche Zusammenfassung	15
Abstract	20
Abbreviations	23
Introduction	25
Background	27
Endometrial cancer.....	27
Epidemiology and aetiology	27
Symptoms and diagnosis	28
Histopathology	29
Preoperative risk assessment	32
Classification	33
Lymphatic anatomy	34
Routes of lymphatic spread	38
Surgical treatment.....	38
Adjuvant treatment	40
Lymphatic complications	43
Prognosis	46
Sentinel lymph node biopsy	50
Development	50
Sentinel lymph node biopsy in endometrial cancer	51
Aims	57
General aims.....	57
Specific aims	57

Material and methods	59
Study I	59
Studies II–IV	60
Ethical considerations	67
Results.....	69
Study I	69
Study II	71
Study III	75
Study IV	76
Further results.....	78
Discussion	79
Feasibility of robot-assisted lymphadenectomy	79
Lymphatic anatomy	80
Tracer injection site	81
Surgical algorithm for sentinel lymph node detection	82
Lymphatic complications following lymphadenectomy or sentinel lymph node biopsy	83
Conclusions	85
Future aspects	87
Acknowledgements	89
References	91

Thesis at a glance

Study	Aim	Results	Conclusion
Study I: Robotic infrarenal paraaortic and pelvic nodal staging for endometrial cancer: feasibility and lymphatic complications.	To evaluate the feasibility and lymphatic complications of robotic pelvic and infrarenal para-aortic lymphadenectomy in endometrial cancer patients.	Robotic infrarenal para-aortic lymphadenectomy was intended in 71% of consecutive high-risk endometrial cancer patients. The lymphadenectomy performed included the infrarenal area in 70%, was restricted to the inframesenteric area in 21% and was aborted or incomplete in 9%. The median number of removed para-aortic lymph nodes was 10 (range 2–39). An unsuccessful staging was associated with high body mass index and surgeon's inexperience. Grade 1 lower extremity lymphoedema was seen in 12% and Grade 2 in 2% of patients. Eleven women (8%) exhibited pelvic lymphoceles.	Infrarenal robotic para-aortic lymphadenectomy was feasible in 70% of high-risk endometrial cancer patients when intended and in 88% of non-obese patients operated on by experienced surgeons. Lower extremity lymphoedema following lymphadenectomy occurred in 14% of patients.
Study II: A study on uterine lymphatic anatomy for standardization of pelvic sentinel lymph node detection in endometrial cancer.	To describe the anatomy of uterine lymphatic drainage following cervical or fundal tracer injection to enable standardization of a pelvic sentinel lymph node concept in endometrial cancer.	Two consistent lymphatic pathways with pelvic sentinel lymph nodes were identified: an upper paracervical pathway with draining medial external iliac and/or obturator lymph nodes, and a lower paracervical pathway with draining presacral nodes. Bilateral display of at least one pelvic pathway following cervical and fundal injection occurred in 98% and 80% of patients, respectively ($p = 0.005$). Nearly one-third of the 19% node-positive patients had metastases along the lower paracervical pathway. No false-negative sentinel lymph nodes were identified.	Bilateral detection of at least one sentinel lymph node in both the upper and lower paracervical pathway should be the aim. Although the pelvic pathways and positions of sentinel lymph nodes are independent of the tracer injection site, cervical injection is preferable because it had a higher technical success rate.
Study III: Description of a reproducible anatomically based surgical algorithm for detection of pelvic sentinel lymph nodes in endometrial cancer.	To describe and evaluate a reproducible, anatomically based surgical algorithm for detection of pelvic sentinel lymph nodes in endometrial cancer that included reinjection of a tracer to improve the technical success rate.	The bilateral detection rate including tracer reinjection was 96%. All 24 (23.5%) node-positive patients had at least one metastatic sentinel lymph node. Presacral lymph node metastases were found in 33.3% of node-positive patients. One patient (4.2%) had an isolated presacral lymph node metastasis.	The described cranial-to-caudal anatomically based surgical sentinel lymph node algorithm, including presacral dissection and reinjection of tracer, resulted in a high sentinel lymph node detection rate and identified all patients with lymph node metastases.
Study IV: Sentinel lymph node biopsy in endometrial cancer – feasibility, safety and lymphatic complications.	To compare the rate of lymphatic complications in women undergoing sentinel lymph node biopsy versus sentinel lymph node biopsy followed by full pelvic and infrarenal para-aortic lymphadenectomy and to examine the overall feasibility and safety of the sentinel lymph node procedure.	Sentinel lymph node biopsy alone resulted in a lower incidence of leg lymphoedema than infrarenal para-aortic and pelvic lymphadenectomy (1.3% vs 18.1%, respectively; $p = 0.0003$). The bilateral detection rate of sentinel lymph nodes was 96% after cervical tracer injection. No intraoperative complication was associated with the sentinel lymph node biopsy per se. Compared with hysterectomy alone, the additional average operating time for removal of sentinel lymph nodes was 33 minutes.	The high feasibility, absence of intraoperative complications and low risk of lymphatic complications support the implementation of this concept for detecting sentinel lymph nodes in low-risk endometrial cancer patients.

Original studies

This thesis is based on following original studies, referred to in the text by their Roman numerals. The studies are appended at the end of the thesis. Reprints are made with permission from the publisher.

- I. Geppert B, Persson J. Robotic infrarenal paraaortic and pelvic nodal staging for endometrial cancer: feasibility and lymphatic complications. *ACTA Obstetrica et Gynecologica Scandinavica* 2015 Oct;94 (10):1074–81.
- II. Geppert B, Lönnerfors C, Bollino M, Arechvo A, Persson J. A study on uterine lymphatic anatomy for standardization of pelvic sentinel lymph node detection in endometrial cancer. *Gynecologic Oncology* 145 (2017) 256–261.
- III. Persson J, Geppert B, Lönnerfors C, Bollino M, Måsbäck A. Description of a reproducible anatomically based surgical algorithm for detection of pelvic sentinel lymph nodes in endometrial cancer. *Gynecologic Oncology* 147 (2017) 120–125.
- IV. Geppert B, Lönnerfors C, Bollino M, Persson J. Sentinel lymph node biopsy in endometrial cancer – feasibility, safety and lymphatic complications. In revision after submission in *Gynecologic Oncology*.

Populärvetenskaplig sammanfattning

Livmoderkroppscancer är den vanligaste gynekologiska canceren i Sverige och drabbar årligen ca 30 av 100 000 kvinnor. Prognosen är överlag god då tumören ofta ger tidiga symptom i form av vaginala blödningar efter klimakteriet. Canceren kan botas genom att operera bort livmoder, äggledare och äggstockar. I vissa fall sker dock en spridning till lymfkörtlar, vilket försämrar prognosen och ofta kräver efterbehandling i form av strålterapi och cellgift. För att avgöra om canceren har spridit sig till lymfkörtlar måste dessa opereras bort och undersökas mikroskopiskt.

Man vet att vissa typer och växtsätt av livmodercancer ger ökad risk för cancerspridning till lymfkörtlar. Därför har man gjort ett vårdprogram där man delar in patienter i ”lågriskpatienter” där man inte behöver genomgå en lymfkörtelutrymning (avlägsna lymfkörtlar) och ”högriskpatienter” där man ska genomgå en lymfkörtelutrymning i bäckenet och längs den stora kroppspulsådern. Det finns dock flera problem med uppdelningen:

1. Även om risken för cancer i lymfkörtlarna är låg i lågriskgruppen är den inte noll. Flera studier har visat att ca 5 % av patienterna som tillhör lågriskgruppen har cancerväxt i lymfkörtlarna.
2. Gruppindelningen baseras på ultraljud för att avgöra växtsätt i livmodern och ett ofta litet vävnadsprov som har tagits från livmoderkroppens slemhinna för att ställa diagnosen. Indelningen stämmer i ca 20 % inte överens med den slutgiltiga mikroskopiska undersökningen av hela livmodern. Det visar sig att patienter som innan operationen bedömdes tillhöra lågriskgruppen i själva verket tillhör högriskgruppen eller tvärtom.
3. I högriskgruppen har bara ca 20 % av patienterna cancer i lymfkörtlarna. Detta innebär att 80 % genomgår en längre operation med risk för komplikationer och bestående biverkningar utan någon vinst i överlevnaden.

Traditionellt sett har man opererat bort livmodern och lymfkörtlarna med öppen kirurgi. Då det i många studier har visat sig att titthålsteknik ger snabbare återhämtning än öppen kirurgi, undersöktes det i **delarbete I** om man kan operera bort lymfkörtlar i bäckenet och längs den stora kroppspulsådern med robot-assisterad titthålsteknik. Det undersöktes också vilken andel patienter som är lämpliga för denna teknik. Titthålsteknik innebär att man opereras med instrument via 8–15 mm tjocka rör som förs in genom bukväggen istället för ett stort buksnitt. På kvinnokliniken i Lund, Skånes Universitetssjukhus, finns sedan 2005 en operationsrobot som är ett avancerat hjälpmedel för svårare titthålskirurgi. Den möjliggör bland annat tredimensionellt seende och har en handledsfunktion, vilket inte finns vid vanlig titthålsteknik. I delarbete I undersöktes det även hur många

patienter som får problem med lymfatiska komplikationer, så som bensvullnad och lymfcystor.

Mellan 2010 och 2013 behandlades 212 patienter med livmoderkroppscancer där man bedömde att det fanns risk för spridning av cancer till lymfkörtlarna på kvinnokliniken i Lund. Av dessa valdes 150 (71 %) ut för robot-assisterad kirurgi med borttagning av lymfkörtlarna. De andra hade antingen tecken till cancerspridning i buken, skulle inte opereras, tålde inte titthålskirurgi eller borttagande av lymfkörtlar. En fullständig lymfkörtelutrymning i bäckenet och längs den stora kroppspulsådern var möjligt i 70 % av valda patienter. Fetma och en mindre erfaren kirurg var orsaker till att man bara kunde genomföra en begränsad lymfkörtelutrymning. Efter lymfkörtelutrymningen utvecklade 14 % av kvinnorna ett lymfödem i benen. Slutsatsen av denna studie var att ingreppet kan göras robot-assisterat, men att det ska centraliseras så att det kan utföras av erfarna operatörer. Det spekulerades över att en förbättrad teknik kan öka lyckandefrekvensen, vilket bekräftades efter inskaffandet av en ny modell av operationsrobot i februari 2015. Dessa data är dock inte publicerade än.

Problemet med borttagande av lymfkörtlar och risk för bestående lymfödem finns inte bara vid livmodercancer, utan också vid till exempel bröstcancer. Därför har det utvecklats tekniker för att hitta de lymfkörtlar dit tumören har störst risk att sprida sig, så kallade "portvakslymfkörtlar" (bild 1). Teorin bakom detta är att lymfan rinner i definierade banor där lymfkörtlar ligger som pärlor på ett snöre. Om den första lymfkörteln, portvakslymfkörteln, är cancerfri är efterföljande lymfkörtlar också friska. Först opererar man bort portvakslymfkörteln och undersöker den. Om den är frisk behöver inga fler lymfkörtlar avlägsnas. Vid bröst- och hudcancer används konceptet sedan flera år, men inte vid livmoderkroppscancer.

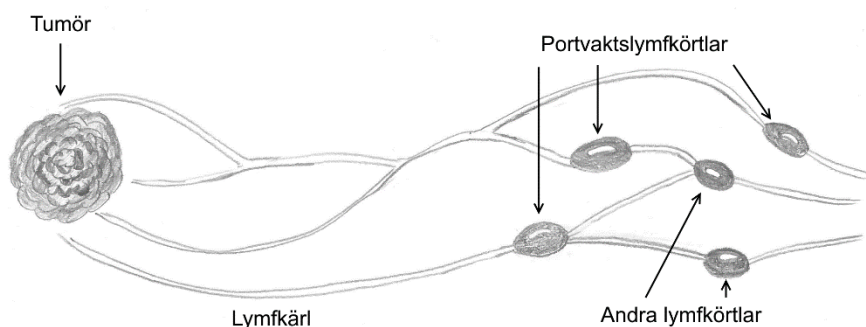


Bild 1
Principen bakom portvakslymfkörtlar

Med tanke på att 80 % av alla patienter med livmoderkroppscancer ur högriskgruppen genomgår lymfkörtelutrymning utan att vinna i överlevnad men riskerar bestående lymfsvullnad, var målet med **delarbete II** att kartlägga lymfanatomin. Den skulle ligga till grund för utvecklingen av ett koncept att identifiera portvaktslymfkörtlar. Det undersöktes också om det är bättre att spruta in ett färgämne som visar var lymfkörtlarna ligger i livmoderhalsen eller livmoderkroppen. Färgämnet heter Indocyanin grön (ICG) och lyser grönt om man använder en speciell teknik som finns i operationsroboten. Man kan inte se färgämnet i vanligt ljus.

Det inkluderades 90 kvinnor i det andra delarbetet. ICG sprutades hos 60 kvinnor i livmoderhalsen och hos 30 kvinnor i livmoderkroppen. Det är tekniskt enklare att spruta i livmoderhalsen, men motståndare mot denna teknik säger att det inte motsvarar lymfavflödet från cancer som ligger i livmoderkroppen. Två lymfbånar på varje sida i bäckenet hittades. Den övre banan går till bäckenkärnen och den nedre banan går mot korsbenets framsida. Den övre banan har visats i många studier och är välkänd, men den nedre banan, även om den finns med i historiska anatomiska studier, verkar ha glömts bort. Båda banor med liknande lokalisering av portvaktslymfkörtlar kunde visas oavsett om man hade sprutat ICG i livmoderhalsen eller -kroppen. Dock lyckades det betydligt oftare att hitta portvaktslymfkörtlar på båda sidor i bäckenet efter injektion i livmoderhalsen varför en slutsats av delarbetet var att använda livmoderhalsen som injektionsställe framöver. Den andra slutsatsen var att man måste försöka att hitta en portvaktslymfkörtel per bana för att kunna vara säker att inte missa cancer.

Delarbete III handlade om att utveckla och utvärdera en algoritm för upptäckten av portvaktslymfkörtlar. Det togs fram en algoritm där man sprutar ICG i livmoderhalsen eftersom delarbete II visade att det gav bättre lyckandefrekvens. Efter injektionen skulle operatören avlägsna en portvaktslymfkörtel i varje lymfbana som delarbete II hade visat. Om det inte kunde identifieras en lymfkörtel i varje bana, skulle man spruta ICG en gång till för att se om det hjälpte. Efteråt skulle patienten opereras med en fullständig lymfkörtelutrymning för att säkerställa att konceptet inte missade någon patient med cancer i lymfkörtlarna.

Det inkluderas 102 patienter i denna studie. Då de flesta andra studier om identifiering av portvaktslymfkörtlar inte tar hänsyn till lymfanatomi, är en vanlig definition av lyckandegraden att man har hittat en portvaktslymfkörtel per sida. Detta lyckades i 96 % av patienterna med hjälp av förnyad injektion av ICG. Konceptet hittade alla patienter där cancer hade spridit sig till lymfkörtlarna. Det är dock svårare att hitta portvaktslymfkörtlar i den nedre lymfbanan än den övre. Cancer i lymfkörtlarna är vanligare längs den övre banan, men en tredjedel av alla patienter med cancer i lymfkörtlarna hade det också i den nedre banan.

En av anledningarna till att intresset för portvaktslymfkörtlar vid livmodercancer har stigit enormt det senaste året är att man tror att biverkningarna är färre än efter en full lymfkörtelutrymning. Enligt nya riktlinjer får man nu använda konceptet i USA. Men trots detta är det ingen som har undersökt om det verkligen är så att färre kvinnor får problem med lymfsvullnad efter enbart borttagande av portvaktslymfkörtlarna. I **delarbete IV** har det därför undersökts hur många kvinnor där man bara tog bort portvaktslymfkörteln som får problem med lymfsvullnad i jämförelse med de där man har gjort en full lymfkörtelutrymning. Det har även undersökts om konceptet är säkert så att det också kan användas vid de patienter som har låg risk för cancer i lymfkörtlarna.

Det jämfördes 83 kvinnor som genomgick full lymfkörtelutrymning med 76 kvinnor där man bara tog bort portvaktslymfkörtlarna. Risken för operativ komplikation var låg i båda grupperna och ingen komplikation skedde under eller pga. själva borttagande av portvaktslymfkörtlarna. Efter en full lymfkörtelutrymning utvecklade 18 % lymfödem, efter borttagande av endast portvaktslymfkörtlarna 1 % vilket var en statistiskt signifikant skillnad. Slutsatsen av denna studie var att konceptet är så säkert att man ska använda det hos patienter med låg risk för cancer i lymfkörtlarna, där man enligt vårdprogrammet hittills inte har tagit bort några lymfkörtlar över huvud taget. Fler studier behövs för att kunna statistiskt säkert avgöra om konceptet är så säkert att det kan användas hos de patienterna som har hög risk för cancerspridning till lymfkörtlarna, men preliminära resultat är lovande.

Sammanfattningsvis har denna doktorsavhandling visat att det i de flesta fall är möjligt att operera livmoderkroppscancer med operationsroboten. En algoritm baserad på lymfanatomi har utvecklats för identifiering av portvaktslymfkörtlar. Att ta bort portvaktslymfkörtlar är ett säkert ingrepp som minskar risken för lymfsvullnad i benen betydligt i jämförelse med en full lymfkörtelutrymning. Konceptet kan användas för kvinnor där det finns en låg risk för cancer i lymfkörtlarna. En pågående studie i Lund kommer att besvara frågan om konceptet även kan ersätta den fulla lymfkörtelutrymning som man har hittills gjort om det finns en hög risk för cancer i lymfkörtlarna.

Populärwissenschaftliche Zusammenfassung

Gebärmutterkrebs, der von der Gebärmutter Schleimhaut ausgeht, ist der häufigste gynäkologische Krebs in Schweden. Jedes Jahr erkranken zirka 30 von 100 000 Frauen. Die Prognose ist insgesamt gut, da dieser Krebs frühe Symptome in Form von vaginalen Blutungen nach den Wechseljahren zeigt. Die meisten Frauen können durch Entfernung der Gebärmutter, der Eierstöcke und der Eileiter geheilt werden. Manchmal breitet sich der Krebs jedoch auf Lymphknoten aus, wodurch sich die Prognose verschlechtert. Um dem entgegenzuwirken, folgt dann der Operation noch eine weitere Behandlung mit Strahlen- und Chemotherapie. Die operative Entfernung der Lymphknoten für eine feingewebliche Untersuchung ist die einzige Möglichkeit, herauszufinden, ob sie befallen sind.

Das Risiko, dass die Lymphknoten auch befallen sind, ist bei manchen Typen und größeren Tumoren erhöht. Daher hat man in Schweden und international Richtlinien entwickelt, die die Patientinnen vor der Operation in eine „Hochrisiko-“ und eine „Niedrigrisiko“-Gruppe einteilen. In der Niedrigrisiko-Gruppe entfernt man nur die Gebärmutter, die Eierstöcke und die Eileiter. In der Hochrisiko-Gruppe entfernt man zusätzlich auch die Lymphknoten im Becken und entlang der Aorta. Diese Aufteilung ist jedoch aus mehreren Gründen problematisch:

1. Auch wenn das Risiko für Lymphknotenbefall in der Niedrigrisiko-Gruppe klein ist, ist es nicht gleich Null. Mehrere Studien haben gezeigt, dass auch in dieser Gruppe zirka 5 % der Patientinnen krebsbefallene Lymphknoten haben.
2. Die Einteilung basiert zum einen auf Ultraschall, um zu sehen, ob der Krebs in den Gebärmutterhals und tief in die Gebärmutterwand einwächst und zum anderen auf einer oft nur kleinen Gewebeentnahme der Gebärmutter Schleimhaut. Wenn nach der Operation die ganze Gebärmutter mikroskopisch untersucht wird, zeigt sich in zirka 20 %, dass Niedrigrisiko-Patientinnen eigentlich Hochrisiko-Patientinnen sind oder umgekehrt.
3. In der Hochrisiko-Gruppe beträgt die Wahrscheinlichkeit von befallenen Lymphknoten zirka 20 %. Das bedeutet, dass sich 80 % aller Patientinnen einer größeren Operation unterziehen müssen, die oft zu bleibenden Nebenwirkungen führt, aber ihre Prognose nicht verbessert.

Die Entfernung der Gebärmutter und Lymphknoten hat man lange mit offener Chirurgie durchgeführt. Da aber viele Studien gezeigt haben, dass sich Patientinnen nach Schlüssellochchirurgie schneller erholen, wurde in der **1. Teilarbeit** untersucht, ob man die Lymphknoten im Becken und entlang der Aorta auch mit einem Operationsroboter entfernen kann und ein wie großer Anteil von Patientinnen dazu geeignet ist. Bei der Schlüssellochchirurgie wird statt mit einem großen Bauchschnitt über Instrumente operiert, die durch 8–15 mm dicke Röhren durch

die Bauchdecke in die Bauchhöhle eingeführt werden. Die Frauenklinik in Lund, Skånes Universitätskrankenhaus, Schweden, besitzt seit 2005 einen Operationsroboter, der ein hochentwickeltes Hilfsmittel für Schlüssellochchirurgie ist. Beim Operieren sieht man dreidimensional und die Instrumente haben eine Handgelenksfunktion, was es beides bei der traditionellen Schlüssellochtechnik nicht gibt. Weiterhin wurde in der 1. Teilarbeit untersucht, wie viele Frauen nach dieser Operation lymphatische Komplikationen wie Lymphödem (Schwellung wegen angestauter Lymphe) oder Lymphzysten bekommen.

Zwischen 2010 und 2013 wurden 212 Patientinnen mit Gebärmutterkrebs, die zur Hochrisiko-Gruppe gehörten, an der Frauenklinik in Lund behandelt. Schlüssellochchirurgie mit dem Operationsroboter und Entfernung der Lymphknoten wurden in 71 % der Fälle geplant. Bei den anderen Patientinnen bestand entweder ein Verdacht auf einen weiter fortgeschrittenen Krebs, sie sollten nicht operiert werden, vertrugen keine Schlüssellochchirurgie oder keine Entfernung der Lymphknoten. Eine vollständige Entfernung der Lymphknoten im Becken und entlang der Aorta war in 70 % der geplanten Fälle möglich. Einige Operationen konnten nur eingeschränkt durchgeführt werden, weil die Patientinnen entweder übergewichtig oder die Operateure weniger erfahren waren. 14 % der Patientinnen hatten nach der Operation ein Lymphödem. Die Schlussfolgerung dieser Studie ist, dass man die Lymphknoten mit Hilfe des Operationsroboters entfernen kann, aber dass es nur an ausgewählten Zentren durchgeführt werden soll, damit die Operateure genug Erfahrung sammeln können. Es wurde diskutiert, ob ein verbesserter Operationsroboter zu besseren Ergebnissen führen könnte. Diese Annahme hat sich bestätigt, nachdem die Frauenklinik in Lund im Februar 2015 einen neuen Operationsroboter bekommen hat. Diese Daten sind jedoch noch nicht veröffentlicht.

Das Dilemma der Lymphknotenentfernung und dem daraus entstehenden Risiko auf ein Lymphödem existiert auch bei anderen Krebsarten, wie bei Haut- und Brustkrebs. Daher hat man Techniken entwickelt, diejenigen Lymphknoten zu identifizieren, wohin sich der Krebs zuerst ausbreitet. Man nennt diese Lymphknoten „Wächterlymphknoten“. Lymphknoten sind wie Perlen auf einer Kette angeordnet. Wenn der erste Lymphknoten nach dem Tumor frei von Krebs ist, sind die weiteren Lymphknoten ebenfalls nicht betroffen (Abbildung 2). Bei Brust- und Hautkrebs hat man ein Konzept entwickelt, in dem man zuerst die Wächterlymphknoten entfernt. Falls diese krebsfrei sind, muss man keine weiteren Lymphknoten entfernen. Beim Gebärmutterkrebs war diese Vorgehensweise jedoch bisher nicht möglich, unter anderem, weil die anatomischen Verhältnisse eine Herausforderung waren.

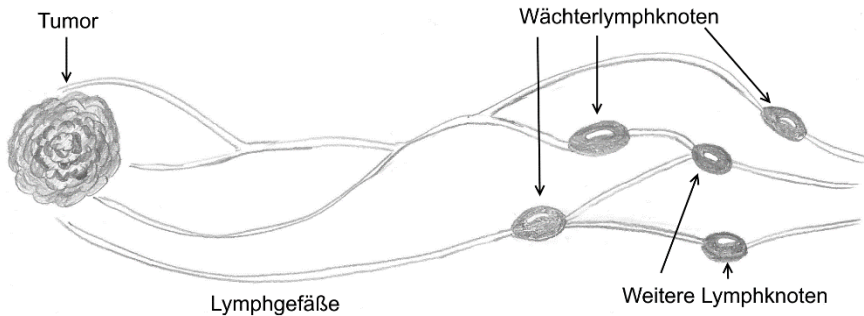


Abbildung 2
Das Prinzip der Wächterlymphknoten

Daher war das Ziel der **2. Teilarbeit**, die lymphatische Anatomie der Gebärmutter zu untersuchen, um darauf aufbauend ein Konzept zur Entfernung der Wächterlymphknoten zu entwickeln. Weiterhin wurde untersucht, ob es besser ist, einen Farbstoff zur Identifizierung der Lymphknoten in den Gebärmutterhals oder -körper zu spritzen. Es wurde ein spezieller Farbstoff (Indozyanin grün, ICG) verwendet, der nur bei der Benutzung einer speziellen Lampe sichtbar wird, die es im Operationsroboter gibt.

Der Farbstoff wurde bei 60 Frauen in den Gebärmutterhals und bei 30 Frauen in den Körper der Gebärmutter gespritzt. Der Gebärmutterhals ist leichter zu erreichen, aber es war bisher umstritten, ob der Lymphabfluss des Gebärmutterhalses identisch mit dem des Gebärmutterkörpers ist, in dem ja der Krebs wächst. Unabhängig von der Einstichstelle wurden zwei Lymphbahnen auf jeder Seite des Beckens gefunden. Die obere führt zu den großen Blutgefäßen im Becken, die untere zur Vorderseite des Kreuzbeines. Die obere Bahn ist allgemein bekannt, aber die untere Bahn, die in vielen anatomischen Untersuchungen während der vorletzten Jahrhundertwende gefunden wurde, scheint in Vergessenheit geraten zu sein. Beide Bahnen mit denselben Wächterlymphknoten wurden gefunden, egal, ob der Farbstoff in den Gebärmutterhals oder -körper eingespritzt worden war. Da es nach dem Einspritzen in den Gebärmutterhals doch wesentlich häufiger gelang, Wächterlymphknoten zu finden, war ein Ergebnis dieses Artikels, dass man den Gebärmutterhals als Einspritzstelle benutzen kann. Weiterhin sollte man einen Wächterlymphknoten in jeder Lymphbahn finden, um sicher zu sein, dass man keine Lymphknoten mit Krebsbefall übersieht.

Basierend auf diesem Wissen, wurde in der **3. Teilarbeit** ein Konzept für das Auffinden der Wächterlymphknoten beim Gebärmutterkrebs entwickelt. Nach Spritzen des Farbstoffes in den Gebärmutterhals sollte ein Wächterlymphknoten pro Lymphbahn gefunden werden. Falls das nicht gelang, sollte man den Farbstoff noch einmal spritzen, um zu sehen, ob das die Erfolgsrate erhöht. Nach der Entfernung

der Wächterlymphknoten sollten alle Lymphknoten entfernt werden, damit untersucht werden konnte, dass das Konzept keinen Krebsbefall übersieht.

In dieser Studie wurden 102 Frauen aus der Hochrisiko-Gruppe untersucht. Ein Wächterlymphknoten pro Beckenhälfte wurde bei 96 % der Patientinnen identifiziert, wenn man bei Bedarf den Farbstoff erneut spritzte. Alle Patientinnen mit befallenen Lymphknoten wären von dem Konzept erfasst worden. Es war aber schwieriger, Wächterlymphknoten in den unteren Lymphbahnen als in den oberen zu finden. Befallene Lymphknoten lagen meistens in der oberen Bahn, aber ein Drittel aller Patientinnen mit befallenen Lymphknoten hatte diese auch entlang der unteren Lymphbahn.

Das Interesse am Wächterlymphknotenkonzept ist in den letzten Jahren sehr gestiegen. Ein Grund dafür ist die Annahme, dass weniger Patientinnen nach der Entfernung der Wächterlymphknoten Probleme mit einem Lymphödem in den Beinen bekommen als nach einer kompletten Entfernung der Lymphknoten im Becken und entlang der Aorta. Laut neuesten Richtlinien darf man das Wächterlymphknotenkonzept in den USA beim Gebärmutterkrebs benutzen – obwohl es noch keine Studien gibt, die zeigen, dass sich die Annahme der geringeren Nebenwirkungen wirklich bestätigt. Daher wurde in der **4. Teilarbeit** untersucht, wie viele Patientinnen nach Entfernung der Wächterlymphknoten im Vergleich zur Entfernung aller Lymphknoten im Becken und entlang der Aorta Nebenwirkungen in Form von Lymphödemen in den Beinen entwickelten. Es wurde weiterhin untersucht, ob das Konzept operationstechnisch so sicher ist, dass man es auch bei Niedrigrisiko-Patientinnen benutzen kann, bei denen normalerweise ja keine Lymphknoten entfernt werden.

Ein Vergleich wurde zwischen 83 Patientinnen nach einer kompletten Entfernung der Lymphknoten mit 76 Patientinnen nach Entfernung der Wächterlymphknoten durchgeführt. Das Komplikationsrisiko war in beiden Gruppen niedrig. Es gab während der Entfernung der Wächterlymphknoten keine Komplikationen. Nach Entfernung aller Lymphknoten entwickelten 18 % der Patientinnen ein Lymphödem in den Beinen, nach Entfernung der Wächterlymphknoten nur 1 %, was ein statistisch signifikanter Unterschied ist. Die Schlussfolgerung dieses Artikels war, dass das Wächterlymphknotenkonzept so sicher ist, dass man es für Niedrigrisiko-Patientinnen benutzen kann. Eine laufende Studie in Lund wird Auskunft darüber geben, ob das Konzept so sicher krebsbefallene Lymphknoten findet, dass es auch für Hochrisiko-Patientinnen eingeführt werden kann. Vorläufige Ergebnisse sind vielversprechend.

Insgesamt hat diese Doktorarbeit gezeigt, dass die meisten Patientinnen mit Gebärmutterkrebs mit Hilfe des Operationsroboters operiert werden können. Basierend auf lymphatischer Anatomie wurde ein Konzept für das Auffinden der Wächterlymphknoten entwickelt, das bei Niedrigrisiko-Patientinnen benutzt

werden kann, da es operationstechnisch gesehen sicher ist und in nur 1 % aller Fälle zu einem Lymphödem führt. Dieses Konzept muss noch weiter getestet werden, bevor es auch bei Hochrisiko-Patientinnen eingeführt werden kann, bei denen bislang die Lymphknoten komplett entfernt wurden.

Abstract

Endometrial cancer is the most common gynaecological malignancy in Sweden and there is an increasing incidence because of the ageing population and increasing body mass index (BMI). With the development of robot-assisted laparoscopic surgery, new techniques have emerged to treat endometrial cancer minimally invasively and to identify sentinel lymph nodes. However, the technical progress of these techniques must be evaluated. The general aims of this thesis were to investigate the overall feasibility of robot-assisted pelvic and infrarenal para-aortic lymphadenectomy and to develop and evaluate a sentinel lymph node algorithm in endometrial cancer.

Aims of the studies

Study I: To evaluate the feasibility and lymphatic complications of robot-assisted infrarenal para-aortic and pelvic lymphadenectomy.

Study II: To describe the anatomy of uterine lymphatic drainage following cervical or fundal tracer injection to enable standardization of a pelvic sentinel lymph node concept.

Study III: To describe and evaluate an anatomically based surgical algorithm for detection of sentinel lymph nodes.

Study IV: To assess the feasibility and safety of sentinel lymph node biopsy and to compare the rate of lymphatic complications with those of full pelvic and infrarenal para-aortic lymphadenectomy.

Material and methods

Study I: All patients with high-risk endometrial cancer treated at Skåne University Hospital, Lund, Sweden, from January 2010 to August 2013 were identified ($n = 212$). All patients ($n = 140$) who were planned to receive complete robot-assisted lymphadenectomy were included, and the success rate of infrarenal para-aortic lymphadenectomy, lymphatic complications and factors associated with nodal yield were analysed.

Studies II–IV: The prospective study “Near-infrared fluorescent technique for sentinel lymph node mapping in endometrial cancer” was opened in June 2014 and is ongoing (NCT02690259). Patients with endometrial cancer intended to receive robot-assisted surgery were approached for inclusion. In low-risk endometrial cancer patients, sentinel lymph node biopsy using indocyanine green (ICG) was performed before the hysterectomy and bilateral salpingo-oophorectomy. In high-risk endometrial cancer patients, sentinel lymph node biopsy was followed by pelvic and infrarenal para-aortic lymphadenectomy and hysterectomy.

Study II: Patients operated on from June 2014 to February 2016 were included in this study. ICG was injected into the cervix uteri ($n = 60$) or uterine fundus ($n = 30$) and systematic trans- and retroperitoneal mapping of uterine lymphatic drainage was performed. Positions of the pelvic sentinel lymph nodes and lymph node metastases were compared.

Study III: High-risk endometrial cancer patients ($n = 102$) operated on between June 2014 and December 2016 and having received cervical ICG injection were analysed in this study. An algorithm for trans- and retroperitoneal identification of tracer display in the two bilateral pelvic lymphatic pathways was applied including reinjection of ICG after failure of sentinel lymph node identification in a pathway. After removal of sentinel lymph nodes, pelvic and infrarenal para-aortic lymphadenectomy was performed.

Study IV: Both high- and low-risk endometrial cancer patients ($n = 188$) operated on between June 2014 and September 2016 using either cervical or fundal ICG injection were included in this study. In low-risk patients, the lymphadenectomy was restricted to sentinel lymph node biopsy alone, and in high-risk patients, unless contraindicated, sentinel lymph node biopsy was followed by full lymphadenectomy. The effect of the extent of the lymphadenectomy on the rate of complications was evaluated.

Results

Study I: Infrarenal para-aortic lymphadenectomy was possible in 70% of women for whom full staging was intended, was restricted to the inframesenteric area in 21% of patients and was aborted or incomplete in 9% of patients. A median of 10 (range 2–39) para-aortic lymph nodes was harvested. High BMI and the surgeon's inexperience limited para-aortic nodal staging. Lower extremity lymphoedema occurred in 14% of patients.

Study II: Independent of the injection site, two consistent lymphatic pathways with pelvic sentinel lymph nodes were detected: an upper paracervical pathway with draining medial external iliac and/or obturator lymph nodes, and a lower paracervical pathway with draining presacral lymph nodes. The bilateral sentinel lymph node detection rates were 98% for cervical injection and 80% for fundal injection ($p = 0.005$).

Study III: The anatomically based algorithm including reinjection of tracer resulted in a bilateral detection rate of 96%. All 24 (23.5%) node-positive patients had at least one metastatic sentinel lymph node. One-third of node-positive patients had presacral lymph node metastases.

Study IV: No intraoperative complication was associated with the sentinel lymph node biopsy as such. Sentinel lymph node biopsy alone resulted in a lower incidence

of lower extremity lymphoedema than sentinel lymph node biopsy followed by infrarenal para-aortic and pelvic lymphadenectomy (1.3% vs 18.1%, respectively; $p = 0.0003$).

Conclusions:

Infrarenal robot-assisted para-aortic lymphadenectomy is feasible in most patients but may be limited in obese patients and by the surgeon's inexperience. The lymphatic anatomy comprising two bilateral pelvic pathways and similar positions of sentinel lymph nodes could be depicted independent of the tracer injection site. However, cervical injection was advantageous because of its higher technical success rate. Based on this knowledge, the anatomically based algorithm for sentinel lymph node detection developed using cervical ICG injection showed a high sentinel lymph node detection rate and identified all patients with lymph node metastases. Sentinel lymph node biopsy was feasible and safe, and significantly reduced the risk for lower extremity lymphoedema compared with full lymphadenectomy. Therefore, this thesis supports the implementation of sentinel lymph node biopsy in low-risk endometrial cancer patients. Further studies on sensitivity and false-negative rates in high-risk patients are warranted before introducing sentinel lymph node biopsy as the standard of care for endometrial cancer.

Abbreviations

BMI = Body mass index

CN = Copy number

CT = Computed tomography

EC = Endometrial cancer

FIGO = International Federation of Gynaecology and Obstetrics

ICG = Indocyanine green

IPP = Infundibulopelvic pathway

L1CAM = L1 cell adhesion molecule

LND = Lymphadenectomy

LNМ = Lymph node metastases

LPP = Lower paracervical pathway

LVSI = Lymphovascular space invasion

MRI = Magnetic resonance imaging

MSI = Microsatellite instability

MSS = Microsatellite stability

POLE = DNA polymerase epsilon gene

SLN = Sentinel lymph node

TNM = Tumour–node–metastasis

UPP = Upper paracervical pathway

Introduction

Endometrial cancer is the most common gynaecological malignancy in industrialized countries and its incidence is increasing [1, 2]. The prognosis is dependent on the histology and stage, the latter of which has been surgically assessed since 1988, but the indications for and therapeutic role of pelvic and para-aortic lymphadenectomy have been controversial ever since [3-5]. Given the evidence derived from two large prospective randomized trials that showed that pelvic lymphadenectomy does not play a therapeutic role in endometrial cancer, some authors do not recommend lymphadenectomy in any form [6, 7]. However, these trials have been heavily criticized for their design and because retrospective data show otherwise, there is wide variation in clinical practice [4, 8, 9].

The sentinel lymph node concept, first described by Gould et al. in 1960 for parotid cancer and by Burke et al. in 1996 for endometrial cancer, may offer a solution to this controversy about the treatment of endometrial cancer [10, 11]. However, although interest in and use of sentinel lymph node biopsy in endometrial cancer have increased over the past decade, some fundamental questions such as those relating to lymphatic anatomy and the presumably decreased incidence in lymphatic complications following sentinel lymph node biopsy, have not been addressed properly.

This thesis focused on the development, feasibility, safety and side effects of an anatomically based surgical algorithm for robot-assisted detection of sentinel lymph nodes in endometrial cancer.

Background

Endometrial cancer

Epidemiology and aetiology

Endometrial cancer, which is a tumour that originates in the endometrium, is the most common gynaecological malignancy in industrialized countries and its incidence is increasing [1, 2]. In Sweden, an incidence of 30.2 per 100 000 women has been reported and has been increasing steadily in the past decades (Figure 3) [1]. The risk factors are high body mass index (BMI), early age at menarche, nulliparity, late-onset menopause and tamoxifen use [12-15]. Lynch syndrome, also called hereditary nonpolyposis colorectal cancer, which is caused by mutations in DNA-mismatch-repair genes, is a hereditary condition with a 42–60% risk of developing endometrial cancer by age 70 years [16]. For each given birth, the use of the combined oral contraceptive pill for at least 5 years or the use a progesterone-releasing intrauterine device decreases the risk of endometrial cancer [14, 17-19]. The relationship between endometrial cancer and diabetes is controversial [20, 21].

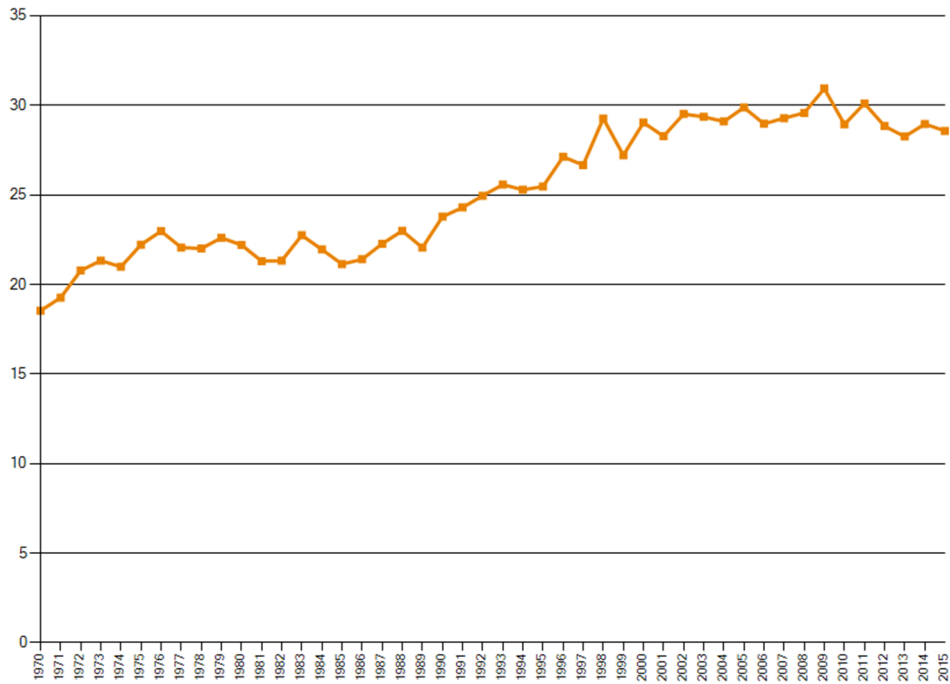


Figure 3

Incidence of endometrial cancer in Sweden (Reproduced with permission of Swedish National Board on Statistics in Cancer, homepage assessed 27 November 2017, www.socialstyrelsen.se/Statistik/statistikdatabas/).

Symptoms and diagnosis

The main symptom, postmenopausal vaginal bleeding, often occurs early, and most endometrial cancer cases are diagnosed when the disease is confined to the uterus [1]. Other symptoms can be the development of menorrhagia, haematometra, pyometra or abnormal discharge [22]. Women with postmenopausal bleeding should undergo a gynaecological examination, Pap smear and transvaginal sonography [23]. If the endometrium is found to be ≥ 5 mm or unmeasurable, endometrial biopsy and hydrosoneography should be performed to identify the presence of a non-focal or focal lesion [23, 24]. Hysteroscopy can be performed in cases of focal lesions or failed endometrial biopsy [23].

Histopathology

The landmark article by Bokhman in 1983 has led to a dualistic view of endometrial cancer [25]. Endometrial cancer was subdivided into type I, which are mostly low-grade endometrioid hormone receptor-positive tumours associated with obesity and have a good prognosis, and type II, which are non-endometrioid or high-grade tumours associated with hormone receptor loss and a poor prognosis (Table 1) [22, 25, 26]. The later literature confirmed the basic tenets of this dichotomy including the significant prognostic differences [26]. Several epithelial carcinomas of the uterine corpus have been described: endometrioid, serous, clear cell, mucinous, squamous cell and undifferentiated [27]. Endometrioid adenocarcinomas account for 75%, serous carcinomas 5–11% and clear cell carcinomas 1–5% of all epithelial tumours of the uterine corpus [27, 28].

Table 1

Dualistic classification of endometrial cancers, according to Bokhman subtype. Reproduced from Morice et al.; reprinted with kind permission of Elsevier publishers [22].

	Type I	Type II
Associated clinical features	Metabolic syndrome: obesity, hyperlipidaemia, hyperglycaemia, and increased oestrogen concentrations	None
Grade	Low	High
Hormone receptor expression	Positive	Negative
Histology	Endometrioid	Non-endometrioid (serous, clear-cell carcinoma)
Genomic stability	Diploid, frequent microsatellite instability (40%)	Aneuploid
TP53 mutation	No	Yes
Prognosis	Good (overall survival 85% at 5 years)	Poor (overall survival 55% at 5 years)

However, recent epidemiological studies and genomic characterization of endometrial cancer have made it increasingly clear that more nuanced classifications are needed to integrate the clinical, pathological and molecular data [22, 26, 27, 29]. The Cancer Genome Atlas has defined four clinically distinct endometrial cancer types based on the identification of four molecular subgroups: DNA polymerase epsilon gene (POLE) ultramutated, microsatellite instability (MSI) hypermutated, copy-number-low microsatellite stability (MSS) and copy-number-high serous-like; the first has an excellent prognosis but the fourth has a poor prognosis (Figures 4, 5) [22, 27, 29].









	<i>POLE</i> ultramutated	MSI hypermuted	Copy-number low, MSS	Copy-number high, serous-like
Mutation load				
Somatic copy number alterations load				
Histology	Endometrioid	Endometrioid	Endometrioid	Serous and endometrioid
Grade				
<i>PI3K</i> alterations				
<i>KRAS</i> mutation				
<i>TP53</i> mutation	35%	5%	1%	>90%
Prognosis	Excellent	Intermediate	Intermediate	Poor

Figure 4

Molecular and genomic heterogeneity of endometrial cancer according to the four genomic classes. Reproduced from Morice et al. 2016 with the kind permission of Elsevier publishers [22]. MSI: microsatellite instability; MSS: microsatellite stability. Light blue represents grade 1, medium blue represents grade 2, and dark blue represents grade 3.

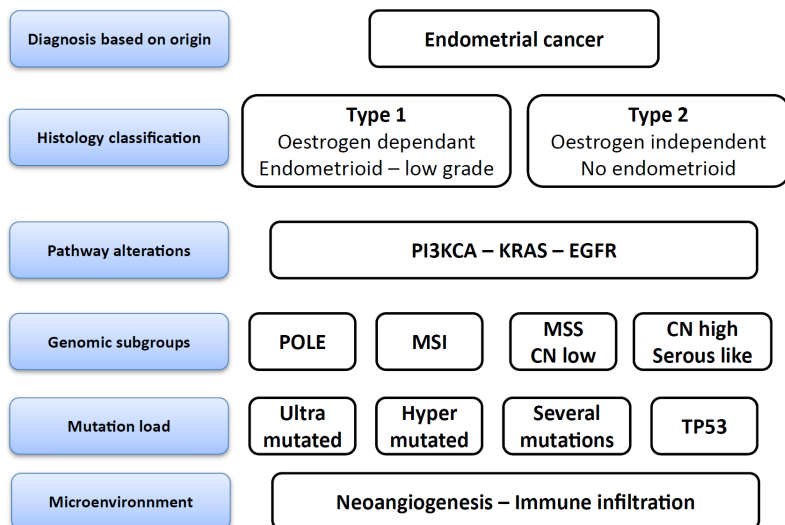


Figure 5

Evolution of the endometrial cancer classification. MSI: microsatellite instability; MSS: microsatellite stability; CN: Copy number. Reproduced from Lheureux et al. 2016, with the kind permission of Elsevier [30].

POLE is a subunit of DNA polymerase epsilon, which is involved in DNA replication and repair [29]. Inactivating mutations in this gene lead to erroneous proofreading during DNA synthesis [31]. The mutation rates and number of tumour-infiltrating lymphocytes are higher in POLE-mutated and microsatellite unstable tumours than in the two other groups of tumours [31]. The accumulation of neoantigens in these tumours is thought to lead to reaction and attack by the immune system [31]. This could explain why POLE-mutated tumours, while exhibiting more aggressive histological characteristics, seem to have a very good prognosis (Figure 6) [31].

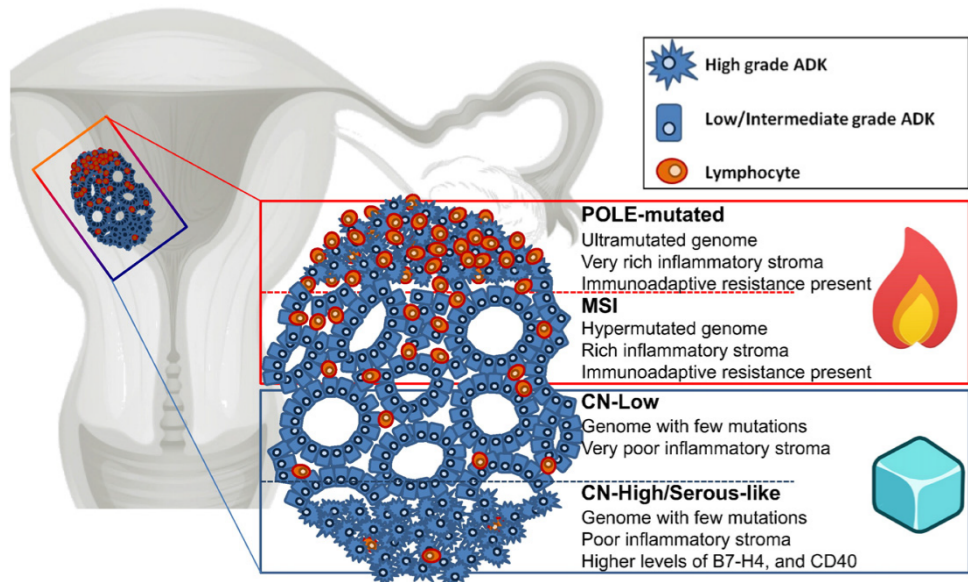


Figure 6

Graphical presentation of the types of endometrial cancer showing that those with higher mutation rates are more often infiltrated by lymphocytes and exhibit immunoadaptive resistance ("hot" tumours), whereas those with fewer mutations exhibit less inflammation ("cold" tumours). ADK: adenocarcinoma; MSI: microsatellite instability; CN: copy number. Reproduced from Piulats et al. 2017, with kind permission of Elsevier [31].

Other theories suggest that deterioration of metastasizing capability occurs because of an extremely high number of mutations or increased sensitivity to chemotherapy based on defective DNA repair [32]. However, prospective studies are needed to confirm the association between genotype and clinical behaviour because this categorization is based on retrospectively collected material and includes heterogeneously treated patients [27, 29, 33].

Preoperative risk assessment

Endometrial cancer has been surgically staged since 1988, and the stage at diagnosis is the strongest predictor of 5-year survival [3, 5, 34]. The risk of lymph node metastases is low in some patients with endometrial cancer and lymphadenectomy is associated with persisting lymphatic complications. Therefore, various recommendations have been published to distinguish between patients at low risk (“low-risk patients”), for whom it is safe to forgo lymphadenectomy because of their low risk of lymph node metastases, and at those at high risk (“high-risk patients”), who may benefit from lymphadenectomy [8, 9, 35-38]. The risk of lymph node metastases increases with increasing grade and depth of myometrial invasion (Table 2) [28].

Table 2

Relationship between histology, depth of invasion and pelvic lymph node metastases in 5121 patients with both pelvic and aortic nodal status and myometrial invasion information. Reproduced from Creasman et al. 2017 with kind permission of Elsevier [28]

Depth of invasion	Histology							
	EG1	EG2	EG3	SER	CLC	SAR	OMX	OTH
	%	%	%	%	%	%	%	%
Endometrium only	0.8	1.6	1.7	7.9	1.3	2.0	6.3	0.0
Inner half	2.0	3.9	3.9	18.3	15.5	14.4	11.8	8.3
Outer half	15.4	16.8	29.1	44.3	40.5	29.6	42.2	24.6
Serosa	42.9	50.0	67.6	66.7	70.0	58.3	60.0	47.1

E: endometrioid, G: FIGO grade, SER: serous, CLC: clear cell, SAR: carcinosarcoma, OMX: mixed, OTH: others.

Commonly used risk criteria to define a high-risk group are International Federation of Gynaecology and Obstetrics (FIGO) Grade III, FIGO stage \geq IB and/or non-endometrioid histology [8, 9, 36]. Tumour size and DNA ploidy are used more selectively [8, 39, 40]. Different definitions are used to identify high-risk patients, which has led to variations in the proportions of high-risk patients and differences in treatments internationally [8, 22, 35, 36].

Preoperatively, imaging by computed tomography (CT) and expert vaginal ultrasonography or magnetic resonance imaging (MRI) are recommended for assessing myometrial and cervical involvement [22, 36].

However, erroneous preoperative risk assessment occurs frequently. It has been reported that 15–29% of women whose preoperative endometrial biopsy shows grade 1 tumours have a higher grade at the final pathology evaluation [41, 42]. Twenty-one per cent of preoperatively presumed low-risk patients were upstaged by final histology [43]. Another point of concern is the poor interobserver

reproducibility (~60%) in the pathology diagnosis of high-risk endometrial cancer [44]. This indicates the need for molecular tools to improve the accuracy and reproducibility when diagnosing these tumours [44]. Preoperative imaging to assess myometrial invasion is correct in 74–84% of cases diagnosed using transvaginal ultrasonography and 82% diagnosed using MRI [45, 46].

Between 2010 and 2017, the guidelines for southern Sweden advocated full pelvic and infrarenal para-aortic lymphadenectomy in endometrial cancer patients with at least one of the following risk factors: Grade 3 tumours, FIGO Stage \geq IB, non-endometrioid histology or DNA non-diploidy [47]. In February 2017, new national guidelines recommended forgoing lymphadenectomy in cases of DNA non-diploidy as only risk factor [48].

Classification

Although the lymphatic anatomy had been elucidated and articles on the surgical–pathological pattern of endometrial cancer spread have been published, clinical staging classifications were used until 1971 because the spread pattern had not been evaluated in a systematic manner [35, 49–52]. Because landmark studies have shown that an appreciable number of cases of clinical stage I endometrial cancer involve disease outside the uterus, the FIGO Committee on Gynaecologic Oncology introduced surgical staging in 1988 [3, 5, 35]. Based on survival data for more than 42 000 endometrial cancer patients who underwent surgical staging, FIGO proposed a revised classification in 2009. The revised classification simplified stages I and II but subdivided stage IIIC into IIIC1 and IIIC2 based on the difference in survival between women with and without para-aortic lymph node metastases (Table 3) [49]. Although there is a tumour–node–metastasis (TNM) classification for endometrial cancer, most studies use the FIGO classification system (Table 3) [36, 40].

Table 3

FIGO and TNM classifications of endometrial cancer according to surgical and histological characteristics. Reproduced from Morice et al. with kind permission of Elsevier publishers [22].

	FIGO stage*	TNM category
Primary tumour cannot be assessed	..	TX
No evidence of primary tumour	..	T0
Carcinoma in situ	..	Tis†
Tumour confined to the corpus uteri	Stage I	T1
Tumour limited to endometrium or invades less than 50% of the myometrium	Stage IA	T1a
Tumour invades 50% or more of the myometrium	Stage IB	T1b
Tumour invades cervical stroma but does not extend beyond uterus	Stage II	T2
Tumour with local or regional extension	Stage III	T3 or N1–2, or both
Tumour involves serosa or adnexa, or both	Stage IIIA	T3a
Vaginal involvement or parametrial involvement	Stage IIIB	T3b
Regional lymph node metastasis	Stage IIIC	
Regional pelvic lymph node metastasis	Stage IIIC1	N1
Regional para-aortic lymph node metastasis with or without pelvic lymph node metastasis	Stage IIIC2	N2
Tumour invades bladder or bowel mucosa, or distant metastatic disease present (or any combination thereof)	Stage IV	
Tumour invades bladder or bowel, or both	Stage IVA	T4
Distant metastatic disease (includes inguinal lymph node, intraperitoneal disease, lung, bone, or liver)	Stage IVB	M1

TNM classification: NX (regional lymph nodes cannot be assessed), N0 (no regional lymph node metastasis), and M0 (no distant metastasis). FIGO=International Federation of Gynecology and Obstetrics. *Either G1, G2, or G3. †FIGO does not include stage 0 (Tis) in its classification.

Lymphatic anatomy

Uterine lymphatic anatomy was studied extensively in the 19th and in the first half of the 20th centuries [53–59]. At first, cadavers of women who died from puerperal fever were examined, and their pus was used as a “tracer” during the autopsy. Later, different injection techniques such as injection of quicksilver or Prussian blue were developed [53, 58, 59]. Many studies have been performed in newborns [53, 54, 58, 60]. The following lymphatic pathways have been visualized.

1. An upper paracervical pathway (also called external iliac pedicle, pre-ureteral pedicle or primary pedicle), which courses along the uterine artery and drains the external iliac and obturator lymph nodes (Figures 7–9).

2. A lower paracervical pathway (also called posterior pedicle, hypogastric pedicle or retro-ureteral pedicle), which runs along the uterine vein to the hypogastric and/or presacral area (Figures 7–9).

3. An infundibulopelvic pathway, which runs along the infundibulopelvic ligament to the para-aortic lymph nodes (Figure 8).

Some authors describe a fourth pathway, which runs through the round ligaments and terminates extrapelvically in a femoral node [61]. Often, the lymphatic drainage from the cervix uteri is described separately from that of the corpus uteri, although they have the same embryonic origin and blood supply, and anastomoses between the upper and lower paracervical pathways in the parametrium have been described [58, 60, 61]. Some authors have been unable to visualize the lower paracervical pathway. One possible reason could be that lymph nodes may atrophy with increasing age [54, 58]. Historically, there has been controversy concerning the existence of lymph nodes in the parametrium, although these have been reported by several authors [58, 60, 62].

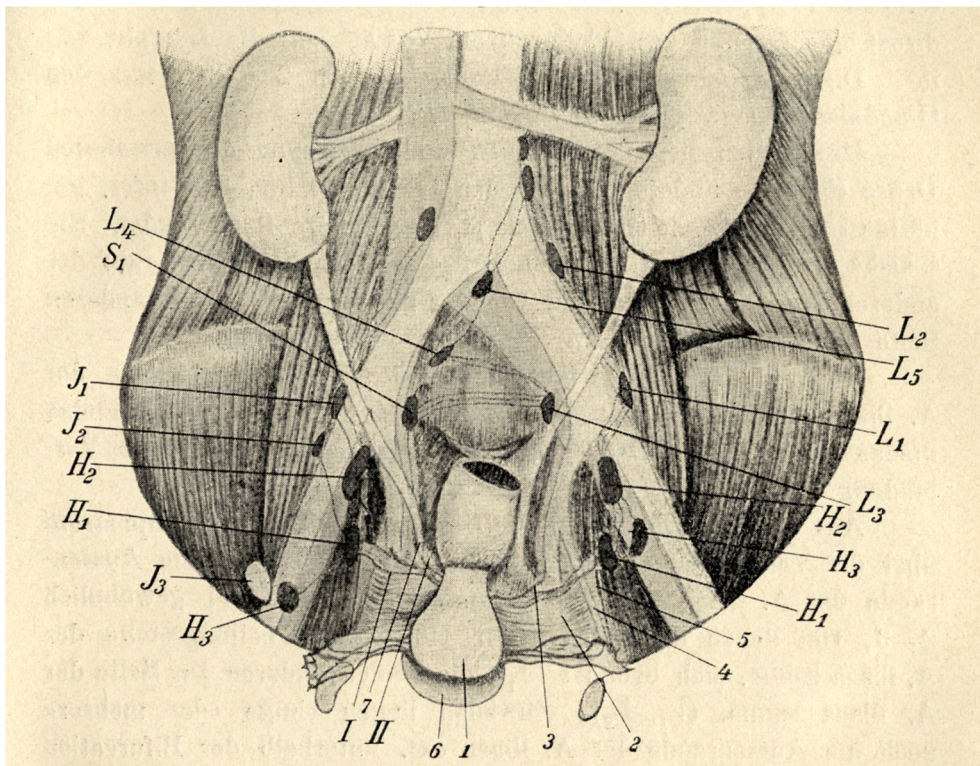


Figure 7
Uterine lymphatic anatomy as depicted by Peiser, 1898. Reproduced with kind permission from Lund University Library's collection [53].

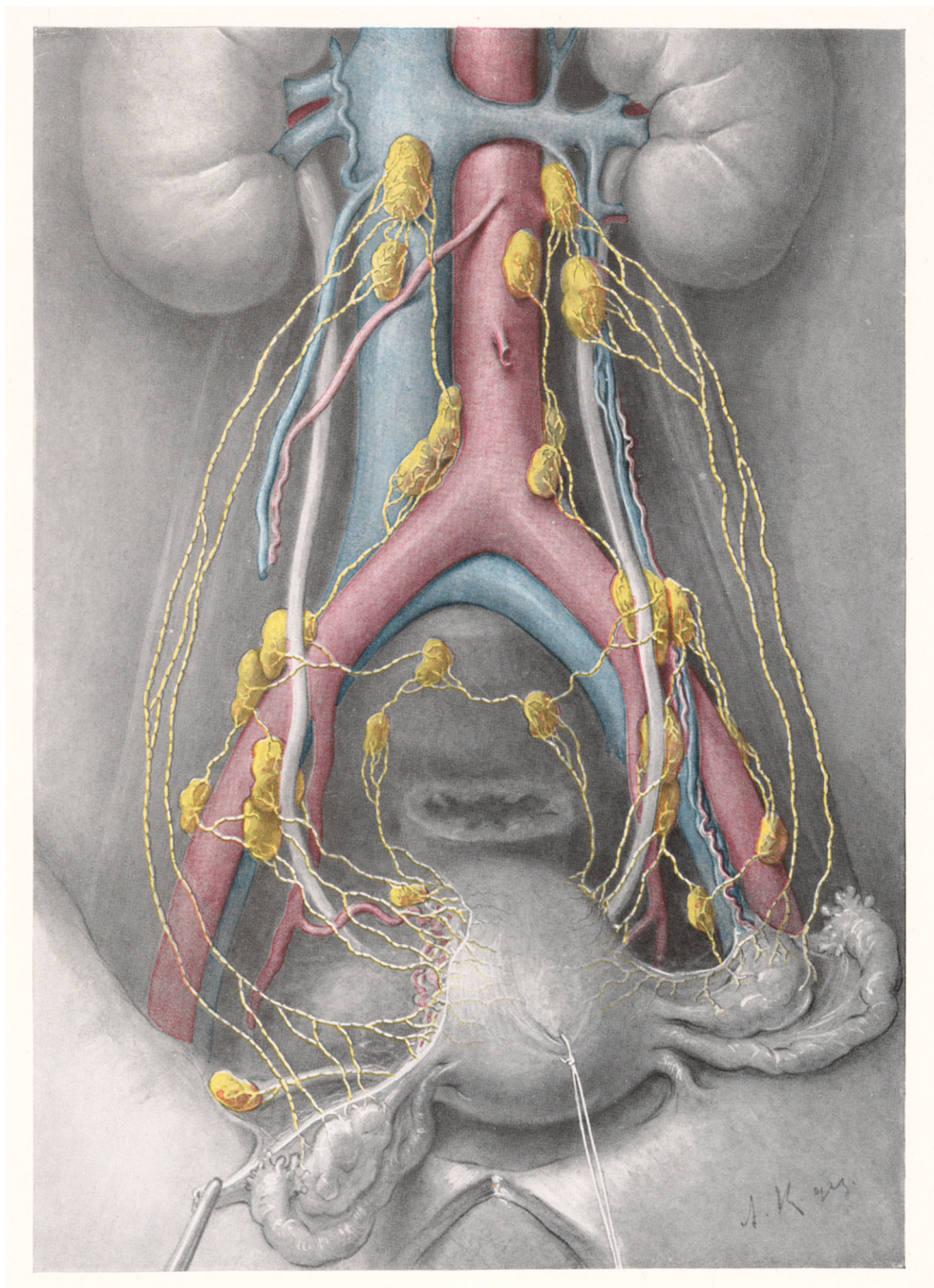


Figure 8
Uterine lymphatic anatomy according to Döderlein and Krönig in 1912 [62]. Reproduced with kind permission from Thieme Medical Publishers, Germany.

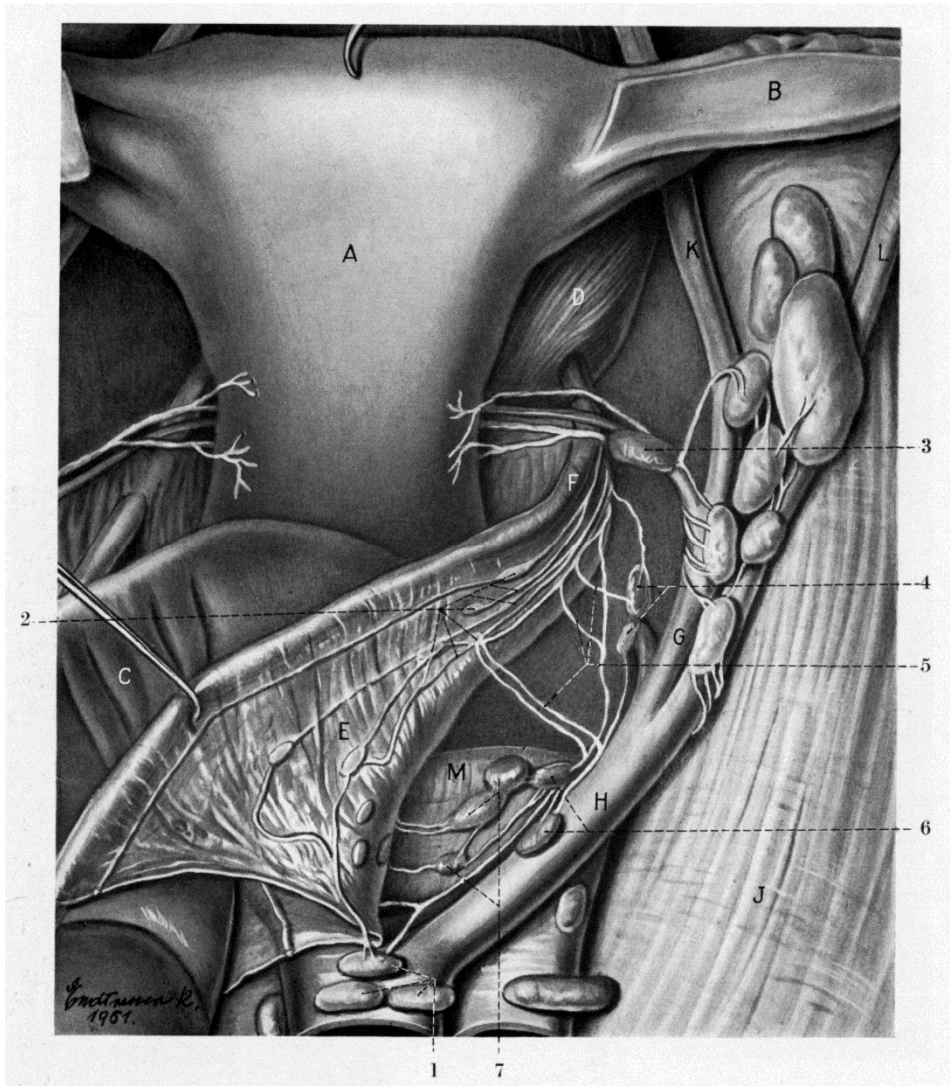


Figure 9

The lymphatics of the cervix uteri according to Reiffenstahl in 1957 [58]. Reproduced with kind permission from the author's daughter Ingrid Heiter-Reiffenstahl and Wolters Kluwer.

Routes of lymphatic spread

It is difficult to compare the lymphatic spread described by different studies because the terminology differs between authors. Some authors describe the external iliac nodes as the most commonly involved lymph nodes in endometrial cancer, whereas others describe the obturator fossa as the most affected site [34, 63, 64]. Lymph node metastases occur in 17–21% of high-risk patients [64, 65]. In the presence of pelvic lymph node metastases, about half of patients also have para-aortic lymph node metastases [28, 34, 65]. Isolated para-aortic nodes have been described in 1–3% of patients [28, 34, 65].

Surgical treatment

Total hysterectomy and bilateral salpingo-oophorectomy are the standard treatment for endometrial cancer [22, 36, 40]. Fertility-preserving therapy can be considered in selected young women of childbearing age who present with grade 1 endometrioid adenocarcinoma without signs of extrauterine disease [36, 40]. If a patient is not deemed to be suitable for primary surgery in a risk–benefit assessment, external beam radiotherapy, brachytherapy, chemotherapy or hormonal treatment can be considered [36, 40].

Traditionally, endometrial cancer surgery has been performed via laparotomy [3, 34]. With the development of laparoscopic surgery in the 1990s, randomized trials compared laparoscopy and laparotomy for the management of endometrial cancer [66, 67]. A systematic review of the safety of laparoscopy versus laparotomy showed that laparoscopy was similar in terms of intraoperative complications but resulted in fewer postoperative complications [68]. The introduction of laparoscopy did not reduce survival [67, 69, 70].

Conventional laparoscopy has severe limitations. For example, one trial involving randomizing between laparotomy and laparoscopy showed that conversion to laparotomy was necessary in 25.8% of patients, and more than half of these conversions resulted from poor exposure [66]. Patients with a BMI >40 kg/m² had a conversion rate of 57.1%, which indicated the need for further technical development. This was met by the introduction of the da Vinci[®] Surgical System (Intuitive Surgical Inc., Sunnyvale, CA, U.S.A.), which received U.S. Food and Drug Administration approval for gynaecological surgery in 2005. The system provides instruments with a wrist function, movement downgrading and a stable three-dimensional view that can be steered by the surgeon sitting in a comfortable position.

A recent review comparing robot-assisted hysterectomy to laparoscopic or abdominal hysterectomy for endometrial cancer showed a shorter length of stay,

less estimated blood loss and lower complication and readmission rates [71]. No significant differences were found in the number of retrieved lymph nodes or overall survival [71]. The conversion rate to laparotomy has been reported to be lower in robot-assisted than in conventional laparoscopy [71, 72]. Another review that compared robot-assisted to conventional laparoscopy found fewer overall complications but higher costs for patients treated with robot-assisted laparoscopy [72]. Emerging data on robot-assisted hysterectomy on obese patients has shown low conversion and complication rates [73].

Lymph nodes are usually the first place of dissemination of endometrial cancer, and accurate non-invasive tests are lacking, which is why surgical staging was introduced in 1988 [3, 35]. Since then, there has been controversy about the indications for and extent of lymphadenectomy [4, 6, 7, 74]. Although lymphadenectomy provides important information about the need for postoperative treatment, it also increases surgical morbidity and persistent side effects such as lymphatic complications [37, 38]. Different models have been developed to identify patients at risk for lymph node metastases [8, 9].

Prospective randomized trials to assess the therapeutic role of lymphadenectomy have shown no survival advantage but increased morbidity [6, 7]. The design of these trials was heavily criticized because systematic para-aortic lymphadenectomy was not part of the prescribed protocol but was performed arbitrarily in only some patients [4, 74]. In one of these trials, the number of lymph nodes removed was low in the lymphadenectomy group; by contrast, 5% of patients who did not receive lymphadenectomy had lymph nodes removed with a substantial number of lymph node metastases [4, 7, 74]. The two randomized arms were not equal in risk factors: the lymphadenectomy arm had more high-risk patients and patients with lymph node metastases could be further randomized to receive no adjuvant treatment [4, 7]. Moreover, in both studies, many included patients had a low risk for lymph node metastases and would therefore not benefit from lymphadenectomy [4, 75]. In the Italian study, the adjuvant treatment was different between the arms treated with or without lymphadenectomy [6].

By contrast, a retrospective study reported improved survival for patients following systematic lymphadenectomy over those who had limited or no sampling performed [76]. Another retrospective study found that lymphadenectomy improved survival of patients with stage I grade 3 and more advanced endometrioid uterine cancers [75]. In a retrospective cohort analysis, compared with pelvic lymphadenectomy, pelvic and para-aortic lymphadenectomy reduced the risk of death in patients with intermediate or high risk [77]. A prospective randomized trial to confirm the superiority of pelvic and para-aortic lymphadenectomy to pelvic lymphadenectomy alone has now been launched [78].

Lymphadenectomy is performed to a varying extent internationally. Although some authors perform only inframesenteric para-aortic lymphadenectomy, others perform dissection to the left renal vein because it has been shown that isolated lymph node metastases can occur in the supramesenteric para-aortic area [34, 65, 79]. According to the U.S. National Comprehensive Cancer Network guidelines, pelvic lymphadenectomy is the removal from the external iliac, internal iliac, obturator and common iliac basins, although other centres also remove presacral nodes, as proposed by FIGO [6, 40, 63, 65, 77, 80, 81].

Adjuvant treatment

Different modalities of adjuvant treatment are used, including chemotherapy, external radiotherapy, brachytherapy and combinations thereof [36, 40, 47, 48]. Stage, high FIGO grade and non-endometrioid histology are common risk factors used to identify high-risk patients in need of adjuvant therapy. Other risk factors, such as lymphovascular space invasion (LVSI), are considered more selectively. Tumour size is used in the U.S. guidelines only, whereas the Swedish guidelines also used DNA ploidy until January 2017 [40, 47]. An overview of the different adjuvant treatment recommendations in Sweden, Europe and the U.S.A. is shown in Table 4 [36, 40, 47, 48]. No international consensus exists.

Patients with advanced or recurrent endometrial cancer and endometrioid histology can be treated with hormonal therapy if they are ineligible for surgery, local radiotherapy or chemotherapy [22, 36].

The development of therapies targeted at the molecular pathways vital to cancer cell survival including angiogenesis, DNA repair and apoptosis, could further enhance the prognosis for endometrial cancer patients. Bevacizumab, the most commonly studied anti-angiogenic agent, has shown promising results in recurrent or persistent endometrial cancer patients [30, 81]. Cell growth and apoptosis are regulated by the mammalian target of rapamycin (mTOR), and inhibition of mTOR has led to stable disease in patients with metastatic or recurrent endometrial cancer [81].

Table 4

Overview of postoperative treatment according to Swedish, European and U.S. guidelines [36, 40, 47, 48]

Endometrial cancer stage and type	Swedish guidelines 2017 to ongoing [48]	Swedish guidelines 2010–2017 [47]	ESMO–ESGO–ESTRO* guidelines [36]	US National Comprehensive Cancer Network guidelines [40]
Stage IA, endometrioid, FIGO grade 1 or 2	Surveillance	Surveillance	Surveillance, or, if LVSI positive, brachytherapy. If no lymphadenectomy is performed and LVSI positive, external radiotherapy	Surveillance or brachytherapy. If adverse risk factor (LVSI, tumour size, lower uterine segment involvement) present, and grade 2, consider external radiotherapy
Stage IA, endometrioid, FIGO grade 3	Surveillance	Surveillance	Surveillance, or, if LVSI positive, brachytherapy. If no lymphadenectomy performed, radiotherapy if LVSI positive. If LVSI negative brachytherapy	Observation if no adverse risk factor, or brachytherapy and/or external radiotherapy ± chemotherapy
Stage IB, endometrioid, FIGO grade 1 or 2	Surveillance	Surveillance	Brachytherapy or surveillance	Observation or brachytherapy and/or external radiotherapy
Stage IB, endometrioid, FIGO grade 3, pelvic and infrarenal para-aortic lymphadenectomy performed	Surveillance	4 cycles of carboplatin and paclitaxel	Consider external radiotherapy or brachytherapy, adjuvant chemotherapy is under investigation	Brachytherapy and/or radiotherapy ± chemotherapy
Stage IB, endometrioid, FIGO grade 3, pelvic and infrarenal para-aortic lymphadenectomy not performed	Restaging if possible, otherwise 4 cycles of carboplatin and paclitaxel and pelvic external radiotherapy 45–46 Gy/23–25 fractions	4 cycles of carboplatin and paclitaxel and pelvic external radiotherapy 46 Gy/23 fractions	External pelvic radiotherapy. Sequential chemotherapy may be considered. More evidence to giving both modalities combined than either alone	Restaging if possible, brachytherapy and/or radiotherapy ± chemotherapy
Stage I, non-endometrioid, pelvic and infrarenal para-aortic lymphadenectomy performed	4 cycles of carboplatin and paclitaxel	4 cycles of carboplatin and paclitaxel	Consider chemotherapy, consider vaginal brachytherapy if stage IA and LVSI negative. Consider additional external radiotherapy in stage IB	Stage IA surveillance or chemotherapy ± brachytherapy or radiotherapy ± brachytherapy All other stages: Chemotherapy ± radiotherapy ± brachytherapy
Stage I, non-endometrioid, pelvic and infrarenal para-aortic lymphadenectomy not performed	Restaging if possible, followed by 4 cycles of carboplatin and paclitaxel, otherwise 4 cycles of carboplatin and paclitaxel and pelvic external radiotherapy 45–46 Gy/23–25 fractions	4 cycles of carboplatin and paclitaxel and pelvic external radiotherapy 46 Gy/23 fractions	Restaging if possible, consider chemotherapy, consider vaginal brachytherapy if stage IA and LVSI negative. Consider additional external radiotherapy in stage IB	Restaging if possible, chemotherapy ± brachytherapy (preferred in stage IA) or radiotherapy ± brachytherapy
Stage II, endometrioid, FIGO grade 1 or 2, pelvic and infrarenal para-aortic lymphadenectomy performed	Surveillance	4 cycles of carboplatin and paclitaxel and brachytherapy 10 Gy/2 fractions	Brachytherapy if LVSI negative. External radiotherapy, consider brachytherapy boost if LVSI positive	Brachytherapy and/or radiotherapy

*ESMO: European Society for Medical Oncology, ESGO: European Society of Gynaecological Oncology, ESTRO: European Society for Radiotherapy & Oncology

Table 4 (continued)

Overview of postoperative treatment according to Swedish, European and U.S. guidelines [36, 40, 47, 48]

Endometrial cancer stage and type	Swedish guidelines 2017 to ongoing [48]	Swedish guidelines 2010–2017 [47]	ESMO–ESGO–ESTRO* guidelines [36]	US National Comprehensive Cancer Network guidelines [40]
Stage II, endometrioid, FIGO grade 1 or 2, pelvic and infrarenal para-aortic lymphadenectomy not performed	Restaging if possible, otherwise 4 cycles of carboplatin and paclitaxel and pelvic external radiotherapy 45–46 Gy/23–25 fractions	4 cycles of carboplatin and paclitaxel, pelvic external radiotherapy 46 Gy/23 fractions and brachytherapy 12.5 Gy/5 fractions	External radiotherapy; consider brachytherapy boost If LVSI positive, consider sequential adjuvant chemotherapy	Restaging if possible, chemotherapy ± radiotherapy ± brachytherapy
Stage II, endometrioid, either myometrial invasion >50% or FIGO grade 3, pelvic and infrarenal para-aortic lymphadenectomy performed	Surveillance	4 cycles of carboplatin and paclitaxel, and brachytherapy 10 Gy/2 fractions	External radiotherapy; consider brachytherapy. Chemotherapy is under investigation	Radiotherapy ± brachytherapy ± chemotherapy
Stage II, endometrioid, myometrial invasion >50% and FIGO grade 3, pelvic and infrarenal para-aortic lymphadenectomy performed	4 cycles of carboplatin and paclitaxel	4 cycles of carboplatin and paclitaxel, and brachytherapy 10 Gy/2 fractions	External radiotherapy; consider brachytherapy. Chemotherapy is under investigation	Radiotherapy ± brachytherapy ± chemotherapy
Stage II, non-endometrioid, pelvic and infrarenal para-aortic lymphadenectomy performed	4 cycles of carboplatin and paclitaxel	4 cycles of carboplatin and paclitaxel, and brachytherapy 10 Gy/2 fractions	Chemotherapy; consider radiotherapy	Chemotherapy ± radiotherapy ± brachytherapy
Stage II, non-endometrioid, pelvic and infrarenal para-aortic lymphadenectomy not performed	Restaging if possible, followed by 4 cycles of carboplatin and paclitaxel, otherwise 4 cycles of carboplatin and paclitaxel and pelvic external radiotherapy 45–46 Gy/23–25 fractions	4 cycles of carboplatin and paclitaxel, pelvic external radiotherapy 46 Gy/23 fractions and brachytherapy 12.5 Gy/5 fractions	Restaging if possible; consider chemotherapy and radiotherapy	Restaging if possible, chemotherapy ± radiotherapy ± brachytherapy
Stage IIIA, pelvic and infrarenal para-aortic lymphadenectomy performed	4 cycles of carboplatin and paclitaxel	4 cycles of carboplatin and paclitaxel, and pelvic external radiotherapy 46 Gy/23 fractions	Chemotherapy; consider radiotherapy	Chemotherapy and/or radiotherapy ± brachytherapy
Stage IIIA, pelvic and infrarenal para-aortic lymphadenectomy not performed	Restaging if possible, followed by 4 cycles of carboplatin and paclitaxel, otherwise 4 cycles of carboplatin and paclitaxel and consider pelvic external radiotherapy 45–46 Gy/23–25 fractions	4 cycles of carboplatin and paclitaxel, and pelvic external radiotherapy 46 Gy/23 fractions	Chemotherapy; consider radiotherapy	Consider restaging, otherwise chemotherapy and/or radiotherapy ± brachytherapy
Stage IIIB, pelvic and infrarenal para-aortic lymphadenectomy performed	6 cycles of carboplatin and paclitaxel, and pelvic external radiotherapy 45–46 Gy/23–25 fractions or brachytherapy if only vaginal engagement	4 cycles of carboplatin and paclitaxel, and pelvic external radiotherapy 46 Gy/23 fractions; if vaginal spread, brachytherapy 12.5 Gy/5 fractions	Chemotherapy; consider radiotherapy	Chemotherapy ± radiotherapy ± brachytherapy

Table 4 (continued)

Overview of postoperative treatment according to Swedish, European and U.S. guidelines [36, 40, 47, 48]

Endometrial cancer stage and type	Swedish guidelines 2017 to ongoing [48]	Swedish guidelines 2010–2017 [47]	ESMO–ESGO–ESTRO* guidelines [36]	US National Comprehensive Cancer Network guidelines [40]
Stage IIIB, pelvic and infrarenal para-aortic lymphadenectomy not performed	Restaging if possible, otherwise 4–6 cycles of carboplatin and paclitaxel, and pelvic external radiotherapy 45–46 Gy/23–25 fractions	4 cycles of carboplatin and paclitaxel, and pelvic external radiotherapy 46 Gy/23 fractions; if vaginal spread, brachytherapy 12.5 Gy/5 fractions	Chemotherapy; consider radiotherapy	Consider restaging, otherwise chemotherapy ± radiotherapy ± brachytherapy
Stage IIIC1	4–6 cycles of carboplatin and paclitaxel, and consider pelvic external radiotherapy 45–46 Gy/23–25 fractions	4 cycles of carboplatin and paclitaxel, and pelvic external radiotherapy 46 Gy/23 fractions, consider including the para-aortic area	Chemotherapy; consider radiotherapy	Chemotherapy and/or radiotherapy ± brachytherapy
Stage IIIC2	4–6 cycles of carboplatin and paclitaxel, and consider external radiotherapy 45–46 Gy/23–25 fractions including the para-aortic area	4 cycles of carboplatin and paclitaxel, and pelvic external radiotherapy 46 Gy/23 fractions, consider including the para-aortic area	Chemotherapy; consider extended field radiotherapy	Chemotherapy and/or radiotherapy ± brachytherapy
Stage IV and residual known tumour in stage III	Individual assessment if radiotherapy, chemotherapy or hormonal treatment	Individual assessment if radiotherapy, chemotherapy or hormonal treatment	Individual assessment if radiotherapy, chemotherapy or hormonal treatment	Chemotherapy ± radiotherapy ± brachytherapy

Lymphatic complications

Although lymphatic staging for endometrial cancer has been recommended for high-risk patients since 1988, most studies of lymphatic complications have been published in the past decade [3, 5, 37, 38, 82–97]. The described complications are lower extremity lymphoedema, lymphocele formation, truncal/genital lymphoedema and chylous ascites [37, 38, 83–98].

Lower extremity lymphoedema

Lower extremity lymphoedema is the most common lymphatic complication with a reported incidence after surgical treatment of endometrial cancer ranging from 0% to 50% [82, 99]. The wide variation in findings reflects the lack of generally accepted standardized terminology for the assessment of lower extremity lymphoedema [37]. Swelling of the limb is caused by accumulation of excess water, plasma proteins, blood cells and cell products in the extracellular space because of insufficient transportation capacity of the lymphatic system [100].

Cheville et al. proposed a grading system of limb oedema with four grades: Grade 1 is a 5–10% inter-limb discrepancy in volume or circumference; grade 2, >10% to 30% inter-limb discrepancy; grade 3, >30% discrepancy; and grade 4, progression

to malignancy [101]. The International Society of Lymphology published an updated consensus for the diagnosis and treatment of peripheral lymphoedema in 2016 and also described four stages: Stage 0 is a latent or subclinical condition in which swelling is not yet evident despite impaired lymph transport [100]. Stage I represents the early accumulation of fluid high in protein content that subsides with leg elevation. Limb elevation rarely reduces the tissue swelling in stage II. Stage III represents lymphostatic elephantiasis. Simple volume differences help in the assessment of functional severity as minimal ($>5\%$ to $<20\%$), moderate (20–40%) and severe ($>40\%$) increase in volume difference. Because it is easily measured and inexpensive, the volume difference is most often assessed by circumferential measurement of the limb, but water displacement volumetry is also used [100].

The first study of morbidity after lymphadenectomy found no patients with lower extremity lymphoedema [82]. However, several more recent studies have reported the prevalence of lower extremity lymphoedema following endometrial cancer treatment [87, 90, 93]. A prospective pilot study that included baseline data reported an incidence of 12.8% when lower extremity lymphoedema was defined as a 20% increase in leg circumference but no difference in the incidence of lower extremity lymphoedema between patients treated with laparoscopy or laparotomy [90]. Another prospective study found a 42.4% cumulative incidence of postoperatively new measured lymphoedema and 44.4% incidence of self-reported 2 years postoperatively [93]. Yost et al. used a validated 13-item lymphoedema screening questionnaire and found that the attributable risk of developing lower extremity lymphoedema was 23% for patients who underwent lymphadenectomy compared with hysterectomy alone [87]. Using patient questionnaires, Tanaka found incidence rates of 50.0% and 27.5% for patients treated with closure versus non-closure of the peritoneum, respectively, and suggested leaving the retroperitoneum open [99]. A retrospective study showed an incidence of 12.7% of lower extremity lymphoedema following robot-assisted staging for endometrial cancer [86].

Lower extremity lymphoedema is associated with loss of quality of life, decreased physical activity and unmet supportive care needs [87, 102, 103]. Several risk factors for the development of lower extremity lymphoedema have been discussed. An increasing risk of lower extremity lymphoedema with an increased number of lymph nodes removed has been described, but the critical number varies between 10 and 31 lymph nodes [83, 88]. One reason for the varying number may be the lack of a standardization for counting of lymph nodes by the pathologist [104]. Another risk factor for the development of lower extremity lymphoedema is removal of the circumflex iliac lymph node [88, 105]. The use of radiotherapy may also be associated with an increased risk of lower extremity lymphoedema, although some studies have not found an increased risk [7, 83, 88, 99]. A recent review article on lymphoedema noted that more prospective longitudinal trials are needed to clearly

identify the risk factors for lower extremity lymphoedema following endometrial cancer treatment [37].

Treatment of lower extremity lymphoedema is classified as conservative and operative methods. Long-standing experience shows that combined physical therapy, including skin care, light manual massage, muscle pumping exercises and compression devices, is often successful [100]. Different operative methods, such as microsurgery, vascularized lymph node transplantation and liposuction, have been described, but no randomized studies are available [100]. In addition, many centres use a combination of conservative and operative methods, which makes it difficult to evaluate individual treatment effects [100]. A recent prospective study found that 150 minutes or more of moderate-intensity physical activity each week decreased the odds of developing lower extremity lymphoedema [93].

Lymphocele formation

Lymphoceles, or lymphocysts, are a circumscribed collection of lymphatic fluid in the retroperitoneal space and can occur both in the pelvic and para-aortic region following lymphadenectomy [38]. Most often, they represent incidental findings without clinical significance and usually resolve spontaneously [38]. Compression of the surrounding organs can lead to leg oedema, deep vein thrombosis and obstructive uropathy [38]. The most feared complication is infection leading to sepsis [38].

Cheville et al. grade a lymphocele as grade 1 if it is asymptomatic and is a clinical or radiographic finding only; grade 2 if medical intervention is indicated and grade 3 if interventional radiology or operative intervention is necessary [101]. Despite this proposed grading, different definitions of lymphoceles are used in the literature [38, 85, 86, 96].

Incidence rates of lymphoceles of 15.4% for laparotomy and 1.4% for laparoscopy have been reported following pelvic lymphadenectomy [38]. The largest prospective trial reported incidence rates of 9.4% for asymptomatic lymphoceles and 4.6% for symptomatic lymphoceles in patients with endometrial cancer, and that laparotomy increased the incidence of both asymptomatic and symptomatic lymphoceles [96]. That study did not report the incidence rates for cancer patients with endometrial cancer classified according to operative method [96]. Robot-assisted staging was associated with incidence rates of 4.2% for asymptomatic and 1.6% for symptomatic lymphoceles [86]. In patients who develop infection or other symptoms, non-invasive percutaneous evacuation and drainage under ultrasound or CT guidance and antibiotic prophylaxis are simple methods with a success rate of 90–100% when repeated; this option is preferable to operative treatment, if possible [96].

Truncal/genital lymphoedema

Following pelvic and/or para-aortic lymphadenectomy, swelling of the truncal and/or genital region can occur. It is often transient and can be treated conservatively [93]. According to Cheville et al., a “swelling or obscuration of anatomic architecture on close inspection and/or pitting oedema” is a grade 1 truncal/genital lymphoedema [101]. Grade 2 comprises readily apparent obscuration of anatomic architecture and grade 3 comprises lymphorrhea and/or gross deviation from the normal anatomic contour. Although this swelling is often described by patients during the first postoperative weeks, few studies have focused on this lymphatic complication and the true incidence is unknown [98, 106, 107]. The treatment for genital lymphoedema is challenging because decongestive therapies, the treatment of choice for lower extremity lymphoedema, are difficult to apply given the complex structure of the genitalia. Lymphaticovenular anastomoses and laser CO₂ treatment have been reported to have satisfactory results [98, 106].

Chylous ascites

Following lymphadenectomy, milky-appearing fluid with high levels of triglycerides can accumulate in the peritoneal cavity, a condition called chylous ascites in contrast to lymphatic ascites in which the fluid is straw-coloured or clear [108, 109]. Common symptoms are abdominal distension, nausea, vomiting, chylous fluid from abdominal drains and a milky-appearing discharge from the vagina [109, 110]. An incidence of 2–9% has been described after gynaecological staging procedures [109, 110]. Conservative treatment should be attempted, including a low-fat diet with median-chain triglycerides to decrease the intestinal lymphatic flow and triglyceride transport, and consequently to prevent lymph and triglyceride accumulation [97]. If necessary, the nutritional and metabolic impairments caused by chylous ascites can be restored with total parenteral nutrition [97]. Paracentesis should be performed only if necessitated by serious abdominal or respiratory symptoms [97]. Octreotide therapy can be added for patients with persistent chylous ascites and has a good success rate [97, 109, 111]. In patients for whom the above-mentioned therapy options fail, lymphoscintigraphy to localize the leak site followed by imaging-guided sclerotherapy or surgical repair is recommended [97, 110].

Prognosis

Endometrial cancer usually gives early symptoms in the form of postmenopausal bleeding, and over 80% of such cancers are diagnosed in stage I [36]. The overall 5-year survival rate for endometrial cancer is over 80% and the 10-year survival rate is 78% [35, 112, 113]. The most important factor to prognosis is the stage at diagnosis [114]. The survival rates for each stage over time are shown in Figure 10.

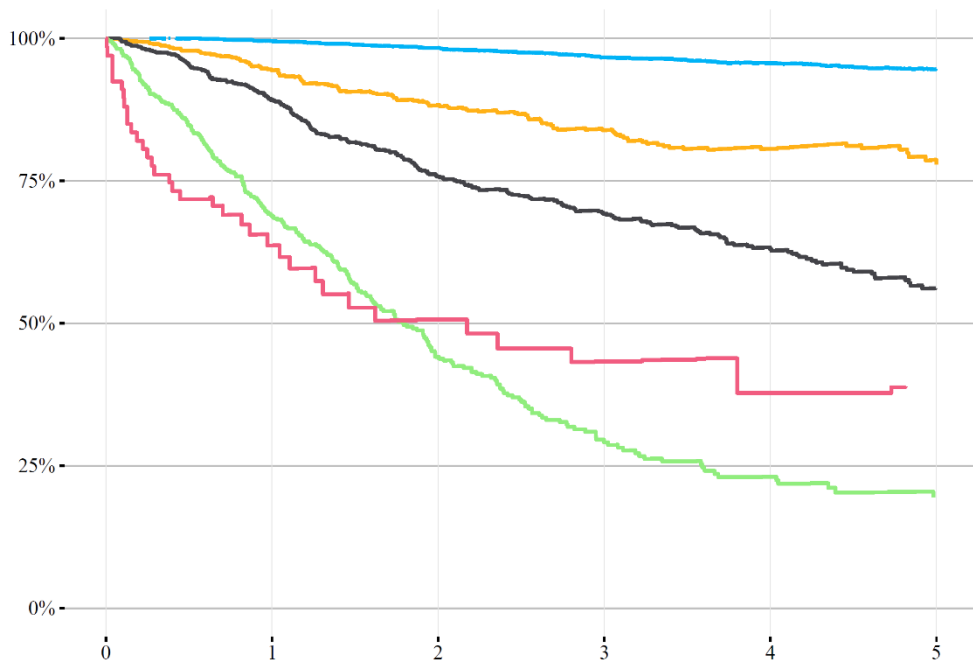


Figure 10

Survival in years in relation to stage for women with endometrial cancer diagnosed in 2010–2015 in Sweden [115]. Blue: FIGO stage I, orange: FIGO stage II, black: FIGO stage III, green: FIGO stage IV, red: FIGO stage not specified.

Other important prognostic factors are histology and tumour grade (Figures 11, 12) [114]. Endometrioid adenocarcinoma has a better prognosis than adenocarcinoma of non-endometrioid histology (Figure 11) [114]. High-grade endometrioid adenocarcinoma has a worse prognosis than low- or intermediate-grade endometrioid adenocarcinoma (Figure 12) [114]. Aneuploidy has also been shown to be associated with a higher risk of cancer-specific death [114].

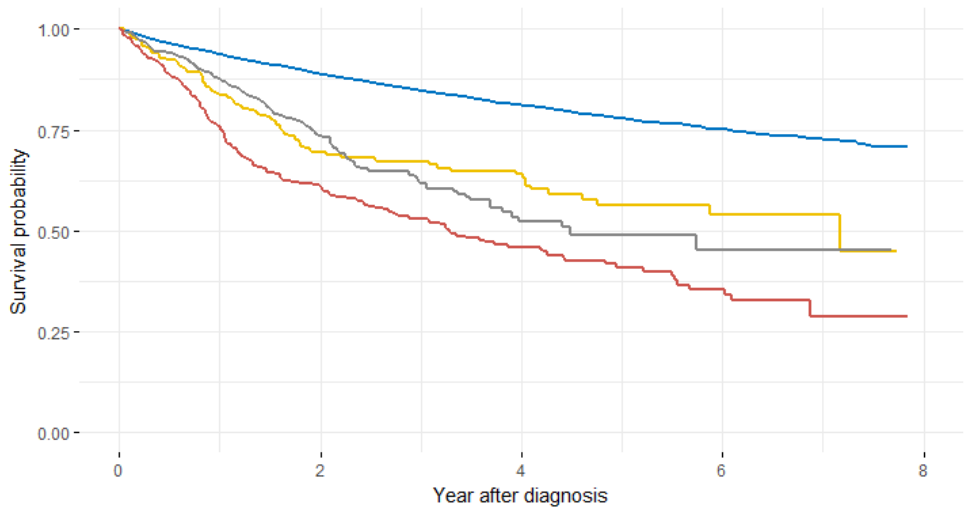


Figure 11

Survival probability in relation to histology for women with endometrial cancer diagnosed in 2010–2017 in Southern Sweden [Data from Regional Cancer Centre South, Sweden. www.cancercentrum.se/syd]. Blue: endometrioid adenocarcinoma, yellow: clear cell, grey: serous, red: carcinosarcoma.

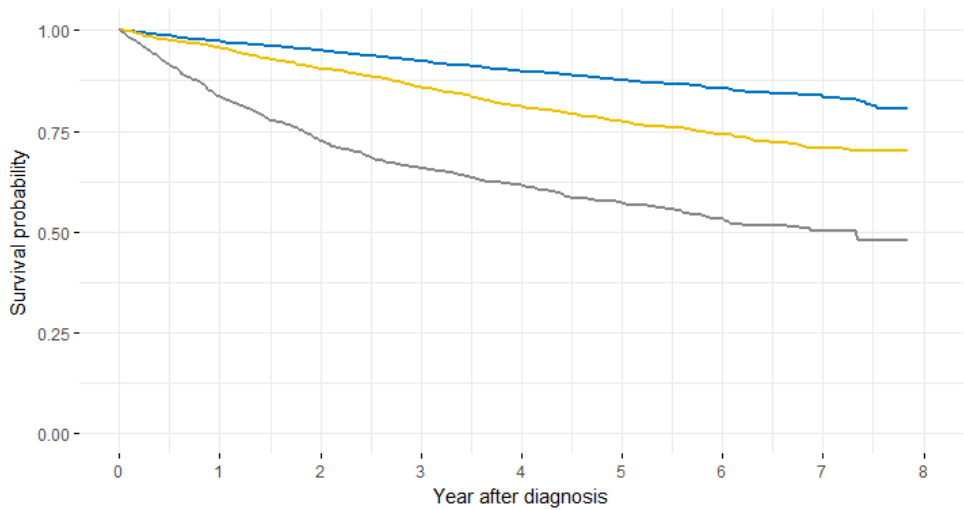


Figure 12

Survival probability in relation to FIGO grade for women with endometrioid adenocarcinoma diagnosed in 2010–2017 in Southern Sweden [Data from Regional Cancer Centre South, Sweden. www.cancercentrum.se/syd]. Blue: FIGO grade 1 endometrioid adenocarcinoma, yellow: grade 2, grey: grade 3.

LVSI has emerged as another prognostic factor for distant metastases, pelvic regional recurrence and overall survival [116, 117]. However, an international consensus on its categorization is lacking, and different definitions of LVSI are used. The expression LVSI can refer to both invasion of lymphatic and blood vessels, and the site is rarely stated. Although some authors distinguish only between the presence and absence of LVSI, others use a three-tiered classification according to the extent of invasion [118-120]. A high interobserver incongruence in the assessment of LVSI has been reported [116]. Although conceptually logical, an international consensus on how to categorize LVSI and reproducible diagnostics is lacking but is needed [121].

In recent years, scientific interest has focused on predictive biomarkers such as L1-cell adhesion molecule (L1CAM) and stathmin [117, 122]. L1CAM drives tumour cell proliferation, invasion and motility, and acts as a pro-angiogenetic factor [117, 123]. Immunohistochemistry is used to identify L1CAM-positive cells [117, 124]. Using criteria published by Zeimet et al., many authors consider L1CAM to be positive if $\geq 10\%$ of tumour cells are positive [117, 123-125]. However, another definition uses “high” and “low” expression defined according to the median value of L1CAM expression [126]. According to the former definition, 6–10% of endometrioid adenocarcinomas are L1CAM positive [117, 127, 128]. By contrast, 55–75% of non-endometrioid adenocarcinomas are described as L1CAM positive [124, 125, 127, 128]. It was suggested in 2013 in a series of over 1000 endometrial cancer patients that patients with L1CAM-positive tumours have a worse clinical outcome [124].

Several retrospective studies have confirmed L1CAM as an indicator of the risk of distant recurrence and poor prognosis in patients with endometrial carcinomas [117, 123, 126, 127]. However, although some studies show L1CAM to be predictive in low-risk endometrial cancer graded according to the recent European guidelines, others suggest that the addition of L1CAM to the risk stratification improves the triage of patients in intermediate- and high-risk advanced metastatic groups [117, 123]. In another study, the expression of L1CAM was a strong predictor of poor outcome in patients with endometrioid adenocarcinoma but not those with non-endometrioid adenocarcinoma [128]. L1CAM positivity may help the clinician choose the adjuvant treatment because L1CAM-positive cancer cells can exhibit resistance to chemotherapy, and L1CAM antibodies are under investigation [127, 128]. The prognostic value and feasibility of serum L1CAM as a predictive biomarker and the mechanism by which this molecule is associated with metastases is unclear, but a Finnish study in 40 patients did not show that soluble L1CAM correlates with L1CAM expression in tumours [125, 126].

Stathmin, a regulator of microtubule dynamics, plays an important role in the cell cycle and is involved in cell motility, migration and regulation of apoptosis [122,

129]. In a study that included both preclinical data and a retrospective analysis of prospectively included patients, high stathmin level was associated with a poor response to paclitaxel-containing chemotherapy [122]. However, this was not seen in a retrospective analysis of patients despite the associations between stathmin expression and shorter progression-free survival and overall survival [130]. Another retrospective study found significant overexpression of stathmin in patients with lymph node metastases [129].

Sentinel lymph node biopsy

Development

The German pathologist Virchow suggested that cancer spreads via lymphatic vessels to lymph nodes and that lymph nodes function as a filter in the lymphatic system. This suggestion was inspired by the observation in an autopsy that carbon pigment from a skin tattoo localized to a single lymph node [131]. As described above, extensive studies on the lymphatic anatomy were conducted in the second half of the 19th and first half of the 20th centuries [53, 54, 58, 60, 62]. In 1923, the British surgeon Braithwaite used blue dye (indigo carmine) to identify the lymphatic drainage of the omentum and called the identified lymph nodes “gland sentinels”, thus becoming the first to refer to lymph nodes as a “sentinel” [132, 133]. In a study on parotid cancer, Gould et al. coined the term “sentinel node”, which was the first lymph node with tumour spread [10].

Two principles form the basis of the sentinel lymph node concept: lymphatic drainage to regional lymph nodes and the functioning of this lymph node as an effective filter of tumour cells (Figure 13) [134]. Both entrapment of tumour cells in the first draining lymph node and sequential lymphatic dissemination can occur [134]. The sentinel lymph node is the first node in a regional basin and, if it is histologically cancer free, reflects the status of the entire basin.

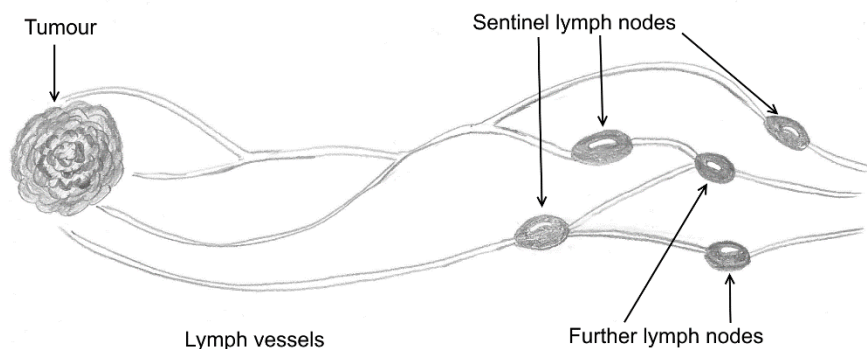


Figure 13
Principle of the sentinel lymph node concept.

The sentinel lymph node concept was described for penile cancer in 1977 and for testicular cancer in 1987 [135, 136]. In 1992, Morton and Cochrane published a landmark article on intraoperative lymphatic mapping in early stage melanoma [137]. The first article on sentinel lymph node biopsy for breast cancer was published in 1994 and introduced pathologic ultrastaging using multiple sections of paraffin-embedded tissue and sensitive cytokeratin stains [138]. Further development of this technique has resulted in less-extensive operations and preserved function for several cancer diagnoses while not jeopardizing the chance of regional control and survival [133]. A sentinel lymph node biopsy is now the standard of care for breast cancer, early stage vulvar cancer and melanoma [139-141].

Sentinel lymph node biopsy in endometrial cancer

Type of procedure

Using injection of isosulfan blue into the fundus uteri, Burke et al. pioneered the detection of sentinel lymph nodes in endometrial cancer in 1996 [11]. Sentinel lymph node biopsy has been described for laparoscopic, robot-assisted laparoscopic and open surgery [11, 142, 143]. Although first performed in open surgery, the use of conventional and robot-assisted laparoscopy in sentinel lymph node biopsy has increased in the past decade in parallel with its development, as described above [143-147]. A recent meta-analysis that included 4915 women in 55 studies showed no significant association between the sentinel lymph node detection rate and the type of surgical approach [148].

Injection site

Given the occurrence of both pelvic and para-aortic lymph node metastases in endometrial cancer, different tracer injection sites have been discussed. Potential injection sites are (a) the cervix uteri, (b) the fundus uteri or (c) peritumoral injection using transvaginal sonography or hysteroscopy [145, 149-151]. The proposed advantages of the cervix uteri as the injection site are its accessibility and that it is rarely scarred from prior procedures or distorted by anatomical variations, such as myomas [149, 151]. However, concerns have been raised about whether the lymphatic drainage of the cervix represents the true lymphatic drainage of the tumour situated in the corpus uteri, both within the pelvis and to the para-aortic area [152]. The proposed advantages of the fundus uteri as the injection site are its closeness to the tumour, but a disadvantage is its inaccessibility and some authors doubt that it reflects the parametrial lymphatic drainage of the uterus [151]. Using transvaginal sonography or hysteroscopy for peritumoral tracer injection seems attractive because, at least conceptually, it should represent the best way to highlight the drainage of the tumour, although it is technically challenging, time consuming and cumbersome [145, 149-151].

In recent years, several studies have addressed the controversy about the optimal injection site [145, 149]. A meta-analysis in 2017 has shown that cervical injection results in a higher detection rate of sentinel lymph nodes than uterine injection techniques [148]. However, the para-aortic sentinel lymph node detection rate was significantly lower with the cervical compared with the uterine injection technique [148]. Only 1–3% of endometrial cancer patients have isolated para-aortic metastases and, based on the superior detection rate of sentinel lymph nodes after cervical tracer injection, sentinel lymph node mapping using a superficial and deep cervical injection of dye may be considered according to the U.S. National Comprehensive Cancer Network guidelines [34, 40, 65]. Sentinel lymph node detection using cervical injection of tracer has been proposed as the standard of care in women with clinical stage I endometrial cancer [40, 148, 153, 154]. However, according to a European consensus conference, sentinel lymph node biopsy should be offered only in the setting of a clinical trial [36].

Tracer

The use of coloured tracers or radiotracers to detect sentinel lymph nodes has been described for several cancers [133, 137, 138]. Traditionally, patent blue, isosulfan blue and methylene blue have been used as coloured tracers. These have the advantages of being inexpensive techniques not requiring the purchase of special imaging systems. However, isosulfan blue causes anaphylactic reactions in 1/1000 uses and methylene blue can cause paradoxical methaemoglobinaemia, which can lead to a falsely low serum oxygen saturation [155, 156]. Technetium 99, a radiocolloid, percolates into lymph nodes, which can then be detected

intraoperatively using a hand-held gamma probe [143]. Coloured tracers and radiotracers can be used together [157].

Indocyanine green (ICG) is a dye that fluoresces in the near-infrared spectrum under illumination of 806 nm near-infrared light. It emits a signal at 830 nm, which can be captured using a video camera equipped with appropriate optical filters specific for the ICG returning wavelength [144]. ICG visualizes lymph vessels and lymph nodes in green in contrast to the surrounding tissue, which appears grey in the integrated fluorescence imaging system of the surgical robot. Techniques for the identification of sentinel lymph nodes using ICG are available for open, laparoscopic and robot-assisted surgery [144, 146, 158]. Patients with iodine allergy, which can occur in 1–2% of an unselected patient group, can develop hypersensitivity to ICG because it contains 5% sodium iodine [144, 159]. The U.S. Food and Drug Administration approved ICG for human use in 1959. ICG was first used in the detection of sentinel lymph nodes in breast cancer in 2005, followed by its use in melanoma treatment in 2009 [160, 161]. ICG for sentinel lymph node detection in gynaecological cancers was first described in 2012 [144].

The past literature shows heterogeneity in terms of the tracers used during sentinel lymph node biopsy [11, 142, 147, 157]. The French study of sentinel node biopsy in early stage endometrial cancer (Senti-Endo), a prospective multicentre study of 125 patients, showed a sensitivity of 84% and a negative predictive value of 97% using cervical dual injection of technetium and patent blue [143]. A large multicentre prospective cohort study of 340 patients who received ICG and robot-assisted surgery showed a bilateral detection rate of sentinel lymph nodes in only 52% of patients; however, 89% of the surgeons were new to the sentinel lymph node technique [142]. In that study, the sensitivity to detect metastatic lymph nodes was 97.2% and the negative predictive value was 99.6% [142]. A recent meta-analysis that included all previous data showed that the use of ICG is associated with a higher rate of bilateral sentinel lymph node detection than using blue dye or a radiotracer [148]. ICG also improves the rate of successful mapping in obese patients [162].

Surgical algorithm

The potential of the sentinel lymph node technique for endometrial cancer has been recognized only in the past decade. A variety of dyes and radiotracers, alone or in combination, are used to depict sentinel lymph nodes, which are described as “radioactive/hot nodes” or “coloured nodes” [163-166]. However, most studies fail to refer to lymphatic anatomy, and only a few studies have considered the additional lymphatic dispersion of tracer in the lymphatic pathways [142, 157, 163-167].

An algorithm for sentinel lymph node mapping was published in 2012 and incorporated the need for removal of suspicious nodes and side-specific

lymphadenectomy in cases of failed sentinel lymph node detection (Figure 14) [168].

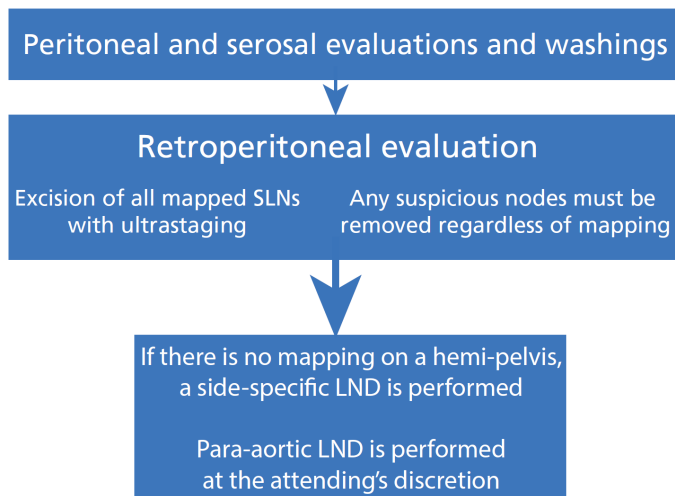


Figure 14

Surgical algorithm for sentinel lymph node (SLN) biopsy endometrial cancer as proposed by Barlin et al. [168]. LND: lymphadenectomy. Reproduced with kind permission of Elsevier.

The application of the algorithm reduced the 15% false-negative rate to 2% and missed only one patient with an isolated para-aortic lymph node metastasis [168]. The sensitivity increased from 85.1% to 98.1%, and the negative predictive value from 98.1% to 99.8% [151, 168]. However, even though it is an improvement in providing a reproducible standardized approach, the algorithm fails to consider lymphatic anatomy. This algorithm has been externally validated using ICG; the bilateral detection rate was 78%, but the false-negative rate could not be calculated because complementary lymphadenectomy was not performed [147]. Another external validation of this algorithm found a bilateral detection rate of 71.1% and a false-negative rate of 7% [169].

Definition of detection rate

Although the uterus is situated in the midline and has bilateral lymphatic drainage, many studies on the use of sentinel lymph node biopsy report the unilateral detection rate, which is defined as one sentinel lymph node identified per patient. The identification of at least one sentinel lymph node per hemi-pelvis, also called bilateral detection rate, better reflects the midline position of the uterus from the anatomical point of view. However, this generally applied definition does not consider both the upper and lower paracervical pathways.

Pathology assessment of sentinel lymph nodes

According to many authors, a full pelvic lymphadenectomy is defined as the removal of at least 10 lymph nodes [142, 151]. Another study advocates the definition of complete lymphadenectomy if 20 lymph nodes are removed [6]. Five para-aortic lymph nodes should be removed to count as a complete para-aortic lymphadenectomy [170]. It is noteworthy that in articles on lymphadenectomy in endometrial cancer, the lymph node count varies considerably between studies. An Asian study reported the removal of a median of 62.5 pelvic lymph nodes (maximum >100 lymph nodes), whereas a U.S. study reported a mean of 36 and a European study reported a mean of 24 [64, 65, 80]. One explanation may be the lack of standardization of the process of defining the pathological lymph node count [104]. Both the inter- and intraobserver variability have been described in a study in which 10 pathologists counted 15 slides with lymph nodes twice: The number of counted lymph nodes varied between 62 and 101, and there was no slide that all pathologists agreed on [104].

Traditionally, routine pathology comprises the use of haematoxylin and eosin staining on one section of each lymph node because it is economically and logistically not feasible to examine each lymph node entirely [171]. With the development of sentinel lymph node biopsy in breast cancer and ultrastaging of sentinel lymph nodes, definitions of low-volume metastatic disease have emerged. Isolated tumour cells as microscopic clusters and single cells measuring ≤ 0.2 mm, micrometastases are defined as a focus of metastatic tumour cells measuring 0.2–2 mm, and macrometastases as tumour clusters measuring >2 mm [151, 171, 172]. Ultrastaging is often performed using haematoxylin and eosin staining as the initial examination. If this assessment is negative, two adjacent sections are cut from each paraffin block at each of two levels, 50 μ m apart. At each level, both haematoxylin and eosin staining and immunohistochemistry are used [151, 171]. Ultrastaging improves the detection of micrometastases in endometrial cancer staging, but it is unclear whether this affects disease-free and overall survival [171, 173].

Morbidity after sentinel lymph node biopsy

Although research on the sentinel lymph node concept in endometrial cancer has been conducted for over a decade and may be considered in clinical practice according to the U.S. guidelines, to the best of my knowledge there are no published data on the incidence of perioperative and long-term morbidity following sentinel lymph node biopsy in patients with endometrial cancer [40]. Only one article has addressed intraoperative outcomes and showed that sentinel lymph node biopsy is associated with shorter operative times and less estimated blood loss compared with pelvic and para-aortic lymphadenectomy [146].

Need for improvement in sentinel lymph node biopsy in endometrial cancer

To implement sentinel lymph node biopsy as the standard of care for patients with endometrial cancer, an algorithm is needed with a low false-negative rate, high technical success rate, and distinct definition of a sentinel lymph node, and it must be based on lymphatic anatomy.

A high technical success rate is essential for minimizing the need for a complementary lymphadenectomy in cases of failed sentinel lymph node detection. Tracers identify not only the sentinel lymph nodes but disperse throughout the lymphatic pathways to secondary lymph nodes. Care must be taken to identify the true sentinel lymph node in each pathway. Bulky nodes and lymph nodes with clear afferent vessels without tracer accumulation must be considered because these may also indicate metastatic disease [174]. A logical prerequisite for a sentinel lymph node algorithm is the knowledge and incorporation of lymphatic uterine drainage. However, despite the research conducted in the past decade, there is no sentinel lymph node algorithm that fulfils all of these requirements. This lack of an algorithm has been the motivation for this doctoral dissertation.

Aims

General aims

The overall aims of this thesis were to investigate the overall feasibility of robot-assisted pelvic and infrarenal para-aortic lymphadenectomy, and to develop and evaluate a sentinel lymph node algorithm in endometrial cancer.

Specific aims

- To evaluate the feasibility of robot-assisted pelvic and infrarenal para-aortic lymphadenectomy in endometrial cancer patients (study I)
- To assess lymphatic complications following robot-assisted pelvic and infrarenal para-aortic lymphadenectomy (study I)
- To examine the lymphatic uterine anatomy to provide a basis for a standardized sentinel lymph node detection and definition (study II)
- To examine whether cervical or fundal injection of tracer is preferable (study II)
- To describe and evaluate a reproducible, anatomically based surgical sentinel lymph node algorithm based on lymphatic anatomy (study III)
- To evaluate whether reinjection of tracer improves the technical success rate of sentinel lymph node detection (study III)
- To assess the overall percentage of endometrial cancer patients deemed suitable for sentinel lymph node detection with a near-infrared fluorescence technique and the safety of the described algorithm (study IV)
- To compare side effects of a full lymphadenectomy with those after sentinel lymph node biopsy only (study IV)
- To provide a basis for future evaluation of the false-negative rate and sensitivity of sentinel lymph node biopsy (studies II–IV)

Material and methods

Study I

All patients diagnosed with high-risk endometrial cancer (at least one risk factor, FIGO grade 3, FIGO stage \geq IB, non-diploid type in flow cytometry or non-endometrioid histology) from January 2010 until August 2013 were identified using the national cancer registry database. The hospital surgery registry was used to identify patients who had been operated on. The reasons for the planned approach (no operation, laparotomy or robot-assisted laparoscopy) were retrieved from the patients' charts.

The regional institutional review board approved the study (633/2008). All patients gave their written consent before surgery. A registry for perioperative and follow-up data for all patients who are planned to receive robot-assisted surgery using prospective designated protocols was established when robot-assisted surgery was implemented at Skåne University Hospital, Lund, Sweden. Relevant perioperative data were retrieved for all women who were intended to receive robot-assisted pelvic and para-aortic lymphadenectomy. A re-evaluation of all patients' charts was performed with special emphasis on the development of lymphatic complications. Missing data were obtained by telephone contact with the patient.

Preoperatively, a CT scan of the thorax and abdomen, expert transvaginal ultrasonography to assess myometrial and/or cervical invasion, and clinical examination to evaluate the uterine size in relation to the vagina were performed. One of five gynaecological oncology surgeons performed all operations. A da Vinci® S or Si system with a single central pelvic docking of the patient cart, four robot arms and usually one 12 mm assistant's port was used. Peritoneal cytology along with systematic para-aortal and pelvic lymphadenectomy, bilateral salpingo-oophorectomy and hysterectomy were performed, as was an infracolic omentectomy in patients with non-endometrioid histology.

Sponge-reinforced sutures helped to lateralize the sigmoid colon. A peritoneal incision beginning at the aortic bifurcation was extended along the right common iliac artery and lateral to the caecum and ascending colon for mobilization of the small bowel mesentery and ascending colon. Relevant anatomical structures were identified, and vessel anomalies diagnosed. Starting with the infrarenal lymph

nodes, the lymphadenectomy continued distally along the aorta and vena cava until it reached the aortic bifurcation. To facilitate the supramesenteric para-aortic lymphadenectomy, the third robot arm and the assistant lifted the peritoneum to expose the aorta and vena cava, and to prevent the bowel from interfering with visualization. If necessary, operation towels were used to further retract the bowel. After the para-aortic lymphadenectomy, lymph nodes along the common iliac and external iliac artery and in the obturator fossa were harvested. A re-insertable retrieval bag facilitated retrieval of lymph nodes through the 12 mm assistant's port (LINA Medical, Glostrup, Denmark). The procedure was finalized by performance of the hysterectomy and bilateral salpingo-oophorectomy. All removed tissue underwent histopathology analysis.

All patients with non-endometrioid histology and those with endometrioid cancer with two or more of the aforementioned risk factors received adjuvant chemotherapy, unless contraindicated by comorbidity or advanced age. In patients with lymph node metastases, locoregional radiotherapy was applied.

Postoperative clinical examinations were performed three times annually and included gynaecological investigation, palpation of lymph nodes, control of lymphatic complications, if needed, and vaginal ultrasonography to identify pelvic lymphoceles. Patients with lower extremity lymphoedema were examined at a specialized unit using the Common Toxicity Criteria 3.0 [101]. CT scans were performed according to the protocol for patients receiving adjuvant treatment and for symptomatic patients.

For statistical analyses, the Wilcoxon signed-rank test, Mann–Whitney's *U* test and Fisher's exact test were used as appropriate. A *p*-value of <0.05 was considered to be significant. An intention-to-treat policy was used for the analyses.

Studies II–IV

After thorough pilot studies on the dosing, timing and injection techniques of ICG, the study “Near-infrared fluorescent technique for sentinel lymph node mapping in endometrial cancer” was opened for recruiting in June 2014. The study complied with the Declaration of Helsinki, was approved by the institutional review board (2013/163) and was registered at ClinicalTrials.gov (NCT02690259). Consecutive patients with endometrial cancer scheduled for robot-assisted surgery using a da Vinci® Si or Xi Surgical System were approached for inclusion. All women gave their preoperative written consent. Only during the implementation phase of the study, the number of surgeons trained in the surgical algorithm for detection of sentinel lymph nodes limited the inclusion of patients who were operated on by

other gynaecological oncology surgeons and thus not enrolled in the study. Data on patients not suitable for inclusion in the study were collected prospectively and simultaneously to determine the percentages of included patients and patients treated by minimally invasive surgery. A preoperative CT scan of the thorax and abdomen, and a transvaginal expert ultrasonography were performed to assess the dissemination, myometrial and/or cervical invasion.

Preoperatively, patients were classified as either “low-risk” or “high-risk” patients. Patients who presented with at least one risk factor (FIGO grade 3, FIGO stage \geq IB, non-diploid on flow cytometry or non-endometrioid histology) were allocated to the high-risk group. Because the preoperative risk allocation does not always correspond with the definitive histology, both pre- and postoperative risk allocations were recorded [42, 43, 46]. All patients were scheduled for hysterectomy, bilateral salpingo-oophorectomy and sentinel lymph node biopsy, followed by a complementary pelvic and infrarenal para-aortic lymphadenectomy in high-risk patients. In patients with a non-endometrioid histology, an infracolic omentectomy was also performed. A limited procedure (para-aortic lymphadenectomy restricted to the level of the inferior mesenteric artery, a full pelvic lymphadenectomy without para-aortic dissection or sentinel lymph node biopsy alone) was upfront planned in high-risk patients with comorbidity or advanced age.

The aim of study II was to determine the success rate for identifying sentinel lymph nodes using tracer injection into the uterine fundus compared with that for cervical injection. Between June 2014 and February 2016, either cervical or fundal injections of tracer were used. However, cervical injection resulted in a higher technical success rate and identified the same pelvic lymphatic pathways and sentinel lymph nodes, and only cervical injection of tracer was used after February 2016.

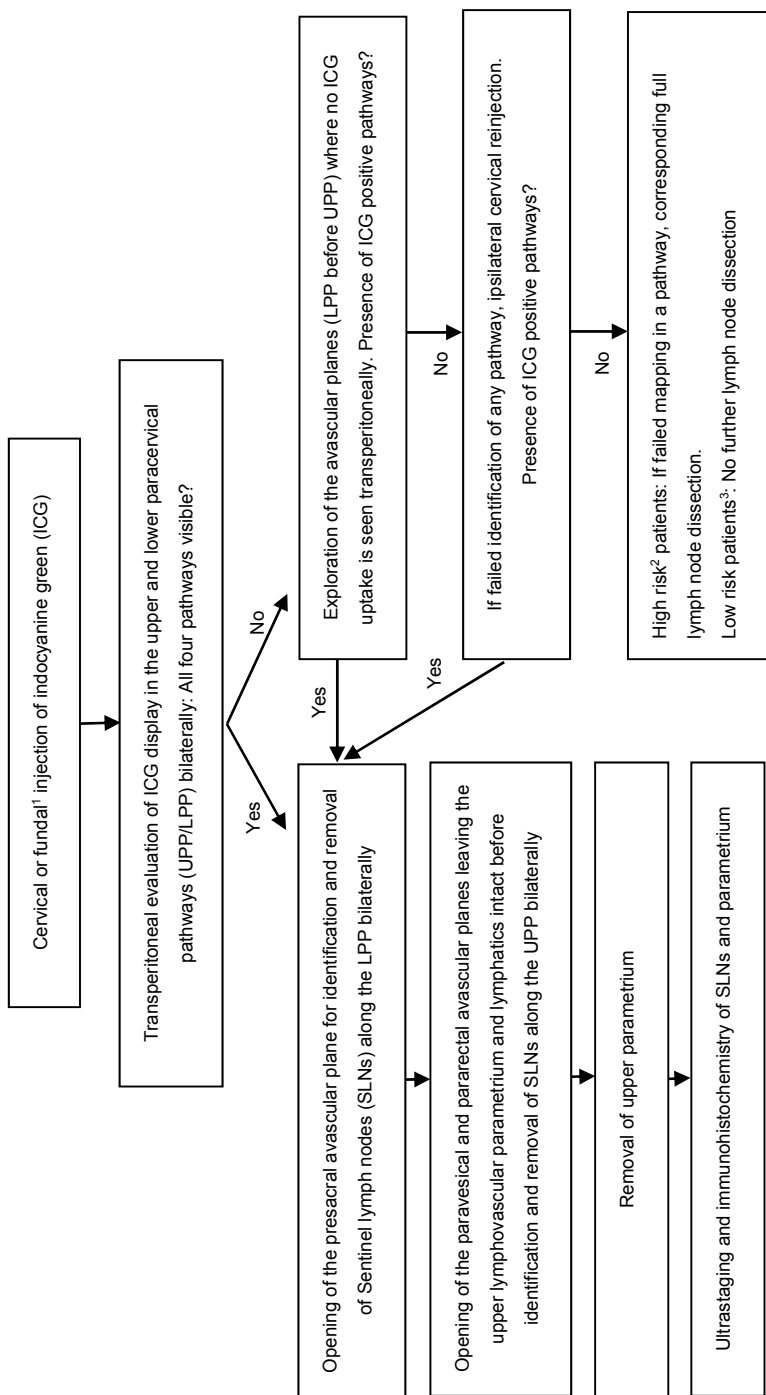
For the injection, 25 mg ICG powder (Pulsion Medical Systems, POCG0025SE, Feldkirchen, Germany) was diluted in 10 mL of sterile water to produce a solution at a concentration of 2.5 mg/mL. For cervical injection, which was performed during vaginal preparation, 0.25 mL (0.625 mg) of ICG was slowly injected at each injection site (2–4–8–10 o’clock positions) using a 0.6×38 mm 23G \times 1½ needle and four 1-mL syringes. Half of the volume was administered submucosally and the other half was injected 3 cm into the cervical stroma, after which a vaginal tube was applied around the cervix to visualize the fornices. For the transabdominal fundal injection, an equal amount of ICG was injected subserosally at four injection sites (2 cm below the round ligament anteriorly and posteriorly at each side). A 45-cm 23G Williams Cystoscopic Injection Needle with an 8-mm tip (Cook Incorporated, Bloomington, U.S.A.) was used. To compensate for the 45-cm length of the needle, 0.3 mL of ICG solution was added to the first injection.

Under the illumination with a near-infrared (803 nm) light, ICG emits fluorescence at 830 nm. The Firefly technology of the surgical robot, which has integrated

fluorescence imaging capability, enables visualization of the draining lymph vessels and lymph nodes in a green colour against grey surrounding tissue. A swift change between Firefly imaging and normal light is possible. Because the aim of study II was to elucidate uterine lymphatic anatomy, the Firefly mode was used during ICG injection for visual observation of the lymphatic drainage through an intact peritoneum for at least 15 minutes during data acquisition for study II. The lymphatic mapping was recorded on an anatomical chart.

When visualization of the lymphatic drainage was achieved, the peritoneum was opened medially to the right common iliac artery just below the aortic bifurcation for identification of the presacral sentinel lymph nodes. The common iliac arteries and veins, ureters and the hypogastric nerve were identified before sentinel lymph node removal. Thereafter, the paravesical and pararectal avascular spaces were developed while leaving the lymph vessels intact, and the upper parametrial tissue was removed separately after completion of the sentinel lymph node biopsy. If present, parametrial lymph nodes represent the most juxta-uterine node; that is, the true sentinel lymph node. To avoid division of the lymphatic vessels and to allow for a second evaluation, the Firefly mode was used frequently. All procedures were recorded for later review.

Based on knowledge of lymphatic spread with the occurrence of presacral lymph node metastases in endometrial cancer, an algorithm was developed for sentinel lymph node detection (Figure 15). Per this algorithm, uptake in both pathways bilaterally was needed (in two pathways in each hemi-pelvis) to define the procedure as technically successful. An additional 0.25 mL of ICG (0.625 mg) was injected as a submucosal, cervical ipsilateral reinjection at 3 or 9 o'clock positions in patients with one or more unidentified pathways. Side docking of the robot allowed for easy removal and reinsertion of the fornix presenter when reinjection was needed. Visual observation was performed for at least 10 minutes. An anatomical chart was used by the surgeon to depict the positions of sentinel lymph nodes and lymphatic pathways after the first injection and, when applicable, the subsequent injection if ICG (Figure 16). This was done to allow calculation of both the commonly used bilateral detection rate for one sentinel lymph node per hemi-pelvis and the detection rate per pathway.



UPP = Upper paracervical pathway, LPP = Lower paracervical pathway, Sentinel lymph node (SLN) type 1: ICG positive juxtauterine coloured lymph node in each pathway, SLN type 2: ICG negative lymph node closest to the uterus with a clear afferent lymph vessel in the absence of ipsilateral coloured nodes, SLN macro: any macroscopically suspicious lymph node. If failed mapping in a pathway: lymph node dissection along this pathway.

¹ Based on findings of study II, fundal injection was omitted in February 2016.

² At least one of the following risk factors: FIGO grade 3, non-endometrioid histology, non-diploid flow cytometry, myometrial invasion >50% or cervical invasion.

³ No risk factor.

Figure 15
Surgical algorithm for identification of sentinel lymph nodes (SLNs) in endometrial cancer patients.

Anatomical chart to depict positions of sentinel lymph nodes and lymphatic pathways

Injection site: ☐ cervix ☐ fundus

Visualization after first injection:

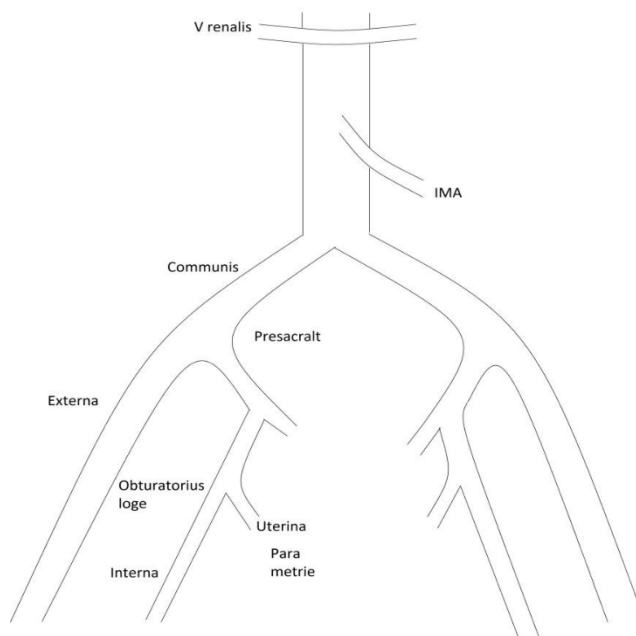
	UPP	LPP	IPP
Right			
Left			

Reinjection cervix: ☐ yes ☐ no

Reinjektion fundus: ☐ yes ☐ no

	UPP	LPP	IPP
Right			
Left			

	UPP	LPP	IPP
Right			
Left			



○ = ICG positive Sentinel node (SLN 1)

□ = ICG negative sentinel lymph node with afferent lymph vessel (SLN 2)

X = bulky node (SLN macro)

Figure 16

Anatomical chart used to depict positions of sentinel lymph nodes (SLN), lymphatic uterine pathways, tracer injection site and need for reinjection. UPP = upper paracervical pathway. LPP = lower paracervical pathway. IPP = infundibulopelvic pathway. ICG = indocyanine green.

Three separate categories of sentinel lymph nodes were defined: sentinel lymph node type 1 was a juxta-uterine ICG-positive lymph node in each pathway with a clear afferent lymph vessel. In the absence of a sentinel lymph node type 1 but in the presence of an ICG-positive afferent lymph vessel, the ICG-negative node draining this lymph vessel was categorized as sentinel lymph node type 2. In some cases, this type represents a metastatic lymph node because such nodes do not always accumulate tracer due to lymphatic obstruction by tumour cells [174]. Sentinel lymph node macro was any macroscopically suspect lymph node regardless of its ICG uptake and localization.

The procedure was thereafter completed as planned before surgery. The anatomical landmarks for defining the respective lymphatic compartment are shown in Table 5.

Table 5

Anatomical description of lymph node compartments in the female pelvis

Lymph node compartment	Proximal limit	Lateral limit	Distal limit	Medial limit
External iliac area	Bifurcation of external and internal iliac artery	Genitofemoral nerve	Cloquet's lymph node	External iliac vein
Obturator fossa	Internal iliac vein	Iliopsoas muscle	Os pubis, obturator nerve	Obliterated umbilical artery
Common iliac	Aortic bifurcation	Genitofemoral nerve	Bifurcation of external and internal iliac artery	Common iliac artery
Presacral	Aortic bifurcation	Common iliac artery	Promontory	Hypogastric nerve (distinction between right and left)
Lower para-aortic (inframesenteric)	Inferior mesenteric artery	Ureter	Aortic bifurcation	
Higher para-aortic (infrarenal)	Left renal vein	Ureter	Inferior mesenteric artery	
External iliac area	Bifurcation of external and internal iliac artery	Genitofemoral nerve	Cloquet's lymph node	External iliac vein
Obturator fossa	Internal iliac vein	Iliopsoas muscle	Os pubis, obturator nerve	Obliterated umbilical artery

The position of the removed lymph nodes including sentinel lymph nodes was recorded on a numbered list. Premade corresponding labels were used to mark individual jars for the nodal tissue removed. For pathology analysis, all macroscopically identified sentinel lymph node/lymphoid tissue was embedded and bisected or cut in 2–3 mm thick slices, if the maximum thickness exceeded 3 mm. Ultrastaging involved five sections at three different levels separated by 200 µm,

using haematoxylin and eosin staining on all levels and on first- and second-level also immunohistochemistry (pan-cytokeratin, MNF116), if the maximum diameter of sentinel lymph node lymphoid tissue exceeded 1 mm. The most suspicious palpable find was embedded and investigated microscopically if no lymph node was macroscopically identified in the sentinel lymph node or parametrial tissue.

Patients with stage I endometrioid adenocarcinoma with at most one risk factor (myometrial invasion >50%, FIGO grade 3, non-diploid by flow cytometry) received no adjuvant treatment. Patients with two risk factors or non-endometrioid histology without lymph node metastases received four cycles of carboplatin and taxanes, as did stage II and III patients. Stage II and III patients also received 46 Gy of external radiotherapy to the pelvis and, if indicated, to the para-aortic area unless contraindicated by age or comorbidity. Brachytherapy (10 Gy) was applied in patients with cervical and/or vaginal engagement.

For all patients, baseline demographics and perioperative and follow-up data were collected prospectively. Using the Clavien–Dindo classification, postoperative complications were graded up to 6 weeks postoperatively [175]. A clinical follow-up using a designated protocol for defined surgical, lymphatic and neural complications, and their clinical course was scheduled every 4 months for at least 2 years. At each visit, vaginal ultrasonography was performed to identify pelvic lymphoceles. A physiotherapist who specialized in lymphatic diseases assessed all patients with lower extremity lymphoedema using the Common Toxicity Criteria 3.0 classification [101]. Copies of the patient's chart and, in case of missing information, telephone contact were used to follow up patients living a long distance from the hospital.

For study IV, we identified all patients having undergone a benign hysterectomy by one surgeon between September 2015 and September 2016 from the registry approved for all robot-assisted surgery (Ethical approval 2010/663). We compared patients with low-risk endometrial cancer who underwent a hysterectomy and sentinel lymph node biopsy with those who received a benign hysterectomy by the same surgeon in the same period and were matched for BMI and uterine size. Median operative times were extracted from the database to investigate the time needed for sentinel lymph node biopsy only.

For study II, consecutive women with endometrial cancer operated on between June 2014 and February 2016 were evaluated. For study III, all high-risk endometrial cancer patients who received cervical injection of ICG operated between June 2014 and December 2016 were selected from the database. For study IV, all endometrial cancer patients operated on between June 2014 and September 2016 were selected to achieve a follow-up of at least 12 months. It was possible for a patient who was initially included in the study to be included in 1–3 studies.

For statistical analyses, Fisher's exact test and the Mann–Whitney *U* test were used. A *p*-value <0.05 was considered to be significant. An intention-to-treat policy was used for the analyses.

For the sentinel lymph node algorithm to be implemented as the standard of care instead of systemic lymphadenectomy in clinical practice, a low false-negative rate and high sensitivity are needed. Sentinel lymph node biopsy can only be considered a safe alternative to full lymphadenectomy if the non-metastatic sentinel lymph node predicts the status of further lymph nodes. Although calculation of a false-negative rate and sensitivity was not an aim of this thesis, the study initiated is ongoing to provide data for a future calculation. Based on the assumption that 20% of high-risk endometrial cancer patients would have lymph node metastases, a power analysis using the Clopper–Pearson exact method was used. Two hundred and fifty high-risk patients need to be included to reach a clinically relevant and sufficient lower confidence level for sensitivity (Table 6). The additional inclusion of a further 125 patients would not lead to a substantial increase of the lower confidence level. Each patient who undergoes at least a complementary pelvic lymphadenectomy acts as her own control. Sentinel lymph node status is compared with non-sentinel lymph node status within the same patient to calculate false-negative rate and sensitivity.

Table 6
Power calculation using the Clopper–Pearson exact method

Number of included patients with high-risk endometrial cancer	Estimated number of patients with lymph node metastases	Expected confidence interval
100	20	83–100%
250	50	93–100%
375	75	95.2–100%

Ethical considerations

All participants in the studies I–IV participated willingly and provided written consent. All participants were informed that they could terminate their participation at any time.

Participation in study I did not change the treatment or follow-up except for a phone call to some patients. Participation in studies II–IV involved an injection of ICG in all patients and a sentinel lymph node biopsy for low-risk patients for whom no lymphadenectomy would have been performed otherwise. ICG is a well-known substance that was approved for use in humans by the U.S. Food and Drug Administration in 1959 and has a low risk of allergic reaction [144]. The

performance of the sentinel lymph node biopsy prolonged the surgical procedure for low-risk patients but also had the potential for identifying patients with lymph node metastases and to spare patients from the need for a reoperation for lymphatic staging in cases of erroneous preoperative risk assessment. For high-risk patients, the study prolonged the surgical time but had the advantage of providing better diagnostics in the form of ultrastaging and immunohistochemistry for sentinel lymph nodes.

The Regional Research Ethics Committee approved all studies (study I: 633/2008, studies II–IV: 2013/163, study IV: 2010/663).

Results

Study I

During the study period, 212 women with high-risk endometrial cancer were identified, of whom 197 were surgically treated. Figure 17 shows the planned surgical approach and success rate of the robot-assisted full infrarenal para-aortic lymphadenectomy. A para-aortic lymphadenectomy to the left renal vein was achievable in 98 of 140 patients (70%); this approach was restricted to the level of the inferior mesenteric artery in another 30 patients (21%) and restricted to sampling or aborted in 12 patients (9%). Experienced surgeons harvested infrarenal lymph nodes in 88% of all non-obese patients. The median numbers of retrieved pelvic and para-aortic lymph nodes in patients treated with a para-aortic lymphadenectomy including the infrarenal area were 18 (range 4–39) and 10 (range 2–39), respectively. The median number of infrarenal nodes was 5 (range 1–19).

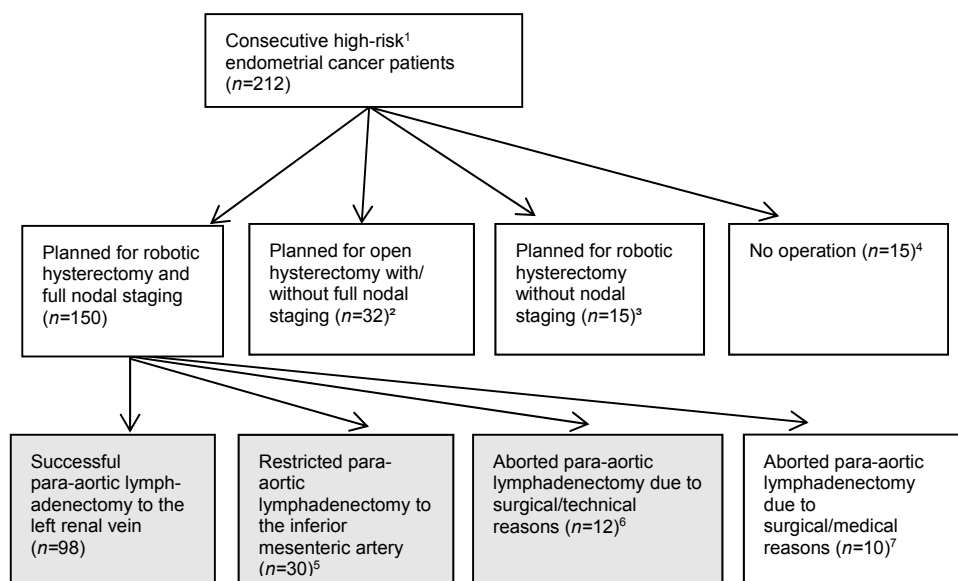


Figure 17

Overview of the surgical approach planned for consecutive high-risk endometrial cancer patients at a tertiary referral gynaecological centre and success rates for robotic full para-aortic nodal staging. Feasibility studies on robotic para-aortic lymphadenectomy performed on patient groups are marked with a grey background. ¹At least one of the following characteristics: grade III tumour, FIGO Stage \geq IB, non-endometrioid histology or DNA non-diploidy. ²Uterine size/surgical reasons ($n = 23$), disseminated disease ($n = 9$). ³Older age ($n = 10$), comorbidity ($n = 5$). ⁴Disseminated disease ($n = 8$), older age ($n = 6$), comorbidity ($n = 1$). ⁵High BMI ($n = 14$), adhesions ($n = 10$), bleeding ($n = 4$), older age ($n = 2$). ⁶High BMI ($n = 9$), adhesions ($n = 3$). ⁷Disseminated disease ($n = 7$), aortic aneurysm ($n = 1$), venous hypertension/liver cirrhosis ($n = 1$), reason related to anaesthesia ($n = 1$).

Univariate analysis showed that failure to perform an infrarenal para-aortic lymphadenectomy and the number of retrieved para-aortic and pelvic lymph nodes were significantly associated with BMI ($p = 0.005$, $p < 0.001$ and $p < 0.001$, respectively) and surgeon's inexperience. The para-aortic lymphadenectomy was aborted in 21% of patients when operated on by an experienced surgeon and in 43% of patients when operated on by an inexperienced surgeon ($p = 0.004$). Significantly more para-aortic lymph nodes were harvested by experienced surgeons in patients receiving an infrarenal para-aortic lymphadenectomy: median 11 nodes (range 4–39) for experienced vs 8.5 nodes (range 2–30) for inexperienced surgeons ($p = 0.047$).

A follow-up of a minimum of 12 months was possible in 134 patients: 16 patients (12%) developed grade 1 and three patients (2%) grade 2 lower extremity lymphoedema (graded according to the Common Toxicity Criteria v 3.0) [101]. Pelvic lymphoceles were identified in 11 patients (8%) and a para-aortic lymphocele in one patient (1%).

Study II

A total of 90 women were included in this study. ICG was injected into the cervix of 60 patients and into the fundus in 30 patients. Regardless of the injection site, two consistent lymphatic pathways with pelvic sentinel lymph nodes were identified: an upper paracervical pathway running along the uterine artery that drained the medial external iliac and/or obturator lymph nodes, and a lower paracervical pathway coursing along the upper rim of the sacrouterine ligament to the presacral area medial of the internal iliac artery (Figures 18, 19).

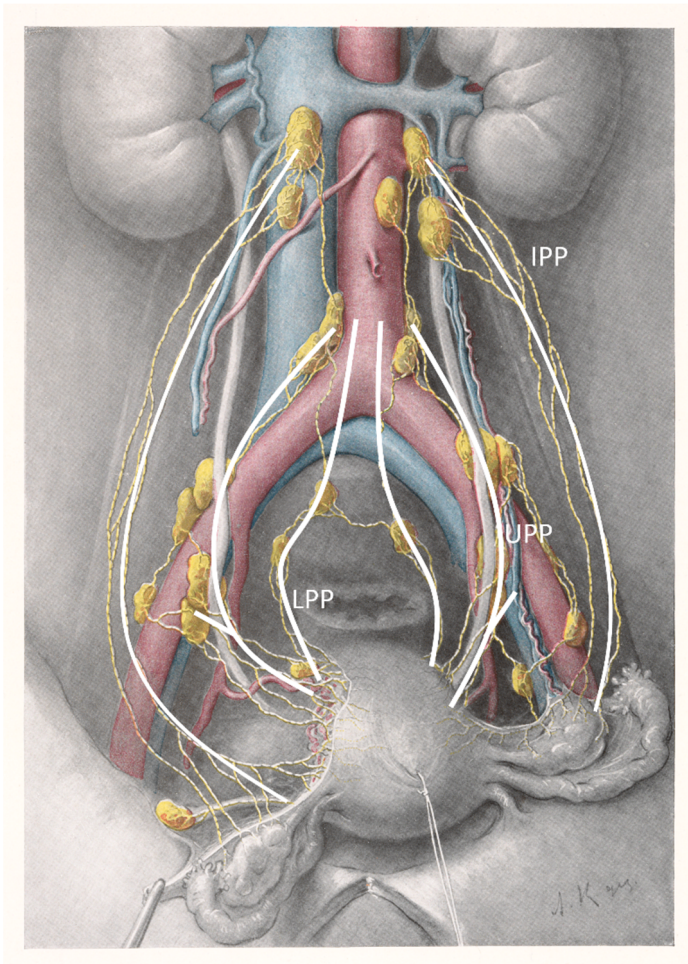


Figure 18
Schematic overview of the uterine lymphatic pathways. UPP = upper paracervical pathway, LPP = lower paracervical pathway, IPP = infundibulopelvic pathway. Modified after Döderlein and Krönig [62], 1912, with kind permission of Thieme Medical Publishers, Germany.

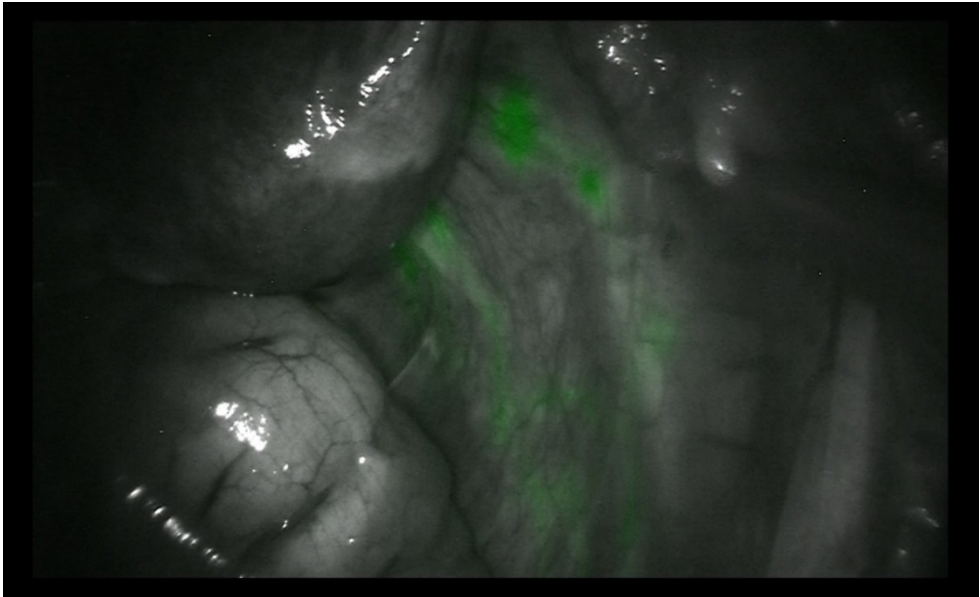


Figure 19
Upper and lower paracervical pathways visualized using indocyanine green in a patient with endometrial cancer.

In addition, an infundibulopelvic pathway with a course running along the fallopian tube and upper broad ligament was seen (Figures 18, 20).

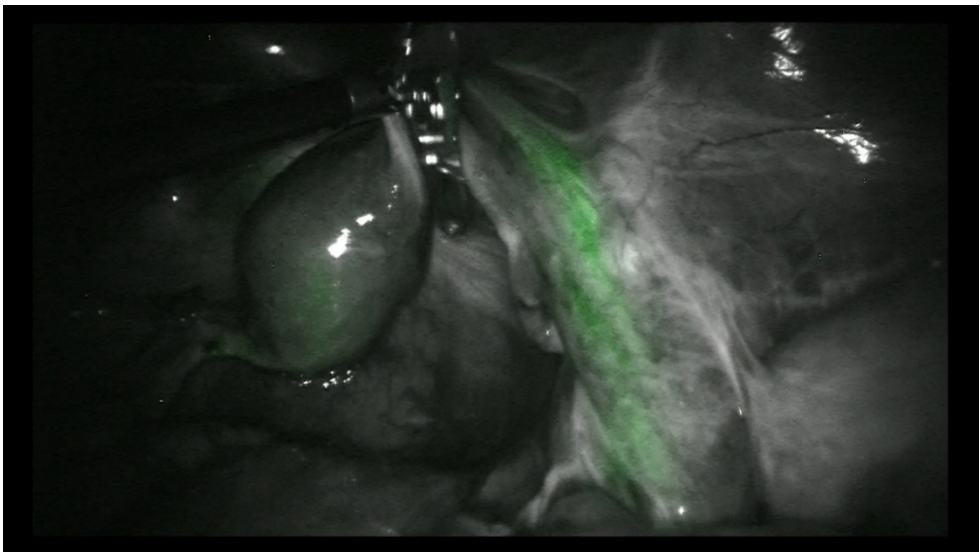


Figure 20
The infundibulopelvic pathway visualized using indocyanine green in a patient with endometrial cancer.

Cervical injection resulted in a bilateral detection rate (at least one sentinel lymph node per hemi-pelvis) of 98% and fundal injection a detection rate of 80% ($p = 0.005$). Bilateral display of both pelvic pathways occurred in 30% and 20% of patients given a cervical or fundal injection, respectively ($p = 0.6$) because the lower paracervical pathway was less often displayed. Cervical and fundal injection of tracer resulted in similarly located sentinel lymph nodes (Table 7). The typical localization of sentinel lymph nodes is shown in Figure 21.

Table 7

Display of lymphatic pathways from the uterus and localization of sentinel nodes (SLNs) per lymphatic compartment following cervical or fundal injection of indocyanine green in endometrial cancer patients

	Cervical injection <i>n</i> = 60 (%)	Fundal injection <i>n</i> = 30 (%)	<i>p</i> -value
Unilateral detection rate ¹	60 (100)	28 (93)	0.11 n.s.
Bilateral detection rate ¹	59 (98)	24 (80)	0.005*
UPP ² unilateral	60 (100)	25 (83)	0.003*
UPP ² bilateral	57 (95)	21 (70)	0.002*
LPP ³ unilateral	33 (55)	14 (47)	0.5 n.s.
LPP ³ bilateral	20 (33)	6 (20)	0.22 n.s.
UPP ² and LPP ³ bilateral	18 (30)	7 (20)	0.62 n.s.
IPP ⁴ unilateral	3 (5)	14 (47)	<.01*
IPP ⁴ bilateral	1 (2)	9 (30)	<.01*
UPP ² +LPP ³ +IPP ⁴ bilateral	1 (2)	3 (10)	0.11 n.s.
Localization of SLN per lymph node compartment ⁵			
Right external iliac artery	47 (78)	24 (80)	1 n.s.
Left external iliac artery	49 (82)	23 (77)	0.59 n.s.
Right obturator fossa	33 (55)	10 (33)	0.07 n.s.
Left obturator fossa	30 (50)	10 (33)	0.18 n.s.
Right presacral area	28 (47)	12 (40)	0.65 n.s.
Left presacral area	22 (37)	10 (33)	0.82 n.s.
Right common iliac artery	6 (20)	4 (13)	0.73 n.s.
Left common iliac artery	9 (15)	1 (3)	0.16 n.s.
<p>* statistically significant, n.s. = not significant</p> <p>¹ Refers to detection of at least one of LPP or UPP lymphatic pathway and subsequent identification of an SLN.</p> <p>² UPP = Upper paracervical pathway, draining external iliac and/or obturator lymph nodes</p> <p>³ LPP = Lower paracervical pathway, draining presacral lymph nodes</p> <p>⁴ IPP = Infundibulopelvic ligament pathway, draining para-aortic lymph nodes</p> <p>⁵ For anatomical description of lymph node compartments, see Table 5</p>			

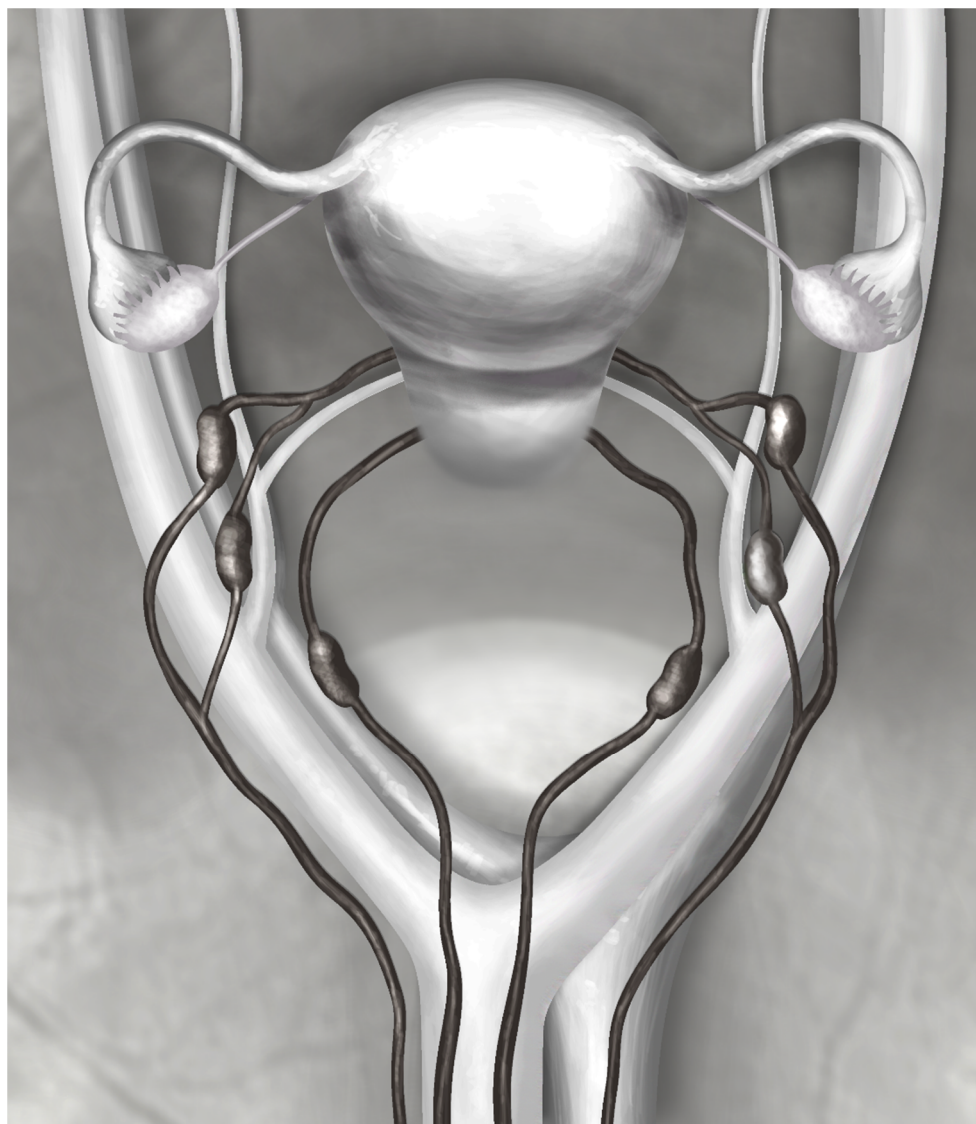


Figure 21
Schematic overview of the pelvic uterine lymphatic pathways with typical localization of sentinel lymph nodes.

The median number of pathologically identified sentinel lymph nodes was 6 (1–21) following cervical injection and 5.5 (0–21) after fundal injection ($p = 0.77$). All patients with lymph node metastases who underwent an infrarenal para-aortic and pelvic lymphadenectomy had at least one metastatic sentinel lymph node. Lymph node metastases along the lower paracervical pathway in the presacral area were diagnosed in 29% of node-positive patients. According to the final pathology report

regarding risk factors, lymph node metastases were found in 8% of low-risk and 23% of high-risk patients. Inconsistency in the pre- and postoperative risk assessment was found in 15 patients: three of 16 patients (19%) were under-staged and 12 of 74 (16%) were over-staged.

Study III

A total of 102 women with high-risk endometrial cancer were included in this study but in one no ICG was injected because of adhesions. The bilateral success rate (identification of at least one sentinel lymph node per hemi-pelvis) was 88% after the first injection and 96% after reinjection (Table 8) ($p = 0.07$). Reinjection significantly improved the bilateral identification of each pathway and the identification of both pathways bilaterally (Table 8).

Table 8

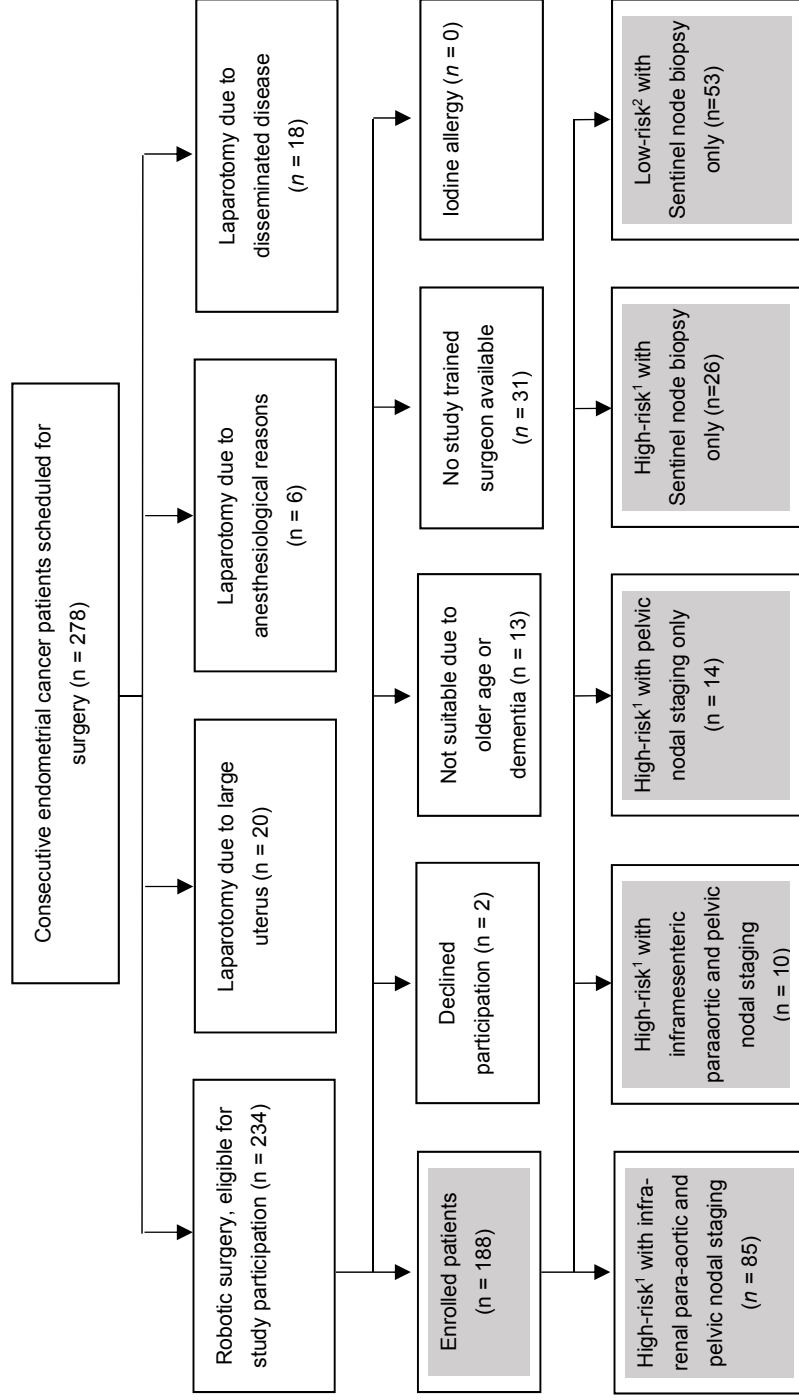
Display of lymphatic pathways from the uterus following cervical injection of indocyanine green in 101 high-risk endometrial cancer patients

	First injection <i>n</i> (%)	Reinjection <i>n</i> (%)	<i>p</i> -value
Unilateral detection rate ^a	97/101 (96)	100/100 (100) ^d	0.12 n.s.
Bilateral detection rate ^a	89/101 (88)	96/100 (96) ^d	0.07 n.s.
UPP ^b unilateral	97/101 (96)	100/100 (100) ^d	0.12 n.s.
UPP ^b bilateral	84/101 (83)	93/98 (95) ^d	0.01*
LPP ^c unilateral	59/95 (62) ^e	74/87 (85) ^d	0.0007*
LPP ^c bilateral	37/95 (39) ^e	54/79 (68) ^d	0.0001*
UPP ^b and LPP ^c bilateral	34/95 (36) ^e	52/79 (66) ^d	0.0001*
^a Refers to detection of at least one of LPP or UPP lymphatic pathways and subsequent find of a SLN. ^b UPP = Upper paracervical pathway, draining external iliac and/or obturator lymph nodes ^c LPP = Lower paracervical pathway, draining presacral lymph nodes ^d Changed number of patients because of lack of reinjection (protocol violation) ^e Changed number of patients as presacral area surgically not reachable * statistically significant, n.s. = not significant			

The pathology report showed a median of 7 (1–15) removed sentinel lymph nodes. All 24 (23.5%) patients with lymph node metastases had at least one metastatic sentinel lymph node. One-third of node-positive patients had presacral lymph node metastases, one of which was isolated. Seven of these patients (87.5%) had non-endometrioid cancer. Infrarenal lymphadenectomy was performed in 84 (82.4%) patients, 19 of whom (22.6%) had lymph node metastases. Para-aortic lymph node metastases were identified in 10 of these 19 patients (52.6%), but no patient had isolated para-aortic lymph node metastases. An erroneous preoperative evaluation of depth invasion or change in the histological type or grade occurred in 17 (16.7%) patients and lead to a preoperative over-staging. When defined by final histology, 6% of patients with a low-risk and 27% of patients with high-risk profile had lymph node metastases.

Study IV

The percentages of patients with endometrial cancer who underwent surgery and the included patients are shown in Figure 22. Cervical injection, including reinjection of tracer in 43% of patients, resulted in a bilateral detection rate (identification of at least one sentinel lymph node per hemi-pelvis) of 96%. The sentinel lymph node biopsy per se did not result in a conversion to laparotomy or intraoperative complications. The surgical time differed by 33 minutes between surgery for low-risk endometrial cancer with sentinel lymph node biopsy alone and benign hysterectomy in patients matched for BMI and uterine size (114 minutes, range 100–182, vs 81 minutes, 59–147). Sentinel lymph node biopsy alone was associated with a significantly lower incidence of lower extremity lymphoedema than sentinel lymph node biopsy followed by pelvic and infrarenal para-aortic lymphadenectomy (1/76 patients, 1.3% versus 15/83, 18.1%, $p = 0.0003$).



¹At least one / ²none of the following characteristics preoperatively found: FIGO grade 3, FIGO stage \geq Ib, DNA non-diploidy or non-endometrioid histology

Figure 22
Overview of the planned surgical approach in endometrial cancer patients (n = 278) at a tertiary referral gynaecological centre, distribution of high- and low-risk endometrial cancer patients and extent of the lymphadenectomies performed in enrolled patients (marked with grey background)

Further results

In February 2015, a new version of the surgical robot, the da Vinci® Xi, was installed at Skåne University Hospital, Lund, Sweden. This new system enables multi-quadrant procedures without replacing the system, and a new technique for the para-aortic lymphadenectomy was developed. The robot was placed at the right side of the patient. The robot arms were placed in a line at the height of the umbilicus, with one assistant's port placed at Palmer's point and the other above the symphysis. With the camera looking cranially, the peritoneum was opened at the aortic bifurcation. The ureters, inferior mesenteric artery and hypogastric nerve fibres were identified before the inframesenteric and infrarenal para-aortic lymphadenectomy was performed. Of the 64 high-risk patients scheduled to receive a full lymphadenectomy using the Xi robot and operated on between February 2015 and December 2016, an infrarenal lymphadenectomy was performed in 60 patients (93.8%), inframesenteric lymphadenectomy in three patients (4.7%) and pelvic only in one patient (1.5%).

The study "Near-infrared fluorescent technique for sentinel lymph node mapping in endometrial cancer" using ICG is still recruiting patients. To reach a clinically relevant and sufficiently low confidence level for sensitivity, 50 patients with lymph node metastases who received at least pelvic lymphadenectomy should be included. This goal should be achieved in summer 2018 and will be facilitated by the fact that Karolinska University Hospital, Stockholm, Sweden, was integrated into this prospective trial and started recruiting patients in February 2017. A multicentre database has been constructed to analyse risk factors further for recurrence and poor patient outcome.

Discussion

This thesis shows that robot-assisted pelvic and infrarenal lymphadenectomy is feasible and safe. Given its feasibility and safety, and the rediscovered knowledge about two bilateral pelvic lymphatic pathways, an anatomically based surgical algorithm for detection of sentinel lymph nodes in endometrial cancer has been developed. The use of cervical ICG injection and reinjection of tracer in patients with failed uptake resulted in the highest bilateral detection rate described for the use of ICG. The applied algorithm identified all patients with lymph node metastases, had a high feasibility and caused no intraoperative complications. The risk for lower extremity lymphoedema was decreased by 93% after sentinel lymph node biopsy alone when compared with full pelvic and para-aortic lymphadenectomy. The feasibility and safety of sentinel lymph node biopsy support the implementation of the sentinel lymph node concept in low-risk patients with endometrial cancer.

Feasibility of robot-assisted lymphadenectomy

An infrarenal robot-assisted para-aortic lymphadenectomy is feasible in most high-risk endometrial cancer patients, but the odds of a favourable outcome are reduced in obese patients and in those operated on by an inexperienced surgeon. Unpublished data show that implementation of the new surgical robot has led to a clinically relevant improvement in the success rate. Our data are in agreement with the results of a recent review that compared total robot-assisted hysterectomy for endometrial cancer to total laparoscopic and abdominal hysterectomy, and found no significant differences in the number of retrieved lymph nodes, but a shorter hospital stay, less estimated blood loss and lower complication and readmission rates [71]. The robot-assisted surgical approach is the standard of care for endometrial cancer in Lund as well as in many other centres [142, 147, 173]. However, it is not recommended in patients with disseminated disease [36, 40].

Lymphatic anatomy

Two consistent lymphatic pathways with pelvic sentinel lymph nodes exist: an upper paracervical pathway that drains the medial external iliac and/or obturator lymph nodes and a lower paracervical pathway that drains the internal iliac and/or presacral nodes. Another pathway, the non-pelvic infundibulopelvic pathway, runs along the infundibulopelvic ligament to the para-aortic lymph nodes. The upper paracervical pathway is well known, and lymphadenectomy along its basins is performed routinely when indicated for endometrial cancer patients because most lymph node metastases are situated along its course [34, 40, 64].

However, although several historical anatomical studies have shown the lower paracervical pathway and corresponding lymphadenectomy is performed in some centres, many guidelines on operative technique fail to include this pathway [34, 40, 53, 55]. This pathway is important for two reasons. First, with the increasing use of the sentinel lymph node concept in endometrial cancer and forgoing complementary lymphadenectomy, an algorithm must be applied that is based on lymphatic anatomy and therefore includes all pelvic pathways and not only the upper paracervical pathway. Second, the occurrence of isolated para-aortic metastases, which are presumably spread via the infundibulopelvic pathway, is an argument against the implementation of the sentinel lymph node concept because it is more challenging to identify para-aortic sentinel lymph nodes [148]. Isolated para-aortic metastases have been described in 3% of patients in studies in which no presacral lymphadenectomy was performed [65]. Interestingly, in a study in which patients also received presacral lymphadenectomy, the prevalence of isolated para-aortic lymph node metastases was only 1% [34]. The lower paracervical pathway, which continues to the lower para-aortic area, may represent an unrecognized pathway for metastatic spread. Furthermore, it has been shown that pathological ultrastaging increases the detection of micrometastases in endometrial cancer patients [171]. This may also decrease the incidence of isolated para-aortic metastases, but further studies are warranted.

Presacral lymph node metastases were present in 8% of all patients and in 33% of node-positive patients in study III but represented the sole metastatic site in only one patient (1% of all patients, 4% of all node-positive patients). Seven of eight patients (87.5%) with presacral lymph node metastases had non-endometrioid tumours. Presacral lymph node metastases were previously described in 1.5–3% of all patients and in 10–14% of node-positive patients [34, 80]. Further studies are needed to determine the clinical impact of presacral sentinel lymph node detection and lymphadenectomy. It may be the case that only special subgroups of endometrial cancer patients, for example with non-endometrioid histology, benefit from presacral sentinel lymph node detection or lymphadenectomy.

Although the most used algorithm for sentinel lymph node detection does not advocate the need for sentinel lymph node identification along both pelvic lymphatic pathways, studies using this algorithm have also identified presacral sentinel lymph nodes [142, 151, 169].

Tracer injection site

The use of cervical tracer injection produced a significantly higher bilateral sentinel lymph node detection rate than fundal injection (98% vs 80%, $p = 0.005$) and the identification of the same lymphatic pathways and same localization of sentinel lymph nodes.

This finding is in agreement with a recent meta-analysis of sentinel lymph node assessment in endometrial cancer that included 4915 women reporting a significantly higher sentinel lymph node detection rate after cervical injection [148]. This analysis also showed that cervical injection was associated with a significantly lower rate of para-aortic sentinel lymph node detection [148]. However, when considering that the two pelvic lymphatic pathways continue to the lower para-aortic area after exiting the pelvis, a lower inframesenteric para-aortic sentinel lymph node can only be found in the absence of sentinel lymph nodes in the upper and lower paracervical pathways. Infrarenal sentinel lymph nodes represent lymphatic drainage via the infundibulopelvic pathway and can only be defined as sentinel lymph nodes in the absence of a sentinel lymph node in the inframesenteric area. Otherwise, they may represent secondary lymph nodes. Many studies have failed to distinguish between a sentinel lymph node and secondary dyed lymph nodes along the lymphatic pathway, which will accumulate tracer eventually. No patients in this study had an infrarenal para-aortic dyed node in the absence of pelvic sentinel lymph nodes with clear filling of the infundibulopelvic pathway (i.e., a true para-aortic sentinel lymph node). As discussed above, the incidence of true para-aortic isolated lymph node metastases needs to be reassessed in a prospective study of both presacral lymphadenectomy and pathological ultrastaging. None of the patients in this study who underwent full pelvic and infrarenal para-aortic staging presented with isolated para-aortic lymph node metastases. A weakness of study III is the lack of randomization between the tracer injection sites.

Surgical algorithm for sentinel lymph node detection

Based on the uterine lymphatic anatomy and the superiority of cervical injection, a surgical algorithm that included presacral sentinel lymph node detection and reinjection of tracer was developed. The use of this algorithm resulted in a high bilateral sentinel lymph node detection rate and identified all patients with lymph node metastases.

A surgical algorithm was proposed in 2012 that reflected the need to standardize the method of sentinel lymph node biopsy in endometrial cancer [168]. Although this was an improvement because it decreased the false-negative rate from 15% to 2%, it failed to incorporate the lymphatic anatomy. The knowledge of uterine lymphatic anatomy is a logical prerequisite in the development of a standardized sentinel lymph node algorithm. Although the lower paracervical pathway is recognized as an area of possible metastatic spread, studies have failed to include it in an algorithm to detect sentinel lymph nodes in a structured manner [34, 52, 80, 147, 168]. However, presacral sentinel lymph nodes are described more frequently in recent literature on sentinel lymph node detection in endometrial cancer [142, 169].

The described algorithm using cervical tracer injection and reinjection, when necessary, resulted in a high bilateral detection rate when applying the most common definition of the identification of one sentinel lymph node per hemi-pelvis. A high technical success rate is necessary when applying the sentinel lymph node concept with the aim of decreasing the need for complementary lymphadenectomy.

However, considering the lymphatic anatomy, the surgeon should strive to identify one sentinel lymph node per pelvic pathway. Even with cervical injection and reinjection, this was achieved in only 66% of patients, mostly because of failure to identify the lower paracervical pathway. Further research is warranted to improve the detection rate of sentinel lymph nodes bilaterally along both pathways and to assess its need in subgroups of endometrial cancer patients. The development of fluorescent tracers may make it easier to identify through un-dissected tissue and may improve sentinel lymph node detection along the lower paracervical pathway.

No false-negative sentinel lymph nodes were found in this study when evaluating the patients individually. However, when evaluating each pathway separately, two cases of non-metastatic sentinel lymph nodes in the upper paracervical pathway were identified in which secondary lymph nodes in the same pathway were metastatic. Metastatic sentinel lymph nodes were identified in another pathway. Further studies are warranted to determine the best way to minimize the rate of false-negative sentinel lymph nodes while retaining the clinical advantages that the sentinel lymph node concept implies.

Preoperative assessment is crucial to identifying patients at high risk for lymph node metastases when following the current guidelines [36]. In this study, 16% of patients were over-staged and 23% were under-staged. Discrepancies in the assessment of myometrial or cervical invasion and pathology evaluation pre- and postoperatively have been previously described but are not often mentioned in clinical studies [42, 46]. Ballester reported that 21% of patients were under-staged and 27% over-staged after comparing preoperative assessment with the final histology [43]. A reliable sentinel lymph node concept renders preoperative risk assessment unnecessary and prevents both under- and overtreatment.

The performance of sentinel lymph node biopsy took about 30 minutes, which is consistent with the 3 to 40 minutes reported by other studies [148]. The sentinel lymph node concept renders lymph node metastasis detection possible in low-risk endometrial cancer patients, implies a tailored surgical approach without the risk for over- or undertreatment and will probably not cause intraoperative complications related to the sentinel lymph node procedure per se. Therefore, this additional surgical time seems to be worthwhile.

Lymphatic complications following lymphadenectomy or sentinel lymph node biopsy

Lower extremity lymphoedema was the most common lymphatic complication following full lymphadenectomy; the incidence was 14–18%, but this was significantly reduced to 1.3% following sentinel lymph node biopsy alone.

Only recently has interest focused on lymphatic complications following lymphadenectomy in endometrial cancer in the medical community [37, 93]. A wide range in the incidence of lower extremity lymphoedema following endometrial cancer surgery has been reported, probably because of the lack of generally accepted standardized terminology [37]. Our results are within the range of the 12.8–42.4% reported by other prospective studies of lymphoedema. Limitations of our study were the lack of baseline measurements and the fact that only patients with either self-reported lymphedema or clinical findings were referred to a specialized unit.

Performing sentinel lymph node biopsy alone implied a 93% decreased risk of developing a lower extremity lymphoedema compared with full pelvic and infrarenal lymphadenectomy. To the best of my knowledge, no studies have assessed the incidence of morbidity following sentinel lymph node biopsy in endometrial cancer patients.

The second most common lymphatic complication following lymphadenectomy was the development of lymphoceles. The incidence decreased to 2.6% after

sentinel lymph node biopsy alone; this compares favourably with the incidence of 13.3% for complications after infrarenal para-aortic and pelvic lymphadenectomy. Lymphoceles were reported to occur in 6–14% of patients after lymphadenectomy [86, 96]. One patient in this study required antibiotic treatment of a pelvic lymphocele after sentinel lymph node biopsy, which shows that the potential for lymphatic complications remains even with a limited procedure.

Conclusions

- Robot-assisted pelvic and infrarenal para-aortic lymphadenectomy is feasible in most patients and produces a lymph node yield and complication rate similar to or better than those of alternative approaches. The surgeon's inexperience and high BMI reduce the success rate, which suggests that this procedure should be performed only in high-volume centres. Unpublished results show that more experience and further development of the surgical robot with enhanced range of motion decreases the failure rate in para-aortic lymphadenectomy to 1.5%.
- Two consistent uterine pelvic lymphatic pathways exist: an upper paracervical pathway with draining medial external iliac and/or obturator lymph nodes, and a lower paracervical pathway with draining internal iliac and/or presacral lymph nodes.
- The pelvic pathways and positions of pelvic sentinel lymph nodes can be depicted independently of the tracer injection site. However, the cervical injection of tracer produced a significantly higher bilateral detection rate of sentinel lymph nodes and is preferable over fundal injection.
- The described anatomically based surgical algorithm for pelvic sentinel lymph node detection, including presacral dissection and reinjection of tracer, resulted in a bilateral detection rate of 96% and identified all patients with lymph node metastases.
- The described algorithm has a high technical success rate and a low risk of complications, which support the implementation of this concept for the detection of sentinel lymph nodes in low-risk endometrial cancer patients. Further studies are needed to confirm the preliminary data on the sensitivity and false-negative rates before applying the sentinel lymph node concept as the standard of care in high-risk patients.
- A 93% decreased risk for lower extremity lymphoedema occurred following sentinel lymph node biopsy alone (1.3%) compared with full lymphadenectomy (18% in study IV).

Future aspects

Although recent research and this thesis have provided substantial data for the validation of the sentinel lymph node algorithm, there are several aspects that need to be addressed before and while implementing this method as the standard of care in endometrial cancer patients.

In our ongoing study of “Near-infrared fluorescent technique for sentinel lymph node mapping in endometrial cancer”, 50 patients with lymph node metastases who received at least complementary pelvic lymphadenectomy must be included to enable evaluation of the described algorithm in terms of the false-negative rate and sensitivity, and the clinically sufficient lower confidence level to test whether this is a reliable method for analysing sentinel lymph nodes. We hope that this goal will be achieved in summer 2018.

The algorithm described for identification of sentinel lymph nodes including reinjection of tracer had the highest bilateral detection rate reported after use of ICG only, but identification of all four pelvic pathways was possible in only two-thirds of patients. Further development of tracers and cameras to improve sentinel lymph node identification may improve the detection rate. A high detection rate will help to reduce the number of complementary lymphadenectomies needed in patients for whom sentinel lymph node detection has failed.

Although ultrastaging of sentinel lymph nodes improves the detection of micrometastases, the clinical significance of low-volume metastases remains unclear [153, 154, 171, 173, 176, 177]. Prospective trials are needed to investigate the effects of low-volume disease on oncological outcomes and the benefits of adjuvant therapy in these patients [153]. In the study by St Clair et al., patients with isolated tumour cells or micrometastases had a better 3-year recurrence-free survival than did those with macrometastases, but all patients were considered to have stage IIIC disease and received adjuvant treatment [177]. The natural history of untreated low-volume metastasis is unclear. A small study of 10 patients with low-risk endometrial cancer and isolated tumour cells in sentinel lymph nodes showed a 3-year progression-free survival of 100% for those who received either vault brachytherapy only or no adjuvant treatment [176].

Another question to be addressed is the role of complementary lymphadenectomy in patients with metastatic sentinel lymph nodes [154]. Although randomized

controlled trials have shown no therapeutic effects of lymphadenectomy, several retrospective trials have reported improved survival after lymphadenectomy [6, 7, 75, 76]. A retrospective study reported that sentinel lymph node biopsy was associated with similar oncological outcome compared with lymphadenectomy, but the study did not state clearly whether restaging was performed in cases of metastatic sentinel lymph nodes or was omitted [178]. The prospective French Senti-Endo study did not find a difference in recurrence-free survival in terms of sentinel lymph node status but showed that sentinel lymph node status contributed to differences in surgical management and indications for adjuvant treatment. However, this study may have been insufficiently powered to show a difference in survival [179]. Hopefully, the Selective Targeting of Adjuvant Therapy in Endometrial Cancer (STATEC, NCT02566811) trial, which randomizes patients to receive a hysterectomy with or without pelvic and para-aortic lymphadenectomy, will clarify whether lymphadenectomy is solely diagnostic or also therapeutic [180].

The size of the sentinel lymph node metastasis may be used as a predictor to assess the indication of lymphatic restaging. In the study by Touhami et al., the risk of having further metastatic lymph nodes was only 5% when the size of the sentinel lymph node metastasis was ≤ 2 mm [181]. It has been argued that systematic lymphadenectomy should be considered only in patients with macrometastases. However, another study found a similar incidence of co-existing non-sentinel lymph node metastases in both micro- and macrometastases, and further research is warranted [173].

Further prospective studies are needed to assess complementary lymphadenectomy in patients with metastatic sentinel lymph nodes, the significance and treatment of low-volume metastatic disease and whether the value of a sentinel lymph node algorithm in endometrial cancer improves survival or prevents morbidity or, it is hoped, both.

Research on new biomarkers, for example L1CAM, has shown promising results. Prospective trials that consider L1CAM in the selection and initiation of adjuvant treatment are needed to assess the clinical significance of L1CAM immunostaining and other predictive biomarkers. Because blood samples were collected prospectively from all enrolled patients in the ongoing study, retrospective analyses of the significance of biomarkers, such as L1CAM and stathmin level, may help to expand this area of research [122]. Large, prospectively collected biobanks with multiple data samples per patient are needed in further research of potential prognostic, predictive and pharmacodynamic biomarkers [182]. Integration of molecular classifications of endometrial carcinoma with pathology diagnoses may improve the assessment of prognosis and need for adjuvant treatment, although further prospective studies are warranted [27, 31, 33].

Acknowledgements

The contribution of many people made this thesis possible, and I wish to thank everyone sincerely and express my special gratitude to the following people.

The **patients** who participated. They made the studies possible. It was an honour to meet so many wonderful women who willingly participated and took an interest in this research.

My supervisor, Associate Professor **Jan Persson**. Your capability, thoroughness and diligence are outstanding. You were always there for me when needed these past years. I thank you for your patience in guiding me through both the academic and clinical work.

My co-supervisor **Thomas Bossmar** for listening to my questions and problems. Thank you for taking the time to answer my questions and helping me to solve the problems.

My co-supervisor **Bengt Lindahl** both for your academic help and for your clinical guidance in the beginning of my career as a gynaecologist. I refer to you often inside the operation room and still miss your cheerfulness.

My co-supervisor **Anna Måsbäck** for your help with the pathological aspects of the studies and answering my questions about pathology.

Céline Lönnerfors for your clinical and academic guidance in these past years. You are an extraordinary person. I am inspired by our work together and our friendship.

Michele Bollino for your help and co-authorship. I look forward to continuing the academic work together.

Pétur Reynisson for your clinical help through the years. Your delight in operating and anatomy is stimulating!

Päivi Kannisto, Christer Borgfeldt, Peter Hinsell, Mats Jernetz and Eimantas Svedas for your guidance with my clinical work. I feel blessed to be part of a team whose members I admire all for their individual qualities.

Louise Moberg for caring and knocking on my door these past months and making the process of writing this thesis a more pleasurable one.

All other members of “**Tumörteamet**” for being part of a stimulating, inspiring and industrious team.

Jana Brodzski for many good conversations while sharing a room for a decade.

The **staff** at the **operating theatre** for your patience when starting our studies, your enthusiasm at improving the practical details, your knowledge and your kindness.

Jennie Ekeberg, Elisabeth Lindsjö, Kjersti Asmundsson and Therese Persson. You always give me a smile when we meet between operations, and it is a pleasure to work with you. Thank you for your practical help with the studies, too.

The **gynaecological ward staff** for your practical help with the study.

Lefterija Dimovska for your practical work with the studies and your kindness.

Louise Fife Aardal for your generous and outstanding help with the English language.

Marie, Lena, Sylvia, Gitte and Agneta for your help with planning and conducting the follow-up of patients included in the studies.

Jonas Björk for your help with statistics.

Caroline Heijl, Cecilia Dietsch, Christine Ekdahl Clementson, Margareta Heby and Maria Värendh. Our group has supported and inspired me many times for more than a decade. Thank you for listening.

My parents, **Adelheid** and **Christian Geppert**, for always being there, having confidence in me and supporting me. You showed me that it is possible to be caring parents *and* good doctors, and encouraged me to pursue my dream of being both, too.

My parents-in-law, **Anette Wennström** and **Staffan Nilsson**, for welcoming me with open arms into your family and for your help through the years.

And, finally, the most important people in my life.

My children **Paula, Felix** and **Emma**. Thank you for reminding me each day what is important in life. You fill my heart with joy and happiness. *“Zeit, die nicht mit dem Herzen wahrgenommen wird, ist so verloren, wie die Farben eines Regenbogens für einen Blinden.”** Wenn ich mit Euch zusammen bin, nehme ich die Zeit mit dem Herzen wahr.

My husband **Daniel Nilsson** for being the best husband I could ever have dreamed of. You make me laugh, hold me when needed and are my best friend. Without your support, help and understanding, this would never have been possible. Ich liebe Dich.

**Momo*, Michael Ende, Thienemann 1973

References

- [1] Cancerfonden. Cancer i siffror - Populärvetenskapliga fakta om cancer: Socialstyrelsen; 2013.
- [2] Siegel RL, Miller KD, Jemal A. Cancer Statistics, 2017. *CA Cancer J Clin.* 2017;67(1):7-30.
- [3] Creasman WT, Morrow CP, Bundy BN, Homesley HD, Graham JE, Heller PB. Surgical pathologic spread patterns of endometrial cancer. A Gynecologic Oncology Group Study. *Cancer.* 1987;60(8 Suppl):2035-41.
- [4] Creasman WT, Mutch DE, Herzog TJ. ASTEC lymphadenectomy and radiation therapy studies: are conclusions valid? *Gynecol Oncol.* 2010;116(3):293-4.
- [5] FIGO Stages - 1988 Revision. *Gynecol Oncol.* 1989;35:125-7.
- [6] Benedetti Panici P, Basile S, Maneschi F, Alberto Lissoni A, Signorelli M, Scambia G, et al. Systematic pelvic lymphadenectomy vs. no lymphadenectomy in early-stage endometrial carcinoma: randomized clinical trial. *J Natl Cancer Inst.* 2008;100(23):1707-16.
- [7] Kitchener H, Swart AM, Qian Q, Amos C, Parmar MK. Efficacy of systematic pelvic lymphadenectomy in endometrial cancer (MRC ASTEC trial): a randomised study. *Lancet.* 2009;373(9658):125-36.
- [8] AlHilli MM, Mariani A. The role of para-aortic lymphadenectomy in endometrial cancer. *Int J Clin Oncol.* 2013;18(2):193-9.
- [9] Falcone F, Balbi G, Di Martino L, Grauso F, Salzillo ME, Messalli EM. Surgical management of early endometrial cancer: an update and proposal of a therapeutic algorithm. *Med Sci Monit.* 2014;20:1298-313.
- [10] Gould EA, Winship T, Philbin PH, Kerr HH. Observations on a "sentinel node" in cancer of the parotid. *Cancer.* 1960;13:77-8.
- [11] Burke TW, Levenback C, Tornos C, Morris M, Wharton JT, Gershenson DM. Intraabdominal lymphatic mapping to direct selective pelvic and paraaortic lymphadenectomy in women with high-risk endometrial cancer: results of a pilot study. *Gynecol Oncol.* 1996;62(2):169-73.
- [12] Shaw E, Farris M, McNeil J, Friedenreich C. Obesity and Endometrial Cancer. *Recent Results Cancer Res.* 2016;208:107-36.
- [13] Swerdlow AJ, Jones ME, British Tamoxifen Second Cancer Study G. Tamoxifen treatment for breast cancer and risk of endometrial cancer: a case-control study. *J Natl Cancer Inst.* 2005;97(5):375-84.
- [14] Lambe M, Wu J, Weiderpass E, Hsieh CC. Childbearing at older age and endometrial cancer risk (Sweden). *Cancer Causes Control.* 1999;10(1):43-9.

- [15] Gong TT, Wang YL, Ma XX. Age at menarche and endometrial cancer risk: a dose-response meta-analysis of prospective studies. *Sci Rep*. 2015;5:14051.
- [16] Mutch D, Denny L, Quinn M, Oncology FCoG. Hereditary gynecologic cancers. *Int J Gynaecol Obstet*. 2014;124(3):189-92.
- [17] Soini T, Hurskainen R, Grenman S, Maenpaa J, Paavonen J, Pukkala E. Cancer risk in women using the levonorgestrel-releasing intrauterine system in Finland. *Obstet Gynecol*. 2014;124(2 Pt 1):292-9.
- [18] Iversen L, Sivasubramaniam S, Lee AJ, Fielding S, Hannaford PC. Lifetime cancer risk and combined oral contraceptives: the Royal College of General Practitioners' Oral Contraception Study. *Am J Obstet Gynecol*. 2017;216(6):580 e1- e9.
- [19] Wu QJ, Li YY, Tu C, Zhu J, Qian KQ, Feng TB, et al. Parity and endometrial cancer risk: a meta-analysis of epidemiological studies. *Sci Rep*. 2015;5:14243.
- [20] Nead KT, Sharp SJ, Thompson DJ, Painter JN, Savage DB, Semple RK, et al. Evidence of a Causal Association Between Insulinemia and Endometrial Cancer: A Mendelian Randomization Analysis. *J Natl Cancer Inst*. 2015;107(9).
- [21] Luo J, Beresford S, Chen C, Chlebowski R, Garcia L, Kuller L, et al. Association between diabetes, diabetes treatment and risk of developing endometrial cancer. *Br J Cancer*. 2014;111(7):1432-9.
- [22] Morice P, Leary A, Creutzberg C, Abu-Rustum N, Darai E. Endometrial cancer. *Lancet*. 2016;387(10023):1094-108.
- [23] Epstein E, Valentin L. Managing women with post-menopausal bleeding. *Best Pract Res Clin Obstet Gynaecol*. 2004;18(1):125-43.
- [24] Dijkhuizen FP, Mol BW, Brolmann HA, Heintz AP. The accuracy of endometrial sampling in the diagnosis of patients with endometrial carcinoma and hyperplasia: a meta-analysis. *Cancer*. 2000;89(8):1765-72.
- [25] Bokhman JV. Two pathogenetic types of endometrial carcinoma. *Gynecol Oncol*. 1983;15(1):10-7.
- [26] Suarez AA, Felix AS, Cohn DE. Bokhman Redux: Endometrial cancer "types" in the 21st century. *Gynecol Oncol*. 2017;144(2):243-9.
- [27] Murali R, Soslow RA, Weigelt B. Classification of endometrial carcinoma: more than two types. *Lancet Oncol*. 2014;15(7):e268-78.
- [28] Creasman WT, Ali S, Mutch DG, Zaino RJ, Powell MA, Mannel RS, et al. Surgical-pathological findings in type 1 and 2 endometrial cancer: An NRG Oncology/Gynecologic Oncology Group study on GOG-210 protocol. *Gynecol Oncol*. 2017;145(3):519-25.
- [29] Kandoth C, Schultz N, Cherniack AD, Akbani R, Liu Y, Shen H, et al. Cancer Genome Atlas Research Network: Integrated genomic characterization of endometrial carcinoma. *Nature*. 2013;497(7447):67-73.
- [30] Lheureux S, Oza AM. Endometrial cancer-targeted therapies myth or reality? Review of current targeted treatments. *Eur J Cancer*. 2016;59:99-108.
- [31] Piulats JM, Guerra E, Gil-Martin M, Roman-Canal B, Gatiús S, Sanz-Pamplona R, et al. Molecular approaches for classifying endometrial carcinoma. *Gynecol Oncol*. 2017;145(1):200-7.

- [32] Bellone S, Bignotti E, Lonardi S, Ferrari F, Centritto F, Masserdotti A, et al. Polymerase epsilon (POLE) ultra-mutation in uterine tumors correlates with T lymphocyte infiltration and increased resistance to platinum-based chemotherapy in vitro. *Gynecol Oncol.* 2017;144(1):146-52.
- [33] Cosgrove CM, Cohn DE, Goodfellow PJ. Primum non nocere: Are we ready for POLE testing in endometrial cancer? *Gynecol Oncol.* 2017;147(2):240-2.
- [34] Hirahatake K, Hareyama H, Sakuragi N, Nishiya M, Makinoda S, Fujimoto S. A clinical and pathologic study on para-aortic lymph node metastasis in endometrial carcinoma. *J Surg Oncol.* 1997;65(2):82-7.
- [35] Creasman WT, Odicino F, Maisonneuve P, Quinn MA, Beller U, Benedet JL, et al. Carcinoma of the Corpus Uteri. *International Journal of Gynecology & Obstetrics.* 2006;95:S105-S43.
- [36] Colombo N, Creutzberg C, Amant F, Bosse T, Gonzalez-Martin A, Ledermann J, et al. ESMO-ESGO-ESTRO Consensus Conference on Endometrial Cancer: Diagnosis, Treatment and Follow-up. *Int J Gynecol Cancer.* 2016;26(1):2-30.
- [37] Lindqvist E, Wedin M, Fredrikson M, Kjolhede P. Lymphedema after treatment for endometrial cancer - A review of prevalence and risk factors. *Eur J Obstet Gynecol Reprod Biol.* 2017;211:112-21.
- [38] Ghezzi F, Uccella S, Cromi A, Bogani G, Robba C, Serati M, et al. Lymphoceles, lymphorrhea, and lymphedema after laparoscopic and open endometrial cancer staging. *Ann Surg Oncol.* 2012;19(1):259-67.
- [39] Larson Dale BR, Shaw G, Krawisz B. Prognostic Significance of DNA Ploidy in Endometrial Cancer. *Gynecol Oncol.* 1999;74:356-60.
- [40] Koh W, Abu-Rustum N, Bean S, Bradley K, Campos S, Cho K, et al. Uterine Neoplasms - NCCN Clinical Practice Guidelines in Oncology. National comprehensive Cancer Network. 2017 (Version 1.2018).
- [41] Eltabbakh GH, Shamonki J, Mount SL. Surgical stage, final grade, and survival of women with endometrial carcinoma whose preoperative endometrial biopsy shows well-differentiated tumors. *Gynecol Oncol.* 2005;99(2):309-12.
- [42] Leita MM, Jr., Kehoe S, Barakat RR, Alektiar K, Gattoc LP, Rabbitt C, et al. Accuracy of preoperative endometrial sampling diagnosis of FIGO grade 1 endometrial adenocarcinoma. *Gynecol Oncol.* 2008;111(2):244-8.
- [43] Ballester M, Naoura I, Chereau E, Seror J, Bats AS, Bricou A, et al. Sentinel node biopsy upstages patients with presumed low- and intermediate-risk endometrial cancer: results of a multicenter study. *Ann Surg Oncol.* 2013;20(2):407-12.
- [44] Gilks CB, Oliva E, Soslow RA. Poor interobserver reproducibility in the diagnosis of high-grade endometrial carcinoma. *Am J Surg Pathol.* 2013;37(6):874-81.
- [45] Savelli L, Ceccarini M, Ludovisi M, Fruscella E, De Iaco PA, Salizzoni E, et al. Preoperative local staging of endometrial cancer: transvaginal sonography vs. magnetic resonance imaging. *Ultrasound Obstet Gynecol.* 2008;31(5):560-6.
- [46] Ortoft G, Dueholm M, Mathiesen O, Hansen ES, Lundorf E, Moller C, et al. Preoperative staging of endometrial cancer using TVS, MRI, and hysteroscopy. *Acta Obstet Gynecol Scand.* 2013;92(5):536-45.

- [47] Bjurberg M, Hinsell P, Söderström A, Koul A, Larsson G, Måsbäck A, et al. Vårdprogram för endometriecancer (corpuscancer) och uterusarkom (in Swedish). 2012.
- [48] Cancercentrum. Livmoderkroppscancer (Endometriecancer) Nationellt vårdprogram (in Swedish): Cancercentrum; 2017 [20171010].
- [49] Creasman W. Revised FIGO staging for carcinoma of the endometrium. *Int J Gynaecol Obstet*. 2009;105(2):109.
- [50] Lewin SN. Revised FIGO staging system for endometrial cancer. *Clin Obstet Gynecol*. 2011;54(2):215-8.
- [51] Henriksen E. The lymphatic spread of carcinoma of the cervix and of body of the uterus. *Am J Obstet Gynecol*. 1949;58(5):924-42.
- [52] Henriksen E. The lymphatic dissemination in endometrial carcinoma. A study of 188 necropsies. *Am J Obstet Gynecol*. 1975;15(123):570-6.
- [53] Peiser E. Anatomische und klinische Untersuchungen über den Lymphapparat des Uterus mit besonderer Berücksichtigung der Totalexstirpation bei Carcinoma uteri. *Zeitschrift für Geburtshilfe und Gynäkologie*. 1898;39:259-325.
- [54] Bruhns C. Über die Lymphgefäße der weiblichen Genitalien nebst einigen Bemerkungen über die Topographie der Leistendrüsen. *Archiv für Anatomie und Physiologie*. 1898:57-83.
- [55] Delamere G. *The Lymphatics*. Chicago: W.T. Keener and Co; 1904.
- [56] Leveuf J, Godard H. Les lymphatiques de l'utérus. *Revue de Chirurgie*. 1923:219-24.
- [57] Ackerman LV, Regato J. *Cancer. Diagnosis, Treatment and Prognosis*. St Louis: The CV Mosby Company; 1947.
- [58] Reiffenstahl G. *Lymphatics of the Female Genital Organs*: JB Lippincott Co, USA; 1965.
- [59] Lucas-Championniere. *Lymphatique utérine*. Paris 1870.
- [60] Kroemer P. Die Lymphorgane der weiblichen Genitalien und ihre Veränderungen bei malignen Erkrankungen des Uterus. *Archiv für Gynaekologie*. 1904;73:57-158.
- [61] Plentl AA, Friedman EA. Lymphatic system of the female genitalia. The morphologic basis of oncologic diagnosis and therapy. *Major Probl Obstet Gynecol*. 1971;2:1-223.
- [62] Döderlein A, Krönig B. *Operative Gynäkologie*. Leipzig: Verlag von Georg Thieme; 1912.
- [63] Mariani A, Webb MJ, Keeney GL, Podratz KC. Routes of lymphatic spread: a study of 112 consecutive patients with endometrial cancer. *Gynecol Oncol*. 2001;81(1):100-4.
- [64] Fotopoulou C, Savvatis K, Kraetschell R, Schefold JC, Lichtenegger W, Sehouli J. Systematic pelvic and aortic lymphadenectomy in intermediate and high-risk endometrial cancer: lymph-node mapping and identification of predictive factors for lymph-node status. *Eur J Obstet Gynecol Reprod Biol*. 2010;149(2):199-203.
- [65] Kumar S, Podratz KC, Bakkum-Gamez JN, Dowdy SC, Weaver AL, McGree ME, et al. Prospective assessment of the prevalence of pelvic, paraaortic and high paraaortic lymph node metastasis in endometrial cancer. *Gynecol Oncol*. 2014;132(1):38-43.

- [66] Walker JL, Piedmonte MR, Spirtos NM, Eisenkop SM, Schlaerth JB, Mannel RS, et al. Laparoscopy compared with laparotomy for comprehensive surgical staging of uterine cancer: Gynecologic Oncology Group Study LAP2. *J Clin Oncol.* 2009;27(32):5331-6.
- [67] Lu Q, Liu H, Liu C, Wang S, Li S, Guo S, et al. Comparison of laparoscopy and laparotomy for management of endometrial carcinoma: a prospective randomized study with 11-year experience. *J Cancer Res Clin Oncol.* 2013;139(11):1853-9.
- [68] Zullo F, Falbo A, Palomba S. Safety of laparoscopy vs laparotomy in the surgical staging of endometrial cancer: a systematic review and metaanalysis of randomized controlled trials. *Am J Obstet Gynecol.* 2012;207(2):94-100.
- [69] Walker JL, Piedmonte MR, Spirtos NM, Eisenkop SM, Schlaerth JB, Mannel RS, et al. Recurrence and survival after random assignment to laparoscopy versus laparotomy for comprehensive surgical staging of uterine cancer: Gynecologic Oncology Group LAP2 Study. *J Clin Oncol.* 2012;30(7):695-700.
- [70] Janda M, Gebiski V, Davies LC, Forder P, Brand A, Hogg R, et al. Effect of Total Laparoscopic Hysterectomy vs Total Abdominal Hysterectomy on Disease-Free Survival Among Women With Stage I Endometrial Cancer: A Randomized Clinical Trial. *JAMA.* 2017;317(12):1224-33.
- [71] Park DA, Lee DH, Kim SW, Lee SH. Comparative safety and effectiveness of robot-assisted laparoscopic hysterectomy versus conventional laparoscopy and laparotomy for endometrial cancer: A systematic review and meta-analysis. *Eur J Surg Oncol.* 2016;42(9):1303-14.
- [72] Ind T, Laios A, Hacking M, Nobbenhuis M. A comparison of operative outcomes between standard and robotic laparoscopic surgery for endometrial cancer: A systematic review and meta-analysis. *Int J Med Robot.* 2017.
- [73] Iavazzo C, Gkegkes ID. Robotic assisted hysterectomy in obese patients: a systematic review. *Arch Gynecol Obstet.* 2016;293(6):1169-83.
- [74] Naumann RW. The role of lymphadenectomy in endometrial cancer: was the ASTEC trial doomed by design and are we destined to repeat that mistake? *Gynecol Oncol.* 2012;126(1):5-11.
- [75] Chan JK, Wu H, Cheung MK, Shin JY, Osann K, Kapp DS. The outcomes of 27,063 women with unstaged endometrioid uterine cancer. *Gynecol Oncol.* 2007;106(2):282-8.
- [76] Kilgore LC, Partridge EE, Alvarez RD, Austin JM, Shingleton HM, Noojin F, 3rd, et al. Adenocarcinoma of the endometrium: survival comparisons of patients with and without pelvic node sampling. *Gynecol Oncol.* 1995;56(1):29-33.
- [77] Todo Y, Kato H, Kaneuchi M, Watari H, Takeda M, Sakuragi N. Survival effect of para-aortic lymphadenectomy in endometrial cancer (SEPAL study): a retrospective cohort analysis. *Lancet.* 2010;375(9721):1165-72.
- [78] Watari H, Katayama H, Shibata T, Ushijima K, Satoh T, Onda T, et al. Phase III trial to confirm the superiority of pelvic and para-aortic lymphadenectomy to pelvic lymphadenectomy alone for endometrial cancer: Japan Clinical Oncology Group Study 1412 (SEPAL-P3). *Jpn J Clin Oncol.* 2017;47(10):986-90.

- [79] Abu-Rustum NR, Gomez JD, Alektiar KM, Soslow RA, Hensley ML, Leitao MM, Jr., et al. The incidence of isolated paraaortic nodal metastasis in surgically staged endometrial cancer patients with negative pelvic lymph nodes. *Gynecol Oncol.* 2009;115(2):236-8.
- [80] Odagiri T, Watari H, Kato T, Mitamura T, Hosaka M, Sudo S, et al. Distribution of lymph node metastasis sites in endometrial cancer undergoing systematic pelvic and para-aortic lymphadenectomy: a proposal of optimal lymphadenectomy for future clinical trials. *Ann Surg Oncol.* 2014;21(8):2755-61.
- [81] Amant F, Mirza MR, Koskas M, Creutzberg CL. Cancer of the corpus uteri. *Int J Gynaecol Obstet.* 2015;131 Suppl 2:S96-104.
- [82] Larson DM, Johnson K, Olson KA. Pelvic and para-aortic lymphadenectomy for surgical staging of endometrial cancer: morbidity and mortality. *Obstet Gynecol.* 1992;79(6):998-1001.
- [83] Abu-Rustum NR, Alektiar K, Iasonos A, Lev G, Sonoda Y, Aghajanian C, et al. The incidence of symptomatic lower-extremity lymphedema following treatment of uterine corpus malignancies: a 12-year experience at Memorial Sloan-Kettering Cancer Center. *Gynecol Oncol.* 2006;103(2):714-8.
- [84] Tada H, Teramukai S, Fukushima M, Sasaki H. Risk factors for lower limb lymphedema after lymph node dissection in patients with ovarian and uterine carcinoma. *BMC Cancer.* 2009;9:47.
- [85] Konno Y, Todo Y, Minobe S, Kato H, Okamoto K, Sudo S, et al. A retrospective analysis of postoperative complications with or without para-aortic lymphadenectomy in endometrial cancer. *Int J Gynecol Cancer.* 2011;21(2):385-90.
- [86] Backes FJ, Brudie LA, Farrell MR, Ahmad S, Finkler NJ, Bigsby GE, et al. Short- and long-term morbidity and outcomes after robotic surgery for comprehensive endometrial cancer staging. *Gynecol Oncol.* 2012;125(3):546-51.
- [87] Yost KJ, Cheville AL, Al-Hilli MM, Mariani A, Barrette BA, McGree ME, et al. Lymphedema after surgery for endometrial cancer: prevalence, risk factors, and quality of life. *Obstet Gynecol.* 2014;124(2 Pt 1):307-15.
- [88] Todo Y, Yamazaki H, Takeshita S, Ohba Y, Sudo S, Minobe S, et al. Close relationship between removal of circumflex iliac nodes to distal external iliac nodes and postoperative lower-extremity lymphedema in uterine corpus malignant tumors. *Gynecol Oncol.* 2015;139(1):160-4.
- [89] Menderes G, Azodi M, Schwartz P, Silasi DA. Comparison of lymphedema incidence between 2 lymphadenectomy techniques in patients with uterine cancer undergoing robotic staging. *Int J Gynecol Cancer.* 2015;25(1):160-5.
- [90] Hopp EE, Osborne JL, Schneider DK, Bojar CJ, Uyar DS. A prospective pilot study on the incidence of post-operative lymphedema in women with endometrial cancer. *Gynecol Oncol Rep.* 2016;15:25-8.
- [91] Bae HS, Lim MC, Lee JS, Lee Y, Nam BH, Seo SS, et al. Postoperative Lower Extremity Edema in Patients with Primary Endometrial Cancer. *Ann Surg Oncol.* 2016;23(1):186-95.

- [92] Mendivil AA, Rettenmaier MA, Abaid LN, Brown JV, 3rd, Micha JP, Lopez KL, et al. Lower-extremity lymphedema following management for endometrial and cervical cancer. *Surg Oncol.* 2016;25(3):200-4.
- [93] Hayes SC, Janda M, Ward LC, Reul-Hirche H, Steele ML, Carter J, et al. Lymphedema following gynecological cancer: Results from a prospective, longitudinal cohort study on prevalence, incidence and risk factors. *Gynecol Oncol.* 2017;146(3):623-9.
- [94] Biglia N, Zanfagnin V, Daniele A, Robba E, Bounous VE. Lower Body Lymphedema in Patients with Gynecologic Cancer. *Anticancer Res.* 2017;37(8):4005-15.
- [95] Kim HY, Kim JW, Kim SH, Kim YT, Kim JH. An analysis of the risk factors and management of lymphocele after pelvic lymphadenectomy in patients with gynecologic malignancies. *Cancer Res Treat.* 2004;36(6):377-83.
- [96] Zikan M, Fischerova D, Pinkavova I, Slama J, Weinberger V, Dusek L, et al. A prospective study examining the incidence of asymptomatic and symptomatic lymphoceles following lymphadenectomy in patients with gynecological cancer. *Gynecol Oncol.* 2015;137(2):291-8.
- [97] Baiocchi G, Faloppa CC, Araujo RL, Fukazawa EM, Kumagai LY, Menezes AN, et al. Chylous ascites in gynecologic malignancies: cases report and literature review. *Arch Gynecol Obstet.* 2010;281(4):677-81.
- [98] Yamamoto T, Yamamoto N, Yoshimatsu H, Hayami S, Narushima M, Koshima I. Indocyanine green lymphography for evaluation of genital lymphedema in secondary lower extremity lymphedema patients. *J Vasc Surg Venous Lymphat Disord.* 2013;1(4):400-5 e1.
- [99] Tanaka T, Ohki N, Kojima A, Maeno Y, Miyahara Y, Sudo T, et al. Radiotherapy negates the effect of retroperitoneal nonclosure for prevention of lymphedema of the legs following pelvic lymphadenectomy for gynecological malignancies: an analysis from a questionnaire survey. *Int J Gynecol Cancer.* 2007;17(2):460-4.
- [100] The diagnosis and treatment of peripheral lymphedema: 2016 consensus document of the international society of lymphology. *Lymphology.* 2016;49:170-84.
- [101] Cheville A, McGarvey C, Petrek J, Russo S, Thiadens S, Taylor M. The grading of lymphedema in oncology clinical trials. *Seminars in Radiation Oncology.* 2003;13(3):214-25.
- [102] Hammer SM, Brown JC, Segal S, Chu CS, Schmitz KH. Cancer-related impairments influence physical activity in uterine cancer survivors. *Med Sci Sports Exerc.* 2014;46(12):2195-201.
- [103] Rowlands IJ, Janda M, McKinnon L, Webb PM, Beesley VL, Australian National Endometrial Cancer Study G. Prevalence, predictors, and correlates of supportive care needs among women 3-5 years after a diagnosis of endometrial cancer. *Support Care Cancer.* 2015;23(5):1205-14.
- [104] Parkash V, Bifulco C, Feinn R, Concato J, Jain D. To count and how to count, that is the question: interobserver and intraobserver variability among pathologists in lymph node counting. *Am J Clin Pathol.* 2010;134(1):42-9.
- [105] Abu-Rustum NR, Barakat RR. Observations on the role of circumflex iliac node resection and the etiology of lower extremity lymphedema following pelvic lymphadenectomy for gynecologic malignancy. *Gynecol Oncol.* 2007;106(1):4-5.

- [106] Sopracordevole F, Manciola F, Canzonieri V, Buttignol M, Giorda G, Ciavattini A. Laser CO2 treatment for vulvar lymphedema secondary to gynecological cancer therapy: A report of two cases and review of the literature. *Oncol Lett.* 2015;9(4):1889-92.
- [107] Yamamoto T, Yamamoto N, Furuya M, Hayashi A, Koshima I. Genital Lymphedema Score: Genital Lymphedema Severity Scoring System Based on Subjective Symptoms. *Ann Plast Surg.* 2016;77(1):119-21.
- [108] Frey MK, Ward NM, Caputo TA, Taylor J, Worley MJ, Jr., Slomovitz BM. Lymphatic ascites following pelvic and paraaortic lymphadenectomy procedures for gynecologic malignancies. *Gynecol Oncol.* 2012;125(1):48-53.
- [109] Solmaz U, Turan V, Mat E, Dereli ML, Ekin A, Peker N, et al. Chylous ascites following retroperitoneal lymphadenectomy in gynecologic malignancies: incidence, risk factors and management. *Int J Surg.* 2015;16(Pt A):88-93.
- [110] Tulunay G, Ureyen I, Turan T, Karalok A, Kavak D, Ozgul N, et al. Chylous ascites: analysis of 24 patients. *Gynecol Oncol.* 2012;127(1):191-7.
- [111] Kim EA, Park H, Jeong SG, Lee C, Lee JM, Park CT. Octreotide therapy for the management of refractory chylous ascites after a staging operation for endometrial adenocarcinoma. *J Obstet Gynaecol Res.* 2014;40(2):622-6.
- [112] SEER Stat Fact Sheets: Endometrial cancer <https://seer.cancer.gov/statfacts/html/corp.html>: American National Cancer institute, Surveillance, Epidemiology and End Results Program; 2017 [20171010].
- [113] Uterine cancer survival statistics <http://www.cancerresearchuk.org/health-professional/cancer-statistics/statistics-by-cancer-type/uterine-cancer/survival#heading=Zero>: Cancer Research UK; [20171010].
- [114] Sorbe B. Predictive and prognostic factors in definition of risk groups in endometrial carcinoma. *ISRN Obstet Gynecol.* 2012;2012:325790.
- [115] Gynekologisk cancer - Nationell kvalitetsrapport för diagnosåren 2011-Juni 2015 från Svenska Kvalitetsregister för Gynekologisk Cancer: Regionala Cancercentrum i Samverkan; 2016.
- [116] Bosse T, Peters EE, Creutzberg CL, Jurgensliemk-Schulz IM, Jobsen JJ, Mens JW, et al. Substantial lymph-vascular space invasion (LVSI) is a significant risk factor for recurrence in endometrial cancer--A pooled analysis of PORTEC 1 and 2 trials. *Eur J Cancer.* 2015;51(13):1742-50.
- [117] Kommoss F, Kommoss F, Grevenkamp F, Bunz AK, Taran FA, Fend F, et al. L1CAM: amending the "low-risk" category in endometrial carcinoma. *J Cancer Res Clin Oncol.* 2017;143(2):255-62.
- [118] Aristizabal P, Graesslin O, Barranger E, Clavel-Chapelon F, Haddad B, Luton D, et al. A suggested modification to FIGO stage I endometrial cancer. *Gynecol Oncol.* 2014;133(2):192-6.
- [119] Bendifallah S, Perrin M, Ouldamer L, Lavoue V, Canlorbe G, Raimond E, et al. Honing the classification of high-risk endometrial cancer with inclusion of lymphovascular space invasion. *Surg Oncol.* 2017;26(1):1-7.

- [120] Winer I, Ahmed QF, Mert I, Bandyopadhyay S, Cote M, Munkarah AR, et al. Significance of lymphovascular space invasion in uterine serous carcinoma: what matters more; extent or presence? *Int J Gynecol Pathol.* 2015;34(1):47-56.
- [121] Sadozye AH, Harrand RL, Reed NS. Lymphovascular Space Invasion as a Risk Factor in Early Endometrial Cancer. *Curr Oncol Rep.* 2016;18(4):24.
- [122] Werner HM, Trovik J, Halle MK, Wik E, Akslen LA, Birkeland E, et al. Stathmin protein level, a potential predictive marker for taxane treatment response in endometrial cancer. *PLoS One.* 2014;9(2):e90141.
- [123] Pasanen A, Tuomi T, Isola J, Staff S, Butzow R, Loukovaara M. L1 Cell Adhesion Molecule as a Predictor of Disease-Specific Survival and Patterns of Relapse in Endometrial Cancer. *Int J Gynecol Cancer.* 2016;26(8):1465-71.
- [124] Zeimet AG, Reimer D, Huszar M, Winterhoff B, Puistola U, Azim SA, et al. L1CAM in early-stage type I endometrial cancer: results of a large multicenter evaluation. *J Natl Cancer Inst.* 2013;105(15):1142-50.
- [125] Pasanen A, Loukovaara M, Tuomi T, Butzow R. Preoperative Risk Stratification of Endometrial Carcinoma: L1CAM as a Biomarker. *Int J Gynecol Cancer.* 2017;27(7):1318-24.
- [126] Dellinger TH, Smith DD, Ouyang C, Warden CD, Williams JC, Han ES. L1CAM is an independent predictor of poor survival in endometrial cancer - An analysis of The Cancer Genome Atlas (TCGA). *Gynecol Oncol.* 2016;141(2):336-40.
- [127] Bosse T, Nout RA, Stelloo E, Dreef E, Nijman HW, Jurgenliemk-Schulz IM, et al. L1 cell adhesion molecule is a strong predictor for distant recurrence and overall survival in early stage endometrial cancer: pooled PORTEC trial results. *Eur J Cancer.* 2014;50(15):2602-10.
- [128] van der Putten LJ, Visser NC, van de Vijver K, Santacana M, Bronsert P, Bulten J, et al. L1CAM expression in endometrial carcinomas: an ENITEC collaboration study. *Br J Cancer.* 2016;115(6):716-24.
- [129] He X, Liao Y, Lu W, Xu G, Tong H, Ke J, et al. Elevated STMN1 promotes tumor growth and invasion in endometrial carcinoma. *Tumour Biol.* 2016;37(7):9951-8.
- [130] Reyes HD, Miecznikowski J, Gonzalez-Bosquet J, Devor EJ, Zhang Y, Thiel KW, et al. High stathmin expression is a marker for poor clinical outcome in endometrial cancer: An NRG oncology group/gynecologic oncology group study. *Gynecol Oncol.* 2017;146(2):247-53.
- [131] Virchow R. Die krankhaften Geschwülste. Berlin, Germany: August Hirschwald; 1863.
- [132] Braithwaite LR. The flow of lymph from the ileocaecal angle, and its possible bearing on the cause of duodenal and gastric ulcer. *Br J Surg.* 1923;11:7-26.
- [133] Nieweg OE, Uren RF, Thompson JF. The history of sentinel lymph node biopsy. *Cancer J.* 2015;21(1):3-6.
- [134] Tanis PJ, Nieweg OE, Valdes Olmos RA, Th Rutgers EJ, Kroon BB. History of sentinel node and validation of the technique. *Breast Cancer Res.* 2001;3(2):109-12.
- [135] Cabanas RM. An approach for the treatment of penile carcinoma. *Cancer.* 1977;39(2):456-66.

- [136] Weissbach L, Boedefeld EA. Localization of solitary and multiple metastases in stage II nonseminomatous testis tumor as basis for a modified staging lymph node dissection in stage I. *J Urol*. 1987;138(1):77-82.
- [137] Morton DL, Wen DR, Wong JH, Economou JS, Cagle LA, Storm FK, et al. Technical details of intraoperative lymphatic mapping for early stage melanoma. *Arch Surg*. 1992;127(4):392-9.
- [138] Giuliano AE, Kirgan DM, Guenther JM, Morton DL. Lymphatic mapping and sentinel lymphadenectomy for breast cancer. *Ann Surg*. 1994;220(3):391-8; discussion 8-401.
- [139] Moncayo VM, Aarsvold JN, Grant SF, Bartley SC, Alazraki NP. Status of sentinel lymph node for breast cancer. *Semin Nucl Med*. 2013;43(4):281-93.
- [140] Nieweg OE, Cooper A, Thompson JF. Role of sentinel lymph node biopsy as a staging procedure in patients with melanoma: A critical appraisal. *Australas J Dermatol*. 2017.
- [141] Dellinger TH, Hakim AA, Lee SJ, Wakabayashi MT, Morgan RJ, Han ES. Surgical Management of Vulvar Cancer. *J Natl Compr Canc Netw*. 2017;15(1):121-8.
- [142] Rossi EC, Kowalski LD, Scalici J, Cantrell L, Schuler K, Hanna RK, et al. A comparison of sentinel lymph node biopsy to lymphadenectomy for endometrial cancer staging (FIRES trial): a multicentre, prospective, cohort study. *Lancet Oncol*. 2017;18(3):384-92.
- [143] Ballester M, Dubernard G, Lecuru F, Heitz D, Mathevet P, Marret H, et al. Detection rate and diagnostic accuracy of sentinel-node biopsy in early stage endometrial cancer: a prospective multicentre study (SENTI-ENDO). *Lancet Oncol*. 2011;12(5):469-76.
- [144] Rossi EC, Ivanova A, Boggess JF. Robotically assisted fluorescence-guided lymph node mapping with ICG for gynecologic malignancies: a feasibility study. *Gynecol Oncol*. 2012;124(1):78-82.
- [145] Niikura H, Kaiho-Sakuma M, Tokunaga H, Toyoshima M, Utsunomiya H, Nagase S, et al. Tracer injection sites and combinations for sentinel lymph node detection in patients with endometrial cancer. *Gynecol Oncol*. 2013;131(2):299-303.
- [146] Papadia A, Imboden S, Siegenthaler F, Gasparri ML, Mohr S, Lanz S, et al. Laparoscopic Indocyanine Green Sentinel Lymph Node Mapping in Endometrial Cancer. *Ann Surg Oncol*. 2016;23(7):2206-11.
- [147] Hagen B, Valla M, Aune G, Ravlo M, Abusland AB, Araya E, et al. Indocyanine green fluorescence imaging of lymph nodes during robotic-assisted laparoscopic operation for endometrial cancer. A prospective validation study using a sentinel lymph node surgical algorithm. *Gynecol Oncol*. 2016;143(3):479-83.
- [148] Bodurtha Smith AJ, Fader AN, Tanner EJ. Sentinel lymph node assessment in endometrial cancer: a systematic review and meta-analysis. *Am J Obstet Gynecol*. 2017;216(5):459-76 e10.
- [149] Perrone AM, Casadio P, Formelli G, Levorato M, Ghi T, Costa S, et al. Cervical and hysteroscopic injection for identification of sentinel lymph node in endometrial cancer. *Gynecol Oncol*. 2008;111(1):62-7.
- [150] Abu-Rustum NR, Khoury-Collado F, Gemignani ML. Techniques of sentinel lymph node identification for early-stage cervical and uterine cancer. *Gynecol Oncol*. 2008;111(2 Suppl):S44-50.

- [151] Abu-Rustum NR. Sentinel lymph node mapping for endometrial cancer: a modern approach to surgical staging. *J Natl Compr Canc Netw*. 2014;12(2):288-97.
- [152] Frumovitz M, Coleman RC, Soliman PT, Ramirez PT, Levenback CF. A case for caution in the pursuit of the sentinel node in women with endometrial carcinoma. *Gynecol Oncol*. 2014;132(2):275-9.
- [153] Sullivan SA, Rossi EC. Sentinel Lymph Node Biopsy in Endometrial Cancer: a New Standard of Care? *Curr Treat Options Oncol*. 2017;18(10):62.
- [154] Papadia AGM, Mueller MD. Is it time to consider the sentinel lymph node mapping the new standard in endometrial cancer? *Translational cancer research*. 2017;6(Suppl 3):S547-S52.
- [155] Beenen E, de Roy van Zuidewijn DB. Patients blue on patent blue: an adverse reaction during four sentinel node procedures. *Surg Oncol*. 2005;14(4):151-4.
- [156] Momeni R, Ariyan S. Pulse oximetry declines due to intradermal isosulfan blue dye: a controlled prospective study. *Ann Surg Oncol*. 2004;11(4):434-7.
- [157] Holloway RW, Bravo RA, Rakowski JA, James JA, Jeppson CN, Ingersoll SB, et al. Detection of sentinel lymph nodes in patients with endometrial cancer undergoing robotic-assisted staging: a comparison of colorimetric and fluorescence imaging. *Gynecol Oncol*. 2012;126(1):25-9.
- [158] van den Berg NS, Miwa M, KleinJan GH, Sato T, Maeda Y, van Akkooi AC, et al. (Near-Infrared) Fluorescence-Guided Surgery Under Ambient Light Conditions: A Next Step to Embedment of the Technology in Clinical Routine. *Ann Surg Oncol*. 2016;23(8):2586-95.
- [159] Thomsen HS, Bush WH, Jr. Adverse effects of contrast media: incidence, prevention and management. *Drug Saf*. 1998;19(4):313-24.
- [160] Kitai T, Inomoto T, Miwa M, Shikayama T. Fluorescence navigation with indocyanine green for detecting sentinel lymph nodes in breast cancer. *Breast Cancer*. 2005;12(3):211-5.
- [161] Fujiwara M, Mizukami T, Suzuki A, Fukamizu H. Sentinel lymph node detection in skin cancer patients using real-time fluorescence navigation with indocyanine green: preliminary experience. *J Plast Reconstr Aesthet Surg*. 2009;62(10):e373-8.
- [162] Eriksson AG, Montovano M, Beavis A, Soslow RA, Zhou Q, Abu-Rustum NR, et al. Impact of Obesity on Sentinel Lymph Node Mapping in Patients with Newly Diagnosed Uterine Cancer Undergoing Robotic Surgery. *Ann Surg Oncol*. 2016;23(8):2522-8.
- [163] Favero G, Pfiffer T, Ribeiro A, Carvalho JP, Baracat EC, Mechsner S, et al. Laparoscopic sentinel lymph node detection after hysteroscopic injection of technetium-99 in patients with endometrial cancer. *Int J Gynecol Cancer*. 2015;25(3):423-30.
- [164] Sawicki S, Lass P, Wydra D. Sentinel Lymph Node Biopsy in Endometrial Cancer--Comparison of 2 Detection Methods. *Int J Gynecol Cancer*. 2015;25(6):1044-50.
- [165] Signorelli M, Crivellaro C, Buda A, Guerra L, Fruscio R, Elisei F, et al. Staging of High-Risk Endometrial Cancer With PET/CT and Sentinel Lymph Node Mapping. *Clin Nucl Med*. 2015;40(10):780-5.

- [166] Martinelli F, Ditto A, Bogani G, Signorelli M, Chiappa V, Lorusso D, et al. Laparoscopic Sentinel Node Mapping in Endometrial Cancer After Hysteroscopic Injection of Indocyanine Green. *J Minim Invasive Gynecol*. 2017;24(1):89-93.
- [167] Papadia A, Imboden S, Gasparri ML, Siegenthaler F, Fink A, Mueller MD. Endometrial and cervical cancer patients with multiple sentinel lymph nodes at laparoscopic ICG mapping: How many are enough? *J Cancer Res Clin Oncol*. 2016;142(8):1831-6.
- [168] Barlin JN, Khoury-Collado F, Kim CH, Leita MM, Jr., Chi DS, Sonoda Y, et al. The importance of applying a sentinel lymph node mapping algorithm in endometrial cancer staging: beyond removal of blue nodes. *Gynecol Oncol*. 2012;125(3):531-5.
- [169] How J, Boldeanu I, Lau S, Salvador S, How E, Gotlieb R, et al. Unexpected locations of sentinel lymph nodes in endometrial cancer. *Gynecol Oncol*. 2017;147(1):18-23.
- [170] Chan JK, Urban R, Cheung MK, Shin JY, Husain A, Teng NN, et al. Lymphadenectomy in endometrioid uterine cancer staging: how many lymph nodes are enough? A study of 11,443 patients. *Cancer*. 2007;109(12):2454-60.
- [171] Kim CH, Soslow RA, Park KJ, Barber EL, Khoury-Collado F, Barlin JN, et al. Pathologic ultrastaging improves micrometastasis detection in sentinel lymph nodes during endometrial cancer staging. *Int J Gynecol Cancer*. 2013;23(5):964-70.
- [172] Greene; F, Page; D, Fleming; I, Fritz; A, Balch; C, Haller; D, et al. *AJCC Cancer Staging Manual*. 6th ed: Springer; 2002.
- [173] Holloway RW, Gupta S, Stavitzski NM, Zhu X, Takimoto EL, Gubbi A, et al. Sentinel lymph node mapping with staging lymphadenectomy for patients with endometrial cancer increases the detection of metastasis. *Gynecol Oncol*. 2016;141(2):206-10.
- [174] Tanner EJ, Sinno AK, Stone RL, Levinson KL, Long KC, Fader AN. Factors associated with successful bilateral sentinel lymph node mapping in endometrial cancer. *Gynecol Oncol*. 2015;138(3):542-7.
- [175] Dindo D, Demartines N, Clavien PA. Classification of surgical complications: a new proposal with evaluation in a cohort of 6336 patients and results of a survey. *Ann Surg*. 2004;240(2):205-13.
- [176] Plante M, Stanleigh J, Renaud MC, Sebastianelli A, Grondin K, Gregoire J. Isolated tumor cells identified by sentinel lymph node mapping in endometrial cancer: Does adjuvant treatment matter? *Gynecol Oncol*. 2017;146(2):240-6.
- [177] St Clair CM, Eriksson AG, Ducie JA, Jewell EL, Alektiar KM, Hensley ML, et al. Low-Volume Lymph Node Metastasis Discovered During Sentinel Lymph Node Mapping for Endometrial Carcinoma. *Ann Surg Oncol*. 2016;23(5):1653-9.
- [178] Zahl Eriksson AG, Ducie J, Ali N, McGree ME, Weaver AL, Bogani G, et al. Comparison of a sentinel lymph node and a selective lymphadenectomy algorithm in patients with endometrioid endometrial carcinoma and limited myometrial invasion. *Gynecol Oncol*. 2016;140(3):394-9.
- [179] Darai E, Dubernard G, Bats AS, Heitz D, Mathevet P, Marret H, et al. Sentinel node biopsy for the management of early stage endometrial cancer: long-term results of the SENTI-ENDO study. *Gynecol Oncol*. 2015;136(1):54-9.
- [180] Selective Targeting of Adjuvant Therapy in Endometrial Cancer (STATEC) <https://clinicaltrials.gov/ct2/show/NCT025668112017> [20171117].

- [181] Touhami O, Trinh XB, Gregoire J, Sebastianelli A, Renaud MC, Grondin K, et al. Predictors of non-sentinel lymph node (non-SLN) metastasis in patients with sentinel lymph node (SLN) metastasis in endometrial cancer. *Gynecol Oncol.* 2015;138(1):41-5.
- [182] Werner HM, Salvesen HB. Current status of molecular biomarkers in endometrial cancer. *Curr Oncol Rep.* 2014;16(9):403.

Sentinel lymph node biopsy in endometrial cancer

The cover picture, reproduced from a German atlas of gynaecological surgery from 1912, depicts uterine lymphatic anatomy. Given the rising interest in sentinel lymph node biopsy in endometrial cancer, the most common gynaecological malignancy in Sweden and other industrialized countries, knowledge about uterine lymphatic anatomy is needed.



This thesis focuses on the development, feasibility, evaluation and side effects of an anatomically based sentinel lymph node algorithm for endometrial cancer using robot-assisted surgery.

Barbara Geppert is a gynaecologist at Skåne University Hospital, Lund, Sweden. Her special interest is the surgical treatment of gynaecological cancer patients. In her spare time, she enjoys being with her family and reading.



LUND UNIVERSITY
Faculty of Medicine

Department of Obstetrics and Gynaecology

Lund University, Faculty of Medicine
Doctoral Dissertation Series 2018:2
ISBN 978-91-7619-570-3
ISSN 1652-8220

