



LUND UNIVERSITY

FDG-PET in Cervical Cancer - Translational Studies

Bjurberg, Maria

2010

[Link to publication](#)

Citation for published version (APA):

Bjurberg, M. (2010). *FDG-PET in Cervical Cancer - Translational Studies*. [Doctoral Thesis (compilation), Breastcancer-genetics]. Department of Oncology, Clinical Sciences, Lund University.

Total number of authors:

1

General rights

Unless other specific re-use rights are stated the following general rights apply:

Copyright and moral rights for the publications made accessible in the public portal are retained by the authors and/or other copyright owners and it is a condition of accessing publications that users recognise and abide by the legal requirements associated with these rights.

- Users may download and print one copy of any publication from the public portal for the purpose of private study or research.
- You may not further distribute the material or use it for any profit-making activity or commercial gain
- You may freely distribute the URL identifying the publication in the public portal

Read more about Creative commons licenses: <https://creativecommons.org/licenses/>

Take down policy

If you believe that this document breaches copyright please contact us providing details, and we will remove access to the work immediately and investigate your claim.

LUND UNIVERSITY

PO Box 117
221 00 Lund
+46 46-222 00 00

Department of Oncology, Clinical Sciences,
Lund University, Sweden

FDG-PET in Cervical Cancer

Translational Studies

Maria Bjurberg



Thesis 2010

Contact address

Maria Bjurberg, MD
Department of Oncology,
Skåne University Hospital,
Lund, Sweden
Tel. +46 (46)171000
Fax. +46 (46)176079
Mail: maria.bjurberg@med.lu.se

© Maria Bjurberg
Layout by Ortonova AB, Lund

ISSN 1652-8220
ISBN 978-91-86443-65-8
Lund University, Faculty of Medicine Doctoral Dissertation Series 2010:50

Printed in Sweden
Mediatryck, Lund
2010

FDG-PET in Cervical Cancer

Translational Studies

Maria Bjurberg, MD

Department of Oncology, Clinical Sciences,
Lund University, Sweden



LUND UNIVERSITY

Doctoral Thesis

To be publicly defended in the Segerfalk lecture hall, BMC, Sölvegatan 19, Lund
University at 1 pm, Friday May 21st 2010

Faculty Opponent

Professor Seija Grénman
Department of Obstetrics and Gynaecology, Turku University Hospital,
Turku, Finland

Supervisors

Elisabeth Kjellén and Eva Brun,
Department of Oncology, Clinical Sciences,
Lund University, Lund, Sweden

Organization LUND UNIVERSITY	Document name DOCTORAL DISSERTATION	
	Date of issue May 21 2010	
	Sponsoring organization	
Author(s) Maria Bjurberg		
Title and subtitle FDG-PET in Cervical Cancer - Translational Studies		
<p>Abstract</p> <p>Cervical cancer is the second most common cancer in females. The treatment, based on clinical FIGO stage, carries a significant risk of side effects. FDG-PET enables non-invasive studies of glucose metabolism. Cancer cells show an increased glucose uptake and metabolism that can be visualised and further analysed.</p> <p>The aims of this thesis were to evaluate FDG-PET in the clinical management of cervical cancer and to experimentally investigate the metabolic changes in a tumour following cytotoxic treatment.</p> <p>In a prospective study we found that FDG-PET provided important information about the extent of the disease in primary staging of locally advanced cases and in re-staging of recurrent disease. The treatment plans were altered as a result of the FDG-PET findings for one fourth of the patients. Surveillance FDG-PET 6 months after surgery for early-stage disease showed no clinical value. With a predictive FDG-PET early during radiotherapy for locally advanced disease we could identify a group of patients with an excellent prognosis. However, for the majority of the patients early prediction of outcome was not possible. Persisting hypermetabolism on FDG-PET 3 months after completed radiotherapy was associated with relapse.</p> <p>Experimentally, we found a transient metabolic flare in xenografted tumours on day 1 following cisplatin exposure. A metabolic flare in squamous cell carcinoma cells in vitro was found to be an early sign of response to cisplatin treatment. No increase in metabolism was detected in fibroblasts in vitro or in reactive cells in vivo.</p> <p>In conclusion, we have demonstrated a clinical value of FDG-PET in the management of cervical cancer, and in an experimental setting we have increased the understanding of tumour metabolism.</p>		
Key words: Cervical cancer, FDG-PET, staging, re-staging, surveillance, prediction, outcome, squamous cell carcinoma, tumour metabolism, metabolic flare, NBDG		
Classification system and/or index terms (if any):		
Supplementary bibliographical information:	Language English	
ISSN and key title: 1652-8220	ISBN 978-91-86443-65-8	
Recipient's notes	Number of pages 80	Price
	Security classification	

Distribution by (name and address)

I, the undersigned, being the copyright owner of the abstract of the above-mentioned dissertation, hereby grant to all reference sources permission to publish and disseminate the abstract of the above-mentioned dissertation.

Signature Maria Bjurberg


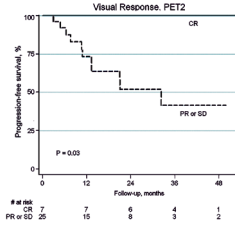
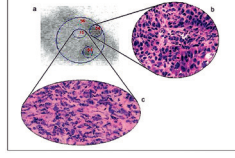
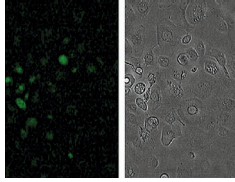
Date 15/3 2010

To my patients

Contents

<i>Thesis at a glance</i>	2
<i>Papers included in the thesis</i>	3
<i>Abbreviations and definitions</i>	4
<i>Populärvetenskaplig sammanfattning</i>	5
<i>Background</i>	6
The scope of the problem	6
Cervical cancer	6
FDG-PET and tumour metabolism	11
<i>Aims</i>	17
<i>Materials</i>	18
Patients	18
Xenografts	18
Cell lines	19
<i>Methods</i>	20
The clinical trial	20
Evaluation of FDG-PET	20
Statistical analyses	21
Cell cultures	21
Phosphor imaging with FDG	21
Real-time fluorescence microscopy with 2-NBDG	21
Flow cytometry	22
<i>Results</i>	23
Paper I	23
Paper II	23
Paper III	24
Paper IV	25
<i>General discussion</i>	26
Clinical applications of FDG-PET in cervical cancer	26
Early metabolic changes after cytotoxic therapy	27
<i>Conclusions</i>	29
<i>Future perspectives</i>	30
<i>Acknowledgements</i>	31
<i>References</i>	32
<i>Papers I–IV</i>	

Thesis at a glance

	Question	Method	Result		Conclusion
I	Does FDG-PET have a role to play in the clinical management of cervical cancer?	A prospective clinical trial of FDG-PET for staging, re-staging, and surveillance of cervical cancer.	FDG-PET results led to treatment changes for 25% of the patients with manifest disease. No benefit of surveillance FDG-PET 6 months post operatively.		For staging and re-staging of cervical cancer FDG-PET adds important information that influences the clinical management.
II	Is it possible to predict patient outcome with FDG-PET early during radiotherapy for locally advanced cervical cancer?	A prospective clinical trial of 37 women with locally advanced cervical cancer. FDG-PET was performed before, during and after radiotherapy.	No patient with metabolic CR during therapy relapsed. 11 of 25 patients with remaining hypermetabolism on FDG-PET during therapy relapsed.		FDG-PET early during therapy can identify one group of patients with excellent prognosis and a larger group of patients with a high risk of relapse.
III	Is there a correlation between early metabolic changes and treatment response in squamous cell carcinomas?	Experimental studies of ¹⁸ F-FDG metabolism following cisplatin treatment in vivo and in vitro.	A transient metabolic flare was seen on day 1, corresponding to regressive changes. Increased FDG uptake per viable tumour cell was found on day 5.		The timing of a predictive FDG-PET scan is essential. An early metabolic flare may be sign of tumour response to therapy.
IV	What is the explanation for the early metabolic flare observed in tumours after cisplatin treatment?	Four cell lines were treated with cisplatin and evaluated with 2-NBDG in real-time fluorescence microscopy.	A metabolic flare was seen in pre-apoptotic cells and was associated to exposure of high cisplatin doses and to sensitivity to cisplatin.		A metabolic flare was an early sign of response to treatment in vitro.

Second illustration from top: Bjurberg et al. Int J Gynecol Cancer -09, with permission.

Papers included in the thesis

This thesis is based on the following papers, referred to in the text by their Roman numerals.

- I. Bjurberg M, Kjellén E, Ohlsson T, Ridderheim M, Brun E. **FDG-PET in Cervical Cancer: Staging, Re-staging and Follow-up.** *Acta Obstet Gynecol Scand* 2007; 86(11): 1385–1391.
Reprinted with permission from Taylor & Francis Group Ltd
- II. Bjurberg M, Kjellén E, Ohlsson T, Bendahl P, Brun E. **Prediction of patient outcome with 2-deoxy-2-[¹⁸F]fluoro-D-glucose-positron emission tomography early during radiotherapy for locally advanced cervical cancer.** *Int J Gynecol Cancer* 2009; 19(9):1600–1605.
Reprinted with permission from Wolters Kluwer Health
- III. Bjurberg M, Henriksson E, Brun E, Ekblad L, Ohlsson T, Brun A, Kjellén E. **Early changes in 2-deoxy-2-[¹⁸F]fluoro-D-glucose metabolism in squamous-cell carcinoma during chemotherapy in vivo and in vitro.** *Cancer Biother Radiopharm* 2009; 24(3): 327–332.
Reprinted with permission from Mary Ann Liebert, Inc., Publishers
- IV. Bjurberg M*, Abedinpour P*, Brun E, Baldetorp B, Borgström P, Wennerberg J, Kjellén E. **Early metabolic flare in squamous cell carcinoma after chemotherapy is a marker of treatment sensitivity in vitro.**
Submitted.
*contributed equally

Abbreviations and definitions

BT	brachytherapy	MRI	magnetic resonance imaging
CIN	cervical intraepithelial neoplasia	2-NBDG	2-[N-(7nitrobenz-2-oxa-1,3-diazol-4-yl)amino]-2-deoxyglucose
CR	complete response	NPV	negative predictive value
CT	computed tomography	OS	overall survival
EBRT	external beam radiotherapy	PALN	para-aortic lymph node
FDG	2-deoxy-2-[¹⁸ F]fluoro-D-glucose	Gy	Gray, unit for absorbed radiation dose, 1 Gy = 1 Joule/kg
FIGO	International Federation of Gynaecology and Obstetrics	PD	progressive disease
G1 phase	gap phase of the cell cycle between the S and M phases	PET	positron emission tomography
G2 phase	gap phase of the cell cycle between M and S phases	PFS	progression-free survival
GLUT	glucose transporter	PPV	positive predictive value
HDR	high dose-rate	PR	partial response
HPV	human papilloma virus	ROI	region of interest
keV	kilo electron volt, unit for energy	SCC	squamous cell carcinoma
LVSI	lymphovascular space involvement	SD	stable disease
MBq	Mega Becquerel, unit for radioactivity	S phase	the DNA synthesis phase of the cell cycle
M phase	the mitotic phase of the cell cycle	SUV	standardised uptake value
MR	metabolic rate		

Populärvetenskaplig sammanfattning

Livmoderhalscancer, cervixcancer, drabbar varje år en halv miljon kvinnor runt om i världen och är därmed den näst vanligaste cancerformen hos kvinnor. Drygt 80 % av fallen återfinns i utvecklingsländerna, där även behandlingsmöjligheterna är mycket begränsade. I Sverige insjuknar varje år ca 450 kvinnor i livmoderhalscancer. Den låga siffran förklaras till största delen av den screeningverksamhet med cellprovskontroller som finns i Sverige sedan 1960-talet. Överlevnaden i livmoderhalscancer varierar med stadium, men är i genomsnitt drygt 50 %.

Inför beslut om lämplig behandling görs en utredning för att bedöma sjukdomsutbredningen. Spridning till lymfkörtlar är prognostiskt ogynnsamt men svårbedömt med rådande diagnostiska metoder. Livmoderhalscancer behandlas i tidiga stadier med kirurgi och i mer avancerade stadier med strålbehandling i kombination med cytostatika. Vid spridd sjukdom eller vid återfall är behandlingen individualiserad och prognosen dålig. Samtliga behandlingar innebär en betydande risk för biverkningar. Att få möjlighet att förutsäga den enskilda patientens svar på behandling, tidigt under pågående behandling, innebär en möjlighet att anpassa fortsatt terapi. Detta har som syfte att undvika såväl onödiga biverkningar som underbehandling.

Positronemissionstomografi, PET, är en nuklearmedicinsk bildgivande undersökning där man med hjälp av radioaktivt märkta spårämnen undersöker biologiska processer i kroppen. Vid cancersjukdomar används oftast sockeranalogen fluorodeoxyglukos, FDG, som spårämne. Anledningen till detta är att cancerceller har ett kraftigt ökat upptag och omsättning av socker vilket gör att tumörer kan spåras med FDG-PET.

Målet med denna avhandling var att undersöka om FDG-PET har en plats i behandlingen av livmoderhalscancer samt att experimentellt undersöka hur tumörers omsättning av socker påverkas av cellshämmande behandling.

I arbete I och II undersökte vi värdet av FDG-PET i tre olika situationer hos kvinnor med livmoderhalscancer. Vi fann att FDG-PET gav bättre

information om sjukdomsutbredningen än tidigare använda metoder. Detta gällde både vid utredning inför strålbehandling och vid utredning av återfall. Behandlingsplanerna ändrades hos en fjärdedel av patienterna till följd av den nya informationen. Rutinmässig FDG-PET sex månader efter operation av tidig livmoderhalscancer gav dock ingen vinst i form av tidigt upptäckta återfall. Med FDG-PET tidigt under pågående strålbehandling undersökte vi om det var möjligt att förutse utgången av behandlingen, så kallad behandlingsprediktion. Det var möjligt att identifiera en liten grupp patienter med utmärkt prognos. För majoriteten av patienterna gick det dock inte att förutsäga behandlingsresultatet. Med FDG-PET tre månader efter strålbehandlingens slut fick man däremot pålitlig prognostisk information. Kvarvarande områden med hög sockeromsättning vid denna tidpunkt innebar stor risk för återfall.

I arbete III och IV redovisas de experimentella undersökningarna. Vid undersökningar av cancerceller i en djurmodell samt av cancerceller i cellförsök noterades att sockerupptaget ökade kraftigt tidigt efter cytostatikabehandling. Ökningen var i cellförsök kraftigast i de cellinjer som var mest känsliga för behandlingen. I de transplanterade tumörerna var ökningen av sockerupptaget övergående och sjönk i takt med att behandlingseffekten fick tumören att gå under. I ytterligare cellförsök fann vi att sockerupptaget per levande cell fem dagar efter cytostatikabehandling var högre än före behandlingen. Vi fann inte något störande sockerupptag från immunförsvarets celler eller stödjeceller, vilka ibland rapporteras vara en källa till falskt positivt upptag.

Sammanfattningsvis har vi funnit att FDG-PET tillför värdefull information för patienter med livmoderhalscancer vid utredning inför strålbehandling och vid återfall. FDG-PET för att förut säga behandlingsresultat vid strålbehandling är ett lovande koncept, men behöver utredas ytterligare. Vidare har vi funnit att ett ökat sockerupptag hos cancerceller tidigt efter cytostatikabehandling kan vara ett tecken på behandlingseffekt.

Background

The scope of the problem

Cancer of the uterine cervix is a serious health problem worldwide. The vast majority of the cases occur in developing countries with limited resources for treatment. In the more privileged parts of the world we thus have a responsibility to conduct research also on such diseases that are of interest on a global perspective. When new knowledge emerges in medicine, it needs to be evaluated both clinically and experimentally to establish if and how it may be beneficial for the patients. We performed these studies to investigate the potential value of positron emission tomography (PET) with 2-deoxy-2-[¹⁸F]fluoro-D-glucose (FDG) in cervical cancer.

Cervical cancer

Epidemiology

Nearly 500,000 women worldwide are diagnosed with cervical cancer each year, making this the second most common female cancer in the world. In 2002, when the most recent global estimates for cancer were performed, 273,000 deaths were attributed to cervical cancer. More than 80% of the cases occurred in less developed countries in South and South East Asia, sub-Saharan Africa and Central and South America (Ferlay et al. 2004; Parkin et al. 2005). The age-adjusted incidence rates vary eight-fold worldwide: from approx. 30/100,000 for parts of Central and South America to rates below 7/100,000 in the Middle Eastern countries (Parkin et al. 2002; Sankaranarayanan 2006). The Swedish incidence rate (world standard rate) was 7.3/100,000 in 2007 (The National Board of Health and Welfare 2008). That same year in Sweden, 466 women were diagnosed with cervical cancer and 162 women died from the disease (The National Board of Health and Welfare 2009b).

The age of women at diagnosis for cervical cancer also varies across the globe. In Sweden, two incidence peaks exist: approx. 35–40 years of age and approx. 75–79 years (The National Board of

Health and Welfare 2009a). In contrast, in most less developed countries, the incidence rates increase with age. This difference in patterns of incidence can be explained, in part, by the screening practice in the more developed countries (Kamangar et al. 2006).

Aetiology, prevention and screening

Human papilloma virus, HPV, is considered a necessary cause for the development of cervical cancer, and the virus has been demonstrated to be present in almost 100% of all cervical cancers (zur Hausen 1991; Walboomers et al. 1999; Bosch et al. 2002). This small double stranded DNA virus exists in nearly 100 different types, of which at least 20 are oncogenic. The high risk HPV types 16, 18, 31, and 45 are accountable for over 80% of all cervical cancers, with types 16 and 18 alone responsible for 70% of the cases (Munoz et al. 2003; Smith et al. 2007). HPV is equally important for developing all of the dominating histological subtypes of cervical cancer: squamous cell carcinoma, adenocarcinoma, and adenosquamous carcinoma (Castellsague et al. 2006). HPV is transmitted mainly through sexual contact. Even though the vast majority of infected women resolve the infection spontaneously, a small fraction of women develop a persistent infection (Elfgren et al. 2000; Woodman et al. 2001). The infection allows the virus to interact with the host through proteins with growth-stimulating and transforming properties, and thus initiate carcinogenesis (zur Hausen 2000). Integration of viral DNA into the host cellular DNA is part of the malignant transformation. Other etiologic co-factors to cervical cancer mediate their effects by either facilitating exposure to HPV or by affecting susceptibility to the carcinogenic effect of HPV. These established co-factors include smoking, low socio-economic status, multiple sexual partners, promiscuous sexual partner, and oral contraceptive use (Plummer et al. 2003; Hellberg et al. 2005; Herrero et al. 1990; Fasal et al. 1981; Moreno et al. 2002).

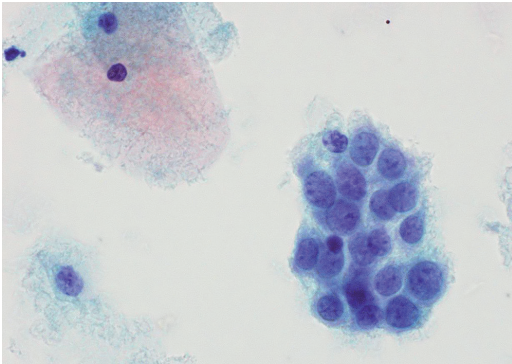


Figure 1. Pap smear showing squamous cell carcinoma cells (dark blue cells in the centre of the image) and normal epithelial cells (top left). With permission from A. Måsbäck, Lund University Hospital, Sweden.

Since the aetiological causality of cervical cancer is well known and the precursor stages, cervical intraepithelial neoplasias (CIN I-III), are identifiable, prevention of this disease would appear feasible. The most widespread screening method is vaginal cytology, i.e. the Papanicolaou (Pap) smear, see Figure 1. The Pap smear was first introduced in 1941, and enables identification of both dysplastic cells and cancer cells (Papanicolaou 1941; Fahey et al. 1995, Nanda et al. 2000). By detecting CIN, the progression to invasive cancer may be prevented by removal of the precancerous lesions. Various screening programmes using Pap smear have been applied over the years and are generally considered to be responsible for the decreasing incidence of cervical cancer in the western world. A population based cytology screening programme was started in Sweden in 1967, and the overall incidence of cervical cancer since then has declined by over 50% (The National Board of Health and Welfare 2009a). In a nationwide audit of the Swedish screening programme it was demonstrated that detected cancers were of earlier stages than in the non-participating women. 64% of all cervical cancers occurred in women who had not had a Pap smear within the recommended screening interval and 83% of the advanced cases were diagnosed in women who had not been tested (Andrae et al. 2008). However, screening programmes are costly and require population registries in order to achieve the necessary high coverage of the population. These factors may explain why cervical cancer screening programmes are difficult to implement

and why they have failed to reduce the incidence of cervical cancer in several less developed countries (Sankaranarayanan et al. 2001).

The recent introduction of prophylactic vaccines against high risk HPV subtypes 16 and 18 is generally considered to be a new paradigm in preventing cancer by way of preventing HPV-related precancerous lesions (Harper et al. 2006; Ault 2007). Although several high income countries have already adopted vaccination programmes for adolescent girls, the parts of the world with the highest incidence of cervical cancer will not be able to implement such vaccination programmes (Bastos et al. 2009). Also, since vaccination programmes need to target young adults before they encounter HPV, it will take decades to achieve an effect in the entire population, and thus the screening needs to continue (Franco et al. 2005).

Diagnosis and staging

The clinical presentation of cervical cancer usually involves post-coital bleeding, profuse vaginal discharge, and in more advanced stages, pelvic pain radiating to the back and to the legs. The diagnosis is made by a histopathological examination of a specimen obtained by either a biopsy or a conisation of the cervix.

Cervical cancer is staged according to the Federation of Gynecology and Obstetrics (FIGO) criteria and is the only gynaecologic cancer with a clinical staging procedure (Benedet et al. 2003). The reason for not integrating advanced radiological or surgical approaches is that the staging procedure must be feasible in parts of the world where cervical cancer is endemic and resources are limited. Thus, the following examinations are permitted as a staging procedure: palpation preferably under anaesthesia, inspection, colposcopy, cystoscopy, proctoscopy, cervical biopsy or conisation, intravenous urography, and x-ray examination of the lungs and the skeleton. For treatment planning purposes other investigations may be undertaken, but the information retrieved from such investigations is not allowed to influence the assignment to a FIGO stage. An outline of the FIGO classification which was valid throughout the time this research was performed and the recently revised classification are shown in Tables 1 and 2, respectively (Pecorelli et al. 1999; Pecorelli et al. 2009).

Table 1. FIGO classification 1994

Stage 0	Carcinoma in situ
Stage I	Invasive carcinoma strictly confined to the cervix
IA	Microscopic lesions
IA1	Stromal invasion not > 3 mm, extension not > 7 mm
IA2	Stromal invasion > 3 mm but not > 5 mm, extension not > 7 mm
IB	Clinically visible lesions or microscopic lesions greater than stage IA
IB1	Lesions not > 4 cm
IB2	Lesions > 4 cm
Stage II	Cervical carcinoma invades beyond uterus but confined to the pelvis
IIA	No parametrial involvement
IIB	Obvious parametrial involvement
Stage III	Carcinoma extension > stage II but confined to the pelvis
IIA	Extension to lower third of the vagina but not to the pelvic wall
IIB	Extension to the pelvic wall and/or hydronephrosis
Stage IV	Involvement of bladder or rectum, or extension beyond the pelvis
IVA	Tumour spread to adjacent organs
IVB	Spread to distant organs

Table 2. FIGO classification 2009

Stage I	Invasive carcinoma strictly confined to the cervix
IA	Microscopic lesions
IA1	Stromal invasion \leq 3 mm, extension \leq 7 mm
IA2	Stromal invasion > 3 mm but not >5 mm, extension not > 7 mm
IB	Clinically visible lesions or microscopic lesions greater than stage IA
IB1	Visible lesions \leq 4 cm in greatest dimension
IB2	Visible lesions > 4 cm in greatest dimension
Stage II	Cervical carcinoma invades beyond uterus but confined to the pelvis
IIA	No parametrial involvement
IIA1	Lesions \leq 4 cm in greatest dimension
IIA2	Lesions >4 cm in greatest dimension
IIB	Obvious parametrial involvement
Stage III	Carcinoma extension > stage II but confined to the pelvis
IIIA	Extension to lower third of the vagina but not to the pelvic wall
IIIB	Extension to the pelvic wall and/or hydronephrosis
Stage IV	Involvement of bladder or rectum, or extension beyond the pelvis
IVA	Tumour spread to adjacent organs
IVB	Spread to distant organs

The small and localised tumours of stages 0 to IB1 are usually referred to as early disease. The locally advanced tumours in stages IB2 to IVA are still confined to the pelvis as opposed to the metastasised tumours of FIGO stage IVB. Tumour spread is both haematogenous and lymphatic, with the most common sites for distant metastases being the aortic and mediastinal lymph nodes, the lungs and the skeleton (Quinn et al. 2006).

Histopathology

Squamous cell carcinoma (SCC) is the dominating

histopathological subtype and is found in approximately 80% of all cervical cancers (Quinn et al. 2006). Adenocarcinomas account for 10–20%, with the higher figures observed in the western world, where the incidence of adenocarcinomas has increased over the last decades (Bray et al. 2005). About 5% of the cervical cancers are adenosquamous carcinomas, which are mixed tumours with elements of both SCC and adenocarcinoma. Clear cell carcinoma is a rare type of adenocarcinoma which is associated with in-utero exposure to diethylstilbestrol (Noller et al. 1972) and accounts for less than 1% of all cervical can-

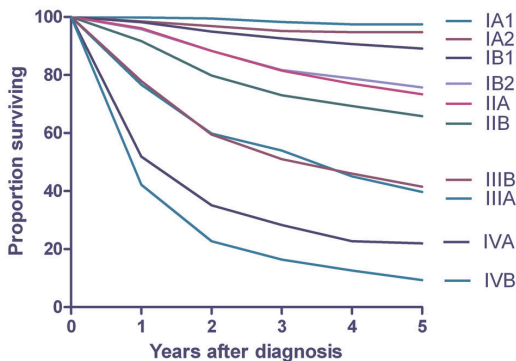


Figure 2. Survival by FIGO stage, $n = 11,639$. Patients treated 1999–2001. Adapted from Quinn et al. FIGO Annual Report, Vol. 26.

cers. Other histopathological tumour types are rare and include neuroendocrine small cell carcinoma and malignant melanoma.

Prognosis and prognostic factors

Tumour stage is by far the strongest prognostic factor for cervical cancer (Kosary 1994). According to the FIGO Annual Report 2006, which comprises reported results for 11,639 patients, the overall survival (OS) at 5 years ranges from 97.5% for patients in stage IA2 to 9.3% for patients in stage IVB (Quinn et al. 2006). Figure 2 shows the survival by FIGO stage. However, since the prognosis varies widely for patients within the same FIGO stage, the search for complementing prognostic factors is important.

Histopathology may influence the prognosis, with adenosquamous carcinoma showing a slightly worse prognosis than squamous cell carcinoma and adenocarcinoma, whereas clear cell carcinoma and neuroendocrine small cell carcinoma have a significantly worse prognosis (Grisaru et al. 2001; Alfsen et al. 2001).

Other prognostic factors are more or less interrelated with FIGO stage. Tumour size >2 cm and in some studies >4 cm, as well as depth of stromal invasion >10 mm are factors indicating poor prognosis (Kristensen et al. 1999; Ayhan et al. 2004). The prognostic value of lymphovascular space involvement (LVSI) is a controversial issue. Since the histopathological assessment of LVSI is difficult, and no uniform guidelines regarding this assessment exist, the prevalence of LVSI varies considerably between reports. Several reports con-

Table 3. Distribution of patients with histologically verified lymph node metastases (LN met) by FIGO stage. $N = 5,173$ pts. Modified from FIGO Annual Report 2006.

FIGO stage	LN met (%)
IA1	3.9
IA2	9.7
IB1	17.1
IB2	30.5
IIA	28.8
IIB	37.7
IIIA	48.3
IIIB	60.7
IVA	57.1
IVB	91.7

cerning early cervical cancer have concluded that LVSI is a marker for poor prognosis, but other reports contradict these conclusions and question the clinical impact of LVSI (Takeda et al. 2002; Ho et al. 2004; Creasman et al. 2004; Herr et al. 2009). A consensus exist however, that the presence of LVSI disqualifies patients from conservative fertility sparing treatment of early disease (Shepherd et al. 2008). The issue of LVSI as an overall prognostic factor in cervical cancer remains to be elucidated.

The presence of lymph node metastases is a sign of poor prognosis and it is also the most important predictor of ultimate treatment failure (Cosin et al. 1998; Kupets et al. 2002). Lymph node metastases occur to various extents in all FIGO stages. Table 3 shows the distribution of patients with histologically proven lymph node involvement by FIGO stage as reported in the FIGO Annual Report 2006 (Quinn et al. 2006).

Treatment and response assessment of early disease

Although single modality treatment with surgery or radiotherapy has quite comparable survival rates for early disease, surgery is the treatment of choice because of the pattern of side effects (Landoni et al. 1997). For the small microscopic tumours in stage IA1, hysterectomy is recommended, but in some cases a large conisation can be enough (Elliott et al. 2000; Costa et al. 2009). A radical hysterectomy with a pelvic lymphadenectomy, the so called Wer-

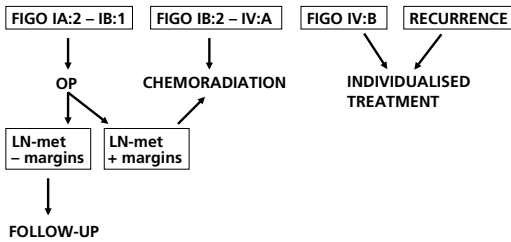


Figure 3. Overview of the treatment of cervical cancer.

them-Meigs operation, has long been the golden standard for tumours of stages IA2 to IB1 (Wertheim 1912; Meigs 1951). In selected cases of young women with small tumours and absence of poor prognostic factors, a fertility sparing surgical approach may be feasible. By performing a laparoscopic lymphadenectomy followed by a trachelectomy, which means a vaginal approach for removing the cervix and parametria, a sufficient amount of tissue can be removed and fertility may be preserved (Dargent et al. 2000).

Post operative adjuvant treatment is recommended for patients where the histopathological evaluation reveals narrow surgical margins, lymph node metastases, or unexpected large tumour size, <4 cm. External beam radiotherapy (EBRT) of at least 45 Gy to the pelvis is the cornerstone of the adjuvant treatment and significantly reduces the risk of recurrence (Sedlis et al. 1999; Rotman et al. 2006). Weekly cisplatin based chemotherapy concomitant during EBRT is recommended since Peters et al. proved a significant survival benefit compared with radiotherapy alone (Peters et al. 2000). An overview of the treatment of cervical cancer is found in Figure 3.

Side effects related to treatment of early stage cervical cancer include surgical complications, lymph oedema, impaired sexual function, gastrointestinal side effects and urogenital side effects (Bergmark et al. 2002; Lorenz et al. 2009). The addition of concomitant cisplatin based chemotherapy to EBRT adds a risk of haematological and renal toxicity (Peters et al. 2000; Rotman et al. 2006). The spectrum of side effects differ by treatment, but an important consideration is that side effects become more severe if both surgery and EBRT are administered (Landoni et al. 1997). This stresses the importance of an accurate staging procedure.

Follow-up of early cervical cancer consists of patient history and pelvic examination at regular intervals (Bodurka-Bevers et al. 2000). For tumours treated conservatively, a vaginal smear is obtained. The clinical value of routine radiological investigations during follow-up is frequently discussed and has yet to be proven.

Treatment and response assessment of locally advanced disease

Today's standard treatment of the locally advanced tumours of FIGO stage IB2 to IVA consists of multimodality treatment with EBRT, brachytherapy and concomitant cisplatin. The prescription of EBRT is mainly based on consensus guidelines and patterns of care studies. It should deliver at least 46 Gy to the pelvis and 50 Gy to the tumour (Lanciano et al. 1991; NSGO 2006). Brachytherapy, initially with radium, has been used to successfully treat cervical cancer since the early 1900s (Cleaves 1903). Nowadays brachytherapy is administered using an after-loading technique and is commonly of high dose-rate (HDR) using iridium. Brachytherapy enables deliverance of a high irradiation dose directly to the tumour by interstitial or intracavitary techniques. The addition of brachytherapy to EBRT is associated with improved survival (Lanciano et al. 1991). The recent development of 3-D based individualised brachytherapy is promising and is gradually being implemented (Pötter et al. 2006). The Nordic Society of Gynaecological Oncology Guidelines, which summarizes the current consensus, recommends brachytherapy together with EBRT to a total radiotherapy dose to the reference point A of at least 80 Gy (NSGO 2006).

The addition of concomitant cisplatin, 40 mg/m² once weekly for a maximum of six weeks during radiotherapy, has been demonstrated in four large randomised trials to significantly improve survival and reduce recurrence rates compared to radiotherapy alone by up to 10% (Rose et al. 1999; Morris et al. 1999; Whitney et al. 1999; Keys et al. 1999). In long-term follow-ups of two of these pivotal trials it has been demonstrated that side effects are related to long-term survival and are not significantly increased by the addition of concomitant cisplatin (Meta-Analysis Group 2008; Eifel et al. 2004). Regardless of the addition of cisplatin, this

multimodality therapy has potentially serious side effects. The incidence of acute serious (grade 3-4) haematological, gastrointestinal and genitourinary toxicities has been reported to be as high as 33%, 26%, and 5%, respectively (Kirwan et al. 2003; Monk et al. 2007). In a metaanalysis of 18 randomised trials of chemoradiation therapy it was estimated that 1% to 3% of the patients experienced serious late adverse events, mostly from the gastrointestinal tract (Meta-Analysis Group 2008). There is a lack of prospective studies of late side effects and quality of life in this group of patients.

The aim of the assessment of the tumour response to treatment is to detect isolated residual disease in the central pelvis. This is a potentially curable situation by means of exenteration surgery with removal of the bladder, the distal colorectal portion of the bowel, and the internal genital organs. The response assessment is usually done by pelvic examination after approximately 2–3 months. That time span is necessary to evaluate the effect of the radiotherapy clinically. This means that patients undergo six weeks of multimodal therapy, which carries a risk of potentially serious and irreversible side effects, without effective methods to monitor the effect on the tumour during the treatment period. This is a general problem in oncology.

Treatment of metastasised or recurrent disease

Most relapses occur within 2 years of the primary diagnosis. Except for isolated pelvic recurrences curable with exenteration surgery, the treatment of metastasised or recurrent cervical cancer is regarded as palliative. Treatment plans have to be individualised and adjusted to the amount and anatomical location of the disease. Radiotherapy is usually part of the treatment to palliate symptoms. Surgery may also be an option in selected cases, e.g. a single pulmonary metastasis. In primary advanced disease surgical debulking of enlarged para-aortic lymph nodes is frequently discussed but has so far not been demonstrated to improve survival (Cosin et al. 1998; Gold et al. 2008).

Single agent cisplatin, in a dose of 50 mg/m² at 3 week intervals, has been the standard treatment of metastasised cervical cancer since 1981 (Thigpen et al. 1981). It was not until 2005 that better survival rates could be demonstrated. In a randomised

study by Long et al., cisplatin in combination with topotecan showed improved survival compared with single agent cisplatin (Long et al. 2005). Since then, it has also been suggested that cisplatin in combination with paklitaxel may be comparable to the topotecan regimen (Monk et al. 2009). It is a growing concern, albeit not yet proven, that by exposing the tumour cells to cisplatin during chemoradiation therapy, resistance to cisplatin can be induced, rendering cisplatin treatment of recurrent disease futile (Long et al. 2005).

FDG-PET and tumour metabolism

PET

PET, positron emission tomography, is a nuclear medical modality that enables non-invasive in vivo studies of the uptake and metabolism of radioactive labelled substances. Acquired images are evaluated visually and additional quantitative analyses can be done. Positron-emitting radionuclides are used to label biological substances that are administered as tracers to the subject (Phelps 2004). A PET image provides information on the relative distribution of the administered tracer. The information is registered as Becquerel (Bq) per volume unit and is then further analysed mathematically.

Radiotracers

The existence of a positively charged anti-particle to the electron, the positron, has been known since the 1930s (Anderson 1933). In the 1950s detection of the annihilation radiation created when a positron and an electron meet, conjugate and annihilate was made possible. Coincidence counting of the energy quanta from the positron decay was found to be of use in the location of the source of annihilation along a straight line, the coincidence line, between the detectors (Wrenn et al. 1951). Figure 4 shows a schematic illustration of positron decay and the creation of annihilation radiation.

Positron-emitting radionuclides are produced in a cyclotron, a powerful accelerator. The half-life of the radionuclide determines its use in clinical practice. Commonly used radionuclides are fluorine (¹⁸F), nitrogen (¹³N), and carbon (¹¹C) with half-lives of 110, 10, and 20 minutes, respectively (Oehr 2004).

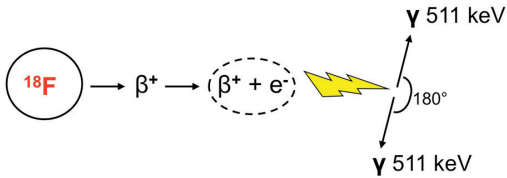


Figure 4. A positron from the administered radioisotope, in this case ^{18}F , conjugate with an electron in a cell, creating annihilation radiation which causes two photons of 511 keV to be emitted at exactly 180° from each other. This coincidence radiation is then detected in a PET camera, and thus the position of the origin of the annihilation radiation can be located.

Most biochemical substances can be radiolabelled and used as tracer molecules for PET imaging. In oncology 2-deoxy-2- ^{18}F fluoro-D-glucose (^{18}F -FDG), as a marker for glucose metabolism, is by far the most used radiotracer. Other examples of tracers are methionine, which is used as a marker for protein metabolism, thymidine, as a marker for cell proliferation, choline, as a marker for membrane lipid synthesis, misonidazole, for hypoxia, and fluorestradiol, which is used in the study of oestrogen receptors (Lindholm et al. 1993; Shields et al. 1996; DeGrado et al. 2001; Rasey et al. 1987; Mankoff et al. 1997).

The PET camera

The discovery of coincidence radiation led to the development of gamma cameras in the 1960s and PET cameras in the 1970s (Schaer et al. 1965; Ter-Pogossian et al. 1975). The annihilation quanta are detected by the PET camera with crystals most commonly composed of bismuth germanate oxide (BGO) and lutetium oxyorthosilicate (LSO). The crystals have a short attenuation length for gamma rays of 511 keV and a short scintillation decay time, in order to achieve a high efficiency and to minimise the detection of random background events (Phelps 2004).

The axial field of view is limited by the size of the detectors in the camera and scanning is carried out with the detector stopping at several positions. The spatial resolution of PET is poorer than that of CT or MRI. For anatomical co-localisation of the registered activity a combination of PET and CT is often used in a sequential set-up. Recently, combinations of PET and MRI have been presented. Software fusion solutions for PET images and

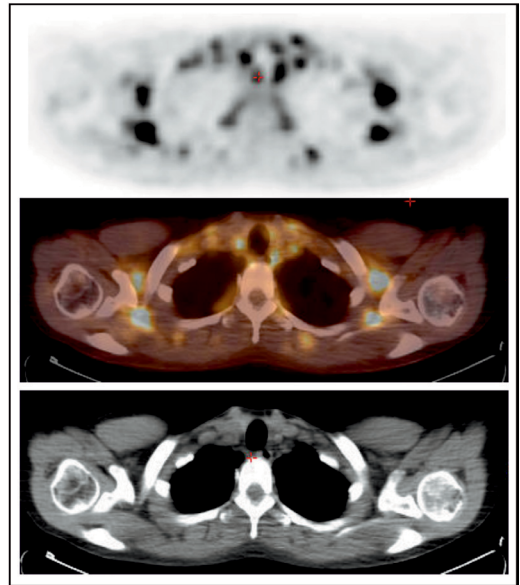


Figure 5. By fusion of a PET image (top) and a CT image (bottom), an anatomical location of the radiotracer uptake can be visualised in a CT-PET image (middle).

conventional images are available. A PET image, a CT image, and the fused PET-CT image is seen in Figure 5.

Tumour metabolism and FDG

The uncontrolled proliferation of malignant cells requires an accelerated metabolism, leading to a high glucose demand and an increased glucose uptake compared with normal cells (Warburg 1956; Weber 1977a; Weber 1977b). Glucose is transported into cells by facilitative glucose transporter (GLUT) proteins. At present, 13 isoforms of GLUTs have been identified, each with a different affinity for glucose and with a different distribution within the body (Joost et al. 2002; Macheda et al. 2005). Overexpression of GLUTs, and in particular of GLUTs with a high affinity for glucose, such as GLUT1 and GLUT3, has been demonstrated in many types of cancer and at an early stage in the malignant transformation (Medina et al. 2002; Flier et al. 1987). In a study of the levels of GLUT mRNA and protein expression in cervical epithelium with CIN 1-3 and cervical carcinoma, Rudlowski et al. found a strong correlation of high levels of GLUT expression to HPV-positive CIN 3-lesions and to invasive carcinomas (Rudlowski

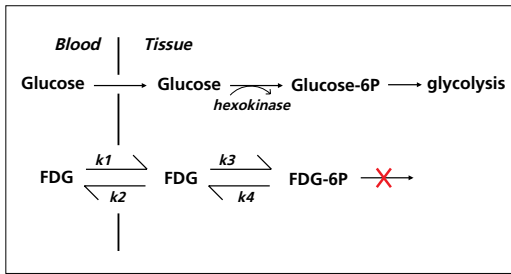


Figure 6. Schematic illustration of the metabolism of glucose and of FDG showing a compartment model of FDG metabolism, in which $k1-k4$ is the transport rate constants between the vascular FDG, the tissue-FDG and the tissue-FDG-6P. Modified from Phelps and from Oehr.

et al. 2003). This suggests that GLUT1 overexpression is an early event in cervical neoplastic transformation. Hypoxia is present to various extents in most tumours, including cervical carcinomas, and the hypoxia induces up-regulation of the GLUTs (Warburg, 1956; Haensgen et al. 2001; Okino et al. 1998). Once inside the cell, the first step in glucose metabolism is phosphorylation by hexokinase. Malignant cells exhibit an increased activity of the enzymes involved in the glycolytic pathway including hexokinase (Board et al. 1990). Hennipman et al. demonstrated that the activities of hexokinase and other glycolytic enzymes were higher in metastases than in primary tumours, suggesting an association of an increasing rate of glycolysis with tumour progression (Hennipman et al. 1988).

Like glucose, FDG is transported into cells by GLUTs and is then phosphorylated by hexokinase. FDG-phosphate (FDG-6P) cannot enter the glycolytic pathway, and thus accumulates in the cell (Hatanaka et al. 1970; Gallagher et al. 1978). Malignant cells exhibit low levels of glucose-6-phosphatase compared with normal tissues and benign inflammatory processes, leading to differences in FDG accumulation between benign and malignant tissues (Yamada et al. 1995; Nakamoto et al. 2000). This is visualised in Figure 6 and in Figure 7.

The relative differences in glucose metabolism visualised with FDG-PET features normal physiological as well as pathologically enhanced glucose demands. Thus, FDG-PET is not selective for

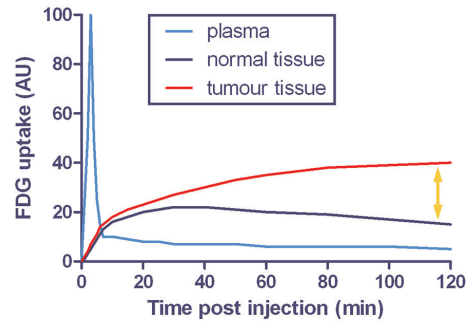


Figure 7. FDG uptake and accumulation in plasma and in benign and malignant tissue. The yellow arrow indicates the relative difference in FDG accumulation between benign and malignant tissue that forms the basis of the FDG-PET image. Modified from Ohlsson.

cancer. In autoradiographic studies of xenografted tumours, a heterogeneous FDG uptake is visible, reflecting variations in tumour pathophysiology and tumour tissue components. Viable tumour cells and hypoxic tumour cells exhibit a higher level of glucose demand compared with necrotic cells and normoxic tumour cells (Brown et al. 1993; Dearling et al. 2004). Inflammatory cells, such as macrophages and lymphocytes, are present to various degrees in tumours and exhibit a high FDG uptake (Kubota et al. 1992; Deichen et al. 2003).

Evaluating FDG-PET scans

Visual analysis of FDG-PET is often enough in routine clinical practice.

For quantitative analysis of tracer uptake, a region of interest (ROI), encompassing the tumour, is defined on the PET image, and the amount of radioactivity within the ROI is evaluated. The most commonly used method in clinical routine is the semi-quantitative analysis of the standardised uptake value (SUV) (Strauss et al. 1991). The SUV is the ratio between the tumour concentration of ^{18}F -FDG in relation to injected activity and body mass of the patient.

$$\text{SUV} = \frac{\text{mean regional activity (Bq/ml)}}{\text{injected activity (Bq)/body weight (g)}}$$

The SUV is dimensionless and a tracer molecule that is evenly distributed within the body will have an SUV of 1. The SUV method is denoted semi-quantitative since it does not take time into

account, but it remains a popular method because it is simple to handle (Huang 2000; Castell et al. 2008). The SUV is presented as either SUV_{mean} which is the mean FDG uptake in a ROI, a tumour, or as SUV_{max} which is the highest SUV value within a ROI. A strong correlation has been demonstrated between the SUV and GLUT1 expression, reflecting the high influx of FDG in tumours (Yen et al. 2004; Riedl et al. 2007).

True quantitative methods of tracer uptake evaluation, i.e. kinetic modelling, follow metabolic activity over a period of time. These models are based on the concept of several ^{18}F -FDG-containing compartments, which are linked by kinetic processes of exchange of FDG (Figure 10, see page 22) (Phelps et al. 1979). The metabolic rate (MR) of glucose measured with FDG, MR_{FDG} , expressed in $\mu\text{mol}/\text{min}/100 \text{ g tissue}$, is obtained through knowledge of plasma radioactivity over time. MR_{FDG} can be calculated using an autoradiographic formula modified from the Sokoloff formula and the Patlak graphical analysis of rate constants, determined through repeated rapid measurements of radioactivity following the administration of the radiotracer (Sokoloff et al. 1977; Brooks 1982; Patlak et al. 1983; Reivich et al. 1985).

$$MR_{\text{glu}} = \frac{C_{\text{glu}} \times Ci^*(T)}{LC \times \int_0^T Cp^*(t)dt}$$

C_{glu} is the plasma glucose concentration, $Ci^*(T)$ is the tissue concentration of FDG in a region i at the time T post-injection, and $Cp^*(t)dt$ is the plasma concentration of FDG as a function of time. LC refers to the lumped constants ($k1-3$), which is the proportion between transport and phosphorylation of glucose and FDG, respectively. By setting the LC to 1, which is done for ROIs outside the brain, the differences in tissue handling of glucose and FDG is not accounted for and thus, the result can be expressed as MR_{FDG} rather than MR_{glu} (Eary et al. 1998). This way of estimating the tumour glucose metabolism by FDG-PET is widely accepted (Mankoff et al. 2003). The MR provides detailed estimation of tumour glucose metabolism, albeit analysing the MR is laborious given the necessary blood sampling.

Limitations of FDG-PET

Before evaluation of radiotracer uptake, data must

be corrected for large potential biases. Attenuation in tissue is due to absorption of the gamma radiation along the coincidence path and thus represents missed information. Some coincidences may be random and are corrected for, since the system cannot determine whether the two photons recorded are the result of the same annihilation or two annihilations that occurred at the same time. Scatter occurs when a photon loses some of its energy by Compton effect. Corrections for attenuation, random events, and scatter are usually done mathematically. It is more difficult to correct for the partial volume effect, which is the finite spatial resolution causing the activity of a small source to be underestimated. The full width at half maximum (FWHM) limits the spatial resolution, in that the size of a ROI must be twice the size of the resolution of the detector in order to produce correct values (Phelps 2004). The FWHM is around 2–5 mm in modern PET cameras. Motion artefacts also need to be taken into consideration when evaluating small lesions.

Since FDG accumulates in metabolically active tissue, as previously mentioned, access to clinical data is vital to produce a valid visual evaluation. Among possible pitfalls are hyperglycaemias in diabetic or non-fasting patients, the physiological FDG accumulation in the brain, the heart, active muscle tissue, the gastrointestinal tract, and in brown fat (Engel et al. 1996; Hany et al. 2002). The FDG uptake of infectious processes and of inflammatory cells may pose an important confounding factor (Ozer et al. 2009; Sanli et al. 2009). This has also been verified in experimental studies where inflammatory cells have shown an elevated FDG uptake (Kubota et al. 1992; Spaepen et al. 2003). In addition, there is a physiological FDG uptake in the ovaries and endometrium of premenopausal women related to the menstrual cycle (Nishizawa et al. 2005). Finally, FDG molecules that are not taken up into cells are excreted via the urinary tract and may complicate evaluation of adjacent structures (Oehr 2004).

FDG-PET and monitoring oncological treatment

An optimal staging procedure provides information on the extent of the disease with a minimal risk and no side effects for the patient. For staging of lymphoma, FDG-PET has been demonstrated

to provide a higher sensitivity and specificity than conventional imaging modalities and the PET findings often lead to up-staging (Partridge et al. 2000; O'Doherty et al. 2002). In patients with lungcancer, van Tinteren et al. found that by adding FDG-PET to the staging procedure significantly more tumour localisations were diagnosed. Due to the high accuracy of FDG-PET many surgical lung biopsies could be avoided (van Tinteren et al. 2002). Furthermore, the staging of lungcancer obtained with FDG-PET correlates better to prognosis than the staging obtained with conventional imaging (Mac Manus et al. 2002).

The distinction between prognosis and prediction is important. A prognostic factor provides information on the general outcome of a disease at the time of diagnosis. A predictive factor is able to identify patients likely to respond to a certain therapy. Prediction with sequential evaluation during cytotoxic tumour treatment will ideally lead to interventions and individualised treatment adjustments based on the response to the therapy. This is only clinically justified if effective alternative therapies are available or if patients can be spared from futile toxic treatments. The concept of early prediction of response to cytotoxic treatment using FDG-PET has been investigated in various types of cancer, and the findings of early metabolic changes are consistently correlated to treatment response. The strongest evidence is found for FDG-PET after 1-2 courses of chemotherapy in Hodgkin's lymphoma, which is consistent with the high FDG avidity of these tumours (Hutchings et al. 2006; Kostakoglu et al. 2006). The less obvious results found for many solid tumours may be related to multiple causes. Contributing factors may be differences in the timing of the FDG-PET scans, in the methods of quantification and evaluation of changes in FDG uptake, and in differences in tumour biology (Brun et al. 2002; Tanvetyanon et al. 2008; Wahl et al. 2009).

The high negative predictive value (NPV) of FDG-PET makes it valuable for therapy evaluation. This has been reported for lymphoma, where the assessment of residual masses poses a clinical challenge, and for head and neck carcinoma, where the distinction of radiotherapy-induced fibrosis and tumour recurrence is difficult (Mikhaeel et al. 2000; Wong et al. 2002).

FDG-PET in staging of cervical cancer

The usefulness of FDG-PET in cervical cancer was first recognized in its ability to assess lymphnode status. A number of reports have established that FDG-PET is more sensitive than CT or MRI in assessing lymphnode status (Lin et al. 2003; Yeh et al. 2002; Choi et al. 2006). A clinical value of FDG-PET imaging as part of the pre-treatment work-up for cervical cancer FIGO stage \geq IB has been demonstrated by Loft et al. (Loft et al. 2007). In their study of 120 consecutive patients they found a positive predictive value (PPV) of 75% and 50% and a NPV of 96% and 95% for the patients planned for surgery or chemoradiation, respectively. A prognostic significance of lymphnode metastases detected by FDG-PET has been demonstrated by Grigsby et al. (Grigsby et al. 2001). In a retrospective study of 101 patients they found a 2-year progression-free survival (PFS) of 18% for PET-positive and CT-negative para-aortic nodes, compared to 64% for PET-negative and CT-negative aortic nodes and 14% for PET-positive, CT-positive aortic nodes. No patients had negative PET and positive CT findings.

FDG-PET and post-treatment evaluation of cervical cancer

FDG-PET for post-treatment evaluation after radical radiotherapy has been evaluated in a retrospective study of 152 patients that underwent FDG-PET at a mean 3 of months after completing radiotherapy (Grigsby et al. 2004). The 5-year cause-specific survival rate was 80% for patients with no pathological FDG-uptake, whereas those with FDG-uptake within or outside the irradiated region showed 5-year cause-specific survival rates of 32% and 0%, respectively. A prospective evaluation of 92 patients that underwent FDG-PET at a mean of 3 months (2-4) after completion of radical radiotherapy produced similar results (Schwarz et al. 2007). The 3-year PFS for patients in whom FDG-PET showed complete response, partial response and progressive disease were 78%, 33% and 0%, respectively.

In routine surveillance, a high rate of false-positive FDG-PET results has been reported (Ryu et al. 2003). No clinical benefit of FDG-PET in this setting has been demonstrated because most studies addressing the issue of routine surveillance

also include patients with signs and/or symptoms of recurrence (Belhocine et al. 2002; Unger et al. 2004; Brooks et al. 2009).

FDG-PET and recurrent cervical cancer

FDG-PET is a clinically valuable addition in the detection and re-staging of recurrent cervical cancer. In the case of a clinically suspected recurrence, FDG-PET findings have a sensitivity and specificity of 86–93%, respectively, and have been demonstrated to alter the clinical management for up to 65% of the patients (Havrilesky et al.

2003; van der Veldt et al. 2008). In patients with histologically verified relapse, FDG-PET findings led to a change in treatment plans for 55% of the patients in a prospective study of 40 patients (Lai et al. 2004). The majority of the changes involved a switch to palliative therapy and a decision to avoid extensive surgery. When performing FDG-PET as re-staging before exenteration surgery in 20 patients with recurrent cervical cancer, Husain et al. found that FDG-PET detected 5 cases of extra-pelvic tumour spread whereas CT only found one of the cases (Husain et al. 2007).

Aims

Paper I

To investigate the potential clinical benefit of using FDG-PET in:

- a) follow-up of early cervical cancer 6 months after surgery with respect to early detection of potentially curable relapses.
- b) staging of locally advanced cervical cancer compared to conventional work-up and to investigate if the information obtained from FDG-PET has an impact on the treatment plans.
- c) detecting and re-staging recurrent cervical cancer and to evaluate the effect of FDG-PET on the clinical management.

Paper II

To investigate the possibility of prediction of patient outcome with FDG-PET early during radiotherapy +/- concomitant chemotherapy of locally advanced cervical cancer.

To compare different methods of evaluating FDG-PET scans, visually and quantitatively, in this setting.

Paper III

To further investigate, in an experimental setting, the changes in glucose metabolism early after cytotoxic treatment in vivo in an animal model and in vitro on squamous cell carcinoma cell lines.

Paper IV

To investigate the early metabolic flare detected in Paper III on a cellular level in squamous cell carcinoma cell lines using a fluorescent deoxyglucose analogue as a model for FDG uptake

Materials

Patients

(Papers I-II)

All patients diagnosed with cervical cancer in the Southern Swedish Health Care region, with 1.7 million inhabitants, are routinely referred to the Department of Oncology at Lund University Hospital for the staging procedure and for treatment recommendations. Between October 2004 and November 2008, patients were consecutively offered inclusion in a prospective clinical trial of FDG-PET in cervical cancer. The study was approved by the regional ethics committee and written informed consent was obtained from every patient at inclusion. Eligible patients had biopsy-proven cervical cancer and tumour characteristics that could be fitted into one of three categories. Group 1 consisted of patients with early disease, which according to the local standard treatment policy did not qualify for any postoperative adjuvant treatment, but still had one poor prognostic factor. Group 2 consisted of patients with locally advanced cervical cancer scheduled for curatively intended radiotherapy with or without concomitant cisplatin. Group 3 consisted of patients with recurrent cervical cancer or a strong clinical suspicion thereof. The medical inclusion criteria are summarized in Table 4.

An interim analysis of the trial was performed on data from the patients that were included during the first 18 months and that had a minimum follow-up time of six months. The aim of the analysis was to detect a possible lack of clinical benefit for any of the study groups. The interim analysis consisted of 10 patients in group 1, 17 patients in group 2 and 15 patients in group 3. The results from the interim analysis are published in Paper I. As a result of the findings in the interim analysis, we stopped recruitment into group 1, the early disease follow-up study. Accrual to group 2 was extended for one year to allow for a sufficient number of patients to be included. Group 3, the relapse group, continued as planned with a total inclusion period of 3 years. In Paper II we published the results from the final

Table 4. Summary of the medical inclusion criteria

<p>A. A diagnosis of cervical cancer that can be fitted into one of the following three groups:</p> <ol style="list-style-type: none"> 1) Undergone surgery for cervical cancer FIGO stage IA2-IB1 and does not qualify for post-operative treatment but pathology report shows one of the following: <ol style="list-style-type: none"> a) LVSI b) depth of stroma invasion >10 mm c) tumour size >2 cm d) histologic subtype with poor prognosis 2) Biopsy-proven cervical cancer FIGO stage IB2-IVA scheduled for curatively intended radical radiotherapy +/- concomitant cisplatin 3) A history of biopsy-proven cervical cancer and one of the following: <ol style="list-style-type: none"> a) histologically verified relapse b) strong clinical suspicion of relapse not yet verified histologically <p>B. No simultaneous malignant disease</p>
--

analysis of the 37 patients in group 2. An overview of the characteristics of the patients included in Papers I and II is found in Table 5.

During the years of the trial period between 70 and 85 women were diagnosed with cervical cancer each year in the health care region (The National Board of Health and Welfare 2008). The accrual into groups 1, 2 and 3 represented approx. 70%, 30%, and 50% of eligible patients, respectively. A reject log was kept during the first 2 years of the trial: limited access to the PET facility with logistic constraints regarding the timing of PET studies and patient treatment were the main explanations for the limited recruitment.

Xenografts

(Paper III)

The BALB/c nude mouse is congenitally athymic and thus has a T-cell immunodeficiency that makes a heterotransplant (xenograft) possible. However, a low grade of T-cell immune response remains, as well as the innate immune response with compensatory higher levels of macrophages and NK cells

Table 5. Summary of patient characteristics in Papers I and II

	Group 1	Paper I Group 2	Group 3	Paper II
Number of patients	10	17	15	32
Mean (range) age at inclusion, years	39 (25–75)	56 (38–75)	50 (33–80)	49 (30–90)
Histology				
squamous cell carcinoma	4	14	11	26
adenocarcinoma	4	2	3	4
adenosquamous carcinoma	2	1	1	2
FIGO stage at diagnosis				
IA2	1	-	4	-
IB1	9	-	4	-
IB2	-	1	1	6
IIA	-	1	-	3
IIB	-	12	2	16
IIIA	-	-	-	1
IIIB	-	1	1	2
IVA	-	2	2	4
IVB	-	-	1	-
Mean (range) follow-up, months	19 (14–26)	20 (2–32)	17 (8–31)	26 (5–53)

Table 6. Summary of cell lines used in Papers III and IV

	Origin	Histology	Sensitivity to cisplatin	Paper
LU-HNxSCC-7	Head and neck carcinoma	Moderately differentiated SCC	High	III and IV
LU-HNxSCC-14	Head and neck carcinoma	Well differentiated SCC	High	III
LU-HNxSCC-24	Head and neck carcinoma	Moderately differentiated SCC	Moderate to high	IV
LU-CX-2	Cervical cancer	Poorly differentiated SCC	Low	IV
SCC = Squamous cell carcinoma				

(Zietman et al. 1988; Taghian et al. 1993). The process of xenografting and the method of evaluation have previously been described in detail from our laboratory (Wennerberg 1984). The nude mice used in our studies have been locally bred, xenografted and serially passed in-house. All use of xenografts was approved by the regional ethics board of southern Sweden regarding animal testing.

Cell lines

(Papers III–IV)

Four different in-house cell lines were used, all originating from primary un-treated tumours. The cell lines are previously tested in vivo and in vitro for sensitivity to cisplatin and their tumour proper-

ties are well known. Table 6 summarizes the characteristics of the cell lines. Tumour cell lines originating from head and neck SCCs from patients diagnosed and treated at Lund University Hospital were used as an experimental model. No cervical carcinoma cell lines were available initially. The strong similarities between SCCs from the head and neck and from the uterine cervix, with respect to histology, HPV relation, and biologic properties, justify the use of both types of tumour cells in our experiments. During the period of this thesis, the cell line LU-CX-2, which originated from a poorly differentiated squamous cell carcinoma of the uterine cervix, was successfully established by our laboratory and subsequently used in Paper IV. This cell line originates from one of the patients included in group 2 in the clinical trial.

Methods

The clinical trial

(Papers I and II)

Patients in group 1, the early disease group, underwent an FDG-PET scan 6 months after radical surgery. The patients with locally advanced disease, group 2, underwent FDG-PET scans as outlined in Figure 8. A baseline FDG-PET (PET1) was performed before treatment start, a second predictive FDG-PET scan (PET2) was performed during the third week of EBRT and before the start of brachytherapy, and finally a third FDG-PET (PET3) was performed 3 months after the completion of treatment. The patients in group 3, the relapse group, underwent an FDG-PET scan as part of the re-staging procedure before starting any relapse treatment.

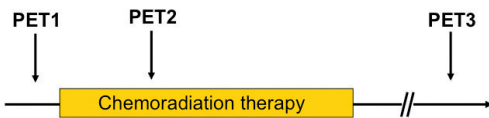


Figure 8. The timing of FDG-PET in group 2.

Evaluation of FDG-PET

(Papers I and II)

Software fusion of PET and CT images was performed using fiducial markers. All images, both PET images and PET-CT fused images, were visually evaluated by two experienced investigators with access to clinical data. The fused images are henceforth referred to as FDG-PET images. Any focus of elevated FDG metabolism above background level, not located in areas of physiological FDG uptake or where the clinical data did not suggest the presence of non-malignant hypermetabolic lesions (i.e. inflammatory or infectious foci), were interpreted as malignant. For the FDG-PET studies obtained during or after treatment, a complete visual metabolic response (CR) was defined as a decrease in FDG uptake to background level at sites of pre-treatment pathological FDG uptake. Partial

metabolic response (PR) was defined as a distinct decrease in metabolism but with residual activity above background level at sites of pathological hypermetabolism in the pre-treatment FDG-PET image. All hypermetabolic sites with minor visual changes, where the above mentioned criteria were not fulfilled, were judged as stable disease (SD). Obvious increases in metabolic activity or new hypermetabolic pathological sites were defined as progressive disease (PD). This is outlined in Figure 9.

In the patients with locally advanced disease, group 2, we further analysed the results of PET1 and PET2 with respect to tumour uptake and metabolism of FDG. The SUVmax was calculated by normalization of regional radioactivity to injected dose and body weight (Strauss et al. 1991). The MR_{FDG} was calculated in terms of $\mu\text{mol}/\text{min}/100\text{ g}$ tumour tissue, as previously described by our group, using a modified autoradiographic formula based on the deoxyglucose model (Brun et al. 1997). For this purpose, repeated blood samples were obtained until 60 minutes after the injection of FDG.

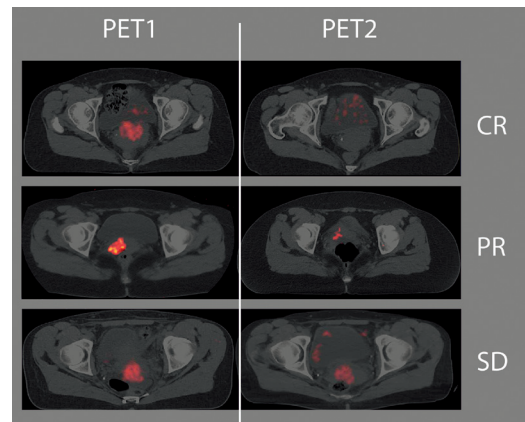


Figure 9. Cervical carcinomas on PET1 and PET2. CR = complete response, PR = partial response, SD = stable disease.

Statistical analyses

(Paper II)

The Kaplan-Meier method was used to estimate progression-free survival (PFS) and the log-rank test, for trend where appropriate, was used to test the null hypotheses of equal PFS in subgroups of patients. Cox regression was used to estimate the prognostic value of variables, measured on a continuous scale, and to estimate the prognostic effect, hazard ratio, of SUV_{max}, of MR_{FDG}, and of visual metabolic response after adjustment for FIGO stage. Multivariate analysis to adjust for FIGO stage was performed. The model was deliberately simplified to limit the complexity of a model fitted to a small dataset with few events. Proportional hazards assumptions were checked graphically. All tests were two-sided and the significance level was set to 0.05. Stata 10.1 (StataCorp 2009) was used for all the statistical analyses.

Cell cultures

(Papers III and IV)

Cell line stocks were stored frozen. After thawing, the malignant cell lines were propagated 7 times before being used in experiments. The fibroblasts used in Paper IV were propagated only once, to ensure that their properties were kept intact. All cell lines were maintained at 37°C in a humidified atmosphere containing 5% CO₂, and grown as monolayer cultures in Dulbecco's Modified Eagle Medium (DMEM) supplemented with foetal calf serum and antibiotics in accordance with the routine practice in our laboratory. The cell line LU-CX-2 was established both *in vitro* and *in vivo*. It has been cytogenetically analysed and tested for sensitivity to cisplatin *in vitro* and *in vivo*, and also tested for radiosensitivity *in vivo*.

Phosphor imaging with FDG

(Paper III)

Phosphor imaging can be used as an alternative to radiography and enables accurate measurements of very weak, or very strong, radioactive samples (Johnston et al. 1990). The phosphor imag-

ing screens are composed of crystals containing europium, Eu+2, that are oxidized to Eu+3 when exposed to ionizing radiation. After exposure, the latent image formed by Eu+3 is released by scanning the screen with a laser (633 nm) that causes the Eu+3 to revert back to Eu+2 releasing a photon at 390 nm. This luminescence is collected, and its position of origin is detected by the laser, which results in a representation of the latent image that can be viewed and analysed with the appropriate software.

The tumour-bearing nude mice were orally fed 0.2 ml (4 MBq) ¹⁸F-FDG 45 min before sacrifice. The tumours were then cut in 10-µm thick sections and phosphor imaging screens were exposed to the sections for approx. 16 hrs. A BAS 3000 reader and Image Gauge software (all from Fuji Photo Film Co., Ltd.) were used to analyse the results. To obtain quantitative results, we spotted increasing amounts of ¹⁸F-FDG on thin-layer chromatography plates and exposed the samples to the phosphor imaging screens together with the tumour sections. This procedure enabled a quantification of the level of ¹⁸F-FDG uptake in the tumour sections as MBq/g tumour tissue.

Real-time fluorescence microscopy with 2-NBDG

(Paper IV)

The fluorescent glucose analogue 2-[N-(7nitrobenz-2-oxa-1,3-diazol-4-yl)amino]-2-deoxyglucose (2-NBDG) was used as an optical marker of cellular glucose uptake. Like FDG, 2-NBDG is transported by the GLUTs into the cells where it accumulates before ultimately undergoing dephosphorylation (Lloyd et al. 1999). 2-NBDG has been demonstrated to provide a good optical marker of glucose uptake and metabolism (O'Neil et al. 2005). The green fluorophore fluorescein (FITC) was conjugated to the 2-NBDG to provide the fluorescence capacity.

The principles of a fluorescence microscope are demonstrated in Figure 10. A specimen labelled with a fluorophore is illuminated with light of a specific wavelength that is then absorbed by the fluorophore causing it to emit longer wavelengths of light of a different colour. Through the use of a

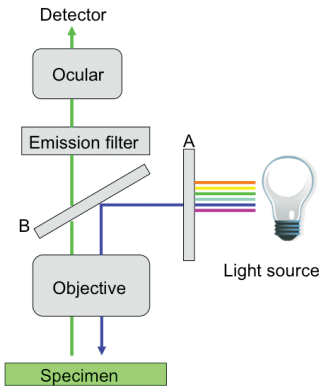


Figure 10. The principle of fluorescence microscopy. A specimen labelled with a fluorophore is illuminated with light of a specific wavelength which is then absorbed by the fluorophore causing it to emit longer wavelengths of light of a different colour. Through the use of an excitation filter (A), a dichromatic beam splitter (B) and an emission filter, a single fluorophore, or colour, is managed at a time.

dichromatic beam splitter and an emission filter, a single fluorophore, or colour, is managed at a time. The fluorescence microscopy was performed using a Leitz Orthoplan Microscope equipped with epilluminator and video-triggered stroboscopic illumination from a xenon arc. A silicon intensified target camera was attached to the microscope and a Zeiss Achroplan 20X/0.5 W objective was used

for capturing images. The fluorescence intensity of the cells was obtained using a green filter protein (GFP) filter set.

Image analysis was performed using Image Pro Plus 6.2 (Media Cybernetics, Inc.). A magnification of 20X was used for image analysis. The average fluorescence intensity was calculated in one field of observation as the number of pixels representing tumour cell area, with intensity above the background level, divided by the number of pixels representing the total tumour cell area. The background level was set as 45 on an arbitrary grey-scale between 0 and 255.

Flow cytometry

(Paper IV)

Flow cytometry was used for cell cycle analysis. The samples were analysed using a FACSCalibur flow cytometer (BD Biosciences) equipped with an argon ion laser. Propidium iodide-stained cells were analysed using an excitation wavelength of 488 nm. The Cell Quest Pro™ software was used for data acquisition and analysis. The cell cycle phase distributions were determined by applying the ModFit Lt 3.1 software (Verity Software House) on the DNA histograms.

Results

FDG-PET in cervical cancer: staging, re-staging and follow-up (I)

For the group of patients with early stage cervical cancer, group 1, no pathological hypermetabolic foci were found on the FDG-PET scans 6 months after surgery. In 9 of the patients no recurrences were found during a mean follow-up time of 19 (14–25) months. One patient suffered a vaginal recurrence 8 months after the negative follow-up FDG-PET scan. This was regarded as a true negative because of the extended time interval.

In group 2, consisting of 17 patients with locally advanced disease, FDG-PET detected every known tumour localisation, previously unknown locations of metastases in 4 patients and a synchronous pulmonary carcinoma in one patient. The findings resulted in a change in treatment plans for 24% (4/17) of the patients. One false negative FDG-PET result was recorded. In that case neither FDG-PET nor CT were able to visualise two pulmonary metastases, 2 and 4 mm in diameter, which were discovered on a following CT scan 5 weeks later.

Group 3 consisted of 15 patients with relapse or a strong clinical suspicion thereof. In 3 cases, a relapse could not be confirmed in spite of a strong clinical suspicion. After an event-free follow-up period of 12, 9, and 6 months, respectively, the FDG-PET scans were considered true negatives. For the remaining 12 patients with confirmed relapses, FDG-PET was true positive in 11 patients and also detected more sites of metastases than CT and MRI did. The FDG-PET findings resulted in additional investigational procedures for 6 patients and changes in treatment plans for 25% (3/12) of the patients. One false positive FDG-PET result was recorded. This was a hypermetabolism in an axillary lymph node of a patient with a pelvic relapse.

Prediction of patient outcome with FDG-PET early during radiotherapy for locally advanced cervical cancer (II)

In this longitudinal study with 32 fully evaluable patients, positive lymphnodes were found on the pre-treatment FDG-PET, PET1, in 11 patients, six of which did not have previously known lymphnode metastases.

PET2 was performed after a mean dose of 23 Gy (range 16–27) of EBRT, +/- concomitant cisplatin, and was evaluated visually (n=32), using SUV_{max} (n=32) and MR_{FDG} (n=22). Visual metabolic CR was found in 7 patients, none of which had relapsed after a median follow-up time of 36 months (range 14–53). For a complete flow diagram of the patient outcome, see Figure 11. Visual metabolic response at PET2 was a significant predictor of PFS in a univariate analysis ($p = 0.03$). The 2-year PFS for patients with visual metabolic CR, PR, and SD on PET2 were 100%, 54% (95% CI 27%–75%), and 54% (95% CI 13%–82%) respectively. In multivariate analyses the visual metabolic response at PET2 was not an independent predictor of PFS ($p = 0.1$) but showed a hazard ratio of 2.3 for relapse in the absence of visual metabolic CR (95% CI 0.8–6.3). No cut-off values for the absolute values of SUV_{max} or MR_{FDG} , for correlation to study end-points, could be established to help further differentiate the patients with visual metabolic PR or SD on PET2. When the seven patients with visual metabolic CR were excluded from analysis, neither the absolute values of SUV_{max} and MR_{FDG} at PET2, nor the relative change in SUV_{max} and MR_{FDG} were significant predictors of relapse after adjustment for FIGO stage.

A remaining hypermetabolism on PET3, which was performed at a mean 3 (range 3–4) months after completion of EBRT, was significantly associated with relapse ($p < 0.0001$, log-rank test for trend over CR, PR, SD, and PD). Relapses were diagnosed at a median of 11 months (range 2–29) after PET3 and involved para-aortic and distant metastases. The only patient who relapsed less than

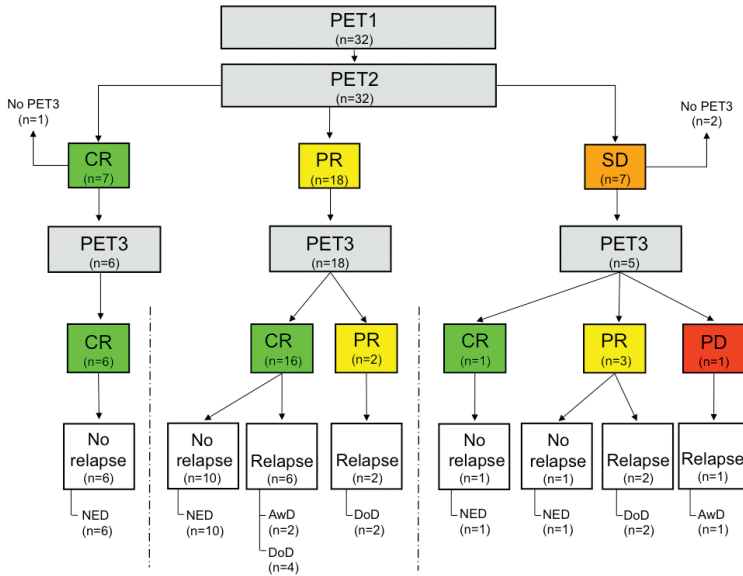


Figure 11. Flow diagram showing the clinical outcome of individual patients in relation to the visual metabolic response on FDG-PET early during treatment. One patient with CR at PET2 did not undergo PET3 for technical reasons but is alive without relapse. Two patients with SD at PET2 did not undergo PET3; one is alive without disease and one has died of intercurrent cause without disease. CR = complete response, PR = partial response, SD = stable disease, PD = progressive disease, NED = alive with no evidence of disease, AwD = alive with disease, DoD = dead of disease.

6 months after PET3 was the patient diagnosed with small pulmonary metastases on CT. Of the 6 patients with remaining metabolic tumour activity at PET3 (PR+PD), all but one have relapsed. The median follow-up time of all patients was 28 months (range 5–53).

Early changes in FDG metabolism in squamous cell carcinoma during chemotherapy in vivo and in vitro (III)

In the cisplatin-treated xenografted tumours, the highest FDG uptake in MBq/g tumour was observed on day 1 after treatment and the levels at this point in time were higher than in the un-treated control group. Thus, a very early increase in the metabolism of the treated tumours, a metabolic flare, was seen. No corresponding tumour growth was seen coupled to this phenomenon. The level of FDG uptake then decreased over time in all treated tumours, whereas the FDG uptake in the control group remained constant at the same high level in every tumour.

With histopathological evaluation we found that on day 1 after cisplatin administration, the hyper-metabolic regions on the phosphor imaging screens contained mainly viable tumour cells. Only a small number of regressively changed cells were present at this point in time. The proportions changed gradually in the sequential observations and on day 8 only scattered viable tumour cells were visible in a mass of regressively changed cells. In the non-treated control group all areas of focal hypermetabolism consisted of viable tumour cells. A high level of FDG uptake correlated well with a large proportion of viable tumour cells. We observed no significant changes in the histopathological pattern in the control group over time. A small number of reactive cells, mainly lymphocytes, were evenly distributed over the tumour sections and did not contribute to the FDG uptake.

Following the in vitro administration of cisplatin to the SCC cell lines, a dose-response relationship was seen, with fewer remaining viable cells after exposure to higher cisplatin doses. At day 5 the FDG uptake per viable cell exposed to cisplatin was increased, compared to the untreated controls,

except for the cells treated with the lowest dose of cisplatin. Thus, an increase in uptake of FDG per viable tumour cell was seen in the surviving cells.

Early metabolic flare in squamous cell carcinoma after chemotherapy is a marker of treatment sensitivity in vitro (IV)

For the tumour cells exposed to cisplatin, the uptake of the glucose analogue 2-NBDG increased over time as opposed to the non-treated control cells, in which the uptake remained constant on a moderate level. The fibroblasts showed a low uptake of 2-NBDG throughout the experiment. The level of 2-NBDG uptake of the tumour cell lines was correlated to the previously known sensitivity to cisplatin, with the more sensitive cell line showing the highest 2-NBDG uptake. We also observed that the higher the dose of cisplatin, the higher the uptake

of 2-NBDG. The difference in 2-NBDG uptake was present already at day 1 in the cell line most sensitive to cisplatin and from day 3 in both of the other tumour cell lines. Visually, the early increase in uptake of 2-NBDG was most pronounced in pre-apoptotic cells. As expected, cell survival following exposure to cisplatin varied between the SCC cell lines, with the two more sensitive cell lines demonstrating a higher degree of cell kill than the less sensitive one.

With flow cytometry we found that cisplatin exposure of the tumour cells resulted in an accumulation of cells in the S phase and subsequent cell cycle arrest in the G2/M phase. This effect was observed on days 3 and 6, with the accumulation more pronounced after the higher cisplatin dose. The untreated tumour cells showed a gradually increasing G1 phase over time and no cell cycle arrest. For the fibroblasts a brief and transient accumulation of cells in the S phase and in the G2/M phase was observed after cisplatin exposure.

General discussion

Clinical applications of FDG-PET in cervical cancer

When the prospective study on cervical cancer and FDG-PET, as described in Papers I and II, was initiated in 2003 there was limited experience regarding the benefit of FDG-PET in this group of patients. As of today, data have accumulated from a number of reports. Although many are single centre retrospective studies, it is clearly shown that FDG-PET has a higher sensitivity and specificity for detection of lymph node metastases than conventional imaging (Unger et al. 2005; Yeh et al. 2002). This was also confirmed by our results. We found previously unknown lymph node metastases in 28% (13/47) of the patients undergoing FDG-PET before treatment for primary or relapsing disease. The presence of lymph node metastases has a significant impact on prognosis. In two retrospective analyses of over 300 patients with locally advanced cervical cancer, nodal status on pre-treatment FDG-PET was the major predictor of outcome and nodal status was superior to FIGO stage in this respect (Grigsby et al. 2001; Narayan et al. 2009).

The most important clinical issue when a new procedure is considered is whether or not it may lead to a benefit for the patients, i.e. an improvement in survival rates or a reduction of treatment side-effects. FDG-PET is a costly method and it is not available on a global perspective. However, the information gained by the addition of FDG-PET to the staging or re-staging of cervical cancer is agreed upon to have a high impact on patient management according to recent reviews (Magne et al. 2008; Maffione et al. 2009). This is in agreement with our findings in which the FDG-PET results changed the treatment plans in one of four patients with locally advanced disease or recurrent disease. The treatment of cervical cancer in the developed world is adapted to the known extent of the disease, regardless of the FIGO stage. In many institutions FDG-PET has become an integral part of the pre-treatment work-up of both primary and recurrent

cervical cancer. In the Southern Swedish Health Care region, FDG-PET has recently been added to the new (as of February 2010) guidelines for treatment of cervical cancer, for the purpose of lymph-node evaluation in locally advanced disease and for restaging of recurrent disease.

In follow-up after surgery for cervical cancer FIGO stage I, our aim was to detect early relapses that would be potentially curable with extensive surgery. However, we did not find a benefit of a surveillance FDG-PET six months after surgery. We believe that our limitations were the small size of the study group, in a patient population where relapses are uncommon, and the time-point chosen. A follow-up scan six months after completed therapy was probably too soon. We postulate that one year after treatment would be a more appropriate time for a follow-up study, although this remains to be tested. The single relapse in our study was diagnosed 14 months after surgery, i.e. 8 months after the FDG-PET scan. No other report has to date been presented concerning follow-up with FDG-PET for this group of patients with early-stage disease.

For patients with locally advanced disease, treated with chemoradiation, the aim of a follow-up examination is to detect local pelvic recurrences or persistent tumours that could be subjected to salvage exenteration surgery with a curative intent. It has been shown that persisting or new hypermetabolic foci on FDG-PET three months after completed chemoradiation are associated with a significantly shorter PFS (Grigsby et al. 2004; Schwarz et al. 2007). We found a similar association with relapses in 5 out of 6 patients with remaining hypermetabolism on PET3. No consensus exists regarding the use of FDG-PET for follow-up after chemoradiation. The key issue is that for the absolute majority of patients with persisting tumour after chemoradiation, no cure is available. This fact makes it ethically questionable to routinely perform evaluation FDG-PET outside of clinical trials.

Being able to predict outcome for individual patients early during the course of the treatment

would ideally lead to individualised treatment adjustments based on the response to therapy. The goal would be to spare patients from over-treatment and to avoid under-treatment. For cervical cancer, the only presently available evidence-based option for potential improvement of survival chances is exenteration surgery (Morley et al. 1989; Sharma et al. 2005). However, the information gained by a predictive FDG-PET scan during therapy could serve as selection criteria for inclusion into clinical trials where the non-responding patients could be offered novel treatment strategies.

With FDG-PET after a mean irradiation dose of 23 Gy, 2–3 weeks into treatment, we identified a small group of patients with a complete metabolic response and an excellent prognosis. However, the majority of the patients achieved a metabolic partial response, PR. Among these patients, both complete remission and treatment failures were found during follow-up. Thus, this early FDG-PET could not discriminate between responders and non-responders in a large part of our study population. When evaluating the visual response we strictly classified a scan as showing PR if any remaining hypermetabolism above physiological background activity was seen. There is a lack of consensus on how to interpret FDG-PET results during therapy. For Hodgkin's lymphoma, a widespread agreement has been reached regarding evaluation of FDG-PET scans. By comparison to background levels in the mediastinal blood pool and in the liver, mild or diffuse remaining hypermetabolism early during or after therapy is regarded as non-pathological (Juweid et al. 2007). Hodgkin's lymphoma is very sensitive to cytotoxic treatment with a rapid response and consequently the predictive value of FDG-PET as early as 1–2 weeks into therapy is proven to be reliable (Kostakoglu et al. 2006). It is well known clinically that the velocity of the response differs between different types of tumours, with lymphomas being among those responding fastest and most solid tumours showing a slower rate of regression. In a study by Schwarz et al., the median time to metabolic CR in cervical cancers undergoing radiotherapy was 30 days (range, 18–43) (Schwarz et al. 2008). That study was designed to evaluate the role of FDG-PET in brachytherapy planning for cervical cancer, but Schwarz et al. also found that prediction of patient

outcome with FDG-PET during treatment was feasible (Schwarz et al. 2008). Thirty-six patients underwent repeated FDG-PET scans on days 4–56 during chemoradiation therapy. In accordance with our results, those authors found 6 patients with CR during therapy, but for the remainder of the patients prediction of outcome was not possible. The timing and the method to evaluate FDG-PET scans need further investigation. With our results and those from Schwarz et al. in mind it is reasonable to assume that an improved predictive capability would be achieved by postponing the FDG-PET scan during therapy until approx. 40 Gy of EBRT has been delivered. This would still allow time for treatment adjustments in non-responders. However, that timepoint remains to be evaluated in prospective clinical trials.

Early metabolic changes after cytotoxic therapy

The biological processes behind the early tumour response, visualised by metabolic imaging of glucose uptake, are not fully understood.

Intra-tumour heterogeneity is an important factor when evaluating the metabolism. In each tumour there are often several different tissue components and more than one tumour cell clone. In the xenografted tumours we found a histopathological heterogeneity within the tumours that corresponded to a metabolic heterogeneity, as shown by the distribution of the FDG uptake. This was presented as areas of hypermetabolism corresponding to viable tumour cells, whereas areas of low metabolism contained keratin, fibrosis and regressed cells. An intra-tumour metabolic heterogeneity has also been demonstrated for cervical cancers where the heterogeneity was found to increase with tumour size (Kidd et al. 2008). In clinical studies, therapy-induced FDG uptake in inflammatory cells is often claimed to cause false positive results in early therapy evaluation, such as in the study by Gilham et al. of oesophageal cancer subjected to chemoradiation therapy (Gillham et al. 2006). In a lymphoma murine model, Spaepen et al. found that a significant part of the FDG uptake in a tumour after chemotherapy originated from inflammatory cells, albeit on a lower level of

uptake per cell compared to that of the tumour cells (Spaepen et al. 2003). We addressed the concerns regarding potentially confounding FDG uptake caused by inflammatory cells in tumour stroma cells by *in vivo* and *in vitro* studies, respectively. We have clearly shown that tumour fibroblasts exhibit a glucose uptake far below that of tumour cells and we detected no confounding FDG uptake in reactive cells. This is in agreement with what Aide et al. found in a xenograft model of testicular cancer (Aide et al. 2009). By understanding that tumour heterogeneity influences the FDG uptake and consequently the FDG-PET image, the use of a mean SUV of a large area should be avoided because it would provide a false low value by including non-tumour tissue or non-viable tumour cells. When evaluating tumours with sequential FDG-PET scans, we believe that the main focus of interest should be the smaller areas of hypermetabolism within a tumour. Those areas, the hotspots, probably provide the most accurate representation of tumour activity.

A possible confounding factor when evaluating FDG-PET early during therapy would be a metabolic flare, a rise in activity induced by the treatment (Aliaga et al. 2007). This has been observed both clinically and experimentally with sequential FDG studies of breast cancer during hormonal treatment (Mortimer et al. 2001; Dehdashti et al. 1999; Aliaga et al. 2007). The presence of a metabolic flare on FDG-PET, after a single dose of 30 mg estradiol, has been shown to be predictive of treatment response to endocrine treatment of metastasised breast cancer and the flare was also associated with improved survival (Dehdashti et al. 2009). The metabolic flare induced by hormonal therapy is generally believed to be the result of an initial agonistic effect on tumour growth which precedes tumour regression (Harris 2010). The mechanisms underlying the metabolic flare we observed in squamous cell carcinomas *in vivo* and *in vitro* are yet to be explained. We believe that the flare is a treatment effect as all controls

were negative in respect to this phenomenon. The main explanation of these findings concerns treatment effects preceding tumour cell kill. The flare may involve an increased tumour cell metabolism, due to energy dependent apoptotic changes, or a passive leakage of FDG, due to a damaged cell membrane. In the responding xenografted tumours we found a distinct and transient increase in FDG uptake on day 1 after treatment. In addition, with a real-time fluorescence microscope, we observed a flare reaction that was most pronounced in the cell lines which had the highest sensitivity to cisplatin and which showed the highest degree of pre-apoptotic cells after exposure to cisplatin. Similar results have been reported from a testicular cancer xenograft model, where a transient increase in FDG uptake was related to cell cycle arrest and early stage apoptosis (Aide et al. 2009). On the other hand, exposure to cytotoxic agents could cause a selection of a resistant and more aggressive clone of tumour cells that could have an increased glucose uptake. Our finding of an increased FDG uptake per viable tumour cell five days after cisplatin exposure *in vitro* is equivocal. Evaluation at later time points would be of interest to elucidate if re-growth occurs.

By using tracer molecules other than FDG, different aspects of the early changes after cytotoxic treatment may be better understood. Interestingly, an increased cellular proliferation rate visible as a flare reaction with radiolabelled thymidine, FLT-PET, has been observed in non-small cell lung cancers responding to 2 Gy of radiotherapy (Everitt et al. 2009). As with the flare in glucose uptake, the flare in proliferation could be a sign of cellular stress after cytotoxic treatment. A tracer molecule to detect apoptosis or irreversible cell damage would be helpful to understand tumour behaviour after cytotoxic treatment. An example of such a marker for apoptosis is annexin V, which is currently being investigated for this purpose (Yagle et al. 2005; Zhang et al. 2009).

Conclusions

Paper I

- FDG-PET was not beneficial in our setting in routine surveillance after surgery for early stage cervical cancer six months after surgery.
- FDG-PET added valuable information on the extent of the disease in staging of locally advanced cervical cancer.
- FDG-PET accurately detected relapses and had a high impact on the clinical management of recurrent cervical cancer.

Paper II

- With FDG-PET early during chemoradiation, a group of patients with an excellent prognosis could be identified. However, for the majority of the patients in our setting, it was not possible to predict outcome at this early time point.
- The visual evaluation of FDG-PET scans during therapy was reliable. No predictive gain was found by adding a semi-quantitative method

(SUV). Full quantitative evaluation (MR) was not a feasible method.

- FDG-PET three months after chemoradiation provided reliable prognostic information.

Paper III

- After cisplatin treatment, an early transient increase in FDG uptake was found in vivo. This was followed by tumour regression.
- In cells surviving exposure to cisplatin in vitro, an increase in FDG uptake per tumour cell was found.

Paper IV

- The 2-NBDG uptake after exposure to cisplatin was increased in tumour cells and not in fibroblasts.
- A metabolic flare after cisplatin exposure was an early sign of response to treatment.

Future perspectives

By explaining the early metabolic changes that cytotoxic treatment induces in a tumour, interpretation of FDG-PET scans performed during therapy is facilitated. Future experimental studies should address intracellular and intra-tumoural metabolic changes following cytotoxic therapy. The relationship that we found between the sensitivity to therapy and the degree of metabolic flare needs to be confirmed. This relationship should also be evaluated for different tumour types and for different types of treatment.

To reliably predict patient outcome it is necessary to explore the optimal timepoint and the standards for evaluation of FDG-PET scans during therapy for cervical cancer. Future clinical trials investigating the predictive potential of FDG-PET during chemoradiation therapy for cervical cancer need large patient populations and should be performed as multi-centre trials. An attractive approach would be to use the results of individual predictive FDG-PET scans as inclusion criteria for clinical trials investigating novel therapies in non-responding patients.

Acknowledgements

The work in this thesis has been made possible by the efforts of many people to whom I am most grateful; but there are some who deserve special thanks.

My supervisor **Lisa Kjellén**, whose sharp intellect and brilliant ideas secured the project. It has been a privilege.

My co-supervisor **Eva Brun**, who initiated the clinical trial. I owe you immensely for every-day tutoring, inspiration and generosity throughout the entire work.

The women that participated in the study. They represent the reason to do research.

Christina Boll and **Margareta Ohlsson**, for always helping me in the nicest way at the lab.

Mona Ridderheim, co-author and inspirational mentor, for always guiding me forward.

Co-authors **Lars Ekblad**, **Eva Henriksson**, **Pär-Ola Bendahl**, and **Arne Brun**, for kindly sharing your expertise with me.

Tomas Ohlsson, physicist and co-author, for FDG assistance and analyses on late Friday afternoons.

Parisa Abedinpour and **Per Borgström**, for friendly collaboration and co-authorship in Paper IV.

Johan Wennerberg, for time, for stimulating discussions in the lab-group and for co-authoring Paper IV.

Bo Baldetorp, for maintaining a welcoming atmosphere at the Kamprad lab and for generous co-authorship.

Carsten Rose, for time and support and for creating a research-friendly work-place at the Department of Oncology.

Anders Sandell, for really trying to make me understand PET physics.

Hans Hansson, for kind assistance at the PET facility.

Anna Måsbäck, for pathologic review. We will find a place for the immunohistochemistry.

All former and present colleagues at the Department of Oncology, for making it such a good place to work.

Collaborating tumour surgeons at the Department at Gynaecology and Obstetrics, and especially **Päivi Kannisto**, for good team-work in the cervix-group.

My friends and colleagues in “The Red Room”; **Susanne Malander** and **Fredrika Killander**. Together we have shared tears and laughter. You hold a special place in my heart.

The DYT team, for girl-power and especially **Jessica Wihl**, for good talks.

Pernilla Stenström, for always listening and never doubting.

My parents, Elsa and Göte, for your support and solid belief in me.

Stefan, my husband, for love, support, endless patience and a clear mind. You are my everything.

Financial support was generously granted from: Gunnar Nilssons Cancerstiftelse, Fru Berta Kamprads Stiftelse För Utforskning och Bekämpning av Cancersjukdomar, Region Skåne, The Faculty of Medicine at Lund University and The Swedish Cancer Society.

References

- Aide N, Poulain L, et al. (2009). Early evaluation of the effects of chemotherapy with longitudinal FDG small-animal PET in human testicular cancer xenografts: early flare response does not reflect refractory disease. *Eur J Nucl Med Mol Imaging* 36: 396-405.
- Alfsen GC, Kristensen GB, et al. (2001). Histologic subtype has minor importance for overall survival in patients with adenocarcinoma of the uterine cervix: a population-based study of prognostic factors in 505 patients with nonsquamous cell carcinomas of the cervix. *Cancer* 92: 2471-83.
- Aliaga A, Rousseau JA, et al. (2007). A small animal positron emission tomography study of the effect of chemotherapy and hormonal therapy on the uptake of 2-deoxy-2-[F-18]fluoro-D-glucose in murine models of breast cancer. *Mol Imaging Biol* 9: 144-50.
- Anderson CD (1933). Free positive electrons resulting from the impact upon atomic nuclei of the photons from TH C⁺. *Science* 77: 432.
- Andrae B, Kemetli L, et al. (2008). Screening-preventable cervical cancer risks: evidence from a nationwide audit in Sweden. *J Natl Cancer Inst* 100: 622-9.
- Ault KA (2007). Effect of prophylactic human papillomavirus L1 virus-like-particle vaccine on risk of cervical intraepithelial neoplasia grade 2, grade 3, and adenocarcinoma in situ: a combined analysis of four randomised clinical trials. *Lancet* 369: 1861-8.
- Ayhan A, Al RA, et al. (2004). Prognostic factors in FIGO stage IB cervical cancer without lymph node metastasis and the role of adjuvant radiotherapy after radical hysterectomy. *Int J Gynecol Cancer* 14: 286-92.
- Bastos J, Peleteiro B, et al. (2009). The state of the art of cancer control in 30 European countries in 2008. E-pub ahead of print: *Int J Cancer*.
- Belhocine T, Thille A, et al. (2002). Contribution of whole-body ¹⁸F-FDG PET imaging in the management of cervical cancer. *Gynecol Oncol* 87: 90-7.
- Benedet JL, Odicino F, et al. (2003). Carcinoma of the cervix uteri. *Int J Gynaecol Obstet* 83 Suppl 1: 41-78.
- Bergmark K, Avall-Lundqvist E, et al. (2002). Patient-rating of distressful symptoms after treatment for early cervical cancer. *Acta Obstet Gynecol Scand* 81: 443-50.
- Board M, Humm S, et al. (1990). Maximum activities of key enzymes of glycolysis, glutaminolysis, pentose phosphate pathway and tricarboxylic acid cycle in normal, neoplastic and suppressed cells. *Biochem J* 265: 503-9.
- Bodurka-Bevers D, Morris M, et al. (2000). Posttherapy surveillance of women with cervical cancer: an outcomes analysis. *Gynecol Oncol* 78: 187-93.
- Bosch FX, Lorincz A, et al. (2002). The causal relation between human papillomavirus and cervical cancer. *J Clin Pathol* 55: 244-65.
- Bray F, Carstensen B, et al. (2005). Incidence trends of adenocarcinoma of the cervix in 13 European countries. *Cancer Epidemiol Biomarkers Prev* 14: 2191-9.
- Brooks RA (1982). Alternative formula for glucose utilization using labeled deoxyglucose. *J Nucl Med* 23: 538-9.
- Brooks RA, Rader JS, et al. (2009). Surveillance FDG-PET detection of asymptomatic recurrences in patients with cervical cancer. *Gynecol Oncol* 112: 104-9.
- Brown RS, Fisher SJ, et al. (1993). Autoradiographic evaluation of the intra-tumoral distribution of 2-deoxy-D-glucose and monoclonal antibodies in xenografts of human ovarian adenocarcinoma. *J Nucl Med* 34: 75-82.
- Brun E, Kjellen E, et al. (2002). FDG PET studies during treatment: prediction of therapy outcome in head and neck squamous cell carcinoma. *Head Neck* 24: 127-35.
- Brun E, Ohlsson T, et al. (1997). Early prediction of treatment outcome in head and neck cancer with 2-¹⁸F-FDG PET. *Acta Oncol* 36: 741-7.
- Castell F, Cook GJ (2008). Quantitative techniques in ¹⁸F-FDG PET scanning in oncology. *Br J Cancer* 98: 1597-601.
- Castellsague X, Diaz M, et al. (2006). Worldwide human papillomavirus etiology of cervical adenocarcinoma and its cofactors: implications for screening and prevention. *J Natl Cancer Inst* 98: 303-15.
- Choi HJ, Roh JW, et al. (2006). Comparison of the accuracy of magnetic resonance imaging and positron emission tomography/computed tomography in the presurgical detection of lymph node metastases in patients with uterine cervical carcinoma: a prospective study. *Cancer* 106: 914-22.
- Cleaves M (1903). Radium: With a preliminary note on radium rays in the treatment of cancer *Med Rec* 64: 601-606.
- Cosin JA, Fowler JM, et al. (1998). Pretreatment surgical staging of patients with cervical carcinoma: the case for lymph node debulking. *Cancer* 82: 2241-8.
- Costa S, Marra E, et al. (2009). Outcome of conservatively treated microinvasive squamous cell carcinoma of the uterine cervix during a 10-year follow-up. *Int J Gynecol Cancer* 19: 33-8.
- Creasman WT, Kohler MF (2004). Is lymph vascular space involvement an independent prognostic factor in early cervical cancer? *Gynecol Oncol* 92: 525-9.
- Dargent D, Martin X, et al. (2000). Laparoscopic vaginal radical trachelectomy: a treatment to preserve the fertility of cervical carcinoma patients. *Cancer* 88: 1877-82.
- Dearling JL, Flynn AA, et al. (2004). Analysis of the regional uptake of radiolabeled deoxyglucose analogs in human tumor xenografts. *J Nucl Med* 45: 101-7.
- DeGrado TR, Coleman RE, et al. (2001). Synthesis and evaluation of ¹⁸F-labeled choline as an oncologic tracer for positron emission tomography: initial findings in prostate cancer. *Cancer Res* 61: 110-7.
- Dehdashti F, Flanagan FL, et al. (1999). Positron emission tomographic assessment of "metabolic flare" to predict response of metastatic breast cancer to antiestrogen therapy. *Eur J Nucl Med* 26: 51-6.

- Dehdashti F, Mortimer JE, et al. (2009). PET-based estradiol challenge as a predictive biomarker of response to endocrine therapy in women with estrogen-receptor-positive breast cancer. *Breast Cancer Res Treat* 113: 509-17.
- Deichen JT, Prante O, et al. (2003). Uptake of [¹⁸F]fluorodeoxyglucose in human monocyte-macrophages in vitro. *Eur J Nucl Med Mol Imaging* 30: 267-73.
- Eary JF, Mankoff DA (1998). Tumor metabolic rates in sarcoma using FDG PET. *J Nucl Med* 39: 250-4.
- Eifel PJ, Winter K, et al. (2004). Pelvic irradiation with concurrent chemotherapy versus pelvic and para-aortic irradiation for high-risk cervical cancer: an update of radiation therapy oncology group trial (RTOG) 90-01. *J Clin Oncol* 22: 872-80.
- Elfgren K, Kalantari M, et al. (2000). A population-based five-year follow-up study of cervical human papillomavirus infection. *Am J Obstet Gynecol* 183: 561-7.
- Elliott P, Coppleson M, et al. (2000). Early invasive (FIGO stage IA) carcinoma of the cervix: a clinico-pathologic study of 476 cases. *Int J Gynecol Cancer* 10: 42-52.
- Engel H, Steinert H, et al. (1996). Whole-body PET: physiological and artifactual fluorodeoxyglucose accumulations. *J Nucl Med* 37: 441-6.
- Everitt S, Hicks RJ, et al. (2009). Imaging cellular proliferation during chemo-radiotherapy: a pilot study of serial ¹⁸F-FLT positron emission tomography/computed tomography imaging for non-small-cell lung cancer. *Int J Radiat Oncol Biol Phys* 75: 1098-104.
- Fahey MT, Irwig L, et al. (1995). Meta-analysis of Pap test accuracy. *Am J Epidemiol* 141: 680-9.
- Fasal E, Simmons ME, et al. (1981). Factors associated with high and low risk of cervical neoplasia. *J Natl Cancer Inst* 66: 631-6.
- Ferlay J, Bray F, et al. (2004). GLOBOCAN 2002: Cancer incidence, mortality and prevalence worldwide. IARC Press: Lyon.
- Flier JS, Mueckler MM, et al. (1987). Elevated levels of glucose transport and transporter messenger RNA are induced by ras or src oncogenes. *Science* 235: 1492-5.
- Franco EL, Harper DM (2005). Vaccination against human papillomavirus infection: a new paradigm in cervical cancer control. *Vaccine* 23: 2388-94.
- Gallagher BM, Fowler JS, et al. (1978). Metabolic trapping as a principle of radiopharmaceutical design: some factors responsible for the biodistribution of [¹⁸F] 2-deoxy-2-fluoro-D-glucose. *J Nucl Med* 19: 1154-61.
- Gillham CM, Lucey JA, et al (2006). (18)FDG uptake during induction chemoradiation for oesophageal cancer fails to predict histomorphological tumour response. *Br J Cancer* 95: 1174-9.
- Gold MA, Tian C, et al. (2008). Surgical versus radiographic determination of para-aortic lymph node metastases before chemoradiation for locally advanced cervical carcinoma: a Gynecologic Oncology Group Study. *Cancer* 112: 1954-63.
- Grigsby PW, Siegel BA, et al. (2001). Lymph node staging by positron emission tomography in patients with carcinoma of the cervix. *J Clin Oncol* 19: 3745-9.
- Grigsby PW, Siegel BA, et al. (2004). Posttherapy [¹⁸F] fluorodeoxyglucose positron emission tomography in carcinoma of the cervix: response and outcome. *J Clin Oncol* 22: 2167-71.
- Grisaru D, Covens A, et al. (2001). Does histology influence prognosis in patients with early-stage cervical carcinoma? *Cancer* 92: 2999-3004.
- Haensgen G, Krause U, et al. (2001). Tumor hypoxia, p53, and prognosis in cervical cancers. *Int J Radiat Oncol Biol Phys* 50: 865-72.
- Hany TF, Gharehpapagh E, et al. (2002). Brown adipose tissue: a factor to consider in symmetrical tracer uptake in the neck and upper chest region. *Eur J Nucl Med Mol Imaging* 29: 1393-8.
- Harper DM, Franco EL, et al. (2006). Sustained efficacy up to 4.5 years of a bivalent L1 virus-like particle vaccine against human papillomavirus types 16 and 18: follow-up from a randomised control trial. *Lancet* 367: 1247-55.
- Harris JR LM, Morrow M, et al. (ed.) (2010) *Diseases of the Breast*. Lippincott Williams & Wilkins: Philadelphia.
- Hatanaka M, Augl C, et al. (1970). Evidence for a functional change in the plasma membrane of murine sarcoma virus-infected mouse embryo cells. Transport and transport-associated phosphorylation of 14C-2-deoxy-D-glucose. *J Biol Chem* 245: 714-7.
- Havrilesky LJ, Wong TZ, et al. (2003). The role of PET scanning in the detection of recurrent cervical cancer. *Gynecol Oncol* 90: 186-90.
- Hellberg D, Stendahl U (2005). The biological role of smoking, oral contraceptive use and endogenous sexual steroid hormones in invasive squamous epithelial cervical cancer. *Anticancer Res* 25: 3041-6.
- Hennipman A, van Oirschot BA, et al. (1988). Glycolytic enzyme activities in breast cancer metastases. *Tumour Biol* 9: 241-8.
- Herr D, Konig J, et al. (2009). Prognostic impact of satellite-lymphovascular space involvement in early-stage cervical cancer. *Ann Surg Oncol* 16: 128-32.
- Herrero R, Brinton LA, et al. (1990). Sexual behavior, venereal diseases, hygiene practices, and invasive cervical cancer in a high-risk population. *Cancer* 65: 380-6.
- Ho CM, Chien TY, et al. (2004). Multivariate analysis of the prognostic factors and outcomes in early cervical cancer patients undergoing radical hysterectomy. *Gynecol Oncol* 93: 458-64.
- Huang SC (2000). Anatomy of SUV. Standardized uptake value. *Nucl Med Biol* 27: 643-6.
- Husain A, Akhurst T, et al. (2007). A prospective study of the accuracy of ¹⁸Fluorodeoxyglucose positron emission tomography (¹⁸FDG PET) in identifying sites of metastasis prior to pelvic exenteration. *Gynecol Oncol* 106: 177-80.
- Hutchings M, Loft A, et al. (2006). FDG-PET after two cycles of chemotherapy predicts treatment failure and progression-free survival in Hodgkin lymphoma. *Blood* 107: 52-9.
- Johnston RF, Pickett SC, et al. (1990). Autoradiography using storage phosphor technology. *Electrophoresis* 11: 355-60.

- Joost HG, Bell GI, et al. (2002). Nomenclature of the GLUT/SLC2A family of sugar/polyol transport facilitators. *Am J Physiol Endocrinol Metab* 282: E974-6.
- Juweid ME, Stroobants S, et al. (2007). Use of positron emission tomography for response assessment of lymphoma: consensus of the Imaging Subcommittee of International Harmonization Project in Lymphoma. *J Clin Oncol* 25: 571-8.
- Kamangar F, Dores GM, et al. (2006). Patterns of cancer incidence, mortality, and prevalence across five continents: defining priorities to reduce cancer disparities in different geographic regions of the world. *J Clin Oncol* 24: 2137-50.
- Keys HM, Bundy BN, et al. (1999). Cisplatin, radiation, and adjuvant hysterectomy compared with radiation and adjuvant hysterectomy for bulky stage IB cervical carcinoma. *N Engl J Med* 340: 1154-61.
- Kidd EA, Grigsby PW (2008). Intratumoral metabolic heterogeneity of cervical cancer. *Clin Cancer Res* 14: 5236-41.
- Kirwan JM, Symonds P, et al. (2003). A systematic review of acute and late toxicity of concomitant chemoradiation for cervical cancer. *Radiother Oncol* 68: 217-26.
- Kosary CL (1994). FIGO stage, histology, histologic grade, age and race as prognostic factors in determining survival for cancers of the female gynecological system: an analysis of 1973-87 SEER cases of cancers of the endometrium, cervix, ovary, vulva, and vagina. *Semin Surg Oncol* 10: 31-46.
- Kostakoglu L, Goldsmith SJ, et al. (2006). FDG-PET after 1 cycle of therapy predicts outcome in diffuse large cell lymphoma and classic Hodgkin disease. *Cancer* 107: 2678-87.
- Kristensen GB, Abeler VM, et al. (1999). Tumor size, depth of invasion, and grading of the invasive tumor front are the main prognostic factors in early squamous cell cervical carcinoma. *Gynecol Oncol* 74: 245-51.
- Kubota R, Yamada S, et al. (1992). Intratumoral distribution of fluorine-18-fluorodeoxyglucose in vivo: high accumulation in macrophages and granulation tissues studied by microautoradiography. *J Nucl Med* 33: 1972-80.
- Kupets R, Thomas GM, et al. (2002). Is there a role for pelvic lymph node debulking in advanced cervical cancer? *Gynecol Oncol* 87: 163-70.
- Lai CH, Huang KG, et al. (2004). Restaging of recurrent cervical carcinoma with dual-phase [¹⁸F]fluoro-2-deoxy-D-glucose positron emission tomography. *Cancer* 100: 544-52.
- Lanciano RM, Won M, et al. (1991). Pretreatment and treatment factors associated with improved outcome in squamous cell carcinoma of the uterine cervix: a final report of the 1973 and 1978 patterns of care studies. *Int J Radiat Oncol Biol Phys* 20: 667-76.
- Landoni F, Maneo A, et al. (1997). Randomised study of radical surgery versus radiotherapy for stage Ib-IIa cervical cancer. *Lancet* 350: 535-40.
- Lin WC, Hung YC, et al. (2003). Usefulness of (18)F-fluorodeoxyglucose positron emission tomography to detect para-aortic lymph nodal metastasis in advanced cervical cancer with negative computed tomography findings. *Gynecol Oncol* 89: 73-6.
- Lindholm P, Leskinen-Kallio S, et al. (1993). Comparison of fluorine-18-fluorodeoxyglucose and carbon-11-methionine in head and neck cancer. *J Nucl Med* 34: 1711-6.
- Lloyd PG, Hardin CD, et al. (1999). Examining glucose transport in single vascular smooth muscle cells with a fluorescent glucose analog. *Physiol Res* 48: 401-10.
- Loft A, Berthelsen AK, et al. (2007). The diagnostic value of PET/CT scanning in patients with cervical cancer: a prospective study. *Gynecol Oncol* 106: 29-34.
- Long HJ, Bundy BN, et al. (2005). Randomized phase III trial of cisplatin with or without topotecan in carcinoma of the uterine cervix: a Gynecologic Oncology Group Study. *J Clin Oncol* 23: 4626-33.
- Lorenz E, Strickert T, et al. (2009). Cervical carcinoma: postoperative radiotherapy: fifteen-year experience in a Norwegian health region. *Int J Gynecol Cancer* 19: 1595-9.
- Mac Manus MP, Wong K, et al. (2002). Early mortality after radical radiotherapy for non-small-cell lung cancer: comparison of PET-staged and conventionally staged cohorts treated at a large tertiary referral center. *Int J Radiat Oncol Biol Phys* 52: 351-61.
- Macheda ML, Rogers S, et al. (2005). Molecular and cellular regulation of glucose transporter (GLUT) proteins in cancer. *J Cell Physiol* 202: 654-62.
- Maffione AM, Piva M, et al. (2009). Positron-emission tomography in gynaecologic malignancies. *Arch Gynecol Obstet* 280: 521-8.
- Magne N, Chargari C, et al. (2008). New trends in the evaluation and treatment of cervix cancer: the role of FDG-PET. *Cancer Treat Rev* 34: 671-81.
- Mankoff DA, Muzi M, et al. (2003). Quantitative positron emission tomography imaging to measure tumor response to therapy: what is the best method? *Mol Imaging Biol* 5: 281-5.
- Mankoff DA, Tewson TJ, et al. (1997). Analysis of blood clearance and labeled metabolites for the estrogen receptor tracer [F-18]-16 alpha-fluoroestradiol (FES). *Nucl Med Biol* 24: 341-8.
- Medina RA, Owen GI (2002). Glucose transporters: expression, regulation and cancer. *Biol Res* 35: 9-26.
- Meigs JV (1951). Radical hysterectomy with bilateral pelvic lymph node dissections; a report of 100 patients operated on five or more years ago. *Am J Obstet Gynecol* 62: 854-70.
- Meta-Analysis Group, MRC. Chemoradiotherapy for Cervical Cancer Meta-Analysis Collaboration (2008). Reducing uncertainties about the effects of chemoradiotherapy for cervical cancer: a systematic review and meta-analysis of individual patient data from 18 randomized trials. *J Clin Oncol* 26: 5802-12.
- Mikhaeel NG, Timothy AR, et al. (2000). 18-FDG-PET for the assessment of residual masses on CT following treatment of lymphomas. *Ann Oncol* 11 Suppl 1: 147-50.
- Monk BJ, Sill MW, et al. (2009). Phase III trial of four cisplatin-containing doublet combinations in stage IVB, recurrent, or persistent cervical carcinoma: a Gynecologic Oncology Group study. *J Clin Oncol* 27: 4649-55.

- Monk BJ, Tian C, et al. (2007). Which clinical/pathologic factors matter in the era of chemoradiation as treatment for locally advanced cervical carcinoma? Analysis of two Gynecologic Oncology Group (GOG) trials. *Gynecol Oncol* 105: 427-33.
- Moreno V, Bosch FX, et al. (2002). Effect of oral contraceptives on risk of cervical cancer in women with human papillomavirus infection: the IARC multicentric case-control study. *Lancet* 359: 1085-92.
- Morley GW, Hopkins MP, et al. (1989). Pelvic exenteration, University of Michigan: 100 patients at 5 years. *Obstet Gynecol* 74: 934-43.
- Morris M, Eifel PJ, et al. (1999). Pelvic radiation with concurrent chemotherapy compared with pelvic and para-aortic radiation for high-risk cervical cancer. *N Engl J Med* 340: 1137-43.
- Mortimer JE, Dehdashti F, et al. (2001). Metabolic flare: indicator of hormone responsiveness in advanced breast cancer. *J Clin Oncol* 19: 2797-803.
- Munoz N, Bosch FX, et al. (2003). Epidemiologic classification of human papillomavirus types associated with cervical cancer. *N Engl J Med* 348: 518-27.
- Nakamoto Y, Higashi T, et al. (2000). Delayed (18F)-fluoro-2-deoxy-D-glucose positron emission tomography scan for differentiation between malignant and benign lesions in the pancreas. *Cancer* 89: 2547-54.
- Nanda K, McCrory DC, et al. (2000). Accuracy of the Papanicolaou test in screening for and follow-up of cervical cytologic abnormalities: a systematic review. *Ann Intern Med* 132: 810-9.
- Narayan K, Fisher RJ, et al. (2009). Patterns of failure and prognostic factor analyses in locally advanced cervical cancer patients staged by positron emission tomography and treated with curative intent. *Int J Gynecol Cancer* 19: 912-8.
- Nishizawa S, Inubushi M, et al. (2005). Physiological ¹⁸F-FDG uptake in the ovaries and uterus of healthy female volunteers. *Eur J Nucl Med Mol Imaging* 32: 549-56.
- Noller KL, Decker DG, et al. (1972). Clear-cell adenocarcinoma of the cervix after maternal treatment with synthetic estrogens. *Mayo Clin Proc* 47: 629-30.
- NSGO; Nordic Society for Gynecological Oncology Advisory Board of Radiotherapy (2006). Guidelines for Irradiation of Advanced Cervical Cancer. Available at www.nsgo.org/.
- O'Doherty MJ, Macdonald EA, et al. (2002). Positron emission tomography in the management of lymphomas. *Clin Oncol (R Coll Radiol)* 14: 415-26.
- O'Neil RG, Wu L, et al. (2005). Uptake of a fluorescent deoxyglucose analog (2-NBDG) in tumor cells. *Mol Imaging Biol* 7: 388-92.
- Oehr P, Biersack HJ, et al. (ed.) (2004) PET and PET-CT in Oncology. Springer-Verlag: Berlin.
- Okino ST, Chichester CH, et al. (1998). Hypoxia-inducible mammalian gene expression analyzed in vivo at a TATA-driven promoter and at an initiator-driven promoter. *J Biol Chem* 273: 23837-43.
- Ozer O, Eskazan AE, et al. (2009). Sarcoidosis mimicking lymphoma on positron emission tomography-computed tomography in two patients treated for lymphoma: two case reports. *J Med Case Reports* 3: 7306.
- Papanicolaou GN (1941). The Diagnostic value of Vaginal Smears in Carcinoma of the Uterus. *Am J Obstet Gynecol* 42: 193-206.
- Parkin DM, Bray F, et al. (2005). Global cancer statistics, 2002. *CA Cancer J Clin* 55: 74-108.
- Parkin DM, Whelan SL, et al. (2002). Cancer Incidence in Five Continents, Vol. VIII. IARC Scientific Publications: Lyon.
- Partridge S, Timothy A, et al. (2000). 2-Fluorine-18-fluoro-2-deoxy-D glucose positron emission tomography in the pretreatment staging of Hodgkin's disease: influence on patient management in a single institution. *Ann Oncol* 11: 1273-9.
- Patlak CS, Blasberg RG, et al. (1983). Graphical evaluation of blood-to-brain transfer constants from multiple-time uptake data. *J Cereb Blood Flow Metab* 3: 1-7.
- Pecorelli S, Benedet JL, et al. (1999). FIGO staging of gynecologic cancer. 1994-1997 FIGO Committee on Gynecologic Oncology. International Federation of Gynecology and Obstetrics. *Int J Gynaecol Obstet* 64: 5-10.
- Pecorelli S, Zigliani L, et al. (2009). Revised FIGO staging for carcinoma of the cervix. *Int J Gynaecol Obstet* 105: 107-8.
- Peters WA, Liu PY, et al. (2000). Concurrent chemotherapy and pelvic radiation therapy compared with pelvic radiation therapy alone as adjuvant therapy after radical surgery in high-risk early-stage cancer of the cervix. *J Clin Oncol* 18: 1606-13.
- Phelps ME (2004). PET. Molecular Imaging and Its Biological Applications. Springer-Verlag: New York.
- Phelps ME, Huang SC, et al. (1979). Tomographic measurement of local cerebral glucose metabolic rate in humans with (F-18)2-fluoro-2-deoxy-D-glucose: validation of method. *Ann Neurol* 6: 371-88.
- Plummer M, Herrero R, et al. (2003). Smoking and cervical cancer: pooled analysis of the IARC multi-centric case-control study. *Cancer Causes Control* 14: 805-14.
- Potter R, Haie-Meder C, et al. (2006). Recommendations from gynaecological (GYN) GEC ESTRO working group (II): concepts and terms in 3D image-based treatment planning in cervix cancer brachytherapy-3D dose volume parameters and aspects of 3D image-based anatomy, radiation physics, radiobiology. *Radiother Oncol* 78: 67-77.
- Quinn MA, Benedet JL, et al. (2006). Carcinoma of the cervix uteri. FIGO 6th Annual Report on the Results of Treatment in Gynecological Cancer. *Int J Gynaecol Obstet* 95 Suppl 1: S43-103.
- Rasey JS, Grunbaum Z, et al. (1987). Characterization of radiolabeled fluoromisonidazole as a probe for hypoxic cells. *Radiat Res* 111: 292-304.
- Reivich M, Alavi A, et al. (1985). Glucose metabolic rate kinetic model parameter determination in humans: the lumped constants and rate constants for [¹⁸F]fluorodeoxyglucose and [¹¹C]deoxyglucose. *J Cereb Blood Flow Metab* 5: 179-92.

- Riedl CC, Akhurst T, et al. (2007). ^{18}F -FDG PET scanning correlates with tissue markers of poor prognosis and predicts mortality for patients after liver resection for colorectal metastases. *J Nucl Med* 48: 771-5.
- Rose PG, Bundy BN, et al. (1999). Concurrent cisplatin-based radiotherapy and chemotherapy for locally advanced cervical cancer. *N Engl J Med* 340: 1144-53.
- Rotman M, Sedlis A, et al. (2006). A phase III randomized trial of postoperative pelvic irradiation in Stage IB cervical carcinoma with poor prognostic features: follow-up of a gynecologic oncology group study. *Int J Radiat Oncol Biol Phys* 65: 169-76.
- Rudlowski C, Becker AJ, et al. (2003). GLUT1 messenger RNA and protein induction relates to the malignant transformation of cervical cancer. *Am J Clin Pathol* 120: 691-8.
- Ryu SY, Kim MH, et al. (2003). Detection of early recurrence with ^{18}F -FDG PET in patients with cervical cancer. *J Nucl Med* 44: 347-52.
- Sankaranarayanan R (2006). Overview of cervical cancer in the developing world. FIGO 6th Annual Report on the Results of Treatment in Gynecological Cancer. *Int J Gynaecol Obstet* 95 Suppl 1: S205-10.
- Sankaranarayanan R, Budukh AM, et al. (2001). Effective screening programmes for cervical cancer in low- and middle-income developing countries. *Bull World Health Organ* 79: 954-62.
- Sanli M, Isik AF, et al. (2009). Reliability of positron emission tomography-computed tomography in identification of mediastinal lymph node status in patients with non-small cell lung cancer. *J Thorac Cardiovasc Surg* 138: 1200-5.
- Schaer LR, Anger HO (1965). Organ visualization using scintillation camera techniques. *Ann Intern Med* 63: 442-53.
- Schwarz JK, Lin LL, et al. (2008). ^{18}F -fluorodeoxyglucose-positron emission tomography evaluation of early metabolic response during radiation therapy for cervical cancer. *Int J Radiat Oncol Biol Phys* 72: 1502-7.
- Schwarz JK, Siegel BA, et al. (2007). Association of post-therapy positron emission tomography with tumor response and survival in cervical carcinoma. *Jama* 298: 2289-95.
- Sedlis A, Bundy BN, et al. (1999). A randomized trial of pelvic radiation therapy versus no further therapy in selected patients with stage IB carcinoma of the cervix after radical hysterectomy and pelvic lymphadenectomy: A Gynecologic Oncology Group Study. *Gynecol Oncol* 73: 177-83.
- Sharma S, Odunsi K, et al. (2005). Pelvic exenterations for gynecological malignancies: twenty-year experience at Roswell Park Cancer Institute. *Int J Gynecol Cancer* 15: 475-82.
- Shepherd JH, Milliken DA (2008). Conservative surgery for carcinoma of the cervix. *Clin Oncol (R Coll Radiol)* 20: 395-400.
- Shields AF, Grierson JR, et al. (1996). Development of labeled thymidine analogs for imaging tumor proliferation. *Nucl Med Biol* 23: 17-22.
- Smith JS, Lindsay L, et al. (2007). Human papillomavirus type distribution in invasive cervical cancer and high-grade cervical lesions: a meta-analysis update. *Int J Cancer* 121: 621-32.
- Sokoloff L, Reivich M, et al. (1977). The [^{14}C]deoxyglucose method for the measurement of local cerebral glucose utilization: theory, procedure, and normal values in the conscious and anesthetized albino rat. *J Neurochem* 28: 897-916.
- Spaepen K, Stroobants S, et al. (2003). [^{18}F]FDG PET monitoring of tumour response to chemotherapy: does [^{18}F]FDG uptake correlate with the viable tumour cell fraction? *Eur J Nucl Med Mol Imaging* 30: 682-8.
- Strauss LG, Conti PS (1991). The applications of PET in clinical oncology. *J Nucl Med* 32: 623-48; discussion 649-50.
- Taghian A, Budach W, Zet al. (1993). Quantitative comparison between the transplantability of human and murine tumors into the subcutaneous tissue of NCr/Sed-nu/nu nude and severe combined immunodeficient mice. *Cancer Res* 53: 5012-7.
- Takeda N, Sakuragi N, et al. (2002). Multivariate analysis of histopathologic prognostic factors for invasive cervical cancer treated with radical hysterectomy and systematic retroperitoneal lymphadenectomy. *Acta Obstet Gynecol Scand* 81: 1144-51.
- Tanvetyanon T, Eikman EA, et al. (2008). Computed tomography response, but not positron emission tomography scan response, predicts survival after neoadjuvant chemotherapy for resectable non-small-cell lung cancer. *J Clin Oncol* 26: 4610-6.
- Ter-Pogossian MM, Phelps ME, et al. (1975). A positron-emission transaxial tomograph for nuclear imaging (PETT). *Radiology* 114: 89-98.
- The National Board of Health and Welfare (2008). Cancer incidence in Sweden 2007: Stockholm, Sweden.
- The National Board of Health and Welfare (2009a). Cancer incidence in Sweden 2008: Stockholm, Sweden.
- The National Board of Health and Welfare (2009b). Causes of death 2007: Stockholm, Sweden.
- Thigpen T, Shingleton H, et al. (1981). Cis-platinum in treatment of advanced or recurrent squamous cell carcinoma of the cervix: a phase II study of the Gynecologic Oncology Group. *Cancer* 48: 899-903.
- Unger JB, Ivy JJ, et al. (2004). Detection of recurrent cervical cancer by whole-body FDG PET scan in asymptomatic and symptomatic women. *Gynecol Oncol* 94: 212-6.
- Unger JB, Ivy JJ, et al. (2005). Whole-body [^{18}F]fluoro-2-deoxyglucose positron emission tomography scan staging prior to planned radical hysterectomy and pelvic lymphadenectomy. *Int J Gynecol Cancer* 15: 1060-4.
- Wahl RL, Jacene H, et al. (2009). From RECIST to PERCIST: Evolving Considerations for PET response criteria in solid tumors. *J Nucl Med* 50 Suppl 1: 122S-50S.
- Walboomers JM, Jacobs MV, et al. (1999). Human papillomavirus is a necessary cause of invasive cervical cancer worldwide. *J Pathol* 189: 12-9.

- van der Veldt AA, Buist MR, et al. (2008). Clarifying the diagnosis of clinically suspected recurrence of cervical cancer: impact of ^{18}F -FDG PET. *J Nucl Med* 49: 1936-43.
- van Tinteren H, Hoekstra OS, et al. (2002). Effectiveness of positron emission tomography in the preoperative assessment of patients with suspected non-small-cell lung cancer: the PLUS multicentre randomised trial. *Lancet* 359: 1388-93.
- Warburg O (1956). On the origin of cancer cells. *Science* 123: 309-14.
- Weber G (1977a). Enzymology of cancer cells (first of two parts). *N Engl J Med* 296: 486-92.
- Weber G (1977b). Enzymology of cancer cells (second of two parts). *N Engl J Med* 296: 541-51.
- Wennerberg J (1984). Changes in growth pattern of human squamous-cell carcinomas of the head and neck during serial passages in nude mice. *Int J Cancer* 33: 245-50.
- Wertheim E (1912). The extended abdominal operation for carcinoma uteri. *Am J Obstet* 66: 169-232.
- Whitney CW, Sause W, et al. (1999). Randomized comparison of fluorouracil plus cisplatin versus hydroxyurea as an adjunct to radiation therapy in stage IIB-IVA carcinoma of the cervix with negative para-aortic lymph nodes: a Gynecologic Oncology Group and Southwest Oncology Group study. *J Clin Oncol* 17: 1339-48.
- Wong RJ, Lin DT, et al. (2002). Diagnostic and prognostic value of $[(18)\text{F}]$ fluorodeoxyglucose positron emission tomography for recurrent head and neck squamous cell carcinoma. *J Clin Oncol* 20: 4199-208.
- Woodman CB, Collins S, et al. (2001). Natural history of cervical human papillomavirus infection in young women: a longitudinal cohort study. *Lancet* 357: 1831-6.
- Wrenn FR, Jr., Good ML, et al. (1951). The use of positron-emitting radioisotopes for the localization of brain tumors. *Science* 113: 525-7.
- Yagle KJ, Eary JF, et al. (2005). Evaluation of ^{18}F -annexin V as a PET imaging agent in an animal model of apoptosis. *J Nucl Med* 46: 658-66.
- Yamada S, Kubota K, et al. (1995). High accumulation of fluorine-18-fluorodeoxyglucose in turpentine-induced inflammatory tissue. *J Nucl Med* 36: 1301-6.
- Yeh LS, Hung YC, et al. (2002). Detecting para-aortic lymph nodal metastasis by positron emission tomography of ^{18}F -fluorodeoxyglucose in advanced cervical cancer with negative magnetic resonance imaging findings. *Oncol Rep* 9: 1289-92.
- Yen TC, See LC, et al. (2004). ^{18}F -FDG uptake in squamous cell carcinoma of the cervix is correlated with glucose transporter 1 expression. *J Nucl Med* 45: 22-9.
- Zhang X, Paule MG, et al. (2009). A minimally invasive, translational biomarker of ketamine-induced neuronal death in rats: microPET Imaging using ^{18}F -annexin V. *Toxicol Sci* 111: 355-61.
- Zietman AL, Suit HD, et al. (1988). Quantitative studies on the transplantability of murine and human tumors into the brain and subcutaneous tissues of NCr/Sed nude mice. *Cancer Res* 48: 6510-6.
- zur Hausen H (1991). Human papillomaviruses in the pathogenesis of anogenital cancer. *Virology* 184: 9-13.
- zur Hausen H (2000). Papillomaviruses causing cancer: evasion from host-cell control in early events in carcinogenesis. *J Natl Cancer Inst* 92: 690-8.

