



LUND UNIVERSITY

Osteonecrosis. Prognosis and Prevention of the Consequences of Osteonecrosis

Juréus, Jan

2014

[Link to publication](#)

Citation for published version (APA):

Juréus, J. (2014). *Osteonecrosis. Prognosis and Prevention of the Consequences of Osteonecrosis*. [Doctoral Thesis (compilation), Orthopaedics (Lund)]. Department of Orthopaedics, Lund University.

Total number of authors:

1

General rights

Unless other specific re-use rights are stated the following general rights apply:

Copyright and moral rights for the publications made accessible in the public portal are retained by the authors and/or other copyright owners and it is a condition of accessing publications that users recognise and abide by the legal requirements associated with these rights.

- Users may download and print one copy of any publication from the public portal for the purpose of private study or research.
- You may not further distribute the material or use it for any profit-making activity or commercial gain
- You may freely distribute the URL identifying the publication in the public portal

Read more about Creative commons licenses: <https://creativecommons.org/licenses/>

Take down policy

If you believe that this document breaches copyright please contact us providing details, and we will remove access to the work immediately and investigate your claim.

LUND UNIVERSITY

PO Box 117
221 00 Lund
+46 46-222 00 00

Osteonecrosis

Prognosis and Prevention of the Consequences of Osteonecrosis

Jan Juréus



LUND
UNIVERSITY

DOCTORAL DISSERTATION

By due permission of the Faculty of Medicine, Lund University, Sweden.
To be defended at Lecture hall 2, Getingevägen 4, Skånes Universitetssjukhus,
Lund. Friday, October 17th, 9 am.

Faculty opponent


Professor Jon Karlsson, University of Gothenburg, The Sahlgrenska Academy

LUND UNIVERSITY Dept. of Orthopedics, Clinical Sciences, Lund, Sweden		DOCTORAL DISSERTATION	
Author(s) Jan Jürés		Date of issue 2014-10-17	
		Sponsoring organization	
Title and subtitle Osteonecrosis. Prognosis and prevention of the consequences of osteonecrosis			
<p>Abstract: Osteonecrosis (ON) means in situ death of bone cells and is an uncommon condition causing joint surface collapse. ON occurs in several skeletal locations but mainly in the knee and hip. After cell death, the necrotic bone is resorbed by osteoclasts and new bone formed by osteoblasts. During this remodelling, the mechanical strength of the bone might temporarily be decreased. If the ON occurs in subchondral bone, the bone may be compressed during load-bearing and a joint collapse the final consequence. We hypothesize that osteoclastic resorption can be stalled by bisphosphonates and the consequences of ON be prevented.</p> <p>Paper I. 17 patients with spontaneous osteonecrosis of the knee (SPONK) were treated with bisphosphonates. 3 years later, the patients were examined and development of osteoarthritis and frequency of surgery were compared with a previous untreated series of 40 patients (paper II). Results: The 17 bisphosphonate treated patients had lower risk of developing secondary degenerative changes than the historic controls ($p < 0,05$).</p> <p>Paper II. A life long follow up was made of the historic control series of 40 patients with SPONK diagnosed 1982-88. In 2012, the patients were evaluated regarding frequency of major knee surgery, and correlation between the size of the lesion and the age of the patient to outcome. Results: 75% of the patients developed secondary degenerative changes and 17/40 patients have had major knee surgery. Younger patients and patients with small ON lesions were at lower risk of major knee surgery ($p < 0,001$).</p> <p>Paper III: ON can be posttraumatic and is common after hip fracture. The consequences are feared for, especially in young patients in whom early hip replacement is best avoided. We followed 10 children and young adults radiographically after a cervical hip fracture but added scintigraphy to evaluate the femoral head circulation after surgery. Patients with no remaining circulation were treated with bisphosphonates. Results: 3/3 patients with normal circulation had normal radiographs at follow up as had 3/4 with partially remaining circulation. 2/3 patients with no postoperative circulation had radiographic changes but only 1 collapsed. We believe scintigraphy can be used to evaluate the femoral head circulation and hypothesize that collapse can be prevented.</p> <p>Paper IV. In a rat model, bone grafts were mounted in a bone chamber allowing the graft to be mechanically loaded. Half were given bisphosphonates and the other half were not. The lengths of the graft, before surgery and after harvest were compared. Results: Bone grafts treated with bisphosphonates were less likely ($p < 0,03$) to collapse compared to the grafts in untreated rats.</p>			
Key words Osteonecrosis, Spontaneous osteonecrosis of the knee (SPONK), Bisphosphonate, Hip-fracture.			
Classification system and/or index terms (if any)			
Supplementary bibliographical information		Language English	
ISSN and key title 1652-8220		ISBN 978-91-7619-035-7	
Recipient's notes	Number of pages	Price	
	Security classification		

I, the undersigned, being the copyright owner of the abstract of the above-mentioned dissertation, hereby grant to all reference sources permission to publish and disseminate the abstract of the above-mentioned dissertation.

Signature _____

Date _____



Osteonecrosis

Prognosis and Prevention of the Consequences of Osteonecrosis

Jan Juréus



LUND
UNIVERSITY

Copyright Jan Juréus

Department of Orthopedics, Clinical Sciences, Lund, Sweden

ISSN 1652-8220

ISBN 978-91-7619-035-7

Lund University, Faculty of Medicine Doctoral Dissertation Series 2014:106

Printed in Sweden by Media-Tryck, Lund University

Lund 2014



Contents

Abbreviations	7
List of papers	9
Abstract	11
Background	11
Methods	11
Results	12
Discussion	12
The purpose of this thesis	13
Hypothesis	15
Introduction	17
Bone composition	18
Bone matrix	18
Bone cells	18
Osteonecrosis	20
General aspects of osteonecrosis	20
Osteonecrosis in the present thesis	25
SPONK, Spontaneous Osteonecrosis of the Knee	25
Osteonecrosis following hip fracture	27
Regulators of bone metabolism	28
Bisphosphonates	28
Methods and Background	31
Patient populations	31
Swedish Knee Arthroplasty Register (SKAR)	32
Radiological methods	32
Magnetic Resonance Imaging (MRI)	32
Scintigraphy	34
SPECT	35
SPECT/CT	35
Osteonecrosis in plain radiographs	35

Radiological classification of osteonecrosis, osteoarthritis and hip fracture.	36
Radiological classification of SPONK	36
Radiological classification of knee osteoarthritis	38
Radiological classification of hip osteonecrosis and hip fracture	39
Animal model	41
Animals	41
Procedure and ethics	42
The bone chamber	42
Evaluation	44
The studies- methods results and discussions	47
Methods and results	47
SPONK	47
Cervical hip fracture	50
Animal study	50
Discussion	52
SPONK	52
Cervical hip fracture	54
Animal study	56
Conclusions	59
Future studies	61
Future clinical studies	61
SPONK	61
Cervical hip fractures	61
Future animal studies	61
Animal model, bone chamber	61
Populärvetenskaplig sammanfattning på svenska	63
Acknowledgements	65
Comparisons in this thesis	67
Paper I	67
Paper II	67
Paper III	67
Paper IV	68
References	69

Abbreviations

ATP	Adenosine triphosphate
AVN	Avascular necrosis
AP	Antero-posterior
BMPs	Bone morphogenetic proteins
BV/TV	Bone volume/total volume
c-Fms	Colony-stimulating factor-1 receptor
CT	Computed tomography
DWI	Diffusion Weighted Imaging
EDTA	Ethylene-diamine-tetraacetic acid
ES	Epiphyseal scar
FPPS	Farnesyl pyrophosphate syntase
GTP	Guanosine triphosphate
GTPases	GTP hydrolase enzymes
HA	Hydroxyapatite
LC	Loaded bone chamber
M-CSF	Macrophage colony-stimulating factor
MDP	Methylene diphosponate
MRI	Magnetic resonance imaging
MSCs	Mesenchymal stem cells
NSAID	Non-steroidal anti-inflammatory drugs
OA	Osteoarthritis
ON	Osteonecrosis
PEMFs	Pulsed electromagnetic fields
PTH	Parathyroid hormone

RANK	Receptor activator of NF- κ B
RANKL	Receptor activator of NF- κ B ligand
SKAR	Swedish Knee Arthroplasty Register
SPECT	Single photon emission computed tomography
SPONK	Spontaneous osteonecrosis of the knee
TNF	Tumor necrosis factor

List of papers

The present thesis is based on the following papers:

- I Juréus J, Lindstrand A, Geijer M, Roberts D, Tagil M. Treatment of spontaneous osteonecrosis of the knee (SPONK) by a bisphosphonate. *Acta Orthopaedica* 2012; 83 (5): 511-4.
- II Juréus J, Lindstrand A, Geijer M, Robertsson O, Tagil M. The natural course of spontaneous osteonecrosis of the knee (SPONK): a 1- to 27-year follow-up of 40 patients. *Acta Orthopaedica* 2013; 84 (4): 410-4.
- III Juréus J, Geijer M, Tiderius CJ, Tägil M. Vascular impairment after cervical hip fractures in children and younger adults. Diagnosis and treatment with prolonged restricted weightbearing and bisphosphonates.
- IV Juréus J, Afendras M, Tägil M. Systemically administered alendronate prevents collapse in mechanically loaded osteochondral grafts. A bone chamber study.

Abstract

Background

Osteonecrosis (ON) is defined by the in situ death of bone cells, osteocytes, hematopoietic and fatty marrow precursor cells. Events and risk factors known to be associated with ON are femoral neck fracture, hip dislocation, slipped capital femoral epiphysis in children, humeral head fracture and insufficiency fractures in load-bearing joints. The etiology of non-traumatic ON is less well understood. Factors associated with non-traumatic ON are corticoid steroid use, alcohol abuse and systemic lupus erythematosus. If factors related to the osteonecrotic lesion cannot be found, the lesion is defined as “spontaneous”. Regardless of the cause, vascular compromise is however the final pathway which leads to cellular death. Ingrowing blood vessels invade the necrotic bone and remodeling starts with simultaneous coupled bone resorption and formation. The changes resemble what happens in fracture healing and bone graft incorporation. The mechanical strength of the remodeling bone might temporarily be decreased due to either the resorption of the necrotic bone or a fatigue stress fracture in necrotic bone not yet revitalized. If the necrosis occurs in subchondral load bearing bone, partial joint collapse and secondary osteoarthritis may be the final consequence.

Methods

In paper 1, a 1-4 year follow-up study was performed of 17 patients with spontaneous osteonecrosis of the knee (SPONK), who were treated with bisphosphonates and evaluated regarding secondary degenerative changes. These 17 treated patients were compared to a previously untreated control group (paper 2).

In paper 2, an almost life long follow-up of 40 SPONK patients was conducted. The patients were matched with the Swedish Knee Arthroplasty Register (SKAR) to evaluate the frequency of major knee surgery.

In paper 3 the risk of ON and secondary degenerative changes after cervical hip fracture was studied in children and younger adults. Radiographs performed at follow-up minimum of 12 months after the fracture were correlated with the scintigraphic examinations evaluating the remaining femoral head circulation made directly post-operatively.

In paper 4, the remodeling of non-vascularized bone grafts under high load was studied in a specially designed bone chamber in rats. Bone chambers with bone grafts were

implanted in the proximal tibial bone. Half of the rats were administered bisphosphonates and the other half were not. The lengths of the grafts, before surgery and after harvest, were compared to assess whether bisphosphonates decreased the compression of the graft during remodeling.

Results

Paper 1. The 17 patients who were treated with bisphosphonate had a significantly ($p < 0,05$) lower risk of developing secondary degenerative changes at the follow-up, compared to the untreated control group.

Paper 2. 75% of the patients developed secondary degenerative changes in this almost life long follow-up study with SPONK patients. 17/40 patients have had major knee surgery with arthroplasty or high tibial osteotomy. Younger patients and patients with small ON lesions were at lower risk of major knee surgery ($p < 0,001$).

Paper 3. 3/3 children or young adults with cervical hip fracture and normal postoperative circulation had normal radiographs at follow up, as had 3/4 with partial remaining circulation. 1/3 patients with absent postoperative circulation in the scintigraphic investigations had a joint collapse, in spite of treatment with bisphosphonates and prolonged restricted weight-bearing. 1 patient had secondary radiological changes but no joint collapse and 1 patient in this group had normal radiographs at follow up.

Paper 4. Bone grafts implanted in loaded bone chambers in rats were less compressed ($p < 0,05$) when treated with bisphosphonates compared to the grafts in untreated rats.

Discussion

Morbidity after untreated ON in subchondral bone in load bearing joint is substantial with a high risk of osteoarthritis and need for secondary joint prosthesis. Evaluating the postoperative circulation in the femoral head after cervical neck fracture helps predict the outcome in children and young adults. Bisphosphonates may reduce the risk of collapse of the necrotic bone during remodelling and thereby reduce the risk for secondary degenerative changes in the affected joint. Randomized clinical series are warranted to further define the role of bisphosphonates or other bone-acting drugs like receptor activator of NF- κ B ligands (RANKL) antibodies and parathyroid hormone (PTH).

The purpose of this thesis

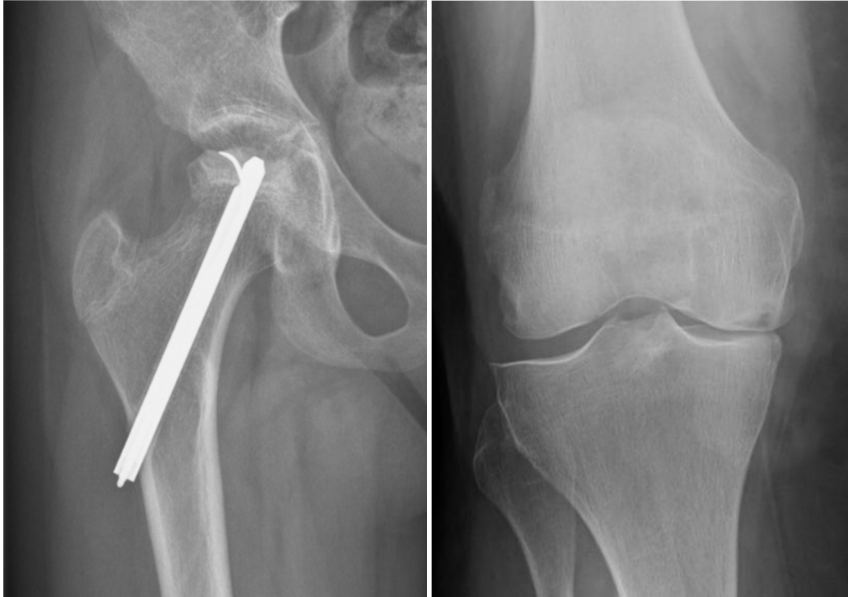

Figure 1. Why this thesis was written.

To the left, the radiogram of the hip in a 12-year-old girl is shown 1 year after a 2 meter fall resulting in a hip fracture. After operation the fracture healed uneventfully but gradually thereafter she developed an osteonecrosis. At the time of the fracture, the arteries supplying the femoral head ruptured and, as seen in this picture, secondary degenerative changes occurred long after fracture healing, causing pain and dysfunction. It is likely that the patient may require a prosthesis relatively early in adulthood. To the right we can see the radiograph of an 82 year old woman with a spontaneous osteonecrosis of the knee (SPONK). This is a condition of unknown cause affecting the middle aged and elderly. SPONK also leads to secondary osteoarthritis in 75% of the affected joints and knee replacement in about 50%. The larger the lesion, the higher the risk.

Osteonecrosis (ON) is an uncommon condition and has been described in several locations in the skeleton. It occurs relatively frequently in the knee and hip joints but also occurs in the elbow, scaphoid, lunate, talus and the humeral head. ON is defined as the death of bone cells and the cause can be traumatic, secondary to disease or of unknown origin. Regardless of cause, the result is avascularity of the affected bone. As healing starts, new vessels will grow into the necrotic bone from the surrounding viable bone and bone-forming cells along with bone-resorbing cells will enter the necrotic

zone. A remodeling of the dead bone will start with the bone resorbing cells preceding the bone forming cells. In subchondral bone a temporary weakening of the bone may occur with degradation of the necrotic bone before new bone has formed. During this phase, even normal joint loading with walking or running may cause the subchondral bone to collapse, resulting in malalignment of the joint surfaces and the development of secondary osteoarthritis as seen in late stages of the disease.

In the present thesis we have focused on spontaneous osteonecrosis of the knee (SPONK) as well as post-traumatic osteonecrosis following hip fracture in children and young adults.

SPONK occurs without known causes and is characterized of sudden onset of pain in the knee without trauma. Most frequently, the medial femoral condyle is affected. In the early stages the lesion is only seen in magnetic resonance imaging (MRI) whereas the radiograph can be normal. The condition is therefore easy to miss initially. A radiolucent lesion however is, most often, in time seen on radiographs. SPONK is associated with an up to 75% risk of secondary knee osteoarthritis, a risk we in the present thesis aim to reduce.

Fortunately, cervical hip fractures are rare in children and young adults. However, just as in adult patients with hip fractures, there is a risk of injuries to the vessels supplying the femoral head and a risk for ON in up to 40% following these injuries. The diagnosis of avascularity can be made by various methods before or shortly after surgery has been performed.

Hypothesis

- I Bisphosphonates reduce the risk for future development of osteoarthritis (OA) and reduce the risk for knee surgery in patients with SPONK.
- II What is the life long risk in patients with SPONK of developing osteoarthritis, leading to major knee surgery with prosthesis or high tibial osteotomy? What risk factors for inferior results can be identified?
- III An evaluation of the postoperative blood circulation in the cervical head after cervical hip fracture in children and young adults helps predict outcome regarding AVN and secondary degenerative changes in the hip joint.
- IV Bisphosphonate treatment protects an osteochondral bone graft from collapse and maintains the joint architecture during remodeling in a high load environment in an experimental loaded bone chamber model in rats.

Introduction

Bone is indeed a living material. Besides being a structural organ, bone is an endocrine organ responsible for the homeostasis of calcium, phosphate and other minerals. Bone has been optimized for million years with respect to its structure and composition to handle stress transfer from the extremities to the axial skeleton in the ambulatory *Homo sapiens*. Regeneration and repair continues throughout life, whereas the balance between strength and weight will be constantly optimized. Bone, at reasonable loads, must be strong enough to resist fracture, but still maintain a low weight to keep us light and swift.

The process of bone remodeling in an individual person is a mechanism that adapts the bone to the mechanical load the individual is exposed to. The bones of a stone-age hunter most certainly differ from the bones of today's sedentary office worker, but the mechanisms are the same. Specialized bone cells, osteoclasts, osteoblasts and osteocytes react to increased or decreased strain/deformation by increasing or decreasing the bone density as well as by optimizing the bone architecture. The mechanism that adapts to the actual mechanical stress also comprises the ability of repairing the bone, when the same specialized cells are responsible for healing of bone fractures. Bone injuries can be caused by macro-damages, such as a fracture, but also by micro-damages due to fatigue during a regular activity. Various conditions result in bone injuries, including metabolic diseases, infections, tumors and trauma, which all may trigger a regenerative healing process to repair the overall structure of the tissue. The mechanical integrity of the bone depends on the regulation of bone formation and resorption by means of integrated processes of osteoblasts and osteoclasts triggered and controlled by the mechanical stress, but also by hormones and transmitter substances. This process is often referred to as bone remodeling. Injuries to the bone damage cell viability and integrity and trigger a regenerative healing process to repair the overall structure of the tissue. The healing process can sometimes result in unwanted side effects in ON. The present thesis will discuss this process.

Bone composition

Like other tissues, bone consists of living cells and extracellular matrix. The cells control the bone metabolism and the synthesis of bone matrix. The cells react to external stimuli such as load and signaling substances by changing the bone mass and/or bone architecture.

Bone matrix

Bone matrix contains approximately 20-25% organic substances, 60-70 % mineral and the rest water. The organic material, mainly collagen, provides elasticity to the bone, while the minerals calcium and phosphorus, mainly in the form of hydroxyapatite (HA), $\text{Ca}_{10}(\text{PO}_4)(\text{OH})_2$, makes the bone rigid. Collagen type 1 is the most abundant collagen in connective tissue. Collagen is a polymer made out of collagen molecules forming long fibers arranged in a 3-D pattern. The composition and architecture of the collagen and the HA together give bone its impressive properties with the optimized mechanical properties related to its weight.

Bone cells

Bone cells make up only a few percent of the bone volume. Two different stem cell populations give rise to the cells that regulate skeletal metabolism, the mesenchymal and the hematopoietic stem cell pools. Osteoblasts and bone lining cells derive from mesenchymal stem cells and osteoclasts develop from hematopoietic stem cells. Osteoblasts are bone-forming cells and osteoclasts are bone-resorbing cells. Their function and interaction in bone remodeling and repair are intricate and only partially understood.

Osteoclasts

Osteoclasts are derived from mononuclear hematogenous progenitor cells that undergo fusion to multinucleated bone resorbing osteoclasts. The development from precursor cells to osteoclasts is regulated by activation of the Colony-stimulating factor-1 receptor (c-Fms) by the cytokine macrophage colony-stimulating factor (M-CSF) as well as the receptor activator of NF- κ B (RANK) receptor with the tumor necrosis factor (TNF) related cytokine RANK-ligand (RANKL). Activation will lead to expression of genes responsible for specific functions of the cells regarding bone resorption and induce transfer of the precursor cells from the circulation to the site of bone resorption. Mononuclear preosteoclasts fuse to form the mature, multinucleated osteoclasts. Osteoclasts are large cells and their cytoplasm contains many mitochondria and lysosomes with degradative enzymes. Osteoclasts respond to numerous regulatory agents known to stimulate bone resorption such as interleukin-1, interleukin-6, TNF

and prostaglandin E. Mature osteoclasts only exist on bone surfaces and in the Haversian canals and have a half-life around 10 days. During bone resorption, the osteoclasts adhere to the bone surface through a “sealing zone” that surrounds the ruffled border. Carbonic acid and degrading enzymes are secreted through the basal membrane into the determined confined space. How the osteoclast knows what part of the bone it should resorb is not fully known.

Osteoblasts

Osteoblasts are bone-forming cells that synthesize and secrete bone matrix (osteoid), and regulate its own mineralization in response to hormonal as well as mechanical stimuli. Osteoblasts also regulate bone remodeling, both directly through the control of bone formation via other osteoblasts, and indirectly via osteoclastic resorption. Osteoblasts help the hematogenic osteoclast progenitor cells to differentiate, secreting RANKL and M-CSF.

Multipotent stroma cells in the bone marrow can develop into adipocytes, chondrocytes, fibroblasts, myocytes or osteoblasts and are referred to as mesenchymal stem cells MSCs. A cell committed to osteoblastic differentiation is termed an osteoprogenitor cell. Osteoblasts in the form of bone lining cells on the bone surface are activated by parathyroid hormone (PTH) and 1,25 dihydroxy-D-vitamin. Further differentiation, under the influence of various growth factors, mainly the bone morphogenetic proteins (BMPs), results in a mature secreting osteoblast. Osteoblasts secrete osteoid, a biologic composite containing proteins such as type I collagen, and smaller molecules such as growth and attachment factors as well as signaling molecules.

Osteoblasts have a life span of approximately 100 days and some remain on the bone surface in the form of a bone lining cells. Bone lining cells can be reactivated in to new osteoblasts. Osteoid secreting cells either become embedded in the bone matrix, and become osteocytes or disappear via apoptosis.

Osteocytes

Osteocytes are the most abundant bone cells and are found in the lacunar spaces of mineralized matrix in cortical and trabecular bone. The osteocytes are not active synthesizing osteoid but instead display numerous small cell processes that traverse the bone within the canaliculi and resemble neural dendrites. All osteocyte are interconnected into a network, which also includes the bone lining cells and osteoblasts on the bone surface as well as cells within the marrow. The osteocytes play a major role in mechano-sensing, measuring and reporting deformations of the bone, thereby monitoring the condition of the matrix as well as levels of nutrients and signaling molecules.

Osteonecrosis

General aspects of osteonecrosis

Osteonecrosis (ON) or avascular necrosis (AVN) are both terms in use (and used synonymously here) and can be used to describe the end condition of several pathological pathways. Any bone relying on intraosseous circulation can be affected, but most prevalent sites are knee, hip, shoulder, talus, hand and wrist (Buckwalter 2007). Osteonecrotic lesions are painful and often lead to secondary osteoarthritic changes if they occur in the subchondral bone. Osteonecrosis of the knee and hip are strongly associated with an increased risk of joint arthroplasty (Jureus 2013, Lai 2005, Lotke 1982). In the USA as many as 20000 new patients are diagnosed with hip osteonecrosis each year and 18% of all hip arthroplasties are performed due to osteonecrosis (Canale and Campbell 2003). In knees, less than one percent of all knee arthroplasties performed in Sweden are registered as caused by osteonecrosis (Knutson and Robertsson 2010). Under-reporting is suspected as knee osteonecrosis often is radiologically difficult to distinguish from primary osteoarthritis. The true incidence is largely unknown.

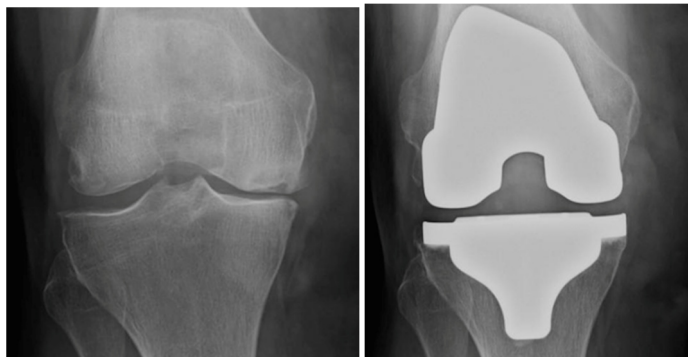


Figure 2. Spontaneous Osteonecrosis of the Knee (SPONK)

Osteonecrosis of the medial femoral condyle with secondary degenerative changes and osteoarthrits (left). The same knee after surgery with knee prosthesis (right).

Pathogenesis

ON in general can be divided as being traumatic and non-traumatic (Buckwalter 2007). Avascular necrosis can be regarded as an infarction of the bone. As the term implies, traumatic osteonecrosis is caused by some sort of major or minor traumatic event that results in a transient or permanent ischemia of the bone. Traumatic events, known to be associated with a risk of ON, are femoral neck fracture (Fig. 1), hip dislocation, slipped capital femoral epiphysis in children, humeral head fracture (Fig.

4), talus fractures (Fig. 3) and insufficiency fractures in load bearing joints (Akamatsu 2012, Forlin 1992, Gross 2014, Harreld 2009, Lai 2005, Morsy 2001). The etiology of non-traumatic ON is less well understood. Factors associated with non-traumatic ON are corticoid steroid use, alcohol abuse, smoking, caisson's disease, systemic lupus erythematosus, sickle cell disease, familial trombophilia, Gaucher's disease, organ transplantation, inflammatory bowel disease and pregnancy (Buckwalter 2007, Canale and Campbell 2003, Jones 1993, Mont 2000, Sharareh and Schwarzkopf 2014). If no factors related to the ON lesion can be found, the lesion is considered to occur spontaneously or to be idiopathic (Ahlback 1968, Ficat 1985). ON following arthroscopic surgery in the knee and shoulder is a third entity well described (Dilisio 2013, Kraenzlin 2010) and characterized by increased pain and dysfunction of the affected joint after arthroscopic intervention and with typical magnetic resonance imaging (MRI) findings. It is a rare event in the light of the number of procedures performed.

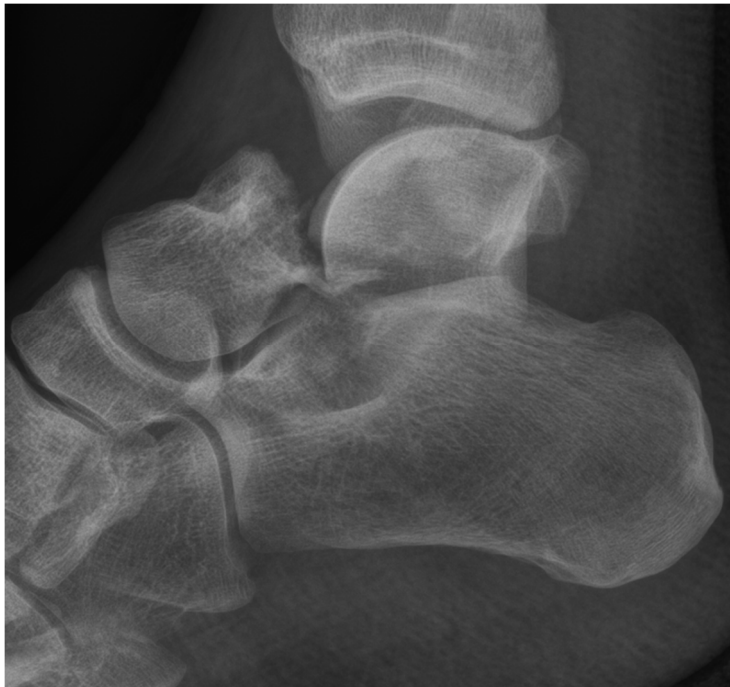

Figure 3. Talus fracture

Talus fractures are associated with risk of ON due to the anatomical structure of the blood supply of the talus bone.

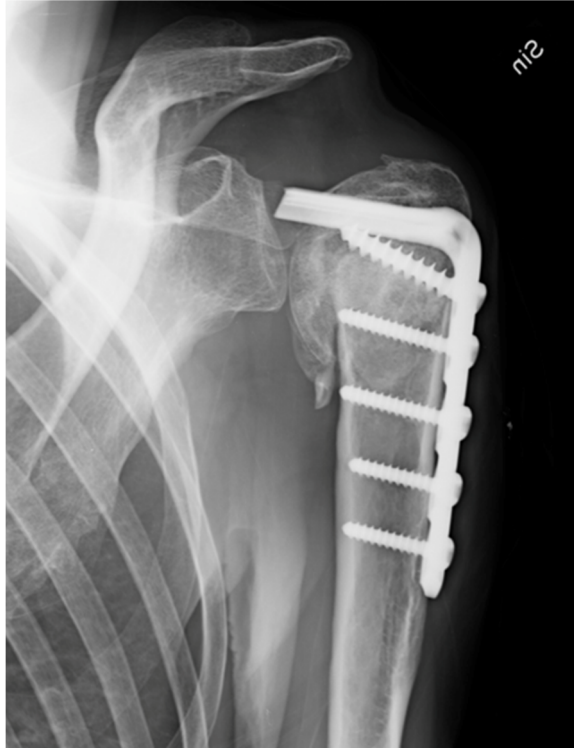

Figure 4. Humeral head ON
Humeral head ON following fracture and plate osteosynthesis.

Osteonecrosis and bone collapse

Regardless of the cause, vascular compromise is the final step, which causes cellular death. Possible mechanisms of vascular compromise are venous occlusion, arterial vessel occlusion or mechanical disruptions of vessels due to traumatic fracture dislocation or fatigue fracture (Buckwalter 2007). Although the cells in the necrotic lesion die, the organic and inorganic matrices with collagen, non-collagenous proteins, minerals and proteoglycans generally are initially unaffected and the bone will retain its load bearing capacity (Parks and Engh 1997). Ingrowing blood vessels invade the necrotic bone from the surrounding living bone, and osteoclasts are brought into the lesion and start to resorb the necrotic bone matrix (Kim and Su 2002). If the bone remains avascular, no cellular resorption will take place but instead fatigue fractures can occur due to the low resistance of dead bone to fatigue. The normal fatty marrow is phagocytized by macrophages which can be seen as an increased water content early on MRI (Buckwalter 2007). Simultaneously primitive mesenchymal cells may start to differentiate into osteoblasts, which in turn activate the osteoclasts to start resorbing the dead bone. Remodeling starts with simultaneous coupled bone resorption and

formation but with the osteoclastic zone preceding the bone formation zone as the remodeling travels into the lesion (Harding 2008). Osteoid is laid down by the living osteoblasts on the remaining necrotic trabeculae in a similar fashion as during fracture healing or non-vascularized bone graft incorporation (Hurtig 2001). The mechanical strength of the remodeling bone might temporarily be decreased due to either a faster resorption of the necrotic bone than new formation or due to fatigue fracture in not yet revitalized necrotic bone. If the necrosis and the subsequent remodeling take place in a low stress part of the bone, the lesion may heal uneventfully. On the other hand, if the remodeling occurs in a highly loaded area, such as in the subchondral bone of a joint, the mechanical strength of the remodeling bone may be temporarily decreased and the bone collapses. Secondary osteoarthritis might be the final consequence (Lai 2005, Okazaki 2012, Pringle 2004, Tagil 2004).

Symptoms

In cases of non-traumatic ON, the symptoms are often characterized as a sudden onset of severe pain, swelling and dysfunction of the affected joint (al-Rowaih 1991). In ON following trauma, normal joint function never returns or the symptoms deteriorate again after a period of improvement (Boardman 2009, Morsy 2001). Asymptomatic ON lesions occurring in the contralateral hip joint has also been noted in patients with manifest symptomatic hip ON (Bradway and Morrey 1993).

Radiographic findings

Radiographic findings in MRI, scintigraphy and plain radiographs reflect the histological changes taking place during bone necrosis and subsequent bone remodeling (Buckwalter 2007). In T1 weighted MRI images the water replacing the fatty marrow after bone necrosis can be seen as a decreased signal. T2-weighted image shows an area of low signal intensity surrounded by a high-intensity signal caused by edema (Bjorkengren 1990, Oner 2011, Yates 2007). A decreased scintigraphic uptake after 1-3 weeks is a strong indicator of loss of blood supply (Stromqvist 1987). Due to increased bone remodeling, an increased focal uptake can be seen at the site of the lesion approximately 5 weeks after the onset of symptoms, as technetium is increasingly taken up by active osteoblasts (Ahlback 1968, al-Rowaih 1990).

The first radiographic signs appear months later. The subchondral cyst formation often seen on plain radiographs reflects the resorption of trabeculae and a confluent subchondral trabecular loss forms the morphologic basis of the crescent sign. Further progression follows with secondary degenerative changes now seen as osteoarthritis on plain radiographs or a full subchondral collapse in more advanced stages (Aglietti 1983).

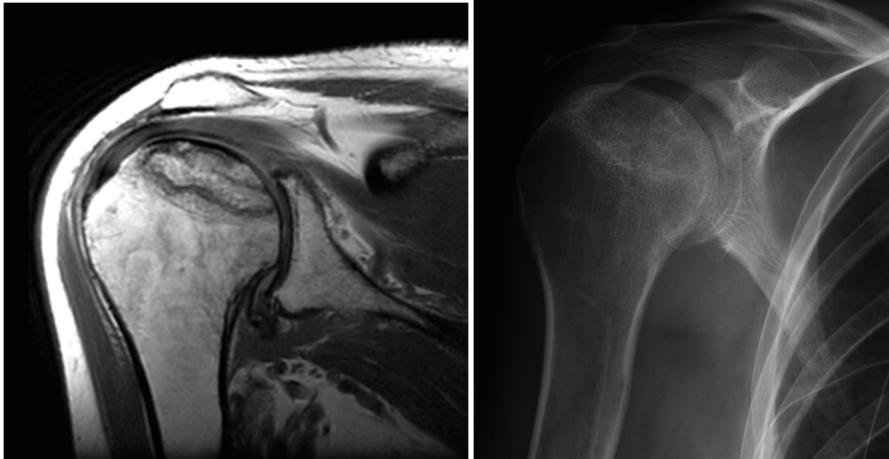


Figure 5. Osteonecrosis in the shoulder joint

Osteonecrosis in the cranial part of the humeral head visible on MRI (left) and on plain radiographs (right)

Treatment options

Today, treatment options comprise both non-surgical methods such as pulsed electromagnetic fields (PEMFs) therapy (Marcheggiani Muccioli 2013) or just restricted weight-bearing, as well as surgical methods like core decompression, or osteochondral autograft transplantation (Duany 2010, Strauss 2011, Zywił 2009). Core decompression (fig 6) is a common procedure meant to relieve the increased intraosseous pressure believed to exist in osteonecrotic lesions (Mont 1996, Mont 1996, Mont 1997). Vascularized fibular grafting is hypothesized to have four positive effects; 1, core decompression (see above), 2 excision of the sequestrum inhibiting revascularization, 3 filling of the defect with osteoinductive cancellous graft, supplying a viable cortical strut to support the subchondral bone and improve revascularization (Garrigues 2009, Urbaniak 1995). The fourth argument is that the procedure is followed by a period of non-weight-bearing which in itself may reduce morbidity. Hip fracture is a known complication (Aluisio and Urbaniak 1998).

Bisphosphonate treatment reduces bone resorption and is hypothesized to have a role in the treatment of ON (Agarwala 2005, Jureus 2012, Lai 2005). Circulating bisphosphonates bind to bone mineral and as the bone is resorbed by osteoclasts, bisphosphonates are internalized and interfere with the cell metabolism, which results in apoptosis of the osteoclast. This prevents resorption of the dead subchondral bone and may thereby prevent the collapse of the joint line. New bone supporting the joint cartilage is laid down on the scaffolding of the necrotic bone (Tagil 2004). No long time, randomized, large series comparing different treatment options have been published.

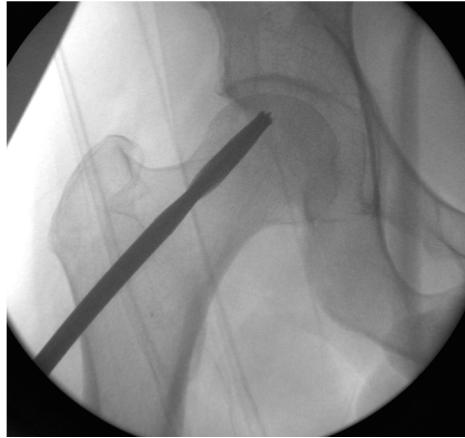


Figure 6 Core decompression

Core decompression of an ON lesion in the femoral head is a common procedure that is hypothesized to relieve the increased intraosseous pressure believed to exist in ON lesions.

Osteonecrosis in the present thesis

The present thesis' aim is to explore the fate of ON involving the subchondral bone in load bearing joints. The focus in the first two publications has been on the prognosis and treatment of Spontaneous Osteonecrosis of the Knee (SPONK), and in the third paper on the diagnosis of vascular impairment in ON following hip fracture in children and young adults. In the fourth paper, an experimental animal study was used to study the effect of bisphosphonates in revascularizing bone under stress as a model of osteonecrosis healing.

SPONK, Spontaneous Osteonecrosis of the Knee

Almost 50 years ago (Ahlback 1968), Ahlbäck and Bauer together with the American surgeon Bohne described a condition, which they called spontaneous osteonecrosis of the knee (SPONK). The condition was originally described as a single entity but is today divided into three conditions (Mont 2000, Mont 2011, Strauss 2011, Zywił 2009). SPONK, the subject of two of the papers in this thesis, typically affects a single condyle in older patients. The medial femoral condyle is most often affected (al-Rowaih 1993), but lesions can also be found in the lateral femoral condyle as well as in the tibia (Marmor 1984, Satku 2003). The term secondary ON is used when the condition has a known cause, such as corticosteroid treatment or sickle-cell anemia. Younger patients are frequently more seriously affected and the radiographic appearance is different with lesions at multiple foci. A third form, ON of the knee post arthroscopy, affects only one condyle and starts with increasing knee pain and positive MRI findings after arthroscopic surgery (Kraenzlin 2010).

The etiology of SPONK is unknown but two main theories have been proposed, a vascular (Jones 1993, Kantor 1987) and a traumatic (Akamatsu 2012, Yamamoto and Bullough 2000). In both cases, SPONK can lead to subchondral collapse and secondary osteoarthritis, and subsequent knee surgery is common. The prognosis of the disease has been shown to depend on the size of the lesion (Lotke 1982).

The condition classically present with an acute onset of pain *without* predisposing trauma and the most common finding on physical examination is localized tenderness over the medial femoral condyle (Lotke 1982). A positive radiograph typically shows a subchondral radiolucent lesion in the weight-bearing area of the medial or lateral femoral condyle (Fig 7). The initial radiograph may be negative, especially if the symptoms are of short duration and therefore the diagnosis is often missed at this stage. In some patients, the radiographs may remain normal during the whole course of the disease (Haupt 1983, Lotke 1977) and changes are only seen with bone scintigraphy or MRI (Koshino 1982). Scintigraphy, performed within a few days of the onset of pain, characteristically shows a high uptake in the affected femoral condyle (Roizing 1980). MRI typically reveals bone marrow edema in the affected condyle along with a focal subchondral lesion (Fig 8 and 9) This is considered the cardinal sign for a ON diagnosis (Bjorkengren 1990, Yates 2007).

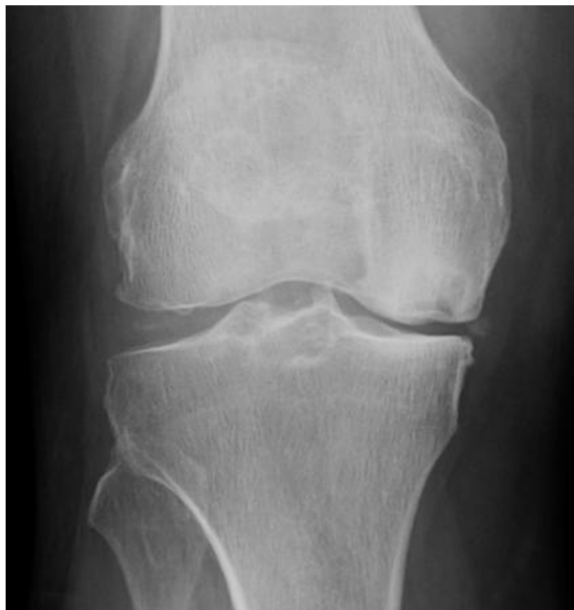

Figure 7. Spontaneous Osteonecrosis of the Knee, SPONK

Spontaneous osteonecrosis of the knee in the medial femoral condyle. Secondary degenerative changes are also seen.

Osteonecrosis following hip fracture

Fractures of the femoral neck in children and young adults are rare, representing less than 1% of all fractures in children. These are usually high-energy injuries with high complication rates such as premature closure of the physis, coxa-vara, coxa-plana, non-union, and avascular necrosis (AVN) (Morsy 2001). Hip fractures in children are categorized according to anatomical location and the most widely used scheme is the Delbet classification (table 4) (Delbet 1907). Delbet typ I, transphyseal fracture (with and without dislocation of the epiphysis A respectively B subtype). Type II, trans-cervical fracture. Type III, baso-cervical fracture. Type IV trochanteric fracture. AVN is the most common complication described (Moon and Mehlman 2006), with an incidence between 20 and 40% (100%) (Boardman 2009, Yeraniosian 2013). The risk for AVN varies with fracture subtype. Transphyseal dislocated fractures (Delbet type IB) have the highest incidence of osteonecrosis, up to 100% (Canale 1981), but are uncommon. Trans-cervical and baso-cervical fractures (Delbet II and III) represent 80% of the hip-fractures in children and are reported to have an incidence of AVN of 28 respectively 18% (Moon and Mehlman 2006) although some authors report incidences of AVN in up to 61 % in these fracture types (Canale and Bourland 1977, Ratliff 1962). AVN following trochanteric fractures (Delbet type IV) is less common but still occurs in 5-14% of these fractures types (Moon and Mehlman 2006, Ratliff 1962). The risk for AVN in children rises by 1,14 times for each year of increasing age (Moon and Mehlman 2006) The vascular supply of the femoral head relies mainly on the retinacular vessels from the medial femoral circumflex artery but the lateral circumflex artery and the artery of the ligamentum teres also contribute to the blood supply of the femoral head. The vascular anatomy is complex and the significance of the different arteries changes with the osseous development of the proximal femur (Boardman 2009).

At the time of the fracture, at reduction or at surgery, the vessels may be torn and the entire femoral head becomes avascular (fig 8) (Boardman 2009, Kalhor 2009, Trueta 1957).

Bone scintigraphy is the classic tool to diagnose AVN (al-Rowaih 1990, Stromqvist 1987). Immediately after the loss of blood supply there will be a complete or marked decrease of isotope uptake in the femoral head. With healing, a hyperaemic response in the surrounding tissues results in an increased uptake of isotopes in the area surrounding the necrosis and eventually, in case of complete restitution, in the entire femoral head. On MRI the pathognomonic sign of AVN is seen as a subchondral 'band-like' low-signal lesion in T1 weighted images (Karantanias 2013) and as a "double-line" sign in T2-weighted, non-fat suppressed images (Mitchell 1986).

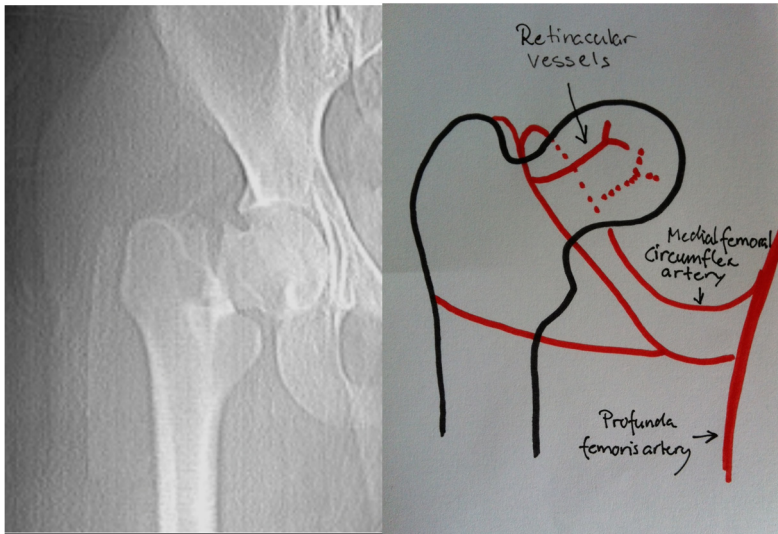


Figure 8. Cervical hip fracture

The vascular supply of the femoral head mainly relies on the retinacular vessels from the medial femoral circumflex artery. The retinacular vessels follow the cervical neck in a proximal direction to the femoral head and at the time of fracture or reduction the vessel may be torn.

Regulators of bone metabolism

Bisphosphonates

Bisphosphonates are a group of drugs, which are mainly used for osteoporosis and bone malignancies. Circulating bisphosphonates bind to bone mineral and as the bone is resorbed by osteoclasts, bisphosphonates are internalized and interfere with the cell metabolism of the osteoclast eventually leading to apoptosis and reduced bone resorption (Rogers 2003). Bisphosphonates have been used in medicine since the 1960s. They were initially intended to be used to prevent calcifications of blood vessels in atherosclerosis, the formation of kidney stones and plaque in dental care (Russell 2011). Today the drug is used in conditions related to bone fragility such as Paget's disease, multiple myeloma, primary hyperparathyroidism, osteogenesis imperfecta and fibrous dysplasia.

Bisphosphonates remain in the bone for a very long time and have a half-life ranging from 1-10 years (Lin 1996). Sites with ongoing bone resorption and remodeling possess high affinity for bisphosphonates. The osteoclasts are exposed to high drug concentrations as the protein layer covering the mineral has been removed. The osteoclasts then typically turn into apoptosis. As long as the bone is laden with

bisphosphonates, every new osteoclast resorbing bone will meet the same fate. Over time, all bisphosphonate laden bone will be resorbed, if new drugs are not distributed. The next wave of osteoclasts will now be effective and the resorption is reinitiated. A single dose or a short-term dosing regime can therefore be seen as a delay of the resorptive part of the bone remodeling. In contrast, when bisphosphonates are given for years, the bone remodeling is down-regulated and even with retained bone volume the quality may be reduced. Spontaneous fatigue fractures may occur as in the atypical femur fracture described in patients taking bisphosphonate for extended time periods (Aspenberg and Schilcher 2014).

Bisphosphonates are synthetic drugs and chemically similar to inorganic naturally occurring pyrophosphates. The compound is called bisphosphonate because it has two phosphonate (PO^3) groups covalently linked to carbon, in contrast to pyrophosphates where the phosphonate groups are linked to oxygen. Bisphosphonate drugs have two side chains determining their specific function. The long side chain (R2) determines the chemical properties. The short side chain (R1), “the hook”, mainly influences chemical properties and pharmacokinetics. Together with the two phosphonate groups, “the hook” with its three-dimensional molecular structure, is essential for binding to Ca^{2+} ions and bone mineral such as hydroxyapatite (HA). Bisphosphonates with a hydroxyl group (OH) or an amino group at the R1 position will have increased affinity to calcium and bone mineral. The R2 side-chain determines the antiresorptive potency and also affects binding to HA by its structure and three-dimensional conformation. Bisphosphonates preferentially bind to the mineral phase of bone exposed by osteoclasts (Russell 2007).

There are at least two classes of bisphosphonates (Russell 2011), the N-containing and the non-N containing, interfering with different mechanisms in the osteoclast and bone resorption. The first generation bisphosphonates such as etidronate and clodronate are non-nitrogen compounds, having side chains R1 and R2 of simple chemical structures such as Cl, CH^3 and OH. They are metabolized into non-hydrolysable analogs of adenosine triphosphate (ATP) causing osteoclast apoptosis. The targeting of bisphosphonates to bone and the selective uptake of these cytotoxic ATP analogs by osteoblasts accounts for their ability to selectively induce apoptosis for osteoclasts but not other bone cells (Rogers 2003).

The second generation nitrogen containing bisphosphonates includes the commonly used drugs alendronate, risendronate, pamidronate and zoledronic acid. The R2-chain is modified to include an amino group and their antiresorptive activity has been found to be much higher compared to the first generation of bisphosphonates. Their effects are exerted by inhibiting the intracellular mevalonate pathway, also known as the HMG-CoA reductase pathway, an important cellular pathway for the biosynthesis of molecules used in the cell membrane function, hormones, protein prenylation and protein anchoring. Inhibition of the enzyme farnesyl pyrophosphate synthase (FPPS) in

the mevalonate pathway prevents prenylation and thereby formation of GTPases. GTPases, of which G-proteins are a group, are important for the transmission of signals across the cell membrane and are crucial for osteoclast functions such as cytoskeletal arrangement in the ruffled border, integrin signaling, membrane protein trafficking and induction of apoptosis. Although the exact mechanism of action is not fully understood the inhibition of protein prenylation is presumably the most important molecular mechanism by which nitrogen containing bisphosphonates reduces bone resorption (Russell 2007).

Zoledronate, a third generation bisphosphonate, has been shown to have an anti-angiogenic effect (Fournier 2002) supporting its use in the treatment of malignant bone diseases as well as in bone diseases with angiogenic components. It poses, however, at least a theoretical downside in the treatment of osteonecrosis where ingrowth of vessels is a prerequisite for healing.

Bisphosphonates have, perhaps surprisingly with regards to this thesis, been shown to be associated with osteonecrosis in the jaw of cancer patients. These patients have normally been administered high doses of intravenous bisphosphonates due to bone metastasis and during this time-period also been treated for dental conditions. The reason for this side effect of bisphosphonates is not fully understood (Ristow 2014).

Bisphosphonates could have beneficial effects on the treatment of ON by inducing apoptosis in osteoclasts and reducing bone resorption. ON in load bearing joints might lead to collapse of the subchondral bone. By reducing or delaying the rate of bone resorption with bisphosphonates, the mechanical strength of the necrotic bone can be preserved long enough for new bone formation, thus hindering the subchondral joint collapse and subsequent osteoarthritis (Lai 2005, Ramachandran 2007, Tagil 2004).

Methods and Background

The present thesis includes four papers with three clinical studies. Two of the clinical studies cover spontaneous osteonecrosis of the knee, SPONK. The first study addresses the possibility of treating SPONK patients with bisphosphonates (Jureus 2012). The second SPONK series is a long time follow-up of 40 patients and describes the natural course of this disease in an almost life long perspective (Jureus 2013). In the third clinical study we assess the post-operative circulation in the femoral head after cervical hip fracture in children and young adults and discuss the possibility of treating patients with compromised circulation at risk of AVN with prolonged restricted weight bearing and bisphosphonates. In the fourth paper we study bisphosphonate treatment of bone grafts experimentally in a mechanically loaded bone chambers in rats.

Patient populations

Paper 1 (Jureus 2012). Between the years 2006-2009, 17 consecutive SPONK patients were treated with bisphosphonates at our department. Patients with secondary ON were excluded. The group treated with bisphosphonate was compared to a previous group of 40 untreated consecutive patients with SPONK at our department (al-Rowaih 1991). The groups were compared in terms of requiring knee arthroplasty and development of secondary osteoarthritis.

Paper 2 (Jureus 2013). A long-term follow-up study was performed after 1-27 years in 40 consecutive untreated SPONK patients originally diagnosed at our department during the period 1982-1988. A short-term follow-up study, 1-7 years, has been previously published (al-Rowaih 1991). The records of all 40 patients were reevaluated in 2012 in terms of need for further major knee surgery (knee arthroplasty or high tibial osteotomy) and the significance of the size of the osteonecrosis.

Paper 3. A cohort of 12 children and young adults with a cervical hip fracture and thereby at risk of impaired femoral head circulation was studied. In 2006, we started to evaluate the postoperative circulation in the femoral head in children and young adults after cervical hip fracture. Cervical hip fractures in these young patients are rare, and between 2006 and 2012, 12 patients, 7-23 years old, were diagnosed and, in case of an avascular femoral head, treated with bisphosphonates for this condition at our department. 10 of these 12 patients had the postoperative circulation in the femoral

head evaluated (see below) and all these 10 patients were included in the study. The patients were followed for a minimum of 1 year in terms of development of AVN and secondary degenerative changes.

Paper 4. An experimental animal study on rats. 24 animals had a loaded bone chamber with a bone graft implanted in the proximal tibia. Systemically administered bisphosphonates were given to 12 rats with the other 12 serving as controls. The ability of bisphosphonates to protect the subchondral bone from collapse and compression in a high load environment was evaluated.

Swedish Knee Arthroplasty Register (SKAR)

Information from the Swedish Knee Arthroplasty Register (SKAR) was used to identify SPONK patients who had undergone reconstructive knee surgery (Jureus 2013). The SKAR was started in 1975, and all hospitals performing knee arthroplasties in Sweden report both primary procedures and revision procedures to the SKAR. The SKAR covers 100% of the Swedish hospitals and 97% of the Swedish knee arthroplasties have been shown to be included in the register (Knutson and Robertsson 2010).

Radiological methods

Multiple methods of radiological evaluation and classifications were used in this thesis and the systems of classification will be discussed but not the method of radiology itself. Early in the remodeling process, the subchondral cysts, normally but not always seen on plain radiographs, represent the increased size of the individual trabeculas. The methods of assessing ON lesions in the hip as well as the knee with magnetic resonance imaging, MRI, will be broadly described as well as the use of scintigraphy in hip AVN following fracture.

Magnetic Resonance Imaging (MRI)

Magnetic resonance imaging, MRI, is a method used in a variety of applications in the medical field. MRI has been proven to be a valuable tool in the diagnosis of knee ON (Bjorkengren 1990, Yates 2007). When the marrow becomes necrotic, the normal fatty marrow is gradually replaced by fibrosis with a higher water content, which in turn is detected in T1-weighted MRI images as a decreased signal replacing the high-intensity fat signal. The T2-weighted image shows areas of low signal intensity surrounded by a high-intensity signal caused by edema.

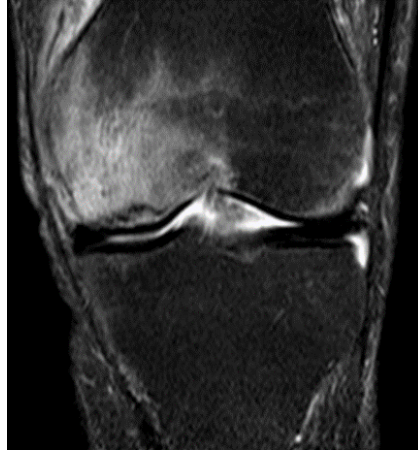

Fig 9. T2-weighted MRI, medial femoral ON

MRI showing bone marrow edema of the medial femur condyle with a focal subchondral lesion typical of ON.

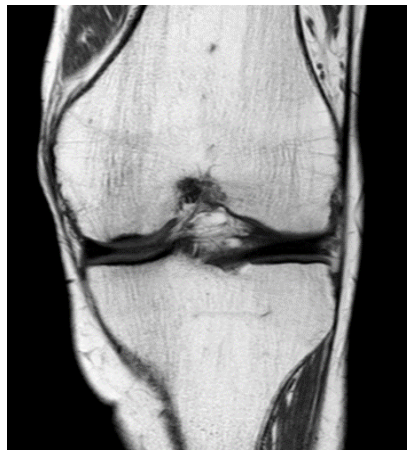

Fig 10. T1-weighted MRI, medial femoral ON

MRI of the same knee as above with decreased signal in the medial femoral condyle in T1-weighted image.

MRI is a valuable tool to diagnose hip ON in a similar way as described for knee osteonecrosis. In MRI, the pathognomonic sign of AVN is seen as a subchondral ‘band-like’ low-signal lesion in T1 weighted images and as a “double-line” sign in T2-weighted, non-fat suppressed images (Karantanas 2013, Mitchell 1986). However, after a fracture the use of MRI becomes more challenging in diagnosing ON especially in the femoral head due to artifacts from the osteosynthesis. A popular method is Diffusion Weighted Imaging (DWI), a sensitive method of detecting early pathological findings in tissue. DWI can be used to differ hip AVN from normal hips (Oner 2011).

Perfusion-MRI, detects the passage of a gadolinium contrast agent through the vessels and tissue, acquiring series of T2 images. It has not been shown to add to the diagnostic or prognostic value of MRI in idiopathic AVN (Karantanas 2013), but does after a femoral neck fracture (Ehlinger 2011, Kaushik 2010). In conclusion, MRI is a sensitive method for early diagnosis of ON but pathological changes on MRI may take several weeks to develop (Sakaia 2000).

Scintigraphy

In scintigraphy, emitted radiation from isotopes is detected by gamma cameras and form two-dimensional images. In bone scintigraphy, technetium 99m is attached to methylene-diphosphonate (MDP), which is preferentially taken up by bone and binds to hydroxyapatite (HA). Bone scintigraphy is the tradition method to diagnose AVN (al-Rowaih 1990, Stromqvist 1987) and a decreased uptake in the femoral head of technetium 99m-MDP 1-3 weeks after a hip fracture is a strong indicator for loss of the vascular supply (Stromqvist 1987). In SPONK (Ahlback 1968, al-Rowaih 1990) but also in hip AVN, an increased focal uptake is seen at the site of the lesion approximately 5 weeks after the onset of symptoms, as technetium 99m-MDP is taken up by increased osteoblast activity during remodeling. Some authors report a characteristically high uptake in the affected femoral condyle after just a few days of the onset of pain (Rozing 1980). Today, SPONK is mainly diagnosed by MRI (Yates 2007).

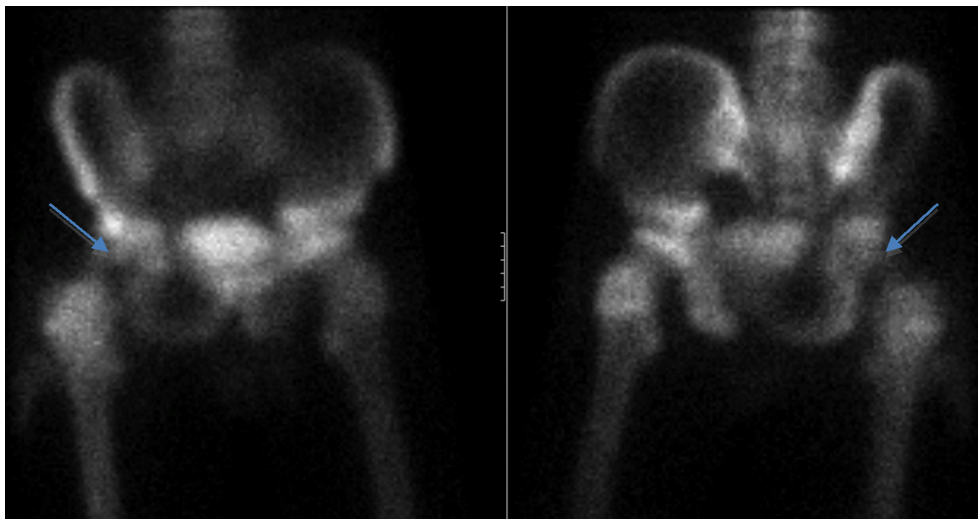


Figure 11. Scintigraphy

Scintigraphy of a right cervical hip fracture in a 16-year-old boy, performed 1 week after surgery. Left frontal view and right dorsal view showing decreased uptake (arrow) in the right femoral head indicating loss of blood supply and risk of AVN.

SPECT

Single-photon emission computed tomography (SPECT) is similar to conventional scintigraphy as described above and uses gamma cameras for imaging. The information can be provided in true 3D. Multiple 2D scintigraphic pictures are acquired from different angles and converted into a 3D structure by using a computer algorithm. The data set can show thin slices of any chosen axis.

SPECT/CT

When computed tomography (CT) is added to SPECT, fusion images known as SPECT/CT can be created, containing both physiologic information from the SPECT and anatomic information from the CT. The diagnostic capability of AVN is improved over SPECT alone. It allows anatomical location of increased scintigraphic uptake, or tissues, which may be seen on SPECT but are otherwise difficult to locate with regard to other anatomical structures (Luk 2010).

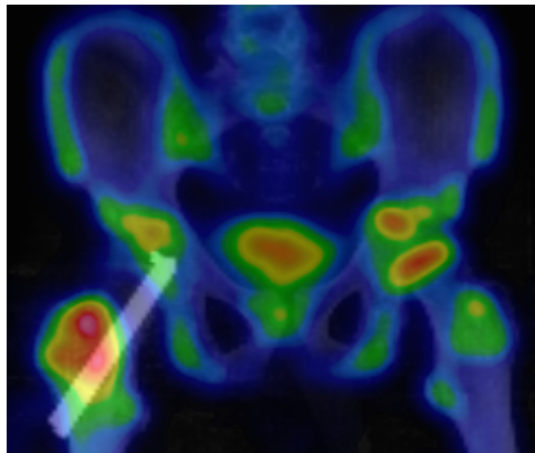


Figure 12. SPECT/CT

A SPECT/CT of a 15-year-old boy is seen showing an operated right-sided cervical hip fracture. When computed tomography (CT) is added to SPECT, fusion images known as SPECT/CT can be created. Scintigraphic information is displayed in color and CT information in gray-scale. The pins, which fixate the femoral neck fracture, can be clearly seen along with a distinctly reduced (partial) scintigraphic intensity in the right femoral head compared to the left. The intense uptake in the trochanteric region is caused by the surgery.

Osteonecrosis in plain radiographs

During the early stage after a vascular disruption and the subsequent necrosis of the bone- and other mesenchymal cells, the standard radiographic investigation is normal. Scintigraphy performed at the same time may show a decreased or increased uptake

and T2-weighted MRI images may show a central area of low signal intensity, surrounded by a high-intensity signal, which is caused by edema. By using exclusively a radiographic examination, an ON can be missed (Ahlback 1968, Lotke 1977). Findings on plain radiographs as well as the changes on T1 weighted MR images develop at a later stage, after the bone remodeling process has started. The central black cyst, seen in the center of an ON on radiographs, represents the increased size of the individual trabeculae and takes months to develop. The gradual return of the bone density is used to monitor healing of an ON. The healing tissue of the ON gradually ossifies with sclerotic changes as a result of mineral being laid down onto the necrotic trabeculae, forming new bone. The typical “crescent” sign seen in later stages of knee ON, probably represents either subchondral collapse of the necrotic bone or fluid leaking in from the joint space initiating osteoclastic resorption (Buckwalter 2007). Regardless of cause, the changes in the subchondral bone ultimately can lead to collapse of a portion or the entire affected joint. At the end stage secondary arthritic changes appear in plain radiographs as a result of the collapse and the subsequent joint incongruency.

Radiological classification of osteonecrosis, osteoarthritis and hip fracture.

Several methods of measuring and evaluating ON lesions exist and they all may be important. The size of the necrotic lesion has been shown to be prognostic in SPONK (Lotke 1982), which was confirmed in our study of the natural course of SPONK (Jureus 2013). The use of different methods and staging systems can be somewhat confusing. In addition the use of different methods of staging ON lesions in the knee and hip sometimes makes it difficult to compare the outcome of different treatment options.

Radiological classification of SPONK

Lotke

All the methods of measuring osteonecrosis of the knee involve approximations. The Lotke method (Lotke 1982) used in Paper 1 and 2 (fig 13) uses only the antero-posterior (AP) view. Lotke relates the width of the lesion to the size of the affected condyle. This method often allows the lesion to be measured. It does not however take into account the volumetric size of the ON, nor does the method measure the progression of the disease or stage secondary changes.

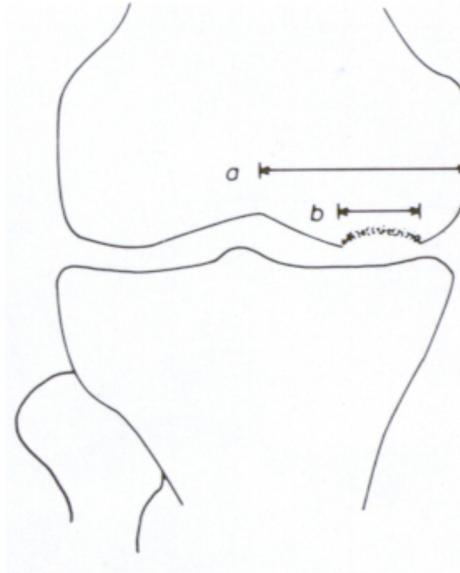


Figure 13. The Lotke index

The Lotke index relates the width of the lesion to the size of the affected condyle, b/a .

Muheim and Bohne

Using the method of Muheim and Bohne, an area of the necrotic lesion is calculated by multiplying the width on the AP with the length of the lesion on the lateral view (Muheim and Bohne 1970). Sometimes the ON lesion is seen only in the frontal or in the lateral view, which limits the use of this method.

Aglietti

Aglietti (Aglietti 1983) classified the necrotic lesion into five stages after modification from Koshino (Koshino 1982) without relation to the size. Stage I simply indicates normal radiographs, whereas Stage II represents a flattening of the affected condyle. In Stage III, a subchondral radioluculent lesion can be observed, surrounded by limited sclerosis, which in Stage IV has developed into a more evident surrounding sclerosis and subchondral bone collapse. Finally in Stage V, secondary degenerative changes have appeared. The Aglietti method, thus, measures the progression of the disease and also takes in to account secondary changes. It does not relate the stage to the size of the osteonecrotic lesion, a disadvantage, since several studies have shown the size to correlate with the prognosis. (Jureus 2013, Lotke 1977, Muheim and Bohne 1970, Rozing 1980)

Mont

The necrotic angle was described by Mont (Mont 2000) and measures the size of the epiphyseal lesion. The angle is measured from the epiphyseal scar (ES) in the sagittal and coronal plane and the two necrotic angles are summed to provide the combined necrotic angle. Lesions of 150° or less are categorized as small, lesions of $151-249^\circ$ as medium and lesions of 250° or more as large. The method further requires the lesion to be visible in both the frontal and lateral views Fig (14).

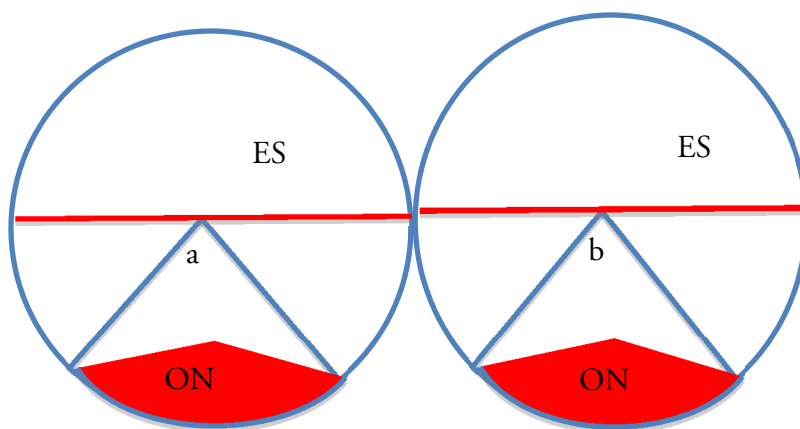


Figure 14. The necrotic angle described by Mont

The left circle represents the affected femur condyle in the coronal view and the right circle the same condyle in the sagittal view on plain radiographs. The angle (a and b respectively), which covers the ON lesion, is measured from the epiphyseal scar (ES) in the sagittal and coronal plane. The two necrotic angles (a+b) are summed to give the combined necrotic angle. Lesions (a+b) of 150° or less are categorized as small, lesions of $151-249^\circ$ as medium and lesions of 250° or more are categorized as large.

Radiological classification of knee osteoarthritis

Ahlbäck

The prognosis of SPONK is poor and associated with a high frequency of osteoarthritis (OA) (Lotke 1982). In paper 1 and 2, we used the Ahlbäck classification (Ahlback 1968) to evaluate the incidence and especially the development of secondary osteoarthritis. Stage 0 means no osteoarthritis. In Stage 1, a narrowing of the joint space of $>50\%$ is observed and in Stage 2, the whole joint space is obliterated. In Stage 3 a bone defect/loss of less than 5 mm is seen and lesions are classified as Stage 4 if the bone defect/loss is between 5-10 mm. In Stage 5, the bone defect/loss exceeds 10 mm and is often combined with subluxation and arthritis of the other compartment (Table 1).

Tabel 1. Ahlbäck classification

The Ahlbäck classification of knee osteoarthritis was used in paper 1 and 2 for description and evaluation of secondary arthritic findings following SPONK.

Stage	Description
I	Narrowing of the joint space inferior to the half of the space in the other compartment
II	Obliteration of the joint space
III	Bone defect/loss <5 mm
IV	Bone defect/loss between 5 and 10 mm
V	Bone defect/loss >10 mm often with subluxation and arthritis of the other compartment

Kellgren-Lawrence

Another scale used to grade OA in the knee and sometimes in other joints such as the hip and hand, is the Kellgren-Lawrence grading scale (Kellgren and Lawrence 1957). Grade 1 is used when a narrowing of joint space starts and osteophytes appear. The distinction between normal radiographs and stage 1 can be difficult. Grade 2 is interpreted as the definite formation of osteophytes and a definite narrowing of the joint space. In grade 3, moderate multiple osteophytes and definite narrowing of joint space are seen combined with some sclerosis and deformity of the bone contour. In grade 4, finally, large osteophytes, marked narrowing of joint space, severe sclerosis and deformity of bone contour can be found.

Other systems

The Osteoarthritis Research Society international grading system for medial and lateral tibiofemoral joint space uses the narrowing of the joint space in percent to be divided into Grade 0= normal, Grade 1= mild (1-33%), Grade 2, moderate (34-66%) and Grade 3, severe (67-100%).

Radiological classification of hip osteonecrosis and hip fracture

Ficat and Arlet

The Ficat and Arlet (Ficat 1985) staging system is the most commonly used system for ON of the femoral head and used in paper 3. The staging system is based mainly on plain radiographic changes that occur as a result of the bone necrosis, but also the subsequent reparative changes, collapse and degeneration of the femoral head. In *Stage I*, the radiographs are normal. In *Stage II*, osteopenia and/or sclerosis are seen but the head remains spherical. In *Stage III*, the head is flattened and often a crescent sign is

seen. In Stage IV secondary degenerative changes are present. Today a “Stage 0” is often added to the classification but was not originally described by Ficat and Arlet. In stage 0 plain radiographs are normal as well as scintigraphy and MRI. In stage 1 plain radiographs are normal, the bone scan may be non-diagnostic and difficult to interpret but the MRI indicate early changes. It should be noted that using only plain radiographs to stage osteonecrosis of the hip, as in paper 3, it is not possible to differentiation between stage 0 and 1 (Table 2).

Table 2. Ficat and Arlet classification

The Ficat and Arlet classification system was used to stage osteonecrotic lesions in the femoral head in paper 3.

Stage	Radiograph	Bone scan	MRI
0	Normal	Normal	Normal
I	Normal	Non diagnostic	Early changes
II	Osteopenia/sclerosis spherical head	Positive	Positive
III	Flattened head crescent sign	Positive	Positive
IV	Secondary degenerative changes	Positive	Positive

Stulberg

The Stulberg classification is the gold standard for diagnosing and staging radiological findings, originally developed for the Perthes disease (Stulberg 1981). The method has been questioned due to a low inter- and intra observer reliability (Neyt 1999).) The Stulberg classification has been used also to stage radiological changes after traumatic AVN of the hip (Ramachandran 2007). Stage 1= normal. Stage 2= spherical head with coxa magna/breva or steep acetabulum (spherical congruency, good prognosis). Stage 3= non-spherical head (aspherical congruency, OA late adulthood). Stage 4= flat head and flat acetabulum (aspherical congruency, OA late adulthood). Stage 5= aspherical incongruence (Aspherical incongruence, OA before the age of 50 yrs. The Stulberg classification was used in paper 3 to measure the collapse of the femoral head (Table3).

Table 3. The Stulberg classification

The Stulberg classification is the gold standard for diagnosing and staging radiological findings in Perthes disease.

Stage	Description
I	Normal
II	Spherical head with coxa magna/breva or steep acetabulum (Spherical congruency, good prognosis)
III	Non-spherical head (aspherical congruency, OA late adulthood)
IV	Flat head and flat acetabulum (aspherical congruency, OA late adulthood)
V	Aspherical incongruence (aspherical incongruence, OA before 50 years of age)

Table 4. The Delbet classification

The Delbet classification is used to describe pediatric hip fractures.

Type	Description
I	Transphyseal, without or with dislocation (type A respectively type B)
II	Transcervical (cervical)
III	Cervicotrochanteric (baso-cervical)
IV	Intertrochanteric (trochanteric)

Animal model

Animals

In the animal model, male Sprague-Dawley rats were used (328–367g, Møllegaard, Køge, Denmark). The use of animals allows larger reproducible series to be performed. The animals are inbred and are sexually mature at 7-8 weeks. A rat continues to grow their entire life of approximately 3-4 years. Rats differ in many ways from humans but physiological principles can be extrapolated. The rat skeleton organic matrix has lower collagen content, 60 percent versus 90 percent in humans (Jorgensen 1991). In rats, the cortical bone is subdivided into an outer zone of concentric lamellar bone and an inner zone of more irregular oriented non-lamellar bone, with the outer zone developing at 3 months (Danielsen 1993). The rat bone has a remodeling and healing

capacity much larger than in humans. The cellular mechanisms involved in bone metabolism are, however much the same as in humans and the rat skeleton provides a valid model to evaluate the principal effects of therapeutic bone agents on bone (Frost and Jee 1992). We used male rats in the experiments, mainly to avoid the effect of the polyestral cycle in female rats and because the male rat tibia is larger and hence more suited for the bone chamber used in the study. Grafts were taken from female rats for historical reasons because of a notion that they possess a more homogenous trabecular structure of the bone in the proximal tibia, where the grafts are harvested.

Procedure and ethics

Approval of the Institutional Review Board was obtained before the study was started. The rats were kept at the university animal facility with two rats in each cage and free access to food pellets and water. For the surgical procedure the animals were anesthetized with peritoneal injections of a pentobarbital and diazepam. The chambers were implanted under aseptic conditions.

The bone chamber

The loaded bone chamber (LC) (Tagil and Aspenberg 1999) (Figure 15) consists of a titanium cylinder formed out of two half cylinders, held together by a cap. There are two bone ingrowth openings at the end, implanted in the bone where tissue can grow in from the subcortical cancellous bone. A mechanical load can be transmitted to the tissue within the chamber by applying a known force on the top of the piston. A spring returns the piston to the original position when the loading is interrupted. The inside diameter of the LC is 2mm and the distance between the chamber bottom with its ingrowth openings and the piston is 5mm when the chamber is unloaded and 1,5 mm when a force is applied and the piston is loaded and in its most downward position. A rubber coat covers the top of the chamber with its mobile parts preventing tissue from interfering with the mechanism. The resistance of the rubber coating and the spring has been measured in bench tests.

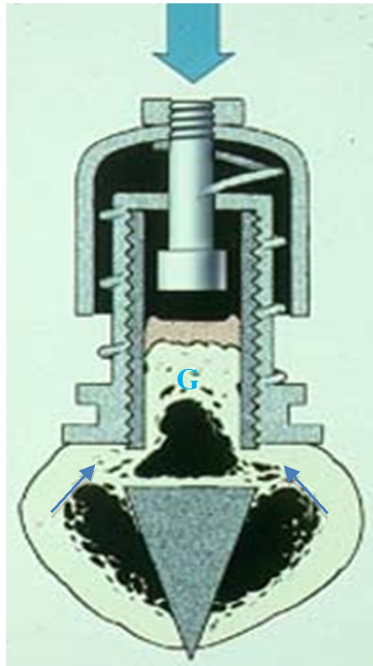


Figure 15. The loaded bone chamber

The loading force is applied by a dynamometer from outside of the skin at the upper end (large arrow). Mesenchymal tissue grows into the graft (G) from the openings at the lower end (small arrows), mimicking the situation in the subchondral bone in load bearing joints. The chamber allows various therapeutically active agents to be tested either administered locally before implantation or systemically before, or after, surgery.

Bone chambers with or without bone grafts, implanted in the proximal rat tibia, have been used in various models at our department to study bone metabolism and the effect of different drugs administered both locally and systemically (Aspenberg 1996, Astrand and Aspenberg 2002, Astrand 2006, Belfrage 2011, Belfrage 2012, Harding 2008, Jeppsson 2003, Khayeri 2009). The bone chamber offers a unique opportunity to study the effect on bone remodeling. Most of the studies have been in the unloaded chamber model, which does not fully mimic the situation in load bearing joints. In the unloaded chambers both systemic (Astrand 2006) and local (Belfrage 2012) bisphosphonates have been shown to reduce bone resorption. In a modified bone chamber (Tagil and Aspenberg 1999) (Fig 15) the bone graft was mechanically loaded and local treatment with bisphosphonates was shown to prevent collapse of the bone graft (Tagil 2004).

In study IV, osteochondral grafts were taken with a hole-cutter perpendicular to the joint cartilage from the femoro-patellar groove of female donor Sprague Dawley rats of the same age. The length of the grafts were measured by a caliper both before insertion

and at harvest with the idea that loading of the chamber and thereby the grafts would mimic the situation of a load bearing joint.

After preparation of the proximal rat tibia one end of the implant can be screwed in to the bone. The skin is then closed over the implant leaving the other end of the chamber subcutaneously. The chamber is left in situ for two weeks to allow tissue to grow in and after two weeks the loading starts. The rats were treated systemically with zoledronate. With a specially designed dynamometer an external loading force of 8 N is applied to the top of the chamber. The pressure applied on the tissue beneath the piston was calculated to be approximately 2 MPa. The loading regime was applied once daily 5/7 days in cycles of 10. After six weeks the animals were sacrificed and the chamber taken out and the length of the grafts were again measured. The grafts were taken for histological examination.

Evaluation

After harvest the specimens were measured with respect to their lengths. The degree of compression of the graft due to bone resorption and loading of the graft, resembles what could happen in a load-bearing joint with an subchondral ON lesion.

After fixation in formalin and decalcification in ethylenediaminetetraacetic acid (EDTA), the specimens were embedded in paraffin and cut parallel to the longitudinal axis of the chamber with a microtome. Three sections, 300 μ m apart and from the middle of the specimens can be used for histological and histomorphometric analyses after staining with hematoxylin and eosin. Using the Videoplan equipment at 40 \times screen magnification, the area of the new ingrown bone can be measured by circumscribing it on a digitizing table. This area includes graft remnants and marrow cavities that had been circled or covered by new bone. The mean bone ingrowth distance (d) can be calculated on each slide by dividing the new bone area with the width of the specimens. Fibrous tissue had advanced further into the chamber ahead of the new bone in all cases and the total tissue ingrowth distance was measured in the same way as bone ingrowth

Classically, a Merz grid ocular lens (Merz and Schenk 1970) with 6 \times 6 crossing lines forming 36 points of an area of interest were used to measure the bone density by a manual point counting method ad modum Cavalieri. An area fraction assessment, expressed as bone area/total area, can be made of both the remaining dead graft as well as living new-formed bone within the area of the point count. Multiple sections of each graft are analyzed at 40 \times magnification. The volume (V) of the new formed remodeled bone and remaining graft bone in the specimens below and including the edge of the bone formation can be calculated using the mean bone ingrowth distance into the graft (d) and the radius of the chamber (r=1mm), $V=d \times \pi \times r^2$. By multiplying (bone area/total area) with the volume, the total or relative amount of the retained new-

formed and non-resorbed bone graft can be expressed as bone volume/total volume (BV/TV). It was possible to do a distinction between dead graft bone and new living bone by grading the matrix staining and the existence of osteocytes.

New methods of digitally calculating bone ingrowth and BV/TV are now being introduced.

The studies- methods results and discussions

Methods and results

SPONK

Paper 1. Treatment of spontaneous osteonecrosis of the knee (SPONK) by a bisphosphonate

Between 2006 and 2009, 17 consecutive patients (mean age 68 years) with clinical and radiographic signs of knee ON were identified and given alendronate, 70 mg perorally, once a week for a minimum of 6 months. The patients were followed clinically, radiographically, and by MRI. 10 of the 17 patients did not develop osteoarthritis, 4 patients developed mild osteoarthritis but no knee joint surface collapse, and 3 patients had a joint surface collapse. In contrast to the previous, untreated series of ON patients (al-Rowaih 1991) at our hospital, the clinical results in the present series appeared better at an equivalent time period. 59% of the patients had a complete radiographic recovery, compared to 25% in the original study ($p=0.032$, Fischer exact test). 12% were failures regarding the need to undergo surgery when bisphosphonates were administered, as compared to 32% in the previous untreated series (n.s.). In the long-term follow-up of the untreated series (Jureus 2013), the size of the lesion was associated with an inferior outcome but in the bisphosphonate series such association was not found (Fig 16).

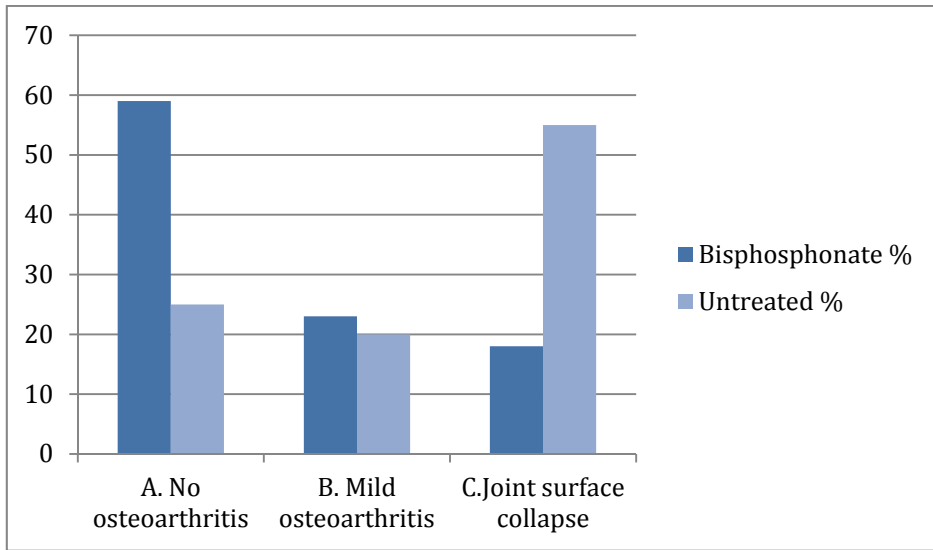


Figure 16. Results of treatment of SPONK by a bisphosphonate

Treatment of spontaneous osteonecrosis of the knee (SPONK) by a bisphosphonate improves the outcome compared to untreated patients, regarding risk for secondary radiological osteoarthritis ($P=0.032$ Fischer exact test).

Paper 2. The natural course of spontaneous osteonecrosis of the knee (SPONK)

Between 1982 and 1988, 40 consecutive patients were diagnosed with SPONK. In the short-term outcome after 1-7 years, 10 patients had a good radiographic outcome and 30 were considered failures, developing osteoarthritis. The short-term results have previously been reported (al-Rowaih 1991).

In 2012, all of the 40 patients were matched with the Swedish Knee Arthroplasty Register, SKAR (Knutson and Robertsson 2010) and their medical records were reviewed to evaluate the long-term need for major knee surgery. In the 2012 review (Jureus 2013), 33 of the 40 patients were dead. The mean follow up time, from diagnosis until death, revision or end of study, was 15 (1-30) years.

None of the 7 patients from the initial report, with a lesion visible only with scintigraphy but not with radiography, were ever operated. None of the 10 patients with a Lotke index of less than 20% were ever operated. At the time of this review, 17/40 patients had been treated operatively, either with a unicompartmental ($n=6$), a total knee arthroplasty ($n=9$) or an osteotomy ($n=2$). All but 1 of the 7 patients with an initial Lotke index of ≥ 40 were eventually operated with knee prosthesis.

1 patient, without radiographic OA changes at the initial review in 1991, later developed OA and was operated with an unicompartmental arthroplasty 9 years after symptom onset. With the exception of this patient, all the patients undergoing major

surgery were in the “failure” group (developing osteoarthritis) in the initial study 1991. The median time to knee surgery was 1,5 (0,5-11) years and 14/17 of the operations were carried out within the first 4 years. No major knee surgery was performed later than 12 years after the diagnosis and in 2012 only 4 un-operated patients were still alive. A Kaplan–Meier failure estimate was calculated and presented as a graph (Fig 17), showing the proportion of patients needing to undergo knee surgery with either osteotomy or arthroplasty over the years.

The age of the patients operated with knee prosthesis or osteotomy was 68 (48-85) years at the time of symptom onset, compared to 74 (64-84, $p= 0,1$) in the group who were never operated but were considered failures in the initial report. The age of the 10 patients with a “good” outcome, who did not develop OA in the initial report, was 56 (41-77) years compared to 71 (48-85) years in the group developing OA ($p<0,001$). No gender-specific differences could be shown in terms of the need to undergo a knee prosthesis surgery.

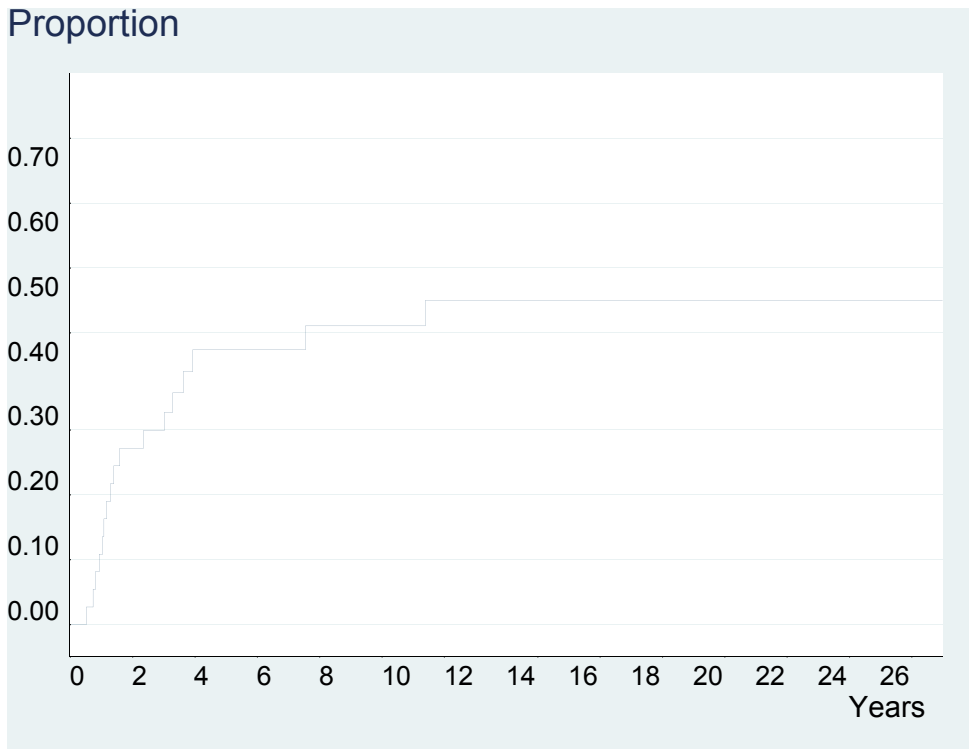


Figure 17. Kaplan-Meier failure estimate

Kaplan–Meier failure estimate, illustrates the proportion of patients undergoing knee surgery with arthroplasty or high tibial osteotomy over the years.

Cervical hip fracture

Paper 3. Vascular impairment after cervical hip fractures in children and younger adults.

10 children or young adults, 5 girls and 5 boys, (mean age 14 years (7-23)) were operated for a cervical or basocervical hip fracture between 2006 and 2012. The femoral head circulation was evaluated post-operatively with scintigraphy. Patients with definitive lack of femoral head circulation had been prescribed non-weight-bearing and bisphosphonates for a minimum of 6 months. All patients were followed for minimum of one year with radiographic examinations. Radiological changes were classified according to the Stulberg and the Ficat and Arlet scores (Table 2 and 3) respectively (Ficat 1985, Stulberg 1981)

In 3 patients, the femoral head had normal circulation postoperatively and all 3 had normal radiographs at follow-up. The patients with normal circulation were non-weightbearing for mean 3 months (1-6). In 3 patients the entire femoral head was avascular post-operatively, and at follow-up 1 patient had normal radiographs, 1 had subchondral sclerosis but normal sphericity and 1 had both subchondral sclerosis and flattening. The patients with complete avascularity underwent a longer period of non-weightbearing after surgery, (mean 12.5 months (7.5-18)). All 3 patients were treated with bisphosphonates. 4 patients post-operatively had retained circulation in parts of the femoral head and 3 of these 4 patients had normal radiographs at follow-up. The 4 patients with retained vascularity in parts of the femoral head were non-weight-bearing for mean 3,5 months (1,5-6) and none were treated with bisphosphonates.

Animal study

Paper 4. Systemically administered zoledronate prevents collapse in mechanically loaded osteochondral grafts. A bone chamber study in rats.

24 male Sprague-Dawley rats, 2 rats in each cage with free access to water and food pellets, were kept in our animal facilities for 1 week before experiments started. Bone grafts were harvested, measured with a caliper and placed in a bone chamber inserted into the tibia of a rat. Host tissue could grow into the graft through openings in the chamber. Weekly injections with zoledronate (0.1 mg/kg s.c, Zometa, Novartis, Ryde, Australia) or saline were subcutaneously administered. The grafts were then loaded for 4 weeks. Pressure was applied by hand using a specially designed dynamometer once a day, five days a week until the rats were harvested after 6 weeks. The specimens were fixed, cut and stained with haematoxylin/eosin and used for histological and histomorphometric analyses. In 8 rats a cyst formed around the chamber. The cysts were punctured and if pus was present (n=2, both saline controls) the rats were excluded and if the fluid was opalescent (n=6), the animal remained in the study. The mean decrease from the original graft length of 3.9 (SD 0.7) mm in both groups was 0.63

(SD 0.63) in the saline treated controls compared to 0.18 (SD 0.20) in the bisphosphonate treated group ($p=0.03$). None of the bisphosphonate treated lost > 0.5 mm whereas 5/10 in the saline group lost $> 0,5$ mm.

Histologically, the whole graft had revascularized and fibrous tissue had grown in to replace the bone marrow. A clear ossification front was seen in all grafts. In the controls, the graft was almost totally resorbed and had been replaced by fatty tissue but in the bisphosphonate treated specimens the graft remained with new formed bone appositioned. The increased bone volume was obvious to the naked eye (Fig 18).

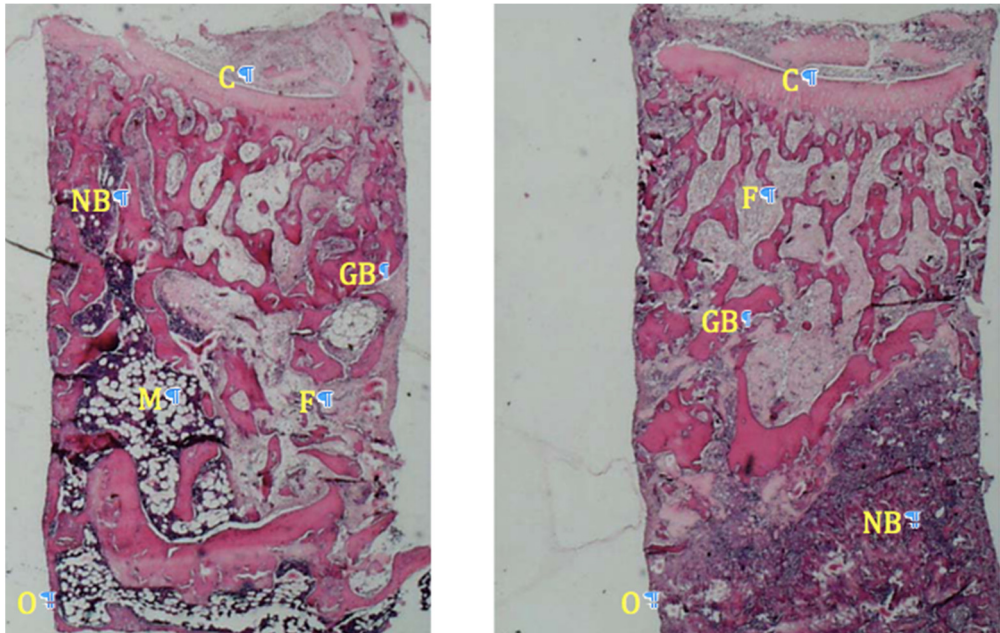


Figure 18. Histology of bone graft.

Left, saline treated control specimen after 2 weeks of non-loading followed by 4 weeks of loading. A marrow cavity (M) has formed where the graft (GB) has been resorbed. Above this, the front of new formed bone (NB) is seen which has reached the top in the periphery but not centrally. Right, zoledronate treated specimen after 2 weeks of non-loading followed by 4 weeks of loading. The ingrowth openings are in the lower end and vessels grow in upwards in the bone part towards the cartilage part (C) of the osteocartilaginous graft. New bone (NB) is formed without marrow cavity. Next to the chamber wall marrow fibrosis (F) seem to appear replacing the subchondral bone underneath the cartilage layer

Discussion

The present thesis aims to increase our knowledge of ON and to find possible ways to prevent the consequences of an ON in subchondral bone in load bearing joints. The focus has been mainly on prognosis and treatment of SPONK but also on diagnosis of vascular impairment and ON following hip fracture in children and young adults. An experimental animal study was performed in a rat model to study remodeling of dead bone under load.

ON in the subchondral bone is painful, often leads to secondary osteoarthritic changes and is associated with an increased risk of surgery with joint prosthesis (Lai 2005, Lotke 1982). ON is defined by death of bone cells, osteocytes, hematopoietic and fatty marrow precursor cells. ON can be divided as being traumatic or non-traumatic. If no factors related to the osteonecrotic lesion can be found the lesion is said to occur “spontaneously”. (Ahlback 1968, Akamatsu 2012, Jones 1993, Kantor 1987, Yamamoto and Bullough 2000). Regardless of cause, vascular compromise is the final pathway that leads to cellular death.

Three of the papers, including the animal study, comprises bisphosphonate treatment studies of the osteonecrotic lesions. Two papers, the first investigating bisphosphonate treated SPONK patients and the second being the animal study, compared treated patients and specimens with untreated controls. In the paper on osteonecrosis following hip fracture, the focus was not primarily on treatment with bisphosphonates, although 3 patients were treated with this drug, but on the diagnosis and prognosis related to the remaining postoperative blood circulation in the femoral cervical head.

SPONK

The long time follow up of SPONK patients describes the natural course of untreated SPONK. Only 4 non-operated patients were still alive at the end of the study making it an almost lifelong follow up, with a mean follow-up period of 15 years ranging from 1 to 30 years. The patients were diagnosed between 1982-88 and the last major knee surgery was performed 11 years after diagnosis making further knee surgery later in life in these patients due to SPONK unlikely or approaching the normal risk of developing osteoarthritis. Previous SPONK studies have all had shorter mean follow up periods, ranging from 3 to 6 years (al-Rowaih 1991, Houpt 1983, Lotke 1982, Rozing 1980, Satku 2003). Rozing (1980) reported the largest series, in which 35/90 knees with SPONK were treated with osteotomy or arthroplasty. Patients with a good outcome in the initial 1-7 year follow-up (al-Rowaih 1991) of our series continued to do well in the long time follow-up of the same 40 patients (Jureus 2013). Only 1 patient without radiographic osteoarthritic changes in the initial study deteriorated and was operated after 9 years. Most surgeries were made during the first years and if the patient had a

small lesion or did not develop OA during this early time period, it appeared less likely that a late deterioration will occur. Younger patients have a significantly better prognosis. Older patients with large lesions and early radiological signs of secondary osteoarthritis should be considered for early intervention with knee prosthesis. However, bisphosphonates might alter the course of SPONK even in older patients with larger lesions.

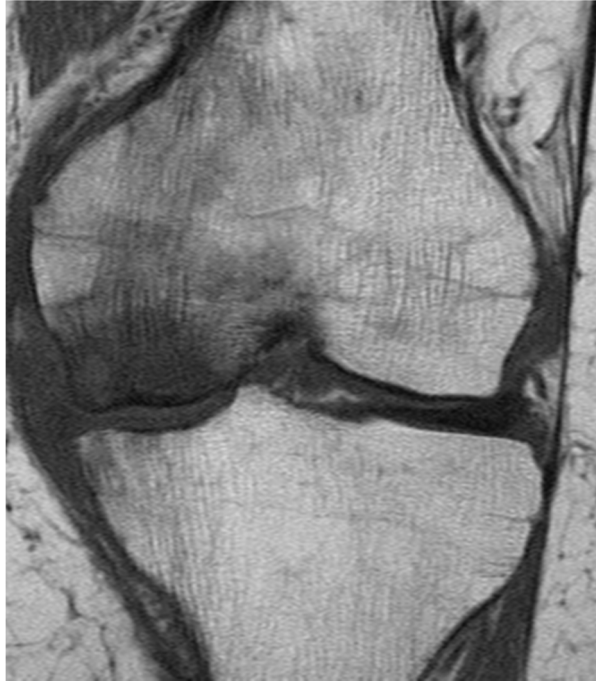

Figure 19. SPONK
Spontaneous osteonecrosis of the knee seen on MRI.

In our study “Treatment of spontaneous osteonecrosis of the knee SPONK by a bisphosphonate” (Jureus 2012), we compared bisphosphonate treated SPONK patients with a previous, untreated series of ON at our hospital (al-Rowaih 1991). The clinical results in the bisphosphonate series was significantly better with 59% of the patients having a complete recovery in plain radiographs compared to 25% in the original study. 12% were failures in terms of a need to undergo surgery when bisphosphonates were given compared to 32% in the previous untreated series. There are however well recognized problems in the comparison of historical series.

Our hypothesis was that an anticatabolic drug would delay the remodeling of the dead bone. Systemic treatment with bisphosphonates has been suggested to postpone the resorption of the necrotic bone during the revascularization and new bone formation.

Bisphosphonates delay the resorption of revascularizing dead bone experimentally (Astrand and Aspenberg 2002, Kim 2005, Little 2003, Tagil 2004) as well as in clinical hip osteonecrosis case series (Agarwala 2005, Nishii 2006, Ramachandran 2007) and knee osteonecrosis series (Kraenzlin 2010). In a randomized human study bisphosphonates given to patients with femoral head osteonecrosis substantially reduced the risk of secondary osteoarthritis and hip arthroplasty (Lai 2005). However, no effect of bisphosphonate treatment could be seen in a randomized short time follow up series of mixed causes of knee osteonecrosis diagnosed with MRI and with the primary objective to study the change in pain score (VAS) after 12 weeks treatment with ibandronate or placebo (Meier 2014).

Only a direct comparison in a long-term prospective randomized study would be able to determine if bisphosphonates are capable of changing the outcome with regard to development of osteoarthritis and need for major surgery. Such a study may, however be difficult to perform due to the low incidence of the condition.

Cervical hip fracture

In our study "Vascular impairment after cervical hip fractures in children and younger adults" we found evaluation of the vascularity of the femoral head to be a useful tool to predict the outcome after cervical or basocervical fractures in children and younger adults. Without pharmacological or other treatment, other than a shorter period of restricted weight-bearing, all patients with a normal bone perfusion investigation healed without signs of radiographic lesions after a follow-up of mean 18 months. Amongst those patients, where scintigraphy revealed reduced vascularity in parts of the femoral head, 3/4 patients healed without signs of radiographic deterioration. 1 patient, diagnosed as having a partially impaired uptake, developed secondary radiographic lesions, The pattern of avascularity in this patient differed from the other 3 patients in this group, who all had normal radiographs at follow up with the partial avascularity appearing in the cranial subchondral part of the femoral head, in the epiphysis, rather than the metaphyseal region (Fig 20). The avascular part corresponded to the final radiographic lesion seen in this patient at follow up. Weight-bearing by itself does not contribute to femoral head AVN but may cause the subchondral bone to gradually collapse (Okazaki 2012, Pringle 2004, Xu 2010). On reflection, it is possible a prolonged period of non-weight-bearing and/or addition of a bone resorptive agent such as bisphosphonate in this patient may have decreased or hindered the development of secondary radiographic changes.

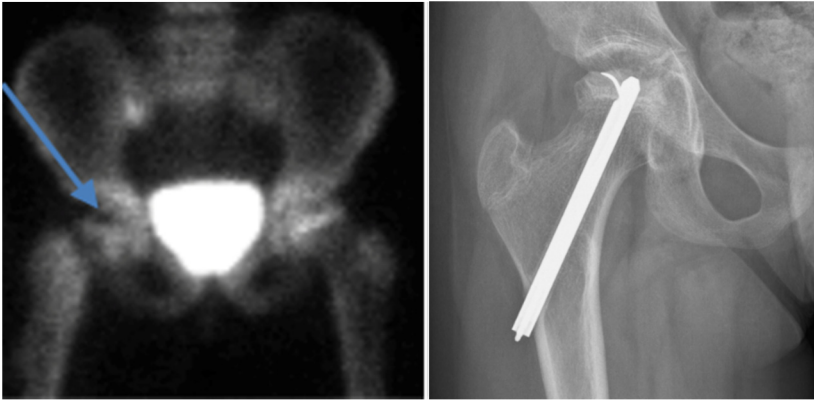

Figure 20. Partial avascularity in the subchondral bone

1 patient, diagnosed as having a partially impaired uptake, developed secondary radiographic lesions. The pattern of avascularity in this patient differed from the other 3 patients in this group, who all had normal radiographs at follow-up, whereas partial avascularity appeared in the cranial subchondral part of the femoral head (arrow) in the epiphysis rather than in the metaphyseal region (left). The avascular part corresponded to the final radiographic lesion seen in this patient at follow-up (right).

The time to the perfusion investigations differed, as did the time for non-weightbearing and time of bisphosphonate treatment. Both prolonged non-weight-bearing as well as bisphosphonates were prescribed in patients with avascularity of the entire femoral head. The length of the non-weight-bearing period differed between the groups in our series, ranging from 1 to 18 months.

Bone resorption occurs rapidly in children with avascularity due to a cervical hip fracture when osteoclasts resorb necrotic bone during revascularization. Ramachandran evaluated a pediatric series of 28 patients with suspected AVN, which included 22 children with slipped capital femoral epiphyses, 4 with femoral neck fractures and 2 with traumatic hip dislocations (Ramachandran 2007). All 17 patients with a cold bone scan, indicating significant lack of blood supply to the femoral head, were treated with intravenously administered bisphosphonates and all had a good or excellent clinical outcome. Radiographically 9 hips were rated as Stulberg class 1 or 2, 6 hips as class 3, and 2 hips as class 4 (Stulberg 1981). The 11 patients with normal bone scans healed without radiographic abnormalities.

Femoral head AVN following cervical neck fracture in children and younger adults is rare but complications are common (Forlin 1992, Morsy 2001) and every effort should be made to limit the consequences in these young patients. Surgical intervention within 24 hours with anatomical reduction, stable fixation and evacuation of intra-capsular hematoma is presumed important as it may reduce the risk for AVN (Boardman 2009). AVN is usually diagnosed radiographically within 12 months but may not be evident for several years.

Evaluating the remaining circulation after surgery helps predict the outcome and in patients with an avascular femoral head after fracture, a prolonged period of non-weight-bearing and drug treatment with bisphosphonates may be beneficial, whereas patients with intact postoperative circulation can be expected to have a good prognosis and can be allowed earlier weight-bearing and return to previous activities.

Animal study

Circulating bisphosphonates bind to bone mineral and as the bone is resorbed by osteoclasts, bisphosphonates are internalized and interfere with the cell metabolism, eventually leading to apoptosis of the osteoclast (Rogers 2003, Russell 2007). We have shown in this study that systemic treatment of an osteochondral graft with a bisphosphonate diminishes the risk of collapse during revascularization in a high-load environment. There are various hypothetical mechanisms that can lead to the collapse of the subchondral bone and in the bone chamber model these can be studied as separate phenomena.

- 1) A fatigue fracture might occur in the necrotic subchondral bone before the necrotic subchondral bone has been reached by the remodeling front.
- 2) Once the subchondral bone has been reached by the remodeling front, a too rapid osteoclastic resorption of the necrotic bone, without sufficient osteoblastic bone formation, weakens the bone as a construct.
- 3) Fluid enters the subchondral space through a fracture and under the influence of oscillating pressure, from the joint during load bearing, which induces resorption.

Fatigue fracture

Bone is a material with low resistance to fatigue and bone entirely relies on the repair mechanism by living osteoblasts and osteoclasts. Necrotic bone lacks the repair system and is prone to fatigue fractures as seen for example in large femur allograft in tumor surgery (Enneking and Mindell 1991). In the chamber, the graft is remodeled from the ingrowth openings in the bottom and upward. It takes time for the remodeling front to reach the top of the chamber with the subchondral bone and the cartilage. Here the loading piston pushes upon the graft and with the high load, fatigue fractures may occur before the subchondral bone has remodeled.

Resorption

Although the cells in an osteonecrotic area become apoptotic, the bone will initially retain its load bearing capacity (Parks and Engh 1997). First when blood vessels from the surrounding living tissue start to invade the necrotic zone, the accompanying osteoblasts and osteoclasts start to remodel the dead bone (Harding 2008). There will be a period of mechanical weakening as the osteoclasts precede the bone formation. If

the remodeling occurs in a highly loaded area such as in the subchondral bone of a joint, the mechanical strength of the remodeling bone may be temporarily decreased so that the bone collapses (Tagil 2004).

Fluid pressure

Fluid pressure, especially fluctuating, induces bone resorption via an osteoclastic induction (Aspenberg and van der Vis 1998, Van der Vis 1998). Joint cartilage may have an important function to protect the subchondral bone from the hydrostatic pressure within a joint by hindering massive fluid flow. Direct communication of joint fluid with subchondral bone, causes cavitory bone resorption, and may play an important role in an osteoarthritic joint, with elevated intracapsular pressure due to effusion and decreased capsular compliance (Schmalzried 1997, van Dijk 2010). It should be noted that osteonecrotic bone lacks activated osteoclasts and that the fluid pressure theory would only be valid in revascularized bone and in the presence of osteoclasts.

In all three scenarios, bisphosphonates would theoretically be effective and in this study we have shown that systemic treatment of an osteochondral graft with a bisphosphonate diminishes the risk of collapse and compression during revascularization in a high-load environment. This supports the clinical use of bisphosphonates in patients with osteonecrotic lesions. However the protecting capacity seems to be somewhat less affective when bisphosphonates are given systemically, as in this present series, when comparing to a previous loaded bone chamber study with local treatment of the bone graft with a bisphosphonate (Tagil 2004). New insights into bone remodeling were acquired. The front of new-forming bone seems to be preceded in space by a zone of osteoclastic resorption. This zone is a locus minori and may even by physiological loading be compressed. With bisphosphonate treatment, less bone will be resorbed in this zone. In addition new bone in the bone forming zone will cover the remaining graft trabeculae and increase the bone volume fraction substantially (Astrand and Aspenberg 2002). The remodeling will then lead to an immediate increase in the strength of the subchondral bone, without the transient weakening that normally occurs. Our findings confirm the loaded bone chamber as a valuable tool to investigate the effect of systemic drug treatment on bone metabolism in a non stress-shielded environment. The results are in analogy with other experimental setups aiming to investigate the role of systemic bisphosphonate treatment in ON lesions in joints (Kim 2005, Little 2005, Little 2003).

The reasons for the somewhat diverse results in clinical series, ranging from excellent (Lai 2005) to poor (Meier 2014) can be discussed. It is reasonable to think that treatment with bisphosphonates should be started before, or at the latest when remodeling of the necrotic bone begins. Resorption of the bone matrices supporting the joint surface can then be delayed, which then serves as a scaffold for new bone formation. In an experimental piglet model on hip ON, pre-ON administration of

bisphosphonates was shown to be more effective than administration of the medication after the ON lesion was induced. (Kim 2005). Initiating bisphosphonate treatment before the ON occurs, for obvious reasons is not applicable in the clinical situation but highlights the need for sensitive radiological examination (al-Rowaih 1990, Karantanas 2013, Luk 2010, Stromqvist 1987, Yates 2007) and early diagnosis in patients at risk, or with clinical manifestations of ON. Little is known about type, dose and length of bisphosphonate treatment and it varies markedly in clinical series. Bisphosphonates are anticatabolic drugs preventing bone resorption but do not stimulate bone formation.

At our department unloaded bone chamber studies have shown promising results, combining bisphosphonates with locally administered bone morphogenic protein (BMP), with both an increased bone ingrowth as well as increased bone retention superior to bisphosphonates alone (Belfrage 2012, Harding 2008, Sandhu and Khan 2002). BMPs can, however, not be given systemically. Intermittently administered parathyroid hormone (PTH) is a systemically administered anabolic drug in clinical use for osteoporosis. A combination of the anabolic effect of PTH and the anticatabolic effect of bisphosphonates has shown promising clinical results in osteoporosis treatment (Cosman 2011) and in promoting fracture healing in animal studies (Kuroshima 2014, Li 2012) and could perhaps in the future improve even further the outcome in patients with subchondral osteonecrotic lesions. RANK-ligand antibodies, which besides being more short acting, have also been shown to be more effective than bisphosphonates in experimentally induced ON (Kim 2006). Combinations of drug treatments and surgical procedures like core decompression may offer further improvements in outcome.

Conclusions

- Morbidity after untreated SPONK is substantial with a more than 75 % risk of secondary osteoarthritis and an almost 50/50 chance of surgery with knee prosthesis or high tibial osteotomy. Younger patients have a lower risk for secondary osteoarthritis. Patients with smaller lesions of less than 20 % of the joint surface rarely (none in our study) require major knee surgery whereas patients with lesions of more than 40% almost always do (6/7 in our study).
- Bisphosphonate treatment, alendronate 70 mg once weekly, for a minimum of 6 months seems to reduce the risk of secondary osteoarthritis in patients with SPONK.
- Evaluation of postoperative blood circulation in the femoral head after cervical hip fracture in children and young adults helps predict outcome and guide postoperative treatment regimes. Patients with normal postoperative circulation can be allowed early weight-bearing and return to previous activities. In patients with an avascular femoral head, or with partial avascularity in the subchondral load bearing part of the femoral head, a prolonged period of non weight-bearing and perhaps treatment with bisphosphonates should be considered.
- Bisphosphonates given systemically in an experimental animal model reduce the risk for compression of a non-vascularized bone graft in a loaded bone chamber. This supports the role for bisphosphonates in patients with AVN in load bearing joints.

Future studies

Future clinical studies

SPONK

The obvious future study is a randomized study in patients with SPONK, comparing bisphosphonate treatment with treatment only with NSAID or paracetamol. The groups could be compared regarding development of secondary degenerative changes, functional scores and frequency of surgery with knee arthroplasty. Since some studies have found a correlation with osteoporosis and SPONK (Akamatsu 2012), the study should also include evaluation of bone mineral density.

Cervical hip fractures

Cervical hip fractures in children and young adults are rare. They are on the other hand common in the elderly population. Today, patients over the age of 70 (60) years old are treated with primary hip arthroplasty (Rogmark 2002) if they have a dislocated hip fracture due to the high risk of complications such as non union and AVN. Patients not operated with arthroplasties due to younger age or because the hip fracture is non-displaced, still run a significant risk for AVN and healing complications (Stromqvist 1987). These patients could be evaluated with scintigraphy/SPECT and randomized between bisphosphonates or placebo treatment if the postoperative blood circulation in the femoral head is absent (cold scints). The groups could be compared regarding development of secondary degenerative changes, functional scores and the incidence of hip arthroplasty.

Future animal studies

Animal model, bone chamber

The animal model with the bone chamber allows us to test different therapeutic agents and combination of agents on experimental AVN. Potential drugs are PTH, RANK-ligand antibodies, BMP and bisphosphonates.

Populärvetenskaplig sammanfattning på svenska

Ben är ett levande material som ständigt omsätts och förnyas. Benvävnaden känner av den omgivande miljön och kan anpassa sig till förändringar i det dagliga livet och vid enskild punktbelastning. Precis som andra organ i kroppen kan benet drabbas av skador och sjukdomar men har en unik förmåga att läka helt utan ärrbildning. Ben ersätts med ben. Osteonekros kallas ett tillstånd då benvävnaden inom ett område dör. Om det område av skelettet som drabbas ligger nära ledytan i en vikt bärande led som höft-, knä- eller fotled, kan det få stora konsekvenser. Under läkningen sjunker benet ihop och det utvecklas en artros (ledsvikt). På grund av värk och dålig funktion måste leden så småningom inte sällan opereras med ledprotes.

Orsakerna till osteonekros kan vara flera, till exempel fraktur i nära anslutning till ledyta såsom lårbenshalsbrott, medicinering med kortison, vissa reumatiska sjukdomar, alkoholism, eller dykarsjuka. Ibland vet vi inte orsaken till osteonekros och vi kallar då tillståndet spontan osteonekros.

De kliniska besvären av en osteonekros kan vara kraftig smärta och nedsatt funktion i den drabbade leden. Diagnosen kan ställas tidigt med magnetkamera-undersökning eller scintigrafi (en undersökning där ett svagt radioaktivt ämne spåras i kroppen). Så småningom, men inte alltid, blir förändringen också synlig på vanlig röntgen.

Naturalförloppet av spontan osteonekros i knä undersöktes i den andra av våra studier. Mellan 1982 och 1988 diagnosticerades 40 patienter med osteonekros på ortopediska kliniken i Lund. Patienterna följdes med upprepade röntgenundersökningar och de första resultaten publicerades 1991. Patienterna hade då följts mellan 1 och 7 år. 2012 gick vi igenom dessa 40 patienter och jämförde med det Svenska Knäprotesregistret där alla som opererats med knäprotes under åren registrerats. Vi kontrollerade via journalsystemet också om de genomgått någon annan större knäoperation. 31/40 patienter hade diagnostiserats med artros (ledsvikt) synlig på röntgen i sitt drabbade knä. 17/40 patienter hade blivit opererade med knäprotes (15 st) eller vinkelosteotomi (2st) varvid underbenet under knäleden vinklas om för att minska belastningen på den drabbade delen av ledytan. Vi fann att yngre patienter med osteonekros har bättre prognos än äldre och att stora osteonekros har sämre prognos än små.

Kan bisfosfonater, ett välbeprövat läkemedel mot benskörhet, minska risken att utveckla artros efter osteonekros? I en djurstudie mätte vi effekten av läkemedlet i en modell som ska efterlikna osteonekros, där dött ben får omvandlas till levande ben under samtidig belastning. Vi använde en så kallad benkammare som opereras in på underbenet hos råttor. I benkammaren kan små benbitar utsättas för tryck. När råttorna behandlades med bisfosfonater minskades risken för att benbiten i kammaren skulle tryckas ihop jämfört med råttor som inte fick bisfosfonater. Vi fann att resultaten stöder vår hypotes att bisfosfonater också kan användas i kliniken vid osteonekros i vikt bärande leder.

I den första studien som ingår i denna avhandling behandlade vi 17 patienter med spontan osteonekros i knäleden med en bisfosfonat. Vid en jämförelse med den tidigare obehandlade gruppen i studie 2 (första uppföljningen som presenterades 1991) såg vi att risken för artros minskade med bisfosfonatbehandling.

En fraktur på lårbenshalsen hos barn och ungdomar är ovanligt men det kan inträffa vid högenergiskador som trafikolyckor, fall från höga höjder eller vid utförsåkning på skidor. Frakturen opereras men ofta leder skadan till en alldeles för tidig artros i höften. Vi tror att detta kan bero på att blodförsörjningen till ledhuvudet i höftleden ibland skadas i själva frakturögonblicket. När blodförsörjningen återetableras och nytt ben ska bildas överväger i början de bennedbrytande cellerna och delar eller hela ledhuvudet riskerar att utveckla en osteonekros. De senaste åren har barn och unga vuxna som drabbas av denna fraktur i Lund och Malmö undersökts huruvida det finns adekvat blodcirkulation i ledhuvudet efter operation. I den tredje studien efterundersökte vi hur det gått för dessa patienter. Alla med normal cirkulation läkte fint med bevarat ledhuvud och ingen utveckling av artros. Om hela eller delar av ledhuvudet saknade blodcirkulation fanns risk för osteonekros och utveckling av artros. Unga patienter med höftfraktur kan därför i framtiden delas upp mellan de som har nedsatt cirkulation i ledhuvudet och som bör ha en försiktigare återgång till normala aktiviteter och kanske också läkemedelsbehandling med bisfosfonater och de som har en normal cirkulation och som kan träna igång tidigare.

Acknowledgements

I wish to express my sincere gratitude to:

Magnus Tägil, my mentor. This thesis was made possible by your knowledge, experience and commitment.

Anders Lindstrand, my assistant mentor. The initiator to the original SPONK series.

Mats Geijer. A master in the field of skeletal radiology.

Carl Johan Tiderius, David Roberts and Otto Robertsson. Colleagues and clinical experts in respectively the juvenile hip and the adult knee .

Johan Nilsson, Per Ola Norrman, Per Bosemark, Anna Kajsa Harding and Christian Anker Hansen: My fellow colleagues at the orthopedic trauma section in Lund. I really enjoy working with you guys.

Olle Sammeli and Mathias Wahlborg. For teaching me the skills of orthopedic surgery during my residency at Mora Hospital.

My brother Anders for inspiration

My parents, Anna and Curt. For support and encouragement.

My wife Pernilla and my children Carl and Clara, you know why.

Comparisons in this thesis

Paper I

Hypothesis: Bisphosphonates reduce the risk for future development of OA and reduce the risk for surgery in patients with SPONK.

Method: 17 patients with SPONK were treated with alendronate 70 mg once a week for a minimum of 6 months. The patients were examined after 3 years regarding development of osteoarthritis and frequency of surgery. The results were compared with a previous untreated series of 40 patients.

Results: The 17 bisphosphonate treated patients had significantly ($p < 0,05$) lower risk of developing secondary degenerative changes in radiographs taken at follow up compared to the untreated group. 12% of the patients in the treatment group received knee prostheses compared to 32% in the untreated group (n.s)

Paper II

Hypothesis: What is the life long risk of osteoarthritis and major knee surgery with prosthesis or high tibial osteotomy following SPONK?

Methods: A life long follow-up was made of 40 patients with SPONK diagnosed from 1982-88. In 2012, the patients were matched with the Swedish Knee Arthroplasty register (SKAR) to evaluate the frequency of major knee surgery. The size of the lesion and the age of the patient with regards to outcome were evaluated.

Results: 75% of the patients developed secondary degenerative changes and 17/40 patients have had major knee surgery including arthroplasty or high tibial osteotomy. Younger patients and patients with small ON lesions were at lower risk of major knee surgery ($p < 0,001$).

Paper III

Hypothesis: An evaluation of the postoperative blood circulation in the cervical head after cervical hip fracture in children and young adults helps predict outcome regarding AVN and secondary degenerative changes in the hip joint.

Methods: In 10 children and young adults with cervical hip fracture, follow up radiographs were taken at a minimum of 12 months after surgery. The radiographs

were classified and correlated with the postoperative scintigraphic examinations evaluating the remaining femoral head circulation after surgery. Patients with no remaining circulation in the femoral head after surgery were treated with bisphosphonates and prolonged restricted weight-bearing

Results: 3/3 patients with normal postoperative circulation had normal radiographs at follow up as had 3/4 with partially remaining circulation. 2/3 patients with no postoperative circulation had radiographic changes of ON but only 1 demonstrated bony collapse.

Paper IV

Hypothesis: Bisphosphonate treatment protects an osteochondral bone graft from collapse and maintains the joint architecture during remodeling in a high load environment

Methods: Bone grafts were mounted in a specially designed bone chamber allowing the graft to be mechanically loaded. The chambers were implanted in the proximal tibial bone. Half of the rats were given bisphosphonates and the other half were not. The lengths of the grafts, before surgery and after harvest, were compared to evaluate if bisphosphonates decreased the compression of the graft during remodeling.

Results: Bone grafts treated with bisphosphonates were less likely ($p < 0,03$) to collapse compared to the grafts in untreated rats.

References

- Agarwala S, Jain D, Joshi V R, Sule A. Efficacy of alendronate, a bisphosphonate, in the treatment of AVN of the hip. A prospective open-label study. *Rheumatology* 2005; 44 (3): 352-9.
- Aglietti P, Insall J N, Buzzi R, Deschamps G. Idiopathic osteonecrosis of the knee. Aetiology, prognosis and treatment. *The Journal of bone and joint surgery British volume* 1983; 65 (5): 588-97.
- Ahlback S. Osteoarthritis of the knee. A radiographic investigation. *Acta radiologica: diagnosis* 1968; Suppl 277:7-72.
- Ahlback S, Bauer G C, Bohne W H. Spontaneous osteonecrosis of the knee. *Arthritis and rheumatism* 1968; 11 (6): 705-33.
- Akamatsu Y, Mitsugi N, Hayashi T, Kobayashi H, Saito T. Low bone mineral density is associated with the onset of spontaneous osteonecrosis of the knee. *Acta orthopaedica* 2012; 83 (3): 249-55.
- al-Rowaih A, Bjorkengren A, Egund N, Lindstrand A, Wingstrand H, Thorngren K G. Size of osteonecrosis of the knee. *Clinical orthopaedics and related research* 1993; (287): 68-75.
- al-Rowaih A, Lindstrand A, Bjorkengren A, Wingstrand H, Thorngren K G. Osteonecrosis of the knee. Diagnosis and outcome in 40 patients. *Acta orthopaedica Scandinavica* 1991; 62 (1): 19-23.
- al-Rowaih A, Wingstrand H, Lindstrand A, Bjorkengren A, Thorngren K G, Gustafson T. Three-phase scintimetry in osteonecrosis of the knee. *Acta orthopaedica Scandinavica* 1990; 61 (2): 120-7.
- Aluisio F V, Urbaniak J R. Proximal femur fractures after free vascularized fibular grafting to the hip. *Clinical orthopaedics and related research* 1998; (356): 192-201.
- Aspenberg P, Schilcher J. Atypical femoral fractures, bisphosphonates, and mechanical stress. *Current osteoporosis reports* 2014; 12 (2): 189-93.
- Aspenberg P, Tagil M, Kristensson C, Lidin S. Bone graft proteins influence osteoconduction. A titanium chamber study in rats. *Acta orthopaedica Scandinavica* 1996; 67 (4): 377-82.
- Aspenberg P, van der Vis H. Fluid pressure may cause periprosthetic osteolysis. Particles are not the only thing. *Acta orthopaedica Scandinavica* 1998; 69 (1): 1-4.
- Astrand J, Aspenberg P. Systemic alendronate prevents resorption of necrotic bone during revascularization. A bone chamber study in rats. *BMC musculoskeletal disorders* 2002; 3: 19.

- Astrand J, Harding A K, Aspenberg P, Tagil M. Systemic zoledronate treatment both prevents resorption of allograft bone and increases the retention of new formed bone during revascularization and remodelling. A bone chamber study in rats. *BMC musculoskeletal disorders* 2006; 7: 63.
- Belfrage O, Flivik G, Sundberg M, Kesteris U, Tagil M. Local treatment of cancellous bone grafts with BMP-7 and zoledronate increases both the bone formation rate and bone density: a bone chamber study in rats. *Acta orthopaedica* 2011; 82 (2): 228-33.
- Belfrage O, Isaksson H, Tagil M. Local treatment of a bone graft by soaking in zoledronic acid inhibits bone resorption and bone formation. A bone chamber study in rats. *BMC musculoskeletal disorders* 2012; 13: 240.
- Bjorkengren A G, AlRowaih A, Lindstrand A, Wingstrand H, Thorngren K G, Pettersson H. Spontaneous osteonecrosis of the knee: value of MR imaging in determining prognosis. *AJR American journal of roentgenology* 1990; 154 (2): 331-6.
- Boardman M J, Herman M J, Buck B, Pizzutillo P D. Hip fractures in children. *The Journal of the American Academy of Orthopaedic Surgeons* 2009; 17 (3): 162-73.
- Bradway J K, Morrey B F. The natural history of the silent hip in bilateral atraumatic osteonecrosis. *The Journal of arthroplasty* 1993; 8 (4): 383-7.
- Buckwalter J A, Einhorn T A, O'Keefe R J, American Academy of Orthopaedic Surgeons. *Orthopaedic basic science : foundations of clinical practice*. 3rd ed. American Academy of Orthopaedic Surgeons, Rosemont, IL 2007.
- Canale S T. Traumatic dislocations and fracture-dislocations of the hip in children. *The Hip* 1981: 219-45.
- Canale S T, Bourland W L. Fracture of the neck and intertrochanteric region of the femur in children. *The Journal of bone and joint surgery American volume* 1977; 59 (4): 431-43.
- Canale S T, Campbell W C. *Campbell's operative orthopaedics*. 10th ed. Mosby :, St. Louis 2003.
- Cosman F, Eriksen E F, Recknor C, Miller P D, Guanabens N, Kasperk C, et al. Effects of intravenous zoledronic acid plus subcutaneous teriparatide [rhPTH(1-34)] in postmenopausal osteoporosis. *Journal of bone and mineral research : the official journal of the American Society for Bone and Mineral Research* 2011; 26 (3): 503-11.
- Danielsen C C, Mosekilde L, Svenstrup B. Cortical bone mass, composition, and mechanical properties in female rats in relation to age, long-term ovariectomy, and estrogen substitution. *Calcified tissue international* 1993; 52 (1): 26-33.
- Diliso M F, Noble J S, Bell R H, Noel C R. Postarthroscopic humeral head osteonecrosis treated with reverse total shoulder arthroplasty. *Orthopedics* 2013; 36 (3): e377-80.
- Duany N G, Zywiell M G, McGrath M S, Siddiqui J A, Jones L C, Bonutti P M, et al. Joint-preserving surgical treatment of spontaneous osteonecrosis of the knee. *Archives of orthopaedic and traumatic surgery Archiv fur orthopadische und Unfall-Chirurgie* 2010; 130 (1): 11-6.

- Ehlinger M, Moser T, Adam P, Bierry G, Gangi A, de Mathelin M, et al. Early prediction of femoral head avascular necrosis following neck fracture. *Orthopaedics & traumatology, surgery & research : OTSR* 2011; 97 (1): 79-88.
- Enneking W F, Mindell E R. Observations on massive retrieved human allografts. *The Journal of bone and joint surgery American volume* 1991; 73 (8): 1123-42.
- Ficat R P. Idiopathic bone necrosis of the femoral head. Early diagnosis and treatment. *The Journal of bone and joint surgery British volume* 1985; 67 (1): 3-9.
- Forlin E, Guille J T, Kumar S J, Rhee K J. Complications associated with fracture of the neck of the femur in children. *Journal of pediatric orthopedics* 1992; 12 (4): 503-9.
- Fournier P, Boissier S, Filleur S, Guglielmi J, Cabon F, Colombel M, et al. Bisphosphonates inhibit angiogenesis in vitro and testosterone-stimulated vascular regrowth in the ventral prostate in castrated rats. *Cancer research* 2002; 62 (22): 6538-44.
- Frost H M, Jee W S. On the rat model of human osteopenias and osteoporoses. *Bone and mineral* 1992; 18 (3): 227-36.
- Garrigues G E, Aldridge J M, 3rd, Friend J K, Urbaniak J R. Free Vascularized Fibular Grafting for treatment of osteonecrosis of the femoral head secondary to hip dislocation. *Microsurgery* 2009; 29 (5): 342-5.
- Gross C E, Haughom B, Chahal J, Holmes G B, Jr. Treatments for Avascular Necrosis of the Talus: A Systematic Review. *Foot & ankle specialist* 2014.
- Harding A K, Aspenberg P, Kataoka M, Bylski D, Tagil M. Manipulating the anabolic and catabolic response in bone graft remodeling: synergism by a combination of local BMP-7 and a single systemic dosis of zoledronate. *Journal of orthopaedic research : official publication of the Orthopaedic Research Society* 2008; 26 (9): 1245-9.
- Harrelld K L, Marker D R, Wiesler E R, Shafiq B, Mont M A. Osteonecrosis of the humeral head. *The Journal of the American Academy of Orthopaedic Surgeons* 2009; 17 (6): 345-55.
- Haupt J B, Pritzker K P, Alpert B, Greyson N D, Gross A E. Natural history of spontaneous osteonecrosis of the knee (SONK): a review. *Seminars in arthritis and rheumatism* 1983; 13 (2): 212-27.
- Hurtig M, Pearce S, Warren S, Kalra M, Miniaci A. Arthroscopic mosaic arthroplasty in the equine third carpal bone. *Veterinary surgery : VS* 2001; 30 (3): 228-39.
- Jeppsson C, Astrand J, Tagil M, Aspenberg P. A combination of bisphosphonate and BMP additives in impacted bone allografts. *Acta orthopaedica Scandinavica* 2003; 74 (4): 483-9.
- Jones J P, Jr. Fat embolism, intravascular coagulation, and osteonecrosis. *Clinical orthopaedics and related research* 1993; (292): 294-308.
- Jorgensen P H, Bak B, Andreassen T T. Mechanical properties and biochemical composition of rat cortical femur and tibia after long-term treatment with biosynthetic human growth hormone. *Bone* 1991; 12 (5): 353-9.

- Jureus J, Lindstrand A, Geijer M, Roberts D, Tagil M. Treatment of spontaneous osteonecrosis of the knee (SPONK) by a bisphosphonate. *Acta orthopaedica* 2012; 83 (5): 511-4.
- Jureus J, Lindstrand A, Geijer M, Robertsson O, Tagil M. The natural course of spontaneous osteonecrosis of the knee (SPONK): a 1- to 27-year follow-up of 40 patients. *Acta orthopaedica* 2013; 84 (4): 410-4.
- Kalhor M, Beck M, Huff T W, Ganz R. Capsular and pericapsular contributions to acetabular and femoral head perfusion. *The Journal of bone and joint surgery American volume* 2009; 91 (2): 409-18.
- Kantor H. Bone marrow pressure in osteonecrosis of the femoral condyle (Ahlback's disease). *Archives of orthopaedic and traumatic surgery Archiv fur orthopadische und Unfall-Chirurgie* 1987; 106 (6): 349-52.
- Karantanas A H. Accuracy and limitations of diagnostic methods for avascular necrosis of the hip. *Expert opinion on medical diagnostics* 2013; 7 (2): 179-87.
- Kaushik A, Sankaran B, Varghese M. To study the role of dynamic magnetic resonance imaging in assessing the femoral head vascularity in intracapsular femoral neck fractures. *European journal of radiology* 2010; 75 (3): 364-75.
- Kellgren J H, Lawrence J S. Radiological assessment of osteo-arthritis. *Annals of the rheumatic diseases* 1957; 16 (4): 494-502.
- Khayyeri H, Checa S, Tagil M, Prendergast P J. Corroboration of mechanobiological simulations of tissue differentiation in an in vivo bone chamber using a lattice-modeling approach. *Journal of orthopaedic research : official publication of the Orthopaedic Research Society* 2009; 27 (12): 1659-66.
- Kim H K, Morgan-Bagley S, Kostenuik P. RANKL inhibition: a novel strategy to decrease femoral head deformity after ischemic osteonecrosis. *Journal of bone and mineral research : the official journal of the American Society for Bone and Mineral Research* 2006; 21 (12): 1946-54.
- Kim H K, Randall T S, Bian H, Jenkins J, Garces A, Bauss F. Ibandronate for prevention of femoral head deformity after ischemic necrosis of the capital femoral epiphysis in immature pigs. *The Journal of bone and joint surgery American volume* 2005; 87 (3): 550-7.
- Kim H K, Su P H. Development of flattening and apparent fragmentation following ischemic necrosis of the capital femoral epiphysis in a piglet model. *The Journal of bone and joint surgery American volume* 2002; 84-A (8): 1329-34.
- Knutson K, Robertsson O. The Swedish Knee Arthroplasty Register (www.knee.se). *Acta orthopaedica* 2010; 81 (1): 5-7.
- Koshino T. The treatment of spontaneous osteonecrosis of the knee by high tibial osteotomy with and without bone-grafting or drilling of the lesion. *The Journal of bone and joint surgery American volume* 1982; 64 (1): 47-58.

- Kraenzlin M E, Graf C, Meier C, Kraenzlin C, Friedrich N F. Possible beneficial effect of bisphosphonates in osteonecrosis of the knee. *Knee surgery, sports traumatology, arthroscopy : official journal of the ESSKA* 2010; 18 (12): 1638-44.
- Kuroshima S, Entezami P, McCauley L K, Yamashita J. Early effects of parathyroid hormone on bisphosphonate/steroid-associated compromised osseous wound healing. *Osteoporosis international : a journal established as result of cooperation between the European Foundation for Osteoporosis and the National Osteoporosis Foundation of the USA* 2014; 25 (3): 1141-50.
- Lai K A, Shen W J, Yang C Y, Shao C J, Hsu J T, Lin R M. The use of alendronate to prevent early collapse of the femoral head in patients with nontraumatic osteonecrosis. A randomized clinical study. *The Journal of bone and joint surgery American volume* 2005; 87 (10): 2155-9.
- Li Y F, Zhou C C, Li J H, Luo E, Zhu S S, Feng G, et al. The effects of combined human parathyroid hormone (1-34) and zoledronic acid treatment on fracture healing in osteoporotic rats. *Osteoporosis international : a journal established as result of cooperation between the European Foundation for Osteoporosis and the National Osteoporosis Foundation of the USA* 2012; 23 (4): 1463-74.
- Lin J H. Bisphosphonates: a review of their pharmacokinetic properties. *Bone* 1996; 18 (2): 75-85.
- Little D G, McDonald M, Sharpe I T, Peat R, Williams P, McEvoy T. Zoledronic acid improves femoral head sphericity in a rat model of perthes disease. *Journal of orthopaedic research : official publication of the Orthopaedic Research Society* 2005; 23 (4): 862-8.
- Little D G, Peat R A, McEvoy A, Williams P R, Smith E J, Baldock P A. Zoledronic acid treatment results in retention of femoral head structure after traumatic osteonecrosis in young Wistar rats. *Journal of bone and mineral research : the official journal of the American Society for Bone and Mineral Research* 2003; 18 (11): 2016-22.
- Lotke P A, Abend J A, Ecker M L. The treatment of osteonecrosis of the medial femoral condyle. *Clinical orthopaedics and related research* 1982; (171): 109-16.
- Lotke P A, Ecker M L, Alavi A. Painful knees in older patients: radionuclide diagnosis of possible osteonecrosis with spontaneous resolution. *The Journal of bone and joint surgery American volume* 1977; 59 (5): 617-21.
- Luk W H, Au-Yeung A W, Yang M K. Diagnostic value of SPECT versus SPECT/CT in femoral avascular necrosis: preliminary results. *Nuclear medicine communications* 2010; 31 (11): 958-61.
- Marcheggiani Muccioli G M, Grassi A, Setti S, Filardo G, Zambelli L, Bonanzinga T, et al. Conservative treatment of spontaneous osteonecrosis of the knee in the early stage: pulsed electromagnetic fields therapy. *European journal of radiology* 2013; 82 (3): 530-7.

- Marmor L. Osteonecrosis of the knee. Medial and lateral involvement. *Clinical orthopaedics and related research* 1984; (185): 195-6.
- Meier C, Kraenzlin C, Friederich N F, Wischer T, Grize L, Meier C R, et al. Effect of ibandronate on spontaneous osteonecrosis of the knee: a randomized, double-blind, placebo-controlled trial. *Osteoporosis international : a journal established as result of cooperation between the European Foundation for Osteoporosis and the National Osteoporosis Foundation of the USA* 2014; 25 (1): 359-66.
- Merz W A, Schenk R K. A quantitative histological study on bone formation in human cancellous bone. *Acta anatomica* 1970; 76 (1): 1-15.
- Mitchell D G, Kressel H Y, Arger P H, Dalinka M, Spritzer C E, Steinberg M E. Avascular necrosis of the femoral head: morphologic assessment by MR imaging, with CT correlation. *Radiology* 1986; 161 (3): 739-42.
- Mont M A, Baumgarten K M, Rifai A, Bluemke D A, Jones L C, Hungerford D S. Atraumatic osteonecrosis of the knee. *The Journal of bone and joint surgery American volume* 2000; 82 (9): 1279-90.
- Mont M A, Carbone J J, Fairbank A C. Core decompression versus nonoperative management for osteonecrosis of the hip. *Clinical orthopaedics and related research* 1996; (324): 169-78.
- Mont M A, Marker D R, Zywił M G, Carrino J A. Osteonecrosis of the knee and related conditions. *The Journal of the American Academy of Orthopaedic Surgeons* 2011; 19 (8): 482-94.
- Mont M A, Schon L C, Hungerford M W, Hungerford D S. Avascular necrosis of the talus treated by core decompression. *The Journal of bone and joint surgery British volume* 1996; 78 (5): 827-30.
- Mont M A, Tomek I M, Hungerford D S. Core decompression for avascular necrosis of the distal femur: long term followup. *Clinical orthopaedics and related research* 1997; (334): 124-30.
- Moon E S, Mehlman C T. Risk factors for avascular necrosis after femoral neck fractures in children: 25 Cincinnati cases and meta-analysis of 360 cases. *Journal of orthopaedic trauma* 2006; 20 (5): 323-9.
- Morsy H A. Complications of fracture of the neck of the femur in children. A long-term follow-up study. *Injury* 2001; 32 (1): 45-51.
- Muheim G, Bohne W H. Prognosis in spontaneous osteonecrosis of the knee. Investigation by radionuclide scintimetry and radiography. *The Journal of bone and joint surgery British volume* 1970; 52 (4): 605-12.
- Neyt J G, Weinstein S L, Spratt K F, Dolan L, Morcuende J, Dietz F R, et al. Stulberg classification system for evaluation of Legg-Calve-Perthes disease: intra-rater and inter-rater reliability. *The Journal of bone and joint surgery American volume* 1999; 81 (9): 1209-16.

- Nishii T, Sugano N, Miki H, Hashimoto J, Yoshikawa H. Does alendronate prevent collapse in osteonecrosis of the femoral head? *Clinical orthopaedics and related research* 2006; 443: 273-9.
- Okazaki S, Nagoya S, Tateda K, Katada R, Mizuo K, Watanabe S, et al. Weight bearing does not contribute to the development of osteonecrosis of the femoral head. *International journal of experimental pathology* 2012; 93 (6): 458-62.
- Oner A Y, Aggunlu L, Akpek S, Celik A, Le Roux P, Tali T, et al. Staging of hip avascular necrosis: is there a need for DWI? *Acta radiologica* 2011; 52 (1): 111-4.
- Parks N L, Engh G A. The Ranawat Award. Histology of nine structural bone grafts used in total knee arthroplasty. *Clinical orthopaedics and related research* 1997; (345): 17-23.
- Pringle D, Koob T J, Kim H K. Indentation properties of growing femoral head following ischemic necrosis. *Journal of orthopaedic research : official publication of the Orthopaedic Research Society* 2004; 22 (1): 122-30.
- Ramachandran M, Ward K, Brown R R, Munns C F, Cowell C T, Little D G. Intravenous bisphosphonate therapy for traumatic osteonecrosis of the femoral head in adolescents. *The Journal of bone and joint surgery American volume* 2007; 89 (8): 1727-34.
- Ratliff A H. Fractures of the neck of the femur in children. *The Journal of bone and joint surgery British volume* 1962; 44-B: 528-42.
- Ristow O, Gerngross C, Schwaiger M, Hohlweg-Majert B, Kehl V, Jansen H, et al. Is bone turnover of jawbone and its possible over suppression by bisphosphonates of etiologic importance in pathogenesis of bisphosphonate-related osteonecrosis? *Journal of oral and maxillofacial surgery : official journal of the American Association of Oral and Maxillofacial Surgeons* 2014; 72 (5): 903-10.
- Rogers M J. New insights into the molecular mechanisms of action of bisphosphonates. *Current pharmaceutical design* 2003; 9 (32): 2643-58.
- Rogmark C, Carlsson A, Johnell O, Sernbo I. A prospective randomised trial of internal fixation versus arthroplasty for displaced fractures of the neck of the femur. Functional outcome for 450 patients at two years. *The Journal of bone and joint surgery British volume* 2002; 84 (2): 183-8.
- Roizing P M, Insall J, Bohne W H. Spontaneous osteonecrosis of the knee. *The Journal of bone and joint surgery American volume* 1980; 62 (1): 2-7.
- Russell R G. Bisphosphonates: the first 40 years. *Bone* 2011; 49 (1): 2-19.
- Russell R G, Xia Z, Dunford J E, Oppermann U, Kwaasi A, Hulley P A, et al. Bisphosphonates: an update on mechanisms of action and how these relate to clinical efficacy. *Annals of the New York Academy of Sciences* 2007; 1117: 209-57.
- Sakaia T, Sugano N, Tsuji T, Nishii T, Yoshikawa H, Ohzono K. Serial magnetic resonance imaging in a non-traumatic rabbit osteonecrosis model: an experimental longitudinal study. *Magnetic resonance imaging* 2000; 18 (7): 897-905.

- Sandhu H S, Khan S N. Animal models for preclinical assessment of bone morphogenetic proteins in the spine. *Spine* 2002; 27 (16 Suppl 1): S32-8.
- Satku K, Kumar V P, Chong S M, Thambyah A. The natural history of spontaneous osteonecrosis of the medial tibial plateau. *The Journal of bone and joint surgery British volume* 2003; 85 (7): 983-8.
- Schmalzried T P, Akizuki K H, Fedenko A N, Mirra J. The role of access of joint fluid to bone in periarticular osteolysis. A report of four cases. *The Journal of bone and joint surgery American volume* 1997; 79 (3): 447-52.
- Sharareh B, Schwarzkopf R. Dysbaric Osteonecrosis: A Literature Review of Pathophysiology, Clinical Presentation, and Management. *Clinical journal of sport medicine : official journal of the Canadian Academy of Sport Medicine* 2014.
- Strauss E J, Kang R, Bush-Joseph C, Bach B R, Jr. The diagnosis and management of spontaneous and post-arthroscopy osteonecrosis of the knee. *Bulletin of the NYU hospital for joint diseases* 2011; 69 (4): 320-30.
- Stromqvist B, Hansson L I, Nilsson L T, Thorngren K G. Prognostic precision in postoperative ^{99m}Tc-MDP scintimetry after femoral neck fracture. *Acta orthopaedica Scandinavica* 1987; 58 (5): 494-8.
- Stulberg S D, Cooperman D R, Wallensten R. The natural history of Legg-Calve-Perthes disease. *The Journal of bone and joint surgery American volume* 1981; 63 (7): 1095-108.
- Tagil M, Aspenberg P. Cartilage induction by controlled mechanical stimulation in vivo. *Journal of orthopaedic research : official publication of the Orthopaedic Research Society* 1999; 17 (2): 200-4.
- Tagil M, Astrand J, Westman L, Aspenberg P. Alendronate prevents collapse in mechanically loaded osteochondral grafts: a bone chamber study in rats. *Acta orthopaedica Scandinavica* 2004; 75 (6): 756-61.
- Trueta J. The normal vascular anatomy of the human femoral head during growth. *The Journal of bone and joint surgery British volume* 1957; 39-B (2): 358-94.
- Urbaniak J R, Coogan P G, Gunneson E B, Nunley J A. Treatment of osteonecrosis of the femoral head with free vascularized fibular grafting. A long-term follow-up study of one hundred and three hips. *The Journal of bone and joint surgery American volume* 1995; 77 (5): 681-94.
- Van der Vis H M, Aspenberg P, Marti R K, Tigchelaar W, Van Noorden C J. Fluid pressure causes bone resorption in a rabbit model of prosthetic loosening. *Clinical orthopaedics and related research* 1998; (350): 201-8.
- van Dijk C N, Reilingh M L, Zengerink M, van Bergen C J. The natural history of osteochondral lesions in the ankle. *Instructional course lectures* 2010; 59: 375-86.
- Xu J, Wang X, Toney C B, Seamon J, Cui Q. Blood supply to the chicken femoral head. *Comparative medicine* 2010; 60 (4): 295-9.

- Yamamoto T, Bullough P G. Spontaneous osteonecrosis of the knee: the result of subchondral insufficiency fracture. *The Journal of bone and joint surgery American* volume 2000; 82 (6): 858-66.
- Yates P J, Calder J D, Stranks G J, Conn K S, Peppercorn D, Thomas N P. Early MRI diagnosis and non-surgical management of spontaneous osteonecrosis of the knee. *The Knee* 2007; 14 (2): 112-6.
- Yeranosian M, Horneff J G, Baldwin K, Hosalkar H S. Factors affecting the outcome of fractures of the femoral neck in children and adolescents: a systematic review. *The bone & joint journal* 2013; 95-B (1): 135-42.
- Zywił M G, McGrath M S, Seyler T M, Marker D R, Bonutti P M, Mont M A. Osteonecrosis of the knee: a review of three disorders. *The Orthopedic clinics of North America* 2009; 40 (2): 193-211.