



# LUND UNIVERSITY

## Acute hematogenous osteomyelitis of the neck of the femur in children treated with drilling.

Danielsson, Lars G; Düppe, Henrik

*Published in:*  
Acta Orthopaedica Scandinavica

*DOI:*  
[10.1080/000164702320155310](https://doi.org/10.1080/000164702320155310)

2002

[Link to publication](#)

*Citation for published version (APA):*  
Danielsson, L. G., & Düppe, H. (2002). Acute hematogenous osteomyelitis of the neck of the femur in children treated with drilling. *Acta Orthopaedica Scandinavica*, 73(3), 311-316.  
<https://doi.org/10.1080/000164702320155310>

*Total number of authors:*  
2

### General rights

Unless other specific re-use rights are stated the following general rights apply:  
Copyright and moral rights for the publications made accessible in the public portal are retained by the authors and/or other copyright owners and it is a condition of accessing publications that users recognise and abide by the legal requirements associated with these rights.

- Users may download and print one copy of any publication from the public portal for the purpose of private study or research.
- You may not further distribute the material or use it for any profit-making activity or commercial gain
- You may freely distribute the URL identifying the publication in the public portal

Read more about Creative commons licenses: <https://creativecommons.org/licenses/>

### Take down policy

If you believe that this document breaches copyright please contact us providing details, and we will remove access to the work immediately and investigate your claim.

LUND UNIVERSITY

PO Box 117  
221 00 Lund  
+46 46-222 00 00

# Acute hematogenous osteomyelitis of the neck of the femur in children treated with drilling

Lars G Danielsson and Henrik D ppe

Department of Orthopedics, Malm  University Hospital, SE-205 02 Malm , Sweden. Correspondence: Dr. H D ppe. E-mail: henrik.duppe@orto.mas.lu.se  
Submitted 01-02-03. Accepted 01-10-02

**ABSTRACT** – We re-examined 11 children (mean age 6.5 years) who had been treated with surgical drilling and intravenous (i.v.) antibiotics in high doses for acute hematogenous osteomyelitis of the neck of the femur. The mean follow-up time was 3.9 (2.9–6.4) years.

9 children who had been treated with early surgical drilling and i.v. antibiotics were all symptom-free and had normal radiographs at follow-up. The other 2 children had radiographic changes (metaphyseal rarefaction) already when referred to us. They had been treated with antibiotics alone before referral until the infection had spread to the hip joint. At follow-up, the clinical and radiographical findings were abnormal, 1 had a severely deformed hip.

In our opinion, treatment with i.v. antibiotics alone may not prevent extension of the infectious process to the hip joint in some cases, even when the medication is given in high doses. Therefore, we believe that the addition of early surgical drilling is justified to prevent this feared complication.

The diagnosis of acute hematogenous osteomyelitis in the neck of the femur in children is difficult, especially because the neck is covered by soft tissue. This may make it hard to detect the localized tenderness typical of acute hematogenous osteomyelitis. The intracapsular location and thin periosteum favor penetration of pus into the joint, with a high risk of severely injuring it.

The role of surgery in the treatment of acute hematogenous osteomyelitis has always been controversial. Some authors consider surgery to be essential (Mollan and Piggot 1977, Andersson et al. 1980, Scott et al. 1990), whereas others believe

that early bone decompression is unnecessary and point out that this treatment is based on analysis of patients in whom antibiotic therapy was inadequate by today's standards (LaMont et al. 1987, Vaughan et al. 1987, Peltola et al. 1997). In the special case of acute hematogenous osteomyelitis of the femoral neck, however, even those who are more conservative tend to recommend surgical decompression (Vaughan et al. 1987).

We retrospectively reviewed the results of treatment of a selected group of children with acute hematogenous osteomyelitis of the femoral neck. 9 of 11 children had been treated with early drilling of the neck of the femur.

## Patients and methods

We reviewed the medical records of patients with acute hematogenous osteomyelitis of the neck of the femur, who had received treatment in the Department of Orthopedics of Malm  University Hospital during 1993–1999. To be included, we required the patient to have one or both of the following criteria: (a) aspiration of pus or a positive culture after intramedullary drilling of the femoral neck; (b) a histologic diagnosis of osteomyelitis. During the study no operated patient had a negative culture and/or normal histology. 11 children (8 boys) met our criteria and were included in the study (8 right-, 3 left-sided). Their average age was 6.5 (1–12) years and mean follow-up 3.9 (2.9–6.4) years.

At the time of referral, the children were treated with open drilling from the lateral subtrochanteric region, centrally in the neck of the femur to about

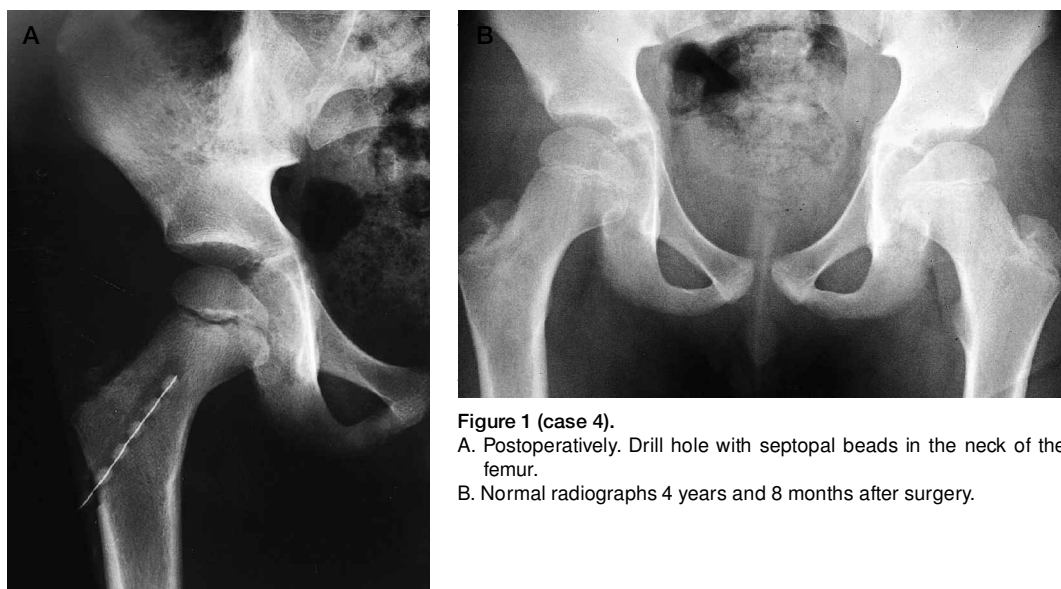


Figure 1 (case 4).

A. Postoperatively. Drill hole with septopal beads in the neck of the femur.

B. Normal radiographs 4 years and 8 months after surgery.

0.5–1 cm from the physis. We used a drill bit with a diameter of 5 mm and its location was checked by means of an image intensifier. A bone biopsy was taken from the neck of the femur. Gentamicin-polymethylmethacrylate (Septopal) beads with a diameter of 3 mm were introduced into the drill hole for local treatment, but also to facilitate drainage of the infected area. The beads were routinely removed after one week. All children were treated with antibiotics. In some cases the treatment had been started before surgery. After surgery, the antibiotics were administered parenterally for 5–14 days, and thereafter orally for 5–12 weeks.

At the follow-up examination, we measured acetabular and center-edge (CE) angles, acetabular head index, the size of the femoral head and the width of the femoral neck and compared the sides. The size of the femoral head was calculated by multiplying the maximal width by the maximal perpendicular height (Danielsson 2000).

### Findings and outcome

A history of a recent upper respiratory infection or otitis media was found in 7 patients, an infected mosquito bite in 1, but 3 children had had no recent infection.

All children presented with pain in the hip and thigh and were limping or unwilling to put weight on the affected leg. They had tenderness in the groin and restricted hip motion.

When admitted to hospital, they had a temperature of  $\geq 38.5$  °C. The white blood count was  $\geq 1.0 \times 10^{10}/L$  in 8 patients and  $\geq 1.3 \times 10^{10}/L$  in 4. In 9 patients we took blood smears, all of which showed a shift to the left. In the 10 patients examined, C-reactive protein was increased ( $> 9$  mg/L) with a mean of 120 (13–236) mg/L.

Conventional radiographs were taken on admission to hospital and at the follow-up. The initial ones were normal in all except 2 patients (cases 10 and 11), in whom a metaphyseal rarefaction was seen. Both of them had had symptoms for 10 and 21 days, respectively, but the others had had symptoms for 1–8 days. 8 children were examined with ultrasound on admission, 1 had an effusion in the hip joint and 2 showed signs of a swollen joint capsule. A technetium bone scan was positive in 4 of the 5 cases investigated.

In 7 patients, blood was taken for cultures, 4 of which showed growth of *Staphylococcus aureus*, the rest were negative. 5 joints were aspirated and 2 of the cultures were positive. Both of these children (cases 10 and 11) had been treated with antibiotics before referral and the osteomyelitis had spread to the joint. An arthrotomy was done and the joint irrigated to remove the pus. The cultures showed *Salmonella* in case 10 and *Staphylococcus aureus* in case 11.

10 were treated by drilling after admission to our clinic. In case 11, metaphyseal rarefaction was not

Table. Observations

A	B	C	D	E	G	H	I	J	K	L	M	N	O	P	Q	R	S	T	X	Y	Z
1	M	1	3.08	3.09	39.8	7.8	+	19,81	20	2,3,4	1	3	1	5	2	1	1,4,6	3	2	1	1
2	M	2	7.04	3.05	38.5	27.9	+	90,128	26	2,3,4	1	2	2	1	1	1	3,4,6	3	1	1	1
3	M	1	12.09	3.07	40.2	20.0	+	13,126	–	1,2,3,4	1	3	1	2	1	1	2,4,6	3	2	1	1
4	M	1	5.07	4.08	40.3	12.8	+	133	–	2,3,4	1	1	2	4	1	1	2,4,6	3	2	1	1
5	F	1	10.09	4.03	39.8	9.1	+	236	105	2,3,4	1	2	2	1	2	1	2,4,6	2	4	1	1
6	M	1	4.07	4.10	40.0	13.0	+	195	45	2,3,4	1	1	1	5	1	1	1,5,8	3	5	1	1
7	F	1	9.03	2.11	39.8	10.6	–	110	–	2,3,4	1	1	2	1	1	1	1,6	3	2	1	1
8	M	1	9.10	2.05	39.0	15.4	+	55	46	2,3,4	1	3	2	3	1	1	3,4,6	3	2	1	1
9	M	1	10.05	4.01	40.4	10.8	+	150	75	2,3,4	1	3	3	1	2	1	1,4,8	3	3	1	1
10	M	2	1.00	6.05	39.8	8.7	+	–	51,102	1,2,3,4	2	2	4	1	3	2	2,7	3	6	2	2
11	F	2	3.03	2.04	39.0	11.6	–	200	–	2,3,4	2	1	3	1	4	3	1,8	1	7	3	3

A Case no.

B Sex

M male,

F female

C Side

1 Right

2 Left

D Age at diagnosis year, month

E Follow-up time year, month

F Initial history

G Temperature °C

H White blood count 10<sup>9</sup>/L

I Neutrophilia

J CRP mg/L

K ESR mm/h

L Clinical signs

1 Refusal to bear weight

2 Limping

3 Tenderness in the groin

4 Restricted range of motion

M Initial radiographs

1 Normal

2 Metaphyseal rarefaction

N Blood culture

1 Not done

2 Negative

3 Staph. aureus

O Ultrasound

1 Not done

2 Normal

3 Joint capsule swollen

4 Effusion

P Bone scan

1 Not done

2 Normal

3 Slightly positive, neck

4 Positive, head

5 Positive, head and neck

Q Aspiration of hip joint

1 Not done

2 Culture negative

3 Salmonella in pus

4 Staph. aureus in pus

R Arthrotomy

1 Not done

2 Pus Salmonella

3 Pus Staph. aureus

S Drilling

1 No pus

2 Pus

3 Fluid with increased pressure

4 Septopal beads 1 week

5 Septopal beads 1 week

(re-exploration after 9 days)

6 Culture negative

7 Salmonella

8 Staph. aureus

T Microscopy

1 Not done

2 Specimen lost

3 Osteomyelitis

U Antibiotics before surgery, see next page

V Antibiotics after surgery, see next page

X Postoperative history

1 Temperature normal after 1 day

2 2 days

3 3 days

4 5 days

5 9 days

6 2 weeks

7 4 weeks

Y Radiography last examination R/L

1 Normal

2 Acetabular angle 12°/15°, CE angle 26°/19°, acetabulum head index 88°/76°, size head 525/765, width neck 26/30

3 Acetabular angle 14°/20°, CE angle 31°/-3°, acetabulum head index 97/51, size head 406/460, width neck 22/33

Z Clinical findings last examination

1 Normal

2 Range of motion hip: Normal, circumference

L thigh –1.5 cm, L calf –1 cm, leg length

ASIS–med. mall. +1 cm

3 Range of motion hip: flexion 0–100°,

abduction 20°, rotation 25°, circumference

L thigh –2 cm, L calf –1 cm, leg length

ASIS–med. mall. –1 cm

Table. continued.

A	F	U	V
1	Chronic otitis. Limping for 3 days. Tenderness in the groin. Range of motion slightly reduced in the hip.	Cloxacillin i.v. 1 day	Cloxacillin + Netilmicin i.v. 1 week Flucloxacillin orally 7 weeks
2	3 days of upper respiratory infection. 1 day of limping.	–	Cefuroxim i.v. 1 week Cefadroxil orally 3 months
3	Mosquito-bite. 1 day of shivering, vomiting, septic fever and hip pain.	–	Cefuroxim + cloxacillin i.v. 1 week Flucloxacillin orally 8 weeks
4	7 days of scarlet fever, pneumonia, septic fever and hip pain.	Fenoxymethyl penicillin orally 1 week Cefuroxim i.v. 1 day	Cefuroxim + Cloxacillin i.v. 1 week Flucloxacillin orally 2 months
5	2 days of hip pain and limping. Cefadroxil orally 6 weeks	Cefotaxim i.v. 2 days	Cefotaxim i.v. 1 week
6	8 days of sore throat, hip pain and limping.	Fenoxymethyl penicillin orally 7 days	Cefuroxim + Cloxacillin i.v. 1 week Flucloxacillin orally 6 weeks
7	2 days of sore throat, 1 day of hip pain and limping.	Cefuroxim i.v. 1 day	Cefuroxim i.v. 5 days Flucloxacillin orally 5 weeks
8	5 days of hip pain, 2 days of severe limping.	Cefuroxim i.v. Cloxacillin i.v. 2 days	Cefuroxim i.v. cloxacillin i.v. 5 days. Flucloxacillin orally 5 weeks
9	3 days of pain in the groin and limping.	–	Cefuroxim i.v. 2 days Netilmicin + cloxacillin i.v. 6 days Flucloxacillin orally 6 weeks
10	Upper respiratory tract infection and a fever for 3 weeks. Ambulatory treatment with erythromycin orally. Admitted paediatric clinic and treated with cefotaxim i.v. 7 days before being referred to orthopedic clinic.	Erythromycin orally 10 days Cefotaxim i.v. 7 days	Cloxacillin i.v. 2 days Cefuroxim i.v. 6 days Trimetoprim-sulfamethoxazol orally 8 weeks
11	10 days of sore throat and limping. Treated ambulatory with fenoxymethyl penicillin orally before being referred to orthopaedic clinic.	Fenoxymethyl penicillin orally 8 days before arthrotomy Cefuroxim i.v. 1 week and cloxacillin i.v. 1 week before drilling	Cefuroxim i.v. 1 week Cloxacillin i.v. 1 week Flucloxacillin orally 3 months

Legends, see previous part of table

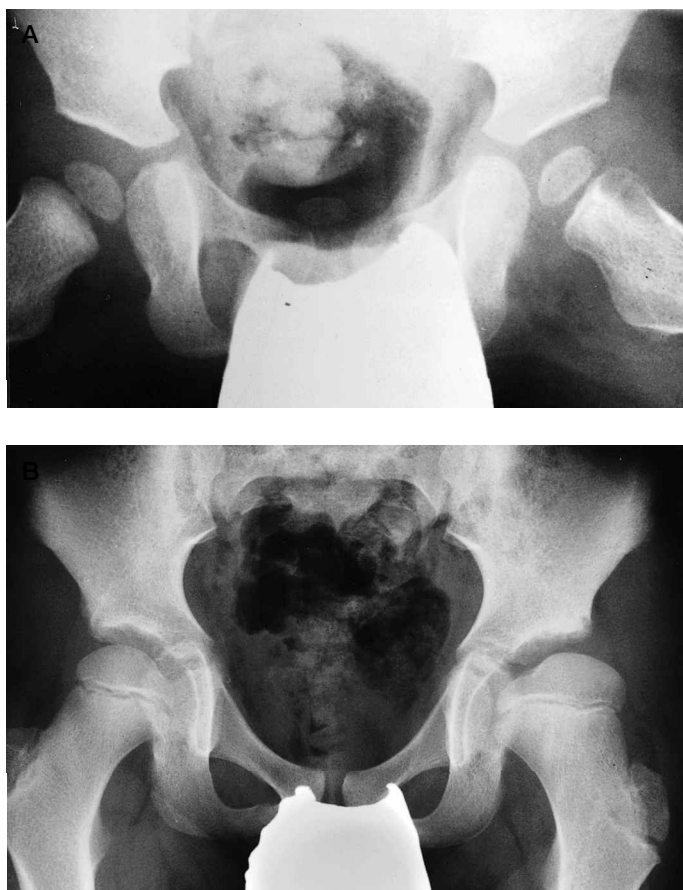detected and the hip was initially treated as a septic arthritis with arthrotomy, irrigation, drainage and intravenous antibiotics. The neck was drilled first 1 week later. Septopal beads were introduced into the drill hole in 8 cases (Figure 1), 1 (case 6) on reoperation after 1 week because of rise in temperature. On drilling, we found pus or seropurulent fluid in 6 cases. Cultures from the drill holes showed *Staphylococcus aureus* in 3 cases and *salmonella* in 1, but on microscopic examination, osteomyelitis was present in all 10 patients.

On reexamination, 9 patients were clinically and radiographically normal (Figure 1). The 2 patients (cases 10 and 11) in whom osteomyelitis had spread into the joint, were clinically and radiographically abnormal (Table, Figures 2 and 3).

## Discussion

Early diagnosis of acute hematogenous osteomyelitis of the neck of the femur is difficult. Signs and symptoms vary considerably. Limping, refusal to bear weight, hip pain, local tenderness and a reduction in the range of motion are found in several other conditions affecting the hip, some of which are commoner than acute hematogenous osteomyelitis. Normal laboratory findings and normal plain radiographs do not exclude acute hematogenous osteomyelitis.

In a survey of the literature, Morrissy (1996) summarized the percentage of normal laboratory findings in acute hematogenous osteomyelitis of the neck of the femur: leukocytes 75, differential



**Figure 2 (case 10).**

- A. Boy, 12 months old. Treated with antibiotics for 17 days. Metaphyseal rarefaction in the left femoral neck.
- B. 6 years and 5 months after surgery. The femoral head and neck are enlarged and the CE angle, acetabulum angle and acetabulum head index are abnormal.

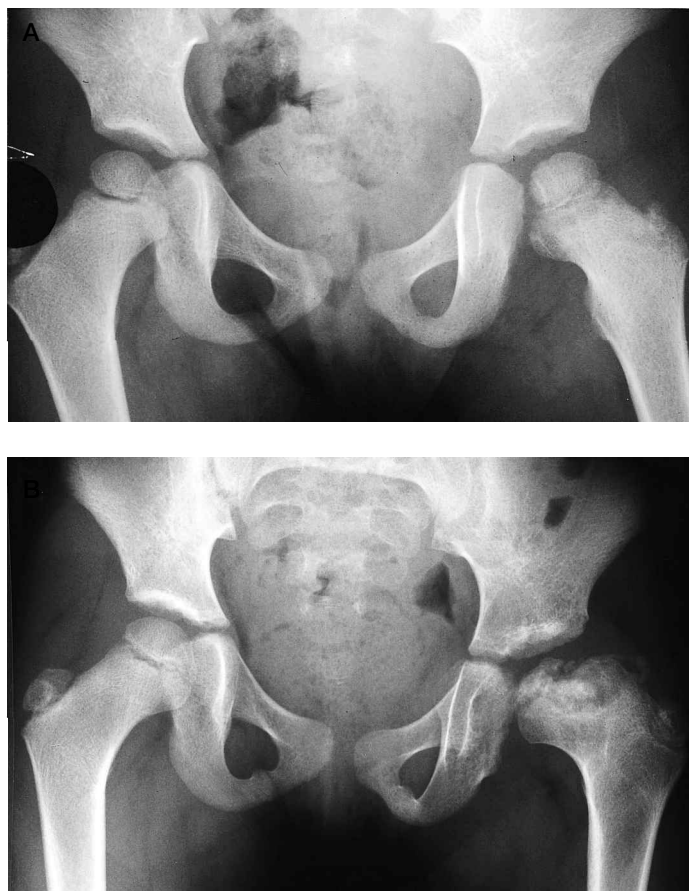
count 35, ESR 8, CRP 2, blood culture 50–73, culture from needle aspiration of bone 27–60 (slightly lower with an open biopsy). In our study, some children presented with normal white blood counts, normal blood smears, and negative cultures from blood and bone biopsies. Bone scans were also normal. However, on admission, all our children had a temperature of  $\geq 38.5$  °C, CRP  $\geq 9$  mg/L and ESR  $\geq 20$  mm/h, findings similar to those reported by Morrissy (1996). However, compared with reports on acute hematogenous osteomyelitis in other locations, our findings indicate that patients with acute osteomyelitis of the hip are usually diagnosed later than those with the disease in other locations (Dahl et al. 1998).

The dangers of closed management of acute hematogenous osteomyelitis of the femoral neck are illustrated by 2 of our cases (10 and 11) who were treated with oral or oral and i.v. antibiotics before surgery. Radiographic changes with a metaphyseal rarefaction were found and extension of the disease into the joint. Surgical debridement, including arthrotomy and drilling of the femoral neck with introduction of Septopal beads into the drill hole combined with continued i.v. antibiotic treatment, resulted in normalization of the temperature and laboratory findings. Both of these cases, however, had abnormal clinical findings and radiographs at follow-up unlike all our other patients who were treated with early surgical drilling, and were clinically and radiographically normal when re-examined.

Early drilling lower the intra-osseous pressure, thereby arresting the progression of the infection/pressure/necrosis chain of events. With this minor surgical procedure we can take adequate bone biopsy cultures.

It also prevents spread of the infection into the joint and, together with adequate antibiotic treatment, will result in a normal hip. We therefore believe that drilling is warranted in some cases in whom intravenous antibiotics might have cured the acute hematogenous osteomyelitis, rather than cases to run the risk of a perforation into the joint with a great likelihood of destruction of the joint. If osteomyelitis has spread to the hip joint, we believe that an arthrotomy should be done together with drilling of the femoral neck.

In one of our cases, in whom drilling was performed, the child's body temperature did not normalize until the drill hole was re-explored and Septopal beads introduced. This would suggest that Septopal beads, apart from their local antibi-



**Figure 3 (case 11).**

- A. Girl, 3 years and 3 months old. On admission after 8 days of oral treatment with fenoxymethyl penicillin. Slight metaphyseal rarefaction in the left femoral neck. Joint space increased. Femur in flexion, abduction and external rotation.
- B. 2 years and 4 months after surgery. The femoral head is necrotic and subluxated and the physis is destroyed. The femoral neck is short and broad and the CE angle, acetabulum angle and acetabulum head index are abnormal.

otic effect, may also help drain the drill hole and thereby maintain a beneficial reduction in intra-osseous pressure in the femoral neck.

In conclusion, we believe that acute hematogenous osteomyelitis of the neck of the femur is a

medical emergency that needs to be treated aggressively with surgical drilling and adequate antibiotic therapy to avoid permanent damage to the hip.

No funds have been received to support this study.

Andersson J R, Orr J D, Maclean D A, Scobie W G. Acute haematogenous osteitis. *Arch Dis Child* 1980; 55 (12): 953-7.

Dahl L B, Hoyland A, Dramsdahl H, Kaaresen P I. Acute osteomyelitis in children: a population-based retrospective study 1965 to 1994. *Scand J Infect Dis* 1998; 30: 573-7.

Danielsson L. Late-diagnosed DDH. A prospective 11-year follow-up of 71 consecutive patients (75 hips). *Acta Orthop Scand* 2000; 71: 232-42.

LaMont R L, Andersson P A, Dajani A S, Thiumoorthi M C. Acute hematogenous osteomyelitis in children. *J Pediatr Orthop* 1987; 7: 579-3.

Mollan R A, Piggot J. Acute osteomyelitis in children. *J Bone Joint Surg (Br)* 1977; 59 (1): 2-7.

Morrissy R T. Bone and joint sepsis. In: Lovell and Winter's Pediatric Orthopaedics (Ed. Morrissy R T). Lippincott-Raven, Philadelphia, New York 1996: 587-8.

Peltola H, Unkila-Kallio L, Kallio M J T. Simplified treatment of acute staphylococcal osteomyelitis of childhood. *Pediatrics* 1997; 99: 846-50.

Scott R J, Christofersen M R, Robertson Jr W W, Davidson R S, Rankin, L, Drummond D S. Acute osteomyelitis in children: A review of 116 cases. *J Pediatr Orthop* 1990; 10: 649-52.

Vaughan P A, Newman N M, Rosman M A. Acute hematogenous osteomyelitis in children. *J Pediatr Orthop* 1987; 7: 652-5.