Percutaneous arthrodesis.

Lauge-Pedersen, Henrik

Published in:
Acta Orthopaedica Scandinavica. Supplementum

DOI:
10.1080/03008820310014109

2003

From the Orthopedic Research Laboratory,
Department of Orthopedics,
Lund University Hospital,
LUND, Sweden

Percutaneous arthrodesis

Henrik Lauge-Pedersen

Thesis 2002

ACTA ORTHOPAEDICA SCANDINAVICA SUPPLEMENTUM NO. 307, VOL. 74, 2003

Cover illustration by Per Aspenberg
Printed in Sweden
Wallin & Dalholm, Lund
2002

Contents

List of Papers

This thesis is based on the following papers:

1. Lauge-Pedersen H, Odenbring S, Knutson K, Rydholm U.
   High failure with the dowel technique for fusion of rheumatoid ankles
   Foot 1998; 8: 147-9.

2. Lauge-Pedersen H, Knutson K, Rydholm U.
   Percutaneous ankle arthrodesis in the rheumatoid patient without debridement of the joint.
   Foot 1998; 8: 226-9.

3. Lauge-Pedersen H, Aspenberg P, Ryd L, Tanner K E.
   Arch-shaped versus flat arthrodesis of the ankle joint: strength measurements using synthetic cancellous bone.
   Proc Instn Mech Engrs Part H: J Engineering in Medicine 2002; 216(1): 43-9.

4. Vázquez A A, Lauge-Pedersen H, Lidgren L, Taylor M
   Finite Element Analysis of the initial stability of ankle arthrodesis with internal fixation. Flat cut versus intact joint contours.
   Clin Biomechanics, conditionally accepted.

5. Lauge-Pedersen H and Aspenberg P.
   Arthrodesis by percutaneous fixation. Patello-femoral arthrodesis in rabbits without debridement of the joint.
   Acta Orthop Scand 2002; 73(2): 186-189.

6. Lauge-Pedersen H and Aspenberg P.
   Percutaneous arthrodesis without cartilage removal—why does it work?
   Submitted.

7. Lauge-Pedersen H, Eneroth M, Aspenberg P.
   Percutaneous arthrodesis in Hallux rigidus
   Submitted.

Thesis at a glance

Question	Species	Method	Answer
Is the dowel technique to be recommended in the rheumatoid ankle?	Man	Clinical and radiographic follow-up	No
Is percutaneous arthrodesis an option in the rheumatoid ankle?	Man	Clinical and radiographic follow-up	Yes
Is the shape of the bone surfaces important for stability?	–	Biomechanical model	Yes
Is shape and placement of screws important for stability?	–	FEM	Yes
Can a healthy joint fuse merely by percutaneous fixation?	Rabbit	Patello-femoral arthrodesis	Yes
Is synovial depletion crucial for cartilage destruction?	Rabbit	Cartilage isolation implant	Yes
Is fusion possible in hallux rigidus merely by percutaneous fixation?	Man	Clinical and radiographic follow -up	Yes

Introduction

Clinical background

Arthrodesis is performed when joint motion produces severe pain or if instability cannot be controlled. Ankle arthrodesis is probably still the safest method of treating a painful destroyed ankle in patients with rheumatoid arthritis or osteoarthritis with significant symptoms that do not respond to conservative treatment. Recent clinical studies (Saltzman 2000, Easley et al. 2002) have shown promising results with total ankle arthroplasty, especially concerning newer prosthesis designs (mobile bearing implant). The indications for total ankle replacement, however, are still unclear.

A variety of arthrodesis techniques have been described, varying in surgical approach, use of bone graft, type and duration of fixation. The multitude of techniques described probably reflects the difficulties of fusing the small area of contact between tibia and talus which is subjected to high stresses by the lever arm of the foot. Whether internal or external compression techniques are used, it has generally been accepted that resection of remaining cartilage, and at least some of the subchondral bone, is essential for fusion. Normally the joint surfaces are resected to produce flat osteotomy surfaces that are easy to fit together, encouraging healing to occur. Open surgery is therefore the most common method. Percutaneous techniques with partial or total preservation of the ankle contour such as dowel arthrodesis (Ottolenghi et al. 1970, Baciu 1986) and arthroscopically assisted ankle arthrodesis (Jerosch et al. 1996, Cameron et al. 2000) have also been described. These methods can only be used in ankles with normal or at least functional alignment.

As various techniques have been used for patients with different diagnoses a comparison of the studies is difficult. The chance of achieving fusion in a rheumatoid joint may differ from that of an osteoarthritic joint due to different risk of infection and different bone quality. In recent years, internal compression fixation techniques have been recommended because of higher fusion rates, fewer complications, shorter fusion times and better clinical outcome than the external compression techniques (Table 1).

Complications associated with ankle arthrodesis include infection, wound-healing problems, fracture, neurovascular injury, malunion and nonunion. Long-term complications include secondary arthrosis of the subtalar joints (Morrey et al. 1980, Demetriades et al. 1998, Thermann et al. 1999).

Clinical outcome

There is no standard scoring system for assessing the functional outcome of ankle fusion (Abidi et al. 2000), although the Mazur ankle grading system (Mazur et al. 1979) has been frequently used. Several recent studies have applied the AOFAS Ankle and Hindfoot Rating scale to evaluate the clinical results (Kitaoka 1994, Mann et al. 1998, Monroe et al. 1999). These functional scores are primarily devised for single-joint disease, and the use of them in evaluation of patients with rheumatoid disease is questionable, as will be discussed later.

Arthrodesis and stability

The stability of the fixation is an important factor in determining success or failure. Different methods of stabilizing the joint have been studied biomechanically. In a study comparing external compression arthrodesis and internal arthrodesis with two screws, internal fixation was found to be superior in dorsiflexion/plantarflexion, but mixed results were obtained for internal/external rotational stresses (Thordarson et al. 1992). In another study the same authors compared internal fixation with and without addition of a fibular strut graft (Thordarson et al. 1990), arthrodesis with fibular strut graft proved to be more stable. In both these studies the joint contour was saved, but the articular cartilage was removed. In another biome-

Table 1. Literature survey of ankle arthrodesis

Author	Diagnosis	Technique	Number of patients	Mean follow-up (years)	Clinical outcome	Fusion rate (%)	Time to fusion (weeks)
Iwata et al. 1980	RA	Internal fixation, fibula garft	10	5	100 [c]	100	6
McGuire et al. 1988	RA[a], OA[a]	External fixation and bone graft	18	3	94 [a]	67	28
Sowaet al. 1989	RA, OA	Internal fixation with compression plate	17	4	85 [b]	94	16
Smith et al. 1990	RA	Charnley compression	11	5	91[b]	82	–
Dennis et al. 1990	Mainly RA [a], OA [a]	Internal fixation	16	1.5	80 [a]	94	10
Carrier et al. 1991	RA	Steinmann pins	5	6	–	100	40
Holt et al. 1991	Mainly RA, OA	Internal fixation	23	2	–	74	16
Moran et al. 1991	RA [a]	Various (external fixation)	30	5	61 [b]	60	–
Maurer et al. 1991		Internal	35	2	–	100	–
		External	8	2	–	82	–
Stone et al. 1991	Mainly RA, OA	Internal (Triffin nail)	18	2–10	–	95	–
Turan et al. 1991	RA	Internal with screws and staples	7	4	–	100	12
Cracchiolo et al. 1992	RA	External	19	3	63 [c]	78	20
		Internal	13	3	78 [c]	77	16
Stranks et al 1994	Mainly RA, OA	Dowel and internal fixation	20	2	70 [b]	95	12.5
Turan et al. 1995	RA	Arthroscopic assisted with screws	10	1	100 [c]	100	12
Dohm et al. 1994	Mainly RA, OA	Various	37	–	–	65	11–20
Chen et al. 1996	Mainly OA	Internal fixation	40	4	90 [c]	95	12
Pfahler et al. 1996	OA	Internal	14	3.5	80 [c]	95	11
		External	7	3.5			17
Dereymaeker et al. 1998	RA	Internal and external fixation	14	3.5	86 [c]	64	18
Mann and Rongstad 1998	OA	Internal fixation	81	3	74 [d]	88	13.8
Felix et al. 1998	RA	Internal and external	24	5	–	96	–
Monroe et al. 1999	OA	Internal fixation	29	2	81 [d]	93	9
O'Brien et al. 1999	(OA)	Internal (arthroscopic assisted)	36	–	–	83	–
Thermann et al. 1999	(OA)	Internal	28	7.5	70 [c]	–	–
		External	22	7.5	55 [c]	–	–
Colgrovc and Bruffey 2001	Mainly OA	Combined external and internal	26	4.5	–	100	10.3

[a]Including re-arthrodesis. [b]Mazur score. [c]Percent excellent and good results. [d]AOFAS Ankle and Hindfoot Rating Scale.

chanical study, crossed screws provided more rigid fixation than parallel screws especially when subjected to torsional stresses (Friedman et al. 1994). The Charnley external fixator was compared with the fibular strut fusion and the T-plate when using parallel saw cuts to prepare the joint surfaces (Scranton et al. 1980). The T-plate was found to be more stable than the external fixator with respect to external rotation and plantar flexion, but not to anterior shear. Arthrodesis with a fibular strut graft was inferior to both the above-mentioned techniques. Three screws proved more resistant to torque than did arthrodesis with two screws (Ogilvie-Harris et al. 1994). This study also used flat cut surfaces to prepare the joint.

The first study to compare the influence of the shape of the arthrodesis joint contour was that of Miller et al. (2000). They used four pairs of cadaveric bone and compared stability between an arthrodesis with the preserved joint contour

Table 2. Literature survey of biomechanical studies performed on ankle arthrodesis

Author	Comparison	Applied forces	Joint preparation	Conclusion
Scranton et al. 1980	Charnley external fixator versus fibular strut fusion versus T-plate	ER, PF, PA	Flat cut	T-plate the most stable
Thordarson et al. 1990	Internal fixation with and without fibular strut graft	IR–ER, PF–DF, M–L	Intact ankle contour	Fibular strut graft the most stable
Thordarson et al. 1992	External fixation versus internal fixation	IR–ER, PF–DF, M–L	Intact ankle contour	Internal fixation the most stable in PF–DF, mixed results with IR–ER
Pilette et al. 1993	Charnley external fixator versus crossed screws versus T-plate	IR, DF, PA	Flat cut	T–plate more stable than crossed screws more stable than T–plate
Dohm et al. 1994	T-plate versus fibular strut graft versus crossed screws	DF	Flat cut	T–plate the most stable
Ogilvie-Harris et al. 1994	Three screw versus two screws	Torque	Flat cut	Three screws better than two screws
Friedman et al. 1994	Crossed screws versus parallel screw	IR–ER, PF–DF M–L	Flat cut	Crossed screw more stable than parallel screws
Berman et al. 1999	Triangular external frame versus compression-only frame	IR–ER, DF	Flat cut	Triangular frame the most stable
Miller et al. 2000	Intact joint contour versus resected	IR–ER [a] PF–DF [a]	Intact and resected	Equal
Nasson et al. 2001	Crossed screws versus blade plate	IR–ER, PF, M–L	Flat cut	Crossed screws more stable than blade plate

IR=internal rotation, ER=external rotation, PF=plantar flexion, DF=dorsiflexion, M–L= medial–lateral bending,
[a] Cyclic loading.

and an arthrodesis with parallel saw cuts. They found the preserved contour to yield better stability, but as this was not statistically significant, they concluded that both methods could be biomechanically sound (Table 2).

These studies all measured gross relative movements between the tibia and the talus. The arthrodesis constructs were tested with various torques and bending forces, but the amount of motion taking place at the fusion site was not evaluated.

There are several ways to measure stability. Strength and stiffness can be measured by testing the arthrodesis construct to failure. Fatigue testing can be performed testing the construct with cyclic loading, and relative motions at the fusion site could be addressed. The relative micromovements at the fusion site may be related to the success or failure of fusion (Boden et al. 1995), but no threshold level of motion for ankle fusion exists in the literature.

There is no consensus as to which method is correct for evaluating stability or which method best describes how an arthrodesis is likely to fail.

Although tibial torque and subsequent flexion-extension are presumed to be the most likely force to affect the ankle postoperatively in a short leg cast (Thordarson et al. 1992) it has not been proven which forces are actually clinically relevant.

Testing cadaveric bone has obvious advantages. Using paired cadaver specimens is even more advantageous, but the limited amounts commonly available make it sometimes necessary to do different tests subsequently in the same specimen. Synthetic bone (Sawbone®) has the advantage of being consistent in mechanical properties, and the amount of testing material is unlimited. The obvious disadvantage is that the mechanical properties may differ from that of real bone.

Finite element modeling

According to a description by Ana Alonso Vázquez (2001) the mathematical formulation of a physical process leads to a set of differential equations and boundary conditions relating the quantities

that characterize it. This mathematical model can be evaluated using computed-assisted numerical methods in order to estimate the characteristics of the physical process. As the exact solution of the equations is often an enormous task and not always possible, approximate methods of analysis are an alternative way to find solutions. This is the case of the finite element method. In finite element modeling, the original complex physical problem being analyzed is represented as a collection of simple discrete parts, the finite elements. The finite elements are connected to each other at points called nodes. The method approximates the solution over each element, deriving approximation functions in terms of the values of the solution at the nodes of the element. In the case of mechanical analysis, the forces and displacements at the nodes of an element, are related by the stiffness matrix of this element.

Since 1972, finite element models have been used in orthopaedic biomechanics to assess the mechanical behavior of different human tissues and structures. Since then, this method has been applied to the stress analyses of bone and bone-prosthesis structures, fracture fixation devices and bone remodeling (Huiskes et al. 1983, Prendergast 1997).

Finite element analyses of the mechanical behavior of ankle arthrodesis have never been reported. Neither have the actual micromotions taking place at the fusion site been addressed earlier.

The role of cartilage in arthrodesis

The Gallie ankle arthrodesis technique was described in 1948 (Gallie). The operation is performed through two anterior incisions with anterior grafts countersunk into the medial and lateral side of the ankle joint without cartilage removal. In 1960, Kennedy described a modification of this technique (1960). The operation differed in three respects from Gallie's original technique: 1) a staple was used; 2) refrigerated bone was employed; and 3) adjacent cartilage was removed. Kennedy writes in his article: " I am quite certain that Dr. Gallie would have disapproved of all three changes" and "the third change—the removal of articular cartilage—is the most debatable and perhaps complicates the procedure more than necessary".

Gallie had observed that the articular cartilage covering the weight-bearing surfaces gradually thinned out and collapsed, allowing the growth of bone from tibia to the talus.

Cartilage can be viewed as a composite containing aggrecan and a fibrillar network, consisting of collagen, and of attached, cross-bridging and linking noncollagenous and collagenous matrix proteins. In both rheumatoid arthritis and osteoarthritis, the normal balance between breakdown and replacement of the matrix constituents is disturbed. A typical finding in these diseases is loss of aggrecan. One function of aggrecan is to help create an osmotic environment that retains water, which gives the cartilage its unique qualities in resisting compression and distributing load (Heinegard et al. 2001). The primary cause of cartilage and bone destruction involves elevated levels of active proteases, secreted from both chondrocytes and the synovial cells. The process is, however, very complicated and although 25 different MMPs (matrix metalloproteinases) have been detected, many of them have not been characterized in relation to arthritic diseases. In the future, antiMMP agents may have a role in the therapies (Murphy et al. 2002), but so far no synthetic MMP inhibitor is available for clinical use.

Nutrition of the articular cartilage is depending on diffusion of soluble nutrients. It is assumed that synovial fluid are the only source of nutrients in adult animals and human beings and that the subchondral bone plate is not permeable (Maroudas et al. 1968, Hodge et al. 1969, Ogata et al. 1978). However, studies that support a subchondral route is also available (Mital et al. 1970, Lane et al. 1977, Mazhuga 1999). Malinin and Ouellette (2000) have shown that in baboon cartilage obstruction of the subchondral route by methyl-methacrylate resulted in late degeneration of the cartilage after 5–12 months. This result may support the theory that changes in the subchondral bone are the precursors of osteoarthritis (Imhof et al. 1999). However, these results also imply that the synovial fluid alone can be responsible for survival of the cartilage for a longer period of time. Nutrient transport is also sometimes thought to be assisted by movement of fluid in and out of

cartilage in response to cyclic loading of the tissue (O'Hara et al. 1990).

The deleterious effects of immobilization on cartilage have been demonstrated in numerous studies (Hong 1996, Jortikka et al. 1997, Fu et al. 1998, Vanwanseele et al. 2002). The resulting changes are similar to those seen in osteoarthritis. The limited capacity of the cartilage to heal and the negative effect of immobilization led Salter to the concept of continuous passive motion (Salter 1996). Moreover, the histological lesions produced by compression are similar to those seen in osteoarthritis (Gritzka et al. 1973).

In a percutaneous arthrodesis with remaining cartilage covering the articular surfaces, the cartilage is under compression and depleted of the synovial fluid in the contact areas. In addition the joint is immobilized, as no cyclic mechanical stimulation is present. In rheumatoid and osteoarthritic joints the cartilage is already degenerated. The chances for survival of the cartilage under such circumstances are thus limited.

The role of compression in arthrodesis

It is well accepted that bony co-adaptation, compression and rigid fixation are essential to achieve fusion. These three phenomena are related, but in a complex way. The effects of compression in arthrodesis are increased bony co-adaptation and increased stability. On the other hand, high levels of compression in osteoporotic bone could result in compaction or perhaps resorption at the arthrodesis interface, thus reducing stability.

Key stated that pressure enhanced fusion (Key 1932). In Charnley's original work compression was a method to increase the stability in arthrodesis (Charnley 1951). The optimal magnitude of compression in ankle arthrodesis has not been established. In a study based on 10 patients, knee arthrodesis with a compression of 500 N required daily adjustment and resulted in a small but significant loss of length. 200 N was suggested as a sufficient compression to obtain fusion without significant loss of bone length (Cunningham et al. 1989). An external fixator gives the opportunity to adjust the amount of compression in the arthrodesis, with internal fixation this is not possible, and the amount of compression will decrease over time. The external compression techniques have, on the other hand, not proved superior in respect of fusion rates compared to the internal compression techniques. Absence of compression may be associated with instability and may not permit close apposition of the bone ends. In a study comparing internal non-compression ankle arthrodesis with internal compression ankle arthrodesis, the latter was found superior in respect of fusion time (Fu et al. 1999).

Bone repair response

The mechanism behind fusion of percutaneous arthrodesis with remaining cartilage covering the articular surfaces may differ from that of a resection arthrodesis. It is, however, likely that the fusion mechanism in both resembles so- called secondary bone healing in several respects. In secondary bone healing, an intermediate connective tissue or fibrocartilage is initially formed within the fracture gap and secondarily replaced by bone. Radiographic characteristics are callus formation, temporary widening of the fracture gap by osteoblastic resorption, and a relatively slow disappearance of the radiolucent fracture line caused by fibrocartilage mineralization and bone formation. Heppenstall's (1980) classification divides fracture repair into a series of six stages including: 1) impaction, 2) induction, 3) inflammation, 4) soft callus, 5) hard callus, 6) remodeling (Table 3). The first stage can be compared to the surgical trauma. Induction of osteogenic precursor cells is a necessity and bone morphogenic protein (BMP) is likely to be involved in the healing process of an arthrodesis. The principle of a bone morphogenic substance was described by Levander (1938) and later demonstrated by Marshall Urist (1965). Since then more than a dozen related BMP's have been discovered (Mont et al. 1998). In animal and in vitro experiments, the response of BMP-containing implants, resemble the sequence of events observed during endochondral bone formation in embryogenesis (Reddi et al. 1972). Cells condense and proliferate around the BMP-implant and produce a cartilaginous matrix. The cartilage cells hypertrophy and are replaced by bone.

Table 3. Stages of secondary bone healing (adapted from Heppenstall (1980)

Stages of secondary bone healing		Time	Characteristics
Stage 1	Impaction	Instantly	Disruption of cortical and cancellous bone
Stage 2	Induction	Immediately after impaction	BMP. Induction of osteoprogenitor cells
Stage 3	Inflammation	From minutes to days	Inflammatory cells. TGF-ß, PDGF
Stage 4	Soft callus	Days	Granulation tissue –> fibrocartilage –> mineralization
Stage 5	Hard callus	Days to weeks	Cartilaginous callus –> woven bone
Stage 6	Remodelling	Months to years	Building and resorption

Once the osteogenic precursor cells have been recruited to the fracture site, they differentiate. There are several theories as to how these cells develop to bone-producing osteoblast. One theory is that the hypoxic, acidic environment following disruption of the blood supply may be responsible for mesenchymal cells transforming into chondroblasts (Heppenstall 1980). Other theories are based on the assumption that mechanical forces may control tissue differentiation; tensile forces determine connective tissue formation, whereas pressure causes differentiation of mesenchymal cells into chondrocytes (Pauwels 1960).

The next phase of bone healing is the inflammatory phase. In an arthrodesis this stage would correspond to the first postoperative days. Inflammatory cells (granulocytes, macrophages and lymfocytes) are part of the fracture-healing response and are present from the earliest stages of the fracture hematoma. These inflammatory cells secrete cytokines that may be important in regulating the early events in the fracture-healing process (Einhorn et al. 1995). The platelets release the signal molecules TGF-β and PDGF that are important in regulating cell proliferation and differentiation of mesenchymal stem cells (Bolander 1984).

Callus formation is the consequence of capillaries and pluripotent mesenchymal cells invading the fibrin scaffold provided by the hematoma. The initial callus is soft, and consists of granulation tissue, which is eventually replaced by fibrocartilage. The fibrocartilage becomes mineralized which is necessary for endochondral ossification to occur. The fibrocartilage then becomes resorbed by chondroclasts and is replaced by woven bone. The last stage is remodeling and involves the resorption of woven bone by osteoclasts and the replacement with lamellar bone by osteoblasts. This process appears to be regulated by mechanical stimulus (Wolff 1892).

Summary of papers

Evolvement of the thesis

While working with the rheumatoid foot I concentrated my research on various aspects of the forefoot, until we stumbled over a case in which the ankle fused unexpectedly, after we had placed some screws across the joint in a rather desperate attempt to diminish pain at least for some time. The patient had a history of septic arthritis and open surgery was regarded as too risky. At the same time, we had disappointing results with an arthrodesis technique using bone dowels, but no device for stabilization. These clinical observations raised several questions that made me change focus to the arthrodesis problem. I started several studies with relation to arthrodesis, all of which are not completed. One of the basic questions that emerged was: how important is stability versus the biological composition of the tissue surfaces brought together? This question is not possible to answer in a strict scientific way, but various aspects of it are addressed in the following papers.

Paper 1. High failure with the dowel technique for fusion of rheumatoid ankles

12 patients (12 ankles) with rheumatoid arthritis were operated on with the dowel technique described by Baciu (1986). One patient had a fixed valgus deformity of the ankle of approximately 15 degrees. In all the other patients the ankle could be reduced to a functional position.

With an image intensifier and the patient supine a Kirchner wire was introduced from the middle of the base of the medial malleolus through the joint space of the ankle and through the lateral malleolus. A 5-cm long vertical skin incision was made centered over the Kirchner wire. The periosteum was freed from the bone and the milling cutter was progressively passed through the medial malleolus, the distal end of the tibia and proximal surface of the talus, and the distal tibiofibular joint to the medial portion of the lateral malleolus, leaving its lateral cortex intact (Figure 1). The cylindrical bone graft was expelled from the cutter. It was then

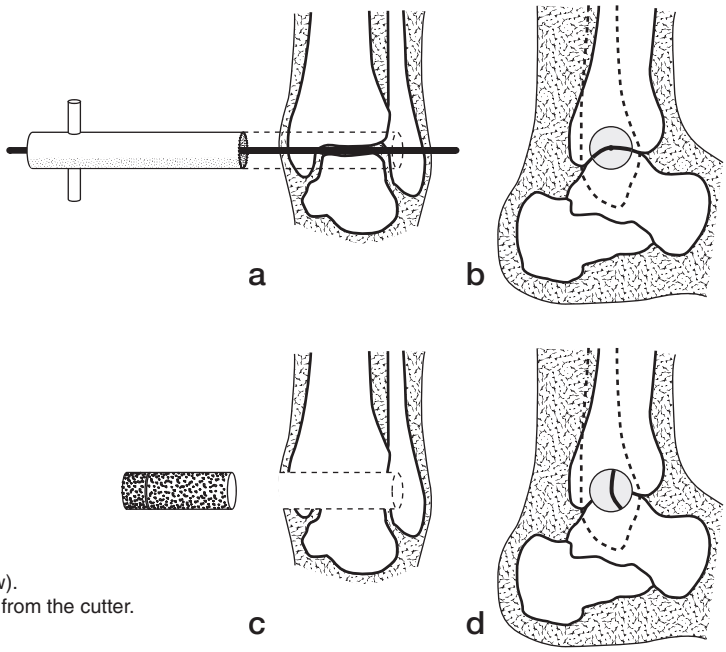

Figure 1. The dowel technique.
a. K-wire through the joint (AP view).
b. Position of the cylinder (lateral view).
c. The cylindrical bone graft expelled from the cutter.
d. Reinsertion of the cylindrical graft.

Figure 2. Radiograph of an ankle operated on with the dowel technique. Lateral view.

Figure 3. Failed arthrodesis after operation with the dowel technique.

reintroduced in reverse so that the medial end of the bone graft was placed in the lateral malleolus; it was also rotated through 90° so that the original surface of the joint was vertical (Figure 2). In 5 patients the technique was somewhat modified. The quality of the bone cylinder was often poor and would only fill the cavity to 50–75%. In order to solve this problem two cylindrical bone grafts were taken from the iliac crest with a Cloward cutter, its inner diameter being the same as the outer diameter of the milling cutter. The cylindrical bone grafts were introduced in addition to the cylindrical bone graft from the ankle.

Results

Fusion was obtained in only 5 of 12 ankles (Figure 3). Adding bone graft from the iliac crest did not improve the results (Table 4).

Table 4. Arthrodesis with the dowel technique

	Fusion	No fusion
Bone graft	2	3
No bone graft	3	4
Total	5	7

Paper 2. Percutaneous ankle arthrodesis in the rheumatoid patient without debridement of the joint

10 patient (11 ankles) with rheumatoid arthritis underwent ankle arthrodesis with percutaneous technique. All patients had severe damage to the joint and radiographs revealed complete loss of joint space. All ankles could be reduced to a functional position. The overall severity of the rheumatic disease was evaluated by means of the HAQ score (Fries 1983). Ankle function was evaluated using the Mazur ankle grading system (Mazur et al. 1979) originally devised for patients with posttraumatic arthritis of the ankle joint, and the modified ankle grading system by Moran et al. (1991). Joint movements were assessed using a hand-held goniometer. Bony fusion was said to have occurred when trabeculations were found to cross the arthrodesis.

The operation was performed under image intensifier control with the patient supine. Two small incisions were made, medially and laterally about 10 cm above the ankle joint. Two guide wires were passed through the joint with the ankle in neutral position, crossing the joint in an oblique medio-lateral and latero-medial direction. In 5 cases an additional incision was made posteriorly

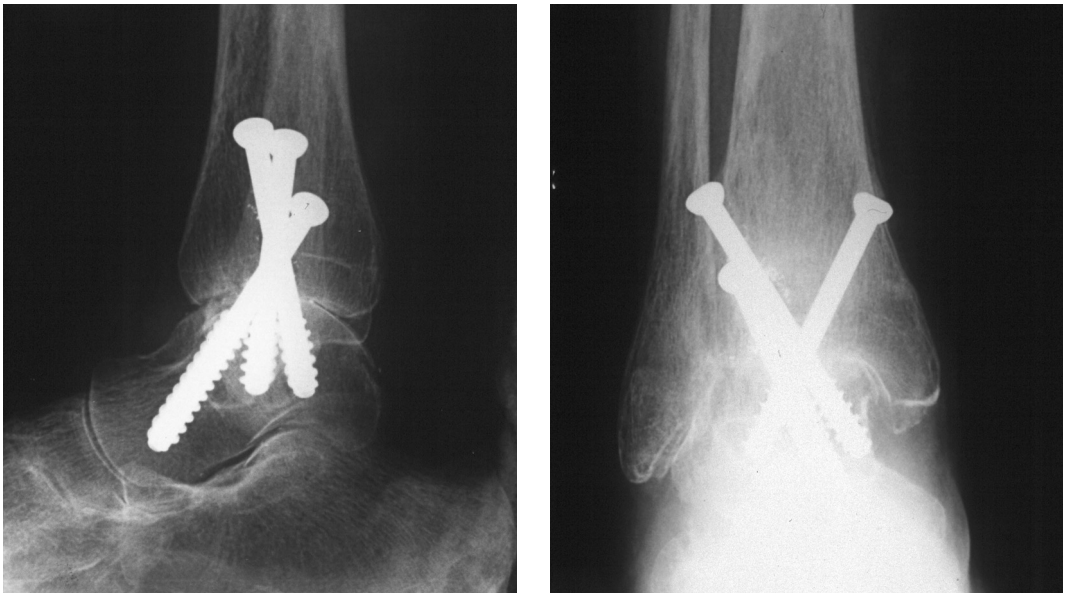

Figure 4 A. AP and lateral view of a percutaneously fused ankle joint

and lateral to the Achilles tendon, and a guide wire was passed in a postero-anterior direction to reach the neck of the talus. Two or three cannulated 7.0-mm partially threaded cancellous screws were then introduced over the guide wires. The medial screw was inserted first to secure the talus to the medial malleolus (Figure 4).

Results

Ten patients obtained a sound bony fusion of the ankle joint (Table 5). One patient died before final evaluation, but 3 years postoperatively the ankle was clinically solid, and the patient walked without walking aids and had no pain. None of the patients had infections related to the operation and no screws had to be removed.

The overall severity of the rheumatic disease was evaluated by means of the HAQ score (1983). 4 patients had severe rheumatoid arthritis with a HAQ score higher than 2. 3 patients had moderate

Table 5. Clinical characteristics and results after percutaneous ankle arthrodesis

Case	Sex	Age (year)	Follow-up (month)	Mazur score	Ankle grading system	HAQ score	Casting time (weeks)	Patient's opinion	Complica-tions	Angle of fusion (°)	Fusion
1	M	62	53	59	86	2.6	12	Satisfied	No	5 valgus	Yes
2	F	72	48	55	81	2.5	12	Satisfied	No	10 valgus	Yes
3	M	58	42	63	91	1.8	10	Satisfied	Yes [a]	10 flexion	Yes
4	F	45	42	85	96	0	9	Satisfied	No	10 flexion	Yes
5 [b]	M	64	34	68	95	0.8	12	Satisfied	No	0	Yes
6	F	80	28	Died	Died	Died	12	Satisfied	No	Died	Yes
7	F	74	12	51	79	2.6	12	Satisfied	No	0	Yes
8	F	66	7	74	97	1.1	10	Satisfied	Yes [c]	0	Yes
9 [b]	M	66	6	68	95	0.8	12	Satisfied	No	0	Yes
10	F	60	6	50	73	3.0	10	Satisfied	No	0	Yes
11	M	70	4	66	95	1.3	13	Satisfied	No	0	Yes

[a] Tibial stress fracture 7 months postoperatively.
[b] Same patient.
[c] Medial malleolar fracture 6 weeks postoperatively.

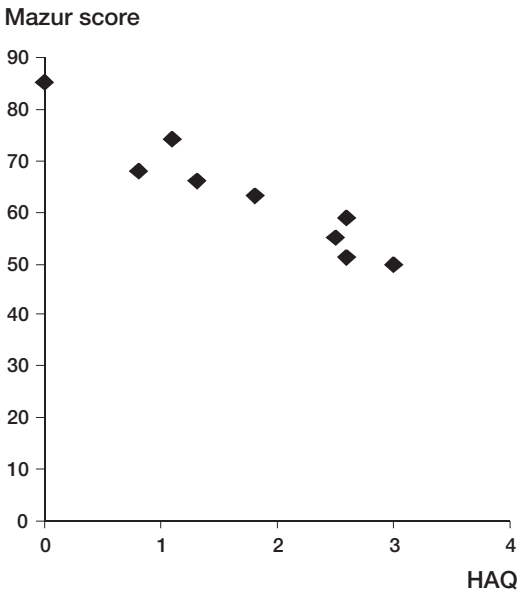

Figure 5. Mazur score versus HAQ score (correlation coefficient –0.95). Case 5 and 9 are right and left ankle of the same patient represented only with one value in the graph.

involvement with a score between 1 and 2, and 2 patients had mild arthritis scoring less than 1. Ankle function was evaluated using the Mazur ankle grading system originally devised for patients with posttraumatic arthritis of the ankle joint. According to the ankle grading system by Mazur et al. (1979) only 1 patient had an excellent result. 1 patient achieved a good result, while 4 were fair and 4 ankles poor. However, all patients claimed to be satisfied and painfree (Table 5, Figure 5).



Figure 6. The four constructs tested. From left the arch, arch–subchondral, the flat and the flat–subchondral constructs.



Figure 7. Bending test.

Paper 3. Arch-shaped versus flat arthrodesis of the ankle joint: strength measurements using synthetic cancellous bone

Which is the most stable construct doing arthrodesis—the preserved ankle contour or the flat cut contour? To test the importance of the geometrical shape for stability, blocks of a synthetic material with low stiffness and strength simulating rheumatoid cancellous bone (Sawbones®) were used. Rectangular blocks (30 × 30 × 60 mm) of low-density rigid polyurethane were produced, and pairs of these blocks were used to model ankle arthrodeses. 24 pairs had flat ends; 12 of these pairs had the flat ends covered with a 1-mm layer of high-density rigid polyurethane to simulate the subchondral bone plate. 24 pairs had the contact surfaces machined to form a concave–convex pair surface in the form of a half cylinder with a radius of curvature of 16 mm, to simulate the geometry of the ankle joint. Again, for 12 pairs of these the surfaces were covered with a layer of high-density rigid polyurethane to simulate the subchondral bone (Figure 6).

Each pair was fixed with two 50-mm long 7.0-mm cannulated screws with a 16-mm thread (AO screws). The screws were positioned in a reproducible manner using a guide originally designed for positioning anterior cruciate ligament reconstructions.

The constructs were then tested to failure in an Instron 8511 load frame with an MTS TestStar II



Figure 8. Torque test.

controller. For each of the four construct groups, six specimens were tested in four point bending tests and six in torque-tests until failure (Figure 7 and 8).

Results

The arch–subchondral construct was the most stable of the four constructs (Table 6).

Paper 4. Finite element analysis of the initial stability of ankle arthrodesis with internal fixation. Flat cut versus intact joint contours

In this finite element model we tested the importance of joint geometry and screw placement for initial stability doing ankle arthrodesis.

An intact healthy male ankle was CT scanned in neutral position. The contours of the distal tibia and the whole talus were extracted from the set of CT images and the geometry of both bones was rebuilt with commercially available software (Materialise 6.3 and I-deas Master Series 7.0.). In order to model the first type of surface preparation, two parallel cuts were made to remove the tibial plafond, the medial malleolus and the dome of the talus. The cut in the tibia was performed at about 1 mm above the articular surface, whereas 4 mm of bone was resected from the top of the talar dome. The talus was then displaced upwards in the frontal plane until the two resected planes were coincident, thus achieving bone-on-bone contact. For the second type of surface preparation, the two intact bones were put in contact by moving the talus upwards in the frontal plane to remove the gap produced by the articular cartilage. To obtain good bone apposition the talus was rotated into a slightly valgus position (2.7 degrees). In both models, two stainless steel cylinders (shaft diameter 4.5 mm, thread length 16 mm) were crossed through the joint, from both sides of the tibia into the body of the talus, simulating 7.0-mm cancellous screws with partial thread commercially available. The medial screw had a slightly posterior-medial to anterior-lateral direction. The lateral screw was placed anterior to the lateral malleolus, in an anterior-lateral to posterior-medial direction, crossing behind the medial screw. The orientation of the screws was assessed by one of the authors, who was an orthopedic surgeon, and deemed to be satisfactory.

The location and length of these two screws were varied to create different models for each type of surface preparation. Below, the models will be referred to as members either of the "flat cut" group or the "intact" group. Two parameters of screw orientation were examined for each of

Table 6. Values are mean (SE)

Group	Bending strength (Nm)	Bending stiffness (Nm/mm)	Torsion (Nm)	Torsion stiffness (Nm/deg)
Flat	14.4 (1.8)	3.6 (0.4)	5.1 (0.1)	0.7 (0.02)
Flat–subchondral	19.2 (0.5)	3.3 (0.3)	5.8 (0.1)	0.5 (0.04)
Arch	13.3 (1.1)	3.7 (0.2)	5.8 (0.3)	0.7 (0.03)
Arch–subchondral	18.6 (0.1)	5.3 (0.2)	8.3 (0.1)	0.8 (0.04)

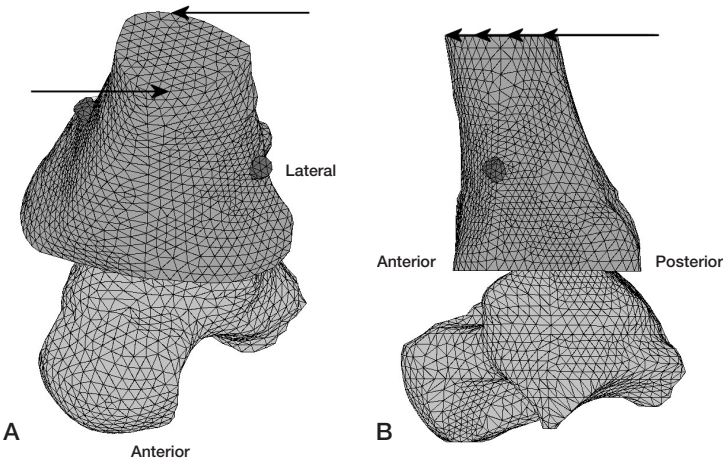

Figure 9. Load cases considered in the FE analysis (inferior face of talus fully constrained, not shown). A) 10 Nm external tibial torsion (for internal tibial torsion, forces go in the opposite directions). B) 200 N posterior-anterior force, equivalent to 10 Nm dorsiflexion torque.

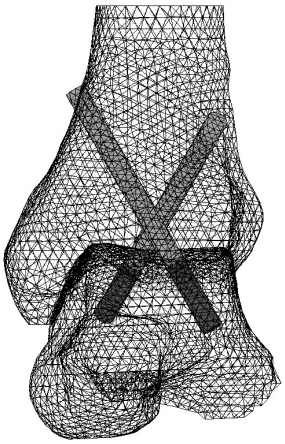

Figure 10. Intact ankle with screws crossed above the joint line.

the surface preparation techniques: the level the screws crossed relative to the fusion site and the angle of insertion. The level of screw crossing was set at approximately +5, 0 and –5 mm relative to the fusion site, by moving the screws vertically in the frontal plane. The angle between each screw and the longitudinal axis of the tibia was set to 30°, 45° and 60° by rotating the screws around an axis perpendicular to the frontal plane. Only those models considered as clinically viable were included in this study. The models with the screws at 45° with the long axis of the tibia and crossed 5 mm above the level of the fusion site, as well as the models with the screws at 60° and crossed approximately +5 and 0 mm relative to the level of the fusion site were rejected because the screws broke out of the fusion site and provided only a marginal purchase in the body of the talus.

The models were meshed with first order tetrahedral elements in I-deas Master Series 7.0. The element edge length for all the contact surfaces was 1.5 mm and 2.5 mm in the rest of the model. The total number of elements for each model ranged from 43102 (model 60-beneath) to 50189 (model I30-beneath). Regarding the material properties, the Young's modulus of the screws was 200 GPa (stainless steel). A modified version of the freeware program Bonemat (Zannoni et al. 1998) was used to assign the Young's modulus to the elements of the two bones. The program averages the CT density values in each element and transforms them to apparent density (ρ_{app}), using the calibration information extracted from the CT scan images. To convert apparent density into Young's modulus, two equations were taken from the literature and combined to obtain a continuous relationship. Low values of apparent density correspond to cancellous bone, whereas higher values are treated as cortical bone:

If $\rho_{app} \leq 476.7$: $E = 0.2\ \rho_{app}^{1.52}$
(Destresse et al. 1995)

If $\rho_{app} > 476.7$: $E = -3842 + 13\ \rho_{app}$
(Rho et al. 1995)

The Poisson's ratio for the bones and screws was assumed to be 0.3 (Keaveny et al. 1993).

In order to model the fixation of the screws, they were rigidly attached to the tibia at the proximal end, to simulate the effect of the head, and perfectly bonded to the talus at the distal end, to simulate the 16 mm thread. Two load cases were defined to compare the stability of the constructs. Internal and external torques of 10 Nm and a posterior-anterior (P-A) force of 200 N, equivalent to a dorsiflexion moment at the fusion site of approximately 10 Nm, were separately applied to the top of the tibia, whereas the inferior face of the talus remained fully constrained. The contact was

Table 7. Maximum relative micromotions (µm) at the fusion site for the intact and flat cut techniques in each screw configuration

Screw configuration	External torsion			Internal torsion			Dorsiflexion		
	Intact group	Flat cut group	% [a]	Intact group	Flat cut group	% [a]	Intact group	Flat cut group	% [a]
30°/ 5 mm	86	145	68	70	104	49	49	55	12
30°/ 0 mm	115	177	54	73	130	77	58	72	25
30°/–5 mm	161	194	21	92	136	48	68	102	49
45°/ 0 mm	168	199	19	102	136	34	105	121	16
45°/–5 mm	179	158	–12	94	112	20	121	165	36
60°/–5 mm	167	150	–10	[b]	97	[b]	198	274	38

[a] Percentage of change from intact to flat cut group. [b] Results not available.

assumed to be frictionless. All the models were solved in March 2001.

Each model was subjected to the three load cases, i.e., the external torsion, the internal torsion and the P-A shear force mentioned above. Relative displacements between the pairs of nodes (one belonging to the tibia and the other to the talus) located at the contact interface were calculated in each case to compare the micromotions produced at the fusion site (Figure 9).

Results

The modeled ankle arthrodeses with internal fixation predicted a better stability when the joint contour was preserved for the load cases most likely to affect the fused ankle immediately after surgery (Table 7). Overall, inserting the two screws at a 30° angle with the long axis of the tibia, and crossing them above the fusion site predicted a better stability for both joint preparation techniques (Figure 10).

Paper 5. Arthrodesis by percutaneous fixation

In this rabbit study the hypothesis that joints can fuse as a consequence of rigid fixation was tested. 9 female skeletally mature lop-ear dwarf rabbits were operated on.

The operation was performed on the right hind limb. A longitudinal incision was made over the patella. The anterior surface of the patella was visualized and the bony edges defined. With the knee in approximately 45 degrees of flexion, two 1.5 mm cortical screws were inserted through the patellofemoral joint in an antero-posterior direction with the lag screw technique. The patella tendon and the quadriceps tendon were then divided close to the patella in order to minimize the risk of motion in the arthrodesis, but the medial and lateral retinaculae were saved. After the operation, radiographs were taken to confirm the alignment in the arthrodesis and the position of the screws (Figure 11).

Micro-CT was performed on 2 randomly selected specimens among those, which were clinically fused. The specimens were then decalcified, serially sectioned in the sagittal plane and stained with hematoxylin and eosin.

Results

5 arthrodeses went to bony fusion. This was confirmed by micro-CT in 2 cases (Figure 12) and by

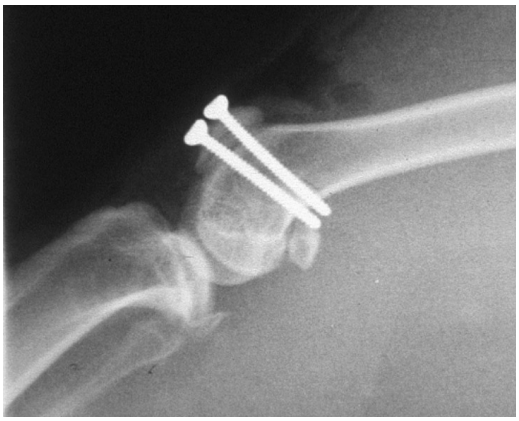

Figure 11. Postoperative radiograph. Patella fixated to the femur.

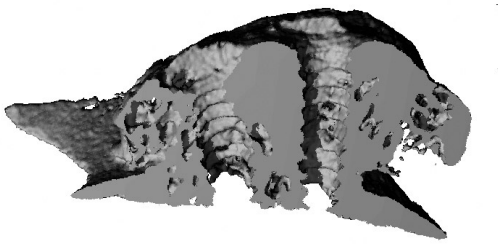

Figure 12. Micro-CT of specimens 3 months after fixation. Screws are removed. Anterior aspect of femoral condyles at the bottom.

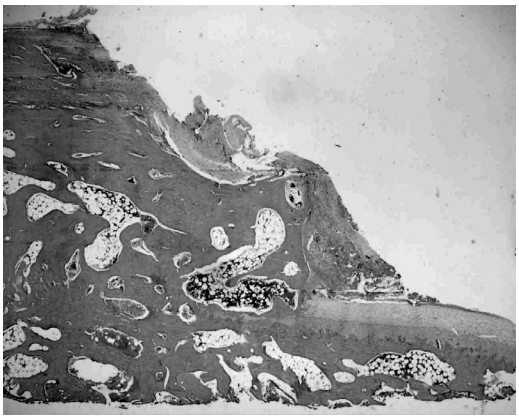

Figure 13. Patella, fused to underlying femur. Femoral cartilage to the right is proximal to the patella.

histology in all 5 cases (Figure 13). 1 arthrodesis went to fibrous healing confirmed by histology. 2 arthrodeses failed because of early fractures of the screws and the patella. One rabbit was killed postoperatively due to paralysis of the hind limbs. Thus in the cases in which the fixation was initially successful, there was fusion in 5 out of 6 attempts.

Paper 6. Joint cartilage destruction after synovial fluid depletion may explain successful artrodesis without operative cartilage removal

42 skeletally mature lop-ear dwarf rabbits aged 6–9 months were operated on.

The operation was performed on the left hind limb. A longitudinal incision was made over the patella. The joint capsule was incised lateral to

Figure 14. Closed metal cap and open metal cap.

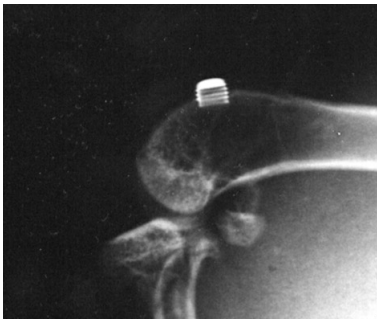

Figure 15. Postoperative radiograph showing the position of the metal cap in the knee.

the patella and the patella luxated medially. With a milling hole-cutter with an inner diameter of 3 mm, a ring-shaped hole was made in the frontal aspect of the femur corresponding to the femoro-patellar joint. Thus, a 3 mm bone plug covered with joint cartilage was left in place. A metal cap of titanium with a height of 3.2 mm with thread (M4 × 0.5) was introduced over this plug (Figure 14). The patella was then reduced, and the lateral joint capsule was sutured. In 14 animals the metal cap was closed in order to deplete the cartilage underneath the metal cap from its synovial nutrition. In 12 animals the metal cap was open (the opening having a diameter of 2 mm) allowing diffusion of synovial fluid to the cartilage. A third group of 16 animals were operated on with a closed metal cap, but the cartilage and subchondral bone underneath the metal cap was perforated once with a 0.65 mm drill. After the operation, radiographs were taken on the first 6 animals to confirm the position of the metal cap in the joint (Figure 15).

Specimen preparation and analysis

The rabbits were killed after 2, 3 or 7 weeks with an overdose of pentobarbital. The metal cap was removed, and the area of interest and the adjacent bone were cut out with a saw and fixed in 4% buffered formalin.

Table 8. Complete resorption versus residual cartilage after 7 weeks

	Closed	Closed with drill-hole	Open
No cartilage	4	8	1
Residual cartilage	3	0	6

The specimens were then decalcified, serially sectioned in the sagittal plane and stained with hematoxylin and eosin, and methylene blue.

Results

The statistical outcome variable was presence of cartilage, as opposed to complete absence. Only 7 weeks results were analyzed statistically. Fisher's exact test was used for pair-wise comparisons of the groups with open cap, closed cap, and closed cap with a drill-hole. A closed cap and a central drill-hole were significantly more effective in causing complete resorption of the cartilage than was the open metal cap (p=0.008) (Table 8).

Paper 7. Percutaneous arthrodesis in hallux rigidus

Can patients with osteoarthritis be operated on solely by percutaneous fixation? The first metatarsophalangeal joint in patients with hallux rigidus was chosen as an appropriate joint to test the percutaneous technique. 10 patients with hallux rigidus were to be included. The study was to be interrupted if 3 patients did not fuse, because with more failures, the 95% confidence interval would not exclude a failure rate above 50%. 6 patients (7 metatarsophalangeal joints, 5 women), with hallux rigidus were operated on before the study was terminated. All patients had severe osteoarthritis of the joint and radiographs revealed narrowing of the joint space and subchondral sclerosis. In all cases the metatarsophalangeal joint could be brought to a normal alignment. Patients with large osteophytes or with malalignment in the joint were excluded.

The operation was performed under image intensifier control with the patient supine. Two small incisions were made on the medial side, proximal and distal to the metatarsophalangeal joint. Two guide wires were passed through the joint in an oblique proximal-distal and distal-proximal direction with the joint in neutral position (i.e. 15 degrees of valgus and 15 degrees of dorsiflexion). Two cannulated 3.5 mm full-threaded cancellous screws were then introduced over the guide wires with the lag screw technique. The screw with the proximal-distal direction was inserted first (Figure 16).

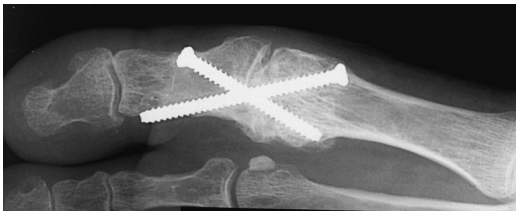

Figure 16. Postoperative radiograph.

After 1 year, we considered the arthrodesis fused if the joint was clinically stable and the patient had no pain while weight bearing, there were no signs of screw loosening on radiographs and radiographs did not contradict healing (Figure 16).

Results

The study was interrupted when the third failure was evident. At that time 6 patients (7 metatarsophalangeal joints) had undergone the operation. 3 patients (4 metatarsophalangeal joints) obtained fusion (Table 9). Three patients did not fuse their arthrodesis. Two of these patients did not follow the instructions concerning the orthosis postoperatively, and had been fully weight bearing from the third week. One of them revealed screw loosening after 6 weeks. The screw was reinserted with a good grip in local anesthetics, but the arthrodesis failed. The other patient had screw loosening after

Table 9. Material and results

Sex	Side	Age (year)	Removal of osteophyte	Fusion
F	Left	55	Yes	No
F	Right	46	Yes	Yes
F	Bilateral	49	Yes/ Yes	Yes/ Yes
F	Left	66	No	Yes
F	Right	57	Yes	No
M	Left	54	No	No

3 months and pain while weight bearing. The third patient had followed the instructions but still revealed a painful joint from the first day of weight bearing. Radiographs were not convincing of pseudarthrosis until 5 months after the operation. The 3 patients with unhealed arthrodesis underwent successful re-arthrodesis with open technique. One patient had to undergo two operations before the arthrodesis fused.

Discussion

Stability

The percutaneous dowel technique for fusion of rheumatoid ankles resulted in a high failure rate. We concluded that the lack of stability in this technique was probably the reason for the low fusion rate. Adding bone graft from the iliac crest did not appear to improve the results. If the dowel technique should be used as a percutaneous technique in the rheumatoid patient, we would suggest some kind of additional fixation with screws or an external fixator. However, the high success rate using percutaneous screw fixation without dowels makes the dowel technique superfluous by applying a minimally invasive arthrodesis technique in rheumatoid arthritis.

Arthrodesis of the ankle joint is more difficult to achieve when there are associated problems with bony deformity or soft tissue abnormalities. These deformities or soft tissue problems often occur in rheumatoid patients. The high fusion rate for arthrodesis with the percutaneous technique in rheumatoid patients could be explained by the fact that these ankles were well aligned, and therefore no bone resection was necessary. Secondly, minimal damage to the soft tissue is an integral part of the technique. Thirdly, the arch shape was preserved with nearly perfect congruence in the arthrodesis, and this could contribute to stability.

The first study to compare the importance of the joint contour for stability was that of Miller et al. (2000). They used four pairs of cadaveric bone from white men with an average age of 56 years (range 41–68 years) and compared stability between an arthrodesis with preserved joint contour and an arthrodesis with parallel saw cuts. A crossed screw configuration was used for the arthrodesis. This study had the advantage of using paired cadaveric specimens. The specimens, however, presumably consisted of strong bone (i.e. relatively young age and male). Furthermore, the specimens were free of any ankle pathology, which is rare at the time of clinical ankle arthrodesis. They found the preserved contour to yield better stability, but this difference was not statistically significant, and they concluded both methods could be biomechanically sound. However, the low number of tested pairs of specimens (n=4) could make it difficult to exclude the possibility of clinically relevant differences.

It is known that screw fixation in osteoporotic bone can be a problem. The relative importance of the ideal geometry for the construct is likely to increase in weak rheumatoid bone. The main reason for using a polyurethane foam model in our study was the difficulties in getting sufficient amounts of reproducible cadaveric bone. The low-density foam was chosen to reproduce the quality of osteoporotic bone in rheumatoid patients. The forces for failure were a factor 5–10 less than in the cadaveric studies discussed above. This difference could be explained by the absence of cortical bone on the sides of the samples and by the fact that low-density foam was used, whereas the cadavers of Miller et al. (2000) were likely to be non-osteoporotic. Doing flat resection arthrodesis of the ankle joint implies, at least for the talus, removing some of the subchondral bone. On the other hand, when preserving the arch shape it is possible to save the subchondral bone. Therefore, the two models that are the most clinically relevant are the flat sample with no subchondral bone, and the round-subchondral samples. In this study the arch-subchondral model gave superior stability by factors of 1.3 (bending) and 1.6 (torque) for strength and 1.5 (bending) and 1.1 (torque) for stiffness.

In rheumatoid patients, the ankle joint is often rather congruent, despite joint and cartilage destruction, and attempts to do flat resections may yield large gaps. Flat resections could also result in impingement of the medial or lateral malleolus or soft tissue and will always result in some degree of leg shortening.

Both open arthrodesis with flat resection surfaces and percutaneous arthrodesis with preserved arch shape could, in clinical practice, be biomechanically sound, but if the results from our experimental study are applicable to the clinical situation, they indicate that the arch shape should

be preserved in the well aligned ankle with congruent joint surfaces.

We concluded that the arch–subchondral construct was the most stable of the four constructs tested on sawbones, indicating that the arch shape and the subchondral bone should be preserved when performing ankle arthrodesis. The importance of this is likely to increase in weak rheumatoid bone.

We also tested the importance of geometry in a finite element model. The modeled ankle arthrodeses with internal fixation predicted a better stability when the joint contour was preserved. Moreover, inserting the two screws at a 30 degrees angle with the long axis of the tibia, and crossing them above the fusion site predicted a better stability for both joint preparation techniques.

We believe that estimation of the micromotions at the bone interface provides a better knowledge of the mechanical environment affecting the fusion site.

The relative micromotions at the fusion site may be related to the success or failure of fusion, with excessive initial micromotion leading to nonunion (Boden et al. 1995). No data exist concerning a safe level of micromotion that will ensure fusion.

However, in total joint replacement, immediate postoperative displacements at the interface between the porous-surfaced implant and the surrounding bone seem to affect the type of tissue forming at the interface and, therefore, the fixation of the implant (Kienapfel et al. 1999). Although exact figures are unknown, published safe levels of micromotion that would allow bone ingrowth range from about 30 to 150 μm (Goodman et al. 1993, Ramamurti et al. 1997, Szmukler-Moncler et al. 1998). In our finite element model we arrived at micromotions in a range from 86 μm to 274 μm depending on the surgical technique. Thus, it appears that technique changes might diminish micromotion down to a safe level.

Regarding the different screw configurations, a clinical range of insertion angles and crossing levels was chosen. Although some mixed results were obtained in torsion, especially in the flat cut group, overall, inserting the screws at 30 degrees with the long axis of the tibia and crossing them above the fusion site, seemed to offer the most stable arthrodesis construct both in torsion and dorsiflexion.

Several simplifications have been assumed in the modelling process in this study as a first attempt to assess the initial stability of ankle arthrodesis. Only the main osseous structures involved were considered (talus and tibia) and the medial malleolus was resected, despite not being a standard surgical procedure. The material properties of the bones were assumed isotropic and the contact considered frictionless. The difficulties of determing standard values of such magnitudes as material properties and frictional parameters when dealing with human tissues are well known. In addition, experimental studies providing ankle joint characteristics to implement in FE models are scarce. The rationale for the frictionless contact considered in this study, was that it represents a worst-case scenario. A reduction in micromotion would be expected if friction were included. The authors are currently implementing friction contact in the models presented here, although the ranking obtained is not expected to change.

Bone quality affects the stability of arthrodesis constructs (Thordarson et al. 1990, Friedman et al. 1994), so that additional means are needed to achieve a rigid fixation, reducing the micromotions to the levels allowing the final fusion. In our finite element model, normal bone quality was assumed. If bone quality is poorer, as happens in many patients undergoing ankle arthrodesis (eg rheumatoid patients), screw fixation can be a problem and larger micromotions are expected (Kim 2001), which could compromise the success of the fusion. In these cases, joint geometry could have an even greater influence in the stability of the arthrodesis.

Although the degree of optimal compression for the arthrodesis healing has not been determined, most of the clinical results of tibiotalar arthrodesis suggest that it affects the final outcome as it seems to increase the stability of the arthrodesis constructs (Holt et al. 1991, Maurer et al. 1991, Fu et al. 1999). In our FE analysis we did not include the effect of the screw compression through the fusion site. This compression is likely to decrease the micromotions at the fusion site, especially when friction is present. However, the degree and duration of such compression have not been estimated experimentally for this type of arthrodesis. If poor bone quality

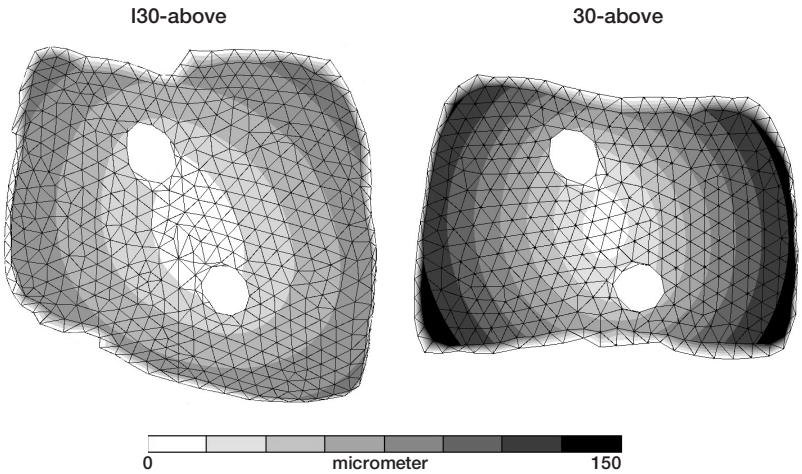

Figure 17. Example of relative micromotions between tibia and talus in external torsion, displayed on the contact surface of the talus (superior view). Preserved articular surface (left) and flat-cut resected surface (right).

is considered, the compression effect may not be very significant, given the relatively small degree of compression achieved with the screws during surgery. Nevertheless, further research needs to be carried out to address this subject.

These simplifications and limitations of the models presented here must be kept in mind when considering the clinical relevance of the results from a quantitative point of view. However, we consider that they can provide useful qualitative information when performing this type of comparative analyses, with the additional advantage that all the variations of the surgical procedure were performed on the same ankle model.

In general, preservation of the articular surfaces produced the most stable arthrodesis. Overall, inserting the two screws at a 30-degree angle with respect to the long axis of the tibia, and crossing them above the fusion site improved stability for both joint preparation techniques (Figure 17).

The rheumatoid ankle

Arthrodesis is normally performed with joint resection or at least with removal of cartilage. It is believed that the best condition for bony fusion is obtained when two cancelleous bone surfaces are aligned and compressed with stability. A case of successful percutaneous ankle arthrodesis on a rheumatoid patient treated without debridement of the joint was reported in 1997 (Borril et al. 1997). We reported successful fusion of all 11 rheumatoid ankles treated with percutaneous fixation only (Lauge-Pedersen et al. 1998). Our first arthrodesis by percutaneous fixation was performed in 1993 on a rheumatoid patient with a history of septic arthritis and a painful ankle with almost no cartilage left in the joint. To minimise the risk of re- infection, 3 screws were inserted over the joint percutanously under fluoroscopic control. The patient not only became painfree after this procedure, but furthermore the joint showed bony fusion on radiographs 6 months later. As a consequence of this observation, we have to date done 25 ankle arthrodeses (follow-up time 5.5 (1–8) years) with the percutaneous technique on rheumatoid patients (Figure 18). We have had only one failure. In some of the ankle joints there was a visible joint space on postoperative radiographs, which later disappeared. In one case a small arthrotomy was necessary to remove an anterior osteophyte that prevented dorsiflexion, allowing us to verify the presence of residual cartilage.

Although the Mazur ankle grading system was originally devised for patients with posttraumatic arthritis, it is sometimes used in the literature for evaluation of the ankle function in patients with rheumatoid artritis (Smith et al. 1990, Moran et al. 1991, Cracchiolo et al. 1992). A correlation coef-

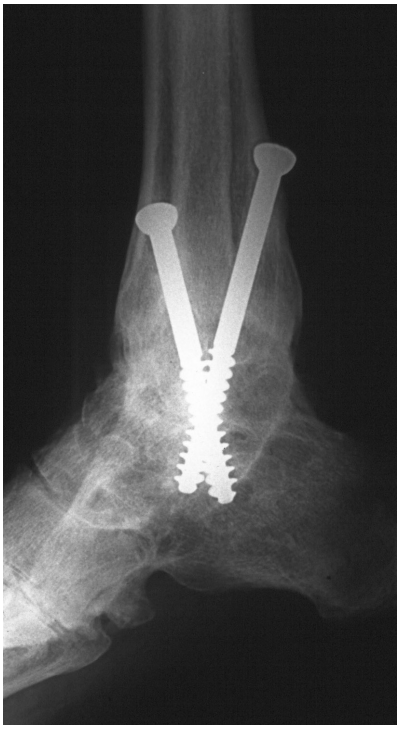

Figure 18. Percutaneous arthrodesis after fusion. Lateral view.

ficient of –0.95 between the points given by the Mazur ankle grading system and the points given by the HAQ score indicates that the Mazur score tends to measure the severity of the rheumatic disease rather than the ankle function (Figure 5). Therefore we do not find the Mazur ankle grading system relevant for patients with rheumatoid arthritis.

The question rose whether fusion following percutaneous fixation is a phenomenon specific to rheumatoid patients, who are sometimes known to fuse at least their subtalar joints spontaneously, or if it may also be possible to initiate bony fusion in a healthy joint merely by rigid stabilisation.

The normal joint

To obtain fusion with the percutaneous technique with cartilage remaining in the joint, the cartilage has to disappear relatively quickly. In paper 5 we concluded that joints can fuse as a consequence of rigid fixation. Histology showed fusion to a variable degree in 5 of 6 rabbits. In the failed case there was chondrolysis and a fibrous union. In the other cases there was bony fusion in almost all areas where there seemed to have been close contact between the cartilage surfaces. In areas where there was a gap between the cartilage surfaces the cartilage had remained. In one case there was contact only at the lateral rim of the patella. It had fused only there, and not at the screw canals. Only rarely were there islands of cartilage remaining inside the bone in the fused areas.

In patients with rheumatoid arthritis, subtalar joints sometimes fuse spontaneously, but this almost never in the ankle joint. The success of percutaneous ankle arthrodesis in such patients may be partly due to synovitis, which has a deleterious effect on cartilage. Our findings, however, imply that even a healthy joint can fuse without joint resection or debridement.

Partial joint immobilisation damages cartilage and causes chondrolysis, cloning of chondrocytes and invasion of the tide mark in rats, rabbits and dogs (Kahanovitz et al. 1984, Smith et al. 1992, Kim et al. 1995, Shevtsov et al. 1995, Hong and Henderson 1996, Jortikka et al. 1997, Fu et al. 1998). Compression of the knee joint in rabbits results in chondrolysis and erosion of the cartilage (Gritzka et al. 1973). These changes are typical of osteoarthritis.

Our findings suggest that bone invades the cartilage from either side of the joint. The cartilage in the congruent part of the arthrodesis is deprived of its oxygen supply and nutrition from the synovial fluid. This damages the cartilage and eventually causes chondrocyte death. This may prevent the cartilage from inhibiting vascular invasion and ossification. The transport of osteoprogenitor cells through the drilling canal during the operation is hardly the only reason for bony fusion, because bony bridges were present at a distance from the screw holes and in the periphery of the joint.

In clinical practice we often fuse joints having posttraumatic arthritis or rheumatoid arthritis with almost normal alignment but a painful range of motion. In these cases percutaneous fixation without debridement of the joint would cause the patient less postoperative pain, reduce the risk of malpositioning, be shorter and the anesthesia would take less time for the patient.

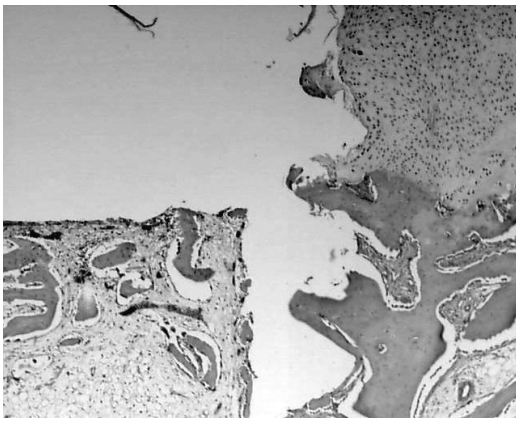

Figure 19. Histology from specimen with closed metal cap and a drill-hole (7 weeks). On the left the isolated plug with total resorption of the cartilage, on the right the area outside the plug showing cartilage with degenerative changes.

To achieve fusion with the percutaneous technique remaining cartilage has to disappear and a bone repair response has to occur. In Paper 6 the effect of synovial depletion on cartilage was evaluated. We found that synovial depletion for a reasonable period of time (7 weeks in rabbits) in combination with a drill-hole is sufficient for the cartilage matrix to disappear. However, the absence of mechanical stimulation was not sufficient for total resorption of the cartilage.

In diseases such as osteoarthritis and rheumatoid arthritis, the normal balance between breakdown and replacement of matrix constituents is disturbed and shifted toward excessive degradation. This degradation involves a complicated process where a typical finding in both diseases is loss of aggrecan. The primary cause of cartilage and bone destruction involves elevated levels of active proteases, secreted from both chondrocytes and the synovial cells (Murphy et al. 2002). This is a reasonably slow process, and for an arthrodesis to fuse in 6–12 weeks, cartilage resorption needs to be much quicker. Our goal was to compare the importance of synovial depletion (i.e. joint congruity in the fixated position) versus unloading (i.e. rigidity of fixation) and drilling canals through the fixated joint.

In conclusion, synovial depletion appears not only to kill the chondrocytes, but also leads to reasonably quick removal of the cartilage matrix. The absence of obvious endochondral ossification, however, suggests that percutaneous arthrodesis should be combined with sufficient trauma to elicit a bone repair response, eg by multiple drill holes across the joint (Figure 19).

Having shown that rheumatoid ankles and even a normal joint (rabbit knee) can fuse as a consequence of rigid fixation, we tested the hypothesis that an osteoarthritic joint can do so as well.

The osteoarthritic joint: Hallux rigidus

The percutaneous technique for arthrodesis of the first metatarsophalangeal joint is a quick operation, and the general impression is that it generates less postoperative pain than the conventional open techniques. However, the mild postoperative symptoms appear to have made the patients less motivated to avoid weight bearing, which we had not foreseen. With a more rigid postoperative regime, similar to that after an operation with an open technique, the outcome might have been better. Further, when positioning the metatarsophalangeal joint in the desired position in some cases, we jeopardized the congruency of the joint, so that the contact only occurred in small areas. This limited contact impaired both the postoperative stability and the areas for fusion to occur. The series was interrupted because at the start of the clinical trial we had decided to stop after 3 failures in 10 patients in our original protocol. We believe, however, that we are in a learning curve and that better results can be achieved with more attention to both surgical technique and postoperative patient activity. The present result demonstrates that it is possible to achieve bony fusion with a percutaneous technique in a small osteoarthrotic joint in humans (Figure 20). The main advantages of this technique are the mild postoperative pain and the short operation time. If the joint fails to fuse, it is still possible to perform an open procedure. Therefore, the advantages of a percutaneous technique could balance a slightly lower rate of fusion.

After now having shown that fusion is possible, we hope to develop this technique to yield an acceptable success rate.

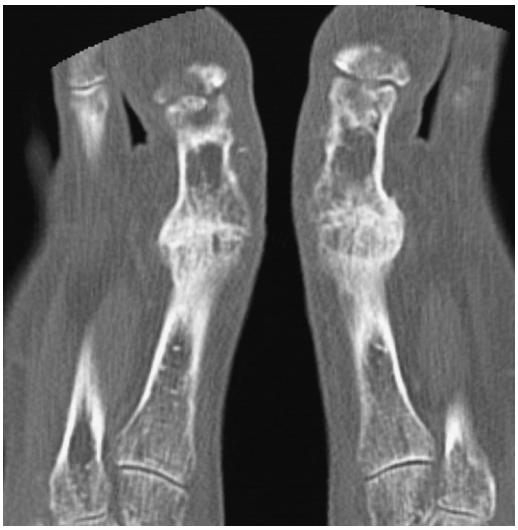

Figure 20. CT scanning of the left and right metatarsophalangeal joint in a patient operated on bilaterally, one year postoperatively.

Future perspectives

We plan to continue to explore the idea of using the percutaneous technique also for osteoarthritic joints, by modifying the technique in a new series of patients. We will concentrate on improving joint surface contact, by taking more care when positioning the joint for fixation, by inserting the screw from distal to proximal first, and by using another type of screws. Further, we will make additional drill holes through the joint by using the guide pin. Finally, we will instruct the patients to unload the foot for 6 weeks, in spite of the absence of pain.

Conclusions

1. The stability appears crucial for fusion of an arthrodesis.
2. Arch shape yields better stability than a flat contour when performing ankle arthrodesis.
3. An insertion angle of 30 degrees to the long axis of the tibia gives the best initial stability when using two screws for ankle arthrodesis. The screws should cross above the joint line.
4. Arthrodesis merely by percutaneous fixation can be recommended in the rheumatoid patient.
5. A normal joint can fuse as a consequence of rigid fixation only.
6. Synovial depletion may be the cause of cartilage disappearance using the percutaneous technique for arthrodesis.
7. An osteoarthrotic joint can fuse as a consequence of rigid fixation only.

Summary

It has been generally accepted that residual cartilage and subchondral bone has to be removed in order to get bony fusion in arthrodeses. In 1998 we reported successful fusion of 11 rheumatoid ankles, all treated with percutaneous fixation only. In at least one of these ankle joint there was cartilage left. This was confirmed by arthrotomy in order to remove an osteophyte, which hindered dorsiflexion. More than 25 rheumatoid patients with functional alignment in the ankle joint have subsequently been operated on with the percutaneous technique, and so far we have had only one failure. Patients with rheumatoid arthritis are known to sometimes fuse at least their subtalar joints spontaneously, and the destructive effect of the synovitis on the cartilage could contribute to fusion when using the percutaneous technique. In a rabbit study we therefore tested the hypothesis that even a normal joint can fuse merely by percutaneous fixation. The patella was fixated to the femur with lag screw technique without removal of cartilage, and in 5 of 6 arthrodeses with stable fixation bony fusion followed. Depletion of synovial fluid seemed to be the mechanism behind cartilage disappearance.

The stability of the fixation achieved at arthrodesis surgery is an important factor in determining success or failure. Dowel arthrodesis without additional fixation proved to be deleterious. A good fit of the bone surfaces appears necessary. In the ankle joint, it would be technically demanding to retain the arch-shaped geometry of the joint after resection of the cartilage. Normally the joint surfaces are resected to produce flat osteotomy surfaces that are thus easier to fit together, encouraging healing to occur. On the other hand it is considered an advantage to preserve as much subchondral bone as possible, as the strong subchondral bone plate can contribute to the stability of the arthrodesis. Ankle arthrodesis can be successfully performed in patients with rheumatoid arthritis by percutaneous screw fixation without resection of the joint surfaces. This procedure has two advantages: first, it is less surgically traumatic, second, both the arch-shaped geometry and the subchondral bone are preserved, and thus both could contribute to the postoperative stability of the construct. Intuitively, preservation of the arch-shape should increase rotational stability. The results of our experimental sawbone study indicate that the arch shape and the subchondral bone should be preserved when ankle arthrodesis is perfomed. The importance of this is likely to increase in weak rheumatoid bone.

In a finite element study the initial stability provided by two different methods of joint preparation and different screw configurations in ankle arthrodesis, was compared.

Better initial stability is predicted for ankle arthrodesis when joint contours are preserved rather than resected. Overall, inserting the two screws at a 30-degree angle with respect to the long axis of the tibia and crossing them above the fusion site improved stability for both joint preparation techniques.

The question rose as to whether patients with osteoarthritis could also be operated on solely by percutaneous fixation technique. The first metatarsophalangeal joint in patients with hallux rigidus was chosen as an appropriate joint to test the percutaneous technique. In this small series we have shown that it is possible to achieve bony fusion with a percutaneous technique in an osteoarthrotic joint in humans, but failed to say anything about the fusion rate.

Acknowledgements

A sincere gratitude is expressed to my tutors Per Aspenberg and Urban Rydholm, to Ana Alonso Vázquez and Mark Taylor for instructive discussions on finite element modelling, to Liz Tanner for instructive discussions on biomechanics, to my co-authors, to my colleagues, to Inger Mårtensson and Carina Forslund for technical assistance, to Mats Christensson for making the necessary metal caps and drills, to Fred Kjellson for performing the mechanical tests, to Mats Nilsson for helping us with the software and hardware to measure density in our CT-scanner and to Lena, Alexander and Christoffer for being there.

This work was supported by grants from:
Medical faculty, Lund University.
The Swedish Medical Research Council projects 2031 and 09509.
Stiftelsen för bistånd åt rörelseshindrade i Skåne.

References

Abidi NA, Gruen GS, Conti SF. Ankle arthrodesis: indications and techniques. J Am Acad Orthop Surg 2000; 8: 200-9.

Baciu CC. A simple technique for arthrodesis of the ankle. J Bone Joint Surg (Br) 1986; 68: 266-7.

Berman, AT, Bosacco ST, Parks BG, Israelite CL, Austin, DK, Farrell ED, Quartararo LG. Compression arthrodesis of the ankle by triangular external fixation: Biomechanical and clinical evaluation. Orthopedics 22: 1129-34

Boden DB, Sumner DR. Biologic factors affecting spinal fusion and bone regeneration. Spine 1995; 20: 102S-112S.

Bolander ME. Regulation of fracture repair by growth factors. Proc Soc Exp Biol Med 1984; 200: 165-70.

Borril JK, Sochart DH, Paul AS. Percutaneous arthrodesis in the rheumatoid patient. Foot 1997; 7: 112-4.

Cameron SE, Ullrich P. Arthroscopic arthrodesis of the ankle joint. Arthroscopy 2000; 16: 21-6.

Carrier DA, Harris CM. Ankle arthrodesis with vertical Steinmann's pins in rheumatoid arthritis. Clin Orthop 1991; 268: 10-4.

Charnley J. Compression arthrodesis of the ankle and shoulder. J Bone Joint Surg (Br) 1951; 33: 180-91.

Chen YJ, Huang TJ, Shih HN, Hsu KY, Hsu RW. Ankle arthrodesis with cross screw fixation. Good results in 36/40 cases followed 3-7 years. Acta Orthop Scand 1996; 67: 473-8.

Colgrove RC, Bruffey JD. Ankle arthrodesis: Combined internal–external fixation. Foot Ankle Int 2001; 22: 92-7

Cracchiolo A, Cimino WR, Lian G. Arthrodesis of the ankle in patients who have rheumatoid arthritis. J Bone Joint Surg (Am) 1992; 74: 903-9.

Cunningham JL, Richardson JB, Soriano RMG, Kenwright J. A mechanical assesment of aplied compression and healing in knee arthrodesis. Clin Orthop 1989; 242: 256-64.

Demetriades L, Strauss E, Gallina J. Osteoarthritis of the ankle. Clin Orthop 1998; 349: 28-42.

Dennis DA, Clayton ML, Wong DA, Mack RP, Susman MH. Internal fixation compression arthrodesis of the ankle. Clin Orthop 1990; 253: 212-20.

Dereymaeker GP, Van Eygen P, Driesen R, De Ferm A. Tibiotalar arthrodesis in the rheumatoid foot. Clin Orthop 1998; 349: 43-7.

Destresse B, Hobatho MC, Darmana R. Etude des proprietes mecaniques de l´os spongieux du tibia humain par une methode ultrasonore. Innov Tech Biol Med 1995; 16: 288-99.

Dohm M, Purdy BA, Benjamin J. Primary union of ankle arthrodesis: review of a single institution/multiple surgeon experience. Foot Ankle Int 1994; 15: 293-6.

Dohm MP, Benjamin JB, Harrison J, Szivek JA. A Biomechanical evaluation of three forms of internal fixation used in ankle arthrodesis. Foot Ankle Int 1994; 15: 297-300

Easley ME, Vertullo CJ, Urban WC, Nunley JA. Total ankle arthroplasty. J Am Acad Orthop Surg 2002; 10: 157-67.

Einhorn TA, Majeska RJ, Rush EB. The expression of cytokine activity by fracture callus. J Bone Miner Res 1995; 10: 1272-81.

Felix NA, Kitaoka HB. Ankle arthrodesis in patients with rheumatoid arthritis. Clin Orthop 1998; 349: 58-64.

Friedman RL, Glisson RR, Nunley JA. A biomechanical comparative analysis of two techniques for tibiotalar arthrodesis. Foot Ankle Int 1994; 15: 301-5.

Fries JF. The assessment of disability: from first to future principles. Br J Rheumatol 1983; 22 (3 Suppl): 48-58.

Fu LL, Maffulli N, Yip KM, Chan KM. Articular cartilage lesions of the knee following immobilisation or destabilisation for 6 or 12 weeks in rabbits. Clin Rheumatol 1998; 17: 227-33.

Fu YC, Huang PJ, Tien YC, Hung SH, Cheng YM, Lin SY, Chen YC, Liu LL, Huang SH. Ankle arthrodesis: internal non-compression arthrodesis versus internal compression arthrodesis. Kaohsiung J Med Sci 1999; 15: 550-5.

Gallie WE. Arthrodesis of the Ankle Joint. J Bone Joint Surg Br 1948; 30: 618-21.

Goodman S, Aspenberg P. Effects of mechanical stimulation on the differentiation of hard tissues. Biomaterials 1993; 14: 563-9.

Gritzka TL, Fry LR, Cheesman RL, Lavugne A. Detoriation of articular cartilage caused by continuous compression in a moving rabbit joint. J Bone Joint Surg (Am) 1973; 55: 1698-1720.

Heinegard D, Lorenzo P, Saxne T. Kelley´s Textbook of Rheumatology, sixth edition, Chapter 3. 2001.

Heppenstall RB. Fracture treatment and healing. Philadelphia, WB Saunders 1980.

Hodge JA, McKibbin B. The nutrition of mature and immature cartilage in rabbits. An autoradiographic study. J Bone Joint Surg Br 1969; 51: 140-7.

Holt ES, Hansen ST, Mayo KA, Sangeorzan BJ. Ankle arthrodesis using internal screw fixation. Clin Orthop 1991; 268: 21-8.

Hong SP, Henderson CN. Articular cartilage surface changes following immobilization of the rat knee joint. A semiquantitative scanning electron-microscopic study. Acta Anat 1996; 157: 27-40.

Huiskes R, Chao EY. A survey of finite element analysis in orthopaedic biomechanics. the first decade. J Biomech 1983; 16: 385-409.

Imhof H, Breitenseher M, Kainberger F, Rand T, Trattnig S. Importance of subchondral bone to articular cartilage in health and disease. Top Magn Reson Imaging 1999; 10: 180-92.

Iwata H, Yasuhara N, Kawashima K, Kaneko M, Sugiura Y, Nakagawa M. Arthrodesis of the ankle joint with rheumatoid arthritis: experience with the transfibular approach. Clin Orthop 1980; 153: 189-93.

Jerosch J, Steinbeck J, Schroder M, Reer R. Arthroscopically assisted arthrodesis of the ankle joint. Arch Orthop Trauma Surg 1996; 115: 182-9.

Jortikka MO, Inkinen RI, Tammi MI, Parkkinen JJ, Haapala J, Kiviranta I, Helminen HJ, Lammi MJ. Immobilisation causes longlasting matrix changes both in the immobilised and contralateral joint cartilage. Ann Rheum Dis 1997; 56: 255-61.

Kahanovitz N, Arnoczky SP, Levine DB, Otis JP. The effects of internal fixation on the articular cartilage of unfused canine facet joint cartilage. Spine 1984; 9: 268-72.

Keaveny TM, Hayes WC. A 20-year perspective on the mechanical properties of trabecular bone. J Biomech Eng 1993; 115: 534-42.

Kennedy JC. Arthrodesis of the ankle joint with particular reference to the Gallie procedure. J Bone Joint Surg (Am) 1960; 42: 1308-16.

Key JA. Positive pressure in arthrodesis for tuberculosis of the knee joint. South Med J 1932; 25: 900-15.

Kienapfel H, Sprey C, Wilke A, Griss P. Implant fixation by bone ingrowth. J Arthroplasty 1999; 14: 355-68.

Kim HK, Kerr RG, Cruz TF, Salter RB. Effects of continuous passive motion and immobilization on synovitis and cartilage degradation in antigen induced arthritis. J Rheumatol 1995; 22: 1714-21.

Kim Y. Prediction of mechanical behaviors at interfaces between bone and two interbody cages of lumbar spine segments. Spine 2001; 26(: 1437-42.

Kitaoka H. Clinical rating systems for the ankle-hindfoot. midfoot, hallux, and lesser toes. Foot Ankle Int 1994; 15: 349-53.

Lane LB, Villacin A, Bullough P. The vascularity and remodeling of subchondral bone and calcified cartilage in adult human femoral and humeral heads. J Bone Joint Surg Br 1977; 59: 272-8.

Lauge-Pedersen H, Knutson K, Rydholm U. Percutaneous ankle arthrodesis in the rheumatoid patient without debridement of the joint. Foot 1998; 8: 226-9.

Levander G. A study of bone regeneration. Surgery 1938; 67: 705-14.

Malinin T, Ouellette EA. Articular cartilage nutrition is mediated by subchondral bone: a long- term autograft study in baboons. Osteoarthritis Cartilage 2000; 8: 483-91.

Mann RA, Rongstad KM. Arthrodesis of the ankle: a critical analysis. Foot Ankle Int 1998; 19: 3-9.

Maroudas A, Bullough P. Permeability of articular cartilage. Nature 1968; 219: 1260-1.

Maurer RC, Cimino WR, Cox CV, Satow GK. Transarticular cross-screw fixation. A technique of ankle arthrodesis. Clin Orthop 1991; 268: 56-64.

Mazhuga PM. [Sources of nutrition and structural regeneration of articular cartilage]. Morfologiia 1999; 115: 43-50.

Mazur JM, Schwartz E, Simon SR. Ankle arthrodesis. Long-term follow-up with gait analysis. J Bone Joint Surg Am 1979; 61: 964-75.

McGuire MR, Kyle RF, Gustilo RB, Premer RF. Comparative analysis of ankle arthroplasty versus ankle arthrodesis. Clin Orthop 1988; 226: 174-81.

Miller RA, Firoozbakhsh K, Veitch AJ. A biomechanical evaluation of internal fixation for ankle arthrodesis comparing two methods of joint surface preparation. Orthopedics 2000; 23: 457-60.

Mital MA, Millington PF. Osseous pathway of nutrition to articular cartilage of the human femoral head. Lancet 1970; 1: 842.

Monroe MT, Beals TC, Manoli A. Clinical outcome of arthrodesis of the ankle using rigid internal fixation with cancellous screws. Foot Ankle Int 1999; 20: 227-31.

Mont MA, Jones LC, Einborn TA, Hungerford DS, Reddi AH. Osteonecrosis of the femoral head.Potential treatment with growth and differation factors. Clin Orthop 1998; 355: 314-35.

Moran CG, Pinder IM, Smith SR. Ankle arthrodesis in rheumatoid arthritis. 30 cases followed for 5 years. Acta Orthop Scand 1991; 62: 538-43.

Morrey BF, Wiedeman GP. Complications and long-term results of ankle arthrodeses following trauma. J Bone Joint Surg Am 1980; 62: 777-84.

Murphy M, Knäuper V, Atkinson S, Butler G, English W, Hutton M, Stracke J, Clark I.

Matrix metalloproteinases in arthritic disease. Arthritis Res 2002; 4: 39-49.

Nasson S, Shuff C, Palmer D, Owen J, Wayne J, Carr J, Adelaar, R, May D. Biomechanical comparison of ankle arthrodesis techniques: Crossed scerws vs. Blade plate. Foot Ankle Int 2001; 22: 575-80

O'Brien TS, Hart TS, Shereff MJ, Stone J, Johnson J. Open versus arthroscopic ankle arthrodesis: a comparative study. Foot Ankle Int 1999; 20: 368-74.

O'Hara BP, Urban JP, Maroudas A. Influence of cyclic loading on the nutrition of articular cartilage. Ann Rheum Dis 1990; 49: 536-9.

Ogata K, Whiteside LA, Lesker PA. Subchondral route for nutrition to articular cartilage in the rabbit. Measurement of diffusion with hydrogen gas in vivo. J Bone Joint Surg Am 1978; 60: 905-10.

Ogilvie-Harris DJ, Fitsialos D, Hedman TP. Arthrodesis of the ankle. A comparison of two versus three screw fixation in a crossed configuration. Clin Orthop 1994; 304: 195-9.

Ottolenghi CE, Animoso J, Burgo PH. Percutaneous arthrodesis of the ankle joint. Clin Orthop 1970; 68: 72-4.

Pauwels F. Eine neue theorie uber den einfluss mechanischer reize auf die differenzierung der stutzgewebe. Z Anat Entwickl-Gesh 1960; 121: 478-515.

Pfahler M, Krodel A, Tritschler A, Zenta S. Role of internal and external fixation in ankle fusion. Arch Orthop Trauma Surg 1996; 115: 146-8.

Pilette S, Huk OL, Yahia L, Fowles JV. [Comparative biomechanical evaluation of the immediate stability of three fixators in arthrodesis of the ankle]. Ann Chir 1993; 47: 905-11.

Prendergast PJ. Finite element models in tissue biomechanics and orthopaedic implant design. Clin Biomech 1997; 12: 343-66.

Ramamurti BS, Orr TE, Bragdon CR. Factors influencing stability at the interface between a porous surface and cancellous bone: a finite element analysis of a canine in vivo micromotion experiment. J Biomed Mater Res 1997; 36: 274-80.

Reddi AH, Huggins C. Biochemical sequences in the transformation of normal fibroblast in adolescent rats. Proc Natl Acad Sci USA 1972; 69: 1601-5.

Rho JY, Hobatho MC, Ashman RB. Relations of mechanical properties to density and CT numbers in human bone. Med Eng Phys 1995; 17: 347-55.

Salter RB. History of rest and motion and the scientific basis for early continuous passive motion. Hand Clin 1996; 12: 1-11.

Saltzman CL. Perspective on total ankle replacement. Foot Ankle Clin 2000; 5: 761-75.

Scranton PE, Fu FH, Brown TD. Ankle arthrodesis: a comparative clinical and biomechanical evaluation. Clin Orthop 1980; 151: 234-43.

Shevtsov VI, Asonova SN. Ultrastructural changes of articular cartilage following joint immobilization with the Ilizarov apparatus. Bull Hosp Jt Dis 1995; 54: 69-75.

Smith EJ, Wood PL. Ankle arthrodesis in the rheumatoid patient. Foot Ankle 1990; 10: 252-6.

Smith RL, Thomas KD, Schurman DJ, Carter DR, Wong M, van der Meulen MC. Rabbit knee immobilization: bone remodeling precedes cartilage degradation. J Orthop Res 1992; 10: 88-95.

Sowa DT, Krackow KA. Ankle fusion: a new technique of internal fixation using a compression blade plate. Foot Ankle 1989; 9: 232-40.

Stone KH, Helal B. A method of ankle stabilization. Clin Orthop 1991; 268: 102-6.

Stranks GJ, Cecil T, Jeffery IT. Anterior ankle arthrodesis with cross-screw fixation. A dowel graft method used in 20 cases. J Bone Joint Surg Br 1994; 76: 943-6.

Szmukler-Moncler S, Salama H, Reingewirtz Y, Dubruille JH. Timing and loading and effect of micromotion on bone-dental implant interface: a review of experimental literature. J Biomed Mater Res 1998; 43: 192-203.

Thermann H, Huefner T, Schratt HE, von Glinski S, Roehler A, Tscherne H. Screw fixation for ankle arthrodesis. Foot Ankle 1999; 5: 131-42.

Thordarson DB, Markolf K, Cracchiolo A. Stability of an ankle arthrodesis fixed by cancellous-bone screws compared with that fixed by an external fixator. A biomechanical study. J Bone Joint Surg Am 1992; 74: 1050-5.

Thordarson DB, Markolf KL, Cracchiolo A. Arthrodesis of the ankle with cancellous-bone screws and fibular strut graft. Biomechanical analysis. J Bone Joint Surg Am 1990; 72: 1359-63.

Turan I, Blomgren G. Ankle arthrodesis by the Heiple technique in rheumatoid arthritis. J Foot Surg 1991; 30: 143-6.

Turan I, Wredmark T, Fellander-Tsai L. Arthroscopic ankle arthrodesis in rheumatoid arthritis. Clin Orthop 1995; 320: 110-4.

Urist MR. Bone formation by autoinduction. Science 1965; 12; 150 698: 893-9.

Vanwanseele B, Lucchinetti E, Stussi E. The effects of immobilization on the characteristics of articular cartilage: current concepts and future directions. Osteoarthritis Cartilage 2002; 10: 408-19.

Vázquez AA. Finite element analysis of ankle joint arthrodesis. MPhil - PhD - Transfer report, University of Southampton 2001; 58-59.

Wolff J. Das Gestz der Transformation der Knochen. Hirschwald, Berlin 1892.

Zannoni C, Mantovani R, Viceconti M. Material properties assignment to finite element models of bone structures: a new method. Med Eng Phys 1998; 20: 735-40.