



LUND UNIVERSITY

Fluorescence Diagnostics of Head and Neck Cancer Utilizing Oral Administration of Delta-amino Levulinic Acid

Svanberg, Katarina; Wang, I; Rydell, R; Elner, A; Wennerberg, J; Clemente, L. P; Cardoso, E; Pratas, R; Clemente, M. P; Andersson-Engels, Stefan; Svanberg, Sune

Published in:

5TH INTERNATIONAL PHOTODYNAMIC ASSOCIATION BIENNIAL MEETING

DOI:

[10.1117/12.203438](https://doi.org/10.1117/12.203438)

1995

[Link to publication](#)

Citation for published version (APA):

Svanberg, K., Wang, I., Rydell, R., Elner, A., Wennerberg, J., Clemente, L. P., Cardoso, E., Pratas, R., Clemente, M. P., Andersson-Engels, S., & Svanberg, S. (1995). Fluorescence Diagnostics of Head and Neck Cancer Utilizing Oral Administration of Delta-amino Levulinic Acid. In DA. Cortese (Ed.), *5TH INTERNATIONAL PHOTODYNAMIC ASSOCIATION BIENNIAL MEETING* (Vol. 2371, pp. 129-141). SPIE.
<https://doi.org/10.1117/12.203438>

Total number of authors:

11

General rights

Unless other specific re-use rights are stated the following general rights apply:

Copyright and moral rights for the publications made accessible in the public portal are retained by the authors and/or other copyright owners and it is a condition of accessing publications that users recognise and abide by the legal requirements associated with these rights.

- Users may download and print one copy of any publication from the public portal for the purpose of private study or research.
- You may not further distribute the material or use it for any profit-making activity or commercial gain
- You may freely distribute the URL identifying the publication in the public portal


Read more about Creative commons licenses: <https://creativecommons.org/licenses/>

Take down policy

If you believe that this document breaches copyright please contact us providing details, and we will remove access to the work immediately and investigate your claim.

LUND UNIVERSITY

PO Box 117
221 00 Lund
+46 46-222 00 00



5TH
INTERNATIONAL PHOTODYNAMIC
ASSOCIATION BIENNIAL MEETING

*The Ritz-Carlton
Amelia Island, Florida, USA*

September 21-24, 1994

Fluorescence diagnostics of head and neck cancer utilizing oral administration of δ -Amino Levulinic Acid

K. Svanberg, I. Wang*

Department of Oncology, Lund University Hospital, Lund, Sweden

R. Rydell, Å. Elner, J. Wennerberg

Department of Oto-Rhino-Laryngology, Lund University Hospital, Lund, Sweden

L. Pais Clemente, E. Cardoso, R. Pratas, M. Pais Clemente

Department of Oto-Rhino-Laryngology, Porto University Hospital, Porto, Portugal

S. Andersson-Engels and S. Svanberg

Atomic Physics Division, Lund Institute of Technology, Lund, Sweden

ABSTRACT

Tissue fluorescence measurements utilizing a point monitoring fluorosensor and a multi-colour fluorescence imaging system were performed in patients with various malignant tumours in the head and neck region. Also precancerous lesions were investigated and characterized by means of laser-induced fluorescence. Oral administration of low-dose δ -amino levulinic acid was used for the induction of protoporphyrin IX, which exhibits a strong fluorescence in the red wavelength region. The blue-green fluorescence emitted from the tissue natural chromophores was also utilized for tumour demarcation. By incorporating both Protoporphyrin IX and natural fluorescence in a tumour demarcation criterion a tumour demarcation with a tumour-to-normal-surrounding-tissue of about 5-10:1 contrast was achieved. Hypertrophic tissue did not exhibit tumour specific signals.

Keywords: ENT-malignancies, laser-induced fluorescence, oral ALA, Protoporphyrin IX sensitization, tumour diagnostics.

INTRODUCTION

Many tumours in the head and neck region can easily be visualized by the naked eye. Also conventional x-ray investigations and CT scanning are used in the diagnostic procedure. As in many other clinical specialities, early lesions in the head and neck area may be difficult to identify. In some cases, patients are presented with loco-regional metastases and the originating foci may be difficult to identify. In such patients a biopsy guiding tool would be of value as well as in situations when biopsy sampling must be restrictive, e.g. in the vulnerable vocal cords.

Fluorescence diagnostics is a non-invasive method for superficial tissue characterization. The method relies on spectral differences in the fluorescence emission from various tissue types.¹⁻⁸ With UV or near-UV light excitation the full fluorescence spectrum can be analyzed and the endogenous tissue fluorescence peaking at about 500 nm as well as the specific fluorescence from exogenously administered sensitizing agents can be included in the tumour demarcation criterion.⁹

The autofluorescence emanates from a variety of different endogenous tissue chromophores. The signal has a broad wavelength distribution with contributions from different fluorophores, such as tryptophane, collagen, elastin, NADH/NAD⁺, flavins and others, each with specific fluorescence characteristics. In spite of a broad emission, the autofluorescence can be utilized in the tumour demarcation criteria since the over-all fluorescence intensity decreases in tumour tissue as compared to normal tissue. Only in a few tumour types, such as scirrotic breast cancer, the autofluorescence intensity shows values comparable to the surrounding normal tissue. In some tumour types, such as in transitional cell carcinoma of the urinary bladder, the emission wavelength maximum is shifted compared to the situation for normal tissue if a short excitation wavelength (e.g. 337 nm) is utilized.

In order to enhance the tumour demarcation, a variety of tumour sensitizing agents has been used. Most of the drugs were developed for photodynamic therapy and only secondarily for the purpose of tumour diagnostics. In particular, haematoporphyrin derivative (Photofrin®) has been utilized. Photofrin is administered intravenously 24-48 hours before the procedure. A well-known side-effect with Photofrin in therapeutical doses is the transient skin sensitisation. For diagnostic purpose, lower doses can be used and the side-effect be avoided, provided that sensitive diagnostic equipment is available.^{10,11} Still the use of Photofrin is somewhat unpractical both what regards the way of administration and the prolonged period between the injection and the investigation. It would be much easier to use a sensitizer with a fast build-up in the tumour within one or two hours and with the possibility to be given orally, maybe already outside the hospital before coming in for the investigation. Another crucial property is, of course, the drug selectivity for tumours. It has been shown that Photofrin has a demarcation of about 2-3:1¹⁰⁻¹² for different kinds of tumours and with the autofluorescence included, a further enhancement with about a factor of 2 is obtained. In order to fulfil the ideal criteria, the sensitizer should exhibit a high uptake ratio tumour-to-normal tissue, show a fast build-up in the tumour and preferably being suitable for oral administration and exhibit only minimal accumulation in the skin and other non-diseased tissue.

Recently, the heme precursor δ -amino levulinic acid (ALA) was introduced for local tumour sensitization in skin malignancies¹³⁻¹⁵ and in the urinary bladder.^{16,17} ALA is the first step in the haem cycle and is transformed in several steps to haem in the organism. The second-last step in the synthesis of haem is protoporphyrin IX (PpIX). Under normal conditions the synthesis of haem is regulated by a feed-back system, controlling the formation of ALA in a condensation process of coenzyme A and glycine, as well as the last step in which the PpIX is transformed to haem with the incorporation of the Fe ion. ALA itself is a straight molecule and thus a non-fluorescent substance. PpIX, on the other hand, has a high fluorescence yield and is also photodynamically very active. The accumulation of PpIX is enhanced in the tumour cells as compared to non-malignant cells, since the contents of the different enzymes regulating the steps in the haem cycle are different.^{18,19}

High oral doses of ALA (30-60 mg/kg b.w.) were administered by Loh²⁰ and Grant²¹ to a few patients with colorectal and oral cancers and a demarcation of the tumours was studied by means of fluorescence microscopy. Several patients with different kinds of malignant tumours in the head and neck region were investigated by us following lower doses of orally administered ALA (5-15 mg/kg b.w.) and some of the results are presented in this paper. A more detailed presentation of the fluorescence investigations is given elsewhere.^{22,23}

The measurements presented in this paper were performed in real time and the build-up of PpIX in the tissue was followed with *in vivo* measurements during a period from the administration until 24 hours *post* the drug delivery. A point-monitoring system as well as an imaging system was used for the recordings.

MATERIALS AND METHODS

About 30 patients with different kinds of malignant and non-malignant tumours in the head and neck region were investigated at different time intervals after the ALA administration. Low doses of ALA varying between 15 and 5 mg/kg b.w. were chosen. The ALA powder (Porphyrin Products, Logan, Utah) was weighted to the right amount and dissolved in about 1 dl of orange juice by careful stirring. The patients were given the full amount directly after the mixing. In 17 patients, investigated at the ENT Department in Porto, the fluorescence investigations were performed from the time 15 minutes up to 24 hours after the ALA administration. In the additional 15 patients the PpIX accumulation was monitored about 2-3 hours *post* administration. A majority of the patients had squamous cell carcinoma located in the oral cavity, in the oropharynx or in the larynx. Several patients with dysplastic areas or carcinoma *in situ* were also investigated. One patient had a malignant non-Hodgkin lymphoma. In the group of non-malignant lesions, chronic laryngitis, hypertrophy or benign papillomatosis were found.

The PpIX build-up in the tissue was monitored by means of laser-induced fluorescence utilizing a point-monitoring, clinically adapted fluorosensor described in detail in Ref. 23. The fluorescence is excited by a pulsed nitrogen laser-pumped dye laser with emission at 405 nm. The excitation light is transmitted to the tissue through a 600 μm fibre, by means of which the generated fluorescence light is also collected and focused onto the entrance slit of a polychromator, where the light is spectrally divided and recorded by an image-intensified diode array. The signal from the diode array is fed into a multi-channel analyzer and the full spectrum is displayed in real-time and stored for further processing and evaluation. Tissue biopsies were taken from the sites for the fluorescence spectral recordings.

In some cases also a multi-colour fluorescence imaging system was used. The system and some initial clinical experience in different fields are described in Refs. 17 and 24. With this system a full image of the tissue area is displayed in real-time. The multi-colour fluorescence image is superimposed on the standard image. Thus, in endoscopic applications the normal investigation can be performed with the visual inspection through the endoscope or the endoscopist uses the image obtained on a monitor with the computer processed fluorescence image superimposed on the normal reflected light colour image. The fluorescence image can be mixed in with a varying weight.

RESULTS

In all malignant tumours, a clear PpIX-related dual-peaked fluorescence signal at about 635 and 700 nm was identified in the fluorescence spectra already about 30 minutes after the ALA administration. The fluorescence in the red wavelength region showed a maximum intensity at about 5-8 hours *post* ALA administration. Also in cases with early non-invasive cancer and precancerous lesions a clear sign of the PpIX fluorescence was recorded. An example of a fluorescence spectrum from a patient with dysplasia of the vocal cord is shown in Fig. 1. A spectrum from normal buccal mucosa recorded at the same time is shown in the same figure. The spectrum from the vocal cord was recorded with the fibre through the working channel of a flexible laryngoscope with the patient sitting in the investigation chair in front of the endoscopist. Only local anaesthesia was administered to the patient immediately before the direct laryngoscopy by applying saturated xylocain-containing cotton pads in the immediate surrounding the *plicae vestibularis*. The measurement was performed 7.5 hours after the oral administration of ALA at a dose of 5 mg/kg b.w. As seen in the spectrum the dysplastic area of the vocal cord is characterized by a marked fluorescence in the red wavelength region with a dual-peaked light emission at about 635 and 710 nm and a very low autofluorescence peaking

at about 500 nm. The spectrum from the buccal mucosa recorded at the same time on the other hand shows a high autofluorescence intensity and no sign of PpIX.

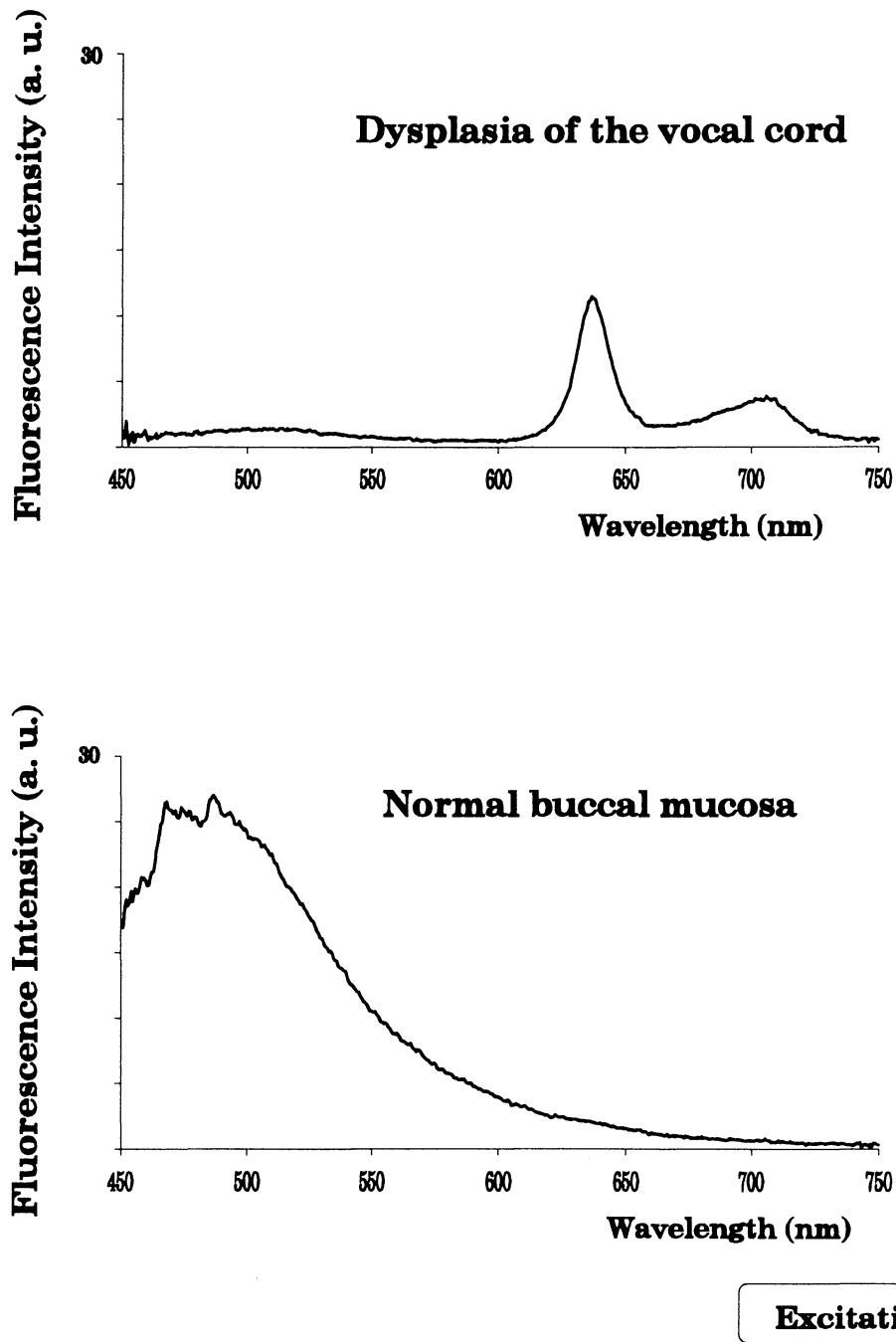


Figure 1. Fluorescence spectra recorded *in vivo* from a dysplastic area of the vocal cord and the buccal mucosa in a patient sensitized with oral ALA at a dose of 5 mg/kg b.w. 7.5 hours earlier. The recordings were performed during direct laryngoscopy with the fibre through the working channel of a flexible laryngoscope. Only local anaesthetics applied in the immediate surroundings of the *plicae vestibularis* was used. The spectrum from the dysplasia is characterized by a clear dual-peaked fluorescence emission at about 635 and 705 nm, which is not seen in the spectrum from the normal buccal mucosa. The autofluorescence in the diseased area is very low as compared to the signal from the normal area.

Another example from a patient with a carcinoma in one of the vocal cords is shown in Fig. 2. This patient had received the same dose of ALA about 2 hours *prior* to the investigation. A clear dual-peaked PpIX-related signal and a weak autofluorescence intensity is seen in the fluorescence emission from the malignant tissue. The other non-diseased vocal cord exhibits no sign of PpIX and a very high autofluorescence intensity. The patient was investigated during anaesthesia. In the patients undergoing the procedure in general anaesthesia several locations in the oro- and hypopharyngeal area, such as the epiglottis, the *vallecula epiglottica* and *vestibulum laryngis* were investigated.

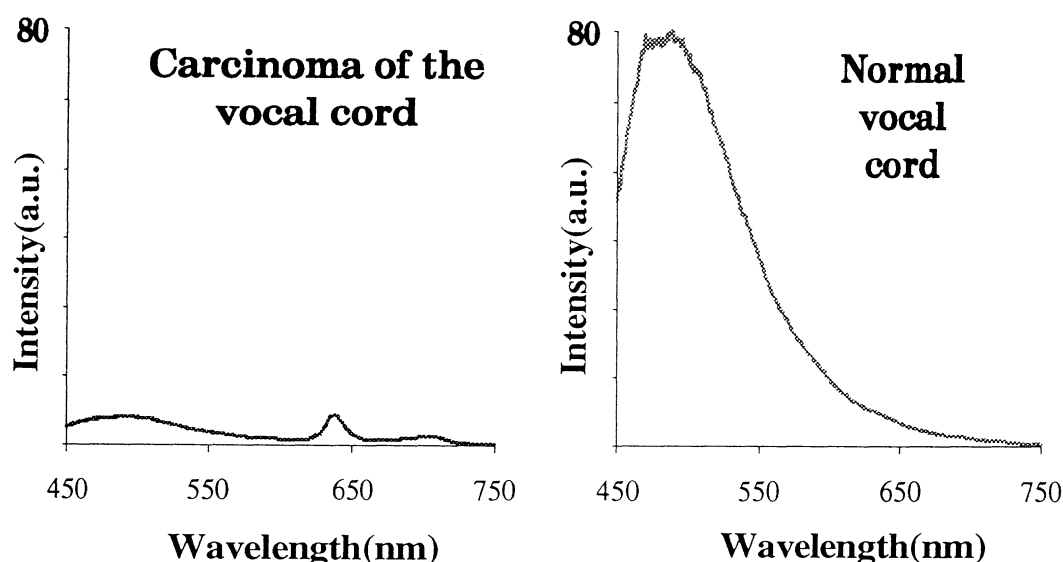


Figure 2. Fluorescence spectra recorded from the surface of a squamous cell carcinoma on the left vocal cord and the normal vocal cord on the other side. The patient had received 5 mg/kg b.w. of oral ALA 2.5 hours *prior* to the investigation. The surface of the glottic carcinoma shows a clear sign of PpIX in the red wavelength and a very low autofluorescence as compared to the surface of the normal vocal cord.

Figure 3 shows a fluorescence image from the same patient. In this figure the two vocal cords are visualized through a straight laryngoscope and the figure is a print-out from the video recorded in real-time during the investigation. The whole area was illuminated by the laser light from a frequency-doubled Alexandrite laser ($\lambda \approx 390$ nm) forming part of a multi-colour fluorescence imaging system (Spectraphos AB, Ideon Research Park, Lund, Sweden). The fluorescence signals are processed pixel by pixel. A contrast function is formed utilizing the background-free fluorescence intensity in the red wavelength region divided by the autofluorescence. A false colour coded image is processed and superimposed on the normal

white light image. The fluorescence image is updated with a rate of about 5 frames/second. One area located in the anterior part of the left vocal cord including the commissure is seen in false colour superimposed on the normal image. Only in this area the "cancer criterion" with a high ratio of fluorescence intensities is fulfilled. The spectral shape of the fluorescence spectrum from one point within this area is shown in the figure above (Figure 2, left).

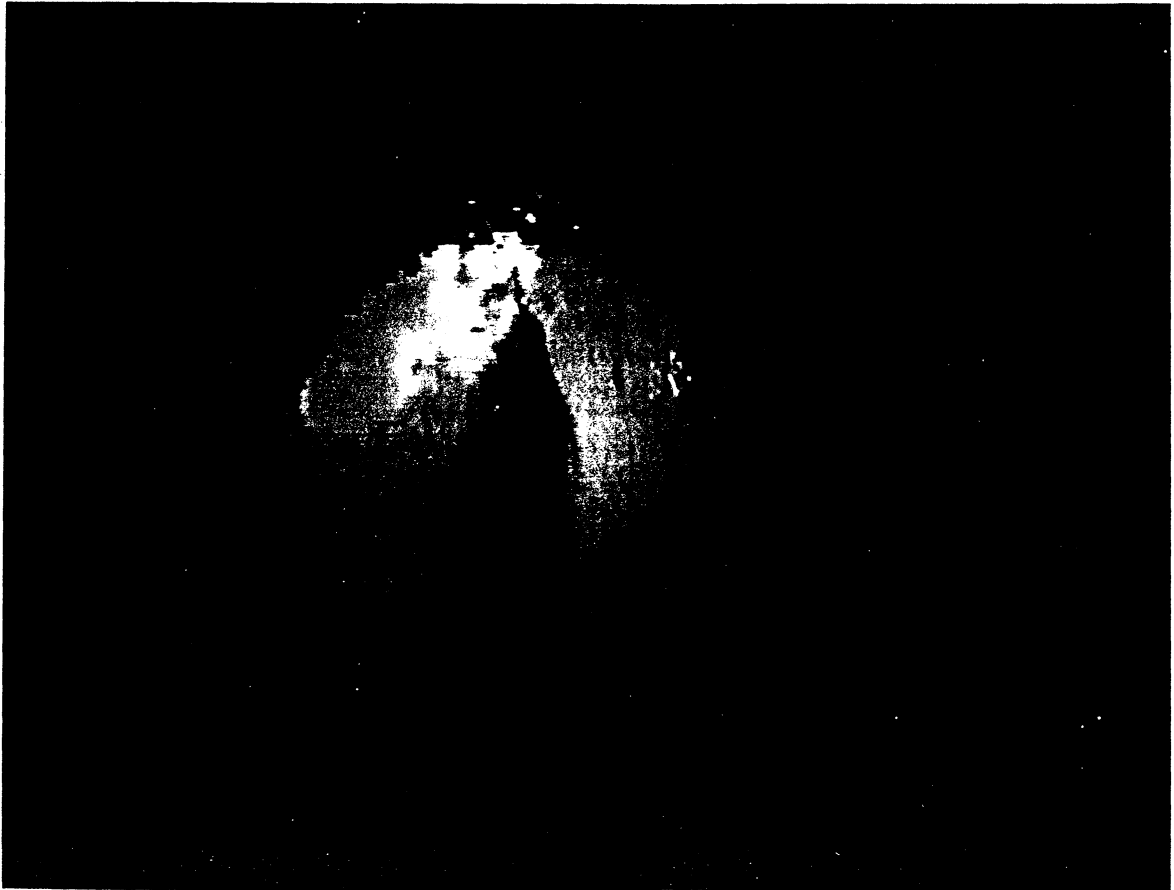


Figure 3. A multi-colour fluorescence image recorded in the vocal cord area with a glottic squamous cell carcinoma of the left vocal cord. The recording is performed in the same patient as presented in Figure 2. The anterior part of the left vocal cord is marked with false-colour added to the normal white-light image. This area fulfils the tumour criterion with a high ratio formed by dividing the fluorescence intensity in the red wavelength region by the autofluorescence intensity.

A third example is from a patient with a T3 squamous cell carcinoma in the oropharyngeal region. The patient was given oral ALA at a dose of 15 mg/kg b.w. and recordings taken at 6 and 8.5 hours are presented in Figures 4 and 5, respectively. In Figure 4 a spectrum recorded from

the tumour as well as spectra from the immediate surrounding mucosa, the tongue and the skin are shown. The tumour is characterized by a dual-peaked PpIX fluorescence. The autofluorescence is very weak as compared to the normal surrounding mucosa with a high intensity peaking at about 500 nm. The skin shows only a small sign of PpIX-related fluorescence as does the tongue.

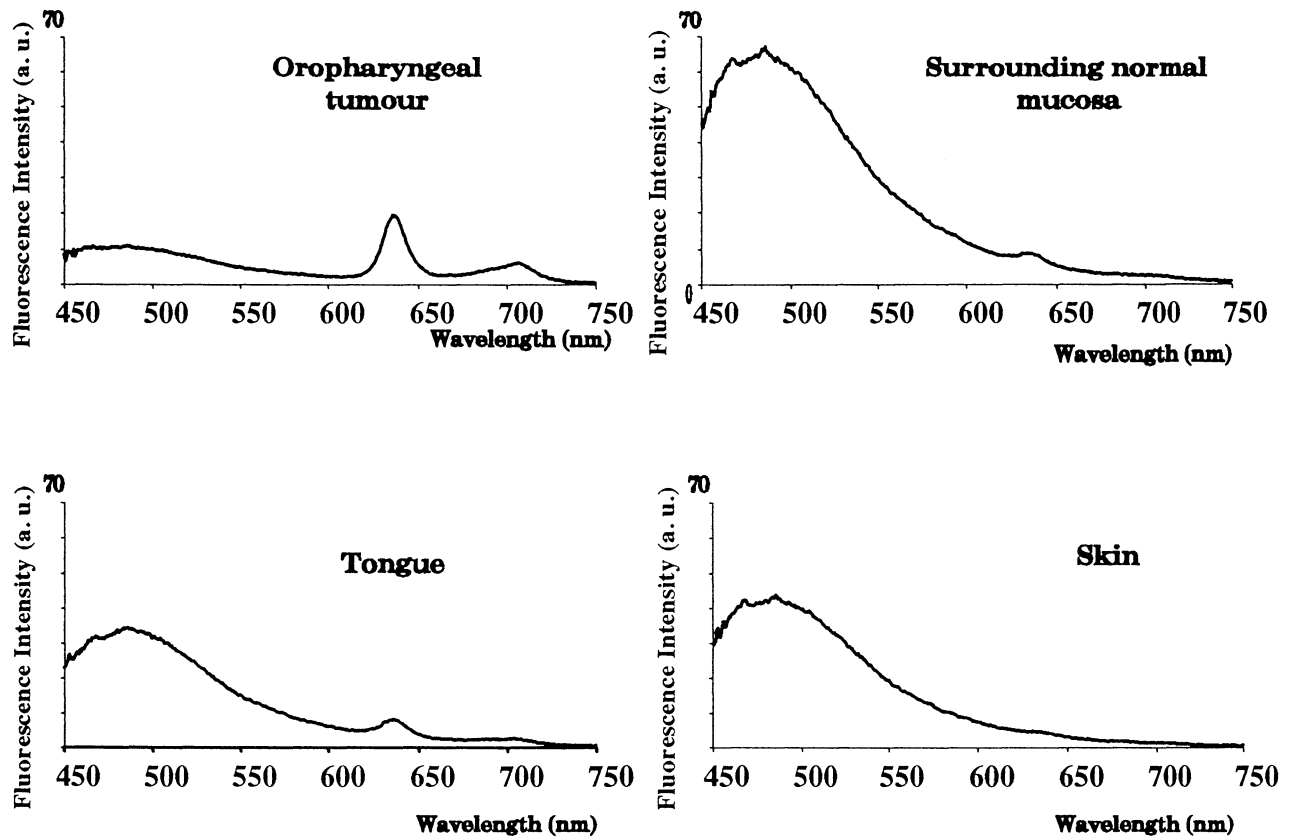


Figure 4. Four fluorescence spectra recorded *in vivo* in a patient with a T3 oropharyngeal tumour. The patient had received oral administration of ALA at a dose of 15 mg/kg b.w. 6 hours *prior* to the investigation. The tumour area is characterized by the PpIX fluorescence and a low autofluorescence. Only a small sign of PpIX-related fluorescence is seen in the tongue and the normal mucosa surrounding the tumour.

Figure 5 shows the fluorescence recordings from the same patient recorded 8 hours after the ALA administration. Spectra are shown from the tumour area with its surrounding mucosa as well as from the nasal mucosa and the tongue. As seen in the figure the tumour area was investigated by a scan monitoring the tumour and its border as well as the mucosal tissue 10 and 5 mm outside the tumour border. All tumour spectra are characterized by a low autofluorescence signal. PpIX-related fluorescence is strongest in the tumour centre. In the

spectrum from the nasal mucosa a PpIX-related signal is seen. The spectrum from the tongue also shows a sign of PpIX.

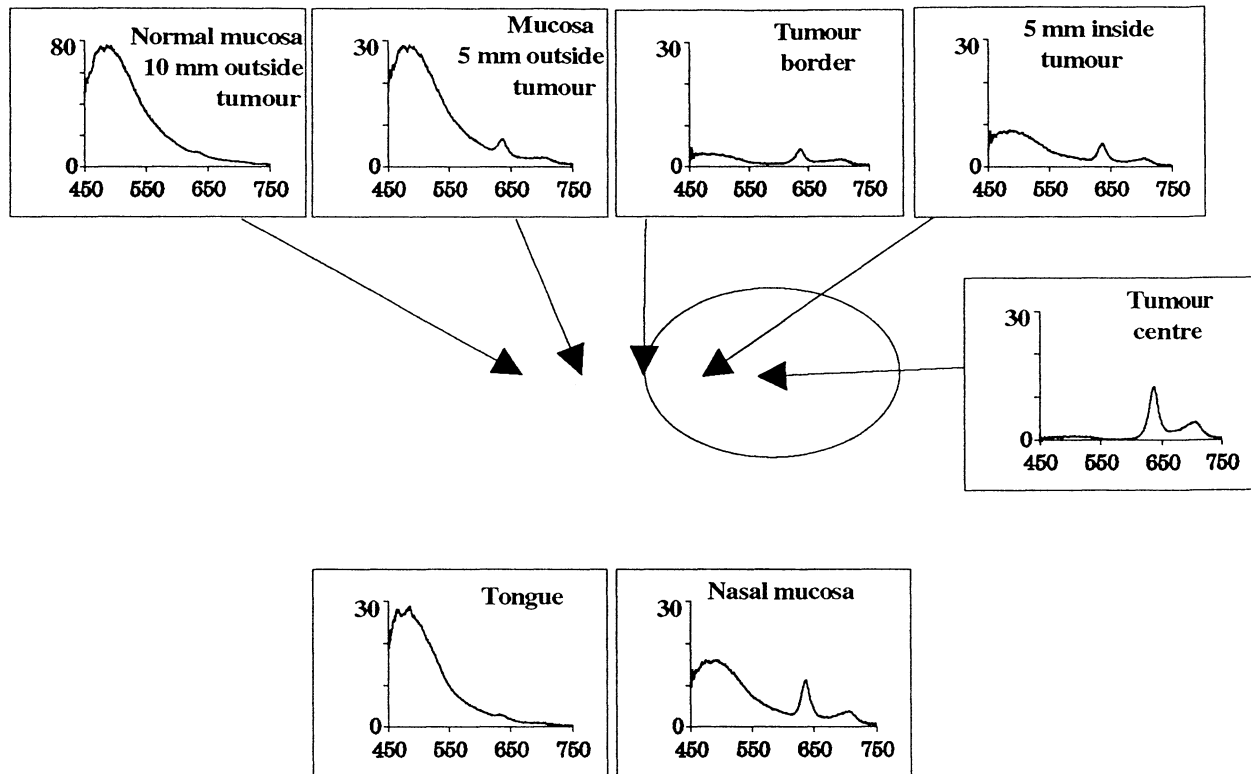


Figure 5. Fluorescence spectra from a patient with a T3 squamous cell carcinoma in the oropharyngeal area (the same patient as presented in Figure 4). The measurements were performed 8 hours *post* oral administration of ALA at a dose of 15mg/kg b.w. The tumour and surrounding tissue were monitored in a scan with the fibre placed in along a line from a point 10 mm outside the visible tumour border to the tumour centre. The PpIX signal is seen in the tumour spectra and also to a certain degree in the spectrum 5 mm outside the tumour border. The autofluorescence shows a low intensity only in the tumour area. The nasal mucosa exhibits a PpIX-related signal, which is not seen in the normal mucosa of the tongue.

The evaluated data for 7 patients who went through an endoscopic investigation only with local anaesthesia applied in the immediate surrounding of the *plicae vestibularis* are shown in Table I. The patients had received 5 or 15 mg/kg b.w. of ALA orally and were investigated with a flexible laryngoscope. The endoscopic procedure took place 6-8 hours after the ALA administration. Two patients (No. 1 and 6) had advanced squamous cell carcinomas in the oropharynx and the epiglottis. Early tumours and precancerous lesions were found in 3 patients (No. 3, 5 and 7). Two patient (No. 2 and 4) had non-malignant diseases. The fluorescence intensity at 635 and 490 nm is evaluated and expressed in terms of an internal reference. In all patients a low PpIX-related fluorescence intensity at 635 nm was found in the measurements from normal tissue except in one patient (No. 6). The autofluorescence shows in all the patients with cancerous or precancerous lesions lower intensity in diseased tissue as compared to normal tissue. The ratio of the intensity at 635 and 490 nm shows a high value in the advanced tumours. For patient no.

3 with dysplastic tissue a high ratio was also found. The tumour demarcation ratio is high in all patients including the patients with dysplasia. In the patient with benign hypertrophia of the false cord the ratio between the lesion and normal tissue does not show any demarcation.

Table I. Evaluated fluorescence data recorded *in-vivo* in seven patients with different kinds of malignant, premalignant and benign lesions in the head-and neck area. The patients were pre-treated with oral administration of ALA at two different ALA doses 6-8 hours before the endoscopic investigation

Tissue studied	Dose ALA	Time post ALA intake	Intensity 635 nm	Intensity 490 nm	Intensity ratio 635/490
Patient nr 1:	15 mg	6 h			
Squamous cell carcinoma in the oropharynx			0.62	0.11	5.9
Normal soft palate			0.25	4.95	0.05
Patient nr 2:	5 mg	7 h			
Hypertrophic false cord			0.69	4.29	0.16
Normal false cord			0.52	3.02	0.17
Normal buccal mucosa			0	3.30	0
Patient nr 3:	5 mg	7.5 h			
Dysplasia at the vocal cord			1.61	0.22	7.3
Carcinoma <i>in situ</i> at the vocal cord			0.42	1.10	0.38
Normal buccal mucosa			0	3.38	0
Patient nr 4:	5 mg	8 h			
Squamous papilloma at the vocal cord			0	20.80	0
Normal buccal mucosa			0	8.06	0
Patient nr 5:	5 mg	7 h			
Dysplasia vocal cord			0.11	0.13	0.85
Normal epiglottic mucosa			0.19	2.20	0.08
Normal buccal mucosa			0	10.47	0
Patient nr 6:	5 mg	8 h			
Squamous cell carcinoma of epiglottis			0.15	0.01	15
Normal buccal mucosa			3.74	7.37	0.51
Patient 7:	5 mg	8 h			
Dysplasia at the false vocal cord			0.48	0.73	0.66
Normal buccal mucosa			0	8.53	0

DISCUSSION

Laser-induced fluorescence is a technique for real-time non-invasive tissue characterization. The fluorescence emission from tissue exhibits alterations in the spectral signature very early in the biological process when normal tissue is affected by different kinds of diseases. Besides the utilization of the tissue fluorescence also different fluorescing sensitizing agents can be used. Recently, the endogenous sensitization utilizing the haem cycle in the body for the ALA-induced PpIX sensitization was introduced. The PpIX build-up is enhanced in tumour tissue as compared to normal non-diseased tissue due to an altered enzyme pattern in malignant tissue. For a maximal tumour demarcation utilizing ALA sensitization the administration dose has to be kept low; otherwise the bioavailability in normal tissue is too high. In our study of different kinds of malignancies in the head and neck region we have identified an ALA dose of 5-7.5 mg/kg b.w. to be optimal for tumour demarcation.

In tumour diagnostics early identification of tumour growth is important. As LIF is non-invasive with the potential of being a technique for the detection of early changes in biological tissue the method is promising. The concept of utilizing spectral tissue identification has been called "optical biopsy". The clinical research where the correlation between the spectral signature and the histopathology is found is very important for the evaluation of the selectivity and sensitivity of the method. It is important to develop the method as a guiding tool for the biopsy sampling, which in many clinical situations is performed blindly. In such cases early tumour growth might otherwise be overseen and diagnosed only later.

ACKNOWLEDGEMENTS

This project was financially supported by the Swedish Cancer Foundation, the Swedish Research Council for Engineering Sciences, the Kamprad Foundation. Society. Generous grants were also provided from the Medical Council of the Portuguese Government. The valuable support from Dick Killander and other members of the Lund University Medical Laser Centre, and the collaboration with Sune Montan within the field of multi-colour imaging are highly appreciated.

REFERENCES

1. J. Ankerst, S. Montán, K. Svanberg and S. Svanberg, "Laser-induced fluorescence studies of haematoporphyrin derivative (HPD) in normal and tumour tissue of rat", *Appl. Spectros.*, Vol. 38, pp. 890-896, 1984.
2. R.R. Alfano, B.T. Darayash, J. Cordero, P. Tomashesky, F.W. Longo and M.A. Alfano, "Laser-induced fluorescence spectroscopy from native cancerous and normal tissue," *IEEE J. Quantum Electron.*, Vol. 20, pp. 1507-1511, 1984.
3. K. Svanberg, E. Kjellén, J. Ankerst, S. Montán, E. Sjöholm and S. Svanberg, "Fluorescence studies of hematoporphyrin derivative in normal and malignant rat tissue", *Cancer Res.*, Vol. 46, pp. 3803-08, 1986.
3. Y. Yang, Y. Ye, F. Li and P. Ma, "Characteristics autofluorescence for cancer diagnosis and its origin", *Lasers Surg. Med.*, Vol. 7, p. 528, 1987.

4. H. Kato, K. Aizawa, J. Ono, C. Konaka, N. Kawate, K. Kinoshita, K. Nishimiya, H. Sakai, M. Noguchi, T. Tomono, S. Kawasaki, Y. Tokuda and Y. Hayata, "Clinical measurement of tumor fluorescence using a new diagnostic system with haematoporphyrin derivative, laser photoradiation, and a spectroscope", *Lasers Surg. Med.*, Vol. 4, pp. 49-58, 1984.
5. H. Kato and D.A. Cortese, "Early detection of lung cancer by means of haematoporphyrin derivative fluorescence and laser photoradiation", *Clin. Chest Med.*, Vol. 6, pp. 237-253, 1985.
6. A.E. Profio and O.J. Balchum, "Fluorescence diagnosis of cancer", in: *Methods in Porphyrin Photosensitization*, p. 43, D. Kessel, ed., Plenum, New York, 1985.
7. A.E. Profio, "Review of fluorescence diagnosis using porphyrins", *SPIE*, Vol. 905, 11, 1988.
8. S. Andersson-Engels, Å. Elner, J. Johansson, S.-E. Karlsson, L. G. Salford, L.-G. Strömblad, K. Svanberg and S. Svanberg, "Clinical recording of laser-induced fluorescence spectra for evaluation of tumour demarcation feasibility in selected clinical specialities", *Lasers Med. Sci.*, Vol. 6:415, pp. 415-424, 1991.
9. S. Andersson-Engels, J. Johansson, U. Stenram, K. Svanberg and S. Svanberg, "Malignant tumor and atherosclerotic plaque diagnosis using laser-induced fluorescence", *IEEE J. Quantum Electron.*, Vol. 26, pp. 2207-2217, 1990.
10. S. Lam, B. Palcic, D. McLean, J. Hung, M. Korbely and A.E. Profio, "Detection of early lung cancer using low dose Photofrin II", *Chest* Vol. 97, pp. 333-37, 1990.
11. L. Baert, R. Berg, B. van Damme, M.A. D'Hallewin, J. Johansson, K. Svanberg and S. Svanberg, "Clinical fluorescence diagnosis of human bladder carcinoma following low-dose Photofrin injection" *Urology* Vol. 41, pp. 322-30, 1993.
12. T. Andersson, R. Berg, J. Johansson, D. Killander, K. Svanberg, S. Svanberg and Yang Yuanlong, "Photodynamic therapy in interplay with fluorescence diagnostics in the treatment of human superficial malignancies", *SPIE*, Vol. 1645, 1992.
13. J.C. Kennedy and R.H. Pottier, "Photodynamic therapy with endogenous protoporphyrin IX: basic principles and present clinical experience", *J Photochem. Photobiol.*, Vol. 6, pp. 143-48, 1990.
14. J.C. Kennedy and R.H. Pottier, "Endogenous protoporphyrin IX, a clinically useful photosensitizer for photodynamic therapy", *J Photochem. Photobiol.*, Vol. 14, pp. 275-92, 1992.
15. K. Svanberg, T. Andersson, D. Killander, I. Wang, U. Stenram, S. Andersson-Engels, R. Berg, J. Johansson and S. Svanberg, "Photodynamic therapy of non-melanoma malignant tumours of the skin using topical δ -amino levulinic acid sensitization and laser irradiation", *British Journal of Dermatology*, Vol. 130, pp. 743-751, 1994.
16. M. Kriegmair, R. Baumgartner and A. Hofstetter, "Intravesikale Instillation von Delta-Aminolävulinsäure (ALA) - Eine neue Methode zur Photodynamischen Diagnostik und Therapie", *Lasermmedizin*, Vol. 8, p. 8, 1992.
17. K. Svanberg, I. Wang, S. Colleen, I. Idvall, Ch. Ingvar, R. Lundgren, R. Rydell, D. Jocham, A. Knipper, S. Thomas, H. Diddens, S. Bown, G. Gregory, S. Montán, I. Jonsson, S. Andersson-Engels and S. Svanberg, "Clinical Multi-colour fluorescence imaging of malignant tumours - Initial experience", To appear.

18. H.A. Dailey and A. Smith, "Differential interaction of porphyrins used in photoradiation therapy with ferrochelatase", *J. Biochem.*, Vol. 223, pp. 441-45, 1984.
19. L. Leibovici, N.I.L.I. Schoenfeld, H.A. Yehoshua, R. Mamet, R. Rakowski, A. Shindel and A. Atsmon., "Activity of porphobilinogen deaminase in peripheral blood mononuclear cells of patients with metastatic cancer", *Cancer*, Vol. 62, pp. 2297-2300, 1988.
20. C.S. Loh, A.J. MacRobert, J. Bedwell, J. Regula, N. Krasner and S.G. Bown, "Oral versus intravenous administration of 5-aminolaevulinic acid for photodynamic therapy", *British J Cancer*, Vol. 68, pp. 41-51, 1992.
21. W.E. Grant, C. Hopper, A.J. MacRobert, P.M. Speight and S.G. Bown "Photodynamic therapy of oral cancer: photosensitisation with systemic aminolaevulinic acid", *The Lancet*, Vol. 142, pp. 147-148, 1993.
22. L. Pais Clemente, E. Cordosa, R. Pratas, M. Pais Clemente, I. Wang, K. Svanberg, S. Svanberg, "Fluorescence diagnostics and kinetics studies in head and neck cancers utilizing oral administration of δ -amino levulinic acid sensitization", To appear.
23. R. Rydell, Å. Elner, J. Wennerberg, I. Wang, S. Andersson-Engels, S. Svanberg and K. Svanberg, "Fluorescence investigations of early and invasive cancer in the head and neck region with oral administration of δ -amino levulinic acid" To appear.
24. S. Andersson-Engels, J. Johansson and S. Svanberg. "Medical diagnostic system based on simultaneous multi-spectral fluorescence imaging", *Applied Optics* (in press), 1994.

* Fellow of the Norwegian Cancer Foundation