



LUND UNIVERSITY

Teflon Paste Injection into the Paralytic Vocal Fold

Kitzing, Peter

Published in:
Scandinavian Journal of Respiratory Diseases

1977

[Link to publication](#)

Citation for published version (APA):
Kitzing, P. (1977). Teflon Paste Injection into the Paralytic Vocal Fold. *Scandinavian Journal of Respiratory Diseases*, 58(4), 197-204. <http://www.ncbi.nlm.nih.gov/pubmed/594700>

Total number of authors:
1

General rights

Unless other specific re-use rights are stated the following general rights apply:
Copyright and moral rights for the publications made accessible in the public portal are retained by the authors and/or other copyright owners and it is a condition of accessing publications that users recognise and abide by the legal requirements associated with these rights.

- Users may download and print one copy of any publication from the public portal for the purpose of private study or research.
- You may not further distribute the material or use it for any profit-making activity or commercial gain
- You may freely distribute the URL identifying the publication in the public portal

Read more about Creative commons licenses: <https://creativecommons.org/licenses/>

Take down policy

If you believe that this document breaches copyright please contact us providing details, and we will remove access to the work immediately and investigate your claim.

LUND UNIVERSITY

PO Box 117
221 00 Lund
+46 46-222 00 00

Teflon Paste Injection into the Paralytic Vocal Fold

A Simple Procedure to Improve Disturbed Cough Function

PETER KITZING & ANDERS LÖFQVIST

Department of Phoniatics, ENT-Clinic, University Hospital, Malmö, and
Department of Phonetics, Lund University, Lund, Sweden

Teflon paste injection into the paralytic vocal fold is a simple method for the relief of difficulties with insufficient expectoration and for the prevention of aspiration caused by laryngeal paralysis. The laryngeal valve and voice functions in three patients with unilateral laryngeal paralysis were studied before and after teflon paste injection. Aerodynamic registrations comprised subglottal and supraglottal air pressure and oral air flow during cough and phonation. The aerodynamic records, as well as the patients' own reports, all showed improved laryngeal valve function as a result of the treatment and these improvements were not accompanied by any deterioration in respiratory function as revealed by pre- and postoperative spirometry.

Key words: cough - teflon - vocal cord paralysis

Accepted for publication 18 February 1977

Patients with laryngeal paresis commonly suffer from hoarseness and disturbances of swallowing and coughing. Respiratory problems, both inspiratory and expiratory, caused by increased laryngeal resistance regularly occur in bilateral paralysis of the recurrent laryngeal nerve but are less common in cases of unilateral paralysis (Schiratzki 1965). The dysphagia as well as the liability to aspiration and supervening pneumonias might be misinterpreted to emanate from chest disease, e.g. bronchial cancer, even if the paralysis of the laryngeal valve function is the major cause of the patient's discomfort.

One of the most common causes of non-traumatic laryngeal paresis is malignant disease in the thorax or neck (Parnell & Brandenburg 1970). More than 50% of all cases of bronchial carcinoma are regarded as unsuitable for surgical treatment (Carlens et al. 1963). Because of tumour progress many patients develop a laryngeal paresis at later stages of their disease. The number of this type of laryngeal paresis can be expected to grow, as the life-expectancy of patients with inoperable carcinomas is increasing due to the development of more efficient therapy.

The method of intracordal injection as

a treatment for vocal cord paralysis was first described by Brünings (1911) who used paraffin. Arnold (1962) found that teflon particles suspended in glycerine* was the most suitable substance for this purpose.

Initial apprehensions that the particles would migrate or be cancerogenic have not been substantiated though the method has been in regular practice during the last 15 years (Lewy 1976).

The aim of this paper is to draw attention to teflon paste injection into the paralytic vocal fold as a simple laryngologic method for the relief of difficulties with insufficient expectoration and with aspiration caused by one-sided laryngeal paralysis. The effect of the treatment on the sphincter and phonatory functions of the larynx is illustrated by pressure-flow studies before and after the teflon paste injection.

PATIENTS AND METHODS

The teflon paste injections were undertaken through a suspension laryngoscope with the patient in general intubation narcosis. The operation field was illuminated and magnified by an operating microscope (a method usually referred to as microlaryngoscopy) yielding perfect control of the bulging of the vocal fold during injection as well as the possibility for photographic documentation of the procedure (Figure 1). Some weeks before the definitive teflon paste injection, which cannot be removed, all patients had a trial

injection with sterile glycerine, which is totally absorbed by the tissues within some days.

Measurements

Spirometry was carried out before and after the injection according to standardized methods (Berglund et al. 1963). In addition, recordings of subglottal air pressure, supraglottal air pressure and oral air flow were made. The experimental arrangement is illustrated in Figure 2. The frequency response of the recording system was flat from 0–20 Hz. Calibration of the system was made before and after each recording and during the experiments the patient's nose was clamped manually.

The patients were required to cough and to phonate on a neutral vowel at a comfortable pitch and intensity. The two tasks were repeated at least five times on each occasion.

During the coughs the maximal value of the difference between subglottal and supraglottal air pressure was measured. During phonation transglottal pressure and flow show rapid fluctuations related to the vibrations of the vocal folds and the opening and closing of the glottis (Kitzing & Löfqvist 1975). These variations could not be registered with the present instrumentation and hence only the mean values of pressure and flow were measured and used for the calculations of laryngeal resistance, defined here as

$$\frac{\Delta P \text{ cm H}_2\text{O}}{V \text{ l/s}}$$

The measurements were made every 0.25 s during the periods of phonation since the aerodynamic parameters vary somewhat with fundamental frequency and intensity of voice.

* Commercially available as Ethicon Polytef Paste, manufactured by Ethicon, Sommerville, N.J., USA. The teflon paste used in the present study was supplied by Johnson & Johnson AB, Sollentuna, Sweden.

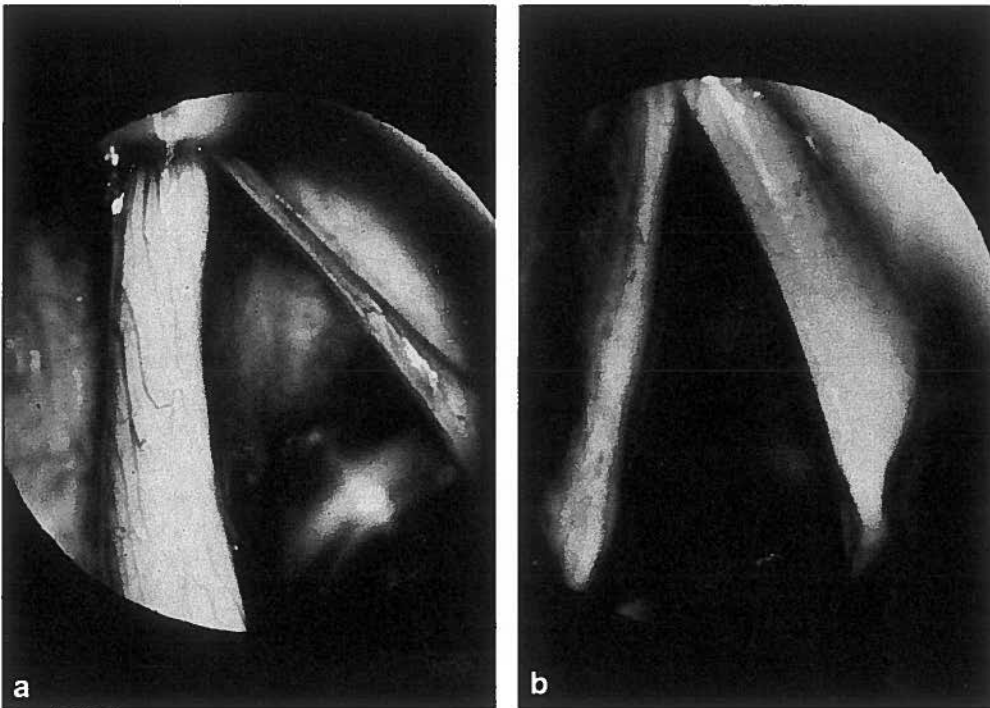


Figure 1. Photographs from direct microlaryngoscopy. Patient S.N. Preoperatively the paralyzed left vocal fold is seen to be excavated and atrophied. After teflon paste injection there is some bulging of the fold. The site of injection can be seen laterally.

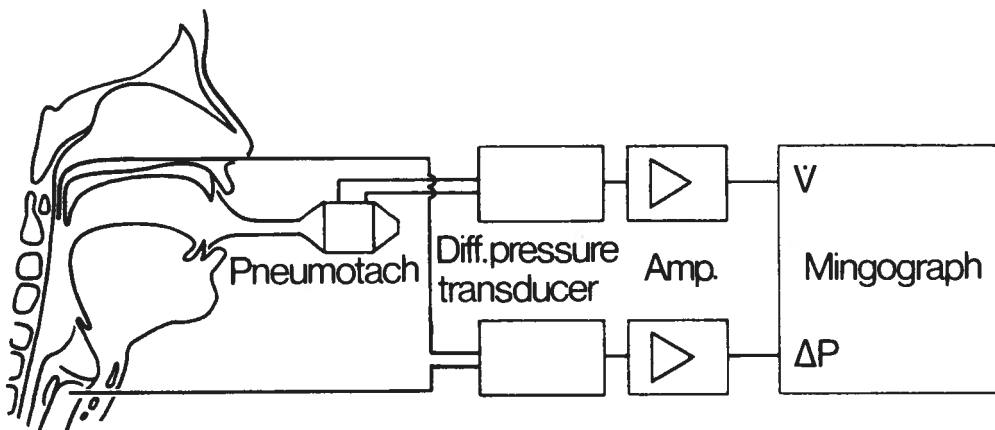


Figure 2. Experimental arrangement. — The air pressure above and below the vocal folds is registered at the same time as the air flow at the outlet of the mouth. The difference between subglottal and supraglottal pressure and the air flow are recorded on an ink-recorder.

Ideally, laryngeal resistance should be studied at constant fundamental frequency and intensity of voice. This could not be done in the present case, however, since the injection of teflon causes such a change in voice quality that the patient cannot maintain the same fundamental frequency and intensity pre- and postoperatively. Laryngeal resistance was therefore only calculated during those periods of phonation where a stable air flow of 0.3 l/s occurred. The value of 0.3 l/s was chosen to cover both the pre- and postoperative range.

Patients

1. A woman aged 73 years and suffering from mild diabetes mellitus complained of hoarseness, dysphagia and difficulty in coughing. Laryngologic examination 6 months after onset of illness showed an excavated, slack, parietic left vocal fold in intermediate position and a 2-mm-wide opening of the glottis during phonation. Stroboscopy revealed no glottic waves and electromyography showed complete denervation of the paralytic vocal fold. No spontaneous recovery occurred and 0.2 ml of teflon paste was injected 1.5 years after onset of paralysis. Upon control 1 year after the injection all the problems caused by the paralysis had disappeared.

2. A 50-year-old woman with left-sided vocal fold paralysis due to thyroidectomy carried out 10 years earlier. She reported dysphagia and problems in coughing together with varying degrees of hoarseness. Laryngologic examination revealed the left vocal fold to be immobilized in paramedian position, atrophied, thin and without glottic waves during phonation. The left arytenoid cartilage was found to be slightly tilting forward. Injection of 0.25 ml of

teflon paste. The patient remained in voice therapy after the injection but the voice had become normal 8 months after the injection and therapy was ended.

3. A 20-year-old girl suffering from neurofibromatosis (von Recklingshausen's disease) according to diagnosis made at the age of five. At 14 years she had spastic paresis in both lower extremities and a right-sided paresis of the recurrent laryngeal nerve. One year later right-sided ocular abducens paresis occurred together with central facial paresis on the left side. Non-radical extirpation of a menigeoma on the spinal cord at the level of C V and Th I was carried out leading to general improvement of motor functions. She complained that her voice was too weak for the work she was preparing for and that she could not cough when she had a cold. Examination showed a slack, thin, atrophied left vocal fold in paramedian position without any glottic waves during phonation and a glottal chink 1 mm wide. 0.2 ml of teflon paste was injected 6 years after the onset of paralysis. Her voice improved and she showed complete recovery upon examination 3 months after the injection.

RESULTS

The results are summarized in Tables 1-2. Spirometry shows about the same values before and after the injection. During coughs the maximal difference between subglottal and supraglottal pressure shows an increase after the injection. For phonation the general trend is that the pressure-drop across the larynx increases, air flow decreases and hence laryngeal resistance increases as a result of the injection of teflon paste. The results show some inter-

TABLE 1

Results of spirometry before and after teflon paste injection.

Subject (sex, age at operation)	VC		MVV _F		FEV ₁		FIV ₁	
	1 Preop.	1 Postop.	1 Preop.	1 Postop.	1 Preop.	1 Postop.	1 Preop.	1 Postop.
K.O. ♀ 73	1.74	1.93	56	46	1.42	1.44	1.63	1.60
E.S. ♀ 52	3.15	3.26	66	64	2.66	2.82	2.11	2.39
S.N. ♀ 20	3.31	2.63	83	86	2.58	2.25	2.74	2.47

VC = Vital capacity.

MVV_F = Maximal voluntary ventilation per minute.FEV₁ = Forced expiratory volume during first second.FIV₁ = Forced inspiratory volume during first second.

individual variation with patient K.O. presenting the most pronounced differences pre- and postoperatively.

DISCUSSION

To an experienced laryngologist the injection of a vocal fold is a very simple procedure. Care must be taken not to overinject as this might result in the disturbance of voice or even respiratory function if the glottis becomes too narrow. There is no method for removing abundant material once it is injected without causing serious

damage to the vocal fold. Other pitfalls of the method are discussed by Rubin (1975). To avoid such complications, the three patients reported on here all had a trial injection with pure glycerine, a substance which is completely absorbed by the tissues after about 2 days. All three patients were very content with the results of this test and once they had experienced the possibility of an improvement of their laryngeal valve and voice function they were eager to get their definitive treatment. In the final examinations the injected amount of teflon paste seemed to be somewhat too

TABLE 2

Maximal difference between subglottal and supraglottal pressure during cough; difference between subglottal and supraglottal pressure and air flow during phonation, and glottal resistance during phonation calculated at an air flow of 0.3 l/s.

Subject		Cough		Phonation			Phonation		
		Δ P cm H ₂ O Preop.	Postop.	Δ P cm H ₂ O Preop.	Postop.	V l/s Postop.	Preop.	Δ P/V Preop.	Postop.
K.O.	\bar{x}	0.7	31.8	0.5	13.3	0.4	0.2	1.3	49.3
	s	0.5	4.0	0.1	4.4	0.1	0.03	0.4	18.9
E.S.	\bar{x}	18.1	31.3	4.3	4.4	0.3	0.2	13.1	19.1
	s	2.8	3.1	1.3	1.6	0.04	0.07	3.8	5.9
S.N.	\bar{x}	10.3	15.8	3.7	6.5	0.4	0.3	9.6	22.8
	s	0.5	1.3	1.0	1.2	0.07	0.05	1.0	4.2

small, and this impression was also substantiated by the results of the aerodynamic measurements.

Nevertheless, the patients' own reports and the aerodynamic registrations revealed a marked improvement in laryngeal valve function during cough and phonation as a result of the injection. At the same time it should be emphasized that these improvements are not accompanied by any deterioration in respiratory function as shown by spirometry before and after the treatment.

The ability to make a sufficient glottal closure is a prerequisite for normal expectoration. This ability had improved as evidenced by the greater difference between subglottal and supraglottal pressure developed after the injection. The values encountered postoperatively in this study are, however, still reduced in comparison with the mean value of 50 cm H₂O reported for normal subjects by Yanagihara et al. (1966). On the other hand, the same authors found that the range in normal subjects varied from 22 to 72 cm of water and two of the present patients fall within this range after the injection of teflon paste.

The reduction of air flow during phonation following the treatment is in agreement with other studies of this parameter under similar conditions (von Leden et al. 1967, Fritzell et al. 1974), but the present values have not decreased to the range of 0.07–0.18 l/s reported for normal subjects by Isshiki & von Leden (1964).

Another result of improved glottal closure during phonation is an increase in laryngeal resistance. Comparable data on laryngeal resistance are scarce. Isshiki (1964) investigated one normal subject and found laryngeal resistance to vary

between 20 and 150 acoustical ohms (1 acoustical ohm = 1.02 cm H₂O/l/s) depending on fundamental frequency and intensity. Isshiki & von Leden (1964) reported a value of 15 acoustical ohms during phonation for a patient with unilateral laryngeal paralysis compared with 13–35 acoustical ohms during whisper in a normal subject. In the present case the values of laryngeal resistance all fell below the range given by Isshiki (1964) before the injection but increased to within the lower part of the range postoperatively.

The rather large interindividual variations encountered for the various parameters under investigation are not too surprising if the varying conditions of the individual patients are taken into account. Specifically, patient K.O. whose left vocal cord was in an intermediate position showed considerable improvement in laryngeal valve function. At the same time it is important to note that even normal subjects display similarly large interindividual variability in air flow rates during phonation (Isshiki & von Leden 1964, Iwata et al. 1972).

The improvement in laryngeal voice function is further illustrated in Figure 3, showing spectrograms (frequency and intensity versus time) of patient K.O. reading a passage pre- and postoperatively. Before the injection the higher frequencies mostly contained noise components due to turbulence created at the glottis but the noise had disappeared after the injection and the same frequencies showed harmonic components. This is in accordance with the findings of Rontal et al. (1975).

In conclusion, all three patients under investigation showed a notable improvement of the sphincter and phonatory functions of the larynx after the injection of

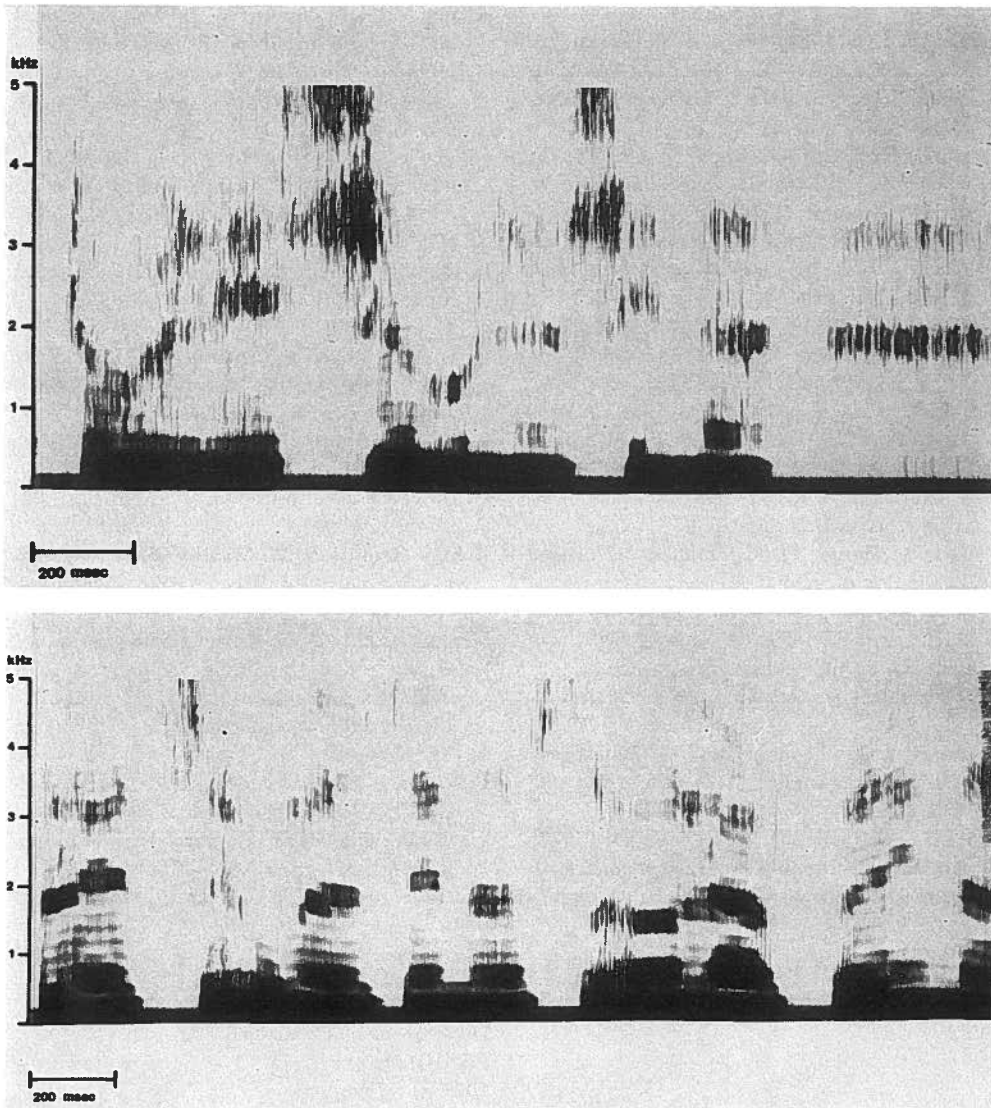


Figure 3. Voice spectrograms of patient K.O. reading a passage preoperatively (top) and postoperatively (bottom). Preoperative noise components at higher frequencies disappear after teflon paste injection and harmonic components can be seen in the normalized voice.

teflon paste into their paralytic vocal folds. When expectorations lack sufficient force and there is a tendency for aspiration in cases of malignant disease in the thorax or neck, the possibility of a laryngeal paralysis should be taken into consideration.

Even patients with inoperable cancer and relatively short life-expectancy should be offered the symptom relief which can be accomplished by the simple procedure described here.

REFERENCES

- Arnold, G. E. (1962) Vocal rehabilitation of vocal dysphonia. IX. Technique of intracordal injection. *Arch. Otolaryng.* **76**, 358–368.
- Berglund, E., Birath, G., Bjure, J., Grimby, G., Kjellmer, J., Sandqvist, L. & Söderholm, B. (1963) Spirometric studies in normal subjects. I. Forced expirograms in subjects between 7 and 70 years of age. *Acta med. scand.* **173**, 185–192.
- Brünings, W. (1911) Über eine neue Behandlungsmethode der Rekurrenslähmung. *Verh. dtsh. laryng. Ges.* **18**, 93 (525).
- Carlens, E., Crafoord, C., Feigenberg, S. & Wiklund, T. (1963) Tumörer i broncher, lungor och pleura. In: S. Feigenberg, E. Poppe & R. Romanus (eds.): *Tumörsjukdomar*. Almqvist & Wiksell, Uppsala.
- Fritzell, B., Hallén, O. & Sundberg, J. (1974) Evaluation of teflon injection procedures for paralytic dysphonia. *Folia phoniat.* **26**, 414–421.
- Isshiki, N. (1964) Regulatory mechanism of voice intensity variation. *J. Speech. Res.* **7**, 15–29.
- Isshiki, N. & von Leden, H. (1964) Hoarseness: Aerodynamic studies. *Arch. Otolaryng.* **80**, 206–213.
- Iwata, S., von Leden, H. & Williams, D. (1972) Air flow measurements during phonation. *J. Commun. Disorders* **5**, 67–79.
- Kitzing, P. & Löfqvist, A. (1975) Subglottal and oral air pressures during phonation – preliminary investigation using a miniature transducer system. *Med. Biol. Engng* **13**, 644–648.
- von Leden, H., Yanagihara, N. & Werner-Kukuk, E. (1967) Teflon in unilateral vocal cord paralysis. *Arch. Otolaryng.* **85**, 666–674.
- Lewy, R. B. (1976) Experience with vocal cord injection. *Ann. Otol. (St. Louis)* **85**, 440–450.
- Parnell, F. W. & Brandenburg, J. H. (1970) Vocal cord paralysis. A review of 100 cases. *Laryngoscope* **80**, 1036–1044.
- Rontal, E., Rontal, M. & Rolnick, M. (1975) The use of spectrograms in the evaluation of vocal cord injection. *Laryngoscope* **85**, 47–56.
- Rubin, H. J. (1975) Misadventures with injectable polytef (Teflon). *Arch. Otolaryng.* **101**, 114–116.
- Schiratzki, H. (1965) Upper airway resistance during mouth breathing in patients with unilateral and bilateral paralysis of the recurrent laryngeal nerve. *Acta Oto-laryng.* **59**, 475–496.
- Yanagihara, N., von Leden, H. & Werner-Kukuk, E. (1966) The physical parameters of cough: The larynx in a normal single cough. *Acta Oto-laryng.* **61**, 495–510.

Address:

Peter Kitzing, M.D.
 Department of Phoniatics
 ENT-Clinic
 University Hospital
 S-214 01 Malmö
 Sweden