



LUND UNIVERSITY

Investigation of Larynx preparations

Kitzing, Peter; Holmer, Nils-Gunnar

Published in:
New methods in Medical Ultrasound

1978

[Link to publication](#)

Citation for published version (APA):
Kitzing, P., & Holmer, N.-G. (1978). Investigation of Larynx preparations. In N.-G. Holmer, & K. Lindström (Eds.), *New methods in Medical Ultrasound* (pp. 232-277). Institution of Technology, Lund.

Total number of authors:
2

General rights

Unless other specific re-use rights are stated the following general rights apply:
Copyright and moral rights for the publications made accessible in the public portal are retained by the authors and/or other copyright owners and it is a condition of accessing publications that users recognise and abide by the legal requirements associated with these rights.

- Users may download and print one copy of any publication from the public portal for the purpose of private study or research.
- You may not further distribute the material or use it for any profit-making activity or commercial gain
- You may freely distribute the URL identifying the publication in the public portal

Read more about Creative commons licenses: <https://creativecommons.org/licenses/>

Take down policy

If you believe that this document breaches copyright please contact us providing details, and we will remove access to the work immediately and investigate your claim.

LUND UNIVERSITY

PO Box 117
221 00 Lund
+46 46-222 00 00

ur

715

Holmér, N-G, Lindström, K.: New methods in
Medical Ultrasound.

Report 4/1978, Lund Inst. of Technology, Lund/Health
1978, s. 232-277




Fig. 8.1. Vibrating vocal folds from a calf.

8 INVESTIGATION OF LARYNX PREPARATIONS

N.-G. Holmer, P. Kitzing, M.D.

8.1 INTRODUCTION

The first experiments with the apparatus described above were carried out on larynges from pigs and calves in order to learn the anatomy and to study the possibilities of the new method. These larynges were made to vibrate with a method described below but without the surrounding artificial neck shown in Fig. 8.2. The ultrasound probe was applied directly to the thyroid laminae which caused problems when the direction of the ultrasound beam had to be altered in order to find a correct positioning of the transducer. An example of results of these experiments with vibrating vocal folds, from a calf is given in Fig. 8.1.

8.2 METHOD

After preliminary experiments with the larynges from animals the principal part of our work has been carried out with human larynx preparations arranged in an artificial throat. This arrangement is shown in Fig. 8.2. On a fork-like stand (A) the upper part of a human larynx preparation (B) was fixed, so that the trachea was suspended vertically and could be connected to a plastic tube (C) for humidified and heated air (E). The temperature and pressure of the air could be measured by a thermometer (T) and a water-manometer (D) respectively. At a certain air pressure and by manipulation of the laryngeal cartilages the vocal folds of the larynx preparation could be made to vibrate, emitting sounds of different pitch and quality. The larynx preparation was inserted into a circular perspex tank (F) with physiological saline or water. Windows (G) were cut in the tank and covered with a thin rubber membrane

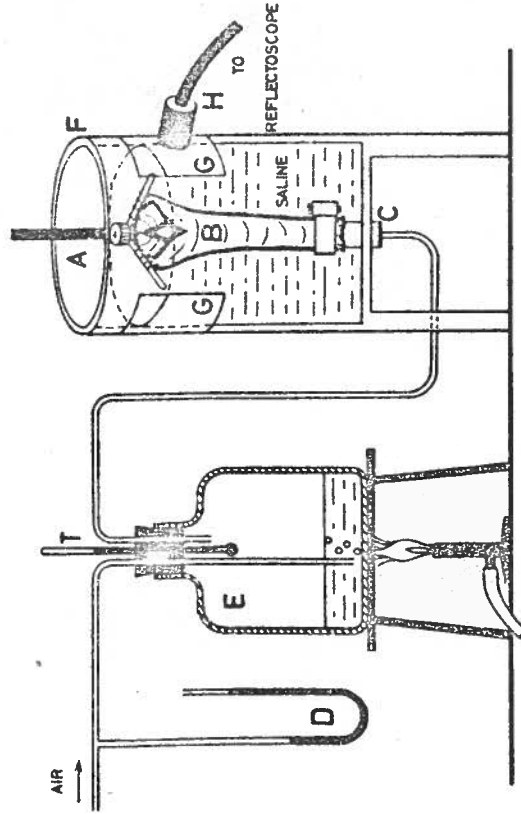


Fig. 8.2. Artificial neck set up. Moist and heated air passes through the trachea of a laryngeal preparation suspended in a saline-filled vessel with windows for the transducer.

for application of the ultrasound transducer (H). The experimental arrangements were made according to the principles developed by van den Berg et al. (1959).

Fig. 8.3 shows the set-up with a human larynx preparation in the artificial neck. The transducer to the right is fixed by a holder, with the possibility to change the ultrasound beam angle in order to study the dependence of angle error.

8.3 RESULTS

In preliminary experiments, ultrasound penetration of human thyroid cartilage was found to vary with age and sex. The attenuation of ultrasound is assumed to depend on the varying degree of ossification of the thyroid cartilage. The degree of ossification was studied by measuring the amplitude attenuation at different frequencies. The results are shown in table 8.1. Measurements were made at the anterior edge and at the centre of four equally thick thyroid laminae varying in age and sex. The attenuation proved to be in good agreement with the ossification as it appeared on an X-ray from the cartilages (Fig. 8.4). As expected from textbook information about the progression of larynx ossification due to age and sex (e.g. Lanz et al., 1955), absorption was shown to be least in the central part of the thyroid cartilage.

The human vocal folds are comparatively small structures: the size of their lateral excursion during vibration is often less than one millimeter. Therefore the best possible resolution is demanded from the ultrasonic apparatus. This can be achieved with ultrasound of high frequency. But, as pointed out earlier, the higher the frequency the greater the absorption,

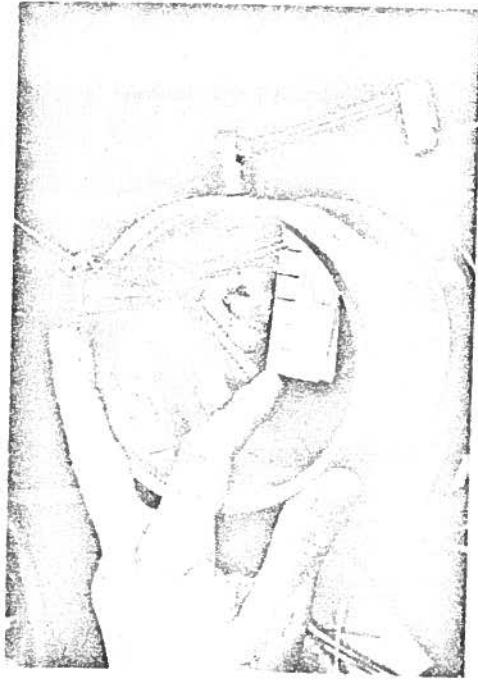


Fig. 8.3. Photograph of a human larynx preparation in the artificial neck.

Table 1

ATTENUATION OF ULTRASOUND INTENSITY IN THYROID LAMINAE (Measured in dB = -10 log I₀/I)

Age/Sex	83/male		43/male		75/female		63/female	
	Edge - db	Middle - db	Edge - db	Middle - db	Edge - db	Middle - db	Edge - db	Middle - db
Transducer Frequency 2	30	6	36	18	10	4	23	6
4	36	16	40	19	20	6	26	10
6	*	26	*	21	25	11	29	16

* very high absorption, not measurable with the technique used.

Fig. 8.4. X-ray photographs from cartilages including table 8.1.

and there is a frequency limit when it becomes impossible to penetrate the tissues under investigation.

In our experiments the sound beam in some cases was almost entirely absorbed by the thyroid cartilage at a frequency of 6 MHz. The ultrasound frequency of 4 MHz was found to be the highest possible for experiments with larynx preparations and the present work was carried out mainly with a transducer of this frequency.

At the beginning, the experiments with larynx preparations were carried out without vibrations of the vocal folds. An echo representing the inner and outer surface of the thyroid laminae of the preparation and another representing the free margin of the vocal fold were demonstrated on the monitor oscilloscope (A-mode). This latter echo was unequivocally identified by the insertion of a thin metal needle under the marginal mucosa of the fold, which resulted in a change of the previously demonstrated echo. Further, the echo could be identified by a good correspondence between the distance displayed on the CRT and the actual distance from the transducer to the free edge of the investigated vocal fold.

Manipulation of the fold, resulting in adduction and abduction movements, were followed as corresponding movements of the previously identified echo on the monitor, whereas the remaining echoes did not move (Fig. 8.5). These slow movements of high amplitude were also demonstrated by TM-recording as an undulating curve (Fig. 8.6).

When the vocal folds were made to vibrate by application of the moist and heated air stream, the excursions of the echo on the monitor were of course too fast for

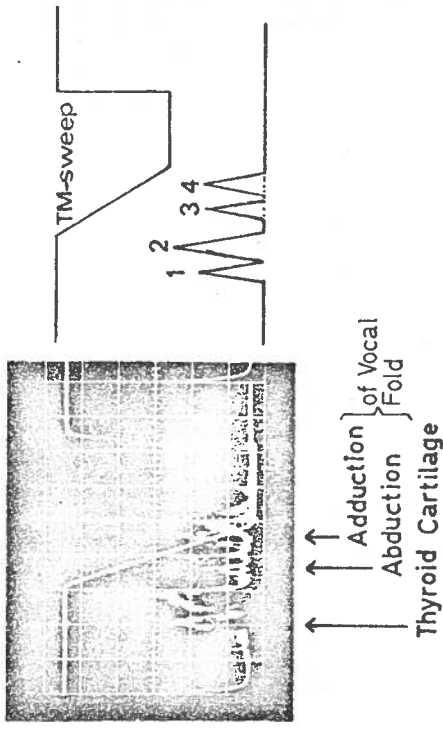


Fig. 8.5. Ultrasound registration of manipulations with a vocal fold. A-scope. Double exposure with representation of the echoes from the same vocal fold in abducted and adducted position respectively. 1, External lamina; 2, internal lamina of thyroid cartilage; 3, vocal fold in abduction; 4, vocal fold in adduction.

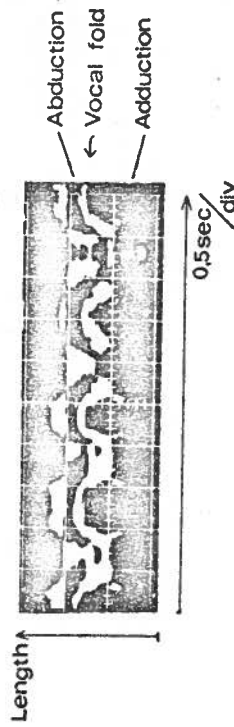


Fig. 8.6. Ultrasound registration of manipulations with a vocal fold. TM-display. The slow ab- and adductory movements of the vocal fold are represented by an undulating curve.

the naked eye to follow, and could only be perceived as a blurring of the vocal fold echo. By TM-display, however, it was clearly possible to get distinct curves from the vibrating folds (Fig. 8.7). As seen from the figure, the repetition frequency of about 10 kHz was sufficient to give a continuous representation of vocal folds, vibrating at about 110 Hz.

8.4 DISCUSSION

The method described above is meant to be the first step in a systematic development of a new clinical procedure. In studies of laryngeal specimens we have been able to locate the echo-evoking structures directly in the larynx. Further, TM-displayed curves have been correlated to slow abductory and adductory movements as well as to vibrations of the vocal fold.

In initial experiments we tried to apply the transducer directly to the thyroid cartilage of the preparation. These attempts failed as the echoes from the laryngeal structures were overshadowed by the start pulse because of the short distance. Therefore, the larynx-preparations were suspended in a vessel filled with water or saline.

In a special study, we analyzed the ability of the echo to penetrate the laryngeal cartilages when these were more or less ossified. Earlier experience, e.g. from echo-encephalography (Jeppsson, 1961), has shown that cancellous bone can absorb ultrasound to a very high extent. It turned out possible to solve this problem by means of a suitable ultrasound frequency and by directing the ultrasound beam perpendicularly to the glottis and against the central parts of the thyroid cartilage.

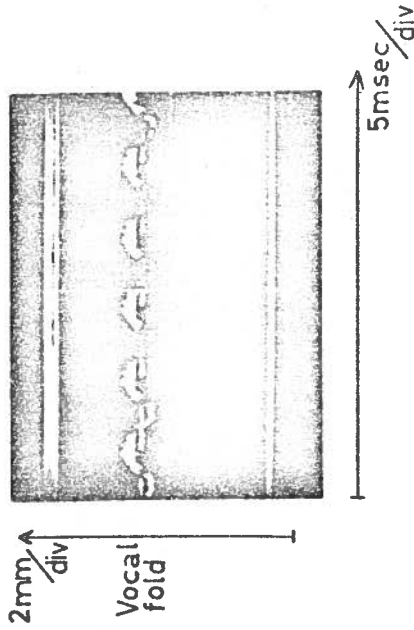


Fig. 8.7. Echologtogram of vocal fold vibrating at 110 Hz. Note similarity of curves with the vibratory pattern well-known from high-speed films and photologtography. The closed, opening- and closing phases can clearly be distinguished.

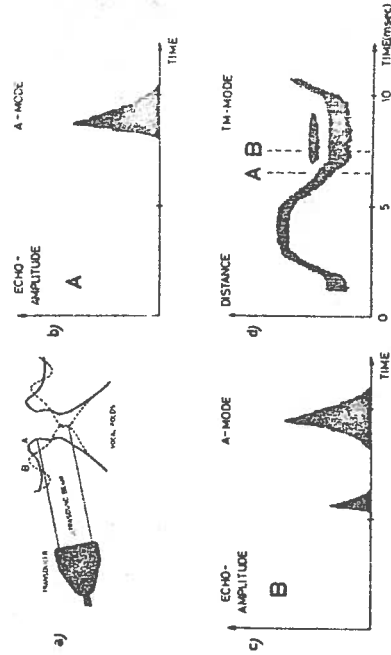


Fig. 8.8. Fig. 8 a - d. Two diagrammatical frontal sections, A and B, showing the complex and changing vocal fold surface during vibration (a), sometimes causing multiple and irregular echoes displayed in A-mode, (b and c) as well as in TM-mode (d).

The greatest difficulty is associated with the complex movement pattern of the vibrating vocal folds, earlier commented upon by Beach and Kelsey (1969) and described in detail by Schönhärl (1960) in his monograph on laryngeal stroboscopy. The vibratory movements do not consist of single-surface amplitudes in only one, the horizontal, plane. Instead, waves of vibration on the vocal folds can be distinguished in all three dimensions of space, as can be seen for instance from Schönhärl's Fig. 16. This of course will affect the resulting echoes as illustrated in Fig. 8.8. The position of the transducer in relation to the vocal folds seems to be difficult to reproduce from one examination to another.

REFERENCES

- Beach, J.L. and Kelsey, C.A. (1969)
Ultrasoundic doppler monitoring of vocal-fold velocity and displacement. J. Acoust. Soc. Amer. 46, p. 1045.
- Berg, J. van den et al., (1959)
Results of experiments with human larynxes. Pract. Otorhinolaryng (Basel) 21, p. 425.
- Jeppsson, S. (1961)
Echoencephalography. Acta Chir. Scand., Suppl. 272.
- Lanz, T. von and Wachsmuth, W. (1955).
Praktische Anatomie. 1. Band, 2. Teil, Hals. 287.
Springer-Verlag, Berlin, Göttingen, Heidelberg.
- Schönhärl, E. (1960)
Die Stroboskopie in der praktischen Laryngologie, Thieme Verlag, Stuttgart.

9 CORRELATION BETWEEN THE ULTRASONIC AND PHOTO- GLOTTOGRAPHIC METHOD

9.1 INTRODUCTION

In phonetic investigations many methods have been used to study the vocal fold vibrations as already mentioned in chapter 2. Several objective methods to measure the fundamental frequency of vocal folds are described in the literature (see chapter 2). A comparatively easy way to record the continuous variations of the glottal area during speech is the photoglottographic method developed by B. Sonesson. This method is well known and used in some clinics. Because of this it was of interest to correlate recordings obtained by this method with corresponding recordings with the ultrasonic method. The question to be answered is if there are any similarities in the curve configuration between these two different methods.

The photoglottographic method uses light that passes through the skin of the neck and further through the glottis. The transilluminating light-beam passing the glottis is measured by a phototransistor. In order to position this phototransistor correctly it is inserted through the nose into the pharynx. When the vocal folds are opened, light passes through this opening and is recorded. The opening area between the vocal folds vary with the frequency of the vocal folds. Theoretically this method will measure the opening area between the vocal folds as a function of time, while our ultrasonic method in principle measures the movement of one point of one vocal fold only. A comparison between the curve configuration obtained by these two methods will therefore be of interest because of which such an investigation is described in the following.

9.2 LINEARITY CONTROL OF THE PHOTOGLOTTOGRAPHIC METHOD

Lately there has been a discussion about the reliability of the photoglottographic method. Therefore, in order to investigate this method, a vibrating vocal fold simulator was built which was illuminated in a similar way as in practice. The whole simulator was examined with respect to its accuracy. Special attention was given to the photo-sensitive transducer. A commercial photoglottographic instrument made by Frøkjær-Jensen (Denmark) was used in this model study. This instrument makes use of a phototransistor as light sensor. A DC-light source was used in order to avoid interference with the simulator frequency.

It is of great importance to know the parameters of the phototransistor, i.e. the light sensitivity as function of incident angle and its frequency response including its amplifier. Firstly the frequency response was checked by using a light emitting diode as light source. This diode was modulated by a rather complicated electrical signal. After checking possible distortion of the modulated light from the photo diode the phototransistor was illuminated. A result from this test is illustrated in Fig. 9.1. The upper curve in this figure corresponds to the transmitted light signal and the lower curve to the signal from the phototransistor. Obviously there are no noticeable differences between these two signals, which means that the frequency response of the receiver unit (phototransistor including amplifier) is satisfactory. The repetition frequency of the modulated signal in Fig. 9.1 is about 75 Hz.

In order to evaluate the angle dependence of the phototransistor a glottis simulator was built. The design




Fig. 9.1. Measurement of the frequency response of the phototransistor. The upper curve corresponds to the transmitting light signal and the lower curve to the signal from the phototransistor.

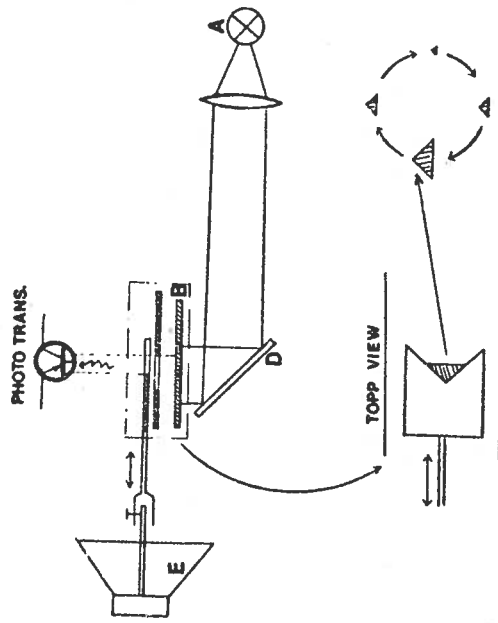


Fig. 9.2. Glottissimulator.

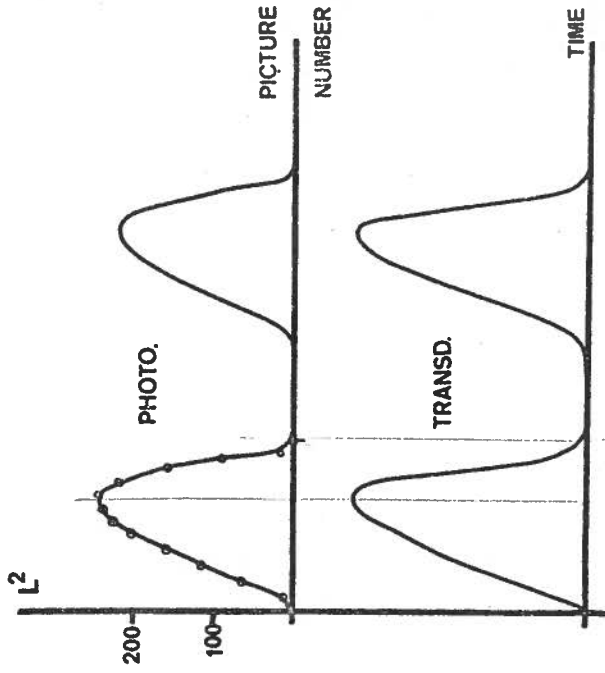


Fig. 9.3. Calculated glottis area (the upper curve), and the area recorded by a phototransistor (lower curve) both as function of time.

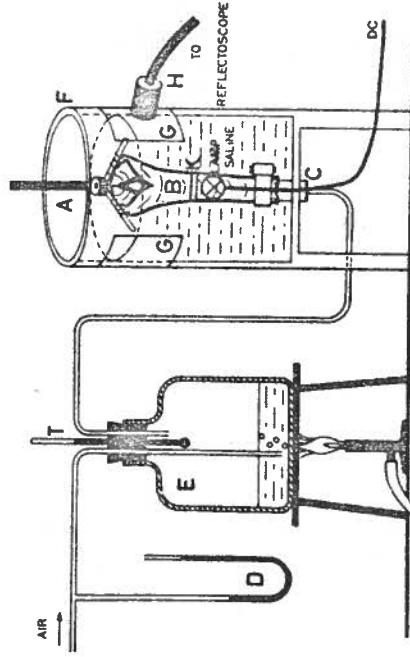


Fig. 9.4. The artificial neck including a lamp and a diffusor K.

of this simulator is shown in Fig. 9.2.

As a light source (A) the lamp and plexiglas rod from the Frøkjær-Jensen equipment was used. The light passes through a diffusor (B) (consisting of some drawing papers) before it will be reflected by a mirror (D) through the opening of the simulator which corresponds to the glottis opening. The opening is made of a rectangular hole in the metal case, above which a plastic disc is moved back and forth by a loudspeaker forming a triangular opening. In order to open and close the glottis simulator a loud-speaker is used which is connected to the plastic disc. The opening forms a triangular surface through which the diffused light will pass up to the phototransistor situated a few centimeters above. When the plastic disc vibrates the opening area also alters and thus also the amount of light passing through. These light variations are recorded by the phototransistor.

With this equipment recordings were made with different transducer angles and positions above the opening. The results of these experiments showed that the output signal from the phototransistor was independent of the transducer angle. The maximum of the signal varied of course but this was immaterial in the present case.

In order to control the accuracy of the measurements of the opening area, we also photographed the glottis simulator area with a movie camera during very slow movements. In this case the signal frequency driving the loud-speaker was about 3 Hz. The result is shown in Fig. 9.3, where the upper curve is calculated from the movie film and the lower curve is the actual glottis area recorded simultaneously with the phototransistor. Obviously a good correspondence exists.

After this check we could assume that the photoglottographic method did not have any dangerous errors. Therefore we intended to use this method in order to check the results obtained with the ultrasonic method.

9.3 PHOTOGLOTTOGRAPHY AND ECHO-GLOTTOGRAPHY USED ON LARYNX PREPARATIONS

In the artificial neck used earlier and described in chapter 8, we added a light source (see Fig. 9.4) inside the tube through which the air activating the vocal folds is blown. In front of the lamp driven by direct current a diffuser was positioned. The phototransistor was applied above the glottis. During the experiment other light sources should be switched off to eliminate 50 Hz interferences. Some registrations obtained with different preparations are shown in Fig. 9.5a, b, c.

Simultaneously with the photoglottographic recording of the vocal fold motion a transducer of an ultrasonic reflectoscope was applied to the artificial neck. The beam of the transducer was directed towards one of the vocal folds as shown in Fig. 9.4. The recording of the motion obtained in this way was displayed in a TM-mode on a cathode ray tube simultaneously with the photoglottographic curve. Since the oscilloscope used had a single beam tube only, the internal chopper of the oscilloscope was employed which explains the periodic interruption of the TM-mode.

In all photographs of Fig. 9.5 the upper curve is the TM-mode recorded by ultrasound while the lower curve represents the simultaneous signal from the photoglottograph.

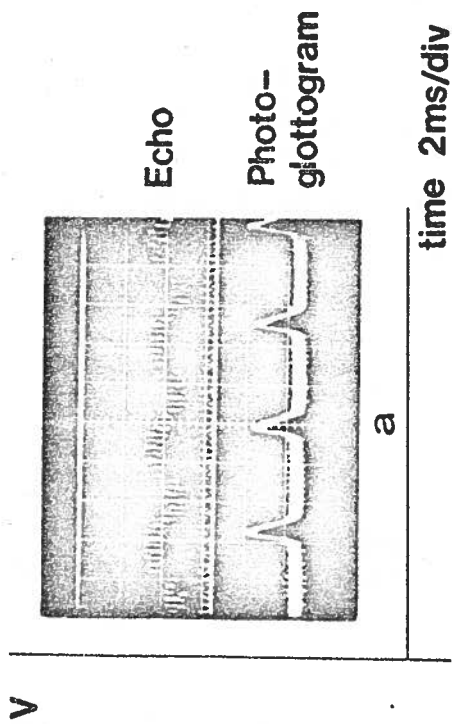


Fig. 9.5a.

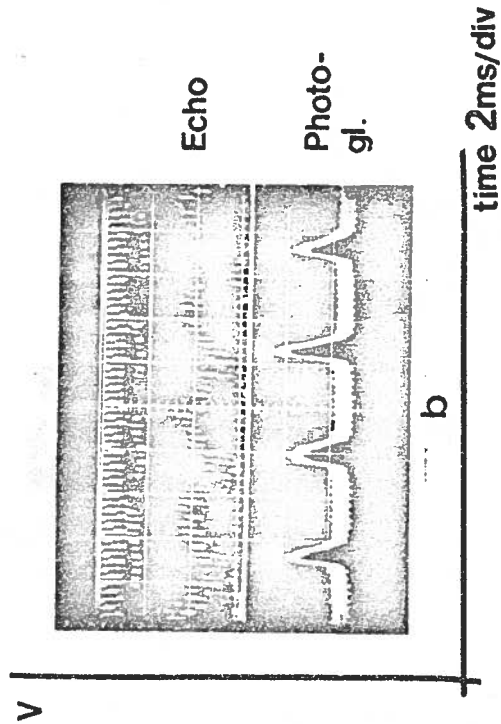


Fig. 9.5b.

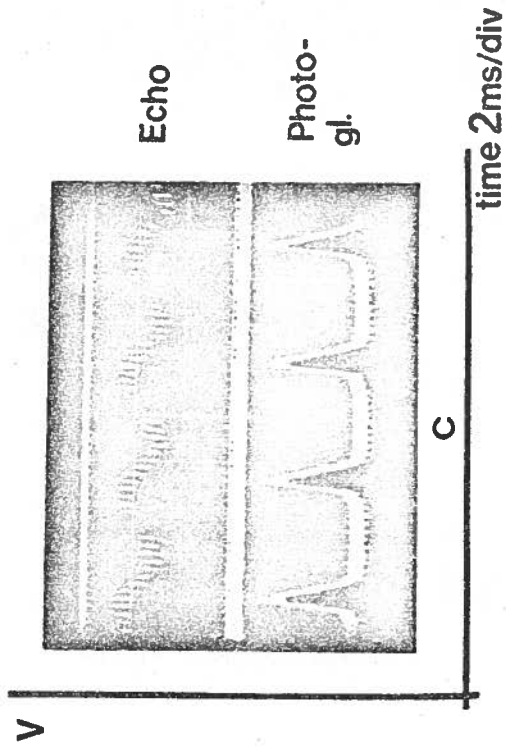


Fig. 9.5a,b,c. Simultaneous echo-glottographic (upper curve) and photoglottographic (lower curve) recordings obtained from three different preparations. The vocal fold movements are about 1 mm at this special investigation point since the echo scale is 1.2 mm/div.

9.4 DISCUSSION

The photoglottographic method which already is well known has lately been criticized. Therefore before we started to use this method the properties of the phototransducer were checked first. This check did not show any drawbacks of such importance that the method could be expected to give unsatisfactory results. As shown in Fig. 9.3 the phototransistor accurately measures the artificial glottis area.

A further reason for this investigation was to check the reliability of the photoglottograph before it was taken into clinical use at the hospital in Malmö. When the curves obtained by the photoglottographic method are compared with the curves from the ultrasonic echo method, the correspondence between the curves is rather bad (see Fig. 9.5a, b, c). This, however, should be expected since the two methods measure different quantities. The photoglottographic method measures the opening area between the vocal folds, while the echo method measures the movement of one vocal fold edge (ideally in one point). Consequently one cannot expect significant similarities of these two curves except for the frequency. However, both methods should show the moment of opening and closing of the vocal folds with not too large a difference in phase.

The disadvantage of the photoglottographic method is that it is unpleasant for the patient. In contrast to this, many patients have expressed the opinion that the ultrasonic method is rather comfortable.

10 RECORDING OF THE VOCAL FOLD MOTION IN VIVO

10.1 INTRODUCTION

The motion of the vocal folds in vivo has been recorded with ultrasound earlier by other authors (especially Kitamura et al. 1968, 1969, Hertz et al. 1970 and Kaneko 1974) as described in chapter 2a. In the same chapter the importance of a high pulse repetition rate of the reflectoscope is stressed for the recording of vocal fold.

However, for a reproducible recording of these motions another difficulty has to be solved. When only one ultrasonic transducer is used for the investigation, it is rather difficult to secure a correct position as well as direction of the sound beam at the neck of the patient to obtain acceptable recordings. Therefore, during an examination we must at first determine the level of the vocal folds. Only after this can we apply the transducer in the correct position. An even greater problem is the choice of the direction of the ultrasonic beam so that it passes the vocal folds at the correct place. These two degrees of freedom, namely the transducer position and the beam direction, complicates the recording of the vocal fold motion since it is very difficult to optimise these parameters simultaneously. Because of this difficulty, it is almost impossible to get reproducible recordings in this way. We have developed another method where the choice of position and beam direction follows automatically upon application. This method (Holmer et al. 1973, Kitzing et al. 1973 and Holmer and Kitzing, 1974, 1975) will now be described.

10.2 METHOD

10.2.1 Principle

This new method makes use of two matched ultrasonic transducers applied simultaneously at each side of the neck. One of the transducers acts as a transmitter and the other as a receiver. This combination actually can be used as a positioning device.

The transducers are mounted with their center axis in line in a mechanical holder, so that the orientation of their axis with respect to each other remains fixed (Fig. 10.1). The holder is applied to the patient in such a way that the transducers touch the neck on either side and their center axis approximately passes the vocal folds as shown in Fig. 10.2. The distance between the transducers can be varied to fit necks of different sizes.

Because of this arrangement of the transducers, the transmitted ultrasonic pulse propagates from the transmitter to the receiving transducer. First let us assume that the ultrasound beam passes the level of the vocal folds when these are open. Under such conditions the intensity of the ultrasound passing through the air-filled glottis will be negligible. This is due to the fact that the acoustic impedance of air is much smaller than that of the surrounding tissue. Consequently, strong reflections will take place from the boundary of the vocal folds and the air. On the other hand, if the vocal folds are in contact with each other, the ultrasound will pass through the contact surface. Thus, assuming that there is no other passage, the received signal alternates simultaneously with the variations of the contact area of the vocal folds. The variation

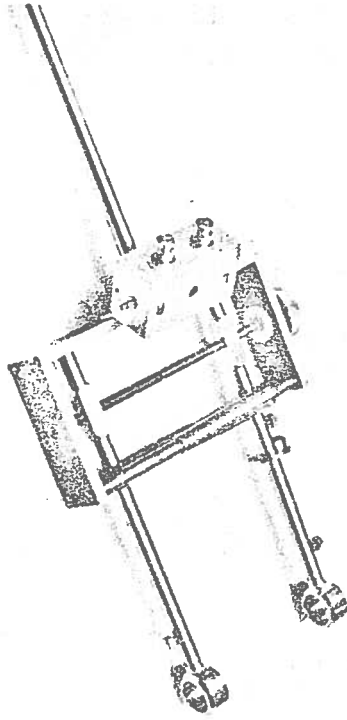


Fig. 10.1. The transducer holder. The transducers are mounted in a holder in such a way that their center axis is in line.

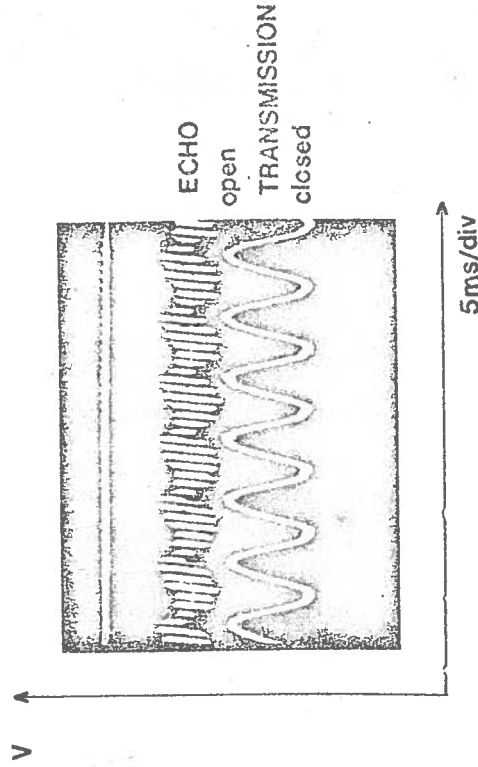
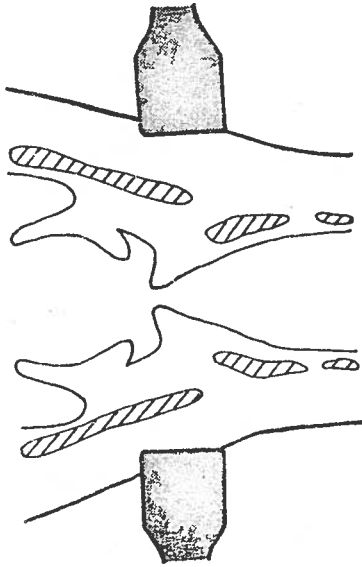


Fig. 10.3. TM-sweep interference with the internal chopper frequency of the oscilloscope.

OPEN



CLOSED

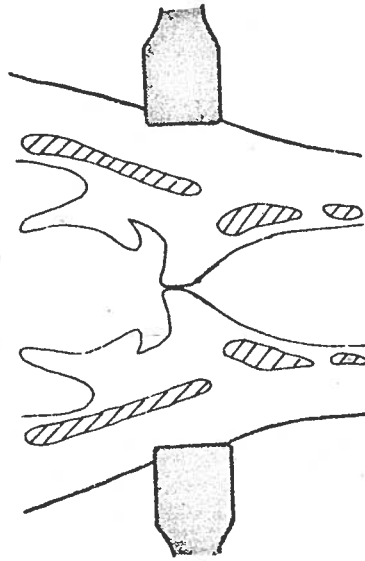


Fig. 10.2. The center axis of the two transducers passes the vocal folds. If there is a contact surface the ultrasound can pass through this otherwise there will be no transmission.

of the received ultrasound intensity is thus proportional to the fundamental frequency of the vocal folds (Hamlet, S. and Reid, J. 1972 and Holmer, N.-G., Rundqvist, H.-E. 1975). Obviously, if the centre axis of the transducers does not pass through the larynx at the level of the vocal folds, no such variation of the ultrasound intensity transmitted through the neck can be observed. This fact can be used for the correct positioning of the reflectoscope transducer before starting the recording of the vocal fold motion. This position can be identified by studying the shape of the transmission signals received at different locations on the neck. A correct position shows a significant amplitude modulation of the ultrasound transmitted through the neck during phonation. The position can also be found if a transmission is received during a cough, but not during breathing. The position found in these two different ways always lies between the lower part to slightly over the middle part of the thyroid cartilage. (See Fig. 10.2).

Of course this method to determine the correct position of the transducer can be realized both with continuous and pulsed ultrasound. In the present application the latter alternative was used since this facilitates the switching of the electronic circuits from the transmitting mode used for positioning to the echo mode employed in the recording of vocal fold motion. When the correct position of the transducers with respect to the vocal folds has been found, the recording of vocal fold motion can be started. This is accomplished by connecting one of the two neck transducers to reflectoscope electronic circuitry, the output of which is shown in the form of a IM-mode presentation on a CRT screen.

10.2.2 Mechanical construction of the transducer holder

As the transducer holder must fit different necks, the distance between the transducers should be variable. It must also be possible to alter the transducer position on the neck. During recording the center axis of the transducers should lie in the same plane as the two vocal folds. However, sometimes it might be advantageous to vary the direction of the beam slightly with respect to the vocal folds. Therefore, one of the transducers can be turned through a small angle around the axis of its holder.

Fig. 10.1 shows a photograph of the transducer holder. The two transducer probes are both mounted in a holder in such a way that their center axis is generally in line.

From the photograph it is obvious that the distance between the transducers can be varied by means of a screw to fit larynxes of different sizes. One half of the screw is left-hand and the other half right-hand threaded. In that way the transducers move either towards or away from each other depending on which direction the screw is turned.

The head of the patient is fixed to a chair on which the transducer holder is mounted. This arrangement is shown in Fig. 10.12. After finding the correct transducer position it will be fixed by another screw marked 2 in the figure.

During this recording, the opposite transducer is still used to monitor the ultrasound transmitted through the neck. The signal obtained in this way is displayed simultaneously on the CRT using a chopper technique as described below. This allows the operator to check that the transducer positioning is not changed during the recording.

There are mainly two possible ways to obtain false amplitude-modulated transmission signals as a result of incorrect positioning of the transducers. The first one arises if the contact surface between the transducer and the neck varies owing to too loose a transducer pressure. This is easily remedied by having a higher transducer pressure on the neck to prevent contact surface variations.

The second one is caused by the fact that also other parts of the larynx vibrate during speech. As the result of this the transmitted signal may show a certain amount of amplitude modulation even if the transducer axis does not pass exactly through the larynx. E.g. this may happen if the ultrasound beam passes through the extreme anterior or posterior parts of the vocal folds, in which case part of the transmitted signal will be of constant amplitude and part of it amplitude modulated. Therefore, to ensure the correct positioning of the transducers, the transmitted signal should show a 100 % amplitude modulation. In the beginning this is difficult to achieve, but after using this technique for some time the experienced investigator recognizes the curve shape on the ultrasound transmission for a correct positioning of the transducers.

10.3 ELECTRONICS

10.3.1 Simultaneous recordings of TM-mode and transmitted signal

Earlier recordings of vocal fold motion were displayed with only a single beam one-channel oscilloscope using the well known TM-mode method. If the position-finding method described above is used, two oscilloscope channels will be necessary to display a) the echo signals from the vocal folds by means of the TM-method and b) the amount of ultrasound which is received by the receiving transducer on the opposite side of the neck. This second trace is used as a position finder which enables the operator to position the transmitting transducer correctly on the neck. If a single beam CRT is to be used for the display of both the TM and the transmitted signal, the chopper-switching between these two signals has to be chosen carefully. Since the time between two transmitter pulses is much longer than the transit time for the sound pulse to travel to the vocal folds and back, the signal transmitted through the neck can be displayed after the completion of each sawtooth cycle of the TM-mode.

If an alternating sweep representation of the two traces is used instead, the first x-sweep will be used to record the TM-mode and during the second x-sweep the ultrasonic transmission is recorded. This means that an alternating sweep does not record the echoes and the transmission simultaneously. A fast chopper technique, however, can record two signals at the same time. In the Tektronix plug-in unit 0 the internal chopper frequency is only 150 kHz. This chopper frequency and the TM-mode display can interfere with each other, which is illustrated in the recording shown in Fig. 10.3. How-

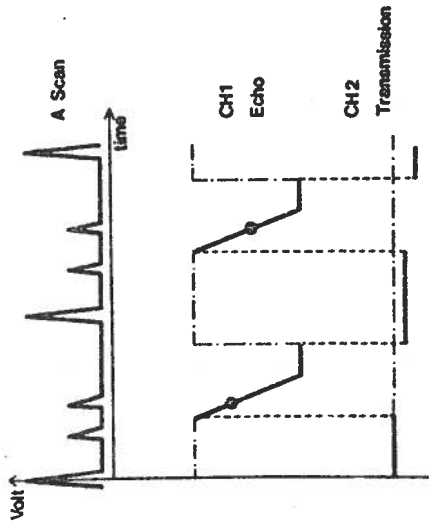


Fig. 10.4. The switching between channel 1 and 2 is governed by a signal from the TM-sweep generator.

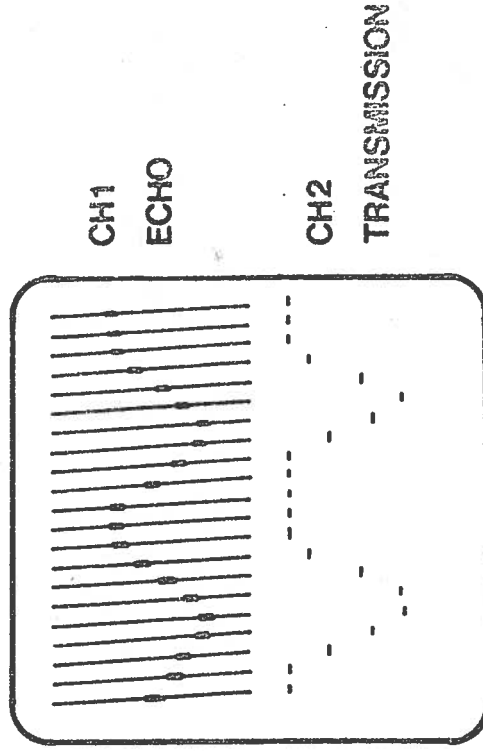


Fig. 10.5. Schematic picture illustrating a real recording with an externally driven chopper.

ever, this problem can be avoided by controlling the chopper by an external chopper signal. By this technique, interference phenomena are avoided. Consequently the electronic chopper in the plug-in must be controlled from the reflectoscope. This choice implies that channel 1 is displayed during a time period corresponding to the slowest period TM-sweep generator. Until the next TM-sweep starts again, channel 2 displays the ultrasound transmission signal. A few cycles of the switching between channel 1 and channel 2 by means of the described chopper signal are illustrated in Fig. 10.4. In Fig. 10.5 a schematical picture illustrates a real recording. Here channel 1 shows the movements of the echoes in TM-mode presentation and channel 2 the intensity of the ultrasound transmission.

10.3.2 Amplifier for the ultrasonic transmission signal

A new amplifier for the ultrasound signal transmitted through the neck had to be added to the original echo equipment for vocal fold measurement. In Fig. 10.6 a block diagram shows the principle of the ultrasonic transmission amplifier. A microphone amplifier is also shown, which will be discussed later in part 10.3.3.

The transmitted acoustic signal, having been amplitude modulated (AM) by vocal fold motion, is first converted by the receiving transducer into an electric signal and then fed into the receiving unit. This receiving unit consists of four blocks, namely:

- 1) a wideband amplifier
- 2) an AM detector
- 3) a low frequency (LF) amplifier
- 4) a microphone amplifier.

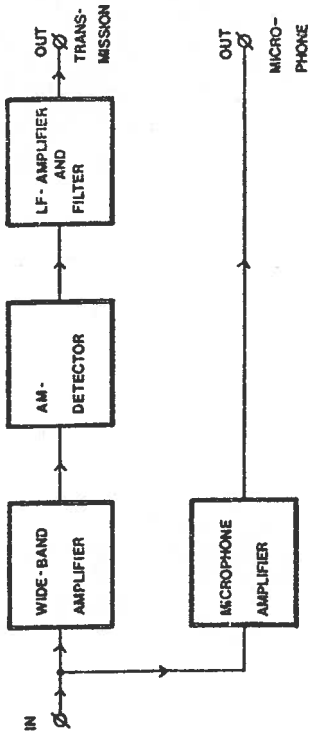


Fig. 10.6. Block diagram of the ultrasonic transmission signal amplifier and microphone amplifier.

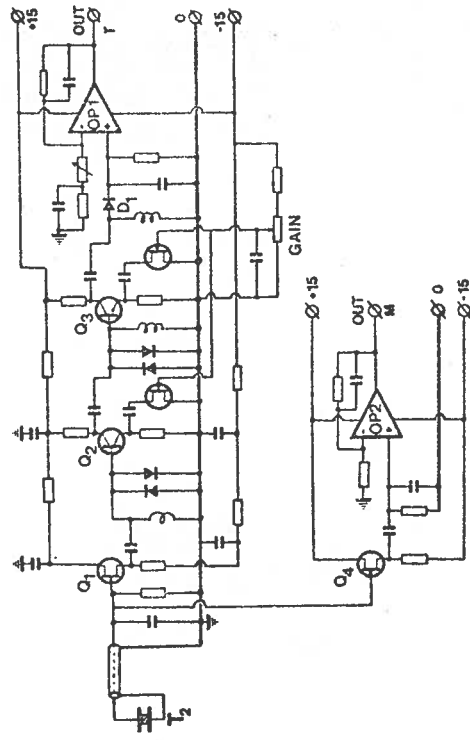


Fig. 10.7. Circuit diagram of the transmission amplifier and microphone amplifier.

Since the ultrasound intensity transmitted is kept as low as possible to avoid any unknown biological effects of ultrasonic irradiation, a wideband amplifier with high gain must be inserted between the receiving transducer and the AM-detector. A gain of at least 100 times has been found to be necessary in order to give a satisfactory recording of the transmission signal.

The circuit diagram of the receiver is shown in detail in Fig. 10.7.

The ultrasound is picked up by the receiving transducer T_2 and converted into an electrical signal which passes through a coaxial cable to the source follower input stage (Q_1). Thereafter the signal is amplified by two wideband amplifier stages (Q_2 and Q_3) and demodulated by a diode detector (D_1). The gain is controlled by FETs, whose drain-to-source impedance varies by the gate-to-source voltage. In this way the negative feedback is adjusted in the amplifier. By this means, the total gain of the wideband amplifier can be varied from 1 to 400 times.

After demodulation, the signal will be low-pass filtered so that only the LF-component is amplified by OP1. The low-pass filter should have a sharp roll-off since the repetition frequency of the transmitter pulse is only 10 kHz. This is actually the carrier frequency, which therefore determines the upper frequency limit of the LF signal. After the filter, the LF-signal is then available for oscilloscope display.

Since the measurement of the ultrasonic transmission signal was added at the final stage of the construction of the equipment, these circuits have their own power supplies and transformer because there were no separate

windings available at the main transformer. An advantage with a separate transformer and power supply in this case is an almost total isolation to the transmitter and clock circuits, whose signals can easily interfere with the sensitive transmission amplifier.

10.3.3 The piezoelectric transducer as a contact microphone

Since the transducer is sensitive to pressure, it is also well suited as a throat microphone. The acoustic pressure signal coming from the vocal folds can be picked up by this transducer and transformed into an electric signal. If the transducer operates both as a microphone and as an ultrasound receiver, the inductance across the transducer has to be taken away in order to allow charge measurements. This inductance is often used for the attenuation of resonances other than the thickness mode resonance.

The microphone signal is first amplified by the source follower (Q_4) and then amplified by the operational amplifier OP2 (Fig. 10.7). This microphone signal is used for comparison with the TM-mode signal and is therefore available at the front panel as "microphone signal".

10.4 RESULTS

10.4.1 Comparison with photoglottography

Before discussing the transducer positioning method described above, some results obtained during the experiments with the transmission method alone shall be discussed.

In Fig. 10.8 the transmission method using continuous ultrasound is compared to the output from the photoglottographic method. Both curves were obtained simultaneously in a normal patient during phonation by using both methods at the same time and displaying their outputs on a dual-beam CRT. The upper curve shows the ultrasound transmission signal before demodulation, i.e. the signal obtained at the receiving transducer, while the lower curve shows the output signal from the light-receiving phototransistor of the photoglottograph.

It is clearly seen from the figure that the light from the photoglottograph passes during the opening period of the vocal fold motion while the transmitted ultrasonic signal shows maximum amplitude during the time when the vocal folds are closed. Thus the results of both methods coincide.

10.4.2 Dependence of sound transmission on transducer position

It has been shown by Hamlet (1972) that the ultrasound transmitted through the neck will be amplitude modulated even when the two transducers are not applied at the level of the vocal folds. With our transmission method we have observed the same phenomenon.

To show this dependence on the position of the transducer, a nine-point investigation over the area of the neck around the location of the vocal folds was made by means of continuously transmitted ultrasound (Holmer and Rundqvist 1975). This investigation (see Fig. 10.9) shows that the transducer position should be in the same level as the vocal folds in order to get reproducible results.

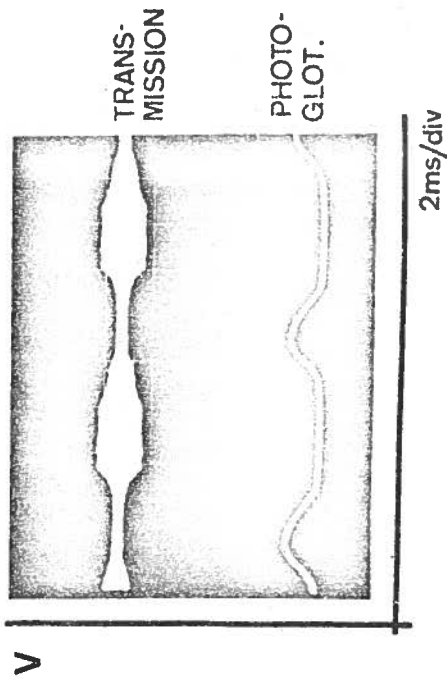


Fig. 10.8. The transmission method (upper curve) is compared with photoglottographic method (lower curve).

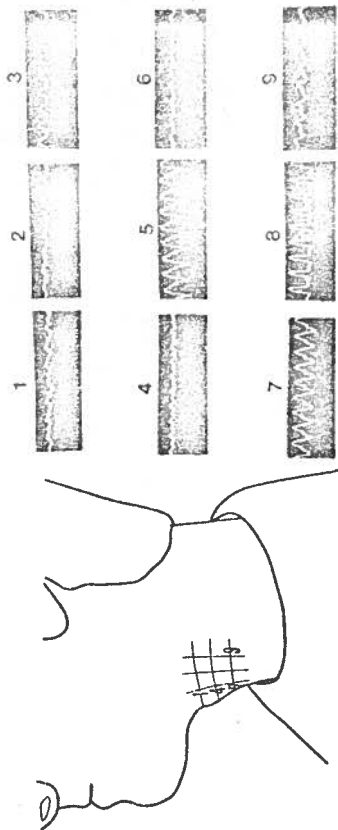


Fig. 10.9. Continuous ultrasound transmission at nine points of the neck.

From the result given in Fig. 10.9 it is obvious that the fundamental frequency of the voice could be recorded in different places on the neck. The two points 5 and 8 of the nine points show the correct transducer position. This is based on the fact that during the opening of the vocal folds no or very little ultrasound is transmitted through the neck. This period corresponds to the narrow part of the upper curve in Fig. 10.8. However, when the vocal folds are closed, the ultrasound transmission measured at the different positions varies in amplitude. These amplitude variations depend on how much ultrasound passes through the contact area to the receiving transducer, and therefore the amplitude measured at the two points 5 and 8 is largest. This fact is used as an indication for the correct positioning of the transducer as has been pointed out earlier.

10.4.3 Transducer construction

The frequency and geometrical shape of the transducer is of great importance. First of all it appears to be advantageous to use a focused transducer as shown in Fig. 10.11 because of the relatively small size of the vocal folds. However, experiments with transducers using both PZT5 bowls (see chapter 4) or plexiglas lenses in front of plane PXE5 disks did not support this assumption. This was mainly due to two facts: first of all the positioning of the transducer was found to be extremely sensitive to small changes in angle. Furthermore, the fact that the vocal fold structure undergoes a complicated movement during phonation may have added to the difficulties in obtaining a reasonably continuous curve with such transducers. Secondly, for geometrical reasons, it was difficult to insure good acoustic contact between the concave surface of the transducer lens and the skin of the neck. Different methods to fill

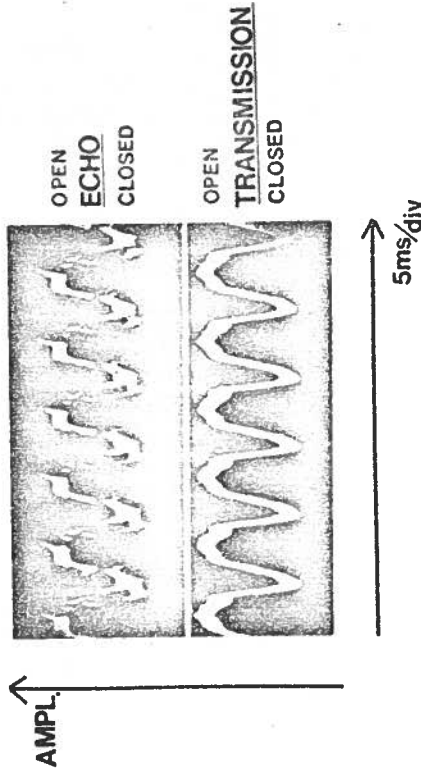
this space with coupling gel were not successful, and therefore focused transducers were abandoned.

It has been pointed out already in chapter 8 that the ultrasound has to pass thyroid cartilage on its way to the vocal folds. This cartilage has been shown to be a heavy sound absorber, the absorption coefficient of which is strongly dependent on sound frequency (Fig. 8.4). This would indicate the use of low frequency ultrasound for the present investigations, e.g. 1 MHz. However, the use of such a frequency implies relatively long ultrasonic pulses, which in its turn results in an unacceptable low resolution in the beam direction. Even the lateral resolution can be distorted by the fact that the vocal folds lie in the near zone of the transducer (chapter 4) for all practical transducer diameters. Thus a higher ultrasound frequency than 1 MHz is indicated.

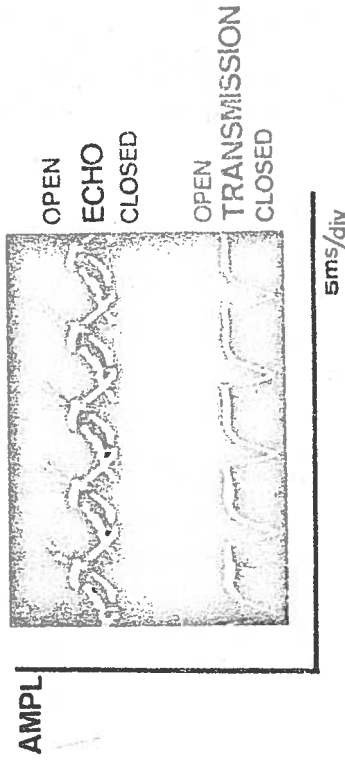
To determine the most favourable frequency, investigations were made with flat, circular transducer disks using frequencies of 1.5, 2, 2.5, 3, 4 and 6 MHz. As a result of these experiments, normally 2.5 MHz is used for the recordings, which empirically gives the best results with most of the male patients with an age lower than 45 years. For older males or in those cases where no acceptable recordings could be obtained with this frequency, a transducer pair having a resonant frequency of 1.5 MHz was used. With female patients, on the other hand, 2.5 MHz was found to give satisfactory results independent of age or other parameters, allowing this frequency to be used in all cases.

10.4.4 Examination procedure

Both the transducer and the patient have to be fixed



a.



b.

Fig. 10.10a and b. A recording of the motion of a normal vocal fold with a correct transmission signal. (The same patient giving a high intensity a) and a lower intensity b) and with a difference in frequency.)

relative to each other to keep the position of the vocal folds always within the transducer area. This is achieved by placing the patient in a dentist's chair with his head fixed to the head support by a "burr-strip". The transducer holder (Fig. 10.12) is fixed to the chair in front of the patient. In this way it is possible to keep the direction of the ultrasonic beam within the vocal folds' level during phonation.

It is important that the fundamental frequency generated by the patient is constant during a sequence of recordings. Otherwise the transducer position has to be adjusted for each recording. This can be avoided by generating a sound of corresponding frequency by a loudspeaker driven from a sine wave generator. This procedure helps the patient to find the right frequency each time a new recording is started.

10.4.5 Recording of normal vocal fold movements

After these general remarks concerning different aspects of the method, the results obtained with the ultrasonic apparatus designed for the recording of the actual vocal fold motion shall now be discussed. First, recordings of normal vocal fold motion are shown, after which the influence of medical parameters as well as disease will be discussed.

Fig. 10.10a and b show typical recordings of a vocal fold motion from the same patient (male, age 30). They were obtained on the CRT screen of the Tektronix 549 oscilloscope in the storage mode using the plug-in-unit 0. The upper curve shows the actual vocal fold motion obtained by the echo method, while the lower curve indicates the intensity of the transmitted ultrasound pulses. Owing to the simultaneous display of the lower curve, the correct positioning of the transducers is

checked continuously. In spite of the fact that both recordings shown in Fig. 10.10 were obtained from the same individual, differences can easily be observed. These differences are partly due to the fact that the fundamental frequency (and thus also the vocal fold motion) was different in both cases. Furthermore, the sound intensity was larger in Fig. 10.10a than in 10.10b, which also influences the results. Finally, in Fig. 10.10b we find a double curve in the vocal fold recording. This phenomenon has been frequently observed in healthy patients, and is probably due to the complicated movement structure of the vocal fold and the fact that the ultrasonic beam has a width of about 10 mm at the location of the larynx.

10.4.6 Medical parameters affecting the recordings

A test was performed to assess the usefulness of the apparatus for clinical routine investigations. Patients were examined in a ratio of about 40 % male to 60 % female. The age of the patients varied between 15 years and 70.

Several difficulties were encountered when applying the apparatus to clinical investigations. First of all it was observed that the symmetry plane of the larynx not necessarily coincided with the symmetry plane of the neck. In these cases the transducer fixture had to be applied at a suitable angle to the normal of the symmetry plane of the neck. This angle had to be determined by a trial and error method and should be chosen so that the axis connecting the transducers in the fixture coincides with a normal on the symmetry plane of the larynx.

The fact that some patients have a rather short neck

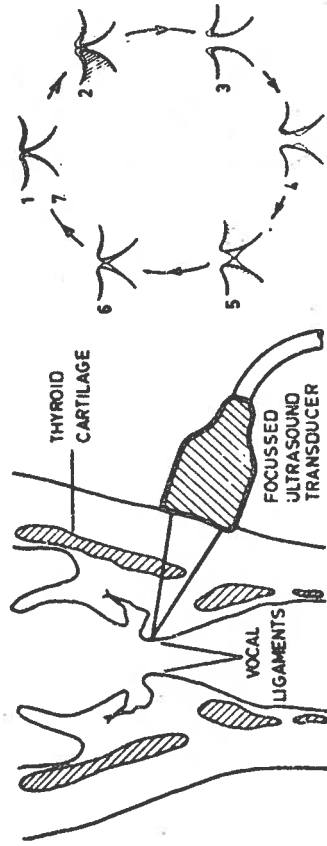


Fig. 10.11. Illustration of the beam from a focused transistor directed towards the vocal folds. To the right is the "vibration-cycle" shown in the open (3 and 4) and closed (1 and 7) states.




Fig. 10.12. In order to get reproducible recordings the patient will be fixed in a chair similar to a dentist's chair. The head can be fixed with a burrstrip.


made it impossible to obtain recordings in at least one patient. This is due to the fact that the larynx is positioned almost inside the upper part of the chest in these cases. Because of this it was impossible to obtain ultrasound transmission through the vocal fold level.

Finally, in patients having recently been operated for struma, the application of the transducer fixture to the neck caused pain to the patient. Because of this, no recordings could be obtained in spite of the fact that it is of interest to check the movement of the vocal folds after operation. The presence of paresis due to an earlier struma operation is shown in Fig. 10.13a and b which show the movements of the vocal folds during a cough. Here the x-sweep is slowed down (1 div/sec) to show the entire cough movement of the folds. By comparing Fig. 10.13a with 10.13b it is obvious which side is paralysed.

As pointed out earlier (Fig. 8.4) the age of the patient determined the choice of the ultrasound frequency. With male patients older than 60-70 years a frequency as low as 1 MHz sometimes absorbed so much that no acceptable recordings could be obtained. Female patients, on the other hand, proved to be less difficult independent of age.


10.4.7 Improvement of the apparatus

If a comparison of the movements of the right and left vocal fold respectively is required, two separate recordings have to be made with the present apparatus. For an example of this, the reader is referred to Fig. 10.13. However, besides being inconvenient and time-consuming, this procedure can lead to misleading results.



a. b.

Fig. 10.13 a and b. An examination of paresis a) left side movements and b) right side movements during a cough. The paresis is obviously at the right side.



c. d.

Fig. 10.13c and d. Similar to a and b but with a tone being voiced instead of a cough.

To overcome this difficulty, preliminary experiments have been made with a modification of the present apparatus. The right and left transducer is used alternately as transmitter and receiver of the ultrasonic pulses. At the same time, the TM sweep form is changed as shown in Fig. 10.14. From this figure we find that the transmitter pulse from the left transducer initiated a negative sweep while the right transmitter pulse starts a positive sweep. From this it is clear that the echoes from the right and left vocal folds are displayed in such a way that two traces appear on the TM mode display, each of which represents the movement of one of the folds. Furthermore, in this type of sweep the movement of the vocal folds relative to each other is correctly reproduced if the sweep times are suitably adjusted. Using this method, only 5000 echo measurements are made from each fold per second. However, this is ample to ensure acceptable resolution of movement details. Fig. 10.15 shows an actual recording taken by using this method. (Published Holmer, Kitzing, 1975).

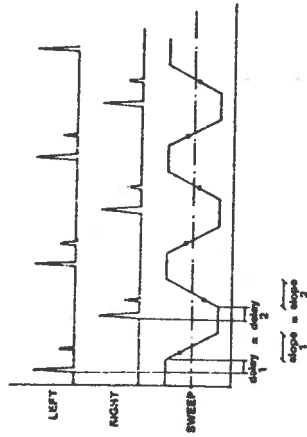


Fig. 10.14. TM-sweep to visualize the echoes from the left and right vocal folds.




Fig. 10.15. Both the author's vocal folds recorded at the same time.

REFERENCES

- Hamlet, S. and Reid, J. (1972)
Transmission of ultrasound through the larynx as a means of determining vocal fold activity. IEEE Trans. Biomed. Eng. BME-19, pp. 34-37.
- Hertz, C.H., Lindström, K. and Sonesson, B. (1970)
Ultrasonic recording of the vibrating vocal folds. Acta Otolaryng (Stockh.) 69, p. 223.
- Holmer, N.-G., Kitzing, P. and Lindström, K. (1973)
ECHO GLOTTOGRAPHY, Ultrasonic recording of vocal fold vibrations in preparations of human larynges. Acta Otolaryng 75, pp. 454-463.
- Holmer, N.-G. and Kitzing, P. (1974)
Registrering av stämbandsrörelser med ultraljud. Nordiska Akustiska Mötet i Lund, June 5-7, (Swedish).
- Holmer, N.-G. and Kitzing, P. (1975)
Localization of the vocal folds and registration of their movements by ultrasound. Proceedings Ultrasonic Congress in Medicine, Munich, p. 349.
- Holmer, N.-G. and Rundqvist, H.E. (1975)
Ultrasonic registration of the fundamental frequency of a voice during normal speech. J. Acoust. Soc. Am., Vol. 58, No. 5, Nov., pp. 1073-1077.
- Kaneko, T. et al. (1974)
L'ultrasonoglotographie. Ann. Oto.-Laryng. (Paris) t. 91, n° 7-8, pp. 403-410.
- Kitamura, T. et al. (1968)
Ultrasonoglotography. Jap. Soc. Ultrasonics in medicine., 5, p. 30.

- Kitamura, T., Kaneko, H., Asano, H. and Miura, T. (1969)
L'ULTRASONOGLOTTOGRAPHIE (Rapport préliminaire) Un procédé ultra-sonore d'inscription de l'accolement glottique au cours de la phonation. Revue de Laryngologie, No 3-4, pp. 190-195.
- Kitamura, T., Kaneko, T., Asano, H. and Miura T. (1969)
Ultrasonic diagnosis in otorinolaryngology. The Eye, Ear, Nose and Throat, No5, Vol. 48, pp. 329-337.
- Kitzing, P., Hertz, H., Holmer, N.-G. and Lindström, K. (1973)
Ultrasonic recording of vocal fold vibratory and respiratory movements, Digest of the 10th international conference on medical and biological engineering, Dresden, p. 309.