



LUND UNIVERSITY

Complete reduction of lymphoedema of the arm by liposuction after breast cancer

Brorson, Håkan; Svensson, Henry

Published in:

Scandinavian Journal of Plastic and Reconstructive Surgery and Hand Surgery

1997

[Link to publication](#)

Citation for published version (APA):

Brorson, H., & Svensson, H. (1997). Complete reduction of lymphoedema of the arm by liposuction after breast cancer. *Scandinavian Journal of Plastic and Reconstructive Surgery and Hand Surgery*, 31(2), 137-143. <http://www.ncbi.nlm.nih.gov/pubmed/9232698>

Total number of authors:

2

General rights

Unless other specific re-use rights are stated the following general rights apply:

Copyright and moral rights for the publications made accessible in the public portal are retained by the authors and/or other copyright owners and it is a condition of accessing publications that users recognise and abide by the legal requirements associated with these rights.

- Users may download and print one copy of any publication from the public portal for the purpose of private study or research.
- You may not further distribute the material or use it for any profit-making activity or commercial gain
- You may freely distribute the URL identifying the publication in the public portal

Read more about Creative commons licenses: <https://creativecommons.org/licenses/>

Take down policy

If you believe that this document breaches copyright please contact us providing details, and we will remove access to the work immediately and investigate your claim.

LUND UNIVERSITY

PO Box 117
221 00 Lund
+46 46-222 00 00

COMPLETE REDUCTION OF LYMPHOEDEMA OF THE ARM BY
LIPOSUCTION AFTER BREAST CANCER

Håkan Brorson and Henry Svensson

Scandinavian Journal of Plastic and Reconstructive
and Hand Surgery 1997; 31: 137-143.

Reprinted with kind permission.

COMPLETE REDUCTION OF LYMPHOEDEMA OF THE ARM BY LIPOSUCTION AFTER BREAST CANCER

Håkan Brorson and Henry Svensson

From the Department of Plastic and Reconstructive Surgery, Malmö University Hospital, Malmö, Sweden

(Submitted for publication 12 July 1996)

Abstract. The incidence of lymphoedema of the arm after mastectomy ranges between 8% and 38%, and it is an appreciable problem from both functional and social aspects. Conservative and previous surgical regimens have not been completely successful. In the light of these experiences, liposuction clearly constitutes an interesting new surgical approach, which is potentially capable of effecting predictable and reliable improvements in patients with lymphoedema. Twenty eight women with lymphoedema of the arm after breast cancer were consecutively treated by liposuction. Limb compression with a compression garment was instituted immediately after operation. All patients had been given radiotherapy after the operation for breast cancer. Mean preoperative volume of oedema was 1845 ml (range 570–3915), and mean volume of aspirate was 2250 ml (range 1000–3850); volume of aspirate correlated linearly with the volume of preoperative oedema. There were no major surgical complications, but blood transfusion was necessary in eight patients whose volume of aspirate exceeded 2000 ml. After 12 months ($n = 24$), an average reduction in volume of oedema of 106% was found. Such a normalisation can be expected in patients with oedema that amounts to about 2500 ml. Although the oedema cannot be completely removed in more severe cases, substantial reduction is beneficial from both functional and cosmetic aspects. We conclude that liposuction is safe and effective for reducing lymphoedema of the arm after operations for breast cancer. In a one-stage procedure, oedematous and hypertrophic fat tissue can be removed with an excellent clinical outcome.

Key words: arm lymphoedema, lymphoedema, arm lymphedema, lymphedema, breast cancer, liposuction, compression therapy, lymph therapy.

The incidence of lymphoedema of the arm after mastectomy ranges between 8% and 38% depending on whether axillary lymph nodes are excised and radiation is given (11). Prophylaxis by applying compression garments seems to be a

worthwhile adjunct, and such conservative treatment is occasionally effective even for established oedema. In many cases, however, surgical treatment is deemed necessary. In 1908, Handley placed silk threads subcutaneously in an attempt to reduce the lymphoedema by capillary forces (7). Subsequently, various materials have been inserted subcutaneously with the intention of creating channels for drainage including rubber tubes (25), polythene (8), and polyvinylchloride (Portex) (10).

Various interventions in the underlying fascia have been made to create functional lymphatic communications from the superficial to the deeper tissues (12–14, 21). The same principle lay behind the idea of implanting shaved dermal flaps (24). By using microvascular techniques, anastomoses have been established between lymph collectors and the venous system (16, 18). Transplantation of lymph collectors has also been tried (1, 2, Baumeister RG. Treatment of lymphoedemas by microsurgical autogenous lymph vessel transplantation. Presented at European Association of Plastic Surgeons, Strasbourg 1995). Promising results have recently been reported after the creation of various forms of lymphatic venous anastomoses (3, 4). Although attractive concepts, however, these methods do not regularly give acceptable clinical results. Wide excision with skin grafting remains an option in severe cases (6, 15, 19), but these patients often develop troublesome skin conditions, such as papillomatosis, eczema, lymph fistulas, keloids, ulceration, and erysipelas. Reduction of the volume of the lymphoedema by use of the less traumatic liposuction technique therefore constitutes an interesting new approach, and preliminary clinical reports

warrant further refinement and evaluation of the procedure (17, 20).

Active prevention of arm lymphoedema is important and can be achieved by non-surgical methods such as pneumatic compression, manual lymph therapy, or, more conservatively, the use of compression dressings only. These regimens can also be used to reduce minor lymphoedema. Nevertheless the condition will progress slowly and steadily. Surgical treatment becomes indicated in patients who fail to respond to conservative treatment, probably because of fibrosis. Our first liposuction was undertaken in 1987 but it was not until 1993 that a more detailed treatment protocol was established. In this paper we describe the protocol, our surgical technique, and report our results from a prospective series of patients operated on by the first author.

PATIENTS AND METHODS

Patients

Twenty eight women with a mean age of 63 years (range 46–81) and a mean disease duration of seven years (range 1–23) were consecutively operated on after having been referred by general surgeons, oncologists, and general practitioners. They had all undergone mastectomy with excision of axillary lymph nodes supplemented by postoperative irradiation. No patient was refused treatment on the grounds of age. The mean interval between the operation for breast cancer and the liposuction was eight years (range 1–24). No patient had generalised disease or local wound problems. All had previously been treated with pneumatic compression or manual lymph therapy, or both, though without satisfactory results. The lymphoedema was in most instances firm with clinical signs of fibrosis; only by pressing hard with a fingertip could an impression be created. The volume of oedema varied between 570 and 3915 ml. Seventeen patients had had bouts of erysipelas.

Surgical procedure

No intensive conservative treatment had preceded the operation. General anaesthesia was induced in all cases but five, in which nerve blockade was preferred. Neither local anaesthetic nor epinephrine was injected locally, hence the 'dry technique' was used. Through numerous 3 mm incisions, the shoulder, arm, hand — and even proximal phalanges when indicated — were treated. Normally, 30–40 incisions were needed. Cannulas were connected to a vacuum pump that gave a negative atmospheric pressure of 0.9. One cannula had an outer diameter of 3 mm (length 15 cm, three openings at the tip); another had a diameter of 4

mm (16 cm, two openings). The finer cannula was used mainly for the hand, fingers, and distal part of the forearm and also when irregularities were remedied. Liposuction was executed circumferentially, step-by-step from hand to shoulder. The incisions were left open to drain. Treated areas were subsequently compressed firmly to stem bleeding and postoperative oedema. Clean rolls of bandage were eventually applied and retained for two days. Elastic bandages were used on the arms, and non-elastic ones on the fingers. The mean operating time was 122 minutes (range 70–220). An isoxazolympenicillin or a cephalosporin was given intravenously for the first 24 hours, and then in tablet form for two weeks.

Postoperative course

The arm was held raised during the hospital stay, usually for five to seven days. Two days postoperatively the bandages were removed. Measurements were taken for a custom-made compression sleeve-and-glove garment that gave compression in the range 32 to 40 mmHg. For temporary use, an interim dressing was worn for two weeks to maintain compression until the first postoperative visit. The new custom-made compression garment was worn permanently, and was removed only briefly when showering and possibly for formal social occasions. Patients were also seen after one, three, and six months and thereafter every six months, according to the postoperative protocol. Additional visits were needed in some instances to adjust the garment (see below).

Compression technique

The postoperative compression therapy is crucial; its use and effect is thoroughly described and discussed with the patient preoperatively. If the patient has doubts about permanent and controlled compression therapy, she will not be accepted for operation. The custom-made compression garment is taken in using a special sewing-machine at each postoperative visit to compensate for reduced elasticity and reduced arm volume. This is particularly important during the first three months when the most obvious changes in volume occur, but even later it is important to adapt the garment to compensate for wear and tear. This can often be managed by the patient herself. At the three month visit the limbs are measured for new custom-made compression garments. The procedure is repeated until the volume of oedema is as close as possible to zero, whereafter new garments can be prescribed based on the latest measurements. Two sleeve-and-glove garments must always be at the patient's disposal, one being worn while the other is being washed. Each duplicate set of garments is renewed three or four times during the first year.

Measurements

At the operation the total volume of aspirate was measured. In nine instances the proportion of free fat (the supernatant) was calculated. Any units of blood given were recorded. Before and 0.5, one, three, six,

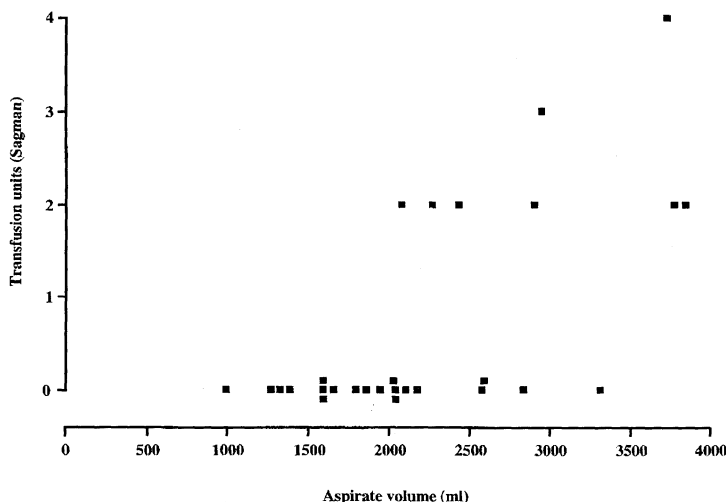


Fig. 1. Units of erythrocyte concentrate (Sagman solution) needed. When the volume of aspirate was over 2000 ml, eight patients needed transfusions.

and 12 months after operation arm volumes were recorded (ml) using the water displacement technique, the displaced water being weighed on a balance to the nearest 5 g. Both arms were measured and the difference in arm volume referred to as the volume of oedema (5, 22, 23). Besides absolute values, the decrease in the volume of oedema was also calculated as a percentage of the preoperative volume of oedema.

Statistical analysis

Measurements are presented as mean (range), unless otherwise stated. SEM is given in Fig. 3 for practical reasons. The significance of differences was assessed with Student's paired *t*-test. The percentage reduction in the volume of oedema after 12 months was compared with that recorded preoperatively, the duration of lymphoedema, and the operation serial number using multiple linear regression analysis. Linear regression was used to calculate the relationship between volume of aspirate and preoperative volume of oedema.

RESULTS

There were no major surgical complications, but one patient sustained transient paraesthesia in the arm operated on. In two instances, temporary superficial abrasions were caused at the wrist by the compression garment. One patient developed pneumonia postoperatively, and one dyspnoea. Two patients each had an episode of erysipelas about three months after the operation; one of them was a diabetic with a small burn on the arm.

Blood transfusion was necessary in eight

patients whose volumes of aspirate exceeded 2000 ml (Fig. 1). The mean volume of aspirate was 2250 ml (range 1000–3850), and the proportion of fat in the aspirate was 63% (range 41–82).

The volume of aspirate correlated linearly with the volume of preoperative oedema; the coefficient of regression was 0.7 and the coefficient of correlation 0.73 (Fig. 2).

The preoperative volume of oedema was 1845 ml (range 570–3915). The effect of operation was obvious, and during the postoperative course a further reduction was seen in the mean volume of oedema. At 12 months, it was 30 ml (from –655 to 1135) corresponding to an average relative reduction of 106% (range 66–179) (Fig. 3). These figures show that the volume actually removed sometimes exceeded the volume of oedema. In 15 patients, a normalisation or even overcorrection of the lymphoedematous condition could thus be achieved after one year.

The percentage reduction in the volume of oedema after 12 months was linearly related to the preoperative volume of oedema (slope = -0.02 , $p < 0.01$, Fig. 4) and the operation serial number (slope = 1.33 , $p < 0.05$), but showed no linearity with the duration of lymphoedema ($n = 24$).

DISCUSSION

Manual lymph therapy and compression pump-

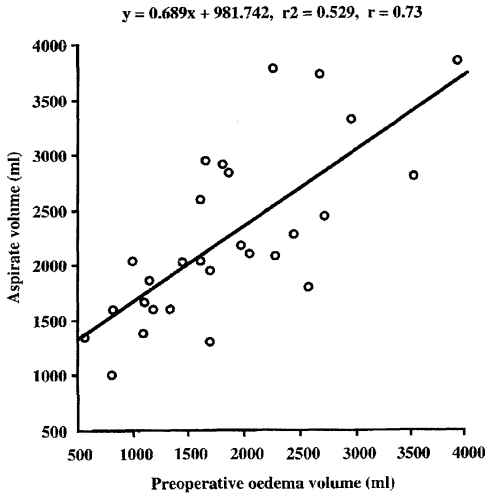


Fig. 2. Regression of volumes of aspirate and volumes of preoperative oedema.

ing are important primary methods of prevention of lymphoedema of the arm. Their direct beneficial effects on longstanding oedema with fibrosis are uncertain. Hutzschenreuter et al. (9), for instance, monitored a series of 62 patients with an initial volume of oedema of 550 ml. Despite intensive treatment in hospital for three weeks, only a 20% decrease in the volume of oedema was achieved. Furthermore, relapses occurred regularly within one year, necessitating

repeated sequences of treatment, so a surgical approach intended either simply to reduce the oedematous tissue, or to create favourable conditions for alternative drainage, seems logical. This is of course particularly obvious in patients with longstanding, massive, and fibrotic oedema. As already mentioned, however, no surgical method has so far proved sufficiently successful in reducing the excess volume of the arm.

Modern microsurgical techniques seem to be a step forward, but reported results are partly contradictory and so still not entirely successful. For instance, in a series of 52 patients treated with lymphatic-venous anastomoses and post-operative compression garments reported by O'Brien et al. (18), 30 patients had not responded at all after a three years' follow-up, whereas in 22 the mean decrease in volume of oedema was 44% (596 ml) after 4.3 years. Baumeister and Siuda (2) used lymphatic grafting combined with compression and obtained a reduction in the volume of oedema of 80% (about a litre) after three years in 11 patients. Long term follow-up of a larger group of patients showed less favourable results, however (Baumeister RG. Treatment of lymphoedemas by microsurgical autogenous lymph vessel transplantation. Presented at European Association of Plastic Surgeons, Strasbourg 1995). Campisi et

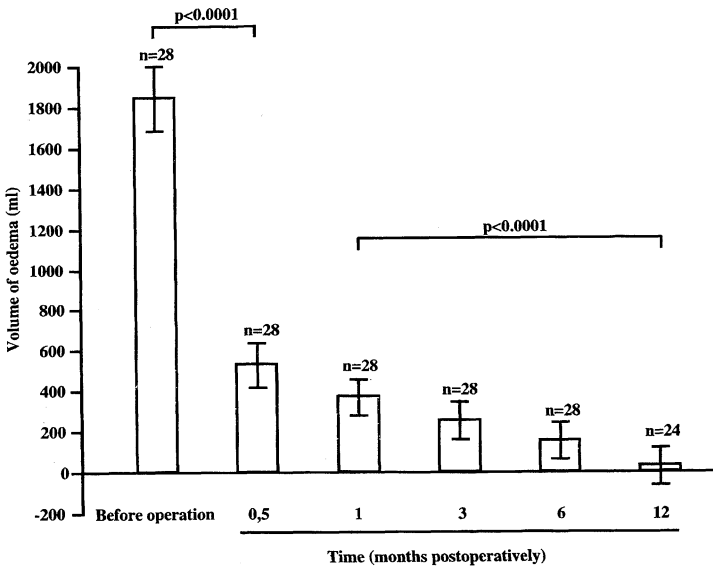


Fig. 3. Mean (SEM) volumes of oedema before and after operation. Note the pronounced effect of operation and that significant improvement continues during the subsequent postoperative course.

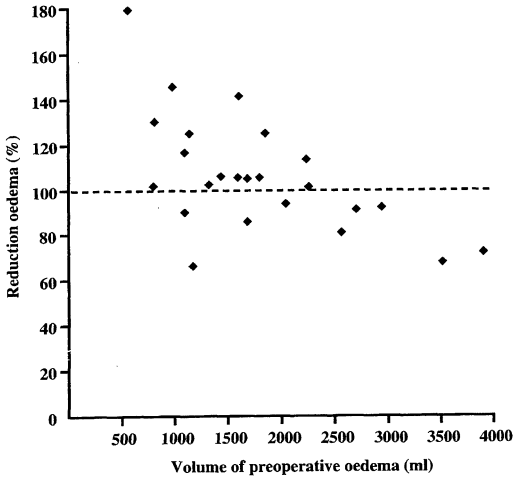


Fig. 4. Percentage reduction of volume of oedema at 12 months compared with preoperatively in 24 patients.

al. (4) undertook lymphatic anastomoses using interpositional vein grafts mainly in the lower limbs and recorded variable results when operation was combined with postoperative compression. The volume of oedema was reduced by at least 75% in 40 patients, between 50 and 75% in 18, and between 25 and 50% in six patients. In a larger series of patients treated by various forms of lymphatic-venous anastomoses, clinical out-

comes also showed pronounced intersubject variability (3). Corresponding figures were 289 (> 75%), 271 (50–75%), 119 (25–50%), while 30 patients did not respond at all.

In the light of these experiences, liposuction is clearly an interesting new surgical technique that is potentially capable of effecting predictable and reliable improvements in cases of lymphoedema. An early report in 1989 by Sando and Nahai (20), however, showed modest results. Slightly better results were reported by O'Brien et al. (17) with a mean decrease in the volume of oedema of 23%, and the present results show that further improvements are possible. Highlighting our present results in greater detail, Fig. 2 shows that the volume of aspirate is linearly related to the preoperative volume of oedema. Regression analysis showed that there was an inverse correlation between the percentage reduction in the volume of oedema and the volume of preoperative oedema after one year in 24 patients. This means that normalisation is easier to achieve when the oedema is less pronounced (Fig. 4). Despite intersubject variations in responsiveness, our results clearly show that complete reduction of the volume of oedema is possible in patients whose volume is up to approximately 2500 ml (Fig. 5). Substantial reductions can be achieved in even more severe cases. In this series, for example, oedema of

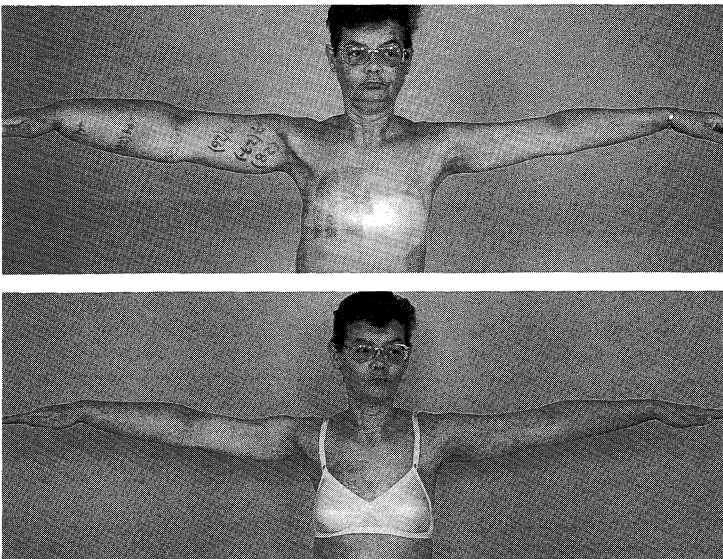


Fig. 5. (a) A 53-year old woman with a preoperative oedema volume of 2050 ml. (b) Clinical result one year after liposuction.

3915 ml was reduced by 72%. In some cases, though, results are worse, possibly as a result of marked fibrosis, although multiple regression analysis did not indicate that duration of the oedema was a significant factor.

Other factors to consider are variations in surgical technique and improvements in the method of liposuction over time. Although our early patients came through with satisfactory clinical results, there was a significant relationship between operation serial number and percentage reduction in oedema. It is therefore conceivable that increasing personal familiarity with the operative technique on the part of the surgeon will improve outcome still further.

Few complications arose and these were easily remedied. The need for blood transfusion in cases of pronounced oedema may be considered a drawback, however. An interesting refinement is therefore to do the operation after exsanguination and application of a temporary arterial occlusion, as introduced by O'Brien et al. (17).

An integral part of our lymphoedema project was the establishment of a lymphoedema team comprising of a plastic surgeon, an occupational therapist, a physiotherapist, and a social welfare officer. A 60-minute period is reserved for each scheduled visit to the team, when arm volumes are measured, garments are adjusted or renewed, the social circumstances are assessed, and other matters of concern are discussed. The patient is also encouraged to contact the team whenever any unexpected problems arise, so that these can be tackled without delay. In retrospect, a working group such as this one seems to be a prerequisite both for thorough preoperative consideration and informing patients and for successful maintenance of immediate postoperative improvements. The long term outcome is also monitored by the team, and our experiences so far indicate that a visit twice a year is necessary to maintain a good functional and cosmetic result in most cases. It is beyond the scope of this study to establish definite standards regarding indications for surgery by liposuction in lymphoedema of the arm, but preliminary findings suggest that the most impressive improvements from a general point of view are

achieved in patients with a preoperative volume of oedema exceeding one litre.

Liposuction has proved to be a safe and effective way of reducing lymphoedema of the arm after breast cancer. By using compression garments the immediate postoperative improvement is maintained and further enhanced. In this series of patients, an average reduction in the volume of oedema of 106% was achieved. Such a normalisation can be expected in patients with volumes of oedema up to approximately 2500 ml. Although complete reduction of the volume cannot be accomplished in more severe cases, substantial reductions are nevertheless beneficial from both a functional and a cosmetic point of view.

ACKNOWLEDGEMENTS

We thank occupational therapist Karin Ohlin and physiotherapist Gaby Olsson for assistance in the measurement and adjustment of garments. The project was supported by Socialstyrelsen: Statligt stimulationsbidrag för habilitering och rehabilitering, Allmänna sjukhusets i Malmö stiftelse för bekämpande av cancer, and Anslag för uppföljnings-, utbildnings-, utvecklings-, och forskningsverksamhet för läkare, Universitetssjukhuset MAS, Malmö.

REFERENCES

1. Baumeister RG, Seifert J, Wiebecke B, Hahn D. Experimental basis and first application of clinical lymph vessel transplantation of secondary lymphoedema. *World J Surg* 1981; 5: 401–407.
2. Baumeister RG, Siuda S. Treatment of lymphoedemas by microsurgical lymphatic grafting: What is proved? *Plast Reconstr Surg* 1990; 85: 64–74.
3. Campisi C, Boccardo F, Alitta P, Tacchella M. Derivate lymphatic microsurgery: indications, techniques, and results. *Microsurgery* 1995; 16: 463–468.
4. Campisi C, Boccardo F, Tacchella M. Reconstructive microsurgery of lymph vessels: the personal method of lymphatic-venous-lymphatic (LVL) interpositioned grafted shunt. *Microsurgery* 1995; 16: 161–166.
5. Casley-Smith JR. Measuring and representing peripheral oedema and its alterations. *Lymphology* 1994; 27: 56–70.
6. Charles H. Elephantiasis of the leg. In: Latham A, English TC, eds. *A system of treatment*. Vol 3. London: Churchill, 1912: 516.
7. Handley WS. Lymphangioplasty: A new method for the relief of the brawny arm of breast-cancer

- and for similar conditions of lymphatic oedema. Preliminary note. *Lancet* 1908; i: 783-785.
8. Hogeman KE. Artificial subcutaneous channels in draining lymphoedema. *Acta Chir Scand* 1955; 110: 154-156.
 9. Hutzschenreuter PO, Wittlinger H, Wittlinger G, Kurz I. Post-mastectomy arm lymphoedema: treated by manual lymph drainage and compression bandage therapy. *Arch Phys Med Rehabil* 1991; 1: 166-170.
 10. Jantet GH, Taylor GW, Kinmonth JB. Operations for primary lymphoedema of the lower limbs. Results after 1 to 9 years. *J Cardiovasc Surg (Torino)* 1961; 2: 27-36.
 11. Kissin MW, Querci della Rovere G, Easton D, Westbury G. Risk of lymphoedema following the treatment of breast cancer. *Br J Surg* 1986; 73: 580-584.
 12. Kondolón E. Die operative Behandlung der elephantiasischen Ödeme. *Zentralbl Chir* 1912; 30: 1022-1025.
 13. Lanz O. Eröffnung neuer Abfuhrwege bei Stauung in Bauch und unteren Extremitäten. *Zentralbl Chir* 1911; 38: 153-155.
 14. Lexer E. Erworbenener Elephantiasis. *Munch Med Wochenschr* 1919; 66: 1274-1276.
 15. Macey HB. A new surgical procedure for lymphoedema of the extremities. Report of a case. *Proceedings of the Staff Meetings, Mayo Clinic* 1940; 15: 49-52.
 16. Nielubowicz J, Olszewski W. Surgical lymphaticovenous shunts in patients with secondary lymphoedema. *Br J Surg* 1968; 55: 440-442.
 17. O'Brien B McC, Khazanchi RK, Kumar PAV, Dvir E, Pederson WC. Liposuction in the treatment of lymphoedema; a preliminary report. *Br J Plast Surg* 1989; 42: 530-533.
 18. O'Brien B McC, Mellow CG, Khazanchi RK, Dvir E, Kumar V, Pederson WC. Long-term results after microlymphaticovenous anastomoses for the treatment of obstructive lymphoedema. *Plast Reconstr Surg* 1990; 85: 562-572.
 19. Poth EJ, Barnes SR, Ross GT. A new operative treatment for elephantiasis. *Surg Gynecol Obstet* 1947; 84: 642-644.
 20. Sando WC, Nahai F. Suction lipectomy in the management of limb lymphoedema. *Clin Plast Surg* 1989; 16: 369-373.
 21. Sistrunk WE. Contribution to plastic surgery. *Ann Surg* 1927; 85: 185-193.
 22. Swedborg I. Effectiveness of combined methods of physiotherapy for postmastectomy lymphoedema. *Scand J Rehabil Med* 1980; 12: 77-85.
 23. Swedborg I. Voluminometric estimation of the degree of lymphoedema and its therapy by pneumatic compression. *Scand J Rehabil Med* 1977; 9: 131-135.
 24. Thompson N. Surgical treatment of chronic lymphoedema of the lower limb. With preliminary report of new operation. *BMJ* 1962; ii: 1566-1573.
 25. Walther C. Note sur une nouvelle méthode de traitement de l'éléphantiasis des membres. *Bull Acad Natl Med*, 3 Sér. 1918; 79: 195-198.

Correspondence to:

Håkan Brorson, MD

Department of Plastic and Reconstructive Surgery

Malmö University Hospital

SE-205 02 Malmö

Sweden

