



# LUND UNIVERSITY

## Diode Laser-Mediated ALA-PDT Guided by Laser-Induced Fluorescence Imaging

af Klinteberg, C; Wang, I; Karu, I; Johansson, Thomas; Bendsöe, Niels; Svanberg, Katarina; Andersson-Engels, Stefan; Svanberg, Sune; Canti, G; Cubeddu, R; Pifferi, A; Taroni, P; Valentini, G

2002

[Link to publication](#)

### *Citation for published version (APA):*

af Klinteberg, C., Wang, I., Karu, I., Johansson, T., Bendsöe, N., Svanberg, K., Andersson-Engels, S., Svanberg, S., Canti, G., Cubeddu, R., Pifferi, A., Taroni, P., & Valentini, G. (2002). *Diode Laser-Mediated ALA-PDT Guided by Laser-Induced Fluorescence Imaging*. (Lund Reports in Atomic Physics; Vol. LRAP-287). Atomic Physics, Department of Physics, Lund University.

### *Total number of authors:*

13

### **General rights**

Unless other specific re-use rights are stated the following general rights apply:

Copyright and moral rights for the publications made accessible in the public portal are retained by the authors and/or other copyright owners and it is a condition of accessing publications that users recognise and abide by the legal requirements associated with these rights.

- Users may download and print one copy of any publication from the public portal for the purpose of private study or research.
- You may not further distribute the material or use it for any profit-making activity or commercial gain
- You may freely distribute the URL identifying the publication in the public portal

Read more about Creative commons licenses: <https://creativecommons.org/licenses/>

### **Take down policy**

If you believe that this document breaches copyright please contact us providing details, and we will remove access to the work immediately and investigate your claim.

LUND UNIVERSITY

PO Box 117  
221 00 Lund  
+46 46-222 00 00

REPORT

**Diode Laser-Mediated ALA-PDT Guided by Laser-Induced  
Fluorescence Imaging**

Lund Reports on Atomic Physics

LRAP-287

Lund, August 2002

# Diode laser-mediated ALA-PDT guided by laser-induced fluorescence imaging

Claes af Klinteberg<sup>1,2</sup>, Ingrid Wang<sup>1,3</sup>, Inga Karu<sup>1,4</sup>, Thomas Johansson<sup>1,2</sup>,  
Niels Bendsoe<sup>1,5</sup>, Katarina Svanberg<sup>1,3</sup>, Stefan Andersson-Engels<sup>1,2</sup>,  
Sune Svanberg<sup>1,2</sup>, Gianfranco Canti<sup>6</sup>, Rinaldo Cubeddu<sup>7</sup>, Antonio Pifferi<sup>7</sup>,  
Paola Taroni<sup>7</sup> and Gianluca Valentini<sup>7</sup>

<sup>1</sup>Lund University Medical Laser Centre (I.K. guest researcher)

<sup>2</sup>Department of Physics, Lund Institute of Technology, Lund, Sweden

<sup>3</sup>Department of Oncology, Lund University Hospital, Lund, Sweden

<sup>4</sup>Department of Anaesthesiology, Mustamäe Hospital, Tallinn, Estonia

<sup>5</sup>Department of Dermatology, Lund University Hospital, Lund, Sweden

<sup>6</sup>Department of Pharmacology, University of Milan, Milan, Italy

<sup>7</sup>INFN-Department of Physics and CEQSE-CNR, Politecnico di Milano, Milan, Italy

## ABSTRACT

Photodynamic therapy using  $\delta$ -aminolevulinic acid-induced protoporphyrin IX as a photosensitizer has been performed on a variety of pre-cancerous skin lesions and non-melanoma skin malignancies. A fibre-coupled diode laser-system, emitting continuous wave light at 633 nm with an output power of 1.5 W, was used as a treatment light source. Its clinical efficacy was, as expected, comparable to that of conventional lasers used in this kind of treatment, with a significant improvement in terms of portability and easy handling.

To monitor the accumulation of PpIX in the lesions, two fluorescence imaging systems were used. One of the systems was based on the processing of identical images simultaneously recorded in different wavelength bands. By forming ratios, an optimal contrast function between the lesion and the normal skin could be formed. The second system acquired sequential images with different delays after the excitation pulse. These images were used to calculate the fluorescence lifetime for each picture element. Differences in the lifetimes could be used to outline the lesions.

**Keywords:**  $\delta$ -aminolevulinic acid, ALA; diode laser; fluorescence imaging; fluorescence spectroscopy; photodynamic therapy

## INTRODUCTION

Photodynamic therapy (PDT) using topically applied  $\delta$ -aminolevulinic acid (ALA) for the induction of protoporphyrin IX (PpIX) as a photosensitizer has been used in particular in the treatment of various cutaneous malignancies [1-7]. Both coherent and non-coherent light has been exploited for the excitation of the photosensitizer [8]. Non-coherent light-sources can be used in the treatment of skin lesions. However, spectra of filtered lamps are usually wider than the absorption peak of the photosensitizer. Thus, most of the light does not contribute

to the PDT, but is absorbed by the tissue. This leads to a rise in temperature, which can be substantial. Another limitation of filtered lamps is the difficulty to focus the light into optical fibres, which are needed for treatment of lesions in the hollow organs of the body. This is not a problem when lasers are used. The main disadvantage of conventional lasers is the unwieldiness that makes their use in clinical practice inconvenient. Diode lasers, on the other hand, are small and easy to handle. They have, however, not until now been available with adequate output power at wavelengths around

635 nm, where PpIX has an absorption maximum that can be utilised for PDT.

The aim of this study was to demonstrate the clinical usefulness of a diode laser emitting light around 635 nm, and to illustrate different imaging techniques that can be used for the visualisation of tumour borders and the build-up of the photosensitizer. Two imaging systems, based on wavelength dispersed and time-resolved fluorescence monitoring, respectively, were employed.

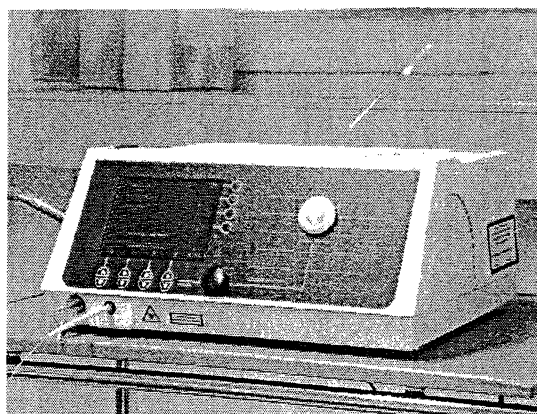
## METHODS

### *Patients*

Eight patients (6 males and 2 females) with 13 lesions – 7 basal cell carcinomas (BCCs), 3 lesions with Bowen's disease, 2 actinic keratosis lesions (AK), and 1 minimally invasive squamous cell carcinoma (SCC) – were included in the study following histopathological verification of the diagnosis. Six of the lesions were localised in the head and neck region, 5 on the extremities, and 2 on the trunk. All lesions were photodocumented before and after treatment. At the 3 months follow-up visit the lesions were photodocumented and evaluated visually and by palpation.

### *Drug*

For the induction of PpIX, topically applied ALA (Porphyrin Products #091295, 20% by weight in Essex cream) was used. Before ALA application, the lesion was prepared by removing crusts and in some cases debulking of the tumour volume by curettage. Then, ALA was applied with a margin of 10 mm in the visibly normal skin and covered with a waterproof dressing (Tegaderm, 3M) for 4-8 hours for 6 patients, and 20-25 hours for 2 patients. During this time period, the ALA cream was removed 2-3 times for about 10 minutes to perform multi-colour and lifetime imaging, and was then



**Fig. 1.** A close-up of the diode laser used for PDT.

smearred out on the area and covered with the dressing again. Prior to the therapeutic laser irradiation, the dressing and remaining ALA cream were removed.

### *Light source*

The irradiation was performed by the portable (18×37×42 cm<sup>3</sup>, 16 kg) diode laser unit (Ceralas PDT635, CeramOptec GmbH, Bonn, Germany, see Fig. 1), emitting continuous wave light at a wavelength of 633 nm. The power from the distal end of the 600- $\mu$ m-diameter output fibre could be adjusted up to 1.5 W. A total light dose of 60 J/cm<sup>2</sup> was given to all lesions with the fluence rate kept below 110 mW/cm<sup>2</sup> to avoid hyperthermic effects in the tissue. Only one ALA-PDT session was performed within the scope of this study.

### *Multi-colour fluorescence imaging*

Multi-colour fluorescence imaging was carried out by simultaneous acquisition of spatially identical images, using different optical bandpass filters, as earlier described in detail in Refs [9,10]. The fluorescence was induced by ultraviolet light (390 nm) from a frequency-doubled Alexandrite laser. The excitation light was delivered to the tissue with an optical fibre. A gated image-intensified CCD camera, synchronized with the laser, was used to acquire the fluorescence images.

**Table 1.** Summary of the treatment results evaluated by visual inspection three months post treatment. The results were classified as complete remission (CR), partial remission (PR), or no remission (NR).

Patient	Lesion	Diagnosis	Location	Prior treatment	3 months response
1	1	SCC	Finger	Cryosurgery	CR
2	1	BCC	Neck	2 × PDT	CR
3	1	BCC	Lower leg	Cryosurgery	PR
4	1	Bowen's disease	Belly	Cytostatic cream	CR
	2	Bowen's disease	Shoulder	Cytostatic cream	CR
	3	Bowen's disease	Lower arm	Cytostatic cream	PR
5	1	AK	Chin	—	CR
	2	AK	Chin	—	CR
	3	BCC	Forehead	Surgical excision	NR
6	1	BCC, nodular	Lower leg	—	PR
7	1	BCC, superficial	Neck	—	CR
	2	BCC, superficial	Upper arm	—	CR
8	1	BCC, nod. cystic	Nose	Surgical excision	CR

Furthermore, a colour CCD camera simultaneously recorded the normal reflected light image. A dimensionless contrast function was calculated as the ratio between the PpIX-related fluorescence (with an emission maximum at 635 nm) and the autofluorescence (in the wavelength region between 500 and 550 nm), for each pixel of the fluorescence images. This function was presented as a pseudo-colour or grey scale image, which could be super-imposed on the same-size normal image from the colour CCD camera.

#### *Fluorescence lifetime imaging*

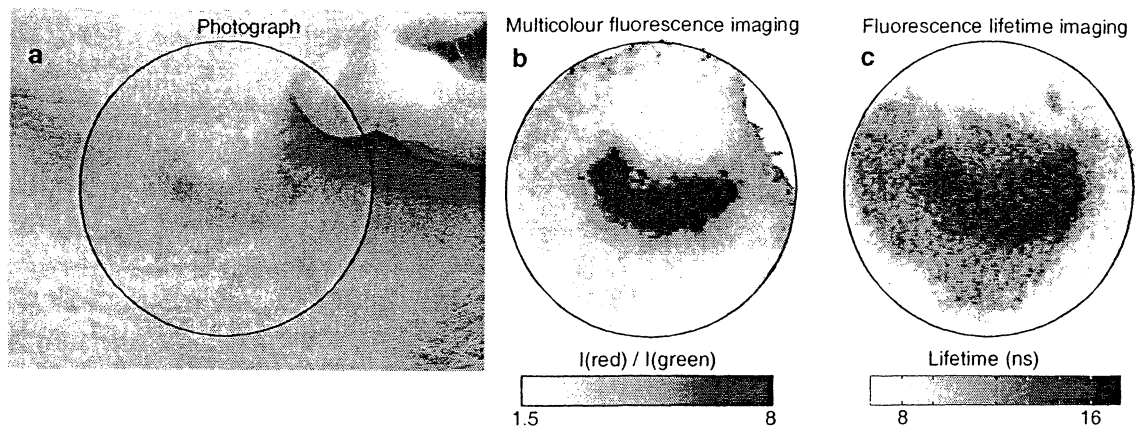
The experimental set-up used for tumour demarcation by fluorescence lifetime imaging is similar to the system described in detail by Cubeddu *et al.* [11]. The basic elements of the system are a nitrogen-laser-pumped dye laser, emitting 1-ns-long pulses at 405 nm, and a gateable intensified CCD camera, with a gate rise time of 2 ns. A cut-off filter (Kodak Wratten N. 22), transmitting the red fluorescence light (about 20% at 560 nm and 90% at 610 nm), was placed in front

of the detector. Thus, most of the autofluorescence, which has its emission maximum in the blue-green wavelength region, was suppressed. The images were acquired in 7 seconds and processed by a high-performance image board in a personal computer.

In the present study, four gated images were recorded from each lesion: 0, 5, 10, and 20 ns after the excitation pulses, respectively. According to a rough model, the fluorescence intensity following a short excitation pulse can be approximated with a mono-exponential decay function. The spatial distribution of the decay time can then be calculated by a linear regression, performed pixel by pixel, on the acquired images. This leads to a lifetime matrix, which is plotted as a pseudo-colour or grey scale image.

## **RESULTS AND DISCUSSION**

The outcome of the initial treatment is presented in Table 1. Complete remission was obtained in nine lesions (69%), while three lesions (23%) responded partially. One lesion did not respond at all to the



**Fig. 2.** White light photograph (a), multi-colour fluorescence image (b) and fluorescence lifetime image (c) of a superficial BCC close to the ear of patient #7. The circles in the two fluorescence images matches the one in the photo. The fluorescence lifetime image was acquired 30 min after ALA application, while the multi-colour fluorescence image was recorded 6 hours post ALA.

therapeutic procedure. This result is in good agreement with what could be expected for these types of lesions after a single treatment session. It should also be noted that eight of the lesions were recurrent tumours after given treatment. Only five lesions were not treated before. Out of these, four responded completely, and only one nodular cystic BCC on the leg responded partially. From experience we know that nodular cystic tumours are more resistant to PDT as compared to only nodular ones. It is also known that nodular lesions usually have to be treated more than once [5].

As expected, there does not seem to be any significant difference between the diode laser and previously used therapeutic laser systems emitting light at 635 nm, such as a dye-laser pumped by a frequency doubled Nd:YAG-laser. There are, however, several advantages using a diode laser as compared to other laser systems. First of all it is a turn-key system, which is very user-friendly. With this system there is no need for changing dyes or aligning the laser, which needs skilled technicians. Furthermore, the diode laser is easily moved from one room to another.

No high-voltage, water-cooling, or gas bottles are needed, only a standard electric outlet. Still, the output power from the treatment fibre can be up to 1.5 W. Such a high power is useful to treat large skin lesions or when endoscopic treatments of extensive areas have to be carried out.

For lesions not requiring fibre-optic light delivery, such as skin lesions, it is also possible to use a filtered lamp as a treatment light source. Lamps are, however, limited in the photodynamically active emission, *i.e.* the power in the wavelength range overlapping the absorption band of the photosensitizer resulting in induction of local hyperthermia. Filtered lamp light is also difficult to guide through an optical fibre, due to the difficulty to focus it. For applications requiring fibre optic delivery, a laser is much more efficient.

The preferential accumulation of PpIX in hyperproliferative tissues together with its strong fluorescence can be exploited for diagnostic purposes. Moreover, imaging techniques based on laser induced fluorescence enable one to monitor the build-up of the photosensitizer in the

whole ALA treated area. As the penetration of UV light is only some hundreds of micrometers, a marked preciseness in the detection of tumour borders can be obtained in an early phase of the tumour development.

The fluorescence imaging systems were both tested for tumour demarcation. As an example, Fig. 2a shows a photograph of a superficial BCC near the ear of patient #7. The corresponding multi-colour image acquired 6 h after the ALA application is depicted in Fig. 2b. A darker pixel corresponds to a higher value of the ratio between the PpIX-fluorescence and the autofluorescence. The lesion is marked with a sharp border, while the normal skin results in lower pixel-values.

The tumour area can also be delineated by a grey-scale image obtained with the lifetime imaging system. In fact, the effective fluorescence lifetime is a measure of the balance between the short-lived endogenous signal and the long-lived exogenous one, which is higher in neoplastic tissues. Accordingly, as shown in Fig. 2c, the fluorescence lifetime is considerably longer in the lesion than in the surrounding normal skin.

In conclusion, due to its portability and easy handling, the diode laser used in this study significantly facilitates the work in the field of ALA-PDT. Its clinical efficacy is comparable to that of conventional lasers used for ALA-PDT, as expected. The introduction of convenient diode laser systems for ALA-PDT can be considered as a break-through in the practical management of malignant skin lesions. At the same time, imaging techniques can contribute to improve the therapeutic effectiveness of PDT. Fluorescence imaging, either spectrally or time-resolved, allows an accurate localization of the lesion to be treated. Moreover, information on the accumulation of PpIX and its

photobleaching following PDT can be obtained from spectroscopic data, and profitably used in order to optimize the therapeutic protocol.

## ACKNOWLEDGEMENTS

This work was supported by the European Community Access to Large Scale Facilities Programme (Contract ERBFMGECT950020), the Gunnar Nilsson Foundation, the Berta Kamprad Foundation, the Medical Faculty at Lund University, and the Swedish Research Council for Engineering Sciences. A grant from the Swedish Institute to support this project is also highly appreciated.

## REFERENCES

1. Kennedy JC, Pottier RH, Pross DC. Photodynamic therapy with endogenous protoporphyrin IX: Basic principles and present clinical experience. *J Photochem Photobiol B* 1990;6:143-8.
2. Kennedy JC, Pottier R. Endogenous protoporphyrin IX, a clinically useful photosensitizer for photodynamic therapy. *J Photochem Photobiol B* 1992;14:275-92.
3. Wolf P, Rieger E, Kerl H. Topical photodynamic therapy with endogenous porphyrins after application of 5-aminolevulinic acid. An alternative treatment modality for solar keratoses, superficial squamous cell carcinomas, and basal cell carcinomas? *J Am Acad Dermatol* 1993;28:17-21.
4. Cairnduff F, Stringer MR, Hudson EJ, Ash DV, Brown S.B. Superficial photodynamic therapy with topical 5-aminolaevulinic acid for superficial primary and secondary skin cancer. *Br J Cancer* 1994;69:605-8.
5. Svanberg K, Andersson T, Killander D, Wang I, Stenram U, Andersson-Engels S et al. Photodynamic therapy of non-melanoma malignant tumours of the skin using topical  $\delta$ -amino

- levulinic acid sensitization and laser irradiation. *Br J Dermatol* 1994;130:743-51.
6. Calzavara-Pinton PG. Repetitive photodynamic therapy with topical  $\delta$ -aminolaevulinic acid as an appropriate approach to the routine treatment of superficial non-melanoma skin tumours. *J Photochem Photobiol B* 1995;29:53-7.
  7. Warloe T, Peng Q, Heyerdahl H, Moan J, Steen HB, Giercksky K-E. Photodynamic therapy with 5-aminolevulinic acid induced porphyrins and DMSO/EDTA for basal cell carcinoma. In: Cortese DA (ed) 5th International Photodynamic Association Biennial Meeting. Vol. 2371. Bellingham, WA: SPIE, 1995:226-235.
  8. Wilson BC. Light sources for photodynamic therapy. *Photodynamics News* 1998;1(3):6-8.
  9. Svanberg K, Wang I, Colleen S, Idvall I, Ingvar C, Rydell R et al. Clinical multi-colour fluorescence imaging of malignant tumours - initial experience. *Acta Radiol* 1998;39:2-9.
  10. Andersson-Engels S, Johansson J, Svanberg S. Medical diagnostic system based on simultaneous multispectral fluorescence imaging. *Appl Opt* 1994;33:8022-9.
  11. Cubeddu R, Pifferi A, Taroni P, Valentini G, Canti G. Tumor detection in mice by measurement of fluorescence decay time matrices. *Opt Lett* 1995;20:2553-5.