LUND UNIVERSITY

Increased pulsatility in the fetal ductus venosus is not related to altered cardiac strain in high-risk pregnancies.

Dahlbäck, Charlotte; Gudmundsson, Saemundur

Published in:
Journal of Maternal-Fetal & Neonatal Medicine

DOI:
10.3109/14767058.2015.1047337

2016

Document Version:
Peer reviewed version (aka post-print)

Link to publication

Citation for published version (APA):
Dahlbäck, C., & Gudmundsson, S. (2016). Increased pulsatility in the fetal ductus venosus is not related to altered cardiac strain in high-risk pregnancies. *Journal of Maternal-Fetal & Neonatal Medicine*, *29*(8), 1328-1333. https://doi.org/10.3109/14767058.2015.1047337

Total number of authors:
2

General rights
Unless other specific re-use rights are stated the following general rights apply:
Copyright and moral rights for the publications made accessible in the public portal are retained by the authors and/or other copyright owners and it is a condition of accessing publications that users recognise and abide by the legal requirements associated with these rights.
• Users may download and print one copy of any publication from the public portal for the purpose of private study or research.
• You may not further distribute the material or use it for any profit-making activity or commercial gain
• You may freely distribute the URL identifying the publication in the public portal

Read more about Creative commons licenses: https://creativecommons.org/licenses/

Take down policy
If you believe that this document breaches copyright please contact us providing details, and we will remove access to the work immediately and investigate your claim.

LUND UNIVERSITY

PO Box 117
221 00 Lund
+46 46-222 00 00

Increased pulsatility in the fetal ductus venosus is not related to altered cardiac strain in high-risk pregnancies

Charlotte Dahlbäck MD, Saemundur Gudmundsson MD, PhD

Lund University, Department of Obstetrics and Gynecology, Skåne University Hospital, Malmö, Sweden.

Correspondence to:

Saemundur Gudmundsson Professor, MD, PhD,
University of Lund,
Dept. of Obstetrics and Gynecology
Skane University Hospital
SE-20502 Malmö
Sweden
Tel: +46 40 332095
Fax: +4640962600
e-mail: saemundur.gudmundsson@med.lu.se

Key words: ultrasound, Velocity vector imaging, fetal heart, strain, Doppler, ductus venosus, umbilical vein, pulsations, hypoxia.

Abstract

Objective: Blood flow velocity patterns in fetal veins are considered to reflect cardiac function, but have not been convincingly documented. The aim of this study was to generate reference values for fetal cardiac strain and compare it with results in fetuses with signs of increased venous pulsatility.

Methods: Cardiac 4 chamber-loops were prospectively stored and analyzed for strain and strain rate in a cohort of 250 healthy fetuses. The results were compared with recordings in 38 fetuses with increased vascular impedance in the umbilical artery, including several with abnormal blood flow velocities in the ductus venosus and umbilical vein.

Results: In the control group, strain rate was slightly higher in the right ventricle, but strain and velocities were similar. There was a significant effect of frame rate on the values of strain and strain rate, but not on velocity. No differences in cardiac strain or strain rate were observed between the control group and the compromised fetuses. There was no correlation between changes in venous blood flow and cardiac strain.

Conclusions: Increased venous pulsatility was not related to fetal cardiac strain. This might indicate that the ductus venosus does not primarily open due to increased central venous pressure and that cardiac strain is affected late in the process of moderate fetal hypoxia.

Introduction

Placental insufficiency, resulting in severe intra-uterine growth restriction (IUGR) is a major cause of perinatal morbidity and mortality. The heart is a central organ in the fetal adaptive mechanisms to hypoxia, but studies on heart function during hypoxia have given conflicting results. While some studies have shown maintained cardiac output in fetuses with IUGR, others suggest that subclinical cardiac dysfunction can be present from early stages of fetal deterioration[1-7].

Fetal echocardiography was initially employed to detect structural abnormalities, but in recent years its use in fetal cardiac function assessment has increased. New echocardiographic imaging technology such as tissue Doppler imaging (TDI) and 2D speckle tracking enables quantification of regional and global myocardial deformation and velocities[8]. Very subtle changes can be identified and, in adults, deformation has been demonstrated as being a sensitive marker of cardiac dysfunction[9].

Doppler-derived strain imaging (Tissue Doppler Imaging -TDI) of the fetal heart has provided valuable information on global and regional myocardial motion and deformation, with higher sensitivity in detecting subclinical fetal cardiac dysfunction compared to conventional Doppler[5,10]. TDI is, however, limited by angle dependency, sensitivity to extra-cardiac movement, need for good-quality images and time-consuming post-processing. Speckle tracking techniques have therefore come into focus. Proposed advantages with speckle tracking include its ability to measure motion independent of the angle of acquisition and the ability to measure motion in multiple directions[11].

2D speckle-tracking employs B-mode images, in which acoustic markers (speckles) are tracked frame-by-frame. An algorithm then calculates myocardial strain (deformation) and strain rate (rate of deformation). As it employs B-mode images, it is in theory an angle independent method. Several softwares are commercially available,

employing different algorithms and tracking techniques. Application of speckle tracking techniques in the fetus has shown promise, but is far from straightforward.

Fetal systemic venous blood flow velocity has a characteristic fluctuating pattern, reflecting the pressure in the right atrium. In fetuses with heart failure or during severe hypoxia an increase in pulsatility can be detected, which is thought to be a reflection of increased central venous pressure[12].

The aim of this study was to identify normal reference ranges for strain and strain rate of the right and left ventricles in healthy fetuses at different gestational ages, and to compare these to results obtained from fetuses with different levels of placental insufficiency, with or without abnormalities in venous blood flow velocity.

Methods

Analysis of cardiac global longitudinal strain, strain rate and velocity was performed on the fetal right and left ventricles in 252 singleton healthy fetuses and in 38 fetuses with increased vascular impedance in the umbilical artery, including several with abnormal venous circulation.

Control group:

Women with uncomplicated singleton pregnancies, attending routine second- or third trimester ultrasound scanning at the Department of Obstetrics and Gynecology at Skane University Hospital in Malmö (Sweden) were invited to participate in the study. A separate 2D ultrasonography scanning was performed by one investigator aiming at examining 10 fetuses per week at gestational ages 19 to 42. Exclusion criteria were systemic disease of the mother, fetal chromosomal/structural abnormalities and pregnancy complications such as preeclampsia, hypertension, diabetes, oligohydramniosis and intra-uterine growth restriction. All the examinations were performed by one operator (CD).

Study group:

Women undergoing conventional fetal-placental Doppler examination due to suspected fetal intra-uterine growth restriction, where included in the study when increased vascular resistance in the umbilical artery (UA) was recorded (pulsatility index (PI) >2 SD above mean for corresponding gestational age). The Doppler examinations were performed by ultrasound technicians according to routine clinical practice. The UA PI was recorded from a free-floating central part of the umbilical cord at a zero degree angle. PI was analyzed during three consecutive cardiac cycles and compared with normal reference values. Umbilical venous blood flow was recorded in the central intra-abdominal part of the vein and in a free-floating part of the vein in the cord. UV-pulsations were defined as a rhythmic decrease in maximum

blood velocity of at least 15%. The ductus venous (DV) pulsatility index for veins (PIV) was also recorded in either a midsagittal or transverse view positioning the Doppler gate at the DV isthmic portion[13]. A 2D video clip of the fetal cardiac four-chamber view was then also obtained as described below.

Gestational age was determined by ultrasound in all cases at a second trimester routine scanning. At delivery, gestational age, birthweight, birthweight percentile, Apgar score, mode of delivery, pH and BE in umbilical artery and vein, and pregnancy complications were recorded. The ethical review board at the University of Lund approved the study and written informed consent was obtained from the participants.

A 2D (B-mode) grey scale image of the fetal cardiac four chamber view was obtained by using GE Voluson E8 ultrasound systems. Images were stored in dicom format and exported to a Syngo Dynamics workstation for later off-line analysis. A typical wall motion velocity vector recording in the left ventricle is shown in figure 1. During examination efforts were made to obtain high quality images with as high frame rate as possible. This was achieved by reducing B-mode image depth, narrowing sector width, avoiding fetal and maternal movements, using high resolution and capturing the entire length of the ventricle in question. A slightly angled apical or basal four-chamber view was preferentially obtained. The frame rate used in image acquisition was noted. A cardiac cycle was identified by assessment of the movement of the mitral valve and end-diastole was defined by the complete closure of the valve. Heart rate was determined by the time interval between two consecutive end-diastolic frames and a single cardiac cycle was analyzed.

Analyses of B-mode images for velocity, strain and strain rate of the right and left ventricle were performed using the Syngo VVI version 1 software according to the manufacturer's instructions. The off-line analysis were performed by one operator (CD),

which was informed of increased umbilical artery vascular impedance in the high-risk group, but was unaware of the degree nor of the results of venous Doppler recording. The endocardium of the ventricles was traced in end-diastole with the reference plane set to the medial and lateral atrioventricular valve annulus, respectively. Care was taken not to include the papillary muscles. The software created tracking curves automatically in subsequent frames. The accuracy of tracking was subjectively verified and corrected when necessary. The software generated velocity vectors and global peak longitudinal cardiac velocity, strain and strain rate were calculated.

Statistical analysis

Data was analyzed with IBM SPSS Statistics version 21. One-way Anova was used for investigating suspected differences between groups. Conventional linear regression analysis was conducted in order to determine the relationship between myocardial strain, gestational age and frame rate. Spline regression was performed to establish reference ranges of the normal group and to assess possible non-linearity in the relationship between strain/strain rate and gestational age. Adjustment to a set frame rate was made using regression with ordinary least squares.

Results

In the control group, the ventricles were successfully traced in 248 out of 250 fetuses. One patient was excluded due to pre-eclampsia and intra-uterine growth restriction with an early debut and one due to technical problems. There were more than ten fetuses included per gestational weeks 19-39, and 7 patients/week for weeks 40-42. Characteristics and information on pregnancy outcome of the control group and study group are displayed in Table 1. DV blood velocity was recorded in 143 of the controls all having normal pattern. Average global peak longitudinal velocity, strain and strain rate for the left and right ventricles were measured and the overall median and mean values of the control group are given in Table 2. Non-significant differences were found between strain values of the right and left ventricles using a paired samples t-test. The strain rate of the left ventricle was slightly greater compared to the right ventricle (mean -2.12 and -2.01, respectively, p=0.006). Curves corresponding to the mean strain ± 2SD of the control group are shown in figures 2 and 3. Data were adjusted for frame rate (see below). The measured strain values were unaffected by gestational age. Table 3 demonstrates the regression formulas for the mean curves of strain and strain rate for the left and right ventricles, respectively.

The study group consisted of 38 patients with signs of increased resistance in the umbilical artery (UA). The PI in UA was + 2-3 SD above mean in 15 patients (adjusted for gestational age) and >3 SD above mean in 14 patients (with a positive flow in diastole). One patient exhibited absent blood flow in diastole and 8 had a reversed diastolic blood flow in the UA. In the study group, mean gestational age at examination was 220.7 days with a

minimum of 141 and a maximum of 277 days. The mean heart rate was 136,3 (range 119-150) and the mean frame rate was 57,9 (range 30-111). The mean gestational age at delivery was 32+3 weeks (min 21+1 and max 39+6), mean birthweight (BW) was 1505 ± 768 g, with a BW deviance from mean of -31.7% ± 17. The rate of cesarean section was 73.8%. Ductus venosus (DV) PIV was measured in all the cases and adjusted to gestational age by calculation of the z-score according to Kessler et al.[13] (mean DV PIV z-score 2.3, SD 4.64). There were 7 with a DV PIV above +2SD. UV-pulsations were observed in 10 cases and the perinatal mortality in the study group was 13,2%. None of the newborns had a pH in the umbilical artery of below 7.1, suggesting mild hypoxia. Apgar score was below 7 at 5 min in 8 newborns all delivered before 34 weeks and 4 were delivered before 26 weeks of gestation. Of these 8, there were 5 that had abnormal venous pulsatilty, but all had normal cardiac strain measurements.

Calculated strain and strain rate of both ventricles showed increasing values for strain and strain rate at increasing frame rates. The maximal frame rate obtained decreased with gestational age. Frame rates during recording ranged between 30 and 212 (mean 80.4 ± 33.0 SD). Values of strain and strain rate were adjusted for a fixed reference frame rate of 80 Hz in order to decrease the influence of frame rate on strain and strain rate measurements.

The mean heart rate was 136 (±9.8 SD). The effect of fetal heart rate were also estimated. Heart rate had no effect on the calculated strain, but a small and significant effect on velocity and strain rate in both ventricles.

Image acquisition was obtained preferentially from the apical or basal view. However, if this was not feasible the angle available during examination was used. To assess whether the

angle of acquisition had an effect on the recordings, results were divided into 5 groups depending on angle of acquisition (apex, base, side, apex (slightly angled) and base, (slightly angled)) and compared. For left ventricular strain and strain rate, a significant difference was seen between the groups with images acquired from the side having significantly higher values compared to images acquired from the base (slightly angled). For the right ventricle, strain values obtained from the apex were significantly greater than those obtained from the base (slightly angled), but no significant difference was seen in velocity or strain rate between the groups.

In figures 2 and 3, strain values obtained from measurements of the right and left ventricles of the study group are plotted as circles and measurements from the control group as stars. No differences were seen in fetal cardiac strain between the two groups. The mean values of strain, strain rate and velocity in the study group and control group were also compared, and after adjusting for gestational age, frame rate and birthweight deviance from mean, no difference was observed between the groups.

There was no correlation between right or left ventricular strain and pulsatilility index of the DV. Umbilical vein pulsations were seen in 10 cases and there was no correlation between occurrence of UV-pulsations and right or left ventricular strain. Adjusting for frame rate and heart rate did not change the correlation between cardiac strain and venous pulsatility.

Discussion

Previous studies have suggested that increased pulsatility of blood flow in the ductus venosus is a reflection of cardiac dysfunction and increased central venous pressure[14, 15]. The present results suggest that the ductus venosus might open in moderate chronic hypoxia without there being signs of increased cardiac strain. Opening of the ductus venosus increases the flow of oxygenated blood mainly to the left side of the heart to supply, preferentially, the coronaries and the brain. The increase in flow of oxygenated blood to the heart might be a physiological "sparing" reaction, resulting in maintenance of cardiac function during moderate fetal hypoxia[18, 19].

Traditional methods for estimation of fetal cardiac function during hypoxia include cardiac morphometry and M-mode or Doppler measurements of blood flow. These methods give indirect measures of cardiac function and have significant limitations with confusing results regarding correlation of pathological findings to fetal circulatory compromise[1-4, 20]. Newer methods are currently being explored, including those estimating strain and strain rate.

Recent studies have employed speckle-tracking techniques for investigations of fetal ventricles and normal values have been described for global and regional values. Published estimates of left ventricle average peak global strain values range from -15 to -25, and for the right fetal ventricle from -16.5 and -24. These studies have employed a variation of study protocols and different software for speckle-tracking analysis, with results similar to ours[21-25].

We used global measurements of strain and strain rate in analysis. This was chosen for two reasons; Inadequate spatial resolution is a potential limitation of the method and measurements of strain are not recommended if the distance between adjacent segments is less than 2-5 mm apart[26]. Segmental dysfunction is also less likely in the fetus, than might be in adults with coronary heart disease.

Our hypothesis was that alterations in cardiac deformation might be detected in fetuses with impaired placental function using the speckle tracking analysis software VVI. Comparison of left and right ventricular strain was made between a cohort of healthy fetuses at different gestational ages and fetuses with signs of increased placental vascular resistance. As shown in figures 2 and 3, strain values of the right and left ventricles do not seem to differ between the groups. This indicates that cardiac strain might be spared long in the process of fetal demise. Problems in interpreting these findings include the potential pitfalls of VVI, a method not validated in the fetus, and originally designed for use in adult cardiology. The optimal frame rate for 2D speckle tracking in the fetus is unknown, but in adults frame rates of 60-110 are recommended to avoid underestimation of time-dependent variables such as velocities and strain rate. Due to the high fetal heart rate, an even higher frame rate might be desirable[27-29], something that, even using high quality ultrasound systems and optimization of images for this purpose, can be difficult to obtain. Due to the effect of ultrasound frame rate on strain rate, the recorded values were corrected for the average frame rate at 80. This correction did not change the results in the comparison of controls and high-risk pregnancies.

Conclusions: The aim of this study was to correlate changes in fetal venous pulsatility and cardiac function. Surprisingly, there was no correlation between heart function and venous pulsatility in fetuses during moderate chronic hypoxia. Still many of the high-risk pregnancies had increased pulsatility in both the ductus venosus and the umbilical vein. This might

suggest that the ductus venosus opens during chronic fetal hypoxia, redistributing blood to the left side of the heart and thus directing more oxygenated blood for the coronaries and brain. This redistribution might explain maintained cardiac function during moderate fetal hypoxia.

Acknowledgements:

The authors are grateful to the sonographers: Pia Soikkeli, Maria Nilsson, Ann Thuring-Jönsson, Zahraa Alsafi and to the midwifes of the ultrasound department of Skane University Hospital in Malmö for great help recruiting patients and to Mats Pihlsgård for expert statistical advise.

Declaration of interest: There are no conflicts of interests involved by any of the authors.

References:

1. Hecher K, Campbell S, Doyle P, Harrington K and Nicolaides K. Assessment of Fetal Compromise by Doppler Ultrasound Investigation of the Fetal Circulation. Circulation. 1995;91:129-138.
2. Turana S, Turana OM, Salimb M, Bergc C, Gembruchc U, Harmana CR and Baschat AA. Cardiovascular Transition to Extrauterine Life in Growth-Restricted Neonates: Relationship with Prenatal Doppler Findings. Fetal Diagn Ther. 2013;33:103-109.
3. Aburawi EH, Malcus P, Thuring A, Fellman V and Pesonen E. Coronary flow in neonates with impaired intrauterine growth. J Am Soc Echocardiogr. 2012;25:313-8.
4. Kiserud T, Ebbing C, Kessler J and Rasmussen S. Fetal cardiac output, distribution to the placenta and impact of placental compromise. Ultrasound Obstet Gynecol. 2006;28:126-36.
5. Comas M, Crispi F, Cruz-Martinez R, Martinez J, Figueras F and Gratacós E. Usefulness of myocardial tissue Doppler vs conventional echocardiography in the evaluation of cardiac dysfunction in early-onset intrauterine growth restriction. American Journal of Obstetrics & Gynecology. 2010;203:45.e1-7.

6. Girsen A, Alakopsala M, Makikallio K, Vuolteenaho O and Rasanen J. Cardiovascular hemodynamics and umbilical artery N-terminal peptide of proB-type natriuretic peptide in human fetuses with growth restriction. Ultrasound in Obstetrics and Gynecology. 2007;29:296-303.
7. Crispi F, Hernandez Andrade E, Pelsers M, Plasencia W, Benavides-Serralde J, Eixarch ELN, F., Ahmed A, Glatz J, Nicolaides K and Gratacos E. Cardiac dysfunction and cell damage across clinical stages of severity in growth-restricted fetuses. Am J Obstet Gynecol. 2008;199:254.e8.
8. Crispi F and Gratacós E. Fetal cardiac function: technical considerations and potential research and clinical applications. Fetal Diagn Ther. 2012;32:47-64.
9. Becker M, Bilke E, Kuhl H, Katoh MK, R. Franke, A., Bucker AH, P. and Hoffmann R. Analysis of myocardial deformation based on pixel tracking in two dimensional echocardiographic images enables quantitative assessment of regional left ventricular function. Heart. 2006;92:1102-1108.
10. Cruz-Lemini M, Crispi F, Valenzuela-Alcaraz B, Figueras F, Sitges M, Gomez O, Bijnens B and Gratacos E. Value of annular M-mode displacement vs tissue Doppler velocities to assess cardiac function in intrauterine growth restriction. Ultrasound in Obstetrics and Gynecology. 2013;42:175-181.
11. Godfrey ME, Messing B, Cohen SM, Valsky DV and Yagel S. Functional assessment of the fetal heart: a review. Ultrasound Obstet Gynecol. 2012;39:131-44.
12. Tulzer G, Gudmundsson S, Wood DC, Cohen AW, Weiner S and Huhta JC. Doppler in non-immune hydrops fetalis. Ultrasound Obstet Gynecol. 1994;4:279-83.
13. Kessler J, Rasmussen S, Hanson M and Kiserud T. Longitudinal reference ranges for ductus venosus flow velocities and waveform indices. Ultrasound Obstet Gynecol. 2006;28:890-8.
14. Baschat AA. Examination of the fetal cardiovascular system. Semin Fetal Neonatal Med. 2011;16:2-12.
15. Baschat AA and Harman CR. Venous Doppler in the assessment of fetal cardiovascular status. Curr Opin Obstet Gynecol. 2006;18:156-63.
16. Baschat AA, Cosmi E, Bilardo CM, Wolf H, Berg C, Rigano S, Germer U, Moyano D, Turan SH, J. Bhide, A., Muller T, Bower SN, K.H. Thilaganathan, B., Gembruch U and Ferrazzi EH, K. Galan, H. Harman, C.R. Predictors of neonatal outcome in early-onset placental dysfunction. Obstet Gynecol 2007;109:253–261.

17. Baschat AA and Harman CR. Venous Doppler in the assessment of fetal cardiovascular status. Curr Opin Obstet Gynecol. 2006;18:156-163.
18. Bellotti M, Pennati G, De Gasperi C, Bozzo M, Battaglia FC and Ferrazzi E. Simultaneous measurements of umbilical venous, fetal hepatic, and ductus venosus blood flow in growth-restricted human fetuses. Am J Obstet Gynecol. 2004;190:1347-58.
19. Kiserud T, Kessler J, Ebbing C and Rasmussen S. Ductus venosus shunting in growth-restricted fetuses and the effect of umbilical circulatory compromise. Ultrasound Obstet Gynecol. 2006;28:143-9.
20. Hassan WA, Brockelsby J, Alberry M, Fanelli T, Wladimiroff J and Lees CC. Cardiac function in early onset small for gestational age and growth restricted fetuses. European journal of obstetrics, gynecology, and reproductive biology. 2013;171:262-5.
21. Barker P HH, Li J, Miller S, Herlong J, Camitta M. Global Longitudinal Cardiac Strain and Strain Rate for Assessment of Fetal Cardiac Function: Novel Experience with Velocity Vector Imaging. Echocardiography 2009;26:28-36.
22. Di Salvo G, Russo M, Paladini D, Felicetti MC, B., Tartaglione A, di Pietto L, Ricci C, Morelli C, Pacileo G and Calabro R. Two-dimensional strain to assess regional left and right ventricular longitudinal function in 100 normal foetuses. Eur J Echocardiogr. 2008;9:754-756.
23. Ishii T, McElhinney D, Harrild D, Marcus E, Sahn D, Truong U and Tworetzky W. Circumferential and Longitudinal Ventricular Strain in the Normal Human Fetus. Journal of the American Society of Echocardiography. 2012;25:105-111.
24. Kapusta L, Mainzer G, Weiner Z, Deutsch L, Khoury A, Haddad S and Lorber A. Second trimester ultrasound: reference values for two-dimensional speckle tracking-derived longitudinal strain, strain rate and time to peak deformation of the fetal heart. J Am Soc Echocardiogr 2012;25:1333-1341.
25. Younoszai A, Saudek D, Emery S and Thomas JD. Evaluation of Myocardial Mechanics in the Fetus by Velocity Vector Imaging. Journal of the American Society of Echocardiography. 2008;21:470-474.
26. D'hooge J, Heimdal A, Jamal F, Kukulski T, Bijnens B, Rademakers F, Hatle L, Suetens P and Sutherland G. Regional Strain and Strain Rate Measurements by Cardiac Ultrasound: Principles, Implementation and Limitations. Eur J Echocardiogr. 2000;1:154-170.

27. Nesbitt GC, Mankad S and Oh JK. Strain imaging in echocardiography: methods and clinical applications. Int J Cardiovasc Imaging. 2009;25:9-22.
28. D'Hooge J, Bijnens B, Jamal F, Pislaru C, Pislaru S, Thoen J, Suetens P, Van de Werf F, Angermann C, Rademakers FE, Herregods MC and Sutherland GR. High frame rate myocardial integrated backscatter: does this change our understanding of this acoustic parameter? Eur J Echocardiogr. 2000;1:32-41.
29. Mondillo S, Galderisi M, Mele D, Cameli M, Lomoriello VS, Zaca V, Ballo P, D'Andrea A, Muraru D, Losi M, Agricola E, D'Errico A, Buralli S, Sciomer S, Nistri S and Badano L. Speckle-tracking echocardiography: a new technique for assessing myocardial function. J Ultrasound Med. 2011;30:71-83.
30. Pu DR, Zhou QC, Zhang M, Peng QH, Zeng S and Xu GQ. Assessment of regional right ventricular longitudinal functions in fetus using velocity vector imaging technology. Prenat Diagn. 2010;30:1057-1063.

Tables:

Table 1: Outcome characteristics of fetuses in the reference and study groups. GA = gestational age, BW = birthweight, NICU = neonatal intensive care unit, DV PIV = ductus venosus pulsatility index for veins, UV = umbilical vein. N: number of patients. Missing values are due to patients moving or being delivered in other hospitals.

	Control group			Study group		
	N	Mean	SD	N	Mean	SD
GA at delivery (weeks)	234	40+0	1.6	36	31+2	4.4
Birth weight (BW) (g)	234	3607.2	574.6	36	1505	768.6
BW deviance from the mean (%)	234	2.16	11.7	36	-31.7%	17.1
Ceasarean section rate (%)	31/247 (12.6%)			31/38 (81.6%)		
Admittance NICU	15/235 (6 .1%)			27/38 (71.1%)		
Perinatal mortality	0			5/38 (13.2%)		
DV PIV z-score	143	-0.04	0.13	38	2.3	4.64
DV PIV > 2SD	0			7		
UV pulsations	0			10/38 (26.3%)		

Table 2: Global peak velocity, strain and strain rate of the left and right ventricles in 248 fetuses of women with normal pregnancies.

	Left ventricle			Right ventricle		
	strain (%)	strain rate (1/s)	velocity (cm/s)	strain (%)	strain rate (1/s)	velocity (cm/s)
Median	-15.41	-2.08	1.60	-14.37	-1.94	1.58
Minimum	-6.62	-0.75	0.38	-6.62	-0.96	0.84
Maximum	-25.84	-4.12	3.98	-27.02	-5.8	3.55
Mean	-15.14	-2.12	1.66	-14.63	-2.01	1.66
SD	4.00	0.59	0.52	4.07	0.58	0.50

Table 3: Regression formulas for the mean curves of peak global velocity (V), strain (S) and strain rate (SR) from the right (RV) and left ventricles (LV). X corresponds to gestational age.

Variable	Regression formula	SD
LV velocity	$y = -2.95 + 6.22*10^{-2}x - 2.96*10^{-4}x^2 + 4.94*10^{-7}x^3$	0,52
LV strain	$y = 33.12 - 0.77x + 3.84*10^{-3}x^2 - 6.11*10^{-6}x^3$	4,00
LV strain rate	$y = 1.02 - 6.0*10^{-2}x + 3.39*10^{-4}x^2 - 5.83*10^{-7}x^3$	0,59

RV velocity	$y = -5.27 + 0.10x – 4.83*10^{-4}x^2 + 7.86*10^{-7}x^3$	0,50
RV strain	$y = 10.41 - 0.53x + 3.15*10^{-3}x^2 – 5.65*10^{-6}x^3$	4,07
RV strain rate	$y = 1.88 – 8.19*10^{-2}x + 4.88*10^{-4}x^2 – 8.71*10^{-7}x^3$	0,58

Legends for figures:

Figure 1: 4-chamber view of the fetal heart. Typical velocity vector tracing of the left ventricle wall.

Figure 2: Strain of the right ventricle of the control group (stares) and results from fetuses with increased umbilical artery vascular impedance (circles) plotted against gestational age in weeks. Curves corresponding to the mean ±2 SD of the control group are shown.

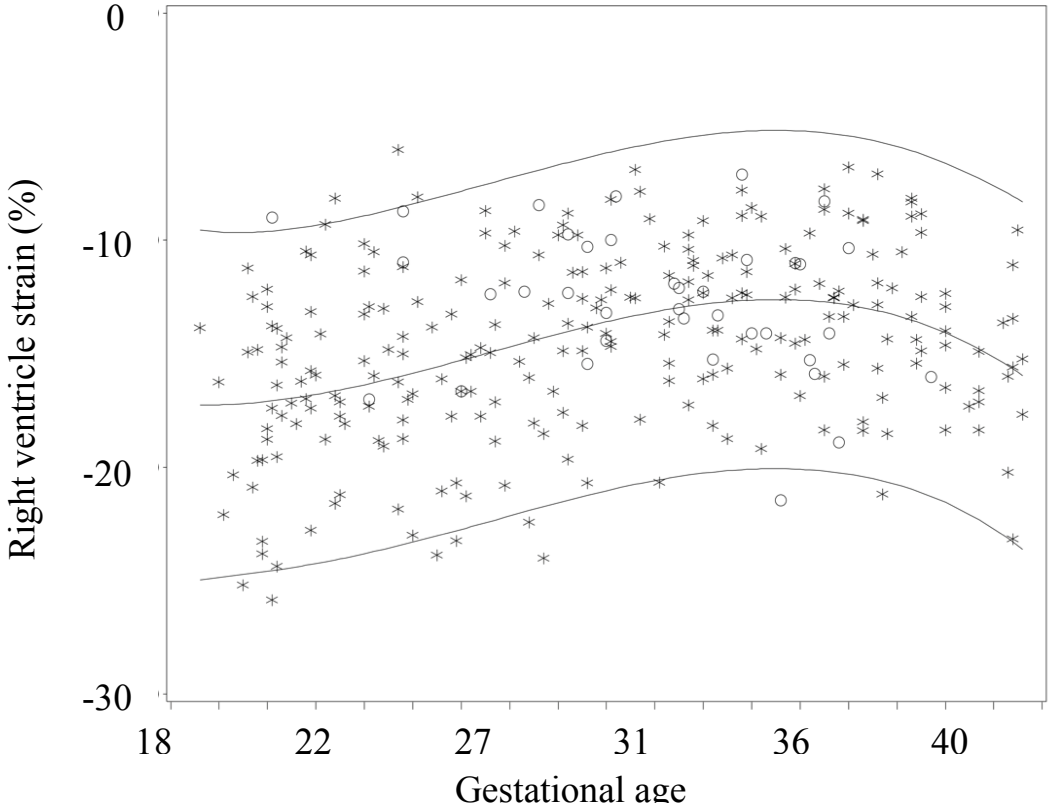
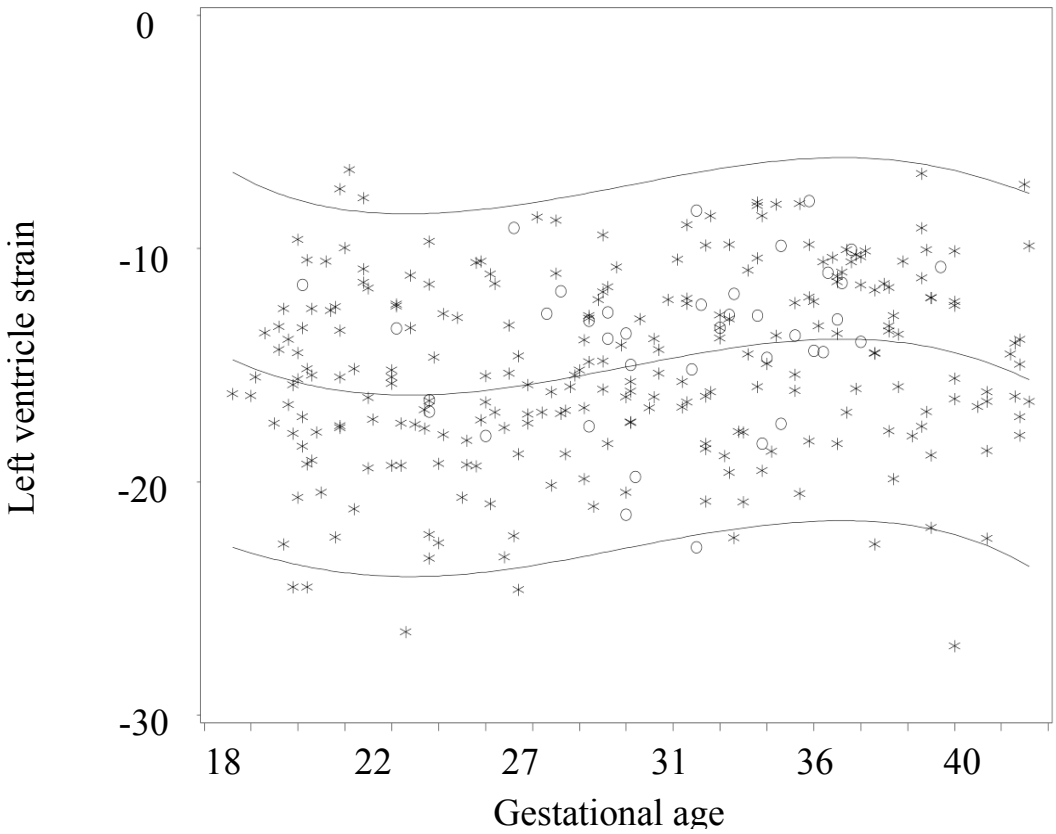
Figure 3: Global peak longitudinal strain of the left ventricle of the control group (stares) with results from fetuses with increased umbilical artery vascular impedance (circles) plotted against gestational age in weeks. Curves corresponding to the mean ±2 SD of the control group are shown.