



LUND UNIVERSITY

Imaging in Lung Transplantation. Evaluation and Imaging of the Lung in Organ Donors.

Bozovic, Gracijela

2016

Document Version:
Publisher's PDF, also known as Version of record

[Link to publication](#)

Citation for published version (APA):
Bozovic, G. (2016). *Imaging in Lung Transplantation. Evaluation and Imaging of the Lung in Organ Donors.* [Doctoral Thesis (compilation), Department of Clinical Sciences, Lund]. Lund University: Faculty of Medicine.

Total number of authors:
1

General rights

Unless other specific re-use rights are stated the following general rights apply:
Copyright and moral rights for the publications made accessible in the public portal are retained by the authors and/or other copyright owners and it is a condition of accessing publications that users recognise and abide by the legal requirements associated with these rights.

- Users may download and print one copy of any publication from the public portal for the purpose of private study or research.
- You may not further distribute the material or use it for any profit-making activity or commercial gain
- You may freely distribute the URL identifying the publication in the public portal

Read more about Creative commons licenses: <https://creativecommons.org/licenses/>

Take down policy

If you believe that this document breaches copyright please contact us providing details, and we will remove access to the work immediately and investigate your claim.

LUND UNIVERSITY

PO Box 117
221 00 Lund
+46 46-222 00 00

Imaging in Lung Transplantation

Imaging in Lung Transplantation

Evaluation and Imaging of the Lung in Organ Donors

Gracijela Božović



LUND
UNIVERSITY

DOCTORAL DISSERTATION


By due permission of the Faculty of Medicine, Lund University, Sweden.
To be defended at Demonstration Room 10, Department of Medical Imaging and
Physiology, Main Building, Level IV, Skåne University Hospital Lund, Date
2016-12-16 at 13.00.

Faculty opponent

Associate Professor Åse Allansdotter Johnsson
Department of Radiology, University of Gothenburg, Sweden

| | | |
|--|---|-------------------------|
| Organization LUND UNIVERSITY Faculty of Medicine, Department of Clinical Sciences Lund, Diagnostic Radiology Author(s) Gracijela Božović | Document name: Doctoral Dissertation | |
| | Date of issue: December 16 th 2016 | |
| | Sponsoring organization | |
| Title and subtitle :Imaging in Lung Transplantation, Evaluation and Imaging of the Lung in Organ Donors | | |
| Abstract Aim To evaluate if circulation can be normalized pharmacologically for 24 h after total brain dead and if forced fluid infusion can be replaced with it and stabilize the circulation, assessed trough blood gases and HRCT. To retrospectively evaluate diagnostic imaging potential lung donors undergo, reader variability of image interpretation, relevance for donation, information gained from imaging studies not primarily intended for lung evaluation and if pre-transplant donor lung imaging findings and blood gas analysis correlate to early and late complications and survival during the first year after lung transplantation. | | |
| Materials & Methods 24 pigs randomized in three groups, two with acute brain death and one control, all supplied with basic fluid therapy and in addition one brain dead group had pharmacological treatment. 28 pigs randomized in three groups, treated as above with additional forced fluid therapy in one brain dead group. The lung function and morphology was evaluated with blood gases and HRCT. All imaging in 110 potential organ donors from 2007-2014 were reviewed by two radiologist and compared to clinical reports. Substantial difference were potential treatment change, bronchoscopy or importance for donation. The mandatory bedside chest X-ray and blood gases from 35 lung donors were correlated with complications, 30-days & 1-year survival and FEV ₁ % at the 1-year follow-up. | | |
| Results After 12 h arterial pressure was < 40 mmHg in the brain dead group whereas the pressure and clinical parameters did not differ significantly between the group with pharmacological treatment and controls. After 4-6 h the group with forced fluid therapy was circulatory unstable and 5/6 showed pronounced pulmonary edema on HRCT (median final PaO ₂ FiO ₂ = 29 kPa). The two other groups were stable for 24 h (median final PaO ₂ FiO ₂ 72 and 66 kPa). Subtle edema appeared in 2/11 pharmacologically treated. 50% had unexpected lung disease on HRCT. 136 bedside chest radiographs showed no difference in 37(27%), minor in 28(21%) and substantial in 71(52%) (p<0.0001). In 31 of 42 (74%) CT-s complete or not, 50 of 74 not primarily reported findings were relevant for donation (p<0.0001). Findings in the mandatory bedside chest radiography in clinical reports and study review differed substantially. Aspiration at study review was correlated with reduced FEV ₁ %. No other correlation could be shown between | | |
| Conclusion Pharmacological substitution can normalize circulation in brain dead pigs for 24 h whereas untreated animals develop circulation collapse within 12 h and it prevents circulatory collapse. HRCT verified edema and substantial occult disease. The majority of donors undergo only chest radiography. A donation targeted review of all imaging depicting the lungs adds important information for lung donation. CT, even if incompletely covering the lung adds valuable information. The mandatory chest radiograph has no influence on 1-year outcome in lung transplantation. Presence of aspiration at study review was correlated with reduced FEV ₁ % which might indicate the importance of better imaging methods and dedicated image interpretation from a transplantation point of view. Larger imaging studies or a change in clinical routine including CT methods may provide evidence for future guidelines. | | |
| Key words: Lung transplantation; Donors, HRCT, Chest Radiography; Computed Tomography, | | |
| Classification system and/or index terms (if any) | | |
| Supplementary bibliographical information | | Language: English |
| ISSN and key title: 1652-8220, Imaging in Lung Transplantation | | ISBN: 978-91-7619-380-8 |
| Recipient's notes | Number of pages: 109 | Price |
| | Security classification | |

I, the undersigned, being the copyright owner of the abstract of the above-mentioned dissertation, hereby grant to all reference sources permission to publish and disseminate the abstract of the above-mentioned dissertation.

Signature 

Date: November 10th, 2016

Imaging in Lung Transplantation

Evaluation and Imaging of the Lung in Organ Donors

Gracijela Božović



LUND
UNIVERSITY

Cover photo by Permission of The Royal Collection Trust / © Her Majesty Queen Elizabeth II 2016. The first structured anatomic study of the lung, probably porcine. Leonardo da Vinci, circa 1508.

Copyright Gracijela Božović. All images, tables and figures are from the author's collection if not stated otherwise.

Faculty of Medicine
Department of Clinical Sciences, Lund
Diagnostic Radiology

Lund University, Faculty of Medicine Doctoral Dissertation Series 2016:152
ISBN 978-91-7619-380-8
ISSN 1652-8220

Printed in Sweden by Media-Tryck, Lund University, Lund 2016



*“Le seul véritable voyage, le seul bain de Jouvence,
ce ne serait pas d’aller vers de nouveaux
paysage mais d’avoir d’autres yeux,
de voir l’univers avec les yeux d’un autre.”*

À la recherche du temps perdu

Marcel Proust

Content

| | |
|---|----|
| List of Publications | 10 |
| Publications included in the Thesis | 10 |
| Related publications and preliminary reports | 10 |
| Other publications | 11 |
| Thesis at a Glance | 12 |
| Abbreviations | 14 |
| Populärvetenskaplig Sammanfattning | 15 |
| General aspects in historical retrospect | 17 |
| How organ transplantation began | 17 |
| Revealing the inside – the emergence of imaging | 22 |
| Animals in the service of science | 38 |
| Introduction | 44 |
| Papers I and II | 47 |
| Papers III and IV | 48 |
| Aims | 49 |
| Paper I | 49 |
| Paper II | 49 |
| Paper III | 49 |
| Paper IV | 49 |
| Materials and Methods: | 50 |
| Paper I | 50 |
| Paper II | 51 |
| Paper III | 55 |
| Paper IV | 59 |

| | |
|------------------------|----|
| Statistical evaluation | 60 |
| Paper I | 60 |
| Paper II | 60 |
| Paper III | 60 |
| Paper IV | 60 |
| Results | 61 |
| Paper I | 61 |
| Paper II | 65 |
| Paper III | 74 |
| Paper IV | 80 |
| Discussion | 83 |
| Papers I and II | 83 |
| Papers III and IV | 88 |
| Final Comments | 92 |
| Acknowledgements | 93 |
| References | 98 |

List of Publications

Publications included in the Thesis

- I. Steen S, Sjöberg T, Liao Q, **Bozovic G**, Wohlfart B. Pharmacological normalization of circulation after acute brain death. *Acta Anaesthesiologica Scandinavica* 06/2012; 56(8):1006-12.
- II. **Bozovic G**, Steen S, Sjöberg T, Schaefer-Prokop C, Verschakelen J, Liao Q, Höglund P, Siemund R, Björkman-Burtscher IM. Circulation stabilizing therapy and pulmonary high-resolution computed tomography in a porcine brain-dead model. *Acta Anaesthesiol Scand.* 2016 Jan; 60(1):93-102.
- III. **Bozovic G**, Adlercreutz C, Höglund P, Björkman-Burtscher I, Reinstrup P, Ingemansson R, Schaefer-Prokop C, Siemund R, Geijer M. Imaging of the lungs in organ donors and its clinical relevance – a retrospective analysis. Accepted in *Journal of Thoracic Imaging*, October 2016.
- IV. **Bozovic G**, Adlercreutz C, Björkman-Burtscher I, Reinstrup P, Ingemansson R, Skensebo E, Geijer M. Impact of Donor Lung Imaging on CT outcome after Lung Transplantation. Manuscript, planned for submission in November 2016.

Related publications and preliminary reports

Kockelkorn TT, Schaefer-Prokop CM, **Bozovic G**, Munoz-Barrutia A, van Rikxoort EM, Brown MS, de Jong PA, Viergever MA, van Ginneken B. Interactive lung segmentation in abnormal human and animal chest CT scans. *Med Phys* 2014; 41.

Bozovic G, Adlercreutz C, Höglund P, Björkman-Burtscher I, Reinstrup P, Ingemansson R, Schaefer-Prokop C, Siemund R, Geijer M: Radiological interpretation quality in lung imaging of organ donors and its clinical relevance – a retrospective analysis. Presentation and e-poster. European Congress of Radiology, Vienna, Austria 2016.

Bozovic G, Steen S, Sjöberg T, Schaefer-Prokop C, Verschakelen J, Liao Q, Siemund R, Björkman-Burtscher I: High resolution computed tomography of the lungs in brain dead heart beating donors treated conventionally and with a new drug

regime in a pig model. Presentation. World Congress of the European Society of Thoracic Imaging, Seoul, Korea 2013.

Bozovic G, Steen S, Sjöberg T, Schaefer-Prokop C, Verschakelen J, Liao Q, Siemund R, Björkman-Burtscher I: Pulmonary changes in lung donors treated with a new hemodynamic stabilizing drug regime assessed with High Resolution Computed Tomography (HRCT) in an experimental pig model. Presentation. Congress of the European Society of Thoracic Imaging, London, UK 2012

Other publications

Walsh SL, Calandriello L, Sverzellati N, Wells AU, Hansell DM; UIP Observer Consort. **Collaborators (113) Bozovic G**. Interobserver agreement for the ATS/ERS/JRS/ALAT criteria for a UIP pattern on CT. Thorax. 2015 Nov 19.

Aronsson D, Hesselstrand R, **Bozovic G**, Wuttge D and Tufvesson E. Airway resistance and reactance are affected in systemic sclerosis. European Clinical Respiratory Journal, Vol 2 (2015)

Hesselstrand R, Wildt M, **Bozovic G**, Andersson-Sjöland A, Andréasson K, Scheja A, Westergren-Thorsson G, Bjermer L, Wuttge DM. Biomarkers from bronchoalveolar lavage fluid in systemic sclerosis patients with interstitial lung disease relate to severity of lung fibrosis. Respir Med. 2013 Jul; 107(7):1079-86.

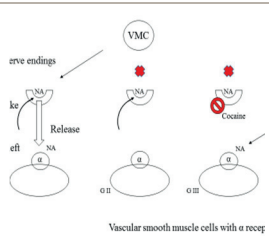
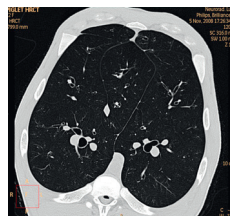
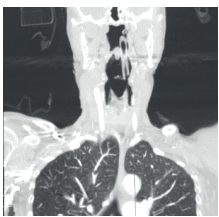
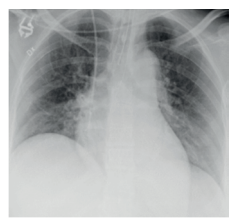
Kanski M¹, Arheden H, Wuttge DM, **Bozovic G**, Hesselstrand R, Ugander M: "Pulmonary blood volume indexed to lung volume is reduced in newly diagnosed systemic sclerosis compared to normals--a prospective clinical cardiovascular magnetic resonance study addressing pulmonary vascular changes." J Cardiovasc Magn Reson. 2013 Sep 25; 15:86.

Vult von Steyern K, Björkman-Burtscher I, Höglund P, **Bozovic G**, Wiklund M, Geijer M. Description and validation of a scoring system for tomosynthesis in pulmonary cystic fibrosis. European Radiology (impact factor: 3.22). 06/2012

Hesselstrand R, Andréasson K, Wuttge D, **Bozovic G**, Scheja A, Saxne T. Increased serum COMP predicts mortality in SSc: results from a longitudinal study of interstitial lung disease. Rheumatology (Oxford, England) (impact factor: 4.24). 01/2012; 51(5):915-20.

Kanski M, Arheden H, Wuttge D, **Bozovic G**, Hesselstrand R, Ugander M. Pulmonary blood density quantified by CMR is reduced in newly diagnosed systemic sclerosis, consistent with pulmonary arteriolar proliferation. Journal of Cardiovascular Magnetic Resonance 01/2011.

Thesis at a Glance

| Imaging in Lung Transplantation | | |
|--|--|--|
| Project | | Aim |
| Donors | | |
|  <p>Vascular smooth muscle cells with α recep</p> | <p>“Pharmacological normalization of circulation after acute brain death”</p> | <p>If circulation can be normalized pharmacologically in pigs for 24 h after total removal of the brain and brainstem.</p> |
|  | <p>“Circulation stabilizing therapy and pulmonary high-resolution computed tomography in a porcine brain-dead model”</p> | <p>If forced fluid infusion can be replaced pharmacologically and stabilize the circulation after brain death by assessing the effects with blood gas parameters and HRCT.</p> |
| Recipients | | |
|  | <p>“Imaging of the lungs in organ donors and its clinical relevance – a retrospective analysis”</p> | <p>To retrospectively evaluate diagnostic imaging performed in potential lung donors undergo, reader variability of image interpretation and its relevance for donation, and potential information gained from imaging studies not primarily intended for lung evaluation but partially including them.</p> |
|  | <p>“Impact of imaging in lung donors on the clinical outcome after lung transplantation”</p> | <p>To evaluate the relevance of donor image interpretation for lung transplantation outcome by following up donated lungs and analyse early and late complications and survival during the first year after lung transplantation, and correlate pre-transplant donor lung imaging findings and blood gas analysis with lung transplantation outcome.</p> |

Imaging in Lung Transplantation

| Material & Method | Results | Conclusion |
|---|--|--|
| Donors | | |
| <p>24 pigs randomized in three equal groups: GI intact and GII and GIII decapitated. All had basic fluid supply and in addition GIII had pharmacological treatment.</p> | <p>After 12 h AP was < 40 mmHg in the decapitated group. With pharmacological treatment the pressure and clinical parameters did not differ significantly from the non-decapitated controls.</p> | <p>Pharmacological substitution can normalize circulation in decapitated pigs for 24 h whereas untreated animals develop severe circulation collapse within 12 h.</p> |
| <p>28 pigs randomized in GI/n=6 and GII/n=11 decapitated and GIII intact control animals. All had basic fluid supply. In addition GI had forced fluid therapy and GII new pharmacologic treatment. Lung function and morphology was evaluated with blood gases and HRCT.</p> | <p>After 4-6 h GI was circulatory unstable and 5/6 showed pronounced pulmonary edema on HRCT (median final PaO₂FiO₂ = 29 kPa). GII and GIII were stable for 24 h (median final PaO₂FiO₂ 72 and 66 kPa respectively). Subtle edema appeared in 2/11 in GII. 50% had unexpected lung disease on HRCT.</p> | <p>Pharmacological therapy prevents circulatory collapse. HRCT verified edema and substantial occult disease</p> |
| Recipients | | |
| <p>Bedside chest X-ray and lung CT complete or not in 110 potential organ donors during 2007-2014 were reviewed by two radiologist in consensus and compared to clinical reports. Substantial difference was defined as treatment change, bronchoscopy or of importance for the donation.</p> | <p>In 136 bedside chest X-rays there were no difference in findings in 37(27%), minor in 28(21%) and substantial difference in 71(52%) (p<0.0001). In 31 of 42 (74%) complete or incomplete CT of the lungs, 50 of 74 findings were relevant for lung donation and had not been primarily reported (p<0.0001).</p> | <p>The majority of donor patients undergo only chest radiography. A targeted imaging review of abnormalities affecting the decision to use donor lungs may be useful in the pre-operative stage. With a targeted list, substantial changes were made from initial clinical interpretations. CT can provide valuable information about donor lung pathology, even if the lungs are only partially imaged.</p> |
| <p>Findings in clinical report and study review of mandatory bedside chest radiographs and blood gases from 35 lung donors in one institution during 2007-2014 were correlated with complications, 30-days & 1-year survival & FEV₁% at the 1-year follow-up.</p> | <p>In 38 recipients (31 DL transplantation and 7 SL) bedside chest radiography findings in clinical reports and study review differed substantially for e.g. reported edema, decompensation, atelectasis or infection. Presence of aspiration at study review was correlated with reduced FEV₁%. No other correlation could be shown.</p> | <p>Mandatory blood gas analysis in this range and chest radiograph have no influence on 1-year outcome in lung transplantation. Presence of aspiration at study review was correlated with reduced FEV₁% which might indicate the importance of better imaging methods and dedicated image interpretation from a transplantation point of view. Larger studies or a change in clinical routine including CT methods may provide evidence for future guidelines.</p> |

Abbreviations

ABE – Actual Base Excess

ALAT - Alanine Amino Transaminase

CT - Computed Tomography

CAR - Chronic Allograft Rejection

CMV - Cytomegalovirus

COPD - Chronic Obstructive Pulmonary Disease

ECG - Electrocardiography

FEV₁% – Forced Expiratory Volume in 1 s Percentage of Predicted Normal Value

GGO - Ground-Glass Opacities

Hb - Hemoglobin

HRCT - High Resolution Computed Tomography

ICU - Intensive Care Unit

IPF - Idiopathic Pulmonary Fibrosis

MRI – Magnetic Resonance Imaging

PaO₂ - Arterial Oxygen Tension

PaO₂/FiO₂ - Arterial Oxygen Tension/Fraction of Inspired Oxygen Ratio

PACS - Picture Archiving and Communication System

PEEP - Positive End-Expiratory Pressure

PET - Positron Emission Tomography

PGD - Primary Graft Dysfunction

RIS - Radiology Information System

Three Rs - Replacement, Reduction and Refinement

T3 - Triiodothyronine

T4 - Thyroxine

VMC - Vasomotor Center

Populärvetenskaplig Sammanfattning

Lungtransplantation är en behandlingsmetod för lungsjuka patienter som är så svårt sjuka att de väntas dö inom två år. I Sverige sker lungtransplantation i Lund och Göteborg med sammanlagt drygt 60 operationer om året. I världen utförs drygt 4000 lungtransplantationer per år.

Lungan som ska transplanteras kommer från en organdonator, ofta någon med stor hjärnblödning eller skallskada där cirkulationen i hjärnan upphört och donatorn därmed är hjärndöd. Andning och cirkulation hos donatorn kan enligt lag upprätthållas upp till 24 h för att organen ska omhändertas. För att lungan ska kunna transplanteras och passa mottagaren behöver den vara i gott skick vilket bedöms enligt strikta regler under dessa 24 h: donators längd och vikt, tidigare infektioner, blodgrupp, syremättnaden i blodet och en röntgenbild av lungorna i liggande. Generellt är det få lungor som uppfyller kraven och av de tillgängliga lungorna utnyttjas bara en dryg femtedel. Med så få utnyttjade organ råder stor brist samtidigt som patienter dör i väntan på lämpligt organ. Orsakerna till detta är flera. Inte sällan stöts maginnehåll upp i samband med insjuknandet och hamnar i lungorna, s.k. aspiration, som kan orsaka infektion. Dessutom är vården av patienter där hjärncirkulationen upphört komplicerad och kräver ofta att patienten tillförs stora volymer vätska för att blodcirkulationen i kroppen ska vara god nog för att bevara organen. I lungorna kan detta orsaka ansamling av vätska med försämrad funktion. Med en relativt ny behandling kan man driva ut vätskan ur lungorna och förbättra funktionen till en viss del. Det bästa vore dock att undvika vätskeutträde i lungan redan från början. För att öka antal tillgängliga organ har man också på senare år utvidgat donationskriterierna och man får numera transplantera lungor från tidigare rökare och från donatorer upp till 70 års ålder vilket gör att risken för sjukdomar så som lungcancer ökar. Därför har det på senare år tillkommit nya frågor inför transplantation som behöver besvaras, nämligen om man kan undvika vätskeutträde i lungorna och om det finns förekomst av vätska, infektion eller cancer inför ställningstagande till lämplighet för transplantation.

I detta arbete har vi provat ut en ny behandlingsmetod avseende vätskeutträde i lungorna som utvärderats både med kliniska parametrar och bilddiagnostik. Vi har också tittat på den bilddiagnostik vi enligt gängse rutiner använder idag vid bedömning av lungan för att se om den kan besvara dessa nya frågor. Behandlingen som vi gett i form av dropp till försöksdjur innehåller allt patienten behöver inklusive en substans som gör att vätskan från droppet stannar i kärlbanan utan att

samlas i lungan. På så vis behöver man inte tillföra stora volymer vätska. När vi tittat på syremättnaden i blodet vid denna behandling har den varit mycket god och bilderna som vi tagit med högupplösande skiktröntgen, den bästa metoden för framställning av lungor, har vi oftast inte sett någon ansamling av vätska. Alla donatorer genomgår enligt regelverket en vanlig röntgenundersökning av lungorna i liggande. Då det ofta är bråttom undersöks de akut och bedöms av en allmänradiolog som ofta saknar detaljerad kunskap om donation. Vi vet att den snabba utvecklingen av bilddiagnostik de senaste åren också gjort att tillgängligheten av skiktröntgen ökat och att antalet undersökningar ökat. Vi har därför samlat in alla lungröntgenbilder från samtliga potentiella donatorer under en åttaårsperiod och alla skiktröntgenbilder som visar hela eller delar av lungorna. Vi har först analyserat den primära bildtolkningen, därefter har vi själva analyserat bildmaterialet och försökt besvara de frågor som transplantationsdoktorn behöver veta för att på bästa sätt bedöma lungornas lämplighet för donation. Det visar sig att om man gör en analys anpassad för donation kan man besvara fler frågor av intresse än vad som besvaras i den primära bildtolkningen. Vi har också sett att i de fall donatorn under sjukdomsförloppet genomgått en skiktröntgen kan betydligt flera frågor besvaras. Vid uppföljning av den obligatoriska lungröntgenbilden hos de som verkligen donerat lungorna och jämförelse med komplikationer och överlevnad hos mottagaren kunde man se att dessa inte påverkas av den primära bildanalysen. Vid den förnyade, för donation anpassade analysen, kunde vi konstatera att förekomst av aspiration har ett samband med sämre lungfunktion hos mottagaren.

Sammanfattningsvis har vi kommit fram till att den nya behandlingen av donatorer fungerar och borde provas ut i klinisk verksamhet, att bedömning av lungbilder inför ställningstagande om lämplighet för donation bättre görs med en för donation anpassad bildanalys. Komplikationer och överlevnad hos mottagaren påverkas inte av den primära bildanalysen medan förekomst av aspiration vid den förnyade, för donation anpassad bildanalysen har ett samband med sämre lungfunktion. Således finns förutsättningar att med en för donation anpassad bildanalys och bättre bilddiagnostik med skiktröntgen finna möjligheter till förbättrad lungfunktion och överlevnad efter lungtransplantation.

General aspects in historical retrospect

How organ transplantation began

The modern solid organ transplantation came to life during the last century. The first human-to-human transplantation was a kidney transplantation performed in 1933 in the Soviet Union by the Ukrainian surgeon Yurii Y. Voronoy (1895-1961). He was well acquainted with the terms of transplantation of that time and proceeded with an attempt of immunological approach. He presented the event in great detail in his medical report, genuinely remarkable for his time (1). Efforts in kidney transplantation were carried on in the 1950's, developing techniques and overcoming immunological difficulties. The most successful examples are transplantations between twins in Boston, the first to result in long-term survival. By the early 1960's the technique was mastered, and the donation and immunosuppression had improved. Kidney transplantation settled into clinical practice, followed by other solid organs: lung and pancreas in 1963, heart in 1967 and liver in 1968 (2).

Early intentions of transplantation caused a lot of debate among both scientists and the public, and were at times quite controversial, foremost in terms of donation and what was ethically acceptable. In the light of successful long-term survival and development of ethical regulations, the general opinion towards transplantation changed to a more open approach, aided by the support from organized religion. Pope Pius XII affirmatively addressed the issue in a conference in Rome in 1956 and the pontiff's statements have ever since been liberal and helpful to organ transplantation as have, with few exceptions, statements from representatives of other religious communities, e.g. Christian, Islam, Hindu, Buddhist and Jewish communities. The few exceptions are faiths where the underlying beliefs contradict the idea of transplantation due to the necessity of an unviolated body, such as the Shinto in Japan, the faith of Roma in Europe or among Native Americans (3). An investigation in Sweden in 2015 showed that about 70% of the population were willing to donate organs. In the European Union in general it is about 55% (4).



Illustration of the research work *Architectural fantasies* 1933, Yakov Chernikov. This futuristic work from the same year as the first human-to-human organ transplantation was the last tribute to the flourishing period of the Russian avant-garde including Malevitch, Kandinskij and Chagall. With Stalin already in power for a decade, continuously bringing down the Russian intelligentsia in the "Great Purge" that followed, the contact with the West was limited and deeply mistrusted. This contributed to the late international recognition of Dr Vorony's truly pioneering work in organ transplantation. He first came to attention in the mid-1950s when the development of kidney transplantation accelerated. He ended his career away from the path he pioneered as the vice president of Blood Transfusion and Haematology Institute in Kiev. Photo credit: Courtesy of Russian State Archive of Literature and Art through the help from RussianArchives.com.

In our minds the appearance of transplantation is linked to modern high-end medicine, but is actually a very old practice with skin transplantation performed in India in a similar way as it is at present, described in the ancient Sanskrit text of medicine and surgery *Suchruta Samitha* from 600 BC (5). According to the legend *Biǎn Què* (扁鵲), the first known Chinese physician performed a heart transplantation in anesthesia in the 5th century BC.

How did it all start? When did the idea of exchanging tissue and organs between living beings emerge? Tracing the answer brings us back to the beginning of humanity and our oldest legends. It is present in mythologies across all continents (2). In Scandinavia we find several examples. In the Norse mythology there is the story about the goddess *Siv*, wife of the mighty god *Thor*. She was known for her exquisite hair. One night while sleeping, the nasty half god, half giant *Loki* cut it off. *Thor* became furious and made him reimburse his deed. *Loki* turned for help to the dwarves, famous for their goldsmith skills. Out of pure gold they created a


beautiful curly hair that miraculously grew onto Siv's head (6). In the oral tradition of the Sami, the indigenous people of the Scandinavian Peninsula, there are many stories about humans interacting with animals and the nature. In one story about a fox, a bear and a Sami, the fox is, after tricking both the bear and the Sami, punished with blindness by fire. However, desperately roaming and trying to regain her sight, she finally fools the poor aspen tree to exchange his eyes for her own and runs away. The aspen tree is ever since covered with reddish spots resembling the burnt eyes of the deceiving fox (7).



The Gods were rarely depicted in the Norse religion of the Vikings. To the left is one of few presentations of Thor with his hammer Mjölner on the Altuna runestone from 11th century; Uppland, Sweden. The Sami people used ceremonial drums (right) decorated with symbols from their cosmology such as reindeers and bears for spiritual and medical purposes. Most of the drums were destroyed during the belligerent christening in the 18th century with only about 70 of them still preserved. Photo credit: Wikimedia Commons (left); Courtesy of Äjtte, The principal Sami Museum, Jokkmokk, Sweden (right).

Through the centuries the idea of transplantation appears in many legends. Christ replacing a servant's ear is only one of several biblical references. In ancient times, when people under hardship and failing of everyday life highly relied on faith and saints, cities and professions had patron saints for support and protection. Although nowadays seldom aware of them, they still remain a part of our tradition. The patron saints of our own profession are St. Cosmas and Damion, twin brothers probably from today's Syria, dedicated to heal the sick without payment and therefore often called the "unmerceneries". They were killed as martyrs in the 4th century during the reign of Emperor Diocletian in the last decades of Roman empire (8). They were later

proclaimed saints for performing several miracles, the most important being the transplantation of a leg from a newly killed Ethiopian gladiator to Deacon Justin. This event is portrayed in art numerous times. Icons representing St. Cosmas and Damian are still often seen in hospitals and health authorities throughout the Orthodox Christian world, as an echo of their Byzantine legacy.



Fra Angelico: The healing of Justin by St. Cosmas and Damian, 1438-40, Museo di San Marco, Florence, Italy. St. Cosmas and Damian's tribute with transplantation of a leg, is here highlighted with different skin colors of the legs of the donor and recipient. They are the patron saints of surgeons, physicians, dentists, children, barbers, pharmacists, veterinarians, and smiths. Photo credit: Wikimedia Commons.

The continuous evolving of the idea of reusing tissue and organs is blazoned in Mary Shelly's *Frankenstein* published in 1818, when a creature is created from several body parts. Already in the 16th century Italy the surgeon Gasparo Tagliacozzi successfully reconstructed noses destroyed by syphilis with skin grafts. By a continuous accumulation of experiences towards the 19th century, principles of skin grafting became well known. A laborious and long effort to solve the enigma of transplantation started, resulting in sustainable procedures in the mid-1950's and 1960's. It was fortified with adequate immunosuppression by the entry of cyclosporine. By itself, the discovery of cyclosporine in 1969 from a fungus (*Tolypocladium inflatum*) isolated in a soil sample from Hardangervidda, Norway, contributed a major part to the prosperity of transplantation and its present thriving (9). Today transplantation is an established practice worldwide, with altogether

good results. The survival rates for the first year are $\geq 80\%$ for transplantation of heart, kidney, liver, pancreas and lung.

The first lung transplantation took place in USA in 1963, led by the American surgeon James Hardy (10). It would require twenty years to overcome the difficulties before putting it into regular practice. It came into practice in 1983 in Toronto under the supervision of the American surgeon Joel Cooper (11). After a few years of experience Dr. Cooper organized an international meeting dedicated to lung transplantation in St Louis in 1989 where he shared the insights and encouraged others to follow. Shortly after, in 1990, the first lung transplantation in Scandinavia was performed in Lund by the surgeon Jan-Otto Solem and his co-workers, closely followed by Gothenburg, becoming the two national centers for lung transplantation. And so they have remained.




Lung transplantation came to Lund through Ass Professor. Jan Otto Solem (left), Professor Stig Steen (middle) and Senior Consultant. Leif Eriksson PhD (right). Transplantation in Lund started with kidney transplantation in 1968. After two decades of experience and more than 800 transplantations it was expanded with heart transplantation in 1988 and lung transplantation two years later, both enabled by the introduction of the Swedish brain dead law in 1988. Jan Otto Solem, Stig Steen and Leif Eriksson organized lung transplantation after gaining knowledge and mastering the technique in St. Louis and Pittsburgh, USA and Harefield, UK, the latter taking care of patients from Lund in need of lung transplantation at the time. This came to a change on January the 13th 1990 when Jan Otto and Stig flew to Linköping with an army helicopter to harvest a donated lung. Back home Jan Otto and the lung transplantation team performed the first single lung transplantation in Scandinavia on a patient suffering from chronic obstructive lung disease. The surgery and recovery proceeded well but the patient died three months later from infection and rejection. Since then, over 300 lung transplantations have been performed in Lund and the hospital nowadays has its own helicopter together with a helipad on the roof. Jan Otto Solem retired from surgery in 2013 but is still active in research about heart decompensation. Professor Stig Steen is engaged in Igelösa Life Science which he founded in 1997, a research center outside Lund contributing to heart and lung surgery. He has contributed with the world's first lung transplantation from a donation after cardiac death, LUCAS (Lund University Cardiopulmonary Resuscitation System), the Vivoline LS1 (the world's first CE-marked medical device system for ex-vivo lung perfusion). He is well known worldwide for his achievements, not least his invention STEEN-solution used for reconditioning lungs from marginal donors. Pulmonologist Leif Eriksson is still active both clinically and in research about cell matrix and the possibilities to use it to create organs for transplantation. Photo credit: Courtesy of Jan Otto Solem, Stig Steen and Leif Eriksson.

The first patient transplanted in Lund died from a Cytomegalovirus (CMV) infection and rejection after three months. The second was far more successful with the patient up to this day, 26 years later, coming for regular check-ups. These two examples summarize to a certain degree the complexity of lung transplantation. Being a huge immunological organ the lungs are one of the uttermost challenges in terms of transplantation with an extensive need of immunosuppression and the least utilization of accessible organs, about 20% (12), the numbers hugely varying between different countries (13). With the introduction of ex-vivo lung perfusion and reconditioning in 2001 and 2006 (14, 15), there are new possibilities to improve the utilization of accessible organs by regaining some of the marginal donor lungs. In Lund, where Professor Stig Steen and co-workers developed these techniques, the utilization of accessible lungs between the years 2007-2014 was 35% indicating the advantages of the new techniques. During this time the organ pool has also been extended by allowance of previous smokers and older donors, up to 70 years of age, adding to the increasing number of used organs. Despite the challenges, as the only medical option for patients with end-stage lung disease it is beneficial with international survival rates of 80%, 53% and 32% after 1, 5 and 10 years, respectively, for both single and bilateral lung transplantation (16). In long term it is still among the lowest compared to other solid organs (17, 18). The number of lung transplantations is constantly increasing worldwide with an impressive number of 4111 lung transplantations performed in 2013 (19).



Revealing the inside – the emergence of imaging

Imaging represents a visual reproduction of an object's form. Some of the oldest images are remains of cave paintings from about 35 000 years ago in Maros, Indonesia. These early images depict animals and humans in symbolic ways with great artistic freedom.



The Edwin Smith Surgical Papyrus from about 1700 BC is the oldest preserved anatomical study (left). To the right is a scheme of anatomical distribution from the text. Photo credit: Jeff Dahl, Public Domain Wikimedia Commons (left) and GNU Free Documentation License (right).

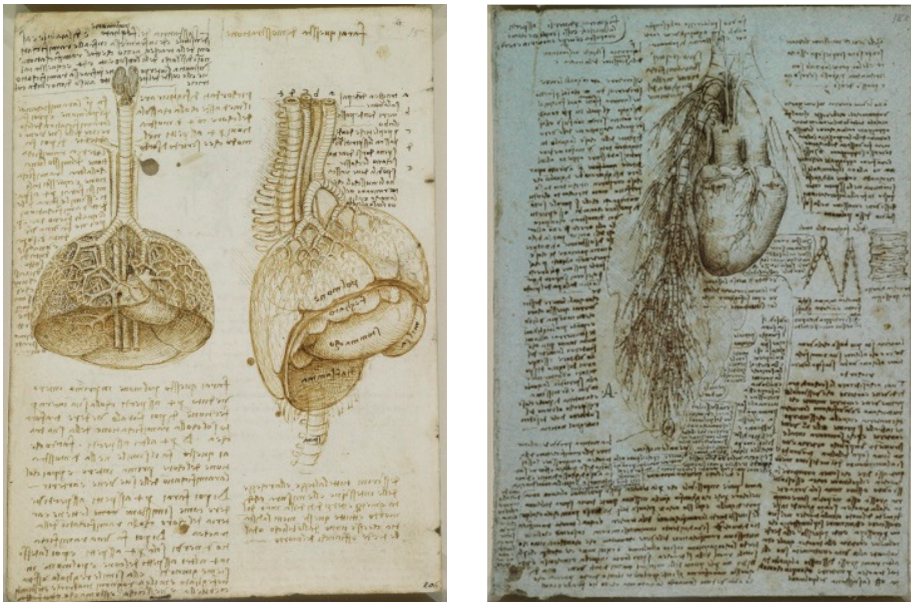
For a long time, it remained that way and the knowledge about the human body was limited, although the anatomy of the interior organs was known already in ancient Egypt through mummification. According to the Egyptian tradition, when preparing the body for the afterlife most organs were removed, providing repeated opportunities to observe and examine them. The oldest preserved anatomical study is an ancient Egyptian medical text from around 1700 BC, called The Edwin Smith Surgical Papyrus (20). Sporadically performed autopsies have been recorded in ancient Greece since 500 B.C. These were to a great extent performed on animals and came to be the foundation of the Galenic and later medieval medicine. In “Al Qānūn fi al-Tibb” (The Canon of Medicine) written by the great Persian physician, philosopher and scientist Ibn Sīnā (980-1037), in the Western world known as Avicenna, anatomy was to a certain degree present.



Title page of the fourth book of “Al Qānūn fi al-Tibb” in Arabic (left) in a copy from the beginning of the 15th century, Iran and the title page in Latin (right) in a copy from 1595. The Canon of Medicine published in 1025 was still in use as a textbook for medical students in the Muslim world and Europe as late as the 17th century. The principles of the Canon are today present in Unani medicine, the traditional Perso-Arabic medicine practiced in Moghul India and Muslim cultures in South East Asia. Avicenna passed away in Hamadan, Iran where his mausoleum in Avicenna Square still stands, open to the public. After the Iranian revolution in 1979 most streets in Iran were renamed in keeping with the new political Islam. The Avicenna Square was a rare exception since the leader of the revolution, Ayatollah Khomeini, was a great admirer. Photo credit: Wikimedia Commons (left). Wellcome Library London (right).

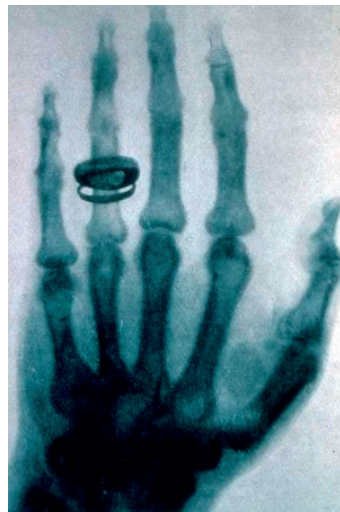The Canon of Medicine came to be the essential textbook in medical studies for about 600 years influencing many generations of physicians. The great contribution of Ibn Sīnā’s work surpasses the awareness of anatomy, and is to be found in his empirical and evidence based scientific approach, reflected in the centuries that followed (21). The first certain official human autopsy was performed by the Italian anatomist and professor of surgery Mondino de Luzzi (c:a 1270-1326) in 1315 at the University of Bologna (22), hinting the new approach that would prosper in

Renaissance, the exiting period between the 14th and 17th centuries. The Renaissance started in Florence, Italy under the wings of the Medici family and spread throughout Europe inspiring humanism, natural science and art to flourish. This is the era of Dante and the *Commedia Divina*, Copernicus revealing the solar system, Columbus discovering America and Gutenberg introducing book printing. It is from this background the first structured anatomical studies were conducted. The first “imaging” of the lungs dates from 1508, performed by no less than the great Leonardo da Vinci himself (23). Although he didn’t fully understand the function of the lungs he depicted them in great detail with an astonishing accuracy of the bronchial arteries. In total about 750 anatomical drawings by Leonardo are known. The vast majority, about 600 including the two drawings of the lungs were probably purchased by Charles II and included in the Royal Collection in the 17th century, reproduced here with the gracious permission of Her Majesty Queen Elisabeth II.




Leonardo da Vinci, circa 1508. The drawing to the left depicts the complete lung, probably porcine. In the drawing to the right the heart with the apex to the right, airways and aorta with the left bronchial artery arising from it are shown in detail. These structures are placed on the opposite side since Leonardo being left handed famously “mirrored” his drawings and handwritings. Leonardo di ser Piero da Vinci (1452-1519), the Toscan polymath who epitomizes the “Renaissance Man” had vast areas of interest from the humanities and natural science to engineering and cartography, but is best known as one of the greatest artists of all time. He started his anatomical studies in the famous art workshop of Andrea del Verrocchio easily mastering topographic anatomy and biomechanics. To improve, he continued with dissection of human bodies, first illegally and later by special permission of the Catholic Church. He gained permission to perform human dissections in the mortuary of “Ospedale di Santa Maria Nuova” in Florence during 1507-1508 and later also in Rome and Milan. His intentions were to sketch a medical book. In total he dissected about thirty human specimens resulting in 750 drawings of ground breaking anatomy before he was forced to stop by the order of Pope Leo X. “Ospedale di Santa Maria Nuova” in Florence is still in use and being founded already in 1288 by Folco Portinari, father of Dante’s beloved Beatrice, it is one of the oldest in the world. Photo credit: By Permission of The Royal Collection Trust / © Her Majesty Queen Elisabeth II 2016.

Anatomical studies pursued and improved, portraying the human body in greater detail. Even so, they were still only subjective representations by various artists. During the early 19th century photoetching and photography developed, representing a new landmark in imaging. This was the first time an objective image of what was seen could be created. The first application of photography in medicine appeared in 1840 with Alfred François Donné photographing sections of bones and teeth in Hôpital Charité in Paris (24), causing a great spin-off with diverse use of photography in medicine. Yet, the interior of the living human body remained unreachable. This came to a complete change with one of the probably greatest scientific discoveries, namely the discovery of X-rays by the German physicist Wilhelm Conrad Röntgen in 1895 (25). To these new rays almost all materials were to a certain degree transparent. He named them X as the mathematical unknown to distinguish them from other existing rays. Testing different materials by holding them between the tube and the fluorescent screen he one night managed to see the ghostly shadow of his own fingers and got the brilliant idea to document it by replacing the fluorescent screen with a photographic plate. In a lecture on January 23, 1896 before the Würzburg Physical Society he made the first X-ray image in public, using the hand of the anatomist Albert von Kölliker (26).



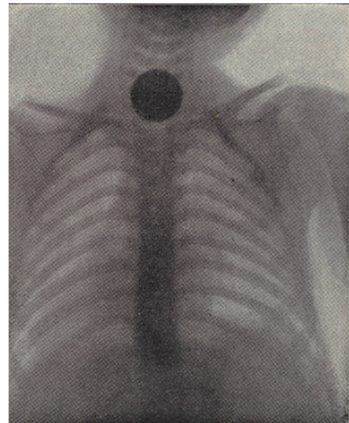
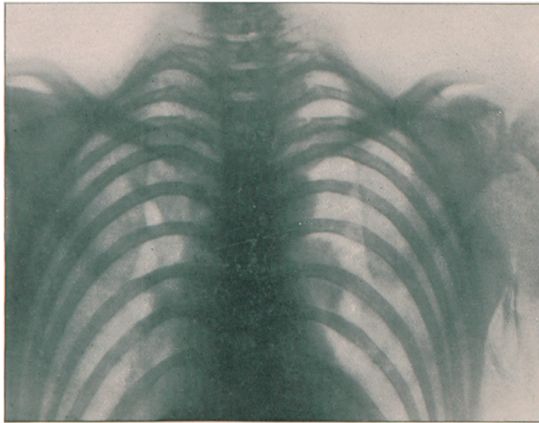
Wilhelm Conrad Röntgen (1845-1923) in 1900 (left). When awarded with the first Nobel Prize in Physics in 1901. Due to his reticence and shun from public engagements, he declined to give the expected Nobel Laureate lecture. Humbly he dispensed his prize money to further scientific studies at the University of Würzburg. The first public X-ray image of the anatomist Albert von Kölliker's hand in 1896 (right). Photo credit: Wikimedia Commons.

Within a year the French physician and pioneer of French radiology Antoine Bèclere at L'hôpital Tenon in Paris installed an "apparatus" performing fluoroscopy. It is in these examinations of the lungs in patients suffering from tuberculosis and the preparation for the presentation of the use of X-rays in medicine by the pioneering American radiologist Francis Henry Williams in 1896 (27) that the lungs of a living patient are observed for the first time. The new technique spread rapidly. In Sweden Thor Stenbeck (1864-1914) founded a Radiology Institute in Stockholm as early as 1898. The building had no electricity so to begin with he had to use accumulators in order to enable the machines to operate. Already in 1897 he realized that radiation could be damaging and advocated protection. With this came the insight of the damaging effects on not only healthy but also diseased tissue and the potential for treatment. In 1899 Dr. Stenbeck was the first to successfully treat a patient suffering from skin cancer with radiotherapy.



Dr. Thor Stenbeck (1864-1914) in his Institute in Stockholm in 1898 (left), Gösta Forssell (right back) and Georg Liljenroth (right front). The pioneer of Swedish radiology was the first ever to treat a patient for skin cancer with radiotherapy. He treated a woman with basal cell carcinoma on her nose in 1899. She was alive and well without relapse as late as 1928. In treating the patient, he was assisted by Gösta Forssell (1876-1950) who would later become the front figure of radiotherapy in Sweden and for many years be in charge of Radiumhemmet in Stockholm which he founded in 1910. He would also become the first to systematically lecture medical radiology in Sweden starting in 1908 and become the first professor of radiology in the world in 1917 (the next one internationally followed in 1926). He founded the radiological journal *Acta Radiologica* (the journal of the Association of the Nordic Societies of Medical Radiology) in 1921 which is still in print and also contributed to the founding of the Karolinska Hospital in Stockholm. Radiumhemmet had physicists closely attached, collaborating with doctors. One of them was Rolf Sievert (1896-1966) who would later be honored with the unit for health effect of ionizing radiation (Sv). Photo credit: Wikimedia Commons.

At the same time when W. C. Roentgen was awarded for his exceptional discovery with the Nobel Prize in 1901, Williams published a comprehensive textbook in radiology considered to be the first one: "The Roentgen Rays in Medicine and Surgery" with many chest X-ray images (28). Now, a good century later, chest radiography is as relevant as ever, continuing to be the bread and butter of chest radiology. According to the United Nation Scientific Committee report at the turn of the millennium, about 40% of all imaging examinations globally were chest radiographs (29). In a broader perspective it is probably the most "democratic" chest examination since it is accessible and affordable worldwide.



"Thorax from a woman", Figure 3 in. F.H.Williams' publication "Notes on X-rays in Medicine" from 1896 (left) probably represents the first published chest image. In Sweden the first published chest image (right) probably comes from Thor Stenbeck's textbook in medical radiology from 1900. It was the first textbook to be published in Swedish called: "Röntgenstrålame i medicinens tjenst populär framställning", Wahlström & Widstrand, Stockholm. Photo credit: "Notes on X-rays in Medicine" from 1896 (left) Jens Östman, National Library of Sweden (right).

From the time of their discovery X-rays and fluoroscopy were extensively used for medical and non-medical purposes. During the first decades, when the danger of radiation still was widely unknown, there was a captivation with the new technique, and radiation appeared in many aspects of everyday life. Drinking radioactive water was considered health promoting, and toothpaste containing radioactive substances was believed to make the teeth shiny and white. X-rays entertained people in travelling circuses. When buying shoes, one could be examined with a shoe-fitting fluoroscope – a pedoscope – to find the most suitable model. It also found its way into the industry, forensics and art. Already in 1897 W. König, one of Röntgen's pupils, used X-rays to prove the authenticity of a painting of Christ ascribed to Albrecht Dürer (26). Fluoroscopic chest examinations became widely used in both health and sickness. During World War I the great Polish-French physicists and the first female Nobel Laureate Marie Skłodowska Curie herself drove a bus with

fluoroscopic equipment, examining the Allied soldiers. Although fluoroscopy is not as present today it is still very much in use, e.g. whenever the motility of the mediastinum or the diaphragms are estimated. Bronchography, nowadays abandoned, emerged in 1906 enabling assessment of the airways, and proved to be helpful in the era when pulmonary tuberculosis complicated with bronchopleural fistulas was still a common disease. The first study of pulmonary arteries in a living human dates from 1923 by Dunner and Calm, and the first one with water-soluble material from 1928 by Adolf Lindblom. These two discoveries enabled the German physician Werner Forssmann to perform the first catheterization of the right ventricle in 1929. Not only did he perform the first catheterization, but he did so on himself, in truth an astonishing accomplishment (26).



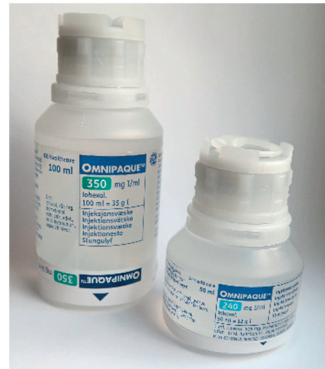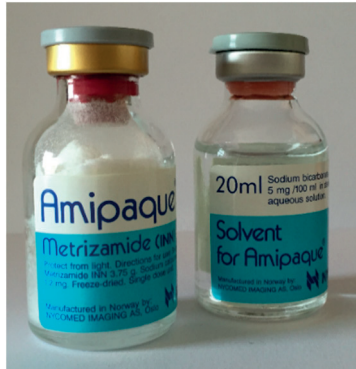Maria Skłodowska Curie (1867-1934) driving a vehicle containing fluoroscopic equipment in 1915. She was the first woman to be awarded the Nobel Prize, the first to be awarded it twice, and to this day the only one awarded it in different fields. She died at an age of 66 from aplastic anemia believed to be caused by the huge radiation she exposed herself to in her scientific experiments. Many establishments are named after her as is one of the bridges in Warszawa. Photo Credit: Wikimedia Commons.

The first pulmonary angiography followed in 1931 by the Portuguese group Moniz, Carvalho and Lima. Despite being severely disabled by gout and unable to perform injections, the neurologist António Egas Moniz developed cerebral angiography, lymphography, phlebography and portal venography (26, 30). In the period 1927-1931 he published no less than 61 papers! He was awarded the Nobel Prize in

Physiology or Medicine in 1949 and honored with having the carotid syphon named after him.

A prerequisite for the development of these imaging methods were the use of intravenous contrast medium. Many substances e.g. bismuth, iodine and calcium had been tried out in the first decades of radiography with sufficient imaging results but more or less intolerable for the patients. Pioneered by Muniz among others, an intravenous contrast media that was well tolerated while also providing excellent images was developed during the 1920s. It was named Thorotrast due to the radioactive substance, Thorium it contained. In its isotope form 232 it has a half-life of 14.05 billion years, the longest half-life of all radioactive substances in nature and approximately of the same duration as the current measurement of the age of our universe. The radioactive compound used in Thorotrast had a much shorter biological half-life of some several hundred years. Unluckily, upon administration it was retained in the reticuloendothelial system which resulted in a lifelong internal alpha radiation exposure and a cumulative radiation dose. The effects were therefore disastrous in the long term with a risk of developing liver or hematological malignancies (31) that persisted and increased with time. Thorotrast was in use from 1928-1959. Under this period other contrast media were developed subsequently replacing it. In the 1950s the first generation of high osmolar iodinated contrast media were available.

Around that time the Swedish radiologist Sven Ivar Seldinger (1921-1998) tried to overcome the puncture difficulties in interventions. In 1956 he presented the needle-guided catheter, after, in his own words “a severe attack of common sense” (32). It is a simple and elegant technique that has become the standard of interventional radiology. Unfortunately, administering available intravenous contrast at the time was a terribly painful experience since the high osmolality attracted water and made the vessels swell resulting in a sensation of heat and pain. Patients therefore often refused to expose themselves to this experience more than once. This came to a favorable change with his fellow colleague and countryman Torsten Almén (1931-2016) introducing the non-ionic low-osmolal contrast media facilitating intravenous administration in the 1970s. The idea for the low osmolality came from his childhood summer experience with less burning in his eyes while swimming in the brackish water of the Swedish south coast compared to the salty water of the Swedish west coast (33). Along with the facilitated administration the discrimination between vessels and tissue in the human body with the aid of contrast media became a substantial part of various imaging techniques.



Low-osmolar intravenous contrast media was first introduced as metrizamide - Ampipaque in 1974. It was complex to produce and delivered as a freeze dried powder with a diluent (left). Although with good intravascular profile it was considered expensive and inconvenient for use. With these characteristics improved in iohexol - Omnipaque was introduced in 1982 (right). It is still one of the most sold intravenous contrast media worldwide. Professor Torsten Almén who developed low osmolar intravenous contrast media was a member of the Royal Swedish Academy of Science and awarded with the Antoine Bécélère Medal at the World Congress of Radiology in 1989. The Torsten Almén Research Center, Nycomed Amersham Imaging in Pennsylvania is named after him. Photo credit: Courtesy of Bengt Pivén, GE Healthcare AB (left) Author's collection (right).

The Italian physiologist L. Spallanzani observed that bats seemed to be guided by sound in 1794. A century later the Curie brothers, Pierre and Jacques, discovered the piezoelectric effect and produced vibrations transmitted as sound waves that could be recorded. Thus the principle of ultrasonic transducers generating and detecting ultrasound was initiated. Along with his wife Marie, Pierre was awarded the Nobel Prize in Physics in 1903. In 1912 the great Titanic sank after a collision with an iceberg in the North Atlantic Ocean with 1514 passengers drowning. The huge catastrophe shocked the world, and many efforts to find the wreck were made, among them the first attempt to localize it with the help of the quite newly introduced ultrasound. The attempt failed, but the method would later be refined and used to localize submarines during the Great Wars. In 1947 it would also enter medicine through the Austrian physician K. Dussik who tried to produce echo images of the brain – ventriculograms. Despite the failure, in only few years acquisition of various echo images succeeded as e.g. of the gallbladder in 1949 (26). The examinations were elaborate and performed with patients in huge tanks surrounded by different solutions such as saline or mineral oils. Although the quality of the images constantly improved, this method could not be applied to all patients, in particular not in those in most need of the examination.

In 1953 Inge Edler and Hellmuth Hertz from Lund, Sweden finalized the first echocardiograph (34). The ultrasound in general though had to be adapted to visualization of other body parts before the first commercial machine was constructed in 1963. It would be complemented with real-time ultrasound in the 1970s. A decade later the Doppler effect, enabling visualization of the blood circulation along with contrast media, was adapted for the method.

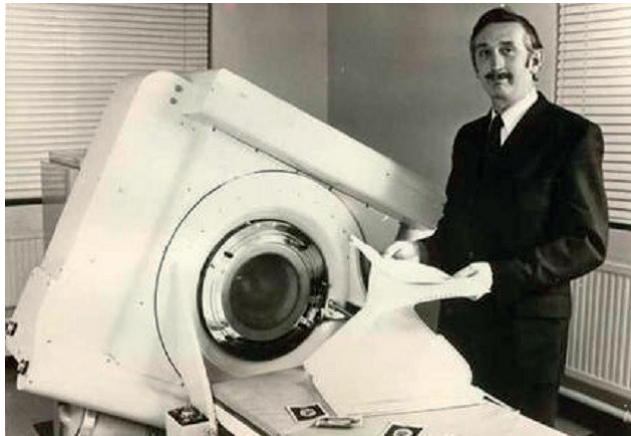


The Howry team's "pan scanner," developed c. 1957–1958. The patient sat on a modified dental chair strapped against the plastic window of a semicircular pan filled with saline solution, while the transducer rotated through the solution in a semicircular arc around the patient. A great many clinical scans were performed with this scanner, which was more appropriate for patient use than were the earlier total immersion scanners. Photo credit: The image originally published by Kodak Health Sciences and courtesy of the American Institute of Ultrasound in Medicine (AIUM) historical archive.

It has found its use in abdominal, skeletal, small parts and breast imaging and is, in the absence of harmful radiation extensively used in pediatric radiology. The air-rich lung is not suitable for imaging with ultrasound since it doesn't transfer the sound waves so the main uses in chest imaging are assessing pleural diseases or for drainage and echocardiography. However, the diseased lung, by losing air is somewhat more manageable with ultrasound. There are efforts to use the variation of artefacts from ultrasound for instance in emergency medicine in search of e.g. pneumothorax and to find incipient fibrosis in patients with scleroderma, a burdened group where early management of the pulmonary complications is important for survival (35). Being present in many medical disciplines, ultrasound is probably the most applied imaging technique in general, and is used also by non-radiologists such as e.g. gynecologists, cardiologists, dermatologists, pulmonologists and rheumatologists.

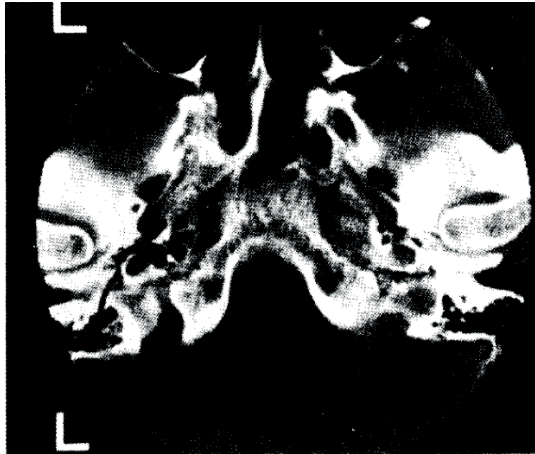
In 1956 the Australian radio astronomer R. N. Bracewell constructed a 2D solar map from multiple ray projections (36). With this, the mathematical model with a two- or three-dimensional object reproduced from an infinite set of all its projections presented by the Austrian mathematician J. Radon in 1917 came into practice. This enabled the South African physicist Allen M. Cormack in the 1960s to calculate flat sections of tissue from measuring the attenuation of X-rays passing through in different angles and provided the mathematical technique later used for computed tomography. The axial tomographic scanner was constructed and introduced in 1967 by the British engineer Godfrey Hounsfield. He was very fond of long walks and

during one of them he got the idea to measure the attenuation of x-rays passing through the body from hundreds of different angles and transform them into an image of the interior body with the help of a computer (37). Later on the unit for measurement of attenuation would be named after him (HU). The first clinical scanner allowing examination of the head was installed in 1971 in Atkinson Morley's Hospital in Wimbledon, London, at the time one of the most advanced brain surgery centers in the world. Together with co-workers Godfrey Hounsfield himself performed the first clinical examination on a human being 1st of October 1971 producing images of a head CT in a patient suffering from a frontal lobe tumor. This marks the clinical entrance of the technique, and it would set off a new era in imaging with an exuberant, still ongoing development.



Sir Godfrey Hounsfield (1919-2004) with a prototype of the axial tomographic scanner. The Nobel laureate was a shy and unobtrusive man who found the public interest in his invention "most embarrassing". He spent some of his prize money to fit out the living-room in his small house with scientific equipment. Hounsfield worked for EMI (Electric and Musical Industries Ltd), the great record label with numerous great artists such as the Beatles, that had a technique developing department aside the music production. He was knighted in 1981. Photo credit: Unknown.

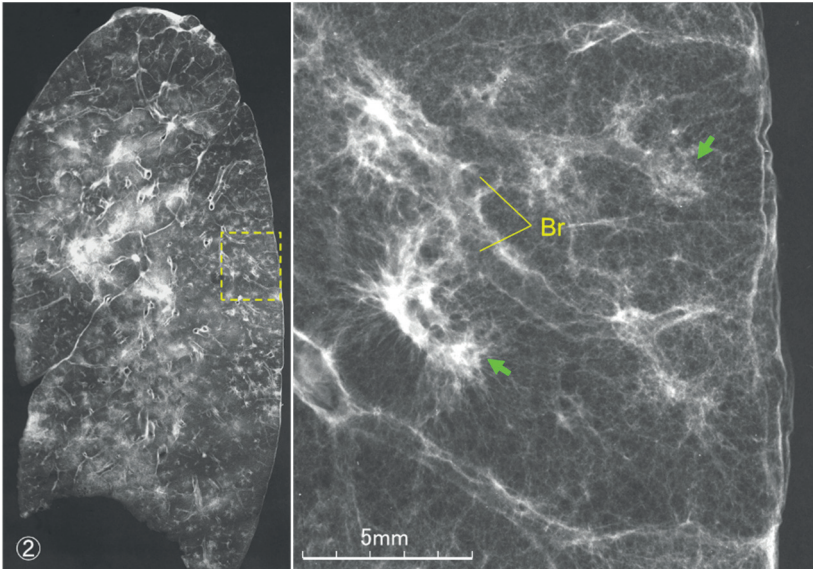
A. M. Cormack and G. Hounsfield shared the Nobel Prize in Physiology or Medicine in 1979. With both of them being far from the world of medicine the choice was to a certain degree controversial. As Cormack noted at the Nobel banquet: "It is not much of an exaggeration to say that what Hounsfield and I know about medicine and physiology could be written in a small prescription form" (38). Yet, however small their link to medicine was, in retrospect there is no doubt that their discovery was the greatest contributions to medical imaging since the discovery of X-rays. CT has become a fast and accessible technique and is today the pillar of medical imaging with few diagnostic and therapeutic medical decisions established without it. The staggering number of about 60 000 CT scanners worldwide was estimated for 2015 (39).



High resolution image of the skull base as presented by Godfrey Hounsfield in his Nobel lecture in 1979 (Fig.15 in the lecture). He presented high resolution CT with several examples in his lecture, having in mind a better image resolution for the future, in contrast to the low image resolution from the first CT scans with a matrix of 128. He did not imply what we today define as high resolution CT technique using certain algorithms that favor details at the expense of losing contrast in the image. At present a matrix of 1024 enabling reconstruction of both lungs at the same time is used. Photo credit: Courtesy of the Nobel Foundation.

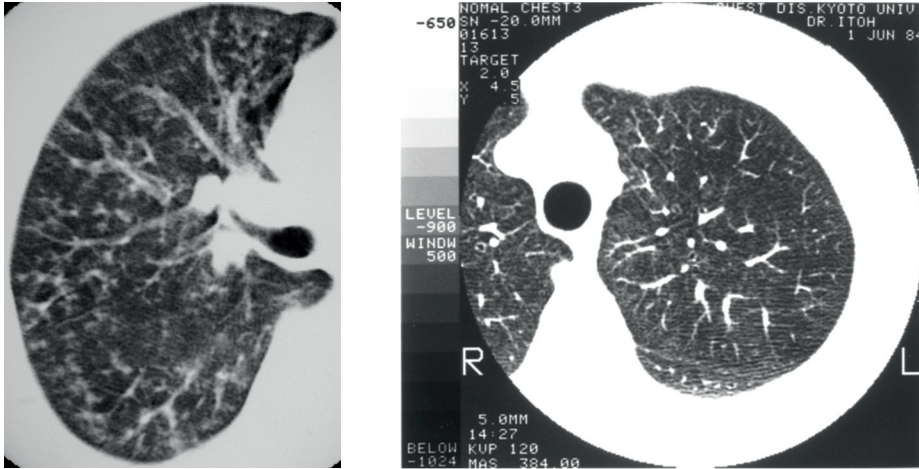
In his Nobel Laurate lecture Godfrey Hounsfield noticed: “It is more than likely that machines in the future will be designed to provide considerably higher resolution than shown in this picture. Such machines would take up many of the present uses of conventional radiography but would do the job considerably better” (40). What he meant at the time was a higher image resolution in general to improve the low resolution images that came with the first scans, not the high resolution technique that already had started to emerge at the time. Initially, CT was used to examine the head. Due to the relatively low spatial resolution it was suitable for imaging of soft tissues but not bone, especially not the irregular temporal bone with a high contrast of both bone and air. With the development of the third generation of CT scanners in the mid-1970s and the introduction of algorithms enabling bone detail reconstruction that increased the spatial resolution (41) the temporal bone could be examined with high resolution CT technique in the late 1970s (42, 43).

Around the same time the Japanese radiologist Harumi Itoh at Kyoto University Hospital investigated the radiologic, anatomic and pathologic correlation in the lung with post mortem radiographs of the lung. The radiographs were performed on 5 mm thin slices of the lung in direct contact with a fine grain film resulting in a resolution of 0.1 mm and photographic enlargement. This revealed the detailed radiologic-anatomic-pathologic correlations in the lung presented in a publication in 1978 (44) and came to be the morphological base for the impending high resolution computed tomography (HRCT) of the lungs that would be developed by the Kyoto group under the leading of Dr. Itoh in the following years.



Radiograph of a sagittal slice of an inflated and fixed left lung with chronic bronchiolitis (left) and an enlarged view of a part of the previous image (right) showing detailed anatomy with centrilobular nodules in the extreme end of the bronchial tree. Images were obtained in the 1970's in the Radiology Department of Kyoto University Hospital. Photo credit: Courtesy of Professor Harumi Itoh.

As revealed in personal communication with Professor Itoh, in 1980 his doctoral student Giro Todo decided to apply the HRCT technique on lung parenchyma. He hypothesized that HRCT of the lung might succeed since it already seemed sufficient for the temporal bone having a similar radiological character with high contrast. With a vast experience in radiologic-anatomic-pathologic correlations in the lung, the clinical importance of the applied new image technique was instantly recognized. With Dr. Todo's finalized thesis in 1986 emphasizing lung lesions on HRCT the Kyoto group confirmed the secondary pulmonary lung lobule as the basic structure where alveolar and interstitial diseases start. They also described the method. However, already in 1982 they published their ground breaking early experience of HRCT in 21 patients with single slice technique describing the peripheral lung in great detail (45). Thereby they initiated a new development in chest radiology, enabling a refined diagnostic approach to interstitial lung disease. With insights in the new technique, advancements and new knowledge came quickly, heightened by publications about the use of CT in chronic diffuse infiltrative lung disease in 1990 (46, 47). Since then, several thousand articles about pulmonary HRCT have been published. Being the first published paper on HRCT of the lung the term itself has been attributed to the Kyoto group. It is notable though, that the expression high resolution computed tomography implying the high resolution technique has been used earlier in publications about the temporal bone (42, 43). It has also been used in earlier comments and presentations, however, not with the same meaning we imply today.



One of the first performed HRCT in a patient with panbronchiolitis from 1st of September 1981 at Kyoto University Hospital (left). More than 40 years later it is still excellent and of diagnostic quality. The first studies included the diseased lung. This was later complemented with scans of a normal lung (right) with Dr. Itoh himself as a healthy volunteer in 1984, shown at the RSNA meeting later the same year as a part of the scientific exhibition: "Secondary pulmonary lobule: A basic radiologic unit of the lung" honored with Cum Laude. Interestingly enough, the paper that came out of it was refused by Radiology because there was no direct correlation between postmortem images and HRCT. The first direct correlation was shown further on in a publication in 1986 by Dr. Murata on behalf of the Kyoto group (48). Photo credit: Courtesy of Professor Harumi Itoh.

HRCT is a different application of CT with a certain algorithm focusing on the air in the image assembled in a thin, 0.625-1.5mm section. Reconstructed with a high resolution weighted filter as the one for bone for instance, it provides excellent images of structures surrounded by air such as the temporal bone or lung.

Initially the greatest limitation for HRCT was the long breath hold necessary of about 10s per slice resulting in major breathing artefacts and unsharp images, particularly unsuitable for patients with respiratory diseases. With the development of CT scanners the breath holding time has been reduced to far less than 1 s per section and larger matrices, enabling fast reconstruction and complemented by volumetric acquisition technique. A volumetric HRCT with 0,625-1,5mm thin sections reconstructed with a bone filter is currently the best imaging method available to non-invasively display subtle parenchymal lung changes and the method of choice for imaging in interstitial lung diseases. The order of magnitude of the structures seen with this technique is less than 1 mm (49). HRCT is today a substantial part of chest imaging with any approach to interstitial lung disease unimaginable without it (50).



Professor Harumi Itoh, the front figure in the development of pulmonary HRCT. He has been dedicated to research in chest imaging for 45 years with radiologic anatomic and pathologic correlation as its base. His present focus is on 3D CT to understand the initial stages of chronic interstitial pneumonias. Professor Itoh's doctoral student in the early 1980s Dr Giro Todo authored the first paper on pulmonary HRCT on the behalf of the Kyoto group. He left chest radiology in mid 1980s and has since been active in general radiology with publications in MRI and nuclear medicine. He is at present director of the Department of Radiology at Osaka Red Cross Hospital in Japan. Photo credit: Courtesy of Professor Harumi Itoh.

At present colleagues in Japan are developing ultra-high resolution CT with higher spatial resolution than conventional HRCT heading for a better assessment of solitary pulmonary nodules. By dividing them with greater precision into ground glass opacities, semi-solid and solid better management may be achieved since the first two carry a higher risk of malignancy (51, 52).

The first papers describing nuclear magnetic resonance from which magnetic resonance imaging (MRI) would develop was published in 1946 by the Americans F. Bloch and E. Purcell, both awarded the Nobel Prize in Physics in 1952. The nuclear magnetic resonance stems from the discovery of the rotating magnetic field by the Serbian-American engineer Nikola Tesla in 1882 (53). The unit of strength of the magnetic fields (T) would later be named after him as would the airport in Belgrade and, more recently, an environmentally friendly electric car. Many elaborations proceeded before MRI emerged in clinical imaging in the 1980s. Once again we find the name of R. N. Bracewell, contributing with a mathematical model of Fourier transformation of great importance for the technique. With contributions to development of both CT and MRI Bracewell has certainly left his mark in the development of medical imaging but also literally throughout the universe since Bracewell's probes – space artefacts powered for interstellar travelling to make contact with other intelligent beings in the galaxy are named after him. In 2003 the

American chemist Paul C Lauterbur and the British physicist Peter Mansfield were awarded the Nobel Prize in Physiology or Medicine for their discoveries enabling MRI. Paul Lauterbur introduced the two-dimensional MR images. Peter Mansfield discovered that use of gradients in the magnetic field gave signals that rapidly could be transformed into an image. This time there was no buzz about the awardees lacking links to medicine since MRI already was such an integrated part of medical imaging. An interesting detail is that when Lauterbur submitted his paper with the first MR images to Nature in 1972 he was initially rejected. He would later comment on the event: "You could write the entire history of science in the last 50 years in terms of papers rejected by Science or Nature". Something for the scientific community to lean on to in times of setbacks.



Nikola Milutin Tesla (1856-1943) in the lobby of the hotel New Yorker, New York circa 1940, where he lived the last ten years of his life. He spoke seven languages and was a good friend of the writer Mark Twain. He has figured in cartoons with Batman and Superman and several movies like "The Prestige" in 2006, impersonated by David Bowie. Photo credit: The Tesla Collection/Photo 52.

Today, with a continuous development of sequences, suitable intravenous contrast media, stronger magnetic fields now reaching 7T and faster acquisition, the MRI technique covers most of the body and is indispensable when it comes to e.g. neuro, skeletal and abdominal imaging. In the chest it is suitable for imaging of the breasts, chest wall, pleura, mediastinum, great vessels and the heart. The lung parenchyma is roughly visualized but, as with ultrasound the diseased lung is somewhat more manageable so MRI has a particular use in patients with cystic fibrosis (54, 55). With CT and HRCT being so superior in assessment of interstitial lung disease MRI

primarily provides a broader spectrum. There are efforts to use MRI to discriminate between fibrosis and inflammation dominant pulmonary lesions (56) which is of great interest nowadays since suitable drugs for treatment of fibrosis has emerged in recent years. The treatment affects the inflammatory reaction in the fibrotic process but not established fibrotic lesions. These can be discriminated with different MRI sequences. There are an estimated 36 000 MR scanners worldwide in 2016 (57).

In Geneva in 1991 D. Townsend et al. developed low cost positron emission tomography (PET) with several rotating detectors opening the possibility to incorporate a different imaging modality between the detector gaps. With the input from the Swiss surgeon R. Egeli suggesting to combine it with a CT scanner the concept of PET/CT was born. The first prototype came into clinical evaluation at the University of Pittsburgh in 1998. The impressive results from scanning about 300 oncology patients stimulated a demand for a commercial PET/CT which came about in 2001 as Discovery LS (GE Healthcare) with an incorporated 4-slice CT scanner. In 2011 there were about 4000 PET/CT scanners worldwide, a tremendous and fast development (58). Nowadays assessing oncology patients is unimaginable without PET/CT. PET/MRI is an alternative combination of imaging modalities.

Animals in the service of science

Throughout the history animals have closely accompanied humans, forming a complex alliance and an inseparable part of our existence. The animals have been feared, worshiped, sacrificed and persecuted. A deeper interest in all living – plants, animals and humans – was widely spread already among philosophers in Ancient Greece and it is here the first recorded animal dissections are to be found. The first is tribute to the philosopher Alcamaeon of Cortona in the 5th century who is believed to have identified the Eustachian tube (59). He was followed by many, not least the giant amongst the Greek philosophers, Aristotle (304-258 BC) (60).

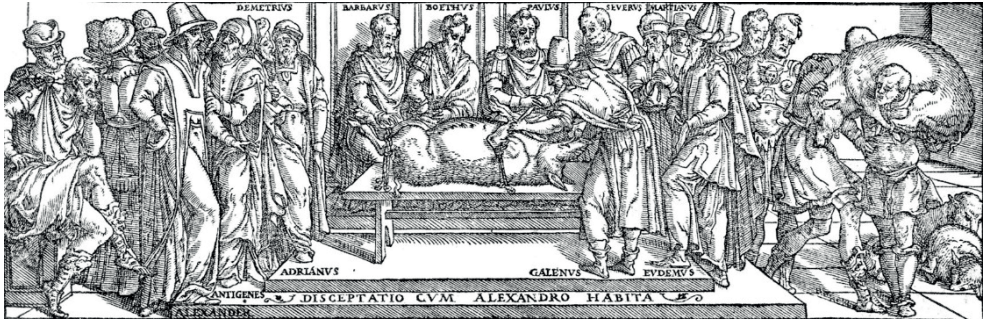The Greek physician and surgeon Galen of Pergamum (129-c: a 210) who practiced in Rome was known as one of the most acclaimed physicians of all times. He performed dissections on pigs and monkeys in the 2nd century (61). His anatomical reports would prevail into the 16th century when replaced by structural anatomical human studies emerging during the Renaissance. Already in the 12th century enlightened Moorish Spain, animal testing was introduced as an experimental method by the Arabic physician and surgeon Ibn Zuhr (1094-1162),



Egyptian carnelian amulet from the Second Naqada period (3650-3300 BC) (left). Celtic bronze figurine representing a boar (100 BC-100 AD) (right). *Sus scrofa* was domesticated from the wild boar in the basin of Tigris about 13000 BC. They are even-toed ungulates, 0.9-1.8 m in size and 50-350 kg in weight, omnivores, highly intelligent company seeking creatures, in behavior similar to dogs and humans. Two of the most ancient of the Egyptian gods, the sky goddess Nut and the storm god Set were often identified as a pig and often worn as amulets. The Celtic pig god Moccus is the protector of warriors. In Ancient Greece pigs were commonly sacrificed to Demetria, the Goddess of harvest. Photo credit: Photograph © Museum of Fine Arts, Boston (left) and Copyright of Norwich Castle Museum and Art Gallery (right).

known as Avenzoar, who recommended testing surgical procedures on animals before applying them on humans (62). From this time on, vivisection gradually came in to practice. The Flemish physician and anatomist Andreas Vesalius (1514-1564) introduced systematic vivisections sacrificing dogs to demonstrate anatomy to his students at the University of Padua, Italy (63). He also authored the first book on modern human anatomy: “*De humani corporis fabrica*” in 1543. The animal scientific experiments began to increase in the 17th and 18th century when blood circulation came into focus and excelled in the late 19th and 20th century with the vast expansion of the medical science experiments. In 1865 the French physiologist Claude Bernard (1813–1878) published his book: “*An Introduction to the Study of Experimental Medicine*” where he set out the principles of modern experimental medicine. The relationship between ideas, experimental facts and thinking is the central theme in Bernard’s philosophy. He advocated that only properly controlled and rigorously conducted animal experiments carefully chosen for the purpose could provide reliable information on physiology and pathology of medical relevance (64).

During the 18th century the gruesomeness of animal experiments started to be questioned by many. The British philosopher Jeremy Bentham (1748–1832) proposed: “The question is not, Can they reason? Nor, Can they talk? But, Can they suffer?” (65). Bentham’s utilitarianism continues to influence today’s debate on animal use in life sciences. One of the first animal protection laws appeared in the United Kingdom in 1822 named “Cruel Treatment of Cattle Act”. In 1876 the “Cruelty to Animals Act” was passed by the Parliament of the United Kingdom and came to be the first piece of legislation ever to regulate animal experimentation.



Galen performs dissection of a pig, illustration from Claudii Galeni Opera Omnia. Photo credit: Welcome Images.

During the last century animal suffering has become morally and socially relevant. An ethical balance between the benefits through biomedical progress and the consideration of animal wellbeing has been sought within a more humane science. This was addressed in the scientific community in the 1950s and confirmed in 1954 with the first edition of the Universities Federation for Animal Welfare’s Handbook on the Care and Management of Laboratory Animals in the United States. The organization’s founder, Charles Hume commissioned a general study on humane techniques in animal experimentation. He commissioned it to the zoologist William Russell (1925–2006) and microbiologist Rex Burch (1926–1996), in a project chaired by the immunologist Peter Medawar (1915–1987). From this work, Russell and Burch developed the tenet of the “Three Rs” –Replacement, Reduction, and Refinement in 1959 (66) that permeates life sciences ever since:

1. Replacement: methods which avoid or replace the use of animals in research
2. Reduction: use of methods that enable researchers to obtain comparable levels of information from fewer animals, or to obtain more information from the same number of animals.
3. Refinement: use of methods that alleviate or minimize potential pain, suffering or distress, and enhance animal welfare for the animals used.

The chairman of the project, the Brazilian-British-Lebanese Immunologist Peter Medawar was later awarded the Nobel Prize in Medicine or Physiology in 1960 for his discoveries of the acquired immune tolerance and transplantation immunology. His discoveries represent the foundation for the present praxis in counteracting acute and chronic immune responses after transplantation.

Along with the awareness of animal suffering and the moral debate about the conditions for animal use in medicine there were some incidences that would variegate the debate. One of the most infamous is the use of thalidomide during the 1950s and 1960s as a tranquilizer and a painkiller (67). Thalidomide was labeled as a “wonder drug” for insomnia, headache and counteracting morning sickness in

pregnancy. Thousands of pregnant women took the drug to relieve their symptoms with disastrous consequences. More than 10 000 children in 46 countries were born with malformations. After a long campaign in the 1960s the drug was finally withdrawn in 1968. No animal testing was done prior to the introduction of the drug. A similar incident occurred already in 1937 when diethylene glycol was used as a solvent for preparation of sulfanilamide. There was no awareness of it being poisonous since no animal testing was done prior to commercial use. It caused a mass poisoning with the death of more than hundred people (67). Incidents like this pointed out the harm to humans from the use of substances that have not first been tested on animals and the perplexing dilemma in balancing the use of animals in biomedical research in view of the significant advances in the treatment of various diseases it has contributed with. Recent disastrous events in some clinical trials previously tested on animals though, as the one with BIA 10-2474 in France in January 2016 with death of one person and brain damage in four other (68) or the so called “Elephant man trial” with TNG 1412 in UK in 2006 with six persons treated for multi organ failure and subsequently loss of fingers and toes (69) underlines that animal use only is a part of the solution for pre-clinical trials without guarantees for a secure outcome in clinical trials.

The number of animals used in research peaked in the 1970s and started to decline thereafter, although the number of biomedical papers has since more than doubled, clearly as a result of implementation of the Three Rs. In 1999, the Declaration of Bologna, signed during the 3rd World Congress on Alternatives and Animal Use in the Life Sciences, would reaffirm that “humane science is a prerequisite for good science, and is best achieved in relation to laboratory animal procedures by the vigorous promotion and application of the Three Rs. The overarching principles of the Three Rs have also influenced several legislative documents regulating animal use in science since the 1980s including the latest European legislation Directive 2010/63/EU of the European Parliament on the Protection of Animals Used for Scientific Purposes in 2010. The Swedish legislation Djurskyddslagen SFS 1988:534 from 1988 is also based on the same principles.

The use of animals in transplantation has gone along with the use of animals in biomedicine in general, with grand advances unfeasible otherwise, and several dubious managements. In the historical retrospect the testis transplantation in humans by grafting monkey testis tissue for rejuvenation purposes in about 500 patients during the 1920s by the Russian-French surgeon Serge Voronoff (70) has to be regarded as a low tide, although somewhat softened during the last decades by new inputs. Modern medicine has established that the Sertoli cells of the testis constitute a barrier to the immune system, rendering the testes an immunologically privileged site for transplantation of foreign tissue, so the thin slices of monkey testicles Voronoff implanted into the patient's testicles may in theory have survived to produce some benefit (71, 72). However, this was unknown at the time making it difficult to approve of the practice. In contrast stands the first successful experimental heart and lung

transplantation in dogs performed in the Soviet Union by the Russian experimental physiologist and surgeon Vladimir Demikhov in 1947 (73).



Vladimir Petrovich Demikhov (Владимир Петрович Демихов) (1916-1998). The Russian organ transplant pioneer contributed the first artificial heart in 1937, the first heart, lung, liver and head transplantation in the 1940s and 1950s including the first mammary-coronary anastomosis in 1952, despite the heart and lung machine having not yet been invented. He solved the circulation problem by ingeniously connecting the vessels back and forth. When he started out his scientific achievement solid organ transplantation was still more of an idea without clinical impact. When he passed away in 1998 transplantation of all solid organs was in regular practice worldwide and is still continuing to increase in number. Of all his experiments one of the most famous and controversial is the head transplantation. For many years it had a science fiction connotation with no clinical credibility for the future. However, head transplantation has in recent years been successfully performed in paraplegic rats and new knowledge about rebridging transected spinal cord and perfusing neural tissue has been gained. The first head transplantation in a human has been announced for 2017 in a 30-year-old volunteer suffering from muscular atrophy with rapidly declining health. Dr Demikhov was awarded the Order for the Merit to the Fatherland and the USSR State Prize. He also received international recognition and was awarded The Pioneer reward of the International Society of Heart and Lung Transplantation in 1989 and membership in several international Societies. Photo credit: ru.wikipedia.org.

Helping out during the World War II he gathered a lot of experience in human pathology and surgery, not least did he become well acquainted with the newly introduced stapling machine that Russian engineers and surgeons developed in the early 1940s as a necessity to handle the countless injured in the horrid war. He would later introduce the stapling machine for various thoracic grafts in transplantation surgery (74). Through his summed experience in the monograph “Transplantation in vital organs in experiments” from 1960 the medical discipline “Transplantology” came to birth. His achievement has been essential for thoracic transplantation and coronary bypass surgery. Remarkably, they were carried out almost without financial support in isolation following the Cold War. The South-African surgeon Christiaan Barnard, who performed the first human heart transplantation in 1967 visited him twice in his laboratory in Moscow and considered him his teacher.

Having mastered and evaluated most of the accurate surgical techniques in thoracic transplantation for time being we now face other challenges where animal use still can be considered such as limited number of accessible organs and long term survival after lung transplantation due to chronic graft dysfunction and obliterative bronchiolitis. In current insight smaller animals, e.g. rodents, are pondered suitable for high-throughput research and larger animals, e.g. pigs, suitable for preclinical trials and repeated measuring of clinical parameters and blood samples (75) with a thorough consideration of the potential benefits of the research judged as important enough to justify the use of animals, and otherwise unattainable.

Reflecting on animal use in biomedicine it has been presented that out of the 106 Nobel Prizes in Physiology or Medicine given since 1901, 94 have been dependent on research using animals including every prize awarded for the past 30 years (76). Almost every great medical discovery in the last century that we benefit from today in diabetes, cancer, Alzheimer's disease, drugs, vaccines, imaging methods etc. has included animals in one way or another. This is worth a thorough deliberation. Today, following strict legislations based on the Three Rs, ethical considerations and a humane approach is necessary for any kind of appropriate and trustworthy scientific use of animals. However, this practice has constantly to be evaluated and improved with the ultimate goal of complete replacement of animals in the future most beautifully put in a quote often attributed to the great Indian statesman Mahatma Gandhi: "The greatness of a nation and its moral progress can be judged by the way its animals are treated".

Summarizing this brief overview of the history and development of organ transplantation, medical imaging and animal use in medicine it can be described as a long story of interaction crossing all scientific and geographical borders. It is also a continuous story without straightforward or end. Where are we heading? Will needed organs be bioengineered from stem cells or will difficulties of xenotransplantation be overcome? Is nanotechnology, now ground-breaking in so many aspects of science, the basis for the next great imaging method – medical nanolithography? Is there a sole scientist in some distant corner of the world nourishing the ground for the next great discovery or will this emerge from our awakened collective awareness of our impact on the environment and urgent need to husband our limited sources? There is no way to know. Nonetheless, in our follow through we are beholden to critically approach what we dispose and look ahead. This thesis is a small attempt to contribute to that matter.

Introduction

Lung transplantation is currently the only available treatment for terminally ill lung patients with a life expectancy of less than two years. The survival after both single and double lung transplantation is beneficial with survival rates of 80% after the first year, 53% after five years and 32% after ten years (16). However, lung transplantation has still among the lowest survival rates compared to other solid organs (17). At present only brain dead organ donors are accepted for lung donation. With a low incidence of brain death, about 3% of all deaths in the Intensive Care Unit (ICU) in Scandinavia (77), it composes a small donor pool. Brain death is commonly caused by severe head trauma, cerebral infarct or hemorrhage, and is determined according to strict legislated routines (78) that are similar throughout the international community. After brain death is determined organs can be harvested for transplantation during a legal time frame of 24 hours in Sweden. Unfortunately, in addition to the small donor pool, not all available lungs can be used for transplantation due to poor oxygenation from e.g. development of pulmonary edema or aspiration pneumonia (12). In 2014 the utilization varied between 9-57% in different countries (13). When cerebral injury occurs it is common for the patient to aspirate stomach content or blood and secretion from the upper airways into the lungs, thereby damaging them. This can also happen during cardiopulmonary resuscitation, with the unconsciousness itself increasing the risk of aspiration (79).

As brain death occurs a “catecholamine storm” with severe hypertension is induced followed by loss of peripheral vascular resistance and a severe systemic hypotension. With the function of the pituitary gland ceasing, a lack of hormones leads to hypothyroidism, adrenocortical insufficiency and diabetes insipidus. To maintain an acceptable blood pressure and thereby preserve organs for transplantation it may be necessary to infuse large volumes of fluid. High doses of catecholamines could help keeping the blood pressure at a sufficient level and limit the needed fluid volumes but are restricted due to concerns regarding the kidneys and the liver. Blood products are restricted for immunological reasons as are plasma expanders because of possible impairment of the kidney function in a potential organ donor. Therefore electrolytic solutions are frequently used to maintain the blood pressure. Since they lack colloid osmotic active molecules they cause hemodilution with extravasation and interstitial edema. The quick resorption of fluid

from the circulation requires repeated fluid infusions with again extravasation and interstitial edema. The lungs, being particularly sensitive to fluid overload, develop pulmonary edema. Edema impairs the oxygenation and the donor may subsequently develop low values of blood gases shifting towards a marginal donor and furthermore eventually jeopardize the donation (80). With brain death the function of the vasomotor center in the brain stem is lost, which can also contribute to the development of neurogenic pulmonary edema through still not completely known mechanisms (81).

A new pharmacological treatment that normalizes the circulation after brain death and thereby counteracts the development of overload edema has been developed but not yet clinically evaluated. Apart from a cocktail of pituitary hormones which is commonly used for treatment of brain dead organ donors (82-85) it consists of cocaine and very small doses of adrenaline and noradrenaline. Cocaine inhibits the re-uptake of adrenaline and noradrenaline, thereby keeping them in the circulatory system, thus maintaining blood pressure at a sufficient level without additional need for fluid substitution. Without large volumes of fluid there is no extravasation and no conditions favoring the development of overload pulmonary edema. In the last decade implementation of ex-vivo perfusion with reconditioning of the lungs as a preservation technique provides more accurate assessment of the lungs. It can also improve the lung function and thereby regain some of the marginal donors, notably if pulmonary edema is present (86). Together with acceptance of donors up to 70 years of age and previous smokers (87) this practice has somewhat expanded the donor pool. For instance, in Sweden the utilization of all available lungs was 27% in the year 2000 and 39% in 2014 (13). However, there is still a substantial shortness of needed organs, and despite the increased number of organs still every fifth patient from the waiting list for lung transplantation in Sweden dies while waiting in line for a transplantation.

Donor management is highly specialized and strictly regulated with a very complex organization. It aims for maintenance of vital functions and assessment of the function of all potentially transplantable organs such as kidneys, heart, lungs, liver, and pancreas with a separate procurement organization for each and every one of these. Because of the legal time frame and the vulnerability of organs the teams work under a severe time pressure. As stated in the international guidelines for organ donor acceptability criteria (12) for the lungs the donor is evaluated according to:

- Weight and height to match the size of the donor lungs with the recipient
- Blood group for compatibility
- Blood gas analysis as a measure of lung function with acceptance limit of arterial oxygen tension (PaO_2) ≥ 40 kPa.

Further, there are some requirements prior to acceptance for donation:

- Information about infections, particularly CMV infection because of the association with post transplantation lymphoma
- A “clear” bedside chest radiograph.

The introduction of ex-vivo perfusion and its transplant rehabilitation potential of marginal donors (80, 88-90) and acceptance of patients up to 70 years of age and previous smokers has expanded these donor criteria (91, 92). The increased donor pool nowadays includes 51% extended donors (93).

The degree of medical urgency and the distance between the donor and recipient are also taken under consideration when matching donors and recipients. For time saving reasons the use of radiologists for image evaluation is avoided in some centers. Instead it relies on members from the transplantation team such as transplantation doctors or coordinators, the latter usually being nurses (94) with the risk of important information loss. The chest radiograph is considered one of the most complex imaging modality to interpret and several studies show that clinicians frequently miss specific radiographic abnormalities with a considerable discrepancy between their interpretations and those of trained radiologists (95-97). It has also been shown that the radiology report of chest x-ray changes the patient management by about 11% (98). This highlights the importance of routine evaluation of chest radiographs by a well-trained radiologist. This even more so since underdiagnoses on bedside chest radiographs in critically ill patients are common for e.g aspiration, pleural effusion or occult pneumothorax (99-101). Furthermore, the accuracy of bedside chest radiographs, although high when detecting tubes and devices, is only moderate when detecting opacities caused by cardio-pulmonary abnormalities (102). The consequences may be unnoticed lung pathology, potentially of importance for the donation and transplantation.

Computed tomography (CT) has a much higher accuracy than bedside chest radiography (103, 104). In recent years CT scanners have improved, becoming faster, and CT examinations are commonly available around the clock in most hospitals. In addition, performing CT with 1 mm or thinner sections with a high-resolution algorithm and reconstructed with a bone filter (high resolution CT, HRCT) is the best imaging method to non-invasively display subtle parenchymal lung disease (46, 47, 105, 106). In contrast to the donor evaluation, once transplanted the lungs in the recipient are meticulously monitored with imaging, chest CT or HRCT as well as with repeated bronchoscopies and biopsies and spirometry in search for pulmonary complications to lung transplantation. Here radiology play a pivotal role in diagnosis and management of complications of lung transplantation (107).

The common complications to be expected after lung transplantation are primary graft dysfunction (PGD) in the early post-transplant phase, chronic allograft rejection (CAR) most commonly manifested through bronchiolitis obliterans syndrome, for long time survival, and overall infections. They are the most prevalent causes of morbidity and mortality. PGD together with CMV and other infections favor an autoimmune response later on causing CAR (108). There is also a connection between PGD and the donor suffering from e.g. aspiration pneumonia, trauma, hemodynamic instability, old age and/or smoking history. Though it is safe to transplant lungs from older donors and previous smokers (91) it pertains an increased risk in general for pre-existing disease and complications to lung transplantation. The incidence of chronic obstructive pulmonary disease (COPD) (109), idiopathic pulmonary fibrosis (IPF) (110) and lung cancer (111) coincide with the increased age of accepted donors and therefore preexisting lung disease in donors may be expected.

Bearing all this in mind it seemed reasonable to focus on the donor and the imaging in this thesis

Papers I and II

The first two papers focus on the circulatory instability in donors and development of pulmonary edema that could compromise potential donation. We evaluated a new pharmacological treatment in an animal model resembling the brain dead organ donor. The treatment consisted of a cocktail of pituitary hormones which is commonly used in treatment to brain dead organ donors and in addition, cocaine and small doses of adrenaline and noradrenaline (Tab. 1). Cocaine is often used in the surrounding bath when investigating segments of blood vessels since it inhibits the uptake of adrenaline and noradrenaline and liberates the post-junctional α -adrenergic receptors (95, 96). At the same time, it causes vasoconstriction.

| Table 1. Pharmacological treatment of brain and brainstem death. | | |
|--|--------|--|
| Dissolved in NaCl to 50 ml | | Doses |
| Cocaine | 1 mg | 0.003-0.014 $\mu\text{g}/\text{kg}/\text{min}$ |
| Noradrenaline | 1 mg | |
| Adrenaline | 1 mg | |
| Desmopressin | 36 mg | 0.12-0.51 $\mu\text{g}/\text{kg}/\text{min}$ |
| Triiodothyronine (T3) | 0.3 mg | 0.001-0.004 $\mu\text{g}/\text{kg}/\text{min}$ |
| Thyroxine (T4) | 0.3 mg | |
| Cortisol | 300 mg | 1.00-4.25 $\mu\text{g}/\text{kg}/\text{min}$ |

Photo credit: Steen et al. Pharmacological normalization of circulation after acute brain death. *Acta Anaesthesiologica Scandinavica*, 2012, Wiley.

The idea was that by keeping adrenaline and noradrenaline in circulation causing vasoconstriction, the blood pressure in a brain dead donor model would be maintained on a sufficient level without the need for additional fluid substitution, thus avoiding development of pulmonary edema. The treatment was evaluated using clinical parameters throughout and state of the art chest imaging after a 24 h observation period. As a preclinical study with the purpose to survey a new treatment through repeated measurements of clinical parameters, blood samples and imaging a suitable brain dead animal model was elaborated. Pigs were chosen as the most suitable animal model in accordance with current insight. Brain death has previously been studied in pigs (112, 113). The anatomy of the pig in general is similar to that of humans and it has been shown that they are suitable as models for radiologic-pathologic correlation (114). In addition they have well-developed interlobular septa (115), of importance since pulmonary edema was expected. When repeatedly measuring the PaO₂, mean arterial pressure and blood analyses the size of the animals becomes important. Although recent advances have been made with small implantable transmitters measuring systemic blood pressure in mice, in small animals it still remains difficult and expensive to achieve as is mechanical ventilation. These parameters are therefore best measured in larger animals (116). For repeated blood analyses a certain amount of blood has to be available which makes small animals unsuitable. The number of used animals was balanced in keeping with the Three Rs lowering it as knowledge was gained. Hence there was an uneven division of animals in the evaluated groups in paper II.

Papers III and IV

In the last two papers imaging of the lungs in donors has been focused on. Imaging in donors at present is simple and inconspicuous proposing a “clear” chest radiograph (12). Although there are publications evaluating the mandatory chest radiograph (117-119) they have not been able to provide firm guidelines regarding utilization of donors with abnormal chest radiograph. A few years ago a proposal was made to encourage the use of computed tomography in addition to the mandatory chest radiograph (120) for donor evaluation. In paper III all imaging, not only the mandatory chest radiograph in potential organ donors during 2007-2014 was retrospectively surveyed and analyzed for the radiological interpretation quality and further in paper IV imaging findings in the mandatory chest radiograph were related to clinical parameters and survival after lung transplantation for the potential organ donors who actually donated the lung.

Aims

Paper I

The aim was to evaluate if the circulation could be normalized pharmacologically with a new treatment for 24 h after acute brain death in a porcine model.

Paper II

The aim was to investigate if circulation could be stabilized by the new pharmacological therapy instead of forced fluid infusion after brain death, and to assess therapeutic effects on lung function and morphology with blood gas parameters and HRCT.

Paper III

The aim was to retrospectively (a) evaluate diagnostic imaging that potential lung donors undergo (b) evaluate reader variability of image interpretation and its relevance for donation and (c) analyze potential information gained from imaging studies not primarily intended for lung evaluation but partially including them.

Paper IV

The aim was to evaluate the relevance of donor image interpretation for lung transplantation outcome by following up donated lungs and analyse early and late complications and survival during the first year after lung transplantation, and correlate pre-transplant donor lung imaging findings and blood gas analysis with lung transplantation outcome.

Materials and Methods:

All studies were approved by the regional Ethical Review Board: Dnr M233-09, Dnr 2014/862 and Dnr 2016/2.

Paper I

Twenty-four Swedish native breed castrated male pigs with a mean weight of 42 kg (range 33 to 55 kg) were randomized into three equal groups (Tab. 2).

Group I (GI)

Intact animals anesthetized for 24 h receiving basic fluid supply and serving as controls.

Group II (GII)

Brain dead animals receiving basic fluid supply and in addition treated with the new pharmacological therapy.

Group III (GIII)

Brain dead animals receiving basic fluid supply.

| Group | n | Procedure | Basic fluid therapy | Treatment |
|-------|---|-------------|--------------------------|---------------------------|
| I | 8 | Controls | Ringer-Glucose 3 ml/kg/h | None |
| II | 8 | Decapitated | Ringer-Glucose 3 ml/kg/h | None |
| III | 8 | Decapitated | Ringer-Glucose 3 ml/kg/h | Pharmacological treatment |

All pigs were anesthetized, tracheotomized, connected to a ventilator and ventilated (volume controlled and pressure regulated) with a tidal volume of 8 ml/kg, positive end-expiratory pressure (PEEP) of 5 cm H₂O and breathing frequency 20/min and received basic fluid therapy with Ringer-Glucose 3 ml/kg body weight/h. The brain and brainstem death of the animals in groups II and III was accomplished by decapitation. All blood vessels in the neck were ligated. With careful hemostasis the

tissue was divided cranial to the catheters and the tracheotomy. Decapitation was completed by dividing the spinal column between C2–C3. Diathermia and surgical wax were used to stop all bleeding from the cut end of the spine. With a minimum of blood loss, this procedure was accomplished within the range of 45 to 60 min. The pharmacological treatment started after decapitation when the animals got hypotensive, i.e., about 30 min after the catecholamine storm. During a 24 h observation period they were followed with electrocardiography (ECG), measurement of cortisol, triiodothyronine (T3) thyroxine (T4), alanine amino transaminase (ALAT), adrenaline, noradrenaline, hemoglobin (Hb), creatinine, blood gases, actual base excess (ABE), renal blood flow, urine production, and arterial blood pressure. Experiments were terminated after 24 h of observation or when the mean aortic pressure was below 40 mmHg.

Paper II

Twenty-eight healthy Swedish domestic pigs (30–50 kg), with normal body temperature (38.5–39°C) were included in the study, randomized into three groups (Tab. 3).

| Group | n | Procedure | Basic fluid therapy | Treatment |
|-------|----|-------------|---------------------------|----------------------------|
| I | 6 | Decapitated | Krebs solution* 3 ml/kg/h | Forced fluid 25-45 ml/kg/h |
| II | 11 | Decapitated | Krebs solution 3 ml/kg/h | Pharmacological treatment |
| III | 11 | Controls | Krebs solution 3 ml/kg/h | None |

*Krebs solution (mmol/l): Na⁺ 144, K⁺ 4.6, Mg²⁺ 1.2, Ca²⁺ 1.5, Cl⁻ 129, HCO₃⁻ 24, H₂PO₄⁻ + HPO₄²⁻ 1.2, glucose (D+) 5.5. Pharmacological therapy see Table 1. Photo credit: Bozovic et al. Circulation stabilizing therapy and pulmonary high-resolution computed tomography in a porcine brain-dead model. *Acta Anaesthesiologica Scandinavica*, 2015, Wiley.

They were prepared as above and received basic fluid therapy with Krebs solution 3 ml/kg/h (the composition of Krebs solution is given in Table 3). Animals in group I (GI) and group II (GII) were decapitated to induce acute brain death in the same way as described above.

Group I (GI)

Brain dead animals receiving basic fluid supply and forced fluid therapy. When the aortic pressure had decreased to 60 mmHg forced fluid therapy with Krebs solution was started (25–45 ml/kg/h). The forced fluid therapy aimed to maintain the blood pressure above 60 mmHg, to ensure organ viability and to secure transportation to the radiology department for HRCT.

Group II (GII)

Brain dead animals receiving basic fluid supply and in addition treated with the new pharmacological therapy.

Group III (GIII)

Intact animals anesthetized for 24 h and serving as controls.

When the pigs in GI became unsustainable despite forced fluid therapy, the animals were ventilated with 100% oxygen for 10 min with 5 cm H₂O PEEP, and blood gases and arterial blood pressure were registered prior to HRCT. The pigs in GII and GIII were stable throughout the 24 h observation period and thereafter tested as above for blood gases and arterial blood pressure prior to HRCT.

HRCT

The animals were transported from the animal facility to the radiology department during the last hour of the 24 h observation period (GII and GIII) or when circulatory collapse became unsustainable (GI). HRCT was performed within 1 h after transport preparation start and with all animals positioned similar to humans in supine position and anterior legs fixed upwards and posteriorly minimizing artefacts from the shoulders (Fig. 1). Examination preparations were done under muscle relaxation and continuous ventilation, while actual image acquisition (10–15 s depending on lung size) was performed in full inspiration and apnea. Volumetric HRCT examinations were performed on a Brilliance 64 slice CT (Philips Medical Systems, Best, The Netherlands) with tube voltage 120 kV, collimation 64*0.625, high-resolution mode, filter kernel D (bone), reconstructed slice thickness 0.7–1.0 mm, slice increment 0.35 mm, and displayed radiation doses equivalent to human HRCT doses. To ensure reproducibility of HRCT images, four of the animals (two in GII and GIII, respectively) were examined with HRCT twice within 15 min. To assure comparable HRCT imaging findings prior and after artificial ventilation, two additional pigs were examined with an initial HRCT within the first hour of artificial ventilation in addition to the examination after 24 h.

Image evaluation

HRCT images were analyzed in consensus by two experienced chest radiologists (CSP, JV), blinded to clinical data, and using a clinical PACS workstation (Agfa Impax) with generally accepted window settings for lung parenchyma (center 500 HU and width 1500 HU). Scored HRCT parameters, listed in Table 4, were defined according to the Fleischner Society Glossary of Thoracic imaging (106). Percentage of total lung volume engaged with consolidations and ground-glass opacities (GGO) was calculated using two volume scores (Tab. 4 and Fig. 2).

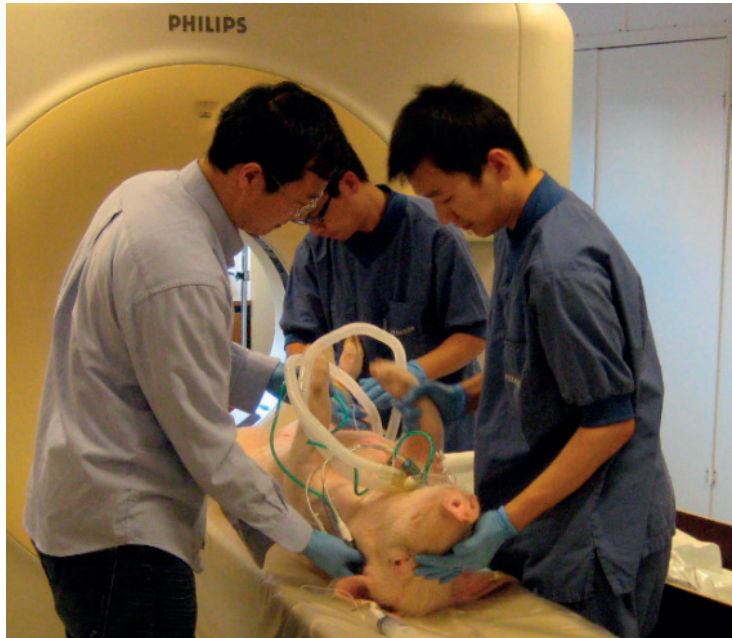

Figure 1. Appreciated and invaluable co-workers preparing a pig in general anesthesia for HRCT scanning after a 24 h observation period in spring 2010.

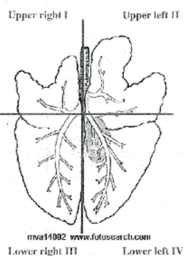
| Table 4. HRCT scoring parameters. | | |
|--|--|--------------------------|
| HRCT scoring parameters | Score extent | Appearance or severity |
| Consolidation (scored as % of lung calculated with two scores) | I: 1-100% (10% steps) II: ≤ 5, 6-25, 26-49, 50-75 or ≤ 75 | III- or well defined |
| Ground glass opacities (as above) | As above | III- or well defined |
| Ventrodorsal gradient of consolidation and GGO (whole lung) | Yes or no | Subtle, moderate, severe |
| Mosaicism | Yes or no | |
| Bronchial wall thickening | Yes or no | Subtle, moderate, severe |
| Centrilobular changes (n) | < 5, 5-10 or > 10 | |
| Fine nodular opacities (n) | < 5, 5-10 or > 10 | |
| Pericardial effusion | Yes or no | |
| Pleural effusion (whole pleura) | Yes or no | |

The lungs were divided into four quadrants using the carina as a landmark. HRCT was scored for each quadrant if not stated otherwise. Photo credit: Bozovic et al. Circulation stabilizing therapy and pulmonary high-resolution computed tomography in a porcine brain-dead model. *Acta Anaesthesiologica Scandinavica*, 2015, Wiley.

Image assessment was finalized with a consensus discussion and establishment of an overall conclusion defining the presence of three entities causing a filling-in of airspaces and thus a reduction of aerated lung with negative impact on respiratory function: (a) CT features consistent with pulmonary edema characterized as bilateral septal thickening with fluid accumulation and bilateral, usually symmetric GGO, without air-bronchogram but with a gravitational distribution/ ventrodorsal gradient, thereby mostly pronounced in the dependent parts (121, 122), (b) CT features not consistent with pulmonary edema but suggesting focal lung disease such as infection or organizing pneumonia, characterized by asymmetric dense and mostly sharply demarcated consolidations or ground-glass opacities (123, 124), (c) other pulmonary changes such as plate like atelectasis and scars. Based on the total extent, appearance, and severity of parenchymal changes seen on HRCT, the overall severity of pulmonary disease was graded using a 4-point scale: not present, mild, moderate, or severe.

Evaluation sheet - HRCT

Step 1. Division of the lung in four quadrants (right and left upper quadrant and right and left lower quadrant with carina as a dividing landmark between the upper and lower quadrants)



PIGLET nr/date: 25/1010/04/28
 SCOERD BY: CSP/SJK
 Första serien
 Carina skive

| | Quadrant | | | |
|---|----------|----|------|------|
| | I | II | III | IV |
| Step 2. Identification of areas of consolidation (0-100% by 10% steps) ≤ 5%: between 6-25%, between 26-49%, between 50-75% and >75% | 0 | 0 | 0 | 0 |
| Subsegmental Ss, Segmental Sg, Lobar L | | | | |
| Step 3. Identification of GGO 0 = no GGO 1 = involving ≤ 5% of the whole volume in the quadrant 2 = between 6-25% 3 = between 26-49% 4 = between 50-75% 5 = >75% | X | X | 2 | 2 |
| Areas of GGO (0-100% by 10% steps) 0 no GGO, 1 questionable, 2 definite but subtle, 3 moderate, 4 severe | | | <10% | <10% |

Evaluation sheet established: GB 2010 sept

| | | | | |
|---|---|---|---|---|
| Ss, S, I | | | | |
| Step 4. presence of a ventrodorsal gradient of GGO yes no | X | X | X | X |
| Step 5. Identification of mosaicism (Fleischner Society Glossary: "A patchwork of regions of differing attenuation that may represent patchy IID, obliterative small airway disease or occlusive vascular disease) Yes No | X | X | X | X |
| Step 6. Bronchial wall thickening Yes No | X | X | X | X |
| 1 = ++, +++ (subtle, moderate, severe) | | | | |
| Step 7. Centrilobular changes including tree in bud 0 = no TIB 1 = <5 2 = between 5-10 3 = >10 | X | X | X | X |
| Step 8. Identification of fine nodular opacities 0 = no nodules 1 = <5 2 = between 5-10 3 = >10 Aclinar Solid | X | X | X | X |
| Step 9. identification of pleural effusion (+, ++, +++/ subtle, moderate, severe) Yes No | | X | | |
| Step 10. Identification of pericardial effusion (+, ++, +++/ subtle, moderate, severe) Yes No | X | | | |

Comments: Scarring small S/II / linear
 not therapy related
 Good lung

Evaluation sheet established: GB 2010 sept

2

Figure 2. Evaluation sheet for HRCT findings used in paper II

Pathology samples

In terminating the experiments tissue samples were gathered from every lobe in both lungs in all animals in GI and five animals in G III. All tissue samples were prepared and colored in keeping with standard pathological praxis.

Paper III

Radiological examinations of 110 consecutive patients diagnosed with brain death at the neuro Intensive Care Unit (ICU) at Skåne University Hospital, Lund, Sweden, during 2007-2014 were included. Imaging studies performed during the hospitalization period were selected in the radiology information system (RIS) and retrieved in the Picture Archiving and Communication System (PACS), except for one chest CT that could not be retrieved and was excluded. Twenty-eight conventional coronary angiographies and 19 conventional cerebral angiographies were not further evaluated since the lungs were not included. Imaging and clinical reporting had been done at various hospitals, both at the authors' institution and at other hospitals in the surrounding catchment area. Examinations were classified as "donor" or "patient" depending on whether the patient was referred to imaging as potential organ donor or not. The local transplantation team provided information on eventual organ donation after the study reading was performed.

A questionnaire was designed in collaboration with transplantation surgeons. Clinical and donation relevant criteria were defined with respect to the limitations of the imaging modality. For chest radiographs it included image quality, catheters and devices, opacities, cardiac and vessel size, pleural effusion, pneumothorax and a final diagnostic interpretation of decompensation, pulmonary edema, infection, aspiration or other diagnosis. For CT it included all of the above and in addition tree-in-bud, air bronchogram, airway occlusion, bronchiectasis, parenchymal nodules, trauma, emphysema, pulmonary emboli, lymph nodes or tumor with the same diagnostic interpretation as above. Presence of findings was graded using a 4-point scale (yes, probably yes, probably no or no) and the extent on a 3-point scale (subtle, moderate or severe).

Image analysis

Catheters and devices were analyzed due to possible implications for the patient if misplaced. A good position of the **tracheal tube** was defined as an intrathoracic tip position more than 2 cm above the carina, the tip of a **central venous catheter** in the superior vena cava, and the side holes of the **nasogastric tube** needed to be located in the stomach, distal to the cardia.

Pulmonary opacities were defined according to the **Fleischner Society glossary of terms for thoracic imaging** (125).

Definitions and grading in chest radiography

Atelectasis was defined as increased opacity or parenchymal attenuation accompanied by volume loss.

Consolidation as increased parenchymal attenuation obscuring the margins of vessels and airway walls with or without an air-bronchogram without volume loss.

Ground glass opacity (GGO) as a hazy, increased opacity of the lung with indistinct bronchial and vascular margins.

The extent of opacities was graded as subtle if segmental, moderate if lobar and severe if transcending lobar borders.

Atelectasis in the left lower lobe, a common finding in supine patients due to compression of the lower lobe bronchus by the heart (126-128) was defined as increased opacities of the retrocardiac lung and loss of the left diaphragmatic silhouette. It was graded as subtle if less than one third of the left hemidiaphragm was obscured, moderate if up to half of the left hemidiaphragm was obscured or severe if more than half of the left diaphragmatic silhouette was obscured (129).

Decompensation was defined by vascular redistribution, enlargement of the heart and vessels, enlargement and loss of definition of hilar structures, septal lines (Kerley A and B), peribronchial and perivascular cuffing with widening and blurring of the margins and thickening of the interlobar fissures with subpleural fluid accumulation (130). It was graded subtle if there were heart enlargement, redistribution and some enlargement of the vessels, moderate if the enlargement of the vessels was obvious with enlargement and loss of definition of hilar structures with some septal lines and severe if there was also peribronchial and perivascular cuffing with widening and blurring of the margins and thickening of the interlobar fissures with subpleural fluid accumulation.

Pulmonary edema was defined as bilateral, usually symmetric parenchymal opacities with a central or basal distribution without air-bronchogram (121, 130, 131). It was graded subtle if there was a slight GGO engaging not more than one half of the lung volume, moderate if the opacification was obvious with GGO and some consolidation engaging not more than one half of the lung volume and otherwise severe.

Infectious lung diseases represent an extensive, heterogeneous term without a uniform but instead several imaging patterns. Bacterial pneumonia is the most common, defined as a single subpleural area of alveolar consolidation with blurred margins restricted to the area next to the fissures or segmental opacities affecting one or several segments or a lobe with or without air bronchogram (132, 133). They were graded as subtle if segmental, moderate if lobar and severe if transcending lobar borders

Aspiration was distinguished by the localization as patchy bronchopneumonic pattern most commonly involving the posterior segment of the upper and superior segments of the lower lobes (134). They were graded as subtle if segmental, moderate if lobar and severe if transcending lobar borders.

Emphysema. Chest radiography is insensitive for emphysema which indirectly presented with flattened diaphragm, irregular radiolucency and widely spread ribs (123).

Definitions and grading in Computed Tomography

Atelectasis and **consolidation** were defined and scored as above.

GGO was defined as a hazy, increased opacity of the lung with preserved bronchial and vascular margins, graded as above.

Atelectasis in the left lower lobe was defined as above but graded subtle if engaging up to one third, moderate if engaging half and severe if exceeding half of the lobe volume.

Decompensation and **pulmonary edema** was defined as bilateral septal thickening with fluid accumulation and bilateral, usually symmetric GGO without air-bronchogram but with a gravitational distribution thereby mostly pronounced in the dependent parts with or without cardiomegaly (121, 130, 131). They were graded subtle if only slight GGO was present with few thickened septa engaging less than half of the lung volume, moderate if there were GGO with some consolidation, a considerable septal thickening engaging less than half the lung volume with or without subtle pleural effusion and otherwise severe.

Infection and **aspiration** were defined as above with additional distinction of aspiration with findings of exudative bronchiolitis presented as a nodular pattern of tree-in-bud (134, 135). They were graded as subtle if segmental, moderate if lobar and severe if transcending lobar borders.

Granuloma was defined as a uniform calcification of a well circumscribed solitary pulmonary nodule (123, 136).

Intrapulmonary lymph node was defined as a round or angular nodule, less than 6mm in size, with a sharply defined border, situated below the level of the carina, not more than 4 cm from the nearest pleural face and with linear densities extending from the nodule (137, 138)

Emphysema was defined as focal areas or regions of low attenuation, usually without visible walls (125). It was graded subtle if engaging estimated 20%, moderate if engaging estimated 50% and severe if exceeding 50% of the lung volume.

Pulmonary embolism was defined as filling defect within an opacified pulmonary artery (139, 140).

All clinical reports were analyzed according to the questionnaire by two chest radiologists in consensus. Thereafter the images were analyzed using the same questionnaire in the same mode. The study review was, however, limited by the

incomplete visualization of the lungs in some examinations. The results from the clinical report and the study review were compared for discrepancies in frequency and scoring of the evaluated findings for each modality separately. Differences were graded as substantial and of clinical importance if the new interpretation of findings would have a) led to change of treatment b) triggered further examination including bronchoscopy or c) were of importance for donor evaluation in general (Tab. 5). Most CT examinations were performed early during the course of illness, with a time interval of 2.5 h to 11 days between the CT examination and the last chest radiograph; thus it was not possible to correlate the imaging findings between modalities.

Table 5. Major differences between clinical reports and study review for chest radiography.

| Finding | Clinical report | Study review | Impact on management |
|--|-----------------|--------------------|-------------------------------|
| Opacities | No | Moderate or severe | Bronchoscopy |
| Decompensation | No | Moderate or severe | Treatment |
| Edema | No | Yes | Treatment |
| Pleural effusion | No | Moderate or severe | Observation or drainage |
| Infection or aspiration | No | Yes | Treatment and/or bronchoscopy |
| Pneumothorax | Yes | No | No observation or drainage |
| | No | Yes | Observation or drainage |
| Extra-pulmonary disease | Yes | No | May be suitable for donation |
| | No | Yes | May compromise donation |
| Earlier surgery e.g. wedge resection | Yes | No | May be suitable for donation |
| | No | Yes | May compromise donation |
| Emphysema, systemic disease, airway plugging, bronchiectasis, nodules, tumor or emboli | Yes | No | May be suitable for donation |
| | No | Yes | May compromise donation |
| Trauma injury | Yes | No | May be suitable for donation |
| | No | Yes | May compromise donation |

The differences were defined together with a transplant surgeon. Note: a negative finding in the clinical report versus a positive, moderate or severe finding at study review was scored as substantial difference, while no findings in the clinical report versus a subtle positive finding at the study review was scored as minor difference for opacities, cardiac decompensation and pleural effusion. For the other entities a finding in the clinical report versus no findings at study review was scored as substantial and vice versa, but a different interpretation of an opacification as infection or aspiration in the clinical report and study review, respectively was not considered as substantial difference. Photo credit: Bozovic et al. Imaging of the lungs in organ donors and its clinical relevance – a retrospective analysis. Journal of Thoracic Imaging. 2016, Wolters Kluwer.

Paper IV

Actual lung donors from the previous study were included. The information on organ donation was provided by the local transplantation team.

Donor data

Lung donors were identified from a previous study (141). Raw data on imaging, imaging reporting and imaging scoring of the mandatory bedside chest radiograph for lung evaluation prior to proceeding to donation were obtained with the same questionnaire for scoring the clinical reports and study review with donation relevant criteria. For scoring, imaging terms were defined according to the Fleischner Society glossary of terms for thoracic imaging (125). Opacities, decompensation, pulmonary edema, infectious lung diseases, and aspiration were scored as 0 if absent, 1 if mild, 2 if moderate and 3 if severe. First the clinical reports and then the bedside chest radiographs were analysed by two chest radiologists in consensus, filling in the questionnaires during the same session, without knowledge about possible organ donation. The blood gas analysis for donor evaluation was retrieved from the medical records by the local transplantation team.

Recipient data

Information about the 38 anonymized recipients was gathered from organisations providing patient-oriented allocation and cross-border exchange of deceased donor organs with follow-up registers for the geographical areas of interest, hence Scandiatransplant for Scandinavia and Eurotransplant for Northern Europe. Collected data included 30-day and 1-year survival, hospitalization time due to transplantation, operative and post-operative complications and early complications such as primary graft dysfunction (PGD) or infection and percentage of predicted normal value of forced expiratory volume in 1 s - FEV₁% at 1-year follow-up. FEV₁% ≤ 80% of predicted FEV₁% was considered as lung function impairment (142, 143).

Data analysis

Donor age, number and scoring of pulmonary findings at clinical image reading and study review, a radiographic diagnosis of aspiration or infection, arterial blood gas analysis for PaO₂ measured after 5 min on 100% O₂ ventilation with PEEP of 5 cm H₂O, pH and location of the nasogastric tube were compared with the outcome parameters 30-day and 1-year survival, early complications, infections, duration of hospitalization time due to transplantation and FEV₁% at the 1-year follow-up.

Statistical evaluation

P-values <0.05 were regarded as statistically significant.

Paper I

Student's *t*-test for paired observations was used. Results are presented as mean \pm standard error of the mean.

Paper II

Based on the previous study the number of included animals was minimized, Six in GI with high expected mortality and 11 each in the other two groups (GII and GIII) were found sufficient for statistical comparisons. Mann–Whitney U-test was used for evaluation of group differences regarding clinical parameters. Fischer's exact test for count data was used for analysis of correlation of clinical and HRCT findings. Asymptotic linear by-linear association test was used to establish group association of HRCT findings.

Paper III

Quantitative data were expressed as frequency and percentage. Differences in detection of imaging findings in the clinical reports and the study reviews were analyzed by chi-square test. Calculations were performed using the statistical package R (144). Unweighted Cohen's kappa was used for calculation of agreement between original reading and study review using an online calculator (145).

Paper IV

Two-tailed Pearson correlations were performed for possible significant correlations between donor age, imaging findings, blood gas analysis and recipient outcome. All analyses were performed with SPSS version 23.

Results

Paper I

Group I (intact controls)

All pigs were circulatory stable throughout the 24 h observation period, with a mean aortic pressure of 80 mmHg (Fig. 4). Laboratory data are shown in the upper part of Table 7.

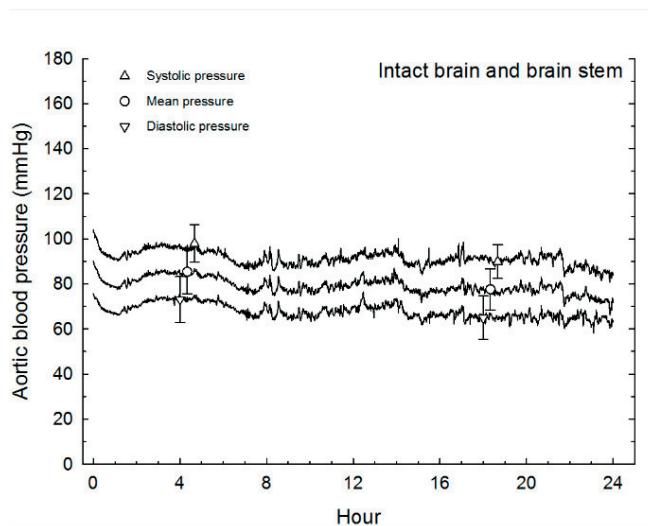


Figure 4. Aortic pressure in 8 animals with intact brain and brainstem with curves showing the systolic (top) mean (middle) and diastolic (bottom) pressure, \pm standard error of mean. Photo credit: Steen et al. Pharmacological normalization of circulation after acute brain death. *Acta Anaesthesiologica Scandinavica*, 2012, Wiley.

Group II (brain dead)

During the time it took to divide all structures in the neck except the spinal column (45–60 min), all animals were circulatory stable with a slight increase in aortic pressure (Fig. 5). Immediately after the spinal column was divided, the blood pressure started to increase and it reached peak values after 2 to 3 min, and after a

further 2 to 3 min, it had returned to basal values (Fig. 5). Experiments were terminated when the mean aortic pressure was below 40 mmHg, the median time to the aortic pressure that was less than 40 mmHg was 9:09 h, range 5:50 to 22:01.

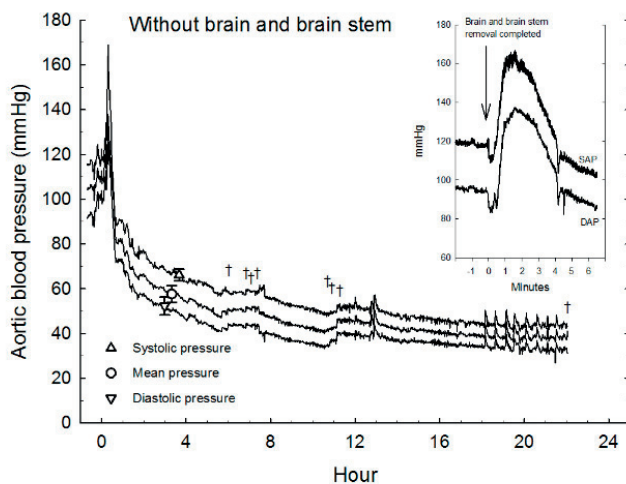


Figure 5. Aortic blood pressure in 8 decapitated animals without pharmacological treatment. † indicates when the mean aortic blood pressure was below 40 mm Hg and the actual experiment was suspended. ± standard error of mean. Inset shows the aortic pressure in one animal during the catecholamine storm. DAP: diastolic aortic pressure. SAP: systolic aortic pressure. Photo credit: Steen et al. Pharmacological normalization of circulation after acute brain death. *Acta Anaesthesiologica Scandinavica*, 2012, Wiley.

The mean concentrations of noradrenaline and adrenaline after anesthesia, but before the neck surgery (base values), and at the peak of the blood pressure rise are shown in Table 6. The noradrenaline concentration increased by a factor of 79 and adrenaline by a factor of 298. The blood pressure increased to values between 160–180 mmHg (Fig. 5). After the catecholamine storm, the blood pressure decreased gradually, and when the mean aortic pressure was less than 40 mmHg, as indicated for each pig with a cross in Figure 5, the experiment was terminated.

Table 6. Sympathetic storm after brain and brainstem death.

| | Base | Peak | Increase (Times) |
|--------------------|----------|-----------------|------------------|
| Noradrenaline (pM) | 600 ± 73 | 47.633 ± 27.190 | 79 |
| Adrenaline (pM) | 115 ± 16 | 34.236 ± 15.860 | 298 |

Photo credit: Steen et al. Pharmacological normalization of circulation after acute brain death. *Acta Anaesthesiologica Scandinavica*, 2012, Wiley.

There was no urine production when the aortic pressure had dropped below 60 mmHg. During the catecholamine storm, the QT-interval shortened and the heart rate increased to 170–190. No significant shift of the ST segment or inversions of the T-wave were seen. After decapitation, the cortisol values decreased from 222 ± 25 nM (base value) to 6.7 ± 1.9 nM at 12 h ($P < 0.001$) (Fig. 6). Triiodothyronine - T3 decreased from a base value of 4.1 ± 0.4 pM to 1.6 ± 0.2 pM at 12 h ($P < 0.01$) and Thyroxine - T4 decreased from 9.0 ± 0.9 pM to 4.8 ± 0.5 pM at 12 h ($P < 0.01$).

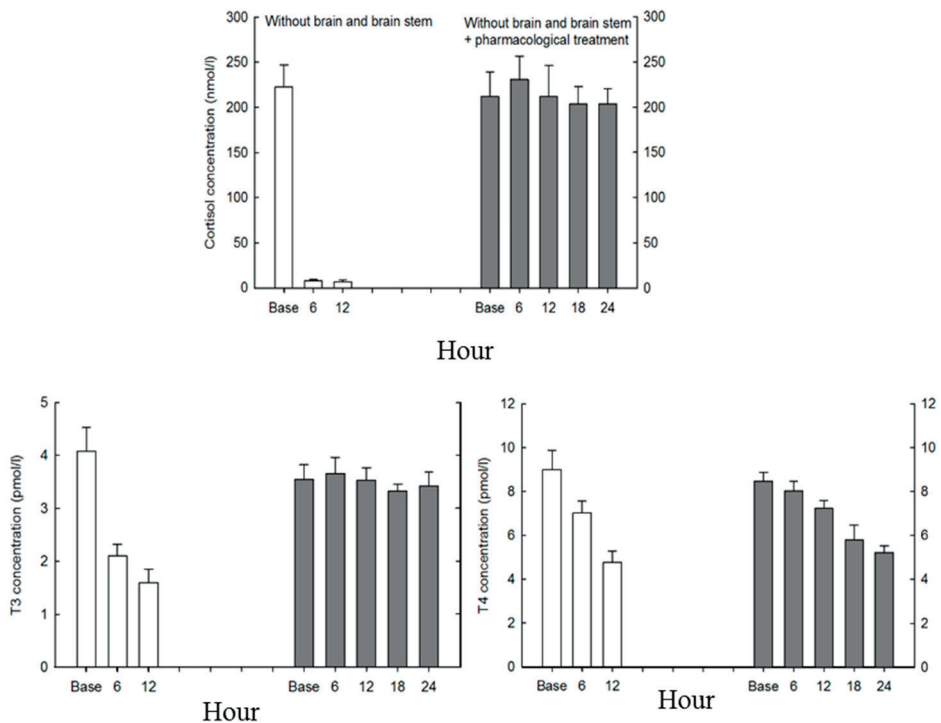


Figure 6. Concentrations of cortisol (top), triiodothyronine (T3 (lower left) and thyroxine (T4) (lower right) without (white bars) and with pharmacological treatment (shaded bars). Photo credit: Steen et al. Pharmacological normalization of circulation after acute brain death. Acta Anaesthesiologica Scandinavica, 2012, Wiley.

Group III (brain dead with pharmacological treatment)

All animals were circulatory stable throughout the 24 h observation period (Fig. 7).

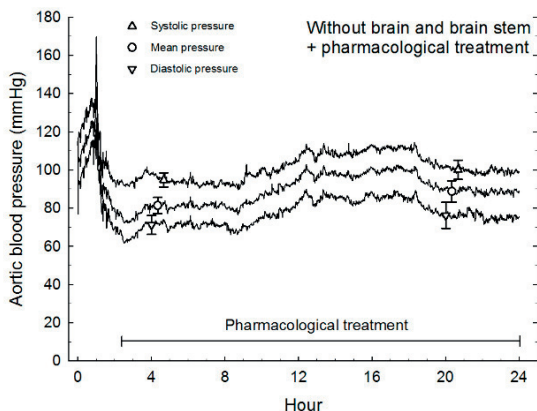


Figure 7. Aortic pressure in decapitated animals treated pharmacologically. $n = 8$; \pm standard error of mean. Photo credit: Steen et al. Pharmacological normalization of circulation after acute brain death. *Acta Anaesthesiologica Scandinavica*, 2012, Wiley.

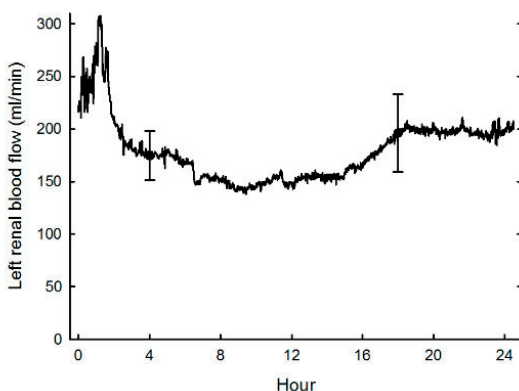


Figure 8. Blood flow in the left renal artery in decapitated pigs receiving pharmacological treatment. $n = 4$ \pm standard error of mean. Photo credit: Steen et al. Pharmacological normalization of circulation after acute brain death. *Acta Anaesthesiologica Scandinavica*, 2012, Wiley.

The concentrations of cortisol, T3 and T4 are shown in Figure 6. The renal blood flow was normal (Fig. 8), as was the 24 h value of creatinine, and the liver function enzyme alanine amino transaminase, ALAT was $1.1 \pm 0.0 \mu\text{kat/l}$ at base and $0.7 \pm 0.0 \mu\text{kat/l}$ at 24 h (Tab. 7).

The 24 h values of the blood gases did not differ significantly from the base values (Tab. 7). The QT-interval shortened during the catecholamine storm, but no significant shift of the ST segment or inversions of the T-wave were seen neither during the catecholamine storm nor up to the 24 h observation period with pharmacological treatment. Compared with group I, there was no statistically significant difference (area under curve) in mean aortic pressure after the catecholamine storm.

| Table 7. Blood gases, temperature and urine production for Group I and III | | |
|--|-------------|-------------|
| Group | Base | 24 h |
| I (n=8), Controls | | |
| PaO ₂ (kPa) | 13.5 ± 0.5 | 13.2 ± 1.1 |
| PaCO ₂ (kPa) | 5.1 ± 0.3 | 5.5 ± 0.4 |
| pH | 7.50 ± 0.02 | 7.45 ± 0.02 |
| ABE (mM) | 5.8 ± 0.6 | 4.4 ± 1.1 |
| Hb (g/l) | 125 ± 3 | 133 ± 9 |
| Temperature (°C) | 37.5 ± 0.4 | 37.3 ± 1.3 |
| Urine production (ml) | 0 | 3025 ± 448 |
| III (n=8), Brain-dead with treatment | | |
| PaO ₂ (kPa) | 13.5 ± 0.4 | 12.5 ± 1.0 |
| PaCO ₂ (kPa) | 4.8 ± 0.2 | 4.8 ± 0.3 |
| pH | 7.41 ± 0.04 | 7.45 ± 0.02 |
| ABE (mM) | -1.3 ± 2.0 | 1.5 ± 0.9 |
| Hb (g/l) | 127 ± 3 | 111 ± 9 |
| Temperature (°C) | 37.3 ± 0.3 | 34.9 ± 0.3 |
| Urine production (ml) | 0 | 2406 ± 229 |
| Creatinine | 134 ± 15 | 115 ± 12 |
| ALAT μ kat/l | 1.1 ± 0.0 | 0.7 ± 0.0 |

PaO₂ arterial oxygen tension, PaCO₂ arterial carbon dioxide tension, ABE actual base excess, Hb hemoglobin, ALAT alanine amino transaminase; The blood gases [fraction of inspired oxygen (FiO₂) = 0.21] were corrected according to the temperature. Photo credit: Steen et al. Pharmacological normalization of circulation after acute brain death. *Acta Anaesthesiologica Scandinavica*, 2012, Wiley.

Paper II

Group I (brain dead treated with forced fluid therapy)

Acute brain death treated with basic fluid therapy plus forced infusion of electrolyte solution (GI) could not stabilize aortic pressure (Fig. 9A and Fig.10) and final arterial oxygen tension/fraction of inspired oxygen ratio (PaO₂/FiO₂) was significantly reduced as shown in Tables 8A and B.

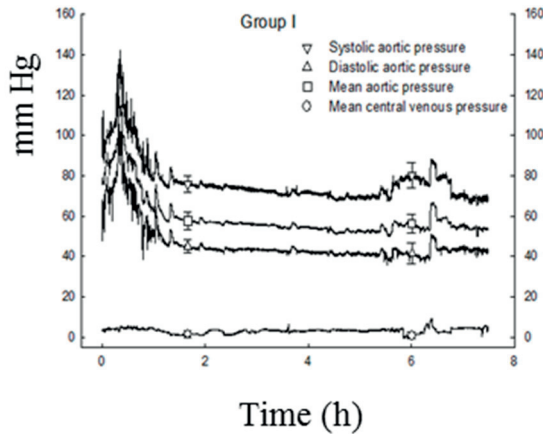


Figure 9 A. Aortic and central venous blood pressure. Diastolic, mean and systolic aortic and venous blood pressure (mmHg) curves over time (h) The curves represent mean values and standard error of the mean is shown or hidden within the symbols. Photo credit: Bozovic et al. Circulation stabilizing therapy and pulmonary high-resolution computed tomography in a porcine brain-dead model. *Acta Anaesthesiologica Scandinavica*, 2015, Wiley.

Group II (brain dead treated with pharmacological treatment)

Brain-dead pigs treated with basic fluid supply and in addition pharmacological therapy were circulatory stable throughout the 24 h observation period (Fig. 9B and Fig.10). There were no significant differences in arterial blood pressure or $\text{PaO}_2/\text{FiO}_2$ as compared to intact controls (GIII) (Tab. 8A and B).

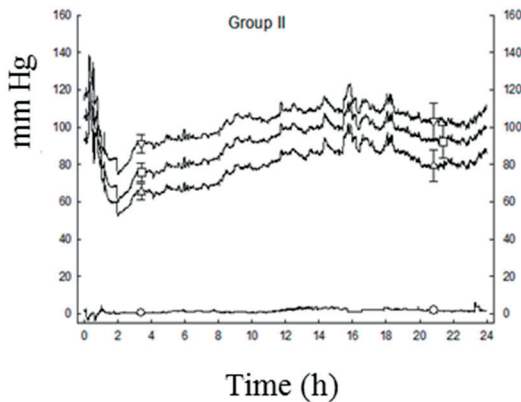


Figure 9 B. Aortic and central venous blood pressure. Diastolic, mean and systolic aortic and venous blood pressure (mmHg) curves over time (h) The curves represent mean values and standard error of the mean is shown or hidden within the symbols. Photo credit: Bozovic et al. Circulation stabilizing therapy and pulmonary high-resolution computed tomography in a porcine brain-dead model. *Acta Anaesthesiologica Scandinavica*, 2015, Wiley.

Group III (intact controls)

The intact controls treated with basic fluid supply were stable throughout the 24 h observation period (Fig. 9C, Tab. 8A and B and Fig. 10).

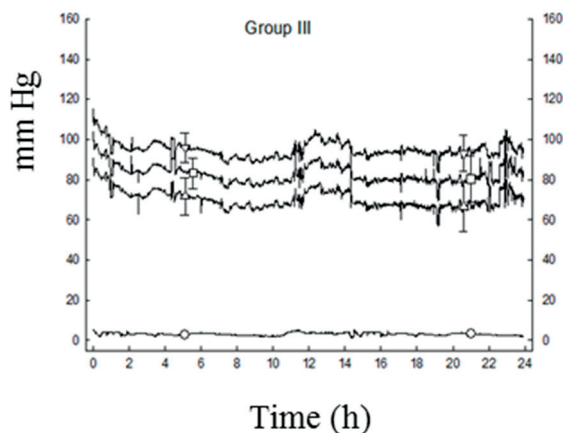


Figure 9 C. Aortic and central venous blood pressure. Diastolic, mean and systolic aortic and venous blood pressure (mmHg) curves over time (h) The curves represent mean values and standard error of the mean is shown or hidden within the symbols. Photo credit: Bozovic et al. Circulation stabilizing therapy and pulmonary high-resolution computed tomography in a porcine brain-dead model. Acta Anaesthesiologica Scandinavica, 2015, Wiley.

| Table 8 A. Group specific data for Group I, II and III. | | | |
|---|------------------------|------------------|-------------------|
| Clinical parameters | G I (n=6) | G II (n=9)* | G III (n=8)* |
| | Median / Q1; Q3; range | | |
| Final mean aortic BP (mmHg) | 55/49;61; 43-65 | 82/79;138;58-144 | 97/86;107;52-118 |
| Final systolic aortic BP (mmHg) | 83/67; 88; 62-96 | 88/86;147;82-148 | 108/96;119;80-127 |
| Final diastolic aortic BP (mmHg) | 41/40; 41; 28-49 | 78/66;118;43-140 | 86/76;96;50-110 |
| Initial PaO ₂ /Fio ₂ (kPa) | 50/47;57; 31-59 | 63/57;66;43-70 | 69/63;72;53-81 |
| Final PaO ₂ /Fio ₂ (kPa) | 29/26; 40; 17-76 | 72/64;76;53-91 | 66/55;78;43-90 |
| Initial hematocrit (%) | 34/33; 36; 30-42 | 38/35;42;34-44 | 39/36;41;28-48 |
| Final hematocrit (%) | 22/15; 26; 11-39 | 31/29;33;26-42 | 38/30;30;46;23-51 |

BP blood pressure; PaO₂/Fio₂ arterial oxygen tension/fractional inspired oxygen ratio; * in GII and GIII 2 respectively 3 pigs were not statistically evaluated for clinical parameters due to technical failure of the continuous data storage during the experiment. Photo credit: Bozovic et al. Circulation stabilizing therapy and pulmonary high-resolution computed tomography in a porcine brain-dead model. Acta Anaesthesiologica Scandinavica, 2015, Wiley.

| Table 8 B. Statistical evaluation for group specific data from Table 7A. | | |
|--|-----------------|------------------|
| Clinical parameters | G I versus G II | G I versus G III |
| Final mean aortic BP (mmHg) | p=0.003 | p=0.008 |
| Final systolic aortic BP (mmHg) | p=0.049 | p=0.014 |
| Final diastolic aortic BP (mmHg) | p<0.001 | p<0.001 |
| Initial PaO ₂ /Fio ₂ (kPa) | p=0.05 | p=0.008 |
| Final PaO ₂ /Fio ₂ (kPa) | p=0.01 | p=0.015 |
| Initial hematocrit (%) | p=0.1 | p=0.2 |
| Final hematocrit (%) | p=0.08 | p=0.02 |

The significant values are highlighted by shadowing.

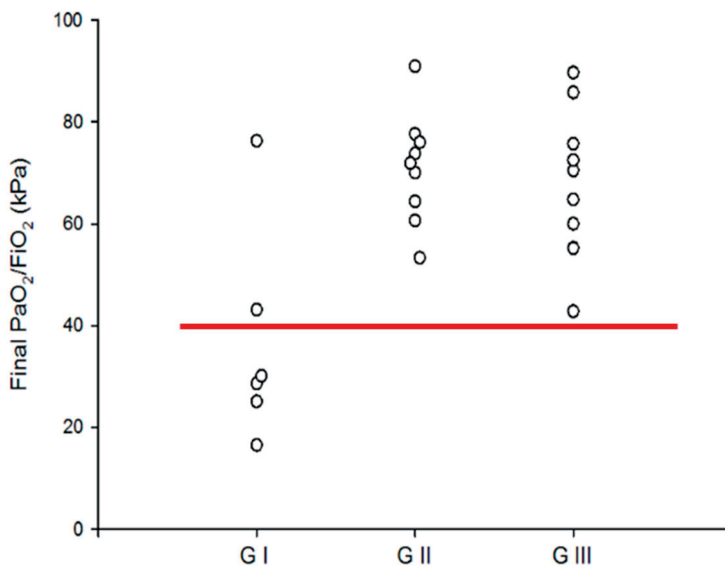


Figure 10. A scatter plot showing the values of the final PaO₂/Fio₂ (kPa) for each animal in all groups. Due to technical failure of the continuous data storage during the experiment, data is missing for one and two animals in G II and G III, treated with pharmacological therapy and controls respectively. Note the very similar distribution in G II and G III with all individuals above 40 mm kPa (red line), the limit of acceptance for donation in opposition to G I, treated with forced fluid therapy.

HRCT

All HRCT examinations were diagnostic and of good quality. CT features consistent with pulmonary edema and focal lung disease/ infection were the main findings revealed by HRCT (Tab. 9).

Table 9. Pulmonary edema and infection given as number of pigs featuring these pulmonary diseases.

| Group | CT features of edema (n of pigs) | | | | CT features of infections (n of pigs) | | | |
|-----------|----------------------------------|----------|----------|--------|---------------------------------------|----------|----------|--------|
| | Occurrence | Severity | | | Occurrence | Severity | | |
| | | Mild | Moderate | Severe | | Mild | Moderate | Severe |
| G I (6) | 5 | 0 | 2 | 3 | 3 | 0 | 2 | 1 |
| G II (11) | 2 | 2 | 0 | 0 | 6 | 4 | 2 | 0 |
| GIII (11) | 0 | 0 | 0 | 0 | 7 | 2 | 4 | 1 |

Photo credit: Bozovic et al. Circulation stabilizing therapy and pulmonary high-resolution computed tomography in a porcine brain-dead model. *Acta Anaesthesiologica Scandinavica*, 2015, Wiley.

Complete detailed HRCT findings are listed in Tables 10A and B. Pulmonary edema was significantly more common in GI (5/6) compared to GIII (0/11) ($P = 0.001$) and compared to brain-dead animals with additional pharmacological treatment (GII; 2/11) ($P = 0.035$). Furthermore, pulmonary edema was more severe in affected animals in GI compared to animals with additional pharmacological treatment (GII), $P = 0.001$, the latter with only two cases of mild edema. Focal lung disease was seen in 16 out of 28 animals (57%) (Tab. 10B). Occurrence ($p > 0.6$) and severity ($p > 0.25$) of infection was not related to group affiliation. Coexistence of GGO, ill-defined consolidations, and a ventrodorsal gradient were seen in all seven (100%) animals with edema. Only one further animal (GIII) showed coexistence of GGO, consolidation, and ventrodorsal gradient; however, the consolidations in this case were well-defined and asymmetric, not consistent with edema but infection. Final $\text{PaO}_2/\text{FiO}_2$ was significantly higher in animals without edema compared with animals with edema ($P = 0.05$) and especially compared with animals with moderate or severe edema ($P = 0.03$). No statistical difference in final $\text{PaO}_2/\text{FiO}_2$ was found for animals with and without focal lung disease. The repeated examination after 15 min in four animals showed no differences in image appearance. HRCT in the two additional pigs examined within the first hour and after 24 h of artificial ventilation showed comparable overall imaging findings between the two examinations except for a sub-segmental atelectasis developed in one pig between the two scans. Examples of typical imaging findings as well as images of repeated examinations in one animal after 1 and 24 h respectively are illustrated in Figure 11.

| Table 10 A. HRCT evaluation results. | | | | | | | | |
|--------------------------------------|---|---------|-------|--|----------|----------|--------|------------------------------|
| Pig | Consolidation (n _{quad} ; % of lung vol) | | | GGO (n _{quad} ; % of lung vol) | | | | Coexist (n _{quad}) |
| | Extent | Defined | | Extent | Severity | | | |
| | | Ill | Well | | Subtle | Moderate | Severe | |
| GI | | | | | | | | |
| 1 | 4; 21 | 3; 16 | 1; 5 | 3; 11 | 0 | 3; 11 | 0 | 3 |
| 2 | 3; 9 | 2; 4 | 1; 5 | 2; 4 | 0 | 2; 4 | 0 | 2 |
| 3 | 4;10 | 0 | 4;10 | 1; 1 | 0 | 1; 1 | 0 | 1 |
| 4 | 3; 30 | 1; 3 | 2; 28 | 3; 55 | 1; 10 | 1; 23 | 1;23 | 2 |
| 5 | 4; 29 | 4; 29 | 1;10 | 2; 30 | 0 | 2; 30 | 0 | 2 |
| 6 | 3; 25 | 1; 3 | 2; 23 | 2; 45 | 2; 45 | 0 | 0 | 2 |
| GII | | | | | | | | |
| 1 | 2; 3 | 2; 3 | 0; 0 | 0 | 0 | 0 | 0 | 0 |
| 2 | 0 | 0 | 0 | 2; 2.5 | 2; 3 | 0 | 0 | 0 |
| 3 | 1; 1 | 1; 1 | 0 | 3; 21 | 1; 1 | 2; 20 | 0 | 1 |
| 4 | 1; 1 | 1; 1 | 0 | 0 | 0 | 0 | 0 | 0 |
| 5 | 0 | 0 | 0 | 0 | 0 | 0 | 0 | 0 |
| 6 | 0 | 0 | 0 | 0 | 0 | 0 | 0 | 0 |
| 7 | 0 | 0 | 0 | 3; 4 | 2; 2 | 1; 1 | 0 | 0 |
| 8 | 1; 1 | 0 | 1; 1 | 2; 8 | 1; 5 | 1; 3 | 0 | 1 |
| 9 | 0 | 0 | 0 | 0 | 0 | 0 | 0 | 0 |
| 10 | 0 | 0 | 0 | 2; 3 | 2; 3 | 0 | 0 | 0 |
| 11 | 4; 5 | 2; 3 | 2; 3 | 4; 38 | 0 | 4; 38 | 0 | 4 |
| GIII | | | | | | | | |
| 1 | 4; 11 | 0 | 4; 11 | 0 | 0 | 0 | 0 | 0 |
| 2 | 3; 11 | 0 | 3; 11 | 2; 5 | 0 | 2; 5 | 0 | 0 |
| 3 | 2; 8 | 1; 3 | 1; 5 | 0 | 0 | 0 | 0 | 2 |
| 4 | 0 | 0 | 0 | 1; 1 | 1; 1 | 0 | 0 | 0 |
| 5 | 2; 3 | 0 | 2; 3 | 2; 3 | 1; 1 | 1; 1 | 0 | 0 |
| 6 | 0 | 0 | 0 | 0 | 0 | 0 | 0 | 2 |
| 7 | 1; 1 | 0 | 1; 1 | 2; 30 | 2; 30 | 0 | 0 | 0 |
| 8 | 0 | 0 | 0 | 1; 1 | 1; 1 | 0 | 0 | 1 |
| 9 | 1; 3 | 0 | 1; 3 | 0 | 0 | 0 | 0 | 0 |
| 10 | 3; 5 | 2; 4 | 1; 1 | 4; 20 | 2; 8 | 2; 13 | 0 | 0 |
| 11 | 2; 3 | 0 | 2; 3 | 1; 3 | 0 | 1; 3 | 0 | 3 |

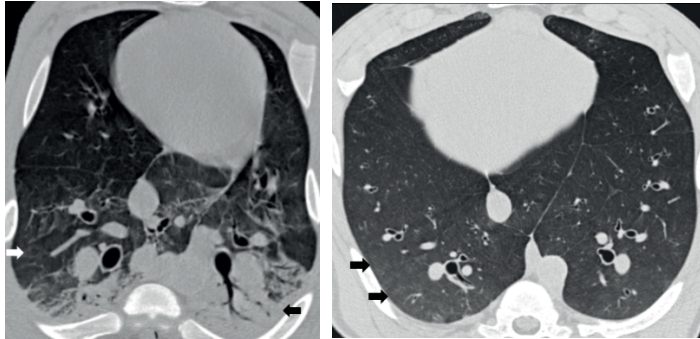
Photo credit: Bozovic et al. Circulation stabilizing therapy and pulmonary high-resolution computed tomography in a porcine brain-dead model. *Acta Anaesthesiologica Scandinavica*, 2015, Wiley.

Table 10 B. HRCT evaluation results.

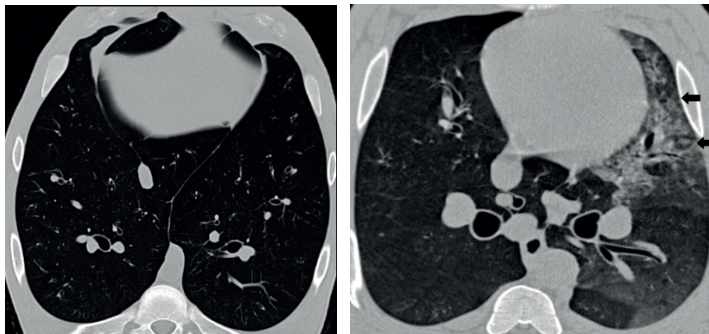
| Pig | Ventrodorsal gradient | Effusion | Mosaicism | Infection | Edema |
|-------------|-----------------------|--------------------|-----------|-----------|----------|
| GI | | | | | |
| 1 | 2 | No | 0 | No | Severe |
| 2 | 2 | No | 0 | No | Moderate |
| 3 | 0 | No | 4 | Severe | No |
| 4 | 3 | No | 0 | Moderate | Moderate |
| 5 | 4 | Yes ^a | 0 | No | Severe |
| 6 | 2 | No | 0 | Moderate | Severe |
| GII | | | | | |
| 1 | 2 | No | 0 | Mild | No |
| 2 | 0 | No | 0 | No | No |
| 3 | 3 | No | 3 | Moderate | Mild |
| 4 | 2 | No | 0 | No | No |
| 5 | 0 | No | 0 | No | No |
| 6 | 0 | No | 0 | No | No |
| 7 | 0 | No | 4 | Mild | No |
| 8 | 0 | No | 2 | Mild | No |
| 9 | 0 | No | 0 | No | No |
| 10 | 0 | No | 0 | Mild | No |
| 11 | 2 | No | 0 | Moderate | Mild |
| GIII | | | | | |
| 1 | 0 | No | 1 | Severe | No |
| 2 | 1 | No | 0 | Moderate | No |
| 3 | 0 | Yes ^a | 0 | Moderate | No |
| 4 | 0 | Yes ^{a,b} | 0 | No | No |
| 5 | 2 | No | 0 | No | No |
| 6 | 0 | No | 0 | No | No |
| 7 | 2 | No | 0 | Mild | No |
| 8 | 0 | No | 0 | No | No |
| 9 | 0 | No | 0 | Mild | No |
| 10 | 0 | No | 4 | Moderate | No |
| 11 | 0 | No | 0 | Moderate | No |

^a Pleural effusion, ^b Pericardial effusion.

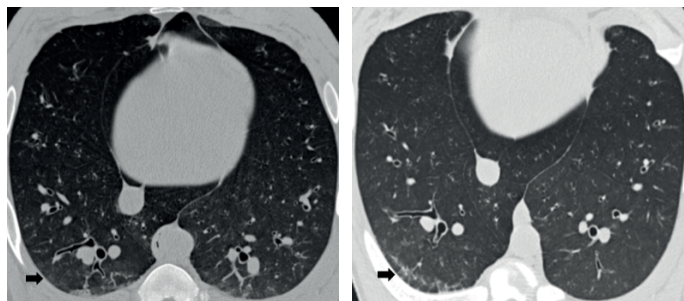
Figure 11. HRCT findings in five pigs with different treatment. All images are from the basal parts of the lungs with the diaphragm appearing in the central part. Photo credit Bozovic et al. Circulation stabilizing therapy and pulmonary high-resolution computed tomography in a porcine brain-dead model. *Acta Anaesthesiologica Scandinavica*, 2015, Wiley.



Left - Severe pulmonary edema in a brain dead animal treated with forced fluid therapy (GI) showing increased density with GGO (white arrow) and consolidation (black arrow) and a ventrodorsal gradient meaning increasing severity of pulmonary changes from the anterior throughout the posterior parts of the lung. Right - Mild pulmonary edema in a brain dead animal treated with the new pharmacological therapy (GII) showing increased density with GGO (black arrow) and a less pronounced ventrodorsal gradient compared to the previous one.



Left - Normal finding in a brain dead animal treated with the new pharmacological therapy (GII). Right - A non brain dead control (GIII) showing increased density in the left upper and lower lobe with foremost GGO (black arrows) in keeping with infection.



Images of an additional non brain dead animal after 1-h (left) and 24 h (right) of ventilation. The images show comparable findings with subtle hyposstatic changes in the dependant parts (black arrow) appearing after 24 h of ventilation. Due to minor differences in the positioning of the animal the image to the right is slightly more angled.

Pathological evaluation

Tissue samples from two animals in G I were initially analyzed. The preliminary findings were unspecific and suggested chronic inflammation and indirect edema. In collaboration with the pathologist we realized that the limited tissue sample we collected could not reliably be connected to an exact spot in the images and furthermore would not be sufficient for evaluation of pulmonary edema, our main aim. The presence of edema could only indirectly be detected by findings such as thickened interlobular septa, red blood cells in the alveolar capillary etc. The method of choice for that purpose would have been to weight the lungs upon sacrifice and preserve them without dehydrating them. Hence we did not investigate the pathology further but used the prepared tissue samples to acquaint ourselves with the porcine lung anatomy. Although similar there are anatomical differences between them. Some are obvious at first glance such as the bronchi of the upper right lobe coming directly from trachea in pigs. Some are less obvious e.g. differences in size between the bronchi and the accompanying artery opposed to humans where the size is similar representing an important landmark in diagnostic imaging as shown in Figure 12.

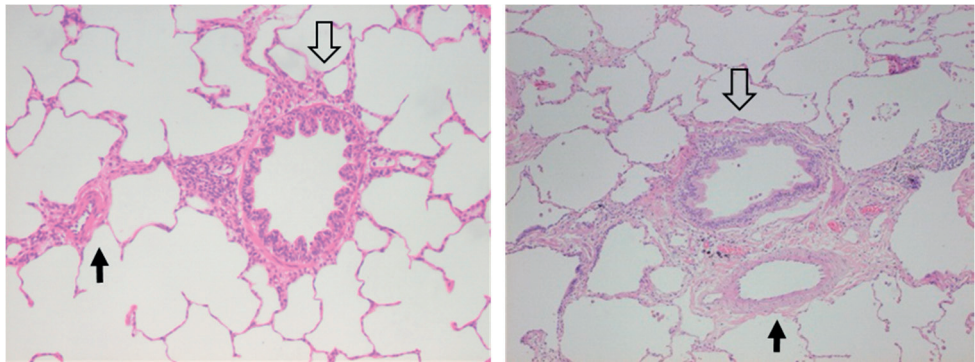


Figure 12. Tissue samples highlighting the difference in the relation between airways (empty arrows) and adjacent arteries (black arrows). in a normal porcine (left) and human (right) lung. In porcine the airway is comprehensively bigger compared to the smaller, collapsed adjacent artery. The cartilage is also thicker compared to humans. In humans the airway and adjacent collapsed artery are more similar in size. Photos credit: Courtesy of Nastaran Monsef (left) and Hans Brunnström (right).

Paper III

In total, 110 consecutive potential organ donors were included in the evaluation, 47 male and 63 female (median age 57 years, range 3-86). Ten were older than 70 years (the age limit for lung donation). The included imaging studies were 136 bedside chest radiographs and 42 CT examinations (Tab. 11). With very few exceptions they were of good diagnostic quality.

| Table 11. Overview of radiologic findings at study review in 136 radiographic and 42 CT examinations. | | | | | |
|---|-------------------|---------------------------|----------------------------|-------------------|-----------|
| | Chest radiography | Chest CT +/- abdominal CT | Head & neck CT angiography | Cervical spine CT | Other CT* |
| Patients (n) | 93 | 13 | 17 | 8 | 4 |
| Examinations (n) | 136 | 13 | 17 | 8 | 4 |
| Findings | | | | | |
| Normal | 17 | 1 | 4 | 5 | 0 |
| Incorrect tubes | 54 | 5 | 1 | 1 | 1 |
| Decompensation | 60 | 0 | | | |
| Edema | 25 | 0 | 2 | | 1** |
| Aspiration or infection | 29 | 4 | 1 | 3 | 0 |
| Atelectasis | 77 | 11 | 3 | | 2 |
| Airways thickened | | 0 | 1 | | 1 |
| Airways occlusion | | 0 | 4 | | 2 |
| Trauma injury | 0 | 4 | | | |
| Pneumothorax | | 3 | | | |
| Pleural effusion | | 4 | 1 | | |
| Pericardial effusion | | 1 | | | |
| Emphysema | 3 | 2 | 4 | 1 | 2 |
| Lymphadenopathy | | 2 | | | |
| Mediastinal tumor | | 1 | | | |
| Sarcoidosis | | 1 | | | |
| Pulmonary emboli | | | 1 | | |
| Dilated aorta ascend | | 1 | | | |
| Aorta dissection | | | 1 | | |
| Anatomic variation | | | 2 | | |
| Other | 2*** | | | | |
| | | Σ= 74 | | | |

*One each: pulmonary CT angiography, aortic CT, hepatic CT, thoracolumbar CT; **Edema or aspiration. *** An unclear finding of a rounded parenchymal opacity and an unclear finding in a rib.

Chest radiographs

In 57 out of 136 chest radiographs the patient was referred as potential organ donor. Seventeen chest radiographs were normal with devices in appropriate locations, without cardiopulmonary abnormalities.

Regarding devices 40 out of 124 (32%) nasogastric tubes were incorrectly positioned with the end or side holes placed in the esophagus or the cardia region (Fig.13), and 28 of them (70%) were not mentioned in the clinical reports. There was a statistically significant difference between the prevalence at reporting correctly and incorrectly placed tubes in the clinical reports and study review, respectively ($p < 0.0001$). For other devices there were no significant differences between clinical reports and study review (Tab. 12.).

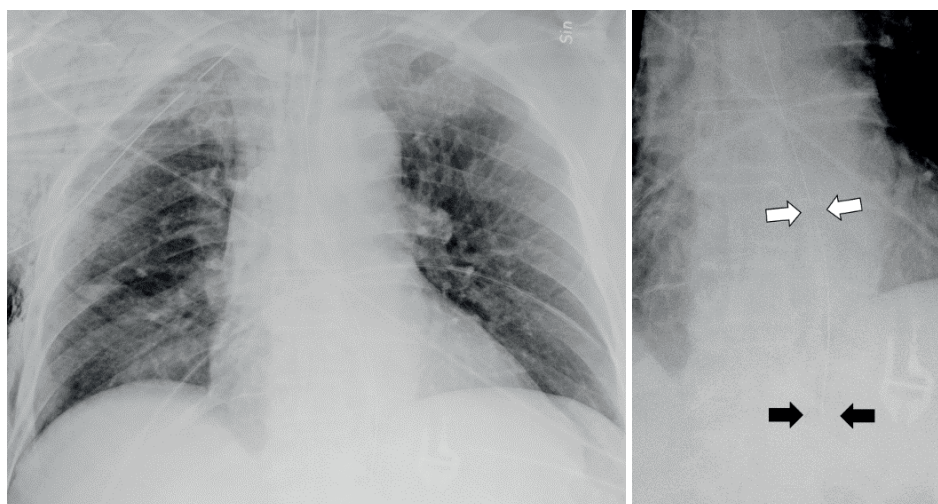


Figure 13. A chest radiograph (left), suboptimally inhaled with subcutaneous emphysema but otherwise clear with an enlarged detail of the present nasogastric tube (right) in insufficient distal position with the end hole located in the distal esophagus (arrowheads) and the side holes located in the esophagus (arrows). Misplaced nasogastric tubes purtain an increased risk for aspiration which is already increased in unconscious patients. Photo credit: Bozovic et al. Imaging of the lungs in organ donors and its clinical relevance – a retrospective analysis. Journal of Thoracic Imaging. 2016, Wolters Kluwer (right image).

Table 12. Overview of devices in the clinical report and study review in 136 chest radiographs.

| Type | Clinical report / Study review | | | | Differences | | p |
|---------|--------------------------------|---------|---------|-----------|-------------|-------------|--------|
| | None | Unnoted | Correct | Incorrect | Minor | Substantial | |
| T-tube* | 7 | 10 | 110/115 | 9/14 | 5 | 5 | 0.382 |
| CVC** | 56 | 8 | 68/74 | 4/6 | 6 | 2 | 0.744 |
| NGT** | 12 | 16 | 96/84 | 12/40 | 15 | 28 | <000.1 |

*Tracheal tube, **Central venous catheter, ***Nasogastric tube

There was no difference between the clinical report and study review regarding pulmonary findings in 37 (27%), minor differences in 28 (21%) and substantial differences in 71 (52%) examinations ($p < 0.0001$). Differences for specific findings are shown in Table 13. There were also three cases (2%) with emphysema at study review. There were no significant differences regarding prevalence of pulmonary findings between radiographs on patients referred as potential donor or patient.

| Table 13. Scoring of the clinical report and study review in 136 chest radiographs. | | | | | | | | | |
|---|----------|--------|-------|-------|------|------|-------------|-------------|---------|
| Clinical report / Study review | | | | | | | | | |
| | Findings | | | | | | Differences | | p |
| | Noted | | Total | S* | M** | S*** | Minor | Substantial | |
| | No | None | | | | | | | |
| Decompensation | 82 | 38/76 | 16/60 | 15/50 | 1/10 | 0/0 | 46 | 36 | <000.1 |
| Edema | 110 | 17/111 | 9/25 | 1/11 | 2/12 | 4/2 | 18 | 14 | 0.006 |
| Infection | 91 | 34/122 | 11/14 | 5/8 | 6/6 | 0/0 | 9 | 6 | 0.675 |
| Aspiration | 126 | 6/120 | 4/16 | 0/11 | 4/5 | 0/0 | 11 | 8 | 0.011 |
| Other | 120 | 4/80 | 10/56 | 2/25 | 8/23 | 0/8 | 23 | 12 | <0.0001 |

*Subtle, **Moderate, ***Severe

Computed tomography

Most CT examinations were performed early during the course of illness with a time interval of 2.5 h to 11 days between the CT examination and the last chest radiograph; thus it was impossible to correlate the imaging findings between modalities. Thirteen complete chest CT examinations were performed in 13 patients, three of whom were referred as potential donors (Fig.14).

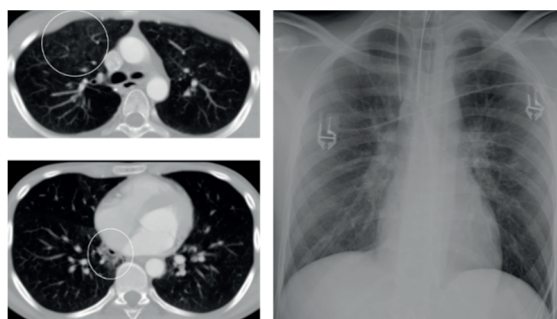


Figure 14. Chest CT (left) showing subtle traumatic injuries with slight bleeding in the right upper lobe (circle top left) and a small contusion with pneumatocele in the right lower lobe (circle bottom left). The mandatory chest radiography for donor evaluation performed 22h and 45 min later did not reveal the subtle traumatic injuries.

The indications were trauma (n=8), abnormal laboratory findings (n=3), occluded airways (n=1) and mediastinal tumor (n=1) with clinical reports reflecting the referral enquiries (Tab. 12). Tubes and devices were generally not mentioned, except for tracheal tubes. One examination was considered normal both in the clinical report and at study review. The remaining 12 examinations showed minor differences in four and one or more substantial differences in eight examinations. Sixteen out of 39 findings at study review were not mentioned in the clinical reports. Fourteen were substantial ($p < 0.0001$). The discrepancies referred to aspiration or infection (n=2), atelectasis (n=2), emphysema (n=2), mediastinal tumor (n=1), lymphadenopathy (n=2), dilated ascending aorta (n=1) measuring 45 mm in AP diameter, suspected sarcoidosis (n=1), incorrect positions of tracheal (n=1) and nasogastric tubes (n=2) as shown in Table 10. Regardless of the time of performance during the course of illness the CT examinations contributed valuable information.

CT with non-pulmonary indications

CT angiography of the head and neck was performed in 17 patients, none referred as potential donor, including 1-12 cm (mean 6.7 cm, median 8 cm) of the apical lungs (Fig. 15). Four examinations were without pulmonary findings. The remaining 13 revealed emphysema (n=4), endobronchial airway obstruction or total occlusion (n=4), pulmonary edema (n=2), atelectasis (n=3), incorrectly placed tracheal tube (n=1), aspiration (n=1), pleural effusion (n=1), pulmonary emboli (n=1), persistent left vena cava superior (n=1) and arteria lusoria (n=1) at study review (Tab. 10). Except for moderate pleural effusion in one examination no findings were mentioned in the clinical reports ($p < 0.0001$).

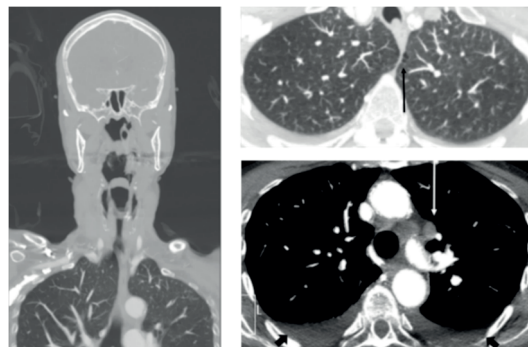


Figure 15. CT angiography of head and neck including approximately 11 cm of the apical lung in coronar and axial planes, (left). There is a moderate bilateral pleural effusion seen on the mediastinal windowing (right lower) and subtle emphysema on the parenchymal windowing (right upper). In addition a persistent vena cava superior on the left side is noted (thin arrow right lower image). Pleural effusion may impair the lung function and affect the blood gases, compromising donor suitability. Emphysema due to previous smoking is connected to PGD. Presence of anatomical variation may require a different operative approach which would be of importance in the preoperative planning. Photo credit: Bozovic et al. Imaging of the lungs in organ donors and its clinical relevance – a retrospective analysis. Journal of Thoracic Imaging. 2016, Wolters Kluwer.

Eight cervical spine CT examinations, none referred as donor, included 1.5- 5 cm of the apical lung. Five were without pulmonary findings (Fig. 16). Three revealed incorrectly placed tracheal tube (n=1), infection or aspiration (n=3) (Fig. 16) and emphysema (n=1) (Fig. 16), none of which were mentioned in the clinical reports. In the four remaining CT examinations pulmonary CT angiography showed emphysema and atelectasis, CT angiography of the aorta showed pulmonary edema and/or aspiration, CT of the thoracic and lumbar spine an incorrectly placed nasogastric tube and hepatic CT including 4.5 cm of the basal lungs revealed atelectasis, bronchial wall thickening and probable emphysema (Tab. 10). No findings were mentioned in the clinical reports.

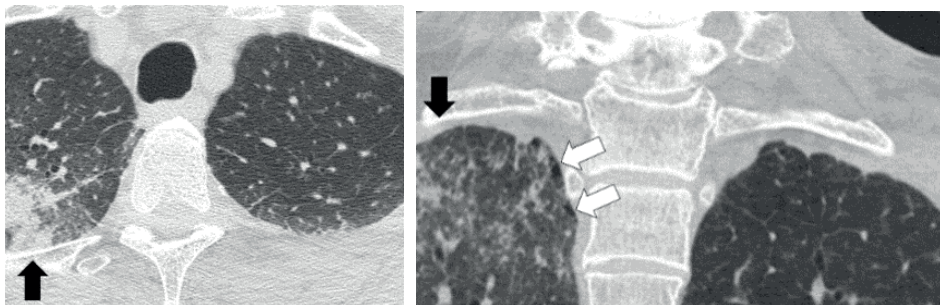


Figure 16. Cervical spine CT in the axial and coronary planes including approximately 5 cm of the apical lung. In the right upper lobe there is a nodular opacity and a consolidation (black arrow), probably caused by infection or aspiration. Additionally, there is subtle subpleural emphysema (white arrows) in the incompletely visualized right upper lobe. Regardless of what the noted opacity on the right side may represent, in a clinical setting for donor evaluation it would indicate a bronchoscopy. Photo credit: Bozovic et al. Imaging of the lungs in organ donors and its clinical relevance – a retrospective analysis. Journal of Thoracic Imaging. 2016, Wolters Kluwer.

Compared with the clinical reports one or more substantial differences were found in 71 chest radiographs (52%) and eight chest CT examinations (62%) at study review. In 29 CT examinations with non-pulmonary indications there were findings of importance in 19 examinations (66%), almost none mentioned in clinical reports. In total 31 out of 42 CT examinations (74%) showed 74 pathological findings of which only 24 were mentioned in the clinical reports. In addition, in ten of those patients (24%) the findings were of direct importance for the donation such as emphysema (n=9), lymphadenopathy (n=2), mediastinal tumor (n=1), suspected sarcoidosis (n=1) and pulmonary emboli (n=1). This proportion was significantly higher ($p < 0.0001$) than for bedside chest radiographs.

Imaging in lung donors only

Out of 110 brain dead patients 77 (70 %) proceeded to organ donation. Thirty-five (35%) out of 100 patients below the age limit for lung transplantation (70 years of age) proceeded to lung donation.

Eleven out of 54 chest radiographs performed on later donated lungs were normal. There were no differences in 23, minor in 4 and substantial differences in 27 examinations ($p < 0.0001$) (Tab. 14). Substantial differences referred to decompensation (n=14), edema (n=4), infection or aspiration (n=8) and incorrectly placed nasogastric tubes (n=13). Four chest CT examinations and one pulmonary CT angiography showed atelectasis (n=2), aspiration (n=1), emphysema (n=1) and suspected sarcoidosis (n=1). Nine incomplete CT examinations showed atelectasis (n=3), airway occlusion (n=3), emphysema (n=2) and incorrectly positioned tracheal tube (n=2) (Tab. 15).

Table 14. Overview of radiologic findings at study review in 54 radiographic and 14 CT examinations in 35 lung donors.

| | Chest radiography | CT Chest + CT pulmonary angiography | CT Head & neck angiography + CT Cervical spine |
|-------------------------|-------------------|-------------------------------------|--|
| Patients (n) | 35 | 5 | 9 |
| Examinations (n) | 54 | 4 + 1 | 5 + 4 |
| Findings | | | |
| Normal | 11 | 0 | 3 |
| Incorrect tubes | 18 | 3 | 2 |
| Decompensation | 14 | 0 | |
| Edema | 4 | 0 | |
| Aspiration or infection | 8 | 1 | |
| Atelectasis | 8 | 2 | 3 |
| Airway sub-occlusion | 0 | 0 | 3 |
| Emphysema | | 1 | 2 |
| Trauma | | 2 | |
| Other | 2 | 1 | 1 |
| Σ | 54 | 10 | 11 |
| | | Σ = 21 | |

In chest radiography other refers to an unclear finding of a rounded parenchymal opacity and an unclear finding in a rib, in CT chest and CT pulmonary angiography to one finding of suspected sarcoidosis and in CT Head and neck angiography and CT cervical spine to an anatomic variation (a lusoria).

Table 15. Overview of devices in the clinical report and study review in 54 chest radiographs in 35 lung donors.

| Type | Clinical report / Study review | | | | Differences | | P |
|---------|--------------------------------|---------|---------|-----------|-------------|-------------|-------|
| | None | Unnoted | Correct | Incorrect | Minor | Substantial | |
| T-tube* | 2 | 10 | 40/47 | 2/5 | 7 | 3 | 0.373 |
| CVC** | 15 | 4 | 34/38 | 1/1 | 4 | 0 | 0.938 |
| NGT** | 5 | 6 | 40/36 | 3/13 | 1 | 10 | 0.014 |

Paper IV

Lungs from 35 donors were transplanted to 38 recipients of whom 30 had double lung transplantation, one had a combined heart and double lung transplantation, and seven had single lung transplantation. Recipients were from Scandinavia (n=35) and Northern Europe (n=3). The mean age of the 35 donors (20 women, 15 men) was 45 years (range 6-71 years, SD 19.1). Seventeen donors fulfilled the extended donor criteria. The transplantations were performed between 2007 and 2014 with a mean number of 4 transplantations/year (range 2 – 8) (Tab. 16). Mean age of the 38 recipients (24 women, 14 men) was 48 years (range 15-64 years, SD 14.5).

The values for blood gas analysis are presented in Table 16.

Table 16. Arterial blood gas analysis for 35 donors

| | Minimum | Maximum | Mean | Standard deviation |
|--|---------|---------|------|--------------------|
| PaO ₂ (on 100% O ₂ , mmHg) | 32.2 | 74.2 | 59.0 | 9.8 |
| PaCO ₂ (mmHg) | 4.1 | 9.6 | 5.4 | 0.9 |
| pH | 7.2 | 7.5 | 7.4 | 0.06 |

Normal values for arterial PaO₂ are 80-100 mmHg, PaCO₂ 35-45 mmHg and pH 7.35-7.45.

Clinical and imaging data of donors

The conventional chest radiography was normal in 14 out of 35 donors without pathologic lung findings or misplaced tubes according to the clinical reports, while eight of these were normal at study review. Further, 27 pulmonary findings were reported at clinical report in 18 donors compared with 67 at study review in 27 donors (Tab. 17). At clinical report five donors were diagnosed with decompensation or edema and one with aspiration or infection (Fig. 17). The corresponding figures for study review were 19 and seven, respectively.

Table 17. Findings in clinical report and study review respectively in 35 mandatory chest radiographies.

| Chest radiography | |
|----------------------------|-------|
| Patients (n) | 35 |
| Examinations (n) | 35 |
| Findings | |
| Normal | 14/8 |
| Incorrect T-tube | 2/5 |
| Incorrect CVC | 1/2 |
| Incorrect NGT | 2/10 |
| Decompensation | 3/15 |
| Edema | 2/4 |
| Aspiration or infection | 1/7 |
| Atelectasis | 12/18 |
| Pleural effusion | 3/4 |
| Unclear rounded opacity | 0/1 |
| Unclear finding in the rib | 1/1 |
| Σ | 27/67 |

While at clinical report only two out of 33 nasogastric tubes were found to be in an incorrect position, this number increased to ten at study review (Tab. 18).

Table 18. Overview of devices in the clinical report and study review in 35 chest radiographs.

| Type | Clinical report / Study review | | | | Differences | | p |
|---------|--------------------------------|---------|---------|-----------|-------------|-------------|-------|
| | None | Unnoted | Correct | Incorrect | Minor | Substantial | |
| T-tube* | 0 | 2 | 31/30 | 2/5 | 2 | 3 | 0.264 |
| CVC** | 0 | 2 | 32/33 | 1/2 | 2 | 1 | 0.590 |
| NGT** | 0 | 2 | 31/25 | 2/10 | 1 | 8 | 0.015 |

Outcome data for recipients

Three recipients died during the first 30 days from perioperative complications (n = 2) and multi-organ failure (n = 1). One additional recipient died during the first year from B-cell lymphoma. Thus 30-day and 1-year survival were 92% and 89%, respectively.

In the 28 recipients of double-lung transplantation surviving the first year post-transplantation median FEV₁% was 82%, range 46% – 144%, i.e. representing a

slightly impaired lung function. For the six surviving single-lung recipients the corresponding figures were 52.5%, range 35% – 94%,

In 36 patients surviving the peri-operative phase early complications consisted of 18 cases of infection (nine pulmonary infections, nine extra-pulmonary), one case of primary graft dysfunction and seven patients with other complications (impairment of kidney function, suspicion of rejection, necrosis in the bronchial anastomosis, tracheostomy, brain ischemia and ileus).

In those patients, correlations were performed with 30-days and 1-year survival, hospitalization time, infectious or other complications, and FEV₁% at the one-year follow-up as outcome measures compared with donor age, decompensation/edema, infection, aspiration, location of the nasogastric tube or arterial pO₂ and pH. A diagnosis of aspiration at study review correlated with reduced FEV₁% at 1 year follow-up ($p=0.021$). A diagnosis of infection correlated with poorer 30-day survival both for clinical report and study review ($p<0.001$ and $p=0.021$, respectively). No other correlations were found.

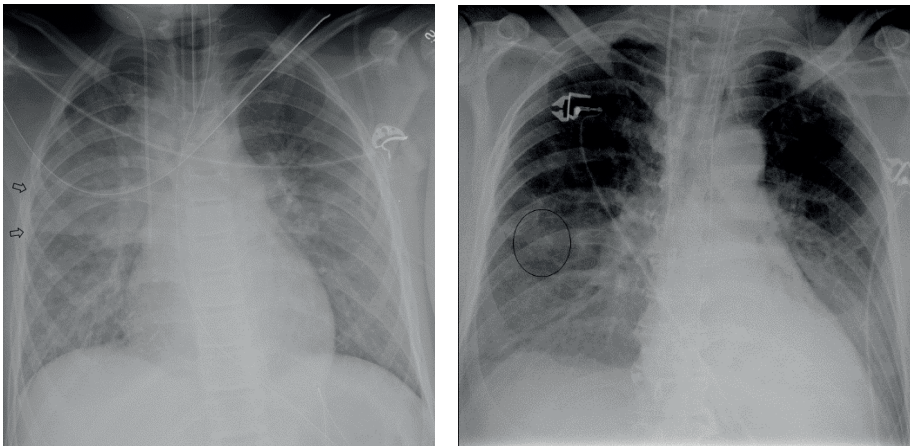


Figure 17. Bedside chest radiograph (left) showing loss of definition of vessels and hilar structures with ground glass opacities in keeping with moderate pulmonary edema which was reported. There is also a more pronounced opacity in the basal part of the right upper lobe (arrows) that seems to respect the anatomical borders raising the suspicion of segmental pneumonia that was not reported in the primary reading. The bedside chest radiograph (right) shows an atelectasis of the left lower lobe with an air bronchogram which was reported. Note the subtle rounded opacity with a diameter of approximately 1.5 cm on the right side (circle). This unclear finding was not reported in the primary reading.

Discussion

Papers I and II

Brain death in a porcine model has been widely debated and studied by Anne Barklin and co-workers (146-149). The method used in their study and in most experimental studies of brain death has been to increase the intracranial pressure by a balloon placed subdurally or epidurally. When the intracranial pressure is higher than the arterial pressure, the brain is assumed to be without circulation; first, a 'sympathetic storm' with hypertension and tachycardia is seen followed by a 'sympathetic collapse' with hypotension. The pig has ascending spinal arteries which provide blood supply to the brain stem and, furthermore, a very strong tentorium cerebelli (149). An inflated balloon in the supratentorial intracranial space will therefore not guarantee complete brain stem death. According to Barklin: 'there are no certain ways to determine the extent of brain stem death. This is a serious concern and reduces the external validity between different models of brain death (149). In the present studies we therefore ensured acute total brain, brainstem and pituitary gland death by decapitation of the pigs between C2 and C3. By this drastic method, we got a reproducible sympathetic 'storm' and 'collapse'. In the decapitated pigs there was a peak increase in plasma concentration of noradrenaline from a base value of 600 pmol/l to 47,000 pmol/l and adrenaline from 115 pmol/l to 34,000 pmol/l.⁹ Inflation of an intracranially placed balloon as described by Barklin et al (146) gave a corresponding peak increase of noradrenaline and adrenaline to 2500 and 5500 pmol/l, respectively, indicating the difficulty to find clinical relevant porcine brain-dead models. Our aim was not to create a model of brain death that simulates clinical brain death. For a discussion of the problems with clinical brain death, we refer to a review article by McKeown et al. (85).

The vasomotor center (VMC), located in the brainstem, transmits parasympathetic impulses through the vagus nerve to the heart and sympathetic impulses through the spinal cord and peripheral sympathetic nerves to virtually all arteries, arterioles and veins of the body (150). Normally, the VMC transmits signals continuously to sympathetic vasoconstrictor nerve fibres that secrete noradrenaline in their terminal nerve endings, causing a sympathetic vasoconstrictor tone. The sympathetic tone keeps almost all the systemic arterioles constricted to about one half of their maximum diameters (150) and it also maintains the tone in the veins which are

richly innervated by sympathetic nerves (151-153). Sympathetic impulses are transmitted to the adrenal medullae at the same time as they are transmitted to the blood vessels, causing secretion into the blood of both noradrenaline and adrenaline, which contributes to the vasoconstrictor tone, heart contractility and heart rate. After being secreted by the terminal nerve endings, noradrenaline is removed from the synaptic clefts by reuptake into the adrenergic nerve endings (up to 80%) and by diffusion into surrounding body fluids and the blood (150).

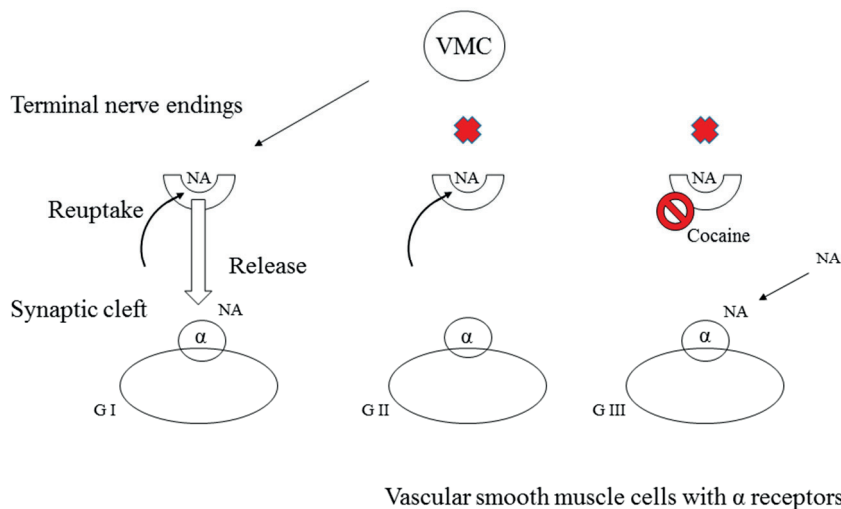


Figure 18. Schematic drawing of a synaptic cleft under the condition for each experimental group. In the normal situation nerve signals from the vasomotor centre (VMC) cause noradrenaline (NA) release from the terminal nerve endings. After exhibiting its effect by binding to post-junctional α -adrenergic receptors on the vascular smooth muscle, a reuptake mechanism transports (NA) back to vesicles within the terminal nerve endings (left panel). In decapitated animals, no nerve signals from VMC occur, but the reuptake mechanism works, emptying the synaptic cleft for (NA) (middle panel). By blocking the reuptake with cocaine (right panel), (NA) given intravenously will reach the post junctional α -adrenergic receptors without being sucked up by the adrenergic nerve terminals.

The first study showed the effect of acute and complete removal of the VMC. Initially, a catecholamine storm occurs, with its peak after 2 min (Fig. 5, Tab. 5). Hypotension starts 30 min after decapitation, and after 12 h, seven out of eight animals have a mean aortic pressure of less than 40 mmHg. When the brainstem is removed, the impulses from the VMC to the sympathetic vasoconstrictor nerves stop and the release of noradrenaline into the synaptic clefts decreases (Fig. 18). When a blood vessel segment is investigated in an organ bath to classify its post-junctional α -adrenergic receptors and noradrenaline is given to the bath, a considerable part of the noradrenaline will be taken up into the synaptic nerve terminals. Cocaine is commonly used to block this reuptake, displacing the noradrenaline concentration–response curve to the left, i.e., half maximum

vasoconstriction is reached with less concentration (151-153). A decapitated pig may be seen as an organ bath, and when the reuptake of noradrenaline into the sympathetic nerve terminals is blocked by cocaine, low intravenous doses of noradrenaline are required to stimulate the post-junctional adrenergic receptors and thereby the blood pressure.

The use of high doses of noradrenaline (> 0.05 mg/kg/min) in donors is associated with increased cardiac graft dysfunction, particularly right ventricular performance, and higher early and late mortality (154, 155). The doses needed in our study were much lower (0.003–0.01 mg/kg/min), (Tab. 1). Noradrenaline is five to ten times as potent on peripheral veins compared with the concomitant arteries (151-153). A low dose of noradrenaline will cause a strong venoconstriction before it affects the arteries. Such a selective venoconstriction by a low-dose noradrenaline will increase the end diastolic pressure of the right ventricle and thereby the cardiac output, without increasing the afterload.

An advantage of the pharmacotherapy used in the study is that the risk of overhydration with crystalloid fluids is minimized, because there is no need for extra fluid supply to counteract arterial hypotension. The blood gases were normal on air ventilation 24 h after decapitation, indicating absence of pulmonary edema. The acute and complete loss of ACTH and TSH after decapitation caused the serum concentration of cortisol and thyroid hormones to fall significantly within 6 h; the replacement therapy given kept the serum concentrations within normal ranges, except for T4, where the given dose was too low. In pilot experiments, pigs were treated with all drugs included in the pharmacological treatment except desmopressin; then a large urine output started 4 to 6 h after decapitation. Desmopressin in the doses needed to omit diabetes insipidus, but to keep an adequate urine production, was therefore included from the start. The dose of desmopressin used to treat the diabetes insipidus in this study may have contributed (156) besides cocaine, to keep up the vascular tone together with the low (permissible) doses of catecholamines.

Both studies showed that basic need of fluid substitution without additional pharmacological therapy in decapitated pigs leads to median aortic blood pressure below 40 mmHg within 6–12 h after decapitation. In the second study forced fluid therapy alone was insufficient to counteract arterial hypotension after brain death in GI and, although an initial rise of blood pressure could be accomplished, the blood pressure did not stabilize at a clinically acceptable level. Furthermore, due to fluid overload pulmonary edema could be expected. Indeed, when evaluating the lungs of brain dead animals treated with forced fluid therapy HRCT showed pulmonary edema to be significantly more common in this group compared to the brain dead animals treated with the pharmacological regimen in GII or non-decapitated controls in GIII. The pharmacological regimen used in GII normalized the blood

pressure throughout the 24 h observation period and final PaO₂/FiO₂ was excellent and did not differ from non-decapitated controls in GIII. Consistent with the failing blood pressure in GI, median final PaO₂/FiO₂ was 29 kPa, which would exclude lungs from donation in a clinical setting, with 40 kPa being the limit for acceptance. HRCT could detect and characterize clinically expected parenchymal lung changes such as pulmonary edema in decompensated animals but also clinically occult lung disease, not revealed by pre-transplant clinical lung function parameters, in this porcine model. HRCT revealed moderate or severe pulmonary edema in 83% of the decapitated animals treated with forced fluid therapy, compared to 18% of the pigs in the pharmacological therapy group and none of the controls. One explanation for the presence of mild pulmonary edema in the latter group could be the occurrence of Neuropeptide Y as a mediator of neurogenic pulmonary edema shown in brain-dead pigs.(157).

In human lung HRCT, hydrostatic pulmonary edema presents itself predominantly with coexistence of ground-glass opacities and consolidations, mainly ill-defined, together with a ventrodorsal gradient (121, 122). The same observations are made in pigs in this study. Considering transmission of pulmonary imaging findings known in human and porcine models, it has to be underlined that considerable anatomical differences need to be taken into account (158), e.g., the broncho-arterial ratio, representing an important landmark in human image interpretation cannot be applied in porcine lungs as described and illustrated in Figure 19.

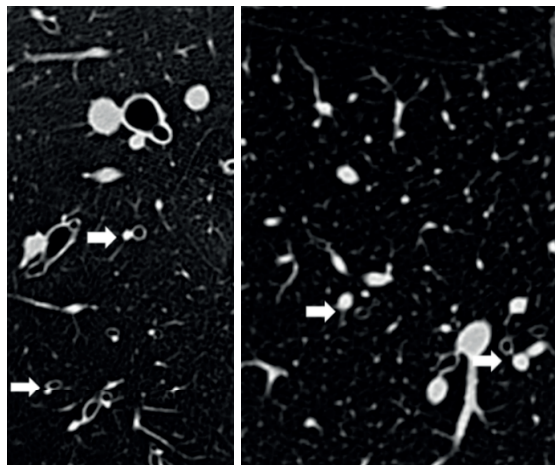


Figure 19. HRCT of the basal part of a porcine (left) and human (right) lung. The broncho-arterial ratio differs between the species. Porcine airways contain thicker cartilage and are larger compared to the accompanying artery (arrows in the left image). In humans the size of the airway and the accompanying artery is similar (arrows in the right image). Photo credit: Bozovic et al. Circulation stabilizing therapy and pulmonary high-resolution computed tomography in a porcine brain-dead model. *Acta Anaesthesiologica Scandinavica*, 2015, Wiley.

Findings of dense, asymmetric consolidations was unexpected, especially as all animals had excellent blood gases prior to inclusion in the study. HRCT patterns conformed to residuals after infection or occult infection though none of the animals showed clinical signs of infection at the time of inclusion (fever, sickness behavior with decreased activity). Based on what is seen in human lungs, the HRCT pattern seen in two of the cases is compatible with organizing pneumonia. All included pigs used in this study were brought up according to national restrictions regarding usage of antibiotics, which could partly explain the high frequency of infectious scarring and lesions revealed by HRCT (59% of the animals). In a clinical setting, the presence of consolidation would indicate a management change, e.g., bronchoscopy, pharmacological treatment, or in the worst scenario rejection for further transplantation. This underlines the potential role of HRCT to detect occult infection in a donor lung considered to be transplantable. 3D-multidetector CT angiography has been used to evaluate the pulmonary arterial anatomy in potential donors and computed tomography volumetry in living lung donors for comparison with pulmonary function (159, 160). However, to our knowledge, HRCT has not previously been evaluated for pre-transplant assessment of donor lungs in porcine or human studies though HRCT has been used to assess porcine models by Todo et al. as early as 1986 (114).

In conclusion, pharmacological substitution of pituitary gland function, blockade of peripheral neuronal catecholamine reuptake by cocaine and low doses of catecholamines keep the circulation in brain dead pigs during an observation period of 24 h, whereas non-treated pigs develop circulatory collapse within 12 h. The pharmacological substitution can replace forced fluid therapy decreasing the fluid overload and risk for development of pulmonary edema and thereby increase the lung function. HRCT is useful to evaluate lung morphology with significant differences of lung parenchymal findings dependent on the regimen chosen for blood pressure stabilization. In addition more than 50% of all pigs showed unexpected signs of lung disease in spite of arterial oxygen tension being well above 40 kPa, the clinical limit for acceptance for transplantation. These results indicate the value of HRCT for a more thorough pre-transplant lung evaluation and its potential should be further evaluated in human studies.

In keeping with the three R's the collected imaging material from animal experiments for this thesis has further been used in a study for developing a system to segment anatomical structures that potentially could be used for segmenting lungs in challenging chest CT scans (161). It will further come to use to veterinarians for extended analysis to improve the knowledge about the living conditions for pigs.

Papers III and IV

The majority (85%) of potential lung donors in the third study were examined with bedside chest radiography. Complete chest CT was performed in a small group of 13 patients. A comparatively large number (n=29) of CT examinations of other body parts incompletely including the lungs were also analyzed. At study review additional important information regarding lung transplantation was found in 71 out of 136 chest radiographs, 8 out of 13 complete chest CT examinations and, notably, in 19 out of 29 other CT examinations. The radiologists did not perform differently for patients referred as "donor" or "patient" respectively.

Seventy percent of the 32% incorrectly placed nasogastric tubes (Fig. 3) were not mentioned in the clinical radiography reports, which is particularly unfavorable in unconscious ICU patients with increased risk of aspiration (79, 162) and potentially devastating for lung donation. Aspiration is a relative contraindication for donation depending on its extent as it is linked to primary graft dysfunction (PGD) (108). A careful search for aspiration pneumonia should be made in these patients (Fig 4). The chest X-ray technique was optimized for lung parenchyma and not for optimal visualization of the nasogastric tubes. Nevertheless, appropriate windowing in the PACS allows evaluation of nasogastric tubes even in unfavorable images (163). Remarkably, apart from the tracheal tubes, other devices were not mentioned in the clinical reports of CT examinations. There is likely to be a lack of awareness of the importance of correctly positioned nasogastric tubes when reviewing chest radiography and CT examinations as they were often not mentioned.

The most common radiographic discrepant parenchymal finding was decompensation and edema. Decompensation can be caused by fluid overload or cardiac decompensation, both eventually resulting in pathologic capillary leak and hydrostatic pulmonary edema. Capillary leak can also be caused by a severe head injury with loss of the function of the vasomotor center resulting in neurogenic pulmonary edema, expected among the patients in the current study. In decompensation the development of pulmonary edema can still be counteracted by reducing the fluid infusion or hastening the donation process. Development of pulmonary edema will reduce oxygenation which subsequently disqualifies the lung from donation. With ex-vivo reconditioning some of these marginal donor lungs can still be reclaimed (88).

When comparing the smaller, heterogeneous group of CT examinations (n=42) with the larger group of bedside chest radiography (n=136) more important information regarding lung transplantation emerged in the CT group due to higher spatial and anatomic resolution. The findings were anatomic variations of importance for preoperative planning, pulmonary edema that may be suitable for ex-vivo reconditioning, aspiration which is a relative contraindication, emphysema as a consequence of smoking both linked to PGD, lymphadenopathy due to infection,

systemic disease or malignancy that would trigger a thorough investigation, tumor and pulmonary emboli that contraindicate transplantation. Some of the findings would also have been important for heart donation such as suspected sarcoidosis, anatomic variants, dilated ascending aorta and enlargement of the heart. CT examinations with a longer time interval to donation will be useful mostly for anatomic evaluation and detection of chronic diseases, whereas CT examinations closer in time to donation will be useful also for evaluation of current treatable conditions.

CT thus has the potential to contribute to a more nuanced evaluation of donor lungs in a pretransplant setting, even more so in the light of an increasing number of older donors with extended criteria. The same reflection about increased information from chest CT has already been demonstrated for ICU patients in general in multiple previous reports (99, 164-166). The CT is in several respects important for the donor evaluation, donor recipient matching and preoperative planning, and thereby contributes to transplant success. Lung size evaluation to avoid mismatch is in most centers at present based on comparison of donor and recipient height and/or predicted total lung capacity with limited exactness. Lung size, the size of the main bronchi and an evaluation of anatomy (159) are easily performed by CT and may facilitate the matching and preoperative planning. CT may help regain marginal donors by detecting other findings such as pulmonary edema suitable for ex-vivo reconditioning, mucus plugging or pulmonary effusion causing secondary atelectasis and decreased lung function that can be treated, and treatable infection and aspiration. Findings of pre-existing lung disease, e.g. COPD, IPF or malignancy can influence the matching or contraindicate the donation. The importance of this increases with the increased age limit for donation of lungs by coinciding with the peak of incidence of these diseases. There are also missed organ donors in the ICU and emergency rooms (167) where CT may play a role.

Chest CT provides more information than chest radiography (103) but also more incidental findings (168) that potentially could jeopardize the use of the lung in question for transplantation and thereby prolong the organ procurement and reduce the number of accessible organs. However, imaging should be considered in the context of the complete clinical setting as a complement to other examinations such as bronchoscopy and blood gas analysis, together contributing to improved diagnostic performance. Routines for management of incidental findings in imaging in this group of patients could be implemented, similar to what is already done in the wider population (169).

The results of the third study indicates that a more targeted review of already existing examinations by a chest radiologist with knowledge about transplantation, facilitated by a structured checklist, would substantially contribute to a more standardized, reader independent and accurate image evaluation (170). Bedside chest radiography of donors is not rarely interpreted by an organ procurement coordinator (94), and it would not be improbable that the same reasoning could be

applied there. Bolton et al. (171) argued that evaluation of lung donor chest radiographs is highly subjective with a limited role. However, in that study the image review was performed by surgeons and pulmonologists without involvement of a radiologist. Nevertheless, it has been shown that radiologists perform superiorly to clinicians in interpreting chest radiographs (95-97, 170). The differences between the clinical report and the study review for bedside chest radiography in the current study are in keeping with experiences elsewhere (172, 173). A recent study suggests a careful interpretation of imaging studies for evaluating donor and recipient in lung transplantation, highlighting the importance of radiologists familiar with the circumstances of transplantation. Furthermore, it emphasizes that communication between the radiologist and the medical and surgical teams can have significant impacts on long-term outcomes (174).

The study is a single center study only reflecting the practice at the authors' institution, which is a limitation. A multicenter study would have given a more objective representation. With the review being done in consensus, interobserver variability was not addressed. This has, however, been reported in other studies (175). The reasons for doing a consensus reading were the difficulty to interpret the clinical reports according to the elaborate questionnaire, needing of discussion, and the difficulties in reliably diagnose decompensation, which were expected in our patients.

From the cohort of 110 potential organ donors the actual lung donors, in total 35 lung donors and 38 lung recipients (seven single and 31 double lung transplantations) were selected for further analysis in study four. Their one-year survival rate was 89% which is similar to or slightly better than international figures (17). Out of 35 chest radiographs, 40% were normal without findings or misplaced tubes in the clinical report and 23% at study review. These are far lower percentages than in a previous study analysing donors where 82% of chest radiographs were considered normal (176). In that study, however, tubes were not accounted for and if excluding tubes in our material 40% were normal. There was a correlation between infection and 30-day survival. This correlation, however, is based on only one patient. On the other hand, the correlation between aspiration and FEV₁% at one year is more interesting and is clinically more significant, as aspiration in donors might contribute to deterioration of lung function and thereby have an impact on long-term survival. Out of 18 donors with atelectasis at the study review 15 represented atelectasis in the left lower lobe, a common finding in supine patients. It is assumed to be due to the heart compressing the left lower lobe bronchi (127, 128) with subsequent atelectasis which is reversible.

Clinically established donor related risk factors for PGD (108) are smoking history, aspiration pneumonia, trauma and hemodynamic instability. We hypothesised that lung transplantation outcome would correlate to imaging findings of those entities or to the presence or absence of findings in general in those donors who met the donor acceptability criteria (12) or extended criteria donors (91). During the 1-year

observation period only few correlations were found between donor imaging findings and outcome parameters. This could be due to the small patient cohort or the complexity of both donor and recipient related possible outcome influencing factors. The outcome parameters in the current study are, however, comparatively coarse, and systematic data for analysis of e.g. number of bronchoscopies performed or the need for bronchial stenting were not available.

The results of the current study showed that aspiration correlated to reduced FEV₁% at one year follow up, which might indicate an impact from aspiration in donors on long-term lung function. What impact the other information gained from imaging regarding pre-existing or acquired donor variables, e.g. emphysema, decompensation or infection, might have is not known. Since the long-term survival after lung transplantation is among the shortest of all solid organ transplantation (18, 177) it would be of interest to identify causes for it. Our results also indicate that bedside chest radiography, being the imaging method least accurate for detecting cardio-pulmonary abnormalities, and interpreted not focusing on aspects relevant for donation, does not have a clinically significant input on donor acceptance and 1-year outcome but probably rule out some of the gross pathologies. The previous study showed that important information regarding donor recipient matching, operative planning and important information for the transplantation as such could be gained by a structured analysis of available imaging studies from a donation point of view. Imaging findings in the subgroup of donors reported in both studies were similar. Also CT, completely or incompletely including the chest, offers more information of value for the transplantation including presence of aspiration with a clear predominance of findings in CT examinations. Therefore, a larger study including more donors than the current study using CT for imaging would be of interest. With the donor pool expanding and moving away from the original donor criteria towards expanded donor criteria (91, 92), now representing about half of the donor pool (93) and coinciding with the peak age for lung cancer (111) and fibrosis (110), but also with donation taking place not only after brain death but also after cardiac death (86) better imaging might be beneficial. More advanced imaging such as chest CT contributes supplementary information that could potentially have an impact on the outcome. Due to its sensitivity, CT can certainly disqualify some donors from proceeding to donation, thereby decreasing the donor pool but it will probably include others that at present are classified as marginal donors.

The discrepancy in number and severity of findings between two readings in the current study, and even so in the larger study from which those data are collected, indicates a substantial observer variation. This has been remarked on previously (12) where the paucity of data regarding the degree of observer variation has prevented the design of firm guidelines regarding how to interpret radiographic findings in a transplant setting. In addition the limitations of this study are the small number of donors from a single institution, and the limited follow-up data in the

recipients. However, the available data is limited by what data the transplantation agencies record.

To our knowledge correlations between donor imaging and lung recipient outcome has not been studied before.

In conclusion, majority of donor patients undergo only chest radiography. With a targeted list substantial changes were made from initial clinical interpretation at study review. Chest CT can provide valuable information about donor lung pathology but various other CT examinations even if only partially including the lung may contribute with valuable information. The mandatory blood gas analysis within this range and chest radiograph before lung donation did not have any influence on the 1-year outcome after lung transplantation. However, presence of aspiration at study review was correlated with reduced FEV1% which might indicate the importance of better imaging methods and dedicated image interpretation from a transplantation point of view. Larger imaging studies or a change in clinical routine including CT methods may provide evidence for future guidelines.

Final Comments

Since the transplantation of solid organs came into practice during the second half of the 20th century it has proven itself to be a beneficial medical option for a certain group of terminally ill patients. It is a complex practice implying a huge organization of many segments and different professionals taking care of: donor management, organ procurement, transport, surgery, post-operative and post transplantation medical treatment, imaging, lifelong monitoring etc. The outcome is therefore the sum of the results of our mutual efforts and competences. With that in mind from my own perspective I hope that imaging in lung transplantation will be adjusted accordingly in the near future.



Acknowledgements

In putting the last pieces of this long lasting project together there is only joy. It started as a happy coincidence, Stig and me discussing the potential use of imaging in lung transplantation, now ending as a thesis. During this journey I have learnt very much, not only about imaging and lung transplantation, but also about practicalities in research and the delicate art of managing too many tasks at the same time. Surprisingly, and to my delight, also a lot of history. My joy is not unblemished though, it has at times been a really bumpy run with some serious considerations about the purpose of it all. Some of my greatest challenges have been the lack of clear landmarks in this unexplored field causing constant transformations of the project. From where we started it is almost unrecognisable in its current shape and has during the course, I feel, shaped itself. What I take with me further on is a much broader horizon, a sense of endless possibilities and first and foremost the rewarding interactions with so many great people who have taught me, guided me, inspired me and helped me out and without whom this project would never have come to light. I thank you all from the bottom of my heart.

Isabella Björkman-Burtscher and Mats Geijer, my supervisors, I thank you for the longstanding guidance. In particular Isabella, for your meticulous structure and ability to overview huge amounts of data seeing the potential and Mats for your effortless efficiency, broad perspectives and not least good sense of humour.

Stig Steen, my co-supervisor. You are one of the most extraordinary persons I have ever met. It has been a real adventure getting a glimpse of your world. I thank you for the opportunity and collaboration.

Roger Siemund, my co-supervisor, whom I have had the great pleasure to get to know during this journey. I thank you for your calm assistance, when most needed.

Trygve Sjöberg, although not officially, in practice you have certainly been my co-supervisor. And what a co-supervisor, with your vast knowledge and experience.

My co-authors with surrounding colleagues and teams: Qiuming Liao, Björn Wohlfart, Cornelia Schaefer-Prokop, Johny Verschakelen, Peter Höglund, Catharina Adlercreutz, Peter Reinstrup, Richard Ingemansson and Elin Skansebo,

I thank for the indispensable contribution with your different competences. It has been most appreciated.

Cornelia Schaefer-Prokop and Johny Verschakelen for your generous and kind contribution to the CT part of my work, “enhancing” it immensely. Dear Cornelia, it has been a privilege getting to know you. You inspire all of us to raise the bar.

Peter Höglund for transforming statistics into an unexpectedly enjoyable subject.

Catharina Adlercreutz, if there were only one acknowledgement to be written it would be to you. Without your enthusiasm and relentless support as my colleague and the former head of my department, this thesis would never have been completed. With all my heart I thank you, my dear friend.

Peter Hochbergs, head of the Department of Medical Imaging and Physiology, Skåne University Hospital and Professor Pia Maly Sundgren, as the representative of the Academy. With the challenging task to balance the clinical reality and research with very limited resources you have to stretch the priorities quite often and find creative solutions. I thank you for the support you have given me and with the finalized thesis in your hands, I hope you find it worth the effort. I thank Anette Persson and Annika Törling-Ring for secretarial assistance.

Nastaran Monsef, Department of Patology, Skåne University Hospital Lund now working in Linköping. I thank you for the generous help with the pathology and the interest in it you have given me. I miss having you around.

Professor Emeritus Anders Lunderquist, I thank for the help in sorting out the porcine anatomy in the most pleasant way.

Assoc. Prof. Roger Hesselstrand, Rheumatology Department, Skåne University Hospital Lund, who early on attached me to research resulting in several mutual publications. I thank you for encouraging and advising me wisely, never lacking humour towards research and not least the financial support on behalf of the Lund Scleroderma Research Group.

Kristina Vult von Steyern, dear friend and mate in research and clinic, for your great support during our mutual journey with lots of shared joy but also comfort in times of setbacks.

The indispensable research assistants at Igelösa Life Science AB and radiographers from my own department: Ann-Charlott Ragnar, Ljubica Dragarska, Nawroz

Chaomar, Yamuhela Binhayimahamanaing and Fatana Asalati for your substantial help with the experimental CT examinations.

Many thanks for helping with data collecting to Scandiatransplant and Eurotransplant, the transplantation coordinators Evamarie Braf in Lund, and Fatma Bergquist in Göteborg and Marie Omnell Persson, Head of Transplant Coordinators unit in Malmö. Sincere thanks to Assoc. Prof. Are Martin Holm, Consultant Pulmonologist, Medical Faculty, Oslo University, Norway for the help with data collecting and for sharing valuable thoughts in doing so. A warm thank you to my dear colleagues from the Transplantations team in Lund for a constructive and open-hearted collaboration.

With HRCT being the core of my work I wanted it to have a prominent part in my thesis. Tracing the upcoming of the method, however, came to be something of a challenge. Beyond Dr Todo's introduction of it in Japanese with a modest summary in English in 1982, there is little to be found in the literature. After a long and fruitless search I thought I had drawn a blank. I'm glad I hadn't. For that I have to thank Professor David M. Hansell, Royal Brompton Hospital, London, UK, who always and unmistakably points out the right direction and Professor Takeshi Johkoh, Kinki Central Hospital of Mutual Aid Association of Public School Teachers, Hyogo, Japan, who kindly took the time and introduced me to Professor Harumi Itoh, University of Fukui, Japan, the pioneer of HRCT and co-author of the earliest paper from 1982. Deeply honoured and with profound gratitude I acknowledge the generosity of Professor Itoh, who most wonderfully shared his experience, filling in the missing pieces. あなたへの私の最も深い感謝

In searching for the history I have also had the generous assistance from many others, whom I sincerely thank: Assoc. Prof. Andreas Nordberg, Department of Ethnology, History of Religion and Gender studies at Stockholm University for the help with the Norse mythology, Professor Harald Gaski, Department of Sami literature, University of Tromsø, Norway, for the help with the Sami mythology, Assoc. Prof. Jan Otto Solem, Professor Stig Steen, Departments of Thoracic Surgery and Senior Consultant Leif Eriksson PhD, Respiratory Medicine, Ystad Hospital, for so generously sharing the insights of the development of lung transplantation in Lund, Vesna Arsić, M. Sc, Physicist, Radioecology Department, Serbian Institute of Occupational Health, Belgrade, Serbia, for the enthusiasm and invaluable assistance with medical physics, Professor Norbert Pelc, Radiology Department, Stanford University, USA, for clarifying the development of bone filters, Dr Alaa Abdulahad, Department of Thoracic Surgery, Skåne University Hospital, Lund for assistance in translating part of Ibn Sina's work from medieval Arabic, my friends from my Italian evening course for the joint effort in translating the chapters about the "unmerceneries" from Biblioteca Sanctorum. I would also like to thank the many

people involved in finding images and permitting me to use them as presented in the historical retrospect of my thesis.

My sincere gratitude for the financial support to Trolle-Wachtmeisters Stiftelse, Igelösa Life Science AB, Olle Olssons Stiftelse, The Lund Scleroderma Research Group, the Medical Faculty of Lund University and the Department of Medical Imaging and Physiology, Skåne University Hospital. It has made all the difference.

I am very fortunate to be surrounded by incredibly nice and inspiring people in my everyday clinical work at the Department of Medical Imaging and Physiology, Lund: colleagues, radiographers, nurses, secretaries, the charming ladies in the archive and the invaluable staff of our technical department, many of you helping me out innumerable times. What I appreciate most is the easy access to our mutual competences. My deepest gratitude to all of you.

Kaori Murata I thank for translating the first published pulmonary HRCT paper from Japanese, Johan Olausson for helping me adjusting the CT protocols for donor evaluation (just waiting to be implemented!) and Ola Lindgren for a never fading enthusiasm and interest in my research.

My warmest thanks go to my own very much cherished section of Chest Radiology with present and past friends: Catharina Adlercreutz, Hanna Markstad, Lisa Ander-Olsson, Adrian Pisteu, Ellen Ostfeld, Sissal Clemmensen, Dariusz Slusarczyk, Lars Bååth, Anna Kahn, Hans Stridbeck and our unofficial member Isabel Goncalves. Thank you for your kind and generous support, understanding and enduring encouragement. With some of you always taking care of the clinical work while I have been engaged in my research I hope you will feel that the final result is a joint accomplishment that could not have been made without you.

Until recently, Chest and Abdomen were one section working closely together. Although no longer so, we still in many ways work as if we were. Therefore a sincere thanks go to all my dear colleagues and friends at the section of Abdominal Radiology who have been following me closely and encouraged me kind-heartedly. In particular I want to thank Richard Stagen for introducing me to Stig's exciting world, the "Grand Ladies" Kerstin Malmgren, Kerstin Lyttkens and Eva-Cecilia Salmonson for so generously supporting me with their vast experience and Zoran Mijović, dear colleague and the best of friends one could ever wish for.

From a more personal prospective I would like to acknowledge:


Ljiljana Andrić and Per Sten Jørgensen, colleagues, mentors and friends from Belgrade and Gällivare who have shaped me into who I am professionally and given me a thorough base to stand on.

Monica Essén, my godmother for always lovingly standing by me.

Tuula Kareketo, Simona Petković and Biljana Petrušić, I thank for your generous love and unfailing, rock solid support. Many thanks to all my friends for the encouragement.

Ewa Tamme, my mother, my sisters Helena, Paulina and Lara for love and support and foremost my lovely nieces Sofia and Emma and my special family member Mikael Miksu Kareketo for their ability to instantly put the perspective right.

Томислав Милорада Божовић, my father for your love and for always trusting me capable to manage any challenge.



Refereces

1. Matevossian E, Kern H, Huser N, Doll D, Snopok Y, Nahrig J, et al. Surgeon Yurii Voronoy (1895-1961) - a pioneer in the history of clinical transplantation: in memoriam at the 75th anniversary of the first human kidney transplantation. *Transplant international : official journal of the European Society for Organ Transplantation*. 2009;22(12):1132-9.
2. Hamilton D. *A History of Organ Transplantation*. Pittsburgh: University of Pittsburgh Press; 2012.
3. Bruzzone P. Religious aspects of organ transplantation. *Transplantation proceedings*. 2008;40(4):1064-7.
4. Utredningar SO. *Betänkande av Utredning av donations- och transplantationsfrågor*. 2015 Contract No.: SOU 2015:84.
5. Bhishagratna KKL. *An English translation of the Sushruta samhita, based on original Sanskrit text*. Calcutta: Kaviraj Kunja Lal Bhishagratna.; 1911.
6. Baeksted A. *Nordiska gudar och hjältar*: Forum Stockholm; 1997.
7. Qvigstad J. *Lappiske eventyr og sagn*. 1928;Vol. II, *Story of Anders Nilsen, Balsfjord recorded in 1888*:2-8.
8. Pontificia Università Lateranense. Istituto Giovanni XXIII. *Biblioteca Sanctorum*. Roma 1961-1970. p. 223-38.
9. Colombo D, Ammirati E. Cyclosporine in transplantation - a history of converging timelines. *Journal of biological regulators and homeostatic agents*. 2011;25(4):493-504.
10. Hardy JD, Webb WR, Dalton ML, Jr., Walker GR, Jr. Lung Homotransplantation in Man. *Jama*. 1963;186:1065-74.
11. Unilateral lung transplantation for pulmonary fibrosis. Toronto Lung Transplant Group. *The New England journal of medicine*. 1986;314(18):1140-5.
12. Orens JB, Boehler A, de Perrot M, Estenne M, Glanville AR, Keshavjee S, et al. A review of lung transplant donor acceptability criteria. *The Journal of heart and lung transplantation : the official publication of the International Society for Heart Transplantation*. 2003;22(11):1183-200.
13. Global Observatory on Donation and Transplantation, 2016. Summary. <http://www.transplant-observatory.org/summary/> [cited 2016 September, 1].
14. Steen S, Sjöberg T, Pierre L, Liao Q, Eriksson L, Algotsson L. Transplantation of lungs from a non-heart-beating donor. *Lancet*. 2001;357(9259):825-9.

15. Wierup P, Haraldsson A, Nilsson F, Pierre L, Schersten H, Silverborn M, et al. Ex vivo evaluation of nonacceptable donor lungs. *The Annals of thoracic surgery*. 2006;81(2):460-6.
16. Yusen RD, Edwards LB, Kucheryavaya AY, Benden C, Dipchand AI, Goldfarb SB, et al. The Registry of the International Society for Heart and Lung Transplantation: Thirty-second Official Adult Lung and Heart-Lung Transplantation Report--2015; Focus Theme: Early Graft Failure. *The Journal of heart and lung transplantation : the official publication of the International Society for Heart Transplantation*. 2015;34(10):1264-77.
17. International Society for Heart and Lung Transplantation. Survival Rates for Transplants performed between October 1, 2010 and September 30, 2014 https://www.ishlt.org/registries/quarterlyDataReportResults.asp?organ=LU&rptType=recip_p_surv&continent=32016 [cited 2016 September, 10].
18. Lodhi SA, Lamb KE, Meier-Kriesche HU. Solid organ allograft survival improvement in the United States: the long-term does not mirror the dramatic short-term success. *American journal of transplantation : official journal of the American Society of Transplantation and the American Society of Transplant Surgeons*. 2011;11(6):1226-35.
19. International Society of Heart and Lung Transplantation. 2015. Registries. <http://www.ishlt.org/registries/slides.asp?slides=heartLungRegistry> [cited 2016 September 6].
20. U.S: National Library of Medicine. An Ancient Medical Treasure at Your Fingertips. "The Edwin Smith Papyrus". 2010, reviewed 2013. https://www.nlm.nih.gov/news/turn_page_egyptian.html [cited 2016 May 10].
21. Masic I. Thousand-year anniversary of the historical book: "Kitab al-Qanun fit-Tibb"- The Canon of Medicine, written by Abdullah ibn Sina. *Journal of research in medical sciences : the official journal of Isfahan University of Medical Sciences*. 2012;17(11):993-1000.
22. Mavrodi A, Paraskevas G. Mondino de Luzzi: a luminous figure in the darkness of the Middle Ages. *Croatian medical journal*. 2014;55(1):50-3.
23. Jones R. Leonardo da Vinci: anatomist. *The British journal of general practice : the journal of the Royal College of General Practitioners*. 2012;62(599):319.
24. Diamantis A, Magiorkinis E, Androutsos G. Alfred Francois Donne (1801-78): a pioneer of microscopy, microbiology and haematology. *Journal of medical biography*. 2009;17(2):81-7.
25. Rosenow UF. Notes on the legacy of the Rontgen rays. *Medical physics*. 1995;22(11 Pt 2):1855-67.
26. Eisenberg RL. *Radiology An Illustrated History*: Mosby-Year Book Inc.; 1992.
27. Williams FH. *Notes on X-rays in medicine*. Boston: Transactions of the Association of American Physicians; 1896.
28. Williams FH. *The Roentgen Rays in Medicine and Surgery*. London: FB &c Ltd, Dalton House; 1901, reprint 2015.

29. United Nations Scientific Committee on Sources and Effects of Ionizing Radiation. 2000. http://www.unscear.org/docs/publications/2000/UNSCEAR_2000_Annex-D.pdf [cited 2016 October 20].
30. Tondreau RL. The retrospectoscope. Egas Moniz 1874-1955. Radiographics : a review publication of the Radiological Society of North America, Inc. 1985;5(6):994-7.
31. dos Santos Silva I, Malveiro F, Jones ME, Swerdlow AJ. Mortality after radiological investigation with radioactive Thorotrast: a follow-up study of up to fifty years in Portugal. Radiation research. 2003;159(4):521-34.
32. Flodmark O, Greitz T. Obituary. Sven-ivar seldinger. Interventional neuroradiology : journal of peritherapeutic neuroradiology, surgical procedures and related neurosciences. 1999;5(1):9-10.
33. Westling H. Torsten Almén och idén till ett nytt röntgenkontrastmedel http://www.med.lu.se/english/about_the_faculty/history_of_the_faculty/personalities_discoveries_and_innovations/torsten_almen: Medicinska Fakulteten, Lunds Universitet; 2005 [Accessed January, 13 2016].
34. Edler I HC. The use of ultrasonic reflectoscope for the continuous recording of the movements of heart walls. Kungl. Fysiografiska Sällskapet i Lund Förhandlingar 1954; 24: 1–19.: 1954.
35. Barskova T, Gargani L, Guiducci S, Randone SB, Bruni C, Carnesecchi G, et al. Lung ultrasound for the screening of interstitial lung disease in very early systemic sclerosis. Annals of the rheumatic diseases. 2013;72(3):390-5.
36. Bracewell RN. Two-dimensional Aerial Smoothing in Radio Astronomy. Aust J Phys. 1956(9):297-314.
37. Thelegraph T. Sir Godfrey Hounsfield <http://www.telegraph.co.uk/news/obituaries/1469553/Sir-Godfrey-Hounsfield.html>: The Telegraph; 2004 [updated 2016-02-10; cited 2016 January, 13].
38. Cormack AM. Nobel Banquet Speech http://www.nobelprize.org/nobel_prizes/medicine/laureates/1979/cormack-speech.html1979 [cited 2015 April, 15].
39. Global Industry Analysts. 2011. CT scanners. http://www.prweb.com/releases/computed_tomography/CT_scanners/prweb8075828.htm [cited 2016 January 13].
40. The Nobel Foundation. 1979. Godfrey Hounsfield Nobel Laureate Lecture. http://www.nobelprize.org/nobel_prizes/medicine/laureates/1979/hounsfield-lecture.pdf [cited 2016 July 12].
41. Pelc N, J., Glover, G., H., Griffie, T., R., Acharya, K., C. A higher resolution reconstruction algorithm for third generation CT systems. 65th Annual Meeting of the RSNA; Atlanta, USA, Nov. 25-30 1979.
42. Lloyd GA, du Boulay GH, Phelps PD, Pullicino P. The demonstration of the auditory ossicles by high resolution CT. Neuroradiology. 1979;18(5):243-8.
43. Shaffer KA, Haughton V M, Wilson C R. High resolution computed tomography of the temporal bone. Radiology. 1980;134(2):409-14.

44. Itoh H, Tokunaga S, Asamoto H, Furuta M, Funamoto Y, Kitaichi M, et al. Radiologic-pathologic correlations of small lung nodules with special reference to peribronchiolar nodules. *AJR American journal of roentgenology*. 1978;130(2):223-31.
45. Todo G, Ito H, Nakano Y, Dodo Y, Maeda H, Murata K, et al. [High resolution CT (HR-CT) for the evaluation of pulmonary peripheral disorders]. *Rinsho hoshasen Clinical radiography*. 1982;27(12):1319-26.
46. Muller NL, Miller RR. Computed tomography of chronic diffuse infiltrative lung disease. Part 1. *The American review of respiratory disease*. 1990;142(5):1206-15.
47. Muller NL, Miller RR. Computed tomography of chronic diffuse infiltrative lung disease. Part 2. *The American review of respiratory disease*. 1990;142(6 Pt 1):1440-8.
48. Murata K, Itoh H, Todo G, Kanaoka M, Noma S, Itoh T, et al. Centrilobular lesions of the lung: demonstration by high-resolution CT and pathologic correlation. *Radiology*. 1986;161(3):641-5.
49. Zerhouni EA, Naidich DP, Stitik FP, Khouri NF, Siegelman SS. Computed tomography of the pulmonary parenchyma. Part 2: Interstitial disease. *Journal of thoracic imaging*. 1985;1(1):54-64.
50. Walsh SL, Hansell DM. High-resolution CT of interstitial lung disease: a continuous evolution. *Seminars in respiratory and critical care medicine*. 2014;35(1):129-44.
51. Kakinuma R, Moriyama N, Muramatsu Y, Gomi S, Suzuki M, Nagasawa H, et al. Ultra-High-Resolution Computed Tomography of the Lung: Image Quality of a Prototype Scanner. *PloS one*. 2015;10(9):e0137165.
52. Kakinuma R, Moriyama N, Muramatsu Y, Gomi S, Suzuki M, Nagasawa H, et al. Correction: Ultra-High-Resolution Computed Tomography of the Lung: Image Quality of a Prototype Scanner. *PloS one*. 2015;10(12):e0145357.
53. Јовановић Б. Тесла - дух, дело, визија: Београд : Freemental; 2001.
54. Eichinger M, Heussel CP, Kauczor HU, Tiddens H, Puderbach M. Computed tomography and magnetic resonance imaging in cystic fibrosis lung disease. *Journal of magnetic resonance imaging : JMRI*. 2010;32(6):1370-8.
55. Wielputz MO, Puderbach M, Kopp-Schneider A, Stahl M, Fritzsche E, Sommerburg O, et al. Magnetic resonance imaging detects changes in structure and perfusion, and response to therapy in early cystic fibrosis lung disease. *American journal of respiratory and critical care medicine*. 2014;189(8):956-65.
56. Yi CA, Lee KS, Han J, Chung MP, Chung MJ, Shin KM. 3-T MRI for differentiating inflammation- and fibrosis-predominant lesions of usual and nonspecific interstitial pneumonia: comparison study with pathologic correlation. *AJR American journal of roentgenology*. 2008;190(4):878-85.
57. Resonance M. Facts and Figures <http://www.magnetic-resonance.org/ch/21-01.html>2016 [cited 2016 May, 16].
58. Townsend DW, Beyer T. A combined PET/CT scanner: the path to true image fusion. *The British journal of radiology*. 2002;75 Spec No:S24-30.

59. Codellas PS. Alcmaeon of Croton: His Life, Work, and Fragments. *Journal of the Royal Society of Medicine*. 1932;25(7):1041–6.
60. Thompson DAW. *On Aristotle as a Biologist*. Oxford: Clarendon press; 1913.
61. von Staden H. The discovery of the body: human dissection and its cultural contexts in ancient Greece. *Yale J Biol Med*. 1992, May-Jun;65(3):223-41.
62. Abdel-Halim RE. Contributions of Ibn Zuhr (Avenzoar) to the progress of surgery: a study and translations from his book *Al-Taisir*. *Saudi medical journal*. 2005;26(9):1333-9.
63. Franco NH. Animal Experiments in Biomedical Research: A Historical Perspective. *Animal*. 2013;3(1):238-73.
64. Jørgensen CB. August Krogh and Claude Bernard on Basic Principles in Experimental Physiology. *Oxford Journals BioScience*. 2001;Volume 51 (Issue 1):Pp. 59-61.
65. Bentham J. *An Introduction to the Principles of Morals and Legislation*. <http://www.econlib.org/library/Bentham/bnthPML12.html#Chapter XII>, Of the Consequences of a Mischievous Act: Oxford: Clarendom Press; 1907.
66. Russell WMSaBRL. *The Principles of Humane Experimental Technique*: Methuen, London; 1959.
67. Hajar R. Animal testing and medicine. *Heart views : the official journal of the Gulf Heart Association*. 2011;12(1):42.
68. Moore N. Lessons from the fatal French study BIA-10-2474. *Bmj*. 2016;353:i2727.
69. Attarwala H. TGN1412: From Discovery to Disaster. *Journal of young pharmacists : JYP*. 2010;2(3):332-6.
70. Schultheiss D, Denil J, Jonas U. Rejuvenation in the early 20th century. *Andrologia*. 1997;29(6):351-5.
71. Editorial. New glands for old. *Lancet*. 1991;338(8779):1367.
72. Valdes-Gonzalez RA, Dorantes LM, Garibay GN, Bracho-Blanchet E, Mendez AJ, Davila-Perez R, et al. Xenotransplantation of porcine neonatal islets of Langerhans and Sertoli cells: a 4-year study. *European journal of endocrinology / European Federation of Endocrine Societies*. 2005;153(3):419-27.
73. Konstantinov I. At the cutting edge of the impossible: a tribute to Vladimir P. Demikhov. *Texas Heart Institue Journal*. 2009;36(5):453-8.
74. Langer RM. Vladimir P. Demikhov, a pioneer of organ transplantation. *Transplantation proceedings*. 2011;43(4):1221-2.
75. Sato M, Keshavjee S, Liu M. Translational research: animal models of obliterative bronchiolitis after lung transplantation. *American journal of transplantation : official journal of the American Society of Transplantation and the American Society of Transplant Surgeons*. 2009;9(9):1981-7.
76. Nobel Prizes AnimalResearch.Info. <http://www.animalresearch.info/en/medical-advances/nobel-prizes/> [cited 2016 May, 16].
77. Sprung CL, Cohen SL, Sjokvist P, Baras M, Bulow HH, Hovilehto S, et al. End-of-life practices in European intensive care units: the Ethicus Study. *Jama*. 2003;290(6):790-7.

78. Socialstyrelsen. 2005. Kriterier för bestämmande av människans död. SOSFS 2005:10 (M).
79. Samantaray A. Pulmonary aspiration of gastric contents: prevention and prophylaxis. *J Clin Sci Res.* 2014;2014;3:243-50.
80. Steen S, Ingemansson R, Eriksson L, Pierre L, Algotsson L, Wierup P, et al. First human transplantation of a nonacceptable donor lung after reconditioning ex vivo. *The Annals of thoracic surgery.* 2007;83(6):2191-4.
81. Davison DL, Terek M, Chawla LS. Neurogenic pulmonary edema. *Critical care.* 2012;16(2):212.
82. Wood KE, Becker BN, McCartney JG, D'Alessandro AM, Coursin DB. Care of the potential organ donor. *The New England journal of medicine.* 2004;351(26):2730-9.
83. Potter CD, Wheeldon DR, Wallwork J. Functional assessment and management of heart donors: a rationale for characterization and a guide to therapy. *The Journal of heart and lung transplantation : the official publication of the International Society for Heart Transplantation.* 1995;14(1 Pt 1):59-65.
84. Dictus C, Vienenkoetter B, Esmaeilzadeh M, Unterberg A, Ahmadi R. Critical care management of potential organ donors: our current standard. *Clinical transplantation.* 2009;23 Suppl 21:2-9.
85. McKeown DW, Bonser RS, Kellum JA. Management of the heartbeating brain-dead organ donor. *British journal of anaesthesia.* 2012;108 Suppl 1:96-107.
86. Snell GI, Paraskeva M, Westall GP. Donor selection and management. *Seminars in respiratory and critical care medicine.* 2013;34(3):361-70.
87. Taghavi S, Jayarajan S, Komaroff E, Horai T, Brann S, Cordova F, et al. Double-lung transplantation can be safely performed using donors with heavy smoking history. *The Annals of thoracic surgery.* 2013;95(6):1912-7; discussion 7-8.
88. Ingemansson R, Eyjolfsson A, Mared L, Pierre L, Algotsson L, Ekmehag B, et al. Clinical transplantation of initially rejected donor lungs after reconditioning ex vivo. *The Annals of thoracic surgery.* 2009;87(1):255-60.
89. Cypel M, Yeung JC, Liu M, Anraku M, Chen F, Karolak W, et al. Normothermic ex vivo lung perfusion in clinical lung transplantation. *The New England journal of medicine.* 2011;364(15):1431-40.
90. Wallinder A, Ricksten SE, Hansson C, Riise GC, Silverborn M, Liden H, et al. Transplantation of initially rejected donor lungs after ex vivo lung perfusion. *The Journal of thoracic and cardiovascular surgery.* 2012;144(5):1222-8.
91. Chaney J, Suzuki Y, Cantu E, 3rd, van Berkel V. Lung donor selection criteria. *Journal of thoracic disease.* 2014;6(8):1032-8.
92. Sommer W, Kuhn C, Tudorache I, Avsar M, Gottlieb J, Boethig D, et al. Extended criteria donor lungs and clinical outcome: results of an alternative allocation algorithm. *The Journal of heart and lung transplantation : the official publication of the International Society for Heart Transplantation.* 2013;32(11):1065-72.
93. Pierre AF, Sekine Y, Hutcheon MA, Waddell TK, Keshavjee SH. Marginal donor lungs: a reassessment. *The Journal of thoracic and cardiovascular surgery.* 2002;123(3):421-7; discussion, 7-8.

94. Powner DJ, Biebuyck JC. Introduction to the interpretation of chest radiographs during donor care. *Progress in transplantation*. 2005;15(3):240-8.
95. Mehrotra P, Bosemani V, Cox J. Do radiologists still need to report chest x rays? *Postgraduate medical journal*. 2009;85(1005):339-41.
96. Kaufman B, Dhar P, O'Neill DK, Leitman B, Fermon CM, Wahlander SB, et al. Chest radiograph interpretation skills of anesthesiologists. *Journal of cardiothoracic and vascular anesthesia*. 2001;15(6):680-3.
97. Galina V, Nesterova M, Clifton A, Leftridge Jr, MD, Aruna R, Natarajan, MD, PhD, Heidi J. Appel, MD, Maria V. Bautista, MD, Gabriel J. Hauser, MD. Discordance in interpretation of chest radiographs between pediatric intensivists and a radiologist: Impact on patient management. *Journal of critical care*. 2010;25(2):179-83.
98. Grosvenor LJ VR, O'Brien R, Entwisle JJ, Finlay D. Does reporting of plain chest radiographs affect the immediate management of patients admitted to a medical assessment unit? *Clin Radiol*. 2003; Sep;58(9):719-22.
99. Mirvis SE, Tobin KD, Kostrubiak I, Belzberg H. Thoracic CT in detecting occult disease in critically ill patients. *AJR American journal of roentgenology*. 1987;148(4):685-9.
100. Hurst JM, Davis K, Jr., Johnson DJ, Branson RD, Campbell RS, Branson PS. Cost and complications during in-hospital transport of critically ill patients: a prospective cohort study. *The Journal of trauma*. 1992;33(4):582-5.
101. Tocino IM, Miller MH, Frederick PR, Bahr AL, Thomas F. CT detection of occult pneumothorax in head trauma. *AJR American journal of roentgenology*. 1984;143(5):987-90.
102. Henschke CI, Yankelevitz DF, Wand A, Davis SD, Shiao M. Accuracy and efficacy of chest radiography in the intensive care unit. *Radiologic clinics of North America*. 1996;34(1):21-31.
103. Self WH, Courtney DM, McNaughton CD, Wunderink RG, Kline JA. High discordance of chest x-ray and computed tomography for detection of pulmonary opacities in ED patients: implications for diagnosing pneumonia. *The American journal of emergency medicine*. 2013;31(2):401-5.
104. Chardoli M, Hasan-Ghaliiae T, Akbari H, Rahimi-Movaghar V. Accuracy of chest radiography versus chest computed tomography in hemodynamically stable patients with blunt chest trauma. *Chinese journal of traumatology = Zhonghua chuang shang za zhi*. 2013;16(6):351-4.
105. Meziane MA, Hruban RH, Zerhouni EA, Wheeler PS, Khouri NF, Fishman EK, et al. High resolution CT of the lung parenchyma with pathologic correlation. *Radiographics : a review publication of the Radiological Society of North America, Inc*. 1988;8(1):27-54.
106. Kazerooni EA. High-resolution CT of the lungs. *AJR American journal of roentgenology*. 2001;177(3):501-19.
107. Ng YL, Paul N, Patsios D, Walsham A, Chung TB, Keshavjee S, et al. Imaging of lung transplantation: review. *AJR American journal of roentgenology*. 2009;192(3 Suppl):S1-13, quiz S4-9.

108. Ahmad S, Shlobin OA, Nathan SD. Pulmonary complications of lung transplantation. *Chest*. 2011;139(2):402-11.
109. Adeloye D, Chua S, Lee C, Basquill C, Papan A, Theodoratou E, et al. Global and regional estimates of COPD prevalence: Systematic review and meta-analysis. *Journal of global health*. 2015;5(2):020415.
110. Ley B, Collard HR. Epidemiology of idiopathic pulmonary fibrosis. *Clinical epidemiology*. 2013;5:483-92.
111. Cheng TY, Cramb SM, Baade PD, Youlden DR, Nwogu C, Reid ME. The International Epidemiology of Lung Cancer: Latest Trends, Disparities, and Tumor Characteristics. *Journal of thoracic oncology : official publication of the International Association for the Study of Lung Cancer*. 2016;11(10):1653-71.
112. Purins K, Sedigh A, Molnar C, Jansson L, Korsgren O, Lorant T, et al. Standardized experimental brain death model for studies of intracranial dynamics, organ preservation, and organ transplantation in the pig. *Critical care medicine*. 2011;39(3):512-7.
113. Valenza F, Coppola S, Froio S, Ruggeri GM, Fumagalli J, Villa AM, et al. A standardized model of brain death, donor treatment, and lung transplantation for studies on organ preservation and reconditioning. *Intensive care medicine experimental*. 2014;2(1):12.
114. Todo G, Herman PG. High-resolution computed tomography of the pig lung. *Investigative radiology*. 1986;21(9):689-96.
115. Murata K, Herman PG, Khan A, Todo G, Pipman Y, Lubner JM. Intralobular distribution of oleic acid-induced pulmonary edema in the pig. Evaluation by high-resolution CT. *Investigative radiology*. 1989;24(9):647-53.
116. Matute-Bello G, Frevert CW, Martin TR. Animal models of acute lung injury. *American journal of physiology Lung cellular and molecular physiology*. 2008;295(3):L379-99.
117. Shumway SJ, Hertz MI, Petty MG, Bolman RM, 3rd. Liberalization of donor criteria in lung and heart-lung transplantation. *The Annals of thoracic surgery*. 1994;57(1):92-5.
118. Gabbay E, Williams TJ, Griffiths AP, Macfarlane LM, Kotsimbos TC, Esmore DS, et al. Maximizing the utilization of donor organs offered for lung transplantation. *American journal of respiratory and critical care medicine*. 1999;160(1):265-71.
119. Bhorade SM, Vigneswaran W, McCabe MA, Garrity ER. Liberalization of donor criteria may expand the donor pool without adverse consequence in lung transplantation. *The Journal of heart and lung transplantation : the official publication of the International Society for Heart Transplantation*. 2000;19(12):1199-204.
120. CT scan Proposal 3.7.12.4 [Internet]. 2011-03-11.
121. Gluecker T, Capasso P, Schnyder P, Gudinchet F, Schaller MD, Revelly JP, et al. Clinical and radiologic features of pulmonary edema. *Radiographics : a review publication of the Radiological Society of North America, Inc*. 1999;19(6):1507-31; discussion 32-3.

122. Storto ML, Kee ST, Golden JA, Webb WR. Hydrostatic pulmonary edema: high-resolution CT findings. *AJR American journal of roentgenology*. 1995;165(4):817-20.
123. David M Hansell DAL, H Page McAdams, Alexander A Bankier. *Imaging of Diseases of the Chest*: Mosby Elsevier; 2010.
124. Robertson BJ, Hansell DM. Organizing pneumonia: a kaleidoscope of concepts and morphologies. *European radiology*. 2011;21(11):2244-54.
125. Hansell DM, Bankier AA, MacMahon H, McLoud TC, Muller NL, Remy J. Fleischner Society: glossary of terms for thoracic imaging. *Radiology*. 2008;246(3):697-722.
126. Khan AN, Al-Jahdali H, Al-Ghanem S, Gouda A. Reading chest radiographs in the critically ill (Part II): Radiography of lung pathologies common in the ICU patient. *Annals of thoracic medicine*. 2009;4(3):149-57.
127. Hyatt RE, Bar-Yishay E, Abel MD. Influence of the heart on the vertical gradient of transpulmonary pressure in dogs. *Journal of applied physiology*. 1985;58(1):52-7.
128. Malbouisson LM, Busch CJ, Puybasset L, Lu Q, Cluzel P, Rouby JJ. Role of the heart in the loss of aeration characterizing lower lobes in acute respiratory distress syndrome. *CT Scan ARDS Study Group. American journal of respiratory and critical care medicine*. 2000;161(6):2005-12.
129. Schaefer-Prokop C. *Critical Care Radiology*: Georg Thieme Verlag, Rudigerstrasse 14, 70469, Stuttgart, Germany; 2011.
130. Cardinale L, Priola AM, Moretti F, Volpicelli G. Effectiveness of chest radiography, lung ultrasound and thoracic computed tomography in the diagnosis of congestive heart failure. *World journal of radiology*. 2014;6(6):230-7.
131. Milne EN, Pistoletti M, Miniati M, Giuntini C. The radiologic distinction of cardiogenic and noncardiogenic edema. *AJR American journal of roentgenology*. 1985;144(5):879-94.
132. Beigelman-Aubry C, Godet C, Caumes E. Lung infections: the radiologist's perspective. *Diagnostic and interventional imaging*. 2012;93(6):431-40.
133. Walker CM, Abbott GF, Greene RE, Shepard JA, Vummidi D, Digumarthy SR. Imaging pulmonary infection: classic signs and patterns. *AJR American journal of roentgenology*. 2014;202(3):479-92.
134. Franquet T, Gimenez A, Roson N, Torrubia S, Sabate JM, Perez C. Aspiration diseases: findings, pitfalls, and differential diagnosis. *Radiographics : a review publication of the Radiological Society of North America, Inc*. 2000;20(3):673-85.
135. Komiyama K, Ishii H, Umeki K, Kawamura T, Okada F, Okabe E, et al. Computed tomography findings of aspiration pneumonia in 53 patients. *Geriatrics & gerontology international*. 2013;13(3):580-5.
136. Khan A. ACR Appropriateness Criteria on solitary pulmonary nodule. *Journal of the American College of Radiology : JACR*. 2007;4(3):152-5.
137. Shaham D, Vazquez M, Bogot NR, Henschke CI, Yankelevitz DF. CT features of intrapulmonary lymph nodes confirmed by cytology. *Clinical imaging*. 2010;34(3):185-90.

138. Hyodo T, Kanazawa S, Dendo S, Kobayashi K, Hayashi H, Kouno Y, et al. Intrapulmonary lymph nodes: thin-section CT findings, pathological findings, and CT differential diagnosis from pulmonary metastatic nodules. *Acta medica Okayama*. 2004;58(5):235-40.
139. Kuzo RS, Goodman LR. CT evaluation of pulmonary embolism: technique and interpretation. *AJR American journal of roentgenology*. 1997;169(4):959-65.
140. Wittram C, Maher MM, Yoo AJ, Kalra MK, Shepard JA, McLoud TC. CT angiography of pulmonary embolism: diagnostic criteria and causes of misdiagnosis. *Radiographics : a review publication of the Radiological Society of North America, Inc.* 2004;24(5):1219-38.
141. Bozovic G, Adlercreutz C, Höglund P, Björkman-Burtscher I, Reinstrup P, Ingemansson I, et al. Imaging of the lungs in organ donors and its clinical relevance – a retrospective analysis *Journal of thoracic imaging*. 2016;Submitted.
142. Lungfunktion-Practice compendium for semester 6. Department of Medical Sciences, Clinical Physiology, Academic Hospital, Uppsala, Sweden. 2010.
143. Meyer KC, Raghu G, Verleden GM, Corris PA, Aurora P, Wilson KC, et al. An international ISHLT/ATS/ERS clinical practice guideline: diagnosis and management of bronchiolitis obliterans syndrome. *The European respiratory journal*. 2014;44(6):1479-503.
144. R Core Team. *A language and enviromental for statistical computing.*: Foundation for Statistical Computing Vienna, Austria; 2016.
145. Lowry R. <http://www.vassarstats.net/kappa.html> 2001-2016 [cited 2016 1st of October].
146. Barklin A, Larsson A, Vestergaard C, Koefoed-Nielsen J, Bach A, Nyboe R, et al. Does brain death induce a pro-inflammatory response at the organ level in a porcine model? *Acta anaesthesiologica Scandinavica*. 2008;52(5):621-7.
147. Barklin A, Larsson A, Vestergaard C, Kjaergaard A, Wogensen L, Schmitz O, et al. Insulin alters cytokine content in two pivotal organs after brain death: a porcine model. *Acta anaesthesiologica Scandinavica*. 2008;52(5):628-34.
148. Barklin A. Systemic inflammation in the brain-dead organ donor. *Acta anaesthesiologica Scandinavica*. 2009;53(4):425-35.
149. Barklin A. Systemic inflammation in the brain dead organ donor. PhD Dissertation.: Faculty of Health and Sciences, Aarhus University, Denmark; 2009.
150. Guyton AC HJ. *Textbook of medical physiology*, 11th edn. Philadelphia, PA.: Elsevier Saunders; 2006.
151. Steen S, Skarby TV, Norgren L, Andersson KE. Pharmacological characterization of postjunctional alpha-adrenoceptors in isolated human omental arteries and veins. *Acta physiologica Scandinavica*. 1984;120(1):109-16.
152. Steen S, Sjoberg T, Skarby TV, Norgren L, Andersson KE. Postjunctional alpha 1- and alpha 2-adrenoceptors mediating contraction in isolated human groin arteries and veins. *Acta physiologica Scandinavica*. 1984;122(3):323-9.
153. Steen S. Human vascular alpha-adrenoceptors. A study of peripheral arteries and veins in vitro and in vivo. Thesis.: Medical Faculty, Lund University.; 1984.

154. Stoica SC, Satchithananda DK, White PA, Parameshwar J, Redington AN, Large SR. Noradrenaline use in the human donor and relationship with load-independent right ventricular contractility. *Transplantation*. 2004;78(8):1193-7.
155. Stehlik J, Feldman DS, Brown RN, VanBakel AB, Russel SD, Ewald GA, et al. Interactions among donor characteristics influence post-transplant survival: a multi-institutional analysis. *The Journal of heart and lung transplantation : the official publication of the International Society for Heart Transplantation*. 2010;29(3):291-8.
156. Yoshioka T, Sugimoto H, Uenishi M, Sakamoto T, Sadamitsu D, Sakano T, et al. Prolonged hemodynamic maintenance by the combined administration of vasopressin and epinephrine in brain death: a clinical study. *Neurosurgery*. 1986;18(5):565-7.
157. Barklin A, Theodorsson E, Tyvold SS, Larsson A, Granfeldt A, Sloth E, et al. Alteration of neuropeptides in the lung tissue correlates brain death-induced neurogenic edema. *The Journal of heart and lung transplantation : the official publication of the International Society for Heart Transplantation*. 2009;28(7):725-32.
158. Dondelinger RF, Ghysels MP, Brisbois D, Donkers E, Snaps FR, Saunders J, et al. Relevant radiological anatomy of the pig as a training model in interventional radiology. *European radiology*. 1998;8(7):1254-73.
159. Duong PA, Ferson PF, Fuhrman CR, McCurry KR, Lacomis JM. 3D-multidetector CT angiography in the evaluation of potential donors for living donor lung transplantation. *Journal of thoracic imaging*. 2005;20(1):17-23.
160. Chen F, Kubo T, Shoji T, Fujinaga T, Bando T, Date H. Comparison of pulmonary function test and computed tomography volumetry in living lung donors. *The Journal of heart and lung transplantation : the official publication of the International Society for Heart Transplantation*. 2011;30(5):572-5.
161. Kockelkorn TT, Schaefer-Prokop CM, Bozovic G, Munoz-Barrutia A, van Rikxoort EM, Brown MS, et al. Interactive lung segmentation in abnormal human and animal chest CT scans. *Medical physics*. 2014;41(8):081915.
162. Teramoto S, Ishii T, Yamamoto H, Yamaguchi Y, Ouchi Y. Nasogastric tube feeding is a cause of aspiration pneumonia in ventilated patients. *The European respiratory journal*. 2006;27(2):436-7; author reply 7-8.
163. Milsom SA, Sweeting JA, Sheahan H, Haemmerle E, Windsor JA. Naso-enteric Tube Placement: A Review of Methods to Confirm Tip Location, Global Applicability and Requirements. *World journal of surgery*. 2015;39(9):2243-52.
164. Bentz MR, Primack SL. Intensive care unit imaging. *Clinics in chest medicine*. 2015;36(2):219-34, viii.
165. Wiener MD, Garay SM, Leitman BS, Wiener DN, Ravin CE. Imaging of the intensive care unit patient. *Clinics in chest medicine*. 1991;12(1):169-98.
166. Trotman-Dickenson B. Radiology in the intensive care unit (part 2). *Journal of intensive care medicine*. 2003;18(5):239-52.
167. Kutsogiannis DJ, Asthana S, Townsend DR, Singh G, Karvellas CJ. The incidence of potential missed organ donors in intensive care units and emergency rooms: a retrospective cohort. *Intensive care medicine*. 2013;39(8):1452-9.

168. Lumbreras B, Donat L, Hernandez-Aguado I. Incidental findings in imaging diagnostic tests: a systematic review. *The British journal of radiology*. 2010;83(988):276-89.
169. MacMahon H, Austin JH, Gamsu G, Herold CJ, Jett JR, Naidich DP, et al. Guidelines for management of small pulmonary nodules detected on CT scans: a statement from the Fleischner Society. *Radiology*. 2005;237(2):395-400.
170. Gatt ME, Spectre G, Paltiel O, Hiller N, Stalnikowicz R. Chest radiographs in the emergency department: is the radiologist really necessary? *Postgraduate medical journal*. 2003;79(930):214-7.
171. Bolton JS, Padia SA, Borja MC, Becker P, Orens JB, Wiener C, et al. The predictive value and inter-observer variability of donor chest radiograph interpretation in lung transplantation. *European journal of cardio-thoracic surgery : official journal of the European Association for Cardio-thoracic Surgery*. 2003;23(4):484-7.
172. Eisen LA, Berger JS, Hegde A, Schneider RF. Competency in chest radiography. A comparison of medical students, residents, and fellows. *Journal of general internal medicine*. 2006;21(5):460-5.
173. Satia I, Bashagha S, Bibi A, Ahmed R, Mellor S, Zaman F. Assessing the accuracy and certainty in interpreting chest X-rays in the medical division. *Clinical medicine*. 2013;13(4):349-52.
174. Backhus LM, Mulligan MS, Ha R, Shriki JE, Mohammed TL. Imaging in Lung Transplantation: Surgical Considerations of Donor and Recipient. *Radiologic clinics of North America*. 2016;54(2):339-53.
175. Potchen EJ, Cooper TG, Sierra AE, Aben GR, Potchen MJ, Potter MG, et al. Measuring performance in chest radiography. *Radiology*. 2000;217(2):456-9.
176. Alvarez A, Moreno P, Espinosa D, Santos F, Illana J, Algar FJ, et al. Assessment of lungs for transplantation: a stepwise analysis of 476 donors. *European journal of cardio-thoracic surgery : official journal of the European Association for Cardio-thoracic Surgery*. 2010;37(2):432-9.
177. Rana A, Gruessner A, Agopian VG, Khalpey Z, Riaz IB, Kaplan B, et al. Survival benefit of solid-organ transplant in the United States. *JAMA surgery*. 2015;150(3):252-9.

