



LUND UNIVERSITY

Discrimination of ST deviation caused by acute coronary occlusion from normal variants and other abnormal conditions, using computed electrocardiographic imaging based on 12-lead ECG.

Akil, Shahnaz; Al-Mashat, Mariam; Hedén, Bo; Hedeer, Fredrik; Jögi, Jonas; Wang, John J; Wagner, Galen S; Warren, James W; Pahlm, Olle; Horáček, B Milan

Published in:
Journal of Electrocardiology

DOI:
[10.1016/j.jelectrocard.2013.02.013](https://doi.org/10.1016/j.jelectrocard.2013.02.013)

2013

[Link to publication](#)

Citation for published version (APA):

Akil, S., Al-Mashat, M., Hedén, B., Hedeer, F., Jögi, J., Wang, J. J., Wagner, G. S., Warren, J. W., Pahlm, O., & Horáček, B. M. (2013). Discrimination of ST deviation caused by acute coronary occlusion from normal variants and other abnormal conditions, using computed electrocardiographic imaging based on 12-lead ECG. *Journal of Electrocardiology*, 46(3), 197-203. <https://doi.org/10.1016/j.jelectrocard.2013.02.013>

Total number of authors:
10

General rights

Unless other specific re-use rights are stated the following general rights apply:
Copyright and moral rights for the publications made accessible in the public portal are retained by the authors and/or other copyright owners and it is a condition of accessing publications that users recognise and abide by the legal requirements associated with these rights.

- Users may download and print one copy of any publication from the public portal for the purpose of private study or research.
- You may not further distribute the material or use it for any profit-making activity or commercial gain
- You may freely distribute the URL identifying the publication in the public portal

Read more about Creative commons licenses: <https://creativecommons.org/licenses/>

Take down policy

If you believe that this document breaches copyright please contact us providing details, and we will remove access to the work immediately and investigate your claim.

LUND UNIVERSITY

PO Box 117
221 00 Lund
+46 46-222 00 00

Discrimination of ST deviation caused by acute coronary occlusion from normal variants and other abnormal conditions, using computed electrocardiographic imaging based on 12-lead ECG[☆]

Shahnaz Akil, MSc,^{a,1} Mariam Al-Mashat, MSc,^{a,1} Bo Hedén, MD, PhD,^a Fredrik Hedeer, MD,^a Jonas Jögi, MD, PhD,^a John J. Wang, MSc,^b Galen S. Wagner, MD,^c James W. Warren, BS,^d Olle Pahlm, MD PhD,^{a,*} B. Milan Horáček, PhD^d

^aDepartment of Clinical Physiology, University Hospital, Lund, Sweden ^bPhilips Healthcare, Andover, MA, USA ^cDepartment of Medicine, Duke University, Durham, NC, USA ^dDalhousie University, Halifax, NS, Canada

[☆] This study was partially supported by Philips Healthcare, Andover, MA, USA.

^{*} Corresponding author. Department of Clinical Physiology, University Hospital, SE-22185 Lund, Sweden.

E-mail address: olle.pahlm@med.lu.se ¹Shahnaz Akil and Mariam Al-Mashat contributed equally to this study.

Abstract

Background: Many graphical methods for displaying ST-segment deviation in the ECG have been tried for enhancing decision-making in patients with suspected acute coronary syndromes. Computed electrocardiographic imaging (CEI), based on a mathematical inverse solution, has been recently applied to transform ST-J point measurements made in conventional 12-lead ECG into a display of epicardial potentials in bull's-eye format. The purpose of this study is to assess utility of CEI in the clinical setting.

Methods: In 99 patients with stable coronary disease, 12-lead ECGs were recorded during elective percutaneous coronary intervention (PCI), first before balloon-catheter insertion and then when an intracoronary balloon blocked blood supply to a region of myocardium for more than 4 minutes (typically 5 minutes). Four groups of patients were additionally studied, namely those with preexcitation, pericarditis, early repolarization syndrome (ERS), and left ventricular hypertrophy (LVH) with strain. Comparisons between performances of published criteria for ST-elevation myocardial infarction (STEMI) and quantitative as well as visual assessment of CEI images were based on sensitivities and specificities.

Results: Visual assessment of CEI outperformed STEMI criteria. This was especially evident for the capability of detecting LCx occlusion with sensitivities for STEMI criteria = 35% and for visual assessment of CEI by 2 physicians = 71%, i. e. twice as many patients were correctly identified by CEI. False positive rates for CEI were low in patients with LVH with strain as well as with preexcitation for both methods. For pericarditis and ERS, visual as well as quantitative assessment of CEI performed better than STEMI criteria.

Conclusion: Visual assessment of CEI is a promising method for increasing the accuracy of ECG- based triage to PCI or conservative care.

Keywords:

12-lead ECG; Acute coronary occlusion; Computed electrocardiographic imaging; Epicardial potentials; ST deviation

Introduction

The 12-lead electrocardiogram (ECG) is a useful diagnostic tool for identifying the acute myocardial ischemia which can evolve to acute myocardial infarction (AMI). Impending AMI, caused by acute coronary artery occlusion, typically manifests itself in the ECG as ST-segment elevation or equivalent depression. Although these changes are typically termed ST-elevation myocardial infarction (STEMI), they appear during the acute ischemic process, while the myocardium remains protected by anaerobic metabolism from the necrosis that releases biochemical markers. At this time, biochemical markers, such as troponins, typically have not appeared in peripheral blood.

Detection of STEMI and so-called STEMI-equivalence (i.e. ST depression in V1-V3) that indicate acute transmural myocardial ischemia facilitates early diagnosis.^{1,2} In this way, treatment decisions and optimal triage to reperfusion therapy such as primary percutaneous coronary intervention, or administration of thrombolytic agents may occur early, potentially improving the patients' prognosis.^{3,4}

Currently, established "STEMI criteria" ¹ are typically applied to the 12-lead ECG to diagnose AMI, often in the ambulance. A limitation of these criteria is their focus only on the presence of a threshold amount of ST elevation, leading to falsely positive or negative diagnoses of the ST elevation that may be caused by occlusion of the left anterior descending (LAD) or right coronary artery (RCA), and misinterpretation of the ST depression caused by occlusion of the left circumflex (LCx).² STEMI criteria have proved to have both low sensitivity⁵ and specificity.^{6,7}

Several studies have suggested methods for improving the accuracy of the 12-lead ECG for diagnosing AMI using graphic tools.^{8–14} These are used for creating graphic displays that indicate ischemic myocardial areas with significant ST deviation. Two studies^{8,9} report that estimation of the size and localization of ischemic myocardium can be made from these displays. One study¹⁰ instead used derived ST-segment vectors¹⁵ to create either "Mercator plots" of myocardial-wall territories or alternatively "polar plots".

Andersen et al.¹¹ developed the "ST compass" method, visualizing ST deviations from the 12-lead ECG as 3-dimensional vectors projected onto two different displays, one illustrating the ST vector (direction and magnitude) in the frontal plane, the other one illustrating it in the transverse plane. A similar, but mathematically simpler approach was used by Nimmermark et al.¹² for creating "ST maps". These were considered to increase the sensitivity of detecting coronary artery occlusion compared to STEMI criteria.

Studies at Dalhousie University^{13,14} utilized the mathematical inverse solution¹⁶ to calculate epicardial surface potential maps from body surface potential maps (BSPM) estimated from the standard 12-lead ECG. The calculated maps were projected onto a 17-segment polar plot,¹⁷ reflecting the distribution of ST deviation in various regions of left ventricular myocardium. This method, termed "computed electrocardiographic imaging" (CEI), was cross-validated qualitatively using a small number of patients who received elective PCI as treatment of stable coronary artery disease. The CEI images were compared with myocardial-perfusion scintigraphic "gold-standard" images.¹¹ Good correspondence of these two imaging methods in reflecting acute ischemia was observed.

Among these various graphic methods, CEI is the most complex. However, it provides the

potential for deriving a clinically applicable method for “ECG imaging” of acute myocardial ischemia that can potentially evolve to infarction.

The primary aim of this study is to investigate the ability of both automated and visual assessment of CEI to distinguish ST-deviations caused by acute coronary occlusion from those that represent normal variation, and those caused by other pathophysiologic conditions.

Methods

Study populations

Patients receiving coronary balloon-occlusion

Twelve-lead ECGs were recorded digitally in 99 patients (63 males/36 females, age ≥ 60 years) who received elective PCI in the STAFF III study during 1995–1996 in Charleston, West Virginia.¹⁸ Written consent was obtained from the enrolled patients. Each patient had stable coronary artery disease with symptoms sufficiently severe to be scheduled for elective PCI. Each patient had 12-lead ECGs recorded continuously before inflation of the balloon, during prolonged complete balloon occlusion (typically exceeding 4 min), and after balloon deflation. ECG recordings from before the procedure were used to create a population with normal or normal-variant patterns. The ECGs recorded at the end of balloon inflation were used to create a population with acute coronary occlusion. The sampling rate was 1000 Hz.

Subjects with ST deviation, but no coronary occlusion

Twelve-lead ECGs of 78 patients (60 males/18 females, age range 12–83 years, average age 52 years) were retrieved from a centralized ECG management system at Skane University Hospital, Lund, Sweden. These ECGs were chosen to represent four subgroups with various causes of pathological ST-deviation, other than acute coronary occlusion: a) ventricular pre-excitation ($n = 12$), b) acute pericarditis ($n = 26$), c) “early repolarization syndrome” (ERS) ($n = 14$), and left ventricular hypertrophy (LVH) with “strain” ($n = 26$). Patient information was treated confidentially and the study was approved by Skåne University Hospital, Lund. To identify these study ECGs, specific keywords such as “suspected pericarditis” were searched among the computer-based interpretive statements in the ECG database. The likelihood for clinical relevance of the interpretive statement was further investigated by surveying the patient records. Verification of the specific ECG changes was performed by an experienced electrocardiographer (OP). ECGs with inadequate signal quality, heart rate exceeding 120 beats per minute and/or atrial flutter were not selected for this study population. The digital sampling rate was 500 Hz.

The characteristics of the various populations are summarized in [Table 1](#).

Application of STEMI criteria

The STEMI criteria used in this study for comparison with the diagnostic performance of CEI were the following 1 :

- The amplitude at the J point in both V2 and V3 $\geq 200 \mu\text{V}$ in men and $\geq 150 \mu\text{V}$ in women
- The amplitude at the J point in lead V1 $\geq 100 \mu\text{V}$ in both genders, and in lead V2 $\geq 200 \mu\text{V}$ in men and $\geq 150 \mu\text{V}$ in women
- The amplitude at the J point in lead V3 $\geq 200 \mu\text{V}$ in men and $\geq 150 \mu\text{V}$ in women, and in lead V4 $\geq 100 \mu\text{V}$ in both genders

- The amplitude at the J point in any of the contiguous lead pairs (V4, V5), (V5, V6), (aVL, I), (I, -aVR), (-aVR, II), (II, aVF), (aVF, III) $\geq 100 \mu\text{V}$ in both genders

N.B. (-aVR denotes the inverted lead aVR).

Data processing and computed electrocardiographic imaging (CEI)

Processing of the 276 ECGs was done at Dalhousie University (Halifax, NS, Canada) in the manner described earlier.^{13,14} In summary, body surface potential maps (BSPM) were developed from the 12-lead ECG using the method of Lux et al.¹⁹ From the BSPM, epicardial potential maps were then obtained by utilizing the mathematical inverse solution.¹⁶ Projections of the epicardial potentials onto 17-segment polar plots ("CEI images") were printed on paper as shown in Fig. 1.¹⁷

The intent of the CEI method is to produce images that exhibit typical patterns with contiguous areas of positive potentials on the epicardial surface, appearing in the anterior and septal regions for LAD, inferior region for RCA, and lateral region for LCx occlusion.

Quantitative analysis of CEI

For the quantitative analysis of the ability of the CEI in distinguishing between occlusion and non-occlusion using the maximum epicardial potential from each image, a receiver operating characteristic curve (ROC) was constructed.

Physician interpretation

The color patterns of the 276 CEI images were judged by 3 physicians who are experienced in interpreting standard ECGs and myocardial perfusion SPECT (single photon emission tomography) images, but not in making decisions for triage of patients with acute coronary syndromes. They were instructed to observe the pattern of the color-coded images to guide them to a positive or negative diagnosis of an acute occlusion of one of the 3 major coronary arteries.

CEI images and SPECT images are usually displayed using the same 17-segment polar plot model.¹⁷ The study populations and the methods for deriving and displaying CEI images were described to the physicians and discussed during a 1-hour tutorial session with one of the senior authors (OP). Fig. 2 provides typical examples of CEI images calculated from a normal ECG (baseline recording in patient before PCI) as well as from the different pathologies studied (coronary occlusion, preexcitation, pericarditis, ERS, and LVH with strain).

The images were judged individually by each physician who did not have access to the corresponding 12-lead ECGs. A case report form was used, on which the physician indicated the presence or absence of coronary occlusion suggested by each CEI image. The sensitivity and specificity of the visual assessment of CEI in distinguishing between occlusion and non-occlusion were calculated for each physician. Further, the abilities of the physicians to classify the non-ischemic ST deviation patterns correctly were assessed.

Results

Diagnosis of acute coronary occlusion

The color patterns of the CEI images from the STAFF III patients were viewed by the 3 physicians to determine the presence or absence of acute coronary occlusion. The sensitivities of 2 of the physicians for correctly identifying occlusion were high at 73% and 76% (Table 2), and compared favorably with the sensitivity of STEMI criteria (at 61%). The specificities of these 2 physicians for correctly identifying no occlusion were likewise high at 98% and 100% (Table 3), and similar to the specificity of STEMI criteria (96%). One of the physicians, however, had notably lower performance rates for both sensitivity (51%) and specificity (87%).

Quantitative analysis of CEI for diagnosis of coronary occlusion

Fig. 3 presents the above results in relation to an ROC curve based on the maximum epicardial potentials before and during prolonged acute coronary occlusion. The performance of the STEMI criteria indicated by an open circle coincidentally falls precisely on the ROC curve. Two of the physicians clearly outperform both the STEMI criteria and the quantitative analysis of the maximum epicardial potentials as expressed by the ROC curves.

Recognition of occlusion in the 3 major coronary arteries

Table 2 also reports sensitivities for physicians' visual assessment of CEI and for the automated STEMI criteria for identifying occlusion of each of the major coronary arteries. As expected, the STEMI criteria achieve a clear hierarchy: LAD (74%), RCA (60%), and LCX (35%); however, there is no corresponding hierarchy in observations of the physicians. There is higher performance of diagnosis of LAD occlusion by one physician (89%) and significant underdiagnosis of LAD occlusion by another physician (34%). For RCA occlusions, differences among physician performances and STEMI criteria were less marked. For LCx occlusion, however, all 3 physicians (at 71%, 71%, and 59%, respectively) clearly outperform STEMI criteria (at 35%).

Identifying absence of coronary occlusion

The ability of CEI images to identify patients with significant ST deviation but no acute myocardial ischemia was compared to the performance of STEMI criteria in the patients with preexcitation, pericarditis, early repolarization, and left ventricular hypertrophy (Table 3). For pericarditis and early repolarization, specificities of STEMI criteria were very low at only 8% and 29% respectively, while the other methods performed much better.

Discussion

The standard ECG serves as the primary test to support the decision for emergency reperfusion therapy for patients with the wide range of symptoms suggesting potentially reversible acute coronary thrombosis.²¹ Ideally, each patient would receive immediate evaluation of both their history and ECG by an experienced and expert clinician. However, in the current era, such experts are not always involved in the urgent process of acute reperfusion decision support.

The currently accepted criteria for STEMI are routinely used, but their limited sensitivity delays definitive treatment in many patients,⁶ and their limited specificity causes inappropriate activation of the cardiac catheterization laboratory for many others.⁷ When STEMI criteria are neither clearly present nor absent, additional leads could be applied;

however, their proper application requires accuracy. In this era there is generally poor performance in even the correct application of the standard leads. Also, valuable time is typically required for their application and interpretation. This study focuses on the diagnostic performance of

assessment of an automated method (CEI) for displaying the ST-segment data of the standard ECG that has now been developed for potential clinical application. This method is aimed at distinguishing between patients with ST-segment deviation associated with acute coronary occlusion and those not associated with occlusion. The overall sensitivities and specificities for both visual and quantitative assessment of CEI were compared to those of published STEMI criteria.¹

The sensitivity of STEMI criteria for identifying patients with acute coronary occlusion varies widely depending on the individual observer, but is recognized to be low.²⁰ Various automated algorithms have been developed in attempt to improve this performance.²¹ In this study, the sensitivity of STEMI criteria was equal to that of applying a threshold on the maximum epicardial potential in the CEI. Two of the physicians had substantially higher sensitivity when assessing the CEI images visually, while one physician had lower sensitivity. Performances differed among coronary occlusion sites. For both visual assessment of CEI and published STEMI criteria, performance was best in patients with LAD occlusion. The largest difference between methods was noted in LCx patients. In these patients twice as many were detected by visual assessment of CEI as with STEMI criteria. The sensitivity of STEMI criteria is particularly low in patients with LCx occlusion because ST segment deviation caused by transmural ischemia in the lateral left ventricular wall typically causes ST depression, rather than elevation, in the standard ECG leads.²² Indeed, the term “STEMI Equivalent” has been proposed to improve sensitivity. Methods for converting ST segment deviation to changes indicated by “ECG imaging” such as CEI, may be particularly valuable in maximizing sensitivity for detecting acute LCx occlusion.

There is clearly normal variation in the level of the ST segment relative to the TP segment baseline, and this was considered in the baseline recordings in the STAFF III patients prior to their intra-coronary intervention. Population studies have documented this variation, and their evidence that baseline ST elevation is particularly common in leads V1, V2, and V3 is the reason that the STEMI threshold of at least 0.2 mV elevation is required in these leads.²³ In this study, the quantitative CEI method did not achieve specificity beyond that of the STEMI criteria, and the visual assessment by 2 of the physicians. However, the lower level of performance by one of the physicians indicates the variation in visual performance, the level of which will require a dedicated future study.

The variation of the level of the ST segments is known to be increased in other pathological conditions such as the 4 included in the “non-ischemic” populations in this study.⁴ In general, the ST segments representing the “post-depolarization” condition are altered by the abnormal ventricular depolarization in cardiac abnormalities such as pre-excitation,

ventricular hypertrophy, and pericarditis.²⁴ Differentiation from the similarly appearing ST deviation of acute coronary occlusion could be potentially accomplished by observation of serial recordings. However, the length of time required to determine if evolutionary changes could “definitely rule out myocardial ischemia” would potentially lead to further extension of infarction within the ischemic area at risk.

There is variation in the level of the ST segment deviation in response to prolonged coronary occlusion in identical locations in different individuals. This can be attributed to the wide variation in collateral circulation in these patients with chronic ischemic heart disease.

Indeed, ST segment deviation from the TP segment baseline is the key ECG abnormality in the “early-repolarization syndrome”.²⁵ For ERS and pericarditis patients in this study, both quantitative and visual assessment of CEI performed much better than STEMI criteria. In

patients with preexcitation the specificities were slightly higher for STEMI criteria and quantitative assessment of CEI than the specificities of the 3 physicians. In patients with LVH with strain there were mixed results.

Limitations

It must be taken into consideration that the 3 physicians who participated in this study were not experienced interpreters of CEI images. The physicians were chosen based on their experience in interpreting standard 12-lead ECGs and SPECT images, but they had no previous education in interpreting CEI images. Further, they were experienced in general diagnostic electrocardiography, but not in triaging patients with suspected acute coronary syndrome. They interpreted the CEI images based on a brief tutorial session on what the image and colors represent, and they had no access to the patients' conventional 12-lead ECGs.

The study would have been strengthened by inclusion of “other types of coronary syndromes” such as occlusion of the left main coronary and its equivalents. However, these examples were not available in the STAFF III database.

One limitation of the dynamically-scaled color pattern of the CEI image, which we adopted from references^{13,14} in the present study, is the inability to distinguish between ST elevations of different magnitudes. To that end, visual interpreters had to take also the maximum epicardial potential (printed above the image) into account. Changing the color scheme, in future studies, in a way that distinguishes between ST elevations of various amplitudes can be made, to potentially further aid with differentiation between ST deviations caused by occlusion and ST- deviations present in non-occlusion patients.

Variations in the appearances of the images caused by different levels of acute occlusion sites within each of the coronary arteries and by different locations of the accessory pathways, are currently being determined in a follow-up study.

The challenge of adapting the standard 12-lead ECG for its ever-increasing role in clinical decision support has been difficult in this era of more invasive therapeutic interventions, but less training in electrocardiography. Previously, when there were expert clinical electrocardiographers, there were few interventions which required specific electrocardiographic decision support.

Conclusion

Most automated methods provide direct graphic representation of the ECG waveforms. The CEI uniquely uses the 2-step process of derivation of a body surface potential map and calculation of epicardial potentials by an “inverse solution”. The improved performance over application of STEMI criteria using CEI by 2 of the 3 physicians shows the promise of this method, while the lesser performance by the 3rd physician shows that further training methods will be required. After this has been developed, a clinical trial of the CEI method will be required to document its role in acute MI reperfusion decision support.

References

1. Thygesen K, Alpert JS, White HD, et al. Universal definition of myocardial infarction. *Circulation* 2007;116:2634.
2. Wagner G, Lim T, Gettes L, et al. Consideration of pitfalls in and omissions from the current ECG standards for diagnosis of myocardial ischemia/infarction in patients who have acute coronary syndromes. *Cardiol Clin* 2006;24:331.
3. Clemmensen P, Ohman EM, Sevilla DC, et al. Changes in standard electrocardiographic ST-segment elevation predictive of successful reperfusion in acute myocardial infarction. *Am J Cardiol* 1990;66:1407.
4. Pepine CJ. Prognostic markers in thrombolytic therapy: looking beyond mortality. *Am J Cardiol* 1996;78:24.
5. Wang J, Wagner G, Martin T, Warren J, Mirmoghisi M, Horáček BM. Validation of New Enhanced ACC/ESC STEMI Criteria on the Population of Patients with Suspected Myocardial Infarction. *Comput Cardiol* 2009;36:109.
6. Birnbaum Y, Bayés de Luna A, Fiol M, et al. Common pitfalls in the interpretation of electrocardiograms from patients with acute coronary syndromes with narrow QRS: a consensus report. *J Electrocardiol* 2012; 45:463.
7. Kayani WT, Huang HD, Bandeali S, Virani SS, Wilson JM, Birnbaum. *Global J Health Sci* 2012;4:51.
8. Bacharova L, Mateasik A, Carnicky J, et al. The Dipolar Electro- CARDioTOpographic (DECARTO)-like method for graphic presentation of location and area at risk estimated from ST-segment deviations in patients with acute myocardial infarction. *J Electrocardiol* 2009;42:172.
9. Ubachs J, Engblom H, Hedström E, et al. Location of myocardium at risk in patients with first-time ST-elevation infarction: comparison among single photon emission computed tomography, magnetic resonance imaging, and electrocardiography. *J Electrocardiol* 2009; 42:198.
10. Strauss D, Olson C, Wu K, et al. Vectorcardiogram synthesized from the 12-lead electrocardiogram to image ischemia. *J Electrocardiol* 2009;42:190.
11. Andersen M, Terkelsen C, Struijk J. The ST compass: spatial visualization of ST-segment deviations and estimation of the ST injury vector. *J Electrocardiol* 2009;42:181.
12. Nimmermark M, Wang J, Maynard C, et al. The impact of numeric and graphic displays of ST-segment deviation levels on cardiologists' decisions of reperfusion therapy for patients with acute coronary occlusion. *J Electrocardiol* 2011;44:502.
13. Horáček BM, Warren J, Wang J. Heart-surface potentials estimated from 12-lead electrocardiograms. *Comput Cardiol* 2010;37:37.
14. Horáček BM, Sapp J, Penney C, Warren J, Wang J. Comparison of epicardial maps derived from the 12-lead electrocardiograms with scintigraphic images during controlled myocardial ischemia. *J Electro- cardiol* 2011;44:707.
15. Edenbrandt L, Pahlm O. Vectorcardiogram synthesized from a 12-lead ECG: superiority of the inverse Dower matrix. *J Electrocardiol* 1988;21:361.
16. Horáček BM, Clements JC. The inverse solutions of electrocardiography; a solution in

terms of single- and double-layer sources on the epicardial surface. *Math Biosci* 1997;144:119.

17. Cerqueira MD, Weissman NJ, Dilsizian V, et al. Standardized myocardial segmentation and nomenclature for tomographic imaging of the heart: a statement for healthcare professionals from the cardiac imaging committee of the Council on Clinical Cardiology of the

American Heart Association. *Circulation* 2002;105:539.

18. Pettersson J, Pahlm O, Carro E, et al. Changes in high-frequency QRS components are more sensitive than ST-segment deviation for detecting acute coronary artery occlusion. *J Am Coll Cardiol* 2000; 36:1827.

19. Lux RL, MacLeod RS, Fuller M, Green LS, Kornreich F. Estimating ECG distributions from small numbers of leads. *J Electrocardiol* 1995;28:92.

20. Massel D. Observer variability in ECG interpretation for thrombolysis eligibility: experience and context matter. *J Thromb Thrombolysis* 2003;15:131.

21. Hamm CW, Bassand JP, Agewall S, et al. ESC guidelines for the management of acute coronary syndromes in patients presenting without persistent ST-segment elevation. [The Task Force for the management of acute coronary syndromes (ACS) in patients presenting without persistent ST-segment elevation of the European Society of Cardiology (ESC)]. *G Ital Cardiol (Rome)* 2012;13:171.

22. Martin TN, Groenning BA, Steedman T, et al. ST-segment deviation analysis of the admission 12-lead electrocardiogram as an aid to early diagnosis of acute myocardial infarction with a cardiac magnetic resonance imaging gold standard. (MALT 5). *J Am Coll Cardiol* 2007;50:1021.

23. Wagner GS, Macfarlane P, Wellens H, et al. AHA/ACCF/HRS recommendations for the standardization and interpretation of the electrocardiogram: Part VI - Acute ischemia/infarction: a scientific statement from the American Heart Association Electrocardiography and Arrhythmias Committee, Council on Clinical Cardiology; the American College of Cardiology Foundation; and the Heart Rhythm Society. *J Am Coll Cardiol* 2009;53:1003.

24. Wagner GS. *Marriott's Practical Electrocardiography*. Philadelphia, PA: Lippincott Williams & Wilkins; 2008.

25. Perez M, Friday K, Froelicher V. Semantic confusion: The case of early repolarization and the J point. *Am J Med* 2012;125:843.

Figure 1.

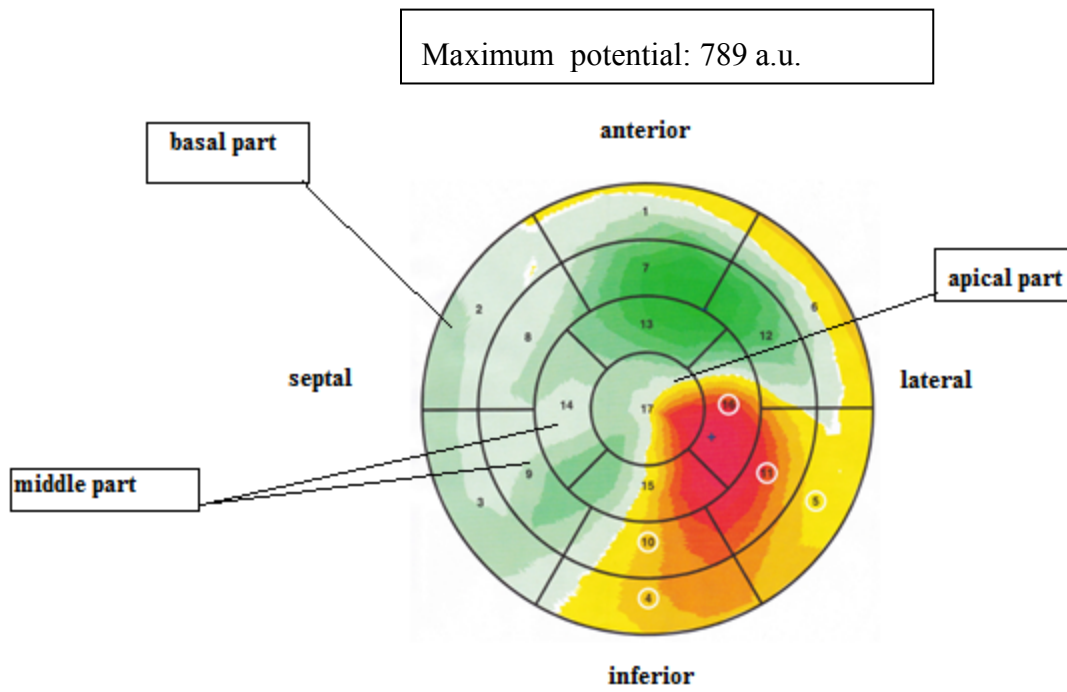


Fig. 1. CEI image of the epicardial surface in a patient with LCx occlusion. Epicardial potential distribution features areas of positive (yellow to red) and negative (green) potentials, dynamically scaled to 8 isopotential levels between zero and the larger extreme (max or min). The white circles indicate segments with the largest sums of positive potentials. Following the AHA standard,¹⁷ the central part of the CEI image corresponds to the left-ventricular apex and the outermost segments correspond to the basal part of the left ventricular myocardium.

Figure 2.

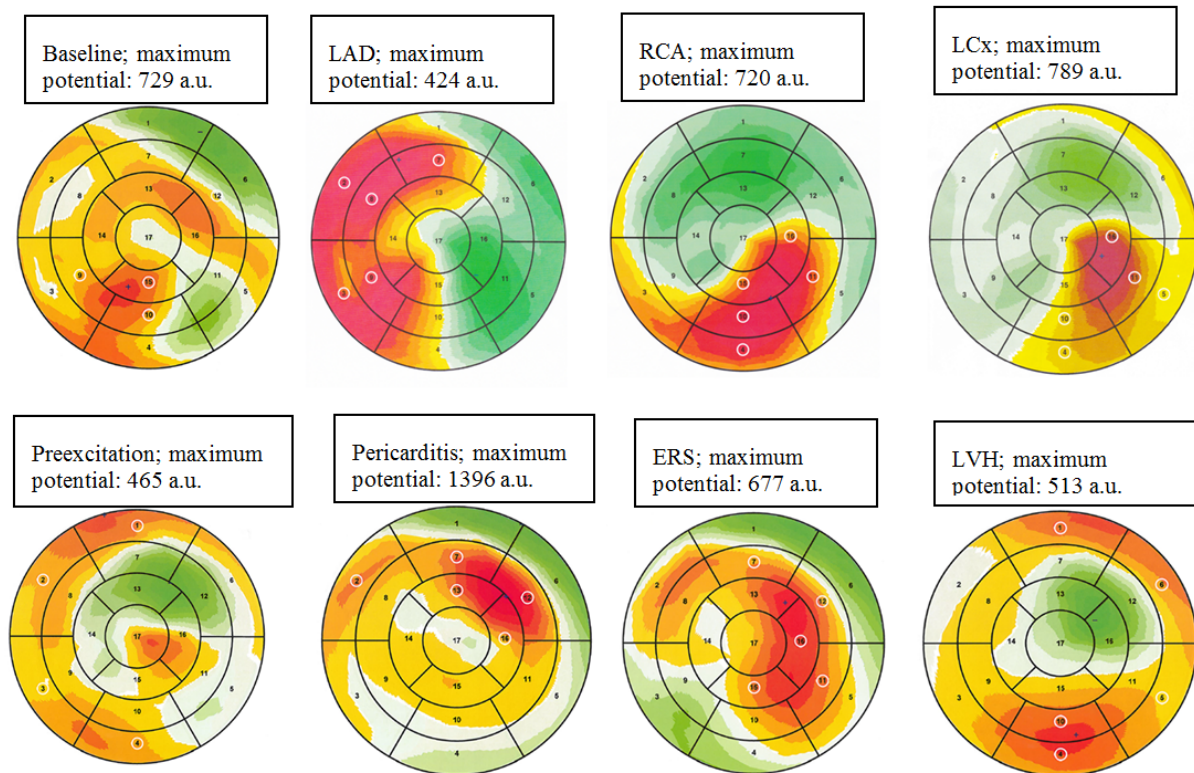


Fig. 2. Examples of CEI images. In the upper row from left to right: CEI images in a patient at preocclusion (baseline) and in patients with LAD, RCA and LCx occlusion. In the lower row from left to right: CEI images in patients with preexcitation, pericarditis, ERS and LVH with strain. The colors indicate the range of potentials from maximum (red) to minimum (green). The white circles indicate areas of the myocardium with the largest sum of positive potentials.

Figure 3.

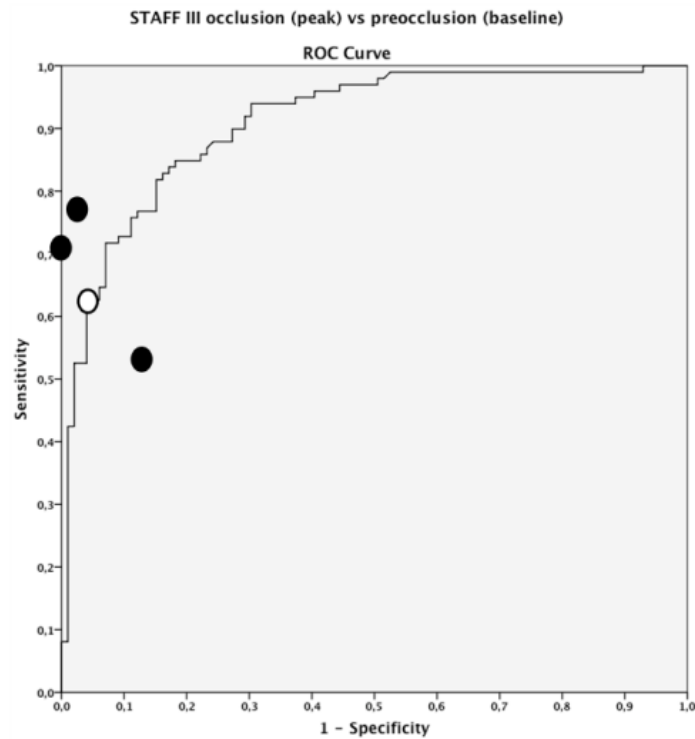


Fig. 3. ROC curve showing the ability of the maximum positive epicardial potential to discriminate between coronary occlusion and non-occlusion. The performance of STEMI criteria applied on ST-J amplitudes in the 12- lead ECGs is indicated by an open circle, while performances of 3 physicians who assessed CEI visually are indicated by filled circles.

Table 1. Characteristics of the various study populations

<i>Study population</i>	<i>N</i>	<i>Characteristics</i>	<i>Sampling Rate(Hz)</i>	
Normal or normal variant	99	Before coronary occlusion	1000	
Transmural ischemia	99	After >4 min of coronary occlusion	1000	
Pre-excitation	12	See text	500	
Pericarditis	26	See text	500	
Early repolarization syndrome	14	See text	500	
LVH with “strain”	26	See text	500	

Table 2. Sensitivities for identification of acute coronary occlusion.

Patient records	Classification Method				
	STEMI	CEI max potential	Physician review of CEI		
			Reviewer		
			#1	#2	#3
All acute coronary occlusion cases (N=99)	61% (60/99)	61% (60/99)	73 % (72/99)	76% (75/99)	51% (50/99)
LAD (N=35)	74% (26/35)	80% (28/35)	77% (27/35)	89% (31/35)	34% (12/35)
RCA (N= 47)	60% (28/47)	51% (24/47)	70% (33/47)	68% (32/47)	60% (28/47)
LCx (N=17)	35% (6/17)	47% (8/17)	71% (12/17)	71% (12/17)	59% (10/17)

Table 3. Specificities for identification of patients at preocclusion (baseline) and patients with ST deviation but no myocardial ischemia.

Patient records	Classification Method				
	STEMI	CEI max potential	Physician review of CEI		
			Reviewer		
			#1	#2	#3
All non-ischemic cases (N = 177)	78% (138/177)	89% (157/177)	96% (170/177)	92% (162/177)	88% (155/177)
Baseline ECG (N = 99)	96% (95/99)	96% (95/99)	100% (99/99)	98% (97/99)	87% (86/99)
Pre-excitation (N=12)	100% (12/12)	100% (12/12)	92% (11/12)	92% (11/12)	75% (9/12)
Pericarditis (N=26)	8% (2/26)	69% (18/26)	81% (21/26)	62% (16/26)	77% (20/26)
ERS (N=14)	29% (4/14)	93% (13/14)	93% (13/14)	100% (14/14)	100% (14/14)
LVH (N=26)	96% (25/26)	73% (19/26)	100% (26/26)	92% (24/26)	100% (26/26)