



LUND UNIVERSITY

Hypospadias Surgery. Clinical Aspects and Outcomes

Nozohoor Ekmark, Ann

2017

Document Version:

Publisher's PDF, also known as Version of record

[Link to publication](#)

Citation for published version (APA):

Nozohoor Ekmark, A. (2017). *Hypospadias Surgery. Clinical Aspects and Outcomes*. [Doctoral Thesis (compilation), Department of Clinical Sciences, Malmö]. Lund University: Faculty of Medicine.

Total number of authors:

1

General rights

Unless other specific re-use rights are stated the following general rights apply:

Copyright and moral rights for the publications made accessible in the public portal are retained by the authors and/or other copyright owners and it is a condition of accessing publications that users recognise and abide by the legal requirements associated with these rights.

- Users may download and print one copy of any publication from the public portal for the purpose of private study or research.
- You may not further distribute the material or use it for any profit-making activity or commercial gain
- You may freely distribute the URL identifying the publication in the public portal

Read more about Creative commons licenses: <https://creativecommons.org/licenses/>

Take down policy

If you believe that this document breaches copyright please contact us providing details, and we will remove access to the work immediately and investigate your claim.

LUND UNIVERSITY

PO Box 117
221 00 Lund
+46 46-222 00 00



Hypospadias Surgery

Clinical Aspects and Outcomes

ANN NOZHOOR EKMARK | FACULTY OF MEDICINE | LUND UNIVERSITY



Hypospadias Surgery

Hypospadias Surgery

Clinical Aspects and Outcomes

Ann Nozohoor Ekmark, MD, MSc



LUND
UNIVERSITY

DOCTORAL DISSERTATION

by due permission of the Faculty of Medicine, Lund University, Sweden.

To be defended at KK-Aulan, March 16th 2017, 13:00.

Faculty opponent

Professor Agneta Nordenskjöld

Karolinska Institutet,

Department of Women's and Children's Health

Organization LUND UNIVERSITY Department of Clinical Sciences Malmö Department of Plastic and Reconstructive surgery and Department of Paediatric Surgery Lund University S-221 85 Lund, Sweden	Document name DOCTORAL DISSERTATION Lund University, Faculty of Medicine Doctoral Dissertation Series 2017:29	
	Date of issue March 16, 2017	
	Sponsoring organization	
Author Ann Nozohoor Ekmark MD, MSc		
Title and subtitle Hypospadias Surgery – clinical aspects and outcome		
Abstract <p>Aim The aim of this thesis was to evaluate the treatment and follow-up of patients undergoing hypospadias surgery at the Department of Plastic and Reconstructive Surgery, Skåne University Hospital, Malmö, in an attempt to improve the overall care of these patients. It also aimed to investigate the tissue properties of the urethral plate and deep chordee in hypospadias patients with significant ventral curvature of the penile shaft.</p> <p>Methods Long term follow-up and patient reported outcomes in a cohort of 157 patients were investigated by chart review and a modified hypospadias functional outcome questionnaire. The hypospadias objective scoring evaluation (HOSE) system was used to objectify the results. In addition, 36 patients with secondary hypospadias repairs were analysed via chart review and 10 patients scheduled for orthoplasty during 2014–2015 consented to biopsy of the urethral plate and deep chordee during surgery.</p> <p>Results HOSE analysis indicated that 86% of patients had satisfactory results after primary and secondary hypospadias repair. Overall fistula frequency was 11% after primary repair and post-pubertal follow-up. The HOSE analysis also showed that 82 to 92% of responding patients were neutral or more satisfied with their overall surgical outcomes, appearance, and urinary and sexual function and 90% of responders were satisfied or requested longer follow-up after surgery. In 22% of patients with salvage repairs, additional surgery was required because of complications or shortcomings after re-repairs per our treatment algorithm. All of the biopsy samples from the urethral plate and the deep chordee had similar tissue characteristics and the biopsies confirmed that chordee is a unique tissue entity. In addition, chronic inflammation, a finding not previously reported, was present in every biopsy specimen, with chronic inflammation in the urethral plate manifested as metaplasia in the form of urethritis cystica.</p> <p>Conclusions Our findings show that the long-term, post-pubertal complication rate after hypospadias surgery is low and that a majority of patients have satisfactory results. Patient-reported outcomes indicated that the responding patients were satisfied with their overall long-term surgical/functional outcomes and with the long-term follow-up program. We also found that our treatment algorithm can be applied successfully in cases of secondary hypospadias repairs, provided local tissues are available for flap coverage. In these cases, it is of particular importance to treat all ventral curvature, secondary to chordee and ventral scarring. Thus, many secondary salvage procedures must be handled in two sessions to optimise safety and minimise postoperative complications. Finally, we also report previously undescribed chronic inflammatory activity in tissue samples from urethral plates and deep chordee in patients with hypospadias and ventral curvature, which suggests a possible dynamic feature in this unique tissue entity.</p>		
Key words: Hypospadias surgery, Hypospadias repair, Secondary Hypospadias Surgery, Salvage Hypospadias Surgery, Post Pubertal Follow up, Long Term Follow Up, Functional Outcome, Patient Reported Outcome, Chordee, Urethritis Cystica, Immunohistochemistry		
Classification system and/or index terms (if any)		
Supplementary bibliographical information		Language: English
ISSN and key title: 1652-8220		ISBN: 978-91-7619-410-2
Recipient's notes	Number of pages:	Price
	Security classification	

I, the undersigned, being the copyright owner of the abstract of the above-mentioned dissertation, hereby grant to all reference sources permission to publish and disseminate the abstract of the above-mentioned dissertation.

Signature _____ Date _____

Hypospadias Surgery

Clinical Aspects and Outcomes

Ann Nozohoor Ekmark



LUND
UNIVERSITY
Faculty of Medicine

Doctoral Thesis
2017

Cover by Victoria Schönström

Copyright Ann Nozohoor Ekmark, MD, MSc

Supervisor: Professor Henry Svensson

Co-Supervisor: Associate Professor Emma Hansson

Department of Plastic and Reconstructive Surgery Skåne University Hospital

Co-Supervisor: Professor Einar Arnbjörsson

Department of Paediatric Surgery Skåne University Hospital

Department of Clinical Sciences Malmö and Lund, Faculty of Medicine, Lund University, Sweden

Faculty of Medicine, Lund University, Sweden

Department of Plastic and Reconstructive Surgery and the Department of Paediatric Surgery, Skåne University Hospital, Sweden

ISBN 978-91-7619-410-2

ISSN 1652-8220

Printed in Sweden by Media-Tryck, Lund University
Lund 2017



*With grateful love to you who every day fill my life with warmth,
joy and happiness: Shahab, Saga, Emil, Otto and the loving
memory of Juni. We lost you, but your fingerprints of sweet love
and grace are left on our lives forever.*

Content

Content.....	7
Papers included in the thesis.....	11
Thesis at a glance.....	12
Introduction and background.....	14
Fig. 1: Anatomical features of hypospadias.....	14
Background to the present investigation.....	15
Embryology.....	15
Sex development.....	15
Fig. 2: Initial development of foetal sex.....	16
Embryology of penile urethra.....	17
Fig. 3: Development of external genitalia.....	18
Fig. 4: Optical projection tomographic visualisation of the foetal penis.....	19
Fig. 5: Scanning electron micrographs of foetal penis and transverse serial sections.....	20
Development of the prepuce.....	21
Fig. 6: Development of the prepuce.....	21
Embryological origin of hypospadias.....	22
Clinical features and classification of hypospadias.....	22
Normal penile anatomy.....	22
Fig. 7: Normal penile anatomy.....	23
Anatomical features of hypospadias.....	24
Hypospadias classification and phenotypes.....	25
Genetics and aetiology.....	25
Epidemiology.....	26
Table 1: Worldwide prevalence of hypospadias.....	27
Surgical Management.....	28
Aims of the surgical treatment.....	28
General surgical principles and relationship to phenotype in hypospadias management.....	28
Management of chordee.....	29
Timing of hypospadias surgery.....	29

Complications in hypospadias repair.....	29
Outcomes assessment	30
Hypospadias Objective Scoring Evaluation (HOSE)	30
Patient-reported outcomes	31
Aims.....	32
Material and Methods	33
Patients.....	33
Study I and III.....	33
Fig. 8: Flow chart of patients in Study I	34
Fig. 9: Flow chart of patients in Study III.....	35
Study II	36
Study IV.....	36
Table 2: Patient characteristics in Study IV.....	37
Methods	38
Studies I–III	38
Clinical classification in Studies I–IV	38
Surgical treatment in Studies I–IV	38
Primary surgical treatment in Studies I and III.....	38
Fig. 10 A–D: Orthoplasty	39
Fig. 11 A–D: The Mathieu procedure.....	40
Fig. 12 A–G: The Scuderi technique	41
Fig. 13 A–E: The Byars two-stage procedure.....	42
Timing of primary surgical treatment, Studies I and III	43
Salvage repairs in Study II.....	44
Fig. 14: Treatment algorithm for re-do hypospadias repair.....	46
Follow-up protocol and clinical evaluation in Studies I–III.....	47
Patient-reported outcomes in Study III.....	48
Tissue sampling in study IV	48
Fig. 15: Biopsy from the urethral plate.....	49
Fig. 16: Biopsy from the deep chordee.....	49
Histopathology and immunohistochemistry in Study IV	50
Statistical analysis.....	50
Ethics	51
Results.....	52
Study I and Study III	52
Table 3. Overview of the patients in Studies I and III.....	52
Study I.....	53
Complications after surgery.....	53

Table 4: Overall complications.....	54
Table 5: Total HOSE scores	55
Study III.....	55
Population and Study Sample.....	55
Table 6: HOSE scores for responders and nonresponders.....	56
Patient Satisfaction with Outcome.....	56
Table 7: Satisfaction with the surgical outcome for responders.....	56
Patients' perception of the follow-up visits	57
Table 8: Patient experiences at the follow-up visits	57
Study II.....	58
Complications and shortcomings, Study II.....	58
Table 9: Treatment Group A.....	59
Table 10: Treatment Group B.....	62
Table 11: Treatment Group C.....	64
Table 12: HOSE Scores	67
Study IV.....	68
Fig. 17: Tissue characteristics.....	68
Fig. 18: Representative histology	69
Fig. 19: Urethritis cystica of the urethral plate	70
Fig. 20: Scarring in deep chordee	71
Table 13: Urethral plate findings.....	72
Table 14: Deep chordee tissue findings.....	74
Discussion.....	75
Considerations regarding complications and long term results.....	75
Degree of hypospadias.....	75
Fistulas and meatal location.....	75
Incurvation.....	76
Patient satisfaction with urinary and sexual function and cosmesis ...	76
Patient perspectives on long-term follow-up.....	77
Considerations regarding salvage repairs	78
Considerations regarding histopathological findings and chordee.....	80
Methodological issues	81
Long-term retrospective follow-up and methods of evaluation, Studies I–III.....	81
Patient reported outcomes: Study III.....	82
Sample size, Study IV.....	82
Ethical considerations.....	83
Conclusions.....	84
Future perspectives	85
Populärvetenskaplig sammanfattning på Svenska – Summary in Swedish.....	87

Inledning och bakgrunden till undersökningen	87
Sammanfattning av undersökningarna i denna avhandling	88
Appendix	91
Appendix 1: Hypospadias Objective Scoring Evaluation (HOSE)	91
Appendix 2: Modified Hypospadias Outcome Questionnaire, English	92
Appendix 3: Modified Hypospadias Outcome Questionnaire, Svenska	93
Acknowledgements	94
References	97
Paper I	103
Paper II	111
Paper III	121
Paper IV	128

Papers included in the thesis

Ekmark AN, Svensson H, Arnbjörnsson E, Hansson E.

Postpubertal examination after hypospadias repair is necessary to evaluate the success of the primary reconstruction.

European Journal of Pediatric Surgery 2013; 23: 304-11.

Nozohoor Ekmark A, Svensson H, Arnbjörnsson E, Hansson E.

Failed hypospadias repair: An algorithm for secondary reconstruction using remaining local tissue.

Journal of Plastic, Reconstructive & Aesthetic Surgery 2015; 68:1600-9.

Nozohoor Ekmark A, Arnbjörnsson E, Svensson H, Hansson E.

Patient-reported long-term outcome after primary hypospadias repair.

Journal of Plastic Surgery and Hand Surgery 2016; 9:1-6.

Manuscript (submitted):

Ekmark AN, Arnbjörnsson E, Svensson H, Hansson E, Gisselsson DL

Chronic inflammation with urethritis cystica is a recurrent feature in the microscopic pathology of hypospadias

Thesis at a glance

Paper	Material/Patients	Methods	Results	Figure	Conclusions
<p>Postpubertal examination after hypospadias repair is necessary to evaluate the success of the primary reconstruction.</p>	<p>Cohort of 157 patients with primary hypospadias repair. 114 patients included in the study after the completion of post pubertal clinical examination.</p>	<p>Chart review. Objectivisation of surgical outcome using HOSE Descriptive statistics and association testing.</p>	<p>There was a significant association between the degree of hypospadias and the occurrence of fistulas and the total number of complications. The overall fistula frequency was 11%. 5% had postpubertal incurvation. 85% had acceptable results according to HOSE.</p>		<p>Patients need post pubertal follow up to identify late onset complications such as incurvation.</p>
<p>Failed hypospadias repair: An algorithm for secondary reconstruction using remaining local tissue.</p>	<p>Cohort of 36 patients referred for secondary correction after previously failed reconstructive attempts</p>	<p>Chart review. Objectivisation of surgical outcome using HOSE Descriptive statistics.</p>	<p>86% of the patients with completed post-pubertal follow up had acceptable results according to HOSE. 22% of patients underwent additional surgery beyond the treatment algorithm.</p>		<p>Success with repairs can be achieved using local available tissues according to our treatment algorithm. This allows liberal use of staged repairs to allow for careful excision of remaining chordae and ventral scarring.</p>

Paper	Material/Patients	Methods	Results	Figure	Conclusions
<p>Patient-reported long-term outcome after primary hypospadias repair.</p>	<p>Cohort of 157 patients aged \geq 18 years with primary hypospadias repair. 134 were included in our study, response rate was 29%.</p>	<p>Questionnaire Descriptive statistics</p>	<p>82-92% of responders were neutral or more pleased with the appearance of their penis, sexual function, ability to urinate, and overall surgical outcome. 90% were either satisfied with the duration or would have preferred a longer follow-up period after surgery.</p>		<p>Longterm functional results are good for most patients. The vast majority was satisfied with or requested longer follow up.</p>
<p>Chronic inflammation with urethritis cystica are recurrent features in the microscopic pathology of hypospadias</p>	<p>Collection of biopsies from the urethral plate and the deep chordae from cohort of 10 hypospadias patients with ventral curvature undergoing primary or secondary reconstruction.</p>	<p>Immunohistochemical staining, light microscope. Descriptive statistics.</p>	<p>All urethral plate biopsies showed features of urethritis cystica. All biopsies from the deep chordae showed similar tissue characteristics including chronic inflammation. A increasing trend in inflammatory markers could be seen in older patients with previous surgery.</p>		<p>Chordee is a unique tissue entity. Chronic inflammation was seen in the deep chordae and in all urethral plates. In the urethral plate it was manifested as metaplasia (urethritis cystica).</p>

Introduction and background

Hypospadias is a common congenital malformation in boys that is characterized by (i) a split prepuce forming a hood on the dorsum of the penis due to failed closure of the ventral portion, (ii) a proximal urethral meatus located on the ventral side of the penis and accompanied by impaired differentiation of the corpus spongiosum, and, frequently, (iii) ventral curvature of the shaft (Fig. 1). The area between the hypospadiac meatus and the expected normal glanular meatus contains remnants from the arrested development of the urethra and corpus spongiosum, which are collectively known as the urethral plate. The chordee is the V-shaped curvature-causing tissue that is located beneath and lateral of the urethral plate underneath the skin (Fig. 16). Chordee is also used as a term indicating presence of ventral curvature.

Uncorrected, the problems caused by these malformations range from cosmetic complaints to difficulties voiding without spraying and leakage of urine, decreased fertility¹, ambiguous sex, and inability to have penetrating intercourse.

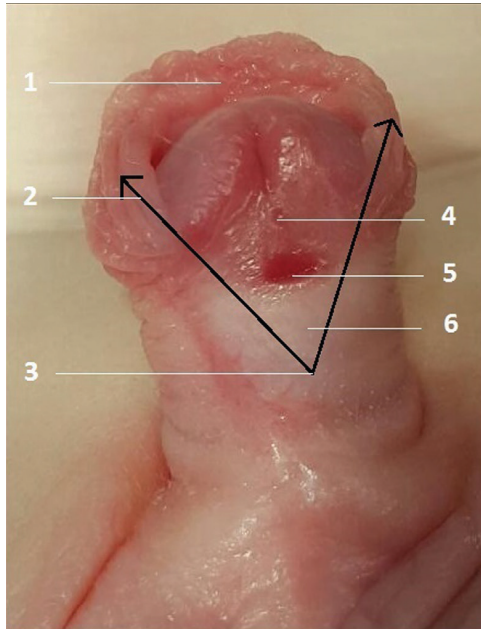


Fig. 1: Anatomical features of hypospadias

With the kind permission for reprint from Dr Nadia Boudaoud Laghmani, American Memorial Hospital, CHU de Reims, Reims, France².

1. Incomplete prepuce resembling a dorsal hood.
2. Internal and external blade of the prepuce.
3. Division of corpus spongiosum.
4. Urethral plate.
5. Hypospadiac meatus.
6. Hypospadiac urethra.

Background to the present investigation

This thesis was initiated as a cooperation between the Department of Paediatric Surgery at Skåne University Hospital, Lund, and the Department of Plastic and Reconstructive Surgery at Skåne University Hospital, Malmö, in an effort to evaluate the treatment and follow-up programs at the Department of Plastic and Reconstructive Surgery and to optimize the treatment offered to all hypospadias patients at Skåne University Hospital. The Department of Paediatric Surgery at Skåne University Hospital, Lund, and the Department of Plastic and Reconstructive Surgery at Skåne University Hospital, Malmö, are two of six clinics in Sweden that perform hypospadias surgery. There is still no national or international consensus regarding hypospadias surgery and follow-up, although the work to formulate national guidelines has recently begun.

Embryology

Sex development

In normal foetal development, the chromosomal sex (XX/XY) determines the gonadal sex and the phenotypical sex. The initial development is independent of the chromosomal sex and is identical in both sexes. The key points of initial foetal sex development are illustrated in Fig. 2.

During the undifferentiated stage, the primitive gonadal structures are derived from the urogenital ridges at approximately 4 weeks after fertilisation³. The urogenital ridges are the common precursors of the urinary and genital systems, through division into a urinary ridge and an adreno-gonadal ridge³. Two duct systems develop in both XX and XY embryos, the mesonephric ducts, also called the Wolffian ducts, and the paramesonephric ducts, also called the Müllerian ducts³. The distal portions of both ducts open into the cloaca, which is the distal expansion of the hindgut that is limited by the cloacal membrane and later divides into the urogenital sinus and the rectoanal sinus³.

At the end of the sixth week, the Sex Determining Region Y (SRY) gene, expressed only on the Y-chromosome, becomes the key initiator of testicular differentiation. This gene acts as a master switch in the initiation of the processes that differentiate testicular tissue from the previously bipotential gonadal ridge³. Two cell types develop in the testis, the Sertoli cells, which produce anti-Müllerian hormone (AMH), and the Leydig cells, which produce androgens and Insulin-Like factor 3 (INSL3)³. Thus, during a time window in gestational weeks 8 and 9, the Müllerian ducts regress in a cranio-caudal direction under the influence

Fig. 2: Initial development of foetal sex

The bipotential gonad in a 6-week embryo. The mesonephric ducts (Wolffian ducts) and the paramesonephric ducts (Müllerian ducts) empty into the cloaca. Under the influence of the SRY gene the Müllerian ducts degenerate and the Wolffian ducts differentiate into epididymis, seminal vesicles, and vas deferens. In the absence of SRY, the Wolffian ducts degenerate and the Müllerian ducts persist and differentiate into the uterine tubes and the uterus.

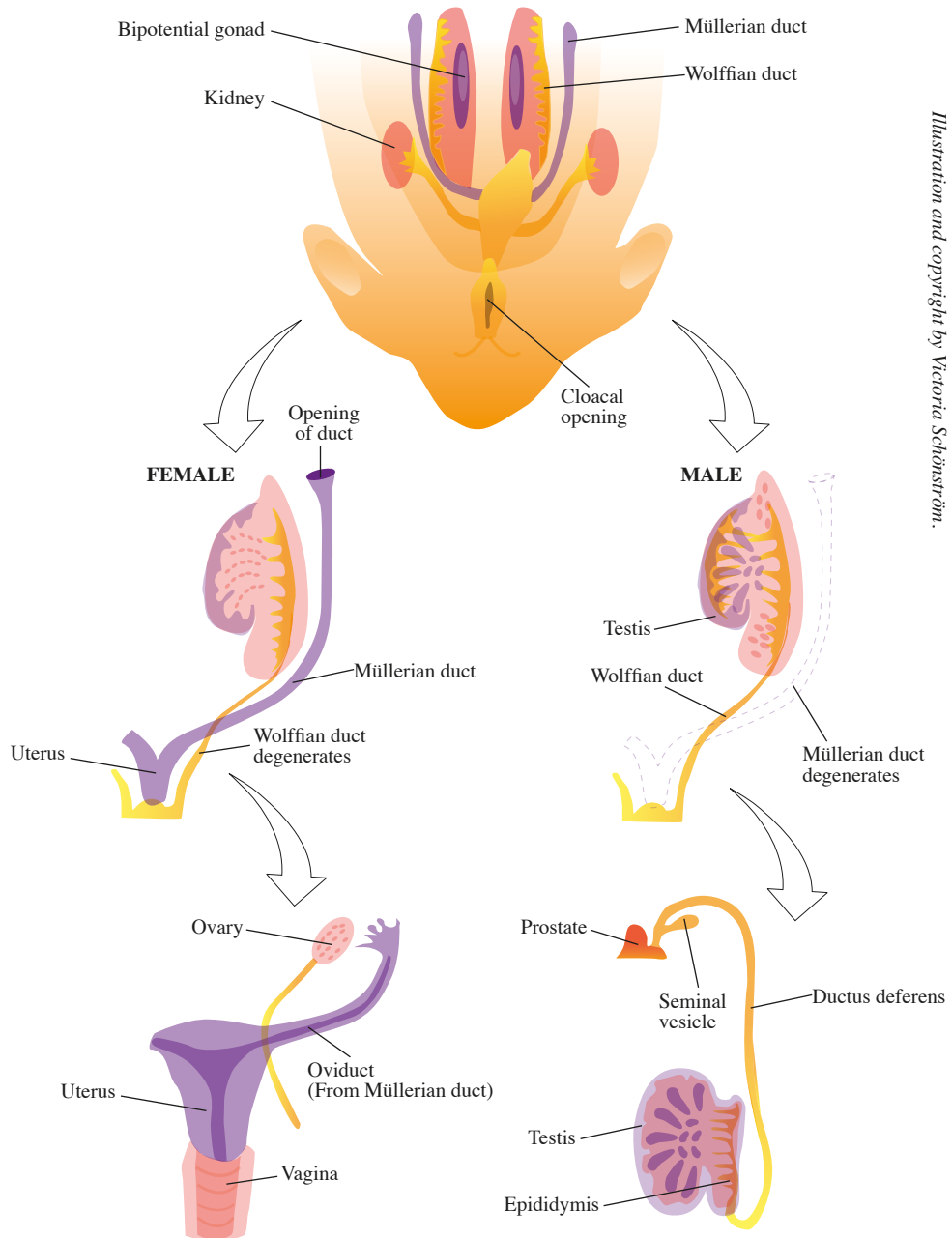


Illustration and copyright by Victoria Schönström.

of AMH³. By week 10, the Müllerian ducts become insensitive to AMH³. The continued differentiation of the Wolffian ducts into the epididymis, vas deferens, and seminal vesicles requires such high testosterone concentrations that it can only occur in the immediate vicinity of the Leydig cells of the testes³. In the absence of testosterone, the Wolffian duct degenerates and, thus, the internal male genitalia fails to develop³. Further, the virilisation of the urogenital sinus and the external genitalia is primarily dependent on the conversion of testosterone to dihydrotestosterone (DHT) by 5 α -reductase type 2 (5ARI-2), which has a much higher binding affinity to the androgen receptor (AR) than testosterone³. Disturbance in the expression of 5ARI-2, despite normal levels of testosterone, results in disturbance of the development of the normal male external genitalia. Through the regulation of human chorionic gonadotropin (hCG) and luteinizing hormone (LH), the Leydig cells produce INSL3, which acts in the steering of the descent of the testicles into the scrotum³. Unilateral or bilateral undescended testis in the presence of hypospadias should lead to further investigation, as it may indicate an underlying disorder of sexual differentiation (DSD).

The urogenital sinus forms the bladder and prostate and caudally the pelvic and phallic portion of the urogenital sinus will form the prostatic and membranous portions of the urethra³. In sum, the initial phase of the formation of the human male genitalia is hormone-independent and the later phase is hormone-dependent.

Embryology of penile urethra

Just as the gonads and internal genitalia are initially sex-independent, the initial development of the external genitalia is identical in males and females (Fig. 3). In the fifth week, the cloacal folds appear as swellings on both sides of the cloacal membrane. These folds meet anteriorly and form a midline swelling called the genital tubercle⁴. The formation of perineum in the seventh week by fusion of the urorectal fold with the cloacal membrane creates an anterior urogenital membrane and a posterior anal membrane⁴. The anterior folds flanking the urogenital membrane are now called urethral folds or genital or urogenital folds⁴. During this time, the labioscrotal swellings develop as additional swellings lateral to the urethral folds⁴ (Fig. 3). At nine weeks, virilisation of the external genitalia by DHT and testosterone begins with the lengthening of the anogenital distance³. The walls of the cloacal membrane in the genital tubercle then come together in a distal-to-proximal direction, resulting in the formation of a solid plate of endodermal epithelium, the urethral plate⁵. This replaces the urogenital membrane and extends to the tip of the phallus⁶.

Fig. 3: Development of external genitalia

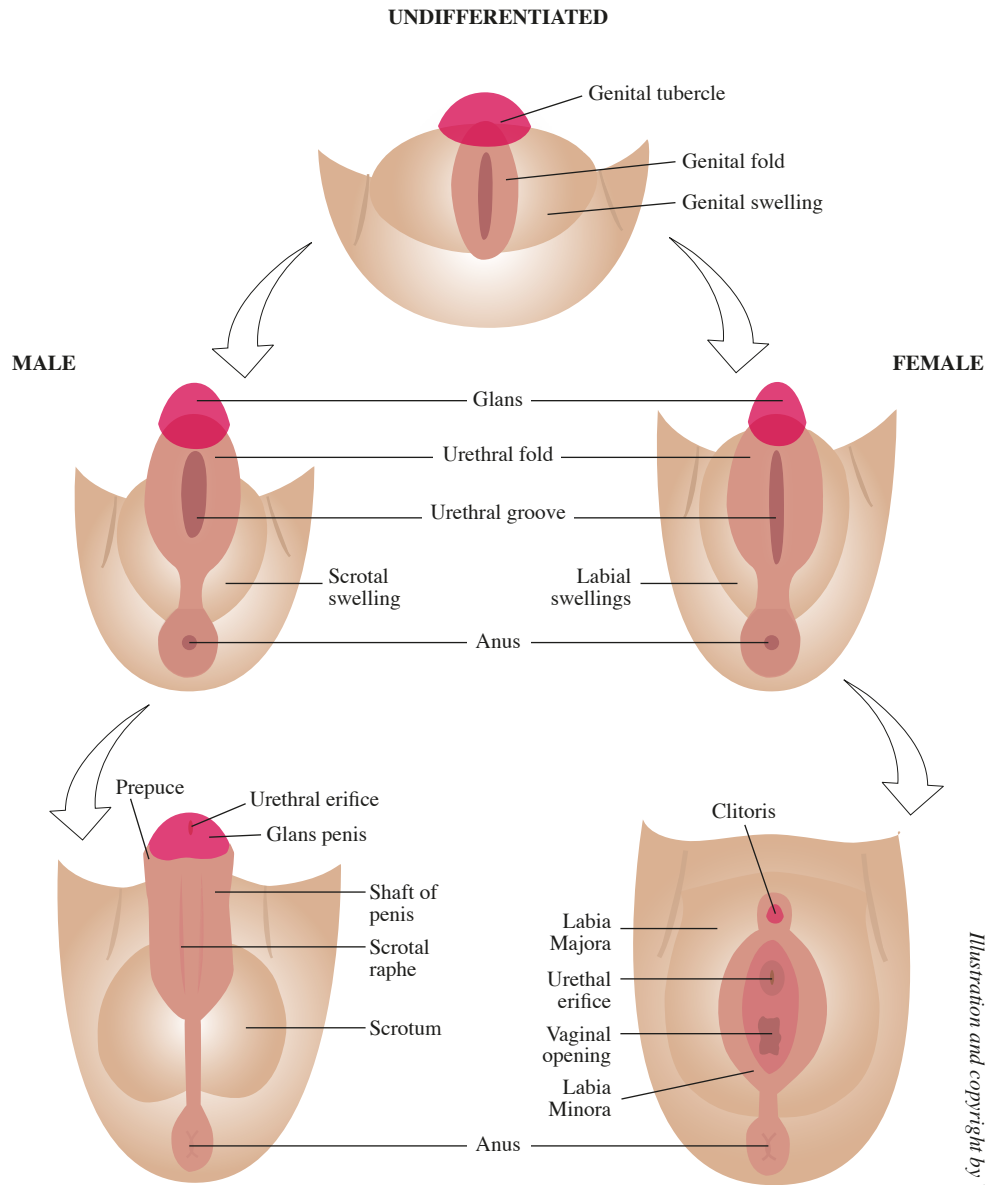


Illustration and copyright by Victoria Schönström.

The details of the development of the human male urethral plate and the urethra, particularly the glanular urethra, are debated⁵⁻⁷. However, recent work by Dr Guncha and Dr Baskin has shed new light on the process. They suggest and illustrate a mechanism whereby the entire male urethra, including the glanular urethra, is formed by dorsal growth of the urethral plate into the genital tubercle and ventral growth and fusion of the urethral folds^{6,8,9}. Their hypothesis is that this complex process occurs by a mechanism they call “the Double-Zipper mechanism”⁹, which they have visualized by using optical projection tomography (OPT)⁹. OPT is a form of computed tomography scan that uses light instead of X-rays. It can be applied to thin, microscopic structures. By OPT, the process of epithelialisation of the urethral groove and the secondary closure via fusion of the edges of the groove can be visualised⁹. With the kind permission of the authors, the image is reprinted below (Fig. 4).

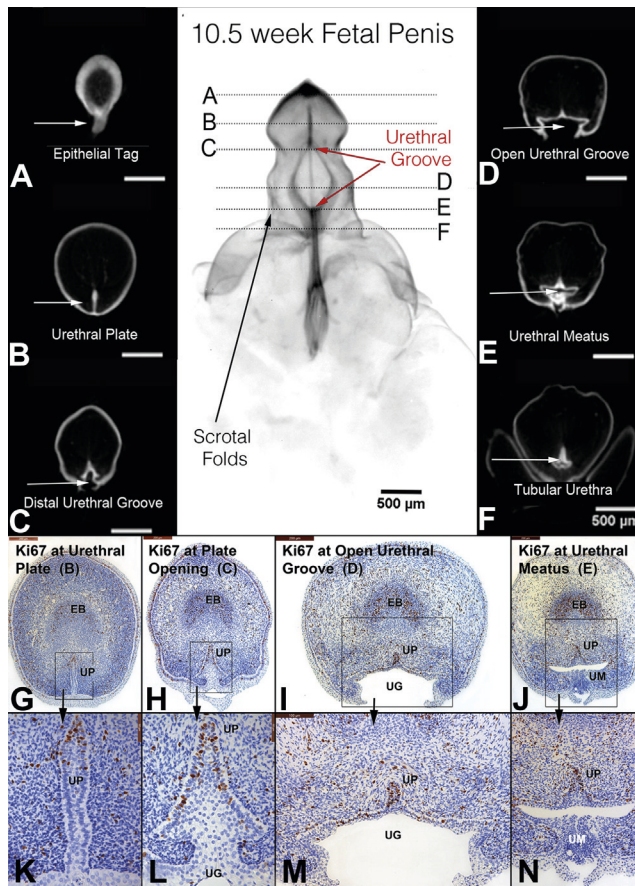


Fig. 4: Optical projection tomographic visualisation of the foetal penis

Reprinted with the kind permission of Dr Laurence Baskin, Division of Pediatric Urology, Benioff Children’s Hospital, UCSF, San Francisco, California, and Elsevier. OPT of 10.5-week penis in the early stages of development with epithelium stained for E-cadherin. Continued proliferation (Ki67-marked) in the urethral plate (UP, opening zipper, G and H, high power, K and L), open urethral groove (UG, red arrows), and fusion of the urethral groove (I and M) to form tubular urethra (J and N). EB, erectile body. UM, urethral meatus⁹.

The Double-Zipper process⁹ encompasses the canalization within the urethral plate that results in the formation of the urethral groove¹⁰, i.e. “the opening zipper”, followed by the later fusion event, i.e. “the closing zipper”. The initial opening zipper process leaves behind a wide urethral groove with lateral epithelial edges (urethral folds) that are ultimately fused to form the tubular urethra during the closing zipper process, i.e. the fusion of the edges of the urethral groove and the distal extension of the tubular urethra⁹. This process has been further investigated using scanning electron microscopy (SEM)⁸, which indicates that the series of layered epithelial fusion events involved in the closing zipper give rise to the penile urethra, the ventral corpus spongiosum, and the penile raphe⁸. With the kind permission of the authors, a representative image is reprinted below (Fig. 5).

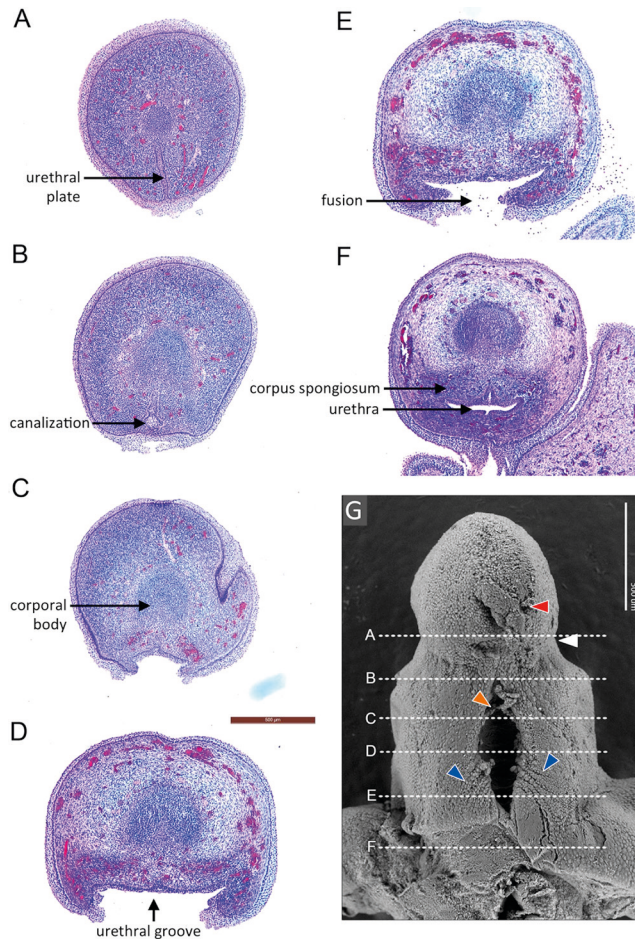


Fig. 5: Scanning electron micrographs of foetal penis and transverse serial sections

Reprinted with the kind permission of Dr Jerry Cunha, Division of Pediatric Urology, Benioff Children’s Hospital, UCSF, San Francisco, California, and Elsevier. Transverse sections from a human foetal penis at 9 weeks’ gestation, stained with hematoxylin and eosin and showing (A) solid urethral plate, (B) beginning of the canalization process, (C) the distal open urethral groove, (D) the mid-shaft open urethral groove, (E) the fusion process, and (F) the formed urethra at the levels indicated in (G). White arrowhead indicates the transition from penile shaft to glans, red arrowhead indicates the distal epithelial tag, orange arrowhead indicates strands of epithelial cells spanning the distal urethral groove, and blue arrowheads indicate wrinkles lateral to the proximal urethral groove, which may be the precursors of the interlaced epithelial cords seen later.

Development of the prepuce

Formation of the prepuce begins at the same time as that of the urethra and is dependent on normal urethral development for completion. The process is illustrated in Fig. 6. At about 8 weeks' gestation, low preputial folds appear on both sides of the penile shaft, which join dorsally to form a flat ridge just proximal to the coronal sulcus¹¹. The ridge does not entirely encircle the glans because it is blocked on the ventral side by the incomplete development of the urethra¹¹. Consequently, in the hypospadiac penis, the ventral preputial tissue is absent and the dorsal preputial tissue is excessive¹¹. The prepuce then rolls over the base of the glans, leaving a groove between it and the coronal sulcus, which becomes filled by active proliferation of cells that carry the prepuce forward along with the proliferation of the epithelial cells in the prepuce¹². The outer and inner layers of the prepuce are separated at about 30 weeks, starting at the distal preputial ridge¹². Remnants of the attachment between the glans and the inner preputial layer can be seen as adhesions in the grown child¹².

Fig. 6: Development of the prepuce

- A. Formation of the preputial fold in the tenth week of gestation.
- B and C. Weeks 10–28: proliferation to the tip of the glans.
- D. Separation of the epithelial layers (week 30).

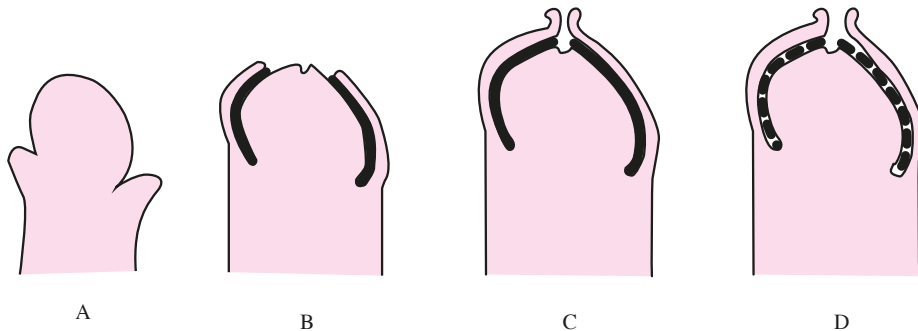


Illustration and copyright by Victoria Schönström.

Embryological origin of hypospadias

Elucidation of the development process for the normal male genitalia and urethra has indicated that hypospadias results from a disruption of the normal closure of the edges of the urethral groove that inhibits formation of the urethral tube^{8,13}. Failed closure of the prepuce is also secondary to failed development of the urethra, as described above. In a few cases, disrupted closure of the urethra is secondary to a disruption in the upstream phenotypical sex development, and children with severe hypospadias and associated undescended testes should be evaluated for possible DSD. Contrary to the now more well-understood urethral development, the origin of the frequently associated ventral curvature and abnormal ventral tissue, the chordee, is not yet clear. It is most often suggested that the chordee is associated with a malformed corpus spongiosum¹⁴⁻¹⁷ or with a growth disparity between the dorsal and ventral tissues. Ventral curvature has also been observed as a normal part of foetal penile development¹⁸. However, the ventral curvature that occurs in the normal foetal penis was present and persisted after development of the penile urethra was complete, in many cases even lasting until the third trimester¹⁸. A possible link between disrupted urethral closure and spongiosum formation with the persistence of normal foetal penile curvature has not yet been shown. Isolated chordee can also occur with a normal glanular meatus with or without normal distal corpus spongiosum covering the urethra^{15,19-21}, which suggests a possible parallel disruption as the origin of chordee.

Clinical features and classification of hypospadias

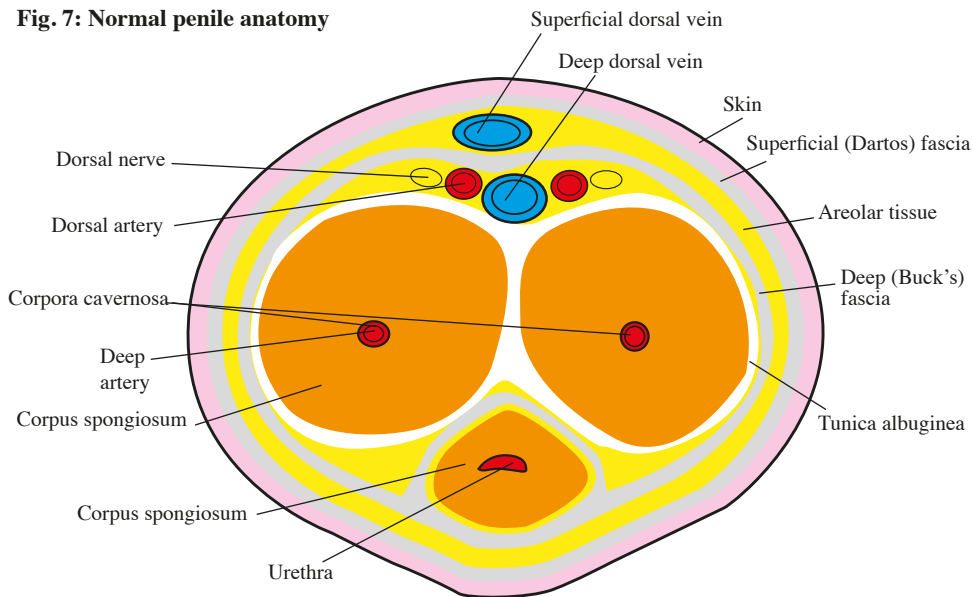
Normal penile anatomy

The normal penile anatomy is shown in cross section in Fig. 7. In the normal anatomy, the two corpora cavernosa are covered by the tunica albuginea. The corpus spongiosum surrounds the urethra and ends in the glans penis. The tunica albuginea corporis spongiosis is the inner lining of the inner sheet of the penile preputium. The diameter of the distal urethra is increased at the navicular fossa, with an initial narrowing in the valvular navicular fossa that is the most distal part of the urethra surrounded by corpus spongiosum and corpora cavernosa and is at the same level as the preputial frenulum and the glandular septum. The tunica albuginea is covered by a deep fascia (Buck's fascia) and a superficial fascia (the Dartos fascia). The central deep vein (vena dorsalis profunda) is located in the dorsum of the penile shaft with superficial arteries and nerves running along both

sides (dorsal arteries and nerves). The deep arteries are located in the centre of the corpora cavernosa.

The pudendal arteries (superior and inferior) supply the penile skin and the prepuce with arterial blood in a symmetrical fashion. They divide into four branches, the superficial penile arteries, at the base of the penis¹². Numerous collateral vessels between these arteries create a fine subcutaneous arterial plexus running to the preputial ring¹², from which point they penetrate the Buck's fascia and anastomose with the deeper dorsal penile artery. In some cases, the arterial blood supply of the prepuce is asymmetrical¹², which is of importance in preputial flap surgeries. Also, the preputial arteries follow the outer preputial sheet until its most distal position and then turn 180 degrees and follow the inner preputial sheet to the coronal sulcus, where they are drained by a venous plexus¹². This allows for the proximal retraction of the prepuce during erection with a resulting unfolding of the arteries. During surgery, it also allows for circular incision along the coronal sulcus without damage to the arterial supply¹².

Fig. 7: Normal penile anatomy



Anatomical features of hypospadias

The anatomy of the dorsum of the hypospadiac penis is similar to that of the normal penis¹³. The hypospadias defect affects mostly the ventral side of the penis, and involves an absence of ventral urethral epithelium, corpus spongiosum, and the skin²². In addition, the penile raphe is not in a median position²¹. The innervation of the normal and hypospadiac penis is similar¹¹. The dorsal nerve arises from the pudendal nerve and continues as two well-defined bundles superior and slightly lateral to the urethra¹¹.

Chordee and penile torsion

Ventral penile curvature (chordee) is frequent, particularly in more advanced forms of hypospadias^{11,21}. Congenital ventral curvature can also occur in association with a normal urethral meatus, which is commonly called chordee without hypospadias or crypto-hypospadias²³. In these cases, the glanular urethra is often normal while the spongio-penile urethra is deficient²³. Rarely, the curvature can exist in association with a completely normal urethra²⁰. The cause of ventral curvature is debated²³, as is the use of the term chordee to describe the ventral curvature²⁴. Ventral curvature can occasionally be surgically released after degloving of the penile skin, although this is not the case for most patients¹⁹, who will require a orthoplasty with excision of chordee tissues.

Penile torsion usually presents with the penile shaft rotated to the left and the raphe deviating to the right²¹. Torsion can occur in the absence of hypospadias or chordee, but it is most commonly found in association with these anomalies²⁵. The cause of the torsion is unknown²⁵, though an association with asymmetric ventral tissues is reported^{7,15}.

Prepuce

The characteristics of the prepuce are less frequently described, in spite of its importance as the most common building block for hypospadias reconstructions. In a study by Radojicic et al (2004), the complication rate after hypospadias repair using preputial flaps was associated with the phenotype of the prepuce²⁶. Their findings indicate that the anatomical distribution of vessels in the prepuce can be predicted by the phenotype, and thus, understanding the phenotype of the prepuce may be of importance in planning hypospadias repair.

Hypospadias classification and phenotypes

Several classification systems have been suggested for hypospadias²⁷, mainly based upon the position of the meatus²⁸. However, a comprehensive classification of the phenotype must also account for the position of the meatus after correction of the ventral curvature (excision of the chordee)²⁷. Indeed, as suggested by Hadidi (2004), a complete classification should describe the presence or absence of chordee, the site of the urethral meatus before and after correction of the curvature, the state of the prepuce (incomplete or complete), the state of the glans (cleft, incomplete cleft, or flat), the width of the urethral plate, the presence or absence of penile torsion, and finally, the presence or the absence of scrotal transposition²⁷. This complete classification accounts for important factors associated with surgical success, and its widespread adoption would allow for more adequate comparisons of surgical results between centres.

The International Classification of Disease (ICD) system includes hypospadias unspecified (Q54.9) and other specified hypospadias (Q54.8) along with four additional descriptive levels: balanic (Q54.0), penile (Q54.1), penoscrotal (Q54.2), and perineal (Q54.3) hypospadias.

Genetics and aetiology

Hypospadias is complex disorder affected by both genes and the environment. It is an isolated malformation in the majority of cases, although it can also occur in association with other abnormalities, most frequently undescended testes or micropenis²⁹. In addition, hypospadias has been described in syndromes with well-defined genetic causes, such as mutations in the WT1-gene in Denys-Drash syndrome (genitourinary malformations and susceptibility to Wilms Tumour) or in the DHCR7-gene in Smith-Lemli-Opitz syndrome (malformations of the heart, lungs, kidneys, gastrointestinal tract, and genitalia)²⁹.

Heritability is high³⁰ and having an affected family member is the greatest risk factor so far identified¹⁰, although most non-syndromic cases are idiopathic²⁹. Familial clustering can be seen in between 4 and 25% of cases¹⁰. The risk to the next male sibling increases by 9–17% with increasing severity of the malformation in the index case¹⁰. This could be due to shared genetic vulnerability as well as shared environmental factors⁸. Overall, the heritability of hypospadias is presently thought to be between 57% and 77%, with equal transmission through maternal and paternal lines^{29,30}.

Regarding environmental factors, low birth weight, when corrected for gestational age, has been found to be a major risk factor for hypospadias¹⁰. Maternal hypertension and preeclampsia are also associated with increased risk,

suggesting that placental insufficiency and suboptimal growth in the first trimester are risk factors⁹. Maternal exposure to chemical pollutants has also been investigated as a possible cause for an increased incidence of hypospadias, but no specific environmental pollutant or endocrine disruptor has yet been identified as having a general impact across populations¹⁰. Interestingly, some studies have shown that the less severe distal and middle types of hypospadias occur more frequently in familial cases, while the more severe proximal types are more closely associated with low birth weight³⁰. Thus, there may be a stronger genetic predisposition for distal hypospadias, while the proximal phenotype is more strongly associated with pregnancy and placenta-related factors³¹.

Epidemiology

Hypospadias is one of the most common congenital malformations in boys. In Sweden, it is estimated that at least 400 boys are born with hypospadias each year³². The majority have a mild malformation³². From the beginning of 2000, an increased incidence of hypospadias has been reported in Sweden and in Europe^{32,33}. The epidemiology of hypospadias has been extensively studied in some countries, however data are heterogeneous and findings are contradictory³⁴ because of inconsistencies in inclusion and exclusion criteria, such as inclusion of all births vs inclusion of all live births or singleton births only, or reports on all cases and phenotypes vs only those undergoing surgical correction, which excludes a potentially large number of patients with mild malformations. Also, there have been few or no studies of hypospadias in low and middle income countries³⁴.

A recent review of studies from Asia and South America (excluding Brazil) indicated a low incidence (<5/10,000 total births) in those regions, while reports from Europe, North America, and the Middle East showed a high incidence (>50/10,000 total births)³⁴ (Table 1).

Worldwide prevalence of hypospadias

Region	Mean prevalence as per 10,000 live births	Range
North America	34.2	6–129.8
Europe	19.9	1–464
Australia		17.1–34.8
Africa	5.9	1.9–110
South America	5.2	2.8–110
Asia		0.6–69

Table 1: Mean worldwide prevalence of hypospadias per 10,000 live births³⁴

Surgical Management

Aims of the surgical treatment

The overall aim is to create a urethra with a distal meatus allowing for functionally good micturition, preferably standing voiding without spraying, along with a straight erection that allows penetrating intercourse, and finally, a cosmetically acceptable result that will minimise stigma. Ideally this can be offered with as few surgical procedures as possible and with few complications.

General surgical principles and relationship to phenotype in hypospadias management

Many methods for the surgical repair of hypospadias have been described throughout history¹¹. Improvements in equipment and materials, such as magnification glasses and sutures, as well as refinements to surgical technique, have made it possible for many patients to have defects repaired in one session, minimising complications, rather than in two sessions followed by possible secondary repairs due to complications. Ultimately, the phenotype or the degree of the malformation will determine the choice of surgical technique and the risk for complications^{11,35}.

Local tissues in the immediate vicinity of the urethral plate can be used for construction of the neo-urethra in some cases, but preputial flaps or transplants are often required to allow for adequate length of the neo-urethra in more advanced cases^{11,36}. In patients with ventral curvature, the repair must begin with excision of the chordee¹¹. The most frequently used local flap is from the prepuce. Use of scrotal flaps has also been described³⁶. However, when skin from the proximal penile shaft or the scrotum is used, the surgeon must account for the (future) presence of hair, as a neo-urethra with internal hairs can cause both cosmetic and obstructive problems³⁷. When local tissues are absent or inadequate, grafts, most frequently oral mucosa, must be used^{36,38}. Generally, the more advanced reconstructions are performed in two steps. The first for excision of the chordee with repair of the ventral defect with a flap or graft which leaves a surplus of tissue on the ventral side that is used in the second session for the urethral repair³⁸. The two sessions should be separated in time to allow for adequate tissue healing and neovascularisation³⁹. The challenges of constructing a long neo-urethra in patients with proximal hypospadias are considerably greater than in the more distal cases. The neo-urethra also lacks the native propulsive qualities of the native, spongiosum-covered urethra, and the longer the reconstruction, the greater the risk of abnormal micturition and ejaculation. Furthermore, the risk of vascular scarcity

scarcity in long reconstructions is always greater as the base of the flap has to be thinned in order to reach the required distance. But, as there is, yet, no reconstructed urethra that possesses the same biological and urodynamic properties as the native urethra, functional outcomes can be affected even in uncomplicated cases⁴⁰. To minimise the risk of fistula formation a fascial layer (Buck's or Darto's) can be interposed between the suture lines⁵⁹.

Management of chordee

Ventral curvature with chordee is common in hypospadias, although the true nature of the chordee, in terms of its role in the pathology of the ventral curvature and the importance of its excision, remain unclear^{14,16,19,24}. Recent literature has recommended three ways to manage chordee with respect to the urethral plate: (1) division and excision of the urethral plate followed by extensive ventral dissection along the corporal bodies; (2) extensive mobilization, without division, of the urethral plate, followed by further dissection at the ventral corporal bodies; and (3) preservation of the urethral plate as a template for an onlay island flap combined with dorsal plication for residual penile curvature¹⁴.

Timing of hypospadias surgery

International expert recommendations suggest surgery of the male genitalia between the ages of 6 months and 18 months⁴¹. This recommendation is based on surgical and anaesthetic considerations and on psychological considerations such as genital awareness and cognitive, emotional, and psychosexual development. However, there has been scant evidence to support these recommendations, and a more recent study did not support them⁴². There is also rising support among patient groups for delaying aesthetic genital surgeries in cases of minor hypospadias without functional impairment until the patient himself is at an appropriate age to give informed consent⁴³.

Complications in hypospadias repair

Hypospadias surgery is beset with difficulty and complications. The most common complications include recurrent curvature, preputial dehiscence, glans dehiscence, urethral fistula, meatal or urethral stenosis, urethral stricture, urethral diverticulum, hairy urethra, penile skin deficiency, and abnormal penile skin configuration³⁵. Although complications can be isolated, they are often

clustered^{44,45}. The term hypospadias cripple describes those patients who are affected by the greatest incidence of multiple complications and failed repairs, in whom the penis may be scarred, hypovascular, and shortened³⁵.

Outcomes assessment

Only a few studies have evaluated long-term results^{40,46-49} and investigated criteria for deeming a reconstruction final. There is as yet no generally accepted system for classification of hypospadias surgery outcomes and complications⁵⁰, and the challenge of standardising the management and assessment of long-term outcomes according to evidence-based protocols remains²⁸. Complicated repairs can be defined as those in which the primary surgery does not achieve the cosmetic and functional goals of a straight penis with a glanular meatus that allows normal urinary and sexual function³⁵. However, functional impairment can be inherited in the original malformation, persisting despite adequate surgical repair, or be related to surgical complications³⁵. Failed surgeries can also include complicated repairs as well as uncomplicated repairs that do not fulfil patient expectations and result in dissatisfaction³⁵. Because patient satisfaction is highly subjective and depends on the ability of the patient to cope with cosmetic and functional abnormalities³⁵, patient perception of the outcomes may diverge widely from the assessment of the surgeon^{35,51}.

Hypospadias Objective Scoring Evaluation (HOSE)

The hypospadias objective score evaluation (HOSE) is a validated five-point scoring system that incorporates five domains: meatal location and shape, urinary stream, straightness of erection, and presence and complexity of urethral fistula (Appendix 1)⁵⁰, for a total score of 5 to 16 points. In the original description of HOSE, a total score of ≥ 14 points indicated an acceptable outcome after hypospadias repair⁵⁰. Since its introduction, HOSE has been used frequently for both short- and long-term assessment after hypospadias surgery^{40,46,52}. Seibold et al⁵² have recommended that a total of score of ≥ 14 points should be defined as excellent, with a score of 16 points indicating no restriction and a score of 12 to 15 points indicating minimal restriction. Other objective and validated scores to evaluate the outcomes of hypospadias surgery include the Paediatric Penile Perception Score⁵³ and the Hypospadias Objective Penile Evaluation Score⁵⁴.

Patient-reported outcomes

The purpose of patient-reported outcomes is to complement traditional clinical outcome measures by including the patient's perspective regarding the treatment provided and the results achieved. The disease burden of hypospadias is life long as hypospadias is a congenital malformation and the patient is usually scheduled for the initial treatment during early childhood, followed by post-operative and long-term clinical follow-up through post-adolescence, and possibly by additional treatments and follow-up as an adult because of long term complications. Thus, data that account for the patient's perspective and memories from the surgery and follow-up care are important to improve the quality of care and to convey maximum benefit to the patient. Information from patient-reported outcomes questionnaires is also useful for improving pre-operative communication and for helping to ensure that the patient has realistic expectations⁵⁵.

Aims

The overall aim of the doctoral project was to evaluate and improve the surgical care and follow-up of hypospadias patients at Skåne University Hospital. The specific aims of the included studies were:

- Evaluation of patients who underwent hypospadias reconstruction according to our surgical algorithm during childhood and assessment of the long-term results after completion of puberty in order to determine the appropriate duration of the post-operative clinical follow-up.
- Evaluation of the surgical algorithm for secondary reconstructions when local tissues are present.
- Investigation of patient satisfaction with long-term results after hypospadias surgery. Also, investigation of the patients' views and memories of the childhood surgery and follow-up visits.
- Detailed characterisation of the cellular composition of the chordee and the urethral plates in hypospadias patients with ventral curvature. Also, to investigate whether there are similarities between the cellular composition of tissues in recurrent ventral curvature requiring re-operation and ventral curvature of native hypospadias.

Material and Methods

Patients

Study I and III

A cohort of 157 patients who underwent primary reconstruction of hypospadias at the Department of Plastic and Reconstructive Surgery, Skåne University Hospital, Malmö, Sweden by the senior hypospadias surgeon between 1989 and 2009 and who were eligible (16 years or older) for a post-pubertal clinical follow-up visit was identified through a search of consecutive patient records. In Study I, 149 of the 157 patients were scheduled for the post-pubertal visit or had been lost to follow-up (see Fig. 8) and the remaining 8 patients were awaiting scheduling of the follow-up visits.

In Study III, the same cohort of 157 patients as in Study I was investigated. All of the patients were now 18 years old or older. Five were excluded due to cognitive impairment. Thus 152 patients were included and sent a questionnaire. Eighteen questionnaires were returned due to invalid address, and these patients were also excluded. Thus, 134 patients were finally included in the study and 39 (29%) returned a completed questionnaire (Fig. 9). Of the 114 patients investigated in Study I, 112 were also included in study III after the exclusion of 2 due to cognitive impairment. Of these, 31 responded.

Fig. 8: Flow chart of patients in Study I

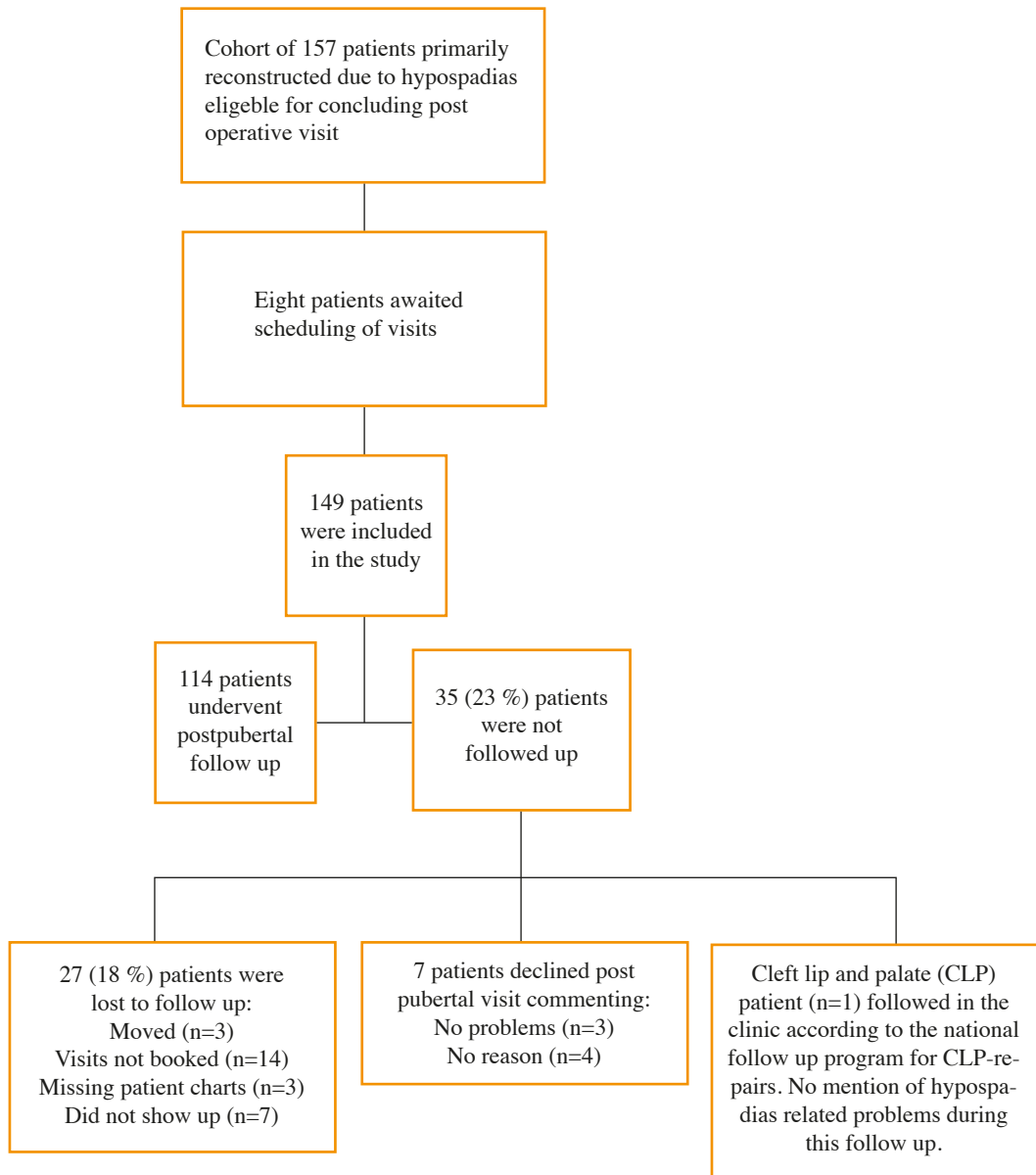
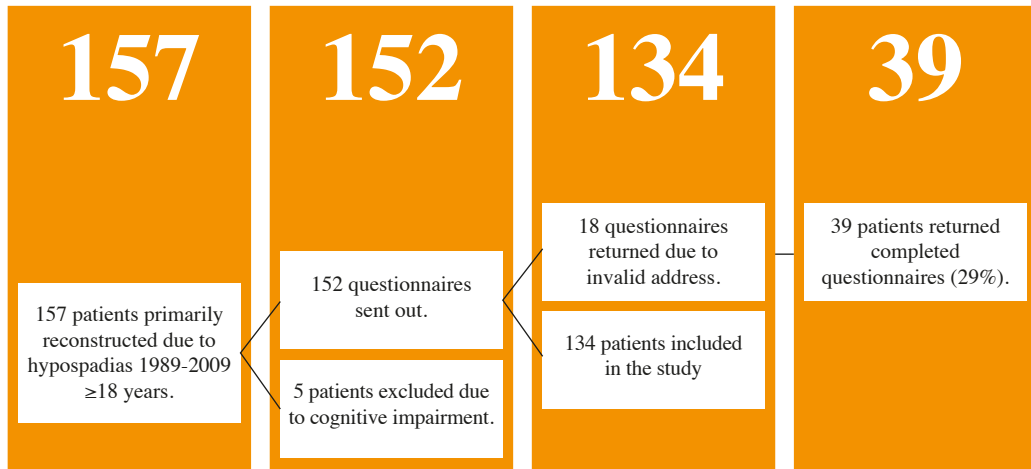


Fig. 9: Flow chart of patients in Study III



Study II

A cohort of 36 patients, aged 5 to 30 years, who were referred to the Department of Plastic and Reconstructive Surgery, Skåne University Hospital, Malmö, Sweden, between April 2007 and April 2014 for re-repair due to previously failed hypospadias reconstructions.

Study IV

A cohort of 10 consecutive patients scheduled for primary or secondary orthoplasty due to hypospadias with ventral curvature at the Department of Plastic and Reconstructive Surgery, Skåne University Hospital, Malmö, Sweden, were included in the study between October 2014 and October 2015.

Median age at biopsy was 5 years (range: 1.5 to 18 years). Five of the patients had had previous surgery (Table 2). In 2 of these, the urethral plate had been preserved and the biopsy could therefore be taken from it. In one patient (patient 10:IV), the portion of skin in the area between the meatus and the penoscrotal angle was so small that a deep chordee biopsy could not be taken as a separate entity, and in 1 patient with crypto-hypospadias only the deep chordee was biopsied as no urethral plate was present (patient 9:IV). In total, 6 biopsies were taken from the urethral plate and 9 from the deep chordee. Details of the degree of hypospadias, types of surgery, and time since last surgery are given in Table 2.

Table 2: Patient characteristics in Study IV

Patient	Age (years)	Degree*	Previous Surgery	Surgery	Time since last surgery (years)
			Yes (Previous Method(s) Used)/No	(Method Used in Current Study)	
1:IV	1.5	III	No	Byars 1 ¹	N/A
2:IV	4.5	II/III	No	Byars 1 ¹	N/A
3:IV	5	II	No	Byars 1 ¹	N/A
4:IV	4.5	III	Yes: (1.Byars 1 ¹)	Complementary orthoplasty	3,5
5:IV	5.5	II/III	Yes: (1.MAVIS ² , 2.Fistula closure)	Orthoplasty	0.5
6:IV	6	III	Yes: (1.MAVIS ² , 2.MAVIS ²)	Orthoplasty	1
7:IV	9.5	III	Yes: (Missing Data**)	Orthoplasty	Missing Data
8:IV	18	III/IV	Yes: (1.Byars 1 ¹ , 2.Complementary orthoplasty, 3.Complementary, orthoplasty, 4.Byars 2 ¹ , 5.Fistula closure)	Complementary orthoplasty after puberty	11
9:IV	1.5	Crypto-hypospadias and rotation	No	Orthoplasty	N/A
10:IV	9	III	No	Byars 1 ¹	N/A

*Degree I: glanular, degree II: penile, degree III: peno-scrotal, degree IV: perineal

** Patient was operated previously in former home country, patient charts were not available.

Surgical Methods: ¹Byars⁵⁶, ²Mathieu⁵⁷

Methods

Studies I–III

The study methodology was a retrospective chart review. All medical charts from all patients included in the studies were reviewed. The clinical characteristics of all hypospadias patients were clearly documented in a structured manner in the charts by the senior hypospadias surgeon. HOSE scores were calculated for the patients based on these detailed notes, which included data relevant to all areas covered in the HOSE form⁵⁰. Data regarding the degree of the malformation, the surgical method, the number of surgical procedures, immediate post-operative complications, and long-term complications reported at the follow-up visits were also obtained from the charts.

Clinical classification in Studies I–IV

Hypospadias was classified according to the location of the meatus after orthoplasty, as determined by the chart review and the ICD classifications as: balanic (degree I), distal (degree II), penoscrotal (degree III), or perineal (degree IV)²⁷. Patients with crypto-hypospadias are those with a normally positioned meatus but significant ventral curvature.

Surgical treatment in Studies I–IV

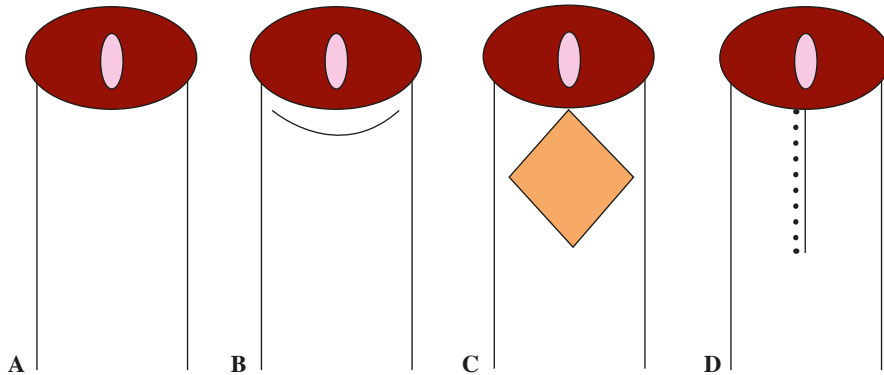
Primary surgical treatment in Studies I and III

The treatment algorithm that has evolved during the study period at the Department of Plastic and Reconstructive Surgery takes the urethral position and the ventral curvature into account when choosing the surgical technique. Historically, all patients at the department had undergone a two-stage reconstruction according to the Byars technique (see below). However, the introduction of the Mathieu and Scuderi techniques have allowed for single-stage reconstructions in patients with less advanced malformations. Thus, after the introduction of the one-step techniques mentioned above, the selection of surgical technique was as follows:

Orthoplasty

Orthoplasty and realignment of the skin was the technique of choice in cases of crypto-hypospadias with ventral curvature and a meatus of good quality located on the glans (Fig. 10 A–D).

Fig. 10 A–D: Orthoplasty



A. Indication for orthoplasty alone is a meatus that is normally positioned on the glans in the setting of ventral curvature of the penile shaft.

B. Orthoplasty is commenced through the division of the foreskin along with a circumferential incision 3 mm from the coronary sulcus.

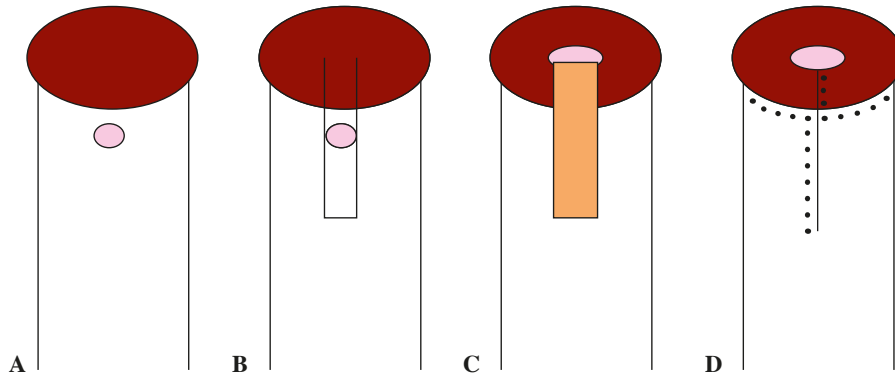
C. This creates a diamond-shaped defect on the penile shaft, through which the chordae can be excised. The plane of preparation is the underlying fascia and all remaining chordae and fibrous tissues are divided and excised.

D. Preputial flaps are rotated to cover the ventral defect.

Mathieu procedure

The Mathieu procedure (Fig. 11 A–D) was suitable in cases of degree I hypospadias with slight or no ventral curvature.

Fig. 11 A–D: The Mathieu procedure



A. Indication for the Mathieu one-stage procedure⁵⁷ is a distal meatus with only moderate ventral curvature.

B. A skin flap is marked on the distal penile shaft for the creation of a flap-based distal urethral reconstruction.

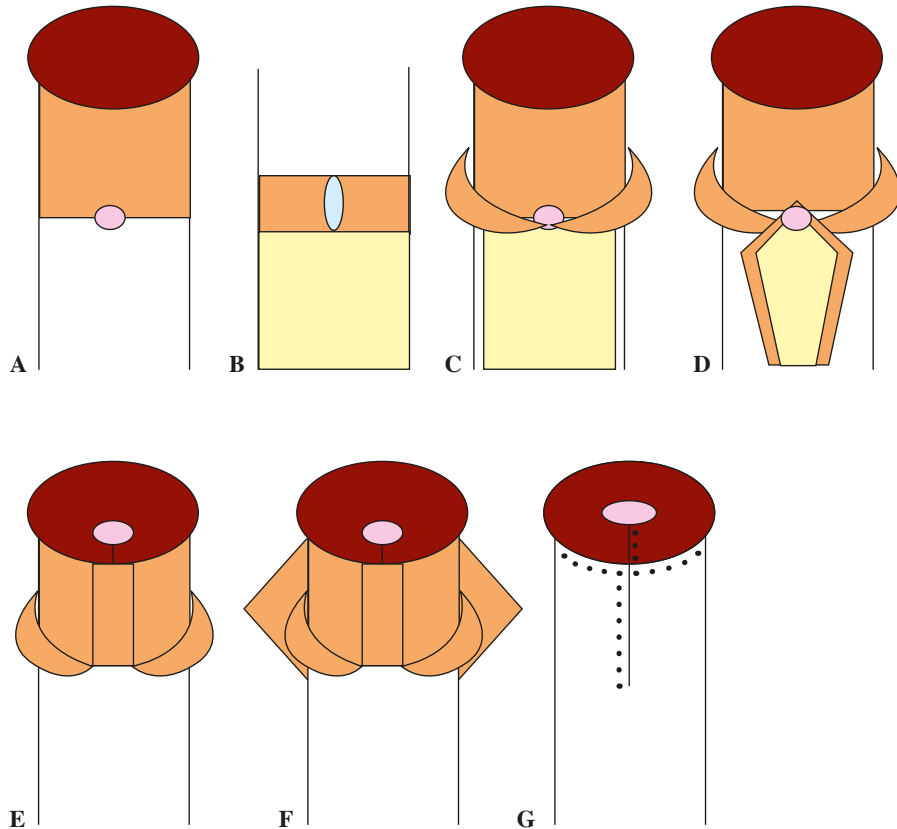
C. The flap is rotated 180° and sutured into incisions on either side of the glanular groove and up to the tip. If chordee tissue is present, it is excised.

D. The prepuce is divided and mobilised until an outer cover is achieved. The catheter is kept postoperatively for 5 days.

Scuderi technique

The Scuderi technique (Fig. 12 A–G) was used for patients with mild degree II hypospadias with no or moderate ventral curvature.

Fig. 12 A–G: The Scuderi technique

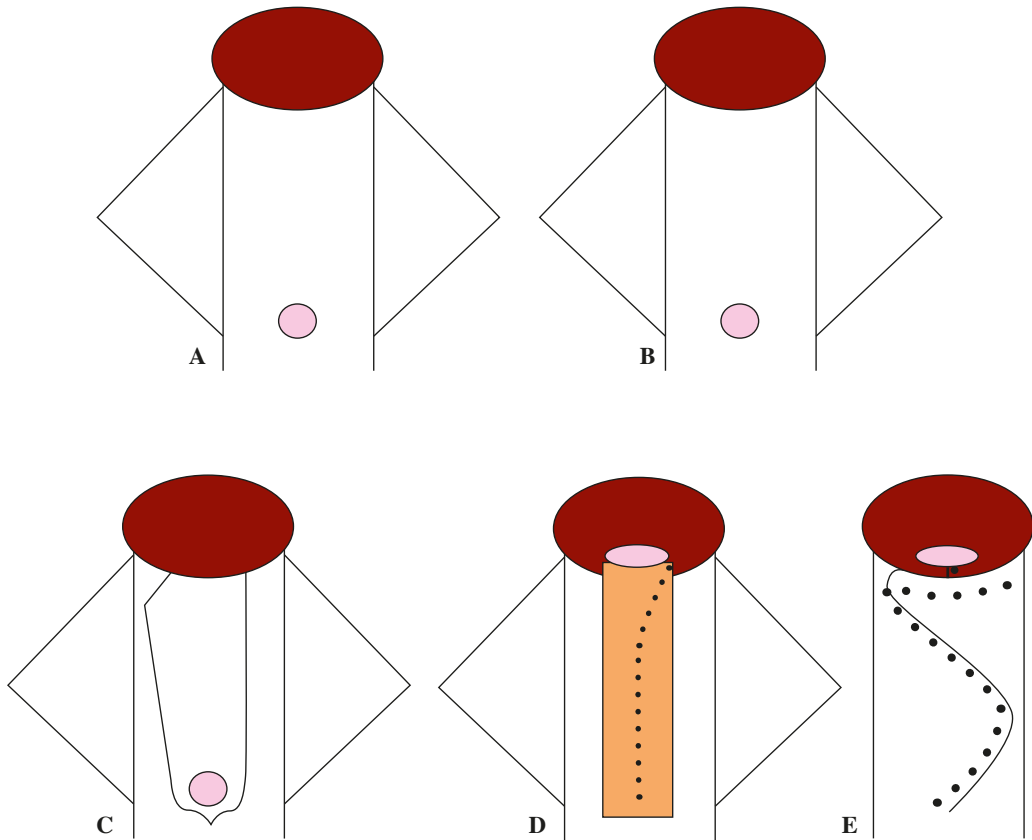


- A. In hypospadias with a mid-shaft meatus after the release of chordee (degree II hypospadias), the Scuderi one-stage procedure⁵⁸ is suitable.
- B. A flap is created from division of the prepuce. It is partly de-epithelialised and incised to create a buttonhole that allows it to be transposed to the ventral side of the penis.
- C. The glans and distal penis are passed through this buttonhole.
- D. The flap with its epithelium are then wrapped around a catheter and anastomosed against the native meatus.
- E. This has the advantage of allowing the seam to be on the dorsal side of the neo-urethra to minimise the risk of fistula.
- F. The remaining lateral portions of the prepuce are used as the outer lining after complete removal of all chordee tissue.
- G. The catheter remains for 6 to 7 days post-operatively.

Byars two-stage procedure

In cases of proximal hypospadias, degree III and IV, and the more pronounced cases of degree II hypospadias, reconstruction was performed in two stages according to Byars (Fig. 13 A–E).

Fig. 13 A–E: The Byars two-stage procedure



A. A staged reconstruction according to Byars⁵⁶ is used when the urethral reconstruction is long and/or the ventral curvature is prominent. At age 4.5 to 5 years, the release of the chordee is initiated. This orthoplasty is commenced through a circumferential incision 3 mm from the coronary sulcus with division of the prepuce dorsally. On the ventral side, the fibrous chordee is divided and partially excised, the plane of preparation being the underlying fascia.

B. The new position of the meatus is secured with a single suture and the dorsal flaps are rotated to cover the ventral defect. A urinary catheter remains in place for 3 to 4 days postoperatively.

C. Stage two comprises urethral reconstruction, which is to be performed 6 months after the stage one procedure. A U-shaped incision is made just proximal to the meatus, terminating on either side of the glans.

D. The inner lining is closed in two layers around a urinary catheter. A waterproofing technique⁵⁹ is used to minimise the risk of fistula formation.

E. The outer lining is also closed in two layers. If there is not enough skin on the outer lining, a diamond-shaped defect is created by an incision on the dorsal side that is covered by a split skin graft. In certain cases the defect can be closed with a transverse primary suture line. The urinary catheter remains for 5 to 6 days postoperatively.

Catheters, suture technique, dressing, and antibiotics

With very few exceptions, conventional Foley catheters, Charrier (Ch) 8 or 10, were used. Initially, 5/0 Chromic Gut™ was used for suturing, but after this product was taken off the European market, 5/0 or 6/0 Vicryl™ was used instead. The dressing consisted of a layer of 1% hydrocortisone cream (Terra-Cortril™) over the suture line, a petroleum jelly (Vaseline™) pad, a cotton pad, a ring of foam rubber, and surrounding tape. Thus, the dressing resembled a chimney. During all urethral reconstruction procedures, including fistula closures, prophylactic sulfamethoxazole and trimethoprim antimicrobial (Eusaprim™), 5 mL twice daily for 5 days, was given.

Fistula closure

Fistulas were closed by circumcision, invagination, and suturing. In some cases, an outer layer could be created simply by mobilising the local skin. In other cases, a local flap was required.

Urethral stricture and meatal stenosis

Meatal strictures were treated by meatotomy, and urethral stenosis was dilated as a first measure.

Timing of primary surgical treatment, Studies I and III

In accordance with the treatment program, the patients were first seen in the outpatient clinic at the age of 3 months for examination of the meatus with regard to possible stricture, to give information to the caregivers, and to begin planning for the future repair. Early release of the chordee was indicated for patients with proximal hypospadias and prominent ventral curvature. The patient was then seen in the outpatient clinic at age 1 year and, when indicated, operated at age 18 months in accordance with step one of the Byars technique, with orthoplasty by release of chordee and transposition of preputial flaps for ventral coverage and for the creation of a skin surplus to allow for the later urethral reconstruction (step two). In patients with ventral curvature and/or proximal hypospadias without the need for early release of chordae was scheduled for the Byars stage one procedure at age 4.5-5 years. Urethral reconstructions (by the Mathieu, Scuderi, or Byars stage two technique) are generally performed at age 5 to 5.5 years. Thus, patients are seen in the outpatient clinic at age 4 years to begin planning of the reconstruction and to evaluate for possible additional orthoplasty in patients who have undergone early release of chordee. The preferred age for urethral reconstruction is based on tradition and on clinical experience in the department, and repairs are planned without delay for patients who are referred to the department after the age of 5.5 years.

Salvage repairs in Study II

Pre-operative evaluation

At the first outpatient visit, the patients were evaluated according to a standard protocol, with particular attention to the presence of a ventral curvature. Review of medical records from the referring hospitals revealed that the 36 patients had undergone a total of 109 prior hypospadias-related surgical procedures, median 3 per patient, range 1 to 8, including isolated preputioplasty (6 patients; 12 procedures). In addition to these procedures, meatotomies had been performed in 8 cases. In 3 cases, conclusive preoperative evaluation could not be accomplished during the routine outpatient visit and the evaluation was therefore supplemented with an examination under general anaesthesia. The findings of the preoperative evaluations included remaining ventral curvature in 21 patients (58%), fistula in 28 (78%), of which one involved the preputium only, meatal dystopia in 13 (36%), and unfavourable aesthetic result in 24 (67%). All of the patients had adequate local tissues to allow secondary repair in accordance with our algorithm. Surgical procedures were conducted from October 2007 through November 2014.

Treatment algorithm

Based on the preoperative outpatient evaluation, the patients were allocated to one of three treatment groups (Fig. 14).

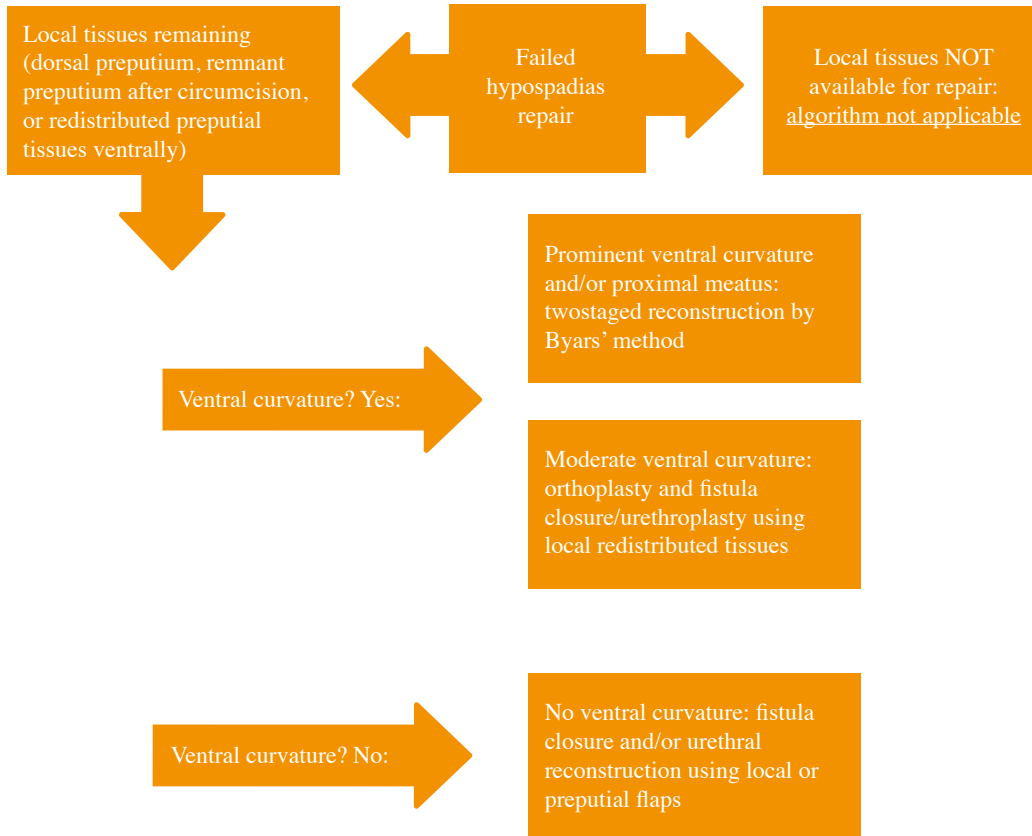
A. Patients without ventral curvature, but in whom fistula closure or supplementary urethral reconstruction was required, underwent one-stage reconstruction. Fistulas were closed following the general principles described below. Local flaps were used for distal urethral reconstruction. Either local flaps or preputial flaps covered any ensuing ventral defect after urethral reconstruction or fistula closure.

B. In patients with moderate ventral curvature, and in whom there was also a need for fistula closure or supplementary distal reconstruction, an orthoplasty was incorporated into the procedure. Thus, all remaining chordee and other constricting tissues were excised before the fistulas were closed and/or the urethra was lengthened. This created a wide ventral defect that was closed by preputial flaps.

C. For patients with completely failed reconstructions and remaining prominent ventral curvature, the treatment was a two-stage reconstruction according to a modified Byars technique⁵⁶. During the first stage, a thorough orthoplasty with excision of all remaining chordee and other constricting tissues

was performed and the dorsal prepuce was divided and moved ventrally to cover the defect. Six months later, the urethral reconstruction was performed by making a U-shaped incision encompassing the meatus and terminating on either side of the glans. The developed flap constituted the inner lining around the catheter and the preputial flaps constituted the outer lining.

Fig. 14: Treatment algorithm for re-do hypospadias repair



General surgical principles

Urethral defects were closed with mucosal inverted sutures using 6/0 Vicryl™ (polyglactin 910; Ethicon, Johnson and Johnson, Medical Limited, Norderstedt, Germany). In addition, a layer of soft tissue from the ventrolateral fascia was placed between the inner and outer linings for waterproofing⁵⁹. Foley urethral catheters, Ch 8 or 10, were used for urine diversion and neo-urethral moulding. In cases requiring a long urethral reconstruction, a suprapubic catheter was used in addition to the urethral catheter. The urethral catheters stayed in for 5 to 7 days, depending on the nature of the reconstruction. Suprapubic catheters were removed when normal micturition through the urethra had been established, usually one day after removal of the urethral catheter. All of the patients remained in-hospital while the catheters were in place. For urethral reconstructions or fistula closures, sulfamethoxazole/trimethoprim (Eusaprim™; Vitaflo Scandinavia, Gothenburg, Sweden) was administered until the catheters were removed.

Follow-up protocol and clinical evaluation in Studies I–III

In accordance with a standard follow-up protocol, the patients who underwent reconstruction at the Department of Plastic and Reconstructive Surgery, Skåne University Hospital, Malmö, were scheduled for a first visit 3 weeks after release from the hospital and at any other time it was clinically indicated. When staged surgery was planned, the boys were also evaluated 2 to 3 months prior to the second procedure to ensure optimal conditions for the operation. After the completion of surgical repairs, the standard follow-up protocol included visits at ages 7, 10, 13, and past puberty, normally age 16. If patients had completed puberty at the 13-year visit, no additional visits are planned unless clinically indicated. For patients who had not completed puberty by age 16, an additional clinic visit after the completion of puberty was planned. Pre-pubertal children who have undergone salvage repairs are included in the standard follow-up protocol.

At the final, post-pubertal visit, the patient was examined and interviewed about his urinary and sexual function in accordance with a structured interview. At this visit, the patient also received a thorough history and explanation of his malformation and of the surgical treatments rendered.

Until 2004, patients underwent screening uroflow evaluations to supplement the physical examination. However, as these examinations did not detect any occult strictures⁶⁰, and they are now performed only when clinically indicated.

Patient-reported outcomes in Study III

A previously used and validated questionnaire⁴⁷ was translated and adapted to fit Swedish conditions. For linguistic validation and conceptual equivalence, the questions were forward-translated by the authors and then back-translated by a professional translator. The questionnaire consisted of 9 items (Appendix 2 and 3), which included 4 satisfaction outcome questions derived from the hypospadias outcome questionnaire⁴⁷ and 5 questions about the patient's experiences with his medical care. The satisfaction outcome questions addressed the patient's satisfaction with his penile appearance, sexual and urinary function, and overall surgical results. These were rated on a 1 to 5 visual scale, with 1 being very dissatisfied, 3 being neutral, and 5 being very satisfied. Each question provided additional space for comments. The questions regarding the patient's experiences with his medical care addressed the paediatric surgery, the follow-up program, and whether or not additional medical care was needed because of the hypospadias malformation or its initial repair. The patients had a choice of answers that included "yes", "no", "do not know", "positive", or "negative". A patient who replied "yes" to the question about receiving medical care outside of our department was asked to specify the nature of the problem and when it had appeared.

The questionnaires were sent to the 152 study patients in 2014 together with a study information sheet, a consent form, and 2 pre-addressed, stamped envelopes (one for the completed questionnaire and one for the signed consent form). The consent form and the questionnaire were both marked with the patient's study identification number, which was known only to the study investigators; two envelopes were sent to allow the questionnaire to be returned anonymously, separate from the signed consent form. Patients who did not respond but could be contacted by telephone were called, informed about the study, and asked if they had any questions or comments. Patients who did not respond were also sent the questionnaire and study information a second time.

Tissue sampling in study IV

During surgery, the urethral plate was identified as the epithelium-lined structure distal to the hypospadiac meatus and stretching to the expected position of the normal urethral meatus, along with the immediate underlying tissue. The chordee, or the deep chordee, was defined as the fibrous tissue underneath and lateral and proximal to the urethral plate. This tissue reaches down to the fascia albuginea surrounding the corpora cavernosa. Samples 5 to 10 x 5 x 1 mm were taken from

the urethral plate when present (Fig. 15) and from the deeper subcutaneous fibrotic ventral tissue, i.e. the deep chordee (Fig. 16). The samples were sent in 4% neutral buffered solution of formaldehyde for microscopic examination.

Fig. 15: Biopsy from the urethral plate

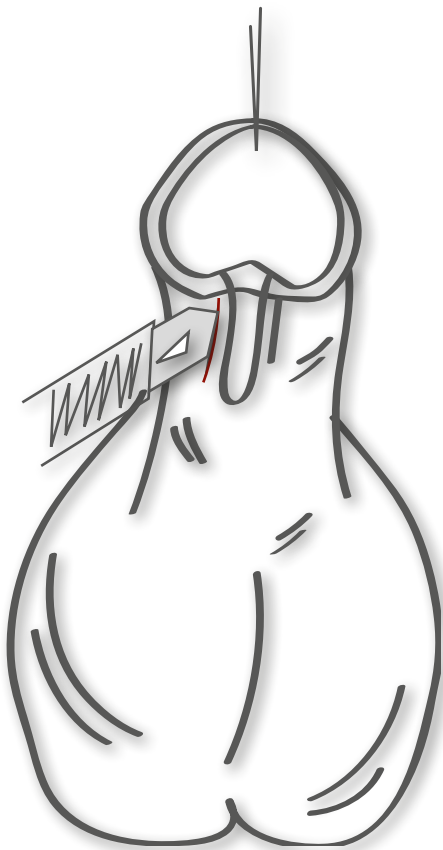


Fig. 16: Biopsy from the deep chordee

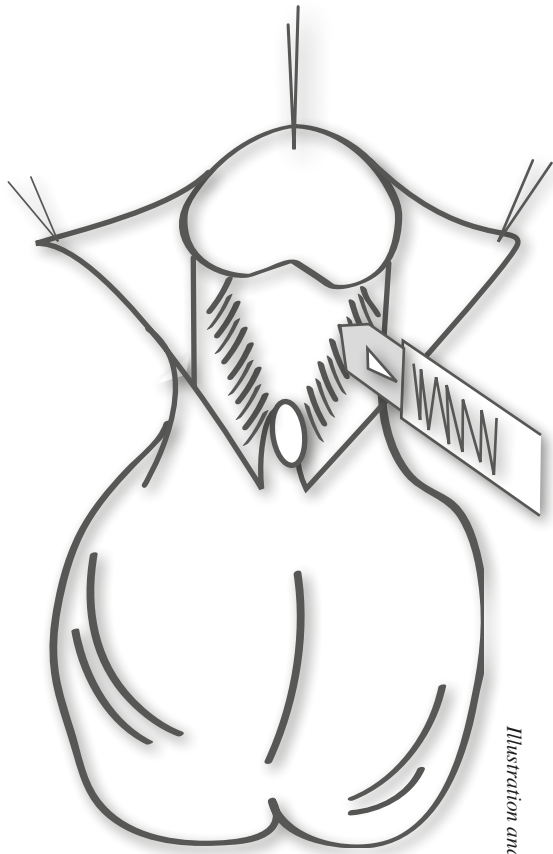


Illustration and copyright by Victoria Schönström.

Histopathology and immunohistochemistry in Study IV

After fixation, all sampled tissue was embedded in paraffin, with one block representing the urethral plate, if present, and the other representing the chordee. Sectioning, haematoxylin-eosin staining, and Alcian blue periodic acid Schiff base and Masson trichrome staining were performed by standard histochemical methods. For immunohistochemistry, sections (4 μm) were cut to positively charged slides and subjected to heat-induced antigen retrieval before incubation with primary antibodies and automated staining on a Benchmark Ultra (Ventana). The following antigens (primary antibodies in parentheses) were detected in all samples: CD3 (clone 2GV6, ready to use, Ventana), CD20 (clone L26, ready to use, Ventana), CD68 (clone mPG-m1; 1:100, DAKI), CD31 (clone JC70, ready to use, Ventana), cytokeratin 7 (clone OV-TL 12/30, ready to use, DAKO), desmin (clone D33, 1:40, DAKO), S100 (polyclonal, Ventana), and Ki67 (clone MIB-1, 1:50, DAKO). In each section, the relative prevalence of T lymphocytes (CD3+), B lymphocytes (CD20+), macrophages (CD68+), vessels (CD31+), smooth muscle cells (desmin+), and nerve branches (S100+) were graded on a scale from 0 to 3, where 0 represented a complete absence and 3 corresponded to rich presence. For a more precise estimation of macrophage prevalence, deep chordee sections were also scored for CD68+ cells in 10 randomly selected high-power fields (magnification 40 x 10). Ki67 was used to distinguish non-proliferating from proliferating cell types.

Statistical analysis

Categorical values were expressed as frequencies or proportions and continuous variables were expressed as medians and ranges. The chi-squared test was used for categorical variables, except when the expected frequency was below five, in which case Fisher's exact test was used. Non-parametric tests were used because data were not normally distributed. The Mann-Whitney U test was used for non-parametric continuous variables and expressed as the median with interquartile range (IQR).

A p-value of less than 0.05 was considered to indicate a statistically significant association. The percentages have been rounded off to whole numbers, and therefore the total do not always amount to 100. Percentages were not calculated for groups with $n < 25$. Data were analysed with SPSS (Statistical Package for the Social Sciences 19.0, IBM, Chicago, IL).

Ethics

Permission to create a patient register was obtained in accordance with the Swedish Privacy Protection Law. The procedures followed were in accordance with the revised Helsinki Declaration of 1964 and the Good Clinical Practice (GCP) guidelines. Studies III and IV were approved by the Regional Ethical Review Board in Lund, Sweden (2013/758 and 2015/535 respectively). Each study patient, or in study IV, the guardians of the patient, gave their written informed consent to participate.

Results

Study I and Study III

Data on degree of malformation and surgical technique for the patient cohort and all patients in Studies I and III are presented in Table 3.

Table 3. Overview of the patients in Studies I and III

	Complete study cohort (n=157)	Study I (n=149)			Study III (n=134)		
	Complete cohort (n=157)	All patients (n=149)	Investigated patients (n=114)	Patients without concluding visit (n=35)	All patients (n=134)	Responders (n=39)	Non-responders (n=95)
Degree of malformation							
I*	109	105	79	26	99	27	72
II	30	29	25	4	25	7	18
III	9	8	6	2	5	2	3
IV	4	4	3	1	3	1	2
Missing data	5	3	1	2	2	1	1
Surgical method							
Orthoplasty	9	9	8	1	7	2	5
Mathieu	35	35	25	10	30	9	21
Scuderi	17	15	14	1	17	8	9
Byars	93	90	67	23	79	18	61
Missing data	3	0	0	0	1	1	0

* Including cryptohypospadias

Study I

All patients with degree III and IV, most of the patients with degree II (72%), and about half (49%) of the patients with degree I hypospadias had a Byars reconstruction. The others were reconstructed with a Scuderi or Mathieu procedure. Eight patients (degree I) only had orthoplasty and realignment of the skin. Among the patients who underwent staged reconstructions, 8 needed intermediate operations, including additional release of chordee, meatotomy, and different types of correction of the skin or flaps, before urethral reconstruction. Median age at urethral reconstruction was 5 years (range 4 to 16). Nineteen patients needed secondary corrections with elongation of the urethra and cosmetic corrections of the skin or of scar formation and excisions of epithelial cysts.

Complications after surgery

At the concluding visit, 32 patients (28%, 32/114) had various shortcomings (23 events) or complications (12 events). Six patients had incurvation reappear during puberty, and one of these required additional orthoplasty; the outcome remains subject to follow-up (Table 4). None of the patients had incurvation after corrective surgery and prior to puberty. Two patients had fistulas, one without functional implications, which is why corrective surgery was declined. The other patient did not want additional surgery at the time. In total, four patients had surgical intervention due to urethral stricture. They were identified at the concluding clinical visit, or at clinical visits thereafter.

The overall rate of fistula formation was 11% (12/114) (Table 4). There was a significant association between the degree of hypospadias and the occurrence of fistula ($p < 0.001$, $\chi^2 = 86.94$). There was also a significant association between the degree of hypospadias and the total number of complications ($p < 0.001$, $\chi^2 = 63.67$). Twelve of the 23 patients had various aesthetic shortcomings, including constricting scar tissue, skin surplus, and epithelial cysts. One had surgical correction due to aesthetic complains. Eight patients complained of spraying, one of whom received surgical correction. Three patients had minor complaints regarding micturition.

Median age at the concluding visit was 16 years (range 13 to 21). According to the total HOSE score, 85% (93/108) of the patients had an acceptable result after reconstruction if the reconstructed meatal shape is considered circular (Table 5). More patients with degree I hypospadias had satisfactory results according to HOSE than patients with degree II and III hypospadias (Table 5).

Table 4: Overall complications

	Type of overall complication per degree of malformation					Type of overall complication per surgical method				
	Degree I (n=79)	Degree II (n=25)	Degree III (n=6)	Degree IV (n=3)	Missing data (n=1)	Byars (n=67)	Orthoplasty (n=8)	Scuderi (n=14)	Mathieu (n=25)	Total %
Incurvation after puberty (n=6 ^a)	4	1	1	0	0	3	1	0	2	5
Urethral stricture (n=4)	1	2	0	0	1	3	0	1	0	4
Fistula (n=12 ^b)	2	4	4	2	0	10	0	1	1	11
Post operative hematoma (n=4)	1	1	1	1	0	3	1	0	0	4
Postoperative urinary catheter dysfunction (n=9)	1	5	2	1	0	7	0	1	1	8
Postoperative infection (n=1)	0	0	0	1	0	1	0	0	0	1
Any complication (n=26^c) (%)	9 (11)	10 (40)	4 (67)	2 (67)	1 (100)	27 (40)	2 (25)	3 (21)	4 (16)	26/114 (22)

Table 4: Overall complications, number of affected patients, and percent of all patients (n=114) per degree of malformation and per surgical method. ^aOne of the patients needed surgical correction. ^bTen of the patients needed fistula closure. ^cOne patient can have more than one complication.

Table 5: Total HOSE scores

Score	HOSE scores (%)	
	14-16	11-13
Degree I n=77 (%)	69 (90)	8 (10)
Degree II n=22 (%)	19 (86)	3 (14)
Degree III n=6 (%)	4	2
Degree IV n=3 (%)	1	2
Total n=108 (%)	93 (86)	15 (14)

Table 5: Total HOSE scores for different degrees of hypospadias.

Notes: HOSE scores was only complete for 108 of the 114 patients. Number of patients (percent of the patients with that degree). A score of 14 or more infers an acceptable final result. With the exception of neourethral reconstruction ad modum Scuderi with the final location at the tip of the glans, we consider the meatal shape of reconstructed meatuses more circular than normal meatuses. The percentages have been rounded off to whole numbers, and therefore, the total does not always amount to 100. Percentages were not calculated for groups with n<20.

Study III

Population and Study Sample

A total of 134 patients received the questionnaire (18 questionnaires were returned due to an invalid address). Thirty-nine of the 134 patients (29%) returned a completed questionnaire (Fig. 9). Responders and non-responders had similar characteristics with regard to age, degree of malformation, surgical method, age at repair, frequency of postoperative complications, and proportion of completed post-pubertal final evaluations (Table 3). About half the responders had undergone a Byars two-stage procedure, and most of the others had undergone a Mathieu or Scuderi one-stage procedure. Two patients had orthoplasty only (Table 3). At the last follow-up visit, 88% of the 39 responders had HOSE scores >14 (Table 6). Two of the 39 had received medical care outside of the Department of Plastic Surgery for urinary problems, and one of these underwent two additional surgeries for urinary incontinence.

Table 6: HOSE scores for responders and nonresponders

HOSE Score	11	12	13	14	15	16	Missing	Median (range)
(5-16)								
Responders n (%)		1 (3)	3 (9)	10 (30)	11 (33)	8 (24)	6 (15)	15 (12-16)
Non-responders n (%)	1 (1)	3 (4)	6 (8)	31 (44)	23 (33)	6 (8)	26 (27)	14 (11-16)

Table 6. Hypospadias Objective Scoring Evaluation (HOSE) scores for responders and non-responders.

Patient Satisfaction with Outcome

Satisfaction scores of 3 to 5 for penile appearance, sexual function, ability to urinate, and overall surgical outcome were given by 82%, 87%, 87%, and 92%, of the 39 patients, respectively (Table 7). Thirteen patients with a score ≥ 3 and 4 patients with a score ≤ 2 added various negative comments about their ability to urinate. The most frequently reported problems were spraying, dribbling, and weak stream, but 2 also reported pain. Eleven patients (28%) had scores of ≤ 2 on at least one of the satisfaction outcomes questions (Table 7). The frequency of any post-operative complication was 2-fold greater for the lower scoring patients (40%) than for the neutral or higher scoring patients (21%), although the difference was not statistically significant ($p=0.404$). The degree of malformation was more advanced in the lower-scoring group; 20% of low score and 4% of the higher scores were from patients who had degree III or IV malformations, though neither was statistically significant ($p=0.164$).

Table 7: Satisfaction with the surgical outcome for responders

Score:	1	1.5	2	3	4	4.5	5
Satisfaction appearance n (%)	1 (3)	1 (3)	5 (13)	12 (31)	12 (31)	1 (3)	7 (18)
Satisfaction sexual function n (%)	1 (3)		4 (10)	7 (18)	9 (23)		18 (46)
Satisfaction ability to urinate n (%)			5 (13)	11 (28)	8 (21)		15 (38)
Satisfaction surgical result n (%)			3 (8)	12 (31)	10 (26)		14 (36)

Patients' perception of the follow-up visits

The majority (54%) of responders were satisfied with the duration of the follow-up program, and 90% of responders were either satisfied with the duration or would have preferred a longer follow-up period after surgery (Table 8). However, of the 13 patients requesting a longer follow-up, three had not completed our follow-up program because they were lost to follow-up (n=2) or had refused the final post pubertal follow-up visit (n=1) (Table 8). Most patients (72%) had a positive opinion of the follow-up program (Table 8). Most of the patients who requested a longer follow-up program wanted it so they could receive information and undergo medical evaluation when they were older than 16 years, particularly with regards to sexual function.

Under the “general comments” section, several men requested better psychosocial support, more information on the surgical procedures, and advice on informing future partners about their condition. Some would have liked the opportunity to meet someone older with the same condition that had completed treatment. Some asked for support on coping with everyday situations, such as being asked questions by classmates and feeling anxious about showering after sports activities or beginning a new sexual relationship. Some reported that having a genital malformation was difficult because they had been bullied. A few respondents (n=3) also expressed gratitude to the surgeon and the staff.

Table 8: Patient experiences at the follow-up visits

	Yes, shorter	Yes, longer	No, adequate length	Do not know
Patient's perception of the duration of the follow up program, request for different length follow up. <i>n</i> (%)	1 (3)	13 ¹ (33)	22 ² (56)	3 (8)
Patients without completed follow-up program. <i>n</i> (%)		3/13 (23)	1/22 (5)	
	Positive	Negative	Do not know	
Patient's perceptions from the regular follow up visits. <i>n</i> (%)	27 ³ (69)	3 (8)	9 (23)	
Patients without completed follow-up program. <i>n</i> (%)	2/27 (7)	2/3 (67)		

¹Including one patient replying “shorter” but commenting “would prefer a longer follow-up”.

²Including one patient replying “do not know” but commenting “duration is probably adequate”.

³Including one patient replying “do not know” but commenting “follow-up was a good thing”.

Study II

Patient characteristics (n=36), surgical procedures, and complications are presented in Tables 9 to 11.

Complications and shortcomings, Study II

Eight patients (22%) underwent additional surgery beyond the treatment algorithm. Two required meatotomies (patients 20:II and 29:II) and three required fistula closures (patients 21:II, 23:II, and 36:II). Patient 36:II developed a serious wound infection as well as a large penoscrotal fistula. When this was closed, a proximal fistula became evident and was subsequently closed. Patient 36:II also awaits a minor correction of a distal skin-bridge in the meatus that is splitting the urinary stream. The other three patients underwent additional surgery to improve cosmetics including splitting a meatal skin-bridge (patient 16:II) and correction of surplus skin (patients 18:II and 32:II).

Of the patients who remain in our follow-up program, one has a ventral curvature (patient 15:II), and one has a penile meatus (patient 3:II). Both might require additional surgery. In the first case, maturation of the scar and the pubertal growth is awaited before any additional surgery will be attempted. In the second case, the patient opted for a fistula closure but no distal urethral reconstruction, due to fatigue after previous repeated surgical failures.

Ten patients completed post-pubertal follow-up or underwent treatment after puberty, and the majority have a HOSE score of 14 or above (Table 12).

Table 9: Treatment Group A

Patient	Age	Previous surgery	Problems	Salvage surgery procedures	Number of surgical procedures	Complications/ Shortcomings	Follow-up (months)
1:II	6	MAVIS Fistula closure x2	F	Fistula closure with ventral coverage from preputial flaps	3/1/4		1
2:II	6	Preputial plasty	F	Distal orthoplasty with division of chordae, ventral coverage with preputial flaps.	1/1/2		0
3:II	6	Duckett, Re-operation due to immediate complications x2 Fistula closure	F, DM	Fistula closure using scrotal skin flap.	4/1/5	Due to despair after repeated surgical failures this patient opted only for a fistula closure. His dystopic meatus may be corrected on his future request.	1
4:II	5	TIP, Fistula closure, MAVIS, Fistula closure	F	Fistula closure with ventral coverage using preputial flaps	4/1/5		51
5:II	6	MAVIS	F, RDR	Distal urethral reconstruction using Mathieu skin flap. Ventral coverage using preputial flaps.	1/1/2		42

Patient	Age	Previous surgery	Problems	Salvage surgery procedures	Number of surgical procedures	Complications/Shortcomings	Follow-up (months)
	*	**	***		****		*****
6:II	7	Byars 1, Byars 2, Fistula closure	F, RPR	Planned reconstruction in two stages: 1. Proximal urethral reconstruction using local Ombredanne skin flap and scrotal skin flap for ventral coverage. 2. Fistula closure connecting the proximal and distal urethral reconstruction.	3/2/5		27
7:II	6	MAVIS, Fistula closure x2	F	Fistula closure using preputial flaps for ventral coverage.	3/1/4		77
8:II	13	Duckett, Fistula closure x3	F	Fistula closure with waterproofing using local dartos flap.	4/1/5	Manifestation of minor proximal fistula after distal fistula closure. Declined additional surgery at post-pubertal follow-up.	33
9:II	15	MAVIS, Fistula closure	F	Fistula closure with preputial flaps for ventral coverage.	2/1/3		6
10:II	14	MAVIS, Circumcision, Fistula closure x2	F	Fistula closure with waterproofing using local dartos flap.	4/1/5		0
11:II	14	Duckett	F	Fistula closure with waterproofing using local dartos flap.	1/1/2		20

Patient	Age	Previous surgery	Problems	Salvage surgery procedures	Number of surgical procedures	Complications/Shortcomings	Follow-up (months)
12:II	30	Dennis Brown, Plasty NUD, Mathieu, Dorsal incision due to parafimosis	F	Fistula closure with waterproofing using local dartos flap.	4/1/5	Shortcomings	0

Table 9. Characteristics and surgical procedures for patients without ventral curvature who required fistula closure and/or distal urethral reconstruction.

* Age (years) at first salvage procedure.

** Previous surgery as interpreted from patient charts or ICD codes.

Brown, D. An operation for hypospadias. Proceedings of the Royal Society of Medicine 1949;42(7):466-8.

Duckett JW. Transverse preputial island flap technique for repair of severe hypospadias. Urol Clin North Am. 1980 Jun;7(2):423-30.

Duckett JW. The island flap technique for hypospadias repair. Urol Clin North Am. 1981 Oct;8(3):503-11.

Boddy SA, Samuel M. Mathieu and 'V' incision sutured (MAVIS) results in a natural glanular meatus. J Pediatr Surg. 2000 Mar;35(3):494-6

Snodgrass W. Tubularized, incised plate urethroplasty for distal hypospadias. J Urol 1994;151:464-5.

Boddy SA, Samuel M. Mathieu and 'V' incision sutured (MAVIS) results in a natural glanular meatus. J Pediatr Surg 2000;35(3):494-6.

Mathieu P. [Traitement en un temps de l'hypospadias balanique et juxta balanique. J Chir (Paris) 1932;39:481-4. In French.

*** Main problem requiring salvage surgical correction:

PF: preputial fistula, F: one or more fistulas, RDR: Ruptured distal urethral reconstruction, RPR: Ruptured proximal urethral reconstruction, DM: Dystopic meatus

**** Number of surgical procedures: number of surgical procedures prior to referral excluding meatotomy in infancy and examination during anaesthesia/number of salvage procedures excluding examination during anaesthesia/total number of surgical procedures.

***** Time (months) between last major salvage surgery and last outpatient check up.

Table 10: Treatment Group B

Patient	Age	Previous surgery	Problems	Salvage surgery	Number of surgical procedures	Complications/Shortcomings	Follow up (months)
	*	**	***		****		*****
13:II	5	Duckett, Re-operation for immediate complication	VC, F	Division of chordee, creation of neo-urethra (fistula closure) and redistribution of ventral skin.	2/1/3		48
14:II	7	Division of web, MAVIS, Circumcision, Fistula closure	VC, F	Division of chordee, fistula closure and redistribution of remnants of prepuce for ventral coverage.	4/1/5		30
15:II	6	Duckett, Fistula closure, Meatotomy, MAVIS x 2	VC	Division of chordee and deep scar tissue and skin closure with z-plasty.	5/1/6	Remaining ventral curvature, patients in active follow-up.	40
16:II	11	MAVIS, Preputial plasty x 4, Fistula closure x 2, TIP + preputial plasty	VC, F	1. Division of ventral scar tissues, fistula closure, coverage of ventral defect through preputial flaps. 2. Splitting of skin bridge across meatus.	8/2/10	Hairy meatus and bifid glans originating from the primary reconstructions. No re-intervention planned to date.	47

Patient	Age	Previous surgery	Problems	Salvage surgery	Number of surgical procedures	Complications/Shortcomings	Follow up (months)
17:II	17	Duckett, Fistula closure x 2, MAVIS	VC, DM *** **	Division of chordee and scar tissue, distally based flap for distal urethral reconstruction. Outer lining adjustment with waterproofing.	4/1/5 ****	Short phallus and general dissatisfaction. No further intervention planned.	10 *****
18:II	19	MAVIS Preputial plasty x 3	VC, F	1. Division of chordee and scar tissue, fistula closure, ventral coverage through preputial flaps. 2. Correction of ventral skin surplus.	4/2/6		6
Median age (years): 9 (5-19)				Total surgical procedures: 27/8/35		Median follow up (months): 35 (6-48)	

Table 10. Characteristics, previous surgery, and salvage surgery for patients with moderate ventral incurvation requiring fistula closure/urethral reconstruction: single session orthoplasty with fistula closure/urethral reconstruction using local or preputial flaps

* Age (years) at first salvage procedure.

** Previous surgery as interpreted from patient charts or ICD codes

Duckett JW. Transverse preputial island flap technique for repair of severe hypospadias. Urol Clin North Am. 1980 Jun;7(2):423-30.

Duckett JW. The island flap technique for hypospadias repair. Urol Clin North Am. 1981 Oct;8(3):503-11.

Boddy SA, Samuel M, Mathieu and "V" incision sutured (MAVIS) results in a natural glanular meatus. J Pediatr Surg. 2000 Mar;35(3):494-6

Snodgrass W. Tubularized, incised plate urethroplasty for distal hypospadias. J Urol 1994;151:464-5.

*** Major problem needing salvage surgical correction

VC: Ventral curvature, F: One or more fistulas, DM: Dystopic meatus.

**** Number of surgical procedures: number of surgical procedures prior to referral excluding meatotomy in infancy and examination during anaesthesia/number of salvage procedures excluding examination during anaesthesia/total number of surgical procedures.

***** Time (months) between last major salvage surgery and last out-patient check-up.

Table 11: Treatment Group C

Patient	Age	Previous surgery	Problems	Salvage surgery	Number of surgical procedures	Complications/ Shortcomings	Follow up (months)
	*	**	***		****		*****
19:II	4	TIP	VC	Byars 1 Byars 2	1/2/3		3
20:II	4	MAVIS	VC	Byars 1 Meatotomy Byars 2	1/3/4		1
21:II	6	Orthoplasty with buccal mucosa, TIP	VC, F	Byars 1 Byars 2 Fistula closure with scrotal flap	2/3/5	Fistula after Byars 2 with successful repair.	1
22:II	7	MAVIS	VC	Byars 1 Byars 2	1/2/3		1
23:II	5	Byar 1, Byar 2, Preputial plasty	VC, F	Byars 1 Byars 2 Fistula closure with local flap and dartos coverage.	3/3/6	Fistula after Byars 2 with successful repair.	1
24:II	5	MAVIS, Fistula closure	VC, F	Byars 1 Byars 2	2/2/4		13
25:II	6	MAVIS, Fistula closure x2	VC, F	Byars 1 Byars 2	3/2/5	Bifid glans due to partial rupture. No further intervention planned to date.	8
26:II	7	MAGPI Snodgrass	VC, F	Byars 1 Byars 2	2/2/4		1
27:II	7	Byar 1, Byar 2	VC, F	Byars 1 Byars 2	2/2/4		7

Patient	Age	Previous surgery	Problems	Salvage surgery	Number of surgical procedures	Complications/Shortcomings	Follow up (months)
	*	**	***		****		*****
28:II	8	MAVIS x2, Fistula closure, Urethral reconstruction NUD	VC, F	Byars 1 Byars 2	4/2/6		11
29:II	7	TIP	VC, F	Byars 1 Meatotomy x2 Byars 2	1/4/5		31
30:II	9	TIP, Fistula closure x3	VC, F	Byars 1 Byars 2	4/2/6		0
31:II	11	Division web Nesbit x3	VC, R	Byars 1 Byars 2	4/2/6		5
32:II	16	MAVIS, Preputial plasty, Fistula closure x3	VC, F	Byars 1 Byars 2 Correction av skin surplus	5/3/8		14
33:II	18	MAVIS Fistula closure x2 Preputial plasty x2	VC, F	Byars 1 Byars 2	5/2/7	Slight ventral curvature without need for intervention.	3
34:II	5	Duckett Re-operation for immediate complication x2	F, DM	Byars 1 Byars 2	3/2/5		12
35:II	5	MAVIS, Fistula closure	F	Byars 1 Byars 2	2/2/4		13

Patient	Age	Previous surgery	Problems	Salvage surgery	Number of surgical procedures	Complications/Shortcomings	Follow up (months)
36:11	7	Byar 1, Byar 2, Meatotomy	DM	Byars 1 Byars 2 Fistula closure with scrotal flap Fistula closure with local flap with dartos coverage.	3/4/7	Purulent infection after Byars 2 with ensuing large proximal fistula. Distal fistula manifested itself after closure of the proximal one. Both successfully closed. Awaits splitting of distal skin-bridge in the meatus.	1
Median age (years): 7 (4-18)							
Sum surgical procedures: 48/44/92							
Median follow-up (months): 4 (0-31)							

Table 11. Characteristics and previous surgery and salvage surgery for patients with prominent ventral incurvation or proximal meatus requiring a complete urethral reconstruction by orchioplasty and urethral reconstruction in two stages

* age (years) at first salvage procedure.

** Previous surgery as interpreted from patient charts or ICD codes:

Duckett JW. Transverse preputial island flap technique for repair of severe hypospadias. Urol Clin North Am. 1980 Jun;7(2):423-30.

Duckett JW. The island flap technique for hypospadias repair. Urol Clin North Am. 1981 Oct;8(3):503-11.

Boddy SA, Samuel M. Mathieu and 'V' incision sutured (MAVIS) results in a natural glanular meatus. J Pediatr Surg. 2000 Mar;35(3):494-6

Snodgrass W. Tubularized, incised plate urethroplasty for distal hypospadias. J Urol 1994;151:464-5.

Boddy SA, Samuel M (2000): Mathieu and 'V' incision sutured (MAVIS) results in a natural glanular meatus. J Pediatr Surg. Mar;35(3):494-6.

Snodgrass W. Tubularized, incised plate urethroplasty for distal hypospadias. J Urol. 1994;151:464-5.

Nesbit RM. Plastic procedure for correction of hypospadias. J Urol 1941;45:699-701.

Byars LT. Surgical repair of hypospadias. Surg Clin North Am 1950;30:1371-5.

*** Main problem needing salvage surgical correction:

F: one or more fistulas, VC: Ventral Curvature, DM: Dystopic meatus, R: Rotation

**** Number of surgical procedures: number of surgical procedures prior to referral excluding meatotomy in infancy and examination during anaesthesia/number of salvage procedures excluding examination during anaesthesia/total number of surgical procedures.

***** Time (months) between last major salvage surgery and last out-patient check-up.

Table 12: HOSE Scores

HOSE scores ^a	
	Total (n = 10)
Meatal location	
Proximal glandulär (3)	8
Distal glandulär (4)	2
Meatal shape, circular (1)	10
Urinary stream	
Single (2)	7
Missing data	3
Erection	
Mild angulation <10° (3)	2
Straight (4)	8
Fistula	
None (4)	9
Single, proximal (2)	1
Total HOSE score (5-16)	
13	1
14	5
15	1 ≥ 14: 86%
Missing data	3 ^b

HOSE scores

^aFor patients who completed post-pubertal follow-up

^bTotal score excluding missing variable: patient 9:II, 12:II, and 13:II respectively.

Study IV

The microscopic analysis of the six urethral plate biopsies showed similar tissue characteristics in all samples (Fig. 17). Squamous epithelial cells covered the surface of the tissue. Subepithelially, there were regional dermal infiltrates of T-cells and B-cells and smaller numbers of macrophages. Focally, T-cells could be seen infiltrating the squamous epithelium (Fig. 18B:I). All urethral plate biopsies showed small cystic structures with cuboidal urothelium, i.e. features of urethritis cystica. The cystic structures were infiltrated and surrounded by lymphocytes and occasional macrophages (Fig. 19). Ki67 labelling indicated proliferation of inflammatory cells and the basal cell layer of the epidermis. Deeper down, fibrous tissue, with few cells without signs of active inflammatory processes, was seen. The grade of vascularisation was moderate to rich. Also, sparse bundles of smooth muscle cells crossed through the fibrous stroma, but only slender, sparse nerve bundles were observed. The individual characteristics of the biopsies are summarised in Table 13.

Fig. 17: Tissue characteristics

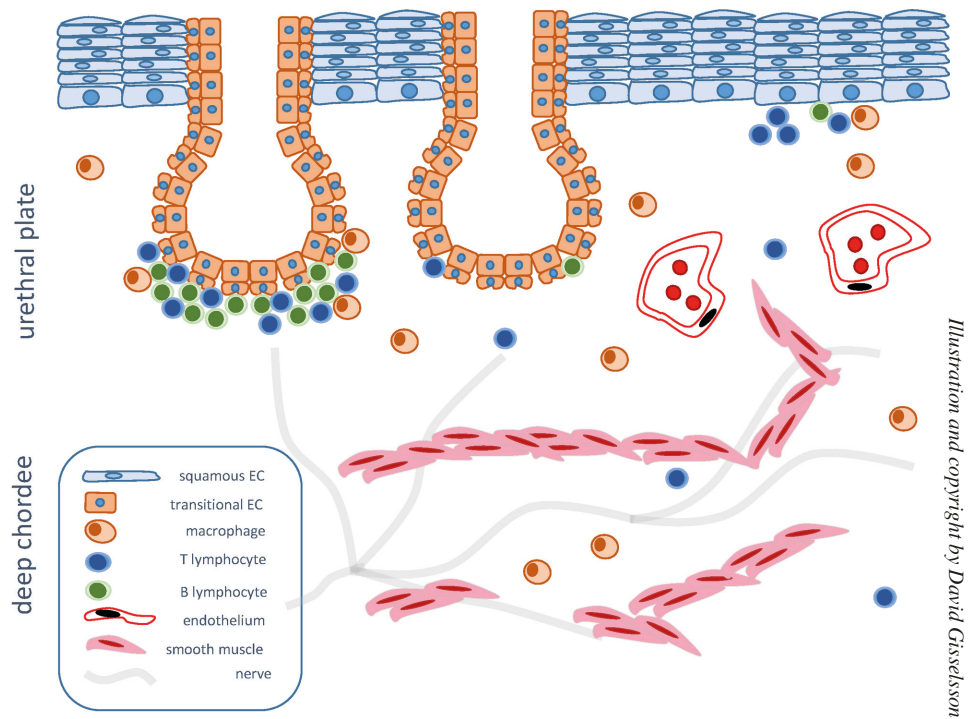


Fig. 17: Tissue characteristics of the urethral plate and the deep chordee.

Fig. 18: Representative histology

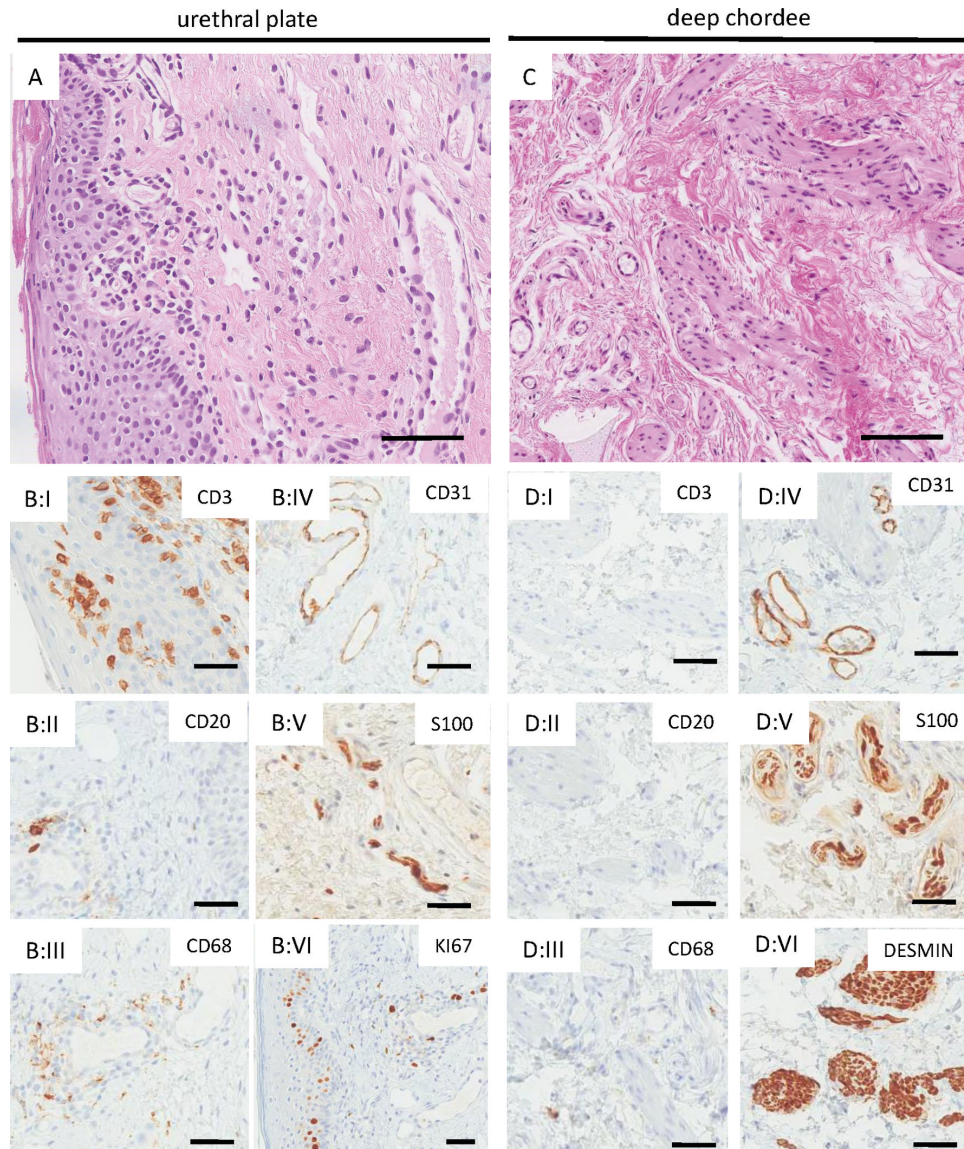


Fig. 18: Representative histology of the urethral plate (A and B) and deep chordee (C and D) from the same patient. A and C represent hematoxylin-eosin staining. Chronic inflammation in the urethral plate is manifested by intraepithelial and subepithelial infiltration of CD3+ T cells (B:I) and sparse subepithelial clusters of CD20+ B cells (B:II) and histiocytes (B:III). There is a prominent CD31+ subepithelial vascularization (A and B:IV), while S100+ nerve fibers are sparse and slender (B:V). Proliferation as visualized by Ki67 is confined to the basal layer of the epithelium and inflammatory cells (B:VI). The deep chordee has little inflammatory activity (C and D:I- III). It is dominated by connective tissue with a rich capillary network (D:IV), abundant coarse nerve fibers (D:V), and smooth muscle bundles (D:VI). Scale bars correspond to 50 μ m.

Fig. 19: Urethritis cystica of the urethral plate

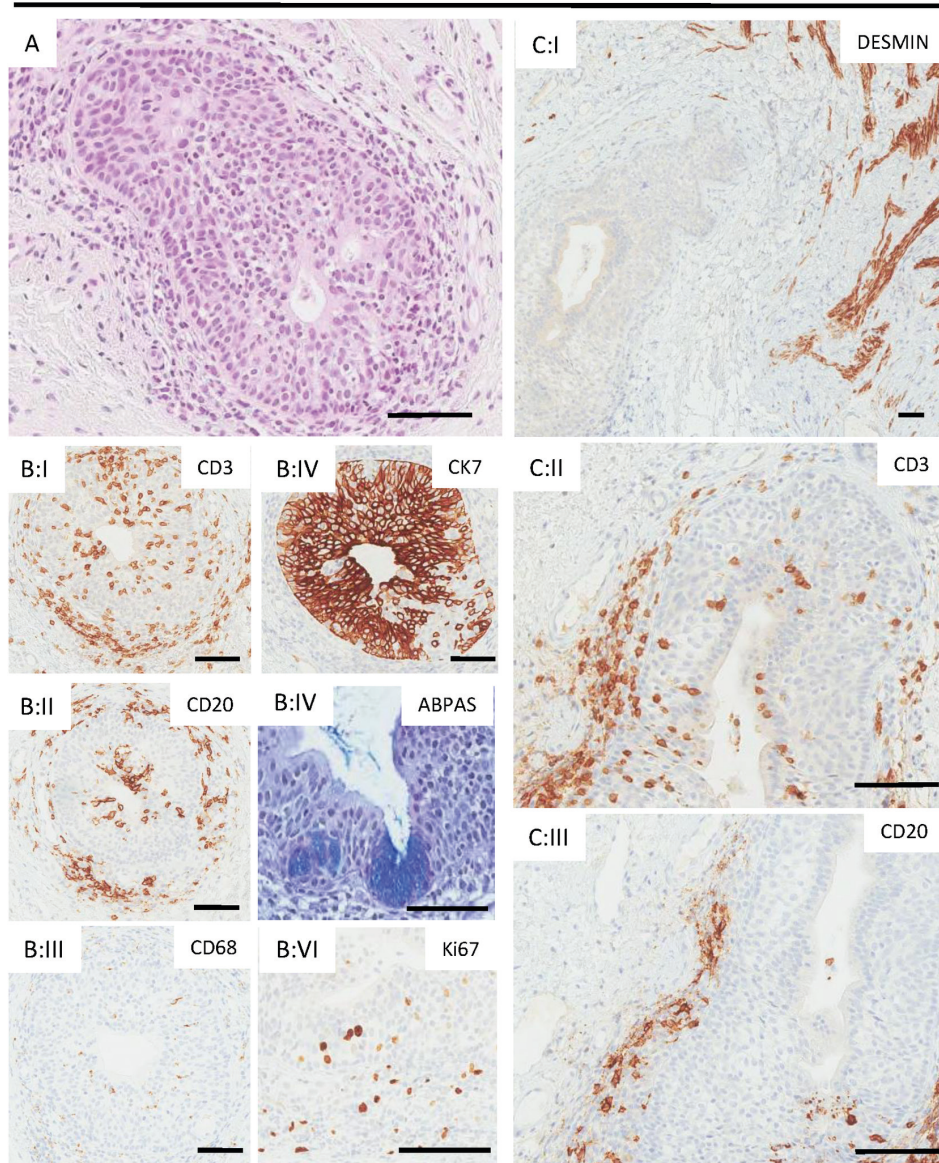


Fig. 19: Urethritis cystica of the urethral plate (hematoxylin eosin in A) is characterized by moderate lymphocytic infiltrates both in its epithelium and in the surrounding connective tissue (B:I-II, C:II-III), while histiocyte activity is sparse (B:III). The epithelium expressed cytokeratin 7, consistent with a urothelial phenotype (B:IV) and showed focal features of cystitis glandularis with positivity in alcian blue periodic acid Schiff base (ABPAS) staining (B:IV). The proliferating cells fraction was confined to the epithelium and surrounding inflammatory cells. Cysts and canals of urethritis cystica were typically embraced by smooth muscle fibers originating from the direction of the deep chordee (C:I). Scale bars correspond to 50 μ m.

Fig. 20: Scarring in deep chordee

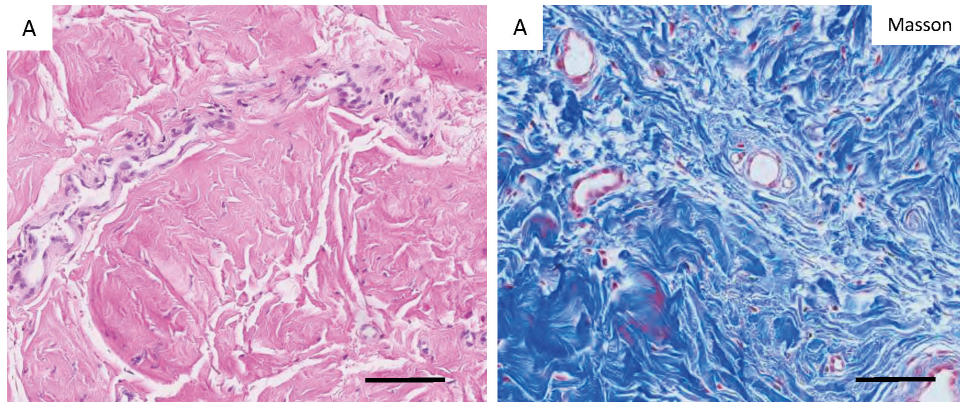


Fig. 20: Scarring in patient 8:II with re-operated deep chordee, as evidenced in hematoxylin-eosin (A) and Masson trichrome stain (B) by accumulation of dense collagenous hypocellular connective tissue with absence of the typical smooth muscle bundles and nerves of the deep chordee (compare Fig. 18C–D). Scale bars correspond to 50 μ m.

Table 13: Urethral plate findings

Patient	Age (Years)	Degree*	B-cells	Macrophages	T-cells	Vessels	Inflammation**		Smooth Muscle	Proliferative Cells	Nerves	Previous surgery
							Sum	Yes/No				
1	1.5	III	1	1	1	2	5	1	Lymphocytes, Epithelial cells	0	No	
2	4.5	II/III	2	1	2	3	8	2	Lymphocytes, Epithelial cells	0	No	
3	5	II	0	0	2	3	5	2	Epithelial cells	1	No	
5	5.5	II	2	1	2	3	8	2	Epithelial cells, Lymphocytes	1	Yes	
6	6	II	2	1	2	3	8	2	Epithelial cells	1	Yes	
10	9	III	1	1	2	2	6	2	Epithelial cells, Lymphocytes	1	No	
Mean	5.25	N/A	1.3	0.8	1.8	2.6	6.7	1.8		0.7		
Median (Range)	5.25 (1.5-9)	N/A	1.5 (0-2)	1 (0-1)	2 (1-2)	3 (2-3)	7 (5-8)	2 (1-2)		1 (0-1)		

Table 13: Tissue findings in the urethral plate samples.

*Degree I: glanular, degree II: penile, degree III: peno-scrotal, degree IV: perineal

**Sum inflammation: sum of grading for inflammatory cells: B-cells, Macrophages and T-cells.

The nine samples from the deep chordae were characterised on microscopic analysis by connective tissue with only a few inflammatory cells. There were fewer vessels compared to the superficial layers of the urethral plate. In contrast to the area just under the urethral plate, prominent bundles of nerves and smooth muscle cells were present (Fig. 18 C–D). Table 14 summarises the individual characteristics of the biopsy specimens. A trend toward increased inflammation and increased levels of CD68+ cells was observed in older patients and in those who had had previous operations, but the CD68+ count was highest in the patient with crypto-hypospadias and rotation (Table 14). Only one patient (number 8:IV) had prominent scar tissue, which was characterised by vast hypocellular areas dominated by collagen bundles. This patient was an adult who had a history of extensive surgery in early childhood due to an advanced original malformation (Fig. 20, Table 2).

Table 14: Deep chordee tissue findings

Patient	Age (Years)	Degree *	B-cells	Macrophages	T- cells	Vessels	Sum Inflammation **	Smooth Muscle		Proliferative Cells		Nerves	CD68	Previous Surgery
								Muscle						
1	1.5	III	0	0	1	1	2	1	0	0	2	0	No	
2	4.5	II/III	0	0	1	1	2	1	0	0	2	0	No	
3	5	II	0	0	1	2	3	2	0	0	2	5	No	
4	4.5	III	0	1	1	2	4	2	Macrophages		2	4	Yes	
5	5.5	II/III	0	1	1	2	4	3	0	0	2	8	Yes	
6	6	III	0	1	1	2	4	2	0	0	2	4	Yes	
7	9.5	III	0	1	1	2	4	2	0	0	2	42	Yes	
8	18	III/IV	0	1	1	2	4	1	0	0	2	36	Yes	
9	1.5	Crypto.	0	1	1	2	4	2	0	0	2	46	No	
Mean	6.2	N/A	0	0.7	1	1.8	3.4	1.8	N/A	2	16.1	N/A		
Median (range)	5.5 (1.5-18)	N/A	N/A	1 (0-1)	N/ A	2 (1-2)	4 (2-4)	2 (1-3)	N/A	N/A	5 (0-46)	N/A		

Table 14: Tissue findings in the deep chordee samples

*Degree I: glanular; degree II: penile; degree III: peno-scrotal; degree IV: perineal; crypto: crypto-hypospadias.

**Sum inflammation: sum of grading for inflammatory cells: B-cells, macrophages, and T-cells.

Discussion

Considerations regarding complications and long term results

The HOSE scores in Study I indicated that a large majority of patients (85%) had excellent result at the final clinical evaluation (Table 5). Previous long-term studies have reported HOSE scores of ≥ 14 ranging from 60%, in patients with severe hypospadias⁴⁶, to 97%, in those with distal hypospadias^{52,61}. We also found that a higher percentage of patients with distal hypospadias (90% degree I) had HOSE scores of ≥ 14 than patients with severe hypospadias (55% degree III and IV) (Table 5). Outcome studies in hypospadias surgery are limited by the heterogenous spectrum of the pathology. Thus the groups might not be comparable. Furthermore, the number of patients with the most advanced malformations and most frequently affected by complications are few in numbers. Thus, only few centers would have the capability of performing adequate subgroup analyses of these patients.

Degree of hypospadias

In a previous study that included 39 patients from present cohort⁶⁰, we hypothesised that the degree of hypospadias is the most decisive risk factor for the frequency of complications after repairs. This study has confirmed that hypothesis, showing a statistically significant association between the two factors. The complication rate for any complication during the entire follow-up period increased from 11% among patients with degree I malformations to 67% among those with degree III and IV malformations, although the groups with the most advanced malformations were very small (degree III, n=6 and degree IV, n=3). Moreover, we did not find any other common denominator among the patients who had complications following reconstruction. Finally, the finding is corroborated by the HOSE scores, as a higher percentage patients with degree I hypospadias had scores indicating an acceptable final result compared with patients with degree III and IV hypospadias (Table 5).

Fistulas and meatal location

Previous reports^{47,62} have indicated that the prevalence of late fistulas (those occurring in patients who have passed puberty) varies from 11% to 43%. The prevalence of late fistulas of 2% (2/114) in the present study was comparatively low.

Regarding meatal location, all but four patients (96%) in Study I had a glanular meatus, which is in accordance with other studies^{46,52,61,63}. However, the number of patients with a distal glanular meatus in our group was slightly lower (52%, 56/108) than in some other reports^{52,61}. There were no patients in our study group with non-apical meatus at the final visit who requested secondary correction because of meatal location.

Incurvation

In this study, 5% of the patients who had straight penis before puberty developed some incurvation during puberty, despite initial orthoplasty and recognition that excision of chordee is fundamental for successful repair of hypospadias. Three of the affected patients had undergone Byars two-stage corrections, one had cryptohypospadias requiring orthoplasty only, and 2 patients had mild hypospadias that was corrected by the Mathieu technique. Hence, at these operations, all possible chordee had apparently been thoroughly extirpated, and artificial erection testing applied in the surgical field could not have added any further information as to why the surgical technique itself did not account for the late incurvation.

Follow-up included both subjective and objective evaluation. At 13 years, there were no indications of incurvation in any of our patients, while at 16 years, subjective and clinical data showed the possibility of curvature in a few patients. We requested photographs from these patients in order to assess the natural erection, rather than using an artificial erection test. Similar reports of late-onset incurvation after puberty have been published by Yucel et al⁶⁴, Vandersteen et al⁶⁵, and Flynn et al⁶². Hence, it is manifest that late-onset incurvation can occur even after meticulous initial orthoplasty.

Patient satisfaction with urinary and sexual function and cosmesis

In Study III, 92% of responders were satisfied with the overall surgical results, which is in accordance with previous studies (satisfaction rate 86%) that used the original questionnaire⁴⁷. Another previous investigation found, not surprisingly, that patients with more advanced malformations and more severe complications were less satisfied with the long-term outcomes⁶⁶, and two of the three patients in

our group who had low scores in the overall surgical results also had more advanced malformations (degree II and III).

A number of studies have found that patients undergoing surgery for hypospadias are often less satisfied with their micturition than healthy controls^{40,46-48} because they often experience dribbling and spraying⁴⁸. In our patients, in Study I, 10% (11/110) reported spraying at the post-pubertal follow-up, and only one patient had a secondary correction for this problem. The patients in Study III also reported various urinary problems, but not all of them perceived dribbling and spraying as a problem that affected their satisfaction, indeed many who were neutral or satisfied commented that they sometimes had problems with spraying and dribbling. Thus, spraying and dribbling might not be a constant occurrence in affected patients or patients may adapt so that imperfect voiding is not considered problematic.

In terms of sexual function, 87% of the respondents in Study III reported that there were generally satisfied (Table 7), which is similar to the findings of several previous studies^{47,67}. However, the results among previous cohorts have varied. For instance, in one study⁶⁸, there were no confirmed differences in sexual function even when the proportion of patients with advanced malformations were relatively high (24%). Hypospadias patients might also have lower levels of sexual satisfaction⁶⁸ with lower frequencies of ejaculation and orgasmic sensations^{40,67} and more frequent erectile problems⁴⁹ compared with controls. Reduced satisfaction with sexual function has been correlated with a more advanced degree of the original malformation⁶⁹, as was also the case with our patients (Paper III, Table 4). Future studies in larger patient groups with subgroup analyses of patients with different degrees of malformation might further clarify this relationship.

Cosmesis is inherently difficult to assess objectively. Previous studies have reported that both patients undergoing hypospadias repair and healthy controls may be dissatisfied with their penile appearance, although hypospadias patients were less satisfied^{49,66}. Studies have reported varying results in terms of patient satisfaction with the appearance of the penis after hypospadias repair. In the present study (Paper III), 82% of the respondents were satisfied, compared to satisfaction rates ranging from 51% to 71% in previous reports^{70, 47}.

Patient perspectives on long-term follow-up

An early final clinical visit after reconstruction implies that the patients initiate contact with the provider if they have problems later on. However, Bracka et al⁷¹ reported that 44% of 213 hypospadias patients between the ages 15 and 24 had considerable difficulties and requested secondary corrections only after they were included in the study, and that none of them had initiated contact on their own. A similar situation was reported in a study that evaluated outcomes of hypospadias

outcomes by questionnaire in which 11% of the participants wound up having further surgery only as a direct result of the study⁵¹. We also found, in Study III, that there were patients who had problems because of their malformation or because of the corrective surgery, who needed additional care, but had not initiated contact with the health care system on their own. A full 90% of the respondents in Study III indicated that follow-up until post-puberty was adequate or should be longer.

The finding in Study I that 5% of the patients developed an incurvation between the prepubertal and the postpubertal examination also indicates that at the present state of knowledge, a reconstruction cannot be considered final until the patients passed puberty.

As still other studies have also indicated that the patients would actually have preferred long-term follow-up^{72,73}, it seems clear that a well-planned routine follow-up programme is important. The respondents in Study III also commented that they preferred a long follow-up period with specific emphasis on sexual function. None of the respondents, even those who had negative opinions about the follow-up appointments or did not attend them, expressed a desire for a shorter follow-up period. Moreover, it is reported up to 74% of the hypospadias patients were aware that something was different with their penises, but they did not understand why they had undergone corrective surgery^{71,74}. Thus, the long-term follow-up visit is also important for psychological and educational purposes.

Considerations regarding salvage repairs

The optimal management of patients requiring secondary or salvage procedures remains unclear. In this study, we investigated whether an algorithm based on using remaining local tissues could attain adequate reconstructive results with few postoperative complications.

Like others, we are of the opinion that the pre-salvage assessment is fundamental to choosing the appropriate surgical technique for a successful salvage repair⁷⁵. The careful use of a structured protocol at the preoperative outpatient clinic visit is essential, with particular attention to the presence of a ventral curvature^{76,77}. In addition, it must be clearly communicated to the patients and the parents what the procedure can achieve, and this explanation must present a realistic view of the problem and its possible surgical solutions³⁹.

More than 50% of the patients who underwent secondary or salvage repairs during our study period presented with a remaining ventral curvature. This could indicate that the degree of curvature was underestimated during the initial reconstruction, and the initial procedures may have focused more on distal urethral lengthening than on the complete excision of the chordee and other constricting tissues. Most patients in our study did require excision of residual chordee in order

to restore a straight penis, which supports the premise that it is essential to address the chordee even in cases of distal hypospadias. Therefore, our algorithm emphasises that ventral curvature is a key factor that must be addressed when planning a salvage repair.

A number of general surgical principles that influence the outcome of hypospadias re-repairs have been reported. The most important include surgical delay³⁹, waterproofing⁵⁹, postoperative urinary diversion^{35,78}, and staging of the repair^{75,79}.

Surgical delay, which entails allowing adequate time between surgical procedures for tissue healing, softening, and neovascularisation, is required for successful secondary procedures³⁹. In this context, we allowed for a minimum of six months between sequential procedures, and all patients were re-evaluated in the outpatient unit between planned procedures to ensure that adequate healing and revascularisation had occurred. In uncertain cases, further procedures were postponed until optimal conditions were present.

Waterproofing is a method to reduce the risk of fistula formation by creating a barrier layer of tissue between the neo-urethra and the penile skin to avoid directly overlying suture lines^{35,59,78,80,81}. There are several approaches to this step^{80,81}. In our patients, we used advancement flaps of Dartos fascia from the lateral aspects of the penis or preputial flaps. Care was taken to orient the flaps in a manner that further reduced the occurrence of overlying suture lines.

Postoperative urinary diversion has also consistently been shown to be a crucial factor in reducing complication rates^{35,78}, although successful simple fistula repair without urinary diversion has also been reported⁸². We and others⁸³ emphasize that urinary diversion may be beneficial in complex cases, such as salvage repairs, because back pressure, turbulence, increased shear stress due to narrowing, skin bridges, and crests might promote fistula formation. All of the patients in the present series had urethral catheters in place for 5 to 7 days, which were supplemented by suprapubic catheters in the more advanced cases.

Two-stage repairs have been shown to be more reliable than one-stage repairs in some cases of salvage surgery^{75,79}, particularly those in which there is a pronounced ventral curvature and scarring of the skin⁷⁹. Indeed, patients in need of salvage repairs have usually undergone a number of operations, in our series ranging from 1 to 8 (Tables 9–11). The 36 patients who presented for reoperation had undergone a total of 109 prior surgeries and required an additional 65 procedures (range: 1 to 4) at our centre to achieve the initial goal. Our algorithm acknowledges that it is often preferable in salvage cases to offer a safe two-stage procedure rather than attempting a single-stage procedure that could result in complications requiring further surgical intervention. This strategy is in accordance with the concept that a liberal approach to staged salvage repair is justified when there is obvious residual curvature^{75,77}, even as it has been shown that in select cases, one-stage salvage repair can be successful⁸⁴. Our results

support the premise that some patients with no or modest ventral curvature can have successful one-stage procedures, while staged procedures are necessary for patients with pronounced ventral curvature.

Considerations regarding histopathological findings and chordee

Ventral curvature or chordee is common in hypospadias^{15,17,85}. Nonetheless, the definition of chordee, its role in the pathophysiology, and the importance of its excision, remain unclear^{14,16,19,23,24}.

Study IV characterised the histopathology of the chordee in primary and secondary cases of hypospadias. The inflammatory changes that we observed in the superficial chordee/urethral plates in all cases have not been described previously. In fact, in previous histological studies, inflammatory changes were a rare or non-existent feature^{15,85}. This may be because many previous studies were focused on the deep chordee, while the inflammation in our specimens was mainly seen as conglomerates of inflammatory cells in the upper portion of the urethral plate, either in the sub epithelial zone or surrounding the formations of urethritis cystica. There was also a low-grade presence of inflammatory cells in the deep chordee. Macrophage-driven inflammatory activity, as manifested by CD68+ cells and by the summary score of T-cells, macrophages, and vessels, were most prominent in the deep chordee in patients who had had previous surgery (cases 4:IV, 5:IV, 6:IV, 7:IV, and 8:IV) and in the patient with rotation and crypto-hypospadias (case 9:IV).

Urethritis cystica was present in all of the urethral plate biopsies. This finding is thought to be due to metaplastic changes secondary to chronic inflammation, and is reported in more proximal parts of the urinary system in conditions such as nephrolithiasis or chronic cystitis⁸⁶. However, we do not know what the irritant might have been in our cases of hypospadias. The finding was present in both primary and secondary cases, excluding previous surgery as a possible irritant. Chronic inflammation with urethritis cystica thus seems to be an inherent feature of the histopathology of hypospadias. Chronic inflammation in the form of balanitis xerotica obliterans (BXO) was reported in hypospadias patients, most commonly in non-operated adults (42.9% in non-operated hypospadias patients and 8.3% in operated hypospadias patients, $p=0.037$), in another group of patients who were treated for genitourinary problems⁸⁷. In our group, none of the patients had notable clinical signs of inflammation at the time of the operation. However, our finding of invariable inflammation at the microscopic level could correspond to an early subclinical phase of BXO.

In this study, it was not possible to differentiate with certainty between the tissue of the original malformation and possible post-operative scarring in the previously operated cases. Convincing hypocellular scarring was observed in only one patient

(8:IV), who had undergone extensive previous surgery. This case could alternatively illustrate an age-related phenomenon, as the total collagen concentration in the extracellular matrix of the human urethral plate seems to increase significantly with age⁸⁵.

In summary, our findings regarding the inflammatory activity and metaplastic reactions in the urethral plates support the notion that the chordee is a unique tissue compartment. Further supporting this are the signs of inflammation that are observed in both primary and secondary cases of hypospadias. Our findings raise questions regarding the effects of inflammatory activity on the natural history of hypospadias. It could be that the chronic inflammation underneath the urethral plate drives the remodelling of the deeper chordee, thereby explaining, in part, the unpredictable clinical course of hypospadias.

Methodological issues

Long-term retrospective follow-up and methods of evaluation, Studies I–III

Thorough long term follow-up after paediatric hypospadias surgery cannot be achieved until 10 to 15 years after the surgery. Therefore, this thesis evaluated outcomes associated with surgical repair methods that were in use 20 years ago. The long-term outcomes of more recently introduced surgical techniques at our department, such as the Snodgrass tubularised incised plate (TIP) repair⁸⁸, cannot presently be evaluated. Ongoing assessment of patient- and surgeon-reported outcomes after hypospadias repair remains essential for tracking long-term urinary and sexual function in order to optimise surgical approaches, care, and follow-up in the future.

Retrospective chart reviews have inherent limitations, particularly information bias. However, the hypospadias patients investigated in this thesis were treated according to a stringent standard protocol for pre-operative evaluation and post-operative care, both with regard to the timing of the visits and the issues covered at the visits. This structure aided the categorisation of study data, which is apparent in the low incidence of missing data, so that there was adequate chart information for complete HOSE scoring in 108 of 114 cases (Study I). Although retrospective evaluations are at risk for information bias, all data required for the completion of the HOSE score were included in the structured hypospadias clinical treatment program, which included patient interviews and clinical examinations that were detailed in the patient charts. This data was recorded in the charts many years prior to the development of the HOSE questionnaire. With the exception of neourethral

reconstructions according to Scuderi with final location of the meatus at the tip of the glans, we consider the shape of reconstructed meatuses more circular than normal meatuses. We have thus graded all the reconstructed patients accordingly.

There were some administrative shortcomings that contributed to the unintended loss of follow-up of 17 patients in Study I. These shortcomings have been corrected to the best of our ability in hopes of preventing this in the future. We have also scrutinised the records of those patients who were lost to long-term follow-up for any reason in Study I (n=27). There was no detectable difference between the patients lost to follow-up and those were included in the Studies I and III in terms of severity of the original malformation or treatment history. Hence, their results are presumably compatible.

Patient reported outcomes: Study III

Because of a long time had elapsed since many of the patients had had their last contact with our department, and because of the nature of their condition, we expected a low response rate, which has frequently been a problem with this type of study^{47,49,50,66,69,89}. We tried to increase the response rate by telephoning the non-responders. However, given the nature of the study, the response rate of 29% might be the highest that can be expected.

Whether or not the responders had opinions that were different from the nonresponders with regard to functional outcome and our treatment program is a matter of speculation. Although selection bias cannot be ruled out, there were no differences in the characteristics of the responders vs. the nonresponders (Paper III Table 1 and Table 3).

Only a small number of questionnaires on the outcomes of hypospadias repair have been validated⁸⁹. Although the satisfaction outcome questions used in this study were previously validated⁴⁷, the translated and modified questionnaire was not. Particularly, the added questions on patient perceptions of the follow-up program and on their childhood memories of the surgical procedure(s) might have been unclear, and we suspect that some respondents might not have understood them. However, the risk of misinterpreting some of the questions and the lack of validity and reliability of the added questions was somewhat reduced by the provision of space after each question for additional comments.

Sample size, Study IV

Study IV included a small sample of only 10 patients. Of these, 50% had had previous surgery. Still, we found similar characteristics in all biopsy specimens, suggesting that the findings could be representative of a larger group. Further

investigation of specific features in different hypospadias phenotypes and in larger groups of native and re-operative cases would add more information.

Ethical considerations

The initial chart review studies (I and II) were conducted after approval to create a patient register was obtained in accordance with the Swedish Privacy Protection Law. Data from the charts were reviewed and analysed, but patient participation in the study *per se*, did not occur, and possible effects on the individuals were not expected.

In Study III, all patients received study information and consent forms together with the study questionnaire. Thus, there was a chance that individual patients would have negative reactions to this solicitation from the health care system and the University, particularly as the issues involved relate to the delicate issue of genital malformation. Also, in our effort to boost the response rate through telephone contact with the patients, we did encounter negative responses in rare cases. Out of respect for the patients, the telephone calls were quickly ended in these instances, and the caller apologised for the intrusion. However, in the large majority of cases, the patients seemed happy to be contacted and interested in the study findings. One patient reported that he initially had negative feelings when the questionnaire arrived but concluded that he very much wanted to participate in our study in any way he could for the possible improvement of care for future hypospadias patients.

All of the patients, or their guardians, in Study IV gave written informed consent to study participation. Patients and guardians seemed willing to participate in the study, as none declined participation. This could of course also reflect their dependence on the surgeon and the health care system. However, we think that this had limited impact in this situation because the patients were not subject to any alternative treatment, and because tissue that is normally discarded was instead sent for analysis. In light of our novel findings of inflammatory activity, a possible benefit could arise for those patients whose samples showed the greatest inflammatory activity, as they might be followed with a higher level of suspicion with regard to complications secondary to inflammation, such as BXO, thus minimising the chance of diagnostic or treatment delay in such instances.

Conclusions

The present thesis highlights long-term complications and results after primary hypospadias repair and salvage repair, as well as histopathological aspects of hypospadias. The main conclusions of the thesis are:

- The decisive risk factor for complications after hypospadias repair is the degree of hypospadias and the presence of chordee.
- Failed hypospadias repairs might be due to an underestimation of the ventral curvature at the initial repair.
- The majority of patients seem satisfied with the functional and aesthetic outcomes of their hypospadias repair.
- Patients should be followed until they have passed puberty, as complications such as incurvation might develop during puberty and the reconstruction therefore cannot be considered final until then. Moreover, patients with problems long after the completion of their surgical treatment might not contact the health care system on their own.
- The urethral plate and the deep chordee seem to constitute a unique entity in which inflammatory signs can be seen. In the urethral plate, metaplastic changes in the form of urethritis cystica can be seen.

Future perspectives

Hypospadias is a complex spectrum disorder of genital malformations. To ensure normal functioning, the more advanced malformations require surgical repair during childhood. The challenge of growth and sexual development require long term follow-up to ensure good long term results and allow for treatment of possible complications. Thus, evaluation of the surgical repair occurs more than 10 years after the completion of surgery, which can be challenge for the scientific investigator as well as for the clinician.

We have found that the results are good, although further improvements can be made. Most notable in this context is that patients, despite debilitating problems, do not necessarily contact the health care system on their own. This supports our finding that long term follow-up is of great importance for this group of patients. Also, the comments of the responding patients indicate that many patients would like more information on the implications of their malformation and its treatment with regard to sexuality at a more mature age than 16 years.

Only a minority of the patients in our second study (10/36) have completed the post pubertal follow-up or were operated on after puberty. Thus, our true long-term results from this cohort are not yet available for analysis. It would be expected that this group with repeated surgeries would be at higher risk for complications, but we do not know if they are in higher risk for long-term complications or if the complication panorama differs in any way. In this context, it is also of interest to investigate whether certain subgroups of hypospadias patients, presumably those with a more advanced malformation or complications with or without repeated surgical interventions, would benefit from a different, longer, or more frequent follow-up program.

Several issues need addressing in order to continuously improve hypospadias care. The issue of timing for hypospadias repair has been raised not only with regard to the age of the patient as a limiting factor itself due to possible age-related tissue healing limitations and psychosocial development, but also with regard to the autonomy of the patient. In particular, parents of children with less advanced malformations have questioned whether or not their children should undergo surgical repair in light of the potential for complications requiring repeated surgery, in the end risking a worse outcome than the original malformation^{90,91}. In addition, the possible role of patient consent to hypospadias surgery needs further investigation⁴³. More information on patients' experiences with all these aspects of

their care could be investigated through a wider use of patient-reported outcome questionnaires.

Finally, there is still much to learn about the chordee and its embryological origin in patients with hypospadias. Our findings indicate that there are dynamic features in the urethral plate and the deep chordee, as we found chronic inflammation in all samples from the small group of patients that we examined. It will be of great interest to continue to investigate chordee in hypospadias patients to elucidate if any measurable parameter in this tissue can indicate increased risk for future complications such as recurrent ventral curvature. Also, if future studies do find that this inflammation indeed contributes to macroscopic changes in the tissue, such as constriction, could these changes be preventable by such simple measures as topical application of corticosteroids or other anti-inflammatory compounds? Our findings of chronic inflammation in the urethral plate and the deep chordee might also have clinical implications with regard to the dynamics of scar formation, constriction, and BXO.

Populärvetenskaplig sammanfattning på Svenska – Summary in Swedish

Inledning och bakgrunden till undersökningen

Hypospadi är en medfödd avvikelse av penis urinrör. Det innebär att urinröret är kortare än normalt och mynnar på penis undersida istället för på ollonets topp. Även förhuden är avvikande och vanligen delad så att den sitter som en kapuschong på ovansidan av ollonet. Den vävnad som skulle ha bildat urinrörets sista del kallas för urinrörsplattan och kan ses som en slemhinnerest framför urinrörsmynningen och den sträcker sig fram mot den förväntade platsen för urinrörsmynningen på ollonet. Det som orsakat detta utseende är en felaktigt avslutad rörslutning av urinrörsslemhinnan under den tidiga fosterutvecklingen. Den sista delen av urinröret förblir därför en öppen urinrörsplatta istället för ett slutet rör. Även den svällkropp som omger urinröret, corpus spongiosum, saknas delvis vid hypospadi. Urinrörets sista del omges alltså inte av någon svällkropp. Studier i mikroskop har visat att den bakre delen av svällkroppen ofta finns men att den saknas framtill där även slutningen av urinröret saknas. Ju tidigare utvecklingen av urinröret störts desto allvarligare blir missbildningen och desto kortare blir urinröret. I de allvarligare fallen finner man även vanligtvis en mer eller mindre påtaglig krökning av penis. Den vävnad som orsakar denna krökning kallas chordeevävnad. Vad denna vävnad utgörs av är ännu inte fastställt, men undersökningar talar för att den kan utgöras av den underutvecklade svällkroppsvävnaden som skulle ha omgivit urinröret. Vid de allra mest avancerade formerna av hypospadi har utvecklingen avstannat så tidigt under fosterutvecklingen att penis hamnat längre bak än normalt och ligger då inbäddad i de två punghalvorna. I dessa fall kan det tom vara svårt att vid födelsen avgöra vilket kön barnet har.

Hypospadipatienterna kan indelas i fyra grader beroende på hur allvarlig grad av avvikelse de har. Indelningssystemet bygger på var urinröret mynnar efter att chordeevävnaden tagits bort så att penis är rak. Det är en kombination av genetiska faktorer och omgivningsfaktorer som orsakar hypospadi. Det har visats att framförallt omgivningsfaktorer som beror på moderkakans bristande funktion och manifesteras i form av t.ex. tillväxthämning är av särskild betydelse vid de

avancerade formerna av hypospadi, medans de enklare formerna av hypospadi har en till större del gemensam ärftlig bakgrund.

Behandlingen som erbjuds patienter med hypospadi är korrigerande kirurgi i barndomen. Med hjälp av vävnad från penis och förhud rätas krökningen upp och urinröret förlängs. Beroende på hur lång förlängningen behöver vara för att nå toppen på ollonet ökar risken för komplikationer. Det konstruerade urinröret kan spricka upp helt eller delvis så att en felaktig förbindelse mellan urinröret och huden uppstår ur vilken urinen läcker, en så kallad fistel. Även förträngningar på grund av inflammation och ärrvävnad i urinröret kan uppstå och förhindra eller försvåra urinpassagen med blåstömningssjukdom som följd. Om den medfödda böjningen av penis inte korrigeras helt under operationen eller återuppstår trots adekvat behandling, kan patienten få problem att genomföra samlag. Ytterligare operationer krävs då för att bemöta dessa komplikationer.

Denna avhandling kom till stånd som ett samarbete mellan de barnkirurgiska och plastikkirurgiska klinikerna vid Skånes Universitetssjukhus med målsättningen att på vetenskapliga grunder förbättra behandlingen för hypospadipatienterna.

Sammanfattning av undersökningarna i denna avhandling

I denna avhandling har vi studerat journaler från patienter som opererats pga. hypospadi av den seniora hypospadioperatören vid plastikkirurgiska kliniken i Malmö mellan 1989-2014. För att göra operationsresultaten mätbara har ett validerat mätinstrument använts: Hypospadias Objecting Scoring Evaluation (HOSE). Genom detta formulär har graden av krökning, förekomsten av eventuella fistlar, urinrörets position och urinstrålens form poängsatts. I en första studie utvärderades de patienter som efter operationen följts upp till dess att de genomgått puberteten. Av de 149 opererade patienterna kom 114 till kontroll efter genomgången pubertet i enlighet med klinikens uppföljningsprogram. Under den mer än 10 år långa uppföljningstiden behandlades 11 % för fistlar, 4 % för urinrörsförträngning och sex patienter (5 %) av 114 undersökta hade återfått krökning under puberteten. En av dessa patienter fick opereras på nytt för att åtgärda detta. Den största andelen av patienterna (86 %) har goda resultat efter sin operation baserat på den sammanlagda poängsumman på HOSE.

I princip samma grupp patienter som undersökts i den första studien och var över 18 år, fick i tredje studien svara på en enkät om hur de upplevde penis funktion och utseende och hur de upplevt operationen/operationerna samt den efterföljande uppföljningen. Enkäten var tidigare validerad och använd i engelskspråkiga länder, varför den översattes men även modifierades för att anpassas till klinikens vårdprogram. Enkäten besvarades av 29 % av de tillfrågade patienterna. Då vi jämförde gruppen som svarat på enkäten med gruppen som inte besvarat den kunde vi inte se att grupperna skiljde sig nämnvärt åt med avseende på ålder, grad

av missbildning, samlade poäng enligt HOSE-formuläret eller förekomsten av komplikationer eller avseende hur stor andel av dem som genomgått uppföljningsprogrammet. De var nöjda med det kirurgiska resultatet, sin sexuella förmåga, det estetiska resultatet samt sin förmåga att urinera i majoriteten av fallen (82-92%). Vidare svarade de flesta (90 %) att de önskade en minst lika lång uppföljning som de hade fått för att säkerställa att resultaten var goda samt för att informeras om sitt tillstånd och sin behandling. Flera önskade längre uppföljning med fokus på sexuell funktion. Våra slutsatser från dessa studier är att långtidsuppföljning av patienter efter hypospadioperationer är nödvändigt för att upptäcka och behandla sent uppkomna komplikationer som t.ex. uppstår då patienten växer och genomgår puberteten. Våra resultat visar även att patienterna är positiva till denna uppföljning och att de upplever att det är viktigt att de i mogen ålder får information om sin avvikelse och dess behandling. Vår andel av komplikationer är låg, men det finns alltså patienter som drabbas av krökning av penis under puberteten.

I den andra studien undersökte vi om de operationsmetoder som används vid kliniken även kan användas om en förnyad operation krävs om den första operationen misslyckas. Vi undersökte en grupp om 36 patienter som sökt vård vid kliniken på grund av att tidigare försök till behandling inte varit framgångsrik. De flesta av patienterna hade krökning av penis och fistlar med urinläckage. Då samtliga patienter dock hade tillräckligt med hud på penis kunde de genomgå behandling i enlighet med vårt behandlingsprogram. En majoritet av patienterna behövde opereras i två steg. Efter vår behandling behövde 22 % av patienterna ytterligare kirurgi för att behandla komplikationer eller optimera det funktionella eller estetiska resultatet. Tio av patienterna fick behandling efter genomgången pubertet eller genomgick puberteten under studiens uppföljningstid. Dessa utvärderades enligt HOSE och visade att 86 % av dem hade goda resultat. Våra slutsatser från undersökningen är att om det föreligger kvarvarande vävnad på penis som kan användas vid förnyade operationer, så kan vår behandlingsalgoritm användas med framgång även vid upprepad kirurgi. Särskilt viktigt är det då att undersöka förekomsten av peniskrökning i dessa fall, och att operationsmetoden tillåter korrigering av krökningen.

I vår sista studie undersökte vi vävnaden på penis undersida: urinrörslattan och chordeevävnaden. Tio patienter som var planerade för upprättningsoperation tackade ja till att delta i studien. Istället för att slänga den krökande vävnaden under operationen skickades den på analys i mikroskop. Vävnadsbitarna analyserades även med hjälp av så kallad immunohistokemi. Då används färgade antikroppar för att binda in till och därmed markera särskilda ytmolekyler på den vävnaden man önskar studera. När vävnaden undersöktes i mikroskop såg vi att den hade liknande utseende i samtliga fall. Vi fann även att det fanns kronisk inflammation i samtliga vävnadsprov. Den inflammatoriska retningen av urinrörslattan var bitvis av en sådan grad att ytskiktet av celler, epitellagret, hade

förändrats och så kallad metaplasi hade uppstått. Denna typ av förändring i denna vävnad har tidigare inte beskrivits i forskningslitteraturen. Vår slutsats av denna undersökning blir att vävnaden på grund av inflammation kan förändras över tid och vi behöver undersöka vidare om inflammationen i denna vävnad kan ge upphov till ytterligare krökning av penis eller till inflammatoriska hudsjukdomar som kan drabba penisvävnad.

Appendix

Appendix 1: Hypospadias Objective Scoring Evaluation (HOSE)

Assessor:		Patient:	
Date:			
Variable	Score	Diagram	
1. Meatal location			
Distal glanular	4		
Proximal glanular	3		
Coronal	2		
Penile shaft	1		
2. Meatal Shape			
Vertical slit	2		
Circular	1		
3. Urinary Stream			
Single stream	2		
Spray	1		
4. Erection			
Straight	4		
Mild angulation ($< 10^{\circ}$)	3		
Moderate angulation ($> 10^{\circ}$ but $< 45^{\circ}$)	2		
Severe angulation ($> 45^{\circ}$)	1		
5. Fistula			
None	4		
Single - subcoronal or more distal	3		
Single - proximal	2		
Multiple or complex	1		
Total			

4. Overall, please indicate below your level of satisfaction with the **result of your hypospadias operation(s)**? (circle number).

Very unsatisfied 1-----2-----3-----4-----5 *Very satisfied*

|
neutral

Comments regarding result of hypospadias operation(s):

5. According to the follow-up programme, patients are followed to the age of 16 years. Would you have preferred *a different duration of follow-up* after your hypospadias operation(s)? (please circle answer)

Yes, shorter / Yes, longer / No, the duration of follow up was adequate / Do not know

Comments regarding duration of follow-up:

6. How did you *perceive* the hypospadias follow-up visits during your childhood? (please circle answer).

Positive / Negative / Do not know

Comments regarding follow-up visits:

7. Do you have memories of your childhood hypospadias' operation(s)? (please circle answer)

Yes / No / Do not know

Comments regarding memories of the operation(s):

8. Do you have negative experiences of your childhood hypospadias' operation? (please circle answer).

Yes / No / Do not know

Comments regarding negative experiences of the operation(s):

9. Have you, because of the hypospadias, *seeked medical care in other departments* than the department of Plastic surgery in Malmö? (please circle answer).

Yes / No / Do not know

IF you have seeked medical care, what/which problem(s) did you have?

WHEN did these problems occur?

Comments regarding medical care in other departments:

GENERAL COMMENTS

Thank you for taking time to fill out our questionnaire!

**Appendix 3: Modified Hypospadias Outcome
Questionnaire, Svenska**

HYPOSPADIAS OUTCOME QUESTIONNAIRE

1. På det stora hela, gradera nedan hur nöjd du är med din penis **utseende** (Ringa in).

Mycket missnöjd 1-----2-----3-----4-----5 *Väldigt nöjd*
|
neutral

Kommentarer angående penis utseende: _____

2. På det stora hela, gradera nedan hur nöjd du är med din penis **sexuella funktion** (Ringa in).

Mycket missnöjd 1-----2-----3-----4-----5 *Väldigt nöjd*
|
neutral

Kommentarer angående sexuell funktion: _____

3. På det stora hela, gradera nedan hur nöjd du är med din **förmåga att kissa** (Ringa in).

Mycket missnöjd 1-----2-----3-----4-----5 *Väldigt nöjd*
|
neutral

Kommentarer angående förmåga att kissa: _____

4. På det stora hela, gradera nedan hur nöjd du är med *resultatet* av din hypospadioperation (Ringa in).

Mycket missnöjd 1-----2-----3-----4-----5 *Väldigt nöjd*
|
neutral

Kommentarer angående nöjdhet: _____

5. Normalt följs patienter efter hypospadioperationer upp till 16 års ålder. Hade du föredragit *en annan uppföljningstid* efter din hypospadioperation? (Ringa in).

Ja, kortare / Ja, längre / Nej, det var en lagom uppföljningstid / Vet ej

Kommentarer angående uppföljningstiden: _____

6. Hur *upplevde du* de regelbundna uppföljande mottagningsbesöken under din barndom med avseende på hypospadioperationerna? (Ringa in)

Positivt / Negativt / Vet ej

Kommentarer angående uppföljande mottagningsbesök: _____

7. Har du minnen av din hypospadioperation i barndomen? (Ringa in)

Ja / Nej / Vet ej

Kommentarer angående minnen av operationen: _____

8. Har du negativa upplevelser av din hypospadioperation i barndomen? (Ringa in)

Ja / Nej / Vet ej

Kommentarer angående negativa upplevelser av operationen: _____

9. Har du på grund av din hypospadi eller vår behandling, **sökt vård på annan/andra kliniker** än Plastikkirurgiska Kliniken i Malmö? (Ringa in)

Ja / Nej / Vet ej

OM du har sökt vård, vilket/vilka problem hade du?

NÄR uppstod detta/dessa problem?

Kommentarer angående vård på annan klinik:

ALLMÄNNA KOMMENTARER: _____

Tack för att du tog dig tid med att fylla i vårt formulär!

Acknowledgements

This thesis was enabled through the support of ST-ALF (Avtal mellan svenska staten och vissa landsting om samarbete om grundutbildning av läkare, medicinsk forskning och utveckling av hälso- och sjukvården). For this I would like to express my gratitude to the University of Lund, Region Skåne, and the Swedish Government. The grant gave me the opportunity to conduct research work during daylight without compromising being a mother, wife, and clinician.

The work in this thesis is the product of the hard work of my research supervisors, and the inspiration, support and patience provided by my family, colleagues and friends. I would like to express my sincere gratitude to all of you for taking me on this journey and helping me along the way.

My warmest thanks goes to the research group as an entity, created by the dynamic personalities of my supervisors and their support, which enabled this thesis:

Professor Henry Svensson. You kindly accepted the “delivery” of me as your PhD-student from the Department of Paediatric surgery. You have introduced me to clinical research and plastic surgery and shared your knowledge and your wisdom. I am grateful for your warm compassion when it was badly needed, your patience and for believing in me, despite so many conflicting priorities in my life.

Professor Einar Arnbjörnsson. Your endless enthusiasm and energy in the Clinic as well as in research is a source of inspiration and deeply admirable. You have given me much needed support and you have added important energy and balance to our research group. Thank you also for the speed in which you reply to all emails.

Associate professor Emma Hansson. This would never have happened without you, neither the start of this project nor a single word printed. Thank you for providing me with this opportunity. You have generously shared eons of knowledge and experience. Thank you for not giving up on me, despite my ignorance and constant lack of time. Your work capacity and dedication is an inspiration. Finally, thank you for your friendship.

In addition, I would like to express my gratitude to:

Professor David Gisselsson. Your contribution to this project was essential, and it has been such a delight working with you. Thank you for your patience and the

sincerely hope to cooperate with you in many future projects as a paediatric surgeon.

Associate professor and former Head of Department Christina Clementson Kockum. Thank you for believing in me and taking me in, for being a role model and enabling this research project. Thank you for your warm support in the hardest of times.

To all my senior colleagues at the Department of Paediatric Surgery for being role models, sources of inspiration, for innumerable fun gatherings and conversations, warm friendship and invaluable support: Torbjörn Backman, Anna Börjesson, Pernilla Stenström, Magnus Anderberg, Lars Hagander, Hans Winberg and Morten Vigen.

To all my wonderful past, present and future junior colleagues at the, Department of Paediatric Surgery for inspiration, energy, knowledge, friendship and support: Kristine Hagelsteen, Mette Hambræus, Martin Salö, Christina Graneli, Erik Omling, Emma Grotting, Maria Naredi, David Sahli, Louise Tofft, Helena Arnadottir and Margret Victorsdottir.

To the colleagues at the Department of Plastic and Reconstructive Surgery for kind help and welcoming.

Associate Professor Johan Sjögren for research mentorship, but more importantly, hilarious conversations and the highly valued warm friendship you and your wonderful family provide us with.

Victoria Schönström, our beautiful neighbour! Without your so very kind Art-Directing hands, this book would be nothing but a bunch of papers with text.

To the persons closest to me who make life full of warmth and love. I am eternally grateful for my life in your presence.

Mother and Father, you provided the most important fundamentals in life in the best possible way. Thank you for your endless support and love, and your patience with my journey in life. My gratitude cannot be expressed in words for the love and support you provided to us all, in the most unselfish way, at the hardest of times.

My sister and her lovely family: Rickard, Elin and Erik. Thank you for being a part of my life, you mean very much to me. Thank you for honest and loving support. How I only wish I could have you a little closer geographically!

Saga, Emil, Juni, *in memoriam*, and Otto. How can I ever deserve the beautiful gift of time spent in your presence? Thank you for your patience

with your crazy mother and your unconditional love, which I rarely deserve, but am so pleased to absorb. I am so proud of you. I love you more than words can ever express.

Shahab. My toughest critic yet my warmest supporter. Where would I ever be in life without you? Thank you for pushing me forward at all time and for your unlimited support along the way. I admire you so much and love you so deeply. Please continue to fill my life with challenges and meaning through your presence.

References

1. Kumar S, Tomar V, Yadav SS, Priyadarshi S, Vyas N, Agarwal N. Fertility Potential in Adult Hypospadias. *Journal of Clinical and Diagnostic Research*. 2016;Aug (10(18)):PC01-PC05.
2. Boudaoud N, Pons M, Bouche Pillon Persyn MA, Lefebvre F, Poli Merol ML, Francois C. Hypospadias. *Annales de Chirurgie Plastique Esthétique*. 2016;61(5):439-449.
3. Rey RA, Grinspon RP. Normal male sexual differentiation and aetiology of disorders of sex development. *Best Practice & Research Clinical Endocrinology & Metabolism*. 2011;25(2):221-238.
4. Larsen WJ. *Human Embryology*. Churchill Livingstone Inc; 1993.
5. Hynes PJ, Fraher JP. The development of the male genitourinary system: II. The origin and formation of the urethral plate. *British Journal of Plastic Surgery*. 2004;57(2):112-121.
6. Kurzrock EA, Baskin LS, Cunha GR. Ontogeny of the male urethra: Theory of endodermal differentiation. *Differentiation*. 1999;64(2):115-122.
7. van der Putte SC. Hypospadias and associated penile anomalies: a histopathological study and a reconstruction of the pathogenesis. *J Plast Reconstr Aesthet Surg* 2007;60(1):48-60.
8. Shen J, Overland M, Sinclair A, et al. Complex epithelial remodeling underlie the fusion event in early fetal development of the human penile urethra. *Differentiation*. 2016;92(4):169-182.
9. Li Y, Sinclair A, Cao M, et al. Canalization of the Urethral Plate Precedes Fusion of the Urethral Folds during Male Penile Urethral Development: The Double Zipper Hypothesis. *The Journal of urology*. 2015;193(4):1353-1360.
10. Thorup J, A. N, Hutson JM. Genetic and environmental origins of hypospadias. *Curr Opin Endocrinol Diabetes Obes* 2014;Jun;21(3):227-232. .
11. Baskin LS, Ebbers MB. Hypospadias: anatomy, etiology, and technique. *Journal of pediatric surgery*. 2006;41(3):463-472.
12. Zacharias Z. Blood supply of the penile skin. In: Hadidi Ahmed T, F AA, eds. *Hypospadias surgery an illustrated guide*. Berlin: Springer Verlag; 2004.
13. Baskin LS, Erol ALI, Li YW, Cunha GR. Anatomical Studies of Hypospadias. *J Urol*. 1998;160(3, Part 2):1108-1115.
14. Erol A, Baskin LS, Li YW, Liu WH. Anatomical studies of the urethral plate: why preservation of the urethral plate is important in hypospadias repair. *BJU International*. 2000;85(6):728-734.

15. Avellán L, Knutsson F. Microscopic Studies of Curvature-Causing Structures in Hypospadias. *Scandinavian Journal of Plastic and Reconstructive Surgery and Hand Surgery*. 1980;14(3):249-258.
16. Hayashi Y, Mizuno K, Kojima Y, et al. Characterization of the urethral plate and the underlying tissue defined by expression of collagen subtypes and microarchitecture in hypospadias. *International journal of urology : official journal of the Japanese Urological Association*. 2011;Apr 18(4):317-322.
17. Snodgrass W, Patterson K, Plaire JC, Grady R, Mitchell ME. Histology of the urethral plate: implications for hypospadias repair. *J Urol*. 2000;164(3, Part 2):988-990.
18. Kaplan GW, Lamm DL. Embryogenesis of chordee. *J Urol* 1975;Nov;114(5):769-772.
19. Kaplan GW, Brock WA. The etiology of chordee. *Urol Clin North Am*. 1981;Oct;8(3):383-387.
20. Yachia D, Beyar M, Aridogan IA, Dascalu S. The incidence of congenital penile curvature. *The Journal of urology*. 1993;150 (5 Pt 1)(0022-5347 (Print)):1478-1479.
21. Avellán L. Morphology of Hypospadias. *Scand J Plast Reconstr Surg* 1980;14(3):239-247.
22. Cunha GR, Sinclair A, Risbridger G, Hutson J, Baskin LS. Current understanding of hypospadias: relevance of animal models. *Nature reviews Urology*. 2015;12(5):271-280.
23. Baskin LS, Duckett JW, Lue TF. Penile curvature. *Urology*. 1996;48(3):347-356.
24. Snodgrass W. A farewell to chordee. *The Journal of urology*. 2007;178(3 Pt 1):753-754.
25. Montag S, Palmer LS. Abnormalities of Penile Curvature: Chordee and Penile Torsion. *TheScientificWorldJOURNAL*. 2011;11:1470-1478.
26. Radojicic ZI, Perovic SV. Classification of prepuce in hypospadias according to morphological abnormalities and their impact on hypospadias repair. *The Journal of urology*. 2004;172(1):301-304.
27. Hadidi AT. Classification of hypospadias. In: Hadidi AT, Azmy AF, eds. *Hypospadias surgery. An illustrated guide*. Berlin: Springer Verlag; 2004:79-82.
28. Springer A, Tekgul S, Subramaniam R. An Update of Current Practice in Hypospadias Surgery. *European Urology Supplements*. 2017;16(1):8-15.
29. Bouty A, Ayers KL, Pask A, Heloury Y, Sinclair AH. The Genetic and Environmental Factors Underlying Hypospadias. *Sexual Development*. 2015;9(5):239-259.
30. Shih EM, Graham Jr JM. Review of genetic and environmental factors leading to hypospadias. *European Journal of Medical Genetics*. 2014;57(8):453-463.
31. Rooij IALM, Zanden LFM, Brouwers MM, Knoers NVAM, Feitz WFJ, Roeleveld N. Risk factors for different phenotypes of hypospadias: results from a Dutch case-control study. *BJU International*. 2013;112(1):121-128.

32. Nordenvall AS, Frisen L, Nordenstrom A, Lichtenstein P, Nordenskjold A. Population Based Nationwide Study of Hypospadias in Sweden, 1973 to 2009: Incidence and Risk Factors. *The Journal of urology*. 2014;Mar 191(3):783-789.
33. Loane M, Dolk H, Kelly A, et al. Paper 4: EUROCAT statistical monitoring: Identification and investigation of ten year trends of congenital anomalies in Europe. *Birth Defects Research Part A: Clinical and Molecular Teratology*. 2011;91(S1):S31-S43.
34. Springer A, van den Heijkant M, Baumann S. Worldwide prevalence of hypospadias. *Journal of Pediatric Urology*. 2016;12(3):152.e151-152.e157.
35. Cimador M, Vallasciani S, Manzoni G, Rigamonti W, De Grazia E, Castagnetti M. Failed hypospadias in paediatric patients. *Nature reviews Urology*. 2013;10(11):657-666.
36. Hadidi AT. Men behind principles and principles behind techniques. In: T HA, Azmy AF, eds. *Hypospadias surgery. An illustrated guide*. Berlin: Springer Verlag; 2004.
37. Kampantais S, C D, L L, I P, P K, Toutziaris C. Urethral hairballs as a long-term complication of hypospadias repair: two case reports. *Case Rep Urol*. 2012(2012:769706). Accessed 20120827 DCOM- 20120827.
38. Bracka A. The role of two-stage repair in modern hypospadiology. *Indian journal of urology : IJU : journal of the Urological Society of India*. 2008;24(2):210-218.
39. Jayanthi VR, McLorie GA, Khoury AE, Churchill BM. Can previously relocated penile skin be successfully used for salvage hypospadias repair? *The Journal of urology*. 1994;152(2 Pt 2):740-743.
40. Rynja SP, de Jong TP, Bosch JL, de Kort LM. Functional, cosmetic and psychosexual results in adult men who underwent hypospadias correction in childhood. *J Pediatr Urol*. 2011;7(5):504-515.
41. Kaas E, Kogan SJ. Timing of elective surgery on the genitalia of male children with particular reference to the. *Pediatrics*. 1996;97(4):590.
42. Weber DM, Schonbucher VB, Gobet R, Gerber A, Landolt MA. Is there an ideal age for hypospadias repair? A pilot study. *Journal of Pediatric Urology*. 2009;5:345-350.
43. Carmack A, Notini L, Earp BD. Should Surgery for Hypospadias Be Performed Before An Age of Consent? *Journal of Sex Research*. 2016;53(8):1047-1058.
44. Barbagli G, De Angelis M, Palminteri E, Lazzeri M. Failed hypospadias repair presenting in adults. *European urology*. 2006;49(5):887-894; discussion 895.
45. Barbagli G, Perovic S, Djinovic R, Sansalone S, Lazzeri M. Retrospective descriptive analysis of 1,176 patients with failed hypospadias repair. *The Journal of urology*. 2010;183(1):207-211.
46. Aulagne MB, Harper L, de Napoli-Cocci S, Bondonny JM, Dobremez E. Long-term outcome of severe hypospadias. *J Pediatr Urol*. 2010;6(5):469-472.
47. Hoag CC, Gotto GT, Morrison KB, Coleman GU, Macneily AE. Long-term functional outcome and satisfaction of patients with hypospadias repaired in childhood. *Can Urol Assoc J*. 2008;2(1):23-31.

48. Moriya K, Kakizaki H, Tanaka H, et al. Long-Term Patient Reported Outcome of Urinary Symptoms After Hypospadias Surgery: Norm Related Study In Adolescents. *The Journal of urology*. 2007;178(4, Supplement):1659-1662.
49. Moriya K, Kakizaki H, Tanaka H, et al. Long-Term Cosmetic and Sexual Outcome of Hypospadias Surgery: Norm Related Study in Adolescence. *The Journal of urology*. 2006;176(4, Supplement):1889-1893.
50. Holland AJ, Smith GH, Ross FI, Cass DT. HOSE: an objective scoring system for evaluating the results of hypospadias surgery. *BJU Int*. 2001;88(3):255-258.
51. Mureau MA, Slijper FM, Slob AK, Verhulst FC, Nijman RJ. Satisfaction with penile appearance after hypospadias surgery: the patient and surgeon view. *The Journal of urology*. 1996;155(2):703-706.
52. Seibold J, Werther M, Alloussi S, et al. Objective long-term evaluation after distal hypospadias repair using the meatal mobilization technique. *Scandinavian Journal of Urology & Nephrology*. 2010;44(5):298-303.
53. Weber DM, Schönbacher VB, Landolt MA, Gobet R. The Pediatric Penile Perception Score: An Instrument for Patient Self-Assessment and Surgeon Evaluation After Hypospadias Repair. *The Journal of urology*. 2008;180(3):1080-1084.
54. van der Toorn F, de Jong TPVM, de Gier RPE, et al. Introducing the HOPE (Hypospadias Objective Penile Evaluation)-score: A validation study of an objective scoring system for evaluating cosmetic appearance in hypospadias patients. *Journal of Pediatric Urology*. 2013;9(6, Part B):1006-1016.
55. Deshpande PR, Rajan S, Sudeepthi BL, Abdul Nazir CP. Patient-reported outcomes: A new era in clinical research. *Perspectives in Clinical Research*. 2011;2(4):137-144.
56. Byars LT. A technique for consistently satisfactory repair of hypospadias. *Surg Gynecol Obstet*. 1955;100(2):184-190.
57. Mathieu P. Traitement en un temps de l'hypospade balanique et juxta-balanique. *J Chir (Paris)*. 1932;39:481-484.
58. Scuderi N, Campus G. A new technique for hypospadias one-stage repair. *Chir Plast*. 1983;7:103-109.
59. Cimador M, Pensabene M, Sergio M, Catalano P, de Grazia E. Coverage of urethroplasty in pediatric hypospadias: randomized comparison between different flaps. *International journal of urology : official journal of the Japanese Urological Association*. 2013;20(10):1000-1005.
60. Hansson E, Becker M, Aberg M, Svensson H. Analysis of complications after repair of hypospadias. *Scandinavian journal of plastic and reconstructive surgery and hand surgery / Nordisk plastikkirurgisk forening [and] Nordisk klubb for handkirurgi*. 2007;41(3):120-124.
61. Reid LA, Curnier AP, Stevenson JH. Objective outcome assessment of the modified Bretteville technique. *Journal of plastic, reconstructive & aesthetic surgery : JPRAS*. 2010;63(3):398-403.
62. Flynn JT, Johnston SR, Blandy JP. Late sequelae of hypospadias repair. *British journal of urology*. 1980;52(6):555-559.

63. Jones BC, O'Brien M, Chase J, Southwell BR, Hutson JM. Early hypospadias surgery may lead to a better long-term psychosexual outcome. *The Journal of urology*. 2009;182(4 Suppl):1744-1749.
64. Yucel S, Sanli A, Kukul E, Karaguzel G, Melikoglu M, Guntekin E. Midline dorsal plication to repair recurrent chordee at reoperation for hypospadias surgery complication. *The Journal of urology*. 2006;175(2):699-702; discussion 702-693.
65. Vandersteen DR, Husmann DA. Late onset recurrent penile chordee after successful correction at hypospadias repair. *The Journal of urology*. 1998;160(3 Pt 2):1131-1133; discussion 1137.
66. Örtqvist L, Fossum M, Andersson M, et al. Long-Term Followup of Men Born with Hypospadias: Urological and Cosmetic Results. *The Journal of urology*. 2015;193(3):975-982.
67. Jiao C, Wu R, Xu X, Yu Q. Long-term outcome of penile appearance and sexual function after hypospadias repairs: situation and relation. *International Urology & Nephrology*. 2011;43(1):47.
68. Bubanj TB, Perovic SV, Milicevic RM, Jovic SB, Marjanovic ZO, Djordjevic MM. Sexual Behavior and Sexual Function of Adults After Hypospadias Surgery: A Comparative Study. *The Journal of urology*. 2004;171(5):1876-1879.
69. Chertin B, Natsheh A, Ben-Zion I, et al. Objective and Subjective Sexual Outcomes in Adult Patients after Hypospadias Repair Performed in Childhood. *The Journal of urology*. 2013;190(4, Supplement):1556-1560.
70. Nelson CP, Bloom DA, Kinast R, Wei JT, Park JM. Long-term patient reported outcome and satisfaction after oral mucosa graft urethroplasty for hypospadias. *The Journal of urology*. 2005;174(3):1075-1078.
71. Bracka A. A long-term view of hypospadias. *Br J Plast Surg*. 1989;42(3):251-255.
72. Olofsson K, Oldbring J, Becker M, Åberg M, Svensson H. Self-perception after hypospadias repair in young mens' perspective. *European Journal of Plastic Surgery*. 2003;26(6):294-297.
73. Aho MO, Tammela OK, Somppi EM, Tammela TL. Sexual and social life of men operated in childhood for hypospadias and phimosis. A comparative study. *European urology*. 2000;37(1):95-100; discussion 101.
74. Sommerlad BC. A long-term follow-up of hypospadias patients. *Br J Plast Surg*. 1975;28(4):324-330.
75. van der Werff JF, van der Meulen JC. Treatment modalities for hypospadias cripples. *Plastic and reconstructive surgery*. 2000;105(2):600-608.
76. Snodgrass W, Macedo A, Hoebeke P, Mouriquand PD. Hypospadias dilemmas: a round table. *J Pediatr Urol*. 2011;7(2):145-157.
77. Devine CJ, Jr., Franz JP, Horton CE. Evaluation and treatment of patients with failed hypospadias repair. *The Journal of urology*. 1978;119(2):223-226.
78. Braga LH, Lorenzo AJ, Suoub M, Bagli DJ. Is statistical significance sufficient? Importance of interaction and confounding in hypospadias analysis. *The Journal of urology*. 2010;184(6):2510-2515.

79. Gill NA, Hameed A. Management of hypospadias cripples with two-staged Bracka's technique. *Journal of plastic, reconstructive & aesthetic surgery : JPRAS*. 2011;64(1):91-96.
80. Khan U, Zic R, Boorman J. Waterproofing in hypospadias: a refinement of the two-stage reconstruction. *Br J Plast Surg*. 2001;54(6):528-531.
81. Telfer JR, Quaba AA, Kwai Ben I, Peddi NC. An investigation into the role of waterproofing in a two-stage hypospadias repair. *Br J Plast Surg*. 1998;51(7):542-546.
82. Waterman BJ, Renschler T, Cartwright PC, Snow BW, DeVries CR. Variables in successful repair of urethrocutaneous fistula after hypospadias surgery. *The Journal of urology*. 2002;168(2):726-730; discussion 729-730.
83. Townsend PL. Silicone rubber casts of the distal urethra in studying fistula formation and other hypospadias problems. *Br J Plast Surg*. 1975;28(4):320-323.
84. Perovic S, Barbagli G, Djinovic R, Sansalone S, Vallasciani S, Lazzeri M. Surgical challenge in patients who underwent failed hypospadias repair: is it time to change? *Urologia internationalis*. 2010;85(4):427-435.
85. da Silva EA, de Marins RL, Rondon A, Damiao R. Age-related structural changes of the urethral plate in hypospadias. *J Pediatr Urol*. 2013;Dec 9(1873-46 pt B):1155-1160.
86. Rothschild JG, Wu G. Ureteritis cystica: a radiologic pathologic correlation. *J Clin Imaging Sci* 2011;1(23).
87. Ching CB, Wood HM, Ross JH, Gao T, Angermeier KW. The Cleveland Clinic experience with adult hypospadias patients undergoing repair: their presentation and a new classification system. *BJU Int*. 2011;107(7):1142-1146.
88. Snodgrass W. Tubularized, incised plate urethroplasty for distal hypospadias. *The Journal of urology*. 1994;151(2):464-465.
89. Liu MMY, Holland AJA, Cass DT. Assessment of postoperative outcomes of hypospadias repair with validated questionnaires. *Journal of pediatric surgery*. 2015;50(12):2071-2074.
90. Ghidini F, Sekulovic S, Castagnetti M. Parental Decisional Regret after Primary Distal Hypospadias Repair: Family and Surgery Variables, and Repair Outcomes. *The Journal of urology*. 2016;195(3):720-724.
91. Lorenzo AJ, Pippi Salle JL, Zlateska B, Koyle MA, Bägli DJ, Braga LHP. Decisional Regret after Distal Hypospadias Repair: Single Institution Prospective Analysis of Factors Associated with Subsequent Parental Remorse or Distress. *The Journal of urology*. 2014;191(5, Supplement):1558-1563.

Paper I

Original Article

Postpubertal Examination after Hypospadias Repair Is Necessary to Evaluate the Success of the Primary Reconstruction

Ann Nozohoor Ekmark¹ Henry Svensson² Einar Arnbjörnsson³ Emma Hansson²

¹Departments of Clinical Sciences Malmö and Department of Pediatric Surgery, Skåne University Hospital, Lund, Sweden

²Departments of Clinical Sciences Malmö and Department of Plastic and Reconstructive Surgery, Skåne University Hospital, Malmö, Sweden

³Departments of Clinical Sciences Lund and Department of Pediatric Surgery, Skåne University Hospital, Lund, Sweden

Address for correspondence Ann Nozohoor Ekmark, MD, MSc, Department of Pediatric Surgery, Skåne University Hospital, SE-221 85 Lund, Sweden (e-mail: Ann.Nozohoor_Ekmark@med.lu.se).

Eur J Pediatr Surg 2013;23:304–311.

Abstract

Introduction Hypospadias is one of the most common congenital anomalies. There are many studies describing successful initial repair, but there are few studies examining long-term result. The aims of this study were to evaluate our patients that have been reconstructed for hypospadias and undergone final clinical examination after puberty and to assess how long clinical follow-up time is warranted after hypospadias repair.

Patients and Methods A standard protocol, with visits at ages 7, 10, 13 and a final clinical examination at the age of 16, was followed. To objectify our long-term functional and aesthetic results, Hypospadias Objective Scoring Evaluation (HOSE) was used.

Results A total of 114 boys reconstructed between 1989 and 2009 had undergone final clinical examination. Seventy-nine were classified as degree I, 25 as degree II, 6 degree III, 3 as degree IV, and 1 boy could not be classified retrospectively. Sixty-seven boys were operated on in stages according to Byars, 25 according to Mathieu, and 14 according to Scuderi. Only eight patients needed release of chordee and realignment of skin. Ten boys needed closure of fistulas and strictures had to be operated on in four cases. At the concluding visit, 86% of the patients had an excellent result according to the total HOSE score. It was noted that six patients had developed an incurvation between the prepubertal and postpubertal checkup.

Conclusion It is important that the boys are followed according to a planned standardized protocol until they have passed puberty as incurvation may occur during puberty.

Keywords

- ▶ hypospadias
- ▶ reconstruction
- ▶ long-term follow-up
- ▶ chordee
- ▶ incurvation

Introduction

Hypospadias is one of the most common congenital anomalies with an incidence of 1 in 200 to 1 in 300 live births.¹ Reconstruction of hypospadias must encompass both straightening of the penis and reconstruction of the urethra so that the meatus is

positioned on the tip of the glans. Nonetheless, there is no standardized treatment method as more than 300 different surgical techniques for repair of hypospadias have been described.¹ The aims of surgical treatment of the condition are good urinary and sexual function as well as an acceptable aesthetic result. There are many studies describing successful

initial repair, but urinary and particularly sexual function cannot be evaluated in the infant. There are few studies that examine long-term result of hypospadias repair.

The aims of this study were to evaluate our patients that have been reconstructed for hypospadias and undergone final clinical examination after puberty and to assess how long clinical follow-up time is warranted after hypospadias repair.

Patients and Methods

Patients

Boys reconstructed due to hypospadias were identified using a consecutive record of patients covering the period from 1989 to 2011. Only boys that had been reconstructed by the senior hypospadias surgeon (H.S.), and that had undergone final clinical examination after puberty, were included in the study. Hypospadias was classified by the degree according to the position of the urethral meatus after orthoplasty²: balanic hypospadias (degree I), distal hypospadias (degree II), penoscrotal hypospadias (degree III), and perineal hypospadias (degree IV).

Ethics

Permission to create a register of the patients was obtained in accordance with the Swedish Privacy Protection Law. The procedures followed were in accordance with the Helsinki Declaration of 1964, as revised, and the Good Clinical Practice guidelines.

Treatment Protocol

The operative technique was chosen according to the position of the meatus and the degree of chordee. Artificial erection test was not routinely used. Evolving over time, the following basis for surgical treatment has been implemented: for the mildest form of degree I hypospadias with slight curvature, orthoplasty and realignment of the skin was sufficient. For degree I, the Mathieu procedure was suitable and for mild degree II, we used the Scuderi technique. In case of proximal hypospadias, more pronounced degrees II, III, and IV, a two-staged reconstruction according to Byars was used. Thus, there has been a shift over time from initially only using two-staged reconstruction toward using one-stage procedures for selected suitable cases as described above.

Mathieu One-Stage Operation

In the Mathieu one-stage procedure,³ a skin flap based toward the meatus is turned 180 degrees and sutured into incisions on either side of the glanular groove and further up to the tip. If chordee tissue is present, it is excised. The prepuce is partially divided and mobilized until an outer cover is achieved. A catheter is retained for 5 days.

Scuderi One-Stage Operation

According to the Scuderi one-stage procedure,⁴ the prepuce constitutes a flap that is transposed to the ventral side of the penis, by de-epithelialization of a part of the flap and the creation of a buttonhole in the area. The glans and distal penis are passed through this. The flap with its epithelium are then

wrapped around a catheter and anastomosed against the native meatus. The remaining lateral parts of the prepuce are used for the outer lining. Care is also taken to remove any chordee tissue. A catheter is retained for 6 to 7 days.

Modified Byars Two-Stage Reconstruction

Stage 1 of the modified Byars two-stage reconstruction⁵ is release of the chordee at the age of 4.5 to 5 years. A circumferential incision is made 3 mm from the coronary sulcus and the prepuce is divided dorsally. On the ventral side, the fibrous chordee is divided and partially excised, the plane of preparation being the underlying fascia. The new position of the meatus is secured with a single suture, and the dorsal flaps are moved around to cover the ventral defect. A urinary catheter is retained for 3 to 4 days. Stage 2 comprises urethral reconstruction. This is done 6 months after the stage 1 procedure. A U-shaped incision is made just proximal to the meatus, ending up on either side of the glans. The inner lining is closed in two layers around a urinary catheter. The outer lining is also closed in two layers. If there is not enough skin on the outer lining, a diamond-shaped defect is created by an incision on the dorsal side; this is covered with a split skin graft. In certain cases, the defect can be closed with a transverse primary suture line. The urinary catheter is retained for 5 to 6 days.

In some cases, operations are necessary between stages 1 and 2 to optimize conditions before the final urethral reconstruction. These procedures include releases and repairs over the penoscrotal junction, meatotomy if the meatus is narrow, adjustment of the skin flaps or the position of the meatus, and other minor procedures.

Catheters, Suture Technique, Dressing, and Antibiotics

With very few exceptions conventional Foley catheters, Charrier (Ch) 8 or 10, were used. At the beginning, 5/0 chromic catgut was mostly used for suturing. The suture material was changed from using chromic catgut (Ethicon, Johnson & Johnson Medical Limited, Norderstedt, Germany) to the use of 5/0 or 6/0 polyglactin 910, Vicryl (Ethicon, Johnson & Johnson Medical Limited, Norderstedt, Germany) because chromic catgut was no longer available on the European market. The change in suture material did not lead to any changes in the postoperative complication rate noted in the group of patients studied. The dressing used was the same for all patients; it consisted of a layer of 1% hydrocortisone cream (Terra-Cortril, Pfizer, Sollentuna, Sweden) over the suture line, a petroleum jelly (Jelonet; Smith & Nephew, Mölndal, Sweden) pad, a cotton pad, a ring of foam rubber, and surrounding tape. The dressing resembled a chimney. In early releases, the penis is normally so short that only a piece of surrounding surgical tape can be used. During all urethral reconstructions, including closure of fistulas, we gave prophylactic antibiotics in the form of Eusaprim (Vitaflo Scandinavia, Gothenburg, Sweden) (sulphamethoxazole and trimethoprim) 5 mL twice a day for 5 days.

Closure of a Fistula

A fistula was closed by circumcision, invagination, and suturing. In some cases, an outer layer could be achieved simply by

mobilizing the local skin. In other cases, a local flap had to be used.

Urethral Stricture and Meatal Stenosis

Meatal strictures were treated by meatotomy, and urethral stenoses were dilated as a first measure.

Secondary Corrections

Secondary procedures included distal urethral reconstruction, correction of the skin, and other aesthetic corrections.

Follow-Up Protocol

A standard protocol, with visits at age 7, 10, 13 and a final clinical examination at the ages of 16, when the boy has normally past puberty, was followed and data were prospectively collected. In a few patients who had completed puberty at age 13 and had no complications, the clinical follow-up was terminated at age 13. If the boy had not passed puberty, the final clinical control was delayed until he had. The patient was

examined and interviewed about his urinary and sexual function at the concluding visit. To supplement the clinical examination, an uroflow examination was performed for all patients until 2004 for documentary purposes. However, as no asymptomatic strictures were detected and all uroflow examinations were normal,⁶ they are now routinely performed, but only when clinically indicated, that is, in patients with poor urinary stream.

Hypospadias Objective Scoring Evaluation

To objectify our long-term functional and aesthetic results, HOSE⁷ was evaluated at the final clinical examination. HOSE is a five-point scoring system incorporating five domains: evaluation of meatal location and shape, urinary stream, straightness of erection, and the presence and complexity of urethral fistula (→Fig. 1).⁷ The scoring system rewards a total score of 5 to 16 points and according to the original description of HOSE, a total score of ≥ 14 is considered to infer an acceptable outcome after hypospadias repair.⁷

Assessor:	Patient:	
Date:		
Variable	Score	Diagram
1. Meatal location		
Distal glanular	4	
Proximal glanular	3	
Coronal	2	
Penile shaft	1	
2. Meatal Shape		
Vertical slit	2	
Circular	1	
3. Urinary Stream		
Single stream	2	
Spray	1	
4. Erection		
Straight	4	
Mild angulation (< 10°)	3	
Moderate angulation (> 10° but < 45°)	2	
Severe angulation (> 45°)	1	
5. Fistula		
None	4	
Single - subcoronal or more distal	3	
Single - proximal	2	
Multiple or complex	1	
Total		

Fig. 1 The HOSE assessment form.⁷ Reprinted with permission from Wiley.

Seibold et al⁸ have suggested that 14 points or greater should be defined as excellent, where 16 points indicate no restrictions and 12 to 15 points indicate minimal restrictions. The system has been validated and a minimal interobserver variation has been seen for it.⁷ HOSE has been used in several studies to evaluate both short-term and long-term results following different hypospadias reconstructions.⁸⁻¹²

Statistics

Categorical values were expressed as frequencies, and continuous variables were expressed as medians and ranges. The chi-squared test was used to test if the degree of hypospadias was related to the number of complications and fistulas. Fisher exact test was used when the expected frequency was less than 5. A p value of less than 0.05 was considered to indicate a statistically significant association. The percentages

have been rounded off to whole numbers, and therefore, the total does not always amount to 100. Percentages were not calculated for groups with n < 25. Data were analyzed with SPSS (Statistical Package for the Social Sciences 19.0, IBM, Chicago, Illinois, United States).

Results

The cohort was composed of a total of 149 patients primarily reconstructed in our department 1989 to 2009 who have undergone puberty and hence have qualified for a concluding clinical visit. Thirty-five patients did not have a final clinical control (- Fig. 2), which left 114 patients in the study.

All patients with degrees III and IV, most of the patients with degree II (72%), and about half (49%) of the patients with degree I hypospadias had a Byars reconstruction (- Table 1).

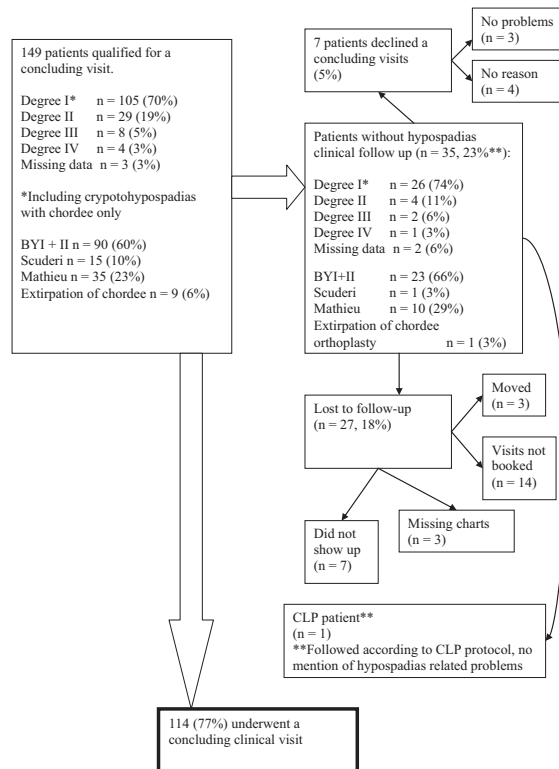


Fig. 2 Followed-up patients. One patient with concomitant cleft lip and palate (CLP) was followed according to the national follow-up schedule for CLP until the age of 19. In this patient, the follow-up of the reconstructed hypospadias was lost, but as the patient had several visits to our clinic without mentioning any problems from the genital area, we must assume the results were satisfactory.

Table 1 Procedures and methods of reconstructions given as number of patients (percent of patients with that degree)

Surgical technique	Degree					
	Missing data <i>n</i> = 1	I <i>n</i> = 79	II <i>n</i> = 25	III <i>n</i> = 6	IV <i>n</i> = 3	Total <i>n</i> = 114
Release of chordee (orthoplasty) and realignment of skin		8 (10%)				8 (7%)
Byars I + Byars II	1 (1%)	39 (49%)	18 (72%)	6 (100%)	3	67 (59%)
Scuderi		12 (15%)	2 (8%)	0		14 (12%)
Mathieu		20 (25%)	5 (20%)	0		25 (22%)

Notes: The percentages have been rounded off to whole numbers, and therefore, the total does not always amount to 100. Percentages were not calculated for groups with $n < 25$.

The others were reconstructed with a Scuderi or Mathieu procedure (–Table 1). Eight patients (degree I) only had orthoplasty and realignment of the skin. Among the patients reconstructed in stages, eight needed intermediate operations, including additional release of chordee, meatotomy, and different types of correction of the skin or flaps, before urethral reconstruction. Median age at urethral reconstruction was 5 years (range 4 to 16). Nineteen patients needed secondary corrections with elongation of the urethra and cosmetic corrections of the skin or scar formation or excisions of epithelial cysts.

In total, four patients in this study had surgical intervention due to urethral stricture. Three of the patients were operated on with the two-staged Byars technique. The first patient had no problems at the final clinical visit, but returned 6 years later and needed surgical treatment because of a stricture. The second patient had a balanic hypospadias and a stricture at the final clinical visit and was treated surgically. The third patient had penile hypospadias and had symptoms of stricture at the prepubertal visit and was successfully dilated with a catheter. However, he returned 3 years after the postpubertal visit with a new stricture, and the entire urethral reconstruction had to be cut open to solve the problem. The fourth patient had penile hypospadias with pronounced chordee and initially operated on according to Scuderi. Six years after reconstruc-

tion, a stricture was detected and cleaved. Six years later, he had to be treated once more due to pronounced strictures. He is still in active follow-up.

The overall fistula frequency was 11% (12/114) (–Table 2). There was a significant association between the degree of hypospadias and the occurrence of fistulas ($p < 0.001$, $\chi^2 = 86.94$). Also, there was a significant association between the degree of hypospadias and the total number of complications ($p < 0.001$, $\chi^2 = 63.67$).

Median age at the concluding visit was 16 (range 13 to 21) years. According to the total HOSE score, 95% (103/108) of the patients had an acceptable result after reconstruction if the reconstructed meatal shape is considered vertical and 85% (93/108) if it is considered circular (–Table 3). More patients with degree I had a satisfactory result according to the HOSE than patients with degrees II and III hypospadias (–Table 3). At the concluding visit, 32 patients (28%, 34/114) had various shortcomings (23 events) or complications (12 events). At the concluding clinical visit, six patients had incurvation of which one needed surgical correction and the outcome is subject to follow up. None of the patients had incurvation after corrective surgery and before puberty. Two patients had fistulas, one without functional implications which is why corrective surgery was declined by the patient. The other patient did not want additional surgery at the moment.

Table 2 Complications after different procedures

Type of complication	Surgical method				
	Byars (<i>n</i> = 67)	Release of chordee (orthoplasty) (<i>n</i> = 8)	Scuderi (<i>n</i> = 14)	Mathieu (<i>n</i> = 25)	Total (<i>n</i> = 114), %
Incurvation after puberty (<i>n</i> = 6 ^a)	3	1	0	2	5
Urethral stricture (<i>n</i> = 4)	3	0	1	0	4
Fistula (<i>n</i> = 12 ^b)	10	0	1	1	11
Postoperative hematoma (<i>n</i> = 4)	3	1	0	0	4
Postoperative urinary catheter dysfunction (<i>n</i> = 9)	7	0	1	1	8
Postoperative infection (<i>n</i> = 1)	1	0	0	0	1

Notes: Number of patients with different types of complications (percent of surgical method). One patient can have more than one type of complication.

^aOne of the patients needed surgical correction.

^bTen of the patients needed fistula closure.

Table 3 Total HOSE scores for different degrees of hypospadias

Score	If all meatal shape after reconstruction is considered circular		If meatal shape after reconstruction is considered vertical	
	14–16	11–13	14–16	11–13
Degree I (n = 77)	69 (90%)	8 (10%)	75 (97%)	2 (3%)
Degree II (n = 22)	19 (86%)	3 (14%)	20 (90%)	2 (10%)
Degree III (n = 6)	4	2	6	0
Degree IV (n = 3)	1	2	2	1
Total (n = 108)	93 (86%)	15 (14%)	103 (95%)	5 (5%)

Abbreviation: HOSE, Hypospadias Objective Scoring Evaluation.

Notes: HOSE score was only complete for 108 of the 114 included patients; number of patients (percent of the patients with that degree). A score of 14 or more infers an acceptable final result. With the exception of neourethral reconstructions ad modum Scuderi with final location at the tip of the glans, we consider the meatal shape of reconstructed meatuses more circular than normal meatuses. The correlation between meatal shape and spraying and the relevance of achieving a vertical meatus has been questioned; therefore, we have calculated two different HOSE scores taking this into consideration. The percentages have been rounded off to whole numbers, and therefore, the total does not always amount to 100. Percentages were not calculated for groups with $n < 25$.

Four patients with strictures were identified at the concluding clinical visit or clinical visits thereafter. Of the 23 patients, 12 had various aesthetic shortcomings including constricting scar tissue, skin surplus, and epithelial cysts. One had surgical correction due to aesthetical complains. Eight patients complained of spraying, one had surgical correction. Three patients had minor complaints regarding micturition.

Discussion

Hypospadias surgery besets with difficulty and complications. Nonetheless, there a few studies examining long-term results¹³ and when the reconstruction can be considered final. The aims of this study were to evaluate our patients that have been reconstructed for hypospadias and undergone final clinical examination after puberty and to assess how long clinical follow-up time is warranted after hypospadias repair.

The Degree of Hypospadias, Choice of Reconstruction Method, and Complications

Part of the cohort has been described in a previous study, with 39 patients completing the final clinical visit.⁶ In that study, we hypothesized that the degree of hypospadias is the most decisive risk factor for the complication frequency after repair of hypospadias. The hypothesis was confirmed in this study, as there was a statistically significant association between the two factors. Moreover, we did not find any other common denominator for the patients that had complications following their reconstructions. Furthermore, the finding is corroborated by the HOSE score as a higher percentage of the boys with degree I hypospadias have a score that indicates an acceptable final result than boys with degrees II and III hypospadias (–Table 3). Nonetheless, the classification system² as a predictor has its limits, as the classification has to be made after the orthoplasty to take the tightness of chordee and hence the true position of the meatus into consideration. In addition, to make an adequate classification of the malformation, release of preputial synechia between

the preputium and the glans must be performed to uncover possible hidden chordee that might mask the degree of malformation.

Most of the boys that have undergone final clinical examination were reconstructed during a time when hypospadias was normally reconstructed in stages (–Table 1). A two-stage procedure is questionable in many cases of hypospadias, and over the years, we have accordingly adjusted our protocol in the direction of a one-stage procedure such as Matheiu and Scuderi, and this can be seen in the material (–Table 1). Nonetheless, a staged procedure remains an option in more severe cases.

Previous studies have indicated that unpleasant memories of hypospadias repair are rare if the operation occur before the age of 5 and that as long as treatment is completed by school age, the age at time of reconstruction may be less significant to most of the boys.¹⁴ Similarly, Sommerlad¹⁵ concluded that few patients have unpleasant memories from the hospital stay, even though they were reconstructed at an age that is now by many considered too high. Hence, we hypothesize that, from a psychological point of view, a robust reconstruction with few complications is preferable to an early one-stage reconstruction followed by several supplementary operations due to complications and a less favorable final result.¹⁶

Long-Term Result of Reconstruction

According to the HOSE score, the great majority of patients in this study had an excellent result at the final clinical control: 95% if the reconstructed meatal shape is considered vertical and 85% if it is considered circular (–Table 3). In other long-term studies, the number of patients with a HOSE score of 14 and more have ranged from 60% (severe hypospadias)¹⁰ to 97% (distal hypospadias).^{8,11}

As regards to the meatal location, all patients but four had a glanular position (96%). This is in accordance with the findings in other studies.^{8–11} However, the number of patients with a distal glandula meatal location is slightly lower than that in some other reports (52%, 56/108).^{8,11} Nonetheless, in most of those studies, the patients themselves or different

surgeons made the evaluation of meatal location and that might have affected the result. Furthermore, a study on meatal location in 500 healthy men has suggested that only 55% have the meatus truly at the tip of the glans.¹⁷ The patients that did not have their meatus at the tip of the glans were unaware of any penile abnormalities, had normal sexual and reproductive history, and were able to micturate in standing position.¹⁷ Based on this, the authors, Fichtner et al,¹⁷ concluded that there is no need to advance the meatus beyond the corona when it is not easily feasible as it might only impair functional and cosmetic results and increase the risk of complications. Hypospadias surgeons have put similar conclusions forward since the 1970s,^{14,15} especially since the reconstructed meatus sometimes retracts back toward the corona as the boy grows.¹⁴ In this study, none of the patients who did not have an apical meatus at the final clinical visit requested secondary corrections due to the meatal location.

With the exception of neourethral reconstructions ad modum Scuderi with final location at the tip of the glans, we consider the meatal shape of reconstructed meatuses more circular than normal meatuses. We have graded all the reconstructed boys accordingly. In the previous studies, hypospadias surgeons have stated that a vertical slit-like meatus was achieved in the majority of their cases.^{8,9} We question the possibility and the relevance to achieve this. Moreover, Reid et al¹¹ have concluded that there is no correlation between meatal shape and spraying. In the evaluation of the final results, one alternative would thus be to exclude the meatal shape. This is why we calculated two different HOSE scores with patients as having a circular and vertical meatus, respectively (– Table 3).

In the previous long-term follow-up studies, up to 85% of the boys had spraying.^{10,13} In the present study, 10% (11/110) of the boys experienced spraying. Only one patient had a secondary correction due to spraying, which has to be considered an excellent result in the light of previous findings. This further supports that an apical, vertical meatus is not the decisive factor for a good urinary function.

In this study, we noted that 5% of the boys who had a straight penis before puberty developed an incurvation during puberty, despite initial orthoplasty and recognition that excision of chordee is fundamental for successful repair of hypospadias. At operation, all possible chordee was extirpated thoroughly and in the surgical field, an artificial erection test could not add any further information. Follow-up included both subjective and objective evaluation. At 13 years, there were no indications of incurvation in any of our patients. At 16 years, subjective report and clinical sigh indicated the possibility of curvature in a few patients and then we preferred to judge the natural erection rather than to perform an artificial one. Similar findings, with late onset incurvation after puberty, have been reported by Yucel et al,¹⁸ Vanders-teen and Husmann,¹⁹ and Flynn et al.²⁰ Hence, it is manifest that late onset incurvation can occur even though meticulous orthoplasty is performed initially, as has been shown in this study. Byars two-stage procedure is a technique that allows for a thorough extirpation of chordee and evaluation of curvature in the operation field. Hence, a thorough extirpa-

tion of chordee was performed in all cases and the method used could therefore not explain the late incurvation. It is noteworthy that 54% of hypospadias surgeons do not even consider correction of chordee, a primary goal in hypospadias reconstruction.²¹ This may present many of the patients who have not been operated on with adequate chordee excision at the risk of developing pronounced curvature during puberty.

The late prevalence of fistulas, that is fistulas in studies of boys who have passed puberty, has been shown to vary between 11²² and 43%²⁰ in the previous studies. The late postpubertal fistula prevalence in the present study was 2% (2/114) and thus has to be considered very low.

How Long Follow-Up Is Warranted?

An early final clinical control after reconstruction implies that the patients contact the health care system themselves if they have problems later on. However, Bracka¹⁴ demonstrated in study on 213 hypospadias patients between the ages 15 and 24 that 44% had considerable difficulties and requested secondary corrections after they had been included in the study. None of them had approached the health care system spontaneously. In our series, 5% of the patients developed incurvation between the prepubertal and the postpubertal examination. Hence, at the present stage of knowledge, the reconstruction cannot be considered final until the boys have passed puberty. Furthermore, previous studies have indicated that the patients would have actually preferred a long-term follow-up.^{16,23} These factors indicate that a planned routine follow-up program is important. Moreover, it has been demonstrated that up to 74% of the hypospadias patients were aware that something was different with their penises but they did not understand why they had undergone correctional surgery.^{14,15} Therefore, a long-term follow-up is beneficial for psychological and educational purposes as well.

Methodological Issues

The strength of this study is that we have used a standard protocol for prospective evaluation since 1989 and that all patients hence have been offered routine clinical follow-up visits until they have past puberty. In this study, most of the patients were followed for more than 10 years. In other studies, long-term follow-up is sometimes defined as a follow-up of a year.²⁴ Moreover, as we have a standard routine follow-up program there is a low loss to follow-up, which is uncommon in long-term follow-up studies of hypospadias.¹³ In addition, over time our administrative routine for patient follow-up has improved and thus reduced the risk of accidental losses to follow-up. We have scrutinized the records of those patients who were lost for the long-term follow-up. There are no indications that these boys had a more pronounced primary malformation or a more complicated reconstructive process than the others. There is consequently no strong reason to believe that these boys were lost due to a poor result. Another strong point of this study is that the same surgeon has been involved in all operations. There was no difference between the included patients and the patients lost to follow-up regarding frequency of the original malformation or treatment history, thus we have no reason to

believe that the patients lost to follow-up have less good final result than the included patients. Another strong point of the study is that we have tried to objectify our results by using the validated HOSE scoring system.^{7,9,10}

Conclusions

In conclusion, the decisive risk factor for complications following reconstruction is the degree of hypospadias and the presence of chordee. Surgeons should not hesitate to do a robust two-stage reconstruction, including thorough orthoplasty, when indicated. It is paramount that the reconstructed boys are followed according to a planned standardized follow-up protocol until they have passed puberty, as incurvation might develop during puberty and the reconstruction therefore cannot be considered final until after puberty. Furthermore, the long-term clinical follow-up makes it possible to educate the patients about their condition and inform them about their operations when they have become old enough to fully comprehend.

Conflict of Interest

None

References

- Baskin LS, Ebberts MB. Hypospadias: anatomy, etiology, and technique. *J Pediatr Surg* 2006;41(3):463–472
- Hadidi A. Classification of hypospadias. In: Hadidi A, Azmy A, eds. *Hypospadias Surgery: An Illustrated Guide*. Berlin: Springer Verlag; 2004:79–82
- Mathieu P. Traitement en un temps de l'hypospade balanique et juxta-balanique. *Journal de Chirurgie (Paris)* 1932;39:481–484
- Scuderi N, Campus G. A new technique for hypospadias one-stage repair. *Chir Plast* 1983;7:103–109
- Byars LT. A technique for consistently satisfactory repair of hypospadias. *Surg Gynecol Obstet* 1955;100(2):184–190
- Hansson E, Becker M, Aberg M, Svensson H. Analysis of complications after repair of hypospadias. *Scand J Plast Reconstr Surg Hand Surg* 2007;41(3):120–124
- Holland AJ, Smith GH, Ross FI, Cass DT. HOSE: an objective scoring system for evaluating the results of hypospadias surgery. *BJU Int* 2001;88(3):255–258
- Seibold J, Werther M, Alloussi S, et al. Objective long-term evaluation after distal hypospadias repair using the meatal mobilization technique. *Scand J Urol Nephrol* 2010;44(5):298–303
- Jones BC, O'Brien M, Chase J, Southwell BR, Hutson JM. Early hypospadias surgery may lead to a better long-term psychosexual outcome. *J Urol* 2009;182(4, Suppl):1744–1749
- Aulagne MB, Harper L, de Napoli-Cocci S, Bondonny JM, Dobremez E. Long-term outcome of severe hypospadias. *J Pediatr Urol* 2010; 6(5):469–472
- Reid LA, Curnier AP, Stevenson JH. Objective outcome assessment of the modified Bretteville technique. *J Plast Reconstr Aesthet Surg* 2010;63(3):398–403
- Fasching G, Arneitz C, Gritsch-Olipp G. Foreskin reconstruction and preservation of a thin distal urethra: a challenge in tubularized incised plate urethroplasty. *Pediatr Surg Int* 2011;27(7): 755–760
- Rynja SP, de Jong TP, Bosch JL, de Kort LM. Functional, cosmetic and psychosexual results in adult men who underwent hypospadias correction in childhood. *J Pediatr Urol* 2011;7(5):504–515
- Bracka A. A long-term view of hypospadias. *Br J Plast Surg* 1989; 42(3):251–255
- Sommerlad BC. A long-term follow-up of hypospadias patients. *Br J Plast Surg* 1975;28(4):324–330
- Olofsson K, Oldbring J, Becker M, Åberg M, Svensson H. Self-perception after hypospadias repair in young mens' perspective. *Eur J Plast Surg* 2003;26:294–297
- Fichtner J, Filipas D, Mottrie AM, Voges GE, Hohenfellner R. Analysis of meatal location in 500 men: wide variation questions need for meatal advancement in all pediatric anterior hypospadias cases. *J Urol* 1995;154(2 Pt 2):833–834
- Yucel S, Sanli A, Kukul E, Karaguzel G, Melikoglu M, Guntekin E. Midline dorsal plication to repair recurrent chordee at reoperation for hypospadias surgery complication. *J Urol* 2006;175(2): 699–702, discussion 702–703
- Vandersteen DR, Husmann DA. Late onset recurrent penile chordee after successful correction at hypospadias repair. *J Urol* 1998;160(3 Pt 2):1131–1133, discussion 1137
- Flynn JT, Johnston SR, Blandy JP. Late sequelae of hypospadias repair. *Br J Urol* 1980;52(6):555–559
- Bologna RA, Noah TA, Nasrallah PF, McMahon DR. Chordee: varied opinions and treatments as documented in a survey of the American Academy of Pediatrics, Section of Urology. *Urology* 1999;53(3):608–612
- Hoag CC, Gotto GT, Morrison KB, Coleman GU, Macneily AE. Long-term functional outcome and satisfaction of patients with hypospadias repaired in childhood. *Can Urol Assoc J* 2008;2(1): 23–31
- Aho MO, Tammela OK, Somppi EM, Tammela TL. Sexual and social life of men operated in childhood for hypospadias and phimosis. A comparative study. *Eur Urol* 2000;37(1):95–100, discussion 101
- Kass EJ, Chung AK. Glanuloplasty and in situ tubularization of the urethral plate: long-term followup. *J Urol* 2000;164(3 Pt 2): 991–993



ELSEVIER



Failed hypospadias repair: An algorithm for secondary reconstruction using remaining local tissue

Ann Nozohoor Ekmark^{a,d,*}, Henry Svensson^{a,c},
Einar Arnbjörnsson^{b,d}, Emma Hansson^{a,c}

^a Departments of Clinical Sciences in Malmö, Lund University, Lund, Sweden

^b Clinical Sciences Lund, Lund University, Lund, Sweden

^c Departments of Plastic and Reconstructive Surgery, Skåne University Hospital, Sweden

^d Paediatric Surgery, Skåne University Hospital, Lund, Sweden

Received 2 December 2014; accepted 21 June 2015

KEYWORDS

Hypospadias salvage;
Cripple;
Secondary reconstruction;
Re-repair;
Local flap

Summary Salvage hypospadias surgery is performed after failed primary reconstruction. Several treatment strategies have been suggested, all with pros and cons. The aim of this study was to evaluate our treatment algorithm for primary hypospadias repair applied to secondary cases in which a salvage procedure is indicated and, most importantly, local tissue is present. The algorithm was applied to 36 consecutive patients who had undergone a total of 109 surgical procedures before referral. In accordance with the algorithm, 12 patients without ventral curvature achieved a satisfactory result with one procedure by the use of local skin flaps. Six patients with moderate ventral curvature underwent orthoplasty, fistula closure, and/or urethral reconstruction using local skin flaps in one session. Eighteen patients with a severe ventral curvature or a proximal meatus were reconstructed in two stages using Byars' technique. After a median of two salvage procedures (range: 1–4), all patients but one, who awaits splitting of a skin bridge in the meatus, were successfully reconstructed. Two patients in active follow-up have potential problems requiring further surgery.

Our findings indicate that failed hypospadias repairs are often due to an underestimation of the ventral curvature at the initial repair. Therefore, reevaluation of the degree of curvature is important. One-stage salvage repairs can be used, provided that none or minimal curvature remains. In cases of marked curvature, however, a meticulous resection of the chordee and

* Corresponding author. Department of Paediatric Surgery, Skåne University Hospital, SE-221 85 Lund, Sweden.
E-mail address: Ann.Nozohoor_Ekmark@med.lu.se (A. Nozohoor Ekmark).

ventral scarring is crucial. The subsequent repair of the large ventral defect and the long urethral reconstruction can, in most cases, be safely managed in a two-stage procedure.

© 2015 British Association of Plastic, Reconstructive and Aesthetic Surgeons. Published by Elsevier Ltd. All rights reserved.

Introduction

The goals of the primary surgical treatment of hypospadias are a straight penis with a functional urethra, without fistulas or strictures, and a cosmetically acceptable appearance. To achieve these goals, we used and evaluated a previously described treatment algorithm for primary reconstructions.^{1–3} For proximal hypospadias, and hypospadias with a significant ventral curvature, the two-stage procedure proposed by Byars⁴ has been used. More distal hypospadias with a slight ventral curvature has been corrected using the Scuderi technique.⁵ For the most distal hypospadias with little or no ventral curvature, we have used the local Mathieu flap⁶ with redistribution of the prepuce. In recent years, the tubularized incised plate urethroplasty (TIP procedure) has also been introduced in our unit.⁷

Secondary or salvage hypospadias repair is challenging due to scarring, shortage of tissue, obliterated tissue planes, and compromised blood supply. Therefore, compared with primary reconstruction, the healing capacity may be reduced. Moreover, in some cases, repeat hypospadias surgery can result in deformities that are even worse than the original malformation.⁸ Various treatment strategies for re-repairs have been proposed.^{8–18} However, the optimal management of these patients remains unclear. Thus, in 2007, we decided to apply our previously described algorithm^{1–3} to the increasing number of patients referred to us for secondary repair caused by a failed reconstruction. All referred patients had adequate local tissue to be reconstructed, and the aim of this study was to evaluate the efficacy of our algorithm for these cases. This algorithm does not cover those without sufficient local tissue. For such cases, we opted for other previously described treatment options.^{8–10,13,14,19}

Patients and methods

Patients and preoperative evaluation

From April 2007 through April 2014, 36 boys born between 1980 and 2008 were referred to our unit for re-repair due to previously failed hypospadias reconstructions. At the first outpatient visit, the clinical presentation was evaluated according to a standard protocol with particular focus on the presence of a ventral curvature. Medical records from the referring hospitals revealed that the patients had undergone 109 prior hypospadias-related surgical procedures (median: 3; range: 1–8), including isolated preputial plasty (six patients; 12 procedures). In addition to these procedures, meatotomies had been performed in eight cases.

In three cases, a conclusive preoperative evaluation could not be achieved during the outpatient visit. Therefore, the evaluation was supplemented with an examination under general anesthesia. The preoperative evaluation revealed that 21 patients (58%) had a remaining ventral curvature; 28 (78%) had fistulas, of which one involved the prepuce only; 13 had meatal dystopia (36%); and 24 (67%) had an unfavorable aesthetic result. All boys had adequate local tissues to allow secondary repair in accordance with our algorithm. Surgical procedures were conducted from October 2007 through November 2014.

Treatment algorithm

Based on the preoperative outpatient evaluation, the patients were allocated to one of the following three treatment options (Figure 1):

1. Patients without a ventral curvature, but who needed fistula closure or supplementary urethral reconstruction, underwent a one-stage reconstruction. Fistulas were closed according to the general principles described subsequently. Local flaps were used for distal urethral reconstruction. Either local flaps or preputial flaps covered any ensuing ventral defect after urethral reconstruction or fistula closure.
2. In patients with a moderate ventral curvature, and who did not need fistula closure or supplementary distal reconstruction, an orthoplasty was incorporated into the procedure. Thus, all remaining chordee and other constricting tissues were excised before the fistulas were closed and/or the urethra was lengthened. This created a wide ventral defect that was closed by preputial flaps.
3. For patients with completely failed reconstructions and remaining prominent ventral curvature, the treatment was a two-stage reconstruction according to a modified Byars' technique.⁴ During the first stage, a thorough orthoplasty with excision of all remaining chordee and other constricting tissues was performed, and the dorsal prepuce was divided and moved ventrally to cover the defect. Six months later, the urethral reconstruction was performed by making a U-shaped incision encompassing the meatus and terminating on either side of the glans. The developed flap constituted the inner lining around the catheter, and the preputial flaps constituted the outer lining.

General surgical principles

Urethral defects were closed with mucosal inverted sutures using 6/0 Vicryl™ (polyglactin 910; Ethicon, Johnson & Johnson, Medical Limited, Norderstedt, Germany). In addition, a layer of soft tissue from the venterolateral

Please cite this article in press as: Nozohoor Ekmark A, et al., Failed hypospadias repair: An algorithm for secondary reconstruction using remaining local tissue, *Journal of Plastic, Reconstructive & Aesthetic Surgery* (2015), <http://dx.doi.org/10.1016/j.bjps.2015.06.024>

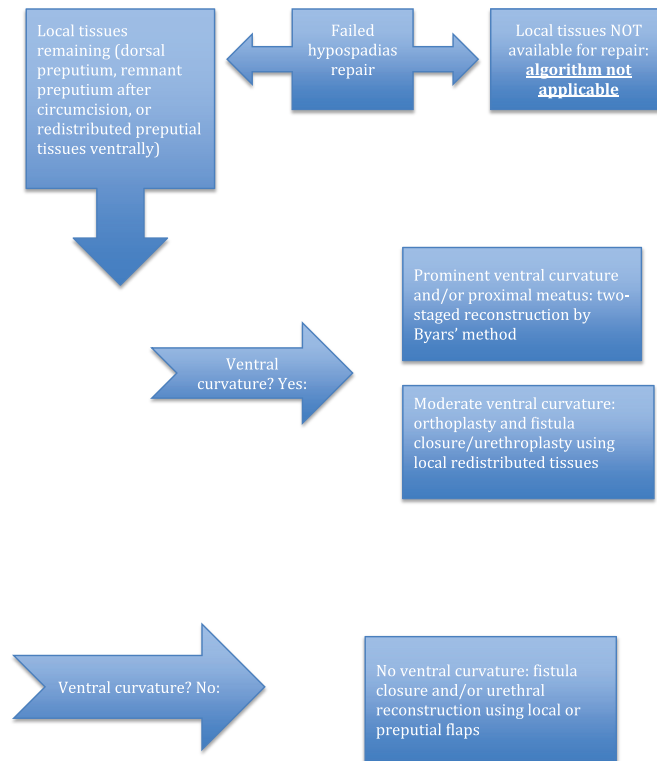


Figure 1 Treatment algorithm for redo hypospadias reconstructions with remaining local tissues.

fascia was interfaced between the inner and outer linings for "waterproofing."²⁰ Foley urethral catheters (Chapter 8 or 10) were used for urine diversion and neo-urethral molding. In cases requiring a long urethral reconstruction, a suprapubic catheter was used in addition to the urethral catheter. The urethral catheters were retained for 5–7 days, depending on the nature of the reconstruction. In cases with a suprapubic catheter, this was removed when normal micturition through the urethra had been established, usually 1 day after removal of the urethral catheter. The patients remained in hospital while the catheters were in place. For urethral reconstructions and fistula closures, antibiotics with sulfamethoxazole and trimethoprim (Eusaprim™; Vitaflo Scandinavia, Gothenburg, Sweden) were administered until the catheters were removed.

Postoperative evaluation

The patients had their first postoperative visit 3 weeks after the procedure. When staged surgery was planned, the boys were evaluated 2–3 months before the next procedure to ensure optimal conditions for the operation. Prepubertal children were then included in the previously described

standard follow-up protocol,¹ with follow-up visits before and after puberty. To more precisely objectify the post-pubertal functional and aesthetic results, the Hypospadias Objective Scoring Evaluation (HOSE)²¹ was used at the final postpubertal clinical examination, as previously described.¹

Statistics

Values are given as medians and ranges.

Ethics

Permission to create a patient register was obtained in accordance with the Swedish Privacy Protection Law. The procedures followed were in accordance with the revised Helsinki Declaration of 1964 and the Good Clinical Practice (GCP) guidelines.

Results

Demographics, surgical procedures, and complications of the 36 patients are presented in Tables 1–3. Eight patients

Table 1 Demographics and surgical procedures for patients without ventral curvature requiring fistula closure and/or distal urethral reconstruction.

Patient	Age ^a	Previous surgery ^b	Problems ^c	Salvage surgery procedures	Number of surgical procedures ^d	Complications/shortcoming	Follow-up (months) ^e
1	6	MAVIS Fistula closure ×2	F	Fistula closure with ventral coverage from preputial flaps	3/1/4		1
2	6	Preputial plasty	F	Distal orthoplasty with division of chordee, ventral coverage with preputial flaps.	1/1/2		0
3	6	Duckett, Reoperation due to immediate complications ×2 Fistula closure	F, DM	Fistula closure using scrotal skin flap.	4/1/5	Due to despair after repeated surgical failures, this patient opted only for a fistula closure. His dystopic meatus may be corrected on his future request.	1
4	5	TIP, Fistula closure, MAVIS, Fistula closure	F	Fistula closure with ventral coverage using preputial flaps	4/1/5		51
5	6	MAVIS	F, RDR	Distal urethral reconstruction using Mathieu skin flap. Ventral coverage using preputial flaps.	1/1/2		42
6	7	Byars 1, Byars 2, Fistula closure	F, RPR	Planned reconstruction in two stages: 1. Proximal urethral reconstruction using local Ombredanne skin flap and scrotal skin flap for ventral coverage. 2. Fistula closure connecting the proximal and distal urethral reconstruction.	3/2/5		27
7	6	MAVIS, Fistula closure ×2	F	Fistula closure using preputial flaps for ventral coverage.	3/1/4		77
8	13	Duckett, Fistula closure ×3	F	Fistula closure with waterproofing using local dartos flap.	4/1/5	Manifestation of minor proximal fistula after distal fistula closure. Declined additional surgery at postpubertal follow-up.	33
9	15	MAVIS, Fistula closure	F	Fistula closure with preputial flaps for ventral coverage.	2/1/3		6
10	14	MAVIS, Circumcision, Fistula closure ×2	F	Fistula closure with waterproofing using local dartos flap.	4/1/5		0
11	14	Duckett	F	Fistula closure with waterproofing using local dartos flap.	1/1/2		20
12	30	Dennis Brown, Plasty NUD, Mathieu, Dorsal incision due to parafimosis	F	Fistula closure with waterproofing using local dartos flap.	4/1/5		0

Please cite this article in press as: Nozohoor Ekmark A, et al., Failed hypospadias repair: An algorithm for secondary reconstruction using remaining local tissue, *Journal of Plastic, Reconstructive & Aesthetic Surgery* (2015), <http://dx.doi.org/10.1016/j.bjps.2015.06.024>

Table 1 (continued)

Patient Age ^a	Previous surgery ^b	Problems ^c	Salvage surgery procedures	Number of surgical procedures ^d	Complications/shortcoming	Follow-up (months) ^e
Median age (years): 6.5 (5–30)		Sum surgical procedures: 34/13/47		Median follow-up (months): 13 (0–77)		

^a Age (years) at first salvage procedure.

^b Previous surgery as interpreted from patient charts or ICD codes. Brown, D. An operation for hypospadias. Proceedings of the Royal Society of Medicine 1949; 42(7):466–8. Duckett JW. Transverse preputial island flap technique for repair of severe hypospadias. Urol Clin North Am. 1980 Jun; 7(2):423–30. Duckett JW. The island flap technique for hypospadias repair. Urol Clin North Am. 1981 Oct; 8(3):503–11. Boddy SA, Samuel M. Mathieu and 'V' incision sutured (MAVIS) results in a natural glanular meatus. J Pediatr Surg. 2000 Mar; 35(3):494–6. Snodgrass W. Tubularized, incised plate urethroplasty for distal hypospadias. J Urol 1994; 151:464–5. Boddy SA, Samuel M. Mathieu and 'V' incision sutured (MAVIS) results in a natural glanular meatus. J Pediatr Surg 2000; 35(3):494–6. Mathieu P. [Traitement en un temps de l'hypospadias balanique et juxta balanique. J Chir (Paris) 1932; 39:481–4. In French.

^c Main problem requiring salvage surgical correction: PF: preputial fistula, F: one or more fistulas, RDR: Ruptured distal urethral reconstruction, RPR: Ruptured proximal urethral reconstruction, DM: Dystopic meatus.

^d Number of surgical procedures: number of surgical procedures before referral excluding meotomy in infancy and examination during anesthesia/number of salvage procedures excluding examination during anesthesia/total number of surgical procedures.

^e Time (months) between last major salvage surgery and last outpatient checkup.

underwent additional surgery beyond the treatment algorithm. Two required meatotomies (patients 20 and 29) and three required fistula closures (patients 21, 23, and 36). Patient 36 developed a serious wound infection as well as a large penoscrotal fistula. When this was closed, a proximal fistula became evident, and it was subsequently closed. Patient 36 also awaits a minor correction of a distal skin bridge in the meatus that is splitting the urinary stream. The other three patients underwent additional surgery to improve cosmetic appearance: splitting a meatal skin bridge (patient 16) and correcting surplus skin (patients 18 and 32).

Of the patients who remain in our follow-up program, one has a ventral curvature (patient 15), and one has a penile meatus (patient 3). Both might require additional surgery. In the first case, maturation of the scar and the pubertal growth are awaited before any additional surgery will be attempted. In the second case, the patient opted for a fistula closure but no distal urethral reconstruction, due to fatigue after previous repeated surgical failures. Ten patients have completed postpubertal follow-up, or they underwent treatment after puberty, and the vast majority have a HOSE score of 14 or above (Table 4). Among the patients scoring lower, one had complaints related to the original urethral reconstruction because he suffered from a hairy urethra (patient 16). He also complained of slight penile deviation, scarring, and a split appearance of the glans. Another patient expressed overall dissatisfaction, possibly due to a small phallus and repeated hypospadias surgeries: four previous attempts and one salvage procedure in our department (patient 17). Patient 8 had a slight ventral curvature during erection and a minor proximal fistula that became evident after the closure of a large distal fistula during salvage surgery. At the postpubertal clinical visit, he declined additional surgical correction regarding the minimal fistula. One patient presented at the postpubertal visit with a slight ventral curvature, without functional implications (patient 33).

Discussion

The optimal management of patients requiring secondary or salvage procedures remains unclear. In this study, we investigated whether an algorithm using remaining local tissues can be used to attain adequate reconstructive results and few postoperative complications.

Like others, we are of the opinion that pre-salvage analysis is fundamental in choosing the technique, thereby attaining a successful salvage repair.¹¹ Previous research has also shown that the hypospadias surgeon's intellectual interest in the malformation is one of the most important factors for a successful outcome.²² The use of a careful and structured protocol at the outpatient preoperative clinical visit is essential as well. Distal obstruction and other underlying factors that carry the risk of fistula formation²³ should be ruled out. Particular attention should be paid to the presence of a ventral curvature, because reconstruction can hardly be successful without a complete and meticulous orthoplasty.^{1,18,22} In addition, the possible outcomes of the procedure must be clearly communicated to the patients and the parents; the explanation must present a realistic view of the problem and its possible surgical solution.¹⁵

In this study, >50% of the included patients had a remaining ventral curvature. This could indicate that the degree of curvature might have been underestimated during the initial surgical reconstruction attempts, perhaps, leading to an incorrect choice of reconstructive method. Consequently, the boys were possibly reconstructed with methods focused primarily on distal urethral lengthening rather than on the release of all fibrous tissues. Most patients had to undergo the excision of the remaining chordee in order to achieve a straight penis. This supports the premise that the chordee is an essential factor to address, even in boys with distal hypospadias. Therefore, in our algorithm, we emphasize that the ventral curvature is one of the key factors to consider when scheduling a patient for salvage treatment.

Please cite this article in press as: Nozohoor Ekmark A, et al., Failed hypospadias repair: An algorithm for secondary reconstruction using remaining local tissue, Journal of Plastic, Reconstructive & Aesthetic Surgery (2015), <http://dx.doi.org/10.1016/j.bjps.2015.06.024>

Table 2 Demographics, previous surgery, and salvage surgery for patients with moderate ventral incurvation requiring fistula closure/urethral reconstruction: single session orthoplasty with fistula closure/urethral reconstruction using local or preputial flaps.

Patient	Age ^a	Previous surgery ^b	Problems ^c	Salvage surgery	Number of surgical procedures ^d	Complications shortcoming	Follow-up (months) ^e
13	5	Duckett, Reoperation for immediate complication	VC, F	Division of chordee, creation of neo-urethra (fistula closure), and redistribution of ventral skin.	2/1/3		48
14	7	Division of web, MAVIS, Circumcision, Fistula closure	VC, F	Division of chordee, fistula closure, and redistribution of remnants of prepuce for ventral coverage.	4/1/5		30
15	6	Duckett, Fistula closure, Meatotomy, MAVIS ×2	VC	Division of chordee and deep scar tissue and skin closure with z-plasty.	5/1/6	Remaining ventral curvature, patients in active follow-up.	40
16	11	MAVIS, Preputial plasty ×4, Fistula closure ×2, TIP + preputial plasty	VC, F	1. Division of ventral scar tissues, fistula closure, coverage of ventral defect through preputial flaps. 2. Splitting of skin bridge across meatus.	8/2/10	Hairy meatus and bifid glans originating from the primary reconstructions. No re-intervention planned to date.	47
17	17	Duckett, Fistula closure ×2, MAVIS	VC, DM	Division of chordee and scar tissue, distally based flap for distal urethral reconstruction. Outer lining adjustment with waterproofing.	4/1/5	Short phallus and general dissatisfaction. No further intervention planned.	10
18	19	MAVIS Preputial plasty ×3	VC, F	1. Division of chordee and scar tissue, fistula closure, ventral coverage through preputial flaps. 2. Correction of ventral skin surplus.	4/2/6		6
Median age (years): 9 (5–19)				Total surgical procedures: 27/8/35		Median follow-up (months): 35 (6–48)	

^a Age (years) at first salvage procedure.

^b Previous surgery as interpreted from patient charts or ICD codes. Duckett JW. Transverse preputial island flap technique for repair of severe hypospadias. *Urol Clin North Am.* 1980 Jun; 7(2):423–30. Duckett JW. The island flap technique for hypospadias repair. *Urol Clin North Am.* 1981 Oct; 8(3):503–11. Boddy SA, Samuel M. Mathieu and 'V' incision sutured (MAVIS) results in a natural glanular meatus. *J Pediatr Surg.* 2000 Mar; 35(3):494–6. Snodgrass W. Tubularized, incised plate urethroplasty for distal hypospadias. *J Urol.* 1994; 151:464–5.

^c Major problem needing salvage surgical correction. VC: Ventral curvature. F: One or more fistulas. DM: Dystopic meatus.

^d Number of surgical procedures: number of surgical procedures before referral excluding meatotomy in infancy and examination during anesthesia/number of salvage procedures excluding examination during anesthesia/total number of surgical procedures.

^e Time (months) between last major salvage surgery and last outpatient checkup.

A number of general surgical principles have been reported to influence the outcome of hypospadias re-repairs. The most important include surgical delay,¹⁵ "waterproofing,"²⁰ postoperative urinary diversion,^{19,24} and staging of the repair.^{11,13}

Surgical delay, which entails adequate time between surgical procedures for tissue healing, softening, and neovascularization, is required for successful secondary procedures.¹⁵ In this context, we allowed a minimum of 6 months to pass between sequential procedures, and all patients were reevaluated in the outpatient unit between planned procedures in order to ensure that adequate

healing and revascularization had occurred. In uncertain cases, further procedures were postponed until optimal conditions were present.

"Waterproofing" is a method to reduce the risk of fistula formation by creating a barrier tissue layer between the neo-urethra and the penile skin in order to avoid direct overlying suture lines.^{19,20,24–26} Several options are available for "waterproofing."^{25,26} In our patients, we opted for an advancement of flaps of dartos fascia obtained from the lateral aspects of the penis or preputial flaps. In addition, care was taken to orient the flaps such that the occurrence of overlying suture lines was reduced further.

Please cite this article in press as: Nozohoor Ekmark A, et al., Failed hypospadias repair: An algorithm for secondary reconstruction using remaining local tissue, *Journal of Plastic, Reconstructive & Aesthetic Surgery* (2015), <http://dx.doi.org/10.1016/j.jbjs.2015.06.024>

Table 3 Demographics and Previous Surgery and Salvage Surgery for Patients with Prominent Ventral Incurvation or Proximal Meatus Requiring a Complete Urethral Reconstruction through Orthoplasty and Urethral Reconstruction in Two Stages.

Patient	Age ^a	Previous surgery ^b	Problems ^c	Salvage surgery	Number of surgical procedures ^d	Complications/shortcoming	Follow-up (months) ^e
19	4	TIP	VC	Byars 1 Byars 2	1/2/3		3
20	4	MAVIS	VC	Byars 1 Meatotomy Byars 2	1/3/4		1
21	6	Orthoplasty with buccal mucosa, TIP	VC, F	Byars 1 Byars 2 Fistula closure with scrotal flap	2/3/5	Fistula after Byars 2 with successful repair.	1
22	7	MAVIS	VC	Byars 1 Byars 2	1/2/3		1
23	5	Byar 1, Byar 2, Preputial plasty	VC, F	Byars 1 Byars 2 Fistula closure with local flap and dartos coverage.	3/3/6	Fistula after Byars 2 with successful repair.	1
24	5	MAVIS, Fistula closure	VC, F	Byars 1 Byars 2	2/2/4		13
25	6	MAVIS, Fistula closure ×2	VC, F	Byars 1 Byars 2	3/2/5	Bifid glans due to partial rupture. No further intervention planned to date.	8
26	7	MAGPI Snodgrass	VC, F	Byars 1 Byars 2	2/2/4		1
27	7	Byar 1, Byar 2	VC, F	Byars 1 Byars 2	2/2/4		7
28	8	MAVIS ×2, Fistula closure, Urethral reconstruction NUD	VC, F	Byars 1 Byars 2	4/2/6		11
29	7	TIP	VC, F	Byars 1 Meatotomy ×2 Byars 2	1/4/5		31
30	9	TIP, Fistula closure ×3	VC, F	Byars 1 Byars 2	4/2/6		0
31	11	Division web Nesbit ×3	VC, R	Byars 1 Byars 2	4/2/6		5
32	16	MAVIS, Preputial plasty, Flistula closure ×3	VC, F	Byars 1 Byars 2 Correction av skin surplus	5/3/8		14
33	18	MAVIS Fistula closure ×2 Preputial plasty ×2	VC, F	Byars 1 Byars 2	5/2/7	Slight ventral curvature without need for intervention.	3
34	5	Duckett Reoperation for immediate compication ×2	F, DM	Byars 1 Byars 2	3/2/5		12
35	5	MAVIS, Fistula closure	F	Byars 1 Byars 2	2/2/4		13

(continued on next page)

Please cite this article in press as: Nozohoor Ekmark A, et al., Failed hypospadias repair: An algorithm for secondary reconstruction using remaining local tissue, Journal of Plastic, Reconstructive & Aesthetic Surgery (2015), <http://dx.doi.org/10.1016/j.bjps.2015.06.024>

Table 3 (continued)

Patient	Age ^a	Previous surgery ^b	Problems ^c	Salvage surgery	Number of surgical procedures ^d	Complications/shortcoming	Follow-up (months) ^e
36	7	Byar 1, Byar 2, Meatotomy	DM	Byars 1 Byars 2 Fistula closure with scrotal flap Fistula closure with local flap with dartos coverage.	3/4/7	Purulent infection after Byars 2 with ensuing large proximal fistula. Distal fistula manifested itself after closure of the proximal one. Both successfully closed. Awaits splitting of distal skin bridge in the meatus.	1
Median age (years): 7 (4–18)				Sum surgical procedures: 48/ 44/92		Median follow-up (months): 4 (0–31)	

^a Age (years) at first salvage procedure.

^b Previous surgery as interpreted from patient charts or ICD codes: Duckett JW. Transverse preputial island flap technique for repair of severe hypospadias. *Urol Clin North Am.* 1980 Jun; 7(2):423–30. Duckett JW. The island flap technique for hypospadias repair. *Urol Clin North Am.* 1981 Oct; 8(3):503–11. Boddy SA, Samuel M. Mathieu and 'V' incision sutured (MAVIS) results in a natural glanular meatus. *J Pediatr Surg.* 2000 Mar; 35(3):494–6. Snodgrass W. Tubularized, incised plate urethroplasty for distal hypospadias. *J Urol.* 1994; 151:464–5. Boddy SA, Samuel M (2000): Mathieu and 'V' incision sutured (MAVIS) results in a natural glanular meatus. *J Pediatr Surg.* Mar; 35(3):494–6. Snodgrass W. Tubularized, incised plate urethroplasty for distal hypospadias. *J Urol.* 1994; 151:464–5. Nesbit RM. Plastic procedure for correction of hypospadias. *J Urol* 1941; 45:699–701. Byars LT. Surgical repair of hypospadias. *Surg Clin North Am* 1950; 30:1371–5.

^c Main problem needing salvage surgical correction: F: one or more fistulas. VC: Ventral curvature. DM: Dystopic meatus. R: Rotation.

^d Number of surgical procedures: number of surgical procedures before referral excluding meatotomy in infancy and examination during anesthesia/number of salvage procedures excluding examination during anesthesia/total number of surgical procedures.

^e Time (months) between last major salvage surgery and last outpatient checkup.

Postoperative urinary diversion has also been shown to be a consistently critical factor in reducing the complication rate.^{19,24} However, successful simple fistula repair without urinary diversion has been reported.²⁷ This and other studies²⁸ have emphasized that urinary diversion may

be beneficial in complex repairs such as salvage repairs because back pressure, turbulence, increased shear stress due to narrowing, skin bridges, and crests might increase fistula formation. In this series of patients, all had a urethral catheter in place for 5–7 days, supplemented by a suprapubic catheter in the more advanced cases.

With regard to staging, two-stage repairs have been demonstrated to be more reliable than one-stage repairs in some cases of salvage hypospadias surgery.^{11,13} This is especially true in cases of a pronounced ventral curvature and scarred skin.¹³ Indeed, patients in need of salvage repairs have usually undergone a large number of operations; in our series, they ranged from one to eight (Tables 1–3). The 36 patients underwent a total of 109 prior surgical procedures, and they required an additional 65 procedures (range: 1–4) to achieve the initial goal. Thus, overall, the patients were subjected to a median of five surgeries (two to 10 procedures) to achieve an adequate reconstructive result. Our algorithm considers that it appears often preferable to offer a safe two-stage option in salvage cases rather than attempting a single-stage procedure, which might result in complications and further surgical procedures. This strategy is in accordance with the notion that a liberal approach to staged salvage repair is justified in cases of an obvious residual curvature.^{11,18} However, it has been shown that salvage hypospadias repair in one stage can be successful in some cases,⁸ and some surgeons argue that single-stage repair should always be performed to minimize the number of procedures the child must undergo.²⁹ Our findings are in accordance with the premise that some cases with modest or no ventral curvature can be successfully repaired with a one-stage procedure, whereas

Table 4 HOSE scores.^a

	Total (n = 10)
Meatal location	
Proximal glandulär (3)	8
Distal glandulär (4)	2
Meatal shape	
Circular (1)	10
Urinary stream	
Single (2)	7
Missing data	3
Mild angulation <10° (3)	2
Straight (4)	8
Fistula	
None (4)	9
Single, proximal (2)	1
Total HOSE score (5–16)	
13	1
14	5 ¹
15	1 ¹ ≥14: 86%
Missing data	3 ^b

^a For patients completed postpubertal follow-up.

^b Total score excluding missing variable: 9, 12, and 13, respectively. 1. Holland AJ, Smith GH, Ross FI, Cass DT. HOSE: an objective scoring system for evaluating the results of hypospadias surgery. *BJU Int* 2001; 88: 255–8.

Please cite this article in press as: Nozohoor Ekmark A, et al., Failed hypospadias repair: An algorithm for secondary reconstruction using remaining local tissue, *Journal of Plastic, Reconstructive & Aesthetic Surgery* (2015), <http://dx.doi.org/10.1016/j.bjps.2015.06.024>

staged procedures are needed in cases of a pronounced ventral curvature.

One advantage of this study is that we were able to retrieve information regarding all previous procedures that the patients had undergone. Moreover, no patients were lost to follow-up, and all patients have been or will be followed up past puberty to ensure long-term success. The fact that all procedures were conducted by a single surgeon at one institution should be regarded as a strength, but it also carries a risk of bias at the postoperative clinical evaluation. The treatment algorithm is a summary of standard methods, and it is not designed to include all complexities of this heterogeneous group of salvage hypospadias patients. Instead, we emphasize that it is important in patients with prior failed treatments but with local penile skin still available. For patients in whom native penile skin flaps cannot be used, other measures have to be taken, such as graft procedures.^{9,13,30–32}

Conclusions

Our findings indicate that hypospadias repairs often fail because the ventral curvature is underestimated at the initial repair. Therefore, the reevaluation of the degree of curvature is important. One-stage salvage repairs can be used, provided that minimal or no curvature remains. In cases of a marked curvature, a meticulous resection of the chordee and ventral scarring is crucial. The subsequent repair of the large ventral defect and the long urethral reconstruction can, in most cases, be safely managed in a two-stage procedure.

Conflicts of interest

None.

Funding

None.

Ethical approval

Permission to create a patient register was obtained in accordance with the Swedish Privacy Protection Law. The procedures followed were in accordance with the revised Helsinki Declaration of 1964 and the Good Clinical Practice (GCP) guidelines.

References

- Ekmark AN, Svensson H, Arnbjornsson E, Hansson E. Post-pubertal examination after hypospadias repair is necessary to evaluate the success of the primary reconstruction. *Eur J Pediatr Surg* 2013;23:304–11.
- Hansson E, Becker M, Aberg M, Svensson H. Analysis of complications after repair of hypospadias. *Scand J Plast Reconstr Surg Hand Surg* 2007;41:120–4.
- Svensson H, Reyman M, Troeng T, Aberg M. Staged reconstruction of hypospadias with chordee: outcome and costs. *Scand J Plast Reconstr Surg Hand Surg* 1997;31:51–5.
- Byars LT. A technique for consistently satisfactory repair of hypospadias. *Surg Gynecol Obstet* 1955;100:184–90.
- Scuderi N, Campus G. A new technique for hypospadias one-stage repair. *Chir Plast* 1983;7:103–9.
- Mathieu P. Traitement en un temps de l'hypospadias balanique et juxta-balanique. *J Chir Paris* 1932;39:481–4.
- Snodgrass W. Tubularized, incised plate urethroplasty for distal hypospadias. *J Urol* 1994;151:464–5.
- Perovic S, Barbagli G, Djinoic R, et al. Surgical challenge in patients who underwent failed hypospadias repair: is it time to change? *Urol Int* 2010;85:427–35.
- Bracka A. The role of two-stage repair in modern hypospadiology. *Indian J Urol* 2008;24:210–8.
- Bracka AA. versatile two-stage hypospadias repair. *Br J Plastic Surg* 1995;48:345–52.
- van der Werff JF, van der Meulen Jacques C. Treatment modalities for hypospadias cripples. *Plastic Reconstr Surg* 2000;105:600–8.
- Patel RP, Shukla AR, Leone NT, Carr MC, Canning DA. Split onlay skin flap for the salvage hypospadias repair. *J Urol* 2005;173:1718–20.
- Gill NA, Hameed A. Management of hypospadias cripples with two-staged Bracka's technique. *J Plast Reconstr Aesthet Surg* 2011;64:91–6.
- Snodgrass WT, Granberg C, Bush NC. Algorithm for comprehensive approach to hypospadias reoperation using 3 techniques. *J Urol* 2009;182:2885–91.
- Jayanthi VR, McLorie GA, Khoury AE, Churchill BM. Can previously relocated penile skin be successfully used for salvage hypospadias repair? *J Urol* 1994;152:740–3.
- Elicevik M, Tireli G, Demirali O, Unal M, Sander S. Tubularized incised plate urethroplasty for hypospadias reoperations in 100 patients. *Int Urol Nephrol* 2007;39:823–7.
- Bar-Yosef Y, Binyamini J, Matzkin H, Ben-Chaim J. Salvage mathieu urethroplasty: reuse of local tissue in failed hypospadias repair. *Urology* 2005;65:1212–5.
- Devine Jr CJ, Franz JP, Horton CE. Evaluation and treatment of patients with failed hypospadias repair. *J Urol* 1978;119:223–6.
- Cimador M, Vallasciani S, Manzoni G, et al. Failed hypospadias in paediatric patients. *Nat Rev Urol* 2013;10:657–66.
- Cimador M, Pensabene M, Sergio M, Catalano P, de Grazia E. Coverage of urethroplasty in pediatric hypospadias: randomized comparison between different flaps. *Int J Urol* 2013;20:1000–5.
- Holland AJ, Smith GH, Ross FI, Cass DT. HOSE: an objective scoring system for evaluating the results of hypospadias surgery. *BJU Int* 2001;88:255–8.
- Snodgrass W, Macedo A, Hoebcke P, Mouriquand PD. Hypospadias dilemmas: a round table. *J Pediatr Urol* 2011;7:145–57.
- Richter F, Pinto PA, Stock JA, Hanna MK. Management of recurrent urethral fistulas after hypospadias repair. *Urology* 2003;61:448–51.
- Braga LH, Lorenzo AJ, Suoub M, Bagli DJ. Is statistical significance sufficient? Importance of interaction and confounding in hypospadias analysis. *J Urol* 2010;184:2510–5.
- Khan U, Zic R, Boorman J. Waterproofing in hypospadias: a refinement of the two-stage reconstruction. *Br J Plast Surg* 2001;54:528–31.
- Telfer JR, Quaba AA, Kwai Ben I, Peddi NC. An investigation into the role of waterproofing in a two-stage hypospadias repair. *Br J Plast Surg* 1998;51:542–6.
- Waterman BJ, Renschler T, Cartwright PC, Snow BW, DeVries CR. Variables in successful repair of urethrocutaneous fistula after hypospadias surgery. *J Urol* 2002;168:726–30. discussion 29–30.

Please cite this article in press as: Nozohoor Ekmark A, et al., Failed hypospadias repair: An algorithm for secondary reconstruction using remaining local tissue, *Journal of Plastic, Reconstructive & Aesthetic Surgery* (2015), <http://dx.doi.org/10.1016/j.bjps.2015.06.024>

28. Townsend PL. Silicone rubber casts of the distal urethra in studying fistula formation and other hypospadias problems. *Br J Plast Surg* 1975;**28**:320–3.
29. Barbagli G, Perovic S, Djinovic R, Sansalone S, Lazzeri M. Retrospective descriptive analysis of 1,176 patients with failed hypospadias repair. *J Urol* 2010;**183**:207–11.
30. Bracka A. Hypospadias repair: the two-stage alternative. *Br J Urol* 1995;**76**(Suppl. 3):31–41.
31. Leslie B, Lorenzo AJ, Figueroa V, et al. Critical outcome analysis of staged buccal mucosa graft urethroplasty for prior failed hypospadias repair in children. *J Urol* 2011;**185**:1077–82.
32. Safwat AS, Elderwy A, Hammouda HM. Which type of urethroplasty in failed hypospadias repair? An 8-year follow up. *J Pediatr Urol* 2013;**9**:1150–4.

Please cite this article in press as: Nozohoor Ekmark A, et al., Failed hypospadias repair: An algorithm for secondary reconstruction using remaining local tissue, *Journal of Plastic, Reconstructive & Aesthetic Surgery* (2015), <http://dx.doi.org/10.1016/j.bjps.2015.06.024>

Paper III



Journal of Plastic Surgery and Hand Surgery



ISSN: 2000-656X (Print) 2000-6764 (Online) Journal homepage: <http://www.tandfonline.com/loi/jphs20>


Patient-reported long-term outcome after primary hypospadias repair

Ann Nozohoor Ekmark, Einar Arnbjörnsson, Henry Svensson & Emma Hansson

To cite this article: Ann Nozohoor Ekmark, Einar Arnbjörnsson, Henry Svensson & Emma Hansson (2016): Patient-reported long-term outcome after primary hypospadias repair, Journal of Plastic Surgery and Hand Surgery, DOI: [10.1080/2000656X.2016.1212713](https://doi.org/10.1080/2000656X.2016.1212713)


To link to this article: <http://dx.doi.org/10.1080/2000656X.2016.1212713>

 View supplementary material [↗](#)

 Published online: 09 Aug 2016.

 Submit your article to this journal [↗](#)

 Article views: 21

 View related articles [↗](#)

 View Crossmark data [↗](#)

Full Terms & Conditions of access and use can be found at
<http://www.tandfonline.com/action/journalInformation?journalCode=jphs20>

Download by: [Lund University Libraries]

Date: 05 November 2016, At: 17:01



ORIGINAL ARTICLE

Patient-reported long-term outcome after primary hypospadias repair

Ann Nozohoor Ekmark^{a,b}, Einar Arnbjörnsson^{b,c}, Henry Svensson^{a,d} and Emma Hansson^{a,d}

^aDepartment of Clinical Sciences in Malmö, Lund University, Lund, Sweden; ^bDepartment of Paediatric Surgery, Skåne University Hospital, Lund, Sweden; ^cDepartment of Clinical Sciences Lund, Lund University, Lund, Sweden; ^dDepartment of Plastic and Reconstructive Surgery, Skåne University Hospital, Lund, Sweden

ABSTRACT

Purpose: Long-term evaluation of the surgical outcome after puberty, particularly patient reported outcome is rare in the literature. The aims of this study were to investigate the patients' satisfaction with the long-term results and their views and memories of their childhood surgery and follow-up.

Methods: A modified version of previously used questionnaire was sent to 134 patients ages 18 years or older previously primarily repaired due to hypospadias by one of the authors (HS) between 1989 - 2009.

Results: Thirty-nine patients responded. Eighty-two per cent were satisfied with the appearance of their penis, 87% were satisfied with their ability to urinate and their sexual function and 92% were satisfied with the overall surgical results. Ninety per cent of patients were positive to the current duration of our post-pubertal follow-up program or would have preferred an even longer follow-up.

Conclusions: The majority of patients were satisfied with the long-term surgical results and the duration of follow-up. Despite having problems patients does not always contact the health care system spontaneously, which warrants long-term follow-up.

ARTICLE HISTORY

Received 16 February 2016
Revised 14 May 2016
Accepted 1 June 2016
Published online 1 August 2016

KEYWORDS

Patient reported outcome; hypospadias repair; urinary function; sexual function; surgical outcome; HOSE

Introduction

Hypospadias is a congenital malformation of the penis and urethra that is often surgically corrected in childhood. Many surgical methods have been described for the repair of hypospadias, and short-term as well as long-term complications are frequent [1]. Published reports on postoperative outcomes after puberty, particularly patient-reported outcomes, are rare [2-7]. In addition, there have been few studies on patients long-term memories of their treatment and their opinion of the follow-up care that they received [8,9]. We previously reported on postpubertal outcomes of patients undergoing surgical repair in our department, which were based on assessments by the surgeons [10]. However, patient satisfaction with outcome is frequently different from the assessment made by the surgeon [5]. The purpose of obtaining patient-reported outcomes is to complement the conventional clinical assessments and to understand the patients opinion of his treatment and the results that were obtained. The information from patient-reported questionnaires on outcome is also useful for improving the preoperative education of the patient, which includes realistic expectations of the surgical outcome [11]. In addition, information on the patients memories of the surgery and their opinions on the follow-up care that they received is essential for the improvement of hypospadias care.

The aims of this study were to obtain information from patients who had undergone hypospadias repair in childhood, regarding their satisfaction with the long-term results and their opinions and memories of their surgery and follow-up care.

Patients and methods

Patients who underwent primary hypospadias repair between 1989-2009 by one of the authors (HS) were identified through a patient register. Only patients 18 years or older were included. Patients with cognitive impairment/mental retardation were excluded. A total of 157 patients were identified, and five of these were excluded because of cognitive impairment/mental retardation. The original malformations were classified according to the Hadidi classification, which is based on the position of the urethral meatus after orthoplasty, as follows: balanic hypospadias (degree I), distal hypospadias (degree II), penoscrotal hypospadias (degree III), and perineal hypospadias (degree IV) [12].

Surgical treatment protocol

The initial treatment protocol used only the Byars two-stage reconstruction technique for hypospadias repair [13]. However, the treatment protocol evolved over time to be based on the location of the meatus and the degree of chordee. Thus, for the mildest, degree I hypospadias with slight curvature, orthoplasty and realignment of the skin was performed. The Mathieu procedure was used for more pronounced degree I hypospadias [14]. The Scuderi technique was used for mild degree II hypospadias [15], and the two-stage reconstruction based on the Byars technique was used for proximal hypospadias, more pronounced degrees II, and degrees III, and IV hypospadias [13]. Stage 1 of the Byars two-

stage repair [13] was release of the chordee. A circumferential incision was made 3 mm from the coronary sulcus, and the prepuce was divided dorsally. The fibrous chordee on the ventral side was divided and partially excised. The new position of the meatus was secured with a single suture, and the dorsal flaps were moved around to cover the ventral defect. Stage 2 was the reconstruction of the urethra, and was performed 6 months after the first stage. A U-shaped incision was made just proximal to the meatus, ending up on either side of the glans. The inner lining was closed in two layers around a urinary catheter. The outer lining was also closed in two layers. In the Mathieu one-stage procedure [14], a skin flap from the ventral shaft of the penis proximal to the hypospadiac meatus was elevated, and the proximal free end of the flap was then turned 180° and sutured into incisions on either side of the glanular groove and further up to the tip. Any chordee tissue was excised. The prepuce was partially divided and mobilised until an outer cover was achieved. In the Scuderi one-stage procedure [15], the prepuce comprised a flap that was transposed to the ventral side of the penis through a buttonhole incision in the area. The glans and distal penis were passed through the buttonhole. The flap was then wrapped around a catheter and anastomosed with the native meatus. The remaining lateral parts of the prepuce were used for the outer lining. Care was also taken to remove any chordee tissue.

The follow-up of every patient consisted of outpatient examination at ages 7, 10, 13, and 16 years, or until the completion of puberty [10]. At the last visit the repair was assessed by a surgeon according to the hypospadias objective scoring evaluation (HOSE) system. HOSE is a five-point scoring system incorporating the five following domains: (1) evaluation of meatal location, (2) shape, (3) urinary stream, (4) straightness of erection, and (5) the presence and complexity of urethral fistula. A total score ranges from 5/16 points, and according to the original description of HOSE a total score of ≥ 14 is thought to be an acceptable outcome for hypospadias repair [16]. Seibold et al. [6] proposed that a HOSE score ≥ 14 should be considered to be an excellent outcome and, based on this, we consider a HOSE score ≥ 14 to be excellent.

A previously used and validated questionnaire [2] was translated and adapted to fit Swedish conditions. For linguistic validation and conceptual equivalence, the questions were forward translated by the authors and then back translated by a professional translator. The questionnaire consisted of nine items (Appendix), which included four satisfaction-outcome questions derived from the hypospadias outcome questionnaire [2] and five questions on the patients experiences with his medical care. The satisfaction outcome questions covered the patients satisfaction with penile appearance, sexual function, urinary function, and overall surgical results. They were rated on a 175 visual scale, with 1 being very unsatisfied, 3 being neutral, and 5 being very satisfied. Each question provided additional space for comments. The questions regarding the patients experiences with his medical care referred to his paediatric surgery, his follow-up programme, and whether or not he had needed additional medical care because of the hypospadias malformation or its initial repair. He was provided a choice of answers, which

included yes, no, do not know, positive, or negative. A patient who replied yes to the question about receiving medical care outside of our department was asked to specify the nature of the problem and when it had appeared.

In 2014, the 152 study patients were sent the questionnaire, together with a study information sheet, a consent form, and two addressed, stamped envelopes (one for the completed questionnaire and one for the signed consent form). The consent form and the questionnaire were both marked with the patients identification study number, which was information only known to the study investigators. Two envelopes were sent to allow the questionnaire to be returned anonymously, separate from the signed consent form. Patients who did not respond and could be contacted by telephone were called about the study, and asked if they had any questions or comments. Patients who did not respond were also sent the questionnaire and study information a second time.

Data from the charts of all patients, including information on the clinical evaluation at the postpubertal follow-up visit and HOSE scores, were reviewed.

The study was approved by the Regional Ethical Review Board in Lund, Sweden (2013/758). Each study patient gave his informed consent to participate. The Declaration of Helsinki and Good Clinical Practice guidelines were followed.

Statistical analysis

Results for categorical data are given as proportions. The Chi-squared test was used for categorical variables, except when the expected frequency was below five, in which case Fishers exact test was used. Non-parametric tests were used because data was not normally distributed. The Mann-Whitney U test was used for non-parametric continuous variables and expressed as the median with IQR. A *p*-value less than 0.05 was considered to indicate a statistically significant association. Statistical analysis was conducted using the Statistical Package for the Social Sciences, ver. 23.0 (IBM, Chicago, IL).

Results

Population and study sample

A total of 134 patients received the questionnaire (18 questionnaires were returned because of an invalid address). Thirty-nine of the 134 patients (29%) returned a completed questionnaire. Responders and non-responders had similar characteristics with regard to age, degree of malformation, surgical method used, age at repair, frequency of postoperative complications, and proportion of completed postpubertal final evaluations (Table 1). About half the responders had undergone a Byars two-stage procedure, and most of the others had undergone a Mathieu or Scuderi one-stage procedure. Two patients had only received an orthoplasty (Table 1). At their last follow-up visit 88% of the 39 responders were assessed to have a HOSE score of >14 (Table 2). Two of the 39 had received medical care outside of the Department of Plastic Surgery for urinary problems, and one

of these patients underwent two additional surgeries for urinary incontinence.

Patients satisfaction with outcome

The percentages of the 39 patients who were neutral/satisfied/very satisfied with the appearance of their penis, sexual function, ability to urinate, and overall surgical outcome were as follows: 82%, 87%, 87%, and 92%, respectively (Table 3). Thirteen patients with a score ≥ 3 and four patients with a score lower than neutral (≤ 2) added different negative

comments about their ability to urinate. The most frequently reported problems were spraying, dribbling, and weak stream, but some also reported pain ($n=2$). Eleven patients (28%) had scores lower than neutral (≤ 2) on at least one of the satisfaction-outcome questions (Table 4). The frequency of any postoperative complication was 2-fold greater for the lower scoring patients (40%) than for the neutral or higher scoring patients (21%), although the difference was not statistically significant ($p=0.404$). The degree of malformation was more advanced in the lower scoring group; 20% of low scorers had degree III or IV malformations, and 4% of higher scorers ($p=0.164$). The degree of hypospadias, treatments, and complications are summarised in Table 3.

Patient 11 underwent additional corrective surgery because of incurvation after the primary repair, but reports he did not obtain much improvement in cosmesis or sexual function. Patient 10 underwent closure of a fistula after the initial repair. He was offered additional corrective surgery at follow-up for residual surplus of preputial skin, but declined. Patient 8 reported a split urinary stream, starting when he was older than 16 years of age and was unhappy with the dorsal scar after the split skin transplant. Patient 3 was unsatisfied and felt insecure with the appearance of his penis and sensitivity of his glans. He was neutral on urinary function, although he reported urinary spraying and dribbling. Patient 6, with a grade IV hypospadias, gave the lowest score on sexual function, without further comment. He underwent secondary surgery in another department because of inability to empty the bladder. Patient 7 underwent closure of a fistula after the initial surgical repair and reported being too sensitive sexually. Patient 5 underwent two surgical corrections for urethral stricture and reports that surplus skin and

Table 1. Baseline characteristics for responders and non-responders.

	Responders n (%)	Non-responders n (%)	p-value
Surgical method (n = 134)			0.153 ^a
Byars	18 (48)	61 (64)	
Scuderi	8 (21)	9 (9)	
Mathieu	9 (23)	21 (22)	
Orthoplasty	2 (5)	5 (5)	
Missing data	1 (3)	0	
Age at urethral reconstruction, median (range) (n = 134)	5 (5-17)	5.5 (4-13)	0.437 ^b
Degree of malformation (n = 134)			0.968 ^a
Glanular	24 (63)	65 (68)	
Penile	7 (18)	18 (19)	
Penoscrotal	2 (5)	3 (3)	
Perineal	1 (3)	2 (2)	
Cordee without hypospadias	3 (8)	7 (7)	
Missing data	1 (3)	1 (1)	
Any complication (n = 134)	10 (26)	15 (16)	0.147 ^a
Missing data	1 (3)	2 (2)	
Post-pubertal final evaluation (n = 134)	34 (90)	77 (80)	0.200 ^a
Age when receiving the questionnaire, median (range) (n = 134)	21 (18-39)	23 (18-31)	0.284 ^b

^aChi²-test; ^bMann-Whitney U-test.

Table 2. Baseline characteristics for responders and non-responders: Hypospadias Objective Scoring Evaluation (HOSE) scores.

Score (5/16)	11	12	13	14	15	16	Missing	Median (range)
Responders, n (%)		1 (3)	3 (9)	10 (30)	11 (33)	8 (24)	6 (15)	15 (12-16)
Non-responders, n (%)	1 (1)	3 (4)	6 (8)	31 (44)	23 (33)	6 (8)	26 (27)	14 (11-16)

Table 3. Satisfaction with the surgical outcome for responders.

Score	1	1.5	2	3	4	4.5	5
Satisfaction with appearance, n (%)	1 (3)	1 (3)	5 (13)	12 (31)	12 (31)	1 (3)	7 (18)
Satisfaction with sexual function, n (%)	1 (3)		4 (10)	7 (18)	9 (23)		18 (46)
Satisfaction with ability to urinate, n (%)			5 (13)	11 (28)	8 (21)		15 (38)
Satisfaction with surgical result, n (%)			3 (8)	12 (31)	10 (26)		14 (36)

Table 4. Low scoring patients with regard to functional outcome score ≤ 2 .

Patient	Appearance	Sexual function	Ability to urinate	Surgical result	Surgical method	Degree of malformation	Age at surgery	Follow-up completed	Complications after surgery	HOSE score
1			x		Mathieu	1	6	Yes	No	14
2	x				Byars	1	5	Yes	No	15
3	x			x	Byars	1	6	LTF	MD	MD
4	x		x		Byars	1	9	Yes	No	15
5		x			Byars	MD	15	Yes	Stricture	MD
6		x	x		Byars	4	5	Yes	Fistulas, stricture	14 ^a
7		x			Byars	1	5	Yes	Fistula	13
8	x		x	x	Byars	3	MD	No	MD	14 ^b
9	x				Byars	2	6	Yes	No	14
10	x	x	x		Mathieu	2	16	Yes	Fistula	15
11	x	x		x	Mathieu	2	5	Yes	Incurvation	12

^aPatient experience symptoms from a stricture after the competition of post-pubertal follow-up and HOSE-score.

^bPatient did not show up for post-pubertal evaluation. HOSE-score from age 13 years.

scarring were prominent, that he covered himself in public showers, and that he had decreased sexual sensitivity. He scored higher on ability to urinate, although reported urination problems (split stream and dribbling), which had recently improved. Patient 1 reported urinary problems due to surplus skin affecting the stream; however, he had declined additional corrective surgery, which was proposed at his postpubertal follow-up. Patient 4 scored low on ability to urinate because of spraying.

Patients perception of childhood surgeries and follow-up visits

Among the 35 patients who remembered their childhood hypospadias surgery, the median age for surgery was 5 years (range = 5-17 years) and four were older than 10 years at the time of surgery (Table 5). Eight patients had unpleasant memories and one of these patients was older than 10 years at the time of surgery.

The majority (54%) of responders were satisfied with the duration of the follow-up programme, and 90% of responders were either satisfied with the duration or would have preferred a longer follow-up period after surgery (Table 6). However, of the 13 patients requesting a longer follow-up, three had not completed our follow-up programme because they were lost to follow-up ($n=2$) or had refused the final postpubertal follow-up visit ($n=1$) (Table 6). Most patients (72%) had a positive opinion of the follow-up programme (Table 6). Most of the men who requested a longer follow-up programme had wanted a longer follow-up to receive information and undergo medical evaluation when they were older than 16 years, particularly with regards to sexual function.

Under the general comments section, several men requested better psychosocial support, more information on the surgical procedures, and advice on informing future

partners about their condition. Some would have liked the opportunity to meet someone older with the same condition who had completed treatment. Some asked for support on coping with everyday situations, such as being asked questions by classmates and feeling anxious about showering after sports activities or beginning a new sexual relationship. Some reported that having a genital malformation was difficult because they had been bullied. A few respondents ($n=3$) also expressed gratitude towards their surgeon and the staff.

Discussion

This was a study of postpubertal patient-reported outcomes and experiences with treatment and follow-up for hypospadias. The long-term clinical evaluation of these patients was reported previously [10]. The majority of the study responders were satisfied with the long-term surgical outcome, the follow-up visits, and the duration of follow-up.

Methodological issues

Because of the long period of time since many of the patients had their last contact with our department, and because of the type of condition they had, and that they were young men, a low response rate was not surprising, and is an inherent problem with this type of study [2,3,7,16-18]. Previous studies have found that telephone contact is effective for increasing the response rate [2]. We tried to increase the response rate by telephoning non-responders. Given the nature of the study, a response rate of 29% might be the highest that can be expected and, therefore, considered acceptable.

A postpubertal patient-reported outcome after hypospadias repair is essential for learning about long-term urinary and sexual function. This information cannot be obtained until 10-15

Table 5. Experiences from the childhood operation^a.

	Yes	No	Do not know
Patient memories from the childhood hypospadias operation, n (%)	31 ^b (79)	5 (13)	3 (8)
Patient negative experiences from their childhood hypospadias operation, n (%)	8 ^c (21)	22 ^{d,e} (56)	9 (23)

^aAge at hypospadias surgery: median = 5 years (range = 5-17 years).

^bIncluding four patients operated on > age 10 years.

^cIncluding one patient operated on > age 10 years.

^dIncluding three patients operated on > age 10 years.

^eIncluding one patient replying do not know, but commenting: does not have any memories from the operations.

Table 6. Patient experiences from the follow-up visits.

	Yes, shorter	Yes, longer	No, adequate length	Do not know
Patients perception of the duration of the follow-up programme, request for different length follow-up, n (%)	1 (3)	13 ^a (33)	22 ^b (56)	3 (8)
Patients without completed follow-up programme, n (%)		3/13 (23)	1/22 (5)	
Patients perceptions from the regular follow-up visits, n (%)	Positive 27 ^c (69)	Negative 3 (8)	Do not know 9 (23)	
Patients without completed follow-up programme, n (%)	2/27 (7)	2/3 (67)		

^aIncluding one patient replying shorter, but commenting would prefer a longer follow-up.

^bIncluding one patient replying do not know, but commenting duration is probably adequate.

^cIncluding one patient replying do not know, but commenting follow-up was a good thing.

years after paediatric surgery. Therefore, this study evaluated outcomes associated with surgical repair methods that were in use 20 years earlier. The long-term outcomes of recent surgical techniques cannot presently be evaluated.

Whether or not the responders had opinions that were different from the non-responders with regard to functional outcome and our treatment programme is a matter of speculation. Although selection bias cannot be ruled out, there were no differences in the characteristics of the responders vs the non-responders (Table 1).

Only a small number of questionnaires on the outcomes of hypospadias repair have been validated [18]. Although the satisfaction-outcome questions used in this study were previously validated [2], the translated and modified questionnaire was not. Indeed, the added questions on patient perceptions of the follow-up programme on their childhood memories of the surgical procedure(s) might have been unclear, and some respondents might not have understood them. This supposition is supported by the fact that some of the patients who thought that the follow-up should have been shorter also commented that they would have preferred a longer follow-up time. However, the risk of misinterpreting some of the questions and the lack of validity and reliability of the added questions was somewhat reduced by the provision of space after each question for additional comments. In brief, the questionnaire could be considered an adequate patient-reported outcome tool for the long-term follow-up of hypospadias repair.

Long-term results and satisfaction

In this study, 92% of responders were satisfied with the overall surgical results, which is in accordance with what was previously reported by investigators using the original questionnaire (86%) [2].

Cosmesis is difficult to assess objectively. Many published studies have reported the subjective impressions of surgeons. Hypospadias surgeons might have expectations that are different from those of individual patients because they have assessed many post-operative cases; whereas individual patients might not have many examples to compare with themselves [19]. Previous studies have reported that both patients undergoing hypospadias repair as well as healthy controls men were dissatisfied with their penile appearance (41% vs 34%, respectively, not statistically) [3]; although, hypospadias patients were less satisfied [7] and generally have thought that their penis is too short [3,7,20]. In our study, only two patients commented spontaneously about the length of their penis. Studies have reported varied results on patient satisfaction with the appearance of the penis after hypospadias repair. In our study, 82% of responders were satisfied, whereas previous studies reported rates of satisfied patients ranging from 51% [21] to 71% [2]. A previous investigation found that patients with more advanced malformations and worse complications were less satisfied with the long-term outcomes [7]. In summary, our responding patients seem to be generally happier with the appearance of their penis, compared with previous studies.

Our patients were generally satisfied (87%) with their sexual function (Table 5), which is similar to the findings of some

previously described cohorts [2,22]. However, the results of previous studies vary. A previous study did not confirm differences in sexual function, even when the proportion of patients with advanced malformations were relatively high (24%) [23]. However, other studies demonstrated that hypospadias patients might have a lower sexual satisfaction [23] with lower frequency of ejaculation and orgasmic sensation [22,24], and more erectile problems [3] compared with controls. Reduced satisfaction with sexual function has been correlated with a more advanced degree of the original malformation [17]. This finding was also seen in our study (Table 2). Future studies with a larger sample size and subgroup analyses of patients with different degrees of malformation might further clarify this relationship.

Previously, it has been indicated that the patients age at which hypospadias repair should be performed should be younger than 5 years, because patients who retain memories of their surgery are less satisfied with the appearance of their penis and have more psychosocial and developmental problems than other children [9]. However, this could not be confirmed by this or other studies [25]. Most of our patient responders retained memories of their procedure, but were satisfied with their sexuality.

Patients undergoing surgery for hypospadias are often less satisfied with their micturition than healthy controls [2,4,24], because they often experience dribbling and spraying [4]. These problems were also frequently mentioned by our study patients. However, not all of the study patients who had urinary dribbling and spraying perceived that condition as a problem that affected their satisfaction. Many of the patients who were neutral or satisfied also commented that they (sometimes) had problems with spraying and dribbling.

Follow-up

This study found that there were patients who had problems because of their malformation, or the corrective surgery, but had not spontaneously contacted the healthcare system although they have problems that require addressing. A similar finding was observed by a study that used a questionnaire for hypospadias surgery outcomes; 11% of the participating patients actually underwent further surgery as a direct result of the study [5]. That result, thus, supports our study. Our study responders also commented that they wanted a long follow-up period with specifically emphasizing sexual function. Similar findings have been seen for example for teenagers who have undergone surgery for anorectal malformations; they wanted the surgeon to raise the issue of their malformation in relation to sexuality at the follow-up visit [26]. None of the responders in this study, including those who had negative opinions about or did not attend the follow-up appointments, expressed the desire for a shorter follow-up period.

Conclusion

The majority of our patients undergoing hypospadias repair who responded to our questionnaire were satisfied with the functional and aesthetic outcomes. Some patients with long-

term problems because of hypospadias did not voluntarily contact the healthcare system spontaneously, a finding that supports offering patients undergoing hypospadias repair long-term follow-up care. Retained memories of childhood hypospadias surgery did not seem to affect the patients long-term satisfaction.

Disclosure statement

No external funding or financial support has been provided for this work. No personal connection or other conflicts of interest apply.

References

- Cimador M, Vallasciani S, Manzoni G, et al. Failed hypospadias in paediatric patients. *Nat Rev Urol* 2013;10:657-66.
- Hoag CC, Gotto GT, Morrison KB, et al. Long-term functional outcome and satisfaction of patients with hypospadias repaired in childhood. *Can Urol Assoc J* 2008;2:23731.
- Moriya K, Kakizaki H, Tanaka H, et al. Long-term cosmetic and sexual outcome of hypospadias surgery: norm related study in adolescence. *J Urol* 2006;176:1889-793.
- Moriya K, Kakizaki H, Tanaka H, et al. Long-term patient reported outcome of urinary symptoms after hypospadias surgery: norm related study in adolescents. *J Urol* 2007;178:1659-62.
- Mureau MA, Slijper FM, Slob AK, et al. Satisfaction with penile appearance after hypospadias surgery: the patient and surgeon view. *J Urol* 1996;155:703-6.
- Seibold J, Werther M, Alloussi S, et al. Objective long-term evaluation after distal hypospadias repair using the meatal mobilization technique. *Scand J Urol Nephrol* 2010;44:298-303.
- Örtqvist L, Fossum M, Andersson M, et al. Long-term followup of men born with hypospadias: urological and cosmetic results. *J Urol* 2015;193:975-782.
- Olofsson K, Oldbring J, Becker M, et al. Self-perception after hypospadias repair in young men's perspective. *Eur J Plast Surg* 2003;26:294-7.
- Jones BC, O'Brien M, Chase J, et al. Early hypospadias surgery may lead to a better long-term psychosexual outcome. *J Urol* 2009;182:1744-9.
- Ekmark AN, Svensson H, Arnbjörnsson E, Hansson E. Postpubertal examination after hypospadias repair is necessary to evaluate the success of the primary reconstruction. *Eur J Pediatr Surg* 2013;23:304-711.
- Deshpande PR, Rajan S, Sudeepthi BL, Abdul Nazir CP. Patient-reported outcomes: a new era in clinical research. *Perspect Clin Res* 2011;2:137-44.
- Hadidi A. Classification of hypospadias. In: Hadidi A, Azmy A, editors. *Hypospadias surgery an illustrated guide*. Berlin: Springer Verlag; 2004. pp. 79-82.
- Byars LT. A technique for consistently satisfactory repair of hypospadias. *Surg Gynecol Obstet* 1955;100:184-90.
- Mathieu P. Traitement en un temps de l'hypospadias balanique et juxta-balanique. *J Chir (Paris)* 1932;39:481-74.
- Scuderi N, Campus G. A new technique for hypospadias one-stage repair. *Chir Plast* 1983;7:103-79.
- Holland AJ, Smith GH, Ross FI, Cass DT. HOSE: an objective scoring system for evaluating the results of hypospadias surgery. *BJU Int* 2001;88:255-78.
- Chertin B, Natsheh A, Ben-Zion I, et al. Objective and subjective sexual outcomes in adult patients after hypospadias repair performed in childhood. *J Urol* 2013;190:1556-60.
- Liu MMY, Holland AJA, Cass DT. Assessment of postoperative outcomes of hypospadias repair with validated questionnaires. *J Pediatr Surg* 2015;50:2071-74.
- Tourchi A, Hoebeke P. Long-term outcome of male genital reconstruction in childhood. *J Pediatr Urol* 2013;9:980-9.
- Vandendriessche S, Baeyens D, Van Hoecke E, et al. Body image and sexuality in adolescents after hypospadias surgery. *J Pediatr Urol* 2010;6:54-9.
- Nelson CP, Bloom DA, Kinast R, et al. Long-term patient reported outcome and satisfaction after oral mucosa graft urethroplasty for hypospadias. *J Urol* 2005;174:1075-78.
- Jiao C, Wu R, Xu X, Yu Q. Long-term outcome of penile appearance and sexual function after hypospadias repairs: situation and relation. *Int Urol Nephrol* 2011;43:4-7.
- Bubanj TB, Perovic SV, Milicevic RM, et al. Sexual behavior and sexual function of adults after hypospadias surgery: a comparative study. *J Urol* 2004;171:1876-9.
- Rynja SP, de Jong TP, Bosch JL, de Kort LM. Functional, cosmetic and psychosexual results in adult men who underwent hypospadias correction in childhood. *J Pediatr Urol* 2011;7:504-15.
- Weber DM, Schonbuecher VB, Gobet R, et al. Is there an ideal age for hypospadias repair? A pilot study. *J Pediatr Urol* 2009;5:345-50.
- Stenström P, Kockum CC, Benér DK, et al. Adolescents with anorectal malformation: physical outcome, sexual health and quality of life. *Int J Adolesc Med Health* 2014;26:49.

Paper IV



LUND UNIVERSITY
Faculty of Medicine

Lund University, Faculty of Medicine
Doctoral Dissertation Series 2017:29
ISBN 978-91-7619-410-2
ISSN 1652-8220



154102

788176

9