



LUND UNIVERSITY

Biopsy findings in giant cell arteritis: relationship to baseline factors and corticosteroid treatment.

Jakobsson, Karin; Jacobsson, Lennart; Warrington, K; Matteson, El; Turesson, Carl

Published in:
Scandinavian Journal of Rheumatology

DOI:
[10.3109/03009742.2013.775330](https://doi.org/10.3109/03009742.2013.775330)

2013

[Link to publication](#)

Citation for published version (APA):
Jakobsson, K., Jacobsson, L., Warrington, K., Matteson, E., & Turesson, C. (2013). Biopsy findings in giant cell arteritis: relationship to baseline factors and corticosteroid treatment. *Scandinavian Journal of Rheumatology*, 42(4), 331-332. <https://doi.org/10.3109/03009742.2013.775330>

Total number of authors:
5

General rights

Unless other specific re-use rights are stated the following general rights apply:
Copyright and moral rights for the publications made accessible in the public portal are retained by the authors and/or other copyright owners and it is a condition of accessing publications that users recognise and abide by the legal requirements associated with these rights.

- Users may download and print one copy of any publication from the public portal for the purpose of private study or research.
- You may not further distribute the material or use it for any profit-making activity or commercial gain
- You may freely distribute the URL identifying the publication in the public portal

Read more about Creative commons licenses: <https://creativecommons.org/licenses/>

Take down policy

If you believe that this document breaches copyright please contact us providing details, and we will remove access to the work immediately and investigate your claim.

LUND UNIVERSITY

PO Box 117
221 00 Lund
+46 46-222 00 00

Biopsy Findings in Giant Cell Arteritis - Relation to Baseline Factors and Corticosteroid Treatment

Karin Jakobsson¹, Lennart Jacobsson¹, Kenneth Warrington², Eric L Matteson², Carl Turesson¹.

¹Department of Rheumatology, Skåne University Hospital, Malmö, Sweden. ²Division of Rheumatology, Mayo Clinic College of Medicine, Rochester, Minnesota, USA.

Letter

Correspondence

Carl Turesson, MD, PhD
Department of Rheumatology
Skåne University Hospital
S-205 02 Malmö
Sweden
Ph: +4640332419
FAX: +4640337018
E-mail: Carl.Turesson@med.lu.se

The diagnosis of giant cell arteritis (GCA) is based on clinical findings as well as histopathologic evidence of vasculitis. In patients with a clinical picture suggestive of GCA, a temporal artery biopsy (TAB) is often used to confirm the diagnosis. A negative biopsy may be the basis for rejecting the diagnosis in cases with atypical presentation and disease course. There are conflicting data on the impact of corticosteroid treatment on TAB findings in GCA (1-4).

We investigated histopathologic features in TAB from a well defined sample of patients with a clinical diagnosis of GCA, and assessed how these features relate to treatment with corticosteroids and baseline inflammatory markers.

Individuals who developed GCA after inclusion in two population based health surveys [the Malmö Diet and Cancer Study (MDCS; N=30447; performed 1991-1996) and the Malmö Preventive Medicine Project (MPMP; N=33346; performed 1974-1992)] performed in the same catchment area were identified by linking the health survey databases to the local patient administrative register and the national hospital discharge register.

In a structured review of medical records, cases were classified according to the American College of Rheumatology criteria for GCA (5), and clinical data regarding GCA, laboratory parameters and results of temporal artery biopsy were extracted.

Cases with a confirmed clinical diagnosis of GCA and details available at the time of the start of corticosteroid therapy and at the time of the TAB were included in this study. Of 83 incident cases in the MPMP and MDCS, 62 could be included in the present investigation. In a structured review of TAB pathology reports, the presence or absence of the following histopathologic features was recorded: giant cells and/or granuloma, fragmented internal elastic lamina, inflammatory infiltrates

and fibrosis.

Sixty-two cases with confirmed GCA diagnosis were included (Table 1). Patients with a positive biopsy had significantly higher CRP ($p=0.002$) and erythrocyte sedimentation rate (ESR) ($p=0.009$) at diagnosis (Table 1). Biopsy positive cases were slightly younger (Table 1). Patients who started treatment with corticosteroids after the biopsy or on the same day were more likely to have inflammatory infiltrates described in the pathology report than those biopsied at a later time point ($p=0.02$), but there were no significant differences in the proportions with a fragmented internal elastic lamina, giant cells and/or granuloma present, or overall positive biopsy report (Figure 1).

The observation that patients with a positive biopsy had significantly higher baseline CRP and ESR levels is in agreement with previous studies (6-7). We did not find the association between higher age and biopsy positivity reported by others (4, 8), but this may be due to the fact that the number of patients aged over 80 years was limited because of the age distribution of the source population.

Our results are compatible with those of Font and Prabhakaran (9), who observed that patients treated for more than 14 days had inflammation limited to the media-adventitia junction whereas the others were more likely to have diffuse infiltrates in the arterial wall. In contrast to their study, we did not see giant cells in fewer patients after treatment. This could be explained by the fact that none of our patients were treated for more than 13 days prior to biopsy.

In a recent study, Deng and co-workers demonstrated that interleukin (IL)-17 producing T-helper (Th)17 cells were sensitive to steroid treatment and interferon (IFN)- γ -producing Th1 cells persisted in patients who had remaining histologic signs of inflammation despite long term treatment (10). This is in agreement with our findings that steroid treatment affects some features of the inflammation seen in TAB.

Limitations of this study include the small sample size, and the relatively short time from

start of corticosteroid treatment to biopsy in all patients. Strengths of the study include the community based approach, reflecting that the patients are representative for GCA cases managed in the area, and the availability of complete medical information and histopathology specimens.

In conclusion, we have demonstrated that inflammatory infiltrates in GCA may be reduced within a few days after starting corticosteroid treatment, but other features of GCA persist for a longer time despite treatment, leading to a similar diagnostic yield in those treated for a brief period. Patients with a positive biopsy had higher baseline CRP and ESR levels.

Table 1.
Characteristics of included patients with GCA and baseline parameters in giant cell arteritis patients with a positive vs. negative temporal artery biopsy

	All cases (n=62)	Biopsy positive (n=43)	Biopsy negative (n=19)	p ¹
Age at GCA diagnosis (years)	70.7 (SD 6.1; range 56-82)	70.0 (SD 6.3; range 58-82)	72.4 (SD 5.4; range 56-79)	0.16
Female sex	45 (73 %)	32 (74 %)	13 (68 %)	0.54
ESR mm/h; mean (SD)	77.9 (27.7)	84.2 (22.7)	64.0 (33.2)	0.009
CRP mg/l; median (IQR)	97 (58-144)	101 (82-173)	54 (25-92)	0.002
Time (in days) from corticosteroid treatment to TAB (median; IQR)	2 (1-4)	2 (1-4)	3 (1-4)	0.92
Initial steroid dose (mg) (median; IQR)	40 (40-60)	40 (40-60)	40 (30-60)	0.79

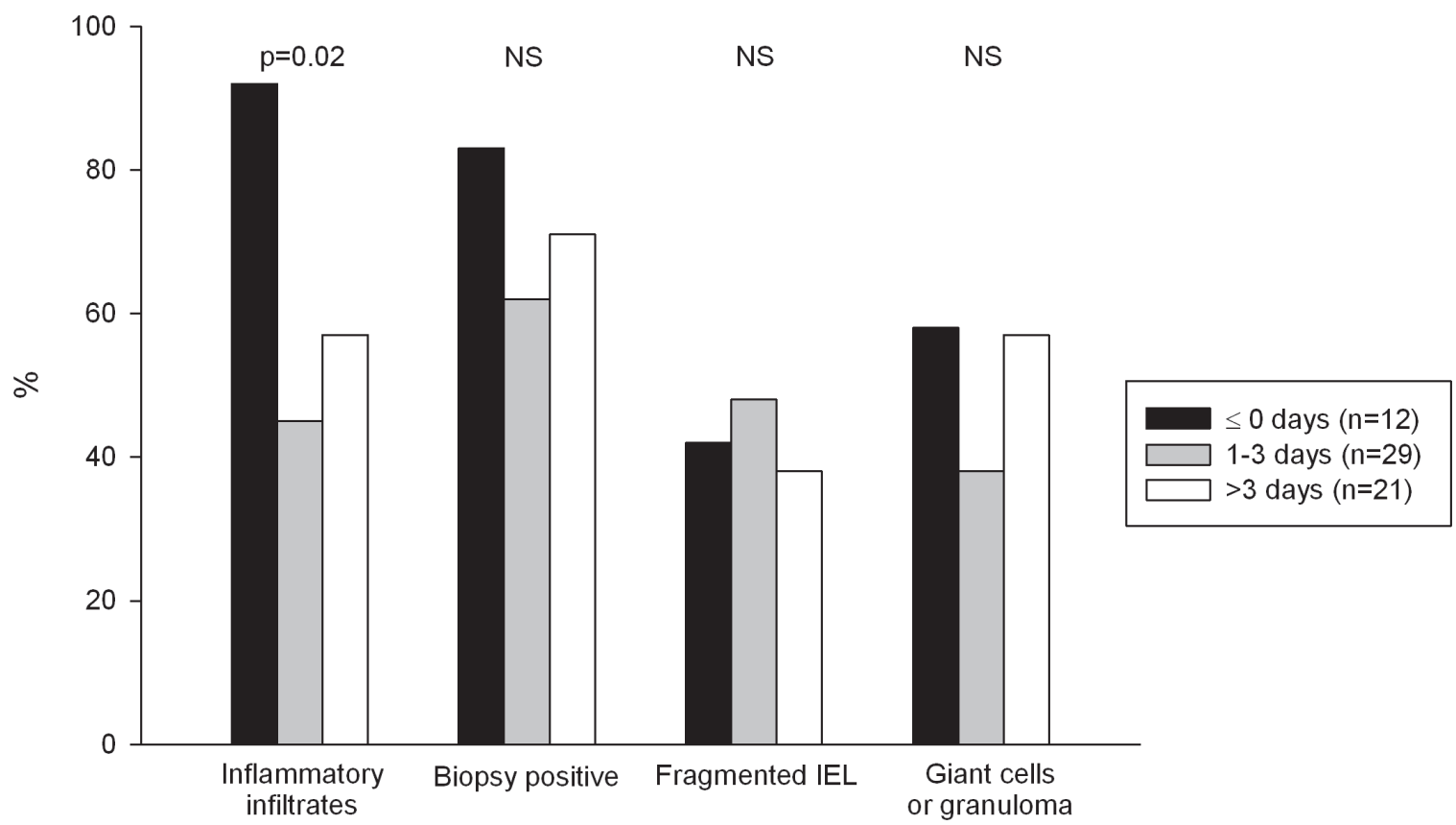
¹ p-value for biopsy positive vs negative

GCA, Giant cell arteritis; ESR, erythrocyte sedimentation rate; CRP, C-reactive protein; TAB, temporal artery biopsy; SD, standard deviation; IQR, interquartile range.

Figure legend

Figure 1.

Proportions of patients with features of giant cell arteritis recorded in the pathology reports, stratified by time from initiation of corticosteroid treatment to biopsy. IEL, Internal elastic lamina; NS, not significant.



References

- (1) Allison M C, Gallagher P J. Temporal artery biopsy and corticosteroid treatment. *Ann of the Rheum Diseases* 1984;43:416-417
- (2) Achar A.A, Lie J T, Hunder G.G, O'Fallon W M, Gabriel S E. How Does Previous Corticosteroid Treatment Affect the Biopsy Findings in Giant Cell (Temporal) Arteritis? *Ann Intern Med.* 1994;120:987-992
- (3) Chmielewski W L, McKnight K M, Agudelo C A, Wise C M. Presenting Features and Outcomes in Patients Undergoing Temporal Artery Biopsy. *Arch Intern Med* 1992;152:1690-1695
- (4) Narváez J, Roig-Vilaseca D, Gómez-Vaquero C, Rodriguez-Moreno J, Valverde J. Influence of Previous Corticosteroid Therapy on Temporal Artery Biopsy Yield in Giant Cell Arteritis. *Semin Arthritis Rheum* 2007;37:13-19
- (5) Hunder GG, Bloch DA, Michel BA, Stevens MB, Arend WP, Calabrese LH, et al. The American College of Rheumatology 1990 criteria for the classification of giant cell arteritis. *Arthritis Rheum* 1990;33:1122-8
- (6) Mari B., Monteagudo M., Bustamante E., Pérez J., Casanovas A., Jordana R. et al. Analysis of temporal artery biopsies in an 18-year period at a community hospital. *Eur J Intern Med* 2009;20:533-536
- (7) Walvick M D, Walvick M P. Giant Cell Arteritis: Laboratory Predictors of a Positive Temporal Artery Biopsy. *Ophthalmology* 2010;118(6):1201-1204

- (8) Lugo J Z, Deitch J S, Yu A, Joon Ho Jang, Patel R, Slova D, et al. Demographic and Laboratory Data ay Predict Positive Temporal Artery Biopsy. J of Surg Research 2011;1-4
- (9) Font R L, Prabhakaran V C. Histological parameters helpful in recognising steroid-treated temporal arteritis: an analysis of 35 cases. 2007;91:204-209
- (10) Deng J, Younge B R, Olshen R A, Goronzy J J, Weyand C M. Th17 and Th1 T-cell Responses in Giant Cell Arteritis. Circulation 2010;121:906-915