LUND UNIVERSITY

Glomus tumours in the long finger and in the thumb of a young patient with neurofibromatosis-1 (Nf-1)

Dahlin, Lars; Müller, Gunilla; Anagnostaki, Lola; Nordborg, Karin

Published in:
Journal of Plastic Surgery and Hand Surgery

DOI:
10.3109/2000656X.2012.754624

2013

Link to publication

Citation for published version (APA):
Dahlin, L., Müller, G., Anagnostaki, L., & Nordborg, K. (2013). Glomus tumours in the long finger and in the thumb of a young patient with neurofibromatosis-1 (Nf-1). *Journal of Plastic Surgery and Hand Surgery*, *47*(3), 238-240. https://doi.org/10.3109/2000656X.2012.754624

Total number of authors:
4

General rights
Unless other specific re-use rights are stated the following general rights apply:
Copyright and moral rights for the publications made accessible in the public portal are retained by the authors and/or other copyright owners and it is a condition of accessing publications that users recognise and abide by the legal requirements associated with these rights.
• Users may download and print one copy of any publication from the public portal for the purpose of private study or research.
• You may not further distribute the material or use it for any profit-making activity or commercial gain
• You may freely distribute the URL identifying the publication in the public portal

Read more about Creative commons licenses: https://creativecommons.org/licenses/

Take down policy
If you believe that this document breaches copyright please contact us providing details, and we will remove access to the work immediately and investigate your claim.

LUND UNIVERSITY

PO Box 117
221 00 Lund
+46 46-222 00 00

Glomus tumours in the long finger and in the thumb of a young patient with neurofibromatosis-1(Nf-1)

Short running title: Glomus tumours and neurofibromatosis-1

Case report

Lars B. Dahlin[1], Gunilla Müller[2], Lola Anagnostaki[3] & Karin Nordborg[4]

[1]Department of Hand Surgery, [2]Department of Diagnostic Radiology, [3]Department of Pathology, Skåne University Hospital, Malmö, [4]Department of Paediatrics', Helsingborg's Hospital, Helsingborg, Sweden

Correspondence: Lars B. Dahlin, Department of Hand Surgery, Skåne University Hospital, SE-205 02 Malmö, Sweden. Tel: +46 40 33 67 69. Fax: +46 40 92 88 55. E-mail: lars.dahlin@med.lu.se

Abstract

Glomus tumours are rare in adults, and such tumours may be associated with neurofibromatosis-1 (Nf-1). Here we describe successful treatment of two glomus tumours initially in the long finger and, one year later, in the thumb in a 17-year young girl with Nf-1.

Key Words: Glomus tumour, neurofibromatosis-1, glomus cells, child, Nf-1, MRI

Introduction

Glomus tumours of the hand are usually reported in adults, where the symptoms may have lasted for a long time before diagnosis and excision of the tumour [1]. They comprise less than 2% of soft tissue tumours in the hand, but up to 10% of these tumours may be multiple [2]. However, glomus tumours may be associated with neurofibromatosis type 1 (Nf-1) [3-6].

Case report

A 17-year-old girl with neurofibromatosis-1 was diagnosed with café-au-lait spots during the neonatal period, so she was followed up by a paediatrician twice yearly. Numerous café-au-lait spots which varied in size, but no neurofibroma, were seen during childhood. Later, multiple cutaneous neurofibromas (mm in size) were noted in the skin. Her mother had neurofibromatos and died of glioblastoma multiforme. Magnetic resonance imaging (MRI) of the child's brain at the age of 13 showed no pathological changes. The girl was at the age of 17 referred because of pain in the right middle finger of 4-5 months duration with no trauma. She had a pulsating pain in the finger particularly during the evening and night. When the finger was touched the pain increased, but there was no impairment in the range of movement. The finger pulp swelled slightly with increased sensation to sharp objects. A conventional radiograph showed no pathological changes, but an ultrasound showed a 2.5 mm low-echoic structure of unknown origin in the finger pulp. MRI showed a 6 x 3 mm oval tumour volar to the distal phalanx in the finger pulp with low signal intensity on T1-weighted images, high signal intensity on STIR, and enhancement on T1-weighted images with gadolinium contrast agent (Figure 1).

Because we were suspicious of a glomus tumour, she was referred to a hand surgeon and operated on at the age of 18. Under a finger block and tourniquet, an oblique incision was

made in the pulp (Figure 2), and the tumour was excised with no complications. The wound healed uneventfully and her preoperative symptoms disappeared. Follow-up a year later showed no abnormality. Microscopic examination confirmed a glomus tumour surrounded by a fibrous capsule (Figure 3). The tumour was caused by glomus cells and small vascular lumina lined with single layers of flattened endothelial cells.

One year later she was again referred to us due to symptoms from a mm large tumour in the pulp of the left thumb. MRI showed a 2 mm tumour in the pulp (Figure 4) and a glomus tumour was suspected. She was operated under a thumb block and tourniquet. An incision as a partial Moberg flap was raised. The tumour was excised with no complications (Figure 5). The wound healed uneventfully. Follow-up showed no abnormality and she had no symptoms. Again, a glomus tumour was confirmed by the microscopic examination. Immunocytochemistry showed tumour cells stained for actin-SM and vimentin, but the cells did not stain for cytokeratin CKAE1/AE3.

Discussion

Glomus tumours are rare in the hand, and probably make up less than 2% of all hand tumours, predominantly occurring in middle-aged patients. The first case report indicating an association with glomus tumour and von Recklinghausen's disease was published in 1937, but few cases have been reported since [4,7]. The association is not well-known. Based on the previous reports that patients with Nf-1 may have an increased incidence of glomus tumours, our working hypothesis was that this was such a tumour when the girl was referred. The suspicion that glomus tumours may be associated with Nf-1 is based mainly on a recent report of 11 patients with 20 glomus tumours in the fingers, and one in the toe. Five of these patients had multiple tumours and our case had two tumours. Interestingly, a meticulous analysis of

these tumours showed that loss of neurofibromin function may be crucial in the pathogenesis of glomus tumours in Nf-1. The neurofibromin, which is a protein product of Nf-1 (tumour suppression gene Nf-1), regulates RAS through its GTPase activity protein related domain [8]. RAS mitogen-activated protein kinase (MAPK) hyperactivity was found in cultured glomus cells, which lack *Nf-1*$^{-/-}$. The cells from the glomus tumours in the report by Brems et al. [8] showed increased activation of extracellular-regulated kinases 1 and 2 (ERK1/2) phosphorylation (p-ERK1/2) after stimulation with acidic fibroblast growth factor (aFGF) in the Nf-1-associated glomus tumour-erived glomus cells. An increased p-ERK:ERK ratio was therefore detected. Taken together, the data indicate an effect of *Nf-1* inactivation on the MAPK pathway in Nf-1-associated glomus tumour-derived glomus cells. Phosphorylation of ERK1/2 (p-ERK1/2) is a prerequisite for proliferation of Schwann cells after damage to nerves in rats [9].

In a previous report, eight of the 11 patients were women aged 26-59 years, and a girl of 11 years [8]. Recently, a case of a painful glomus tumour of the thumb in an 11-year-old boy, on whom initially a neurofibroma of the terminal sensory branch of the digital nerve had been suspected [10], was reported. Glomus tumours in children are extremely rare [11].

The present case, who had two glomus tumours successfully excised, indicates, together with a few cases reported previously, that there is an association between glomus tumours and Nf-1: an association that is related to loss of neurofibromin function secondary to mutations in the tumour's suppressory gene *Nf-1*. We strongly recommend that one should suspect a glomus tumour in patients with Nf-1 if such patients have symptoms from finger pulp or nails. The diagnosis should be kept in mind even if the patient is a child aged less than 18 years.

References

[1] Lee IJ, Park DH, Park MC, et al. Subungual glomus tumours of the hand: diagnosis and outcome of the transungual approach. J Hand Surg Eur Vol 2009;34:685-8.

[2] Gombos Z, Zhang PJ. Glomus tumor. Arch Pathol Lab Med 2008;132:1448-52.

[3] Kim YC. An additional case of solitary subungual glomus tumor associated with neurofibromatosis 1. J Dermatol 2000;27:418-9.

[4] Okada O, Demitsu T, Manabe M, et al. A case of multiple subungual glomus tumors associated with neurofibromatosis type 1. J Dermatol 1999;26:535-7.

[5] Sawada S, Honda M, Kamide R, et al. Three cases of subungual glomus tumors with von Recklinghausen neurofibromatosis. J Am Acad Dermatol 1995;32:277-8.

[6] De Maerteleire W, Naetens P, De Smet L. Glomus tumors. Acta Orthop Belg 2000;66:169-73.

[7] Klaber R. Morbus Recklinghausen with glomoid tumours. Proc R Soc Med 1938;31:347.

[8] Brems H, Park C, Maertens O, et al. Glomus tumors in neurofibromatosis type 1: genetic, functional, and clinical evidence of a novel association. Cancer Res 2009;69:7393-401.

[9] Mårtensson L, Gustavsson P, Dahlin LB, et al. Activation of extracellular-signal-regulated kinase-1/2 precedes and is required for injury-induced Schwann cell proliferation. Neuroreport 2007;18:957-61.

[10] Leonard M, Harrington P. Painful glomus tumour of the thumb in an 11-year-old child with neurofibromatosis 1. J Hand Surg Eur Vol 2010;35:319-20.

[11] Magliulo G, Cristofari P, Terranova G. Glomus tumor in pediatric age. Int J Pediatr Otorhinolaryngol 1996;38:77-80.

Figure legends

Figure 1. (a) T1-weighted coronal and (b) sagittal magnetic resonance images with fat suppression after intravenous injection of gadolinium contrast medium. Arrow denotes the highly vascularised glomus tumour in the long finger on the volar side of the distal phalanx.

Figure 2. Peroperative photograph of the finger pulp showing the glomus tumour deep within. A glomus tumour 5 mm in diameter was excised (insert).

Figure 3. Microscopic picture of the glomus tumour, which is surrounded by a fibrous capsule. It is composed of solid aggregates of glomus cells and small vascular lumina that are lined by a single layer of flattened endothelian cells (Vimentin stain, length of bar 1 mm).

Figure 4. Image of a T1-weighted inversion recovery sequence of the left thumb showing a glomus tumour (arrow) of 2 mm in diameter.

Figure 5. Peroperative photograph of the left thumb showing the 2 mm large glomus tumour (a), which was connected to a small vessel (b; arrow) and excised (insert).

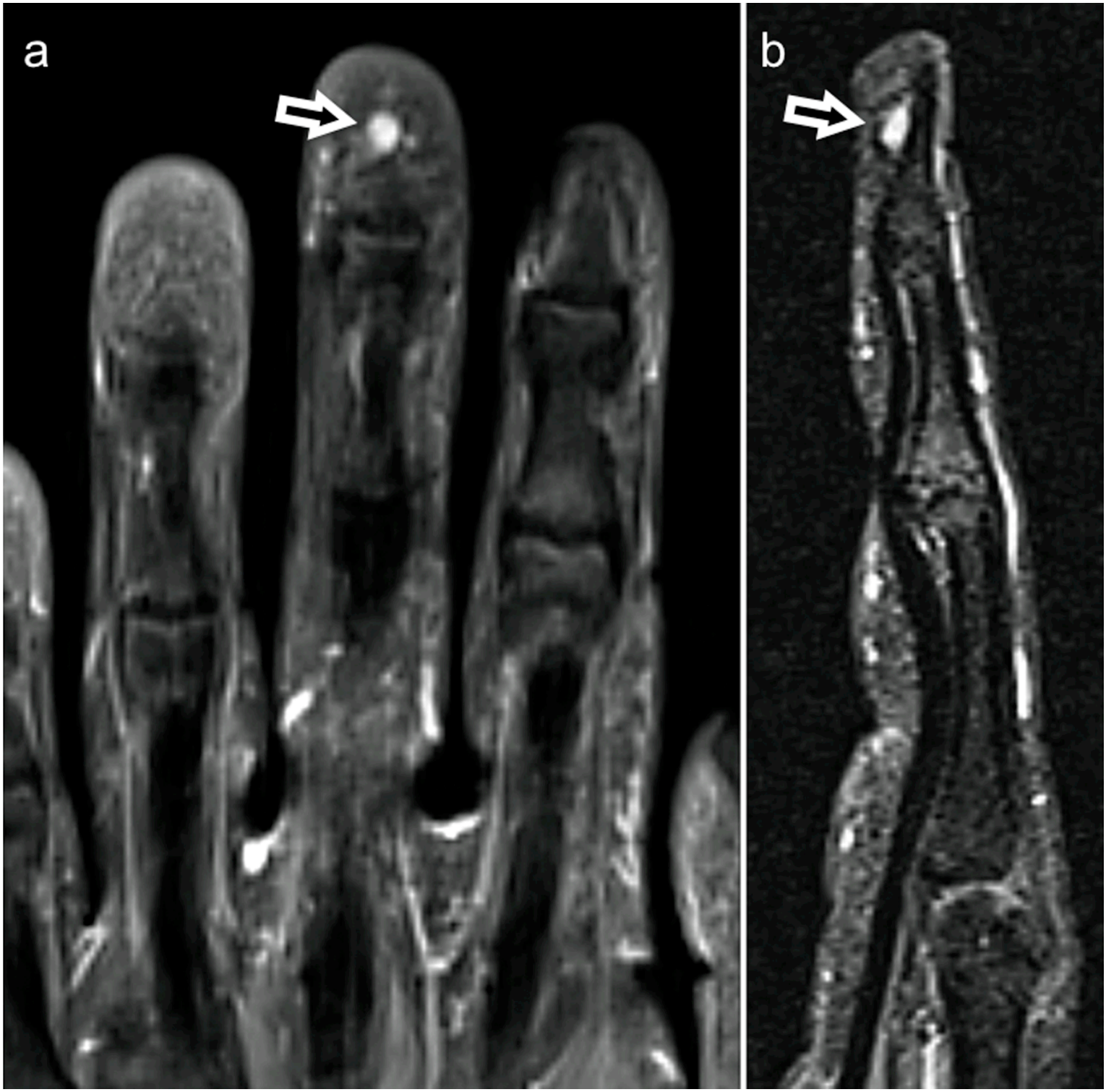
a
b

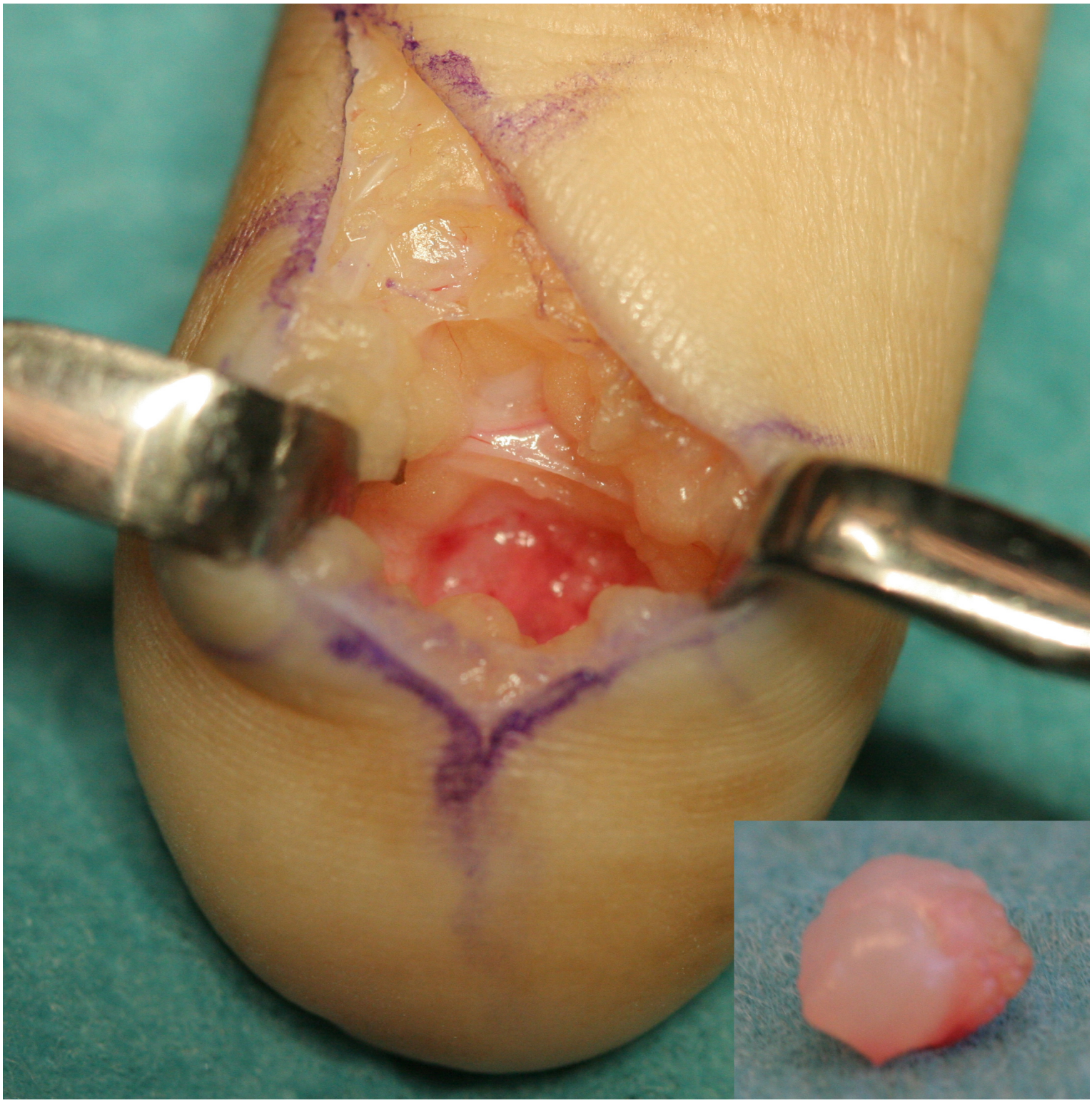

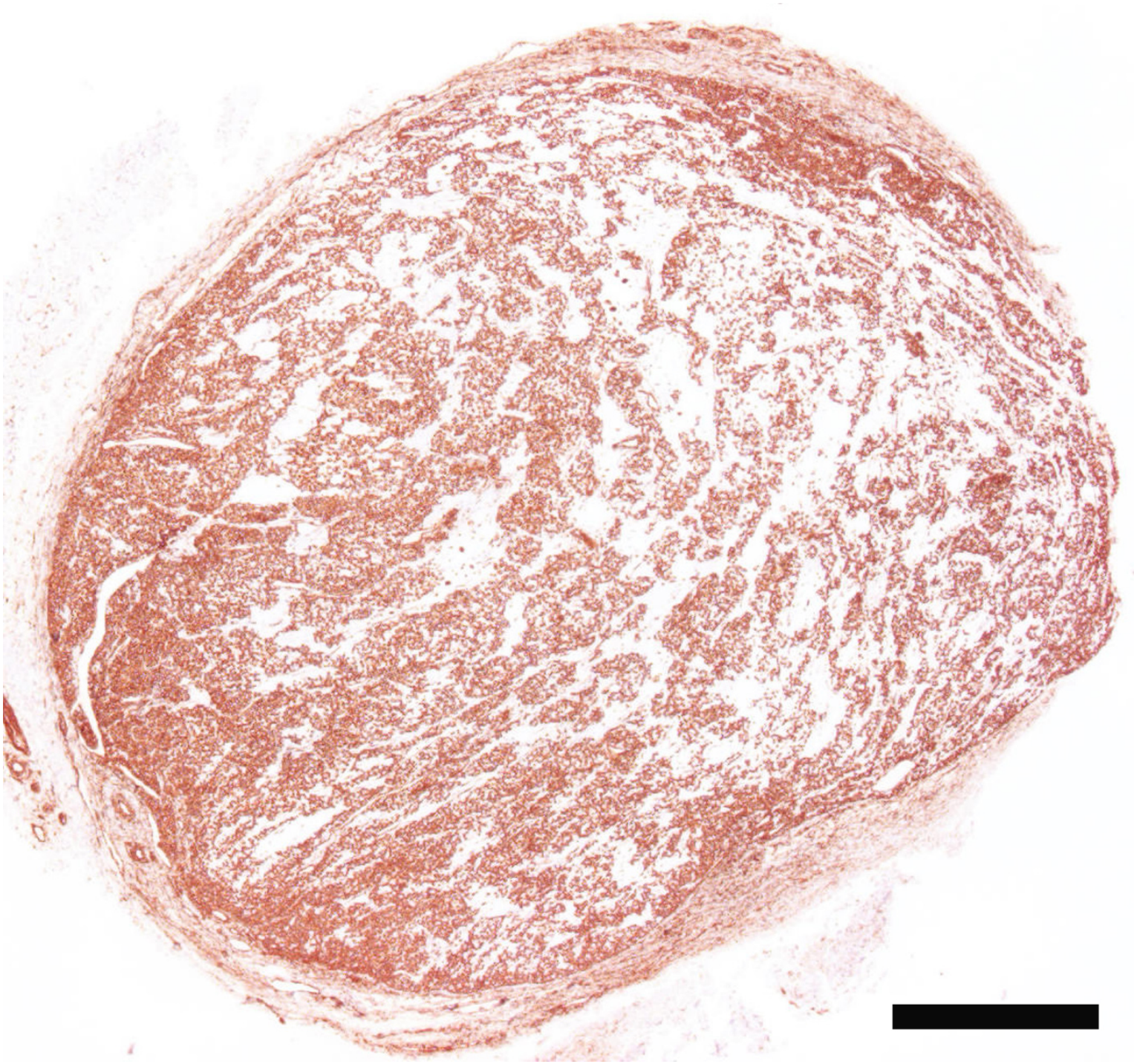

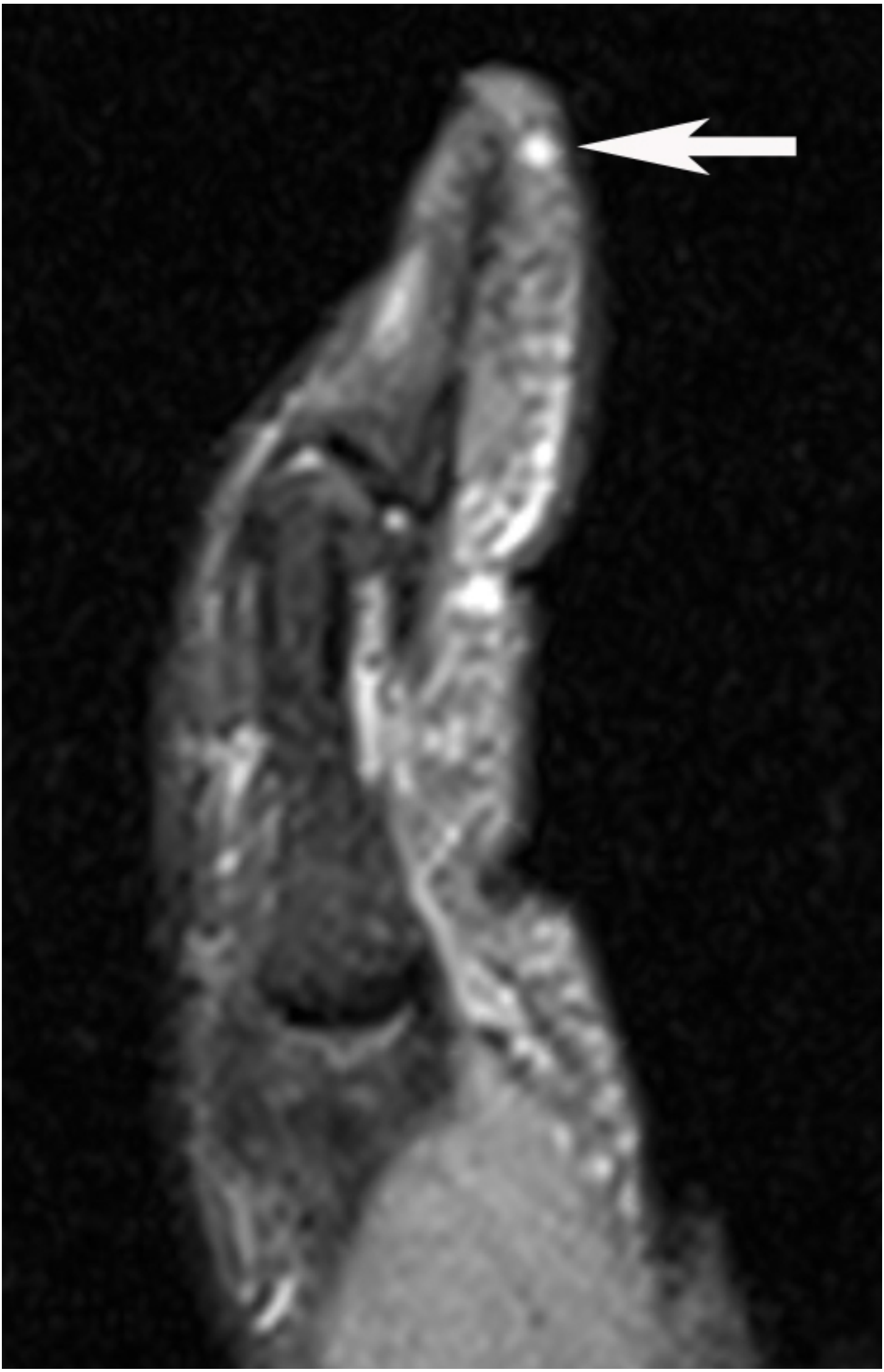

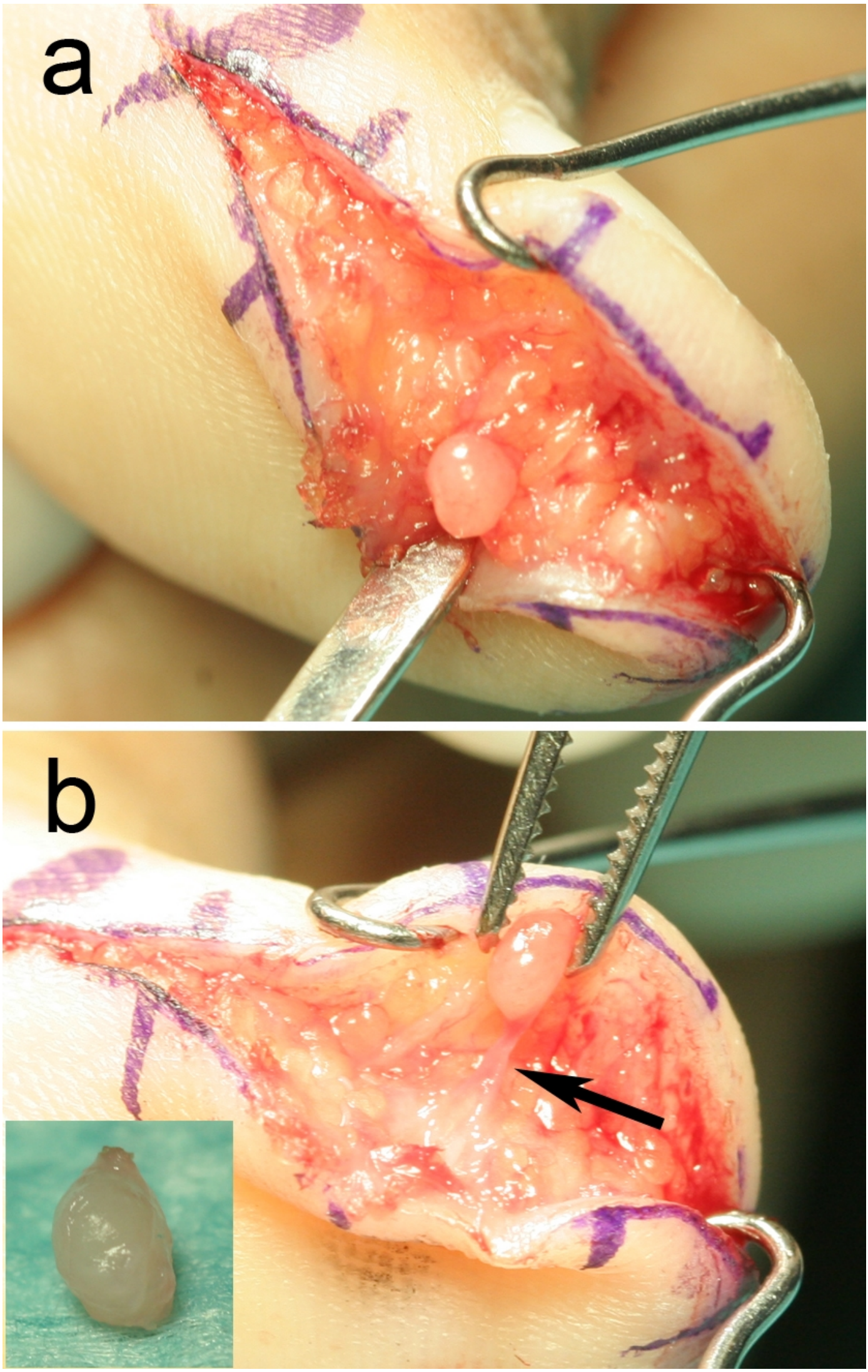
a
b