



# LUND UNIVERSITY

## Organ-sparing reconstructive surgery in penile cancer: initial experiences at two Swedish referral centres.

Håkansson, Ulf; Kirrander, Peter; Uvelius, Bengt; Baseckas, Gediminas; Torbrand, Christian

*Published in:*  
Scandinavian Journal of Urology

*DOI:*  
[10.3109/21681805.2014.955822](https://doi.org/10.3109/21681805.2014.955822)

2015

[Link to publication](#)

*Citation for published version (APA):*  
Håkansson, U., Kirrander, P., Uvelius, B., Baseckas, G., & Torbrand, C. (2015). Organ-sparing reconstructive surgery in penile cancer: initial experiences at two Swedish referral centres. *Scandinavian Journal of Urology*, 49(2), 149-154. <https://doi.org/10.3109/21681805.2014.955822>

*Total number of authors:*  
5

### General rights

Unless other specific re-use rights are stated the following general rights apply:  
Copyright and moral rights for the publications made accessible in the public portal are retained by the authors and/or other copyright owners and it is a condition of accessing publications that users recognise and abide by the legal requirements associated with these rights.

- Users may download and print one copy of any publication from the public portal for the purpose of private study or research.
- You may not further distribute the material or use it for any profit-making activity or commercial gain
- You may freely distribute the URL identifying the publication in the public portal

Read more about Creative commons licenses: <https://creativecommons.org/licenses/>

### Take down policy

If you believe that this document breaches copyright please contact us providing details, and we will remove access to the work immediately and investigate your claim.

LUND UNIVERSITY

PO Box 117  
221 00 Lund  
+46 46-222 00 00

# **Organ-sparing Reconstructive Surgery in Penile Cancer: Initial Experiences at Two Swedish Referral Centres**

*Ulf Håkansson, MD*

Department of Urology, Skåne University Hospital, Malmö, Sweden

*Peter Kirrander, MD*

Department of Urology, Örebro University Hospital, Örebro, Sweden

*Bengt Uvelius, MD, PhD*

Department of Urology, Skåne University Hospital, Malmö, Sweden

*Gediminas Baseckas, MD*

Department of Urology, Skåne University Hospital, Malmö, Sweden

*Christian Torbrand, MD, PhD*

Department of Urology, Skåne University Hospital, Malmö, Sweden

**Corresponding Author:** Dr Ulf Håkansson, Department of Urology, Skåne University Hospital, SE-205 02 Malmö, Sweden. E-mail: [Ulf.K.Hakansson@skane.se](mailto:Ulf.K.Hakansson@skane.se)

**Running head:** Organ-sparing Reconstructive Surgery in Penile Cancer

**Word count:** 244 (abstract), 2104 (manuscript), 2 Figures, 2 Tables

## **Abstract**

*Objective:* To present early outcome data for patients treated for penile cancer with organ-sparing reconstructive surgery at two referral centres in Sweden.

*Methods:* Oncological, cosmetic and functional outcome and complications have been analysed retrospectively during the period 2011-2013. Twelve patients with non-invasive penile cancer were treated with glans resurfacing (GR), while 15 patients with invasive penile cancer underwent total glansectomy with neoglans reconstruction (TGN).

*Results:* The 12 patients treated with GR had a median age of 66 years (range: 35-83 years), and a median follow-up time of 16 months (range: 4-40 months). All patients showed carcinoma *in situ* and negative surgical margins in the final pathology report. The 15 patients treated with TGN had a median age of 71 years (range: 37-78 years), and the median follow-up time was 10 months (range: 1-25 months). All patients had invasive penile cancer and the surgical margins were negative in all cases except one. Complications occurred in five of the 27 patients (18%), and in most cases these were minor and infection related. No recurrences were seen in either group during follow-up, and all patients except one, who had undergone GR, were satisfied with the functional and cosmetic results.

*Conclusions:* GR and TGN seem to be oncologically safe procedures for treating carefully selected patients with penile cancer, and the functional and cosmetic results are promising. Based on our findings, we recommend that penile amputation should only be carried out in patients not suitable for organ-sparing reconstructive surgery.

**Keywords:** penile cancer, organ-sparing, reconstructive surgery, glansectomy, glans resurfacing, neoglans

## **Introduction**

Penile cancer is a rare malignancy in developed countries and in Sweden only approximately 130 new cases are recorded each year. The Swedish National Penile Cancer Register (NPECR) was set up in 2000 as a prospective population-based register of all newly diagnosed penile cancer patients. The degree of correlation between the recommendations of national Swedish and European Guidelines, and the adherence regarding organ-sparing surgery is low [1]. However, during the past two decades various less-mutilating techniques have been described and proposed for organ-preserving and reconstructive surgery in the treatment of penile cancer. The development of these techniques has reduced the negative impact on the functional and cosmetic outcomes associated with penectomy without jeopardizing long-term local oncological control [2-8].

We present initial findings regarding organ-sparing reconstructive surgery at two referral centres for penile cancer in Sweden. Twelve patients with non-invasive penile cancer underwent glans resurfacing (GR), and 15 patients with invasive penile cancer underwent total glansectomy with neoglans reconstruction (TGN).

## Methods

In this retrospective study, patient age at surgery, final pathology including tumour-free margins, complications, length of follow-up, oncological results and functional/cosmetic outcome (as judged by the patient and the surgeon), were analysed in patients with non-invasive penile cancer undergoing GR, or with invasive penile cancer undergoing TGN. All tumours were squamous cell carcinomas. During the period 2011-2013 a total of 27 patients underwent surgery at the Skåne University Hospital (SUS) and Örebro University Hospital (USÖ), Sweden. Patients with clinically palpable lymph nodes (cN1-3), invasive tumours larger than 3 cm in diameter or tumours located on the penile shaft were excluded in this study. The two organ-sparing reconstructive surgical techniques are described below.

### *Glans resurfacing*

GR is performed under tourniquet control following an initial standard circumcision down to Buck's fascia (Figure 1). Only the epithelium and the subepithelial tissue of the glans are removed and a neoglans is constructed using a split skin graft from the thigh, which is carefully sutured to the denuded glans. In all cases with unclear margins there are sent frozen sections perioperatively. The specimen is sent in one piece with a suture through the four meatal flaps. The indwelling catheter and compression bandage are removed after three days, and prophylactic antibiotics are given during this period. The follow-up examination is carried out at the outpatient clinic one month after surgery and then according to guidelines [9, 10].

### *Total glansectomy with neoglans*

The TGN procedure starts with circumcision down to Buck's fascia and the neurovascular bundle is divided to identify the dissection plane between the glans and corporal heads (Figure 2). The glansectomy involves the complete excision of the glans from the corpora cavernosa, and the urethra is then divided freeing the specimen. The urethra is spatulated with the subsequent formation of a new urethral meatus at the tip of the penis. Sections of the tunica albuginea and distal urethral margins are always taken perioperatively and are sent for frozen section. The penile skin is sutured 2 cm from the tip, leaving the corporal heads exposed for skin grafting. The neoglans is reconstructed using a free split-thickness skin graft

harvested from the thigh. The graft is sutured to the distal corpus cavernosa and urethra with resorbable sutures to improve graft take and to prevent haematoma. Perioperative diagnostic sentinel node biopsy (DSNB) was performed according to guidelines [9, 10]. The patient remained in bed for three days after surgery, with an indwelling catheter and bandage, and prophylactic antibiotics were given during this period. A follow-up examination is carried out at the outpatient clinic one month after surgery and then according to guidelines [9, 10].

## Results

Twelve GR procedures were performed (8 at SUS and 4 at USÖ) by two surgeons (UH, PK). Basic characteristics are presented in Table I. The indications for surgery were primary or recurrent non-invasive squamous cell carcinoma on the glans. Complete glans resurfacing, i.e. total GR, was performed in 11 of these patients, and partial glans resurfacing in the remaining patient. The median age was 66 years (range: 35-83 years), and the median follow-up time was 16 months (range: 4-40 months). The final pathology report confirmed pTis in all cases. One patient also had a pT1a tumour, and two cases of concomitant balanitis xerotica obliterans (BXO) were found. All patients had negative margins. A simultaneous DSNB was performed in one case of a previously suspected invasive tumour. Three patients suffered complications: two graft infections and one case of pneumonia, all of which were successfully treated with antibiotics without any sequelae. There was no graft loss or need for re-grafting. So far, no recurrences have occurred. All but one of the patients were satisfied with the functional and cosmetic results.

TGN was performed on 15 patients (14 at SUS and 1 at USÖ), by three surgeons (UH, GB, PK). Basic characteristics are presented in Table II. Indications for surgery were primary invasive squamous cell carcinoma in 14 cases and recurrent dysplasia after previous local irradiation of superficial penile cancer in one case. All primary lesions involved less than half of the glans and were less than 3 cm in diameter. The median age was 71 years (range: 37-78 years), and the median follow-up time was 10 months (range: 1-25 months). The final pathology confirmed invasive squamous cell carcinoma in all patients, except one (pT0). Two patients had concomitant BXO. Negative surgical margins were confirmed in all cases except one (pT3), and all frozen sections were negative. DSNB was performed on nine patients and one patient had a positive finding, and as a consequence radical lymph node dissection was performed. Complications related to the TGN occurred in two patients: one partial skin graft

necrosis and one graft infection, which were treated with neoglans debridement and antibiotics. There was no graft loss or need for re-grafting. So far, no recurrences have occurred. All patients were satisfied with the functional and cosmetic results.

## Discussion

A paradigm shift regarding primary treatment for penile cancer has occurred during the past two decades. The traditional 2 cm excision margin has been questioned, and a margin of only a few millimetres is now considered sufficient in selected cases [11-14]. Negative surgical margins are the “gold standard” in the treatment of penile cancer, although the width of the negative surgical margin does not seem to be an independent prognostic marker [14]. Most penile carcinomas (80%) occur distally and are involving the glans and/or prepuce. Organ-preserving surgery should therefore be suitable in the majority of cases (pTis-pT2) according to the EAU Guidelines [10] and several new techniques have been developed in recent years, e.g. GR and TGN [2, 3, 6-8, 13, 15-18]. Moreover, organ-preserving techniques reduce the negative impact on function, cosmetic appearance and quality of life compared to amputation [19, 20]. Although organ-preserving techniques convey a higher risk of local recurrence, most recurrences are surgically salvageable and overall mortality is comparable to that following primary amputation [13, 21-24]. Penile amputation should therefore be considered overtreatment in the vast majority of patients with penile cancer [2, 13].

Several kinds of organ-preserving treatment have been used to treat non-invasive penile cancer (pTis and pTa), including local resection, laser ablation, topical treatment, Mohs microsurgery and photodynamic therapy. Apart from the negative cosmetic and functional results, these methods are also associated with high recurrence rates and no firm evidence supporting the superiority of either of these techniques exist [10]. Consequently, additional surgical procedures are often required, and new, more effective, permanent forms of treatment are thus needed. GR was initially introduced by Bracka in 2000 for the treatment of persistent BXO [25]. In recent years, reports on GR in small series of patients with non-invasive penile cancer have been published, showing promising oncological, cosmetic and functional results [7, 15, 18]. The largest published series included 25 patients, who maintained a functional penis without compromising oncological control for a mean follow-up time of 29 months [7]. The degree of positive margins in this study was high (48%), but the local recurrence rate was only 4%. There were no cases of progression, and the authors concluded that GR is a safe and effective permanent treatment for pTis.



Historically, invasive penile cancer (pT1 or higher) has been treated with penectomy, but less-mutilating surgery, involving different forms of neoglans reconstruction with flaps or grafts, have been evaluated to these patients in recent years. The use of TGN to treat penile cancer was first described in 1996 by Austoni, who emphasized the anatomical distinction between the corpora cavernosa and the corpus spongiosum [26]. The most recent publication concerns a prospective study on 72 patients who underwent TGN for penile cancer, showing only a 6% recurrence rate, despite 37 patients (51%) with T2 disease and 24 patients (33%) having high-grade tumours [17]. Smaller studies on the use of TGN have also been published, showing excellent local control and good cosmetic and functional results [2, 3, 6, 8]. TGN has also been successfully used in the organ-sparing treatment of primary distal urethral cancer [27].

The management of penile cancer in Sweden has been registered in the NPECR since 2000. According to the actual data in the NPECR, 30% of patients are younger than 60 at diagnosis, and have an excellent prognosis, with an overall relative five-year survival exceeding 80%. The majority of patients (84%) are diagnosed as having tumours that are generally suitable for organ-preserving techniques (pTis-pT2). Swedish guidelines recommend an organ-sparing approach for early stage penile cancer whenever possible [9], but the rate of organ-preserving surgery in the NPECR is only 50% (unpublished data). We believe this is due to a decentralized management of penile cancer and a lack of tradition of reconstructive surgery in Sweden [1]. However, recently measures are being taken to centralize the management of penile cancer in Sweden, based on recommendations in the literature [16, 28-30]. This is the first study from Scandinavia on organ-sparing reconstructive surgery for penile cancer.

In the series of patients with non-invasive penile cancer undergoing GR, the final pathology report confirmed pTis in all cases, and there were no positive margins. Patient selection appears to be adequate as the degree of positive margins is low compared to previous studies [7]. So far, no recurrences have occurred. The complication rate was slightly higher than previous reports [7, 15], but these were minor and resolved without sequelae. All patients but one were satisfied with the functional and cosmetic results. The patient who was dissatisfied had multiple recurrences after local excisions and laser treatment prior to the GR, resulting in minimal remaining spongy tissue. In our opinion prior surgery is not a contraindication to GR. Instead this patient emphasizes that GR should be a first or second line treatment for patient with non-invasive tumours on the glans, especially with concomitant BXO.

In the present study on the result of TGN the final pathology report confirmed invasive squamous cell carcinoma and negative surgical margins in all patients except one. The low rate of complications and no graft loss corresponds well with previous reports [17]. No recurrences have occurred and all patients were satisfied with the functional and cosmetic results of the procedure.

Our initial experiences confirm the results of previous studies on organ-sparing reconstructive surgery in penile cancer. In this study, GR and TGN seem to be oncologically safe in carefully selected patients. The frequency of positive margins was low (4%) and so far, no recurrences have been reported. However, the number of patients was small and the follow-up time is short. Therefore, careful patient selection, perioperative frozen section of the surgical bed to confirm negative margins and close surveillance are mandatory.

The functional and cosmetic results are promising, but these have not been measured using validated questionnaires. The preservation of sexual function following penile-sparing surgery has been inconsistently reported in the literature, and only one study so far has included validated tools or questionnaires for the evaluation of sexual function [20]. In order to evaluate organ-sparing reconstructive surgery in a more rigorous and scientific fashion a prospective study of patient-related outcome, recurrences and overall mortality is planned by our group. The ongoing process in Sweden to centralize the management of penile cancer will hopefully make it easier to perform such a study.

In conclusion, GR and TGN seem to be oncologically safe procedures for treating carefully selected patients with penile cancer, and the functional and cosmetic results are promising. In our opinion, penile amputation should be limited to patients not suitable for organ-sparing reconstructive surgery.

### **Conflicts of interest**

The authors report no conflicts of interest. The authors alone are responsible for the content and writing of the paper.

### **Acknowledgements**

This study was supported by funds from Skåne University Hospital, Sweden.

## References

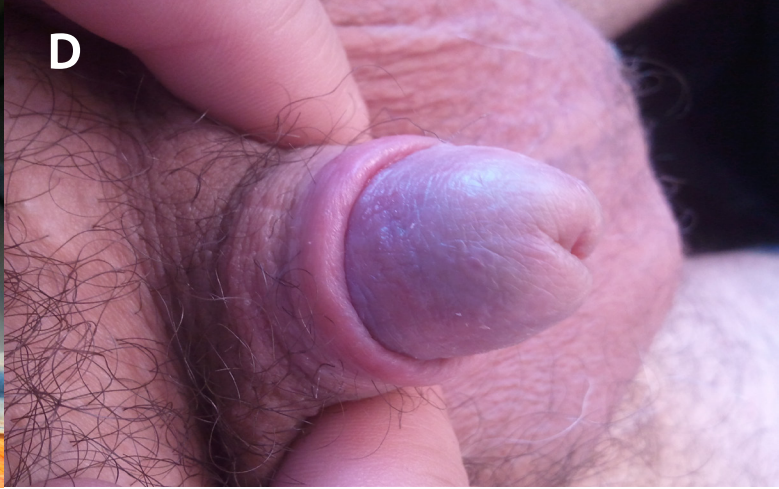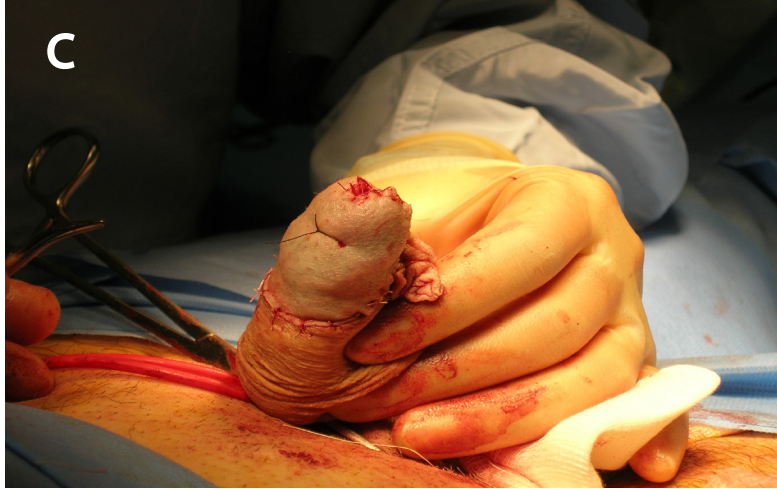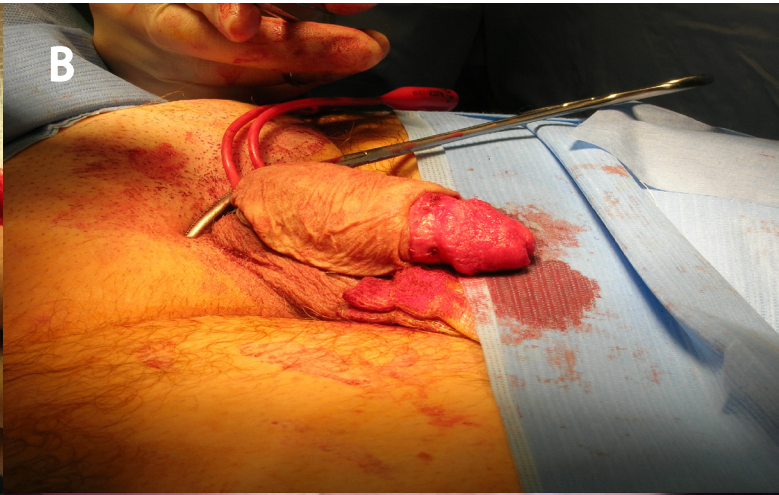
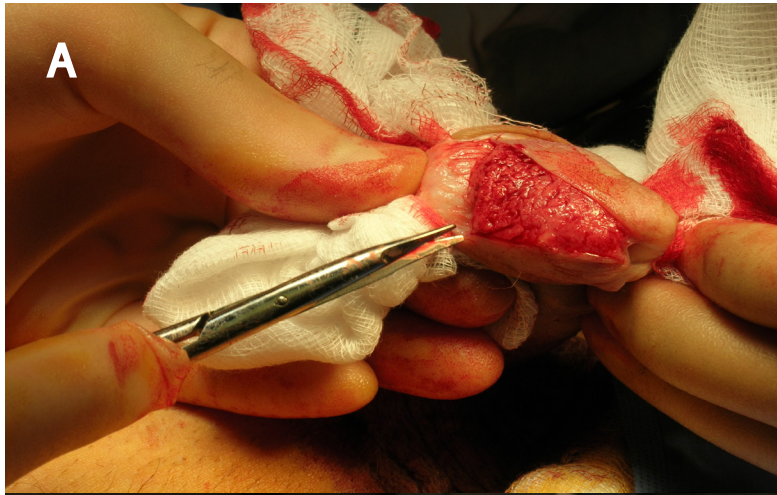1. Persson B, Sjodin JG, Holmberg L, Windahl T, Steering Committee of the National Penile Cancer Register in Sweden. The National Penile Cancer Register in Sweden 2000-2003. *Scand J Urol Nephrol.* 2007;41(4):278-82.
2. O'Kane HF, Pahuja A, Ho KJ, Thwaini A, Nambirajan T, Keane P. Outcome of glansectomy and skin grafting in the management of penile cancer. *Adv Urol.* 2011;2011:240824.
3. Pietrzak P, Corbishley C, Watkin N. Organ-sparing surgery for invasive penile cancer: early follow-up data. *BJU Int.* 2004;94(9):1253-7.
4. Bissada NK, Yakout HH, Fahmy WE, Gayed MS, Touijer AK, Greene GF, et al. Multi-institutional long-term experience with conservative surgery for invasive penile carcinoma. *J Urol.* 2003;169(2):500-2.
5. McDougal WS. Phallic preserving surgery in patients with invasive squamous cell carcinoma of the penis. *J Urol.* 2005;174(6):2218-20, discussion 2220.
6. Morelli G, Pagni R, Mariani C, Campo G, Menchini-Fabris F, Minervini R, et al. Glansectomy with split-thickness skin graft for the treatment of penile carcinoma. *Int J Impot Res.* 2009;21(5):311-4.
7. Shabbir M, Muneer A, Kalsi J, Shukla CJ, Zacharakis E, Garaffa G, et al. Glans resurfacing for the treatment of carcinoma in situ of the penis: surgical technique and outcomes. *Eur Urol.* 2011;59(1):142-7.
8. Veeratterapillay R, Sahadevan K, Aluru P, Asterling S, Rao GS, Greene D. Organ-preserving surgery for penile cancer: description of techniques and surgical outcomes. *BJU Int.* 2012;110(11):1792-5.
9. Regionala cancercentrum i samverkan. Peniscancer: Nationellt vårdprogram [Internet]. 2013 [cited 12 Apr 2014]; In Swedish. Available from: <http://www.cancercentrum.se/sv/Vardprogram/Peniscancer/>
10. Pizzocaro G, Algaba F, Solsona E, Tana S, van der Poel HG, Watkin N, et al. Guidelines on Penile Cancer. European Association of Urology. 2013.
11. Agrawal A, Pai D, Ananthakrishnan N, Smile SR, Ratnakar C. The histological extent of the local spread of carcinoma of the penis and its therapeutic implications. *BJU Int.* 2000;85(3):299-301.
12. Minhas S, Kayes O, Hegarty P, Kumar P, Freeman A, Ralph D. What surgical resection margins are required to achieve oncological control in men with primary penile cancer? *BJU Int.* 2005;96(7):1040-3.
13. Philippou P, Shabbir M, Malone P, Nigam R, Muneer A, Ralph DJ, et al. Conservative surgery for squamous cell carcinoma of the penis: resection margins and long-term oncological control. *J Urol.* 2012;188(3):803-8.
14. Gunia S, Koch S, Jain A, May M. Does the width of the surgical margin of safety or premalignant dermatoses at the negative surgical margin affect outcome in surgically treated penile cancer? *J Clin Pathol.* 2014;67(3):268-71.
15. Hadway P, Corbishley CM, Watkin NA. Total glans resurfacing for premalignant lesions of the penis: initial outcome data. *BJU Int.* 2006;98(3):532-6.
16. Hegarty PK, Shabbir M, Hughes B, Minhas S, Perry M, Watkin N, et al. Penile preserving surgery and surgical strategies to maximize penile form and function in penile cancer: recommendations from the United Kingdom experience. *World J Urol.* 2009;27(2):179-87.
17. Smith Y, Hadway P, Biedrzycki O, Perry MJ, Corbishley C, Watkin NA. Reconstructive surgery for invasive squamous carcinoma of the glans penis. *Eur Urol.* 2007;52(4):1179-85.
18. Palminteri E, Berdondini E, Lazzeri M, Mirri F, Barbagli G. Resurfacing and reconstruction of the glans penis. *Eur Urol.* 2007;52(3):893-8.
19. Maddineni SB, Lau MM, Sangar VK. Identifying the needs of penile cancer sufferers: a systematic review of the quality of life, psychosexual and psychosocial literature in penile cancer. *BMC Urol.* 2009;9:8.
20. Kieffer JM, Djajadiningrat RS, van Muilekom EA, Graafland NM, Horenblas S, Aaronson NK. Quality of life for patients treated for penile cancer. *J Urol.* 2014. [Epub ahead of print]
21. Feldman AS, McDougal WS. Long-term outcome of excisional organ sparing surgery for carcinoma of the penis. *J Urol.* 2011;186(4):1303-7.
22. Leijte JA, Kirrander P, Antonini N, Windahl T, Horenblas S. Recurrence patterns of squamous cell carcinoma of the penis: recommendations for follow-up based on a two-centre analysis of 700 patients. *Eur Urol.* 2008;54(1):161-8.
23. Lont AP, Gallee MP, Meinhardt W, van Tinteren H, Horenblas S. Penis conserving treatment for T1 and T2 penile carcinoma: clinical implications of a local recurrence. *J Urol.* 2006;176(2):575-80; discussion 580.

24. Djajadiningrat RS, van Werkhoven E, Meinhardt W, van Rhijn BW, Bex A, van der Poel HG, et al. Penile sparing surgery for penile cancer-does it affect survival? *J Urol*. 2013. [Epub ahead of print]
25. DePasquale I, Park AJ, Bracka A. The treatment of balanitis xerotica obliterans. *BJU Int*. 2000;86(4):459-65.
26. Austoni E, Fenice O, Kartalas Goumas Y, Colombo F, Mantovani F, Pisani E. [New trends in the surgical treatment of penile carcinoma]. *Arch Ital Urol Androl*. 1996;68(3):163-8.
27. Smith Y, Hadway P, Ahmed S, Perry MJ, Corbishley CM, Watkin NA. Penile-preserving surgery for male distal urethral carcinoma. *BJU Int*. 2007;100(1):82-7.
28. Kumar P, Singh S, Goddard JC, Terry TR, Summerton DJ. The development of a supraregional network for the management of penile cancer. *Ann R Coll Surg Engl*. 2012;94(3):204-9.
29. Bayles AC, Sethia KK. The impact of Improving Outcomes Guidance on the management and outcomes of patients with carcinoma of the penis. *Ann R Coll Surg Engl*. 2010;92(1):44-5.
30. National Institute for Clinical Excellence. Guidance on Cancer Services. Improving Outcomes in Urological Cancers – the Manual. London. 2002:83-5.

## **Legends to figures**

Figure 1. The glans resurfacing procedure includes dissection and removal of the epithelium and the subepithelial tissue of the glans (A), circumcision down to Buck's fascia (B), and reconstruction of the neoglans with a split skin graft from the thigh (C). The outcome after three months is shown in (D).

Figure 2. The total glansectomy with neoglans starts with a circumcision down to Buck's fascia and the division of the neurovascular bundle to identify the dissection plane between the glans and corporal heads (A). Glansectomy involves the complete excision of the glans from the corpora cavernosa, and division of the urethra freeing the specimen (B). The neoglans is constructed using a split skin graft from the thigh (C). The outcome after three months is shown in (D).





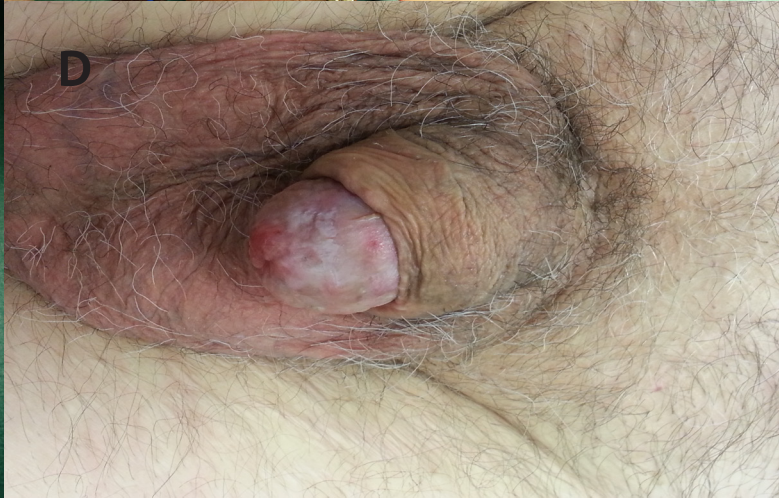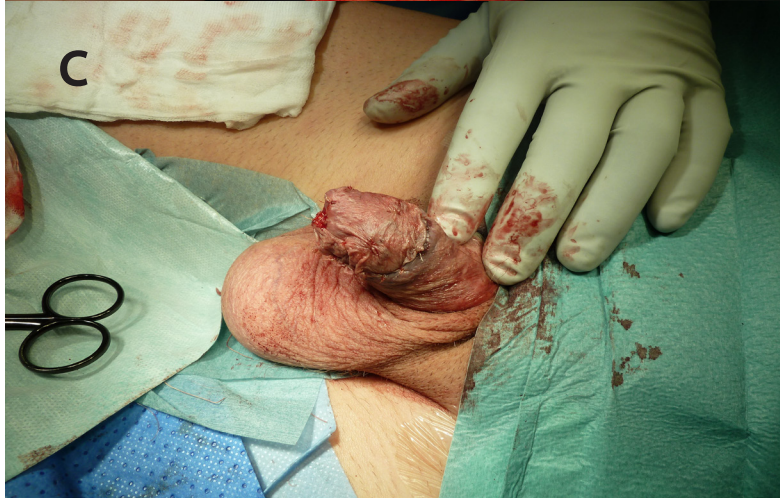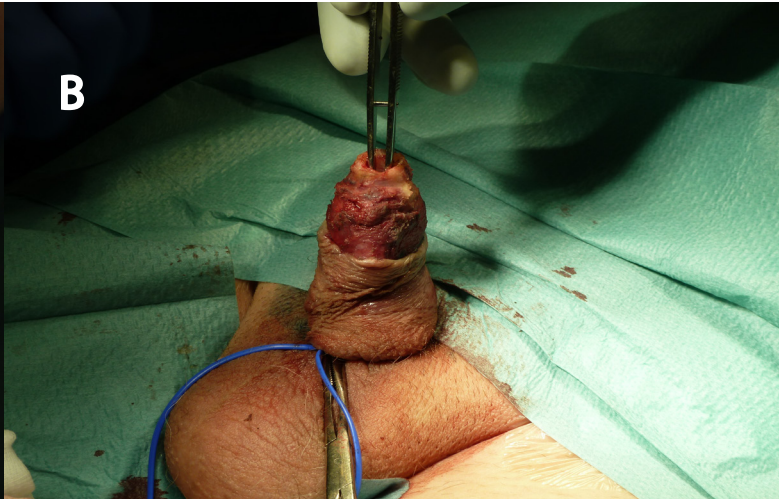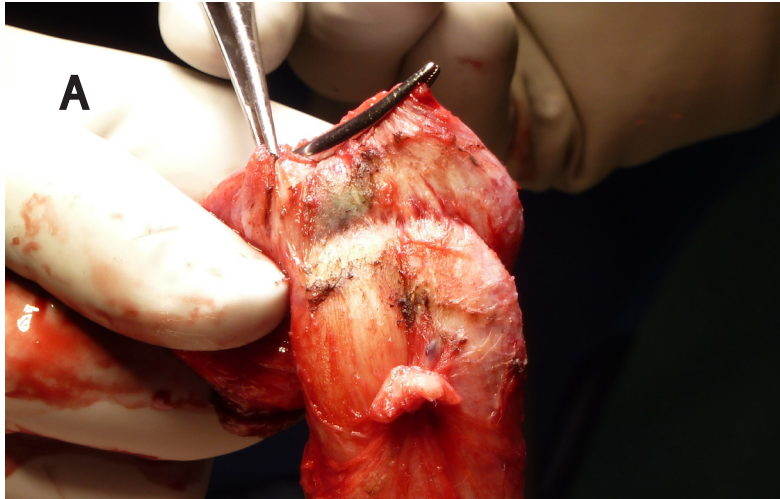


Table I. Basic characteristics of the 12 patients undergoing glans resurfacing (GR).

Patient no.	Hospital	Prior penile surgery	Age (y) <sup>1</sup>	Sentinel node biopsy	GR extent	Final pathology	Margins	FU (mo) <sup>2</sup>	Recurrence	Complications	Cosmetic and functional results <sup>3</sup>
1	SUS	Multiple	80	No	Total	pTis+BXO	Neg	40	None	None	Excellent
2	SUS	Multiple	41	No	Total	pTis	Neg	36	None	None	Excellent
3	SUS	None	73	No	Total	pTis	Neg	32	None	Wound infection	Good
4	SUS	Circumcision	76	No	Total	pTis	Neg	22	None	None	Excellent
5	SUS	None	63	No	Total	pTis	Neg	14	None	None	Good
6	SUS	None	83	No	Total	pTis	Neg	8	None	None	Good
7	SUS	Multiple	35	Yes	Total	pTisN0	Neg	4	None	Wound infection	Excellent
8	SUS	Multiple	46	No	Total	pTis+pT1aG1	Neg	5	None	None	Excellent
9	USÖ	None	75	No	Total	pTis	Neg	23	None	Pneumonia	Excellent
10	USÖ	Multiple	51	No	Partial	pTis+BXO	Neg	17	None	None	Poor
11	USÖ	Circumcision	68	No	Total	pTis	Neg	12	None	None	Excellent
12	USÖ	None	60	No	Total	pTis	Neg	14	None	None	Excellent

<sup>a</sup>Age at surgery (years); <sup>b</sup>follow-up time (months); <sup>c</sup>subjective assessment by the patient and the surgeon.

SUS = Skåne University Hospital; USÖ = Örebro University Hospital; BXO = balanitis xerotica obliterans; Neg = negative.



Table II. Basic characteristics of the 15 patients undergoing total glansectomy with neoglans reconstruction (TGN).

Patient no.	Hospital	Prior treatment	Age (y) <sup>a</sup>	Sentinel node biopsy	Final pathology	Margins	FU (mo) <sup>b</sup>	Recurrence	Complications	Cosmetic and functional results <sup>c</sup>
1	SUS	None	75	Yes	pT2G2N0	Neg	18	None	None	Good
2	SUS	None	60	Yes	pT3G2N0	Pos	25	None	None	Good
3	SUS	None	71	Yes	pT1G2N0	Neg	22	None	Graft infection	Excellent
4	SUS	None	48	Yes	pT2G2N0	Neg	22	None	None	Excellent
5	SUS	None	72	Yes	pT1G2N0 + BXO	Neg	19	None	None	Good
6	SUS	None	72	Yes	pT2G1N0	Neg	15	None	None	Good
7	SUS	Local resection (pT2 with positive margins)	60	Yes	pT0N0	-	10	None	None	Excellent
8	SUS	None	63	Yes	pT1G2N0	Neg	12	None	Graft infection	Excellent
9	SUS	Multiple	72	No	pT1G1Nx	Neg	10	None	None	Excellent
10	SUS	Irradiation	37	No	pT1Gx	Neg	8	None	None	Good
11	SUS	Multiple	53	No	pT2G1	Neg	5	None	None	Good
12	SUS	Multiple	50	No	pT1aG1 + BXO	Neg	2	None	None	Excellent
13	SUS	None	74	Yes	pT2G3N0	Neg	4	None	None	Excellent
14	SUS	Cryotherapy	78	No	pT1N0	Neg	1	None	None	Excellent
15	USÖ	None	72	No	pT1G1	Neg	3	None	None	Good

<sup>a</sup>Age at surgery (years); <sup>b</sup>follow-up time (months); <sup>c</sup>subjective assessment by the patient and the surgeon.

SUS = Skåne University Hospital; USÖ = Örebro University Hospital; BXO = balanitis xerotica obliterans; Neg = negative; Pos = positive