



# LUND UNIVERSITY

## Visualisation of the rectoanal inhibitory reflex with a modified contrast enema in children with suspected Hirschsprung disease.

Vult von Steyern, Kristina; Wingren, Pär; Wiklund, Marie; Stenström, Pernilla; Arnbjörnsson, Einar

*Published in:*  
Pediatric Radiology

*DOI:*  
[10.1007/s00247-013-2622-4](https://doi.org/10.1007/s00247-013-2622-4)

2013

[Link to publication](#)

### *Citation for published version (APA):*

Vult von Steyern, K., Wingren, P., Wiklund, M., Stenström, P., & Arnbjörnsson, E. (2013). Visualisation of the rectoanal inhibitory reflex with a modified contrast enema in children with suspected Hirschsprung disease. *Pediatric Radiology*, 43(8), 950-957. <https://doi.org/10.1007/s00247-013-2622-4>

*Total number of authors:*  
5

### **General rights**

Unless other specific re-use rights are stated the following general rights apply:  
Copyright and moral rights for the publications made accessible in the public portal are retained by the authors and/or other copyright owners and it is a condition of accessing publications that users recognise and abide by the legal requirements associated with these rights.

- Users may download and print one copy of any publication from the public portal for the purpose of private study or research.
- You may not further distribute the material or use it for any profit-making activity or commercial gain
- You may freely distribute the URL identifying the publication in the public portal

Read more about Creative commons licenses: <https://creativecommons.org/licenses/>

### **Take down policy**

If you believe that this document breaches copyright please contact us providing details, and we will remove access to the work immediately and investigate your claim.

LUND UNIVERSITY

PO Box 117  
221 00 Lund  
+46 46-222 00 00

## **Visualization of the rectoanal inhibitory reflex with a modified contrast enema in children with suspected Hirschsprung disease**

Kristina Vult von Steyern<sup>1</sup>, MD, Pär Wingren<sup>1</sup>, MD, Marie Wiklund<sup>1</sup>, MD, Pernilla Stenström<sup>2</sup>, MD, Einar Arnbjörnsson<sup>2</sup>, MD, Associate professor.

Centre for Medical Imaging and Physiology<sup>1</sup>, and Department of Paediatric Surgery<sup>2</sup>, Skåne University Hospital, Clinical Sciences Lund, Lund University, Sweden

Corresponding author:

Kristina Vult von Steyern

Centre for Medical Imaging and Physiology

Skåne University Hospital

S-221 85 Lund, Sweden

kristina.vult\_von\_steyern@med.lu.se

Phone +46 46-171000

Fax number +46 46-176165

**Key words:** Aganglionosis; Biopsy; Contrast enema; Hirschsprung disease; Rectoanal inhibitory reflex.

**Abbreviations:** ARM, anorectal manometry; CE, contrast enema; HD, Hirschsprung disease.

**ABSTRACT**

**Background:** Patients with Hirschsprung disease lack the normal rectoanal inhibitory reflex, which can be studied with anorectal manometry or ultrasound.

**Objective:** To see if the rectoanal inhibitory reflex could be visualized with a modified contrast enema, thereby increasing the diagnostic accuracy of the contrast enema and reducing the number of rectal biopsies.

**Materials and method:** 59 boys and 42 girls (median age 12 months) with suspected Hirschsprung disease were examined with a modified contrast enema, supplemented with two injections of cold, water-soluble contrast medium, in order to induce the reflex. Two paediatric radiologists evaluated the anonymised examinations in consensus. The contrast enema findings were correlated with the results of rectal biopsy or clinical follow-up.

**Results:** Five boys and one girl (median age 7.5 days) were diagnosed with Hirschsprung disease. The negative predictive value of the rectoanal inhibitory reflex was 100%. A contrast enema with signs of Hirschsprung disease in combination with an absent rectoanal inhibitory reflex had the specificity of 98% and sensitivity of 100% for Hirschsprung disease.

**Conclusion:** The modified contrast enema improves the x-ray diagnosis of Hirschsprung disease. By demonstrating the rectoanal inhibitory reflex in children without Hirschsprung disease the proportion of unnecessary rectal biopsies can be reduced.

## INTRODUCTION

Hirschsprung disease is a widely recognized clinical-pathological entity caused by a developmental disorder of the enteric nervous system. Hirschsprung disease occurs in one per 5000 live births and 80-90% of the cases are diagnosed in the neonatal period [1, 2]. The important diagnostic features of Hirschsprung disease are the combination of hypertrophic nerve trunks and aganglionosis, along a variable portion of the distal intestine starting from the internal anal sphincter [3-6]. This leads to a pathognomonic absence of the rectoanal inhibitory reflex [6]. The lack of progression of the peristaltic wave into the aganglionic segment of the intestine involved and absent or abnormal internal anal sphincter relaxation is the hallmark of Hirschsprung disease [7].

The diagnosis of Hirschsprung disease is based on rectal biopsy 1 – 3 cm above the dentate line [7, 8]. Contrast enema has a place in the diagnosis of Hirschsprung disease but is not essential to confirm it. The level of the transition zone found with the contrast enema can be used in the decision regarding whether a transanal, transabdominal laparoscopic or an open surgical approach should be used [9]. Anorectal manometry has frequently been used in combination with rectal biopsy and contrast enema in evaluating patients for Hirschsprung disease [2, 10]. Now there is a broad agreement that anorectal manometry is unnecessary to diagnose Hirschsprung disease [9]. The diagnostic value of the anorectal manometry is the finding of a rectoanal inhibitory reflex and thereby identifying children without Hirschsprung disease. Ultrasonography has been used for visualization of the rectoanal inhibitory reflex in children suspected of Hirschsprung disease [11]. The results indicated that in children with chronic constipation the transperineal ultrasound examination of the rectoanal inhibitory reflex was comparable to the anorectal manometry and could single out the children without Hirschsprung disease.

At our paediatric radiology department we tried the ultrasound method [11], but it was difficult to perform on non-anaesthetised children. The children did not cooperate well enough to lie in the dorsal lithotomy position, with the ultrasound probe placed in the perineum as well as having the tube in the rectum, and thus the ultrasound images generated were non-diagnostic.

The hypothesis of the study was that a modified contrast enema, supplemented with injections of cold contrast medium in the rectum in order to induce the rectoanal inhibitory reflex in children without Hirschsprung disease, could increase the diagnostic accuracy of the contrast enema and thereby reduce the need for rectal biopsies of

patients without Hirschsprung disease. At the same time the contrast enema could provide the information necessary in case an operative intervention was needed.

## **MATERIALS AND METHODS**

### **Study population**

In a prospective study between November 2007 and September 2011, 104 children with clinical symptoms of constipation and suspected Hirschsprung disease were examined with a modified contrast enema examination. Three examinations were excluded from the study since the fluoroscopy sequences had not been documented correctly and could therefore not be re-evaluated. The 101 remaining examinations were of 59 boys and 42 girls, 4 days–17 years old (mean age 25 months, median age 12 months). All the examinations were performed after a request from a paediatric surgeon, paediatrician or a physician according to the clinical routine. None of the patients had, within 24 hours of the examination, received an enema, undergone a digital rectal examination or disimpaction.

### **The modified contrast enema**

Since barium contrast agent is known to have a constipating effect, and water-soluble contrast media on the contrary may relieve these symptoms, Omnipaque® 140 mg/ml was used in all the patients except one (a 17-year-old boy, where the contrast media volume needed to fill the colon was expected to be very large).

Furthermore the use of a water-soluble contrast agent, particularly in infants, is safer since there may be a risk of perforation [12].

A 6 French feeding tube, cut to only have a single end-hole and burnt at the end to make it round at the tip, was inserted no more than 1 cm into the anal canal. Initial filling was made with the patient lying on the left side. To secure a perfect lateral view of the rectum the knees of the patient were placed on top of each other, and held in place by an assistant (parent, nurse or doctor). Water-soluble isotonic contrast medium (Omnipaque® 140 mg/ml) of body temperature was slowly injected during filming of the low pulse fluoroscopy sequence.

The modifications of the normal procedure, based on the studies of Örnö et al [11], were as follows: After the contrast medium had filled the rectum and the distal part of the sigmoid, the catheter was advanced into the central part of the ampulla recti. Two sequential fast (< 5 s.) injections of 20 ml of cold contrast agent (16°C)

were performed during documentation of the low pulse fluoroscopy sequences for about 30 seconds each. The anal canal, rectum and sigmoid were included in the field of view.

To avoid hypothermia the examination was then continued with contrast agent of body temperature, as part of the normal routine. If the colon had an abnormal appearance contrast medium was injected until a transition zone was identified or the whole colon was filled. When the findings were normal the injection was stopped when the descending colon was filled. 24 hours after the examination a supine image of the abdomen and a lateral view of the rectum were obtained.

### **Methods of evaluating the contrast enema and the rectoanal inhibitory reflex**

Two experienced paediatric radiologists reviewed the anonymised examinations and evaluated them in consensus for quality, signs of Hirschsprung disease or other abnormalities, and the presence of a rectoanal inhibitory reflex.

Signs of Hirschsprung disease were defined according to the literature [6, 12-14] (Fig. 1a,b):

- Recto-sigmoid ratio  $<1$  (maximum width of the rectum divided by the maximum width of the sigmoid; abnormal if  $<1$ )
- A transition zone (a calibre change between a narrowed or normal-sized distal aganglionic segment and a dilated proximal ganglionic bowel)
- Serrations, irregular contractions of the wall of the aganglionic segment, spasm and/or mucosal irregularity
- Retained contrast on delayed radiographs

The first phase of the rectoanal inhibitory reflex presents as a movement of contrast medium into the anal canal, with a dilatation of the anal lumen or a complete opening of the sphincter, with emptying of the rectal contents.

The second phase is a contraction of the internal anal sphincter, with a decrease of the lumen diameter and a closing of the anal canal. In the third phase a retrograde transport of contrast medium to the sigmoid occurs. In cases of an inconclusive or nonreactive test the rectum was dilated by the contrast agent injection, but no opening or closing of the sphincter was seen. In some cases of Hirschsprung disease, when the distal aganglionic segment was spastic and contracted, an explosive emptying of the rectum was seen when the catheter was inserted or when the medium was injected. The rectoanal inhibitory reflex was assessed as present if the two first

phases or all three phases of the reflex [11] were seen (in severe constipation the third phase is not always possible to observe) (Fig. 2 and Electronic supplementary material).

### **Ethical considerations**

Intention to treat was the main analysis strategy and encompassed all the patients. The regional research ethics committee approved the study (registration number 2010/49). The data are presented in such a way that it is impossible to identify any single patient and therefore it was not necessary to obtain approval from the individual patients and their guardians.

### **Statistical considerations**

Analysis of data was performed using SPSS 21 (statistical package for social sciences), IBM (Amonk, New York, United States), with the Fisher's exact test, two tailed. A p value < 0.05 was considered significant.



## RESULTS

The demography of the 101 children examined with the modified contrast enema as well as their age at the time of the examination are summarized in Table 1. The anonymized contrast enema examinations were first evaluated for the morphological appearance of the bowel and categorized as: normal contrast enema, pathological contrast enema but without signs of Hirschsprung disease, or pathological contrast enema with signs of Hirschsprung disease. Then the rectoanal inhibitory reflex was assessed as present or inconclusive/absent, resulting in 6 subgroups. In 32 cases a rectal biopsy was performed and in 69 cases the patients improved on clinical follow-up after treatment with conventional conservative therapy for their constipation (Table 2). None of the patients were examined with anorectal manometry, since this method is not used anymore for patients with suspected Hirschsprung disease at our hospital.

In 84 patients the contrast enema was normal and among these a normal rectoanal inhibitory reflex was observed in 73 cases (Tables 2 and 3). In 4 patients the contrast enema was considered pathological but without signs of Hirschsprung disease, in three of these cases the rectoanal inhibitory reflex was inconclusive or absent (two of these patients were later diagnosed with colitis) (Tables 2 and 4).

Thirteen contrast enema studies were assessed as pathological with signs of Hirschsprung disease, in 5 of these a normal rectoanal inhibitory reflex was observed and in 8 the rectoanal inhibitory reflex was inconclusive or absent (Table 2). In this subgroup of 8 patients with an abnormal contrast enema with signs of Hirschsprung disease and inconclusive or absent rectoanal inhibitory reflex 6 had a biopsy verified Hirschsprung disease and were operated on with transanal endorectal pull-through (Table 5).

In this study a pathological contrast enema with signs of Hirschsprung disease in combination with an absent rectoanal inhibitory reflex, thus had the specificity of 98% and the sensitivity of 100% for Hirschsprung disease, compared with 93% specificity and 100% sensitivity of the contrast enema alone and 83% specificity and 100% sensitivity of the rectoanal inhibitory reflex alone (Table 6). The negative predictive value of the rectoanal inhibitory reflex was 100%. The positive predictive value (PPV) of a pathological contrast enema with signs of Hirschsprung disease in combination with an absent rectoanal inhibitory reflex was 75%, but the PPV for the rectoanal inhibitory reflex alone was only 27% (Table 6). Among the six children with Hirschsprung disease (5

boys and 1 girl), four were 10 days or younger, one was one month old and one was three years old when examined (Table 1). In the other five subgroups no patient had Hirschsprung disease, proven by biopsy or clinical follow-up, and these children were successfully treated by conventional conservative therapy for their constipation.

For 93 of the 101 patients in the study dose area products (DAP) and total fluoroscopy times were registered in the Intulo database. Unfortunately it was not possible to read out the DAP values for the cold contrast injection fluoroscopy sequences or the exposed images separately. The fluoroscopy time for each cold contrast injection could be calculated by reviewing the examinations in the PACS system. The rectoanal inhibitory reflex examinations were recorded (by filming of the cold contrast medium injections) once in 8 patients, twice in 78 patients and 3 three times in 7 patients (Table 7). The mean length of the fluoroscopy sequences examining the rectoanal inhibitory reflex was 26.2 s and the sequences contributed in average to 28.7% of the total fluoroscopy time. The contrast enema examinations were performed using only fluoroscopy in most cases, but the two images after 24 h were with a few exceptions exposed images contributing significantly to the registered total DAP values.

## DISCUSSION

In the present study the modified contrast enema, based on the method used by Örnö et al [11], was applied in the investigation of constipated children. The events associated with the rectoanal inhibitory reflex were very distinct and usually easy to detect. In children without Hirschsprung disease peristalsis in the rectum was induced by the stimulation of a cold contrast agent, initiating a wave of contrast medium and rectal contents moving into the anal canal, with subsequent closing of the anal canal and retrograde movement of contrast agent.

It is important to detect the children with Hirschsprung disease in the large group of children with constipation, but also to avoid exposing children without Hirschsprung disease to rectal biopsy. Conventional contrast enema is not a sufficient diagnostic tool to rule out Hirschsprung disease, with a mean sensitivity of only 70% and specificity of 83% in a review of 12 studies for a total of 425 patients [2]. The results of the present study indicate that it is possible with the modified contrast enema to rule out Hirschsprung disease in children with severe constipation if the rectoanal inhibitory reflex is present, the negative predictive value of the rectoanal inhibitory reflex was 100% (Table 6). By combining the findings of the contrast enema and the rectoanal inhibitory reflex examination Hirschsprung disease could be detected with 98% specificity and 100% sensitivity. The positive predictive value (PPV) of a pathological contrast enema with signs of Hirschsprung disease in combination with an absent rectoanal inhibitory reflex was 75%, but the PPV for the rectoanal inhibitory reflex alone was only 27% (which is comparable to the PPV of 30% reported by Örnö et al [11]) (Table 6). These values are expected to improve with more experience in the modified contrast enema method and in the interpretation of the rectoanal inhibitory reflex. We also believe that by increasing the volumes of the contrast agent injections in larger children, which has been implemented after this study was closed, the visualisation of the normal reflex in this group of patients will improve. The study population is small, but the results are comparable with those reported from rectal suction biopsy [2].

Constipation is a common problem in children and most patients can be treated successfully with conservative therapy. Children with severe constipation may reach a limit in the gravity of their symptoms necessitating the ruling out of more serious disorders, such as Hirschsprung disease. These children are usually examined with a contrast enema. The contrast enema has up to now been used in many centres mainly for evaluating the level of

aganglionosis, but can be of value as an initial diagnostic test at centres that lack facilities for biopsy or anorectal manometry [13]; and a normal enema in this setting allows the continuation of medical therapy with further evaluation only if there is a lack of response [15]. When the radiological investigation raises suspicion of aganglionosis or is inconclusive further examination with anorectal manometry may be performed. To finally confirm or exclude Hirschsprung disease a rectal biopsy is mandatory, in the search for histological findings of aganglionosis and neuronal hypertrophy.

The use of anorectal manometry is based on the discovery that children affected by Hirschsprung disease lack the normal rectoanal inhibitory reflex [16]. The rectoanal inhibitory reflex presents as a relaxation of the internal anal sphincter in response to a distention of the rectum, by stimulation of mechanoreceptors of the rectal wall and activation of intramural inhibiting neurons in the myenteric plexus [6]. A method for visualizing the rectoanal inhibitory reflex on transperineal ultrasound, after injection of cold water in the rectum, has been described by Örnö et al [11] and found comparable to anorectal manometry. When the rectoanal inhibitory reflex was found on ultrasound it enabled identification of the children who did not require further investigation. Among the 28 children with suspected Hirschsprung disease in the study by Örnö et al 10 lacked the rectoanal inhibitory reflex. In this group 3 patients showed aganglionosis in their biopsy sample, but in 7 patients without Hirschsprung disease ultrasound failed to reveal the rectoanal inhibitory reflex. As in the present study the negative predictive value of the rectoanal inhibitory reflex was 100%.

In the group of 95 patients without Hirschsprung disease the rectoanal inhibitory reflex was inconclusive or absent in 16 patients (Table 2). In four of these the fluoroscopy sequences documenting the injection of cold contrast medium were short, and the normal reflex may have been missed. In seven cases the children were older than 3 years. We have experienced that it can be more difficult to visualise the normal reflex when the child is older, since they often find the examination unpleasant and thus contract the outer sphincter and lift the pelvic floor. In addition, the injected volume of cold contrast medium was 20 ml for each injection, irrespective of the age and size of the patient, and this may also have influenced the ability to induce the normal reflex in bigger children. When the rectum is larger the effect of the cold medium is reduced, in particular if the rectum is filled with stool. After the present study was closed we therefore changed the protocol and increased the volume of injected cold contrast agent to 30 ml x 2 for children of 15-25 kg and 50 ml x 2 for children of >25 kg. For children weighing <15 kg the injected volume is still 20 ml x 2.

Five of the children without Hirschsprung disease and with an inconclusive or absent rectoanal inhibitory reflex were severely constipated when examined. Severe constipation can render it more difficult to induce the normal rectoanal inhibitory reflex, and if the rectum is distended by faeces it is recommendable to end the examination before injecting contrast medium and instead take the patient back after laxative treatment. Two patients with an inconclusive or absent rectoanal inhibitory reflex were diagnosed with colitis and one patient with a motility disorder of the bowel. These diagnoses can also make it more difficult to induce the normal reflex.

The length of the fluoroscopy sequences documenting the rectoanal inhibitory reflex in the study varied from 3 s to 81 s (mean length 26 s, median length 24 s), depending on the experience of the radiologist and the cooperation of the patient (Table 7). In most cases a sequence of 20-30 s would be optimal, in order not to miss the reflex but still not expose the patient to unnecessary radiation. If the reflex is clearly seen in the first examination there is no need to perform a second injection of cold contrast medium. To reduce the radiation dose of the modified contrast enema we have, after the study was closed, stopped taking exposed x-ray images after 24 h and instead save fluoroscopy images of the abdomen supine and the lateral view of the rectum.

The age of the children in the study cohort is summarised in Table 2, showing that none of the 6 children with Hirschsprung disease was older than 3 years of age, and 83% were one month or less. In a large group of children with Hirschsprung disease reported in the literature [17] 38% were < 1 month, 50% were 1 month–3 years of age and 12% were older than 3 years of age. In Sweden child welfare centre care is free of charge and the majority of children are examined regularly from birth, which may explain why 5 out of 6 patients with Hirschsprung disease in the present study were diagnosed in the neonatal period. The child who was diagnosed with Hirschsprung disease later came to Sweden as a refugee at 3 years of age and was diagnosed soon after arrival.

Since the study started in November 2007 to the present date 55 rectal biopsies have been performed at the department of Paediatric Surgery, thus an average of 11 biopsies a year. Among the 101 study patients 32 were biopsied, the remaining 23 rectal biopsies were performed on children who previously had been examined with a contrast enema at their local hospital (and therefore were not included in the study) or performed after the present study was closed in September 2011. During the five years before the study began 32 biopsies were

taken on average annually. Thus, since the start of the study, the number of biopsies performed on children with suspected Hirschsprung disease at our hospital has decreased by about 65%, as the surgeons have felt more confident with the results of the modified contrast enema with the additional information provided by the rectoanal inhibitory reflex examination. Many patients who previously would have been biopsied have, as the contrast enema was normal and the rectoanal inhibitory reflex was present, instead received conventional conservative treatment and clinical follow-up. None of these patients was later diagnosed with Hirschsprung disease and all improved with treatment. Still 32 of the 101 patients in the study were biopsied. According to the results of this study only the 8 patients with pathological contrast enema with signs of Hirschsprung disease and with an absence of the rectoanal inhibitory reflex would have needed a biopsy.

The collection of patients is still on going and a multicentre study is planned, with the aim to validate the method in a larger study population and also evaluate intra- and interobserver reproducibility. Since the objective of the present study was to see if the rectoanal inhibitory reflex could be studied with a modified contrast enema, as a pilot study, we therefore decided it was sufficient at this point with a consensus evaluation of the examinations.

In particular at centres where diagnostic rectal biopsies are not commonly performed and the surgical decision is mainly based on clinical symptoms and the outcome of the contrast enema, the modified contrast enema with evaluation of the rectoanal inhibitory reflex can be very helpful and increase the diagnostic accuracy significantly. Since the study population is quite small, the method has to be tested further in larger prospective clinical studies.

## CONCLUSION

By using the modified contrast enema it is possible to disclose the normal rectoanal inhibitory reflex in patients without Hirschsprung disease. The present study indicates that when the rectoanal inhibitory reflex is present aganglionosis can be ruled out, increasing the diagnostic accuracy of the contrast enema. The number of unnecessary rectal biopsies of children without Hirschsprung disease could thus be reduced. To validate the results, the method has to be evaluated further in larger prospective clinical studies.

**REFERENCES**

1. Amiel J, Sproat-Emison E, Garcia-Barcelo M et al (2008) Hirschsprung disease, associated syndromes, and genetics: a review. *J Med Gen* 45:1-14.
2. de Lorijn F, Kremer LCM, Reitsma JB, Benninga MA (2006) Diagnostic tests in Hirschsprung disease: a systematic review. *J Pediatr Gastroenterol Nutr* 42:496-505.
3. Kessmann J (2006) Hirschsprung's disease: diagnosis and management. *Am Fam Physician* 74:1319-1322.
4. Khan AR, Vujanic GM, Huddart S (2003) The constipated child: how likely is Hirschsprung's disease? *Pediatr Surg Int* 19:439-442.
5. de Lorijn F, Reitsma JB, Voskuil WP et al (2005) Diagnosis of Hirschsprung's disease: a prospective, comparative accuracy study of common tests. *J Pediatr* 146:787-792.
6. de Lorijn F, Boeckxstaens GE, Benninga MA (2007) Symptomatology, pathophysiology, diagnostic work-up, and treatment of Hirschsprung disease in infancy and childhood. *Curr Gastroenterol Rep* 9:245-253.
7. Burki T, Sinha CK, Yamataka A (2010) Hirschsprung's Disease 3.9. *Handbook of Pediatric Surgery* 3:117-124.
8. Pini Prato A, Martucciello G, Jasonni V (2001) Solo-RBT: a new instrument for rectal suction biopsies in the diagnosis of Hirschsprung's disease. *J Pediatr Surg* 36:1364-1366.
9. Martucciello G, Pini Prato A, Puri P et al (2005) Controversies concerning diagnostic guidelines for anomalies of the enteric nervous system: a report from the fourth International Symposium on Hirschsprung's disease and related neurocristopathies. *J Pediatr Surg* 40:1527-1531.
10. Emir H, Akman M, Sarimurat N et al (1999) Anorectal manometry during the neonatal period: its specificity in the diagnosis of Hirschsprung's disease. *Eur J Pediatr Surg* 9:101-103.
11. Örnö AK, Lökvist H, Marsal K et al (2008) Sonographic visualization of the rectoanal inhibitory reflex in children suspected of having Hirschsprung disease: a pilot study. *J Ultrasound Med* 27:1165-1169.
12. O'Donovan AN, Habra G, Somers S et al (1996) Diagnosis of Hirschsprung's disease. *AJR Am J Roentgenol* 167:517-520.



13. Diamond IR, Casadiego G, Traubici J et al (2007) The contrast enema for Hirschsprung disease: predictors of a false-positive result. *J Pediatr Surg* 42:792-795.
14. Garcia R, Arcement C, Hormaza L et al (2007) Use of the recto-sigmoid index to diagnose Hirschsprung's disease. *Clin Pediatr* 46:59-63.
15. Reid JR, Buonomo C, Moreira C, et al. (2000) The barium enema in constipation: comparison with rectal manometry and biopsy to exclude Hirschsprung's disease after the neonatal period. *Pediatr Radiol* 30:681-684.
16. Lawson JON, Nixon HH (1967) Anal canal pressures in the diagnosis of Hirschsprung's disease. *J Pediatr Surg* 2:544-552.
17. Lopera C, Stenström P, Anderberg M et al (2012) Literature review of the frequency of reoperations after one stage transanal endorectal pull-through procedure for Hirschsprung's disease in children. *Surgical Science* 3:290-294.

**FIGURE LEGENDS**

**Table 1.** The age distribution of the cohort of children and those with Hirschsprung disease examined with the modified contrast enema, compared with the age distribution of children with Hirschsprung disease and operated on with the transanal endorectal pull-through procedure [17]

**Table 2.** The modified contrast enema examinations were evaluated for the morphological appearance of the bowel and the presence or absence of the normal rectoanal inhibitory reflex. In parentheses is the number of patients biopsied in each group.

**Table 3.** The contrast enema in the detection of Hirschsprung disease

**Table 4.** The rectoanal inhibitory reflex in the detection of Hirschsprung disease

**Table 5.** The combination of contrast enema and rectoanal inhibitory reflex in the detection of Hirschsprung disease

**Table 6.** The increase of the diagnostic accuracy of the modified contrast enema in the detection of Hirschsprung disease, by combining the results of the contrast enema with the rectoanal inhibitory reflex examination

**Table 7.** For 93 of the 101 patients in the study the dose area product (DAP) and the total fluoroscopy time for the contrast enema examinations were registered. The lengths of the fluoroscopy sequences of the cold contrast medium injections were calculated by reviewing the examinations in the PACS system.

**Fig. 1.** Contrast enema in a 1-month-old boy with Hirschsprung disease. Typical findings of Hirschsprung disease with recto-sigmoid ratio  $<1$ , a contracted distal aganglionic segment (*arrowheads*) and a rectosigmoid transition zone (*arrows*) (**a** and **b**). When the cold contrast agent was injected an explosive emptying of the bowel was seen (*arrow*), but no rectoanal inhibitory reflex (**c**).

**Fig. 2.** A 2-year-old girl with clinical symptoms of constipation. The contrast enema was normal and the rectoanal inhibitory reflex present. Before injection of the cold contrast medium (**a**). The first phase of the rectoanal inhibitory reflex is seen as a movement of the contrast agent into the anal canal, with a dilatation of the anal lumen (*black arrows*) (**b** and **c**). The second phase is seen as a contraction of the internal anal sphincter, with a decrease of the lumen diameter (*black arrow*) (**d**) and a subsequent closing of the anal canal (*black arrow*) (**e**). Almost simultaneously the third phase occurs, with a retrograde transport of contrast medium to the sigmoid (*white arrows*) (**d** and **e**).

**ELECTRONIC SUPPLEMENTARY MATERIAL (ESM) LEGENDS**

**ESM 1.** Normal contrast enema and normal rectoanal inhibitory reflex, in a 1-month-old girl without Hirschsprung disease. When the cold contrast agent is injected a dilatation of the rectum is seen. After 3–4 s the first phase of the reflex is seen as an opening of the anal canal, which remains open until the closing begins after about 7–8 s from the start of the injection (the second phase of the reflex). Almost simultaneously a retrograde transport of the contrast agent is seen to the sigmoid (the third phase of the reflex).

**ESM 2.** Normal contrast enema and normal rectoanal inhibitory reflex, in a 2-year-old girl without Hirschsprung disease. After 4–5 s an opening of the anal canal is seen. After 18 s the anal canal begins to close again and a retrograde transport of contrast medium is seen to the oral part of the rectum.

**ESM 3.** Pathological recto-sigmoid index  $<1$ , but the rectoanal inhibitory reflex is present, in a 1-month-old boy without Hirschsprung disease. Four s after the start of the injection the anal canal begins to open and contrast agent is seen along the catheter in the anal canal. After 14 s the anal canal begins to close again.

**ESM 4.** The recto-sigmoid index is pathological ( $<1$ ) before the injection of the cold contrast agent, in a 3-week-old boy without Hirschsprung disease. The child is moving during the examination, which makes it more difficult to evaluate, and the sequence documenting the injection is too short (only 14 s), but still the reflex can be seen. After 7–8 s an opening of the anal canal is seen and after 11 s it begins to close again.

**ESM 5.** The recto-sigmoid index is pathological ( $<1$ ) before the injection of the cold contrast agent, in a 1-month-old girl without Hirschsprung disease. The rectoanal inhibitory reflex is present. The catheter tip is placed slightly too high (should be in the central part of the ampulla recti). After 6 s the anal canal begins to open. After 9–10 s it closes again and retrograde transport of contrast agent is seen to the sigmoid.

**ESM 6.** The recto-sigmoid index is pathological ( $<1$ ) before the injection of the cold contrast agent and the rectum is contracted and irregular, in a 2-week-old girl without Hirschsprung disease. The rectoanal inhibitory reflex is present. After 2 s an opening of the anal canal is seen with subsequent emptying of contrast agent. After 6 s the anal canal closes again. A second opening of the anal canal is seen after 8 s, and begins to close again after 11 s.

**ESM 7.** A 1-month-old boy later diagnosed with Hirschsprung disease. The contrast enema is pathological and the rectoanal inhibitory reflex is absent. When the cold contrast agent is injected irregular contractions are seen in the rectum and an explosive emptying of the bowel is seen.

**ESM 8.** A 3-year-old boy later diagnosed with Hirschsprung disease. The contrast enema is pathological and the rectoanal inhibitory reflex is absent. When the cold contrast agent is injected a slight dilatation of the rectum is seen, but no opening of the anal canal.

**Table 1.**

|                   |                   | 101 children examined with the modified contrast enema |                                    | 555 children with Hirschsprung disease, operated with transanal rectal pull-through [17] |
|-------------------|-------------------|--|------------------------------------|--|
|                   |                   | All children   | Children with Hirschsprung disease |  |
| Female/male ratio |                   | 1/1.4  | 1/5                                | 1/3.3  |
| Neonates          | ≤ 4 weeks         | 17 (17%)   | 5 (83%)                            | 213 (38%)  |
| Babies            | > 4 weeks -1 year | 32 (32%)   | 0 (0%)                             | 196 (35%)  |
| Toddlers          | 1 - 3 years       | 25 (25%)   | 1 (17%)                            | 82 (15%)   |
| Children          | > 3 years         | 27 (27%)   | 0                                  | 64 (12%)   |
| Sum               |                   | 101  | 6                                  | 555  |

**Table 2.**

|   | Total number of patients | Rectoanal inhibitory reflex present | Rectoanal inhibitory reflex inconclusive or absent |
|---|--------------------------|-------------------------------------|--|
| Normal contrast enema   | 84 (18)                  | 73 (14)                             | 11 (4)   |
| Pathological contrast enema without signs of Hirschsprung disease | 4 (2)                    | 1 (0)                               | 3 (2)  |
| Pathological contrast enema with signs of Hirschsprung disease    | 13 (12)                  | 5 (4)                               | 8* (8)   |

\*All 6 patients with Hirschsprung disease in the study had a pathological contrast enema with signs of Hirschsprung disease and an inconclusive or absent rectoanal inhibitory reflex.

**Table 3.**

|  | Hirschsprung<br>disease | Normal | Sum |
|--|-------------------------|--------|-----|
| Contrast enema<br>pathological with signs of<br>Hirschsprung disease | 6                       | 7      | 13  |
| Contrast enema without<br>signs of Hirschsprung<br>disease           | 0                       | 88     | 88  |
| Sum  | 6                       | 95     | 101 |

P<0.001 (Fisher's exact test, two tailed)



**Table 4.**

|  | Hirschsprung<br>disease | Normal | Sum |
|--|-------------------------|--------|-----|
| Rectoanal inhibitory<br>reflex inconclusive or<br>absent | 6                       | 16     | 22  |
| Rectoanal inhibitory<br>reflex present                   | 0                       | 79     | 79  |
| Sum  | 6                       | 95     | 101 |

P<0.001 (Fisher's exact test, two tailed)

**Table 5.**

|   | Hirschsprung<br>disease | Normal | Sum |
|---|-------------------------|--------|-----|
| Contrast enema<br>pathological with signs of<br>Hirschsprung disease,<br>rectoanal inhibitory<br>reflex inconclusive or<br>absent                                   | 6                       | 2      | 8   |
| Contrast enema without<br>signs of Hirschsprung<br>disease<br>or contrast enema with<br>signs of Hirschsprung<br>disease but rectoanal<br>inhibitory reflex present | 0                       | 93     | 93  |
| Sum   | 6                       | 95     | 101 |

P<0.001 (Fisher's exact test, two tailed)

**Table 6.**

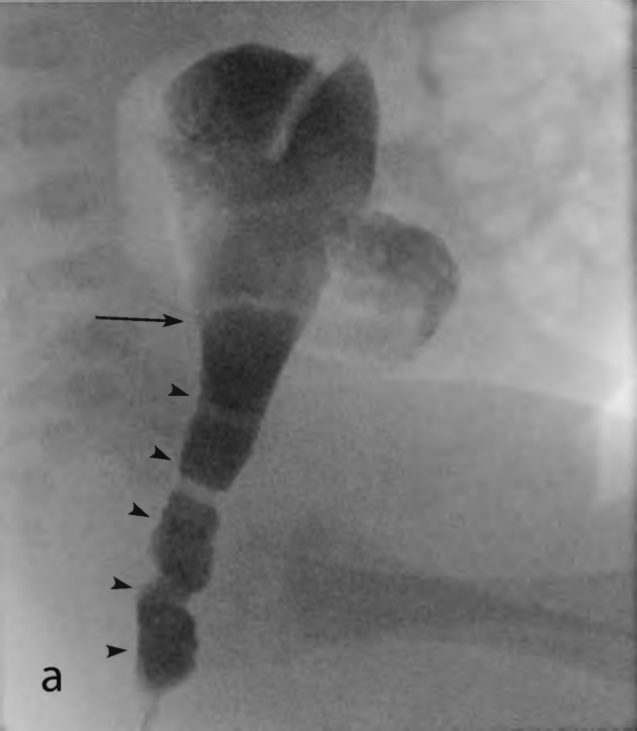
|  | Sensitivity | Specificity | PPV  | NPV |
|--|-------------|-------------|------|-----|
| Contrast enema                                     | 1           | 0.93        | 0.46 | 1   |
| Rectoanal<br>inhibitory reflex                     | 1           | 0.83        | 0.27 | 1   |
| Contrast enema +<br>Rectoanal<br>inhibitory reflex | 1           | 0.98        | 0.75 | 1   |

Positive predictive values (PPV). Negative predictive values (NPV).

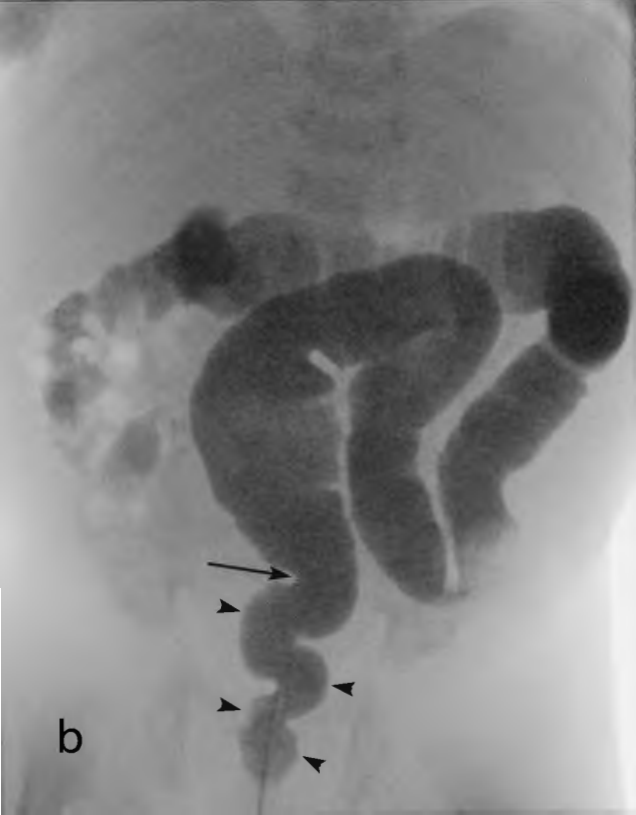**Table 7.**

|        | Age (months) | DAP (dGycm2) | Number of exposed images | Total fluoroscopy time for the contrast enema examination (s) | Fluoroscopy time for each cold contrast medium injection (s) | Total fluoroscopy time for the cold contrast medium injections (s) | Fluoroscopy time for the cold contrast medium injections in percentage of the total fluoroscopy time (%) |
|--------|--------------|--------------|--------------------------|---|--|--|--|
| Mean   | 23.7         | 0.49         | 2                        | 194.4   | 26.2   | 52.2   | 28.7   |
| SD     | 27.8         | 1.28         | 0.8                      | 79.5  | 15.1   | 29.2   | 15.3   |
| Median | 12           | 0.16         | 2                        | 175   | 24   | 48   | 26.3   |
| Min    | 0.1          | 0.02         | 0                        | 85  | 3  | 13   | 5.5  |
| Max    | 144          | 8.46         | 5                        | 537   | 81   | 151  | 84   |

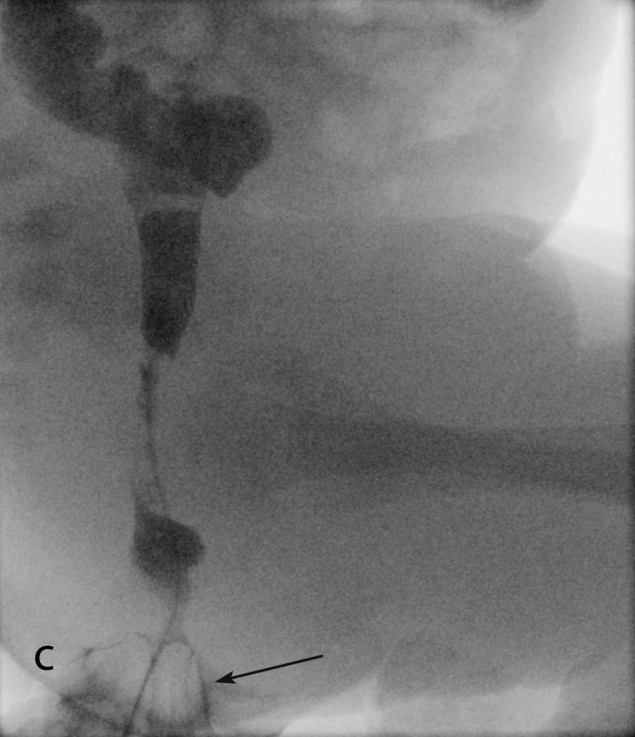
SD = standard deviation of the mean value



a

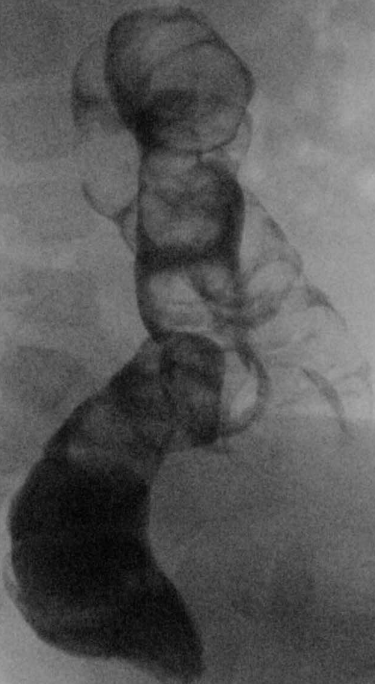


b



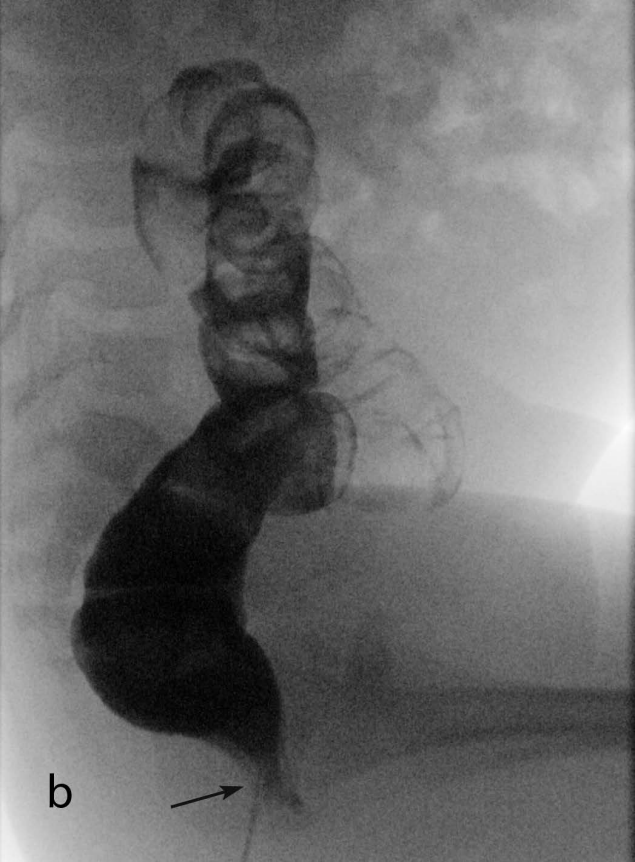
C





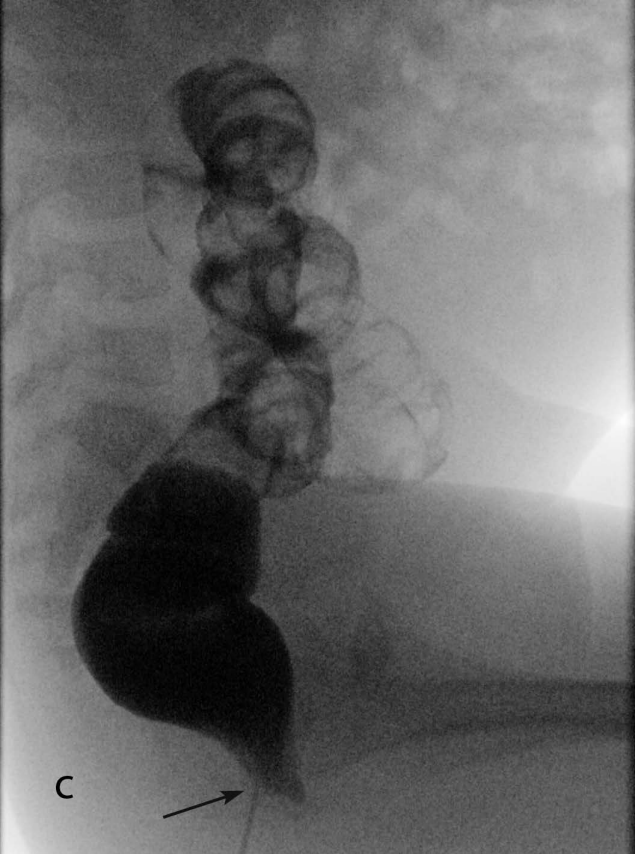a





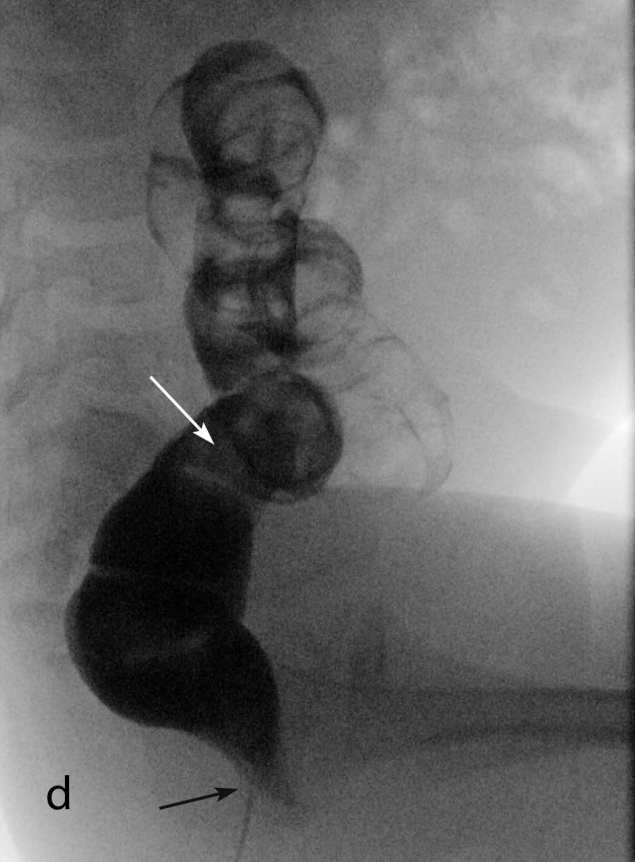
b



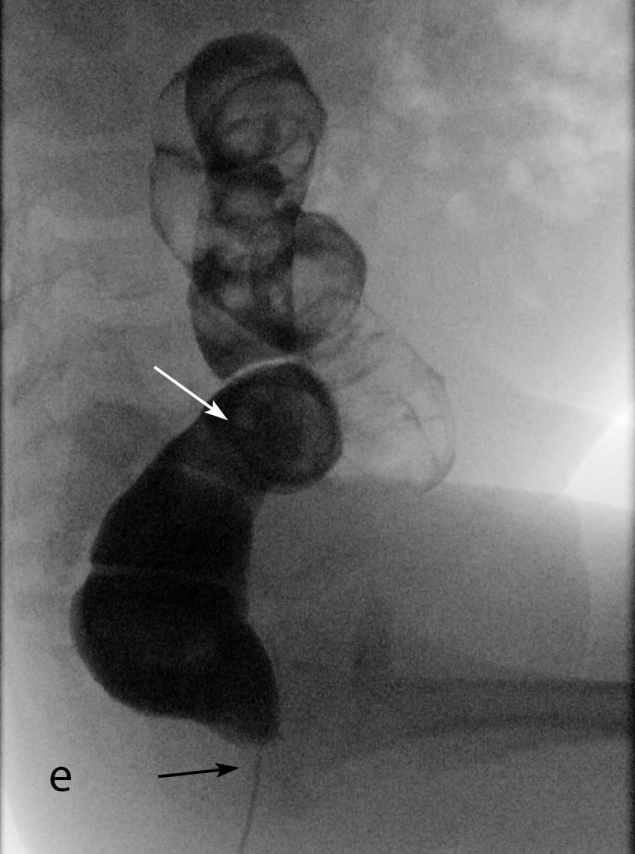


C





d



e