



# LUND UNIVERSITY

## Comparison between fundamental and second-harmonic imaging echocardiography for calculation of left ventricular mass in children.

Dencker, Magnus; Thorsson, Ola; Wollmer, Per

*Published in:*  
Clinical Physiology and Functional Imaging

*DOI:*  
[10.1111/j.1475-097X.2005.00612.x](https://doi.org/10.1111/j.1475-097X.2005.00612.x)

2005

[Link to publication](#)

*Citation for published version (APA):*  
Dencker, M., Thorsson, O., & Wollmer, P. (2005). Comparison between fundamental and second-harmonic imaging echocardiography for calculation of left ventricular mass in children. *Clinical Physiology and Functional Imaging*, 25(4), 223-225. <https://doi.org/10.1111/j.1475-097X.2005.00612.x>

*Total number of authors:*  
3

### General rights

Unless other specific re-use rights are stated the following general rights apply:  
Copyright and moral rights for the publications made accessible in the public portal are retained by the authors and/or other copyright owners and it is a condition of accessing publications that users recognise and abide by the legal requirements associated with these rights.

- Users may download and print one copy of any publication from the public portal for the purpose of private study or research.
- You may not further distribute the material or use it for any profit-making activity or commercial gain
- You may freely distribute the URL identifying the publication in the public portal

Read more about Creative commons licenses: <https://creativecommons.org/licenses/>

### Take down policy

If you believe that this document breaches copyright please contact us providing details, and we will remove access to the work immediately and investigate your claim.

LUND UNIVERSITY

PO Box 117  
221 00 Lund  
+46 46-222 00 00



This is an author produced version of a paper published in Clin Physiol Funct Imaging. This paper has been peer-reviewed but does not include the final publisher proof-corrections or journal pagination.

Citation for the published paper:

Dencker, M and Thorsson, O and Wollmer, P

"Comparison between fundamental and second-harmonic imaging echocardiography for calculation of left ventricular mass in children."

Clin Physiol Funct Imaging. 2005 Jul;25(4):223-5.

<http://dx.doi.org/10.1111/j.1475-097X.2005.00612.x>

Access to the published version may require journal subscription.

Published with permission from: Blackwell Synergy

# Comparison between fundamental and second-harmonic imaging echocardiography for calculation of left ventricular mass in children.

M. Dencker, O. Thorsson, P. Wollmer

Dept of Clinical Sciences, Malmö, Lund University, Sweden.

Running title; Echocardiography in children

Keywords; Echocardiography, Children, Left ventricular mass

Corresponding author:

Magnus Dencker  
Dept of Clinical Sciences, Malmö  
Clinical Physiology and Nuclear Medicine Unit  
University Hospital MAS  
205 02 Malmö, Sweden

E-mail: [magnus.dencker@skane.se](mailto:magnus.dencker@skane.se)

Phone: +46 40-338731

Fax +46 40-338768

## Abstract

In adults, calculation of left ventricular mass (LVM) has been shown to give higher values when based on M-mode measurements obtained by the second-harmonic imaging (SHI) technique than with the older fundamental imaging (FI) technique. No information is available in paediatric subjects. This study, therefore, compares LVM calculated from measurements obtained with SHI and FI in 14 children, aged 6.9-13.0 years. M-mode tracings were obtained in accordance with American Society of Echocardiography (ASE) recommendations. Three experienced sonographers performed measurements on each subject with both SHI and FI. The mean value was used in all calculations. LVM was calculated according to ASE convention and indexed by body surface area. LVM mean values were  $58.9 \pm 9.7$  g/m<sup>2</sup> for SHI and  $57.8 \pm 8.2$  g/m<sup>2</sup> for FI ( $p=0.45$ ). This preliminary study in a small group of paediatric subjects demonstrates no systematic differences between FI and SHI modalities in calculation of LVM. The likely explanation the left ventricular endocardial border is usually well visualised with SHI as well as with FI.

## Introduction

The introduction of second harmonic imaging (SHI) has greatly improved visualisation of the left ventricular (LV) endocardial border. This technique is now applied in routine echocardiography. One study in adults has shown that calculation of left ventricular mass (LVM) gives higher values when based on M-mode measurements obtained with (SHI) than with the older fundamental imaging (FI) technique (Mansencal et al., 2003). Another study found no difference (Graham et al., 2001). Validation of the equations for calculation of LVM has been based on FI M-mode recordings (Devereux & Reichek, 1977; Devereux et al., 1986). Determination of LVM based on M-mode SHI recordings has not been validated. In children, reference values of LVM are based on measurements using FI technique (Henry et al., 1978; Daniels et al., 1988; Huwez et al., 1994). No study has compared LVM based on M-mode measurements obtained with SHI and FI in paediatric subjects. Thus the purpose of this study was to compare LVM measurement obtained using M-mode SHI with those using FI in children.

## Methods

### Subjects

Fourteen children (11 boys and 3 girls), age 6.9-13.0 years, participated. All were healthy volunteers recruited among children of hospital staff. Subjects were included after informed consent was obtained from the parent or legal guardian. The local human research ethics committee approved the study.

### Anthropometric assessment

Height and weight were measured in the laboratory with the child dressed in light clothing.

Height was measured to the nearest cm using a fixed stadiometer. Weight was measured to the

nearest kg with a standard scale. Body surface area (BSA) was calculated as  $(\text{height in cm})^{0.725} \times (\text{weight in kg})^{0.425} \times 0.00718$  (Du Bois & Du Bois, 1916).

### Echocardiography

Echocardiographic examination was performed with subjects in the left lateral supine position with Sonos 2500 and Sonos 5500 (Philips, the Netherlands). Transducers with 3 Mhz were used for both machines. The Sonos 2500 is only equipped with FI whereas the Sonos 5500 is equipped with both FI and SHI. The rationale of using separate machines was that it forced the sonographer to reposition the probe in between measurements. Studies were performed with 2-dimensional (2-D) guided M-mode echocardiography obtained in the parasternal short-axis view, in accordance with American Society of Echocardiography (ASE) recommendations (Sahn et al., 1978). Three experienced sonographers performed two measurements from separate cardiac cycles on each subject with both echo machines. The mean value was used in all calculations. The following variables were measured: end-diastolic inter-ventricular septum (IVS), end-diastolic posterior wall (PW) and end-diastolic LV diameter (LVDD). LVM was calculated using ASE convention and the formula described by Devereux and co-worker (Devereux et al., 1986);  $\text{LVM} = 0.83 \times [(\text{LVDD} + \text{IVS} + \text{PW})^3 - \text{LVDD}^3] + 0.6$  (measurements in cm). LVM was indexed both to BSA (LVM/BSA) and also calculated as LVM divided by  $\text{height}^{2.7}$  (in meters;  $\text{LVM}/\text{H}^{2.7}$ ) (De Simone et al., 1992), which are the most common methods to adjust LVM measurement for body size.

### Statistics

All statistical analyses were performed using Statistica (Microsoft Inc). Means and standard deviations (SD) were calculated for all variables. Paired Student's t-test was used to analyse differences between means. Bland-Altman analysis (Bland & Altman, 1986) was used to identify the limit of agreement between FI and SHI. Univariate correlation was evaluated with Pearson correlation coefficient. A value of  $p < 0.05$  was regarded as a statistically significant difference.

## Results

Successful measurements were obtained from all subjects. Basic characteristics of the study population: age  $10.3 \pm 1.8$  years, height  $144 \pm 10$  cm, weight  $37.4 \pm 8.4$  kg and BSA  $1.2 \pm 0.2$  m<sup>2</sup>. A summary of the echocardiographic examination is shown in Table 1. Small, but statistically significant differences were found in the measurements of IVS and LVDD with the two techniques. We observed a strong correlation between LVM/m<sup>2</sup> mean values obtained with FI and those obtained with SHI (Figs. 1 and 2). There were no significant differences between the LVM as calculated from measurements using SHI or FI.

## Discussion

This preliminary study in a small group of paediatric subjects demonstrates no systematic differences between LVM determined by SHI and FI. There were small differences between SHI and FI in the measurement of LVDD and IVS. This did not affect the calculation of LVM because the slightly thicker IVS by SHI was matched by a slight decrease in LVDD. The difference in LVM index for SHI and FI remained the same, disregarding of method for adjusting the LVM measurements for differences in body size. The likely explanation for our finding is that the left ventricular endocardial border is usually well visualised in children and the use of either modality therefore does not affect the calculation of LVM.

The sole purpose of this study was to evaluate if there existed a fundamental difference in the two imaging techniques. A strength of our study is that three separate sonographers independently performed measurements on separate echo machines which reduces the variability in calculation of LVM. One shortcoming of the present study was that all measurements were not obtained in a



blind fashion. Also, we used the ASE convention only (Sahn et al., 1978), whereas other methods have been proposed (Devereux & Reichek, 1977). However, the ASE convention is the most commonly used. In addition, we only evaluated the effect of M-mode calculations and not any possible effect that might exist, if using 2-D calculations (Schiller et al., 1989).

The main purpose for the development of SHI was for use with contrast agents (Lindner et al., 1997). SHI has been shown to improve visualization of endocardial border in comparison with FI because of reduction in side-lobe artefacts, which lead to a darker ventricular cavity and brighter walls (Kornbluth et al., 1998; Rubin et al., 2000). Image quality is substantially improved and SHI is now fully incorporated in routine echocardiography. All published equations for calculation of LVM have, however, been validated using fundamental M-mode imaging and should not be applied uncritically to measurements with SHI. Our small pilot study suggests that there is no need for revision of these equations and the data obtained with SHI can indeed be used in equations derived from FI technique. One difficulty, when measuring LVM, is to avoid overestimation of LV wall thickness because of the inclusion of paraseptal and posterior wall structures (Keren et al., 1985). One reason for the reported differences in LVM values between FI and SHI techniques could be that with SHI, structures adjacent to the LV wall give clearer echoes that are difficult to separate from the echoes deriving from the LV wall itself. Our small study suggests that these problems of differentiating different LV wall structures may not apply in paediatric subjects and the likely explanation for this is that optimal acoustic window is almost always present.

Acknowledgement: The author is grateful to Ingrid Andersson, Anita Eriksson and Ewa Ericsson for performing excellent echocardiographic examinations.

## References

Bland JM, Altman DG. Statistical methods for assessing agreement between two methods of clinical measurement. *Lancet* (1986); 8: 307-310.

Daniels SR, Meyer RA, Liang YC, Bove KE. Echocardiographically determined left ventricular mass index in normal children, adolescents and young adults. *J Am Coll Cardiol* (1988); 12: 703-708.

De Simone G, Daniels SR, Devereux RB, Meyer RA, Roman MJ, De Divitiis O, Alderman MH. Left ventricular mass and body size in normotensive children and adults: assessment of allometric relations and impact of overweight. *J Am Coll Cardiol* (1992); 20: 1251–1260.

Devereux RB, Reichek N. Echocardiographic determination of left ventricular mass in man. Anatomic validation of the method. *Circulation* (1977); 55: 613–618.

Devereux RB, Alonso DR, Lutas EM, Gottlieb GJ, Campo E, Sachs I, Reichek N. Echocardiographic assessment of left ventricular hypertrophy: comparison to necropsy findings. *Am J Cardiol* (1986); 57: 450–458.

Du Bois D, Du Bois EF. *Arch Intern Med* (1916); 17: 863-871

Graham RJ, Gallas W, Gelman JS, Donelan L, Peverill, RE. An assessment of tissue harmonic versus fundamental imaging modes for echocardiographic measurements. *J Am Soc Echocardiogr* (2001); 14: 1191-1196.

Henry WL, Ware J, Gardin JM, Hepner SI, McKay J, Weiner M. Echocardiographic measurements in normal subjects. Growth-related changes that occur between infancy and early adulthood. *Circulation* (1978); 57: 278-285.

Huwez FU, Houston AB, Watson J, McLaughlin S, Macfarlane PW. Age and body surface area related normal upper and lower limits of M mode echocardiographic measurements and left ventricular volume and mass from infancy to early adulthood. *Br Heart J* (1994); 72: 276-280.

Keren A, Billingham ME, Popp RL. Echocardiographic recognition of paraseptal structures. *J Am Coll Cardiol* (1985); 6: 913–919.

Kornbluth M, Liang DH, Paloma A, Schnittger I. Native tissue harmonic imaging improves endocardial border definition and visualization of cardiac structures. *J Am Soc Echocardiogr* (1998); 11: 693–701.

Lindner JR, Dent JM, Moos SP, Jayaweera AR, Kaul S. Enhancement of left ventricular cavity opacification by harmonic imaging after venous injection of albunex. *Am J Cardiol* (1997); 79: 1657–1662.

Mansencal N, Bordachar P, Chatellier G, Redheuil A, Diebold B, Abergel E, Comparison of Accuracy of Left Ventricular Echocardiographic Measurements by Fundamental Imaging Versus Second Harmonic Imaging. *Am J Cardiol* (2003); 91: 1037-1039.

Rubin DN, Yazbek N, Garcia MJ, Stewart WJ, Thomas JD. Qualitative and quantitative effects of harmonic echocardiographic imaging on endocardial edge definition and side-lobe artifacts. *J Am Soc Echocardiogr* (2000); 13: 1012–1018.

Sahn DJ, DeMaria A, Kisslo J, Weyman A. Recommendations regarding quantitation in M-mode echocardiography: results of a survey of echocardiographic measurements. *Circulation* (1978); 58: 1072–1083.

Schiller NB, Shah PM, Crawford M, DeMaria A, Devereux R, Feigenbaum H, Gutgesell H, Reichek N, Sahn D, Schnittger I, et al. Recommendations for quantitation of the left ventricle by two-dimensional echocardiography. American Society of Echocardiography Committee on Standards, Subcommittee on Quantitation of Two-Dimensional Echocardiograms. *J Am Soc Echocardiogr* (1989); 2: 358-367.

Table 1. Summary of echocardiography findings. Second Harmonic Imaging (SHI) in comparison with Fundamental Imaging (FI) in all children (n=14). Mean values  $\pm$  standard deviation.

	SHI	FI	p-value
IVS (mm)	5.4 $\pm$ 0.8	5.2 $\pm$ 0.5	0.04
PW (mm)	6.4 $\pm$ 0.8	6.2 $\pm$ 0.6	0.25 ns
LVDD (mm)	42.9 $\pm$ 3.8	43.8 $\pm$ 3.8	0.01
LVM (g)	73.1 $\pm$ 20.5	71.6 $\pm$ 17.7	0.41 ns
LVM/BSA (g/m <sup>2</sup> )	58.9 $\pm$ 9.7	57.8 $\pm$ 8.2	0.45 ns
LVM/H <sup>2.7</sup> (g/m <sup>2.7</sup> )	34.7 $\pm$ 6.5	34.0 $\pm$ 5.2	0.40 ns

Figure legends;

Fig 1. Comparison between LVM/BSA (g/m<sup>2</sup>) derived from Second Harmonic Imaging (SHI) versus Fundamental Imaging (FI).

Fig 2. Bland-Altman diagram of the difference between LVM/BSA (g/m<sup>2</sup>) from Second Harmonic Imaging (SHI) versus Fundamental Imaging (FI).

Fig 1.

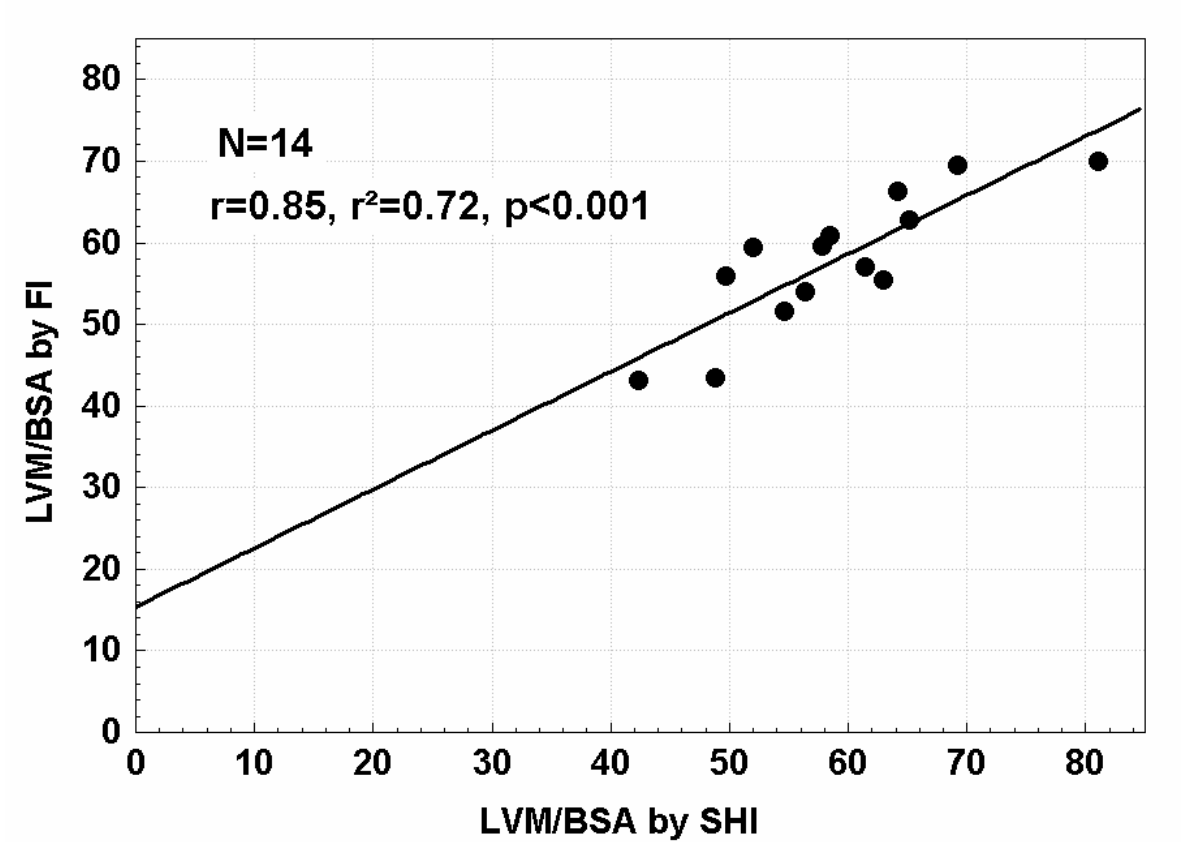


Fig 2.

