



LUND UNIVERSITY

Liver tissue characterization and influence of chemotherapy in liver surgery

Nilsson, Jan

2017

Document Version:

Publisher's PDF, also known as Version of record

[Link to publication](#)

Citation for published version (APA):

Nilsson, J. (2017). *Liver tissue characterization and influence of chemotherapy in liver surgery*. [Doctoral Thesis (compilation), Department of Clinical Sciences, Lund]. Lund University: Faculty of Medicine.

Total number of authors:

1

General rights

Unless other specific re-use rights are stated the following general rights apply:

Copyright and moral rights for the publications made accessible in the public portal are retained by the authors and/or other copyright owners and it is a condition of accessing publications that users recognise and abide by the legal requirements associated with these rights.

- Users may download and print one copy of any publication from the public portal for the purpose of private study or research.
- You may not further distribute the material or use it for any profit-making activity or commercial gain
- You may freely distribute the URL identifying the publication in the public portal

Read more about Creative commons licenses: <https://creativecommons.org/licenses/>

Take down policy

If you believe that this document breaches copyright please contact us providing details, and we will remove access to the work immediately and investigate your claim.

LUND UNIVERSITY

PO Box 117
221 00 Lund
+46 46-222 00 00

An anatomical illustration of a human torso, showing the ribcage, lungs, and internal organs. The liver is highlighted in a bright orange-red glow, and a small, dark, irregular mass representing a tumor is visible on its surface. The background is black, making the glowing organs stand out.

Liver tissue characterization and influence of chemotherapy in liver surgery

JAN NILSSON

DEPARTMENT OF SURGERY | LUND UNIVERSITY



Liver tissue characterization and influence of chemotherapy in liver surgery

Jan Nilsson



LUND
UNIVERSITY

DOCTORAL DISSERTATION

by due permission of the Faculty of Medicine, Lund University, Sweden.
To be defended at Lecture Room 3, Main Building, Skåne University Hospital,
Lund, June 16th 2017 at 1.00 pm

Faculty opponent

Professor Eduard Jonas, University of Cape Town and Groote Schuur Hospital,
Cape Town, South Africa

| | | |
|----------------------------------------------------------------------------------------------------------------------------------------------------------------------------------------------------------------------------------------------------------------------------------------------------------------------------------------------------------------------------------------------------------------------------------------------------------------------------------------------------------------------------------------------------------------------------------------------------------------------------------------------------------------------------------------------------------------------------------------------------------------------------------------------------------------------------------------------------------------------------------------------------------------------------------------------------------------------------------------------------------------------------------------------------------------------------------------------------------------------------------------------------------------------------------------------------------------------------------------------------------------------------------------------------------------------------------------------------------------------------------------------------------------------------------------------------------------------------------------------------------------------------------------------------------------------------------------------------------------------------------------------------------------------------------------------------------------------------------------------------------------------------------------------------------------------------------------------------------------------------------------------------------------------------------------------------------------------------------------------------------------------------------------------------------------------------------------------------------------------------------------------------------------------------------------------------------------------------------------------------------------------------------------------------------------------------------------------------------------------------------------------------------------------------------------------------------------------------------------------------------------------------------------------------------------------------------------------------------------------------------------------------------------------------------------------------------------------------------------------------------------------------------------------------------------------------------------------------------------------------------------------------------------------------------------------------------------------------------------------------------------------------------------------------------------------------------------------------------------------------------------------------------------------|-----------------------------------------------|-------|
| Organization LUND UNIVERSITY | Document name DOCTORAL DISSERTATION | |
| Department of Surgery Clinical Sciences, Lund Lund University and Skåne University Hospital | Date of issue June 16 th , 2017 | |
| Author: Jan Nilsson, MD | Sponsoring organization | |
| Title and subtitle: Liver tissue characterization and influence of chemotherapy in liver surgery | | |
| Abstract | | |
| <p>Background & Aims: Primary liver cancer is the second most common cause of death from cancer worldwide. In the western world, the majority of liver malignancies consist of colorectal metastases. Liver resection is the primary treatment for cure in liver tumor disease. Hepatic injuries such as steatosis, steatohepatitis, fibrosis and sinusoidal obstruction syndrome, which could be a consequence of chronic liver disease and preoperative chemotherapy treatment, has negative impact on liver surgery. There is a need for an intraoperative tool for identification and quantification of these forms of liver damage.</p> <p>The general aim of this thesis was to evaluate methods for intraoperative liver parenchyma characterization and investigate if liver damage could be detected with these methods. In addition, the influence of chemotherapy on liver regeneration and incisional hernia incidence was investigated.</p> <p>Patients & methods: In study I, intraoperative sidestream dark-field imaging microcirculation measurements were performed on 40 patients before and after liver resection. In study II, intraoperative laser speckle contrast imaging measurements of liver microcirculation were performed on 10 patients. In study III, ex vivo diffuse reflectance spectroscopy measurements on excised liver tissue from 18 patients were performed. In study IV, intraoperative surface diffuse reflectance spectroscopy measurements were performed on 40 liver tumor patients. In study V, radiological liver volume measurements on 74 patients operated with a major liver resection were performed. In study VI, 256 patients' computed tomography scans were reviewed for the presence of incisional hernia.</p> <p>Results & Conclusions: Liver resection leads to an increase in red blood cell velocity in the sinusoids. Patients with liver parenchymal damage have higher red blood cell velocity, lesser functional sinusoidal density and larger sinusoidal diameter. Laser speckle contrast imaging can potentially be used to achieve non-contact intraoperative hepatic microcirculation measurements but problems with movement artifacts need to be resolved. Surface diffuse reflectance spectroscopy measurements are descriptive for the entire liver and it is possible to perform measurements across the liver capsule. Liver surface diffuse reflectance spectroscopy measurements enable intraoperative steatosis grade evaluation with explicit distinction between mild-to-moderate and moderate-to-severe steatosis. Volume regeneration after a major liver resection is negatively affected by preoperative chemotherapy treatment in patients with colorectal liver metastases. The time interval between the ending of chemotherapy and operation is crucial for the power of this impact. Incisional hernia location after an extended right subcostal incision is almost exclusively in the midline. Risk factors for incisional hernia are prolonged preoperative chemotherapy, preoperative bevacizumab, and previous incisional hernia.</p> | | |
| Key words: colorectal liver metastases, liver regeneration, incisional hernia, steatosis, hepatic microcirculation, diffuse reflectance spectroscopy, DRS, sidestream dark-field imaging, SDF, laser speckle contrast imaging, LSCI | | |
| Classification system and/or index terms (if any) | | |
| Supplementary bibliographical information | Language: English | |
| ISSN and key title: 1652-8220 | ISBN: 978-91-7619-478-2 | |
| Recipient's notes | Number of pages: 172 | Price |
| | Security classification | |

I, the undersigned, being the copyright owner of the abstract of the above-mentioned dissertation, hereby grant to all reference sources permission to publish and disseminate the abstract of the above-mentioned dissertation.

Signature



Date

May 11, 2017

Liver tissue characterization and influence of chemotherapy in liver surgery

Jan Nilsson



LUND
UNIVERSITY

Copyright Jan Nilsson
e-mail: jan_h.nilsson@med.lu.se

Supervisor: Associate Professor Christian Stureson
Co-supervisor: Professor Roland Andersson

Cover photo by Sebastian Kaulitzki
Back cover photo by Olle Dahlbäck

Faculty of Medicine Doctoral Dissertation Series 2017:98
Department of Surgery, Clinical Sciences Lund,
Lund University and Skåne University Hospital, Lund, Sweden

ISBN 978-91-7619-478-2
ISSN 1652-8220

Printed in Sweden by Media-Tryck, Lund University
Lund 2017



To my family

Tove, Ted and Arvid

“To dare is to lose one’s footing momentarily.
Not to dare is to lose oneself.”

Søren Kierkegaard

Content

| | |
|-----------------------------------------|----|
| List of publications | 8 |
| Thesis at a glance..... | 10 |
| Abstract | 11 |
| Populärvetenskaplig sammanfattning..... | 12 |
| Abbreviations | 15 |
| Introduction | 17 |
| Liver anatomy and physiology | 17 |
| Liver malignancies..... | 21 |
| Primary cancer..... | 21 |
| Metastatic cancer | 22 |
| Liver damage | 26 |
| Liver surgery..... | 29 |
| Technique of liver resection | 29 |
| Complications of liver surgery..... | 32 |
| Liver regeneration | 33 |
| Sidestream dark-field imaging..... | 34 |
| Laser speckle contrast imaging..... | 35 |
| Diffuse reflectance spectroscopy | 35 |
| Aims | 37 |
| Patients and methods..... | 39 |
| Study design..... | 39 |
| Study population..... | 39 |
| Microcirculation measurements..... | 40 |
| SDF and LSCI Systems..... | 40 |
| Clinical Design | 40 |
| Data Analysis..... | 42 |

| | |
|--------------------------------------------------|----|
| DRS measurements | 43 |
| DRS System | 43 |
| Mathematical Model..... | 44 |
| Clinical Design | 45 |
| Data Analysis..... | 46 |
| Liver regeneration..... | 47 |
| Incisional hernia | 48 |
| Histological analysis | 49 |
| Statistical analysis | 50 |
| Ethics | 50 |
| Results..... | 51 |
| Liver tissue characterization | 51 |
| Hepatic microcirculation (study I and II)..... | 51 |
| DRS measurements (study III and IV)..... | 55 |
| Influence of chemotherapy in liver surgery | 60 |
| Liver regeneration (study V) | 60 |
| Incisional hernia (study VI) | 63 |
| Discussion | 69 |
| Liver tissue characterization | 69 |
| Microcirculation measurements | 69 |
| Optical measurements | 72 |
| Influence of chemotherapy in liver surgery | 74 |
| Conclusions | 77 |
| Future perspectives | 79 |
| Acknowledgements | 81 |
| Grants | 82 |
| References..... | 83 |
| Papers I-VI | |

List of publications

This thesis is based on the following included publications and manuscript, referred to in the text by their roman numerals:

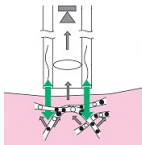


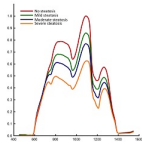
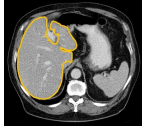
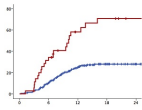
- I. **Nilsson, J.**, Eriksson, S., Blind, P. J., Rissler, P., and Sturesson, C., *Microcirculation changes during liver resection--a clinical study*. *Microvasc Res*, 2014. 94: p. 47-51.
- II. Eriksson, S., **Nilsson, J.**, Lindell, G., and Sturesson, C., *Laser speckle contrast imaging for intraoperative assessment of liver microcirculation: a clinical pilot study*. *Med Devices (Auckl)*, 2014. 7: p. 257-61.
- III. **Nilsson, J. H.**, Reistad, N., Brange, H., Öberg, C. F., and Sturesson, C., *Diffuse Reflectance Spectroscopy for Surface Measurement of Liver Pathology*. *European Surgical Research*, 2017. 58(1-2): p. 40-50.
- IV. **Nilsson, J. H.**, Reistad, N., Bergenfeldt, M., Rissler, P., and Sturesson, C., *Intraoperative liver characterization using diffuse reflectance spectroscopy*. Manuscript.
- V. Sturesson, C., **Nilsson, J.**, Eriksson, S., Spelt, L., and Andersson, R., *Limiting factors for liver regeneration after a major hepatic resection for colorectal cancer metastases*. *HPB (Oxford)*, 2013. 15(8): p. 646-52.
- VI. **Nilsson, J. H.**, Strandberg Holka, P., and Sturesson, C., *Incisional hernia after open resections for colorectal liver metastases - incidence and risk factors*. *HPB (Oxford)*, 2016. 18(5): p. 436-41.

All published papers are reproduced with permission from the copyright owners Elsevier (I, V and VI), Dove Medical Press (II) and KARGER (III).

Additional original publications not included in this thesis:

- ❖ Nilsson, J., Eriksson, S., Nørgaard Larsen, P., Keussen, I., Christiansen Frevert, S., Lindell, G., and Sturesson, C., *Concurrent biliary drainage and portal vein embolization in preparation for extended hepatectomy in patients with biliary cancer*. Acta Radiologica Open, 2015. 4(5).
- ❖ Sturesson, C., Nilsson, J., Lindell, G., Andersson, R. G., and Keussen, I., *Disappearing liver metastases from colorectal cancer: impact of modern imaging modalities*. HPB (Oxford), 2015. 17(11): p. 983-7.
- ❖ Sturesson, C., Valdimarsson, V. T., Blomstrand, E., Eriksson, S., Nilsson, J. H., Syk, I., and Lindell, G., *Liver-first strategy for synchronous colorectal liver metastases – an intention-to-treat analysis*. HPB (Oxford), 2017. 19(1): p. 52-58.
- ❖ Eriksson, S., Nilsson, J. H., Strandberg Holka, P., Eberhard, J., Keussen, I., and Sturesson, C., *The impact of neoadjuvant chemotherapy on skeletal muscle depletion and preoperative sarcopenia in patients with resectable colorectal liver metastases*. HPB (Oxford), 2017. 19(4): p. 331-7.

Thesis at a glance

| Study | Question | Patients/Methods | Result/Conclusion |
|-----------------------------------------------------------------------------------------------|-----------------------------------------------------------------------------------------------------------------------------------------|-------------------------------------------------------------------------------------------------------------------------------------------------------------------|----------------------------------------------------------------------------------------------------------------------------------------------------------------------------------------------------------------------------------------------------------------------------------|
| <p>I</p>  | Does liver resection have any impact on liver microcirculation? Is liver microcirculation affected by liver damage? | Cross-sectional study. In vivo sidestream dark-field imaging measurements on 40 liver tumor patients. | Liver resection leads to an increase of red blood cell velocity in the sinusoids. Patients with liver parenchymal damage have higher red blood cell velocity, lesser functional sinusoidal density and larger sinusoidal diameter. |
| <p>II</p>  | Can intraoperative laser speckle contrast imaging be used to assess hepatic microcirculation? | Cross-sectional pilot study. In vivo laser speckle contrast imaging measurements on 10 patients with colorectal liver metastases. | Laser speckle contrast imaging can potentially be used to achieve intraoperative hepatic microcirculation measurements. However, movement artifact interference problems are considerable and need to be resolved. |
| <p>III</p>  | Is it possible to perform liver surface diffuse reflectance spectroscopy measurements? | Methodological study. Ex vivo diffuse reflectance spectroscopy measurements on excised liver tissue from 18 patients. | Surface measurements are a feasible and, to the liver, noninvasive approach of making diffuse reflectance spectroscopy measurements of the liver. Surface measurements are descriptive for the entire liver and it is possible to perform measurements across the liver capsule. |
| <p>IV</p>  | Can intraoperative liver surface diffuse reflectance spectroscopy measurements be used to detect steatosis? | Cross-sectional study. In vivo diffuse reflectance spectroscopy measurements on 38 liver tumor patients. | Liver surface diffuse reflectance spectroscopy measurements enable intraoperative steatosis grade evaluation with explicit distinction between mild-to-moderate and moderate-to-severe steatosis. |
| <p>V</p>  | Does preoperative chemotherapy influence liver volume regeneration after a major liver resection due to colorectal liver metastases? | Retrospective cohort study. Medical chart and radiological volume measurements on 74 patients operated with a major liver resection due to colorectal metastases. | Preoperative chemotherapy prior to a major liver resection in patients with colorectal liver metastases negatively affects volume regeneration. The time interval between the ending of chemotherapy and operation has a crucial effect on the power of this impact. |
| <p>VI</p>  | What are the incidence, risk factors and localization of incisional hernia after open liver surgery due to colorectal liver metastases? | Retrospective cohort study. Medical chart and computed tomography incisional hernia evaluation on 256 patients operated for colorectal liver metastases. | Prolonged preoperative chemotherapy, preoperative bevacizumab and previous incisional hernia are strong risk factors for development of incisional hernia after open resection for colorectal liver metastases. |

Abstract

Background & Aims: Primary liver cancer is the second most common cause of death from cancer worldwide. In the western world, the majority of liver malignancies consist of colorectal metastases. Liver resection is the primary treatment for cure in liver tumor disease. Hepatic injuries such as steatosis, steatohepatitis, fibrosis and sinusoidal obstruction syndrome, which could be a consequence of chronic liver disease and preoperative chemotherapy treatment, has negative impact on liver surgery. There is a need for an intraoperative tool for identification and quantification of these forms of liver damage.

The general aim of this thesis was to evaluate methods for intraoperative liver parenchyma characterization and investigate if liver damage could be detected with these methods. In addition, the influence of chemotherapy on liver regeneration and incisional hernia incidence was investigated.

Patients & methods: In study I, intraoperative sidestream dark-field imaging microcirculation measurements were performed on 40 patients before and after liver resection. In study II, intraoperative laser speckle contrast imaging measurements of liver microcirculation were performed on 10 patients. In study III, ex vivo diffuse reflectance spectroscopy measurements on excised liver tissue from 18 patients were performed. In study IV, intraoperative surface diffuse reflectance spectroscopy measurements were performed on 40 liver tumor patients. In study V, radiological liver volume measurements on 74 patients operated with a major liver resection were performed. In study VI, 256 patients' computed tomography scans were reviewed for the presence of incisional hernia.

Results & Conclusions: Liver resection leads to an increase in red blood cell velocity in the sinusoids. Patients with liver parenchymal damage have higher red blood cell velocity, lesser functional sinusoidal density and larger sinusoidal diameter. Laser speckle contrast imaging can potentially be used to achieve non-contact intraoperative hepatic microcirculation measurements but problems with movement artifacts need to be resolved. Surface diffuse reflectance spectroscopy measurements are descriptive for the entire liver and it is possible to perform measurements across the liver capsule. Liver surface diffuse reflectance spectroscopy measurements enable intraoperative steatosis grade evaluation with explicit distinction between mild-to-moderate and moderate-to-severe steatosis. Volume regeneration after a major liver resection is negatively affected by preoperative chemotherapy treatment in patients with colorectal liver metastases. The time interval between the ending of chemotherapy and operation is crucial for the power of this impact. Incisional hernia location after an extended right subcostal incision is almost exclusively in the midline. Risk factors for incisional hernia are prolonged preoperative chemotherapy, preoperative bevacizumab, and previous incisional hernia.

Populärvetenskaplig sammanfattning

Levern är ett stort och oundgängligt organ i människokroppen, vars funktion bland annat är en viktig del i ämnesomsättningen, för produktion av blodstillande ämnen och för gallproduktionen. Leverns blodförsörjning är komplicerad och central för dess funktion. I de minsta blodkärlen (mikrocirkulationen) i levern, som kallas sinusoider, sker många av leverns viktigaste processer.

Primär levercellscancer är den näst vanligaste orsaken till cancerrelaterad död globalt sett. I västvärlden är det dock dottertumörer (metastaser) som utgör majoriteten av levertumörerna. Tjocktarmscancer är den tredje vanligaste cancerformen i Sverige. Hos ca 25% av de drabbade sprider sig sjukdomen till levern. De senaste årtiondena har kirurgisk avlägsning av metastaserna utvecklats till den bästa behandlingsformen för dessa patienter med en femårsöverlevnad på omkring 50%. Efter leverkirurgi krävs en viss mängd kvarvarande levervävnad för att undvika att leverns funktionalitet blir otillräcklig (leversvikt). Hos en i övrigt leverfrisk patient är 20-25% av den ursprungliga levervolymen normalt tillräckligt för att undvika leversvikt efter operation.

Många patienter med levertumörer har dock en nedsatt leverfunktion. Vid primär levercellscancer är det vanligt med underliggande leverfibros (bindvävsinlagring i levern) som kan ge betydande funktionsnedsättning. Flertalet av patienterna med metastaser från tjocktarmscancer har fått cellgiftsbehandling före operation. Syftet med sådan behandling är att förbättra långtidsprognosen samt att göra icke operabla patienter operabla genom att krympa tumörbördan. Denna cellgiftsbehandling kan dock leda till förändringar av levervävnaden som ger nedsatt leverfunktion. Vissa cellgiftspreparat kan orsaka en fettinlagring samt en inflammatorisk aktivitet i levern medan andra kan ge en påverkan på små blodkärl i levern. Om dessa förändringar är uttalade kan de observeras visuellt genom att levern är form- och/eller färgförändrad.

Vid lindrig eller måttlig funktionsnedsättning i levern kan kirurgi genomföras men en större andel av den ursprungliga levervolymen måste då lämnas kvar. I vissa fall kan man genom att strypa blodflödet till den tumördrabbade delen av levern (portavensembolisering) få en tillväxt av den del av levern som ska lämnas kvar och därmed förbättra prognosen för patienten.

Det kan vara svårt att upptäcka skador på levervävnaden före operation och det händer att man under operation upptäcker tidigare okända förändringar av levervävnaden. Det finns därför behov av att under operation ges möjlighet att värdera dessa förändringar för att kunna modifiera det planerade ingreppet. Två möjliga vägar att göra detta på skulle kunna vara att studera blodflödet i sinusoiderna eller att använda optiska metoder för karakterisering av levervävnaden.

I delarbete I användes ett handhållet mikroskop (sidestream dark-field imaging) för att mäta leverns mikrocirkulation under operation på 40 patienter som opererades för levertumörer. Mätningar gjordes före och efter att den sjuka delen av levern avlägsnades. Analyser gjordes av blodets hastighet samt sinusoidernas diameter och densitet. Resultaten visade att blodets hastighet i sinusoiderna är högre efter att en del av levern avlägsnats jämfört med före. Patienter med skador på levervävnaden hade högre blodflödes hastighet i sinusoiderna, större diameter på sinusoiderna och lägre densitet av sinusoiderna. Dock kan det vara ett metodologiskt problem i att mikrocirkulationen potentiellt kan påverkas av att mikroskopet hålls mot vävnaden.

I delarbete II mättes leverns mikrocirkulation under operation på 10 patienter med en kontaktlös metod som kallas laser speckle contrast imaging. Mätningarna visade att det är möjligt att använda denna teknik för mikrocirkulationsmätning på lever men störningar i form av rörelseartefakter var påtagliga och behöver lösas för att kunna arbeta vidare med denna metod.

I delarbete III utvecklades ett optiskt mätinstrument för diffus reflektansspektroskopi (DRS) för att kunna genomföra ytmätningar på lever. DRS är en mätmetod där vävnaden belyses och det ljus som reflekteras efter växelverkan med vävnaden detekteras och analyseras. Spektrumet på det reflekterade ljuset beror på vävnadens specifika absorptions- och spridningsegenskaper. Mätningar utfördes på bortopererad levervävnad från 18 patienter. Analyserna visade att det är möjligt att genomföra ytmätningar med DRS på levervävnad.

I delarbete IV utfördes ytmätningar på levern med DRS under operation på 38 patienter. Resultaten visade att det på grupp nivå är möjligt att skilja mellan olika grader av fettinlagring i levern med denna metod.

Levern är ett unikt organ i dess förmåga att återväxa till nästan den ursprungliga volymen efter kirurgisk operation. För att få åtkomst till levern görs vid en öppen leveroperation vanligen ett snitt under höger revbensbåge med en förlängning i medellinjen upp mot bröstbenet. En vanlig komplikation vid all typ av kirurgi är bräckutveckling (avbrott eller utbuktning av bukväggen) i äret. Det finns dock inte så mycket kunskap kring hur levervolymsregenerationen (återväxten av levern) eller ärrbräcksutvecklingen påverkas av cellgiftsbehandling.

I delarbete V studerades påverkan av cellgiftsbehandling på leverregenerationen efter stora leveroperationer. Analyserna visade att cellgiftsbehandling före leverkirurgi påverkar volymsregenerationen negativt. Tidsintervallet mellan cellgiftsbehandlingens avbrytande och kirurgi är avgörande för hur stor den negativa påverkan blir.

I delarbete VI undersöktes förekomst och plats för ärrbräck efter leverkirurgi samt vilken inverkan cellgiftsbehandling har på ärrbräcksförekomsten. Resultaten visade att förlängd cellgiftsbehandling (mer än 6 behandlingar), tidigare ärrbräck samt

behandling med ett specifikt preparat (bevacizumab) är starka riskfaktorer för ärrbråcksutveckling.

Sammanfattningsvis så har vi tagit oss några steg närmre målet att hitta en pålitlig metod för att karakterisera leverns tillstånd under operation. Våra studier belyser även den negativa inverkan som cellgiftsbehandling för tjocktarmsmetastaser har på leverns volymsregeneration samt för ärrbråcksutveckling.

Abbreviations

| | |
|-------|------------------------------------------------------------------------------|
| ALPPS | associating liver partition with portal vein ligation for staged hepatectomy |
| ASA | American society of anesthesiologists |
| BMI | body mass index |
| BSA | body surface area |
| CASH | chemotherapy associated steatohepatitis |
| CRC | colorectal cancer |
| CRLM | colorectal liver metastases |
| CT | computed tomography |
| CUSA | cavitron ultrasonic surgical aspirator |
| CV | coefficient of variability |
| CVP | central venous pressure |
| DRS | diffuse reflectance spectroscopy |
| EGFR | epidermal growth factor receptor |
| FDG | fluorine 18 fluorodeoxyglucose |
| FLR | future liver remnant |
| FLV | functional liver volume |
| FSD | functional sinusoidal density |
| HBF | hepatic blood flow |
| HCC | hepatocellular carcinoma |
| LDF | laser Doppler flowmetry |
| LED | light emitting diode |
| LSCI | laser speckle contrast imaging |
| LSPU | laser speckle perfusion units |
| LV | leucovorin |
| MAP | mean arterial blood pressure |
| MRI | magnetic resonance imaging |

| | |
|-------|-------------------------------------------------|
| NAFLD | nonalcoholic fatty liver disease |
| NAS | nonalcoholic fatty liver disease activity score |
| NASH | nonalcoholic steatohepatitis |
| OPS | orthogonal polarization spectral |
| PEEP | positive end expiratory pressure |
| PET | positron emission tomography |
| PVE | portal vein embolization |
| RBCV | red blood cell velocity |
| RFA | radiofrequency ablation |
| ROI | region of interest |
| SD | sinusoidal diameter |
| SDF | sidestream dark-field |
| SMI | skeletal muscle index |
| SOS | sinusoidal obstruction syndrome |
| THS | total hepatic signal |
| TMA | total muscle area |
| VEGF | vascular endothelial growth factor |
| ZIS | zero inflow signal |

Introduction

Liver anatomy and physiology

The liver is a large internal organ with a mass that amounts to 2-5% of the body weight, located in the upper right quadrant of the abdomen, and almost entirely protected within the rib cage.^{1, 2} Glisson's capsule is the sheath covering the liver surface and is made up of elastin and collagen fiber networks.³ The liver and some of its ligaments are shown in figure 1. The right liver lobe and the left lateral segment are anteriorly separated by the falciform ligament, which suspends the liver to the anterior abdominal wall. The round ligament or ligamentum teres is a remnant of the fetal umbilical vein. In the superiormost liver area, the liver is attached to the diaphragm through the triangular and coronary ligaments. If necessary, all these ligaments can be divided in order to mobilize the liver in a surgical setting. The hepatoduodenal ligament, containing the portal vein, the hepatic artery and the bile duct, enters and attaches to the liver centrally and just to the left of the gallbladder.

Historically, anatomical segmentation of the liver has been topography based on the belief that the falciform ligament constituted the division between the right and left hemilivers. In the late 1800s Sir James Cantlie correctly suggested that this distinction was further lateral to the falciform ligament, running from the gallbladder to the inferior vena cava. This distinction is now called Cantlie's line.^{4, 5} In the 1950s, Claude Couinaud came up with a functional classification of liver anatomy based on the principle that each segment has individual vascular inflow, outflow and biliary drainage.⁶ In this widely adopted classification, the eight segments are numbered in a clockwise direction (figure 2).⁷ Consequently, the left lobe is made up of segments 2, 3 and 4 while the right lobe is made up of segments 5, 6, 7 and 8. Segment 1 is the caudate lobe.

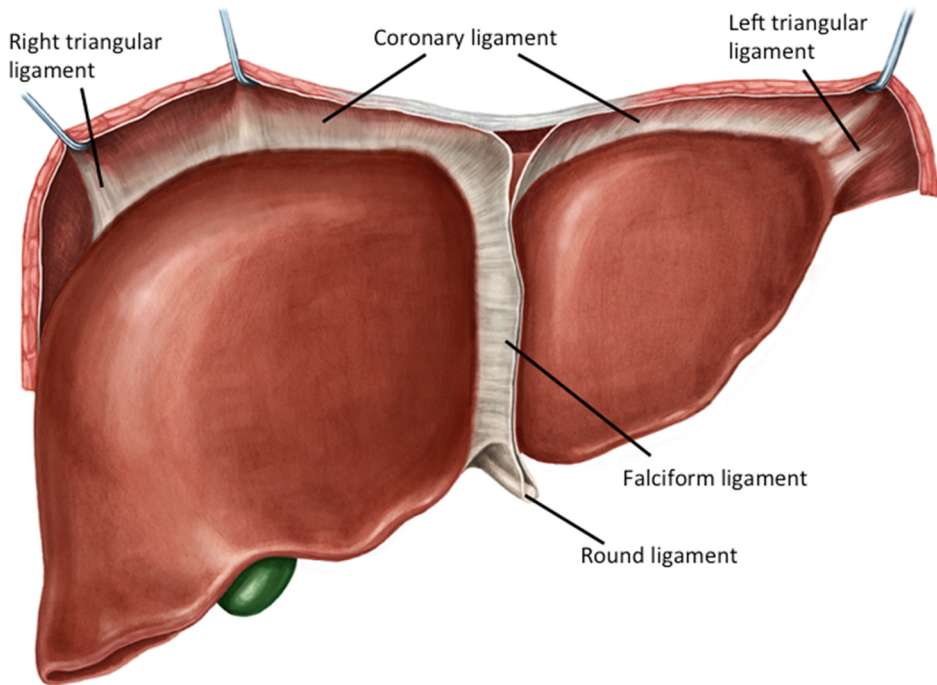


Figure 1. Frontal view of the liver with its ligaments suspending the liver to the diaphragm and anterior abdominal wall. Reproduced by permission from Kenhub (www.kenhub.com); Illustrator: Irina Münstermann.

The liver is the most vascularized organ in the body, receiving up to 25% of total cardiac output.⁸ It has a unique dual blood supply where the hepatic artery delivers approximately 25% and the remaining 75% comes from the portal vein. In the most common arterial anatomy, which is present in approximately 76% of cases, the common hepatic artery begins from the celiac axis along with the left gastric and splenic arteries and then continues laterally and divides into the proper hepatic artery and the gastroduodenal artery.^{2, 8} The portal vein, formed by the confluence of the superior mesenteric vein and splenic vein, drains the splanchnic blood from the stomach, pancreas, spleen, small intestine, and the colon to the liver. The venous drainage consists of the right, middle and left hepatic veins and drains the hepatic blood to the inferior vena cava superiorly of the liver. Intrahepatic bile ducts normally follow the arterial branching system. They finally form the common hepatic duct that courses caudally and joins the cystic duct to form the common bile duct and drains into the duodenum through the ampulla of Vater.

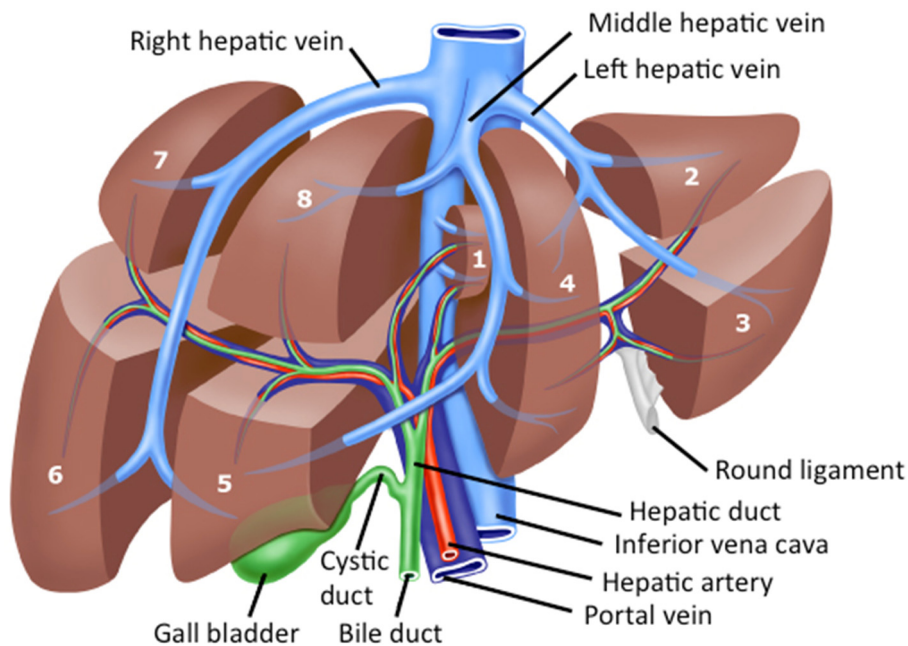


Figure 2. Segmental anatomy of the liver (Couinaud's liver segments). Segments 2 to 4 represent the left lobe while segments 5 to 8 represent the right lobe. Segment 1 is the caudate lobe.

At a cellular level, the liver parenchyma is dominated by hepatocytes but consists also of endothelial cells, stellate cells and Kupffer cells. The cells are organized to form a hepatic lobule with a central vein, sinusoids and the portal triad consisting of a hepatic artery, a portal venule and a bile duct (figure 3). The sinusoids are the smallest vessels in the liver and consist of a type of highly fenestrated capillaries. Hepatocytes are responsible for most functions in the liver e.g. synthesis and storage functions and filtration of the nutrient rich portal venous blood.⁷ The macrophagic Kupffer cells lie within the sinusoid walls and remove debris such as bacteria and worn out blood cells from the passing blood.⁹

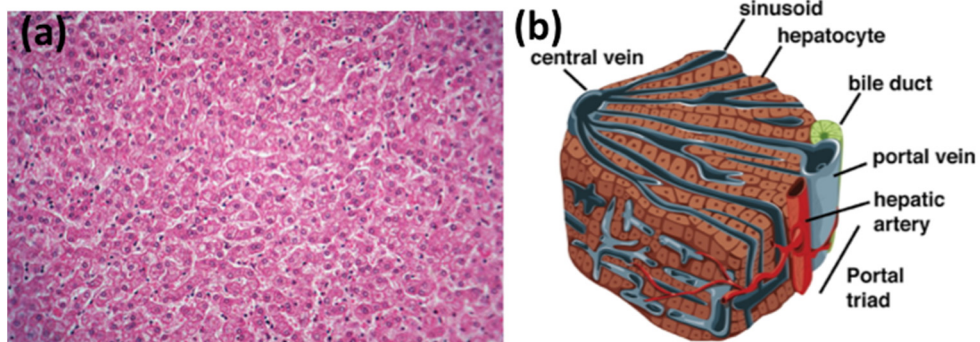


Figure 3. Microscopic anatomy of the liver showing (a) normal human liver histology and (b) part of the hepatic lobule illustrating the central vein, sinusoids and the portal triad consisting of a hepatic artery, a portal vein and a bile duct. Reproduced from (a) Encyclopædia Britannica ImageQuest and (b) Si-Tayeb et al.¹, by permission of Elsevier.

The liver is a vital, multifunctional organ where the key functions can be divided into metabolic, detoxificative and excretory.^{2, 10}

The liver has an essential role in glucose metabolism acting as a glycogen buffer and being involved in gluconeogenesis where glucose is created. Hepatocytes are engaged in the lipid metabolism where they can supply energy through fatty acid oxidation but also convert carbohydrate metabolism products to lipids that can be stored as adipose tissue for later usage. Protein metabolism also takes place in the liver where all non-essential amino acids are synthesized. Aside from immunoglobulins, all plasma proteins are synthesized here. Moreover, the ammonia caused from the protein catabolism is disposed of through the liver as part of the urea cycle. Finally, ethanol oxidation takes place in the liver, which inhibits oxidation of other substrates.

The major solutes in bile are bile acids, phosphatidylcholine and cholesterol. Bile formation takes place in the hepatocytes and it also serves as a medium to get rid of waste products. Via the enterohepatic circulation, the bile acids are reabsorbed and are then transported through the portal blood back to the liver to be reused.

The liver plays an important role in detoxification and converting toxic substances to chemical forms that can be excreted. Drugs in particular are such substances that are metabolized in the liver.

In addition to the above, the liver is also involved in storage and transformation of vitamins, immunological functions and renewal of heavy metals.

Liver malignancies

Treatment of liver malignancies is complex and best managed by a multidisciplinary team that includes surgeons, radiologists, pathologists and oncologists. Malignant liver tumors are classified as primary or metastatic.

Primary cancer

Primary liver malignancies consist of hepatocellular carcinoma (HCC), cholangiocarcinoma and gallbladder cancer. Worldwide, HCC is the fifth most common cancer in men and the ninth in women.¹¹ It is mainly a problem in less developed countries where 83% of new cancer cases occurred in 2012 and where the regions of highest incidence are eastern and southeastern Asia.¹¹

The main risk factors for HCC are viral hepatitis, alcoholic cirrhosis, hemochromatosis and nonalcoholic steatohepatitis (NASH).^{2, 12, 13} Eighty percent of HCC cases arise in eastern Asia and sub Saharan Africa where chronic infection with hepatitis B virus is the dominant risk factor.¹³ Additionally, diabetes has been found to be an independent risk factor for HCC^{12, 13}. Cirrhosis is estimated to be present in 80 to 90% of patients with HCC.¹² One third of patients with cirrhosis will develop HCC during their lifetime.¹⁴ Patients are classified according to the Barcelona Clinic Liver Cancer strategy including the Child-Pugh assessment.^{15, 16} Potentially curative therapies are liver resection, transplantation and ablation.¹⁷ Patients without cirrhosis are often well suited for resection while transplantation is the best treatment in selected candidates among patients with underlying cirrhosis. Image-guided tumor ablation is now an established alternative for patients with early stage HCC where radiofrequency ablation has shown the best effect and is currently the standard method for ablative local tumor treatment.^{13, 18} Non-curative treatment is limited to transarterial chemoembolization and sorafenib, which is an orally administered multikinase inhibitor.¹⁹

Even though cholangiocarcinoma is the second most common primary liver malignancy, representing 10-25% of primary liver tumors in the world, it is still relatively uncommon, especially in the western world. Cholangiocarcinoma is an adenocarcinoma of the bile ducts that has a poor prognosis with similar mortality and incidence rates.²⁰ Cholangiocarcinoma is classified as intrahepatic or extrahepatic.²⁰⁻²² Proximal extrahepatic is the most common localization and is then termed hilar cholangiocarcinoma or Klatskin's tumor. Established risk factors for cholangiocarcinoma include parasitic infections, primary sclerosing cholangitis, biliary-duct cyst, hepatolithiasis and toxins. The only potentially curative treatment

for cholangiocarcinoma is surgery. However, the majority of patients are diagnosed at a late stage and many are found to be unresectable during surgery.^{23, 24}

Gallbladder cancer is the most common biliary tract malignancy in the world although it is relatively rare in the western world.^{25, 26} The incidence is particularly high in Chile, Japan and northern India.²⁶ Gallbladder cancer is commonly diagnosed incidentally, often during laparoscopic cholecystectomy.²⁵ Women are affected 2-6 times more often than men and approximately 85% of the patients have gallstones.²⁷ The prognosis is very poor with an overall mean survival rate of 6 months and a 5-year survival rate of 5%.^{26, 27} However, a curative resection can be made if the diagnosis is early. If the tumor invasion is limited to the mucosa or submucosa, the 5-year survival rates are over 95% and it is about 70% if the subserosa is involved.²⁶

Metastatic cancer

Liver metastases are more common than primary liver cancer.²⁸ Practically all malignancies can metastasize to the liver where they most commonly come from gastrointestinal, breast and lung cancers.^{28, 29} The great propensity for metastasis to the liver is attributed to (1) the dual blood supply of the liver and in the case of gastrointestinal metastases, the enterohepatic circulation where the blood reaches the liver first and (2) the fact that liver vasculature is highly fenestrated, which enables penetration of metastatic cells into the liver parenchyma.^{28, 30}

Colorectal liver metastases

Colorectal cancer (CRC) is the most commonly diagnosed cancer after lung and breast cancer.¹¹ 70% of all CRC are sporadic due to somatic mutations. Another 10-30% have familial predisposition and 3-4% are due to hereditary diseases (mainly hereditary nonpolyposis colorectal cancer and familial adenomatous polyposis).^{31, 32} About 25% of CRC patients will develop colorectal liver metastases (CRLM).³³⁻³⁵ Consequently, CRLM are very common, especially in the western world. It has been found that 15-20% of patients present with synchronous liver metastases, i.e. liver metastases are already present at the time of the primary diagnosis.³³⁻³⁵ The rest of the patients with CRLM will develop metachronous liver metastases, i.e. liver metastases discovered during follow-up.

The only potentially curative treatment that allows long-term survival is liver resection.³⁶ However, due to extrahepatic disease or adverse intrahepatic metastases distribution, the resection rate is only 20% among patients with CRLM.^{37, 38} In resected patients, 5-year survival rates up to 60% are being reported.³⁹⁻⁴¹ In a recent population-based study from Norway where 538 resected patients were analyzed, 3- and 4-year survival rates were 73 and 55% respectively.³⁷ In the past, resection criteria were limited by the number of metastases, the size of the tumors, a mandatory one

cm margin and the presence of extrahepatic disease. Nowadays, the resection criteria are more focused on preservation of a sufficient future liver remnant (FLR) and the preservation of adequate vascular inflow, outflow and biliary drainage.⁴²⁻⁴⁴ Patients with limited extrahepatic disease such as portal lymph nodes or a limited amount of resectable lung metastases can still benefit from hepatic surgery. Since CRLM are often asymptomatic and 80% of all CRLM are detected within the first three years following the primary diagnosis, a frequent radiological follow-up program is recommended.³⁸ Consequently, accurate imaging is essential not only to detect, but also to reliably discriminate resectable from non-resectable CRLM.⁴⁵

Current imaging methods for CRLM are ultrasound (US), computed tomography (CT), magnetic resonance imaging (MRI), fluorine 18 fluorodeoxyglucose (FDG) position emission tomography (PET) and FDG PET/CT. Transabdominal US examination of the liver is fast, inexpensive and has no side effects. However, its use is limited due to its low sensitivity for small lesions, its user dependence and limited image capture availability.^{46, 47} However, in the intraoperative setting, US remains an important modality, often used with intravenous contrast which then constitutes the best chance for CRLM detection.⁴⁶ Contrast-enhanced multidetector CT is the most commonly used modality due to its availability, high resolution and relatively low cost.⁴⁶ Another benefit is that it can be used to examine the chest, abdomen and pelvis in the same session. Thin slices (2-4 mm) are recommended to improve lesion detection.^{48, 49} Still, subcentimeter lesions cannot be detected with CT.⁴⁶ On CT, CRLM are generally hypovascular and more prominent in the portovenous phase compared to normal hepatic parenchyma.^{46, 48, 49} MRI offers better characterization of liver lesions compared to CT, especially for small lesions and in a fatty liver.^{46, 49, 50} CRLM appear with a low signal intensity on T1 weighted images and with moderately high signal intensity on T2 weighted images.⁴⁸ Intravenous contrast is routinely given for the evaluation of CRLM. Extracellular fluid contrast agents composed of gadolinium have been in clinical use for the longest period of time. In the last decades, several hepatobiliary specific agents have been developed that are taken up by the hepatocytes and are excreted in the bile.⁵¹ Gadoteric acid is a hepatobiliary specific contrast agent that makes MRI diagnostic superior compared to other modalities.⁵² In addition, diffusion-weighted MRI has proven to be useful in CRLM detection.^{53, 54} In diffusion-weighted MRI, image contrast is based on differences in the mobility of water between tissues. Although MRI is nowadays regarded as the best preoperative imaging modality, it is often seen as a complementary method because of its longer scan time, higher cost and consequently its lower availability.⁴⁵ FDG PET is a nuclear medicine imaging modality used to detect metabolic active tumor cells. By combining it with a concurrent CT a glucose uptake map of the body can be observed. Sensitivity and specificity have been found to be equal or superior to CT or MRI and PET is considered particularly useful in extrahepatic tumor detection.^{46, 55} A limitation of this modality is its reduced

sensitivity after chemotherapy treatment, probably secondary to reduced tumor metabolism.^{46, 55} Like MRI, availability and cost are other limitations.⁴⁶

Treatment strategies differ depending on CRLM presentation. A majority of patients receive preoperative chemotherapy.^{56, 57} Current chemotherapy regimens base consists of oxaliplatin or irinotecan in addition to 5-fluorouracil (5-FU) and leucovorin (LV). Since 5-FU was introduced in 1957 it has been the base of CRC therapy. Irinotecan is a topoisomerase-I inhibitor that became available in 1996 and the platinum-based agent oxaliplatin was introduced in 2002.⁵⁸ 5-FU/LV in combination with irinotecan is now known as FOLFIRI, and 5-FU/LV in combination with oxaliplatin is known as FOLFOX.

In a metachronous presentation of resectable metastases, neoadjuvant and adjuvant treatment is the standard of care. This is mainly based on a randomized controlled trial by Nordlinger et al. where patients were randomized to receiving six cycles of preoperative FOLFOX and six cycles of postoperative FOLFOX or to surgery alone and showed better progression free survival at three years in the chemotherapy group.⁵⁹ However, chemotherapy is a debated topic and a follow-up study by Nordlinger et al. after 8.5 years showed no significant difference in overall survival between groups.⁶⁰⁻⁶²

In patients with extensive liver metastases presentation, CT-based volumetric FLR measurements can identify patients with inadequate FLR volume and consequently the risk of postoperative liver failure.⁶³ In otherwise normal livers, FLR volume as low as 20-25% can be safe.⁶⁴⁻⁶⁶ Portal vein embolization (PVE) is a method used in order to increase FLR volume before extended hepatectomy.^{67, 68} By embolizing a part of the liver, hypertrophy of the non-embolized part is induced while an atrophy of the embolized tumor-including part occurs. The non-embolized parenchymal volume increase has been shown to be 8-27% in a meta-analysis and PVE can thus increase the number of patients undergoing curative surgery.⁶⁹

Another strategy to deal with small FLR is the two-stage hepatectomy approach where the most possible metastases are resected in a first operation and the remaining metastases are resected in a second operation after the liver has been given the opportunity to regenerate, often along with PVE or portal vein ligation.⁷⁰⁻⁷² Yet another approach that has been implemented by many to deal with small FLR is a novel technique called ALPPS, standing for “Associating Liver Partition with Portal vein ligation for Staged hepatectomy”.⁷³ In this two-stage procedure the liver parenchyma is transected and a portal vein ligation to the liver part that is later to be removed is performed in a first step. After the patient has recovered and allowing hypertrophy of the FLR, typically 1-2 weeks, a second procedure is performed where the tumor-containing part of the liver is removed. Studies with the ALPPS technique have shown promising results with a more rapid FLR volume increase as compared to PVE and a better chance for resection in patients with small FLR.^{74, 75}

Synchronous presentation of CRLM, i.e. CRLM are already present at the time for diagnosis of the primary, are present in 15-20% of patients.³³⁻³⁵ In this situation there are several strategies. In the classical strategy (colorectal-first) the primary is first resected and the CRLM are resected in a second procedure. In patients with asymptomatic primary and CRLM requiring major hepatectomy the reverse strategy (liver-first) may be relevant. In this option, after preoperative chemotherapy, CRLM are resected first followed by the primary in a second stage.⁷⁶ A third alternative is the simultaneous strategy where both CRLM and the primary are resected in the same procedure. This approach has the benefit of avoiding time delay to resection in any of the tumor sites. However, this strategy is limited to a highly selected patient group and both morbidity and mortality have been shown to be higher.⁷⁷⁻⁷⁹

When patients present with unresectable CRLM, effective downsizing chemotherapy may result in resectable patients in 10-20% of cases.³⁸ These patients often receive prolonged chemotherapy treatment and undergo complicated resections resulting in variable reports of survival rates.⁸⁰⁻⁸² With the aim of maximal tumor response, the addition of targeted agents can be made. Bevacizumab is a vascular endothelial growth factor (VEGF) monoclonal antibody used as a supplement to traditional chemotherapy treatment that can result in increased pathologic response.^{83, 84} Another targeted therapy agent is cetuximab, which is an epidermal growth factor receptor (EGFR) inhibitor which has proved to be effective in patients with KRAS wild-type tumors.^{85, 86}

The majority of patients operated for CRLM will develop recurrent disease in the remnant liver.^{87, 88} A repeat resection is the only chance for cure in these patients.⁸⁹ Despite increased technical difficulty in repeated resections, it can be performed in a safe way with acceptable short-term morbidity and mortality and comparable long-term survival to patients undergoing index resections.⁹⁰⁻⁹²

In combination with or addition to hepatic resection, locally ablative modalities can be used to offer curative treatment. Radiofrequency ablation (RFA) is the most common method, in which the tumors are destructed by heating them and surrounding liver tissue.⁹³ The procedure can be performed either percutaneously or during surgery.⁹⁴ Disparate from HCC, RFA has been seen as inferior for local control and survival of CRLM compared to resection.^{95, 96} Traditionally, RFA has played a role in CRLM treatment in highly selected patients with small tumors positioned away from vascular and biliary structures.³⁸ In a recent study by Imai et al. however, resection plus RFA reached long-term results comparable to resection alone.⁹⁷

Liver damage

Nonalcoholic fatty liver disease (NAFLD) is a multifaceted metabolic spectrum of liver diseases with an incidence that is increasing rapidly, mainly due to the ongoing epidemics of obesity and type 2 diabetes.^{98, 99} Furthermore, there are complications to chemotherapy that may induce NAFLD; thus, influencing the result of a liver resection.

Hepatic steatosis is characterized by fatty accumulation in the liver. Steatosis is classified according to D'Alessandro et al. depending on the percentage of hepatocytes containing fat resulting in a grading of none (0-5%), mild (5-30%), moderate (30-60%) or severe (>60%) steatosis.¹⁰⁰ Steatosis can be induced by 5-FU.^{101, 102} Many groups have identified steatosis as an independent risk factor for higher morbidity in the setting of liver resection.¹⁰³⁻¹⁰⁵ Although McCormack et al. revealed a trend toward increased mortality for steatotic patients, no impact on mortality has been found.¹⁰⁶

A more severe form of NAFLD is steatohepatitis, which has the potential to develop into cirrhosis.¹⁰⁷ Steatohepatitis is characterized by steatosis, lobular inflammation and ballooning of hepatocytes (figure 4). Steatohepatitis in the absence of alcohol overconsumption is called nonalcoholic steatohepatitis (NASH) and when it is observed in association with chemotherapy treatment it is called chemotherapy-associated steatohepatitis (CASH). Chemotherapy treatment with irinotecan has been associated with higher risk of steatohepatitis.^{108, 109} Steatohepatitis is generally a worse condition compared to steatosis and in a surgical setting it has been related to increased morbidity and mortality after CRLM resection.¹⁰⁸⁻¹¹⁰

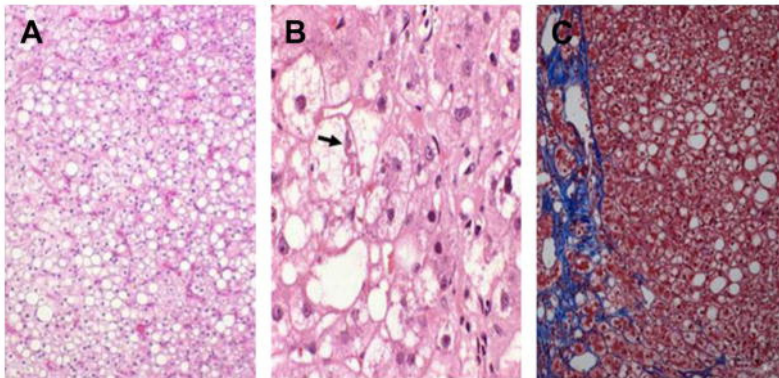


Figure 4. Histologic steatosis and steatohepatitis showing (A) simple steatosis with fat containing vacuoles, (B) steatohepatitis with ballooning degeneration (arrow) and (C) steatohepatitis with perisinusoidal fibrosis. Reproduced from Patel et al.¹¹¹, by permission of Elsevier.

Sinusoidal obstruction syndrome (SOS) is the result of severe toxic injury affecting endothelial cells in the sinusoids.¹¹² It is characterized by sinusoidal fibrosis and dilatation, pericentral hepatocyte necrosis and narrowing of the central veins (figure 5).¹⁰⁷ The vascular influences cause a macroscopically bluish discoloration of the liver and therefore the condition is also called “blue liver syndrome” (figure 6)^{113, 114}. SOS seems to be strongly correlated to the use of oxaliplatin.^{108, 109, 115-117} Interestingly, oxaliplatin-related SOS is less common in patients concomitantly treated with bevacizumab.^{118, 119} Other causes of SOS can be hematopoietic stem cell transplantation, liver transplantation and use of herbal remedies.¹²⁰ The reported incidence of SOS varies, but several reports indicate incidence over 50% when treated with chemotherapy.^{118, 121} Furthermore, the risk of SOS does not seem to be correlated to the duration of chemotherapy.¹⁰⁹ Although SOS has been associated with increased intraoperative transfusions, some studies show no relationship with increased morbidity or mortality.^{107, 109, 115} Narita et al. concluded however, that SOS has a negative impact on liver regeneration after PVE and that it is associated with increased risk of postoperative liver failure after a major liver resection.¹²²

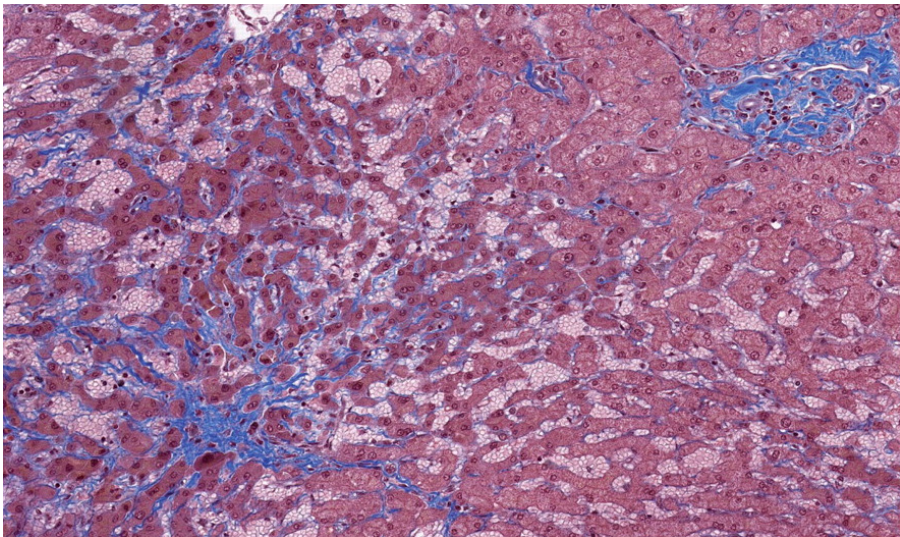


Figure 5. Histologic sinusoidal obstruction syndrome (SOS) showing sinusoidal congestion. Fibrotic perisinusoidal centrilobular spaces and the hepatic vein is occluded by fibrous tissue. Reproduced from Rubbia-Brandt et al.¹²³, by permission of the American Association for Cancer Research.

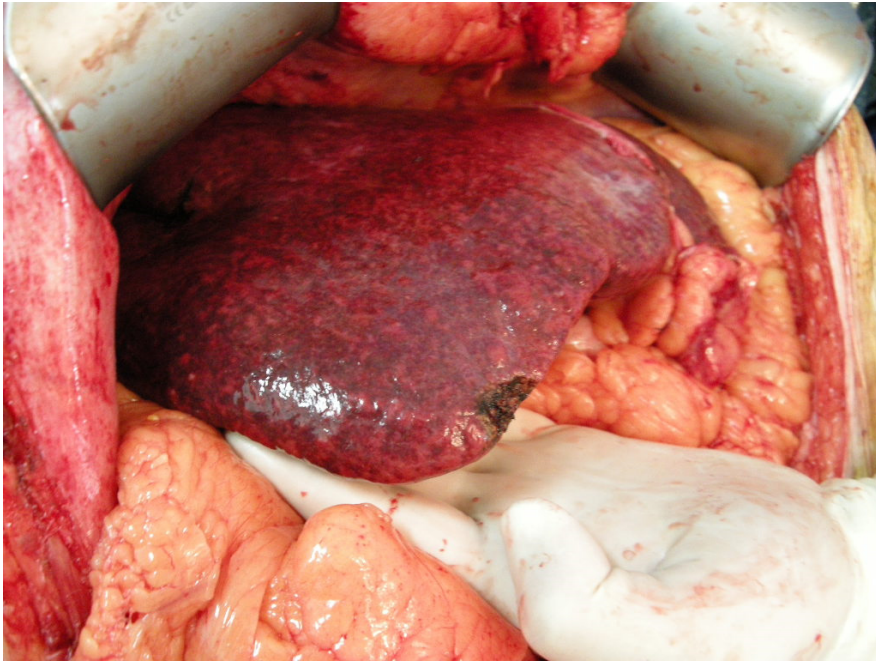

Figure 6. “Blue liver syndrome” in oxaliplatin injured liver with sinusoidal obstruction syndrome (SOS). Reproduced from Robinson et al.¹¹⁴, by permission of Intech.

The gold standard for assessment of liver damage is histological analysis of a liver biopsy.¹²⁴⁻¹²⁶ MRI has proven to be an accurate diagnostic tool for assessment of steatosis, and fibrosis can be evaluated with elastography.^{126, 127} However, clinical implementation of these modalities has been limited by technical feasibility and the time required to complete the tests.¹²⁵ Methods for detection of SOS include increased indocyanine green retention rate, elevated systemic hyaluronic acid, increased spleen size on CT, and elevated aspartate aminotransferase to platelet ratio index.¹²⁸ However, all these indirect markers have modest sensitivity and specificity.^{119, 128-132} Consequently, liver biopsy is still required for diagnosis of these forms of damage. However, biopsy is an invasive method with the risk of sampling error and inter-observer variability.^{124, 133} Furthermore, liver biopsy can lead to tumor dissemination and is therefore not used routinely in a setting intended to be curative.¹³⁴⁻¹³⁶

In a surgical setting, previously unknown liver damage may be found or suspected. Since this damage can affect the surgical strategy, there is a need for methods for intraoperative identification and quantification of such damage.

Liver surgery

Technique of liver resection

Liver surgery has seen rapid development over the last few decades, mainly due to technological advances and increased knowledge of hepatic anatomy and function. The first elective liver resection was performed by Dr. Langenbuch in 1887.¹³⁷ However, the liver is a highly vascularized organ with a great potential to cause excessive bleeding. Consequently, liver surgery has been associated with high morbidity and mortality.^{138, 139}

Even though the International Hepato-Pancreato Biliary Association introduced a common nomenclature of liver resections at a meeting in Brisbane in 2000, the literature is still full of different terminology for liver resections.^{140, 141} Resection types can be divided into two fundamental types, non-anatomical and anatomical.^{142, 143} Non-anatomical or atypical resections are suitable for small peripheral tumors while anatomical resections, which normally involve two or more liver segments, are generally chosen when there is greater tumor burden. Other aspects to consider when choosing resection strategy are FLR size, pre-existing liver disease, preoperative chemotherapy and the risk of postoperative liver failure.^{109, 144} Different types of anatomical resection types are shown in figure 7. No differences in survival or recurrence have been shown when comparing non-anatomic and anatomic resections for CRLM.¹⁴⁵⁻¹⁴⁷ However, in an HCC setting, the anatomical resection type has been shown to have better overall survival and disease-free survival when compared to non-anatomical resection.¹⁴⁸ Of course, it is possible to combine anatomical and non-anatomical resections as well.

As described earlier, an FLR of 20-25% is generally considered sufficient in patients with normal liver parenchyma.^{64, 65, 149} In the presence of risk factors for postoperative liver failure, e.g. cirrhosis, fibrosis, steatosis or preoperative chemotherapy, a considerably larger FLR is required.¹¹⁹ Possible approaches to make an unresectable patient with small FLR resectable are downsizing chemotherapy, PVE and two-stage hepatectomy, as stated earlier.^{71, 73, 76, 150}

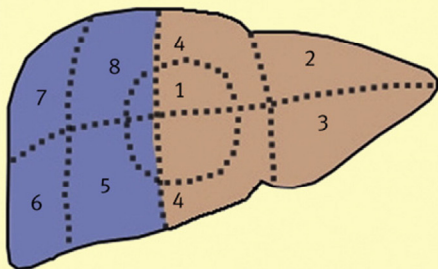
To access the abdominal cavity and the liver, a right subcostal incision is normally made.² Depending on the patient's configuration and liver anatomy, an extension across the midline resulting in a bilateral subcostal incision might be warranted. The round and falciform ligaments are divided and depending on the type of resection, the liver is mobilized by dividing the triangular and the coronary ligaments. The liver can then be examined with bimanual palpation and intraoperative US to locate known tumors and search for any additional tumors.²

High perioperative blood loss is associated with increased mortality.^{104, 151, 152} Since the liver is a highly vascularized organ, using techniques to minimize bleeding is essential. Dr. James Hogart Pringle published a report on liver hemorrhage due to trauma 1908, which led to the “Pringle maneuver” that is used worldwide to control liver bleeding.^{153, 154} In this procedure, the hepatic artery and the portal vein are clamped temporarily. In order to avoid ischemia/reperfusion injuries the Pringle maneuver is normally performed intermittently with occlusion for fifteen min followed by five min of non-occlusion during liver transection if needed.^{155, 156} However, inflow occlusion to the liver has only a modest impact on bleeding from the hepatic veins.⁵⁶ Central venous pressure (CVP) has been found to correlate to bleeding during liver resection and keeping CVP to less than 5 cm H₂O reduces blood loss during hepatic resection.¹⁵⁷ Full bleeding control can only be achieved by total vascular exclusion but this procedure is associated with hemodynamic intolerance and increased postoperative complications.¹⁵⁸⁻¹⁶⁰

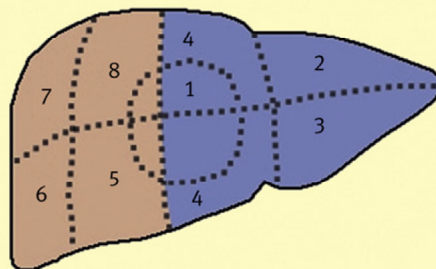
Many techniques and devices for liver parenchyma transection are available. The simplest technique is to crush the hepatic parenchyma between the fingers and thereby expose the small vessels that need to be divided.¹⁴² The clamp crush technique is a further development where basic surgical clamps are used to crush the parenchyma. This method has been found superior to the finger clamp technique and serves as a reference for all other liver parenchyma transection technique studies.¹⁴² One of the most commonly used devices for liver parenchyma transection is the Cavitron Ultrasonic Surgical Aspirator (CUSA).¹⁴³ The CUSA breaks up the liver tissue by ultrasonic energy and then aspirates the tissue fragments leaving solid structures to be divided.¹³⁷ The Harmonic Scalpel works in a similar way but uses ultrasonic shears to divide and seal small blood vessels.¹⁴² The hydro-jet is another technique with a similar result, but uses a high pressure water jet instead to dissect the parenchyma. Also, there are sealing devices, radiofrequency techniques and the vascular stapler technique.¹⁴² With the stapling technique the parenchyma transection can be made quickly and with promising results, but a major disadvantage is the cost of multiple stapler cartridges.^{2, 161} Interestingly, none of the techniques has proved to have significant advantages over the clamp crush technique.^{162, 163} Additionally, there are topical agents or coagulation pads available that can be applied directly to an area to provide hemostasis. These typically consist of collagen or fibrin sheets.^{143, 164}

Common hepatic resections

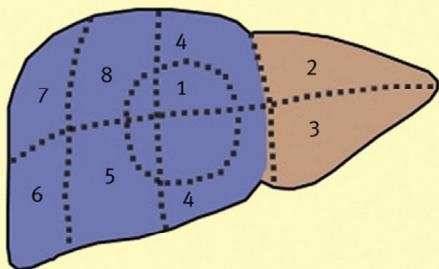
Right hepatectomy



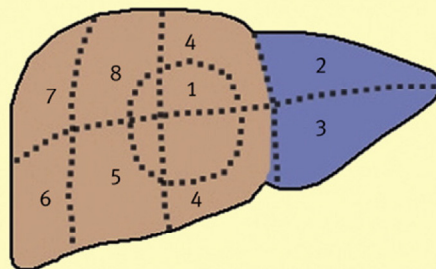
Left hepatectomy



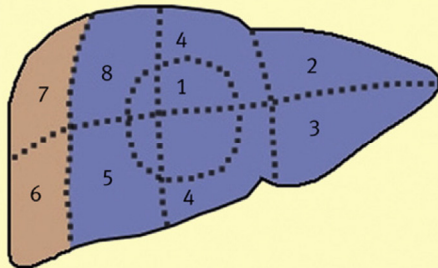
Right trisectionectomy
(extended right hepatectomy)



Left lateral sectionectomy



Left trisectionectomy
(extended left hepatectomy)



Right posterior sectionectomy

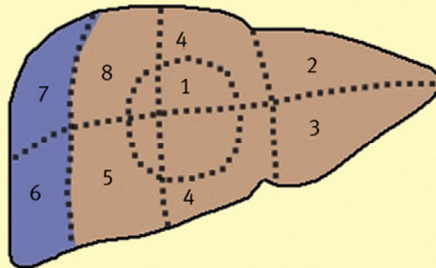


Figure 7. Common anatomical liver resections. Reproduced from Hughes et al.¹⁴³, by permission of Elsevier.

Laparoscopic liver resections

The first report of a laparoscopic liver resection was made in 1991 and since then there has been an exponential growth in the number of reports on the subject.¹⁶⁵ Initially, it was primarily performed on easy accessible benign lesions, but with technological advancements and increased experience, increasing numbers of more advanced hepatic malignancies are being operated with the laparoscopic technique.¹⁶⁶ Although atypical resections and left lateral segmentectomy are the most common laparoscopically performed liver resections, laparoscopic major hepatectomy can be performed safely.^{167, 168} Several advantages of laparoscopic liver resections have been shown in both HCC and CRLM surgery. The operative blood loss is less, postoperative pain is reduced, hospital stay is shorter, and costs are lower.^{166, 169, 170} Oncological results are comparable in terms of negative resection margins, recurrence, and long-term survival.^{171, 172} However, the conclusions are limited to retrospective evidence.

Complications of liver surgery

Technical advances and increased experience concerning liver surgery have led to great improvements regarding mortality and morbidity.^{104, 173} However, liver resection is still complex and has the potential for several postoperative complications. Liver failure is a severe postoperative complication after liver resection and is the leading cause of death after liver surgery.¹⁷⁴ Independent risk factors for liver failure are the amount of liver resected, extended preoperative chemotherapy and the need for a blood transfusion.¹⁷⁴ A prothrombin time < 50% (INR \geq 1.7) and serum bilirubin >50 $\mu\text{mol/L}$ on postoperative day 5 (the 50-50 criteria) has been shown to be an early indicator of postoperative liver failure.¹⁷⁵ Postoperative intraperitoneal hemorrhage is a complication that can arise from bleeding from the resection surface or incomplete intraoperative hemostasis.^{151, 176} Other common causes of complications after liver resections are bile leakage and surgical site infections.¹⁷⁷⁻¹⁷⁹ Postoperative complications are often graded according to the Clavien-Dindo classification (table 1).¹⁸⁰

In addition to the complications associated specifically with liver surgery, there are general complications for all types of surgery. One of the most frequent complications after laparotomy is incisional hernia. Reported risk factors for incisional hernia include age, gender, obesity and surgical site infection.¹⁸¹⁻¹⁸⁴ Also preoperative chemotherapy has been shown to be an independent risk factor for incisional hernia after abdominal surgery.¹⁸⁵ Only a few studies on incisional hernia after liver resection have been made and no study limited to CRLM only has previously been made.^{182, 186,}

¹⁸⁷

Table 1. Clavien-Dindo classification of surgical complications.¹⁸⁰

| Grade | Definition |
|-------|-------------------------------------------------------------------------------------------------------------------------------------------------------------------------------------------------------------------------------------------------------------------------------------------------------------------------------------------------------------------|
| I | Any deviation from the normal postoperative course without the need for pharmacological treatment or surgical, endoscopic, and radiological interventions. Allowed therapeutic regimens are: drugs such as antiemetics, antipyretics, analgesics, diuretics, electrolytes, and physiotherapy. This grade also includes wound infections opened at the bedside. |
| II | Requiring pharmacological treatment with drugs other than those allowed for grade I complications. Blood transfusions and total parenteral nutrition are also included. |
| III | Requiring surgical, endoscopic or radiological intervention. |
| IIIa | Intervention not under general anesthesia. |
| IIIb | Intervention under general anesthesia. |
| IV | Life-threatening complication (including CNS complications) requiring IC/ICU management. |
| IVa | Single organ dysfunction (including dialysis). |
| IVb | Multiorgan dysfunction. |
| V | Death of patient. |

CNS, central nervous system; IC, intermediate care; ICU, intensive care unit.

Liver regeneration

Unlike all other organs in the body, the liver has a regenerative ability so that the size of the organ is always maintained to about its original size.¹⁸⁸ In a liver resection setting, the regeneration is fulfilled by inducing hypertrophy and hyperplasia in the FLR.¹⁸⁹ Consequently, the anatomical appearance after a liver resection will be different from the original liver. After a major liver resection, the replication of hepatocytes normally starts within one day after surgery.¹⁴⁹ The regeneration process has been well-studied and described in different model systems such as mouse and rat models and more recently a zebrafish model.¹⁹⁰ In short, the regeneration process involves cytokines, growth factors and metabolic networks.¹⁸⁹

As described previously, preoperative chemotherapy treatment may influence postoperative outcome and long-term prognosis.^{108, 109, 122} Also, it has been shown that prolonged chemotherapy negatively influences liver regeneration after PVE.¹⁹¹ However, the impact of preoperative chemotherapy on post-resectional liver volume has only been studied to a very limited degree. No studies including only major liver resections have been made.

Sidestream dark-field imaging

Sidestream dark-field (SDF) imaging is a videomicroscopy technique that can be used for direct visualization of microcirculation. The technique was developed many years ago and was first used in the precursor orthogonal polarization spectral (OPS) imaging.¹⁹² By holding a hand-held microscope directly onto the tissue, its microcirculation can be visualized.^{193, 194} The tissue is illuminated by light with a wavelength of 530 nm (green light) that is absorbed by hemoglobin in the red blood cells. This results in a reflected image of the illuminated area where red blood cells look dark, consequently forming an image of the microcirculation (figure 8). SDF imaging is a further development of OPS imaging that enables sharper images due to reduced blurring.¹⁹³ SDF imaging allows measurement of sinusoidal red blood cell velocity (RBCV), sinusoidal diameter (SD) and functional sinusoidal density (FSD).^{195, 196} OPS imaging has been used to assess hepatic microcirculation in liver transplants and SDF imaging has been used to measure hepatic microcirculation in rats.^{197, 198} Limitations of the method are mainly its sensitivity to motion and pressure artifacts.^{193, 199}

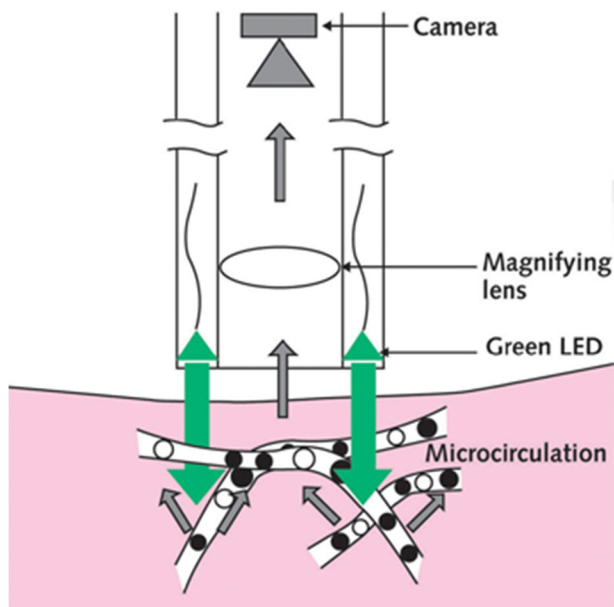


Figure 8. Schematic illustration of sidestream dark-field (SDF) imaging technique. LED, light emitting diodes. Reproduced by permission from MicroVision Medical (www.microvisionmedical.com).

Laser speckle contrast imaging

Another technique to visualize tissue blood perfusion is laser speckle contrast imaging (LSCI). When biological tissue is illuminated by coherent laser light, the backscattered light will form what is called a speckle pattern. When there is movement in the tissue, e.g. microcirculation, the pattern will be blurry. Speckle contrast quantifies the level of blurring and it has been found to correlate with blood flow. LSCI allows fast, non-contact measurements over large areas with good reproducibility.²⁰⁰ The results from LSCI measurements are not quantitative, but expressed as a raw flux value in laser speckle perfusion units (LSPU). Skin microcirculation has been successfully measured with LSCI and the method has been validated for assessment of liver microcirculation in rats.^{198, 201}

Diffuse reflectance spectroscopy

Diffuse reflectance spectroscopy (DRS) is an optical measurement method where light is emitted into and interacts with the tissue after which changes in the spectral distribution of the light are recorded. DRS is a fast and relatively well-established method used in many different areas e.g. skin, lung, breast and gut.²⁰²⁻²⁰⁶ Tissue interaction consists of either absorption or scattering of the light depending on the optical properties of the tissue.

For different wavelengths, chromophores in the tissue absorb different amounts of light. In liver tissue, absorption is dominated by hemoglobin and bile in the visible wavelength range (500-900 nm) and by water, fat and collagen in the near-infrared wavelength range (900-1600 nm).²⁰⁷⁻²⁰⁹ Normalized absorption coefficients of different tissue parameters are shown in figure 9.

When the tissue is illuminated the light will scatter as it propagates through it. The scattering is caused by irregularities and inhomogeneity of the tissue and is also wavelength-dependent. The scattering consists of both Mie- and Rayleigh scattering where Mie scattering is caused by particles that are similar to or larger than the wavelength of light and Rayleigh scattering is caused by particles much smaller than the wavelength of light. The scattered light that is reflected and exits from the tissue can be recorded through an optical fiber, thus resulting in a reflectance spectrum that is wavelength-dependent.

To estimate optical properties and chromophore concentrations, the measured spectrum then has to be modeled to a spectrum with known volume fractions. One method to accomplish these estimations is by an analytical diffusion theory model given by Farrell et al.²¹⁰ This analytical model has previously been used by others for

DRS liver measurements.^{207, 209, 211} Nachabé et al. and Evers et al. have presented interesting DRS liver results in both ex vivo and in vivo clinical studies where they have shown that it is possible to discriminate liver from tumor parenchyma and, most interestingly, have shown the possibility of steatosis quantification.^{207, 209, 211} However, the equipment used in these studies consisted of a fiber-optic needle that was inserted into the liver parenchyma.

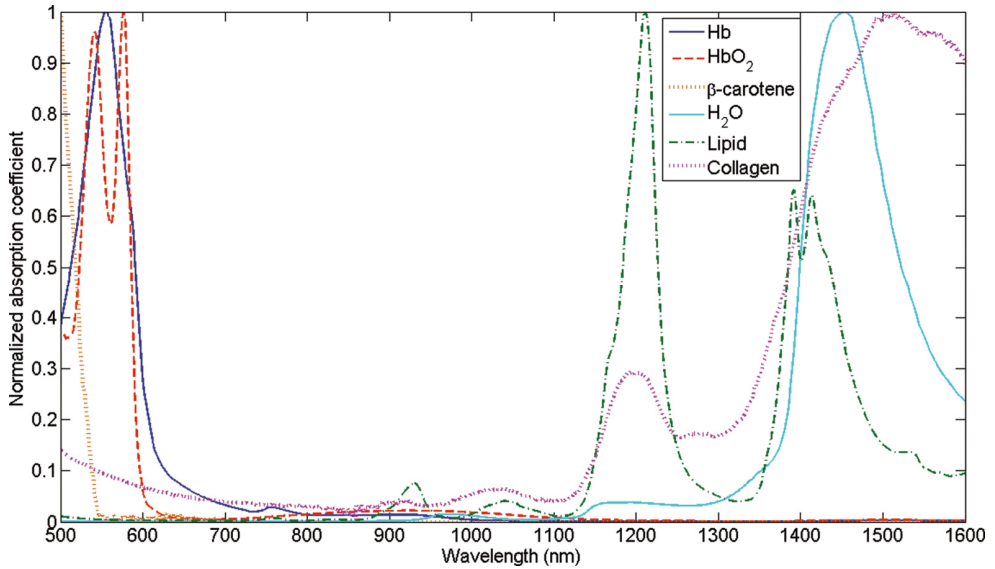


Figure 9. Normalized absorption of different tissue parameters. Reproduced from Nachabé et al.²¹², by permission of Spie.

Aims

The main objective of this thesis was to evaluate and develop new techniques for intraoperative evaluation of liver parenchyma characteristics and detection of chemotherapy-induced liver damage. Additionally, the influence of chemotherapy on liver surgery was studied.

The specific aims of each study were:

- I. To determine whether SDF imaging could be used for intraoperative hepatic microcirculation measurements and whether liver resection has any impact on its microcirculation. We also wanted to study whether histological liver damage could be detected with microcirculation measurements.
- II. To accomplish a pilot study in which the feasibility of intraoperative hepatic LSCI measurements for assessment of liver microcirculation was studied.
- III. To evaluate a hand-held, custom-made DRS probe for liver surface measurements. We wanted to investigate whether the liver capsule affects measurements and whether surface measurements are representative of the whole liver.
- IV. To investigate whether human liver steatosis could be detected with liver surface DRS measurements during surgery.
- V. To retrospectively assess the influence of preoperative chemotherapy on liver volume regeneration after a major liver resection due to CRLM.
- VI. To retrospectively assess the incidence, location and risk factors for incisional hernia after open liver surgery due to CRLM. In particular, the impact of perioperative chemotherapy and targeted therapy was evaluated.

Patients and methods

Study design

Table 2 shows an overview of thesis study design.

Table 2. Summary of the included studies' research design, subjects, method and period.

| Study | Design | Subjects | Method | Period |
|-------|------------------------------|---------------------------------------|--------------------------------------------------|-----------|
| I | Cross-sectional study | 40 liver tumor patients | In vivo SDF imaging measurements | 2013 |
| II | Cross-sectional pilot study | 10 CRLM patients | In vivo LSCI measurements | 2013 |
| III | Methodological ex vivo study | Excised liver tissue from 18 patients | Ex vivo DRS measurements | 2015-2016 |
| IV | Cross-sectional study | 38 liver tumor patients | In vivo DRS measurements | 2015-2016 |
| V | Retrospective cohort study | 74 CRLM patients | Journal review, radiological volume measurements | 2005-2010 |
| VI | Retrospective cohort study | 256 CRLM patients | Journal review, CT hernia review | 2010-2014 |

CRLM, colorectal liver metastases; DRS, diffuse reflectance spectroscopy; CT, computed tomography; LSCI, laser speckle contrast imaging; SDF, sidestream dark-field.

Study population

All patients included in this thesis underwent surgery for hepatic tumors at Skåne University Hospital, Lund, Sweden. All elective liver resections in the region of Skåne, Blekinge and part of Småland and Halland are carried out at this center, resulting in around 125 liver operations per year, of which approximately 80% are due to CRLM. In study V, the patient inclusion was limited to residents of the region of Skåne and in studies II, V and VI, the inclusion diagnosis was limited to CRLM. Patient data other than intraoperative measurements were obtained from patient records and radiological imaging assessments according to the normal patient follow-up program. In the case of missing data for non-Skåne patients (different record system), these data were requested from the domicile hospital; alternatively, a journey was made there to collect the data.

Microcirculation measurements

SDF and LSCI Systems

In study I, a hand-held SDF imaging microscope (MicroScan Video Microscope System, MicroScan BV, Amsterdam, The Netherlands) was used to measure sinusoidal blood flow. By connecting the microscope to an analog-digital capture device (ADVC110, Grass Valley USA, LLC, San Francisco, USA) the SDF imaging microscope image was converted to a digital signal and then recorded (25 frames per sec) to a standard laptop computer using a video capture and vascular analysis software package (AVA 3.0, MicroScan BV, Amsterdam, The Netherlands).

In study II, a commercially available LSCI instrument (MoorFLPI Speckle Contrast Imager, Moor Instruments Ltd, Axminster, UK) was used to acquire liver blood flow data. To be able to place the instrument steadily over the operation area, the instrument was mounted on an adjustable stand and coated with a sterile drape (3M™ Steri-Drape™; 3M Health Care, St Paul, MN, USA).

Clinical Design

All patients scheduled for open liver resection owing to liver tumors (only CRLM in study II) were considered for inclusion. Propofol and fentanyl was used to induce anesthesia and it was sustained using desflurane, isoflurane or sevoflurane, with or without nitrous oxide and fentanyl. Positive end expiratory pressure (PEEP) was set to 5 mmHg. A right subcostal incision with or without a cranial extension to the xiphoid process was used for liver admission. During liver parenchymal transection PEEP was generally set to zero and the aim was to keep CVP to 5 mmHg or lower. A sling was located around the hepatoduodenal ligament admitting the portal vein and hepatic artery to be blocked by temporarily tightening the sling (Pringle's maneuver) when indicated.¹⁵³

In study I, the tip of the instrument was covered with a sterile 10 mm diameter, disposable lens cap (MicroScan Lens, MicroVision Medical, Amsterdam, The Netherlands) and the rest of the probe and about 2 m of the cable system was encased in sterile foil (Video camera laser drape; Microtek Medical BV, Zutphen, The Netherlands). Intraoperative measurements were made, first after the liver had been exposed and mobilized from its diaphragmatic attachments and second straight after the liver resection had been completed. Preceding the measurements, the liver capsule was removed from an area of approximately two times two cm so as to get the probe closer to the liver parenchyma and achieve sharper pictures. Every measurement involved measuring on three places (region of interest, ROI) on a liver area not to be

resected, usually the center of Couinaud's segment three or five.²¹³ Each ROI was recorded for 20 s during apnea, with the SDF imaging probe applied as softly as possible to the liver parenchyma to minimize compression and allow stable pictures (figure 10).²¹⁴

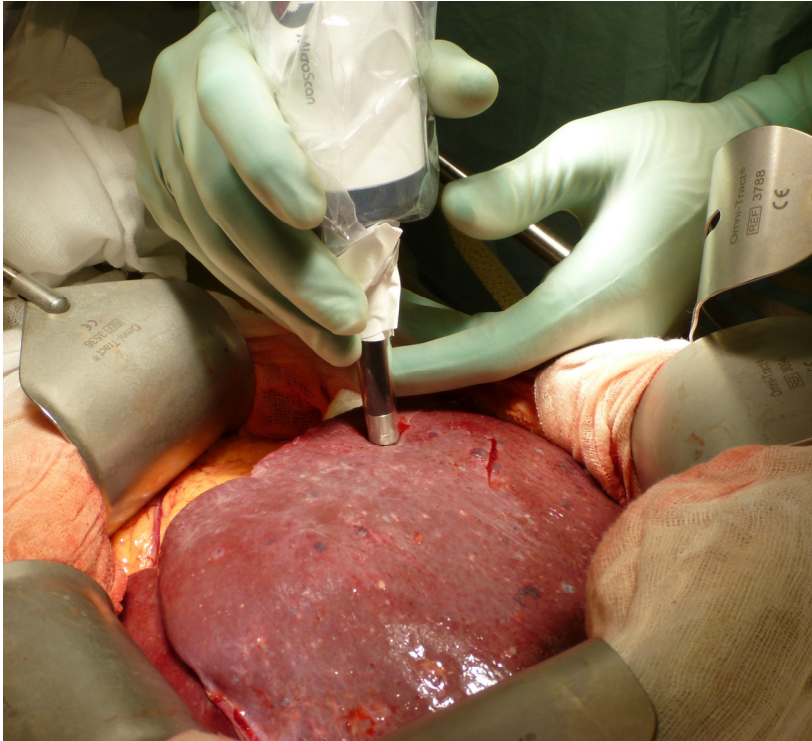


Figure 10. Intraoperative microcirculation measurement with the SDF imaging probe gently applied on the liver parenchyma.

In study II, intraoperative LSCI measurements were performed with the instrument at a distance of 20 cm above the exposed liver surface, allowing a capture of approximately 12×16 cm illuminated with 785 nm laser light from the instrument. Hepatic circulation was represented by the generated speckle contrast captured by the camera. In order to filter source reflections interfering with the blood flow signal, a polarization filter was used. Measurements were made for 10 sec with and without apnea, first with normal liver blood inflow and successively after three minutes of blood inflow occlusion (Pringle's maneuver).

Data Analysis

In study I, video sequence analysis was conducted using the same software package used for video capture (AVA 3.0). Images were digitally stabilized and quality enhanced by altering the contrast and background gray level. After manual identification of three randomly allocated vessels in each recorded sequence, analysis of RBCV was conducted using automatically made space-time diagrams.²¹⁵ SD was determined and FSD was calculated as length of perfused vessels per observation unit area.²¹⁶ A mean for every patient was made and differences between before and after resection were calculated for the three variables.

In study II, computer software (moorFLPI Review V3.0, Moor Instruments Ltd) was used for blood flow analysis. A normal video sequence accompanied the speckle contrast images enabling an ROI definition representing the part of the liver surface visible to the laser speckle instrument. Hepatic perfusion was given in the raw flux value LSPU. Total hepatic signal (THS) was calculated as a mean flux of the chosen ROI over 10 seconds under apnea. Figure 11 shows an example of LSCI images of the liver without and with blood inflow occlusion. Zero inflow signal (ZIS) was expressed as measurements during blood inflow occlusion and apnea. Hepatic blood flow (HBF) was obtained by subtracting ZIS from THS.

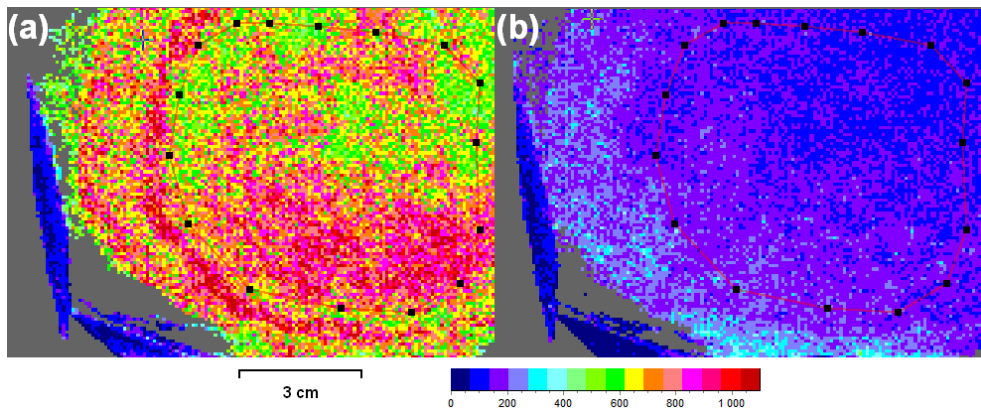


Figure 11. LSCI images of the liver. Hepatic blood flow is represented by the color, (a) with normal blood inflow and (b) with blood inflow occlusion. The ROI is marked with dotted red lines.

DRS measurements

DRS System

The instrumentation setup consisted of a probe cylinder connected to a light source and two spectrometers further connected to a laptop computer (figure 12). Light was emitted from around 360 to 2000 nm using a tungsten halogen light source (Ocean Optics HL-2000-HP; Ocean Optics, Dunedin, Fla., USA). A custom-designed, 10 mm diameter, trifurcated fiber bundle probe was used and at the top a 25 mm probe cylinder was attached in order to minimize pressure effects, foreclose encompassed light and stabilize the probe. The fiber bundle contained a single 400 μm diameter lighting fiber in the center and ten gathering 200 μm diameter fibers placed in a ring with a distance of 2.5 mm from the center. Figure 13 shows a detail image of the probe and the probe cylinder. By using two spectrometers concurrently, spectra were obtained in the range 400 – 1600 nm. Every other gathering fiber was connected to a spectrometer in the visible wavelength range (Ocean Optics QE6500-VIS-NIR) and the others were connected to a spectrometer in the near-infrared range (Ocean Optics NIRQuest512). To acquire data and control the spectrometers, a computer software (Ocean Optics Ocean-View) was used on a standard laptop computer.

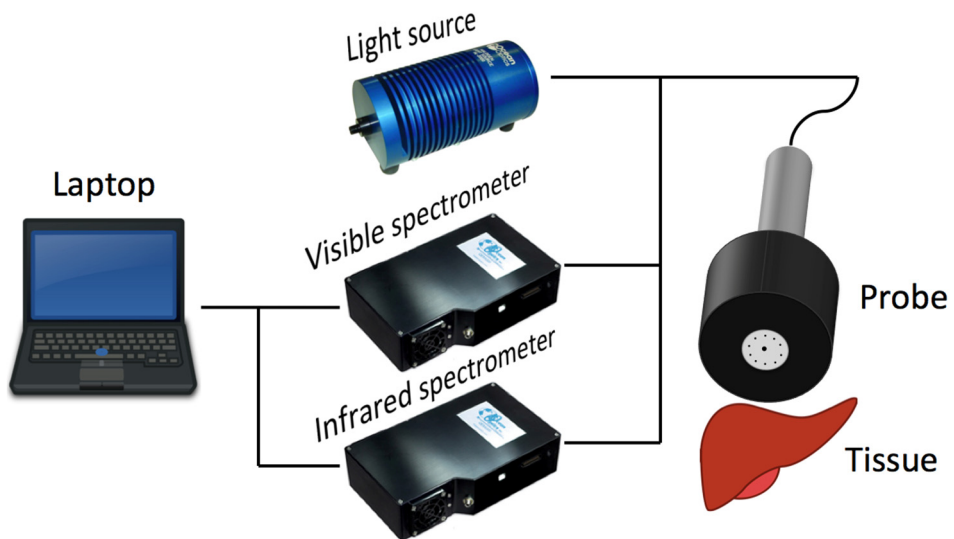


Figure 12. Schematic picture of DRS instrumentation.




Figure 13. Picture of the hand-held probe including the 25 mm diameter probe cylinder (black part) attached at the top.

Mathematical Model

The reduced scattering amplitude at a specific wavelength set to 800 nm (λ_0) was described as $\mu'_s(\lambda) = \mu'_s(\lambda_0)(\rho(\lambda/\lambda_0)^{-b} + (1 - \rho)(\lambda/\lambda_0)^{-4})$, where the scaling factor $\mu'_s(\lambda_0)$ corresponds to the reduced scattering amplitude at this specific wavelength, b the Mie scattering slope and ρ denotes the Mie-to-Rayleigh fraction of scattering and thus constituting the wavelength dependence of scattering in terms of the individual influences of Rayleigh and Mie scattering.²¹⁷ The absorption coefficient within liver tissue was assumed to be approximated by the linear combination $\mu_a^{Tissue}(\lambda) = \mu_a^{Blood}(\lambda) + \mu_a^{WL}(\lambda) + \mu_a^{Other}(\lambda)$ when using available absorption spectra from the literature.^{209, 212, 218-221} $\mu_a^{Blood}(\lambda)$ is made up of absorption of fully oxygenated and deoxygenated blood, $\mu_a^{WL}(\lambda)$ is composed of absorption coefficients of water and lipid and $\mu_a^{Other}(\lambda)$ is represented by the absorption of bile and collagen.

Clinical Design

Patients scheduled for open liver resection owing to liver tumors were considered for inclusion. Propofol and fentanyl were used to induce anesthesia and this was sustained using desflurane, isoflurane or sevoflurane, with or without nitrous oxide and fentanyl. PEEP was set to 5 mmHg. A right subcostal incision with or without a cranial extension to the xiphoid process was used for liver admission.

A standard calibration procedure was performed using a spectrally flat, white reflectance standard (Spectralon SRS-99-010; Labsphere Inc., North Sutton, N.H., USA). By using the same integration time in the calibration and measurement procedures, fixed integration times were enabled. To warm up the light source and the spectrometers, they were left on for at least 15 min prior to the measurements. The probe and approximately 2 m of the cable system were covered in sterile foil (Video camera laser drape; Microtek Medical BV, Zutphen, The Netherlands).

In study III, DRS measurements were made on the excised liver within ten min after resection. Firstly, measurements were made with an intact capsule on the liver parenchyma followed by measurements with the capsule removed on about the same location. Secondly, measurements were made alongside a newly cut surface through the macroscopically normal tissue in 5 mm sections starting from 0 mm up to a maximum of 30 mm depending on tissue thickness. Finally, measurements were made directly on tumor tissue.

In study IV, intraoperative measurements were made directly after the liver had been exposed and mobilized from its diaphragmatic attachments and consisted of measurements with the custom-made probe gently applied to multiple locations spread over the liver surface (figure 14). The total time for the measuring procedure was about five min.

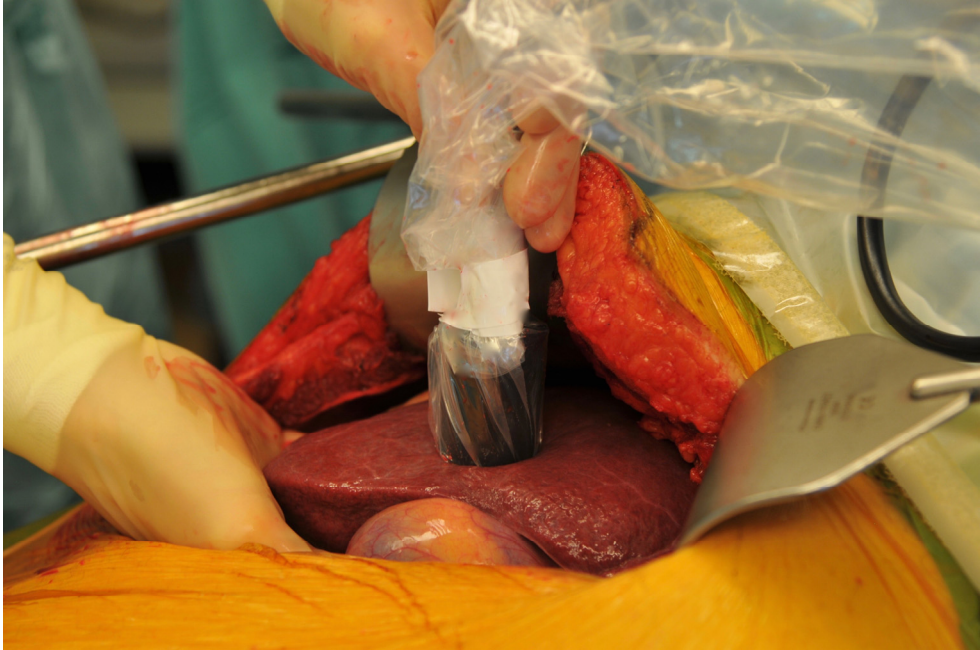

Figure 14. Picture of intraoperative measurements using the custom-made DRS probe encased in sterile foil.

Data Analysis

Both raw tissue spectra $S(\lambda_i)$ and calibration spectra $C(\lambda_i)$ were background corrected by subtracting the acquired background spectra $B(\lambda_i)$ and the diffuse reflectance spectra $R(\lambda_i)$ was then calculated via standard intensity normalization $R(\lambda_i) = (S(\lambda_i) - B(\lambda_i)) / (C(\lambda_i) - B(\lambda_i))$. A matching factor was calculated in order to form continuous spectra from 400 to 1600 nm. The measured diffuse reflectance spectra were fitted to an analytical model first used by Farrell et al. over the wavelength range from 550 to 1450 nm in order to estimate scattering parameters and chromophore volumes.²¹⁰ This is a single-source analytical light propagation model requiring the known wavelength-dependent absorption coefficients and the distance between the emitting and the collecting fibers of the probe as input arguments.^{210, 219, 222, 223} A standard nonlinear least squares fitting algorithm available in the MATLAB software package (MathWorks Inc., Natick, MA) was used for calculations.

Liver regeneration

All consecutive patients domiciled in the region of Skåne with CRLM who underwent a major hepatectomy during a six-year period were included. Major hepatectomy was defined as resection of three or more of Couinaud's segments. Data were obtained retrospectively from patient records and radiological examinations from the normal patient follow-up program were reviewed.

Pre- and postoperative liver volumes were estimated using CT or MRI transversal plane images. The liver contour on all image slices was manually outlined and the area was automatically calculated (figure 15). Every image slice was multiplied with the section thickness (normally 5 mm) and these were then accumulated to obtain the liver volume. The most recent available images prior to surgery were selected as preoperative images and in the case of PVE, the most recent available images prior to PVE were chosen instead. Postoperative images were based on images from the closest to one year after surgery. The functional liver volume (FLV) was calculated by subtracting the metastasis volume from the liver volume. The $\%FLV_{\text{post/pre-op}}$ was defined as the ratio of post- and preoperative FLV.

Body surface area (BSA) was calculated as $BSA \text{ (cm}^2\text{)} = \text{weight}^{0.425} \text{ (kg)} \times \text{height}^{0.725} \text{ (cm)} \times 71.84$.²²⁴ Postoperative liver insufficiency was defined as a peak postoperative bilirubin $>50 \mu\text{mol/l}$ and a peak postoperative INR ≥ 1.7 .

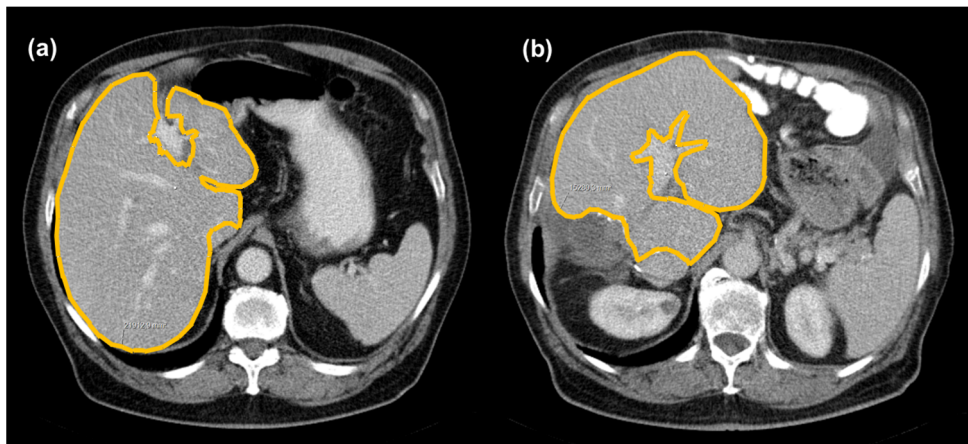


Figure 15. Picture of CT transversal plane images showing (a) preoperative liver area measurement and (b) post right hepatectomy liver area measurement about one year after surgery.

Incisional hernia

All consecutive patients operated with laparotomy due to CRLM during a four-year period were included. Patient records and CT imaging examinations were retrospectively reviewed for data collection. The latest preoperative CT examination and all CT examinations from the normal patient follow-up program were evaluated. Incisional hernia was defined as a discontinuity in the abdominal fascia observed on a CT scan.^{184, 185} The localization of a subcostal hernia was defined as lateral, mid-subcostal or midline. Figure 16 shows a typical midline incisional hernia CT image.

Preoperative total muscle area (TMA) was automatically calculated after a manual trace on the third lumbar level CT transversal plane image.^{225, 226} By correcting for height, skeletal muscle index (SMI) was then calculated. Skeletal muscle depletion was defined as SMI $<43.75 \text{ cm}^2/\text{m}^2$ for men and $<41.1 \text{ cm}^2/\text{m}^2$ for women.^{226, 227} Body fat percentage was calculated as $\text{body weight (kg)} - (0.3 \times \text{TMA (cm}^2\text{)})/\text{body weight (kg)}$.^{228, 229}

Preoperative chemotherapy was defined as chemotherapy administration within 90 days before surgery and postoperative chemotherapy was defined as chemotherapy administration within 90 days after surgery. The 30-day morbidity was classified according to Clavien-Dindo.¹⁸⁰

The liver was normally accessed through an extended right subcostal incision, i.e. a right subcostal incision normally 4-5 cm caudal of the costal margin with a midline cranial extension to the xiphoid process normally measuring 4-8 cm. If necessary, the incision was prolonged to the left, resulting in a Mercedes incision. A major resection was defined as resection of ≥ 3 Couinaud's segments. A running no. 0 PDS suture (Johnsson & Johnsson, Diegem, Belgium) was used to close the abdominal wall fascia in two layers.

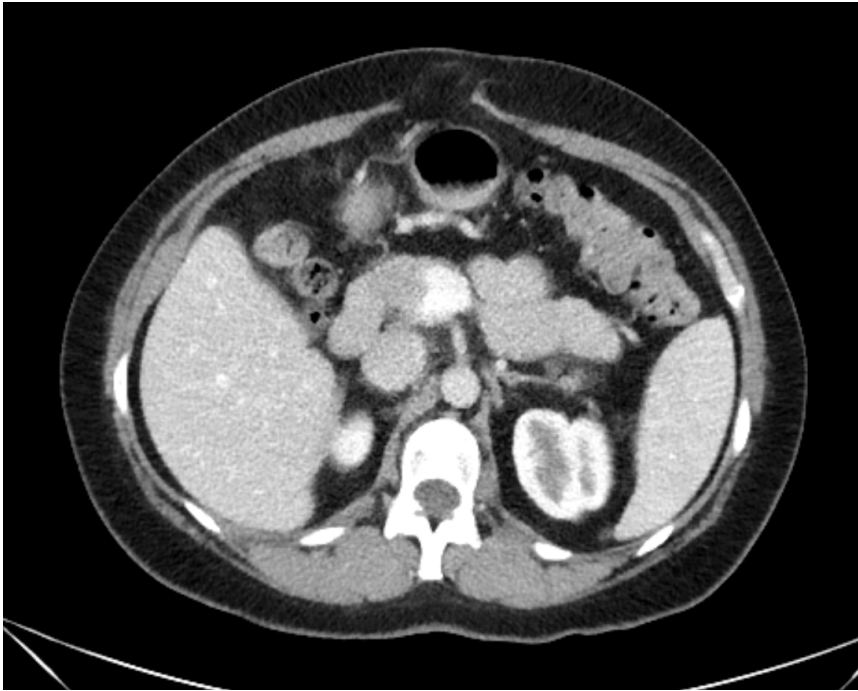

Figure 16. CT transversal plane image showing a typical midline incisional hernia.

Histological analysis

The excised liver was immediately after resection fixed in 4% formalin for later histological analysis, except in study III where ex-vivo DRS measurements were first made. All histological analyses were made by one liver pathologist, who had no information on the patient's clinical data. Analyses were made using hematoxylin and eosin stain or trichrome stain and the classification was made as a joint estimate from analyses of multiple sites from the resected part of the liver. The analyses were made as far from the tumor as possible, and trying to avoid anatomical structures. Steatosis was graded as none, mild, moderate or severe according to D'Alessandro et al. depending on the percentage of hepatocytes containing fat.¹⁰⁰ Fibrosis was graded according to Kleiner et al.¹¹⁰ The Nonalcoholic fatty liver disease Activity Score (NAS) was used to grade steatohepatitis.¹¹⁰ SOS was defined as a sinusoidal dilatation according to Rubbia-Brandt et al.¹¹⁷ In study I, a fibrosis grade ≥ 2 was considered significant fibrosis and liver parenchyma damage was defined as any of steatosis, steatohepatitis, SOS or significant fibrosis.

Statistical analysis

Results are in general expressed as median (range or interquartile range) or mean \pm standard error of the mean. In study V differences between groups regarding %FLV_{post/pre-op} were tested with two-tailed independent sample *t*-tests. Otherwise, a Mann-Whitney *U*-test was used to compare continuous data and Fisher's exact test or χ^2 test was used for categorical data. Tests on related samples were achieved using the Wilcoxon signed-rank test. Linear regression analysis was performed to make correlations and a Pearson correlation coefficient, *r* for parametric variables was computed, while a Spearman correlation coefficient, *r_s* for non-parametric variables was computed.

In study II, the coefficient of variability (CV) was used to analyze intraindividual heterogeneity of HBF. In study IV, differences across steatosis grades were tested with a Kruskal-Wallis test and when significant a Mann-Whitney *U*-test was made with a post hoc Bonferroni correction. In study VI, incisional hernia incidence was estimated using Kaplan-Meier analysis and the log-rank test was used to compare risk factors. Cox regression analysis was used to calculate hazard ratios and 95 per cent confidence intervals in order to analyze the effect of risk factors on incisional hernia incidence. Factors with a *P* < 0.1 on univariable Cox regression analysis were included in further multivariable analysis.

A *P* < 0.05 was considered statistically significant throughout all studies. IBM SPSS Statistics versions 19-22 (IBM, Armonk, NY, USA) was used to perform all statistical analyses.

Ethics

The Regional Ethical Review Board in Lund approved all included studies. At the intraoperative studies (I, II and IV), the instrument was encased in sterile foil and gently held against the surface of the liver. The methods used were safe for the patient and entailed an extended surgery time of only five to ten minutes. Oral and written informed consent was obtained from all patients in studies I-IV. The surgery treatment was never affected by the intervention of the conducted studies. Participating individuals will consequently have no benefit or disadvantage in participating in the studies. Thus, it is the future liver surgical patients who may potentially benefit from these studies.

Results

Liver tissue characterization

Hepatic microcirculation (study I and II)

In study I, 40 patients scheduled for liver resection were included and they were grouped according to whether they were operated with a major (n = 12) or minor (n = 28) resection. Hepatic microcirculation measurements were made in all 40 patients resulting in analyzable SDF imaging film sequences in which flowing red blood cells could be clearly seen in the sinusoids. The intraoperative length of the measuring process was about five min per patient and the following partly manual computer analysis took approximately 30 min per patient.

Table 3 shows patient characteristics and table 4 shows SDF imaging results regarding sinusoidal blood flow velocity and, sinusoidal diameter and sinusoidal density for the two groups major and minor resection. Results considering patients with liver parenchymal damage versus patients with no damage are shown in table 5. No correlation was found between RBCV and CVP or mean arterial blood pressure (MAP) ($r = 0.139$, $P = 0.393$ and $r = 0.022$, $P = 0.895$).

Table 3. Patient characteristics for the major and minor resection groups.

| | Major resection | Minor resection | P |
|---------------------------------------|------------------|------------------|--------|
| No. of patients | 12 | 28 | - |
| Sex | 5:7 | 15:13 | 0.731 |
| Age (years) | 67.5 (61-74) | 66.5 (42-83) | 0.965 |
| BMI (kg/m ²) | 25.8 (17.7-34.8) | 26.2 (20.2-38.1) | 0.652 |
| Smokers | 1 | 3 | 1.000 |
| Patients with diabetes | 1 | 2 | 1.000 |
| Diagnosis | | | |
| Benign | 0 | 2 | 1.000 |
| Biliary cancer | 3 | 0 | 0.541 |
| Colorectal metastases | 8 | 17 | 1.000 |
| Hepatocellular carcinoma | 0 | 4 | 0.297 |
| Other malignancy | 4 | 2 | 0.055 |
| Preoperative serum bilirubin (μmol/l) | 6 (3-15) | 7.5 (3-24) | 0.224 |
| Preoperative INR | 1.0 (0.9-1.1) | 1.0 (0.9-1.4) | 0.142 |
| Preoperative chemotherapy | 4 | 6 | 0.451 |
| Operative bleeding (ml) | 575 (200-3800) | 225 (25-3200) | 0.060 |
| Serum bilirubin POD3 (μmol/l) | 31 (14-69) | 11.5 (4-31) | <0.001 |
| INR POD3 | 1.3 (1.1-1.6) | 1.2 (0.9-1.8) | 0.012 |
| Liver parenchyma damage | | | |
| Steatosis | 2 | 1 | 0.229 |
| Steatohepatitis | 3 | 5 | 0.689 |
| SOS | 1 | 2 | 1.000 |
| Fibrosis | 0 | 4 | 0.287 |

Data are presented as median (range). BMI, body mass index; POD, postoperative day; SOS, sinusoidal obstruction syndrome.

Table 4. SDF imaging results for the two groups major and minor resection.

| | Major resection | Minor resection | P |
|-----------------------------------------------------|------------------|-------------------|-------|
| Red blood cell velocity (μm/s) | | | |
| Before resection | 196 (136-464) | 178 (118-329) | 0.512 |
| After resection | 338 (231-483) | 217 (104-505) | 0.007 |
| Difference | 121 (19-253) | 44 (-113-221) | 0.009 |
| P | 0.002 | 0.016 | |
| Sinusoidal diameter (μm) | | | |
| Before resection | 12.3 (11.7-14.7) | 12.3 (10.7-15.7) | 0.873 |
| After resection | 11.5 (11.0-15.0) | 11.8 (10.0-16.0) | 0.896 |
| Difference | -0.33 (-1.3-0) | -0.5 (-4.3-3.0) | 0.873 |
| P | 0.007 | 0.041 | |
| Functional sinusoidal density (mm/mm ²) | | | |
| Before resection | 21.8 (16.2-25.6) | 21.4(14.6-26.4) | 0.493 |
| After resection | 22.8 (17.2-26.4) | 23.2 (15.8 -27.6) | 0.827 |
| Difference | 1.0 (-1.2 -3.9) | 1.5 (-5.9-6.8) | 0.286 |
| P | 0.060 | 0.011 | |

Data are presented as median (range). SDF, sidestream dark-field.

Table 5. SDF imaging results for patients with liver parenchymal damage versus patient with no damage.

| | Damage (n = 11) | No damage (n = 27) | P |
|----------------------------------------------------|-------------------|--------------------|-------|
| Red blood cell velocity ($\mu\text{m/s}$) | 225 (148-464) | 161 (118-329) | 0.016 |
| Sinusoidal diameter (μm) | 12.7 (11.7-15.7) | 12.0 (10.7-14.7) | 0.009 |
| Functional sinusoidal density (mm/mm^2) | 20.4 (14.6 -22.3) | 22.2 (17.9 -26.4) | 0.007 |

Data are presented as median (range). SDF, sidestream dark-field.

In study II, ten consecutive patients (eight men and two women) undergoing liver resection for CRLM were included. The median age was 68 (range 52-77) years and BMI was $27.5 \pm 1.2 \text{ kg/m}^2$. A preoperative hepatic function test assessed by indocyanine green clearance was normal in all patients. All patients' hepatic microcirculation measurements successfully resulted in applicatory speckle contrast images. The LSCI raw flux signal for the chosen ROI for one typical patient in four different stages is shown in figure 17. Table 6 shows THS and CV for all patients. Mean intraindividual CV was 25%. Mean HBF was $410 \pm 36 \text{ LSPU}$ and the interindividual CV was 28%. Figure 18 shows HBF for all patients. The THS ($682 \pm 37 \text{ LSPU}$) was made up of the sum of ZIS ($272 \pm 25 \text{ LSPU}$) and HBF. ZIS constituted $40 \pm 4\%$ of THS. No significant correlation between ZIS and BMI could be found ($r = -0.58$, $P = 0.081$).

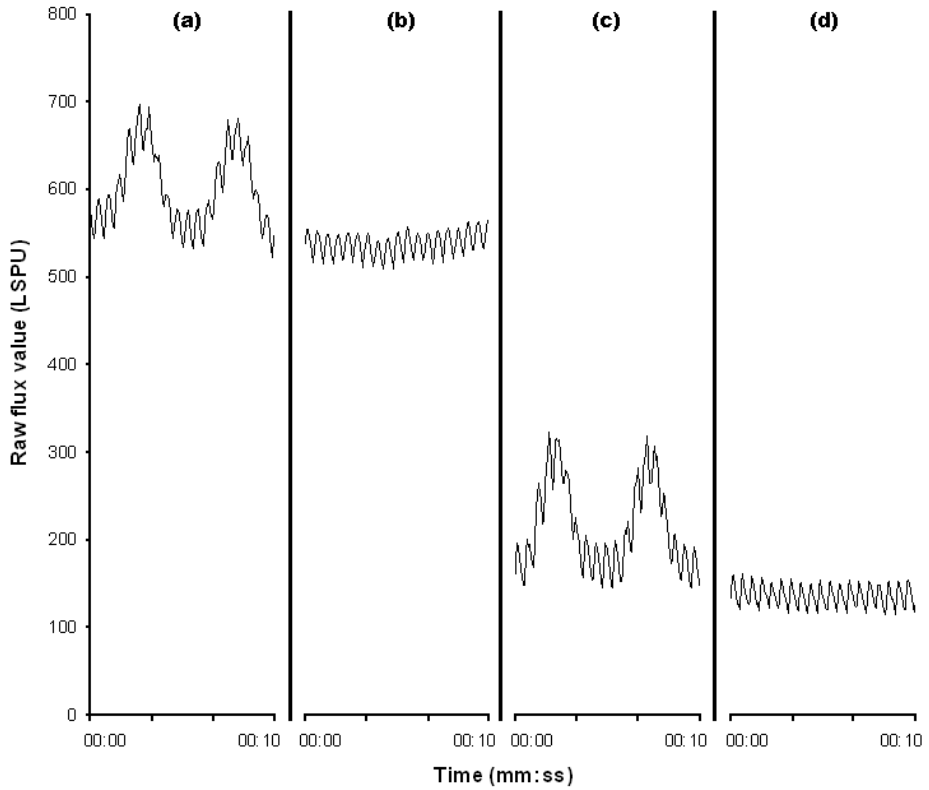


Figure 17. Laser speckle contrast imaging measurements for one patient during (a) no interventions, (b) apnea (THS), (c) vascular inflow occlusion and (d) apnea and vascular inflow occlusion (ZIS). LSPU, laser speckle perfusion units; THS, total hepatic signal; ZIS, zero inflow signal.

Table 6. Laser speckle measurement variability.

| Patient | THS (LSPU) | CV (%) |
|---------|------------|--------|
| 1 | 566 | 26,4 |
| 2 | 645 | 25,1 |
| 3 | 782 | 29,9 |
| 4 | 699 | 26,3 |
| 5 | 646 | 22,4 |
| 6 | 683 | 20,8 |
| 7 | 867 | 21,6 |
| 8 | 550 | 24,4 |
| 9 | 540 | 29,9 |
| 10 | 842 | 26,3 |

THS, total hepatic signal; CV, coefficient of variability; LSPU, laser speckle perfusion units.

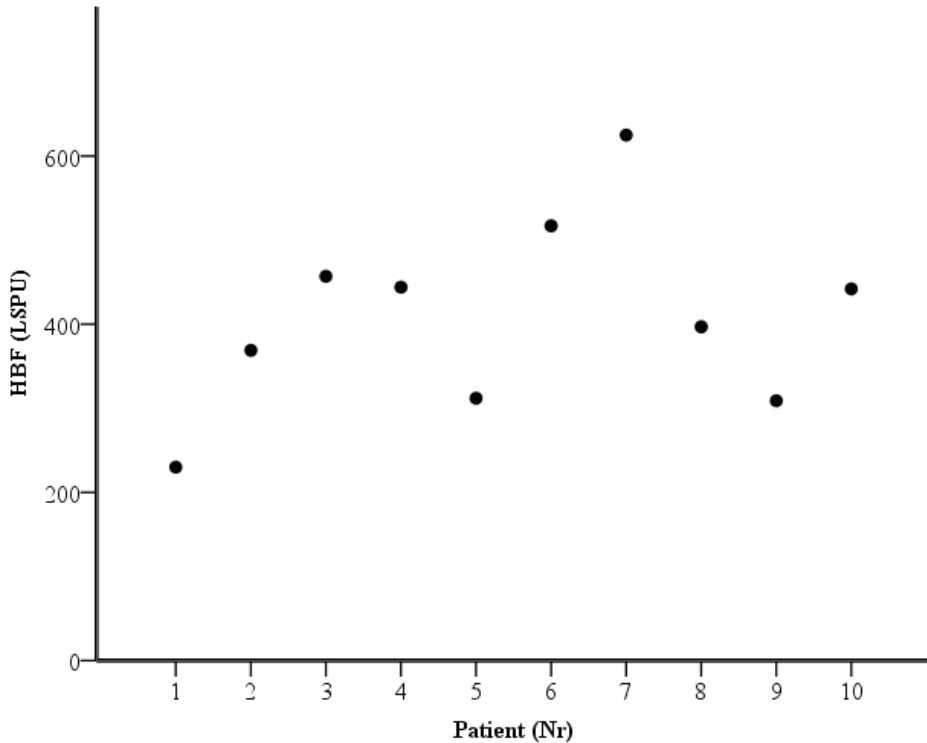


Figure 18. Hepatic blood flow (HBF) for each patient. LSPU, laser speckle perfusion units.

DRS measurements (study III and IV)

In study III, measurements were made on 18 patients' resected liver tissue resulting in 960 DRS spectra from 192 points. Depth measurements were made on 11 patients, capsular measurements on 15 patients and tumor measurements on 15 patients. Out of the 192 measurement points, 54 were made on tumor tissue. Eleven patients were male and seven were female, with a median age of 69.5 years (range 45 – 78 years). Diagnosis was CRLM in 14 patients, HCC in three patients, and duodenal cancer metastases in one patient. Figure 19 shows typical DRS spectra as a function of wavelength for with/without liver capsule, surface/cross-section and tumor/healthy liver tissue. DRS factors for tumor versus healthy liver tissue are shown in figure 20.

In table 7, relevant model analysis results regarding capsule versus no capsule and surface versus cross-sectional measurements are shown. When measuring through the liver capsule the blood volume fraction was $8.4 \pm 3.5\%$, the lipid volume fraction was $9.9 \pm 4.7\%$ and the bile volume fraction was $8.2 \pm 4.6\%$.

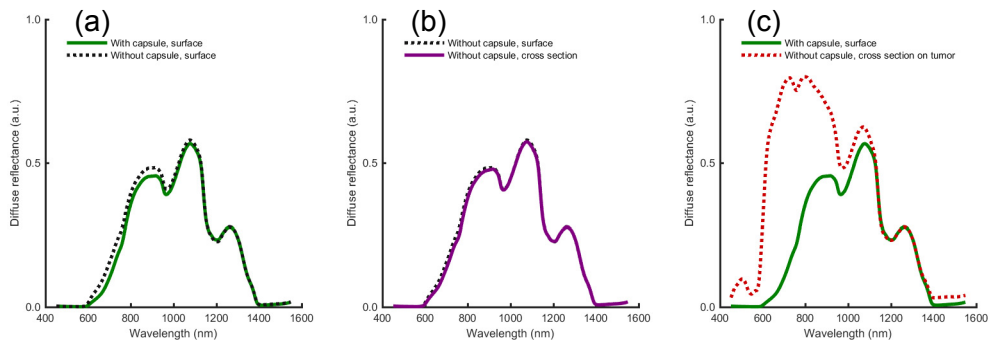


Figure 19. Typical DRS spectra of (a) liver tissue with and without liver capsule, (b) liver tissue surface and cross-section and (c) liver tissue with capsule and tumor without capsule.

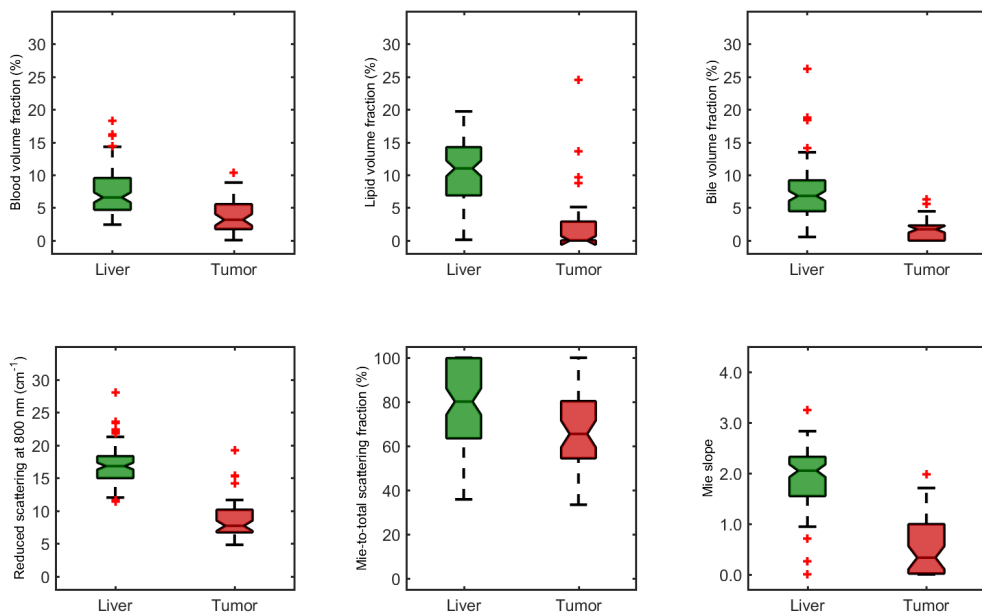


Figure 20. Boxplots of liver tissue parameters versus tumor tissue parameters.

Table 7. DRS results for with/without capsule and surface/cross-section measurements.

| | Capsule | | Depth | |
|--------------------------------------------------------------|-------------------------|-------|----------------------------------|-------|
| | Difference with/without | P | Difference surface/cross-section | P |
| Reduced scattering coefficient at 800 nm (cm ⁻¹) | -0.33 (-1.28 – 0.46) | 0.156 | -0.51 (-1.14 – 0.63) | 0.477 |
| Mie to total scattering fraction (%) | 0.83 (-12.97 – 9.78) | 0.910 | -0.02 (-11.48 – 3.19) | 0.534 |
| Blood volume fraction (%) | 1.63 (0.75 – 2.77) | 0.001 | -0.58 (-1.78 – 1.20) | 0.477 |
| Lipid volume fraction (%) | -0.54 (-2.97 – 0.32) | 0.100 | -1.04 (-2.82 – 1.47) | 0.477 |
| Bile volume fraction (%) | -0.15 (-1.06 – 1.24) | 0.955 | -0.31 (-0.49 – 2.48) | 0.374 |

Data are presented as median (interquartile range) calculated from the average differences in each patient. DRS, diffuse reflectance spectroscopy.

In study IV, 38 patients were included resulting in 1210 DRS spectra from 242 measurement points that were analyzed. Twenty-three patients were male and 15 were female, with a median age of 67.5 years (range 41 – 82 years). Diagnosis was CRLM in 28 patients, HCC in four patients, other malignant tumors in three patients and benign tumors in three patients. Twenty patients had received preoperative chemotherapy. There were 590 DRS spectra (18 patients), which originated from histologically non-steatotic livers, 475 (15 patients) originated from mildly steatotic liver, 80 (three patients) originated from moderately steatotic livers and 65 (two patients) originated from severely steatotic livers. Mean DRS spectra from all measurements categorized by steatosis grade are shown in figure 21. In table 8, relevant model analysis results are shown for steatosis grade none-to-mild versus steatosis grade moderate-to-severe. Figure 22 shows a boxplot of the volumetric DRS ratio factor lipid/(lipid+water) for the different steatosis grades.

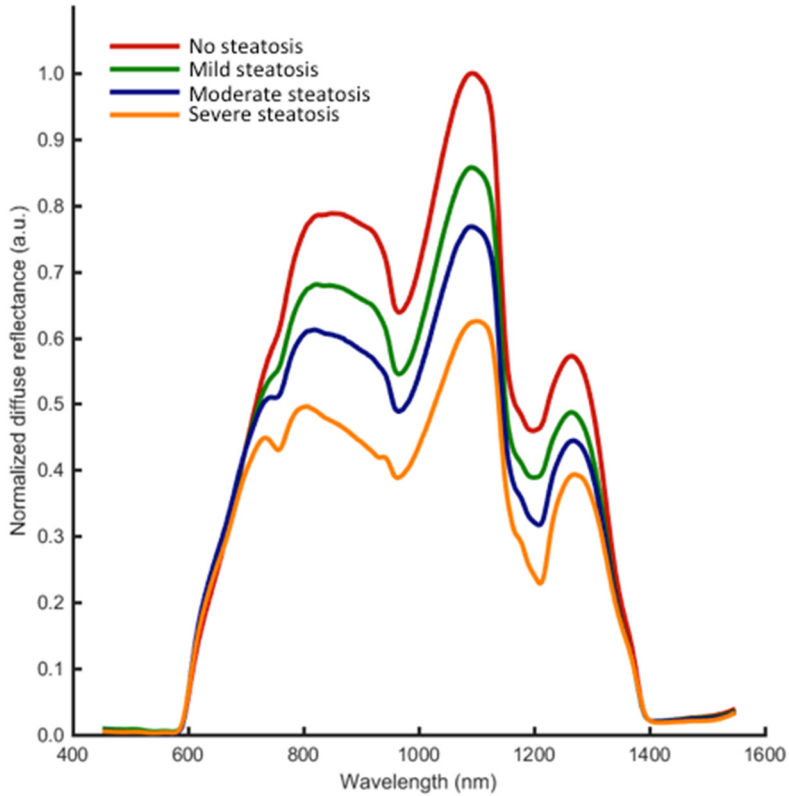


Figure 21. Mean diffuse reflectance spectroscopy spectra of all measurements categorized according to steatosis grade. It is the curve shape around 1200 nm that is most influenced by lipid.

Table 8. Diffuse reflectance spectroscopy results for steatosis grade none-to-mild versus steatosis grade moderate-to-severe.

| | Steatosis grade | | P |
|--------------------------------------------------------------|--------------------|---------------------|--------|
| | None and mild | Moderate and severe | |
| Reduced scattering coefficient at 800 nm (cm ⁻¹) | 13.7 (12.0 – 15.9) | 18.2 (14.3 – 50.0) | <0.001 |
| Mie to total scattering fraction (%) | 71.0 (60.7 – 77.5) | 89.3 (84.3 – 96.4) | <0.001 |
| Mie slope | 0.35 (0.00 – 1.04) | 0.05 (0.00 – 0.24) | 0.003 |
| Lipid / (Lipid + Water) | 10.1 (7.6 – 12.7) | 28.9 (19.4 – 43.1) | <0.001 |
| Blood volume (%) | 8.5 (6.3 – 10.7) | 7.2 (5.5 – 8.6) | 0.044 |
| Bile volume (%) | 13.1 (10.7 – 17.2) | 4.7 (3.4 – 6.7) | <0.001 |

Data are presented as median (interquartile range).

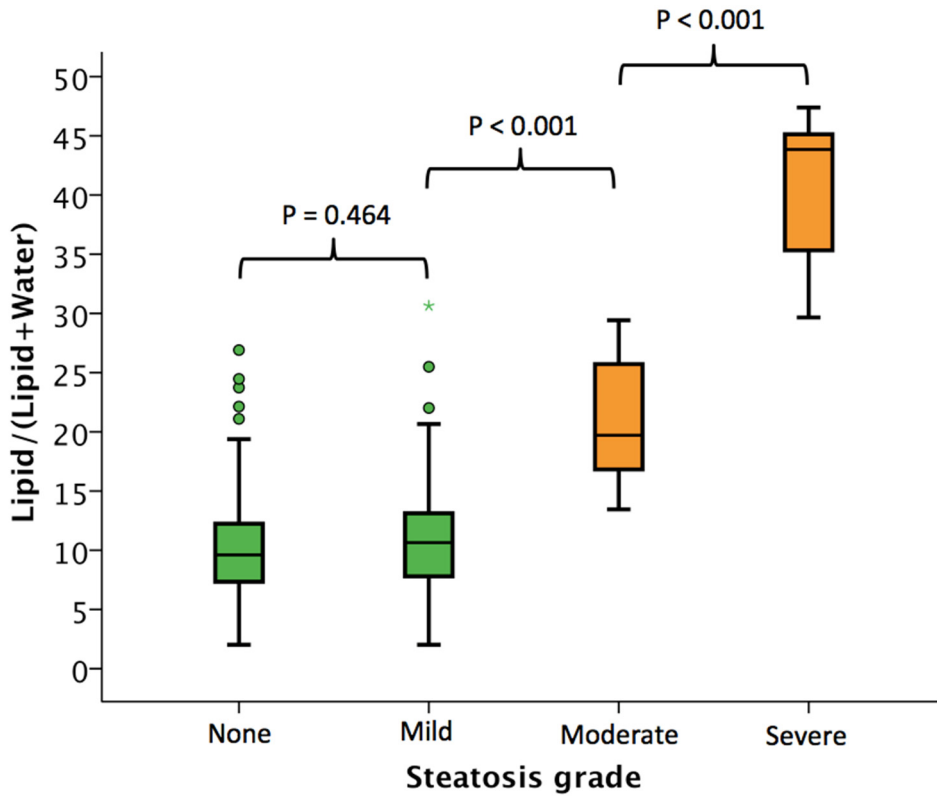


Figure 22. Boxplot of the volumetric diffuse reflectance spectroscopy ratio factor lipid/(lipid+water) for the different steatosis grades. Post hoc Bonferroni P-values presented.

Influence of chemotherapy in liver surgery

Liver regeneration (study V)

In this study, 74 consecutive patients with CRLM who were operated with major hepatectomy were included. Patients were grouped according to whether they had (n = 34) or had not (n = 40) obtained chemotherapy within three months prior to surgery. Table 9 shows patient characteristics and perioperative data. Chemotherapy regimen combinations are presented in table 10. Liver volumes before and after surgery for the two groups are shown in table 11. As shown in figure 23, a linear correlation was found for regenerated volume and the time interval between the end of chemotherapy and surgery. Figure 24 shows correlations between regenerated volume and patient age for the two groups. No differences regarding the ratio of preoperative FLV and BSA between groups could be found (P = 0.80).

Patients treated with versus without bevacizumab presented no difference in %FLV_{post/pre-op} (88 ± 6% versus 83 ± 3, P = 0.43). Nor did patients treated with adjuvant chemotherapy show any different liver regeneration compared to patients who received no adjuvant management (88 ± 2% versus 87 ± 4, P = 0.76). No significant disparity in %FLV_{post/pre-op} among patients who underwent PVE and received preoperative chemotherapy versus patients receiving preoperative chemotherapy alone could be found (89 ± 4% versus 82 ± 4, P = 0.22).

Patients who passed through postoperative liver insufficiency (n = 13, of whom five received preoperative chemotherapy) had a significantly lower %FLV_{post/pre-op} than patients with no liver insufficiency (79 ± 3% versus 89 ± 2, P = 0.013). No disparities considering morbidity between groups could be found (P = 0.35)

Table 9. Patient characteristics and perioperative data.

| | No chemotherapy | Chemotherapy | P |
|-------------------------------------------------------|-----------------|----------------|---------|
| No. of patients | 40 | 34 | - |
| Gender (Male:Female) | 21:19 | 19:15 | 0.82 |
| Age (years) | 66 (46-86) | 62 (42-74) | 0.003 |
| BMI (kg/m ²) | 26.5±0.8 | 24.0±0.4 | 0.010 |
| No. of diabetes patients | 6 | 4 | 0.75 |
| Metastasis volume (ml) | 66±18 | 29±9 | 0.08 |
| No. of metastases | 2 (0-5)* | 2 (0-7)* | 0.74 |
| Size of largest metastasis (mm) | 48 (0-120)* | 25 (12-99)* | 0.30 |
| No. of patients with PVE | 1 | 9 | <0.0001 |
| No. of chemotherapy cycles | | 7 (2-28) | |
| Time to surgery after chemotherapy (days) | | 40 (20-88) | |
| Type of resection (n) | | | |
| right-sided hepatectomy ± atypical resection | 26 | 21 | 0.18 |
| extended right-sided hepatectomy ± atypical resection | 5 | 8 | 0.10 |
| left-sided hepatectomy ± atypical resection | 9 | 5 | 0.30 |
| Operative bleeding [ml] | 700 (100-15000) | 1000(250-4000) | 0.21 |
| Length of hospital stay (days) | 8 (5-79) | 9 (5-19) | 0.69 |
| Peak postoperative bilirubin (µmol/l) | 32 (12-202) | 35 (13-127) | 0.77 |
| Peak postoperative INR | 1.6 (0.9-2.1) | 1.6 (1.1-2.6) | 0.44 |
| Time from operation to postoperative image (days) | 326 (127-822) | 315 (188-593) | 0.45 |

Data are presented as mean ± standard error of the mean (SEM) or median (range). BMI, body mass index; PVE, portal vein embolization.

Table 10. Chemotherapy regimen combinations.

| Chemotherapy regimen | Number of patients |
|--------------------------------------------------|--------------------|
| 5-FU + oxaliplatin | 17 |
| 5-FU + oxaliplatin + bevacizumab | 6 |
| 5-FU + oxaliplatin + panitumumab | 2 |
| 5-FU + oxaliplatin followed by 5-FU + irinotecan | 2 |
| 5-FU + irinotecan | 4 |
| 5-FU + irinotecan + cetuximab | 2 |
| Other combination | 1 |

5-FU, 5-fluorouracil.

Table 11. Liver volumes.

| | No chemotherapy | Chemotherapy | P |
|---------------------------------|-----------------|--------------|-------|
| FLV before resection (ml) | 1521±50 | 1556±47 | 0.64 |
| ΔFLV (ml) | -135±35 | -278±32 | 0.005 |
| %FLV _{post/pre-op} (%) | 91±2 | 83±2 | 0.007 |

Data are presented as mean±SEM. FLV signifies functional liver volume. ΔFLV denotes the paired volume difference in FLV between after and before resection. %FLV_{post/pre-op} is defined as the ratio of post- and preoperative FLV.

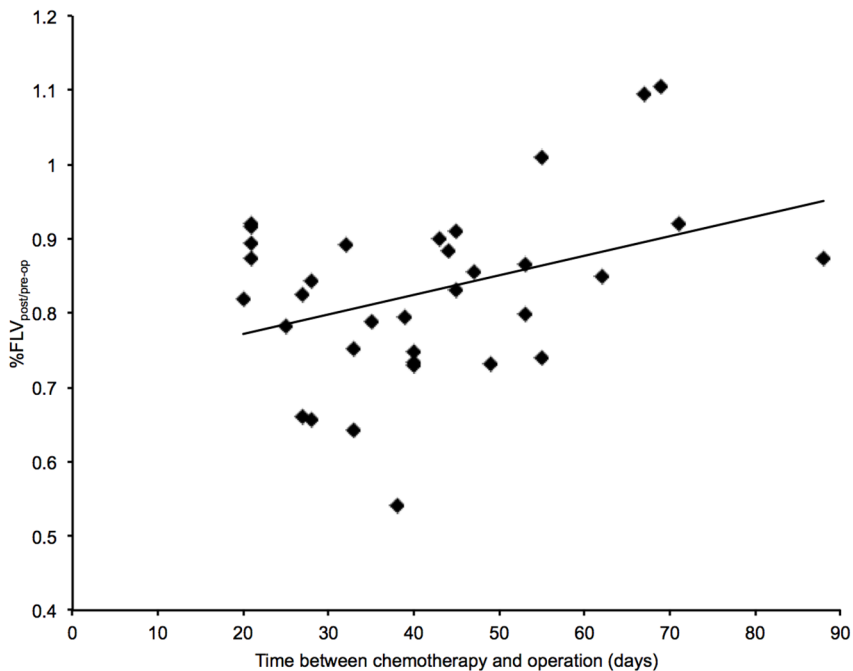


Figure 23. Correlation between regenerated volume and the time interval between cessation of chemotherapy and surgery. A linear correlation was found ($r = 0.37$, $P = 0.031$).

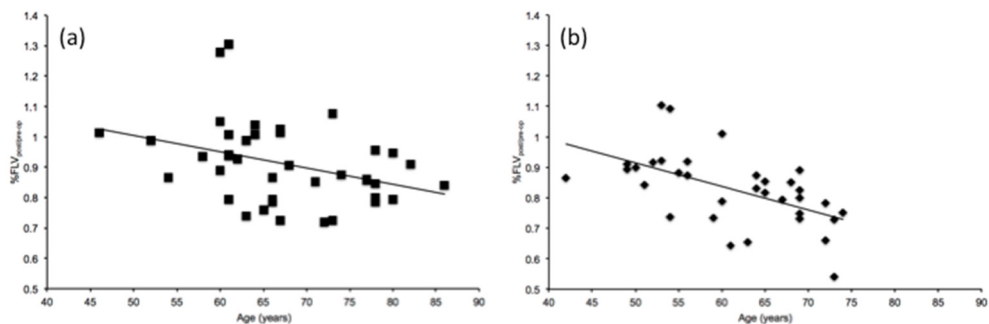


Figure 24. Correlation between regenerated volume and the patient's age for (a) patients without chemotherapy and (b) patients with chemotherapy. Negative linear correlations were found ($r = -0.36$, $P = 0.023$ and $r = -0.558$, $P = 0.0001$, respectively).

Incisional hernia (study VI)

In this study, 256 patients operated with laparotomy for CRLM between 2010 and 2013 were included. Incisional hernia was found in 78 patients (30.5%) and a Kaplan-Maier estimated rate was found to be 34.9% at 60 months. The median follow-up time was 13 (range 2 – 59) months. Table 12 shows patient characteristics and perioperative data for the two groups with and without incisional hernia. Incisions were extended right subcostal (198 patients, 77.3%), Mercedes (52 patients, 20.3%) and midline (3 patients, 1.2%). Hernia locations were midline solitary in 66 patients (84.6%), midline plus mid-subcostal or lateral in eight patients (10.3%) and lateral in three patients (3.8%). The median length of follow-up until a hernia was identified on CT was 7 (range 1 – 27) months. Among patients with incisional hernia prior to current liver surgery ($n = 36$), 24 had hernia after colorectal resection and 12 had hernia after previous liver resection, 23 developed incisional hernia (log-rank $P < 0.0001$, figure 25).

Preoperative chemotherapy was oxaliplatin-based in 75 (54%) patients and irinotecan-based in 34 (24%) patients. Twenty-four (17%) patients were treated with multiple chemotherapy regimens. Patients with prolonged preoperative chemotherapy (> 6 cycles) were more inclined to develop incisional hernia (log-rank $P = 0.025$, figure 26). Eleven out of 19 (58%) patients receiving preoperative bevacizumab developed incisional hernia (log-rank $P < 0.0001$, figure 27). Eight out of 23 patients with surgical site infection developed incisional hernia without a statistical difference as compared to patients without infection (log-rank $P = 0.313$). Obesity (BMI > 30 kg/m²) ($n = 32$) was not found to have any impact on incisional hernia incidence (log-rank $P = 0.340$). Table 13 shows univariable and multivariable hazard ratio analysis of risk factors for incisional hernia development.

Table 12. Patient characteristics categorized as with and without incisional hernia.

| | Incisional hernia | No incisional hernia | P |
|--------------------------------------|--------------------------|-----------------------------|----------|
| Number of patients | 78 | 178 | - |
| Gender (male:female) | 48:30 | 110:68 | 0.969 |
| Age (years) | 68 (37-82) | 68 (35-85) | 0.880 |
| Current smoking | 13 | 36 | 0.505 |
| Diabetes mellitus | 11 | 19 | 0.432 |
| Body mass index (kg/m ²) | 26.0 (18.4-41.1) | 25.0 (17.7-38.2) | 0.076 |
| Total muscle area (mm ²) | 13360 (6391-20599) | 13350 (5460-21906) | 0.802 |
| Skeletal muscle depletion | 27 | 76 | 0.225 |
| Subcutaneous fat (mm) | 12 (3-34) | 12 (2-35) | 0.415 |
| Body fat percentage (%) | 39.1 (19.2-57.2) | 38.0 (8.6-66.6) | 0.531 |
| Preoperative chemotherapy | 44 | 96 | 0.656 |
| Number of chemotherapy cycles | 5 (1-16) | 5 (1-13) | 0.552 |
| Preoperative chemotherapy > 6 cycles | 13 | 19 | 0.169 |
| Preoperative bevacizumab | 11 | 8 | 0.009 |
| Previous liver resection | 15 | 18 | 0.045 |
| Incisional hernia before surgery | 23 | 13 | <0.0001 |
| ASA grade (1/2:3/4) | 54:24 | 129:49 | 0.597 |
| Preoperative albumin (g/l) | 38 (25-46) | 38 (24-47) | 0.522 |
| Preoperative creatinine (μmol/l) | 73.5 (36-132) | 73.0 (31-150) | 0.645 |
| Operating time (hours) | 4.76 (1.0-9.8) | 4.75 (1.1-13.0) | 0.955 |
| Operative bleeding (ml) | 350 (25-2000) | 300 (25-8000) | 0.683 |
| Incision type (ERSI:Mercedes) | 60:16 | 138:36 | 0.948 |
| Major resection | 26 | 68 | 0.457 |
| Hospital stay (days) | 7 (3-34) | 7 (2-76) | 0.804 |
| Incisional surgical site infection | 8 | 15 | 0.638 |
| Remote infection | 3 | 9 | 0.673 |
| Morbidity (Clavien-Dindo ≥ 3) | 9 | 18 | 0.732 |
| Postoperative chemotherapy | 45 | 104 | 0.774 |

Data are presented as number or median (range). ASA, American Society of Anesthesiologists; ERSI, extended right subcostal incision.

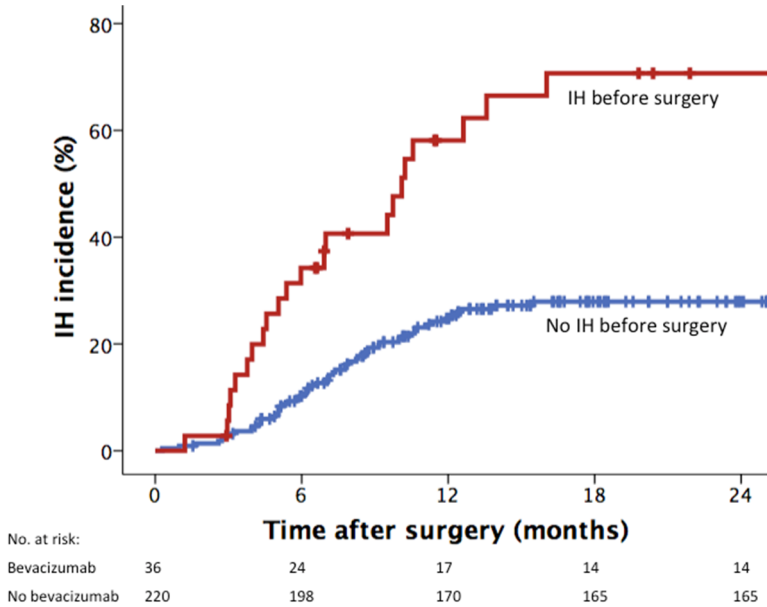


Figure 25. Kaplan-Meier plot of incisional hernia incidence for patients with (red curve) and without (blue curve) incisional hernia before surgery. $P < 0.0001$ (log-rank test).

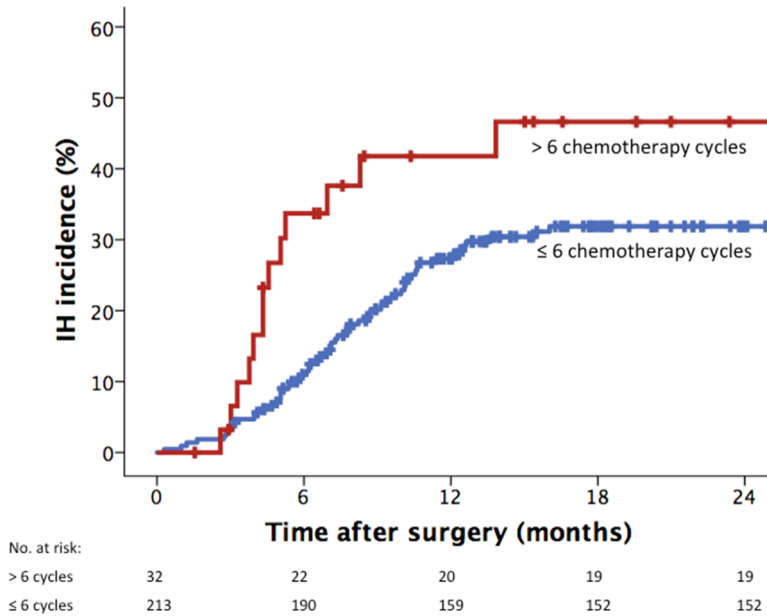


Figure 26. Kaplan-Meier plot of incisional hernia incidence for patients with more than six cycles of preoperative chemotherapy (red curve) and patients receiving six or fewer cycles of preoperative chemotherapy (blue curve). $P = 0.025$ (log-rank test).

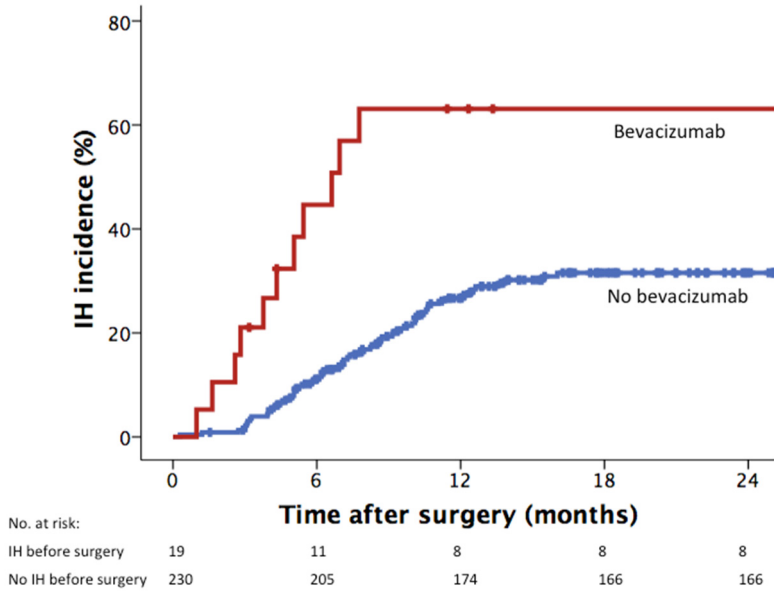


Figure 27. Kaplan-Meier plot of incisional hernia incidence for patients receiving (red curve) preoperative bevacizumab or not (blue curve). P < 0.0001 (log-rank test).

Table 13. Cox proportional hazard analysis of risk factors for incisional hernia.

| Factor | Univariable | | Multivariable | |
|---------------------------------------|------------------|---------|------------------|---------|
| | HR | P | HR | P |
| Gender (male:female) | 1.08 (0.68-1.71) | 0.736 | | |
| Age > 70 | 1.20 (0.76-1.90) | 0.438 | | |
| Current smoking | 0.82 (0.45-1.49) | 0.523 | | |
| Diabetes mellitus | 1.23 (0.65-2.33) | 0.519 | | |
| Body mass index > 26kg/m ² | 1.55 (0.99-2.41) | 0.054 | 1.51 (0.91-2.50) | 0.111 |
| Subcutaneous fat > 20 mm | 1.34 (0.74-2.43) | 0.334 | | |
| Body fat percentage > 50% | 1.74 (0.96-3.15) | 0.070 | 1.52 (0.81-2.86) | 0.194 |
| Skeletal muscle depletion | 0.76 (0.48-1.21) | 0.242 | | |
| Preoperative chemotherapy | 1.23 (0.78-1.93) | 0.380 | | |
| Preoperative chemotherapy > 6 cycles | 1.96 (1.08-3.57) | 0.028 | 2.12 (1.14-3.94) | 0.017 |
| Preoperative bevacizumab | 3.55 (1.85-6.69) | <0.0001 | 3.63 (1.86-7.08) | <0.0001 |
| Previous liver resection | 2.11 (1.20-3.71) | 0.010 | 1.32 (0.71-2.48) | 0.382 |
| Incisional hernia before surgery | 3.58 (2.20-5.84) | <0.0001 | 3.50 (1.98-6.18) | <0.0001 |
| ASA grade (1/2:3/4) | 1.17 (0.72-1.90) | 0.517 | | |
| Incision type (ERSI:Mercedes) | 1.12 (0.66-1.90) | 0.677 | | |
| Incisional surgical site infection | 1.45 (0.70-3.02) | 0.316 | | |
| Resection size (minor:major) | 1.29 (0.81-2.07) | 0.289 | | |
| Morbidity (Clavien-Dindo ≥ 3) | 1.10 (0.55-2.20) | 0.793 | | |
| Postoperative chemotherapy | 0.87 (0.54-1.42) | 0.583 | | |

HR, hazard ratio; ASA, American Society of Anesthesiologists; ERSI, extended right subcostal incision.

Discussion

The first part of this thesis deals with different methods of intraoperative liver tissue characterization and the second part covers different clinical aspects of chemotherapy impact on liver surgery. The liver tissue characterization studies were continuous cross-sectional studies while the studies of chemotherapy impact on liver surgery were retrospective cohort studies.

Liver tissue characterization

Many patients have reduced liver functionality. Patients with HCC often have an underlying fibrosis or cirrhosis. However, the majority of patients who undergo liver surgery in the Western world have CRLM, most of which has been treated with preoperative chemotherapy with the risk of steatosis, steatohepatitis and SOS. These types of liver damage may be challenging to determine prior to surgery, and previously unknown liver damage may be found or suspected during surgery. Our aim is to find a method that can provide a reliable assessment of these types of liver damage in order to give the surgeon the ability to modify the surgical procedure or strategy.

Microcirculation measurements

It is well known that liver damage negatively influences postoperative outcome with increased morbidity and even increased mortality.^{106, 108, 109, 122} However, the pathophysiological way in which liver damage affects the postoperative process is not known. One possibility is that hepatic microcirculation becomes affected. It has been shown that the liver regeneration cascade after liver resection in rats is triggered by an alteration in sinusoidal blood flow.^{230, 231}

In study I, we used SDF imaging to assess liver microcirculation. Our measurements showed that liver resection caused an increase in RBCV, where major resections had a greater increase than minor resections. This conforms with previous rat studies.²³² Furthermore, we found that both the major and minor resection groups had a

decrease in SD and a small increase in FSD after liver resection. This is also in line with previous animal studies results.^{233, 234} However, one explanation for the reduced SD could be that only the diameter of the red blood cell column is assessed with SDF imaging since SDF imaging does not visualize the sinusoidal wall but only contrasts between red blood cells and other tissue. Consequently, a higher RBCV could possibly lead to closer alignment of the red blood cells within the sinusoid, making the cell-free plasma layer to increase in size.

Our measurements show that SDF imaging could potentially be used to assess histological liver damage intraoperatively. Although in our study, patients with histological parenchyma damage were too few to be individually analyzed and had to be grouped together as a heterogeneous group consisting of patients with steatosis, steatohepatitis, SOS and fibrosis, patients with histological liver parenchymal damage were found to have increased RBCV, decreased FSD and greater SD compared to patients without liver damage. Increased RBCV has previously been observed in cirrhotic rats but steatosis and steatohepatitis have been associated with decreased sinusoidal blood flow.²³⁵⁻²³⁹ The decrease in FSD may be caused by increased fat and fibrosis content, resulting in less space being available to contain vessels. This is consistent with the findings in different animal models.^{235, 239} We also found SD to be increased in livers with parenchymal damage. We speculate that this could be the result of irregular vessel walls (the irregularity due to inflammation and fibrosis) causing non-laminar blood flow.

We found RBCV to be generally lower in comparison with previous studies using OPS imaging on human liver.^{195, 197, 240, 241} Still, the result is consistent with studies on rat liver.^{198, 232} We also found larger SD and more minor FSD than others but we used a newer measuring technique and we also removed the obscuring liver capsule.^{195, 197, 240, 241}

This is the first time histologically damaged liver in humans has been identified using in vivo microcirculation measurements. To our knowledge, no previously studies have been made in humans showing alterations in hepatic microcirculation after a liver resection.

The primary limitation of the study is the limited number of patients and in particular the number of patients with single histological parenchyma damages. Only 11 patients were found to have liver parenchyma damage, which were far too few to be statistically analyzed individually. Another limitation of the study is that there was no uniform anesthesia protocol. It has been shown that different anesthetic agents can affect liver microcirculation.^{242, 243} However, these studies compared halothane, which was not used in our study, with isoflurane and enflurane. In our study the anesthetic agents desflurane, isoflurane and sevoflurane were used. No difference in hepatic blood flow was found when comparing isoflurane and desflurane.²⁴⁴ Liver microcirculation could also be affected by other anesthesia factors such as the amount

of intravenous fluids and hemodynamic stability. However, we believe these factors to be represented by CVP and MAP, and we found no correlation of these to RBCV.

We had to remove a 2×2 cm part of the liver capsule to be able to get a sharp view of the liver microcirculation. Pre-study tests through the capsule only showed a blurred parenchyma which was inadequate for use for evaluation purposes. Only Rauchfuss et al. describe the same experience from OPS measurements on human liver while others do not seem to have this problem.^{195, 197, 198, 240, 241, 245} Yet the primary limitation of the method is its sensitivity to motion and pressure artifacts. Respiratory movements can be managed by temporarily stopping ventilation during image recording but propagating heart movements poses some problems. Image stabilization in the analysis software can help to limit this interference to an acceptable level though. Although we applied the SDF-probe only gently to the liver parenchyma with as little pressure as possible, we cannot exclude the possibility that the microcirculation was affected by compression of tissue vessels.

Driven by the fact that microcirculation may be affected by a contact method, we wanted to evaluate a non-contact method of microcirculation measurements. LSCI allows fast, non-contact microcirculatory measurements over wide areas. LSCI has previously been validated for measurement of hepatic microcirculation in an animal model.¹⁹⁸

In study II, we used LSCI to perform intraoperative liver microcirculation measurements in a pilot study on ten patients. Using this technique, the results are not given in a quantitative unit but are expressed as a raw flux value (LSPU). This differs from clinical microcirculation measurements with SDF imaging. Our measurements showed a relatively large intraindividual heterogeneity for hepatic blood flow with an intraindividual CV of 25%. Similar results have been found in the rat, using laser Doppler flowmetry (LDF) with several measuring points.²⁴⁶ Accordingly, it is an advantage for LSCI as a method, which uses a larger measuring area, thereby making it less sensitive to single point deviations. The greatest benefit of the method however, is the non-contact feasibility that allows measurements without interfering with the microcirculation due to pressure effects.

Although the preoperative liver function tests showed no abnormalities and all patients had a normal liver on intraoperative visual inspection, there were substantial differences in hepatic blood flow between patients with an interindividual CV of 28%. Still, hepatic microcirculation measurements using LDF and OPS have resulted in high values as well.^{197, 237} Also other methods for liver blood perfusion estimation such as MRI and liver blood inflow measurements have shown large interindividual variations. Hence, there seem to be a high intersubject variability in hepatic blood flow.

The main limitations of this study consist of the small number of included patients and the fact that we did not compare the LSCI results with any other microcirculatory measurement method. A major limitation of the method is its sensitivity to movement artifacts. All motions in the recorded surface are registered as microcirculation. Respiratory movements are easily handled by stopping ventilation in the same way as in SDF imaging measurements. However, the heartbeats propagated through the diaphragm to the liver seem to constitute a large part of ZIS. These movements were also obvious to the eye. The ZIS in the present study was significantly larger than a previous study on rat liver and human forearm skin.^{198, 247} In studies on the skin, tests have been made using an opaque reference area in order to carry out point-by-point subtraction of artifact signals.^{248, 249} It should be possible to develop similar solutions in a liver measurement setting as well.

Optical measurements

Pronounced liver steatosis is known to form a typical yellow appearance and SOS is characterized by a blue liver discoloration.¹¹³ Hence, these hepatic parenchyma changes should be well suited for detection with optical measuring methods. DRS is a fast and portable optical measuring method used in many different areas to detect different pathologies. In collaboration with colleagues from the Faculty of Engineering, LTH, we have developed equipment for clinical DRS measurements.

In study III, we evaluated DRS for surface measurements on 18 patients' resected liver specimens in an ex vivo setting. Although surface DRS measurements have been performed previously in several settings, it has never been used on human internal organs before.^{206, 250} Evers and Nachabé et al. have performed DRS measurements on several different human organs including the liver, but they use an invasive technique with a fiber-optic needle.^{202, 203, 207, 209, 211, 212} We believe that this could be problematic to implement in a clinical setting due to the risk of hemorrhage, in the same way as in needle biopsy.²⁵¹

The study objectives were to confirm that we could characterize tumor and liver parenchyma, investigate whether hepatic surface measurements are representative of the whole liver, and investigate the influence of the liver capsule on DRS measurements. An analytical model that has been widely used was used to analyze the measurement data.^{209, 210, 219, 252}

Because of our previous problems with the liver capsule when making measurements with SDF imaging, the impact of the capsule on DRS measurements was particularly interesting to us. Measurements through the liver capsule showed a liminal diminished diffuse reflectance in the visible wavelength range and no impact in the near-infrared range (figure 19). There was no influence on the shape of the spectra. When applying the data to the model, the only affected parameter was blood volume

fraction, which was found to be somewhat greater with the capsule intact. We speculate that this could be due to the process of removing the capsule, since some subcapsular blood could be removed with it.

Surface DRS measurements are limited to the most superficial part of the parenchyma with a penetration depth of 7 mm at most. According to our measurements, liver parenchyma composition was the same at the surface as in cross-section and we found nothing implying that the parenchyma structure was inhomogeneously distributed. Therefore, spread surface measurements should be representative of the whole normal liver.

In our study, tumor could easily be separated from liver parenchyma by observing DRS spectra (figure 19). The difference was especially clear in the wavelength range where hemoglobin and bile are the dominant chromophores between 500 and 900 nm.²⁰⁹ Previous studies on human liver parenchyma have revealed that liver parenchyma contains more blood and fat than tumor tissue, which could be verified in this study.^{207, 209} This is most certainly due to the extremely high vascularization of the liver parenchyma.

A limitation of this study is the small number of included patients. However, the total number of collected DRS spectra was high, which strengthens the data trustworthiness. Also, there is a possibility that measurements could result in marginally altered values in an in vivo setting since absorption coefficients vary slightly with temperature. To minimize this risk, measurements were performed in the operating theater directly after the excised liver section had been removed from the patient.

In study IV, intraoperative surface DRS measurements were performed in the interest of hepatic steatosis evaluation. Liver steatosis has a rising prevalence and in addition, preoperative chemotherapy treatment is known to induce steatosis further.^{109, 253} In the present study, 1210 DRS spectra including all histological steatosis grades were analyzed. No prior DRS liver studies have included severe steatosis.

The volumetric ratio parameter of the absorption of fat and water lipid/(lipid+water) turned out to be the most significant parameter to classify grades of steatosis after applying the data to the analytical model described earlier. Lipid/(lipid+water) revealed an obvious discrepancy between mild to moderate and between moderate to severe steatosis (figure 22). No distinction between no steatosis and mild steatosis could be found. Moderate-to-severe steatosis has been shown to impair liver regeneration after liver resection, and moderate or severe steatosis is associated with worse clinical outcome in patients after transplantation.^{254, 255} Moderate steatosis may be tolerable under certain circumstances but severely steatotic livers are generally not acceptable in liver transplantation.²⁵⁶ Thus, there is a need to be able to distinguish among none-to-mild, moderate and severe steatosis.

By comparison, between none-to-mild and moderate-to-severe steatosis grade, there were significant differences for all declared parameters (table 8). A higher steatosis grade resulted in a greater lipid/(lipid+water) ratio, which was expected. Bile volume fraction and blood volume fraction were less in moderate-to-severe compared to none-to-mild steatosis grades. We believe that this could be explained by suppression of blood by mechanical compression of sinusoids by fat vacuoles.

In fatty liver disease, homogeneously fatty liver deposition is the most common form but a geographic pattern also occurs as well as more unusual distribution forms such as focal and perivascular.²⁵⁷ Consequently, multiple site surface measurements should be performed to allow accurate steatosis grading.

The primary weakness of this study was the limited number of patients with moderate-to-severe steatosis. However, multiple site measurements resulted in 145 analyzed spectra in these patients, which should assure high reliability of the data. Also, the histological analysis was not based on the exact area of the measurement points but on the resected region of the liver. No analysis on an individual basis could be made due to the small number of patients with moderate-to-severe steatosis, thus the present study is limited to group level analysis.

The advantage of the method using surface DRS measurements is that multiple measurements may be made, which provides reliable data, and means there is less sensitivity to sampling error than biopsy and single point measurements. In contrast to previous published liver DRS studies, surface measurements allow, to the liver, non-invasive analysis and thus avoiding the risk of hemorrhage.

The primary limitation of the method is the potential impact of probe pressure on the liver parenchyma composition. To minimize this risk, a probe cylinder surrounding the probe was developed in order to distribute tissue pressure more consistently (figure 13). Also, the probe was applied with as little pressure as possible.

Influence of chemotherapy in liver surgery

Study V is a retrospective one in which we investigated the impact of preoperative chemotherapy treatment on liver volume regeneration. The impact of chemotherapy on liver regeneration has mostly been studied in the setting of PVE and the results from these studies are not unequivocal.^{191, 258, 259} Hence, the preoperative chemotherapy impact on liver volume regeneration has previously been studied only to a limited extent. In a study by Tanaka et al. the authors found that hepatic volume regeneration after primarily minor liver resections was unaffected by preoperative chemotherapy.²⁶⁰

In the present study we included major resections only for the purpose of increasing the probability of finding differences in regeneration due to greater total volume gain.²⁶¹ We found that the regenerated liver volume was lower in patients treated with preoperative chemotherapy. The %FLV_{post/pre-op} was 91% in patients who received no treatment and 83% in patients who had received preoperative chemotherapy treatment. Our regeneration results are in the upper range compared to previous studies on volume regeneration.²⁶²⁻²⁶⁴ Although most of the regeneration will take place soon after a resection the process is not completely finished until six months to one year after a hepatectomy.^{262, 265, 266} Therefore, we chose to compare preoperative volumes to the volumes attained approximately one year after surgery.

Theoretically, patients treated with preoperative chemotherapy could have increased preoperative liver volumes due to chemotherapy-induced steatosis since the liver volume has been shown to be proportional to the liver fat content.²⁶⁷ However, preoperative chemotherapy did not seem to change the liver volume in our study since the ratio of preoperative liver volume and BSA was the same for the two groups. Furthermore, no difference in liver regeneration was found when comparing patients treated with PVE compared to patients who were not. This is consistent with previous reports.²⁶⁸

Patients with postoperative liver insufficiency, in the form of postoperative peak bilirubin >50µmol/l and INR ≥1.7, had significantly lower volume regeneration. This possibly means that liver regeneration is determined shortly after surgery.

The main limitation of this study is due to its retrospective design, since we inevitably may have missed or misjudged some form of bias. Also, the total number of included patients was relatively small. As liver parenchymal histology was not studied, there exists a possibility that patients who received preoperative chemotherapy had impaired liver regeneration due to chemotherapy-induced liver damage such as steatosis, steatohepatitis and SOS. Moreover, although the majority of chemotherapy-treated patients received oxaliplatin-based regimens the total group was inhomogeneous and different regimens may have a different influence on regeneration.

Major liver resection, defined as resection of three or more of Couinaud's segments, was used as an inclusion criterion, but the type of resection varied slightly between groups. However, no difference has been shown in liver regeneration by comparison between right-sided and left-sided hemihepatectomies.²⁶⁹

It has been shown that patients with incisional hernia experience a lower health-related quality of life on physical components and worse body image.^{270, 271} In study VI, an incisional hernia incidence of 30.5% was found after analyzing 256 patients operated for CRLM. Incisional hernia incidence after liver resection has previously been reported to be between five and 31.5%.^{182, 186, 187, 272} The large spread in reported

incidence is almost certainly due to different diagnostic methods. Studies using CT for diagnosis have similar incidence rates as the present study.^{186, 272}

The abdominal wall closure was made according to guidelines in two layers with a running, slowly absorbable monofilament suture, although not standardized among operating surgeons with regard to the size of the bites for abdominal closure. The vast majority of incisional hernias were where the subcostal incision met the midline or in the midline cranial extension. It has been shown that midline incisions are more disposed to incisional hernias than transverse incisions.¹⁸³ Surgical site infection and obesity are two known risk factors for incisional hernia.¹⁸⁵ None of these were identified as risk factors in the present study, although BMI >26 kg/m² resulted in an almost significant P-value of 0.054 in univariable analysis. However, to detect such a difference, a larger study is probably needed. Also, as this was a retrospective study, there was a risk of underestimating infection incidence.

Multivariable analysis identified three independent risk factors for incisional hernia after open liver resection for CRLM. Preoperative chemotherapy >6 cycles resulted in a significant hazard ratio of 2.12. Increased risk for incisional hernia after preoperative chemotherapy has been shown in one previous study, although the authors in that study included different types of abdominal procedures.¹⁸⁵ The number of chemotherapy cycles is normally limited to six in a neoadjuvant setting.⁵⁹ The most powerful risk factor for incisional hernia was preoperative bevacizumab treatment with a hazard ratio of 3.63. Bevacizumab has previously been suggested to affect wound healing but no previous correlation to incisional hernia has been shown.²⁷³ Another strong risk factor for incisional hernia was the presence of incisional hernia before liver surgery. The majority of these patients had an incisional hernia after previous colorectal surgery.

The primary limitation of this study is the retrospective design and the relatively few patients with the detected risk factors for incisional hernia. For example, only 19 patients were treated with bevacizumab. Also, the incisional hernia incidence reflects radiological hernias, i.e. no evaluation of the clinical relevance was made.

Conclusions

- I. When measuring hepatic microcirculation with sidestream dark-field imaging, liver resection leads to an increase of red blood cell velocity in the sinusoids. Patients with liver parenchymal damage, defined as any of steatosis, steatohepatitis, sinusoidal obstruction syndrome or significant fibrosis, have higher red blood cell velocity, lesser functional sinusoidal density and larger sinusoidal diameter.
- II. Laser speckle contrast imaging can potentially be used to achieve intraoperative hepatic microcirculation measurements. However, movement artifact interference problems are considerable and need to be resolved.
- III. Surface measurements are a feasible and, to the liver, noninvasive approach to making diffuse reflectance spectroscopy measurements of the liver. Surface measurements are descriptive for the entire liver and it is possible to perform measurements across the liver capsule.
- IV. Liver surface diffuse reflectance spectroscopy measurements enable intraoperative steatosis grade evaluation with explicit distinction between mild-to-moderate and moderate-to-severe steatosis.
- V. Preoperative chemotherapy prior to a major liver resection in patients with colorectal liver metastases negatively affects volume regeneration. The time interval between the ending of chemotherapy and operation has a crucial effect on the power of this impact.
- VI. Prolonged preoperative chemotherapy, preoperative bevacizumab and previous incisional hernia are strong risk factors for the development of incisional hernia after open resection for colorectal liver metastases. The hernia location is almost exclusively in the midline.

Future perspectives

Liver tumor disease is today a comprehensive disorder where liver resection is the standard of care. However, many patients have liver injuries that can affect the choice of surgical strategy. The incidence of NAFLD is growing and preoperative chemotherapy is known to induce further liver damage. Our goal is to find a method that will provide an intraoperative and reliable estimate of the liver's condition to allow the surgeon to adjust the surgical procedure if necessary. The findings in this thesis show several steps toward this goal. Still, there is some research required to achieve the goal.

To use hepatic microcirculation measurements for parenchyma characterization is one interesting path to consider. However, the identified drawbacks of the methods for conducting microcirculatory measurements need to be addressed further. A larger study should be performed using SDF imaging for microcirculatory analysis. By including more patients, especially patients with the different forms of histological damage, more in-depth analysis of the impact of the various forms of liver damage on the microcirculation could be carried out. Also, the time-consuming semi-automatic off-line analysis have improved considerably since we performed our study. The off-line analysis contained some manual interventions which could be a possible source of error, and it would be interesting to test this new software version. It would also be interesting to perform a larger LSCI study including histological analysis to investigate the impact of liver damage on LSCI result. First, however, a method of filtering out the movement artifacts must be developed.

It is the optical measurements with DRS that we believe have the greatest potential and which we have chosen to continue to study in our projects. We have shown that it is possible to discriminate between different steatosis grades using DRS surface measurements on a group level. The next step will be to include additional patients, with a focus on patients with risk factors for steatosis, and also start evaluating other types of liver damage such as fibrosis and SOS. Moreover, we are working to improve the discrimination process. One way of doing this is by combining many different model parameters instead of just one as we have done so far. Another way could be to use principal component analysis to distinguish different conditions instead of using the analytical model that we are using today. By including more patients and improving the discrimination, we hope to be able to analyze data on an individual level with sensitivity and specificity evaluations. Provided that our subsequent studies

in the subject go well, we are also planning to construct a DRS probe for laparoscopic use. It would be an advantage to be able to start with minimally invasive surgery before a decision to conduct more extensive open surgery is made. To make multiple surface DRS measurements laparoscopically could also be a future, more accurate, alternative to liver biopsy in a wider context.

We showed that the incisional hernia location was almost exclusively in the midline after open surgery for CRLM. Whenever possible, the midline cranial extension of the subcostal incision should therefore be minimized or abandoned completely. Tests are being conducted at our institution where the cranial extension is excluded completely, which seems to be possible in the vast majority of cases. A new study has recently been started in our research group where a quality of life health survey regarding hernia symptoms has been sent to all patients who underwent open liver resection at our institution. Depending on the result of this survey, it may be relevant to perform a randomized interventional study to assess the impact of the midline cranial extension on incisional hernia incidence.

Acknowledgements

The realization of this thesis would not have been doable on my own. I would especially like to thank all the patients who have participated in the studies. I would also like to express my sincere gratitude and appreciation to the following colleagues, friends and family:

Christian Sturesson, Associate Professor of Surgery and main supervisor, for the best imaginable support and guidance and for giving me the most excellent scientific training. Also for your choice of me to be your first PhD student.

Roland Andersson, Professor of Surgery and co-supervisor, for constructive criticism, valuable advices and professional research guidance.

Nina Reistad, Associate Professor of Physics and co-author, who taught me in physics in the 90's and now has done a lot of work with construction of the DRS equipment used in the optical measurement projects, for great team-work.

Stefan Andersson-Engels, Professor of Physics, for making the collaboration possible that has led to our optical measurement projects.

Gert Lindell, Associate Professor of Surgery, head of the Section of Upper Gastrointestinal and Endocrine Surgery and co-author, for providing conditions and facilities to perform clinical research and giving me valuable advice and feedback along the way.

Sam Eriksson, fellow PhD student and co-author, with whom I started my research career with, for great collaboration and friendship.

All of my other co-authors, *Magnus Bergenfeldt*, *Per-Jonas Blind*, *Hannes Brange*, *Peter Strandberg Holka*, *Pehr Rissler*, *Lidewij Spelt* and *Carl-Fredrik Öberg*, for valuable contributions in the various studies.

All the non-already mentioned participants in the Hepato-Pancreato-Biliary team, *Bodil Andersson*, *Jenny Lundmark Rystedt*, *Bobby Tingsedt*, *Caroline Williamson* and *Daniel Åkerberg*, for invaluable help with the intraoperative measurements and for generally good advice and cheerful calls.

Helena Andersson, Marie-Louise Pendse, Tove Pentmo and Shila Zangoei at the surgical reception and all the nurses and other hospital personnel at the operating theater, for always being positive and helpful even though our research projects create extra work for you.

Monica Keidser, research administrator, for administrative guidance and help.

Maria Cornelius, friends and colleagues at Department of Surgery, Helsingborg Hospital, for giving me leave of absence to be able to finish this thesis.

My parents *Elsie* and *Hans*, who raised me with love and support and who always come to help when needed.

My beloved sons *Ted* and *Arvid*, whom I love to take a break and go out to do some physical activities with.

My wife *Tove* for love and support. I couldn't have made it without you!

Grants

The research projects in this thesis were partly financially supported by grants from Erik and Angelica Sparre Research Foundation, the Royal Physiographic Society of Lund and Thelma Zoégas Fund for Medical Research.

References

1. Si-Tayeb, K., Lemaigre, F. P., and Duncan, S. A., *Organogenesis and development of the liver*. Dev Cell, 2010. 18(2): p. 175-89.
2. Brunnicardi, F.C., Andersen, D.K., Billiar, T.R., Dunn, D.L., Hunter, J.G., Matthews, J.B., and Pollock, R.E., *Schwartz's principles of surgery 10th edition*. McGraw-Hill Education, 2015.
3. Jayyosi, C., Coret, M., and Bruyere-Garnier, K., *Characterizing liver capsule microstructure via in situ bulge test coupled with multiphoton imaging*. J Mech Behav Biomed Mater, 2016. 54: p. 229-43.
4. Chen, T. S. and Chen, P. S., *The accomplishments of Sir James Cantlie*. J Med Biogr, 1999. 7(4): p. 197-9.
5. Cantlie, J., *On a new arrangement of the right and left lobes of the liver*. Proc Anat Soc Great Britain Ireland, 1897. 32(4).
6. Couinaud, C., *Le foie: études anatomiques et chirurgicales*. 1957: Masson & Cie.
7. Juza, R. M. and Pauli, E. M., *Clinical and surgical anatomy of the liver: a review for clinicians*. Clin Anat, 2014. 27(5): p. 764-9.
8. Abdel-Misih, S. R. and Bloomston, M., *Liver anatomy*. Surg Clin North Am, 2010. 90(4): p. 643-53.
9. Marieb, E.N. and Hoehn, K., *Human anatomy and physiology 7th edition*. Pearson Benjamin Cummings, 2007.
10. Koeppen, B.M. and Stanton, B.A., *Berne and Levy Physiology 6th edition*. Mosby Elsevier, 2008.
11. Ferlay, J., Soerjomataram, I., Dikshit, R., Eser, S., Mathers, C., Rebelo, M., Parkin, D. M., Forman, D., and Bray, F., *Cancer incidence and mortality worldwide: sources, methods and major patterns in GLOBOCAN 2012*. Int J Cancer, 2015. 136(5): p. E359-86.
12. El-Serag, H. B., *Hepatocellular carcinoma*. N Engl J Med, 2011. 365(12): p. 1118-27.
13. Forner, Alejandro, Llovet, Josep M., and Bruix, Jordi, *Hepatocellular carcinoma*. The Lancet, 2012. 379(9822): p. 1245-1255.
14. Sangiovanni, A., Prati, G. M., Fasani, P., Ronchi, G., Romeo, R., Manini, M., Del Ninno, E., Morabito, A., and Colombo, M., *The natural history of compensated cirrhosis due to hepatitis C virus: A 17-year cohort study of 214 patients*. Hepatology, 2006. 43(6): p. 1303-10.
15. Llovet, J. M., Bru, C., and Bruix, J., *Prognosis of hepatocellular carcinoma: the BCLC staging classification*. Semin Liver Dis, 1999. 19(3): p. 329-38.
16. Child, C. G. and Turcotte, J. G., *Surgery and portal hypertension*. Major Probl Clin Surg, 1964. 1: p. 1-85.

17. Bruix, J. and Sherman, M., *Management of hepatocellular carcinoma: an update*. Hepatology, 2011. 53(3): p. 1020-2.
18. Lencioni, R., *Loco-regional treatment of hepatocellular carcinoma*. Hepatology, 2010. 52(2): p. 762-73.
19. Keating, Gillian M., *Sorafenib: A Review in Hepatocellular Carcinoma*. Targeted Oncology, 2017: p. 1-11.
20. Tyson, G. L. and El-Serag, H. B., *Risk factors for cholangiocarcinoma*. Hepatology, 2011. 54(1): p. 173-84.
21. Blechacz, B., *Cholangiocarcinoma: Current Knowledge and New Developments*. Gut Liver, 2017. 11(1): p. 13-26.
22. Patel, T., *Cholangiocarcinoma*. Nat Clin Pract Gastroenterol Hepatol, 2006. 3(1): p. 33-42.
23. Morimoto, Y., et al., *Long-term survival and prognostic factors in the surgical treatment for intrahepatic cholangiocarcinoma*. J Hepatobiliary Pancreat Surg, 2003. 10(6): p. 432-40.
24. Endo, I., et al., *Intrahepatic cholangiocarcinoma: rising frequency, improved survival, and determinants of outcome after resection*. Ann Surg, 2008. 248(1): p. 84-96.
25. Duffy, A., et al., *Gallbladder cancer (GBC): 10-year experience at Memorial Sloan-Kettering Cancer Centre (MSKCC)*. J Surg Oncol, 2008. 98(7): p. 485-9.
26. Hundal, R. and Shaffer, E. A., *Gallbladder cancer: epidemiology and outcome*. Clin Epidemiol, 2014. 6: p. 99-109.
27. Rakic, M., Patrlj, L., Kopljar, M., Klicek, R., Kolovrat, M., Loncar, B., and Busic, Z., *Gallbladder cancer*. Hepatobiliary Surg Nutr, 2014. 3(5): p. 221-6.
28. Ananthakrishnan, A., Gogineni, V., and Saeian, K., *Epidemiology of primary and secondary liver cancers*. Semin Intervent Radiol, 2006. 23(1): p. 47-63.
29. Golubnitschaja, O. and Sridhar, K. C., *Liver metastatic disease: new concepts and biomarker panels to improve individual outcomes*. Clin Exp Metastasis, 2016. 33(8): p. 743-755.
30. Obenauf, A. C. and Massague, J., *Surviving at a distance: organ specific metastasis*. Trends Cancer, 2015. 1(1): p. 76-91.
31. Burt, R. W., *Colon cancer screening*. Gastroenterology, 2000. 119(3): p. 837-53.
32. Rustgi, A. K., *The genetics of hereditary colon cancer*. Genes Dev, 2007. 21(20): p. 2525-38.
33. Hackl, C., Neumann, P., Gerken, M., Loss, M., Klinkhammer-Schalke, M., and Schlitt, H. J., *Treatment of colorectal liver metastases in Germany: a ten-year population-based analysis of 5772 cases of primary colorectal adenocarcinoma*. BMC Cancer, 2014. 14: p. 810.
34. Leporrier, J., Maurel, J., Chiche, L., Bara, S., Segol, P., and Launoy, G., *A population-based study of the incidence, management and prognosis of hepatic metastases from colorectal cancer*. Br J Surg, 2006. 93(4): p. 465-74.
35. Manfredi, S., Lepage, C., Hatem, C., Coatmeur, O., Faivre, J., and Bouvier, A. M., *Epidemiology and management of liver metastases from colorectal cancer*. Ann Surg, 2006. 244(2): p. 254-9.

36. Fong, Y., Fortner, J., Sun, R. L., Brennan, M. F., and Blumgart, L. H., *Clinical score for predicting recurrence after hepatic resection for metastatic colorectal cancer: analysis of 1001 consecutive cases*. *Ann Surg*, 1999. 230(3): p. 309-18; discussion 318-21.
37. Angelsen, J. H., Horn, A., Sorbye, H., Eide, G. E., Loes, I. M., and Viste, A., *Population-based study on resection rates and survival in patients with colorectal liver metastasis in Norway*. *Br J Surg*, 2017. 104(5): p. 580-589.
38. Tzeng, C. W. and Aloia, T. A., *Colorectal liver metastases*. *J Gastrointest Surg*, 2013. 17(1): p. 195-201; quiz p.201-2.
39. Brouquet, A., et al., *Surgical strategies for synchronous colorectal liver metastases in 156 consecutive patients: classic, combined or reverse strategy?* *J Am Coll Surg*, 2010. 210(6): p. 934-41.
40. Choti, M. A., Sitzmann, J. V., Tiburi, M. F., Sumetchotimetha, W., Rangsri, R., Schulick, R. D., Lillemoe, K. D., Yeo, C. J., and Cameron, J. L., *Trends in long-term survival following liver resection for hepatic colorectal metastases*. *Ann Surg*, 2002. 235(6): p. 759-66.
41. Fernandez, F. G., Drebin, J. A., Linehan, D. C., Dehdashti, F., Siegel, B. A., and Strasberg, S. M., *Five-year survival after resection of hepatic metastases from colorectal cancer in patients screened by positron emission tomography with F-18 fluorodeoxyglucose (FDG-PET)*. *Ann Surg*, 2004. 240(3): p. 438-47; discussion 447-50.
42. Charnsangavej, C., Clary, B., Fong, Y., Grothey, A., Pawlik, T. M., and Choti, M. A., *Selection of patients for resection of hepatic colorectal metastases: expert consensus statement*. *Ann Surg Oncol*, 2006. 13(10): p. 1261-8.
43. Pawlik, T. M., Schulick, R. D., and Choti, M. A., *Expanding criteria for resectability of colorectal liver metastases*. *Oncologist*, 2008. 13(1): p. 51-64.
44. Pawlik, T. M., et al., *Effect of surgical margin status on survival and site of recurrence after hepatic resection for colorectal metastases*. *Ann Surg*, 2005. 241(5): p. 715-22, discussion 722-4.
45. Masi, G., Fornaro, L., Caparello, C., and Falcone, A., *Liver metastases from colorectal cancer: how to best complement medical treatment with surgical approaches*. *Future Oncol*, 2011. 7(11): p. 1299-323.
46. Adams, R. B., Aloia, T. A., Loyer, E., Pawlik, T. M., Taouli, B., and Vauthey, J. N., *Selection for hepatic resection of colorectal liver metastases: expert consensus statement*. *HPB (Oxford)*, 2013. 15(2): p. 91-103.
47. Bismuth, H., Adam, R., Levi, F., Farabos, C., Waechter, F., Castaing, D., Majno, P., and Engerran, L., *Resection of nonresectable liver metastases from colorectal cancer after neoadjuvant chemotherapy*. *Ann Surg*, 1996. 224(4): p. 509-20; discussion 520-2.
48. Martinez, L., Puig, I., and Valls, C., *Colorectal liver metastases: Radiological diagnosis and staging*. *Eur J Surg Oncol*, 2007. 33 Suppl 2: p. S5-16.
49. Schima, W., Kulinna, C., Langenberger, H., and Ba-Ssalamah, A., *Liver metastases of colorectal cancer: US, CT or MR?* *Cancer Imaging*, 2005. 5 Spec No A: p. S149-56.
50. Misiakos, E. P., Karidis, N. P., and Kouraklis, G., *Current treatment for colorectal liver metastases*. *World J Gastroenterol*, 2011. 17(36): p. 4067-75.
51. Seale, M. K., Catalano, O. A., Saini, S., Hahn, P. F., and Sahani, D. V., *Hepatobiliary-specific MR contrast agents: role in imaging the liver and biliary tree*. *Radiographics*, 2009. 29(6): p. 1725-48.

52. Zech, C. J., Korpraphong, P., Huppertz, A., Denecke, T., Kim, M. J., Tanomkiat, W., Jonas, E., and Ba-Ssalamah, A., *Randomized multicentre trial of gadoxetic acid-enhanced MRI versus conventional MRI or CT in the staging of colorectal cancer liver metastases*. British Journal of Surgery, 2014. 101(6): p. 613-621.
53. Koh, D. M., Collins, D. J., Wallace, T., Chau, I., and Riddell, A. M., *Combining diffusion-weighted MRI with Gd-EOB-DTPA-enhanced MRI improves the detection of colorectal liver metastases*. Br J Radiol, 2012. 85(1015): p. 980-9.
54. Kim, H. J., Lee, S. S., Byun, J. H., Kim, J. C., Yu, C. S., Park, S. H., Kim, A. Y., and Ha, H. K., *Incremental value of liver MR imaging in patients with potentially curable colorectal hepatic metastasis detected at CT: a prospective comparison of diffusion-weighted imaging, gadoxetic acid-enhanced MR imaging, and a combination of both MR techniques*. Radiology, 2015. 274(3): p. 712-22.
55. Sacks, A., Peller, P. J., Surasi, D. S., Chatburn, L., Mercier, G., and Subramaniam, R. M., *Value of PET/CT in the management of liver metastases, part 1*. AJR Am J Roentgenol, 2011. 197(2): p. W256-9.
56. Heinrich, S. and Lang, H., *Liver metastases from colorectal cancer: technique of liver resection*. J Surg Oncol, 2013. 107(6): p. 579-84.
57. Scoggins, C. R., Campbell, M. L., Landry, C. S., Slomiany, B. A., Woodall, C. E., McMasters, K. M., and Martin, R. C., *Preoperative chemotherapy does not increase morbidity or mortality of hepatic resection for colorectal cancer metastases*. Ann Surg Oncol, 2009. 16(1): p. 35-41.
58. Goldberg, R. M., *Advances in the treatment of metastatic colorectal cancer*. Oncologist, 2005. 10 Suppl 3: p. 40-8.
59. Nordlinger, B., et al., *Perioperative chemotherapy with FOLFOX4 and surgery versus surgery alone for resectable liver metastases from colorectal cancer (EORTC Intergroup trial 40983): a randomised controlled trial*. Lancet, 2008. 371(9617): p. 1007-16.
60. Kassahun, W. T., *Unresolved issues and controversies surrounding the management of colorectal cancer liver metastasis*. World J Surg Oncol, 2015. 13: p. 61.
61. Nordlinger, B., et al., *Perioperative FOLFOX4 chemotherapy and surgery versus surgery alone for resectable liver metastases from colorectal cancer (EORTC 40983): long-term results of a randomised, controlled, phase 3 trial*. Lancet Oncol, 2013. 14(12): p. 1208-15.
62. Vauthey, J. N., Nordlinger, B., Kopetz, S., and Poston, G., *Sequenced chemotherapy and surgery for potentially resectable colorectal liver metastases: a debate over goals of research and an approach while the jury remains out*. Ann Surg Oncol, 2010. 17(8): p. 1983-6.
63. Vauthey, J. N., et al., *Standardized measurement of the future liver remnant prior to extended liver resection: methodology and clinical associations*. Surgery, 2000. 127(5): p. 512-9.
64. Kishi, Y., Abdalla, E. K., Chun, Y. S., Zorzi, D., Madoff, D. C., Wallace, M. J., Curley, S. A., and Vauthey, J. N., *Three hundred and one consecutive extended right hepatectomies: evaluation of outcome based on systematic liver volumetry*. Ann Surg, 2009. 250(4): p. 540-8.

65. Nagasue, N., Yukaya, H., Ogawa, Y., Kohno, H., and Nakamura, T., *Human liver regeneration after major hepatic resection. A study of normal liver and livers with chronic hepatitis and cirrhosis.* Ann Surg, 1987. 206(1): p. 30-9.
66. Ferrero, A., Vigano, L., Polastri, R., Muratore, A., Eminencedic, H., Regge, D., and Capussotti, L., *Postoperative liver dysfunction and future remnant liver: where is the limit? Results of a prospective study.* World J Surg, 2007. 31(8): p. 1643-51.
67. Di Stefano, D. R., et al., *Preoperative percutaneous portal vein embolization: evaluation of adverse events in 188 patients.* Radiology, 2005. 234(2): p. 625-30.
68. Kinoshita, Hiroaki, Sakai, Katsuji, Hirohashi, Kazuhiro, Igawa, Sumito, Yamasaki, Osamu, and Kubo, Shoji, *Preoperative portal vein embolization for hepatocellular carcinoma.* World Journal of Surgery, 1986. 10(5): p. 803-808.
69. Abulkhir, A., Limongelli, P., Healey, A. J., Damrah, O., Tait, P., Jackson, J., Habib, N., and Jiao, L. R., *Preoperative portal vein embolization for major liver resection: a meta-analysis.* Ann Surg, 2008. 247(1): p. 49-57.
70. Sharma, S., Camci, C., and Jabbour, N., *Management of hepatic metastasis from colorectal cancers: an update.* J Hepatobiliary Pancreat Surg, 2008. 15(6): p. 570-80.
71. Regimbeau, J. M., Cosse, C., Kaiser, G., Hubert, C., Laurent, C., Lapointe, R., Isoniemi, H., and Adam, R., *Feasibility, safety and efficacy of two-stage hepatectomy for bilobar liver metastases of colorectal cancer: a LiverMetSurvey analysis.* HPB (Oxford), 2017.
72. Wicherts, D. A., et al., *Long-term results of two-stage hepatectomy for irresectable colorectal cancer liver metastases.* Ann Surg, 2008. 248(6): p. 994-1005.
73. Schnitzbauer, A. A., et al., *Right portal vein ligation combined with in situ splitting induces rapid left lateral liver lobe hypertrophy enabling 2-staged extended right hepatic resection in small-for-size settings.* Ann Surg, 2012. 255(3): p. 405-14.
74. Alvarez, F. A., Ardiles, V., Sanchez Claria, R., Pekolj, J., and de Santibanes, E., *Associating liver partition and portal vein ligation for staged hepatectomy (ALPPS): tips and tricks.* J Gastrointest Surg, 2013. 17(4): p. 814-21.
75. Schadde, Erik, et al., *ALPPS Offers a Better Chance of Complete Resection in Patients with Primarily Unresectable Liver Tumors Compared with Conventional-Staged Hepatectomies: Results of a Multicenter Analysis.* World Journal of Surgery, 2014. 38(6): p. 1510-1519.
76. Mentha, G., Majno, P. E., Andres, A., Rubbia-Brandt, L., Morel, P., and Roth, A. D., *Neoadjuvant chemotherapy and resection of advanced synchronous liver metastases before treatment of the colorectal primary.* Br J Surg, 2006. 93(7): p. 872-8.
77. Lim, Chetana, Doussot, Alexandre, Osseis, Michael, Salloum, Chady, Gomez Gavara, Concepcion, Compagnon, Philippe, Brunetti, Francesco, Calderaro, Julien, and Azoulay, Daniel, *Primary Tumor Versus Liver-First Strategy in Patients with Stage IVA Colorectal Cancer: A Propensity Score Analysis of Long-term Outcomes and Recurrence Pattern.* Annals of Surgical Oncology, 2016. 23(9): p. 3024-3032.
78. Reddy, S. K., et al., *Simultaneous resections of colorectal cancer and synchronous liver metastases: a multi-institutional analysis.* Ann Surg Oncol, 2007. 14(12): p. 3481-91.
79. Tanaka, K., Shimada, H., Matsuo, K., Nagano, Y., Endo, I., Sekido, H., and Togo, S., *Outcome after simultaneous colorectal and hepatic resection for colorectal cancer with synchronous metastases.* Surgery, 2004. 136(3): p. 650-9.

80. Cauchy, F., Aussilhou, B., Dokmak, S., Fuks, D., Gaujoux, S., Farges, O., Faivre, S., Lepillé, D., and Belghiti, J., *Reappraisal of the risks and benefits of major liver resection in patients with initially unresectable colorectal liver metastases*. *Annals of surgery*, 2012. 256(5): p. 746-752; discussion 752-754.
81. Adam, R., et al., *Patients with initially unresectable colorectal liver metastases: is there a possibility of cure?* *J Clin Oncol*, 2009. 27(11): p. 1829-35.
82. Goere, D., Gaujoux, S., Deschamp, F., Dumont, F., Souadka, A., Dromain, C., Ducreux, M., and Elias, D., *Patients operated on for initially unresectable colorectal liver metastases with missing metastases experience a favorable long-term outcome*. *Ann Surg*, 2011. 254(1): p. 114-8.
83. Ribero, D., et al., *Bevacizumab improves pathologic response and protects against hepatic injury in patients treated with oxaliplatin-based chemotherapy for colorectal liver metastases*. *Cancer*, 2007. 110(12): p. 2761-7.
84. Hurwitz, H., et al., *Bevacizumab plus irinotecan, fluorouracil, and leucovorin for metastatic colorectal cancer*. *N Engl J Med*, 2004. 350(23): p. 2335-42.
85. Van Cutsem, E., et al., *Cetuximab and chemotherapy as initial treatment for metastatic colorectal cancer*. *N Engl J Med*, 2009. 360(14): p. 1408-17.
86. Van Cutsem, E., et al., *Cetuximab plus irinotecan, fluorouracil, and leucovorin as first-line treatment for metastatic colorectal cancer: updated analysis of overall survival according to tumor KRAS and BRAF mutation status*. *J Clin Oncol*, 2011. 29(15): p. 2011-9.
87. Tomlinson, J. S., et al., *Actual 10-year survival after resection of colorectal liver metastases defines cure*. *J Clin Oncol*, 2007. 25(29): p. 4575-80.
88. Simmonds, P. C., Primrose, J. N., Colquitt, J. L., Garden, O. J., Poston, G. J., and Rees, M., *Surgical resection of hepatic metastases from colorectal cancer: a systematic review of published studies*. *Br J Cancer*, 2006. 94(7): p. 982-99.
89. Adam, R., Bismuth, H., Castaing, D., Waechter, F., Navarro, F., Abascal, A., Majno, P., and Engerran, L., *Repeat hepatectomy for colorectal liver metastases*. *Ann Surg*, 1997. 225(1): p. 51-60; discussion 60-2.
90. Neal, C. P., Nana, G. R., Jones, M., Cairns, V., Ngu, W., Isherwood, J., Dennison, A. R., and Garcea, G., *Repeat hepatectomy is independently associated with favorable long-term outcome in patients with colorectal liver metastases*. *Cancer Med*, 2017. 6(2): p. 331-338.
91. de Jong, M. C., et al., *Repeat curative intent liver surgery is safe and effective for recurrent colorectal liver metastasis: results from an international multi-institutional analysis*. *J Gastrointest Surg*, 2009. 13(12): p. 2141-51.
92. Petrowsky, H., Gonen, M., Jarnagin, W., Lorenz, M., DeMatteo, R., Heinrich, S., Encke, A., Blumgart, L., and Fong, Y., *Second liver resections are safe and effective treatment for recurrent hepatic metastases from colorectal cancer: a bi-institutional analysis*. *Ann Surg*, 2002. 235(6): p. 863-71.
93. Curley, S. A., et al., *Radiofrequency ablation of unresectable primary and metastatic hepatic malignancies: results in 123 patients*. *Ann Surg*, 1999. 230(1): p. 1-8.

94. Vogl, T. J., Farshid, P., Naguib, N. N., Darvishi, A., Bazrafshan, B., Mbalisike, E., Burkhard, T., and Zangos, S., *Thermal ablation of liver metastases from colorectal cancer: radiofrequency, microwave and laser ablation therapies*. Radiol Med, 2014. 119(7): p. 451-61.
95. Reuter, N. P., Woodall, C. E., Scoggins, C. R., McMasters, K. M., and Martin, R. C., *Radiofrequency ablation vs. resection for hepatic colorectal metastasis: therapeutically equivalent?* J Gastrointest Surg, 2009. 13(3): p. 486-91.
96. Weng, M., Zhang, Y., Zhou, D., Yang, Y., Tang, Z., Zhao, M., Quan, Z., and Gong, W., *Radiofrequency ablation versus resection for colorectal cancer liver metastases: a meta-analysis*. PLoS One, 2012. 7(9): p. e45493.
97. Imai, K., Allard, M. A., Castro Benitez, C., Vibert, E., Sa Cunha, A., Cherqui, D., Castaing, D., Baba, H., and Adam, R., *Long-term outcomes of radiofrequency ablation combined with hepatectomy compared with hepatectomy alone for colorectal liver metastases*. Br J Surg, 2017. 104(5): p. 570-579.
98. Vuppalanchi, R. and Chalasani, N., *Nonalcoholic fatty liver disease and nonalcoholic steatohepatitis: Selected practical issues in their evaluation and management*. Hepatology, 2009. 49(1): p. 306-17.
99. Angulo, P., *Nonalcoholic fatty liver disease*. N Engl J Med, 2002. 346(16): p. 1221-31.
100. D'Alessandro, A. M., et al., *The predictive value of donor liver biopsies for the development of primary nonfunction after orthotopic liver transplantation*. Transplantation, 1991. 51(1): p. 157-63.
101. Laurent, A., et al., *Controlling tumor growth by modulating endogenous production of reactive oxygen species*. Cancer Res, 2005. 65(3): p. 948-56.
102. Zorzi, D., Laurent, A., Pawlik, T. M., Lauwers, G. Y., Vauthey, J. N., and Abdalla, E. K., *Chemotherapy-associated hepatotoxicity and surgery for colorectal liver metastases*. Br J Surg, 2007. 94(3): p. 274-86.
103. Begriche, K., Igoudjil, A., Pessayre, D., and Fromenty, B., *Mitochondrial dysfunction in NASH: causes, consequences and possible means to prevent it*. Mitochondrion, 2006. 6(1): p. 1-28.
104. Belghiti, J., Hiramatsu, K., Benoist, S., Massault, P., Sauvanet, A., and Farges, O., *Seven hundred forty-seven hepatectomies in the 1990s: an update to evaluate the actual risk of liver resection*. J Am Coll Surg, 2000. 191(1): p. 38-46.
105. Gomez, D., Malik, H. Z., Bonney, G. K., Wong, V., Toogood, G. J., Lodge, J. P., and Prasad, K. R., *Steatosis predicts postoperative morbidity following hepatic resection for colorectal metastasis*. Br J Surg, 2007. 94(11): p. 1395-402.
106. McCormack, L., Petrowsky, H., Jochum, W., Furrer, K., and Clavien, P. A., *Hepatic steatosis is a risk factor for postoperative complications after major hepatectomy: a matched case-control study*. Ann Surg, 2007. 245(6): p. 923-30.
107. Khan, A. Z., Morris-Stiff, G., and Makuuchi, M., *Patterns of chemotherapy-induced hepatic injury and their implications for patients undergoing liver resection for colorectal liver metastases*. J Hepatobiliary Pancreat Surg, 2009. 16(2): p. 137-44.
108. Robinson, S. M., Wilson, C. H., Burt, A. D., Manas, D. M., and White, S. A., *Chemotherapy-associated liver injury in patients with colorectal liver metastases: a systematic review and meta-analysis*. Ann Surg Oncol, 2012. 19(13): p. 4287-99.

109. Vauthey, J. N., et al., *Chemotherapy regimen predicts steatohepatitis and an increase in 90-day mortality after surgery for hepatic colorectal metastases*. J Clin Oncol, 2006. 24(13): p. 2065-72.
110. Kleiner, D. E., et al., *Design and validation of a histological scoring system for nonalcoholic fatty liver disease*. Hepatology, 2005. 41(6): p. 1313-21.
111. Patel, Vaishali and Sanyal, Arun J., *Drug-Induced Steatohepatitis*. Clinics in liver disease, 2013. 17(4): p. 533-vii.
112. Stevenson, Heather L., Prats, Mariana M., and Sasatomi, Eizaburo, *Chemotherapy-induced Sinusoidal Injury (CSI) score: a novel histologic assessment of chemotherapy-related hepatic sinusoidal injury in patients with colorectal liver metastasis*. BMC Cancer, 2017. 17: p. 35.
113. Kneuert, P. J., Maithel, S. K., Staley, C. A., and Kooby, D. A., *Chemotherapy-associated liver injury: impact on surgical management of colorectal cancer liver metastases*. Ann Surg Oncol, 2011. 18(1): p. 181-90.
114. Robinson, S. M., Scott, J., Manas, D. M., and White, S. A., *The Assessment and Management of Chemotherapy Associated Liver Injury*, in *Hepatic Surgery*, H. Abdeldayem, Editor. 2013.
115. Aloia, T., et al., *Liver histology and surgical outcomes after preoperative chemotherapy with fluorouracil plus oxaliplatin in colorectal cancer liver metastases*. J Clin Oncol, 2006. 24(31): p. 4983-90.
116. Karoui, M., Penna, C., Amin-Hashem, M., Mitry, E., Benoist, S., Franc, B., Rougier, P., and Nordlinger, B., *Influence of preoperative chemotherapy on the risk of major hepatectomy for colorectal liver metastases*. Ann Surg, 2006. 243(1): p. 1-7.
117. Rubbia-Brandt, L., et al., *Severe hepatic sinusoidal obstruction associated with oxaliplatin-based chemotherapy in patients with metastatic colorectal cancer*. Ann Oncol, 2004. 15(3): p. 460-6.
118. Rubbia-Brandt, L., et al., *Sinusoidal obstruction syndrome and nodular regenerative hyperplasia are frequent oxaliplatin-associated liver lesions and partially prevented by bevacizumab in patients with hepatic colorectal metastasis*. Histopathology, 2010. 56(4): p. 430-9.
119. Narita, M., Oussoultzoglou, E., Fuchshuber, P., Pessaux, P., Chenard, M. P., Rosso, E., Nobili, C., Jaeck, D., and Bachellier, P., *What is a safe future liver remnant size in patients undergoing major hepatectomy for colorectal liver metastases and treated by intensive preoperative chemotherapy?* Ann Surg Oncol, 2012. 19(8): p. 2526-38.
120. Fan, C. Q. and Crawford, J. M., *Sinusoidal Obstruction Syndrome (Hepatic Venooclusive Disease)*. Journal of Clinical and Experimental Hepatology, 2014. 4(4): p. 332-346.
121. Vreuls, C. P., Driessen, A., Olde Damink, S. W., Koek, G. H., Duimel, H., van den Broek, M. A., Dejong, C. H., Braet, F., and Wisse, E., *Sinusoidal obstruction syndrome (SOS): A light and electron microscopy study in human liver*. Micron, 2016. 84: p. 17-22.
122. Narita, M., Oussoultzoglou, E., Chenard, M. P., Rosso, E., Casnedi, S., Pessaux, P., Bachellier, P., and Jaeck, D., *Sinusoidal obstruction syndrome compromises liver regeneration in patients undergoing two-stage hepatectomy with portal vein embolization*. Surg Today, 2011. 41(1): p. 7-17.

123. Rubbia-Brandt, L., Tauzin, S., Brezault, C., Delucinge-Vivier, C., Descombes, P., Dousset, B., Majno, P. E., Mentha, G., and Terris, B., *Gene expression profiling provides insights into pathways of oxaliplatin-related sinusoidal obstruction syndrome in humans*. *Mol Cancer Ther*, 2011. 10(4): p. 687-96.
124. Bohte, A. E., van Werven, J. R., Bipat, S., and Stoker, J., *The diagnostic accuracy of US, CT, MRI and 1H-MRS for the evaluation of hepatic steatosis compared with liver biopsy: a meta-analysis*. *Eur Radiol*, 2011. 21(1): p. 87-97.
125. Levene, A. P. and Goldin, R. D., *The epidemiology, pathogenesis and histopathology of fatty liver disease*. *Histopathology*, 2012. 61(2): p. 141-52.
126. Lucero, C. and Brown, R. S., *Noninvasive measures of liver fibrosis and severity of liver disease*. *Gastroenterology and Hepatology*, 2016. 12(1): p. 33-40.
127. Dulai, P. S., Sirlin, C. B., and Loomba, R., *MRI and MRE for non-invasive quantitative assessment of hepatic steatosis and fibrosis in NAFLD and NASH: Clinical trials to clinical practice*. *J Hepatol*, 2016. 65(5): p. 1006-1016.
128. van den Broek, M. A., et al., *Hyaluronic acid as a marker of hepatic sinusoidal obstruction syndrome secondary to oxaliplatin-based chemotherapy in patients with colorectal liver metastases*. *Ann Surg Oncol*, 2013. 20(5): p. 1462-9.
129. Nakano, H., Oussoultzoglou, E., Rosso, E., Casnedi, S., Chenard-Neu, M. P., Dufour, P., Bachellier, P., and Jaeck, D., *Sinusoidal injury increases morbidity after major hepatectomy in patients with colorectal liver metastases receiving preoperative chemotherapy*. *Ann Surg*, 2008. 247(1): p. 118-24.
130. Overman, M. J., et al., *Oxaliplatin-mediated increase in spleen size as a biomarker for the development of hepatic sinusoidal injury*. *J Clin Oncol*, 2010. 28(15): p. 2549-55.
131. Park, S., et al., *Changes in Noninvasive Liver Fibrosis Indices and Spleen Size During Chemotherapy: Potential Markers for Oxaliplatin-Induced Sinusoidal Obstruction Syndrome*. *Medicine (Baltimore)*, 2016. 95(2): p. e2454.
132. Soubrane, O., Brouquet, A., Zalinski, S., Terris, B., Brezault, C., Mallet, V., Goldwasser, F., and Scatton, O., *Predicting high grade lesions of sinusoidal obstruction syndrome related to oxaliplatin-based chemotherapy for colorectal liver metastases: correlation with post-hepatectomy outcome*. *Ann Surg*, 2010. 251(3): p. 454-60.
133. Bravo, A. A., Sheth, S. G., and Chopra, S., *Liver biopsy*. *N Engl J Med*, 2001. 344(7): p. 495-500.
134. Cresswell, Adrian B., Welsh, Fenella K. S., and Rees, Myrddin, *A diagnostic paradigm for resectable liver lesions: to biopsy or not to biopsy?* HPB : The Official Journal of the International Hepato Pancreato Biliary Association, 2009. 11(7): p. 533-540.
135. Ferrucci Jr, J. T., Wittenberg, J., Margolies, M. N., and Carey, R. W., *Malignant seeding of the tract after thin-needle aspiration biopsy*. *Radiology*, 1979. 130(2): p. 345-346.
136. Jones, O. M., Rees, M., John, T. G., Bygrave, S., and Plant, G., *Biopsy of resectable colorectal liver metastases causes tumour dissemination and adversely affects survival after liver resection*. *British Journal of Surgery*, 2005. 92(9): p. 1165-1168.
137. Stoot, J. H. M. B., Coelen, R. J. S., Vugt, J. L. A. van, and Dejong, C. H. C., *General Introduction: Advances in Hepatic Surgery, in Hepatic Surgery*, H. Abdeldayem, Editor. 2013, InTech: Rijeka. p. Ch. 01.

138. Cescon, M., Vetrone, G., Grazi, G. L., Ramacciato, G., Ercolani, G., Ravaioli, M., Del Gaudio, M., and Pinna, A. D., *Trends in perioperative outcome after hepatic resection: analysis of 1500 consecutive unselected cases over 20 years*. *Ann Surg*, 2009. 249(6): p. 995-1002.
139. Jarnagin, W. R., Gonen, M., Fong, Y., DeMatteo, R. P., Ben-Porat, L., Little, S., Corvera, C., Weber, S., and Blumgart, L. H., *Improvement in perioperative outcome after hepatic resection: analysis of 1,803 consecutive cases over the past decade*. *Ann Surg*, 2002. 236(4): p. 397-406; discussion 406-7.
140. Strasberg, S. M., *Nomenclature of hepatic anatomy and resections: a review of the Brisbane 2000 system*. *J Hepatobiliary Pancreat Surg*, 2005. 12(5): p. 351-5.
141. Strasberg, S. M. and Phillips, C., *Use and dissemination of the brisbane 2000 nomenclature of liver anatomy and resections*. *Ann Surg*, 2013. 257(3): p. 377-82.
142. Aragon, R. J. and Solomon, N. L., *Techniques of hepatic resection*. *Journal of Gastrointestinal Oncology*, 2012. 3(1): p. 28-40.
143. Hughes, M. J. and Wigmore, S. J., *Principles of liver surgery*. *Surgery (United Kingdom)*, 2014. 32(12): p. 643-647.
144. Gold, J. S., Are, C., Kornprat, P., Jarnagin, W. R., Gonen, M., Fong, Y., DeMatteo, R. P., Blumgart, L. H., and D'Angelica, M., *Increased use of parenchymal-sparing surgery for bilateral liver metastases from colorectal cancer is associated with improved mortality without change in oncologic outcome: trends in treatment over time in 440 patients*. *Ann Surg*, 2008. 247(1): p. 109-17.
145. Finch, R. J., Malik, H. Z., Hamady, Z. Z., Al-Mukhtar, A., Adair, R., Prasad, K. R., Lodge, J. P., and Toogood, G. J., *Effect of type of resection on outcome of hepatic resection for colorectal metastases*. *Br J Surg*, 2007. 94(10): p. 1242-8.
146. Sarpel, U., Bonavia, A. S., Grucela, A., Roayaie, S., Schwartz, M. E., and Labow, D. M., *Does anatomic versus nonanatomic resection affect recurrence and survival in patients undergoing surgery for colorectal liver metastasis?* *Ann Surg Oncol*, 2009. 16(2): p. 379-84.
147. Zorzi, D., et al., *Comparison between hepatic wedge resection and anatomic resection for colorectal liver metastases*. *J Gastrointest Surg*, 2006. 10(1): p. 86-94.
148. Cucchetti, A., Cescon, M., Ercolani, G., Bigonzi, E., Torzilli, G., and Pinna, A. D., *A comprehensive meta-regression analysis on outcome of anatomic resection versus nonanatomic resection for hepatocellular carcinoma*. *Ann Surg Oncol*, 2012. 19(12): p. 3697-705.
149. Clavien, P. A., Petrowsky, H., DeOliveira, M. L., and Graf, R., *Strategies for safer liver surgery and partial liver transplantation*. *N Engl J Med*, 2007. 356(15): p. 1545-59.
150. Kokudo, N., et al., *Proliferative activity of intrahepatic colorectal metastases after preoperative hemihepatic portal vein embolization*. *Hepatology*, 2001. 34(2): p. 267-72.
151. Shimada, M., Matsumata, T., Akazawa, K., Kamakura, T., Itasaka, H., Sugimachi, K., and Nose, Y., *Estimation of risk of major complications after hepatic resection*. *Am J Surg*, 1994. 167(4): p. 399-403.

152. Melendez, J., Ferri, E., Zwillman, M., Fischer, M., DeMatteo, R., Leung, D., Jarnagin, W., Fong, Y., and Blumgart, L. H., *Extended hepatic resection: a 6-year retrospective study of risk factors for perioperative mortality*. J Am Coll Surg, 2001. 192(1): p. 47-53.
153. Pringle, J. H., V. *Notes on the Arrest of Hepatic Hemorrhage Due to Trauma*. Ann Surg, 1908. 48(4): p. 541-9.
154. Man, K., Fan, S. T., Ng, I. O., Lo, C. M., Liu, C. L., and Wong, J., *Prospective evaluation of Pringle maneuver in hepatectomy for liver tumors by a randomized study*. Ann Surg, 1997. 226(6): p. 704-11; discussion 711-3.
155. Ishizaki, Y., Yoshimoto, J., Miwa, K., Sugo, H., and Kawasaki, S., *Safety of prolonged intermittent pringle maneuver during hepatic resection*. Archives of Surgery, 2006. 141(7): p. 649-653.
156. Man, K., Fan, S. T., Ng, I. O., Lo, C. M., Liu, C. L., Yu, W. C., and Wong, J., *Tolerance of the liver to intermittent pringle maneuver in hepatectomy for liver tumors*. Arch Surg, 1999. 134(5): p. 533-9.
157. Jones, R. M., Moulton, C. E., and Hardy, K. J., *Central venous pressure and its effect on blood loss during liver resection*. Br J Surg, 1998. 85(8): p. 1058-60.
158. Azoulay, D., et al., *In situ hypothermic perfusion of the liver versus standard total vascular exclusion for complex liver resection*. Ann Surg, 2005. 241(2): p. 277-85.
159. Belghiti, J., Noun, R., Zante, E., Ballet, T., and Sauvanet, A., *Portal triad clamping or hepatic vascular exclusion for major liver resection. A controlled study*. Ann Surg, 1996. 224(2): p. 155-61.
160. Torzilli, G., Makuuchi, M., Midorikawa, Y., Sano, K., Inoue, K., Takayama, T., and Kubota, K., *Liver resection without total vascular exclusion: hazardous or beneficial? An analysis of our experience*. Ann Surg, 2001. 233(2): p. 167-75.
161. Reddy, S. K., Barbas, A. S., Gan, T. J., Hill, S. E., Roche, A. M., and Clary, B. M., *Hepatic parenchymal transection with vascular staplers: a comparative analysis with the crush-clamp technique*. Am J Surg, 2008. 196(5): p. 760-7.
162. Gurusamy, K. S., Pamecha, V., Sharma, D., and Davidson, B. R., *Techniques for liver parenchymal transection in liver resection*. Cochrane Database Syst Rev, 2009(1): p. Cd006880.
163. Pamecha, V., Gurusamy, K. S., Sharma, D., and Davidson, B. R., *Techniques for liver parenchymal transection: a meta-analysis of randomized controlled trials*. HPB (Oxford), 2009. 11(4): p. 275-81.
164. Huntington, J. T., Royall, N. A., and Schmidt, C. R., *Minimizing blood loss during hepatectomy: a literature review*. J Surg Oncol, 2014. 109(2): p. 81-8.
165. Reich, H., McGlynn, F., DeCaprio, J., and Budin, R., *Laparoscopic excision of benign liver lesions*. Obstet Gynecol, 1991. 78(5 Pt 2): p. 956-8.
166. Rao, A., Rao, G., and Ahmed, I., *Laparoscopic vs. open liver resection for malignant liver disease. A systematic review*. Surgeon, 2012. 10(4): p. 194-201.
167. Cheek, S. M., Sucandy, I., Tsung, A., Marsh, J. W., and Geller, D. A., *Evidence supporting laparoscopic major hepatectomy*. J Hepatobiliary Pancreat Sci, 2016. 23(5): p. 257-9.
168. Nguyen, K. T., Gamblin, T. C., and Geller, D. A., *World review of laparoscopic liver resection-2,804 patients*. Ann Surg, 2009. 250(5): p. 831-41.

169. Alkhalili, E. and Berber, E., *Laparoscopic liver resection for malignancy: A review of the literature*. World Journal of Gastroenterology, 2014. 20(37): p. 13599-13606.
170. Cipriani, F., Rawashdeh, M., Stanton, L., Armstrong, T., Takhar, A., Pearce, N. W., Primrose, J., and Abu Hilal, M., *Propensity score-based analysis of outcomes of laparoscopic versus open liver resection for colorectal metastases*. British Journal of Surgery, 2016. 103(11): p. 1504-1512.
171. Hallet, J., Beyfuss, K., Memeo, R., Karanicolas, P. J., Marescaux, J., and Pessaux, P., *Short and long-term outcomes of laparoscopic compared to open liver resection for colorectal liver metastases*. Hepatobiliary Surg Nutr, 2016. 5(4): p. 300-10.
172. Tian, Z. Q., Su, X. F., Lin, Z. Y., Wu, M. C., Wei, L. X., and He, J., *Meta-analysis of laparoscopic versus open liver resection for colorectal liver metastases*. Oncotarget, 2016. 7(51): p. 84544-84555.
173. Benzoni, E., Cojutti, A., Lorenzin, D., Adani, G. L., Baccarani, U., Favero, A., Zompicchiati, A., Bresadola, F., and Uzzau, A., *Liver resective surgery: a multivariate analysis of postoperative outcome and complication*. Langenbecks Arch Surg, 2007. 392(1): p. 45-54.
174. Ribeiro, H. S., et al., *Extended preoperative chemotherapy, extent of liver resection and blood transfusion are predictive factors of liver failure following resection of colorectal liver metastasis*. Eur J Surg Oncol, 2013. 39(4): p. 380-5.
175. Balzan, S., Belghiti, J., Farges, O., Ogata, S., Sauvanet, A., Delefosse, D., and Durand, F., *The "50-50 criteria" on postoperative day 5: an accurate predictor of liver failure and death after hepatectomy*. Ann Surg, 2005. 242(6): p. 824-8, discussion 828-9.
176. Jin, Shan, Fu, Quan, Wuyun, Gerile, and Wuyun, Tu, *Management of post-hepatectomy complications*. World Journal of Gastroenterology : WJG, 2013. 19(44): p. 7983-7991.
177. Sadamori, H., Yagi, T., Shinoura, S., Umeda, Y., Yoshida, R., Satoh, D., Nobuoka, D., Utsumi, M., and Fujiwara, T., *Risk factors for major morbidity after liver resection for hepatocellular carcinoma*. Br J Surg, 2013. 100(1): p. 122-9.
178. Sadamori, H., et al., *Risk factors for organ/space surgical site infection after hepatectomy for hepatocellular carcinoma in 359 recent cases*. J Hepatobiliary Pancreat Sci, 2013. 20(2): p. 186-96.
179. Yang, Tian, et al., *Risk Factors of Surgical Site Infection after Hepatic Resection*. Infection Control Hospital Epidemiology, 2016. 35(3): p. 317-320.
180. Dindo, D., Demartines, N., and Clavien, P. A., *Classification of surgical complications: a new proposal with evaluation in a cohort of 6336 patients and results of a survey*. Ann Surg, 2004. 240(2): p. 205-13.
181. Claes, K., Beckers, R., Heindryckx, E., Kyle-Leinhase, I., Pletinckx, P., Claeys, D., and Muysoms, F., *Retrospective observational study on the incidence of incisional hernias after colorectal carcinoma resection with follow-up CT scan*. Hernia, 2014. 18(6): p. 797-802.
182. D'Angelica, M., et al., *Optimal abdominal incision for partial hepatectomy: increased late complications with Mercedes-type incisions compared to extended right subcostal incisions*. World J Surg, 2006. 30(3): p. 410-8.

183. Muysoms, F. E., et al., *European Hernia Society guidelines on the closure of abdominal wall incisions*. *Hernia*, 2015. 19(1): p. 1-24.
184. Yamada, T., Okabayashi, K., Hasegawa, H., Tsuruta, M., Abe, Y., Ishida, T., Matsui, S., and Kitagawa, Y., *Age, Preoperative Subcutaneous Fat Area, and Open Laparotomy are Risk Factors for Incisional Hernia following Colorectal Cancer Surgery*. *Ann Surg Oncol*, 2015.
185. Itatsu, K., et al., *Incidence of and risk factors for incisional hernia after abdominal surgery*. *Br J Surg*, 2014. 101(11): p. 1439-47.
186. Kayashima, H., et al., *Risk factors for incisional hernia after hepatic resection for hepatocellular carcinoma in patients with liver cirrhosis*. *Surgery*, 2015.
187. Togo, S., Nagano, Y., Masumoto, C., Takakura, H., Matsuo, K., Takeda, K., Tanaka, K., Endo, I., and Shimada, H., *Outcome of and risk factors for incisional hernia after partial hepatectomy*. *J Gastrointest Surg*, 2008. 12(6): p. 1115-20.
188. Michalopoulos, G. K., *Hepatostat: Liver regeneration and normal liver tissue maintenance*. *Hepatology*, 2017. 65(4): p. 1384-1392.
189. Fausto, N., Campbell, J. S., and Riehle, K. J., *Liver regeneration*. *Hepatology*, 2006. 43(2 Suppl 1): p. S45-53.
190. Forbes, S. J. and Newsome, P. N., *Liver regeneration - mechanisms and models to clinical application*. *Nat Rev Gastroenterol Hepatol*, 2016. 13(8): p. 473-85.
191. Sturesson, C., Keussen, I., and Tranberg, K. G., *Prolonged chemotherapy impairs liver regeneration after portal vein occlusion - an audit of 26 patients*. *Eur J Surg Oncol*, 2010. 36(4): p. 358-64.
192. Sherman, H., Klausner, S., and Cook, W. A., *Incident dark-field illumination: a new method for microcirculatory study*. *Angiology*, 1971. 22(5): p. 295-303.
193. Goedhart, P. T., Khalilzada, M., Bezemer, R., Merza, J., and Ince, C., *Sidestream Dark Field (SDF) imaging: a novel stroboscopic LED ring-based imaging modality for clinical assessment of the microcirculation*. *Opt Express*, 2007. 15(23): p. 15101-14.
194. Eriksson, S., Nilsson, J., and Sturesson, C., *Non-invasive imaging of microcirculation: a technology review*. *Med Devices (Auckl)*, 2014. 7: p. 445-52.
195. Puhl, G., Schaser, K. D., Vollmar, B., Menger, M. D., and Settmacher, U., *Noninvasive in vivo analysis of the human hepatic microcirculation using orthogonal polarization spectral imaging*. *Transplantation*, 2003. 75(6): p. 756-61.
196. Langer, S., Harris, A. G., Biberthaler, P., von Dobschuetz, E., and Messmer, K., *Orthogonal polarization spectral imaging as a tool for the assessment of hepatic microcirculation: a validation study*. *Transplantation*, 2001. 71(9): p. 1249-56.
197. Puhl, G., Schaser, K. D., Pust, D., Kohler, K., Vollmar, B., Menger, M. D., Neuhaus, P., and Settmacher, U., *Initial hepatic microcirculation correlates with early graft function in human orthotopic liver transplantation*. *Liver Transpl*, 2005. 11(5): p. 555-63.
198. Sturesson, C., Milstein, D. M., Post, I. C., Maas, A. M., and van Gulik, T. M., *Laser speckle contrast imaging for assessment of liver microcirculation*. *Microvasc Res*, 2013. 87: p. 34-40.
199. De Backer, D., Ospina-Tascon, G., Salgado, D., Favory, R., Creteur, J., and Vincent, J. L., *Monitoring the microcirculation in the critically ill patient: current methods and future approaches*. *Intensive Care Med*, 2010. 36(11): p. 1813-25.

200. Roustit, M., Millet, C., Blaise, S., Dufournet, B., and Cracowski, J. L., *Excellent reproducibility of laser speckle contrast imaging to assess skin microvascular reactivity*. *Microvasc Res*, 2010. 80(3): p. 505-11.
201. Roustit, M. and Cracowski, J. L., *Assessment of endothelial and neurovascular function in human skin microcirculation*. *Trends Pharmacol Sci*, 2013. 34(7): p. 373-84.
202. Evers, D. J., Nachabe, R., Klomp, H. M., van Sandick, J. W., Wouters, M. W., Lucassen, G. W., Hendriks, B. H., Wesseling, J., and Ruers, T. J., *Diffuse reflectance spectroscopy: a new guidance tool for improvement of biopsy procedures in lung malignancies*. *Clin Lung Cancer*, 2012. 13(6): p. 424-31.
203. Evers, D. J., et al., *Diffuse reflectance spectroscopy: towards clinical application in breast cancer*. *Breast Cancer Res Treat*, 2013. 137(1): p. 155-65.
204. Langhout, G. C., Spliethoff, J. W., Schmitz, S. J., Aalbers, A. G., van Velthuysen, M. F., Hendriks, B. H., Ruers, T. J., and Kuhlmann, K. F., *Differentiation of healthy and malignant tissue in colon cancer patients using optical spectroscopy: A tool for image-guided surgery*. *Lasers Surg Med*, 2015.
205. Murphy, B. W., Webster, R. J., Turlach, B. A., Quirk, C. J., Clay, C. D., Heenan, P. J., and Sampson, D. D., *Toward the discrimination of early melanoma from common and dysplastic nevus using fiber optic diffuse reflectance spectroscopy*. *J Biomed Opt*, 2005. 10(6): p. 064020.
206. Repez, A., Oroszy, D., and Arnez, Z. M., *Continuous postoperative monitoring of cutaneous free flaps using near infrared spectroscopy*. *J Plast Reconstr Aesthet Surg*, 2008. 61(1): p. 71-7.
207. Evers, D. J., Nachabé, R., Hompes, D., van Coevorden, F., Lucassen, G. W., Hendriks, B. H., van Velthuysen, M. L., Wesseling, J., and Ruers, T. J., *Optical sensing for tumor detection in the liver*. *Eur J Surg Oncol*, 2013. 39(1): p. 68-75.
208. Hosoyamada, Y. and Sakai, T., *The ultrastructure of periductal connective tissue and distinctive populations of collagen fibrils associated with ductal epithelia of exocrine glands*. *Arch Histol Cytol*, 2003. 66(5): p. 407-18.
209. Nachabe, R., Evers, D. J., Hendriks, B. H., Lucassen, G. W., van der Voort, M., Wesseling, J., and Ruers, T. J., *Effect of bile absorption coefficients on the estimation of liver tissue optical properties and related implications in discriminating healthy and tumorous samples*. *Biomed Opt Express*, 2011. 2(3): p. 600-14.
210. Farrell, T. J., Patterson, M. S., and Wilson, B., *A diffusion theory model of spatially resolved, steady-state diffuse reflectance for the noninvasive determination of tissue optical properties in vivo*. *Med Phys*, 1992. 19(4): p. 879-88.
211. Evers, D. J., et al., *Diffuse reflectance spectroscopy: toward real-time quantification of steatosis in liver*. *Transpl Int*, 2015. 28(4): p. 465-74.
212. Nachabe, R., et al., *Diagnosis of breast cancer using diffuse optical spectroscopy from 500 to 1600 nm: comparison of classification methods*. *J Biomed Opt*, 2011. 16(8): p. 087010.
213. Boerma, E. C., Mathura, K. R., van der Voort, P. H., Spronk, P. E., and Ince, C., *Quantifying bedside-derived imaging of microcirculatory abnormalities in septic patients: a prospective validation study*. *Crit Care*, 2005. 9(6): p. R601-6.

214. Tytgat, S. H., van der Zee, D. C., Ince, C., and Milstein, D. M., *Carbon dioxide gas pneumoperitoneum induces minimal microcirculatory changes in neonates during laparoscopic pyloromyotomy*. Surg Endosc, 2013. 27(9): p. 3465-73.
215. Dobbe, J. G., Streekstra, G. J., Atasever, B., van Zijderveld, R., and Ince, C., *Measurement of functional microcirculatory geometry and velocity distributions using automated image analysis*. Med Biol Eng Comput, 2008. 46(7): p. 659-70.
216. Genzel-Boroviczeny, O., Christ, F., and Glas, V., *Blood transfusion increases functional capillary density in the skin of anemic preterm infants*. Pediatr Res, 2004. 56(5): p. 751-5.
217. Jacques, S. L., *Optical properties of biological tissues: a review*. Phys Med Biol, 2013. 58(11): p. R37-61.
218. Hale, G. M. and Query, M. R., *Optical Constants of Water in the 200-nm to 200-microm Wavelength Region*. Appl Opt, 1973. 12(3): p. 555-63.
219. Nachabé, R., Hendriks, B. H. W., Desjardins, A. E., Van Der Voort, M., Van Der Mark, M. B., and Sterenborg, H. J. C. M., *Estimation of lipid and water concentrations in scattering media with diffuse optical spectroscopy from 900 to 1600 nm*. Journal of Biomedical Optics, 2010. 15(3).
220. Taroni, P., Bassi, A., Comelli, D., Farina, A., Cubeddu, R., and Pifferi, A., *Diffuse optical spectroscopy of breast tissue extended to 1100 nm*. J Biomed Opt, 2009. 14(5): p. 054030.
221. van Veen, R. L., Sterenborg, H. J., Pifferi, A., Torricelli, A., Chikoidze, E., and Cubeddu, R., *Determination of visible near-IR absorption coefficients of mammalian fat using time- and spatially resolved diffuse reflectance and transmission spectroscopy*. J Biomed Opt, 2005. 10(5): p. 054004.
222. Nachabe, R., Hendriks, B. H., van der Voort, M., Desjardins, A. E., and Sterenborg, H. J., *Estimation of biological chromophores using diffuse optical spectroscopy: benefit of extending the UV-VIS wavelength range to include 1000 to 1600 nm*. Biomed Opt Express, 2010. 1(5): p. 1432-1442.
223. Zonios, G., Bassukas, I., and Dimou, A., *Comparative evaluation of two simple diffuse reflectance models for biological tissue applications*. Appl Opt, 2008. 47(27): p. 4965-73.
224. Vauthey, J. N., et al., *Body surface area and body weight predict total liver volume in Western adults*. Liver Transpl, 2002. 8(3): p. 233-40.
225. Dello, S. A., Lodewick, T. M., van Dam, R. M., Reisinger, K. W., van den Broek, M. A., von Meyenfeldt, M. F., Bemelmans, M. H., Olde Damink, S. W., and Dejong, C. H., *Sarcopenia negatively affects preoperative total functional liver volume in patients undergoing liver resection*. HPB (Oxford), 2013. 15(3): p. 165-9.
226. van Vledder, M. G., Levolger, S., Ayez, N., Verhoef, C., Tran, T. C., and Ijzermans, J. N., *Body composition and outcome in patients undergoing resection of colorectal liver metastases*. Br J Surg, 2012. 99(4): p. 550-7.
227. Harimoto, N., et al., *Sarcopenia as a predictor of prognosis in patients following hepatectomy for hepatocellular carcinoma*. Br J Surg, 2013. 100(11): p. 1523-30.

228. Lodewick, T. M., van Nijnatten, T. J., van Dam, R. M., van Mierlo, K., Dello, S. A., Neumann, U. P., Olde Damink, S. W., and Dejong, C. H., *Are sarcopenia, obesity and sarcopenic obesity predictive of outcome in patients with colorectal liver metastases?* HPB (Oxford), 2014.
229. Prado, C. M., Lieffers, J. R., McCargar, L. J., Reiman, T., Sawyer, M. B., Martin, L., and Baracos, V. E., *Prevalence and clinical implications of sarcopenic obesity in patients with solid tumours of the respiratory and gastrointestinal tracts: a population-based study.* Lancet Oncol, 2008. 9(7): p. 629-35.
230. Schoen, J. M., Wang, H. H., Minuk, G. Y., and Lauth, W. W., *Shear stress-induced nitric oxide release triggers the liver regeneration cascade.* Nitric Oxide, 2001. 5(5): p. 453-64.
231. Sato, Yoshinobu, Koyama, Shuntaro, Tsukada, Kazuhiro, and Hatakeyama, Katsuyoshi, *Acute portal hypertension reflecting shear stress as a trigger of liver regeneration following partial hepatectomy.* Surgery Today, 1997. 27(6): p. 518-526.
232. Cantre, D., Schuett, H., Hildebrandt, A., Dold, S., Menger, M. D., Vollmar, B., and Eipel, C., *Nitric oxide reduces organ injury and enhances regeneration of reduced-size livers by increasing hepatic arterial flow.* Br J Surg, 2008. 95(6): p. 785-92.
233. Abshagen, K., Eipel, C., Menger, M. D., and Vollmar, B., *Comprehensive analysis of the regenerating mouse liver: an in vivo fluorescence microscopic and immunohistological study.* J Surg Res, 2006. 134(2): p. 354-62.
234. Palmes, D., Budny, T. B., Dietl, K. H., Herbst, H., Stratmann, U., and Spiegel, H. U., *Detrimental effect of sinusoidal overperfusion after liver resection and partial liver transplantation.* Transpl Int, 2005. 17(12): p. 862-71.
235. McCuskey, R. S., Ito, Y., Robertson, G. R., McCuskey, M. K., Perry, M., and Farrell, G. C., *Hepatic microvascular dysfunction during evolution of dietary steatohepatitis in mice.* Hepatology, 2004. 40(2): p. 386-93.
236. Rosenstengel, S., Stoeppler, S., Bahde, R., Spiegel, H. U., and Palmes, D., *Type of steatosis influences microcirculation and fibrogenesis in different rat strains.* J Invest Surg, 2011. 24(6): p. 273-82.
237. Seifalian, A. M., Chidambaram, V., Rolles, K., and Davidson, B. R., *In vivo demonstration of impaired microcirculation in steatotic human liver grafts.* Liver Transpl Surg, 1998. 4(1): p. 71-7.
238. Seifalian, A. M., Piasecki, C., Agarwal, A., and Davidson, B. R., *The effect of graded steatosis on flow in the hepatic parenchymal microcirculation.* Transplantation, 1999. 68(6): p. 780-4.
239. Vollmar, B., Siegmund, S., and Menger, M. D., *An intravital fluorescence microscopic study of hepatic microvascular and cellular derangements in developing cirrhosis in rats.* Hepatology, 1998. 27(6): p. 1544-53.
240. Puhl, G., Schaser, K. D., Pust, D., Kohler, K., Vollmar, B., Menger, M. D., Neuhaus, P., and Settmacher, U., *The delay of rearterialization after initial portal reperfusion in living donor liver transplantation significantly determines the development of microvascular graft dysfunction.* J Hepatol, 2004. 41(2): p. 299-306.

241. Rauchfuss, F., Scheuerlein, H., Ludewig, S., Uberruck, T., Heise, M., Zanow, J., and Settmacher, U., *In vivo assessment of the hepatic microcirculation after mesenterico-portal bypass (REX-shunt) using orthogonal polarization spectral imaging*. *Liver Int*, 2010. 30(9): p. 1339-45.
242. Gatecel, C., Losser, M. R., and Payen, D., *The postoperative effects of halothane versus isoflurane on hepatic artery and portal vein blood flow in humans*. *Anesth Analg*, 2003. 96(3): p. 740-5, table of contents.
243. Grundmann, U., Zissis, A., Bauer, C., and Bauer, M., *In vivo effects of halothane, enflurane, and isoflurane on hepatic sinusoidal microcirculation*. *Acta Anaesthesiol Scand*, 1997. 41(6): p. 760-5.
244. O'Riordan, J., O'Beirne, H. A., Young, Y., and Bellamy, M. C., *Effects of desflurane and isoflurane on splanchnic microcirculation during major surgery*. *Br J Anaesth*, 1997. 78(1): p. 95-6.
245. Cerny, V., Turek, Z., and Parizkova, R., *In situ assessment of the liver microcirculation in mechanically ventilated rats using sidestream dark-field imaging*. *Physiol Res*, 2009. 58(1): p. 49-55.
246. Wheatley, A. M., Almond, N. E., Stuart, E. T., and Zhao, D., *Interpretation of the laser Doppler flow signal from the liver of the rat*. *Microvasc Res*, 1993. 45(3): p. 290-301.
247. Millet, C., Roustit, M., Blaise, S., and Cracowski, J. L., *Comparison between laser speckle contrast imaging and laser Doppler imaging to assess skin blood flow in humans*. *Microvasc Res*, 2011. 82(2): p. 147-51.
248. Mahe, G., Abraham, P., Le Faucheur, A., Bruneau, A., Humeau-Heurtier, A., and Durand, S., *Cutaneous microvascular functional assessment during exercise: a novel approach using laser speckle contrast imaging*. *Pflugers Arch*, 2013. 465(4): p. 451-8.
249. Mahe, G., Rousseau, P., Durand, S., Bricq, S., Leftheriotis, G., and Abraham, P., *Laser speckle contrast imaging accurately measures blood flow over moving skin surfaces*. *Microvasc Res*, 2011. 81(2): p. 183-8.
250. McIntosh, L. M., Summers, R., Jackson, M., Mantsch, H. H., Mansfield, J. R., Howlett, M., Crowson, A. N., and Toole, J. W., *Towards non-invasive screening of skin lesions by near-infrared spectroscopy*. *J Invest Dermatol*, 2001. 116(1): p. 175-81.
251. Robertson, E. G. and Baxter, G., *Tumour seeding following percutaneous needle biopsy: the real story!* *Clin Radiol*, 2011. 66(11): p. 1007-14.
252. van Veen, R. L., Verkruyse, W., and Sterenborg, H. J., *Diffuse-reflectance spectroscopy from 500 to 1060 nm by correction for inhomogeneously distributed absorbers*. *Opt Lett*, 2002. 27(4): p. 246-8.
253. Younossi, Z. M., Koenig, A. B., Abdelatif, D., Fazel, Y., Henry, L., and Wymer, M., *Global epidemiology of nonalcoholic fatty liver disease-Meta-analytic assessment of prevalence, incidence, and outcomes*. *Hepatology*, 2016. 64(1): p. 73-84.
254. Chu, M. J. J., Dare, A. J., Phillips, A. R. J., and Bartlett, A. S. J. R., *Donor Hepatic Steatosis and Outcome After Liver Transplantation: a Systematic Review*. *Journal of Gastrointestinal Surgery*, 2015. 19(9): p. 1713-1724.
255. Kele, P. G., Van der Jagt, E. J., Gouw, A. S. H., Lisman, T., Porte, R. J., and De Boer, M. T., *The impact of hepatic steatosis on liver regeneration after partial hepatectomy*. *Liver International*, 2013. 33(3): p. 469-475.

256. McCormack, L., Dutkowski, P., El-Badry, A. M., and Clavien, P. A., *Liver transplantation using fatty livers: always feasible?* J Hepatol, 2011. 54(5): p. 1055-62.
257. Decarie, P. O., Lepanto, L., Billiard, J. S., Olivie, D., Murphy-Lavallee, J., Kauffmann, C., and Tang, A., *Fatty liver deposition and sparing: a pictorial review.* Insights Imaging, 2011. 2(5): p. 533-538.
258. de Baere, T., et al., *Predictive factors for hypertrophy of the future remnant liver after selective portal vein embolization.* Ann Surg Oncol, 2010. 17(8): p. 2081-9.
259. Ribero, D., Abdalla, E. K., Madoff, D. C., Donadon, M., Loyer, E. M., and Vauthey, J. N., *Portal vein embolization before major hepatectomy and its effects on regeneration, resectability and outcome.* Br J Surg, 2007. 94(11): p. 1386-94.
260. Tanaka, K., Kumamoto, T., Matsuyama, R., Takeda, K., Nagano, Y., and Endo, I., *Influence of chemotherapy on liver regeneration induced by portal vein embolization or first hepatectomy of a staged procedure for colorectal liver metastases.* J Gastrointest Surg, 2010. 14(2): p. 359-68.
261. Tani, M., et al., *Regulating factors of liver regeneration after hepatectomy.* Cancer Chemother Pharmacol, 1994. 33 Suppl: p. S29-32.
262. Nadalin, S., Testa, G., Malago, M., Beste, M., Frilling, A., Schroeder, T., Jochum, C., Gerken, G., and Broelsch, C. E., *Volumetric and functional recovery of the liver after right hepatectomy for living donation.* Liver Transpl, 2004. 10(8): p. 1024-9.
263. Shimizu, Y., et al., *Natural course of the remnant hepatic functional reserve as estimated by technetium-99m-galactosyl human serum albumin scintigraphy after a hepatectomy.* J Gastroenterol, 2010. 45(3): p. 308-16.
264. Yamanaka, N., et al., *Dynamics of normal and injured human liver regeneration after hepatectomy as assessed on the basis of computed tomography and liver function.* Hepatology, 1993. 18(1): p. 79-85.
265. Nagino, M., Ando, M., Kamiya, J., Uesaka, K., Sano, T., and Nimura, Y., *Liver regeneration after major hepatectomy for biliary cancer.* Br J Surg, 2001. 88(8): p. 1084-91.
266. Pomfret, E. A., Pomposelli, J. J., Gordon, F. D., Erbay, N., Lyn Price, L., Lewis, W. D., and Jenkins, R. L., *Liver regeneration and surgical outcome in donors of right-lobe liver grafts.* Transplantation, 2003. 76(1): p. 5-10.
267. Hockings, P. D., Changani, K. K., Saeed, N., Reid, D. G., Birmingham, J., O'Brien, P., Osborne, J., Toseland, C. N., and Buckingham, R. E., *Rapid reversal of hepatic steatosis, and reduction of muscle triglyceride, by rosiglitazone: MRI/S studies in Zucker fatty rats.* Diabetes Obes Metab, 2003. 5(4): p. 234-43.
268. van den Esschert, J. W., et al., *Volumetric and functional recovery of the remnant liver after major liver resection with prior portal vein embolization : recovery after PVE and liver resection.* J Gastrointest Surg, 2009. 13(8): p. 1464-9.
269. Aoki, T., Imamura, H., Matsuyama, Y., Kishi, Y., Kobayashi, T., Sugawara, Y., Makuuchi, M., and Kokudo, N., *Convergence process of volumetric liver regeneration after living-donor hepatectomy.* J Gastrointest Surg, 2011. 15(9): p. 1594-601.
270. de Goede, B., et al., *Incisional hernia after liver transplantation: risk factors and health-related quality of life.* Clin Transplant, 2014. 28(7): p. 829-36.

271. van Ramshorst, G. H., Eker, H. H., Hop, W. C., Jeekel, J., and Lange, J. F., *Impact of incisional hernia on health-related quality of life and body image: a prospective cohort study*. Am J Surg, 2012. 204(2): p. 144-50.
272. Garcia-Urena, M. A., Lopez-Monclus, J., Hernando, L. A., Montes, D. M., Valle de Lersundi, A. R., Pavon, C. C., Ceinos, C. J., and Quindos, P. L., *Randomized controlled trial of the use of a large-pore polypropylene mesh to prevent incisional hernia in colorectal surgery*. Ann Surg, 2015. 261(5): p. 876-81.
273. Thornton, A. D., Ravn, P., Winslet, M., and Chester, K., *Angiogenesis inhibition with bevacizumab and the surgical management of colorectal cancer*. Br J Surg, 2006. 93(12): p. 1456-63.



Jan Nilsson, MD, studied medicine at Lund University. He is now doing his specialty training in surgery at Helsingborg Hospital. Since 2010, he has carried out research within the field of liver surgery at the Department of Surgery in Lund in parallel with his education and clinical work. He is married and has two children.

The primary aim of this thesis was to evaluate methods for intraoperative liver parenchyma characterization in order to improve surgical strategies in liver resections.



LUND UNIVERSITY
Faculty of Medicine

Department of Surgery, Clinical Sciences, Lund
and Skåne University Hospital

Lund University, Faculty of Medicine
Doctoral Dissertation Series 2017:98
ISBN 978-91-7619-478-2
ISSN 1652-8220

