LUND UNIVERSITY

A comparison of lycopene and orchidectomy vs orchidectomy alone in the management of advanced prostate cancer.

Bratt, Ola

Published in:
BJU International

DOI:
10.1111/j.1464-410X.2005.4440_7.x

2005

Link to publication

Citation for published version (APA):
Bratt, O. (2005). A comparison of lycopene and orchidectomy vs orchidectomy alone in the management of advanced prostate cancer. *BJU International*, *95*(1), 192-192. https://doi.org/10.1111/j.1464-410X.2005.4440_7.x

Total number of authors:
1

General rights
Unless other specific re-use rights are stated the following general rights apply:
Copyright and moral rights for the publications made accessible in the public portal are retained by the authors and/or other copyright owners and it is a condition of accessing publications that users recognise and abide by the legal requirements associated with these rights.
• Users may download and print one copy of any publication from the public portal for the purpose of private study or research.
• You may not further distribute the material or use it for any profit-making activity or commercial gain
• You may freely distribute the URL identifying the publication in the public portal

Read more about Creative commons licenses: https://creativecommons.org/licenses/

Take down policy
If you believe that this document breaches copyright please contact us providing details, and we will remove access to the work immediately and investigate your claim.

LUND UNIVERSITY

PO Box 117
221 00 Lund
+46 46-222 00 00

letters

WRITE TO THE EDITOR AT BJU INTERNATIONAL, 47 ECCLES STREET, DUBLIN 7, IRELAND

A TECHNIQUE FOR PLACING INFANTS IN THE LITHOTOMY POSITION USING TOWEL ROLLS

Sir,
I read with interest the article by Tan *et al.* [1]; putting patients in the lithotomy position has always been a subject of concern [2–4]. The idea of using silicon headrests for this position is interesting, but when the ankle is fixed as described by authors, it (together with the hip joint) will act as a fulcrum, on which the knees will swing from side to side. This instability will be clumsy during operative procedures.

Putting an infant in the lithotomy position is not difficult if the basic anatomical differences between the hip joint of infants and adults is appreciated. In infants the acetabular cup is shallower than that of adults. The head of the femur is also larger and nearly a third of it lies outside the acetabulum [5]. Moreover, the ligamentum teres is longer in infants. All these factors together allow a greater range of mobility of the infant hip joint. The flexed hip of infants can be abducted to 90° so that both the knees can simultaneously touch the couch, a movement impossible in adults. Urologists wishing to place an infant in the lithotomy position should use this anatomical advantage. Using this principle, I suggest the following technique, which I have used for the past 8 years.

FIG. 1. A, The lithotomy position using towel rolls, and B, the same child in lateral view.

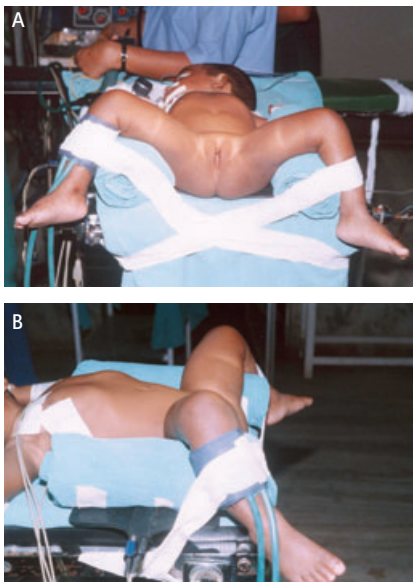

The perineum of the infant is brought to the edge of the operation table. Both hip joints are symmetrically flexed, abducted and externally rotated. A towel roll of appropriate size is placed, one on either side, below the flexed knees (Fig. 1a,b). The towel rolls are kept lateral to the hip joints but medial to the ankle joints, supporting the knees. The infant is secured in this position using adhesive tapes. This gives unhindered access to the perineum and abdomen.

I have used this technique in several hundred children since 1997, for cystoscopy, urethroplasty, bladder surgery and anorectal operations. This technique is applicable to children aged <3 years. I have operated for up to 8 h with the patient in this posture, with no adverse consequences. As the towel rolls are soft, pressure effects and neuropraxia are unlikely. Radiolucent cloth rolls permit on-table radiography. As the size of towel rolls can be customized, and as they are universally available, they are a better option than silicon headrests for placing infants in the lithotomy position.

VENKATACHALAM RAVEENTHIRAN,
Division of Pediatric Surgery, Rajah Muthiah Medical College, Annamalai University, Tamilnadu, India

1 **Tan HL, Lopez PJ, Shankar KR, Boucaut HAP.** Silicon headrests are ideal lithotomy restraints for neonatal and infant cystoscopy. *BJU Int* 2004; **93**: 177–8
2 **Ozveren B, Ilker Y, Akdas A.** Use of plastic fluid-bags in dorsal lithotomy positioning. *Br J Urol* 1998; **82**: 585–6
3 **Muralidhar V.** Blocks to facilitate lithotomy positioning in spastic paraplegics. *Anesth Analg* 1996; **82**: 219
4 **Usher-Somers GE.** A new type of foot support for the lithotomy position. *Br Med J* 1950; **1**: 1266
5 **Crelin E, Collins P.** Neonatal anatomy and development. In Williams PL, Bannister, LH, Berry MM ***et al***. eds, *Gray's Anatomy*, 38th edn, London: Churchill Livingstone, 1995: 343–73

RADIONUCLIDE BONE SCINTIGRAPHY IN PATIENTS WITH BIOCHEMICAL RECURRENCE AFTER RADICAL PROSTATECTOMY: WHEN IS IT INDICATED?

Sir,
We read with interest the suggestion made by Gomez *et al.* [1]. that taking bone scans in patients with a serum PSA level of <7 ng/mL during biochemical recurrence after radical prostatectomy (RP) is unlikely to be positive, and that clinicians should request bone scans for patients with a PSA level of >7 ng/mL. Serum PSA is a useful predictor of disease recurrence after surgery but it is difficult to distinguish between local recurrence and distant metastases. Studies assessing the usefulness of bone scans in this situation have produced conflicting advice as to when scanning is appropriate and if a PSA threshold can be used. In 1991, Terris *et al.* [2] recommended that patients with detectable PSA levels after RP should routinely have bone scans, while Partin *et al.* [3], after evaluating 51 men with PSA-only recurrence after RP, recommended annual bone scans in patients with biochemical recurrence. However, 60% and 70% of patients with positive bone scans in both these studies had nodal metastases at RP. Lee and Oesterling [4]

concluded from their experiences that it would be reasonable to omit bone scans in patients with recurrent prostate cancer after RP when their PSA was <2 ng/mL. Cher *et al.* [5] showed that the probability of a positive bone scan was <5% until the PSA increased to 40–45 ng/mL, while Jhaveri and Klein [6] concluded that bone scans in patients with a PSA recurrence after RP have limited usefulness until the PSA is >30 ng/mL. The sensitivity of serum PSA for predicting bone metastases may also be affected by adjuvant hormonal therapy after RP. In a study by Koizumi *et al.* [7] two of the six patients on hormones had developed bone metastases although their PSA levels were low.

Gomez *et al.* suggest a PSA threshold of 7 ng/mL, but their study is flawed; they included patients being staged before possible salvage therapy, and those with symptoms suggestive of metastatic disease, but these two groups might more usefully be considered separately. The inclusion of one symptomatic patient with a high PSA value (100 ng/mL) and positive bone scan is likely to have skewed the mean value of PSA in patients with a positive scan. In addition, the study group was highly selected; although 153 patients had a biochemical recurrence, only 35 of them had a bone scan. The reasons for not scanning the other 118 were not explained. Finally, three of the group of 35 patients were excluded, but their results seem to have been included in the analysis, which again may have influenced the final PSA threshold.

At present, bone scintigraphy is still the standard for detecting bone metastases, but is likely to be negative in patients with a low PSA level after surgery. However, in our view the published data do not clearly define a PSA threshold below which bone imaging should not be used; this could only be achieved by a large prospective study. In addition, evidence is accumulating that adjuvant radiotherapy after RP is only effective at low PSA levels, but in this situation spread to bone is usually by micro-metastases which are not reliably identified by any of the current imaging techniques. In the future, bone-specific biochemical markers may be a better way of detecting prostate cancer recurrence in these patients.

RAMESH THURAIRAJA, JONATHAN P. McFARLANE* and RAJENDRA PERSAD, *Departments of Urology, Bristol Royal Infirmary and *Royal United Hospital Bath, UK*

1. **Gomez P, Manoharan M, Kim SS, Soloway MS.** Radionuclide bone scintigraphy in patients with biochemical recurrence after radical prostatectomy: when is it indicated? *BJU Int* 2004; **94**: 299–302
2. **Terris MK, Klonecke AS, McDougall IR, Stamey TA.** Utilization of bone scans in conjunction with prostate-specific antigen levels in the surveillance for recurrence of adenocarcinoma after radical prostatectomy. *J Nucl Med* 1991; **32**: 1713–7
3. **Partin AW, Peason JD, Landis PK *et al.*** Evaluation of serum prostate specific antigen velocity after radical prostatectomy to distinguish local recurrence from distant metastasis. *Urology* 1994; **43**: 649–59
4. **Lee CT, Oesterling JE.** Using prostate-specific antigen to eliminate the staging radionuclide bone scan. *Urol Clin North Am* 1997; **24**: 389–94
5. **Cher ML, Bianco FJ, Lam JS *et al.*** Limited role of radionuclide bone scintigraphy in patients with prostate specific antigen elevations after radical prostatectomy. *J Urol* 1998; **160**: 1387–91
6. **Jhaveri FM, Klein EA.** How to explore the patient with a rising PSA after radical prostatectomy: defining local versus systemic failure. *Semin Urol Oncol* 1999; **17**: 130–4
7. **Koizumi M, Yonese J, Fukui I, Ogata E.** The serum level of the amino-terminal propeptide of type 1 procollagen is a sensitive marker for prostate cancer metastasis to bone. *BJU Int* 2001; **87**: 348–51

PROSTATE SIZE INFLUENCES THE OUTCOME AFTER PRESENTING WITH ACUTE URINARY RETENTION

Sir,
I am concerned that the article by McNeil *et al.* [1] made no reference to an identical study from our unit which was published in the *BJU Int* only 4 years ago, and which reached exactly the same conclusion [2]. Perhaps this was an oversight. The lapse is unfortunate, particularly as Mr McNeil criticised our study for using the DRE as a means of assessing prostate size. His precise comment at that time read: 'I do not think conclusions can be drawn about how prostate size may influence the outcome after AUR until a study is conducted using a reliable method for accurately assessing prostate size' [3]. I note that prostate size in his present study was based on a DRE 'by the admitting urologist'. There is no mention of grade of trainee or how many individuals conducted the examinations, in contrast to our (uncited) study in which the DRE was by the experienced finger of one consultant urological surgeon. Has Mr McNeil had a change of heart as well as a memory lapse?

PAUL P. IRWIN, *Consultant Urological Surgeon, Michael Heal Department of Urology, Leighton Hospital, Crewe, UK*

1. **McNeil AS, Rizvi S, Byrne DJ.** Prostate size influences the outcome after presenting with acute urinary retention. *BJU Int* 2004; **94**: 559–62
2. **Kumar V, Marr C, Bhuvangiri A, Irwin P.** A prospective study of conservatively managed acute urinary retention: prostate size matters. *BJU Int* 2000; **86**: 816–9
3. **McNeil AS.** A prospective study of conservatively managed acute urinary retention: prostate size matters (letter). *BJU Int* 2001; **87**: 904–5

PRENATALLY DIAGNOSED UNILATERAL RENAL PELVIC DILATATION: A DYNAMIC CONDITION OF ULTRASOUND AND DIURETIC RENOGRAPHY

Sir,
These authors [1] highlighted that their study was not randomized and therefore have been guarded in their conclusions, and recognize the retrospective nature of their work. However, the conclusion that the data support the benign nature of prenatal unilateral hydronephrosis needs to be challenged; the conclusion is true for a portion of cases, but not all.

There is no doubt that in most cases of prenatal pelvic dilatation it will resolve, but not all pelvi-ureteric obstruction has the same cause and not all kidneys have a benign course. Some patients have infection, stone formation and loss of function, and

© 2005 BJU INTERNATIONAL

identifying the features of those likely to have subsequent adverse events should be the focus, rather than consider that all patients and kidneys are the same.

Aspects of the Great Ormond Street study [1] that are a problem, and not well considered in the article on hydronephrosis include: (i) Failure to consider that nephrons can be lost with no change in the differential function, which would make conservatively managed kidneys look better than they may be. (ii) Conservatively managed kidneys were less obstructed and better functioning that those surgically treated. (iii) As the study was retrospective, some patients treated by surgery may have been over-treated. (iv) There is no recording of the operative findings that would allow for validation of the decision to proceed to surgery. (v) The follow-up in the study is very short, too short to realistically assess the impact of the decision on prognosis. (vi) There is no mention of the clinical history of pain, infection, stone formation; if these were present then surgery would be more appropriate. (vii) A tense kidney on palpation would appropriately undergo surgery, and should not be considered benign. (viii) Changes on ultrasonography consistent with high intrarenal pressure should be considered additional information to promote surgical treatment, including hyperperistalsis of the pelvis, marked calyceal dilation with thin parenchyma, and the eggshell sign [2,3]. (ix) The late treatment of patients in the surgical group may have limited the possible improvement in some, particularly as we do not know the infection history. (x) A history of pain during the nuclear medicine study, would let the physician know that a patient who was experiencing pain and had significant hydronephrosis was inadvertently not obstructed at the time of the nuclear medicine study. A case in point is the patient reported who had the obstruction, it was causing pain, and had lead to the child presenting with *Escherichia coli* meningitis secondary to a UTI. The nuclear medicine study did not show the obstruction (the patient had no pain at that time), but the voiding cysto-urethrogram shows an obviously obstructed system, while the patient had pain. The findings at operation, and the subsequent elimination of pain after feeding, supports the cysto-urethrography conclusion. Reflux is the benign disease, not the obstruction.

For the best treatment of all cases, and to avoid situations like the meningitis case, a more individualized approach to patients with significant dilation would seem appropriate, rather than the general conclusion that unilateral hydronephrosis is benign being applied to all patients.

PADDY DEWAN, PADMA RAO and SHARMINI KUMAR,
Urology Unit, Royal Children's Hospital, University of Melbourne, Victoria, Australia

1 **Ozcan Z, Anderson PJ, Gordon I.** Prenatally diagnosed unilateral renal pelvic dilatation: a dynamic condition on ultrasound and diuretic renography. *J Urol* 2004; **172**: 1456–9
2 **Dewan PA, Moon D, Anderson K.** The presence of the egg-shell sign in obstructive uropathy. *Urology* 2002; **59**: 28–9
3 **Imaji R, Dewan PA.** Calyx to parenchymal ratio in pelvi-ureteric junction obstruction. *BJU Int* 2002; **89**: 73–7

LIFELONG PREMATURE EJACULATION: FROM AUTHORITY-BASED TO EVIDENCE-BASED MEDICINE

Sir,
In response to my article on evidence-based research of lifelong premature ejaculation [1], Denniston and Hill expressed their concern that circumcision was not mentioned as an important factor in the development of premature ejaculation [2]. With their reference to the studies of O'Hara and O'Hara [3] and Gemmell and Boyle [4], readers may erroneously have the impression that circumcision is considered as a scientifically accepted risk factor for developing premature ejaculation. My current reply mainly considers the notion that both references are methodologically insufficient. For example, O'Hara and O'Hara [3] reported about women who had experienced intercourse with both circumcised and intact partners. These women stated that more of their circumcised than intact partners had premature ejaculation. However, notably in this study, premature ejaculation was defined as having an orgasm within 2–3 min in more than half the attempts. Apart from this arbitrary definition of premature ejaculation, the analysis was based on an open-label retrospective design with a questionnaire, assessing subjective judgements of these women. In other words, the actual ejaculation time of the men reported was not prospectively recorded with an objective timer.

Indeed, the presence or absence of a prepuce may be influential on how intercourse or other forms of sexual contact is conducted and experienced by both partners. However, no information about the exact role of circumcision on the development of ejaculatory disorders has been provided by evidence-based studies.

A scientific and realistic way to obtain basic information on this issue is to conduct population-based studies among different cultures, using stopwatch analysis of the intravaginal ejaculation latency time (IELT) [5]. Only comparison of the IELT distribution in both circumcised and intact men (with no genital diseases) and within and between cultures or countries will provide answers on the role of circumcision as a risk factor for developing either lifelong premature or delayed ejaculation.

MARCEL D. WALDINGER,
Department of Psychiatry and Neurosexology, Leyenburg Hospital, The Hague, The Netherlands

1 **Waldinger MD.** Lifelong premature ejaculation: from authority-based to evidence-based medicine. *BJU Int* 2004; **93**: 201–7
2 **Denniston GC, Hill G.** Lifelong premature ejaculation: from authority-based to evidence-based medicine. Letter. *BJU Int* 2004; **93**: 1360
3 **O'Hara K, O'Hara J.** The effect of male circumcision on the sexual enjoyment of the female partner. *BJU Int* 1999; **83** (Suppl 1): 79–84
4 **Gemmell T, Boyle GJ.** Neonatal circumcision: its long-term harmful effects. In Denniston GC, Hodges FM, Marilyn Milos MF eds, *Understanding Circumcision: a Multi-Dimensional Approach to a Multi-Dimensional problem.* New York: Kluwer Academic/ Plenum Publishers, 2001: 241–52
5 **Waldinger MD, Hengeveld MW, Zwinderman AH.** Paroxetine treatment of premature ejaculation: a double-blind, randomised, placebo-controlled study. *Am J Psychiatry* 1994; **151**: 1377–9

A COMPARISON OF LYCOPENE AND ORCHIDECTOMY VS ORCHIDECTOMY ALONE IN THE MANAGEMENT OF ADVANCED PROSTATE CANCER

Sir,
A previous issue of *BJU Int* [1] included a report of a remarkable response by metastatic prostate cancer to low-dose lycopene in addition to orchidectomy. Unfortunately, the Kaplan-Meier curve in the article obviously did not correspond with the reported results, as it showed shorter survival for the orchidectomy + lycopene group (O+L) than the orchidectomy-alone (O) group, and many more deaths in total than had occurred in the study. In response to my letter to the Editor [2], a new legend, identifying the former O+L curve as the O curve and vice versa, was published as an erratum in the same issue. A reply by the authors appeared in September 2004 [3], in which they say that they have reviewed their data, reaching the same results, but do not comment on the question about the number of deaths in the study.

The remaining comment is, therefore; in the Results it is stated that 12 of 27 patients in the O group and seven of 27 in the O+L group died during 24–28 months of follow-up, i.e. survivals of 56% and 74% at the end of the study. The Kaplan-Meier curves show survival at 27 months of ≈20% in both groups. As the reported results will affect prostate cancer treatment profoundly if repeated by other researchers, I would very much appreciate a reply from the authors on this specific inconsistency.

OLA BRATT, UROLOGIST,
Lund University Hospital, Sweden

1 **Ansari MS, Gupta NP.** A comparison of lycopene and orchidectomy vs orchidectomy alone in the management of advanced prostate cancer. *BJU Int* 2003; **92**: 375–8
2 **Bratt O.** A comparison of lycopene and orchidectomy vs orchidectomy alone in the management of advanced prostate cancer. Letter. *BJU Int* 2004; **93**: 637
3 **Ansari MS, Gupta NP.** A comparison of lycopene and orchidectomy vs orchidectomy alone in the management of advanced prostate cancer. Reply. *BJU Int* 2004; **94**: 678

THE DIFFICULT URETHRAL CATHETERIZATION: USE OF A HYDROPHILIC GUIDEWIRE

Sir,
With regard to this report [1], the concept of using hydrophilic guidewires and/or ureteric dilators is not new. Blitz [2] proposed a technique where a urethral catheter was loaded over a hydrophilic guidewire with the aid of an intravenous catheter. Dewan *et al.* [3] presented their experience with dilatation of urethral strictures using a guidewire and sheath dilator technique in paediatric patients. Zammit and German [1] presented their interesting experience with the use of a hydrophilic guidewire, a 16 F urethral catheter and/or 6–12 F semirigid ureteric dilators. In a recent study (unpublished data) we successfully used a combination of both a straight flexi-tip 0.09 mm hydrophilic guidewire (Terumo Radiofocus Guide Wire M) and a 14/16 F ureteric access sheath (Forte, Applied Medical). Hydrophilic coatings have proved their efficacy and atraumatic characteristics within the ureteric lumen. Based on the existing experience in the ureteric lumen we decided to use the same concept within the larger diameter urethral lumen. The development of larger diameter hydrophilic sheaths may lead to a totally atraumatic 'one step' management of urethral strictures.

ANASTASIOS ATHANASSOPOULOS, EVANGELOS N. LIATSIKOS and GEORGE A. BARBALIAS, *Department of Urology, University of Patras, Rion, Greece*

1 **Zammit PA, German K.** The difficult urethral catheterization: use of a hydrophilic guide wire. *BJU Int* 2004; **93**: 883–4
2 **Blitz BF.** A simple method using hydrophilic guide wires for the difficult urethral catheterization. *Urology* 1995; **46**: 99–100
3 **Dewan PA, Gotov E, Chiang D.** Guide wire-assisted urethral dilatation for urethral strictures in pediatric urology. *J Pediatr Surg* 2003; **38**: 1790–2

© 2005 BJU INTERNATIONAL