



# LUND UNIVERSITY

## Acute effects of liver vein occlusion by stent-graft placed in transjugular intrahepatic portosystemic shunt channel: An experimental study

Keussen, Inger; Bergqvist, Lennart; Rissler, Pehr; Cwikiel, W

*Published in:*  
Cardiovascular and Interventional Radiology

*DOI:*  
[10.1007/s00270-004-0288-x](https://doi.org/10.1007/s00270-004-0288-x)

2006

[Link to publication](#)

*Citation for published version (APA):*  
Keussen, I., Bergqvist, L., Rissler, P., & Cwikiel, W. (2006). Acute effects of liver vein occlusion by stent-graft placed in transjugular intrahepatic portosystemic shunt channel: An experimental study. *Cardiovascular and Interventional Radiology*, 29(1), 120-123. <https://doi.org/10.1007/s00270-004-0288-x>

*Total number of authors:*  
4

### General rights

Unless other specific re-use rights are stated the following general rights apply:  
Copyright and moral rights for the publications made accessible in the public portal are retained by the authors and/or other copyright owners and it is a condition of accessing publications that users recognise and abide by the legal requirements associated with these rights.

- Users may download and print one copy of any publication from the public portal for the purpose of private study or research.
- You may not further distribute the material or use it for any profit-making activity or commercial gain
- You may freely distribute the URL identifying the publication in the public portal

Read more about Creative commons licenses: <https://creativecommons.org/licenses/>

### Take down policy

If you believe that this document breaches copyright please contact us providing details, and we will remove access to the work immediately and investigate your claim.

LUND UNIVERSITY

PO Box 117  
221 00 Lund  
+46 46-222 00 00



This is an author produced version of a paper published in Cardiovascular and Interventional Radiology. This paper has been peer-reviewed but does not include the final publisher proof-corrections or journal pagination.

Citation for the published paper:

Keussen, Inger and Bergqvist, Lennart and Rissler, Pehr and Cwikiel, Wojciech  
"Acute Effects of Liver Vein Occlusion by Stent-Graft Placed in Transjugular  
Intrahepatic Portosystemic Shunt Channel: An Experimental Study."  
Cardiovasc Intervent Radiol. 2006 Jan-Feb;29(1):120-3  
<http://dx.doi.org/10.1007/s00270-004-0288-x>

Access to the published version may require journal subscription.

Published with permission from: Springer

**Acute effects of liver vein occlusion by stent-graft placed in  
transjugular intrahepatic portosystemic shunt channel.  
An Experimental Study**

**Inger Keussen<sup>1</sup>, Lennart Bergqvist<sup>2</sup>, Pehr Rissler<sup>3</sup>,  
Wojciech Cwikiel<sup>4</sup>**

Departments of Radiology<sup>1</sup>, Radiation Physics<sup>2</sup>, Pathology<sup>3</sup>, University Hospital,  
Lund, Sweden, Department of Radiology, University of Michigan<sup>4</sup>, Ann Arbor, MI,  
USA

Address for correspondence:

Inger Keussen, MD

Center for Medical Imaging and Physiology,

Lund University Hospital

S-221 85 Lund, Sweden

Fax +46 46 211 69 56

E-mail: inger.keussen@skane.se

## **ABSTRACT**

*Purpose:* To evaluate the effects of hepatic vein occlusion by stent-graft used in transjugular intrahepatic porto-systemic shunt (TIPS).

*Material and methods:* The experiments were performed in six healthy pigs under general anesthesia. Following percutaneous transhepatic implantation of a port-a-cath in the right hepatic vein, TIPS was created with a stent-graft (Viatorr, W L Gore, Flagstaff, AZ, USA). The outflow from the hepatic vein, blocked by the stent-graft was documented by injection of contrast medium and repeated injections of  $^{99}\text{Tc}^{\text{m}}$ -labelled human serum albumin ( $^{99}\text{Tc}^{\text{m}}$ -HSA) through the port-a-cath. After two weeks the outflow was re-evaluated, the pigs were sacrificed and histopathologic examination of the liver was performed.

*Results:* Occlusion of the hepatic vein by a stent-graft had a short and temporary effect on the outflow. Histopathological examination from the affected liver segment showed no divergent pattern.

*Conclusion:* Stent-grafts used in TIPS block the outflow from the liver vein, but do not have a prolonged circulatory effect and do not affect the liver parenchyma.

*Key words:* Portal hypertension, transjugular intrahepatic portosystemic shunt, stent-graft, hepatic vein occlusion.

## INTRODUCTION

Over the last ten years, TIPS procedures have almost completely replaced surgical porto-systemic shunts in treatment of patients with portal hypertension and repeated bleeding from gastro-oesophageal varices (1, 2, 3, 4, 5) or refractory ascites. Long-term results of TIPS are, however, unsatisfactory due to development of pseudo-intimal hyperplasia in the shunt channel and/or intimal hyperplasia in the adjacent hepatic vein (6).

To overcome these problems stent-grafts have been used (7, 8, 9, 10, 11,12). These stent-grafts separate the shunt channel from the liver tissue, bile ducts and the wall of the hepatic vein, preventing development of hyperplasia.

Following TIPS, blood from the portal vein passes through the created shunt towards the right atrium, while flow to the intrahepatic portal vein branches is substantially decreased (13). The cranial portion used for TIPS stent-graft, may block the outflow from the hepatic vein to which the shunt extends. Decrease in the hepatic arterial flow to the liver segment drained by the blocked liver vein was reported (14) as well as segmental liver ischemia (15). Patients treated with TIPS often have an impaired liver function. Reduced blood flow through one liver segment can cause further deterioration.

The present study was performed in order to evaluate if the outflow from the hepatic vein blocked by a stent-graft, causing a “pseudo Budd Chiari-syndrome”, changed over two weeks of time and if there were any possible consequences for the affected liver segment.

## MATERIALS AND METHODS

### *Animals and anesthesia*

Six healthy pigs, 36- 40 kg body weight were used for the experiments after approval from the local ethic committee for animal research.

All procedures were performed under general anesthesia, induced by intramuscular injection of azaperone (Stresnil Vet, Leo, Helsingborg, Sweden) 2 mg/kg, followed by intravenous injection of thiopental (Pentothal Natrium, Abbot Lab, N. Chicago, IL,

USA) 5% solution, 2-4 ml. Following intubation, anesthesia was maintained by artificial ventilation with a mixture of oxygen and nitric oxide and continuous infusion of Ketamin-hydrochloride (Ketalar, Parke-Davis, Solna, Sweden) 1 mg/min and Midazolam (Dormicum, Roche, Stockholm, Sweden) 5 mg/hour. At the end of the experiments, all animals were sacrificed by an intracardial injection of an overdose of potassium.

#### *Preparation of radiopharmaceutical.*

Human serum albumin labelled to  $^{99}\text{Tc}^{\text{m}}$  is frequently used for circulation and blood flow studies. In our study we used TechneScan® HSA (Mallinckrodt Medical B.V., Petten, Holland) which was labelled to  $^{99}\text{Tc}^{\text{m}}$  according to the manufacturer's instructions. Freeze-dried HSA was dissolved in 8-10 ml pertechnetate solution (406-1790 MBq). After a 15-min incubation time, the preparation was ready to use. All preparations were tested within 5 h after labelling with instant thin-layer chromatography (ITLC-SG; Gelman Sciences, Ann Arbor, MI, USA), using 1 x 8 cm strips and 2-butanone (ethyl-methyl-ketone) as mobile phase. The amount of free pertechnetate varied between 0.04% and 0.45% (mean 0.25%). The injected activity was determined by measurements of the syringe before and after injection in a radioisotope calibrator (CRC-35R; Capintec, Pittsburgh, PA, USA). Blood samples were weighed and measured for radioactivity in a gamma counter (1282 CompuGamma CS, Wallac Oy, Turku, Finland). Assuming that the blood volume in pigs was 8% of the body weight, the percentage of the injected radioactivity leakage to peripheral blood was calculated.

#### *Procedures*

The left jugular vein was punctured after surgical cut down and thereafter catheterised. The tip of a 5 F Cobra catheter (Cordis, Johnson & Johnson C O, Roden, Netherlands) was manipulated jointly with a 0.035 glidewire (Terumo, Tokyo, Japan) into a peripheral branch of the right hepatic vein. Subsequently the tip of the catheter was used as a target for the percutaneous transhepatic puncture of this vein. The puncture was performed using Seldinger technique, with a 20 G needle (Medioplast, Malmö, Sweden), subsequently replaced over a 0.018 inch Cope wire

by a 5 Fr catheter (transhepatic cholangiography catheter cannula, both William Cook Europe, Bjaeverskov, Denmark). Contrast injection (Omnipaque, 350 ml I / ml, Amersham Health, Oslo, Norway) confirmed free outflow from the right hepatic vein.

Thereafter, a subcutaneous reservoir (port-a-cath, Deltec, Smiths Medical Industries, St. Paul, MN, USA), was implanted subcutaneously at the level of the liver, with the tip of the catheter placed in the right hepatic vein, approximately 5 mm from the confluence into the inferior vena cava. A transjugular, transhepatic access to the portal vein was created with a Cook TIPS Set (William Cook, Europe). Through the port-a-cath the radionuclide  $^{99}\text{Tc}^{\text{m}}$ -HSA was injected into the right hepatic vein. Samples of venous blood from the peripheral circulation was obtained after 1,3, 5 and 10 minutes, before the TIPS was created.

The TIPS was created with a 10 x 40 mm stent-graft, (VIATORR, W L Gore, Flagstaff, AZ, USA). The stent-graft was dilated with a 10 x 40 mm balloon (MediTech, Boston Scientific, Watertown, MA, USA). Free flow through the TIPS channel a was confirmed by portography (Fig 1 a). Occlusion of the right hepatic vein by the inserted stent-graft was documented by injection of contrast medium in the port-a-cath (Fig 1b). Injection of  $^{99}\text{Tc}^{\text{m}}$ -HSA through the port-a-cath in the occluded right hepatic vein was followed by blood sampling from the peripheral vein after 1, 3, 5 and 10 minutes.

A repeated injection of  $^{99}\text{Tc}^{\text{m}}$ -HSA as described above, was planned for two weeks later. Unfortunately, all the port-a-caths had dislodged from the intended location in the right hepatic veins. Under fluoroscopic guidance percutaneous puncture of the right hepatic vein, was therefore performed with a 20 G needle, towards the cephalic portion of the stent-graft. The position of the needle in the occluded hepatic vein was confirmed by contrast injection. The  $^{99}\text{Tc}^{\text{m}}$ -HSA was thereafter injected through the needle. The sampling of peripheral blood was repeated in the same intervals as previously.

Following sacrifice of the animals, parts of the liver, including segments with the occluded hepatic vein, stent-graft and normal liver from the left lobe were resected and sent to histopathological examination for evaluation of possible changes

secondary to venous congestion. Three samples from each liver lobe were evaluated. The liver tissue was fixed in 10% natural buffer formalin and embedded in paraffin. Slides were prepared and stained with haematoxylin and eosin according to standard protocols.

## **RESULTS**

Despite successful insertion of the stent-grafts in the intended position, the hepatic vein was not completely blocked in one pig due to an anatomic variation and this pig was excluded from the study. In one pig the placed stent-graft was too short and its bare part did not reach far enough into the portal vein. This portion of the shunt was therefore supported with a 12 x 80 mm stent (Smart, Cordis), to obtain optimal blood flow through the shunt channel. One pig died of respiratory failure just prior to the final radionuclide examination. Consequently the experiments could only be completed in four pigs, which excluded possibility of statistical evaluation at the end point of the study.

The radionuclide examination after TIPS, showed primarily (after one minute) decreased outflow from the occluded hepatic vein, compared to the measurements before TIPS. However, already after three minutes the outflow was normalized (Table 1). Values obtained in four pigs after two weeks were comparable to the ones obtained before TIPS, indicating good outflow from the liver vein, closed by the stent-grafts. There were no complications secondary to dislodgement of the subcutaneous reservoirs from the liver.

The stent-grafts were fully patent in one pig, while the remaining were occluded to 75-100%.

One animal showed macroscopic cirrhosis, while the others showed no macroscopic fibrosis, cirrhosis, steatosis or sign of congestion. Most of the samples had microscopically a similar pattern with normal acinar structure. There were no marked portal fibrosis, no bile-duct damage or interface hepatitis. A few neutrophils,

lymphocytes and plasma cells were found in the portal tract. Terminal hepatic venule and sinusoids showed minor dilatation but no fibrosis around central veins.

One pig had a different histopathological finding. This pig had signs of cirrhosis with marked infiltration of neutrophils, lymphocytes and plasma cells, shown in both samples, findings most likely related to chronic defects. In two more samples, from different pigs and from different lobes, light portal fibrosis was found with a mild infiltration of neutrophils, lymphocytes and plasma cells, but no fibrosis around central veins.

## **DISCUSSION**

The advantage of stent-grafts in TIPS is its ability to separate the shunt channel from the liver parenchyma, bile ducts and the wall of the hepatic vein, preventing development of pseudointimal and intimal hyperplasia (2, 4, 11). The stent-graft has also been used to treat haemorrhage after extra-hepatic portal vein puncture during a TIPS procedure (16). Several graft materials have been used for construction of stent-grafts (8, 9, 10). The Viatorr stent-graft (WL Gore, Flagstaff, AZ, USA) used in our study, is a nitinol-polytetrafluoroethylene stent-graft for TIPS, commercially available and easy to handle (17). These dedicated stent-grafts can also be safely used in patients, who need a TIPS while waiting for liver transplantation (18).

Changes in the hepatic perfusion of the liver occur after TIPS placement (13). The blood flow to the intrahepatic portal vein branches is diminished and the liver is supplied with blood mainly from the hepatic artery. The cranial portion of a stent-graft used for TIPS, positioned in a hepatic vein, blocks the outflow from this vein (14,15). It has been shown that the use of stent-grafts can decrease perfusion to the adjacent liver segment, due to occlusion of a liver vein (14). This can potentially have serious consequences for a patient with an already impaired liver function. In cirrhotic patients, CT has revealed segmental liver ischemia in a few cases (15) even remaining for a long time.

In our experiment, we wanted to evaluate venous outflow from the liver segment, drained by hepatic vein, which became occluded by the stent-graft used for TIPS. Activity of  $^{99}\text{Tc}^{\text{m}}$  HSA injected in the occluded liver vein, measured in peripheral blood was primarily slightly decreased. However, in our experiments the activity reached

the same level after three minutes as that measured before TIPS. Our findings indicated that occlusion of one liver vein, affected the venous outflow only for a very short period of time, when the other liver veins remained open. The measurements obtained after two weeks confirmed these findings.

Histopathological assessment showed normal acinar structure in most of the samples. One pig had a divergent pattern, probably due to more chronic changes. Two pigs showed a very light increase of fibrosis, which may be within normal anatomical variation.

Statistical evaluation of our material was not possible, because completion could only be performed in four animals, due to the complications described above. Another limitation of the study is of course, that it was performed in healthy animals and the findings can be different in patients with cirrhosis.

We conclude in our limited experimental study that a “pseudo Budd-Chiari syndrome”, which appeared after insertion of a stent-graft in the TIPS channel, had no significant impact on venous outflow. Occlusion does not cause obvious changes in the affected liver segment.

## REFERENCES

1. Richter GM, Noeldge G, Palmaz JC et al (1990). Transjugular intrahepatic portocaval stent shunt. Preliminary clinical results. Radiology 174:1027-1030.
2. Haskal ZJ, Ring EJ, LaBerge JM et al (1992). Role of parallel transjugular intrahepatic portosystemic shunts in patients with persistent portal hypertension. Radiology 185:813-817.
3. Burroughs AK, Patch D (1999). Transjugular intrahepatic portosystemic shunt. Semin Liver Dis 19:457-473.

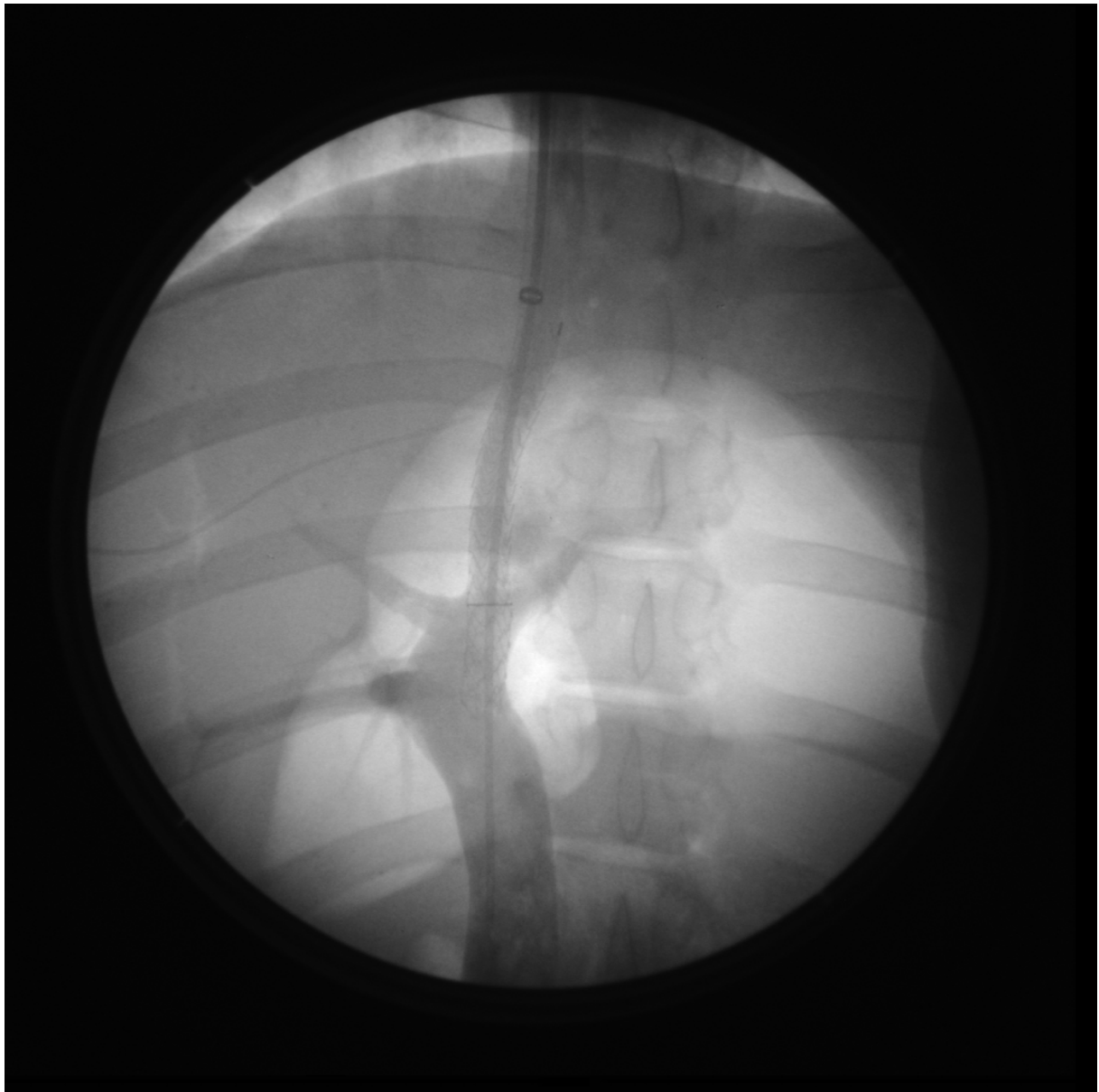
4. Rees CJ, Nylander DL, Thompson NP et al (2000). Do gastric and oesophageal varices bleed at different portal pressures and is TIPS an effective treatment? *Liver* 20:253-256.
5. Lake JR (2000). The role of transjugular portosystemic shunting in patients with ascites. *N Engl J Med* 342:1745-1747.
6. Saxon RR, Ross PL, Mendel-Hartvig J et al (1998). Transjugular intrahepatic portosystemic shunt patency and the importance of stenosis location in the development of recurrent symptoms. *Radiology* 207:683-693.
7. Haskal ZJ, Brenneke LJ (1999). Porous and nonporous polycarbonate urethane stent-grafts for TIPS formation: Biologic responses. *JVIR* 10:1255-1263.
8. Haskal ZJ, Davis A, McAllister A et al (1997). PTFE-encapsulated endovascular stent-graft for transjugular intrahepatic portosystemic shunts: Experimental evaluation. *Radiology* 205:682-688.
9. Cejna M, Thurnher S, Pidlich J et al (1999). Primary implantation of polyester-covered stent-grafts for transjugular intrahepatic portosystemic stent shunts (TIPSS): A pilot study. *Cardiovasc Intervent Radiol* 22:305-310.
10. Tanihata H, Saxon RR, Kubota Y et al (1997). Transjugular intrahepatic shunt with silicone-covered Wallstents: results in a swine model. *Radiology* 205: 181-184.
11. Andrews RT, Saxon RR, Bloch RD et al (1999). Stent-Grafts for de novo TIPS: Technique and early results. *JVIR* 10:1371-1378.

12. Cejna M, Peck-Radosavljevic M, Thurnher S et al (2002). ePTFE-covered stent-grafts for revision of obstructed transjugular intrahepatic portosystemic shunt. *Cardiovasc Intervent Radiol.* 25:365-372.
13. Walser EM, DeLa Pena R, Villanueva-Meyer J et al (2000). Hepatic perfusion before and after the transjugular intrahepatic portosystemic shunt procedure: impact on survival. *JVIR* 11:913-918.
14. Keussen I, Ho-Young Song, Bajc M et al (2002). Changes in the Distribution of Hepatic Arterial Blood Flow Following TIPS with Uncovered Stent and Stent-Graft: An Experimental Study. *Cardiovasc Intervent Radiol.* 25:314-317.
15. Bureau C, Otal P, Chabbert V et al (2002) Segmental liver ischemia after TIPS procedure using a new PTFE-covered stent. *Hepatology* 36:1554.
16. Brountzos EN, Alexopoulou E, Koskinas I et al (2000). Intraperitoneal portal vein bleeding during transjugular intrahepatic portosystemic shunt: Treatment with stent-graft placement. *AJR* 174:132-134.
17. Rose JDG, Pimpalwar S, Jackson RW (2001). A New Stent-Graft for Transjugular Intrahepatic Portosystemic Shunts. *British Journal of Radiology* 74:908-912.
18. Maleux G, Pirenne J, Vaninbroukx et al (2004). Are TIPS stent-grafts a contraindication for future liver transplantation? *Cardiovasc Intervent Radiol.* 27:140-142.

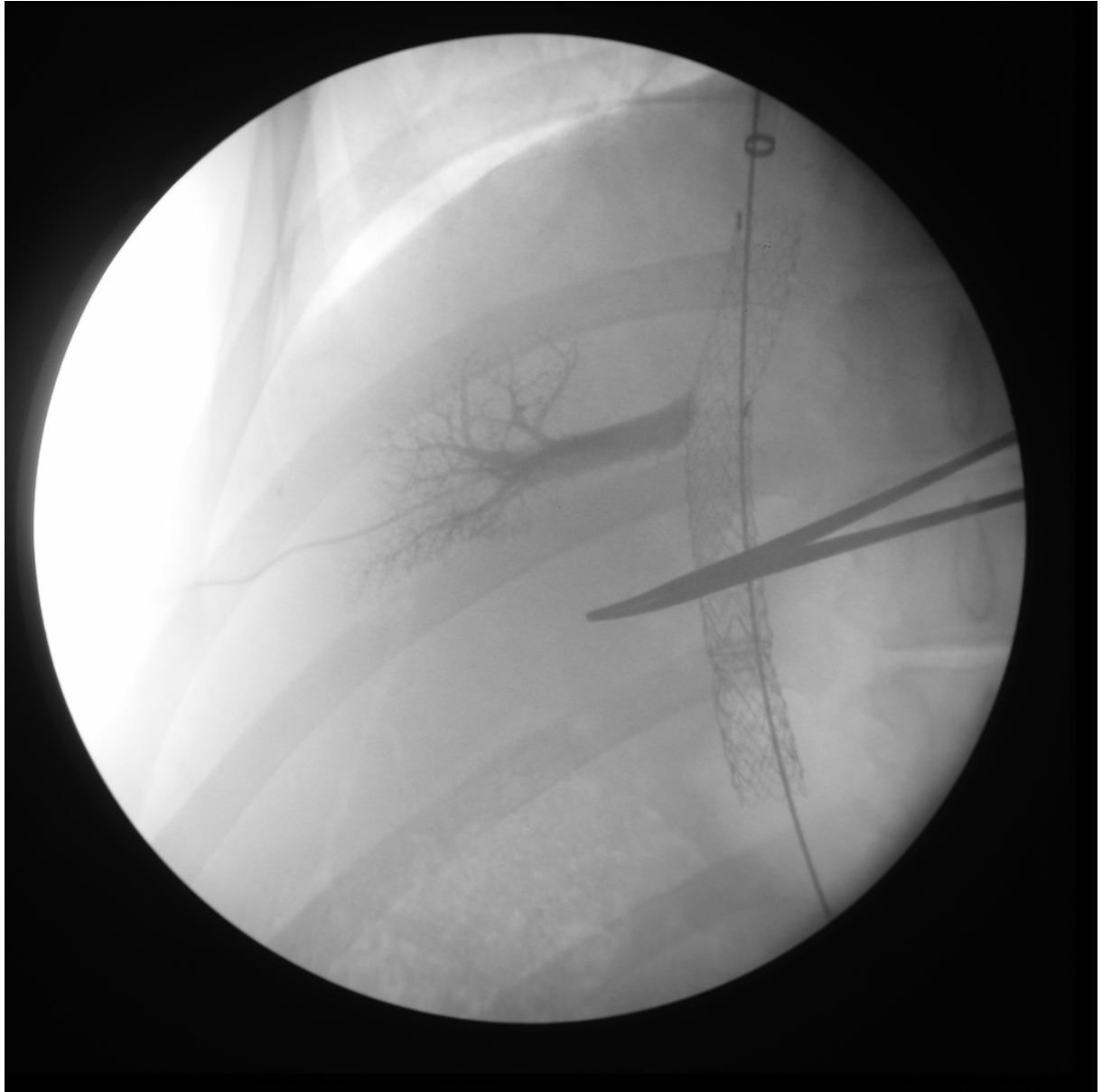
## LEGENDS

Fig 1.

- a. Portography after TIPS shows blood flow through the TIPS channel.
- b. Percutaneous contrast injection show blockage of the right hepatic vein after TIPS.



a.



b.

**TABLE 1**

Measurements of  $^{99}\text{Tc}^{\text{m}}$ -HSA in peripheral blood before and after occlusion of the hepatic vein with a stent-graft. Mean values.

