



LUND UNIVERSITY

Decreasing myelin density reflected increasing white matter pathology in Alzheimer's disease-a neuropathological study.

Sjöbeck, Martin; Haglund, Mattias; Englund, Elisabet

Published in:
International Journal of Geriatric Psychiatry

DOI:
[10.1002/gps.1384](https://doi.org/10.1002/gps.1384)

2005

[Link to publication](#)

Citation for published version (APA):
Sjöbeck, M., Haglund, M., & Englund, E. (2005). Decreasing myelin density reflected increasing white matter pathology in Alzheimer's disease-a neuropathological study. *International Journal of Geriatric Psychiatry*, 20(10), 919-926. <https://doi.org/10.1002/gps.1384>

Total number of authors:
3

General rights

Unless other specific re-use rights are stated the following general rights apply:
Copyright and moral rights for the publications made accessible in the public portal are retained by the authors and/or other copyright owners and it is a condition of accessing publications that users recognise and abide by the legal requirements associated with these rights.

- Users may download and print one copy of any publication from the public portal for the purpose of private study or research.
- You may not further distribute the material or use it for any profit-making activity or commercial gain
- You may freely distribute the URL identifying the publication in the public portal

Read more about Creative commons licenses: <https://creativecommons.org/licenses/>

Take down policy

If you believe that this document breaches copyright please contact us providing details, and we will remove access to the work immediately and investigate your claim.

LUND UNIVERSITY

PO Box 117
221 00 Lund
+46 46-222 00 00

The following pages constitute the final, accepted and revised manuscript of the article:

Sjöbeck, Martin and Haglund, Mattias and Englund, Elisabet

“Decreasing myelin density reflected increasing white matter pathology in Alzheimer's disease-a neuropathological study.”

Int J Geriatr Psychiatry. 2005 Oct;20(10):919-26.

Publisher: Wiley

Use of alternative location to go to the published version of the article requires journal subscription.

Alternative location: <http://dx.doi.org/10.1002/gps.1384>

Decreasing myelin density reflected increasing white matter pathology
in Alzheimer's disease
- A neuropathological study

Martin Sjöbeck, Mattias Haglund and Elisabet Englund

All at the Department of Pathology, Division of Neuropathology, University Hospital

S-221 85 Lund, Sweden

Running title

Myelin density in AD white matter

Correspondence address

Martin Sjöbeck MD

Department of Pathology, Division of Neuropathology

University Hospital

S-221 85 Lund, Sweden

Tel: +46-46-17 34 09

Fax: +46 46 14 33 07

E-mail: Martin.Sjobeck@med.lu.se

Key words

Myelin, Alzheimer's disease, dementia, white matter disease, optical density

Summary

Background

White matter disease (WMD) is frequently seen in Alzheimer's disease (AD) at neuropathological examination. It is defined as a subtotal tissue loss with a reduction of myelin, axons and oligodendrocytes as well as astrogliosis. Studies quantitatively defining the myelin loss in AD are scarce. The aim was to develop a method that could provide numerical values of myelin density in AD. The purpose was to compare the myelin contents in increasing grades of pathology of WMD, with age and cortical AD pathology as well as in different regions of the brain in AD.

Material and methods

16 cases with AD and concomitant WMD were investigated with an in house developed image analysis technique to determine the myelin attenuation with optical density (OD) in frontoparietal, parietal, temporal and occipital white matter on whole brain coronal sections stained for myelin with Luxol Fast Blue (LFB). The OD values in LFB were compared grouped according to Haematoxylin/Eosin (HE) evaluated mild, moderate and severe WMD or normal tissue. The OD values were also correlated with age and cortical AD pathology and compared between the different studied white matter regions.

Results

Increasing severity of WMD was associated with a statistically significant OD reduction. No correlation was seen between age and OD or overall cortical AD pathology. The OD values were significantly lower in frontoparietal- compared to occipital white matter.

Conclusions

Myelin loss in AD with WMD is a marked morphologic component of the disease and it is possible to determine the reduction objectively in neuropathological specimens with quantitative measures. This may be of use for clinical diagnostics including brain imaging.

Introduction

White matter disease (WMD) is seen at neuropathological examination in more than 50 percent of Alzheimer's disease (AD) cases (Brun and Englund, 1986). The WMD is non-focal and mild, associated with a stenosing fibrohyaline arteriolosclerosis and no complete infarcts are seen (Englund and Brun, 1990). The localisation of the WMD is widespread with the frontal lobes being more severely affected (Brun and Englund, 1986; Sjobeck *et al.*, 2005, in press). However, in all cases of WMD of any degree, there are spared areas of microscopically normal white matter. The WMD is thought to be of ischemic origin due to its resemblance to the white matter surrounding the complete infarct seen in vascular dementia and stroke and also due to the associated arteriolosclerosis (Brun and Englund, 1986). Morphologically, the WMD consists of an oligodendrocytic reduction and astrocytosis (Sjobeck and Englund, 2003), in parallel with axonal and myelin attenuation and fibrohyaline arteriolosclerosis (Brun and Englund, 1986; Englund and Brun, 1990). Severity of WMD has been shown to correlate with number of microvessels in the white matter, i.e., more pronounced changes are associated with fewer vessels (Sjobeck *et al.*, 2003), but no association has been shown between overall severity of cortical AD pathology and severity of WMD (Brun and Englund, 1986; Haglund and Englund, 2002). The congophilic amyloid angiopathy (CAA) of AD, however, has been shown to correlate with severity of WMD in AD (Haglund and Englund, 2002), suggesting a vascular link in the pathogenesis of the white matter pathology.

Recently, a hypothetical model of AD was presented that links myelin breakdown and vulnerable oligodendrocytes to both ageing and cortical AD pathology (Bartzokis, 2004). Studies have shown that the myelin density is reduced in ageing (Ge *et al.*, 2002; Bartzokis *et al.*, 2003) and in disorders affecting the white matter such as multiple sclerosis (Fazekas *et al.*, 2002; Keegan and Noseworthy, 2002), CADASIL (Baudrimont *et al.*, 1993; Okeda *et al.*,

2002), Binswangers disease (Roman, 1985) and vascular dementia (Wallin and Blennow, 1991).

The reduction of myelin has never been neuropathologically assessed with quantitative measures in AD-WMD, whereas the white matter components (axons, glia, vessels etc.) have been measured (Englund and Brun, 1990; Sjobeck and Englund, 2003; Sjobeck *et al.*, 2003). To be able to determine the myelin density in neuropathological specimens, a computer assisted morphometric image analysis technique was developed.

Utilising this method, the myelin density in normal white matter and in white matter with different degrees of WMD was assessed. The main hypothesis was that increasing severity of WMD should correspond to measures of gradually lower myelin density.

Aims

- To develop a method that could provide quantitative measures of myelin attenuation on neuropathological sections.
- To determine the myelin density for microscopically normal appearing white matter in AD and compare with myelin density in white matter with increasing severity of pathology.
- To correlate myelin density in different regions of the brain with overall cortical AD pathology and age to evaluate the possible additional effects of ageing per se.
- To determine differences in regional myelin density in AD between white matter in the lobes of the brain with the overall purpose to further elucidate the relationship between AD and WMD.

Material

16 cases with a neuropathological diagnosis of AD and no mixture of vascular dementia were analysed. The cases were deceased between 1994 and 2000. All cases had a clinical diagnosis

of dementia and had been participating in the Lund Longitudinal Dementia Study, in which they were followed with repeated psychiatric evaluation, neuropsychological testing, regional cerebral blood flow measurements and structural neuroimaging (Brun and Gustafson, 1993). The cases were carefully selected to represent pure AD, i.e. cases with white or grey matter complete infarcts were excluded. The cases were thus “non-mixed” AD cases, although with a concomitant WMD of a mild ischemic type (Brun and Englund, 1986).

Baseline characteristics for the 16 cases are presented in table 1. Mean age at death for the AD-WMD cases was 77.2 years (SD = 10.8, range 59-91 years).

The study design was approved by the local research ethics committee at the University of Lund (LU 913-03).

Table 1

Methods

Neuropathological histotechnical processing

Prior to this study the brains were processed and neuropathologically analysed for final clinical/pathological diagnosis in the following way: At autopsy the brain were fixed in formaldehyde for no less than one month and later cut in 1 cm whole brain coronal slices.

From the cut whole brain, roughly every other coronal slice was embedded in paraffin, sectioned and stained with routine Haematoxylin/Eosin (HE) and Luxol Fast Blue (LFB).

Whole brain sections were also stained with Congo red for amyloid and the silver stainings Campbell for senile plaques and Gallyas for neurofibrillary tangles and dystrophic neurites, respectively.

Assessment of severity of Alzheimer's disease

The diagnosis of AD was made according to definitions used at the department (Brun and Englund, 1981). These criteria encompass several histopathological features in an assessment of the entire brain (glial reactions, neuronal degeneration, estimation but not quantitative assessment of congophilic angiopathy and cortical atrophy), thus enabling the exclusion of concurrent disease. With this method the regional grey matter Alzheimer encephalopathy was graded according to a scale from 0-4 and overall whole-brain Alzheimer pathology was summarized as mild, moderate or severe, also allowing for grades “in-between” (table 1). This scale also met with international consensus criteria (Braak and Braak, 1991; Mirra *et al.*, 1991).

Assessment of severity of white matter disease and myelin density

WMD was analysed on HE and LFB stained whole brain sections; one coronal section through the frontoparietal and temporal lobes at the level of either mid-hippocampus or amygdala, one through the parietal lobes and one through the occipital lobes. Thus in all, 3 sections stained with HE and 3 sections stained with LFB were analysed representing left and right hemisphere frontoparietal- parietal- temporal- and occipital white matter regions (figure 1). In a few cases, one section from one of the lobes was missing or only one hemisphere was present on the slide.

Altogether, 6 small, targeted white matter samples were marked for analysis of myelin attenuation in ladder like boxes representing consecutive areas in each hemisphere on the LFB stained slides (figure 1). Thus, in most cases 12 white matter samples were analysed in each of the frontoparietal, temporal, parietal and occipital lobes rendering a total of 680 specified areas in all 16 cases. Within these small regions digital pictures were taken in a microscope with the X10 objective. The pictures were taken under identical light conditions for all cases.

An Olympus DP-40 digital camera (Olympus Corporation, Japan) mounted on a Olympus BH-2 microscope (Olympus Corporation, Japan) was used augmented by the software Irfan View 3.80 (© 1996-2002 Irfan Skiljan, freeware at www.irfanview.com) and Twain Viewfinder 3.0.1 (© 1998-2002 Pixera Corporation, Los Gatos, California, USA). The pictures were taken with the Twain Viewfinder setting at the manual exposure mode with exposure time of 1/120 s and a sensitivity of 100. The images were saved as greyscale 0-255 pixel value tiff files with a resolution of 300 dpi. The size of the saved images was 302 kilobytes per image.

The optical density (OD) corresponds to the brightness of an image in the greyscale range of 0-255 with 8 bit pixel values, so that 0 corresponds to maximum white and 255 maximum black. The OD has previously been used for determination of the regional distribution of WMD in AD as well as estimation of glial numbers in the department (Sjoberck *et al.*, 2005, in press; Sjoberck and Englund, 2003;). Furthermore, others used OD for quantification of gene expression using in situ hybridization and in immunohistochemical analysis (Panegyres *et al.*, 2000; Hellier *et al.*, 2002; Wang and Li, 2003).

The OD was measured using an image processing and analysis software program designed for the PC, Scion Image (© 2000 Scion Corporation, Version Beta 4.0.2, freeware at www.scioncorp.com). Scion Image was used to calculate OD in each image using the rectangular selection tool. Tissue artefacts were omitted in the delineated regions. In all the analyses, the identity of the case was blinded to the observer.

On the HE stained slides, 6 consecutive white matter samples were delineated bilaterally in each hemisphere in ladder like boxes in the corresponding regions as on the LFB-stained slides. In each small sample the WMD-grade was estimated in the microscope by two of the authors (MS and MH) using a 4 step scale originally designed for semi-quantitative estimation

of severity of white matter disease (Brun and Englund, 1986), albeit not covering the associated arteriolar pathology. The main features of the scale are represented in levels:

Normal white matter.

Mild: No appreciable reduction in axonal meshwork density and easily recognised long axons. Occasional axonal debris. A slightly increased number of reactive astrocytes compared with normal white matter.

Moderate: A slight reduction of axonal meshwork density and a reduction of oligodendroglial cell nuclei and a further increased number of reactive astrocytes.

Severe: A marked reduction of myelin, axons and oligodendroglial cell nuclei with relatively marked astrocytic reaction and loosely scattered macrophages, but no complete cerebral infarct.

Statistical analysis and myelin optical density adjustment with values for normal white matter

Statistical analysis was performed using the SPSS® 11.0 software (SPSS inc.) on a personal computer. To determine myelin density in white matter with increasing severity of pathology the OD values in LFB were grouped according to HE evaluated severity of WMD in four groups: samples with normal white matter, samples with mild-, moderate- and severe pathology, respectively. Differences in OD between the groups were tested using a one-way ANOVA with post-hoc testing with Bonferroni adjustment for multiple comparisons. All the groups followed approximately the normal distribution when plotted in a histogram and the OD measurements were considered independent observations.

Since LFB staining is known to vary in intensity between cases depending on the histotechnical procedure employed, the OD values in frontoparietal- parietal- temporal- and occipital white matter regions were adjusted by the following procedure. For each case, the

mean OD in the white matter samples graded as normal in HE was calculated. For each case, the mean OD obtained from the 12 samples in frontoparietal- parietal- temporal- and occipital white matter regions, respectively were then divided by the case specific mean OD for normal graded white matter. This procedure resulted in OD ratios for myelin density, thus enabling correlation analysis involving all cases and analysis of myelin content between different white matter regions in AD.

Correlations were tested using the non-parametric two-tailed Spearman Rank test.

Correlation analyses were made between overall cortical Alzheimer encephalopathy grade as well as age and mean OD values in the different white matter regions (frontoparietal-, parietal-, temporal- and occipital white matter) divided by the case specific OD for normal white matter. To study differences in OD ratios obtained from the different white matter regions, the non-parametric Kruskal-Wallis test was used with post-hoc two-tailed Mann-Whitney testing and Bonferroni correction for multiple analyses.

OD in the corresponding left and right hemisphere was also correlated. For this analysis, the mean OD calculated from the 6 white matter regions in each hemisphere and white matter region (frontoparietal-, parietal-, temporal- and occipital white matter) was used.

For all analyses, the level of significance was set at $p < 0.05$.

Figure 1

Results

The total number of small white matter samples analysed for myelin attenuation with OD as well as severity of WMD was 680 in all 16 cases. The OD values for white matter samples in normal tissue, mild-, moderate- and severe WMD are presented in figure 2.

The mean OD value in the white matter samples graded as normal was 115 ($n = 95$, $SEM = 1.90$), in the regions graded as mild 111 ($n = 364$, $SEM = 0.94$), in the samples graded as

moderate 108 ($n = 173$, $SEM = 1.25$) and in the samples graded as having severe pathology 102 ($n = 48$, $SEM = 2.10$). There were statistically significant differences between the samples of normal and moderate pathology, between the samples of normal and severe pathology and between mild and severe pathology (table 2 and figure 2).

After Bonferroni adjustment for multiple analysis, no statistically significant correlations were seen between OD ratios in any of the studied white matter regions (frontoparietal- parietal- temporal- and occipital white matter) and severity of cortical AD pathology or age at death (table 3).

The OD correlated significantly in the corresponding right and left hemisphere (Correlation coefficient = 0.79, $p < 0.001$, $n = 56$, figure 3).

There was a statistically significant difference in OD ratios between the studied white matter regions (frontoparietal- parietal- temporal- and occipital white matter, Kruskal-Wallis $p = 0.026$) and post-hoc testing revealed statistically significant lower mean OD ratio in frontoparietal- compared to occipital white matter (two tailed Mann-Whitney with post-hoc Bonferroni adjustment, $p = 0.048$). There were no other significant differences in mean OD ratio between the studied white matter regions.

Figure 2

Table 2

Table 3

Figure 3

Discussion

Methodological considerations

Several factors could influence the OD values obtained for the stained brain sections. The values depend on the intensity of the staining, which in turn can depend on the histotechnical

procedure employed, type of staining and the type of pathology. The patients included in the study succumbed between 1994 and 2000 and were subsequently neuropathologically analysed for final diagnosis. The whole brain sections originally prepared were later used in the present study for evaluation of myelin density. Differences in methodology over the years could influence the staining intensity, especially since the LFB staining requires a histotechnical subjective differentiation step for optimal visualisation of myelin. However, the slides that were analysed were prepared according to standardised protocols for fixation, original brain slice thickness, dehydration, sectioning and staining procedure and a limited number of technicians prepared the sections. The analyses were furthermore based on comparison with OD for normal white matter as evaluated in HE staining, either by grouping OD values according to severity of pathology and compare with values for normal white matter or by dividing the OD values with the corresponding value for normal white matter. The cases were selected carefully to represent AD with WMD and without any additional pathology. Thus cases with complete infarcts and other white matter pathologies were excluded, as were cases exhibiting changes emanating from a final hypoxic oedema. Despite this procedure there were variations in the OD values obtained. A single OD measurement should not be considered as an absolute measurement of the myelin density but must be compared with values obtained for normal white matter. With such comparisons we believe that OD measurement is suitable to determine the magnitude of the myelin density for different grades of white matter pathology and for different regions of the brain in AD.

Different white matter pathologies in AD

As evaluated in the microscope, the AD white matter harbour different types of pathology (Englund, 1998). Firstly, in AD combined with vascular dementia, one may detect cerebrovascular pathology of complete infarcts and a surrounding attenuation of tissue.

Secondly, whether in mixed cases or in pure AD, Wallerian degeneration is accentuated in brain regions where the cortical AD changes are pronounced, i.e. the temporal lobes (Englund, 2000). The third form of white matter pathology believed to be the predominant, focused on in the present study is of mild, non focal ischemic type in the central regions. No significant correlations were seen between severity of overall cortical AD pathology and OD ratios, in line with previously observed lack of correlation between the grey- and white matter pathology (Brun and Englund, 1986; Sjobeck and Englund, 2003). The association between WMD, central white matter arteriolosclerosis and CAA in the meninges and outer cortex is notable (Haglund and Englund, 2002; Tian *et al.*, 2004). The number of small vessels correlates inversely with severity of WMD, further indicating the association with vascular manifestations (Sjobeck *et al.*, 2003).

Comments on the main findings and clinical implications

The main finding of the present study was that myelin density measured with OD gradually decreased with increasing severity of WMD. Compared to normal white matter, there was a significantly low myelin density in moderate and severe WMD. In AD, myelin reduction has been shown by neuropathology, biochemical analyses and MRI (Englund and Brun, 1990; Roher *et al.*, 2002; Bartzokis *et al.*, 2003). This is, however, to our knowledge the first time white matter myelin loss in AD has been quantitatively estimated neuropathologically on sections for microscopy. Loss of myelin is seen in multiple disorders affecting the brain and is suggested in normal ageing (Ge *et al.*, 2002; Bartzokis *et al.*, 2003). In the present study, no correlation was seen between white matter OD ratios in any of the studied regions and age at death, implying that the myelin content is more affected by the AD process than by ageing. We believe that the WMD in focus of the present study could be due to recurrent episodes of ischemia with a gradual loss of oligodendrocytes and myelin. The white matter has only

limited ways of response to different stressors and the neuropathological outcome could be similar. Therefore, the WMD is similar to the perifocal territory surrounding a complete infarct in the white matter seen in stroke or vascular dementia. The distribution of the changes in the white matter throughout the brain and its relation to concurrent pathologies in adjacent structures is relevant. The overall WMD has been shown to be pronounced in the frontal lobes although with an involvement also of the other lobes of the brain (Brun and Englund, 1986; Kobayashi *et al.*, 2002; Sjobeck *et al.*, 2005, in press). In line with these findings, there was a statistically significant lower OD ratio in the frontoparietal- compared to occipital white matter in the present study, suggesting that in frontal areas also the myelin reduction in AD is substantial.

The statistically significant correlation between the OD values in the corresponding right and left hemispheres, as shown here, suggest that the WMD myelin reduction is not lateralised, but uniformly distributed in the right and left hemisphere.

The reduction of myelin as demonstrated in this study could be of relevance for the symptom profile in the demented patient (Englund *et al.*, 1989; Londos *et al.*, 2000). The clinical presentation could be due to the distribution of the changes and be related to cortical-subcortical disconnection (Brun and Englund, 1986; Kobayashi *et al.*, 2002). In AD, executive dysfunction is seen (Graham *et al.*, 2004), that in part could be due to impairment of neuronal impulses through the frontal lobes.

We conclude that AD with WMD is subject to a differential reduction of myelin, a reduction that is possible to evaluate quantitatively in post-mortem neuropathological specimens. The hereby presented method could be suitable for further studies aimed at evaluating the relationship between microvascular pathology, age and AD specific changes.

Key points

- Myelin loss is a marked morphologic component in white matter disease associated with Alzheimer's disease.
- It is possible to determine the reduction of myelin objectively on sections for microscopy.
- The anterior part of the brain is more heavily affected by myelin reduction than the posterior part.
- The regional distribution of demyelinated white matter in Alzheimer's disease could be of relevance for the symptom profile in the demented patient.

Acknowledgements

This study was supported by grants from Stiftelsen Demensfonden - the Swedish Dementia Foundation, the Kockska Foundation, the Stohne Foundation, the Swedish Alzheimer Foundation, the Crafoord Foundation, Pfizer Sweden, the Lund University Hospital and the Royal Physiographic Society, Lund. The authors wish to thank Kerstin Stureson, Annette Persson, Sanaz Mojighashghaei and Anna Härfstrand, all at the Department of Pathology for histotechnical work and advice, Lars Olofsson and Leif Olofsson, the Department of Pathology and Eric Carlemalm of the Electron Microscopy Unit, for their help and advice with image processing and Håkan Lökvist, Region Skåne Competence Centre for Clinical Research, for statistical assistance.

References

- Bartzokis G. 2004. Age-related myelin breakdown: a developmental model of cognitive decline and Alzheimer's disease. *Neurobiol Aging* **25**(1): 5-18; author reply 49-62.
- Bartzokis G, Cummings JL, Sultzer D, *et al.* 2003. White matter structural integrity in healthy aging adults and patients with Alzheimer disease: a magnetic resonance imaging study. *Arch Neurol* **60**(3): 393-398.
- Baudrimont M, Dubas F, Joutel A, *et al.* 1993. Autosomal dominant leukoencephalopathy and subcortical ischemic stroke. A clinicopathological study. *Stroke* **24**(1): 122-125.
- Braak H, Braak E. 1991. Neuropathological staging of Alzheimer-related changes. *Acta Neuropathol (Berl)* **82**(4): 239-259.
- Brun A, Englund E. 1981. Regional pattern of degeneration in Alzheimer's disease: neuronal loss and histopathological grading. *Histopathology* **5**(5): 549-564.
- Brun A, Englund E. 1986. A white matter disorder in dementia of the Alzheimer type: a pathoanatomical study. *Ann Neurol* **19**(3): 253-262.
- Brun A, Gustafson L. 1993. The Lund longitudinal dementia study: A 25-year perspective on neuropathology, differential diagnosis and treatment. In *Alzheimer's Disease: Advances in clinical and basic research*, Corain B, Iqbal K, Nicolini M, Winblad B, Wisniewski H, Zatta P (eds). John Wiley & Sons Ltd: New York; 3-18.
- Englund E. 1998. Neuropathology of white matter changes in Alzheimer's disease and vascular dementia. *Dement Geriatr Cogn Disord* **9 Suppl 1**: 6-12.
- Englund E. 2000. Neuropathology of White Matter Disease: Parenchymal Changes. In *The Matter of White Matter. Clinical and Pathophysiological Aspects of White Matter Disease Related to Cognitive Decline and Vascular Dementia*, Pantoni L, Inzitari D, Wallin A (eds). Academic Pharmaceutical Productions: Utrecht; **10**; 223-246.

- Englund E, Brun A. 1990. White matter changes in dementia of Alzheimer's type: the difference in vulnerability between cell compartments. *Histopathology* **16**(5): 433-439.
- Englund E, Brun A, Gustafson L. 1989. A white-matter disease in dementia of Alzheimer's type - Clinical and neuropathological correlates. *Int J Geriatr Psychiatry* **4**: 87-102.
- Fazekas F, Ropele S, Enzinger C, *et al.* 2002. Quantitative magnetization transfer imaging of pre-lesional white-matter changes in multiple sclerosis. *Mult Scler* **8**(6): 479-484.
- Ge Y, Grossman RI, Babb JS, *et al.* 2002. Age-related total gray matter and white matter changes in normal adult brain. Part II: quantitative magnetization transfer ratio histogram analysis. *AJNR Am J Neuroradiol* **23**(8): 1334-1341.
- Graham NL, Emery T, Hodges JR. 2004. Distinctive cognitive profiles in Alzheimer's disease and subcortical vascular dementia. *J Neurol Neurosurg Psychiatry* **75**(1): 61-71.
- Haglund M, Englund E. 2002. Cerebral amyloid angiopathy, white matter lesions and Alzheimer encephalopathy - a histopathological assessment. *Dement Geriatr Cogn Disord* **14**(3): 161-166.
- Hellier WP, Wagstaff SA, O'Leary SJ, *et al.* 2002. Functional and morphological response of the stria vascularis following a sensorineural hearing loss. *Hear Res* **172**(1-2): 127-136.
- Keegan BM, Noseworthy JH. 2002. Multiple sclerosis. *Annu Rev Med* **53**: 285-302.
- Kobayashi K, Hayashi M, Nakano H, *et al.* 2002. Apoptosis of astrocytes with enhanced lysosomal activity and oligodendrocytes in white matter lesions in Alzheimer's disease. *Neuropathol Appl Neurobiol* **28**(3): 238-251.
- Londos E, Passant U, Brun A, *et al.* 2000. Clinical Lewy body dementia and the impact of vascular components. *Int J Geriatr Psychiatry* **15**(1): 40-49.

- Mirra SS, Heyman A, McKeel D, *et al.* 1991. The Consortium to Establish a Registry for Alzheimer's Disease (CERAD). Part II. Standardization of the neuropathologic assessment of Alzheimer's disease. *Neurology* **41**(4): 479-486.
- Okeda R, Arima K, Kawai M. 2002. Arterial changes in cerebral autosomal dominant arteriopathy with subcortical infarcts and leukoencephalopathy (CADASIL) in relation to pathogenesis of diffuse myelin loss of cerebral white matter: examination of cerebral medullary arteries by reconstruction of serial sections of an autopsy case. *Stroke* **33**(11): 2565-2569.
- Panegyres PK, Zafiris-Toufexis K, Kakulas BA. 2000. Amyloid precursor protein gene isoforms in Alzheimer's disease and other neurodegenerative disorders. *J Neurol Sci* **173**(2): 81-92.
- Roher AE, Weiss N, Kokjohn TA, *et al.* 2002. Increased A beta peptides and reduced cholesterol and myelin proteins characterize white matter degeneration in Alzheimer's disease. *Biochemistry* **41**(37): 11080-11090.
- Roman GC. 1985. The identity of lacunar dementia and Binswanger disease. *Med Hypotheses* **16**(4): 389-391.
- Sjobeck M, Englund E. 2003. Glial levels determine severity of white matter disease in Alzheimer's disease: a neuropathological study of glial changes. *Neuropathol Appl Neurobiol* **29**(2): 159-169.
- Sjobeck M, Haglund M, Persson A, *et al.* 2003. Brain tissue microarrays in dementia research: white matter microvascular pathology in Alzheimer's disease. *Neuropathology* **23**(4): 290-295.
- Tian J, Shi J, Bailey K, *et al.* 2004. Relationships between arteriosclerosis, cerebral amyloid angiopathy and myelin loss from cerebral cortical white matter in Alzheimer's disease. *Neuropathol Appl Neurobiol* **30**(1): 46-56.

Wallin A, Blennow K. 1991. Pathogenetic basis of vascular dementia. *Alzheimer Dis Assoc Disord* **5**(2): 91-102.

Wang SF, Li GW. 2003. Early protective effect of ischemic preconditioning on small intestinal graft in rats. *World J Gastroenterol* **9**(8): 1866-1870.

Decreasing myelin density reflected increasing white matter pathology in Alzheimer's disease
 A neuropathological study
 Martin Sjöbeck, Mattias Haglund and Elisabet Englund

Table 1: Details of the AD-WMD cases

Diagnosis	Neuropathological severity of AD		Cause of death	Age at death	Sex	Brain weight (g)
	Whole brain (a)	Temporo-Hippocampal (b)				
AD-WMD	+	V	Ruptured aortic aneurysm	76	Female	1080
AD-WMD	+	IV	Pneumonia	82	Male	1260
AD-WMD	+	V	Pneumonia	83	Female	No data
AD-WMD	++	IV	Cholangiocarcinoma	86	Male	1460
AD-WMD	+++	VI	Pneumonia	59	Male	1240
AD-WMD	+++	V	Pulmonary embolism	66	Female	1075
AD-WMD	+++	V	Pneumonia	67	Female	1125
AD-WMD	+++	V	Pneumonia	69	Female	1085
AD-WMD	+++	V	Pneumonia	81	Male	1325
AD-WMD	+++	III	Cardiac failure	85	Male	1200
AD-WMD	+++	V	Pneumonia	88	Female	1025
AD-WMD	+++	III-IV	Pulmonary embolism	91	Female	No data
AD-WMD	++++	VI	Pneumonia	85	Female	895
AD-WMD	++++	VI	Pneumonia	90	Female	1140
AD-WMD	+++++	V	Pneumonia	63	Female	No data
AD-WMD	+++++	V	Pneumonia	64	Female	1020

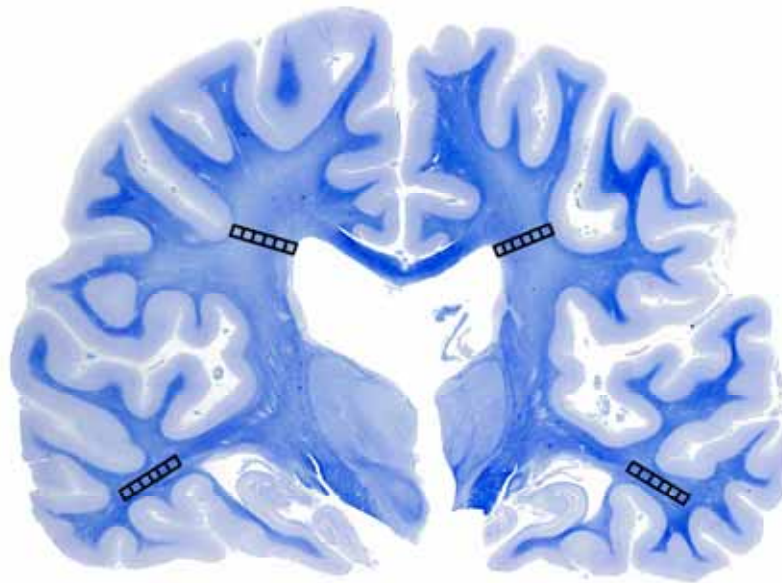
(a) Whole brain Alzheimer encephalopathy - mild, moderate or severe according to Brun and Englund (Brun and Englund, 1981):

+ mild, ++ mild-moderate, +++ moderate, ++++ moderate-severe, +++++ severe.

(b) Temporo-hippocampal Alzheimer encephalopathy of stages I-VI according to Braak and Braak (Braak and Braak, 1991)

Decreasing myelin density reflected increasing white matter pathology in Alzheimer's disease
A neuropathological study
Martin Sjöbeck, Mattias Haglund and Elisabet Englund

Figure 1



An 86-year old male with Alzheimer's disease and white matter disease (WMD). Scanned whole coronal brain section through the frontoparietal and temporal lobes including hippocampus stained with Luxol Fast Blue (LFB). Note the pale staining in the deep white matter indicating myelin loss. The ladder like boxes each represents 6 consecutive areas chosen for the OD measurements. Severity of WMD was evaluated as normal, mild, moderate or severe in corresponding boxes delineated on sections stained with Haematoxylin/Eosin (HE). OD measurements and WMD grading were made bilaterally in each of the frontoparietal and temporal-, parietal- and occipital lobes.

Decreasing myelin density reflected increasing white matter pathology in Alzheimer's disease
 A neuropathological study
 Martin Sjöbeck, Mattias Haglund and Elisabet Englund

Figure 2: Mean and 95% confidence interval (CI) for optical density (OD) values from myelin Luxol Fast Blue stained white matter samples in AD with microscopically evaluated normal white matter and white matter graded as mild-, moderate- and severe white matter disease (WMD) in Haematoxylin/Eosin.

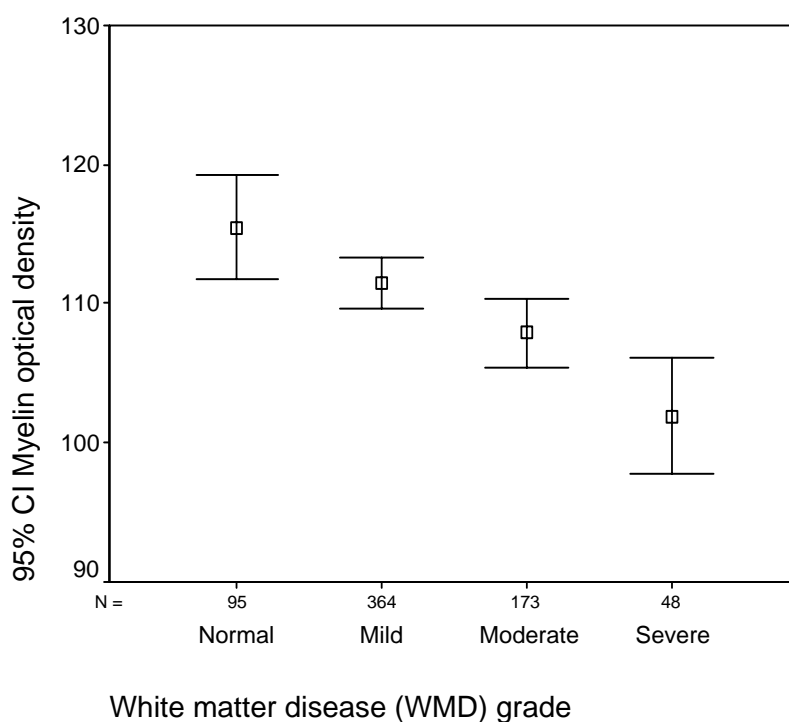


Table 2: Differences in optical density (OD) values from myelin Luxol Fast Blue stained white matter samples in AD between microscopically evaluated normal white matter and white matter graded as mild-, moderate- and severe white matter disease (WMD) in Haematoxylin/Eosin. One-way ANOVA with post-hoc Bonferroni adjustment for multiple comparisons

WMD grade	WMD grade	Mean Difference in OD	Std. Error	Sig.	95% Confidence Interval	
					Lower Bound	Upper Bound
Normal <i>Mean OD 115</i>	Mild	4.01	2.01	0.279	-1.31	9.33
	Moderate	7.56(*)	2.23	0.004	1.67	13.46
	Severe	13.57(*)	3.09	<0.001	5.39	21.75
Mild <i>Mean OD 111</i>	Normal	-4.01	2.01	0.279	-9.33	1.31
	Moderate	3.55	1.61	0.167	-.71	7.82
	Severe	9.56(*)	2.68	0.002	2.47	16.65
Moderate <i>Mean OD 108</i>	Normal	-7.56(*)	2.23	0.004	-13.46	-1.67
	Mild	-3.55	1.61	0.167	-7.82	0.71
	Severe	6.01	2.85	0.211	-1.53	13.54
Severe <i>Mean OD 102</i>	Normal	-13.57(*)	3.09	<0.001	-21.75	-5.39
	Mild	-9.56(*)	2.68	0.002	-16.65	-2.47
	Moderate	-6.01	2.85	0.211	-13.54	1.53

* The mean difference is significant at the .05 level.

Decreasing myelin density reflected increasing white matter pathology in Alzheimer's disease
 A neuropathological study
 Martin Sjöbeck, Mattias Haglund and Elisabet Englund

Table 3: Correlations between optical density (OD) ratios adjusted with corresponding values for normal white matter in frontoparietal, parietal, temporal and occipital white matter and overall cortical AD pathology as well as age. Two-tailed Spearman Rank with Bonferroni adjustment for multiple comparisons

		White matter myelin optical density ratios (b)			
		Frontoparietal / Normal	Parietal / Normal	Temporal / Normal	Occipital / Normal
Overall neuropathological severity of AD (a)	Correlation Coefficient	0.60	-0.02	0.23	0.50
	Sig. (2-tailed)	0.128	>0.99	>0.99	0.428
	N	13	13	14	12
Age at death	Correlation Coefficient	-0.59	-0.02	-0.30	-0.39
	Sig. (2-tailed)	0.132	>0.99	>0.99	0.868
	N	13	13	14	12

(a) Overall Alzheimer encephalopathy mild, mild-moderate, moderate, moderate-severe or severe (Brun and Englund, 1981).

(b) Optical density (OD) ratios for Luxol Fast Blue stained white matter regions calculated as the OD obtained in white matter samples divided by mean OD for normal white matter in the same case, as evaluated in Haematoxylin/Eosin.

Decreasing myelin density reflected increasing white matter pathology in Alzheimer's disease
 A neuropathological study
 Martin Sjöbeck, Mattias Haglund and Elisabet Englund

Figure 3: Optical density (OD) values in corresponding right and left hemisphere in frontoparietal-, parietal- temporal- and occipital white matter regions (two-tailed Spearman Rank, correlation coefficient = 0.79, $p < 0.001$, $n = 56$)

