LUND UNIVERSITY

Development of high-grade lymphoma in Helicobacter pylori-infected C57BL/6mice

Wang, Xin; Willén, Roger; Andersson, Christina; Wadström, Torkel

Published in:
APMIS : acta pathologica, microbiologica, et immunologica Scandinavica

DOI:
10.1034/j.1600-0463.2000.d01-89.x

2000

Link to publication

Citation for published version (APA):
Wang, X., Willén, R., Andersson, C., & Wadström, T. (2000). Development of high-grade lymphoma in Helicobacter pylori-infected C57BL/6mice. *APMIS : acta pathologica, microbiologica, et immunologica Scandinavica*, *108*(7-8), 503-508. https://doi.org/10.1034/j.1600-0463.2000.d01-89.x

Total number of authors:
4

General rights
Unless other specific re-use rights are stated the following general rights apply:
Copyright and moral rights for the publications made accessible in the public portal are retained by the authors and/or other copyright owners and it is a condition of accessing publications that users recognise and abide by the legal requirements associated with these rights.
• Users may download and print one copy of any publication from the public portal for the purpose of private study or research.
• You may not further distribute the material or use it for any profit-making activity or commercial gain
• You may freely distribute the URL identifying the publication in the public portal

Read more about Creative commons licenses: https://creativecommons.org/licenses/

Take down policy
If you believe that this document breaches copyright please contact us providing details, and we will remove access to the work immediately and investigate your claim.

LUND UNIVERSITY

PO Box 117
221 00 Lund
+46 46-222 00 00

Download date: 12. Oct. 2024

APMIS 108: 503–8, 2000
Printed in Denmark . All rights reserved

Copyright © APMIS 2000

APMIS
ISSN 0903-4641

Development of high-grade lymphoma in *Helicobacter pylori*-infected C57BL/6 mice

XIN WANG,[1] ROGER WILLÉN,[2] CHRISTINA ANDERSSON[3] and TORKEL WADSTRÖM[1]

[1]Department of Infectious Diseases & Medical Microbiology, [3]Department of Pathology, University of Lund, Lund and [2]Department of Pathology, Sahlgrenska University Hospital, Gothenburg, Sweden

Wang X, Willén R, Andersson C & Wadström T. Development of high-grade lymphoma in *Helicobacter pylori*-infected C57BL/6 mice. APMIS 2000;108:503–8.

Helicobacter pylori infection is associated with chronic gastritis, peptic ulcer disease, gastric adenocarcinoma and MALT lymphoma. Mice with *H. pylori* infection develop severe gastritis and atrophic changes in their stomachs after 6 months. We followed *H. pylori*-infected animals for 13 months to find out whether dysplasia, carcinoma or lymphoma developed. Six-week-old C57BL/6 mice were infected with the CagA-positive and VacA-positive *H. pylori* mouse-passaged strain 119/95, fed a low antioxidant diet, and kept in microisolated cages. Histopathological changes were examined after 13 months' infection. All *H. pylori*-inoculated mice (n=5) developed a gastric squamous papilloma with nagging of the lamina muscularis after 13 months. Three out of five animals developed high-grade B-cell lymphoma derived from a MALT lymphoma at the squamous-corpus border with manifestations also in the liver, spleen and kidney. There was a suspicion of local gastric lymphoma in the two remaining mice but with no significant changes in the liver, spleen or kidney. The normal control mice showed no pathological changes in any of these organs. It is concluded that this mouse model with infection by the CagA-positive, vac-toxin-producing *H. pylori* strain 119/95 is suitable for use in the study of lymphoma development and also development of squamous cell papilloma with proliferative features.

Key words: Lymphoma; papilloma; *Helicobacter pylori*; C57BL/6 mice.

Torkel Wadström, Department of Infectious Diseases and Medical Microbiology, University of Lund, Sölvegatan 23, S-223 62 Lund, Sweden. e-mail: Torkel.Wadstrom@mmb.lu.se

Helicobacter pylori infection in man is associated with chronic type B gastritis, peptic ulcer disease, MALT (mucosa-associated lymphoid tissue) lymphoma and gastric carcinoma (1, 2). The histopathological features of low-grade primary gastric lymphoma resemble structures of Peyer's patches (1, 3–5). Transformation of low-grade MALT lymphoma to high-grade primary gastric lymphoma is well recognized and often a mixture of both can be found (4, 6, 7). Sometimes only a high-grade primary gastric lymphoma is found and therefore a de novo lymphoma cannot be ruled out (3). The MALT-lymphoma formation and growth is probably antigen driven and it has been suggested that *H. pylori* could serve as such. Neoplastic B cells are not immunoresponsive to *H. pylori* but their proliferation is dependent on cognate help from *H. pylori*-specific T-cells (8–10). B- and T-cells are recruited to the gastric mucosa as part of the complex immune response to *H. pylori*. Conversion to high-grade lymphoma might not require the presence of *H. pylori* (1, 3, 11).

We have previously shown that mice with *H. pylori* infection for 6 months develop severe gastritis and atrophic changes (12). In this study we followed *H. pylori* infection for 13 months in

Received December 22, 1999.
Accepted May 2, 2000.

C57BL/6 mice to elucidate whether malignancy might develop and thus provide us with a suitable model for pathogenesis studies of *H. pylori*-related lymphoma development and treatment studies.

MATERIALS AND METHODS

Bacterial strains

The *H. pylori* mouse-passaged strain 119/95 (a CagA+, VacA+ strain originally isolated from a duodenal ulcer patient at the University Hospital of Lund, Sweden) (13) was grown on GAB-Camp agar supplemented with 10% horse serum and incubated for 48 h at 37°C under microaerophilic conditions (14). The cells were harvested in PBS, centrifuged at 3000 rpm for 10 min, and resuspended in PBS to a final concentration of 10^9 colony-forming units (cfu)/ml.

Animals

Six- to eight-week-old conventional C57BL/6 mice were kept in microisolated cages with a 12-h light-dark cycle and provided with a rat and mouse standard diet no. 2 expanded (B&K Universal Company, Stockholm, Sweden) (15) and water ad libitum. Mice were inoculated with 0.3 ml of *H. pylori* suspension three times at 2-day intervals. After 13 months, mice (n=2 normal control group and n=5 *H. pylori*-inoculated group) were killed using carbon dioxide and blood was drawn by heart puncture. Stomach, jejunum and ileum, colon, liver and kidney were collected for histopathology.

Histopathology and immunohistochemistry

Murine stomach, liver, spleen and kidney tissues were fixed in 10% buffered formalin, embedded in paraffin, and 4 μm sections were prepared, stained with hematoxylin-eosin using standard procedures. A new classification of gastric lymphoma has been published (5, 16) and grading of the lymphoma (grades 0–5) was according to Wotherspoon et al. (16).

Lymphoma tissues were subjected to immunohistopathology with markers for T-cells (CD3) (Cedarlane, dilution 1:20) in an avidin-biotin system as well as antibody against B-cell tissue CD45R (Cedarlane, dilution 1:300). To visualize the presence of intraepithelial lymphocytes the epithelial marker AE1/AE3 (DAKO, dilution 1:100) was used. To show the presence of *H. pylori*, hematoxylin-eosin, Giemsa and immunostaining (anti-Hp, DAKO, dilution 1:20) were used. The density was evaluated according to Dixon et al. (17)

RESULTS

The normal control animal demonstrated a well-developed corpus mucosa with specialized cells and normal foveolar surface (Fig. 1A). The canalis was normal, covered with foveolar cells, and no inflammatory cell reaction was noticed. In the proximal part of the gastric tissue the mucosa was covered by squamous epithelium. In the inflow area of the esophagus into the gastric area, papillomatous-like tissue was seen covered by squamous epithelium. In that area normally a slight increase in lymphoplasmocytic cells was noted in the stroma. Slides from liver, spleen and kidney showed a normal picture without any lymphocytic or abnormal cell infiltration.

Animals infected by *H. pylori* for 13 months demonstrated a completely different feature (Fig. 1 B & C). In the proximal gastric area with a squamous cell surface a profound inflammatory cell reaction was found. The infiltration consisted of highly abnormal lymphocytes and these cells demonstrated rough chromatin, rich mitosis, and uneven nuclear and cell borders; often several nucleoli were noted (Fig. 1I). Lymphoepithelial lesions (LEL) were seen in both the squamous cell populations as well as in the surface and lower part of the gastric mucosa. The lymphoma seems to be derived from MALT-omas with subsequent dedifferentiated lymphomatous parts. It grew diffusely in the squamous covered mucosa, the corpus mucosa, and showed deep infiltration into the ventricular wall. The tumor was also seen growing outside the gastric tissue partly surrounding the esophagus-gastric junction. Local lymph glands were most probably also involved.

Fig. 1. A: Normal mouse gastric mucosa with corpus mucosa and squamous upper part (×5); B: Lymphoma infiltrate in mucosa, submucosa and muscular tissue (×2.5); C: Epithelial proliferation with nagging of lamina muscularis mucosa (×5); D: Lymphoma infiltrate in kidney tissue (×10); E: Lymphoma infiltrate in spleen (×10); F: Lymphoma infiltrate in liver tissue (×10); G: CD45R immunostain for B-lymphocytes positive (×5); H: CD3 immunostain for T-lymphocytes negative (×5); I: Higher magnification of lymphoma cell infiltrate. Mixture of normal lymphocytes and plasmacytoid blastic cells (×100); J: Immunostain for *H. pylori*. Curved bacteria at arrows (×100); K: Giemsa stain for *H. pylori* (arrow) (×60).

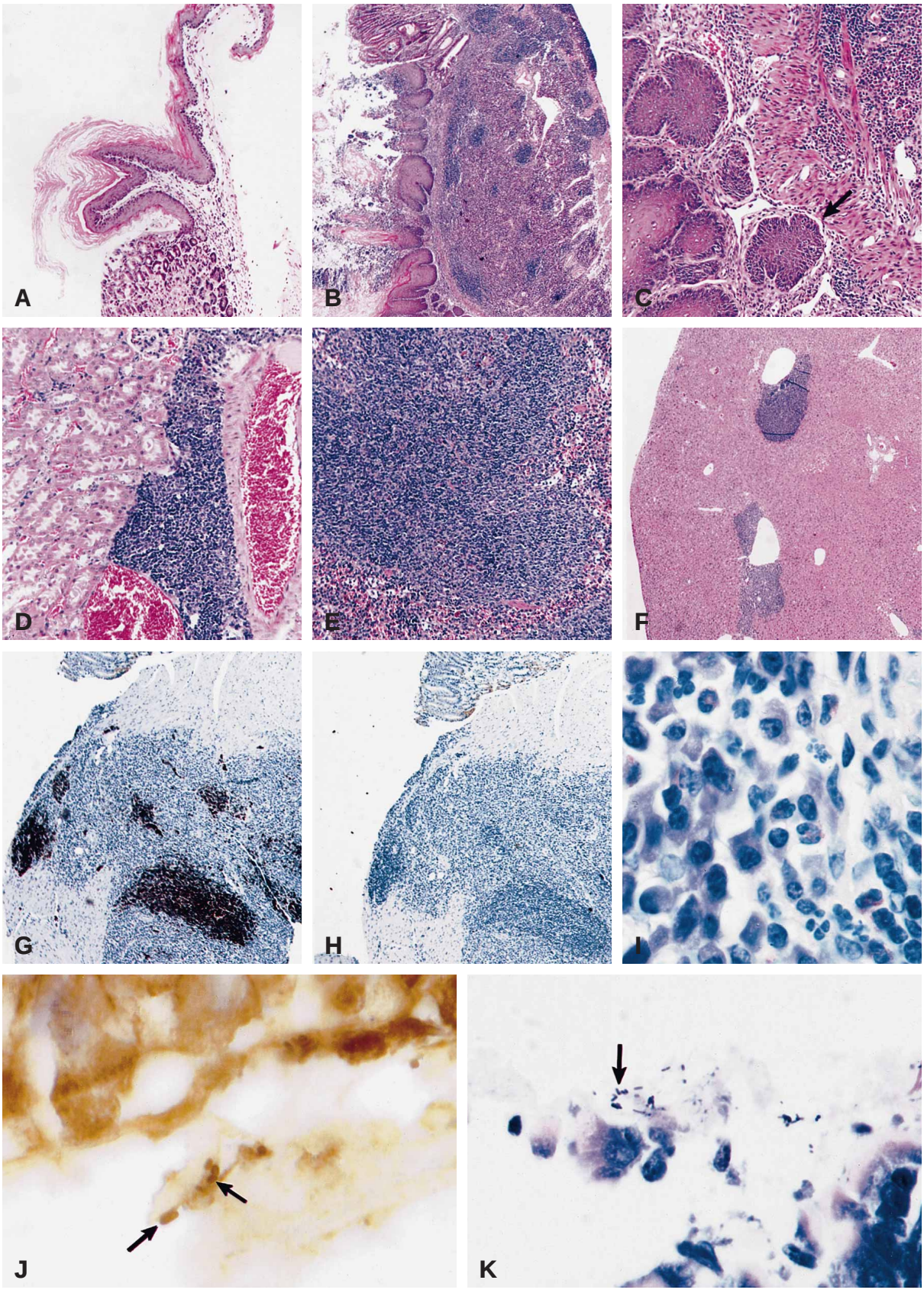
A
B
C
D
E
F
G
H
I
J
K

In the squamous area a squamous papillomatous proliferation was seen with hyper- and parakeratosis, acanthosis and downbulging squamous epithelium. From time to time seemingly free-floating squamous cell areas were noted. These squamous cell areas were seen bulging into the lamina muscularis mucosa but not penetrating it. The cell tissue was mostly indolent and sometimes mitosis was noted. It was thus not clear if we had a squamous papilloma with a tendency to proliferation or a very highly differentiated squamous carcinoma. Infiltrates of lymphoblastic cells were also noted in kidney, spleen and liver (Fig. 1D, E & F). The lymphoma tissue was subjected to immunohistopathology with markers for T-cells (CD3) (Fig. 1H) as well as antibody against B-cell tissue CD45R (Fig. 1G). The reactivity for T-cells was basically negative while reactivity for B-cells was strongly positive. AE1/AE3 for intermediate epithelial filaments helped to demonstrate the presence of LEL. LEL were found in both the squamous as well as in the glandular cells.

Hematoxylin-eosin stain and Giemsa stain for gastric tissue as well as antibodies for *H. pylori* showed a few *H. pylori* in the mucus as well as in some glands (Fig. 1, J & K).

Grading of the lymphomas according to Wotherspoon et al. (16) revealed three cases of grade 5 and two cases of grade 4. No lymphoma (grade 0) was noted in the control group.

DISCUSSION

C57BL/6 mice subjected to *H. pylori* infection for one week and then kept for another 13 months as described previously (13) developed two main changes: squamous papilloma-like structures with growth pattern to some extent mimicking highly differentiated squamous cell carcinoma and blast-like high-grade lymphoma positive for B-cell marker showing highly abnormal cells and mitosis. The tumor cell population destroyed the local mucosa and muscular tissue and was seen growing outside the gastric tissue. Moreover, heavy infiltration of the same cell population in liver, spleen and kidney tissue clearly demonstrated the malignant features of the lymphoma.

H. pylori usually creates a low-grade lymphoma, the so-called MALT lymphoma, in human as well as animal models (8, 18, 19). There are also reports of high-grade lymphoma as well as a mixture of high- and low-grade lymphoma in both human and mouse systems (1, 11, 18). De novo high-grade lymphoma sometimes occurs (1). It is concluded that our mouse model exposed to *H. pylori* strain 119/95, a CagA-positive and vac toxin-producing strain, is another good example of an animal model suitable for studying lymphoma development.

Squamous cell proliferation can also be stimulated in this model at least up to a squamous cell papilloma with proliferative features. In this study we were not able to find manifest infiltrative carcinoma (20), but the pushing borders clearly demonstrated the proliferative capacity of the tumors. It might be argued that an agent other than *H. pylori* in the present setting might be the cause of lymphoma and squamous cell proliferation. However, parallel to this study we had several groups of mice – controls and other long-term food treatment groups – at the same facility during the same time period. None of these animals in the different treatment groups developed a lymphoma or any squamous cell proliferation. It is therefore unlikely that the *H. pylori* does not play any part in the tumor development. There are few animals in this preliminary study due to the fact that these results appeared in one of many groups of animals in a study of different antioxidant treatment in combination with *H. pylori*. This reduces the possibility of a more certain interpretation. Further studies with more animals to determine the value of this animal model are, however, ongoing in our laboratory.

H. pylori can be identified in more than 90% of cases of gastric MALT lymphoma (6, 16). In more advanced cases fewer *H. pylori* are found (21). This suggests that *H. pylori* is more closely associated with the precursor or initial genesis of MALT lymphoma (2). High-grade MALT lymphoma transformation may be more likely to occur following infection with CagA+ strains of *H. pylori* (22). The strain used in this study was both CagA and VacA positive. Grading according to Wotherspoon et al. (16) revealed definite or suspicion of local gastric lymphoma with a B-cell pattern. However, in humans few cases of T-cell lymphoma have been

reported (18, 23). We did not stain for *kappa* or *lambda* chains as monoclonality can also be seen in benign gastric lymphoid infiltration (24). Moreover, more than 95% of immunoglobulins contain *kappa* chains in the normal mouse (19), so it would be difficult to detect minor deviations from that with the present immune technique (2). The mechanisms behind the decrease in *H. pylori* during lymphoma formation in man are uncertain. Mucosal atrophy, intestinal metaplasia and reduction of neutrophils have been suggested. The fact that antibiotic treatment can be successful in the earlier phase of low-grade MALT lymphoma (16), while high-grade and more advanced lymphoma with few *H. pylori* are usually non-responders, may be attributed to a sequence of molecular events (1, 4, 25, 26). Immunological drive with *H. pylori*-specific T cells is diminished with lack of *H. pylori* bacteria (11). More advanced molecular events beyond trisomy 3, translocation 1;14 and changes of *p*53 mutant detection, seem to be a process no longer *H. pylori* dependent (1, 21, 26). Thus, no further clinical effect of antibiotics is to be expected.

In our study using hematoxylin-eosin, Giemsa and specific *H. pylori* immunostaining no bacteria were found in the control group while in the treatment group a few *H. pylori*-like bacteria were seen.

In order to further evaluate the molecular events, genetics and treatment regimen attempts it is of value to have a model system which is easy to handle. Lymphoma development occurred over a shorter time period in this model than in earlier published studies (11, 19).

Spontaneous lymphomas are known to appear in aged mice (27): average incidence after 20 months in Balb/c mice is 16%. Enno et al. (19) reported equal numbers of malignant lymphoma in test and control groups in the spleen, but gastric MALT-omas were only observed in *Helicobacter*-infected animals. In an extended study (11) gastric lymphomas were also seen, but these were not of a MALT type. Our animals were not old and other groups of animals kept for the same period of time did not demonstrate lymphomatous changes. Only the *H. pylori*-treated group showed lymphomatous changes, which speaks in favor of an *H. pylori*-related cause of lymphoma development.

H. pylori can be found in combination with gastric carcinoma (25). Coexisting adenocarcinoma and lymphoma have been reported; in this study we found high-grade B-cell lymphoma derived from MALT lesions together with highly proliferative squamous cells with a papillomatous structure and expanding borders, though with no definite carcinoma. Whether this model will also be suitable for studying the carcinoma development remains to be elucidated.

This work was supported by grants from the Swedish Medical Research Council (16X04723), Swedish Forestry Agriculture Research Council (50.0497/98), Kungliga fysiografiska sällskapet in Lund, John and Augusta Perssons Foundation in Lund, the Medical Faculty, Lund University, and AstaCarotene AB, Gustavsberg, Sweden,
We would like to thank Ulric Pedersen for the skilled photography.

REFERENCES

1. Isaacson PG. Recent developments in our understanding of gastric lymphomas. Am J Surg Pathol 1996;20:S1–7.
2. Nakamura S, Aoyagi K, Furuse M, Suekane H, Matsumoto T, Yao T, et al. B-cell monoclonality precedes the development of gastric MALT lymphoma in *Helicobacter pylori*-associated chronic gastritis. Am J Pathol 1998;152:1271–9.
3. Bouzourene H, Haefliger T, Delacretaz F, Saraga E. The role of *Helicobacter pylori* in primary gastric MALT lymphoma. Histopathology 1999;34: 118–23.
4. De Wolf-Peeters C, Achten R. The histogenesis of large-cell gastric lymphomas. Histopathology 1999;34:71–5.
5. Hsi ED, Eisbruch A, Greenson JK, Singleton TP, Ross CW, Schnitzer B. Classification of primary gastric lymphomas according to histologic features. Am J Surg Pathol 1998;22:17–27.
6. Chan JK, Ng CS, Isaacson PG. Relationship between high-grade lymphoma and low-grade B-cell mucosa-associated lymphoid tissue lymphoma (MALToma) of the stomach. Am J Pathol 1990;136:1153–64.
7. Matolcsy A, Nagy M, Kisfaludy N, Kelenyi G. Distinct clonal origin of low-grade MALT-type and high-grade lesions of a multifocal gastric lymphoma. Histopathology 1999;34:6–8.
8. Hussell T, Isaacson PG, Crabtree JE, Spencer J. The response of cells from low-grade B-cell gastric lymphomas of mucosa-associated lymphoid tissue to *Helicobacter pylori*. Lancet 1993,342: 571–4.
9. Hussell T, Isaacson PG, Crabtree JE, Dogan A,

Spencer J. Immunoglobulin specificity of low grade B cell gastrointestinal lymphoma of mucosa-associated lymphoid tissue (MALT) type. Am J Pathol 1993;142:285–92.
10. Hussell T, Isaacson PG, Crabtree JE, Spencer J. *Helicobacter pylori*-specific tumour-infiltrating T cells provide contact dependent help for the growth of malignant B cells in low-grade gastric lymphoma of mucosa-associated lymphoid tissue. J Pathol 1996;178:122–7.
11. Enno A, O'Rourke J, Braye S, Howlett R, Lee A. Antigen-dependent progression of mucosa-associated lymphoid tissue (MALT)-type lymphoma in the stomach. Effects of antimicrobial therapy on gastric MALT lymphoma in mice. Am J Pathol 1998;152:1625–32.
12. Wang X, Willén R, Wadström T. Gastric dysplasia due to *H. pylori* infection and carcinogenic substances in mice. Gut (Suppl) 1998;43:A69.
13. Wang X, Willén R, Wadström T, Aleljung P. RAPD-PCR, histopathological and serological analyis of four mouse strains infected with multiple strains of *Helicobacter pylori*. Microbial Ecol Health Dis 1998;10:148–54.
14. Wang X, Sturegard E, Rupar R, Nilsson HO, Aleljung PA, Carlén B, et al. Infection of BALB/c A mice by spiral and coccoid forms of *Helicobacter pylori*. J Med Microbiol 1997;46:657–63.
15. Wang X, Sjunnesson H, Sturegard E, Wadström T, Willén R, Aleljung P. Dietary factors influence the recovery rates of *Helicobacter pylori* in a BALB/c A mouce model. Zentralbl Bakteriol 1998;288:195–205.
16. Wotherspoon AC, Doglioni C, Diss TC, Pan L, Moschini A, de Boni M, et al. Regression of primary low-grade B-cell gastric lymphoma of mucosa-associated lymphoid tissue type after eradication of *Helicobacter pylori*. Lancet 1993;342:575–7.
17. Dixon MF, Genta RM, Yardley JH, Correa P. Classification and grading of gastritis. The updated Sydney System. International Workshop on the Histopathology of Gastritis, Houston 1994. Am J Surg Pathol 1996;20:1161–81.
18. Isaacson PG. Gastrointestinal lymphoma. Hum Pathol 1994;25.1020–9.
19. Enno A, O'Rourke JL, Howlett CR, Jack A, Dixon MF, Lee A. MALToma-like lesions in the murine gastric mucosa after long-term infection with helicobacter felis. A mouse model of *Helicobacter pylori*-induced gastric lymphoma. Am J Pathol 1995;147:217–22.
20. Rokkas T, Wotherspoon A. Carcinogenesis. Curr Opin Gastroenterol 1999;15(Suppl 1):S23–8.
21. Dayal Y. Introduction. Am J Surg Pathol 1996;20(Suppl 1):iv–vi.
22. Peng H, Ranaldi R, Diss TC, Isaacson PG, Bearzi I, Pan L. High frequency of CagA+ *Helicobacter pylori* infection in high-grade gastric MALT B-cell lymphomas. J Pathol 1998;185:409–12.
23. Foss HD, Schmitt-Graff A, Daum S, Anagnostopoulos I, Assaf C, Hummel M, et al. Origin of primary gastric T-cell lymphomas from intraepithelial T-lymphocytes report of two cases. Histopathology 1999;34:9–15.
24. Savio A, Franzin G, Wotherspoon AC, Zamboni G, Negrini R, Buffoli F, et al. Diagnosis and posttreatment follow-up of *Helicobacter pylori*-positive gastric lymphoma of mucosa-associated lymphoid tissue: histology, polymerase chain reaction, or both? Blood 1996;87:1255–60.
25. Eidt S, Stolte M. The significance of *Helicobacter pylori* in relation to gastric cancer and lymphoma. Eur J Gastroenterol Hepatol 1995;7:318–21.
26. Du M, Peng H, Singh N, Isaacson PG, Pan L. The accumulation of *p*53 abnormalities is associated with progression of mucosa-associated lymphoid tissue lymphoma. Blood 1995;86:4587–92.
27. Dunn TB, Deringer MK. Reticulum cell neoplasm, type B, or the "Hodgkin's-like lesion" of the mouse. J Natl Cancer Inst 1968;40:771–821.