



# LUND UNIVERSITY

## **The relationship between electrical axis by 12-lead electrocardiogram and anatomical axis of the heart by cardiac magnetic resonance in healthy subjects.**

Engblom, Henrik; Foster, John E; Martin, Thomas N; Groenning, Bjoern; Pahlm, Olle; Dargie, Henry J; Wagner, Galen S; Arheden, Håkan

*Published in:*  
American Heart Journal

*DOI:*  
[10.1016/j.ahj.2004.10.041](https://doi.org/10.1016/j.ahj.2004.10.041)

2005

[Link to publication](#)

### *Citation for published version (APA):*

Engblom, H., Foster, J. E., Martin, T. N., Groenning, B., Pahlm, O., Dargie, H. J., Wagner, G. S., & Arheden, H. (2005). The relationship between electrical axis by 12-lead electrocardiogram and anatomical axis of the heart by cardiac magnetic resonance in healthy subjects. *American Heart Journal*, 150(3), 507-512.  
<https://doi.org/10.1016/j.ahj.2004.10.041>

*Total number of authors:*  
8

### **General rights**

Unless other specific re-use rights are stated the following general rights apply:

Copyright and moral rights for the publications made accessible in the public portal are retained by the authors and/or other copyright owners and it is a condition of accessing publications that users recognise and abide by the legal requirements associated with these rights.

- Users may download and print one copy of any publication from the public portal for the purpose of private study or research.
- You may not further distribute the material or use it for any profit-making activity or commercial gain
- You may freely distribute the URL identifying the publication in the public portal

Read more about Creative commons licenses: <https://creativecommons.org/licenses/>

### **Take down policy**

If you believe that this document breaches copyright please contact us providing details, and we will remove access to the work immediately and investigate your claim.

LUND UNIVERSITY

PO Box 117  
221 00 Lund  
+46 46-222 00 00

The following pages constitute the final, accepted and revised manuscript of the article:

Engblom, Henrik and Foster, John E and Martin, Thomas N and Groenning, Bjoern and Pahlm, Olle and Dargie, Henry J and Wagner, Galen S and Arheden, Håkan

“The relationship between electrical axis by 12-lead electrocardiogram and anatomical axis of the heart by cardiac magnetic resonance in healthy subjects”

Am Heart J. 2005 Sep;150(3):507-12.

Publisher: Elsevier.

Use of alternative location to go to the published version of the article requires journal subscription.

Alternative location: <http://dx.doi.org/10.1016/j.ahj.2004.10.041>

Section: Clinical investigations

**The Relationship between Electrical Axis by 12-Lead ECG and Anatomical Axis of the  
Heart by CMR in Healthy Subjects**

Short title: Electrical vs anatomical heart axis

Henrik Engblom<sup>1</sup>, MD, John E. Foster<sup>2</sup>, PhD, Thomas N. Martin<sup>2</sup>, MD, Bjoern Groenning<sup>2</sup>,  
MD, Olle Pahlm<sup>1</sup>, MD, PhD, Henry J. Dargie<sup>2</sup>, MD, PhD, Galen S. Wagner<sup>3</sup>, MD, Håkan  
Arheden<sup>1</sup>, MD, PhD

<sup>1</sup>Department of Clinical Physiology, Lund University Hospital, Sweden, <sup>2</sup>Glasgow Cardiac  
Magnetic Resonance Unit, Glasgow, Lanarkshire, UK, <sup>3</sup>Duke University Medical Center,  
Durham, NC

Financial support: Swedish Medical Research Council; Swedish Heart Lung Foundation;  
British Heart Foundation; The Medical Faculty, Lund University

Address for correspondence:  
Håkan Arheden, MD, PhD  
Dept. of Clinical Physiology  
Lund University Hospital  
S-221 85 Lund, Sweden  
Tel: +46 46 173328  
Fax: +46 46 151769  
E-mail: hakan.arheden@klinfys.lu.se

## ABSTRACT

**Background:** The traditional assumption has been that there is a close relationship between the electrical and anatomical axes of the heart. The aim of this study was to test the hypothesis that there is a correlation between the electrical and anatomical axes of the heart, in both the frontal and transverse planes, in healthy subjects.

**Methods:** Ninety-four healthy volunteers (48 males, 46 females; age, 21-82 years) were studied by cardiac magnetic resonance (CMR) and 12-lead ECG. The anatomical axis was determined by CMR and projected onto the frontal and transverse orthogonal planes for comparison with the electrical axis in the corresponding planes.

**Results:** The electrical and anatomical axes were in the same range in the frontal plane ( $+39 \pm 31^\circ$  and  $+38 \pm 10^\circ$ , mean  $\pm$  SD), but in different ranges in the transverse plane ( $-30 \pm 18^\circ$  and  $+46 \pm 7^\circ$ , mean  $\pm$  SD). The partial correlation coefficients between electrical and anatomical axes was  $r = 0.30$  ( $p < 0.01$ ) and  $r = 0.14$  ( $p = \text{NS}$ ) in the frontal and transverse planes, respectively. Age was more strongly correlated to electrical axis than to anatomical axis in the frontal plane.

**Conclusions:** There is only a weak correlation between electrical and anatomical axes in the frontal plane and no correlation in the transverse plane. The change of electrical axis with increased age is not explained only by change in the anatomical axis. The results suggest that there is no simple relationship between the electrical and anatomical axes of the heart.

**Keywords:** electrocardiography, magnetic resonance imaging, left ventricle, electrical axis

## INTRODUCTION

The traditional assumption has been that there is a close relationship between the electrical axis and anatomical orientation of the heart (1-6). Wilson *et al* (7) described five positions of the heart on the basis of ECG appearances. These were horizontal, semihorizontal, intermediate, semivertical, and vertical. Furthermore, several studies have reported that body habitus and age affect the electrical axis in the frontal plane, assuming that change in position and orientation of the heart would be part of the explanation (8-12). However, to which extent the change in electrical axis depends on change in heart orientation has, to date, been difficult to test due to deficiencies in gold standards for *in vivo* measurements of heart orientation.

Cardiac magnetic resonance (CMR) has shown ability to depict cardiac anatomy in great detail (13). Direct visualization of cardiac landmarks enables determination of the left ventricular (LV) long axis spatial direction, referred to as the anatomical axis of the heart (14). CMR has earlier been used to study the relationship between position of the heart and ECG findings (15,16). However, the correlation between electrical axis by 12-lead ECG and anatomical axis by CMR has not yet been studied. Documentation of a close relationship between electrical and anatomical axes could provide a basis for use of the anatomical axis to adjust lead specific ECG criteria.

The purpose of the present study was to test the hypothesis that there is a correlation between electrical and anatomical axes of the heart in the frontal and transverse plane, respectively, and to examine the impact of body mass index and age on the electrical and anatomical axes in healthy subjects.

## METHODS

### Participants and study design

The prospectively recruited study population consisted of 94 participants (characterized in table 1) of which 77 were healthy volunteers from the local community in Lund, Sweden, and 17 were participants with no cardiac disease from the Western Infirmary Hospital, Glasgow, UK. To be eligible for this study they had to have no previous history of cardiovascular disease, normal ECG (no signs of conduction abnormalities or ischemic heart disease), normal blood pressure (SBP  $\leq$  140 mmHg and DBP  $\leq$  90). Exclusion criteria comprised generally accepted contraindications for CMR (metal implants, cerebral aneurysm clips, claustrophobia) and abnormal global or local LV function by CMR.

CMR was performed upon inclusion and ECGs were recorded on the same day. The analysis of the ECGs was undertaken by two independent observers, blinded to all other results. Discrepancies were agreed on in conference for the purpose of comparison with the corresponding anatomical axis by CMR. The observers performing the CMR analysis were blinded to the ECG results. The investigation protocol and procedures were approved by the local ethics committees at Lund University and Western Infirmary Hospitals and all participants gave their written informed consent to participate in the study.

### Cardiac magnetic resonance imaging and analysis

CMR was performed on commercially available 1.5 T scanners (Siemens Vision or Sonata, Siemens Medical Solutions, Erlangen, Germany) using phased array chest coils. All participants were imaged in supine position. LV dimensions were evaluated by cine short axis images acquired in end-expiratory breath-hold. Imaging was performed using either a turbo fast low angle shot (FLASH) sequence: slice thickness 10 mm, field of view 380 mm, matrix

126x256, TR 100 ms (echo sharing resulting in phases every 50 ms), TE 4.8 ms; or a true fast imaging with steady-state free precession (FISP) sequence: slice thickness 8 mm, field of view 340 mm, TR 3.14 ms, TE 1.58 ms. Images were acquired from the base of the LV (atrioventricular valve plane) to the apex. The procedure used in the study for identifying the imaging planes has previously been described (17) and is used in clinical routine at both hospitals (Fig 1).

The anatomical axis of the heart was determined from an end-diastolic MR long axis image and defined as a vector starting at the center of the mitral annulus and projecting through the LV (Fig 1D). The projection of the anatomical axis onto the frontal and transverse orthogonal planes was obtained using either a recently published method for determining the anatomical axis of the heart (14) or an off-line software package (CMRtools, Imperial College, London, UK). Trigonometry was applied to express the anatomical axis in the same hexaxial reference system used for describing the electrical axis (Fig 2). The angle was defined as 0° to the patient's left and increasing in clockwise direction when observed from the patient's front (frontal plane) and counterclockwise when observed from the patient's feet (transverse plane). Angle precision and software reliability for CMR measures of anatomical axis of the heart has previously been validated in healthy subjects (14).

### **Electrocardiographic recording and analysis**

A standard 12-lead ECG was recorded at the time of the MR examination using either a MEGACART-R (Siemens-Elema AB, Solna, Sweden) or a Pagewriter XLi (Philips Medical Systems, Andover, MA). The frequency response was set at the range of 0.05-150Hz and the sampling rate was 500 Hz.

The frontal leads were assumed to be separated by 30° based on Einthoven's triangle in the frontal plane (Fig 2A) (18,19). This assumption is clinically established and used for teaching

purposes although Einthoven's triangle is only a special case of Burger's triangle which takes into consideration that the human body is a three-dimensional volume conductor (20-22). A similar method for determination of the electrical axis in the transverse plane was used, assuming that the chest leads in the transverse plane are separated by approximately 30°. It is accepted that leads V<sub>2</sub> and V<sub>5</sub> are approximately orthogonal (23). Lead V<sub>1</sub> was considered to be 30° to the right of V<sub>2</sub>, leads V<sub>3</sub> and V<sub>4</sub> equally spaced between V<sub>2</sub> and V<sub>5</sub>, and V<sub>6</sub> 30° posterior to V<sub>5</sub> (Fig 2B). The following method was then applied for both planes. The transitional lead (in which the QRS complex had most nearly equal positive and negative components) was located for the limb leads and for the chest leads, respectively. The angular value of the lead, perpendicular to the transitional lead (using the hexaxial reference system) in the direction in which the positive QRS components increased, was defined as the electrical axis. The electrical axis designation was rounded to the nearest 15°.

### **Statistical analysis**

All measurements are expressed as mean  $\pm$  SD. The strength of the relation between the electrical and anatomical axes was assessed by Pearson correlation coefficients. To correct for observations in the frontal plane, partial correlation coefficients were calculated controlling for observations in the transverse plane. The corresponding analysis was performed in the transverse plane controlling for observations in the frontal plane. Pearson correlation coefficients were also used for assessing the impact of BMI and age on the electrical and anatomical axes. For all tests,  $p < 0.05$  was considered statistically significant. All statistical analyses were done with SPSS (release 11.0.1).



## RESULTS

### Ranges of electrical and anatomical axes

Figure 2 shows the distribution of electrical and anatomical axes in the frontal and transverse planes, respectively. In the frontal plane the electrical and anatomical axes measured  $+38 \pm 10^\circ$  (range 16-66°) and  $+39 \pm 31^\circ$  (range -30-90°), respectively. The measurements in the transverse plane were  $+46 \pm 7^\circ$  (range 29-70°) and  $-30 \pm 18^\circ$  (range -75-15°), respectively. Thus, the electrical and anatomical axes were generally within the same range in the frontal plane, but in different ranges in the transverse plane.

The difference between the 2 observers performing the ECG analysis was  $1 \pm 6^\circ$ . For the 2 observers performing the CMR analysis the difference was  $2 \pm 2^\circ$ .

### Correlation between electrical and anatomical axes

The correlations between the electrical and anatomical axes in both the frontal and transverse planes are presented in Figure 3. In the frontal plane the partial correlation coefficient between the electrical and anatomical axes was  $r = 0.30$  ( $p = 0.004$ ), when controlling for observations in the transverse plane. However, in the transverse plane no statistically significant partial correlation was found ( $r = 0.14$ ,  $p = 0.18$ ), when controlling for observations in the frontal plane.

### Variation in electrical and anatomical axes due to BMI and age

BMI and age were both shown to affect the electrical and anatomical axes (Table 2).

Electrical axis was more strongly correlated to age ( $r = -0.37$ ,  $p < 0.001$ ) than was anatomical axis ( $r = -0.28$ ,  $p = 0.007$ ) in the frontal plane (Fig 4). Neither BMI nor age showed a

statistically significant correlation to the electrical axis in the transverse plane. No relationship between BMI and age was found ( $r = 0.02$ ,  $p = 0.84$ ).

## DISCUSSION

In the present study, as opposed to earlier studies, only a weak correlation between the electrical and anatomical axes was found in the frontal plane, and no statistically significant correlation was found in the transverse plane. Furthermore, the electrical and anatomical axes were found to be in the same range in the frontal plane, but not in the transverse plane. BMI and age were found to affect the anatomical axis in both planes, but the electrical axis only in the frontal plane. Age was more strongly related to the electrical axis than the anatomical axis in the frontal plane.

The present study showed a weaker relationship between the electrical and anatomical axes of the heart than reported in earlier studies (2,5,6,10,24) using chest x-ray to determine the anatomical axis. Given the ability of CMR to image the heart in relation to its long axis it can be assumed that CMR gives a more accurate description of the anatomical axis of the heart than chest x-ray. More recently, van Oosterom *et al* (16) used CMR to show that a significant amount of the interindividual variability in the normal ECG is due to geometrical factors of the torso and suggested that ECG electrodes be placed in relation to the heart rather than to intercostal spaces. However, Hoekema *et al* (15) have shown that the interindividual variability of the normal ECG is not reduced by merely shifting the electrodes to a position relative to the position of the heart, rather than the conventional intercostal spaces. The findings in the present study support their findings, suggesting that the relationship between electrical and anatomical axes is not as simple as previously described.

The results in the present study are also in agreement with earlier studies demonstrating that BMI and age affect the electrical axis (8-10).

Different physiological and pathophysiological conditions such as pregnancy, (11) obesity, (12) and pulmonary emphysema (25,26) have been shown to affect the QRS complex,

indirectly suggesting that there could be a relationship between the electrical and anatomical axes. However, only a weak relationship was found in the present study. An explanation for the great variability in the electrical axis in relation to the anatomical axis of the heart may be a great interindividual variability in how the Purkinje network of the heart is organized. It has been shown that there is a considerable variation in the architecture of the distal conduction system (27). Furthermore, the stronger age-dependence of electrical axis than of anatomical axis found in the frontal plane in present study, might partly be explained by increased fibrosis and fatty infiltration in the conduction system with increased age (28).

Previous studies (3,5,6,16,24) have reported that LV rotation affects the transitional zone, especially in the transverse plane. The definition of LV rotation in the literature varies. Some authors have defined LV rotation as the angle of LV direction in the transverse plane (3,6) and others as the rotation of the LV around its long axis (5,16,24). The LV rotation around its long axis was not taken into consideration in the present study and might partly explain why no relationship between electrical and anatomical axes was found in the transverse plane.

In the present study the electrical axis, resulting from the QRS complex, was correlated to LV spatial direction. A limitation to this approach may be that the right ventricle (RV) was not considered for the anatomical axis, whereas the QRS complex reflects the activation of both ventricles. However, in subjects with no cardiac disease, the QRS complex is assumed to mainly reflect the activation of the LV due to its considerably larger mass (29). Yet, when the RV hypertrophies, this assumption cannot be made. In RV hypertrophy the mean electrical axis moves rightward in the frontal plane, the R-wave amplitude in lead  $V_1$  increases and the S-wave amplitudes in leads  $V_5$  and  $V_6$  decrease, thus reflecting the increased influence of the RV on the mean electrical axis (30-32). In the present study, the influence of the RV may likely be negligible since no participant had any sign of RV hypertrophy by ECG or CMR.

## **CONCLUSIONS**

This study has shown that there is no simple relationship between electrical and anatomical axes of the heart when the electrical axis is determined by 12-lead ECG. The change of electrical axis with increased age is not explained only by change in the anatomical axis.

## REFERENCES

1. Grant R. The relationship between the anatomic position of the heart and the electrocardiogram. A criticism of "unipolar" electrocardiography. *Circulation*. 1953;7:890-902.
2. Hyman A, Failey R, Ashman R. Can the longitudinal anatomical axis of the ventricles be estimated from the electrocardiogram? *Am Heart J*. 1948;36:906-910.
3. Ashman R, Gardberg M, Byer E. The normal human ventricular gradient. III. The relation between the anatomic and electrical axes. *Am Heart J*. 1943;26:473-494.
4. Meek W, Wilson A. The effect of changes in position of the heart on the QRS complex of the electrocardiogram. *Arch Int Med*. 1925;36:614-627.
5. Fowler N, Braunstein J. Anatomic and electrocardiographic position of the heart. *Circulation*. 1951;3:906-910.
6. Dougherty JD. The relation of the frontal QRS axis to the anatomic position of the heart. *J Electrocardiol*. 1970;3:267-84.
7. Wilson FN, Johnston FD, Rosenbaum FF, et al. The precordial electrocardiogram. *Am Heart J*. 1944;27:19-85.
8. Simonson E, Keys A. The effect of age and body weight on the electrocardiogram of healthy men. *Circulation*. 1952;6:749-761.
9. Luskin A, Whipple G. Effects of age and habitus upon the mean electrical axis of the electrocardiogram in normal males. *Ann Intern Med*. 1961;55:610-619.
10. Dougherty JD, Stoudt HW. The relation of frontal QRS axis to age and body build. *J Electrocardiol*. 1970;3:285-98.
11. Schwartz DB, Schamroth L. The effect of pregnancy on the frontal plane QRS axis. *J Electrocardiol*. 1979;12:279-81.

12. Zack PM, Wiens RD, Kennedy HL. Left-axis deviation and adiposity: the United States Health and Nutrition Examination Survey. *Am J Cardiol.* 1984;53:1129-34.
13. Higgins CB, Byrd BF, 2nd, McNamara MT, et al. Magnetic resonance imaging of the heart: a review of the experience in 172 subjects. *Radiology.* 1985;155:671-9.
14. Engblom H, Hedström E, Palmer J, et al. Determination of the Left Ventricular Long-Axis Orientation from a Single Short-axis MR Image: Relation to BMI and Age. *Clin Physiol Funct Imaging* (In press).
15. Hoekema R, Uijen GJ, van Erning L, et al. Interindividual variability of multilead electrocardiographic recordings: influence of heart position. *J Electrocardiol.* 1999;32:137-48.
16. van Oosterom A, Hoekema R, Uijen GJ. Geometrical factors affecting the interindividual variability of the ECG and the VCG. *J Electrocardiol.* 2000;33 Suppl:219-27.
17. Pennell DJ. Ventricular volume and mass by CMR. *J Cardiovasc Magn Reson.* 2002;4:507-13.
18. Einthoven W. The different forms of the human electrocardiogram and their signification. *Lancet.* 1912;1:853-61 (Reprint: *Am Heart J* 1950; 40: 195-211).
19. Einthoven W, Fahr G, de Waart A. Über die Richtung und die manifeste Grösse der Potentialschwankungen im menschlichen Herzen und über den Einfluss der Herzlage auf die Form des Elektrokardiogramms. *Pfluegers Arch Ges Physiol.* 1913;150:275-315 (Translation: *Am Heart J* 1950; 40: 163-94).
20. Burger H, van Milaan J. Heart-vector and leads. Part I. *Br Heart J.* 1946;8:157-61.
21. Burger H, van Milaan J. Heart-vector and leads. Part II. *Br Heart J.* 1947;9:154-60.
22. Burger H, van Milaan J. Heart-vector and leads. Part III. *Br Heart J.* 1948;10:229-33.

23. Weyne AE, De Buyzere ML, Bauwens FR, et al. Assessment of myocardial ischemia by 12-lead electrocardiography and Frank vector system during coronary angioplasty: value of a new orthogonal lead system for quantitative ST segment monitoring. *J Am Coll Cardiol.* 1991;18:1704-10.
24. Dougherty JD. Change in the frontal QRS axis with changes in the anatomic positions of the heart. *J Electrocardiol.* 1970;3:299-308.
25. Littman D. The electrocardiographic findings in pulmonary emphysema. *Am J Cardiol.* 1960;5:339-348.
26. Selvester RH, Rubin HB. New criteria for the electrocardiographic diagnosis of emphysema and cor pulmonale. *Am Heart J.* 1965:437-447.
27. Massing GK, James TN. Anatomical configuration of the His bundle and bundle branches in the human heart. *Circulation.* 1976;53:609-21.
28. Michaud K, Romain N, Taroni F, et al. Evaluation of a simplified method of the conduction system analysis in 110 forensic cases. *Forensic Sci Int.* 2002;130:13-24.
29. Barr R. Genesis of the electrocardiogram. In: Macfarlane P, Lawrie T, eds. *Comprehensive electrocardiology: Theory and practice in health and disease.* 1st ed. Oxford: Pergamon press; 1989. p.140-42.
30. Sokolow M, Lyon TP. The ventricular complex in right ventricular hypertrophy as obtained by unipolar precordial and limb leads. *Am Heart J.* 1949;38:273-294.
31. Butler PM, Leggett SI, Howe CM, et al. Identification of electrocardiographic criteria for diagnosis of right ventricular hypertrophy due to mitral stenosis. *Am J Cardiol.* 1986;57:639-43.
32. Mazzoleni A, Wolff R, Wolff L, et al. Correlation between component cardiac weights and electrocardiographic patterns in 185 cases. *Circulation.* 1964;30:808-829.



## FIGURE LEGENDS

### Figure 1

Magnetic resonance images demonstrating the standard procedure for identifying imaging planes in relation to the long axis of the heart. **A)** Coronal scout image for positioning of the transverse image (line). **B)** Transverse image upon which the vertical long axis (VLA) was positioned (line). **C)** VLA image used to obtain the horizontal long axis (HLA) perpendicular to the atrioventricular plane. **D)** The end-diastolic phase of an end-expiratory breath-hold HLA cine image upon which the short-axis images were carefully positioned parallel to the atrioventricular plane. This HLA image was also used to obtain the anatomical axis (defining the vector through the center of the mitral annulus and the left ventricular apex) identified by 2 sets of three-dimensional coordinates ( $X_1;Y_1;Z_1$  and  $X_2;Y_2;Z_2$ ).

### Figure 2

Ranges of electrical and anatomical axes of the heart in the frontal (**A**) and transverse planes (**B**), respectively. Angular values of the ECG leads in the hexaxial reference system are shown for both planes.

### Figure 3

The relationship between the electrical and anatomical axes of the heart in the frontal (**A**) and transverse (**B**) planes, respectively.

### Figure 4

The relationship between age and both electrical (**A**) and anatomical (**B**) axes of the heart in the frontal plane.

Table 1: Demographic and anthropometric characteristics of the participants

<b>Demographic</b>							All
	n=15	n=19	n=18	n=20	n=11	n=11	n=94
Age (years)	20-29	30-39	40-49	50-59	60-69	70-	21-82
Male/female*	8/7	9/10	8/10	11/9	8/3	4/7	48/46
<b>Anthropometric</b>							
SBP (mmHg)	119 ± 7	120 ± 13	118 ± 11	122 ± 11	130 ± 10	135 ± 8	123 ± 12
DBP (mmHg)	70 ± 6	74 ± 9	72 ± 9	76 ± 8	75 ± 7	75 ± 8	74 ± 8
HF (beats/min)	63 ± 12	64 ± 14	65 ± 13	65 ± 12	69 ± 8	66 ± 15	65 ± 12
BMI	24 ± 3	25 ± 4	26 ± 3	23 ± 3	25 ± 3	25 ± 5	25 ± 4
LV mass (gram)	172 ± 34	156 ± 39	151 ± 43	145 ± 35	159 ± 41	131 ± 32	152 ± 39

Data are presented as mean ± SD. SBP=systolic blood pressure. DBP=diastolic blood pressure. HF=heart rate. BMI=body mass index. LV=left ventricle. \* number of participants

Table 2: The impact of body mass index and age on electrical and anatomical axes of the heart  
in the frontal and transverse planes (Pearson's correlation coefficients)

	Anatomical axis		Electrical axis	
	Frontal	Transverse	Frontal	Transverse
Body mass index	-0.36 <sup>‡</sup>	0.25*	-0.35 <sup>†</sup>	-0,03 NS
Age	-0.28 <sup>†</sup>	0.23*	-0.37 <sup>‡</sup>	0.05 NS

NS = non-significant. \*  $p < 0.05$ ; <sup>†</sup>  $p < 0.01$ ; <sup>‡</sup>  $p < 0.001$

Figure 1

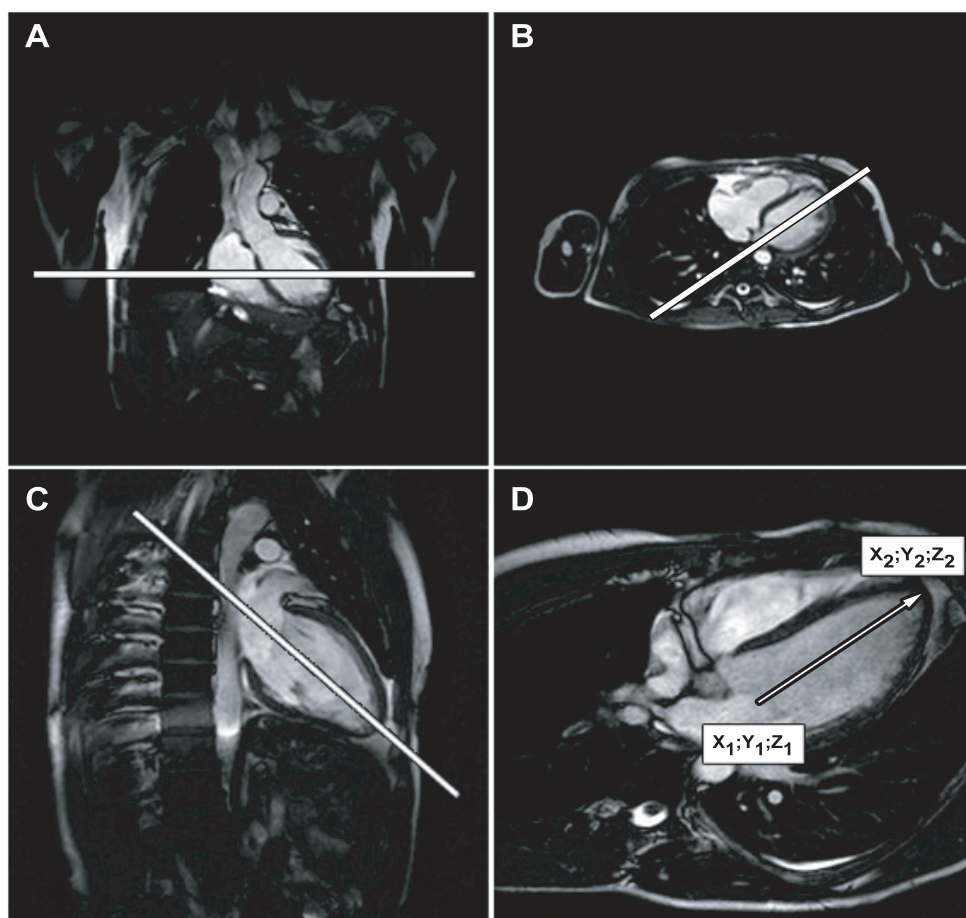


Figure 2

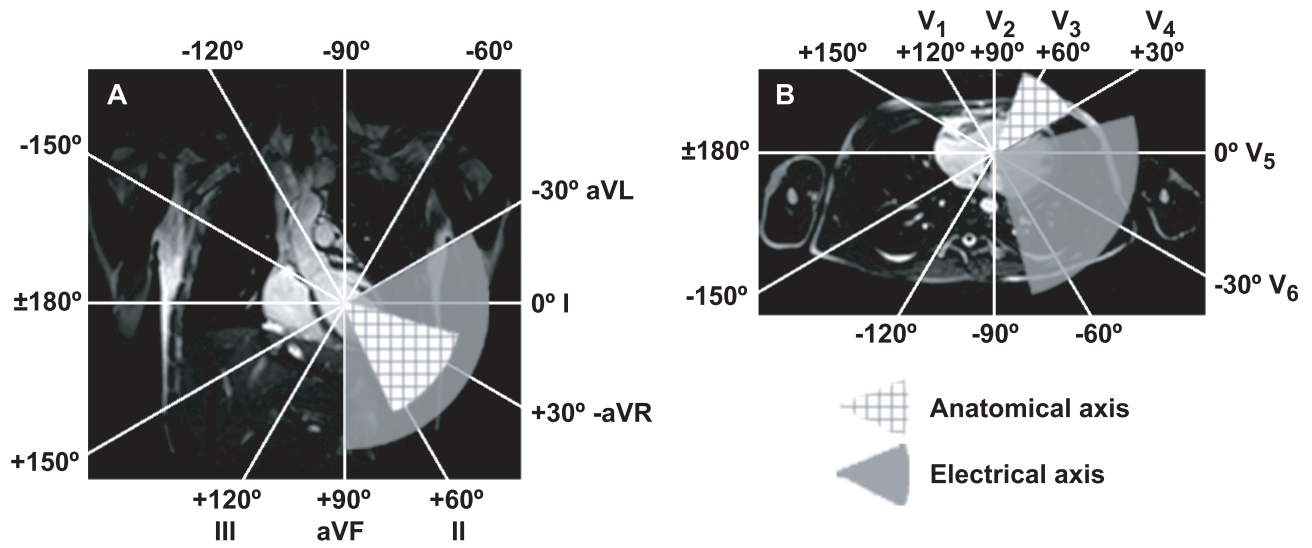


Figure 3

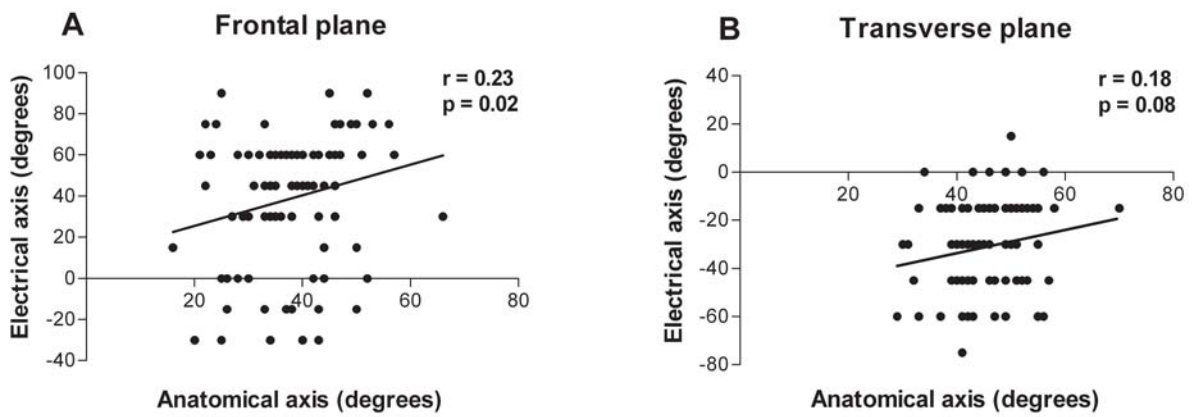


Figure 4

