



LUND UNIVERSITY

An easy-to-use method for detecting fetal hemoglobin-A test to identify bleeding from vasa previa.

Lindqvist, Pelle; Gren, Peter

Published in:

European Journal of Obstetrics, Gynecology, and Reproductive Biology

DOI:

[10.1016/j.ejogrb.2006.05.011](https://doi.org/10.1016/j.ejogrb.2006.05.011)

2006

[Link to publication](#)

Citation for published version (APA):

Lindqvist, P., & Gren, P. (2006). An easy-to-use method for detecting fetal hemoglobin-A test to identify bleeding from vasa previa. *European Journal of Obstetrics, Gynecology, and Reproductive Biology*, 131(2), 151-153.
<https://doi.org/10.1016/j.ejogrb.2006.05.011>

Total number of authors:

2

General rights

Unless other specific re-use rights are stated the following general rights apply:

Copyright and moral rights for the publications made accessible in the public portal are retained by the authors and/or other copyright owners and it is a condition of accessing publications that users recognise and abide by the legal requirements associated with these rights.

- Users may download and print one copy of any publication from the public portal for the purpose of private study or research.
- You may not further distribute the material or use it for any profit-making activity or commercial gain
- You may freely distribute the URL identifying the publication in the public portal

Read more about Creative commons licenses: <https://creativecommons.org/licenses/>

Take down policy

If you believe that this document breaches copyright please contact us providing details, and we will remove access to the work immediately and investigate your claim.

LUND UNIVERSITY

PO Box 117
221 00 Lund
+46 46-222 00 00



LUND UNIVERSITY
Faculty of Medicine

LUP

Lund University Publications
Institutional Repository of Lund University

This is an author produced version of a paper published in European journal of obstetrics, gynecology, and reproductive biology. This paper has been peer-reviewed but does not include the final publisher proof-corrections or journal pagination.

Citation for the published paper:
Lindqvist PG, Gren P.

"An easy-to-use method for detecting fetal hemoglobin--
a test to identify bleeding from vasa previa"
European journal of obstetrics, gynecology, and
reproductive biology, 2007, Vol: 131, Issue: 2,
pp. 151-3.

<http://dx.doi.org/10.1016/j.ejogrb.2006.05.011>

Access to the published version may
require journal subscription.
Published with permission from: Elsevier Scientific
Publishers

An easy-to-use method for detecting fetal hemoglobin –a test to identify bleeding from vasa previa

Pelle G Lindqvist, MD, PhD, and Peter Gren MD
Department of Obstetrics and Gynecology
Department of Clinical Sciences
Malmö University Hospital, MAS
Lund University
Sweden

CONDENSATION

We describe an easy-to-use method for detecting fetal hemoglobin that might be used for identification of bleeding at vasa previa.

An easy-to-use method for detecting fetal hemoglobin –a test to identify bleeding from vasa previa.

BACKGROUND: Vasa previa is a rare but potentially dangerous fetal condition that may occur during pregnancy. Ideally, all cases such cases are detected antenatally, but many present as late vaginal hemorrhaging. At the current time, there is no test for fetal hemoglobin (HbF) in general use.

METHOD: A modified method of identifying HbF is presented. Five ml of 0.14M NaOH was combined with 50 microliters of a mixture of fetal and maternal blood. After two minutes, it was judged if the solution still had a red tone or not. The sensitivity of this method for detecting HbF was assessed.

RESULTS: All 15 clinical personnel could identify both 69% and 34% HbF mixed with adult hemoglobin (100% sensitivity), 14 out of 15 could identify 17% HbF (93% sensitivity), and 12 out of 15 could identify a mixture containing 8% HbF (80% sensitivity).

CONCLUSION: Our rapid, simple test for HbF was at least as sensitive as slower, more cumbersome alkali denaturation tests in common use. It could prove to be a lifesaving tool in ruling out vasa previa bleeding in cases of unclear late pregnancy hemorrhages.

INTRODUCTION

Vasa previa is a condition in which the umbilical vessels run unprotected through the amniotic membrane that is located before the presenting part of the fetus. It is reported to occur in one in 2500 to 5000 deliveries, almost always in conjunction with a low placenta to which the umbilical cord is not attached. Instead, the cord is connected to the amniotic membranes (velamentous insertion), leaving the umbilical vessels without the protection of the gel of the umbilical cord [1]. Vasa previa usually presents by a vaginal hemorrhage upon rupture of the membranes, when one of the umbilical vessels breaks (Figure 1). This hemorrhage is not maternal and originates from the fetal circulation. If delivery is not performed immediately, the fetus may be exsanguinated. When unidentified, vasa previa is associated with a high (75% to 90%) risk of fetal mortality, although maternal risk remains minimal [2].

Odunsi and coworkers reported an evaluation of the various tests available for detection of fetal hemoglobin (HbF), such as alkali denaturation tests (Apt, Ogita, Loendersloot), hemoglobin electrophoresis, and the Kleihauer test [3-6]. The Kleihauer test and hemoglobin electrophoresis were found to be both reliable and sensitive, i.e., they were able to identify the presence of HbF in concentrations down to a minimum of 0.01%. However, both tests are too slow to be clinically useful in the diagnosis of vasa previa. Alkali denaturation tests, on the other hand, have been shown to be reliable and fast, but are quite insensitive. The Apt test and Loendersloot's method require the presence of at least 60% HbF to be positive, and the Ogita test needs 20% HbF [3]. The main reason that neither of these tests are in common use is that they are too complicated to perform as a routine clinical procedure. The basis of the alkali denaturation tests is that HbF is more resistant to variations in pH, as compared to maternal adult hemoglobin. The Ogita test and the Loendersloot test use 0.1M KOH and the APT test uses 0.2M NaOH when modified for testing of HbF from the umbilical artery [7]. Seeking an easier-to-use, more sensitive, and rapid procedure, we constructed a modified alkali denaturation test using a solution of 0.14M NaOH (pH 13.1). HbF is resistant to this base and maintains its red color after two minutes have elapsed, while maternal hemoglobin becomes denaturated and turns a brownish-green color (Figure 2).

The purpose of this paper was to determine the proportion of fetal/adult hemoglobin at which it was possible to identify HbF, i.e., the sensitivity threshold of this easy-to-use test for HbF.

METHODS

We designed an experiment using a dilution series with mixtures of fresh maternal blood (adult Hb) and HbF at 69% HbF, 34% HbF, 17% HbF, and 8% HbF in EDTA tubes. Fifty microliters of blood in 5 ml of 0.14M NaOH resulted in a clearly discernible light red color. The tests for HbF were prepared with 5 ml of 0.14M NaOH and 50 microliters of blood at various dilutions, as above. These samples, together with four samples of maternal blood (negative controls), were shown to 15 observers. The observers were asked to record a positive score if they could still determine a clear red tone in the sample after two minutes. The eight samples in the dilution series were shown to them in random order.

RESULTS

All fifteen observers judged the 69% HbF and the 34% HbF dilutions as clearly containing HbF, i.e., 100% sensitivity. Fourteen of the 15, judged the 17% HbF sample as positive for HbF (93% sensitivity), and 12 the 8% HbF as positive (80% sensitivity). There were no false positive results in the dilution series. No one of the observers hesitated in judging the samples with 69% and 34% HbF as clearly positive, i.e., they were visibly bright red in contrast to the controls.

DISCUSSION

Ideally, all cases of vasa previa should be identified prior to delivery [8]. However, a large proportion of vasa previa cases present themselves as late pregnancy hemorrhages. A fast, easily-performed, and reliable procedure like our simplified test for HbF might save infant lives if used routinely in late pregnancy hemorrhages, especially such hemorrhages that coincide with the rupture of membranes. It is also vital for pediatricians to be alerted when this condition is present, since an emergency transfusion of Rh negative O blood might prevent neonatal fatalities.

In clinical practice, we keep a bottle containing 0.14M NaOH, as described above, on hand at the obstetric unit (Figure 2). While examining women with third-trimester hemorrhage, we have at ready a urinary test-tube half-filled with 0.14M NaOH. During the routine speculum examination, a cotton swab is introduced into the hemorrhage, dipped in the test tube, and stirred until a slightly blood-tinged color appears. The swab is then removed, the test tube sealed and the speculum examination proceeds. After about two minutes, the color of the liquid is checked. HbF will retain its red color, while maternal blood will have turned brownish-green (Figure 2). If the test is positive for HbF, a sample of maternal blood should be retested to rule out causes other than bleeding from vasa previa. To regard the test as positive for HbF, the maternal test must be confirmed negative.

A hemorrhage from placental abruption may contain sufficient HbF to yield a positive test. If the pH of the testing solution is too low to denaturate the maternal hemoglobin or, in rare cases, if persistent hereditary HbF is present, the confirmatory maternal test will also be positive. Once again, in order to consider the test positive, the confirmatory test must be negative. The persistent HbF in maternal circulation after a fetomaternal hemorrhage will probably score similarly in vaginal and maternal tests [9]. Because most color blindness involves red and green deficits, the test should not be read by color blind persons.

Including the above test in the routine management of any unclear late pregnancy hemorrhage, will require less than a minute of additional time. In cases of vasa previa bleeding, which consists of pure fetal blood, the test will turn bright red, in contrast to the brown-greenish of maternal blood (Figure 2), making it both easy to perform and interpret the test.

We believe our rapid easy-to-use test for HbF is at least as sensitive as other alkali denaturation tests, making it valuable for ruling out vasa previa bleeding in cases of unclear late pregnancy hemorrhages.

Figure 1

A placenta showing velamentous insertion of the umbilical cord

Arrow –A break in one of the fetal vessels, causing a vasa previa hemorrhage

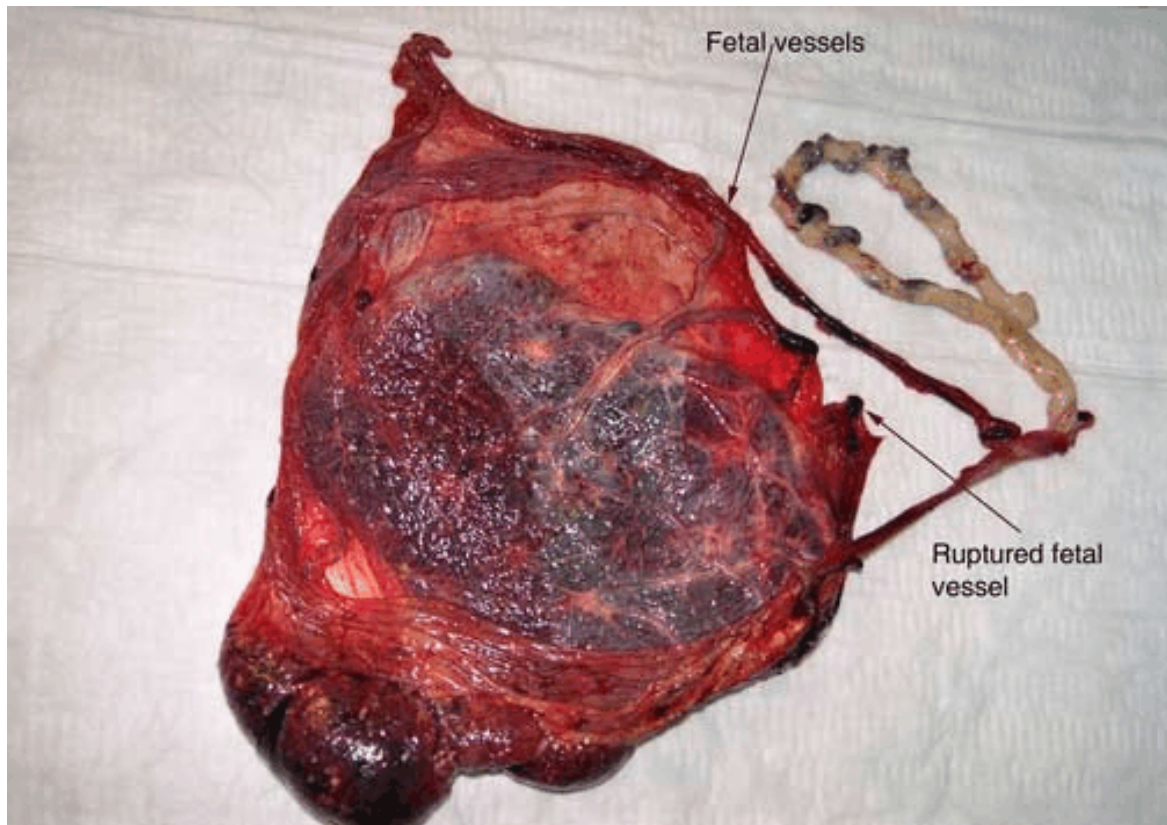
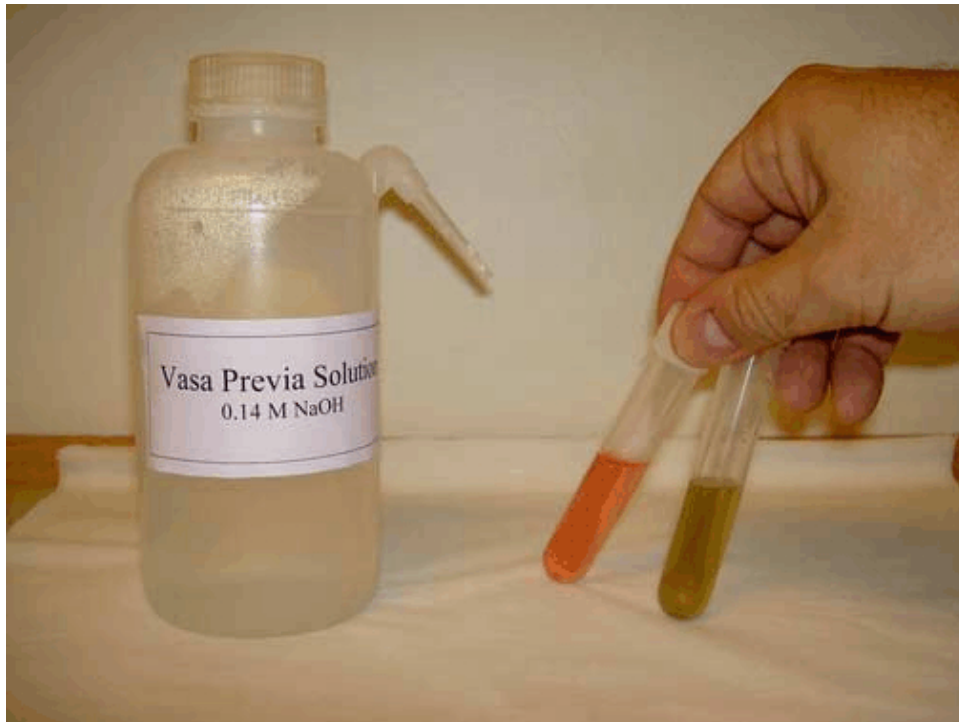

Figure 2

The complete vasa previa testing setup:

Shown: a beaker of 0.14M NaOH and two urinary test tubes, one with traces of HbF (red) and one containing solely maternal blood (brownish-green).



ACKNOWLEDGEMENT

This study was supported by the "ALF" (Faculty of Medicine, Lund University, Region Skåne).

REFERENCES

1. Jones KP, Wheeler AW, Musgrave W. Simple test for bleeding from vasa praevia. *Lancet* 1987;2(8573):1430-1.
2. Lee W, Lee VL, Kirk JS, Sloan CT, Smith RS, Comstock CH. Vasa previa: prenatal diagnosis, natural evolution, and clinical outcome. *Obstet Gynecol* 2000;95(4):572-6.
3. Odunsi K, Bullough CH, Henzel J, Polanska A. Evaluation of chemical tests for fetal bleeding from vasa previa. *Int J Gynaecol Obstet* 1996;55(3):207-12.
4. Apt L, Downey WS, Jr. Melena neonatorum: the swallowed blood syndrome; a simple test for the differentiation of adult and fetal hemoglobin in bloody stools. *J Pediatr* 1955;47(1):6-12.
5. Ogita S, Ishiko O, Matsumoto M, Hasegawa H, Sugawa T. A simplified method for measuring fetal hemoglobin. *Obstet Gynecol* 1976;48(2):237-8.
6. Loendersloot EW. Vasa previa. *Am J Obstet Gynecol* 1979;135(5):702-3.
7. Moir M, Holbrook RH, Jr. Application of the hemoglobin alkaline denaturation test to determine the fetal origin of blood: applicability to funipuncture. *Obstet Gynecol* 1993;81(5 (Pt 1)):793-6.
8. Oyelese Y. Placenta previa and vasa previa: time to leave the Dark Ages. *Ultrasound Obstet Gynecol* 2001;18(2):96-9.
9. Kush ML, Muench MV, Harman CR, Baschat AA. Persistent fetal hemoglobin in maternal circulation complicating the diagnosis of fetomaternal hemorrhage. *Obstet Gynecol* 2005;105(4):872-4.