LUND UNIVERSITY

Aspects of skin cancer diagnosis in clinical practice

Ahnlide, Ingela

2015

Document Version:
Publisher's PDF, also known as Version of record

Link to publication

Citation for published version (APA):
Ahnlide, I. (2015). *Aspects of skin cancer diagnosis in clinical practice*. [Doctoral Thesis (compilation), Dermatology and Venereology (Lund)]. Department of Clinical Sciences, Lund University.

Total number of authors:
1

General rights
Unless other specific re-use rights are stated the following general rights apply:
Copyright and moral rights for the publications made accessible in the public portal are retained by the authors and/or other copyright owners and it is a condition of accessing publications that users recognise and abide by the legal requirements associated with these rights.
• Users may download and print one copy of any publication from the public portal for the purpose of private study or research.
• You may not further distribute the material or use it for any profit-making activity or commercial gain
• You may freely distribute the URL identifying the publication in the public portal

Read more about Creative commons licenses: https://creativecommons.org/licenses/

Take down policy
If you believe that this document breaches copyright please contact us providing details, and we will remove access to the work immediately and investigate your claim.

LUND UNIVERSITY

PO Box 117
221 00 Lund
+46 46-222 00 00

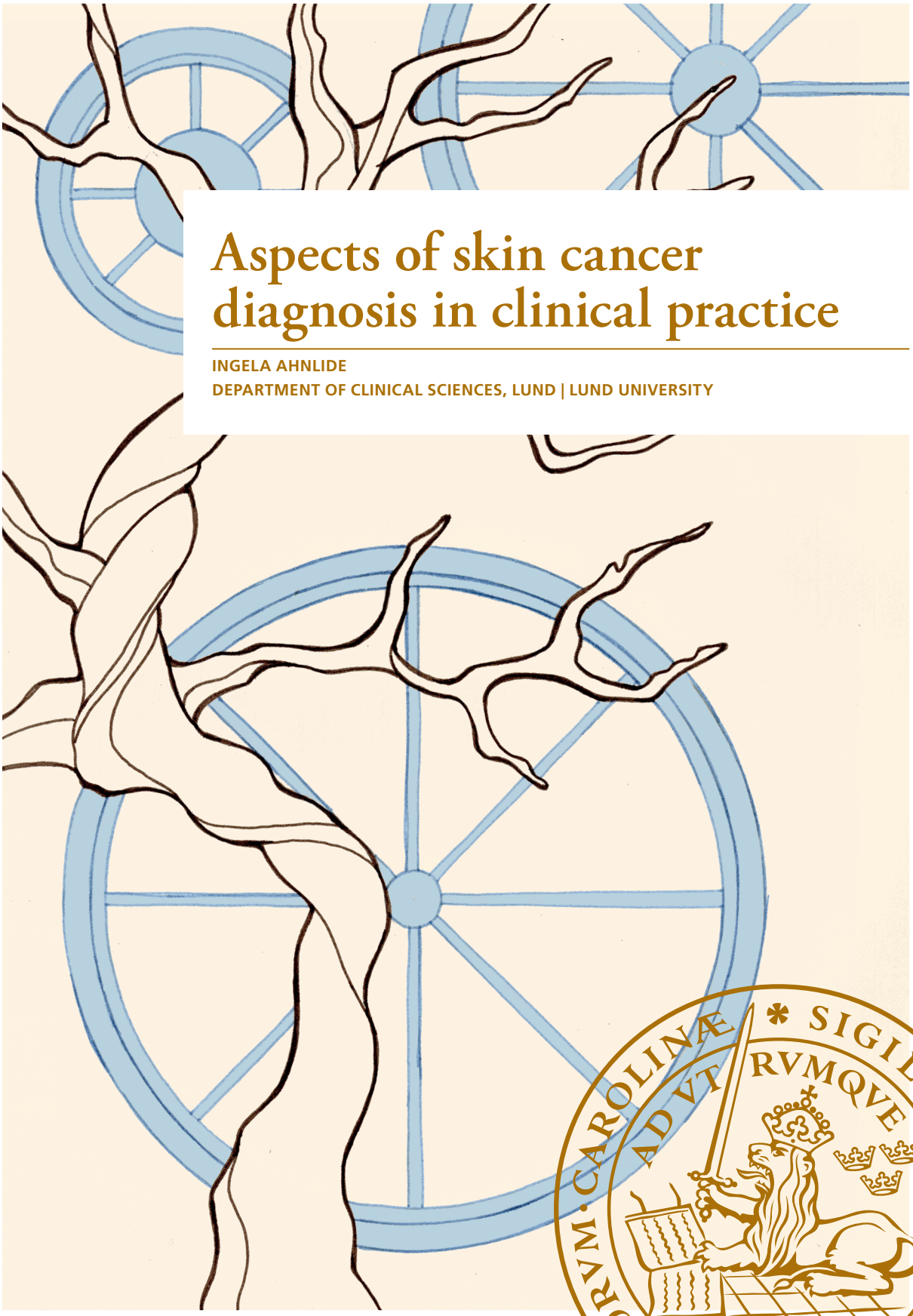

Aspects of skin cancer diagnosis in clinical practice

INGELA AHNLIDE
DEPARTMENT OF CLINICAL SCIENCES, LUND | LUND UNIVERSITY

Aspects of skin cancer diagnosis in clinical practice

Ingela Ahnlide

DOCTORAL DISSERTATION
by due permission of the Faculty of Medicine, Lund University, Sweden.

To be defended on 27 November 2015 at 1.00 pm
in Segerfalksalen, BMC, Lund.

Faculty opponent

Professor Chris Anderson, Department of Clinical and Experimental Medicine, Division of Dermatology, Faculty of Health Sciences, Linköping University, Linköping, Sweden

Organization	Document name
LUND UNIVERSITY	DOCTORAL DISSERTATION
Department of Clinical Science	Date of issue 15-11-27
Author(s)	Sponsoring organization

Title and subtitle

Aspects of skin cancer diagnosis in clinical practice

Abstract

Skin cancer incidence is increasing in fair-skinned populations. The three most common skin cancers are basal cell carcinoma (BCC), squamous cell carcinoma (SCC) and malignant melanoma (MM). A correct diagnosis is crucial for an efficient and tailored treatment for the skin cancer patient. The purpose of this thesis was to evaluate different aspects of the preoperative diagnosis of skin cancer. The studies making up this thesis were based on analysis of data from a register including all skin tumour excisions at the Department of Dermatology in Helsingborg, Sweden, from March 2008 to January 2015. The registered data included e.g. sex and age of the patient, tumour site and size, dermoscopic features of the tumour, the preliminary preoperative and final postoperative (histopathological) diagnosis as well as tumour cells at surgical margins.

The preliminary preoperative clinical diagnosis was compared with the final histopathological diagnosis in 2,953 excised tumours, whereof 1,626 (55.1%) were malignant, showing high diagnostic accuracy for the diagnosis of malignant tumour and for the diagnosis of basal cell carcinoma (BCC). A total of 96.0% of all excisions had tumour-free margins.

The number needed to excise (NNE) for melanoma (the number of pigmented lesions excised to find one melanoma) was calculated for 1,717 cases of excised skin tumours (252 melanomas, 1,395 naevi and 70 seborrhoeic keratoses (SK)). The overall NNE value during the study period was 6.5 (SKs not included). When SKs were included in the calculations the NNE was 6.8. The NNE value decreased with increasing age of the patient and varied for different body locations, with the highest values found for the trunk and the lowest for the arms.

When the ABCD rule of dermoscopy was used preoperatively at the bedside in 309 cases (46 melanomas and 263 naevi), use of the algorithm achieved 83% sensitivity and 45% specificity for melanoma diagnosis. A sensitivity of 74% and specificity of 91% were seen for the clinical diagnosis. A considerable percentage (19.6%) of very early melanomas were preoperatively not expected to be melanomas by the dermatologist.

The prediction of histopathological subtype of BCC is important for choosing optimal treatment in BCC patients and was assessed in 1,501 cases with pre- or postoperative diagnosis of BCC. The prediction of superficial BCC (sBCC) significantly improved after an educational update on dermoscopic criteria for sBCC in cases assessed by dermoscopy.

In conclusion, these studies have shown high accuracy of the preoperative diagnosis of malignant tumour and BCC. With increasing age of the patient, a higher rate of excised pigmented skin lesions was melanomas. Bedside use of the ABCD rule of dermoscopy achieved high sensitivity but low specificity for melanoma diagnosis; however, clinical information seemed to add to specificity. Prediction of sBCC was enhanced after a dermoscopy training session and when dermoscopy was mandatory.

Key words: skin cancer; skin cancer diagnosis; skin surgery; dermoscopy; basal cell carcinoma; squamous cell carcinoma; melanoma; dysplastic naevus; naevus; algorithms

Classification system and/or index terms (if any)

Supplementary bibliographical information	Language English
ISSN and key title 1652-8220; Lund University, Faculty of Medicine Doctoral Dissertation Series 2015:124	ISBN 978-91-7619-204-7

Recipient's notes	Number of pages 93	Price
	Security classification	

I, the undersigned, being the copyright owner of the abstract of the abovementioned dissertation, hereby grant to all reference sources permission to publish and disseminate the abstract of the abovementioned dissertation.

Signature _____Date 15-10-29_____

Aspects of skin cancer diagnosis in clinical practice

Ingela Ahnlide



LUND
UNIVERSITY

Copyright Ingela Ahnlide

Cover:
“The tree of knowledge of spoke wheel and leaves” Artwork: Alma Ahnlide

Department of Clinical Sciences
Faculty of Medicine, Lund University, Sweden
ISBN 978-91-7619-204-7
ISSN 1652-8220

Printed in Sweden by Media-Tryck, Lund University
Lund 2015

Contents

Contents 1
List of papers 1
Abbreviations 3
Introduction 5
Background 7
The human skin 7
Skin cancer 8
Risk factors for skin cancer 9
Squamous cell carcinoma 10
Basal cell carcinoma 12
Melanoma 17
Benign and premalignant skin lesions 20
Treatment of skin cancer 25
Histopathology of skin tumours 28
Dermoscopy 29
Dermoscopy of pigmented skin lesions 30
Pattern recognition 32
Dermoscopic algorithms 33
Dermoscopy of basal cell carcinoma 38
Summary of clinical, dermoscopic and histopathological findings in different subtypes of basal cell carcinoma 39
Dermoscopy of squamous cell carcinoma 43
The diagnostic process 43
Aims of the thesis 45
Materials and methods 47
Background data 47
Statistics 48
Study design, study populations and methods 50
Results 55
Discussion 59
General discussion 59

General methodological considerations 59
Study I 62
Study II 64
Study III 66
Study IV 67
Conclusions 71
Future prospects 73
Sammanfattning på svenska 75
Tack! 79
References 81

List of papers

This thesis is based on the following papers, which are referred to in the text by their Roman numerals.

Study I

Ingela Ahnlide, Mats Bjellerup

Title: Accuracy of clinical skin tumour diagnosis in a dermatological setting.

Acta Dermato-Venereologica, Volume 93, pp. 305–308, 2013

Study II

Ingela Ahnlide, Kari Nielsen, Mats Bjellerup

Title: Diagnosis of pigmented skin tumours in a dermatological setting: different aspects of the number needed to excise as a measure of efficiency.

Acta Dermato-Venereologica, Volume 94, pp. 683–686, 2014

Study III

Ingela Ahnlide, Mats Bjellerup, Fredrik Nilsson, Kari Nielsen

Title: Validity of melanoma diagnosis using the ABCD rule of dermoscopy in clinical practice.

Accepted for publication in Acta Dermato-Venereologica.

Study IV

Ingela Ahnlide, Iris Zalaudek, Fredrik Nilsson, Mats Bjellerup, Kari Nielsen

Title: Preoperative prediction of histopathologic outcome in basal cell carcinoma – flat surface and multiple small erosions predict superficial basal cell carcinoma in lighter skin types.

Under revision for British Journal of Dermatology

Abbreviations

AK	actinic keratosis
ALA	aminolaevulinic acid
ANOVA	analysis of variance
BCC	basal cell carcinoma
CASH	colour, architecture, symmetry, homogeneity
C&C	curettage and cautery
CI	confidence interval
CMN	congenital melanocytic naevus
CN	common naevus
DN	dysplastic naevus
DNA	deoxyribonucleic acid
ENT	ear, nose and throat
FN	false negative
FP	false positive
5-FU	5-fluorouracil *or* fluorouracil
GP	general practitioner
IQR	interquartile range
LM	lentigo maligna
LMM	lentigo maligna melanoma
LR-	negative likelihood ratio
LR+	positive likelihood ratio
MAL	methyl aminolaevulinate
MM	malignant melanoma
MMS	Mohs micrographic surgery

nBCC	nodular BCC
NM	nodular melanoma
NMSC	non-melanoma skin cancer
NNE	number needed to excise
NNT	number needed to treat
NPV	negative predictive value
PDT	photodynamic therapy
PpIX	protoporphyrin IX
PPV	positive predictive value
PTCH1	patched 1 gene
PUVA	psoralen + ultraviolet A
RCT	randomized controlled trial
ROS	reactive oxygen species
sBCC	superficial BCC
SCC	squamous cell carcinoma
SD	standard deviation
SK	seborrhoeic keratosis
SLNB	sentinel lymph node biopsy
SN	sentinel node
SSM	superficial spreading melanoma
TDS	total dermoscopy score
TN	true negative
TP	true positive
UV	ultraviolet
UVA	ultraviolet A
UVR	ultraviolet radiation
WHO	World Health Organization
XP	xeroderma pigmentosum

Introduction

Skin cancer is an increasing health problem in fair-skinned populations and skin cancers are among the cancers with the most rapidly increasing incidence in Sweden[1]. In addition to the human suffering due to morbidity and mortality, the economic burden on society caused by skin cancer is significant and increasing[2,3]. This underlines the importance of analysing all aspects of diagnosis and treatment of skin cancer to find the most effective and efficient management. Early treatment is crucial for a good prognosis and a correct diagnosis is a prerequisite for adequate treatment of the patients. Clinical and dermoscopic diagnosis is fast, and even a complete skin examination takes only a few minutes for a trained physician[4]. Dermatologists are trained to assess skin conditions including skin cancer and dermatology departments are equipped to give tailored treatment to each skin cancer patient. It is, however, important to evaluate the diagnostic abilities of physicians and different tools at hand, and to assess different aspects of diagnostic accuracy to define areas for improvement and to find the most effective management option for skin cancer patients:

> *Without information on how we are doing, it is not possible to review progress and improve on our abilities. If you wish to perform – and in this sense medicine is about performance – you have to actively seek out ways to improve. Mere passive contemplation is not sufficient*[5]

This thesis is focused on evaluation of different aspects of clinical and dermoscopic diagnosis of skin cancer.

Background

The human skin

The skin is a protective coat that covers our body. It constitutes the first-line defence against external factors and is crucial for maintaining homeostasis. Among other functions, the skin prevents water loss, serves as an insulator and thermoregulator and protects against external damage, like mechanical trauma, microorganisms, chemical irritants or toxins and ultraviolet radiation (UVR). The skin is also involved in the synthesis of vitamin D.

The skin is composed of three layers: the epidermis, dermis and subcutis (Fig. 1).

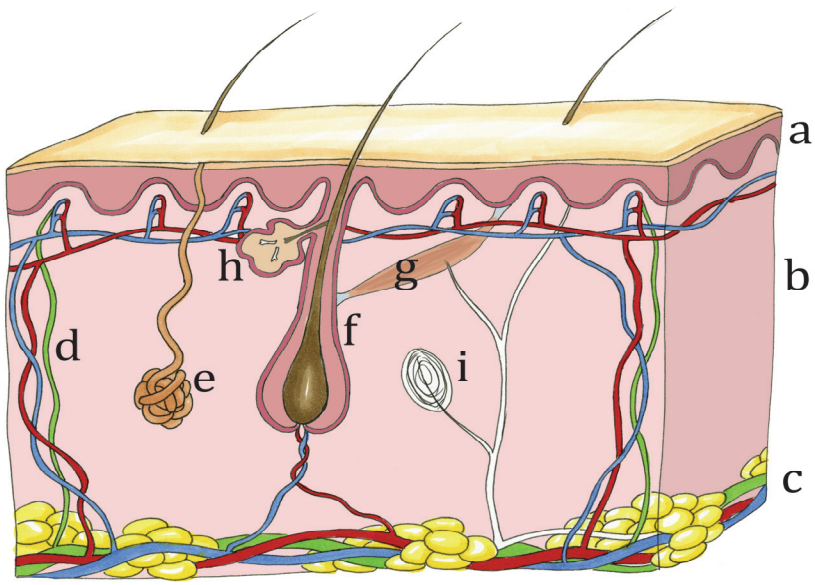

Figure 1. The skin.
a. epidermis **b.** dermis **c.** subcutis **d.** blood and lymph vessels **e.** sweat gland **f.** hair follicle **g.** arrector pili muscle **h.** sebaceous gland **i.** nerve ending and Pacinian corpuscle (mechanoreceptor). (Artwork: Alma Ahnlide)

The outermost layer of the skin, the epidermis, mainly consists of keratinocytes. Keratinocytes proliferate at the basal layer (stratum basale), differentiate through the stratum spinosum, lose the nucleus in the stratum granulosum and eventually form the cornified layer, the stratum corneum, where the cells finally shed off. Most of the barrier functions are localized in the stratum corneum. Also present in the stratum basale are the Merkel cells, involved in the light touch sensation, and the pigment-producing melanocytes. The migratory Langerhans cells and intra-epidermal T cells – both parts of the immune system – are also found in the epidermis. Beneath the epidermis, the thin fibrous basal membrane separates the epidermis from the next layer of the skin – the dermis.

The dermis is composed of connective tissue that supports the overlying epidermis. The dermis is divided into the superficial papillary dermis, with loose connective tissue, and the deeper, dense reticular dermis. The blood supply of the epidermis and dermis is located in the dermis as the interconnected, horizontally arranged superficial and deep vascular plexuses. The major cell type in the dermis is the fibroblast. The dermis also contains nerve endings, lymphatics and epidermal appendages, such as sebaceous glands, sweat glands and hair follicles.

Beneath the dermis is the deepest layer of the skin, the subcutaneous layer. This layer consists of loose connective tissue and lobules of adipose cells, and acts as insulation, trauma protection and, to some extent, thermoregulation.

Skin cancer

The three most common skin neoplasms are basal cell carcinoma (BCC), squamous cell carcinoma (SCC) and malignant melanoma (MM) (Fig. 2). Squamous cell carcinoma and BCC are often referred to as “non-melanoma skin cancer (NMSC)” or “keratinocyte cancers”. Non-melanoma skin cancers are the most common of all malignancies in fair-skinned populations[6]. Basal cell carcinoma is the most common, with a BCC:SCC ratio of about 4:1.

There are several other rare cancers that originate from skin or skin appendages (e.g. dermatofibrosarcoma protuberance, atypical fibroxanthoma, Merkel cell carcinoma). This thesis will, however, concentrate on BCC, SCC and MM.

In 2013 a total of 45,590 cases of BCC, 6,302 cases of invasive SCC, 8,234 cases of SCC *in situ*, and 3,357 cases of invasive melanoma, as well as 2,672 cases of melanoma *in situ* were reported to the Swedish Cancer Registry[7]. The incidence of skin cancer is increasing and for SCC, the average yearly incidence increase rate during the last 10-year period was 4.9% for men and 6.5% for women. For melanoma, the corresponding values were 5.5% for both sexes[7]. Melanoma and SCC account for about 15% of the cancer cases in Sweden[7].

Skin cancer is predominantly seen in fair-skinned populations and in a global perspective the incidence rises with proximity to the Equator[6,8]. The highest incidence rates for melanoma are reported from Australia, where a marked gradient within Australia is seen, with substantially higher incidence rates in the low-latitude compared with the southern parts of the country[8]. In Europe, however, higher melanoma rates are reported from the northern countries compared with southern Europe[9], presumably owing to different pigmentation phenotypes across Europe.

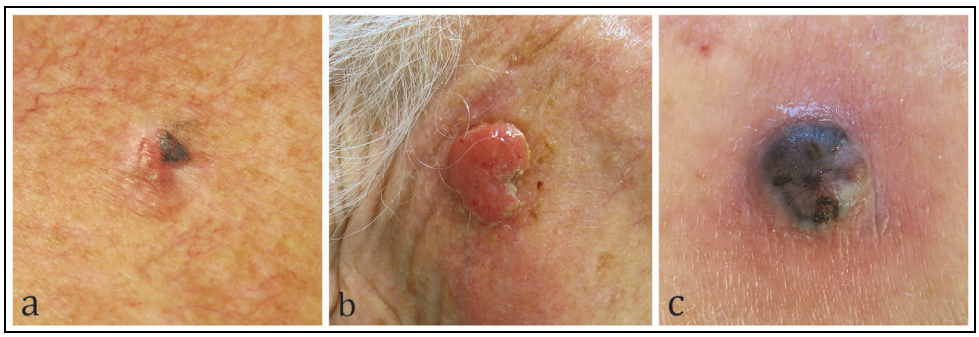

Figure 2. The three most common skin cancers.
a. Basal cell carcinoma. **b**. Squamous cell carcinoma **c**. Malignant melanoma. (Photo: I Ahnlide)

Risk factors for skin cancer

Environmental factors

The principal risk factor for skin cancer is UVR through sun exposure[10-13], but UVR from artificial sources such as tanning beds[14,15] or medical treatments, like PUVA[16,17] (psoralen + ultraviolet A (UVA)), also increases the risk. Chronic sun exposure is the main risk factor for NMSC, illustrated by the fact that the majority of NMSCs arise at skin areas chronically exposed to the sun, such as the head and neck area[10]. For melanoma, there are age-related differences in the anatomic distribution; in younger ages, melanomas are commonly located on intermittently sun-exposed skin areas (i.e. trunk and limbs), while chronically sun-exposed skin areas are a more common location at older ages[11,18].

Other risk factors for skin cancer are e.g. immunosuppression[19] and ionizing radiation[20].

Host factors

Constitutional risk factors for skin cancer are fair skin, red hair and blue eyes[21]. The number of naevi (banal or dysplastic naevi (DNs)) is related to the risk of developing melanoma. For people with a total naevus count of >100, the relative risk is almost tenfold higher compared with people with no or only a few naevi[22,23].

Defects in deoxyribonucleic acid (DNA) repair genes, as in the rare genetic disorder xeroderma pigmentosum (XP), convey increased risk of developing skin cancer, especially SCC[24]. The genetic disorder basal cell naevus syndrome (Gorlin syndrome) predisposes to BCC[25,26]. Patients with this disorder carry mutations in the patched 1 gene (PTCH1) that function as a tumour suppressor gene and regulate the so-called "hedgehog-signalling pathway". The PTCH1 is frequently mutated in sporadic BCCs as well[27].

Squamous cell carcinoma

Squamous cell cancer *in situ*

Clinical presentation

Cutaneous SCC is derived from epidermal keratinocytes. Squamous cell carcinoma *in situ* (also called "Bowen's disease") is an intra-epithelial SCC and presents as a slow-growing erythematous plaque with crusting or scaling on the surface[28] (Fig. 3a).

Prognosis

The risk of progression to invasive carcinoma is low and estimated to be around 2–5%[28].

Differential diagnoses

Superficial BCC, flat actinic keratoses (AKs), as well as psoriasis and eczema are relevant differential diagnoses of SCC *in situ*.

Treatment

Several treatment options are available, such as complete excision, topical fluorouracil (5-FU), curettage and cautery (C&C), and photodynamic therapy (PDT)[28].

Invasive squamous cell carcinoma

Clinical presentation

Squamous cell carcinoma is clinically heterogeneous and can present as a growing, dome-shaped or papillomatous tumour often covered by a keratosis. Keratoacanthoma is a variant of well-differentiated SCC, presenting as a dome-shaped rapidly growing tumour with a central keratosis (Fig. 3b). Poorly differentiated tumours often show an ulcerated, eroded, easily bleeding surface (Fig. 3c). Squamous cell carcinomas are commonly located on chronically sun-exposed and sun-damaged skin, like the face, back of the hands and forearms, and the scalp (especially in men)[29].

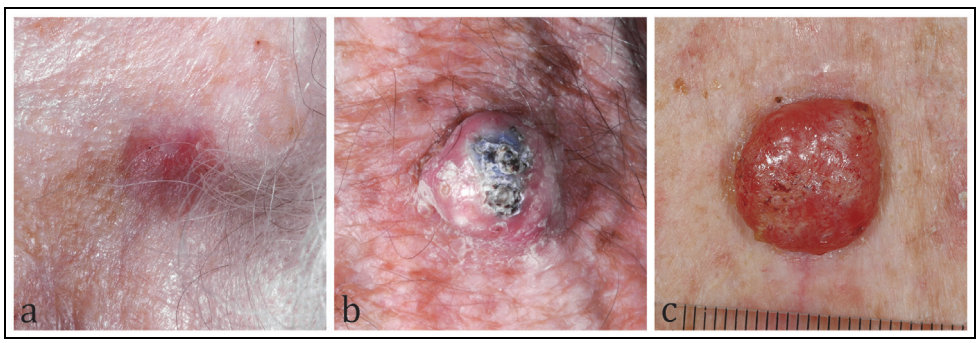

Figure 3. Squamous cell carcinoma (SCC).
a. SCC *in situ* presenting as an erythematous plaque. (Photo: I Ahnlide) **b**. Keratoacanthoma-like SCC presenting as a dome-shaped tumour with central keratosis. (Photo: I Ahnlide) **c.** Invasive SCC presenting as a red nodule. (Photo: M Bjellerup).

Prognosis

Cutaneous SCC has the potential of metastatic spread. The risk for metastasis from SCC that appears on sun-damaged skin is, however, low and estimated to be 2–5%[30]. The risk for metastatic spread is higher in tumours >2 cm in diameter, and in tumours with high-risk features such as location on the lip or ear, tumour invasion depth >2 mm, poor differentiation, and perineural invasion[31].

Differential diagnoses

The most important differential diagnosis of SCC is BCC. Basal cell carcinomas are usually more slow-growing and lack the covering keratosis. The diagnosis can be difficult in poorly differentiated tumours where the differential diagnosis might be BCC as well as amelanotic melanoma. The dermoscopic characteristics of SCC are further described below.

Treatment

Complete surgical excision with adequate surgical margins depending on size of tumour and tumour stage is the treatment of choice for invasive SCC[32]. Alternative treatments, such as cryosurgery, and radiotherapy, may yield good results in experienced hands and in carefully selected cases[32].

Basal cell carcinoma

Basal cell carcinoma is a slow-growing, locally invasive malignant keratinocyte tumour. Histologically, BCC cells resemble the cells in the basal layer of epidermis. It has been proposed that BCCs are derived from pluripotent cells in the hair follicle; however, the precise cell of origin has not been determined[33,34].

Prognosis

Basal cell carcinomas very rarely metastasize[35-37]. However, the tumour is locally invasive and if left untreated may destruct tissues like cartilage and bone. Based on different clinical and histopathologic features, various subtypes, including pigmented variants, can be distinguished. Classification according to the histopathological growth pattern reflects the tendency of the tumour to grow invasively and destructively in the surrounding tissues. In Sweden the so-called Glas classification (or Sabbatsberg classification) is used[38], which divides tumours into non-/low aggressive BCC (including nodular (nBCC) and superficial BCC (sBCC)), intermediate/infiltrating BCC, and highly aggressive BCC (also called "morpheiform"). The growth pattern is the most crucial factor to take into account in treatment decisions for BCC patients. The presence of pigmentation in the tumour can also be of importance for the clearance rates of e.g. PDT; this feature is, however, not taken into account in the Glas classification[39].

Nodular basal cell carcinoma

Clinical presentation

Nodular BCC (Glas type IA) is presented clinically as a slow-growing, often ulcerated, papule or nodule with visible ectatic vessels (Fig. 4a). It is the most common subtype, comprising more than 50% of all BCCs. In the majority of cases, nBCCs are located in the head-neck area, while the second most common localization is the trunk[40,41].

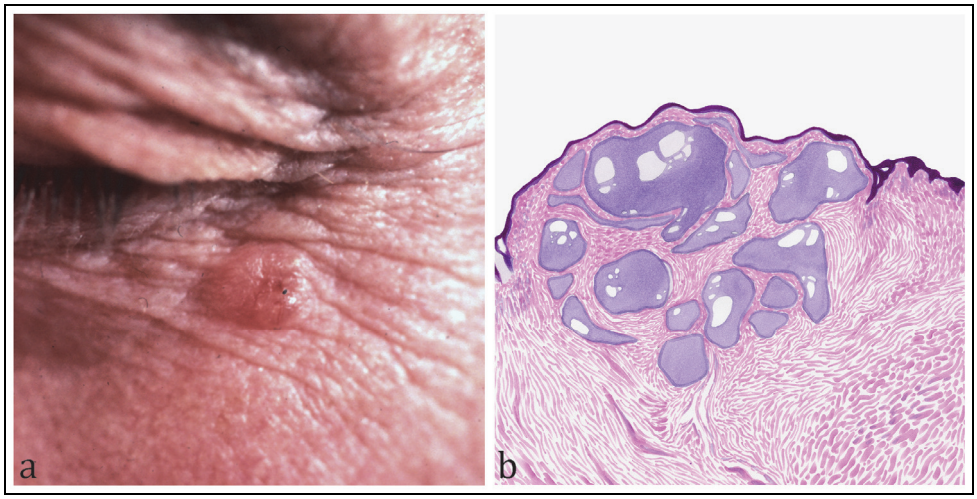

Figure 4. Nodular basal cell carcinoma (nBCC).
a. Clinical picture showing a well-circumscribed, skin-coloured, nodular tumour. (Photo: M Bjellerup). b. Illustration depicting the histopathology of nBCC with well circumscribed basaloid tumour masses. (Artwork: Alma Ahnlide)

Histopathology

Histologically, the tumour is well circumscribed, with sharply delineated tumour masses consisting of basaloid cells with palisading of the cells at the periphery (Fig. 4b). There is often a slit-like retraction between the tumour and the adjacent stroma[42].

Superficial basal cell carcinoma

Clinical presentation

Superficial BCC (Glas type IB) is commonly presented as a macular or slightly infiltrated patch or plaque, usually red or violaceous in colour, sometimes with small crusts on the surface (Fig. 5a). Superficial BCCs comprise around 20–30% of BCCs, and the majority are located on the trunk[40,41,43].

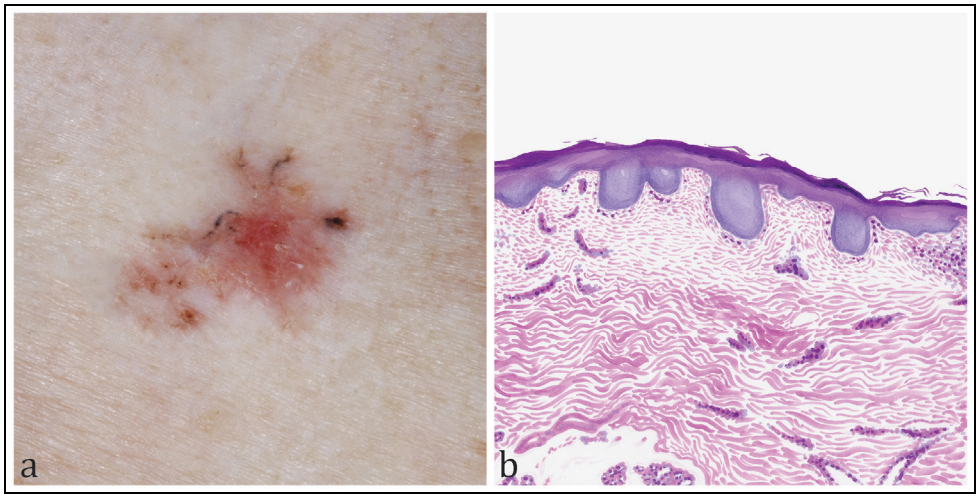

Figure 5. Superficial basal cell carcinoma (sBCC).
a. Clinical picture showing a red, partly pigmented plaque. (Photo: I Ahnlide). **b**. Illustration depicting the histopathology of sBCC with small tumour nests connected to the epidermis. (Artwork: Alma Ahnlide)

Histopathology

Superficial BCC presents as tumour nests with connection to the epithelium (Fig. 5b). The tumour mainly grows parallel to the epidermis and not beneath the papillary dermis[42].

Intermediately aggressive (infiltrative) basal cell carcinoma

Clinical presentation

Tumours showing features of both nodular and more invasive BCC are categorized as intermediately aggressive or infiltrative (Glas type II)[38]. Clinically they present as indurated, nodular or plaque-like, usually shiny white or red tumours (Fig. 6a). Infiltrative BCCs are located in the head-neck area in the majority of cases[43].

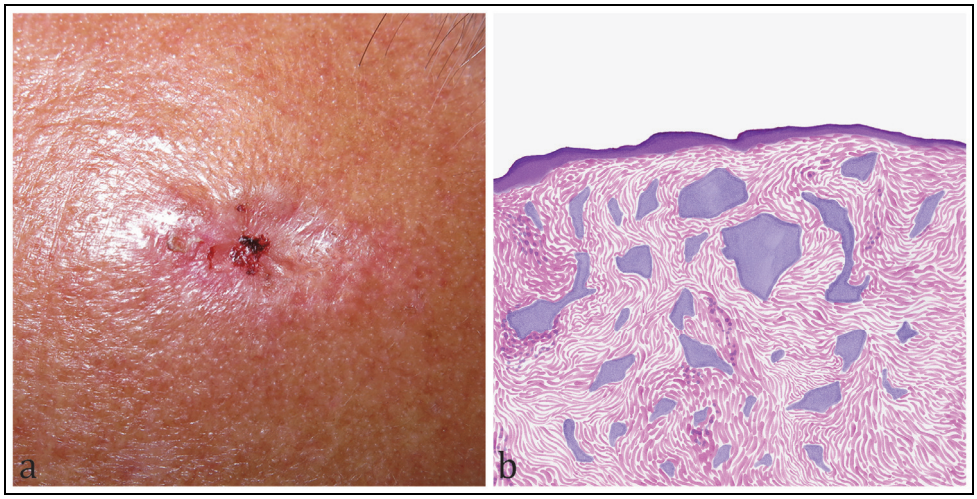

Figure 6. Infiltrative basal cell carcinoma (BCC).
a. Clinical picture showing a plaque-like shiny white tumour. (Photo: I Ahnlide). **b**. Illustration depicting the histopathology of infiltrative BCC with irregularly shaped tumour nests in the dermis. (Artwork: Alma Ahnlide)

Histopathology

Infiltrative BCCs show invasive growth on histopathology, but the tumour strands are not as thin as in morpheiform BCC (Fig. 6b). The tumour comprises irregularly shaped tumour nests that are poorly circumscribed and may invade the subcutis. Micronodular BCC comprises a special variant of intermediately aggressive BCC, in which the tumour nests have the same shape as in nBCC, but are smaller and show a more deeply infiltrating growth pattern[42].

Highly aggressive basal cell carcinoma

Clinical presentation

Highly aggressive BCC (Glas type III) clinically manifests as a slow-growing sclerotic plaque in the head-neck area[42]. The exact borders of the tumour are usually extremely difficult to visualize (Fig. 7a).

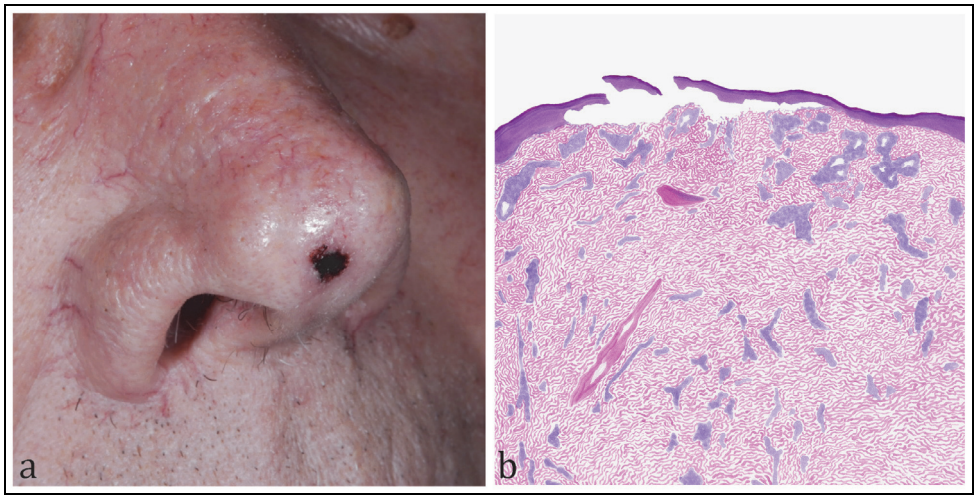

Figure 7. Highly aggressive basal cell carcinoma (BCC).
a. Highly aggressive BCC involving the tip of the nose, presenting as a sclerotic tumour with indistinct borders and a central small ulceration. (Photo: J Nilsson) **b**. Illustration depicting the histopathology of highly aggressive BCC with widespread invasion with thin tumour strands, infiltrating the tissue in a densely fibrotic stroma. (Artwork: Alma Ahnlide)

Histopathology

Histologically, the tumour shows widespread invasion with thin tumour strands, sometimes only a few cells wide, infiltrating deep into the tissue in a densely fibrotic stroma[42] (Fig. 7b).

Differential diagnoses

Since the different histological subtypes of BCC have different clinical presentation, the clinical differential diagnoses differ correspondingly[42]. The implications of misdiagnosis also differ because of the growth patterns of subtypes of BCC.

The most important differential diagnosis to nBCC is SCC, but also adnexal tumours such as hypertrophic sebaceous glands.

Superficial BCC can be misdiagnosed as AK, SCC *in situ* (Bowen's disease) or eczema.

The highly aggressive or morpheiform BCC is difficult to diagnose at an early stage as it is usually only presented as a slow-growing sclerotic patch with diffuse borders that is easily missed by both patient and physician. The invasive behaviour of the tumour and late detection can lead to the need for extensive excisions to eradicate the tumour.

Treatment of basal cell carcinoma

When choosing the most optimal treatment for BCC, several factors must be taken into account, such as tumour location, site and size, and whether the patient presents with one or multiple tumours, as well as the general health of the patient. The most relevant factor for the decision is, however, the histopathological subtype of the BCC, since the outcome of any given treatment will be dependent on the growth pattern. First-line therapy for the majority of BCCs is complete surgical excision[44]. For highly aggressive (morpheiform) BCC, complete excision with wide margins or Mohs micrographic surgery (MMS) is recommended[45]. Curettage and cryotherapy is an option for non-morpheiform BCC[46-48]. For sBCC cryotherapy, C&C, PDT, and imiquimod as well as 5-FU are all treatment alternatives[49-59]. The different treatment modalities are further explained below.

Melanoma

Melanoma generally arises from melanocytes within the epidermis in the skin, but may arise in any organ where melanocytes are present. In the majority of cases, the tumour has an intra-epithelial phase before it becomes invasive. The duration of this *in situ* phase seems to vary considerably (from months to years)[60].

A pre-existing naevus (common or dysplastic) can be found in about 30% of melanomas, while approximately 70% of cases seem to arise *de novo*[61].

The majority of melanomas can be divided into four clinical-pathological subsets: superficial spreading melanoma (SSM); nodular melanoma (NM); lentigo maligna melanoma (LMM); and acral lentiginous melanoma[62].

Differential diagnoses

The diagnosis of melanoma constitutes a major diagnostic challenge for physicians. The goal for secondary prevention of melanoma is early detection and treatment. The diagnosis may be easy in fully developed, clear-cut cases, but very difficult in the early stages, when the clues to the diagnosis are subtle. The most relevant and prevalent differential diagnosis of melanoma is naevus. However, with increasing age of the patient the number and size of seborrhoeic keratoses (SKs) increases and may pose diagnostic difficulties. Furthermore, pigmented BCCs constitute important differential diagnoses to melanoma[63]. Differential diagnoses of hypo- or amelanotic melanoma may be any non-pigmented skin tumour (e.g. SCC and BCC).

Superficial spreading melanoma

Superficial spreading melanoma is the most common type of melanoma. It can evolve on any body site, but the most common sites are legs in females and the back in males. This melanoma type has a radial growth phase of varying duration before it becomes invasive[64]. Clinically it presents as a growing, flat, pigmented lesion that is becoming irregular in shape and colour (Fig. 8a). A nodular component may evolve as it becomes invasive.

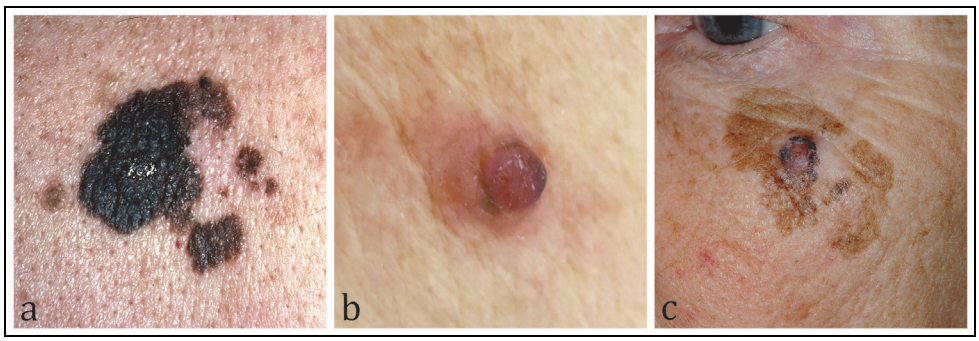

Figure 8. Melanoma.
a. Superficial spreading melanoma (SSM) presenting as a macular, irregular pigmented lesion. (Photo: M Bjellerup) **b**. Hypopigmented nodular melanoma (NM) presenting as a nodule with only sparse pigment. (Photo: I Ahnlide). **c**. Lentigo maligna melanoma (LMM) showing a large irregular, pigmented macular lesion with a nodular component indicating invasive growth. (Photo: M Bjellerup)

Nodular melanoma

Nodular melanoma seems to grow vertically from the beginning and invade the dermis without an *in situ* phase[65]. Patients with NM are commonly older and this melanoma type is more common in men and on the trunk[66]. It presents as a rapidly growing nodule, sometimes without any or with only sparse pigment (referred to as hypo- or amelanotic melanoma) (Fig. 8b). These lesions are often symmetrical in shape and may therefore cause diagnostic difficulties.

Lentigo maligna melanoma

Lentigo maligna melanoma arises in chronically sun-damaged skin and in its prolonged radial *in situ* growth phase is called lentigo maligna (LM). The *in situ* phase can last over years or even decades[67]. It starts as a pigmented, slow-growing macula becoming increasingly irregular. Subsequently, as it transits to a vertical invasive phase, it develops a palpable component[68,69] (Fig. 8c).

Acral lentiginous melanoma

This subtype comprises about 2–3% of all melanomas, but makes up a higher proportion of MM in darker-skinned individuals[70]. This type is found mainly on the nail bed, palms and soles and presents as a macular, lentiginous area around a raised, invasive component[71].

Prognosis

The prognosis of melanoma is dependent on the tumour stage at detection. The tumour thickness (Breslow thickness) is a crucial prognostic factor for melanoma[72], but the presence of ulceration or dermal mitoses has also been shown to be relevant[73].

For melanomas with a Breslow thickness of >1.0 mm, and for melanomas ≤1 mm and with ulceration, a sentinel lymph node biopsy (SLNB) is recommended[74]. In the SLNB procedure, the first regional lymph node that receives lymph from the primary melanoma site is identified, excised and histopathologically examined. If the sentinel node (SN) shows melanoma cells, a complete lymphadenectomy is considered. The result of the SLNB provides prognostic information. A positive SLNB indicates spread beyond the primary site and significantly lower 10-year survival rates are shown for patients with positive SLNB compared to those with negative SLNB[75].

Treatment

For melanoma or suspected melanoma, complete surgical excision and histopathological examination of the specimen is the treatment of choice. Further treatment should be carried out according to existing guidelines and depends on the results of the histopathological assessment[74].

Benign and premalignant skin lesions

Benign and premalignant diagnoses that are relevant differential diagnoses to skin cancer are presented below.

Non-melanocytic lesions

Actinic keratosis

Actinic keratoses are clinically presented as erythematous, scaly or hyperkeratotic macules, papules or plaques. Often, multiple lesions are present on chronically sun-damaged skin and AKs represent abnormal differentiation of keratinocytes in the epidermis. The lesions are usually small, 1–5 mm in diameter, but may vary considerably in size (Fig 9.). Occasionally the lesions exhibit pigmentation.

Relevant differential diagnoses are SCC *in situ* (Bowen's disease), SCC, and superficial BCC. For the pigmented, non- or minimally keratotic AK, LM is a relevant differential diagnosis both clinically and dermoscopically[76,77].

Actinic keratoses have the potential of developing into SCC. The individual risk of malignant progression in a single lesion is low, but AKs represent a marker of increased risk of SCC in a patient – however, based on existing data, the risk level is difficult to estimate[78,79].

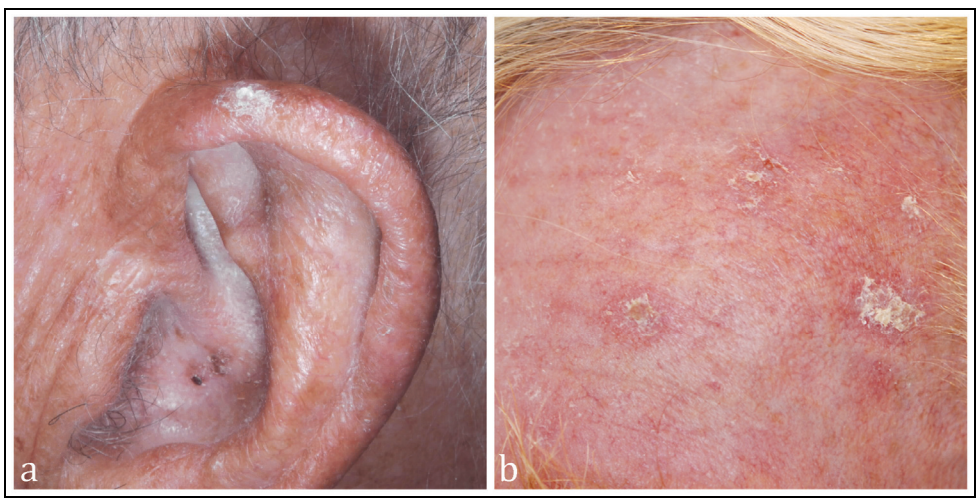

Figure 9. Actinic keratosis.
a. Keratosis on the helix **b.** Erythematous macules with keratoses on the forehead. (Photo: I Ahnlide)

Seborrhoeic keratosis

Seborrhoeic keratosis is one of the most common benign tumours of the skin. It is composed of epidermal keratinocytes and increases in prevalence with increasing age[80]. The lesions may occur on any body site but are most common on the trunk. When they first appear, the lesions are flat and they may remain superficial for a long time, but most commonly they become verrucous and vary in colour from yellow to black (Fig. 10). The differential diagnoses depend on the clinical appearance of the lesion and range from LM and pigmented AK to MM and SCC. Dermoscopy is a very valuable tool for distinguishing SK from malignant tumours.

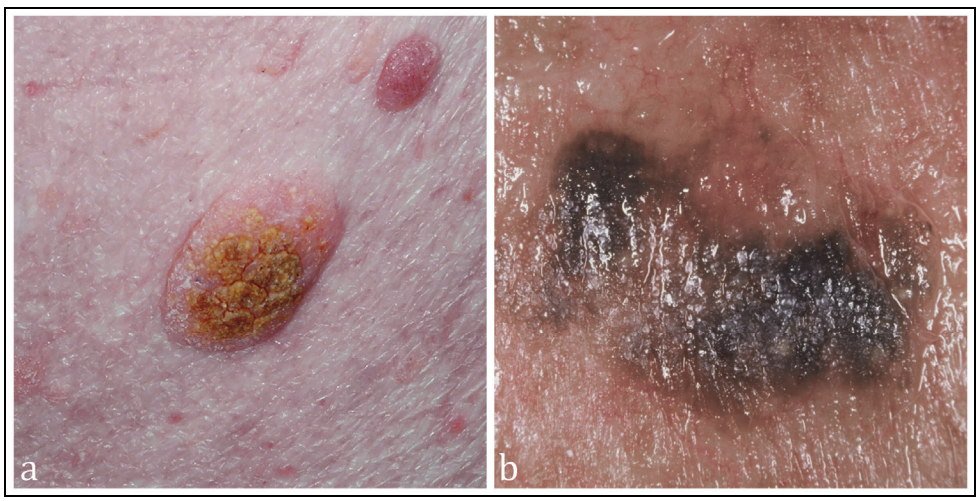

Figure 10. Seborrhoeic keratosis (SK).
a.Verrucous yellowish-brown SK. (Photo: I Ahnlide). b. Irregular darkly pigmented lesion, macroscopically difficult to discriminate from melanoma. Dermoscopy revealed features typical of SK. (Photo: M Bjellerup).

Melanocytic lesions

Benign melanocytic tumour – naevus/mole

A naevus is a benign proliferation of melanocytes (naevus cells) at the dermal-epidermal junction (Fig. 11). Naevi develop through childhood and the number of naevi increases significantly from puberty and is at its peak in midlife. Subsequently, in the second half of life, naevi involute and the total naevus count decreases[81]. The total naevus count is determined by both hereditary factors and, to a lower extent, environmental factors such as ultraviolet (UV) exposure[82,83].

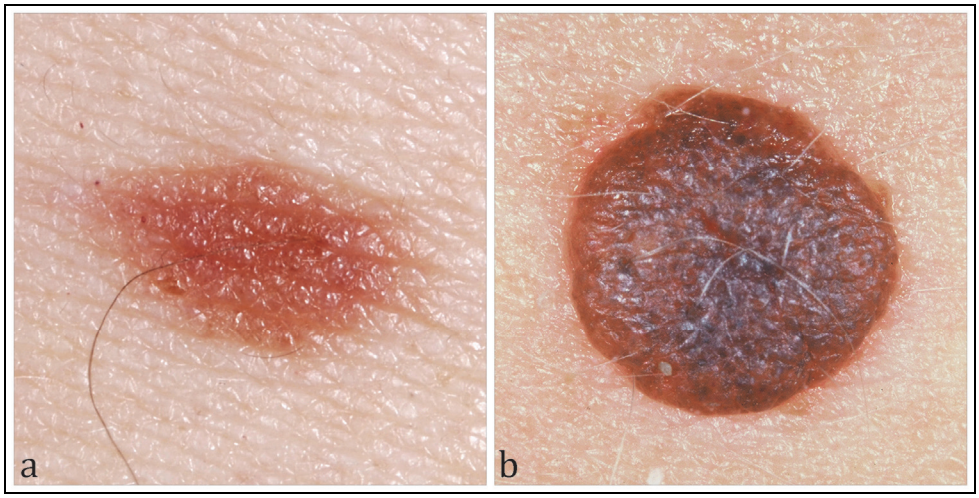

Figure 11. Common naevus (CN).
a. Macular symmetric reddish-brown naevus. (Photo: I Ahnlide) **b.** Dome-shaped symmetric brown naevus. (Photo: M Bjellerup).

Common naevus (common acquired naevus)

The common naevus (CN) can be categorized according to the histopathological localization of the naevus cells or nests in the skin, as junctional, compound or dermal naevus. In junctional naevus, the naevus nests are situated at the dermo-epidermal junction; in compound naevus they are located both at the dermo-epidermal junction and in dermis, while in dermal naevus they are seen only in the dermis. Naevi may also be classified according to the appearance on dermoscopy (Fig. 14)[84,85].

Spitz naevus

Spitz naevus is a naevus mainly seen in children, which exhibits distinctive histopathological and dermoscopic features. The classic Spitz naevus is a reddish-brown, rapidly growing nodule. The pigmented variant (also called "Reed naevus") is usually densely pigmented with a regular starburst pattern on dermoscopy. The differential diagnosis to melanoma can in some cases be difficult, both clinically, and dermoscopically and histopathologically[86].

Blue naevus

In this naevus variant the benign pigment-producing cells are located in the dermis. Clinically a blue, sometimes slightly raised lesion is seen, that dermoscopically shows a structure-less blue area[87].

Congenital melanocytic naevus

Congenital melanocytic naevi (CMNs) develop *in utero* and the majority are apparent at birth, whereas some grow and acquire melanin slowly and therefore do not become evident until later. This type of naevus is commonly classified, according to its predicted size in adulthood, into small (<1.5 cm), medium-sized (1.5–<20 cm), large (20–<50 cm) and giant (>50 cm). One reason for this classification is that the risk of developing malignancy, to some extent, is related to the size of the lesion[88].

Dysplastic naevus

The term dysplastic naevus (DN) is used as a histopathological description of a naevus that exhibits various degrees of structural changes or cellular atypia. The concept was introduced by Clark *et al*[89], who described four main features characterizing the DN: (1) atypical melanocytic hyperplasia; (2) melanocytes with cytological features characteristic of malignant melanocytes; (3) mesenchymal changes in the papillary dermis (eosinophilic fibroplasia); and (4) lymphocytic infiltrate. To make the diagnosis of DN more distinct with higher interobserver concordance, the World Health Organization (WHO) have proposed major and minor criteria for the histological diagnosis of DN. The major criteria are: (1) basilar proliferation of atypical melanocytes extending at least three rete ridges or "pegs" beyond the dermal component; and (2) organization of this proliferation into a lentiginous or epithelioid cell pattern. The minor criteria include: (1) presence of lamellar fibrosis or concentric eosinophilic fibrosis; (2) neovascularization; (3) inflammatory response; and (4) fusion of rete ridges. For the diagnosis of DN, both major and at least two minor criteria are required[90]. The grade of dysplasia is stratified into low, moderate, and severe. Interobserver concordance between pathologists regarding the diagnosis of DN based on the WHO criteria seems to be fairly high, however with lower concordance for the grade of dysplasia[90].

While there is substantial evidence that patients with DN are at increased risk for developing melanoma, there is a lack of evidence that DN is a true precursor of melanoma. In patients with DN, melanoma can also be found in connection to CN, suggesting that DN is a marker of increased risk rather than being a precursor at any higher risk than CN[91]. Since DN is a histopathological diagnosis, a prerequisite for the diagnosis is excision, which precludes further surveillance and development of the lesion. This makes it difficult to determine whether DN is a precursor of melanoma or not. As stated above, it seems that around 30% of melanomas arise from naevi, while 70% arise *de novo* and melanomas appear to arise from DNs and CNs in more or less equivalent proportions[92,93]. However, the risk of transformation of naevus to melanoma is low[91]. Tsao *et al* have estimated

the lifetime risk of any individual naevus (on a 20-year individual) transforming into melanoma being in the order of 1/3,000 in men and 1/10,000 in women[94].

The prevalence of DNs in the general population is not known; previous studies have found varying numbers. In a Swedish study, 40% of patients with a history of melanoma had histologically diagnosed DNs, compared with 8% in controls[91].

Most authors agree that DNs are and should be treated as benign lesions. Nevertheless no criteria exist to make a 100% safe distinction between severely dysplastic naevi and early melanomas. In these cases the term "dysplasia" expresses a diagnostic uncertainty. The same does not apply for the lower grades of dysplasia and the clinical significance of DNs with low or moderate dysplasia can therefore be questioned[95].

Atypical naevus

The term atypical naevus is a clinical description of a naevus with a clinical or dermoscopic picture that does not fit into the typical benign CN types (Fig. 12). The term also expresses a clinical diagnostic uncertainty as to whether the lesion is benign or malignant, since the lesions often share some of the clinical and dermoscopic criteria of melanoma, like asymmetry, several colours, several dermoscopic structures, size >5 mm in diameter.

There is a lack of correlation between the clinical diagnosis of atypical naevus, and the histopathological criteria for DN[96,97]. There is also considerable interobserver variability regarding the clinical diagnosis of atypical naevus[96].

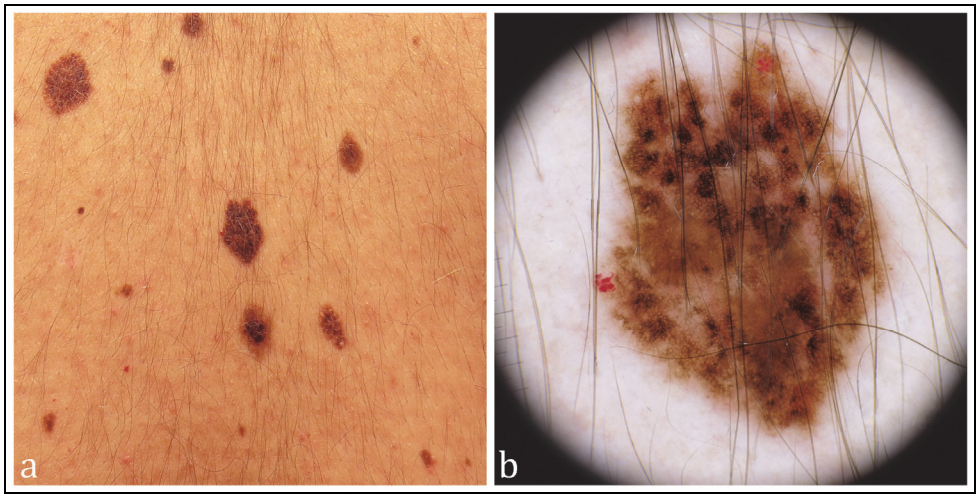

Figure 12. Atypical naevi
a. Patient presenting with several clinically atypical naevi. **b.** Dermoscopic picture of the naevus in the center of figure 12a showing a patchy atypical network. Histopathology showed moderately dysplastic naevus. (Photo: K Nielsen).

Treatment of skin cancer

The treatment of skin cancer has to be carefully considered and tailored to each case. To decide on the most suitable treatment, several patient and tumour-related factors must be taken into account, such as suspected tumour diagnosis and the need for complete excision with determination of tumour-free margins, the general health of patient, tumour size and site, side effects of the treatment, risk for incomplete clearance, need and possibilities for follow-up, recurrence risk, the risk that a recurrence might be missed by the patient or doctor (i.e. the degree of difficulty in detecting a relapse), as well as the risks associated with a possible recurrence.

All cases included in this thesis were surgically excised tumours. However, at our department different treatment options for skin cancer are available and used in an attempt to find the most optimal treatment in each case. The most common available treatment options are briefly covered below.

Surgical excision

Complete excision is the gold standard treatment for most skin cancers, including melanoma, invasive SCC and BCC (exceptions are described below). An

advantage of complete excision, compared with e.g. destructive techniques, is that the specimens can be sent for histopathological examination for confirmation of diagnosis and assessment of margins. In most cases, skin tumours can be excised under local anaesthetic by a simple elliptical excision, and the defect can be closed and sutured primarily. In a previous study from our clinic, based on 2,448 excisions of skin tumours, about 50% of which were localized to the head and neck area, it was possible to excise just over 85% with a simple elliptical excision sutured primarily[98]. The recommended macroscopic surgical margins depend on the diagnosis of the excised tumour and a correct preoperative diagnosis may therefore be important for the outcome[44,99,100]. With conventional histopathological examination, only a small part of the surgical margins are examined. This is relevant, especially for tumours with irregular and ill-defined borders (e.g. highly aggressive BCCs) since there is a potential to miss incomplete excisions.

Mohs surgery

Mohs surgery, also called Mohs micrographic surgery (MMS)[45], is a specialized surgical technique of staged tumour resection, developed to enable peroperative examination of all surgical margins. A circular saucer-shaped excision of the tumour is made. The specimen is then mounted and freeze-sectioned horizontally so that all margins, both lateral and deep, can be examined. The specimen is thoroughly marked and corresponding markings are made on the patient, enabling localization and mapping of residual tumour. Re-excisions are continued until all margins are free and the defect can then be closed. The excisions are made under local anaesthesia and can usually be completed during 1 day. Advantages of MMS, compared with common surgical excision, are high cure rates[101,102] and that a minimal amount of normal tissue at the tumour margins is excised. Mohs surgery can be used for various tumours, but in Sweden the method is reserved mainly for excision of highly aggressive or recurrent BCCs in sensitive areas where tissue sparing is essential[103,104].

Curettage and cautery

Curettage and cautery has for many years been widely used for removal of skin cancer[50]. There are different protocols for the technique, but all are based on the same principle. The treatment is done under local anaesthesia and the technique includes thorough debulking of the tumour by curette. Thereafter electric cautery is applied to the skin defect, to destroy residual tumour cells and achieve haemostasis. Curettage and cautery may be used for treatment of low-risk skin cancer (e.g. superficial BCC and SCC *in situ*) in low-risk locations[28,44]. The results

are heavily dependent on the experience and skill of the physician as well as the selection of cases appropriate for the treatment[44].

Cryosurgery

Cryosurgery via liquid nitrogen uses extremely low temperatures (-50 to -60ºC tissue temperature) to cause cell death and tumour destruction. The technique is widely used for treatment of AK and low-risk BCC and SCC *in situ*[28,49]. Many variations of the technique exist; a proper technique is crucial for the result. Double freeze cycles are generally more effective, but for superficial BCC on the trunk, one cycle may be sufficient[51]. A combination of thorough curettage and a double freeze/thaw cycle has shown low risk of recurrence for non-morpheiform BCCs on nose and ear as well as elsewhere on the face and on the scalp[46-48].

Photodynamic therapy

Photodynamic therapy refers to a treatment where a photosensitizer is activated by visible light. In dermatology, mainly 5-aminolaevulinic acid (ALA) or its ester, methyl aminolaevulinate (MAL), is used in the form of a topical cream. The cream is applied to the skin and occluded for a period of time, usually around 3 hours. The aminolaevulinic acid is involved in cellular haem synthesis and the photoactive protoporphyrin IX (PpIX) is endogenously formed. The formation of the PpIX is more rapid in tumour cells than in normal cells, thus contributing to the selective treatment effect on cancer cells, and is ascribed several factors such as altered skin barrier in tumours, enzyme differences and increased blood flow. The skin is thereafter illuminated with light. Various light sources are available; in Europe, red light with a peak wavelength of 630 nm is often used[55]. The reaction between PpIX and the light gives rise to reactive oxygen species (ROS) causing cell necrosis[54,57]. Photodynamic therapy is suitable for treatment of superficial lesions, since the effect is restricted by both penetration of the ALA/MAL cream and the light (with red light having the deepest penetration, of up to 5 mm). Photodynamic therapy is considered a first-line therapy option for superficial BCC and SCC *in situ* as well as for AK. Clearance rates for SCC *in situ* and sBCC are comparable, around 80–90%[44,52,54,55,57,58]. The benefits of PDT are good cosmesis, that it is tissue-sparing, and that it is suitable for treatment in slow-healing sites (e.g. lower leg).

Imiquimod

Imiquimod is administered as a topical cream whose mode of action is primarily based on activation of the innate immune system through toll-like receptors 7 and 8, resulting in antitumoural and antiviral cellular immune response[105]. It is approved for treatment of AK and sBCC. The recommended treatment regimen for sBCC is once daily, 5 days a week, for 6 weeks. The treatment success rate for small primary sBCCs is about 80–90%[52,56,58]. In a multi-centre randomized controlled trial (RCT), imiquimod was inferior to surgery in terms of clinical success, defined as absence of initial treatment failure or absence of signs of recurrence at 3 years from start of treatment (84% in the imiquimod group compared with 98% in the surgery group)[53]. It was, however, concluded that imiquimod might "still be a useful treatment option for small low-risk superficial or nBCC dependent on factors such as patient preference, size and site of the lesion, and whether the patient has more than one lesion"[53]. A literature review found comparable treatment success rates for sBCC for imiquimod and PDT[58].

Fluorouracil

Fluorouracil, also known as 5-FU, is a pyrimidine analogue that acts as an antimetabolite and inhibits DNA synthesis. It can be administered topically, usually as 5% cream. Fluorouracil is currently not commercially available in Sweden, but can be prescribed after issuing a special licence for an individual patient.

Fluorouracil can be used for treatment of AK, sBCC and SCC *in situ*. Different treatment protocols exist, but it is commonly applied once or twice daily for 2–8 weeks, depending on the diagnosis. In a single-blind RCT on nBCC and sBCC comparing 5-FU with MAL-PDT, at 3 and 12 months' follow-up topical 5-FU (5%) had a clearance rate of 80.1% compared with 83.4% for MAL-PDT[53]. In an RCT on SCC *in situ*, 5-FU showed significantly lower clearance rates at 12 months (48%) compared with PDT (82%)[59].

Histopathology of skin tumours

Histopathological diagnosis is the gold standard for diagnosis of skin cancer. It is the reference method against which the results of other diagnostic techniques are compared. There are defined criteria for the histopathological diagnosis of different skin tumours. However, the assessment of each specimen is a subjective weighing and interpretation by the pathologist of the different criteria seen and the

assessment is subject to interobserver variability[106-108]. Furthermore, different classification systems exist, e.g. for subtype of BCC[38,106,109,110].

For the histopathological diagnosis, a biopsy of the lesion is taken, as either an incisional or a complete excisional biopsy. The advantages of an excisional biopsy are that diagnosis and treatment are carried out in the same procedure and that the narrowest margins to the tumour can be determined. Furthermore, complete excision is favourable in tumours where the histopathological features vary throughout the lesion as well as in lesions where the architecture is crucial for achieving a correct diagnosis. With pigmented skin lesions, complete primary excision is highly recommended to achieve a correct diagnosis. For the histopathological examination of an elliptical excisional specimen, transverse blocks are taken for further sectioning. The recommended intervals between blocks depend on the suspected diagnosis.

Incisional biopsies are merely diagnostic. They are carried out to confirm diagnosis when treatments other than complete surgical excision are planned (e.g. PDT, imiquimod, 5-FU) or when needed to plan the surgical procedure.

Common incisional biopsies are punch or shave biopsies. Since only a small part of the lesion is examined, the final diagnosis of e.g. BCC subtype cannot always be determined by an incisional biopsy[111-113]. In one study comparing punch and shave biopsies with subsequent excision of the tumour, punch biopsies accurately identified 81% of BCCs while shave biopsy identified 76%[114].

Dermoscopy

Dermoscopy is a non-invasive technique that allows visualization of structures of the superficial parts of the skin that are not visible to the naked eye. Microscopy of the skin surface has been used for diagnostic purposes in medicine since the 17th century. One of the first clinicians to show the usefulness of dermoscopy for assessment of pigmented lesions was MacKie[115]. The first hand-held skin microscope (dermatoscope/dermoscope) was introduced in 1989[116]. The devices have since then developed, but are still using the same principles based on optical magnification, a built-in light source, and liquid immersion. The liquid reduces reflection in the cornified layer and makes the skin surface more translucent. The hand-held devices give a 10–20x magnification and the technique allows visualization of structures within the epidermis, the dermo-epidermal junction and the superficial dermis. Polarized dermoscopes were introduced in 2000. The polarization allows deeper structures of the skin to be seen under the dermoscope without the need for liquid immersion. There is also no need for direct contact between the device and the skin[117].

Today, dermoscopy is widely used in clinical routine and it has been shown to be very useful for examining pigmented and non-pigmented skin tumours[118].

Dermoscopy of pigmented skin lesions

The two-step algorithm

The dermoscopic diagnosis of pigmented lesions is based on a two-step procedure[119] (Fig. 13). In the first step the lesion is judged as being melanocytic or not. If the lesion is classified as melanocytic in the first step, further analysis is done in the second step to classify the lesion as benign, suspect or malignant. For the classification in the second step, pattern analysis or simplified algorithms can be used.

Step one

Step one starts with a search for dermoscopic criteria for melanocytic lesions, i.e. a pigment network, branched streaks, a negative network, aggregated globules, homogeneous blue pigmentation, a pseudo-network (face) or parallel pattern (palms of the hands, or the soles and mucosa). If any of these structures are present the lesion is judged to be melanocytic, leading on to step two. An exception to this rule is dermatofibroma, which in typical cases exhibits a peripheral network and a central, scar-like area.

If a lesion does not meet the criteria of melanocytic lesions, it is further analysed for criteria for BCC and SK. If these criteria are not met, the next step is to look for criteria for a vascular lesion like a haemangioma or angiokeratoma, and then for morphology and distribution of blood vessels specific for non-melanocytic lesions or specific blood vessels in melanocytic lesions.

If none of the aforementioned criteria match the lesion, the lesion should be excised to exclude melanoma.

Step two

If the lesion in step one is determined to be of melanocytic origin, the next step is to determine whether it is benign or malignant. For this, pattern analysis or simplified algorithms can be used.

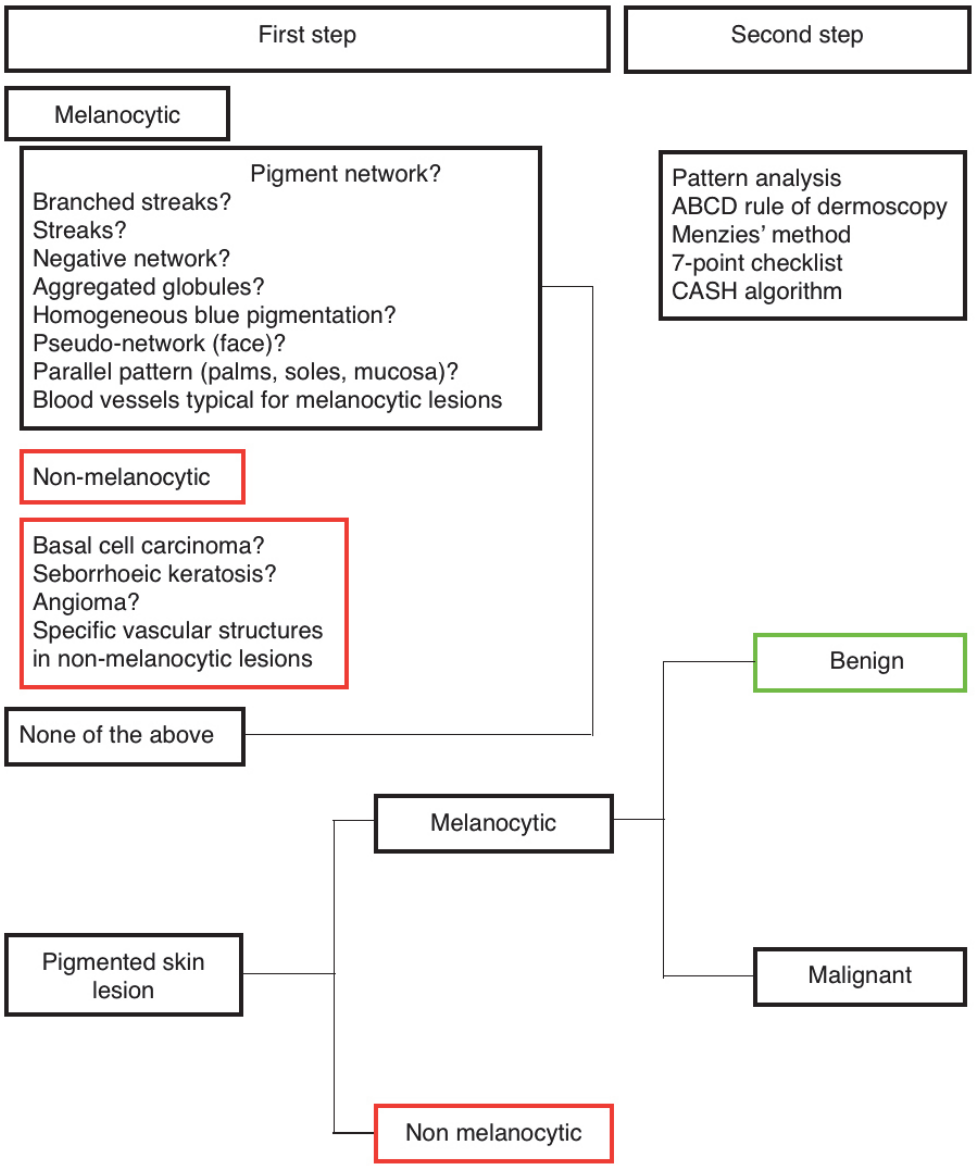

Figure 13. The two-step algorithm.
Step one starts with a search for dermoscopic criteria for melanocytic lesions. If a lesion does not meet the criteria of melanocytic lesions, it is analysed for criteria for basal cell carcinoma, seborrhoeic keratosis or vascular lesion and then for blood vessels specific for non-melanocytic lesions or specific blood vessels in melanocytic lesions. If none of the aforementioned criteria match the lesion, the lesion should be excised to exclude melanoma. **Step two:** For a lesion that in step one is determined to be of melanocytic origin, the next step is to determine whether it is benign or malignant.

Pattern recognition

The classic approach for diagnosing pigmented skin lesions is simultaneous assessment of the dermoscopic morphology and different dermoscopic structures of a given lesion[120]. This approach is known as pattern recognition. Pattern recognition includes a subjective evaluation of criteria, for which, experience is needed[121]. The clinician has to recognize the different patterns of benign naevi (Fig. 14) or whether a lesion deviates from those benign patterns, as well as recognize melanoma-specific patterns[85].

Dermoscopic patterns of benign naevi

Clinically and dermoscopically banal benign naevi or common naevi are naevi that have symmetry of colour and structures[85]. In most individuals the majority of naevi show a specific similar pattern[85,122]. Recognition of this pattern is helpful in the assessment of individual lesions, since the lesion of concern can be judged in the frame of the patients' other naevi[123].

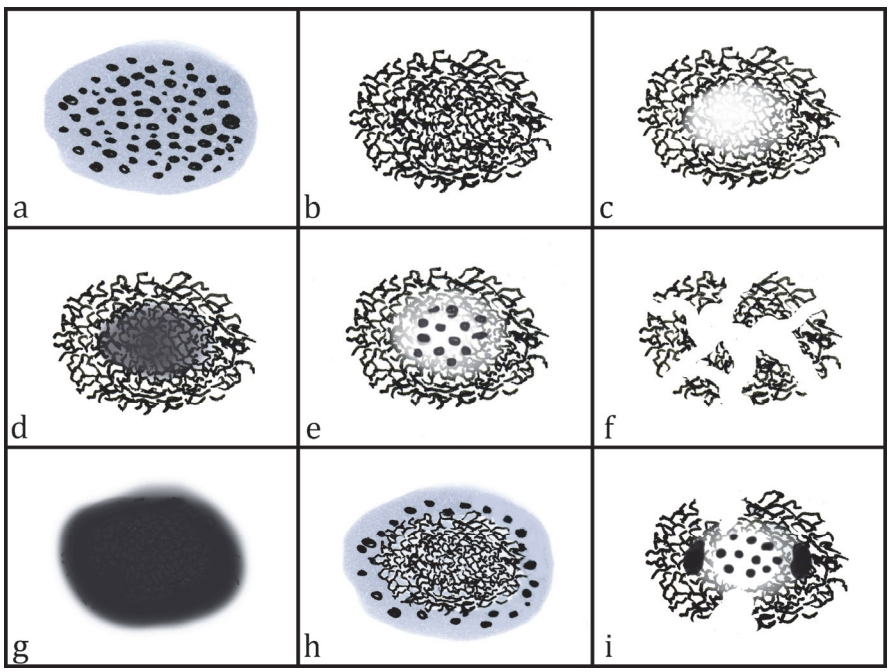

Figure 14. Dermoscopic patterns of benign naevi.
Schematic picture of typical dermoscopic patterns seen in benign naevi. **a.** Globular. **b.** Reticular. **c**. Periferal reticular with central hypopigmentation. **d.** Periferal reticular with central hyperpigmentation. **e.** Periferal reticular with central globules. **f.** Patchy reticular. **g.** Structureless/homogeneous. **h.** Periferal globules and central reticular. **i.** Symmetric multicomponent. (Artwork: Alma Ahnlide, adapted from Marghoob AA *et al.* The beauty and the beast sign in dermoscopy. *Dermatol Surg* 2007; **33**: 1388-91.)[85]

Dermoscopic algorithms

To simplify learning and use of dermoscopy for non-experts, several algorithms for the second step of dermoscopic diagnosis have been developed over the years, including the ABCD rule of dermoscopy, Menzies' method, the 7-point checklist of dermoscopy and the CASH algorithm[124-127]. The different dermoscopic algorithms are based on the simple fact that the dermoscopic image of melanoma typically is more chaotic than that of non-melanoma. The assessment is based on asymmetry and specific structures and colours seen more frequently in melanoma.

This thesis will focus on the ABCD rule of dermoscopy and the other algorithms will only be covered briefly.

The ABCD rule of dermoscopy

The first attempt to facilitate dermoscopic diagnosis for non-experts was the ABCD algorithm, introduced by Stolz *et al* in 1994[124]. In the algorithm a semi-quantitative scoring system based on asymmetry, border, colour, and different dermoscopic structures leads to a total dermoscopy score (TDS) for each lesion (Fig. 15). The higher the score, the higher the risk of the lesion being a melanoma. The ABCD dermoscopy algorithm has the benefit of being comparatively easy to memorize and also being easy to teach to physicians not experienced in dermoscopy.

For some lesions, the ABCD rule is not applicable, e.g. papillomatous naevus, Spitz naevus, and congenital naevus as well as lesions in special locations like the face, palms, soles, and mucosa. These lesions should be assessed using pattern recognition. Furthermore, the ABCD algorithm does not seem to apply to small diameter lesions[128].

Asymmetry

A lesion is bisected by two 90° axes that are positioned to produce the lowest possible asymmetry score. The score is 0–2 depending on whether there is no asymmetry (score 0), or asymmetry on one (score 1) or two axes (score 2). The shape of the lesion as well as colour and structural components are considered.

Border

The lesion border is divided into eighths. A gradual indistinct cut-off at the periphery of the lesion has the score 0, whereas a sharp, abrupt cut-off gets a score of 1. Thus, the maximum border score is 8 and the minimum is 0.

Colour

The number of colours present in the lesion are counted, with a maximum of six colours. Possible colours are white, red, light brown, dark brown, blue-grey, and black. White is only considered if the area is lighter than the adjacent skin. Red vascularized areas in melanocytic naevi are scored. The maximum colour score is 6 and the minimum score is 1.

Dermoscopic structures

Five dermoscopic structures are considered: network, structureless (or homogeneous) areas, branched streaks, dots, and globules. A pigment network is a regular light to dark brown fine network thinning out at periphery. Branched streaks or atypical pigment network is a broken-up or fragmented black, brown, or grey network with irregular holes and thick lines. Dots are small, round structures that may be black, brown, grey or bluish and are <0.1 mm in diameter, whereas globules are brown, black, blue-grey or red round to oval structures with a diameter of >0.1 mm.

Structureless (or homogeneous) areas are counted if they cover >10% of the lesion. Branched streaks and dots are counted only if more than three are present, whereas globules are considered if two or more are present. Red dots and globules are scored; red streaks due to vessels are not.

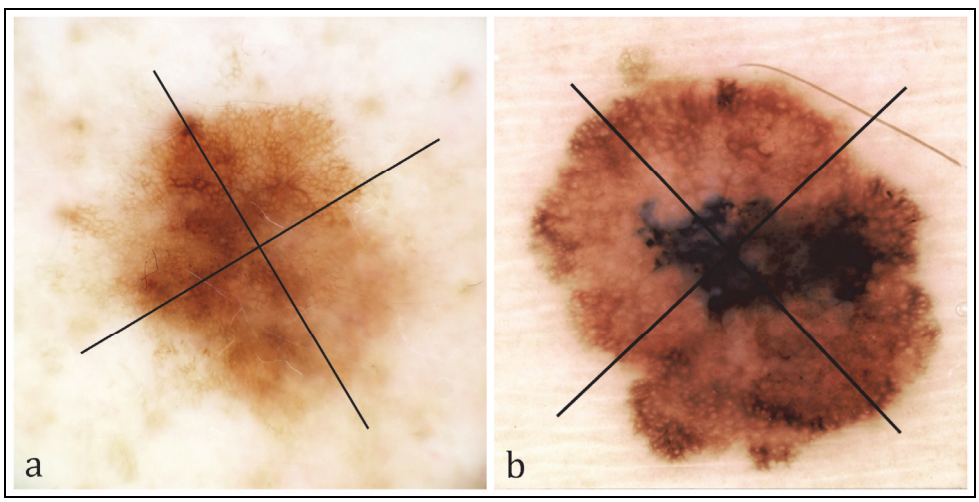

Figure 15. The ABCD rule of dermoscopy
a. Pigmented lesion with asymmetry in two axes, no sharp cut-off, two colours, (light brown and dark brown) and three dermoscopic structures (network, branched streaks (atypical network) and structureless). (**TDS**=2x1.3+0x0.1+2x0.5+3x0.5=**5.1**). Histology showed a dysplastic naevus. (Photo: I. Ahnlide). **b.** Pigmented lesion displaying asymmetry on two axes, a sharp cut-off in five segments, five colours (white, light brown, dark brown, blue-grey, and black) and five dermoscopic structures (network, structureless areas, branched streaks, dots and globules (in the center)). (**TDS**=2x1.3+5x0.1+5x05+5x0.5=**7.8**). Histology showed a melanoma *in situ.* (Photo: M Bjellerup).

Total dermoscopy score

The separate scores for asymmetry, border, colour, and dermoscopic structures are multiplied by the weight factor (see Table 1) and then added together, resulting in a TDS. According to Stolz *et al*[124], a TDS of 4.74–5.45 indicates a suspicious lesion and a lesion with TDS ≥5.45 is highly suspicious for melanoma.

Table 1. Total dermoscopy score (TDS).
The separate scores for asymmetry, border, colour, and dermoscopic structures are multiplied by the weight factor and then added together.

Dermoscopic criterion	Weight factor	Min-max scores
Asymmetry (0–2)	1.3	0–2.6
Border (0–8)	0.1	0–0.8
Colour (1–6)	0.5	0.5–3.0
Dermoscopic structure (1–5)	0.5	0.5–2.5
Total dermoscopy score	1.3A+0.1B+0.5C+0.5D	1.0–8.9

Menzies' method

Menzies' method was introduced in the mid-1990s and is based on eleven features, two that are negative and nine that are positive for melanoma[125,129]. For the diagnosis of melanoma, a pigmented lesion must have neither of the negative and at least one of nine positive features.

Negative features – both features must be absent for the diagnosis of melanoma

1. Symmetry of pattern, i.e. symmetry of all pattern structures including colour along any axis through the centre of a lesion (this does not require symmetry of shape).
2. A single colour (a single colour excludes the diagnosis of melanoma). The colours scored are black, grey, blue, red, dark brown, and tan.

Positive features – at least one feature must be found for the diagnosis of melanoma

1. Blue-white veil
2. Multiple brown dots
3. Pseudopods
4. Radial streaming
5. Scar-like depigmentation
6. Peripheral black dots/globules
7. Multiple (five to six) colours

8. Multiple blue-grey dots
9. Broadened network

The 7-point checklist

The 7-point checklist was proposed by Argenziano *et al* in 1998[126]. It is based on seven features associated with melanoma. In the original paper it was proposed that the features be divided into major and minor criteria, as follows.

Major criteria

1. Atypical pigment network
2. Blue-white veil
3. Atypical vascular pattern

Minor criteria

1. Irregular streaks
2. Irregular dots/globules
3. Irregular blotches
4. Regression structures

The major criteria score 2 points each, while the minor criteria each score 1 point. For the diagnosis of melanoma, a score of 3 or more is required. In the revised, simplified 7-point checklist introduced in 2010, the criteria are not divided into major and minor. Moreover, the threshold is lowered to only one criterion required for melanoma to be considered. This revision was proposed to increase the sensitivity for melanoma[130].

CASH algorithm

The colour, architecture, symmetry, homogeneity (CASH) algorithm was introduced in 2007[127]. This algorithm adds architectural disorder, a feature not used in any other algorithm.

Colour – six colours are considered (light brown, dark brown, black, red, white, blue), each assigned 1 point (1–6 points).

Architectural disorder – stratified into no/mild, moderate, and marked disorder (0–2 points).

Symmetry – biaxial, mono-axial, and none (0–2 points)

Homogeneity/heterogeneity (based on the number of dermoscopic structures) – seven structures are considered (network, dots/globules, blotches, regression, streaks, veil (blue), polymorphous vessels), each assigned 1 point (1–7 points).

The threshold is at 8 points; a score of 8 or greater classifies the lesion as suspicious for melanoma.

Chaos and clues

The "Chaos and Clues" algorithm was designed to be applied to any pigmented skin lesion to detect any type of malignancy (both melanocytic and non-melanocytic)[131].

Chaos

In the first step the lesion is screened for asymmetry of structure or colour ("chaos").

Clues to malignancy

In the second step the lesion is screened for clues to malignancy. If one or more of the clues are present, the lesion is deemed to require a biopsy to exclude malignancy. There are eight clues to malignancy: eccentric structureless area, thick reticular or branched lines, grey or blue structures, peripheral black dots or clods, segmental radial lines or pseudopods, polymorphous vessels, white lines, and parallel lines on ridges (acral lesions).

Which is the best dermoscopic algorithm?

Which dermoscopic diagnostic approach has the best diagnostic accuracy?

Several studies have addressed the question of which of the algorithms has the best diagnostic accuracy[126,132-135]. A meta-analysis in 2002 showed no significant difference between different algorithms[136]. In a consensus meeting among experts in 2003 addressing the same question, the pattern analysis was judged to have the best diagnostic performance, while the simplified algorithms were deemed to show similar sensitivity but lower specificity[119].

Teaching and learning dermoscopy

Dermoscopy needs training to be useful. Dermoscopy compared with naked-eye examination increases the sensitivity for diagnosing melanoma in experts (average gain 10%), while it decreases the sensitivity in non-experts (average loss 10%)[121]. Short-term formal training has been proven beneficial for dermatologists[137] as well as non-dermatologists[138,139].

Which method should be used for training dermoscopy?

Use of simplified algorithms such as the ABCD rule of dermoscopy seems to enhance diagnostic abilities for beginners, but not for experts[140]. Carli *et al*

compared three different diagnostic methods taught to residents in dermatology (pattern analysis v. two simplified algorithms: the ABCD rule and 7-point checklist). They found that the pattern analysis yielded the best diagnostic ability[133]. In an Australian study, non-experts were trained in four different diagnostic methods: Menzies' method, the ABCD algorithm, the 7-point checklist, and pattern analysis. Whereas Menzies' method showed the highest sensitivity, pattern analysis showed the highest specificity, but in conclusion all algorithms performed well[134].

Dermoscopy of basal cell carcinoma

Dermoscopy has primarily been used for diagnosing pigmented skin lesions, and initially dermoscopy of BCC was focused on distinguishing pigmented BCC from melanoma[63]. However, dermoscopy has shown over time to be valuable also for the diagnosis of non-pigmented tumours, as well as for inflammatory conditions[141,142]. The development of non-contact polarized dermoscopy has been important since some dermoscopic features can be better seen under polarized dermoscope examination. The global pattern and morphology of blood vessels are crucial keys to the diagnosis of non-pigmented skin lesions and without the pressure from the dermoscope's glass plate, blood vessels are more easily seen. In addition, features have been described which can only be seen under polarized light, such as crystalline structures[143].

Menzies *et al* studied dermoscopic features to differentiate between melanoma, pigmented BCCs and benign naevi and proposed a method for diagnosis of pigmented BCCs[63]. According to this method, for the diagnosis of BCC, one negative feature (absence of a pigmented network) and at least one positive feature (presence of ulceration, large blue-grey nests, multiple blue-grey globules, maple-leaf-like areas, spoke wheel areas, or arborizing telangiectasias) are needed.

Dermoscopy and subtype of basal cell carcinoma

Studies on correlation between dermoscopic features and subtype of BCC have shown that shiny white to red areas, short fine telangiectasias, multiple small ulcerations and leaf-like or spoke-wheel-like pigmentation are indicative of sBCC, whereas ulceration, large blue-grey ovoid nests, and arborizing telangiectasias indicate nBCC[144-148].

In a retrospective study based on photos of 77 sBCCs and 258 non-sBCCs, Lallas *et al* assessed the accuracy of dermoscopic criteria for differentiating sBCC from other subtypes. They found that maple leaf-like areas and short fine superficial telangiectasias in the absence of arborizing vessels, blue-grey ovoid nests, and

ulceration are highly predictive of sBCC. The authors proposed an algorithm for discriminating sBCC from nBCC based on their results[147].

In a study of photos of 501 histopathologically proven sBCCs and nBCCs (66.9% and 33.1%, respectively), Suppa *et al* aimed to describe the dermoscopic variability of BCC according to subtype and anatomic location[148]. They confirmed previous findings, that arborizing telangiectasias are more likely to be found in nBCCs, while leaf-like areas, short fine telangiectasias, small erosions, concentric structures and spoke wheel areas are detected more frequently in sBCCs. Furthermore, they found an association between body site and certain dermoscopic features independent of the clinical type of BCC. Arborizing telangiectasias were independently associated with facial BCCs and short fine telangiectasia, small erosions and spoke wheel areas were independently associated with truncal BCC. They also found that the more palpable the sBCC, the higher the likelihood that it would display dermoscopic characteristics of nBCC, such as arborizing vessels.

Demirtasoglu *et al* evaluated the correlation between dermoscopic and histopathological features in pigmented BCCs. Pigmentation was seen within both tumour nests and stroma, as well as in hyperplastic melanocytes[149]. In another study on the correlation between dermoscopic and histopathologic features, Tabanlioglu Onan *et al* found that maple leaf and spoke wheel areas correspond to multifocal tumour nests in papillary dermis, while large, blue-grey ovoid nests correspond to well-bordered pigmented tumour nests with small buddings at the periphery localized to the papillary and/or reticular dermis[150].

Summary of clinical, dermoscopic and histopathological findings in different subtypes of basal cell carcinoma

Nodular basal cell carcinoma

Clinical presentation

Nodular BCC clinically presents as a slow-growing papule or nodule, often ulcerated, with visible ectatic vessels.

Dermoscopy

The dermoscopic hallmark of nBCC is arborizing vessels. If pigment is present it can often be seen as round or oval, blue-grey masses called ovoid nests (Fig. 16).

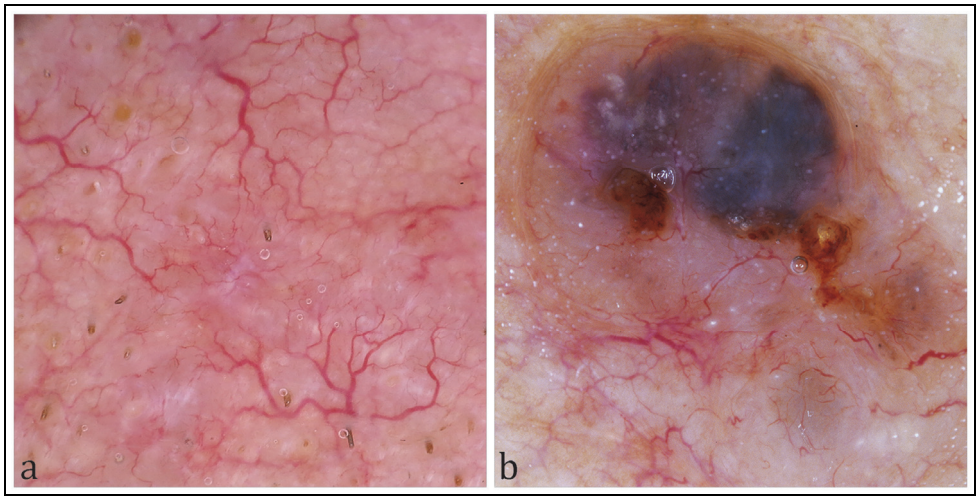

Figure 16. Nodular basal cell carcinoma (nBCC)
Dermoscopic picture showing arborizing vessels in a large nBCC (a) (Photo: J Nilsson) and blue-grey ovoid nest (b) (Photo: I Ahnlide).

Histopathology

Histologically, the tumour is well circumscribed, with sharply delineated tumour masses consisting of basaloid cells with palisading of the cells at the periphery.

Superficial basal cell carcinoma

Clinical presentation

Superficial BCC clinically presents as a macular or slightly infiltrated patch or plaque, usually red or violaceous in colour, sometimes with small crusts on the surface.

Dermoscopy

The dermoscopic hallmarks of sBCC are leaf-like or spoke-wheel-like pigmentation, short fine telangiectasias, multiple erosions, and shiny, red-white areas (Fig. 17).

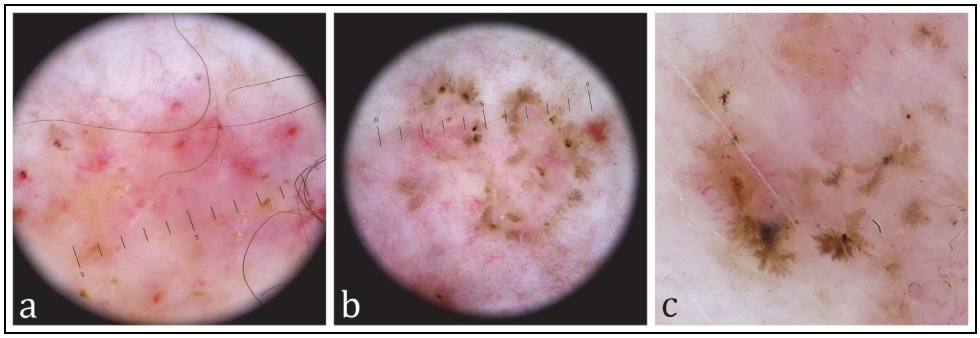

Figure 17. Superficial basal cell carcinoma (sBCC)
Dermoscopic pictures of sBCCs showing multiple erosions (a), leaf-like pigmentation (b) (Photo: I Ahnlide) and spoke-wheel-like pigmentation (c) (Photo: A Steinman).

Histopathology

Histologically, sBCC consists of small tumour masses with connection to the epithelium.

Intermediately aggressive basal cell carcinoma

Clinical presentation

Tumours with intermediate features usually of both nBCC and more invasive BCC are categorized as intermediately aggressive. Clinically they present as an infiltrated, nodular or plaque-like, usually shiny white or red tumour.

Dermoscopy

The dermoscopic features of intermediately aggressive BCC are not yet fully described, nor how to dermoscopically discriminate this subtype from other subtypes. Arborizing vessels may be seen, but they are usually finer than in nBCC and the background is usually white-red and structureless[151] (Fig. 18).

Figure 18. Infiltrating basal cell carcinoma (BCC).
Dermoscopic picture of an infiltrating BCC showing a white-red, structureless background, fine arborizing vessels and ulceration. (Photo: I Ahnlide)

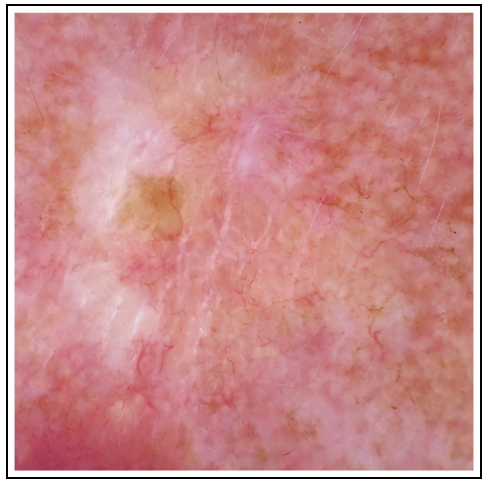

Figure 19. Highly aggressive basal cell carcinoma (BCC).
Dermoscopic picture of a highly aggressive BCC showing a diffuse white, structureless background and fine arborizing vessels. (Photo: J Nilsson)

Histopathology

Histologically the tumour has a more invasive growth pattern compared with nBCC, but the tumour strands are not as thin as in the morpheiform BCC.

Highly aggressive basal cell carcinoma

Clinical presentation

Highly aggressive BBCs present clinically as sclerotic plaques in the skin. The exact borders of the tumour are usually extremely difficult to visualize.

Dermoscopy

The specific dermoscopic features of morpheiform BCC are not studied in larger series, but a whitish background is often seen, sometimes with fine, scattered arborizing vessels[151] (Fig. 19).

Histopathology

Histologically, the tumour is invasive, with thin tumour strands, sometimes only a few cells wide, infiltrating deep into the tissue and with a fibrous reaction in the surrounding tissue.

Dermoscopy of squamous cell carcinoma

Dermoscopy of squamous cell carcinoma *in situ*

The dermoscopic characteristics of SCC *in situ* are glomerular or dotted vessels arranged in clusters and in combination with surface scales[142].

Dermoscopy of invasive squamous cell carcinoma

On dermoscopy, invasive SCC shows irregular vessels (dotted, glomerular, linear–irregular) often in combination with ulceration, central keratin crusting or scales[142].

The diagnostic process

In the process of arriving at a plausible diagnosis, two different paths are thought to underlie the intellectual processes. Analytical processing means that a diagnosis is achieved by analysis of clinical signs, features and symptoms presented. Weighing and analysing these different clues will eventually result in a plausible diagnosis[152]. In non-analytical processing, by contrast, a case is evaluated in the context of all previously encountered cases and the diagnosis is achieved through similarity to previous cases. In clinical practice both these processes are used simultaneously, and depending on the complexity of the condition, either process is activated. The automation of certain procedures is crucial, as this will free up cognitive resources to deal with more complex situations where the slower and more demanding analytical approach is needed[153].

The non-analytical processing (pattern recognition) will start immediately when a skin condition is presented and a diagnostic hypothesis begins to take shape. Every attempt to apply a more analytical approach to the condition will be influenced by the first impression and the first diagnostic hypothesis. When evaluating the diagnostic accuracy of different rules or algorithms, it has to be kept in mind that the first impression will influence the evaluation and even the perception of the presence or not of certain criteria for the diagnosis[154].

The clinical information pertaining to the lesion, and the patient history will also affect the diagnostic process. In a study on expert radiologists, another image-based diagnostic specialty, it was found that when clinical information was provided with a picture, not only the overall judgment of the diagnosis, but also the assessment of the presence or not of certain criteria was influenced[155].

When using the dermoscope, the basic principles described for the diagnostic process apply. The non-analytical, heuristic approach will immediately be activated when the clinician is confronted with the dermoscopic picture. Moreover, by the application of the dermoscope to the skin lesion, the clinician is forced to slow down and use a more analytical approach. Dermoscopy thereby gives the clinician an opportunity to reconsider the diagnosis made with the naked eye.

> *A critical element of becoming an expert is accruing the vast experience that enables experts to recognize patterns effortlessly most of the time – and to recognize, as well, when the signs and symptoms do not fit a pattern at all.*[156]

Aims of the thesis

The overall aims of this thesis were to study the accuracy, among dermatologists, of the diagnosis of skin cancer and the effects of using algorithms in the diagnostic process. Specific research questions asked in each study are detailed below.

Study I

How accurate is the preoperative clinical diagnosis of skin cancer? What kind of errors do we make?

Study II

How efficient is the diagnosis of melanoma in terms of number of excised pigmented lesions per excised melanoma (i.e. number needed to excise (NNE)), and NNE evaluated in relation to the patient's age, sex, and tumour site as well as changes over time?

Study III

How accurate is the diagnosis of pigmented skin lesions in relation to the dermatologists' self-assessed confidence in the clinical diagnosis and use of a diagnostic algorithm for dermoscopic melanoma diagnosis, the ABCD rule of dermoscopy?

Study IV

How accurate is the preoperative prediction of subtype of BCC in clinical practice?

Does dermoscopic examination enhance the accuracy of the prediction of subtype of BCC and specifically the prediction of sBCC v. non-superficial BCC? The final aim was to find the best predictors for sBCC in our material consisting of a population-based selection of patients with predominantly fair skin types.

Materials and methods

Background data

The studies were performed at the Department of Dermatology at Helsingborg Hospital, Helsingborg, Sweden, which is a medium-sized regional hospital in the south of Sweden, serving about 250,000 inhabitants. The department is a referral centre for general dermatology including skin cancer patients. Since 2001 the local protocol for referral of skin tumours from general practitioners (GPs) and specialists at Helsingborg Hospital has been that all referrals for suspected skin tumours should be sent to the Department of Dermatology[98]. The rationale for this protocol is that specialists in dermatology are the most experienced in the clinical diagnosis of malignant and pre-malignant skin lesions, and dermatology departments are equipped for providing tailored treatment for these patients.

For the majority of referred skin tumours, treatment is carried out at the Department of Dermatology. In selected cases, e.g. tumours on the eyelids, the patients are further referred to other specialist clinics. For head and neck tumours, there is collaboration with ear, nose and throat (ENT) specialists. Head and neck tumours are excised at the Department of Dermatology by either a dermatologist or an ENT specialist/resident. For selected cases (five to ten cases/year) of highly aggressive BCC, patients are referred for MMS, which is performed at Lund University Hospital.

A register for all skin tumours excised at the Department of Dermatology, Helsingborg, was started in 2001. During the first years the registrations were entered into a separate database. The results from the first years have been presented previously[98,157].

In 2008 the register was integrated into the computerized patient record (Journalsystem Melior®, Siemens AB, Upplands Väsby, Sweden) as a standardized note with fixed answer options. The note also serves as the internal referral for surgery. This arrangement warrants a close to 100% coverage of tumours excised at the department. Data from the records were extracted and processed using the program QlikView® (QlikTech International AB, Lund, Sweden).

The register includes surgically excised lesions; tumours treated with other treatment modalities are not included. Patients who underwent surgical excision

from March 2008 to January 2015 were prospectively enrolled in the studies. The dermatologist who made the decision for surgery entered tumour size and site as well as the preliminary preoperative clinical diagnosis into the register preoperatively. Only one clinical diagnosis was allowed. For the different study periods, complementary data were collected as outlined below. After the excision, tumour specimens were sent for histopathological diagnosis, which was registered as the correct diagnosis. Tumour cells present at surgical margins were registered. The postoperative registrations were done by a nurse.

Statistics

The studies aimed to explore different aspects of the accuracy of the preoperative diagnosis/classification of skin cancer. The accuracy can be evaluated by statistical measures that assess various aspects of the diagnostic procedure, with different relevance for the clinical situation. The basic concepts of statistical measures for diagnostic accuracy are explained below (Fig. 20).

Sensitivity (true positive (TP) rate) is defined as the probability that the positive cases are identified as positive (TP/TP+false negative (FN)), i.e. in this context, that the cases with a histopathological diagnosis of malignant tumour were preoperatively also diagnosed as malignant. For tumours where the primary goal is not to miss positive cases, a high sensitivity is crucial, even if this is at the expense of over-diagnosis (low specificity).

Specificity (TN rate) is defined as the probability that the negative cases are identified as negative (TN/(TN+FP)).

Positive predictive value (PPV) (TP/(TP+FP)) is the probability that a test can predict a positive outcome, i.e. in this context, that a clinical diagnosis is verified histopathologically. A high PPV is relevant when a correct preoperative diagnosis is more important than e.g. not missing a positive case. The PPV is dependent on the prevalence of the disease in the studied population since at the same diagnostic skills of the physician, i.e. the same rate of misdiagnosis, the number of FPs will be proportionately higher if the prevalence of the disease is low.

Positive likelihood ratio (LR+) (sensitivity/(1-specificity)) is the probability of having a positive test if you have the disease, divided by the probability of having a positive test if you do not have the disease. It can also be shown to be the odds of having a disease given a positive test, divided by the odds of the disease in the population. A diagnostic test with a high LR+ has a high likelihood of finding cases with the disease.

Negative likelihood ratio (LR-) ((1-sensitivity)/specificity) is the probability of having a negative test if you have the disease, divided by the probability of having

a negative test if you do not have the disease. It can also be shown to be the odds of having disease given a negative test, divided by the odds of disease in the population. A diagnostic test with a low LR- has a high likelihood of clearing patients without disease.

Microsoft Excel® (Microsoft Corp., Seattle, WA, USA) and PASW Statistics 18 (SPSS Inc., Chicago, IL, USA) were used for the statistical analyses of studies I and II; for studies III and IV, statistical calculations were done using R, version 3.1.2[158].

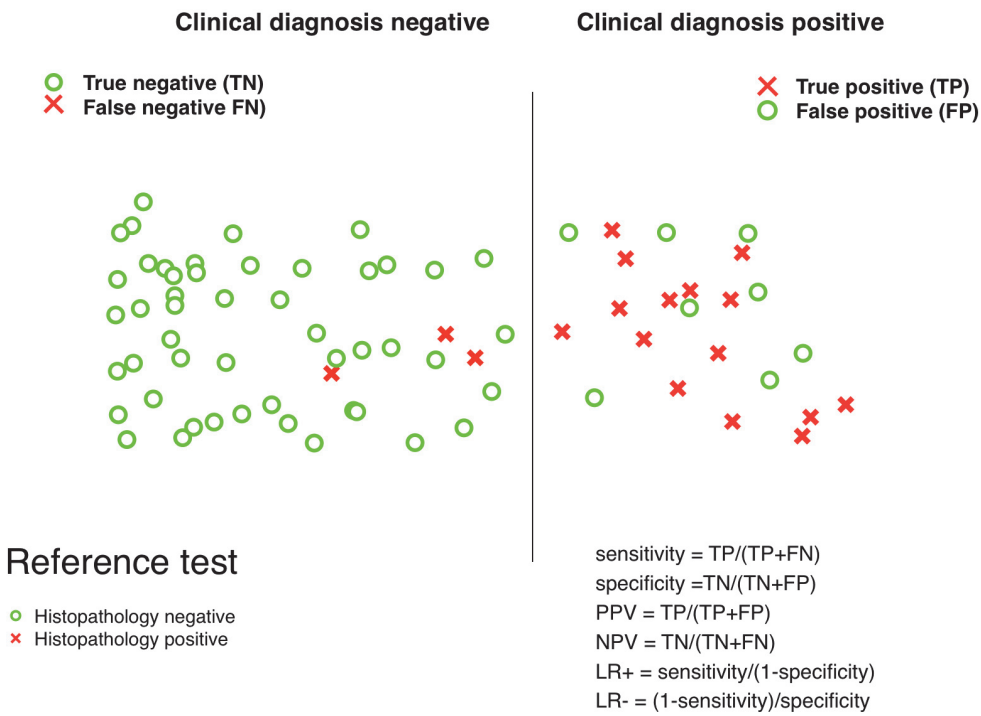

Figure 20.
Graphic illustration of the results of an index test (clinical diagnosis) in relation to a reference test (histopathology). True positive (TP) – cases with histopathologically confirmed disease that are clinically correctly diagnosed as having the disease. False positive (FP) – cases without disease that are wrongly diagnosed as having the disease. True negative (TN) – cases without disease that are correctly diagnosed as not having the disease. False negative (FN) – cases with disease that are wrongly diagnosed as not having the disease.

Study design, study populations and methods

Study I

Design

The preliminary clinical preoperative diagnosis was compared with the histopathological diagnosis, which was considered the correct diagnosis (reference method). The accuracy of the clinical diagnosis was assessed using two measures, sensitivity and PPV, as outcome variables. The sensitivity reflects the ability of not missing positive cases and the PPV the ability to predict positive cases.

Patients

Patients who underwent surgical excision at the Department of Dermatology, Helsingborg Hospital, from March 2008 to September 2011, were enrolled in the study.

Cases where a histopathological diagnosis had been determined before surgery (e.g. by punch biopsy), cases without a preoperative visit, as well as cases with equivocal pathology reports were excluded.

Methods

Preoperatively, the dermatologist who made the decision for surgery registered sex, age, tumour size and site, and clinical diagnosis. Only one clinical diagnosis was allowed. After excision the tumour specimens were sent for histopathological diagnosis; this was registered as the correct diagnosis. Malignant tumours were categorized into three diagnoses: BCC, SCC, and melanoma (SCC and melanoma included both *in situ* and invasive tumours). Furthermore, it was recorded whether the surgical margins were tumour-free.

Statistics

The sensitivity and PPV for the malignant diagnoses were calculated.

Study II

Design

The number needed to excise (NNE) is calculated by dividing the sum of excised melanomas and naevi by the number of excised melanomas. This metric is used as a measure of the efficiency in melanoma diagnosis, as it reflects the rate of "unnecessary" excisions of non-malignant lesions. The NNE value was calculated for the whole study period, and per year during the 4-year study period, and correlated to sex, age of patient and tumour site. In addition, NNE values were

calculated including SKs, as with increasing age of the patient this benign tumour is an increasingly relevant differential diagnosis for melanoma.

Patients

During the study period (January 2009 to December 2012), all skin tumours surgically excised at the department were consecutively registered. Only excised tumours with the histopathological diagnosis of CN, DN, melanoma *in situ* (including LM), invasive melanoma or SK were included in the study. Wide local excisions, excisions of melanoma metastases, local melanoma recurrences, as well as other benign or malignant skin tumours were excluded.

Methods

The sex and age of patients, as well as tumour location and histopathological diagnosis were recorded for all patients. The NNE values were calculated by dividing the number of excised pigmented tumours (CN, DN, melanoma *in situ* and invasive melanoma) by the number of excised melanomas. However, separate NNE calculations were also made including SK as a benign pigmented tumour. In all calculations, the variable "melanoma" included both melanoma *in situ* and invasive melanoma. Changes in NNE values over time, as well as NNE values in relation to sex and age of the patient and body location were evaluated.

Statistics

Linear regression was used for the analysis of changes over time for NNE value, the numbers of excised melanomas and for DNs. The chi-square test was used for comparing excised melanomas and naevi in men and women and for comparing location of melanoma in men and women.

Study III

Design

The ABCD rule of dermoscopy was developed to facilitate dermoscopic diagnosis for non-experts. In this study the accuracy of the algorithm when used bedside in a clinical setting was evaluated and compared with the dermoscopy-assisted clinical diagnosis. The physicians' self-assessed confidence in the clinical diagnosis was registered.

Patients

All skin tumours surgically excised at the department during the study period of 7 March 2013 to 28 April 2014 were consecutively registered. Only cases with a histopathological diagnosis of CN, DN, melanoma *in situ* or invasive melanoma,

and with a preoperative scoring using the ABCD rule of dermoscopy were included.

Methods

For clinically or dermoscopically pigmented skin tumours, the physicians who made the decision for surgery were encouraged to use dermoscopy and to score suspected melanocytic lesions according to the ABCD rule of dermoscopy. During the bedside examination the physicians noted the different values for asymmetry (0–2), border (0–8), colour (1–6) and dermoscopic structures (1–5). Preoperatively these data were entered into the computerized patient file. The TDS was automatically computed when the data were extracted.

The physician who made the decision for surgery also registered a preoperative dermoscopy-assisted clinical diagnosis of the skin tumour, as well as his or her self-assessed confidence in the clinical diagnosis on a 5-grade scale (5 = very confident and 1 = very unconfident). For discriminatory reasons the confidence level was multiplied by +1 if the physician had registered melanoma (*in situ* or invasive) as the preoperative clinical diagnosis, and by -1 for naevus (CN or DN). Consequently a confidence level of 5 was interpreted as showing that the physician was very confident that the lesion was a melanoma, while -5 meant that the physician was very confident that the lesion was a naevus.

All excised tumours were sent for histopathological analysis and assessment. A nurse postoperatively registered the histopathological diagnoses. The histopathological diagnosis was regarded and registered as the correct diagnosis.

Statistics

When a parametric test was suitable, we compared means using Welch's *t*-test if there were two groups and an analysis of variance (ANOVA) when there were several groups. Post-hoc testing in the latter case was done using the step-down procedure to produce p-values that maintain the family-wise error rate. These results are reported as difference in means.

For non-parametric comparisons between groups, we used the exact Wilcoxon-Mann-Whitney test if there were two groups, and the Monte Carlo exact test if there were more than two groups (different melanomas and different naevi). Where the latter was significant, post-hoc testing was done using the Nemenyi-Damico-Wolfe-Dunn test (joint ranks). The calculations were done in R-3.1.2, using the coin package 1.0–24[159]. In order to relate differences between groups to observable quantities we report non-parametric results as differences in medians with 95% bootstrapped confidence intervals (CIs) (10,000 replicates).

Confidence intervals for proportions were Clopper-Pearson intervals, which guarantee 95% coverage. Confidence intervals for relative proportions (such as

LR+ and LR-) were calculated using a log link in a logistic regression. Comparisons between different sensitivities and specificities were done using the exact McNemar's test with Bonferroni-Holm adjustment for multiple comparisons.

Study IV

Design

We assessed the accuracy of the preoperative prediction of histopathological subtype of BCC, specifically sBCC. The accuracy was assessed before and after an educational update on dermoscopic features indicative of sBCC, held in May 2013.

Clinical and dermoscopic features related to histopathological subtype of BCC were described.

Patients

During the study period from September 2011 to January 2015, primary excisions, all diagnoses, without preoperative histopathology were consecutively registered. Cases with a pre- or postoperative diagnosis of BCC were included. For study period 2 (after the educational update in May 2013), only cases assessed by dermoscopy were included.

Methods

Preoperatively, the physician who made the decision for surgery registered the single most probable preoperative clinical diagnosis, including suspected histopathological subtype of BCC, according to the Sabbatsberg criteria[38]. Postoperatively, a nurse registered the histopathological diagnosis, including subtype of BCC. Where a tumour had a mixed pattern, the more aggressive growth pattern was registered. The accuracy of the preoperative diagnosis of BCC of any subtype was assessed for the whole study period and based on all included excised tumours with different diagnoses. For the calculations of accuracy of subtype of BCC, cases with a pre- or postoperative diagnosis of BCC were included. For the second study period, after the educational update in May 2013, only cases assessed by dermoscopy were included. During study period 1 dermoscopy was optional and dermoscopy-use was not registered.

A classification tree for the best macroscopic and dermoscopic predictors of sBCC was created.

Statistics

The diagnostic accuracy, sensitivity, specificity, negative predictive value (NPV) and PPV were calculated for the whole study period, as well as separately for the

two study periods. . Positive likelihood ratios (LR+) for sBCC were calculated for the two study periods.

Clopper-Pearson CIs were used for proportions, guaranteeing at least 95% coverage. For comparisons between two different binomial outcomes, Fisher's exact test was used.

The software package rpart, version 4.12[160], was used to create a classification tree[161] to find the dermoscopic criteria in our material that best discriminated between sBCC and non-sBCC. We used the following criteria: presence of short fine telangiectasias; blue-grey ovoid nests; arborizing vessels; leaf-like/spoke-wheel-like pigmentation; multiple small erosions; ulceration and shiny red-white, structureless areas; surface type; pigmented tumour; and skin type of the patient. The classification tree works by starting with no predictors, then testing each predictor, grouping it into two different groups if necessary, and noting the reduction in classification error. The best predictor is retained. Then the process is repeated for each branch until there is no further significant reduction in error. The final size of the tree is determined by cross-validation, which ensures that no over-fitting is present.

Results

Study I

After exclusions, 2,953 tumours could be evaluated and were included in the study. Altogether, 55.1% (n = 1,626) of the excised lesions were malignant; seven of these cases were uncommon skin malignancies, while 1619 cases could be categorized as BCC (n=1180), SCC (n=303) or melanoma (n=136).

All in all, 49.8% of the malignant tumours were located in the head and neck area, and 96% of malignant tumours had tumour-free surgical margins. For the diagnosis of malignant tumour (of any diagnosis), the sensitivity was 98.0% (95% CI: 97.2-98.7%), specificity 79.3% (95% CI: 77.0-81.4%) and PPV 85.3% (95% CI: 83.6-86.9). (There is a discrepancy between the values for specificity for the diagnosis of malignant tumour presented in Paper I and the correct value presented here; this was due to a miscalculation.)

Diagnostic accuracy for the three malignant tumours

The values for sensitivity, specificity, PPV and LR+ for the three malignant tumours are shown in Table 2. Specificity and the LR+ were not included in the final manuscript, but can be calculated from the presented data.

	Sensitivity (%) (95% CI)	Specificity (%) (95% CI)	PPV (%) (95% CI)	LR+ (%) (95% CI)
BCC	95.4 (94.1-96.5)	89.6 (88.0-91.0)	85.9 (83.9-87.7)	9.1 (8.0-10.5)
SCC	68.0 (62.4-73.2)	96.2 (95.4-96.9)	67.3 (61.8-72.5)	18.0 (14.7-22.3)
Melanoma	70.6 (62.2-78.1)	96.8 (96.0-97.4)	51.3 (43.9-58.7)	21.9 (17.4-27.6)

Table 2. Sensitivity, specificity, PPV and LR+ for the three malignant tumours, basal cell carcinoma (BCC), squamous cell carcinoma (SCC) and melanoma. CI = confidence interval.

	Clinical diagnosis					
Histopathological diagnosis	Basal cell carcinoma	Squamous cell carcinoma	Melanoma	Naevus	Unspecified malignant tumour	Unspecified benign tumour
Basal cell carcinoma	**1,126**	30	12	2	8	2
Squamous cell carcinoma	85	**206**	0	0	12	0
Melanoma	9	0	**96**	28	3	0

Table 3. Clinical diagnosis of 1,619 malignant tumours diagnosed histopathologically as 1,180 basal cell carcinomas (BCCs), 303 squamous cell carcinomas (SCCs) and 136 melanomas.

The clinical diagnoses of the cases with malignant histopathology (BCC, SCC or melanoma) are shown in Table 3.

Calculations that were not included in the final paper for editorial reasons were analyses of waiting time to surgery for melanoma. Waiting time to surgery differed significantly between cases clinically diagnosed as melanoma (correct or incorrect) (n=186, median=9.0 days, mean=13.1 days, interquartile range (IQR)=14) and cases with final diagnosis of melanoma but with incorrect clinical diagnosis (n=40, median=14.5 days, mean=24.2 days, IQR=23) (p = 0.003, Mann-Whitney U test).

Study II

In total, 1,717 cases were included in the study, 252 of which were melanomas (125 *in situ* and 127 invasive), 1,395 were naevi (of which 563 were dysplastic) and 70 were SK. Altogether 98.5% of the tumours were radically excised.

The overall NNE value, SKs not included, was 6.5 (95% CI: 5.8-7.3). During the 4-year study period there was a decrease in NNE values, with a yearly decrease rate of 1.05 (r = 0.959, p = 0.041). Melanomas were increasingly excised during the study period.

The NNE value varied with body location and was highest for the trunk and lowest for the upper extremities. The NNE values decreased with increasing age, from 153 in the age group 0–20 years and 63.3 in the age group 21–30 years to 1.8 in the age group ≥80 years.

In total, 70 SKs were excised, representing 4.1% of all excised lesions included in the study. In the age group ≥60 years, the rate of excised SKs was 9.5%.

The overall NNE value including SKs was 6.8 (95% CI: 6.0-7.6).

Study III

During the study period, only cases with a histopathological diagnosis of CN, DN, melanoma *in situ* or invasive melanoma and with a preoperative scoring according to the ABCD rule of dermoscopy were included. Altogether 309 cases, 46 melanomas and 263 naevi, met the inclusion criteria.

Fifty per cent of the melanomas were invasive and the median Breslow thickness of invasive melanomas was 0.7 mm (mean 1.34 mm, IQR 0.50–1.35). The median TDS values differed significantly between melanomas (*in situ* and invasive) and naevi (CNs and DNs) (p<0.018). The distribution of TDS values for the four included diagnostic groups overlapped considerably between diagnoses.

The sensitivity for the ABCD algorithm with cut-off values for TDS of >4.75 and >5.45 was 83% (95% CI: 69–92%) and 74% (95% CI: 59–86%), respectively. The sensitivity for the preliminary clinical diagnosis was 74% (95% CI: 59–86%). For the preliminary clinical diagnosis the specificity was 91%, compared with 67% for the ABCD algorithm at TDS >5.45 and 45% for TDS >4.74.
In nine out of 46 histopathologically confirmed melanomas (19.6%, 95% CI: 9.4–34%), the physician was fairly confident preoperatively that the lesion was a naevus (in eight of the nine cases the clinical diagnosis was DN). All of these cases were early melanomas: eight were melanomas *in situ* and one was an early invasive melanoma.

Study IV

All in all, 3,544 primary excised skin tumours of all diagnoses were included, 1,642 of which had a preliminary preoperative clinical or postoperative histopathological diagnosis of BCC. The sensitivity for the diagnosis of BCC (any subtype) was 93.3% (95% CI: 91.9–94.5%), specificity was 91.8% (95% CI: 90.6–93.0) and the PPV was 89.0% (95% CI: 87.4–90.6%).

The study period was split in two (before and after the educational update) including cases with a preoperative or postoperative diagnosis of BCC. For the second part of the study 141 cases were excluded because no dermoscopy had been performed. This resulted in 1501 cases that could be evaluated. Of the 1501 included cases, 850 were registered during study period 1 and 651 during study period 2.

The PPV as well as LR+ for sBCC were higher during study period 2 compared with period 1 ((PPV = 59.8% v. 43.8%; p = 0.015) and (LR+=7.75 v. LR+=4.48; p=0.011) respectively). The best macroscopic and dermoscopic predictors of sBCC in this sample were a flat surface and multiple small erosions.

Surgical margins were tumour-free in 96.4% of all included histologically confirmed BCCs.

Discussion

General discussion

In this thesis we have investigated different aspects of preoperative diagnosis of skin cancer. We have found high accuracy for the diagnosis of malignant tumour and for the most common malignant skin tumour, BCC. The efficiency in melanoma diagnosis, as measured by the NNE value, differs substantially according to the age of the patient and body location. There was a decrease in the NNE value over the study period. We found low specificity for a diagnostic algorithm for dermoscopy (ABCD), but higher specificity for the clinical diagnosis, for which the algorithm was used in complement to the clinical examination. A considerable percentage of early melanomas in the study were not preoperatively expected to be melanomas by the dermatologist. Finally, we found that preoperative prediction of superficial BCC was suboptimal, but could be improved by education on and use of dermoscopy.

Malignant skin tumours are an increasing health problem in fair-skinned populations and the socio-economic costs of diagnosing and treating skin cancer are significant[3]. A correct clinical diagnosis is crucial as decisions for the management primarily have to be based on the clinical assessment. The accuracy of the diagnosis has various implications for the three different skin tumour diagnoses MM, SCC and BCC.

General methodological considerations
(mainly applicable to studies I, III and IV)

In these studies we assessed the diagnostic accuracy of clinical diagnosis and dermoscopic algorithms. The studies were conducted in clinical practice and there was no change to normal routines because of the studies, other than the systematic and structured registration of clinical, dermoscopic and histopathological findings.

This design has made it possible to conduct long-term studies, resulting in large patient materials. All registrations were done prospectively. We aimed to study, not the decision to excise or not, but the accuracy of the preoperative diagnosis;

therefore only one single, leading clinical diagnosis was registered. In addition, in Study III the physicians' confidence level in the leading diagnosis was registered.

The algorithms evaluated in studies III and IV have previously been tested in a more experimental setting, which is why it is important to study their validity in routine clinical practice[124,126,134]. However, there are several potential sources of bias confined to diagnostic accuracy tests that have to be considered in our studies as well[162]. Variation of outcomes in diagnostic tests can be due to imprecision, bias and differences in study parameters (such as population, index test, reference test and outcome).

Internal validity (reliability)

The reliability of the studies can be subject to both bias and imprecision. Bias is a result of systematic errors – while imprecision is caused by random errors.

A possible source of **bias** in the dermoscopic diagnosis in our studies is that all included dermatologists and residents work at the same department. In our feedback sessions, our assessments of diagnostic criteria were "calibrated" against each other and systematic misinterpretations of e.g. certain dermoscopic criteria are possible. We try to avoid this by repeatedly attending national and international courses on dermoscopy. **Imprecisions** in the registrations were also likely to occur to some extent. Only one physician made the registrations for each case, and always under pressure of time in the daily clinical routine. To try to minimize mistakes, the registrations were all part of the ordinary patient file with fixed questions and fixed answer options. As the questions were part of the patient file all information registered by doctors and nurses was confirmed by signature. The large size of our study materials is also likely to have decreased the impact of random errors in individual registrations.

External validity (applicability)

Population

The clinical setting where a test is performed affects the spectrum of the disease in patients presented. "Easy cases", e.g. clear-cut benign naevi, are unlikely to be referred to our department. There was further selection in our studies as only excised lesions were included. It is therefore probable that the population includes high rates of clinically ambiguous lesions (such as atypical naevi in Study III and clinically ambiguous sBCCs in Study IV) and therefore our studies suffer from

spectrum bias. The effect of this may be lower specificity since the benign and malignant conditions show overlapping features. On the other hand, the selection will also cause a higher prevalence of disease in the study population, which will give a higher PPV (see below), for example.

Index test (clinical diagnosis and dermoscopic algorithms)

The clinical diagnosis and dermoscopic assessment are subjective evaluations and appraisals of different signs and criteria. The assessments are highly dependent on the experience level of the physician, whether diagnosis is made in consensus between several doctors, on photographs or bedside, and the time allocated. In our studies, every assessment was made bedside by a single doctor working under pressure of time. Residents had the opportunity to ask more experienced colleagues and it was therefore not meaningful to assess the accuracy with respect to experience level. These circumstances reflect the common clinical situation and we therefore think that they improve the applicability of the results.

Reference test (histopathology)

We use the histopathological diagnosis as the reference test. In our studies different pathologists made the histopathological assessments according to our ordinary clinical routine. It is well known that histopathological diagnosis of skin lesions is a subjective assessment. This is certainly true for ambiguous cases of pigmented skin lesions and subtypes of BCC[106,107]. The pathologists were not blinded to the clinical information on the referral form. The provided clinical information may have given rise to diagnostic review bias, meaning that when the pathologist is aware of the clinical information, this might influence interpretation of ambiguous lesions.

Outcome

The studies were based on a set of excised lesions, i.e. in all of the included lesions the physician had decided that excision was warranted. Skin lesions that were not eligible for excision were not included. This means that the decision to continue with the reference test (histopathology) was dependent on the index test (clinical and dermoscopic examination). This is a common problem in studies where the reference method is invasive. To excise every clinically assessed lesion would have been impossible both ethically and practically, especially since each patient with skin lesions presents with numerous different benign and malignant lesions that are assessed at one clinical visit. However, this has to be thoroughly considered when the presented values for diagnostic accuracy are appraised.

A way to partly overcome this and get a picture of missed malignant tumours, for example, would have been to follow up all patients. However, this would not have been possible for practical reasons considering the large number of patients included. Linking with the Swedish Cancer Register would be a possibility, but

was not done, however, it has been done previously in a Swedish study on melanoma[163].

Study I

Methodological considerations

The sensitivity and PPV were chosen as outcome variables since they reflect two aspects of the diagnostic performance. Sensitivity reflects the ability not to miss a disease. High sensitivity can, however, easily be achieved by applying a low threshold for the clinical diagnosis of the disease, which then results in over-diagnosing. The PPV, on the other hand, measures the physician's ability to predict the disease and will therefore reflect the rate of over-diagnosing. When comparing the PPV in different studies it has to be taken into account that the value is highly dependent on the prevalence of the disease in the evaluated populations.

The study was based on a set of excised lesions. Cases that on clinical examination were judged as benign and not eligible for excision were not included. The study is therefore subject to verification bias.

The included malignant diagnoses were categorized into BCC, SCC and melanoma (seven cases representing other rare skin tumours were excluded). Squamous cell carcinoma and melanoma included both *in situ* tumours and invasive tumours. This is a limitation, especially since the differential diagnoses differ between e.g. SCC *in situ* and invasive SCC.

General discussion

We found high sensitivity and a high PPV for the diagnosis of malignant tumour. We also found high sensitivity and PPV for the diagnosis of BCC. The overall rate of radical excisions was high. For the histopathological diagnosis of BCC, the most common clinical misdiagnosis was SCC. For SCC, the most common clinical misdiagnosis was BCC, while for melanoma it was naevus.

Our results imply that dermatologists have a higher diagnostic accuracy (measured in terms of sensitivity and PPV) in diagnosing skin cancer, compared with previously published data among physicians of different specialties[164-167]. This is not surprising since dermatologists are trained to assess skin conditions. However, to compare diagnostic accuracy between specialties by comparing studies conducted in different settings can be questionable, as stated above.

Why is a correct clinical diagnosis relevant? For melanoma and SCC, it is important for early detection of a potentially lethal condition. For BCC, several treatment options exist and a correct clinical diagnosis enables the physician to tailor the most optimal treatment for the patient. The appropriate width of surgical margins depends on the diagnosis and a preoperative misjudgement can lead to too narrow, as well as unnecessarily wide, margins. The most serious consequence of misdiagnosis of skin cancer is of course if a lesion is judged as benign and not treated. The rate of such cases cannot be assessed with the current study design, as only excised lesions were included.

In clinical practice, where prioritization is commonly necessary, a misjudgement of diagnosis might lead to delayed surgical treatment. This in turn can lead to impaired prognosis and a risk of tumour growth during the waiting time and consequent need for more extensive surgery. The clinical diagnosis in this study was the physicians' single leading preliminary diagnosis. Our results therefore do not reflect differential diagnoses at hand.

The clinician's confidence in the diagnosis was not registered in this study. However, the clinician's confidence in his or her clinical diagnosis is likely to affect the implications of and risks associated with incorrect diagnosis. With lower confidence in the clinical diagnosis, the clinician will most probably take measures to minimize the consequences of a possible incorrect clinical diagnosis. For example, if the leading diagnosis is atypical naevus but the physician's confidence in the diagnosis is low, this might be reflected in the waiting time to surgery. We found longer waiting times to surgery for melanomas that were misdiagnosed preoperatively compared with those correctly diagnosed. Nevertheless, albeit statistically significant, the median waiting time to surgery was only 5.5 days longer for the misdiagnosed cases of melanoma.

Do our results support restrictive indications for preoperative biopsies? The study includes close to 3,000 skin tumours excised without a preoperative biopsy. The high rate of radical excisions and the high accuracy for the diagnosis of malignant tumour indicate that in most cases a preoperative biopsy can be omitted. A biopsy or excision is of course preferred over missing a malignant tumour and may therefore be necessary in ambiguous cases that are not easily completely excised. However, an additional biopsy to confirm the diagnosis preoperatively in all of the cases included in this study would have added a cost of around €150,000–200,000 for the histopathological analysis, costs associated with taking the biopsy and extra administration not counted. Moreover, a preoperative biopsy means an extra procedure for the patient and may considerably delay final treatment. To minimize the consequences of a clinical misdiagnosis, waiting times to surgery should be kept short in general, and especially for ambiguous cases.

Study II

Methodological considerations

Number needed to treat (NNT) is a measure that is used to describe the effects of a specific treatment in practice[168]. It describes how many patients, in a certain context, must be treated (e.g. with a medicine) for a specified period of time, for one of them to escape a certain event (e.g. a fracture, cardiac event, or death).

A related measure, NNE, is an attempt to confer the concept of NNT to reflect the efficiency in diagnosing melanoma[169], i.e. how many pigmented lesions have to be excised to find one melanoma. The method for calculating NNE is not standardized, which precludes direct comparison of the NNE values found in different studies. In most studies the benign counterparts to excised melanomas are approximated to include the benign naevi excised during the certain period of time[169-173]. Some studies also include SKs[167,173] while others only include lesions explicitly excised to exclude melanoma[172,174,175]. Instead of NNE, some authors use the benign:malignant ratio, i.e. the number of excised naevi, divided by the number of excised melanomas[176,177]. To be able to compare NNE values between different units, the calculation of NNE has to be standardized.

The NNE value reflects the diagnostic acumen of the physicians, i.e. their ability to discern melanomas from benign pigmented lesions. The NNE value is, however, affected by the underlying melanoma risk in the evaluated population, as well as the complexity of the lesions assessed. The local routines for referral of clear-cut or highly suspected melanomas will also affect NNE values.

The NNE value mainly reflects the specificity, since it measures the number of benign lesions in relation to melanomas.

In our study we present NNE values both including and excluding SK. The selection of included patients in our study was based on histopathological diagnoses and not the explicit reason for excision in each case. There are possible sources of error in this patient selection; all naevi, including those that were clinically clear-cut benign and excised for reasons other than to exclude melanoma, were included, as were SKs that may have been excised for suspicion of SCC. On the other hand, during the study period there might have been pigmented BCCs that were excised to exclude melanoma; those were not included. The reasons for the differences in NNE values seen, according to age of patient, sex, and tumour site, and over time can only be speculated on.

General discussion

We report an overall NNE value in line with the NNE values found for specialized pigmented skin lesion clinics in a larger, multi-centre study[170]. We also show that there was a yearly decrease in the overall NNE values during the study period.

The study shows differences in NNE value according to the age of the patient; in the oldest patient group (>80 years) every second pigmented skin lesion excised was a melanoma, while e.g. in the age group 31–40 years the NNE value was 63. The NNE value was also correlated to tumour site, with the highest NNE values being on the trunk, and found in women. We report a low rate of excised SKs, but increasing with age of patient; in patients aged >60 years, 9.5% of excised pigmented lesions were SKs.

For melanoma, early detection is crucial for the prognosis, since melanoma is potentially lethal. However, if the tumour is excised at an early stage, the patient can be cured with low risk for metastasis. The challenge in melanoma diagnosis is that the benign counterpart to melanoma, naevus, is extremely frequent in the general population. Furthermore, in the early stages, melanoma can be indiscernible or very difficult to discriminate from clinically atypical naevus. Multiple naevi (CNs or DNs) are independent risk factors for melanoma[22], but the risk of an individual naevus developing into melanoma is extremely low[94]. About two-thirds of melanomas arise de novo[61], and it is generally perceived that prophylactic excision of common or clinically atypical naevi is not a relevant action to reduce the risk of melanoma[178]. Therefore the goal in the management of pigmented skin lesions is to find early melanomas, when the disease is still curable by a simple excision, but to avoid unnecessary excisions of benign lesions. The total naevus count of the patients was not registered in our study. This is a limitation since it would have been of interest to know at which rate the excisions were made in patients with multiple naevi.

Lindelöf et al in 2005 estimated the overall ratio between excised naevi and excised melanomas in Sweden to be 58 excised naevi per melanoma. The authors stated that if the number of unnecessary excisions could be reduced, it would cause significant reduction in the costs per excised melanoma[179].

Is dermoscopic assessment of patients with pigmented skin lesions of value for improvement of NNE values, with preserved sensitivity for melanoma? Dermoscopy improves diagnostic accuracy for melanoma mainly by increasing sensitivity[118]. In a large, multi-centre study by Argenziano *et al*, the NNE value decreased in centres specialized in pigmented skin lesions, while there was no change in non-specialized settings. Increased use of dermoscopy may be one of the explanations for decreasing NNE values over time, as found in our study, as well as in the study by Argenziano *et al*[170]. In a study comparing GPs in Australia, there was a significantly lower NNE value in those practising in skin cancer

medicine only compared with those in general practice. There was also a higher use of dermoscopy among GPs in specialized practices, and it was not possible to study these factors separately.

What is an ideal NNE value? The ideal NNE value is the lowest value at which no melanomas are missed. The benign naevi are not *needed* to be excised to find the melanoma. The NNE value is dependent on the acumen of the physician. However, even for experts, the available diagnostic methods (clinical and dermoscopic examination) are not specific enough to allow the NNE value to be too low. The NNE value does not take into account whether melanomas are missed, and decreasing NNE value to a minimum might result in increased risk of missing melanomas. In Study III we show that, for a substantial rate of very early melanomas, the dermatologist favoured a non-malignant diagnosis (DN or CN) as the leading diagnosis. If the goal for the NNE value would have been lower, these cases might have been missed.

Several studies have shown lower NNE values in specialized clinics compared with general practice[170,172-175,180]. This could motivate that excision of pigmented lesions should be carried out at centres specialized in skin cancer. Even though the cost per excision is usually higher in specialized units, a lower total cost per excised melanoma due to the lower rate of unnecessary excisions of benign lesions makes the treatment more cost-effective[179].

Study III

Methodological considerations

We chose to evaluate the validity of the ABCD algorithm as a tool for assessing pigmented skin lesions in clinical practice. This algorithm has been taught and used at our department for many years. The ABCD rule of dermoscopy has the advantage of being easy to memorize. The preoperative diagnosis in this study was independent of the decision to excise or not, and gives a picture of what the clinician really thought was the most probable diagnosis, irrespective of the chosen treatment. A limitation of the study design is that the preliminary preoperative diagnosis was made after the dermoscopic evaluation. Furthermore, the clinical information was known to the physician when the dermoscopic assessment was made, which may have influenced the interpretation of the dermoscopic picture. There is, however, a lack of studies assessing the accuracy of the different simplified algorithms in clinical practice and we think that this study is important, in spite of the limitations linked to the study design.

The exact reason for excision in each case was not documented. The self-assessed confidence in the clinical diagnosis was dichotomized, for practical reasons, into naevus and melanoma, were naevus included a clinical preoperative diagnosis of both DN and CN. There were, however, only 14 cases with a clinical and histopathological diagnosis of CN and in only four of these was the physician very confident in the clinical diagnosis, i.e. there were few clinically clear-cut benign lesions in the material. Therefore, the majority of pigmented lesions included in the study were most probably diagnostically challenging, which is likely to have affected the specificity for both the ABCD algorithm and the preliminary diagnosis.

General discussion

We found a high sensitivity for the ABCD algorithm; however, this was paired with a low specificity. The ABCD algorithm was primarily developed as a tool to assist non-experts in dermoscopic assessments, and in a non-expert setting, high sensitivity is important. The very narrow spectrum of clinical and dermoscopic appearance among malignant and benign lesions in this selected set of lesions is probably one of the explanations for the low specificity found in this study. The specificity was higher for the preliminary clinical diagnosis, indicating that clinical information is important to improve specificity. Another explanation for this difference may be that pattern recognition was used as a complement in the dermoscopic examination. Assessment using pattern recognition has previously been shown to achieve higher specificity compared with simplified algorithms[119].

The results of the study also illustrate the difficulties associated with diagnosing very early melanomas. In almost 20% of excised melanomas included in this study, the clinician had preoperatively favoured a non-malignant diagnosis, and rated his or her confidence in this diagnosis as 4 on a 5-grade scale. We could also confirm that the clinicians were more confident about and more correct regarding the diagnosis of invasive melanoma compared with melanoma *in situ*. We think that, to avoid missing early melanomas, these findings support the need for keeping generous indications for surgery.

Study IV

Methodological considerations

In this study we evaluated the accuracy of the preoperative prediction of subtype of BCC. The study period was split in two. During the first part of the study the

use of dermoscopy was optional and was not registered. By contrast, during study period 2, dermoscopy was mandatory and cases that were not assessed by dermoscopy were excluded. The start of study period 2 was preceded by an educational seminar on dermoscopic signs of subtype of BCC. This study design precludes further analysis on whether the mandatory use of dermoscopy or the educational update, or both, caused the increase in PPV found for study period 2.

The study only included excised lesions and this has important implications, especially for a tumour like BCC where other treatment options exist. It is probable that the study set included more ambiguous lesions than those, which received other treatments. It is also possible that with increasing knowledge of dermoscopic signs of sBCC among the dermatologists during the course of the study, an increasing rate of sBCCs was scheduled for non-surgical treatments, which then might have affected the results. However, the rate of sBCCs did not differ between the study periods, speaking against such a change in management.

While the study was running, the paper by Lallas *et al* was e-published and during the final study year the dermoscopic criteria identified in that paper were included in the register[147]. In our study we only included the dermoscopic criteria included in the algorithm proposed by Lallas. Dermoscopic criteria other than these, such as other types of vascular patterns or pigmentation, were not registered.

General discussion

The high accuracy for the diagnosis of BCC (any subtype) found in this study, as well as in Study I, indicates that the diagnosis of BCC is reliable. This, together with the high rate of radical excisions, speaks in favour of applying restrictive indications for preoperative punch biopsy. Moreover, a punch biopsy can predict the most aggressive growth pattern in only about 85% of cases[111,113,181]. In conclusion, for the majority of cases, a pre-surgical punch biopsy is of no, or only limited, benefit for the patient.

An important finding in this study was that the rate of pre-surgical misdiagnoses of SCC as BCC was significantly reduced during study period 2. This is clinically relevant since misdiagnosing an SCC as BCC can delay treatment, as generally longer waiting times to surgery are accepted for BCC.

Prediction of subtype of BCC, and specifically sBCC, is relevant for several reasons. Many patients develop multiple BCCs during their life[182] and for sBCC, there are several non-surgical treatment options, e.g. cryotherapy, PDT, imiquimod, and fluorouracil[52,53]. These treatments are, along with surgical excision, considered first-line therapy for sBCC. The treatment for each specific tumour may be chosen based on patient and tumour-specific factors, such as tumour location and the general health and preferences of the patient[183]. It is well

known that, in clinical practice, a significant number of BCCs are treated without histopathological confirmation of the diagnosis. This is true mainly for BCCs located on the trunk and for those suspected to be superficial[184,185]. Correct diagnosis of subtype is therefore crucial to accomplish tailored treatment for and follow-up of the patient.

If a correct diagnosis of subtype can be made without pre-treatment punch biopsy, resources can be saved. We found that after an educational update on dermoscopic criteria for subtypes of BCC and in cases assessed by dermoscopy, the preoperative prediction of sBCC improved.

The most important predictor of superficial subtype was a flat surface. All in all, 71.4% of sBCCs were flat and of all lesions that were clinically flat, 71.4% were sBCCs.

Conclusions

Study I

We showed high accuracy for the preoperative diagnosis of malignant tumour as well as for BCC. Altogether, 96% of the malignant tumours were radically excised.

Our results indicate that pre-surgical biopsies can be omitted in the majority of skin cancer cases, saving the patient an extra procedure and time, and saving costs for the treatment.

In comparison with previously published data, our results indicate that dermatologists diagnose skin tumours with higher accuracy compared with other specialists. We therefore conclude that dermatologists should be placed in the first line regarding skin cancer diagnosis and treatment.

Study II

The NNE value decreased with increasing age of the patient and varied according to body location, with the highest values found on the trunk and the lowest on the arms.

Study III

When the ABCD rule of dermoscopy was applied bedside, the sensitivity for melanoma diagnosis was fairly high, but the specificity was low. However, clinical information seemed to add to specificity for preoperative melanoma diagnosis.

A considerable percentage of very early melanomas were preoperatively not expected to be melanomas by the dermatologist.

Study IV

The accuracy of the preoperative diagnosis of BCC was high, but considerably lower for diagnosing BCC subtype.

The prediction of sBCC was significantly improved after an educational update on dermoscopic criteria for sBCC in cases assessed by dermoscopy.

The best macroscopic and dermoscopic predictors for sBCC in the fair-skinned study population were a flat surface and multiple erosions, and absence of ulceration and arborizing vessels.

Future prospects

This thesis has addressed different aspects of accuracy in skin cancer diagnosis. This field of research is infinite, as we need to continuously seek out ways to improve diagnostic accuracy. Aspects for future possible research are presented below.

The high NNE values we found for younger patients and on the trunk highlight the need for development of better and more specific preoperative diagnostic methods to distinguish melanomas from naevi.

The majority of previous studies on validating dermoscopic algorithms were based on photographs[124,126,129,133-135,140,186]. Further prospective studies on the value of different dermoscopic algorithms in a clinical setting are needed to answer the question of which algorithm has the best accuracy.

Dermoscopic evaluations made bedside are subject to influence from the conditions pertaining to the clinical situation, such as the anxiety of the patient and also time pressure. It would be of interest to compare the dermoscopic evaluations made bedside with assessments on photographs to further address the question of which algorithm works best in the clinical setting.

For the early recognition of melanoma, not only dermatologists but also physicians of other specialties need to be able to recognize the tumour. The different dermoscopic algorithms have been developed to simplify melanoma diagnosis for novices; however, only few have been tested or validated for this purpose. It would be of value to study which dermoscopic method is best for teaching melanoma diagnosis to medical students.

Further research on the dermoscopic characteristics of the different subtypes of BCC is needed. Dermoscopic criteria for discrimination between nBCC and intermediately aggressive BCC preoperatively would be of great clinical value as a misdiagnosis can lead to inadequate surgical margins.

We have found that the rate of tumours that were radically excised was high in our studies, however it differed between tumour subtypes. To further improve clinical results, the pitfalls in preoperative design of surgical margins have to be determined.

Sammanfattning på svenska

Förekomsten av hudcancer ökar i ljushyade befolkningsgrupper och hudcancer tillhör de cancergrupper som ökar mest i Sverige. De tre vanligaste formerna av hudcancer är basalcellscancer, skivepitelcancer och malignt melanom. Under 2013 utgjorde skivepitelcancer och malignt melanom ca 16 % av alla cancerfall som rapporterades in till Svenska Cancerregistret; över 6 000 fall av skivepitelcancer och över 3 000 fall av malignt melanom inrapporterades. Den allra vanligaste cancern är basalcellscancer med ca 45 000 inrapporterade fall under 2013.

Majoriteten av hudcancerfall botas genom att tumören opereras bort. Malignt melanom är den mest maligna av de tre cancerformerna; ca 500 personer dog av sin melanomsjukdom under 2013. Dödligheten i skivepitelcancer är låg och ligger runt 50-60 fall per år. Vid båda dessa cancerformer är tidig diagnos och avlägsnande av tumören av högsta vikt och för prognosen.

Basalcellscancer växer lokalt aggressivt, men sprider sig inte till andra organ. De största utmaningarna när det gäller basalcellscancer är dels det stora antalet tumörer, dels att denna tumörform i ungefär hälften av fallen uppstår i ansiktet. Korrekt handläggning är därför av största vikt för gott slutresultat.

Den kraftiga ökningen av hudcancer märks tydligt på Sveriges hudkliniker, där hudcancer eller misstänkt hudcancer numera är en av de vanligaste besöksorsakerna. Vikten av effektiv och korrekt handläggning av hudcancerpatienter är uppenbar, både för att minska det personliga lidandet för enskilda patienter och för att sjukvårdens resurser ska kunna användas på ett så effektivt sätt som möjligt.

All behandling har sin utgångspunkt i en diagnos och en korrekt diagnos är en självklar förutsättning för ändamålsenlig och effektiv behandling. Diagnosen hudcancer ställs på basen av tumörens utseende, i kombination med bakgrundsinformation, såsom hur länge tumören har funnits, tillväxt eller annan förändring i utseendet, förekomst av blödning, ömhet eller klåda. Till sin hjälp i diagnostiken har dermatologen också ett speciellt handhållet mikroskop (dermatoskop) som förstorar förändringen ca 10 gånger, men också ger möjlighet att se strukturer som ligger precis under hudytan, i överhuden och i övre läderhuden. Dermatoskop utvecklades för användning i rutinbruk för undersökning av pigmenterade hudförändringar i början av 1990-talet. Värdet av dermatoskopi för att förbättra diagnostiken av melanom har visats i flera studier. På senare år har

man alltmer uppmärksammat värdet av att använda dermatoskop även i undersökning av tumörer som vanligen inte är pigmenterade, såsom basalcellscancer och skivepitelcancer.

Den viktigaste behandlingen för de flesta hudcancerformer är operation. Alternativa behandlingsformer finns för skivepitelcancer i tidigt stadium och vissa former av basalcellscancer, särskilt den ytliga. Vid operation är det viktigt att hela tumören avlägsnas, vilka marginaler man väljer avgörs bland annat av vilken diagnos som misstänks. Den avlägsnade tumören undersöks mikroskopiskt av patolog för fastställande av diagnos och bedömning av marginaler av frisk hud, för att avgöra om tumören är fullständigt avlägsnad. Diagnosen som fastställs vid den patologiskt mikroskopiska undersökningen har i undersökningarna i denna avhandling räknats som den korrekta, dvs. den patologiskt mikroskopiska undersökningen är referensmetod.

Vi har studerat olika aspekter av hur korrekt diagnostiken av hudtumörer är i den kliniska vardagen. Studierna baseras på registreringar som gjorts i samband med att hudtumörer opererats bort på hudkliniken i Helsingborg under perioden mars 2008 till januari 2015. De uppgifter som registrerats är bland annat ålder och kön på patienten, storlek och kroppslokalisation samt dermatoskopiskt utseende av tumören, undersökande dermatologs preliminära huvuddiagnos (endast en diagnos, den viktigaste, har registrerats) och den slutgiltiga patologiskt mikroskopiska diagnosen. I vissa fall har ett vävnadsprov av tumören undersökts mikroskopiskt för fastställande av diagnos innan operation, dessa tumörer har inte tagits med i våra beräkningar.

I de analyser vi har gjort för bedömningen av om dermatologens diagnos före operation är korrekt har vi använt oss av statistiska beräkningar som brukar användas för bedömning av en diagnostisk metod jämfört med en referensmetod. De mått vi har använt är bland annat sensitivitet, specificitet och positivt prediktivt värde. Sensitivitet speglar känsligheten i metoden, dvs. hur stor andel av de som i verkligheten har en viss diagnos hittar man med sin undersökning. Specificitet å andra sidan speglar metodens förmåga att utesluta sjukdom hos de som är friska. Positivt prediktivt värde ger ett mått på hur stor andelen verkligt sjuka är, av alla de fall som man har ställt diagnosen på.

I det första arbetet har vi studerat hur korrekt hudcancerdiagnosen är för de tre vanligaste tumörerna genom att jämföra den preliminära diagnosen som ställts före operation med den patologiskt-mikroskopiska diagnosen. Under studieperioden som sträckte sig från mars 2008 till september 2011 inkluderades 2 953 bortopererade hudtumörer, av dessa var 55.1 % (1 626 tumörer) elakartade (maligna). Resterande tumörer var godartade (benigna); den vanligaste benigna tumören som opererats bort var pigmentnevus (964 fall). Av de maligna tumörerna var 1 180 basalcellscancer, 303 skivepitelcancer och 136 melanom. Sensitiviteten för malign tumör var hög, liksom förmågan att prediktera att tumören var malign.

Den diagnostiska säkerheten för diagnosen basalcellscancer var också hög, medan korrektheten för de andra två tumörerna var något lägre. För skivepitelcancer var den vanligaste kliniska feldiagnosen basalcellscancer och för melanom var det godartat pigmentnevus (också kallat ”födelsemärke” eller ”leverfläck”). Samtliga tumörer i studien var dock bortopererade, så tumörerna missades inte, men i dessa fall var inte den korrekta diagnosen dermatologens huvuddiagnos före operation.

I delarbete två har vi enbart studerat diagnostiken av melanom. För melanom är, som beskrivits ovan, den viktigaste alternativdiagnosen inte en annan malign tumör, utan godartat pigmentnevus. Pigmentnevus är extremt vanligt i befolkningen, de flesta människor har ett flertal sådana förändringar, vissa personer har mer än hundra. Målet är att hitta melanom i tidigt skede då sjukdomen är botbar. I det skedet har melanomet ofta inte utvecklat alla synliga karakteristika och kan därför vara svårt att skilja från pigmentnevus. Man vill hitta och behandla melanom i tidigt skede, men samtidigt inte göra för många onödiga operationer av godartade förändringar. I denna studie har vi beräknat antalet melanom som opereras bort delat med det totala antalet pigmentförändringar (godartade och elakartade) som opereras bort. Det värde man får fram kallas Number Needed to Excise (NNE) med andra ord: antalet pigmentförändringar som opereras bort för att hitta ett melanom. Vi fann att NNE sett över hela studieperioden var 6.5. Vi såg en minskande trend i NNE under de fyra år som studien pågick, att NNE var lägre vid högre ålder på patienten (1.8 hos patienter som var äldre än 80 år) och när det gäller kroppslokalisation av tumören var NNE högst på bålen och lägst på armen.

I den tredje studien har vi att utvärderat en diagnostisk algoritm som har utarbetats för att förenkla diagnostiken av melanom med dermatoskop. Vi fann att användning av algoritmen gav hög sensitivitet för melanomdiagnosen (83 %) men låg specificitet (45 %), dvs. man hittade de flesta fallen av melanom men däremot var algoritmen inte lika bra på att utesluta melanom hos de som var godartade. I denna studie fick dermatologen inte bara notera sin huvuddiagnos, utan också på en 5-gradig skala skatta hur säker han/hon var på diagnosen. Vi fann då att i nästan 20 % av mikroskopiskt påvisade melanom var dermatologen relativt säker före operationen (skattat 4 på den 5-gradiga skalan) på att den mikroskopiska undersökningen inte skulle visa melanom. Samtliga dessa fall rörde sig om tumörer i ett tidigt stadium, och fyndet illustrerar att melanomdiagnosen kan vara svår, särskilt tidigt i förloppet. Alla dessa tumörer opererades dock bort, vilket visar att man ändå bedömt dem som misstänkta och de missades därför inte.

Basalcellscancer förekommer i fyra varianter. Uppdelningen baseras på hur tumören växer i huden och denna diagnos ställs patologiskt-mikroskopiskt. De olika varianterna har emellertid också olika utseende för ögat och har olika kännetecken vid undersökning med dermatoskop. En av basalcellscancerformerna sitter ytligt i huden. Vid denna form finns, förutom kirurgi, också flera andra behandlingsalternativ. I den fjärde studien har vi undersökt hur väl dermatologen,

före operation kan bedöma (prediktera) vilken variant av basalcellscancer tumören tillhör. Vi studerade särskilt ytlig basalcellscancer eftersom man gärna vill kunna behandla denna tumörform med alternativa behandlingsmetoder, utan att behöva ta ett hudprov innan. Vi kunde, liksom i vårt första arbete, konstatera hög träffsäkerhet för diagnosen basalcellscancer. Däremot var det svårare att med säkerhet pricka rätt vad gäller de olika formerna. Efter ett utbildningstillfälle för alla doktorer på hudkliniken i Helsingborg om dermatoskopisk undersökning av basalcellscancer, ökade säkerheten i prediktionen av den ytliga formen för de fall som undersökts med dermatoskop.

Sammanfattningsvis har vi visat på hög träffsäkerhet för diagnosen malign tumör och basalcellscancer. Antalet godartade pigmentförändringar som tas bort per melanom är högst på bålen och minskar med ökande ålder på patienten. Användning av en förenklad algoritm för dermatoskopisk undersökning av pigmentförändringar hittade stor andel av melanomen, men var sämre på att utesluta melanom hos de friska. Prediktionen av ytlig basalcellscancer förbättrades för de förändringar som undersökts med dermatoskop efter ett utbildningstillfälle om dermatoskopi av basalcellscancer.

Tack!

Den här avhandlingen har möjliggjorts genom att jag är omgiven av underbara människor som har stöttat och hjälp mig på olika sätt. Tack till er alla!

Ett särskilt tack till:

Min huvudhandledare Mats Bjellerup som har varit min förebild och mentor sedan mitt första vikariat på hudklinik för mer än 20 år sedan. Det började med studier om bensår, pinch graft och lipodermatoscleros och vi publicerade vår första gemensamma artikel 1997. Nu, nästan 20 år senare, har det blivit en bok om hudtumör-diagnostik – inte en dag för tidigt kan man säga. Det är en stor förmån att få arbeta med dig och jag känner en djup tacksamhet för att du har stöttat mig under alla dessa år. Du har en oöverträffad pedagogisk skicklighet. Du har också en förmåga att skapa trivsel omkring dig och du lyckas få dina medarbetare att vilja prestera sitt allra bästa. Och när som helst, när man minst anar det, kommer det ett skämt.

Kari Nielsen, min outtröttliga, positiva, entusiastiska bihandledare. Tack för att du svarar på mail och SMS, dygnet runt! Och om du skulle råka vara i duschen så svarar din man Niklas, lika klok han.

Professor Artur Schmidtchen, bihandledare. Arbetet tog en lite annan riktning än vi trodde från början, så det blev inga staffar i avhandlingen. Tack för den positiva energi du förmedlar.

Fredrik Nilsson statistiker, medförfattare och blivande kollega. För att du varit lika engagerad i mina siffror som jag, och att du dessutom har förmågan att reda ut dem. Tack för allt tålamod och all hjälp med statistiken till arbete III och IV och för att det är så kul att jobba med dig.

Iris Zalaudek co-author of study IV, nice, friendly and enthusiastic expert and superstar on the dermoscopic sky, who always answers my emails promptly.

Dick Nelson för hjälp med de statistiska beräkningarna till våra första arbeten.

Arbetskamraterna vid hudkliniken i Helsingborg av alla yrkeskategorier som alla i högsta grad bidragit till att detta avhandlingsarbete kunnat genomföras. Tack för att ni hjälpt till att fylla i alla uppgifter i journalmallen. Tack för ert engagemang för att tillsammans ge patienterna bästa möjliga vård och samtidigt skapa en trivsam arbetsplats. Det är en stor förmån att få arbeta med er.

Mina härliga kollegor som verkligen fått ansträngа sig lite extra vid varje operationsanmälan, trots att tiden egentligen inte finns. Bara den som haft en stressig mottagning kan riktig förstå vidden av den insats ni har gjort, varje arbetsdag. TACK!!

Kerstin Martinell, min vän och vapendragare på op. Utan ditt stöd och din humor hade det nog inte blivit någon bok.

Pia Svensson, hudklinikens nav och järnlady med järnkoll. Tack för att du alltid hittar lösningar.

Ulla-Britt Karlsson, för all vänlighet och praktisk hjälp kring anslag.

Lars Gustafsson, för hjälp med QlikView.

Hela Mohs-teamet på hudkliniken i Lund, med Bertil Persson och Katarina Lundqvist i spetsen, för att det är så kul att arbeta med er. Tack Bertil för att du så generöst delar med dig av din enastående kirurgiska skicklighet. Tack Katarina för att du är en så trevlig, schysst kollega och duktig dermatopatolog och för att du gett feedback på delar av kappan.

Tack till stiftelser och fonder som gjort projektet möjligt: Stig och Ragna Gorthons stiftelse, Thelma Zoégas stiftelse, Hudfonden, Kungliga Fysiografiska sällskapet i Lund, Thorsten Birger Segerfalks stiftelse, Vera och Carl J Michaelsens fond samt Region Skåne (regionalt forskningsstöd för doktorander).

Vännerna, vad vore livet utan vänner – som en bok utan innehåll. Tack för långa promenader och löprundor, tennis, iskalla och halvkalla bad, god mat, resor, sång och musik. Ett särskilt tack till Jill Storry för hjälp med språkliga hårklyverier och Krister Gerhardsson för goda råd strax innan målgång.

Familjen – stödet från min familj har varit en absolut förutsättning för att det här projektet skulle kunna föras i hamn.

Till mina föräldrar, min syster Helena och svägerska Eva för förbehållslös kärlek, alltid! Ni är bäst!

Jan Anders min stora kärlek och vän genom livets skiften. Tack för all kärlek och tålamod och också enormt mycket hjälp med boken.

Våra barn Johannes, Alma, Alice och Josef. Ni är mitt allt! Johannes för oändligt tålamod, allmän datorsupport och många timmars Excel-hjälp med de första arbetena. Alma för de fina illustrationerna till boken. Alice för att du ifrågasätter och tvingar oss att tänka efter. Josef för att du är så klok och börjar ta över som min datorsupport.

References

1 Socialstyrelsen. Cancer incidence in Sweden 2012. *National Board of Health and Welfare* 2014.

2 Eriksson T, Tinghog G. Societal cost of skin cancer in Sweden in 2011. *Acta Derm Venereol* 2015; **95**: 347-8.

3 Tinghog G, Carlsson P, Synnerstad I *et al.* Societal cost of skin cancer in Sweden in 2005. *Acta Derm Venereol* 2008; **88**: 467-73.

4 Zalaudek I, Kittler H, Marghoob AA *et al.* Time required for a complete skin examination with and without dermoscopy: a prospective, randomized multicenter study. *Arch Dermatol* 2008; **144**: 509-13.

5 Rees J. Skin Cancer Diagnosis: Shining Light into Dark Places *Acta Derm Venereol* 2013.

6 Diepgen TL, Mahler V. The epidemiology of skin cancer. *Br J Dermatol* 2002; **146 Suppl 61**: 1-6.

7 Socialstyrelsen. Cancerincidens i Sverige 2013. *The Swedish Cancer Registry. National Board of Health and Welfare.* http://www.socialstyrelsen.se 2014.

8 Baade P, Meng X, Youlden D *et al.* Time trends and latitudinal differences in melanoma thickness distribution in Australia, 1990-2006. *Int J Cancer* 2012; **130**: 170-8.

9 Forsea AM, Del Marmol V, de Vries E *et al.* Melanoma incidence and mortality in Europe: new estimates, persistent disparities. *Br J Dermatol* 2012; **167**: 1124-30.

10 Buettner PG, Raasch BA. Incidence rates of skin cancer in Townsville, Australia. *Int J Cancer* 1998; **78**: 587-93.

11 Whiteman DC, Bray CA, Siskind V *et al.* A comparison of the anatomic distribution of cutaneous melanoma in two populations with different levels of sunlight: the west of Scotland and Queensland, Australia 1982-2001. *Cancer Causes Control* 2007; **18**: 485-91.

12 Whiteman DC, Whiteman CA, Green AC. Childhood sun exposure as a risk factor for melanoma: a systematic review of epidemiologic studies. *Cancer Causes Control* 2001; **12**: 69-82.

13 Green A, Whiteman D, Frost C *et al.* Sun exposure, skin cancers and related skin conditions. *Journal of epidemiology / Japan Epidemiological Association* 1999; **9**: S7-13.

14 Boniol M, Autier P, Boyle P *et al.* Cutaneous melanoma attributable to sunbed use: systematic review and meta-analysis. *BMJ* 2012; **345**: e4757.
15 Hery C, Tryggvadottir L, Sigurdsson T *et al.* A melanoma epidemic in Iceland: possible influence of sunbed use. *Am J Epidemiol* 2010; **172**: 762-7.
16 Lindelof B, Sigurgeirsson B, Tegner E *et al.* PUVA and cancer risk: the Swedish follow-up study. *Br J Dermatol* 1999; **141**: 108-12.
17 Stern RS, Study PFu. The risk of melanoma in association with long-term exposure to PUVA. *J Am Acad Dermatol* 2001; **44**: 755-61.
18 Whiteman DC, Stickley M, Watt P *et al.* Anatomic site, sun exposure, and risk of cutaneous melanoma. *J Clin Oncol* 2006; **24**: 3172-7.
19 Lindelof B, Dal H, Wolk K *et al.* Cutaneous squamous cell carcinoma in organ transplant recipients: a study of the Swedish cohort with regard to tumor site. *Archives of dermatology* 2005; **141**: 447-51.
20 Lichter MD, Karagas MR, Mott LA *et al.* Therapeutic ionizing radiation and the incidence of basal cell carcinoma and squamous cell carcinoma. The New Hampshire Skin Cancer Study Group. *Arch Dermatol* 2000; **136**: 1007-11.
21 Khalesi M, Whiteman DC, Tran B *et al.* A meta-analysis of pigmentary characteristics, sun sensitivity, freckling and melanocytic nevi and risk of basal cell carcinoma of the skin. *Cancer epidemiology* 2013; **37**: 534-43.
22 Holly EA, Kelly JW, Shpall SN *et al.* Number of melanocytic nevi as a major risk factor for malignant melanoma. *J Am Acad Dermatol* 1987; **17**: 459-68.
23 Olsen CM, Carroll HJ, Whiteman DC. Estimating the attributable fraction for melanoma: a meta-analysis of pigmentary characteristics and freckling. *Int J Cancer* 2010; **127**: 2430-45.
24 Kraemer KH, Lee MM, Scotto J. Xeroderma pigmentosum. Cutaneous, ocular, and neurologic abnormalities in 830 published cases. *Arch Dermatol* 1987; **123**: 241-50.
25 Gailani MR, Bale SJ, Leffell DJ *et al.* Developmental defects in Gorlin syndrome related to a putative tumor suppressor gene on chromosome 9. *Cell* 1992; **69**: 111-7.
26 Hahn H, Wicking C, Zaphiropoulous PG *et al.* Mutations of the human homolog of Drosophila patched in the nevoid basal cell carcinoma syndrome. *Cell* 1996; **85**: 841-51.
27 Epstein EH. Basal cell carcinomas: attack of the hedgehog. *Nat Rev Cancer* 2008; **8**: 743-54.
28 Cox NH, Eedy DJ, Morton CA. Guidelines for management of Bowen's disease: 2006 update. *Br J Dermatol* 2007; **156**: 11-21.
29 Marks R. Squamous cell carcinoma. *Lancet* 1996; **347**: 735-8.

30 Alam M, Ratner D. Cutaneous squamous-cell carcinoma. *N Engl J Med* 2001; **344**: 975-83.
31 Farasat S, Yu SS, Neel VA *et al.* A new American Joint Committee on Cancer staging system for cutaneous squamous cell carcinoma: creation and rationale for inclusion of tumor (T) characteristics. *J Am Acad Dermatol* 2011; **64**: 1051-9.
32 Motley R, Kersey P, Lawrence C. Multiprofessional guidelines for the management of the patient with primary cutaneous squamous cell carcinoma. *British journal of plastic surgery* 2003; **56**: 85-91.
33 Donovan J. Review of the hair follicle origin hypothesis for basal cell carcinoma. *Dermatol Surg* 2009; **35**: 1311-23.
34 Kruger K, Blume-Peytavi U, Orfanos CE. Basal cell carcinoma possibly originates from the outer root sheath and/or the bulge region of the vellus hair follicle. *Archives of dermatological research* 1999; **291**: 253-9.
35 Malone JP, Fedok FG, Belchis DA *et al.* Basal cell carcinoma metastatic to the parotid: report of a new case and review of the literature. *Ear, nose, & throat journal* 2000; **79**: 511-5, 8-9.
36 Snow SN, Sahl W, Lo JS *et al.* Metastatic basal cell carcinoma. Report of five cases. *Cancer* 1994; **73**: 328-35.
37 Weiss GJ, Korn RL. Metastatic basal cell carcinoma in the era of hedgehog signaling pathway inhibitors. *Cancer* 2012; **118**: 5310-9.
38 Jernbeck J, Glaumann B, Glas J. [Basal cell carcinoma. Clinical evaluation of the histological grading of aggressive types of cancer]. *Lakartidningen* 1988; **19**: 3467-70.
39 Lallas A, Argenziano G, Kyrgidis A *et al.* Dermoscopy uncovers clinically undetectable pigmentation in basal cell carcinoma. *Br J Dermatol* 2014; **170**: 192-5.
40 Socialstyrelsen. Basal Cell Carcinoma in Sweden 2004–2008. http://www.socialstyrelsen.se 2009; **National Board of Health and Welfare**.
41 Bastiaens MT, Hoefnagel JJ, Bruijn JA *et al.* Differences in age, site distribution, and sex between nodular and superficial basal cell carcinoma indicate different types of tumors. *J Invest Dermatol* 1998; **110**: 880-4.
42 Crowson AN. Basal cell carcinoma: biology, morphology and clinical implications. *Mod Pathol* 2006; **19 Suppl 2**: S127-47.
43 Arits AH, Schlangen MH, Nelemans PJ *et al.* Trends in the incidence of basal cell carcinoma by histopathological subtype. *J Eur Acad Dermatol Venereol* 2011; **25**: 565-9.
44 Telfer NR, Colver GB, Morton CA. Guidelines for the management of basal cell carcinoma. *Br J Dermatol* 2008; **159**: 35-48.
45 Shriner DL, McCoy DK, Goldberg DJ *et al.* Mohs micrographic surgery. *J Am Acad Dermatol* 1998; **39**: 79-97.
46 Lindemalm-Lundstam B, Dalenback J. Prospective follow-up after curettage-cryosurgery for scalp and face skin cancers. *Br J Dermatol* 2009; **161**: 568-76.

47 Nordin P, Larko O, Stenquist B. Five-year results of curettage-cryosurgery of selected large primary basal cell carcinomas on the nose: an alternative treatment in a geographical area underserved by Mohs' surgery. *Br J Dermatol* 1997; **136**: 180-3.
48 Nordin P, Stenquist B. Five-year results of curettage-cryosurgery for 100 consecutive auricular non-melanoma skin cancers. *The Journal of laryngology and otology* 2002; **116**: 893-8.
49 Kuflik EG. Cryosurgery for skin cancer: 30-year experience and cure rates. *Dermatol Surg* 2004; **30**: 297-300.
50 Sheridan AT, Dawber RP. Curettage, electrosurgery and skin cancer. *Australas J Dermatol* 2000; **41**: 19-30.
51 Mallon E, Dawber R. Cryosurgery in the treatment of basal cell carcinoma. Assessment of one and two freeze-thaw cycle schedules. *Dermatol Surg* 1996; **22**: 854-8.
52 Arits AH, Mosterd K, Essers BA *et al.* Photodynamic therapy versus topical imiquimod versus topical fluorouracil for treatment of superficial basal-cell carcinoma: a single blind, non-inferiority, randomised controlled trial. *Lancet Oncol* 2013; **14**: 647-54.
53 Bath-Hextall F, Ozolins M, Armstrong SJ *et al.* Surgical excision versus imiquimod 5% cream for nodular and superficial basal-cell carcinoma (SINS): a multicentre, non-inferiority, randomised controlled trial. *Lancet Oncol* 2014; **15**: 96-105.
54 Braathen LR, Szeimies RM, Basset-Seguin N *et al.* Guidelines on the use of photodynamic therapy for nonmelanoma skin cancer: an international consensus. International Society for Photodynamic Therapy in Dermatology, 2005. *J Am Acad Dermatol* 2007; **56**: 125-43.
55 Christensen E, Warloe T, Kroon S *et al.* Guidelines for practical use of MAL-PDT in non-melanoma skin cancer. *J Eur Acad Dermatol Venereol* 2010; **24**: 505-12.
56 Gollnick H, Barona CG, Frank RG *et al.* Recurrence rate of superficial basal cell carcinoma following treatment with imiquimod 5% cream: conclusion of a 5-year long-term follow-up study in Europe. *Eur J Dermatol* 2008; **18**: 677-82.
57 Morton CA, McKenna KE, Rhodes LE. Guidelines for topical photodynamic therapy: update. *Br J Dermatol* 2008; **159**: 1245-66.
58 Roozeboom MH, Arits AH, Nelemans PJ *et al.* Overall treatment success after treatment of primary superficial basal cell carcinoma: a systematic review and meta-analysis of randomized and nonrandomized trials. *Br J Dermatol* 2012; **167**: 733-56.
59 Salim A, Leman JA, McColl JH *et al.* Randomized comparison of photodynamic therapy with topical 5-fluorouracil in Bowen's disease. *Br J Dermatol* 2003; **148**: 539-43.
60 Argenziano G, Kittler H, Ferrara G *et al.* Slow-growing melanoma: a dermoscopy follow-up study. *Br J Dermatol* 2010; **162**: 267-73.

61 Bevona C, Goggins W, Quinn T *et al.* Cutaneous melanomas associated with nevi. *Arch Dermatol* 2003; **139**: 1620-4; discussion 4.
62 Clark WH, Jr., Elder DE, Van Horn M. The biologic forms of malignant melanoma. *Human pathology* 1986; **17**: 443-50.
63 Menzies SW, Westerhoff K, Rabinovitz H *et al.* Surface microscopy of pigmented basal cell carcinoma. *Arch Dermatol* 2000; **136**: 1012-6.
64 Greenwald HS, Friedman EB, Osman I. Superficial spreading and nodular melanoma are distinct biological entities: a challenge to the linear progression model. *Melanoma Res* 2012; **22**: 1-8.
65 Clark WH, Jr., Elder DE, Guerry Dt *et al.* A study of tumor progression: the precursor lesions of superficial spreading and nodular melanoma. *Human pathology* 1984; **15**: 1147-65.
66 Lindholm C, Andersson R, Dufmats M *et al.* Invasive cutaneous malignant melanoma in Sweden, 1990-1999. A prospective, population-based study of survival and prognostic factors. *Cancer* 2004; **101**: 2067-78.
67 Clark WH, Jr., Mihm MC, Jr. Lentigo maligna and lentigo-maligna melanoma. *The American journal of pathology* 1969; **55**: 39-67.
68 Koh HK, Michalik E, Sober AJ *et al.* Lentigo maligna melanoma has no better prognosis than other types of melanoma. *J Clin Oncol* 1984; **2**: 994-1001.
69 Weinstock MA, Sober AJ. The risk of progression of lentigo maligna to lentigo maligna melanoma. *Br J Dermatol* 1987; **116**: 303-10.
70 Bradford PT, Goldstein AM, McMaster ML *et al.* Acral lentiginous melanoma: incidence and survival patterns in the United States, 1986-2005. *Arch Dermatol* 2009; **145**: 427-34.
71 Coleman WP, 3rd, Loria PR, Reed RJ *et al.* Acral lentiginous melanoma. *Arch Dermatol* 1980; **116**: 773-6.
72 Breslow A. Thickness, cross-sectional areas and depth of invasion in the prognosis of cutaneous melanoma. *Ann Surg* 1970; **172**: 902-8.
73 Balch CM, Gershenwald JE, Soong SJ *et al.* Final version of 2009 AJCC melanoma staging and classification. *J Clin Oncol* 2009; **27**: 6199-206.
74 http://www.cancercentrum.se/sv/Vardprogram/Malignt-melanom/. Nationellt vårdprogram för melanom. 2014.
75 Morton DL, Thompson JF, Cochran AJ *et al.* Final trial report of sentinel-node biopsy versus nodal observation in melanoma. *N Engl J Med* 2014; **370**: 599-609.
76 Akay BN, Kocyigit P, Heper AO *et al.* Dermatoscopy of flat pigmented facial lesions: diagnostic challenge between pigmented actinic keratosis and lentigo maligna. *Br J Dermatol* 2010; **163**: 1212-7.

77 Zalaudek I, Ferrara G, Leinweber B *et al.* Pitfalls in the clinical and dermoscopic diagnosis of pigmented actinic keratosis. *J Am Acad Dermatol* 2005; **53**: 1071-4.
78 Marks R, Rennie G, Selwood TS. Malignant transformation of solar keratoses to squamous cell carcinoma. *Lancet* 1988; **1**: 795-7.
79 Werner RN, Sammain A, Erdmann R *et al.* The natural history of actinic keratosis: a systematic review. *Br J Dermatol* 2013; **169**: 502-18.
80 Sanderson KV. The structure of seborrhoeic keratoses. *Br J Dermatol* 1968; **80**: 588-93.
81 Zalaudek I, Catricala C, Moscarella E *et al.* What dermoscopy tells us about nevogenesis. *J Dermatol* 2011; **38**: 16-24.
82 Green A, Siskind V, Hansen ME *et al.* Melanocytic nevi in schoolchildren in Queensland. *J Am Acad Dermatol* 1989; **20**: 1054-60.
83 Wachsmuth RC, Turner F, Barrett JH *et al.* The effect of sun exposure in determining nevus density in UK adolescent twins. *J Invest Dermatol* 2005; **124**: 56-62.
84 Hofmann-Wellenhof R, Blum A, Wolf IH *et al.* Dermoscopic classification of atypical melanocytic nevi (Clark nevi). *Arch Dermatol* 2001; **137**: 1575-80.
85 Marghoob AA, Korzenko AJ, Changchien L *et al.* The beauty and the beast sign in dermoscopy. *Dermatol Surg* 2007; **33**: 1388-91.
86 Lallas A, Moscarella E, Longo C *et al.* Likelihood of finding melanoma when removing a Spitzoid-looking lesion in patients aged 12 years or older. *J Am Acad Dermatol* 2015; **72**: 47-53.
87 Ferrara G, Soyer HP, Malvehy J *et al.* The many faces of blue nevus: a clinicopathologic study. *Journal of cutaneous pathology* 2007; **34**: 543-51.
88 Kovalyshyn I, Braun R, Marghoob A. Congenital melanocytic naevi. *Australas J Dermatol* 2009; **50**: 231-40; quiz 41-2.
89 Clark WH, Jr., Reimer RR, Greene M *et al.* Origin of familial malignant melanomas from heritable melanocytic lesions. 'The B-K mole syndrome'. *Arch Dermatol* 1978; **114**: 732-8.
90 Clemente C, Cochran AJ, Elder DE *et al.* Histopathologic diagnosis of dysplastic nevi: concordance among pathologists convened by the World Health Organization Melanoma Programme. *Human pathology* 1991; **22**: 313-9.
91 Augustsson A, Stierner U, Rosdahl I *et al.* Common and dysplastic naevi as risk factors for cutaneous malignant melanoma in a Swedish population. *Acta Derm Venereol* 1991; **71**: 518-24.
92 Marks R, Dorevitch AP, Mason G. Do all melanomas come from "moles"? A study of the histological association between melanocytic naevi and melanoma. *Australas J Dermatol* 1990; **31**: 77-80.

93 Gruber SB, Barnhill RL, Stenn KS *et al.* Nevomelanocytic proliferations in association with cutaneous malignant melanoma: a multivariate analysis. *J Am Acad Dermatol* 1989; **21**: 773-80.
94 Tsao H, Bevona C, Goggins W *et al.* The transformation rate of moles (melanocytic nevi) into cutaneous melanoma: a population-based estimate. *Arch Dermatol* 2003; **139**: 282-8.
95 Kittler H, Tschandl P. Dysplastic nevus: why this term should be abandoned in dermatoscopy. *Dermatol Clin* 2013; **31**: 579-88, viii.
96 Barnhill RL, Roush GC. Correlation of clinical and histopathologic features in clinically atypical melanocytic nevi. *Cancer* 1991; **67**: 3157-64.
97 Annessi G, Cattaruzza MS, Abeni D *et al.* Correlation between clinical atypia and histologic dysplasia in acquired melanocytic nevi. *J Am Acad Dermatol* 2001; **45**: 77-85.
98 Ahnlide I, Bjellerup M. [Effective management of suspected skin cancer. New logistics introduced in Helsingborg]. *Lakartidningen* 2006; **103**: 3946-9.
99 http://www.cancercentrum.se/Global/RCC Samverkan/Dokument/V%C3%A5rdprogram/NatVP_Malignt_melanom_130520_final%5Bl%C3%A5ng%5D.pdf.
100 Brodland DG, Zitelli JA. Surgical margins for excision of primary cutaneous squamous cell carcinoma. *J Am Acad Dermatol* 1992; **27**: 241-8.
101 Rowe DE, Carroll RJ, Day CL, Jr. Mohs surgery is the treatment of choice for recurrent (previously treated) basal cell carcinoma. *J Dermatol Surg Oncol* 1989; **15**: 424-31.
102 Rowe DE, Carroll RJ, Day CL, Jr. Long-term recurrence rates in previously untreated (primary) basal cell carcinoma: implications for patient follow-up. *J Dermatol Surg Oncol* 1989; **15**: 315-28.
103 Paoli J, Daryoni S, Wennberg AM *et al.* 5-year recurrence rates of Mohs micrographic surgery for aggressive and recurrent facial basal cell carcinoma. *Acta Derm Venereol* 2011; **91**: 689-93.
104 Stenquist B, Wennberg AM, Larko O. Mohs micrographic surgery in Gothenburg, Sweden. *Acta Derm Venereol* 2000; **80**: 152.
105 Schon MP, Schon M. Imiquimod: mode of action. *Br J Dermatol* 2007; **157 Suppl 2**: 8-13.
106 Nedved D, Tonkovic-Capin V, Hunt E *et al.* Diagnostic concordance rates in the subtyping of basal cell carcinoma by different dermatopathologists. *Journal of cutaneous pathology* 2014; **41**: 9-13.
107 Braun RP, Gutkowicz-Krusin D, Rabinovitz H *et al.* Agreement of dermatopathologists in the evaluation of clinically difficult melanocytic lesions: how golden is the 'gold standard'? *Dermatology* 2012; **224**: 51-8.
108 Duncan LM, Berwick M, Bruijn JA *et al.* Histopathologic Recognition and Grading of Dysplastic Melanocytic Nevi: An

Interobserver Agreement Study. *Journal of Investigative Dermatology* 1993; **100**: 318S-21S.
109 Rippey JJ. Why classify basal cell carcinomas? *Histopathology* 1998; **32**: 393-8.
110 Saldanha G, Fletcher A, Slater DN. Basal cell carcinoma: a dermatopathological and molecular biological update. *Br J Dermatol* 2003; **148**: 195-202.
111 Kamyab-Hesari K, Seirafi H, Naraghi ZS *et al.* Diagnostic accuracy of punch biopsy in subtyping basal cell carcinoma. *J Eur Acad Dermatol Venereol* 2012.
112 Roozeboom MH, Mosterd K, Winnepenninckx VJ *et al.* Agreement between histological subtype on punch biopsy and surgical excision in primary basal cell carcinoma. *J Eur Acad Dermatol Venereol* 2013; **27**: 894-8.
113 Wolberink EA, Pasch MC, Zeiler M *et al.* High discordance between punch biopsy and excision in establishing basal cell carcinoma subtype: analysis of 500 cases. *J Eur Acad Dermatol Venereol* 2013; **27**: 985-9.
114 Russell EB, Carrington PR, Smoller BR. Basal cell carcinoma: a comparison of shave biopsy versus punch biopsy techniques in subtype diagnosis. *J Am Acad Dermatol* 1999; **41**: 69-71.
115 MacKie RM. Cutaneous microscopy in vivo as an aid to preoperative assessment of pigmented lesions of the skin. *British journal of plastic surgery* 1972; **25**: 123-9.
116 Braun-Falco O, Stolz W, Bilek P *et al.* [The dermatoscope. A simplification of epiluminescent microscopy of pigmented skin changes]. *Hautarzt* 1990; **41**: 131-6.
117 Pan Y, Gareau DS, Scope A *et al.* Polarized and nonpolarized dermoscopy: the explanation for the observed differences. *Arch Dermatol* 2008; **144**: 828-9.
118 Vestergaard ME, Macaskill P, Holt PE *et al.* Dermoscopy compared with naked eye examination for the diagnosis of primary melanoma: a meta-analysis of studies performed in a clinical setting. *The British journal of dermatology* 2008; **159**: 669-76.
119 Argenziano G, Soyer HP, Chimenti S *et al.* Dermoscopy of pigmented skin lesions: results of a consensus meeting via the Internet. *J Am Acad Dermatol* 2003; **48**: 679-93.
120 Pehamberger H, Steiner A, Wolff K. In vivo epiluminescence microscopy of pigmented skin lesions. I. Pattern analysis of pigmented skin lesions. *J Am Acad Dermatol* 1987; **17**: 571-83.
121 Binder M, Schwarz M, Winkler A *et al.* Epiluminescence microscopy. A useful tool for the diagnosis of pigmented skin lesions for formally trained dermatologists. *Arch Dermatol* 1995; **131**: 286-91.
122 Wazaefi Y, Gaudy-Marqueste C, Avril MF *et al.* Evidence of a limited intra-individual diversity of nevi: intuitive perception of

dominant clusters is a crucial step in the analysis of nevi by dermatologists. *J Invest Dermatol* 2013; **133**: 2355-61.
123 Argenziano G, Catricala C, Ardigo M *et al.* Dermoscopy of patients with multiple nevi: Improved management recommendations using a comparative diagnostic approach. *Archives of dermatology* 2011; **147**: 46-9.
124 Stolz W, Riemann A, Armand B *et al.* ABCD rule of dermatoscopy: a new practical method for early recognition of malignant melanoma. *European Journal of Dermatology* 1994; **4**: 7.
125 Menzies SW, Ingvar C, McCarthy WH. A sensitivity and specificity analysis of the surface microscopy features of invasive melanoma. *Melanoma Res* 1996; **6**: 55-62.
126 Argenziano G, Fabbrocini G, Carli P *et al.* Epiluminescence microscopy for the diagnosis of doubtful melanocytic skin lesions. Comparison of the ABCD rule of dermatoscopy and a new 7-point checklist based on pattern analysis. *Arch Dermatol* 1998; **134**: 1563-70.
127 Henning JS, Dusza SW, Wang SQ *et al.* The CASH (color, architecture, symmetry, and homogeneity) algorithm for dermoscopy. *J Am Acad Dermatol* 2007; **56**: 45-52.
128 Pizzichetta MA, Talamini R, Piccolo D *et al.* The ABCD rule of dermatoscopy does not apply to small melanocytic skin lesions. *Arch Dermatol* 2001; **137**: 1376-8.
129 Menzies SW, Ingvar C, Crotty KA *et al.* Frequency and morphologic characteristics of invasive melanomas lacking specific surface microscopic features. *Arch Dermatol* 1996; **132**: 1178-82.
130 Argenziano G, Catricala C, Ardigo M *et al.* Seven-point checklist of dermoscopy revisited. *Br J Dermatol* 2010.
131 Rosendahl C, Tschandl P, Cameron A *et al.* Diagnostic accuracy of dermatoscopy for melanocytic and nonmelanocytic pigmented lesions. *J Am Acad Dermatol* 2011; **64**: 1068-73.
132 Carli P, De Giorgi V, Massi D *et al.* The role of pattern analysis and the ABCD rule of dermoscopy in the detection of histological atypia in melanocytic naevi. *Br J Dermatol* 2000; **143**: 290-7.
133 Carli P, Quercioli E, Sestini S *et al.* Pattern analysis, not simplified algorithms, is the most reliable method for teaching dermoscopy for melanoma diagnosis to residents in dermatology. *Br J Dermatol* 2003; **148**: 981-4.
134 Dolianitis C, Kelly J, Wolfe R *et al.* Comparative performance of 4 dermoscopic algorithms by nonexperts for the diagnosis of melanocytic lesions. *Arch Dermatol* 2005; **141**: 1008-14.
135 Annessi G, Bono R, Sampogna F *et al.* Sensitivity, specificity, and diagnostic accuracy of three dermoscopic algorithmic methods in the diagnosis of doubtful melanocytic lesions: the importance of light brown structureless areas in differentiating atypical melanocytic nevi from thin melanomas. *J Am Acad Dermatol* 2007; **56**: 759-67.

136 Kittler H, Pehamberger H, Wolff K *et al.* Diagnostic accuracy of dermoscopy. *Lancet Oncol* 2002; **3**: 159-65.
137 Binder M, Puespoeck-Schwarz M, Steiner A *et al.* Epiluminescence microscopy of small pigmented skin lesions: short-term formal training improves the diagnostic performance of dermatologists. *J Am Acad Dermatol* 1997; **36**: 197-202.
138 Westerhoff K, McCarthy WH, Menzies SW. Increase in the sensitivity for melanoma diagnosis by primary care physicians using skin surface microscopy. *Br J Dermatol* 2000; **143**: 1016-20.
139 Argenziano G, Puig S, Zalaudek I *et al.* Dermoscopy improves accuracy of primary care physicians to triage lesions suggestive of skin cancer. *J Clin Oncol* 2006; **24**: 1877-82.
140 Binder M, Kittler H, Steiner A *et al.* Reevaluation of the ABCD rule for epiluminescence microscopy. *J Am Acad Dermatol* 1999; **40**: 171-6.
141 Zalaudek I, Kreusch J, Giacomel J *et al.* How to diagnose nonpigmented skin tumors: a review of vascular structures seen with dermoscopy: part I. Melanocytic skin tumors. *J Am Acad Dermatol* 2010; **63**: 361-74; quiz 75-6.
142 Zalaudek I, Kreusch J, Giacomel J *et al.* How to diagnose nonpigmented skin tumors: a review of vascular structures seen with dermoscopy: part II. Nonmelanocytic skin tumors. *J Am Acad Dermatol* 2010; **63**: 377-86; quiz 87-8.
143 Liebman TN, Jaimes-Lopez N, Balagula Y *et al.* Dermoscopic features of basal cell carcinomas: differences in appearance under non-polarized and polarized light. *Dermatol Surg* 2012; **38**: 392-9.
144 Giacomel J, Zalaudek I. Dermoscopy of superficial basal cell carcinoma. *Dermatol Surg* 2005; **31**: 1710-3.
145 Scalvenzi M, Lembo S, Francia MG *et al.* Dermoscopic patterns of superficial basal cell carcinoma. *Int J Dermatol* 2008; **47**: 1015-8.
146 Altamura D, Menzies SW, Argenziano G *et al.* Dermatoscopy of basal cell carcinoma: morphologic variability of global and local features and accuracy of diagnosis. *J Am Acad Dermatol* 2010; **62**: 67-75.
147 Lallas A, Tzellos T, Kyrgidis A *et al.* Accuracy of dermoscopic criteria for discriminating superficial from other subtypes of basal cell carcinoma. *J Am Acad Dermatol* 2014; **70**: 303-11.
148 Suppa M, Micantonio T, Di Stefani A *et al.* Dermoscopic variability of basal cell carcinoma according to clinical type and anatomic location. *J Eur Acad Dermatol Venereol* 2015.
149 Demirtasoglu M, Ilknur T, Lebe B *et al.* Evaluation of dermoscopic and histopathologic features and their correlations in pigmented basal cell carcinomas. *J Eur Acad Dermatol Venereol* 2006; **20**: 916-20.
150 Tabanlioglu Onan D, Sahin S, Gokoz O *et al.* Correlation between the dermatoscopic and histopathological features of pigmented basal cell carcinoma. *J Eur Acad Dermatol Venereol* 2010; **24**: 1317-25.

151 Lallas A, Apalla Z, Argenziano G *et al.* The dermatoscopic universe of basal cell carcinoma. *Dermatology practical & conceptual* 2014; **4**: 11-24.
152 Kulatunga-Moruzi C, Brooks LR, Norman GR. Coordination of analytic and similarity-based processing strategies and expertise in dermatological diagnosis. *Teach Learn Med* 2001; **13**: 110-6.
153 Moulton CA, Regehr G, Mylopoulos M *et al.* Slowing down when you should: a new model of expert judgment. *Academic medicine : journal of the Association of American Medical Colleges* 2007; **82**: S109-16.
154 Norman GR, Brooks LR. The Non-Analytical Basis of Clinical Reasoning. *Advances in health sciences education : theory and practice* 1997; **2**: 173-84.
155 Norman GR, Brooks LR, Coblentz CL *et al.* The correlation of feature identification and category judgments in diagnostic radiology. *Memory & cognition* 1992; **20**: 344-55.
156 Norman G. Building on experience--the development of clinical reasoning. *N Engl J Med* 2006; **355**: 2251-2.
157 Ahnlide I, Bjellerup M. [Surgery in the management of skin tumors. Experiences from Helsingborg]. *Lakartidningen* 2010; **107**: 981-4.
158 Team RC. R: A language and environment for statistical computing. R Foundation for Statistical Computing, Vienna, Austria. URL. http://www.R-project.org/ 2014.
159 Hothorn T, Hornik K, Wiel MAvd *et al.*

A Lego System for Conditional Inference. *The American Statistician* 2006; **60**: 257-63.
160 Therneau T, Atkinson B, Ripley B. rpart: Recursive Partitioning and Regression Trees. R package version 4.1-8. . http://CRAN.R-project.org/package=rpart 2014.
161 Breiman L, Friedman J, Olshen R *et al.* Classification and regression trees. *Wadsworth, Belsmont*.
162 Schmidt RL, Factor RE. Understanding sources of bias in diagnostic accuracy studies. *Arch Pathol Lab Med* 2013; **137**: 558-65.
163 Lindelof B, Hedblad MA, Sigurgeirsson B. Melanocytic naevus or malignant melanoma? A large-scale epidemiological study of diagnostic accuracy. *Acta dermato-venereologica* 1998; **78**: 284-8.
164 Ek EW, Giorlando F, Su SY *et al.* Clinical diagnosis of skin tumours: how good are we? *ANZ J Surg* 2005; **75**: 415-20.
165 Har-Shai Y, Hai N, Taran A *et al.* Sensitivity and positive predictive values of presurgical clinical diagnosis of excised benign and malignant skin tumors: a prospective study of 835 lesions in 778 patients. *Plast Reconstr Surg* 2001; **108**: 1982-9.
166 Heal CF, Raasch BA, Buettner PG *et al.* Accuracy of clinical diagnosis of skin lesions. *Br J Dermatol* 2008; **159**: 661-8.
167 Youl PH, Baade PD, Janda M *et al.* Diagnosing skin cancer in primary care: how do mainstream general practitioners compare

with primary care skin cancer clinic doctors? *Med J Aust* 2007; **187**: 215-20.
168 Laupacis A, Sackett DL, Roberts RS. An assessment of clinically useful measures of the consequences of treatment. *N Engl J Med* 1988; **318**: 1728-33.
169 English DR, Del Mar C, Burton RC. Factors influencing the number needed to excise: excision rates of pigmented lesions by general practitioners. *Med J Aust* 2004; **180**: 16-9.
170 Argenziano G, Cerroni L, Zalaudek I *et al.* Accuracy in melanoma detection: A 10-year multicenter survey. *Journal of the American Academy of Dermatology* 2011.
171 Baade PD, Youl PH, Janda M *et al.* Factors associated with the number of lesions excised for each skin cancer: a study of primary care physicians in Queensland, Australia. *Arch Dermatol* 2008; **144**: 1468-76.
172 Chia AL, Simonova G, Dutta B *et al.* Melanoma diagnosis: Australian dermatologists' number needed to treat. *Australas J Dermatol* 2008; **49**: 12-5.
173 Hansen C, Wilkinson D, Hansen M *et al.* How good are skin cancer clinics at melanoma detection? Number needed to treat variability across a national clinic group in Australia. *Journal of the American Academy of Dermatology* 2009; **61**: 599-604.
174 Rosendahl C, Williams G, Eley D *et al.* The impact of subspecialization and dermatoscopy use on accuracy of melanoma diagnosis among primary care doctors in Australia. *J Am Acad Dermatol* 2012.
175 Wilson RL, Yentzer BA, Isom SP *et al.* How good are US dermatologists at discriminating skin cancers? A number-needed-to-treat analysis. *J Dermatolog Treat* 2012; **23**: 65-9.
176 Carli P, De Giorgi V, Crocetti E *et al.* Improvement of malignant/benign ratio in excised melanocytic lesions in the 'dermoscopy era': a retrospective study 1997-2001. *The British journal of dermatology* 2004; **150**: 687-92.
177 Terushkin V, Warycha M, Levy M *et al.* Analysis of the benign to malignant ratio of lesions biopsied by a general dermatologist before and after the adoption of dermoscopy. *Arch Dermatol* 2010; **146**: 343-4.
178 Zalaudek I, Kittler H, Blum A *et al.* Who benefits from prophylactic surgical removal of "dysplastic" nevi? *J Dtsch Dermatol Ges* 2010; **8**: 279-80.
179 Lindelof B, Hedblad MA, Ringborg U. [Nevus or malignant melanoma? Correct diagnostic competence results in lower costs]. *Lakartidningen* 2008; **105**: 2666-9.
180 Argenziano G, Zalaudek I, Hofmann-Wellenhof R *et al.* Total body skin examination for skin cancer screening in patients with focused symptoms. *Journal of the American Academy of Dermatology* 2012; **66**: 212-9.

181 Roozeboom MH, Kreukels H, Nelemans PJ *et al.* Subtyping Basal Cell Carcinoma by Clinical Diagnosis Versus Punch Biopsy. *Acta Derm Venereol* 2015.
182 Flohil SC, Koljenovic S, de Haas ER *et al.* Cumulative risks and rates of subsequent basal cell carcinomas in the Netherlands. *Br J Dermatol* 2011; **165**: 874-81.
183 McCormack CJ, Kelly JW, Dorevitch AP. Differences in age and body site distribution of the histological subtypes of basal cell carcinoma. A possible indicator of differing causes. *Arch Dermatol* 1997; **133**: 593-6.
184 Flohil SC, Proby CM, Forrest AD *et al.* Basal cell carcinomas without histological confirmation and their treatment: an audit in four European regions. *Br J Dermatol* 2012; **167 Suppl 2**: 22-8.
185 Flohil SC, van Tiel S, Koljenovic S *et al.* Frequency of non-histologically diagnosed basal cell carcinomas in daily Dutch practice. *J Eur Acad Dermatol Venereol* 2013; **27**: 907-11.
186 Lorentzen H, Weismann K, Kenet RO *et al.* Comparison of dermatoscopic ABCD rule and risk stratification in the diagnosis of malignant melanoma. *Acta Derm Venereol* 2000; **80**: 122-6.

LUND UNIVERSITY
Faculty of Medicine

Lund University
Faculty of Medicine
Doctoral Dissertation Series: 2015:124
ISBN 978-91-7619-204-7
ISSN 1652-8220