



LUND UNIVERSITY

Contact Allergy to Gold in Patients with Oral Lichen Lesions.

Ahlgren, Camilla; Bruze, Magnus; Möller, Halvor; Gruvberger, Birgitta; Axéll, Tony; Liedholm, Rolf; Nilner, Krister

Published in:
Acta Dermato-Venereologica

DOI:
[10.2340/00015555-1247](https://doi.org/10.2340/00015555-1247)

2012

[Link to publication](#)

Citation for published version (APA):

Ahlgren, C., Bruze, M., Möller, H., Gruvberger, B., Axéll, T., Liedholm, R., & Nilner, K. (2012). Contact Allergy to Gold in Patients with Oral Lichen Lesions. *Acta Dermato-Venereologica*, 92(2), 138-143.
<https://doi.org/10.2340/00015555-1247>

Total number of authors:
7

General rights

Unless other specific re-use rights are stated the following general rights apply:

Copyright and moral rights for the publications made accessible in the public portal are retained by the authors and/or other copyright owners and it is a condition of accessing publications that users recognise and abide by the legal requirements associated with these rights.

- Users may download and print one copy of any publication from the public portal for the purpose of private study or research.
- You may not further distribute the material or use it for any profit-making activity or commercial gain
- You may freely distribute the URL identifying the publication in the public portal

Read more about Creative commons licenses: <https://creativecommons.org/licenses/>

Take down policy

If you believe that this document breaches copyright please contact us providing details, and we will remove access to the work immediately and investigate your claim.

LUND UNIVERSITY

PO Box 117
221 00 Lund
+46 46-222 00 00

INVESTIGATIVE REPORT

Contact Allergy to Gold in Patients with Oral Lichen Lesions

Camilla AHLGREN¹, Magnus BRUZE², Halvor MÖLLER², Birgitta GRUVBERGER², Tony AXÉLL³, Rolf LIEDHOLM⁴ and Krister NILNER¹

Departments of ¹Prosthetic Dentistry and ⁴Oral and Maxillofacial Surgery and Oral Medicine, Faculty of Odontology, Malmö University, ²Department of Occupational and Environmental Dermatology, Skåne University Hospital, Lund University, Malmö, and ³Oral and Maxillofacial Unit, Halmstad Hospital, Halmstad, Sweden

The aetiology of oral lichen lesions is obscure. In this study the frequency of contact allergy to gold in 83 patients with oral lichen lesions was compared with that in two control groups, comprising 319 age- and gender-matched patients with dermatitis selected from files and 83 clinically examined dermatitis patients. All patients were tested epicutaneously with gold sodium thiosulphate. The two control groups tested were under examination for a tentative diagnosis of allergic dermatitis not related to oral problems. The frequency of contact allergy to gold was 28.9% in the patients with oral lichen lesions, 18.2% in patients selected from files, and 22.9% in the clinically examined control patients. The difference in frequency between patients with oral lichen lesions and those taken from files was statistically significant. Key words: delayed hypersensitivity; dental gold; oral lichen planus.

(Accepted July 18, 2011.)

Acta Derm Venereol 2012; 92: 138–143.

Camilla Ahlgren, Odont, DDS, Department of Prosthetic Dentistry, Faculty of Odontology, Malmö University, Carl Gustafs väg 34, SE-205 06 Malmö, Sweden. E-mail: Camilla.Ahlgren@mah.se

Contact allergy to gold occurs frequently (1, 2), but its clinical relevance is unclear. The clinical features of intra-oral contact allergy related to gold exposure are not specific, although lichenoid reactions appear to be the most common manifestation of contact allergy in the oral mucosa (3). Studies on contact allergy to gold and oral mucosal problems often comprise small samples only, and the most frequently studied lesions are oral lichen planus (OLP) and oral lichenoid contact reactions (OLCR).

OLP and OLCR are indistinguishable clinically and histologically (4). This has been claimed to be a diagnostic dilemma for the clinician and the oral pathologist (5). The terminology used in studies may differ, making it difficult to compare results.

Patients with OLP and OLCR have presented relatively high frequencies of contact allergy to gold and other dental materials, such as amalgam (6–8). Some patients disclosed complete or partial healing of lesions when amalgam restorations were removed, even though they were not sensitized to mercury (9–11).

Contact allergy *per se* is not a disease, but can cause allergic contact dermatitis or stomatitis in a patient with exposure to the allergen in question. Establishing contact allergy to mercury or gold may be problematic. Test methods vary, as do the day on which patch tests are read. Thus, there are difficulties in comparing the results of different studies. Furthermore, some metals (mercury, gold, and palladium) give rise to late allergic reactions during testing (7, 12), and consequently the results of studies in which patch test readings are restricted to the first 4 days should be interpreted with caution.

Traditionally, gold trichloride (GTC), potassium dicyanoaurate, and gold sodium thiomalate (GSTM) were used to patch test for contact allergy to gold, but in recent years gold sodium thiosulphate (GSTS) has been the test substance of choice (13). In 1994, positive reactions to GSTS were shown to represent true allergy (1). The histological and immunochemical study by Möller et al. strongly supports this finding (14).

Gold compounds, when given systemically for rheumatic diseases, are the drugs that are most frequently reported to cause cutaneous drug reactions (15). Studies on contact allergy to gold in patients with oral lichenoid lesions/reactions report higher frequencies of positive reactions (6, 16) compared with the corresponding frequency of a dermatitis population in 2001 to 2002 reported by the North American Contact Dermatitis Group (NACDG) (6, 17). In dermatitis patients, contact allergy to gold and presence of dental gold are associated. The first indication of an over-representation of higher frequencies of contact allergy to gold in patients with gold restorations in a questionnaire study was published in 1994 (18) and the results were confirmed in clinical studies groups (19, 20). The relationship between presence and amount of dental gold and contact allergy to gold has thereafter been verified in a cohort study with appropriate methodological testing (21).

As removal of gold restorations is more hazardous than removal of amalgam, more research in the field is needed before intervention studies are performed. The aim of the present study therefore was to investigate the frequencies of contact allergy to gold in three groups of age- and gender-matched patients: (i) patients with oral lichen lesions (OLL) (OLP and OLCR), (ii) a control group of dermatitis patients selected from files (PSFF

group), and (iii) an orally examined control group of patients with suspected contact dermatitis (DP group). It was hypothesized that patients with OLL would have a higher frequency of contact allergy to dental gold than dermatitis patients (DP and PSFF groups), indicating a possible aetiology and/or maintenance of the OLL.

MATERIALS AND METHODS

Patients

During 2005 to 2008, 96 consecutive patients referred for suspicion of OLP/OLCR were invited to participate in the study. The patients had been referred to the Oral and Maxillofacial Unit in Halmstad, the Department of Oral and Maxillofacial Surgery and Oral Medicine, Faculty of Odontology at Malmö University or to the Department of Oral and Maxillofacial Surgery, Malmö University Hospital, Malmö. The main inclusion criterion was fulfilment of the revised and modified World Health Organization (WHO) criteria according to van der Meij et al. (22). No distinction was made between OLP and OLCR in this study, and patients were pooled under the term OLL.

If the histopathological diagnosis of OLL was non-conclusive, the diagnosis was based on the following clinical criteria:

- A lacelike network of slightly raised grey-white lines (reticular pattern)
- Bilateral buccal, more or less symmetrical lesions
- Erosive (ulcerative), atrophic (erythematous), bullous, and plaque-type lesions when reticular lesions occur elsewhere in the oral mucosa

Specialists experienced in oral medicine determined fulfilment of clinical criteria. Exclusion criteria were:

- Current systemic corticosteroid treatment
- Lesions limited to the gingiva
- Patients below the age of 20 years

Eighty-three of the 96 patients in the OLL group completed the study. One patient presented a leukoplakia and was excluded and 12 patients declined to participate because of lack of time or illness. One patient, who fulfilled the clinical criteria for OLL and only doubtfully fulfilled the histopathological criteria, was included (Fig. 1). Mean age in the OLL group was 60.0 years ($n=83$, F (females) = 65.1%).

Control groups

An age- and gender-matched control group of 319 dermatitis patients tested under the same time period as the OLL patients at the Department of Occupational and Environmental Dermatology in Malmö (hereafter: the department) were randomly recruited from patient files (PSFF group). The aim was to select four matched (age and gender) patients per OLL patient. This was, however, not possible in all groups although the distribution of the patients in the OLL and PSFF group, respectively, did not differ significantly ($p>0.05$, Table I). Mean age in the PSFF group was 59.4 years ($n=319$, F = 64.9%).

In addition to the PSFF group, a second control group of dermatitis patients, the DP group, was recruited. Two approaches were used to invite 154 consecutive patients who had been referred to the department, for suspicion of eczematous disease to participate in the clinically examined control group (DP group); (i) 94 patients were contacted by telephone before patch testing and offered a clinical dental examination and a radiological examination; and (ii) 60 patients who were undergoing routine patch testing because of a suspected allergic contact dermatitis were contacted at the department.

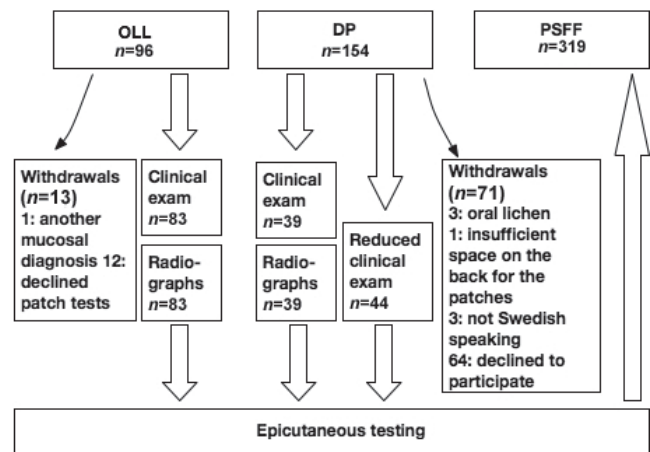


Fig. 1. Patients available and included (open arrows) for different examinations in the oral lichen lesions (OLL) group and the two control groups, respectively. The chart also shows the drop-outs (small arrows). PSFF: patients selected from files; DP: dermatitis patients.

Exclusion criteria were:

- Current systemic corticosteroid treatment
- Patients with oral mucosal problems or problems allegedly caused by dental materials
- Patients below the age of 20 years

Fifty-five of the 94 control patients contacted by telephone declined to participate in the clinical dental examination. Sixteen patients from the group of 60 who underwent a less comprehensive clinical examination in conjunction with epicutaneous patch testing declined to participate or were excluded (Fig. 1). Mean age in the DP group was 56.5 years ($n=83$, F = 72.3%).

Questionnaire and medical history

Before the oral examination, the clinically examined patients (OLL and DP groups) completed a questionnaire containing questions on general and oral health, current medication, occupational exposure to gold, and skin problems related to wearing gold jewellery. The controls from the DP group who were contacted during routine patch testing at the department and consented to participate ($n=44$) did not complete a questionnaire. However, they answered questions on oral health, so that patients with possible allergic oral symptoms caused by dental materials could be excluded.

Clinical examination

Ninety-six patients with OLL and 39 control patients (from the DP group) who had been contacted by telephone underwent a thorough clinical dental examination including registration of dental materials and inspection of the oral mucosa. Clinical colour photographs of the oral mucosa were taken in all OLL patients.

For each tooth, the number of surfaces with a dental gold restoration was quantified as follows:

- 0 = no surface
- 1 = one surface or one gold post
- 2 = two surfaces
- 3 = three surfaces
- 4 = four or more surfaces, or an artificial crown covering an anterior tooth
- 5 = an artificial crown covering a posterior tooth

Another 44 control patients (from the DP group) who had been approached at the department were examined intra-orally at the

Table I. Matched patients selected from files (PSFF) in relation to number of patients with oral lichen lesions (OLL)

Age groups (years)	Females		Males		Total	
	OLL patients, <i>n</i>	PSFF patients, <i>n</i>	OLL patients, <i>n</i>	PSFF patients, <i>n</i>	OLL patients, <i>n</i>	PSFF patients, <i>n</i>
31–35			1	4	1	4
36–40	1	4	2	8	3	12
41–45	3	12	2	8	5	20
46–50	2	8	4	16	6	24
51–55	8	32	2	8	10	40
56–60	11	44	5	20	16	64
61–65	12	48	6	24	18	72
66–70	7	28	4	13	11	41
71–75	5	16	1	4	6	20
76–80	4	11	2	7	6	18
81–85	1	4			1	4

department for presence of: (i) dental restorations (quantified as above); and (ii) mucosal lesions.

Biopsies

In the OLL group, biopsies of the lesions were performed to support the clinical diagnosis of a lichenoid lesion according to the revised criteria by van der Meij et al. (22). The histopathological criteria were:

- Presence of a well-defined band-like zone of cellular infiltration that is confined to the superficial part of the connective tissue and consists mainly of lymphocytes.
- Signs of liquefaction degeneration in the basal cell layer.
- Absence of epithelial dysplasia.

In case patients fulfilled clinical, but only doubtfully histological, OLL criteria they were included in the study.

Radiological examination

To confirm clinical observation concerning dental materials, panoramic radiographs were taken in all patients with OLL and 39 of the control patients. When cast-gold posts, screw posts, or other intra-radicular posts, due to their density and configuration, were observed in a panoramic radiograph, intraoral bitewing or periapical radiographs were also taken.

Epicutaneous tests

Patients with OLL were patch-tested with a dental material series (from the dental series, cheilitis series and additional substances), including GSTS 2.0% w/w in petrolatum (pet) (Chemotechnique Diagnostics, Vellinge, Sweden) on the upper back in IQ chambers® (Chemotechnique Diagnostics). After 2 days, the patients removed the patches. On day 3 (D3) and day 7 (D7), readings were performed by an experienced dermatologist according to International Contact Dermatitis Research Group (ICDRG) guidelines (23). OLL patients with doubtful reactions to GSTS 2.0% in pet on D3 were re-tested with GSTS 5.0% w/w in pet. Their patches were read after another 4 days, i.e. on D7 (24).

Control patients were tested with the dermatological baseline series (including 2% GSTS) and, depending on reasons for referral, with other substances. PSFF patients tested also with the dental series and the cheilitis series were excluded. As mentioned, DP patients were excluded when there was a suspicion of contact allergy to dental materials and therefore were not tested with the dental and cheilitis series.

Statistical analyses

The Statistical Package for the Social Sciences (SPSS, version 16.0; SPSS, Chicago, IL, USA) was used for statistical analyses.

The significance level was set at $p < 0.05$. Pearson's χ^2 test and Fisher's exact test evaluated differences between two groups. *t*-tests compared the number of surfaces with gold in the two groups studied.

Informed consent and ethical approval

All clinically examined study participants signed an informed consent form. The Regional Ethical Review Board, Lund, Sweden, approved the study per the Declaration of Helsinki and the International Conference of Harmonization (ICH) guidelines on Good Clinical Practice.

RESULTS

Questionnaire

The following findings were significantly more common in the DP control group ($n = 39$) than in the OLL group ($n = 83$): asthma and/or allergy ($p = 0.004$), hay fever ($p = 0.011$), dry skin ($p = 0.020$), atopic dermatitis ($p = 0.014$), and smoking ($p = 0.009$). Diabetes mellitus, age, and gender did not differ significantly.

Four (4.8%) patients with OLL and one (2.6%) DP patient reported psychiatric illness ($p = 1.00$). Medication for high blood pressure did not differ significantly between OLL patients (28%) and controls (DP, 15.8%) ($p = 0.144$).

Eleven (13%) of the patients in the OLL group reported OLL onset associated with dental restorative treatment, 4 (4.8%) patients illness and general disease and 6 (7.2%) patients family problems. Of the 6 patients in the OLL group who reported lichen lesions on the skin, 4 presented contact allergy to gold.

Contact allergy to gold

The frequency of contact allergy to gold differed between the OLL and PSFF groups (28.9% and 18.2%, respectively, $p = 0.032$, Table II), but did not differ between the two control groups (DP and PSFF, $p = 0.438$).

In the OLL group, 28.9% of the patients tested positive to GSTS compared with 22.9% in the DP control group; a difference between the two groups that was not statistically significant ($p = 0.376$, Table II). Twenty-one

Table II. Number of patients with contact allergy to gold

	DP			OLL			PSFF	
	n	Au allergy, n (%)	p	n	Au allergy, n (%)	p	n	Au allergy, n (%)
Males	23	4 (17.4)	0.386	29	8 (27.6)	0.119	112	17 (15.2)
Females	60	15 (25.0)	0.579	54	16 (29.6)	0.120	207	41 (19.8)
All	83	19 (22.9)	0.376	83	24 (28.9)	0.031	319	58 (18.2)

DP: dermatitis patients; OLL: patients with oral lichen lesions; PSFF: patients selected from files.

OLL patients (25.3%) with doubtful reactions were re-tested with GSTS 5.0% and were read on D7 (4 days after re-testing). Of these patients, three reacted positively to GSTS 5.0% (D4), and two had positive reactions to GSTS 2.0% on D7.

No significant differences were found between the OLL group and the DP control group also when recruitment method was considered. Contact allergy to gold was found in 20.5% of the 39 DP control patients who had undergone a clinical dental examination and 25% of the 44 DP control patients who were merely examined in conjunction with epicutaneous patch testing at the department.

Fifteen (31.9%) of 47 patients with OLL judged to be in contact with a dental gold restoration had a contact allergy to gold ($p=0.491$).

Dental gold

Dental gold was found in 60.2% of the patients with OLL and 54.2% of the control patients (DP group). The mean number of tooth surfaces with dental gold was $19.7 \pm$ standard deviation 26.9) in the OLL group, and 15.5 ± 24.2 in the DP group ($p=0.298$).

The difference between the OLL and DP groups with regard to presence of dental gold restorations was not significant ($p=0.433$).

DISCUSSION

High frequencies of contact allergy to gold were found in this controlled study. The frequency of contact allergy to gold differed significantly between the OLL (28.9%) and PSFF (18.2%) groups. The difference was not statistically significant between OLL and DP groups, but there was a numeric difference and approximately 25% more OLL patients had a contact allergy to gold. The number of tooth surfaces restored with dental gold alloys did not differ significantly between the clinically examined groups (OLL and DP).

Patients selected from files tested with GSTS 2% in the baseline series from the same time-period were combined with an orally examined control group to enhance the validity of the study. The selection of two control groups also reduced the possible bias that patients in the DP group might have agreed to participate in case of having dental gold restorations and possible subjective suspicion of contact allergy to gold.

Although the prevalence of OLL in the Swedish adult population is approximately 2% (25), recruitment was time-consuming. This may be due to the fact that most patients with OLL visit their general dental practitioner regularly and are referred to a specialist clinic only when the lesions change in magnitude or appearance or give rise to symptoms.

As OLP and OLCR are indistinguishable clinically and histologically (4), these groups of patients were pooled into an OLL group, which refers mainly to the clinical appearance. A clinical diagnosis of OLL that was not confirmed histologically did not exclude the patient from the study. In fact, all but one clinical OLL diagnosis were supported by histology, thus strengthening the clinical diagnostic accuracy of OLL. Out of the 83 patients with OLL, 6 (7.2%) had lichen ruber planus on the skin and 7 (8.4%) a widespread distribution of lichen lesions in the oral mucosa. Thus, the lesions of most patients with OLL were restricted to the oral mucosa close to dental materials. These findings are in accordance with the results of another study in a Swedish adult general population (25). Information on other locations of lesions were asked for during history-taking, but were not examined as to why no conclusions on this issue can be drawn from this study.

Three of the re-tested patients reacted positively to gold, and these patients are included in the 28.9% patients with OLL and contact allergy to gold. As no difference was found between OLL and DP patients, these 3 patients did not influence the results in either direction. Due to patient flow problems only patients with doubtful reactions in the OLL group were re-tested.

Allergic contact stomatitis is often difficult to diagnose, and the oral clinical relevance of a contact allergy to gold demonstrated epicutaneously is difficult to estimate. Several studies have, however, reported associations between a hypersensitivity to gold or, especially, mercury and OLP/OLCR manifestations (6, 7, 16, 26).

In a retrospective study (27) of 206 patients with suspicion of contact allergy to dental metals, 28 patients had positive patch test reactions to dental metals, and OLP and stomatitis were the most frequent oral manifestations in these patients. However, only in <15% of the lichen patients could a possible influence of their contact allergy be assumed. The low frequency of positive reactions to gold (4.9%) in that study might be explained by the use of too low test substance concentration (0.25% GSTS) and by the omission of a late reading (24).

In a retrospective study by Yiannias et al. (26), 30.4% of the 46 patients with OLP tested positive to gold. Vamnes et al. (28) tested 172 patients referred to an adverse reaction unit for dental biomaterials in Bergen, Norway, and found that 23% were allergic to gold. The patients had been referred due to extra- and intra-oral signs and symptoms and a suspicion of adverse reactions related to dental materials. Martin et al. (29) reported the following risk factors for OLP: number of teeth with amalgam, total surfaces of amalgam, number of teeth with gold, corrosion, and bimetallism.

The study 2002 by Ahlgren et al. (21) on dermatitis patients found a correlation and a dose-response relationship between contact allergy to gold and dental gold restorations. The dermatitis patients were expected to have a high frequency of contact allergy and therefore, the high frequency of contact allergy to gold among the controls in the present study was not surprising. Controls from a general population would obviously have been desirable, but for the present study such controls were not available.

A study on endovascular coronary stents (30) found 31% of the stented patients and 19% of a control group of dermatitis patients to have a contact allergy when patch-tested with GSTS 2.0%. The mean age of the stent patients was 67.7 years and the dermatitis patients were age- and gender-matched. Of the stented patients, 60.4% reported having dental gold restorations. The dermatitis patients in that study did not answer the questionnaire, but there is little reason to assume a substantial difference in dental gold exposure. In the present study, 60.2% of the patients with OLL had dental gold restorations compared with 54.4% of the control patients. Because mean age in the OLL group was 60.0 years and in the control group 56.5 years, the presence of dental gold restorations found is neither unexpected nor exceptional.

Dental rehabilitation with gold alloys has been widespread for decades. The discussion concerning the inertness of gold is an old one. All dental casting alloys, except titanium, seem to have the potential for eliciting adverse reactions in hypersensitive patients (31). Gold occurs in saliva and blood (32), and the blood concentration of gold (B-Au) is related to the amount of dental gold (33). The clinical relevance of increased levels of gold in blood and saliva in relation to contact allergic reactions in the oral mucosa has not yet been evaluated.

The study by Ekqvist et al. (34) on patients with uncoated (nickel) or gold-coated stainless steel stents found that patients with gold-coated stents exhibited a five-fold higher B-Au than patients with uncoated (Ni) stents. The authors concluded that the gold-coated stent releases gold. The patch test reactions to gold were also correlated with B-Au. A controlled crossover provocation trial (35) by the same research group on 24

dermatitis patients with a known contact allergy to gold showed that the B-Au level influences the skin reactivity to a topically applied gold antigen.

Gold is used in the medical treatment of rheumatoid arthritis. Compared with non-smokers who undergo gold sodium thiomalate treatment, patients who smoke and receive such treatment: (i) are at higher risk of developing dermatitis (36); (ii) have a higher uptake of gold in red blood cells (37); and (iii) develop side-effects of the medication more quickly (37). Previously, our group found a significant positive correlation between contact allergy to gold and smoking in dermatitis patients who lack oral symptoms or signs (21). In the present study, smoking was more common among DP patients, possibly partly explaining the relatively high frequency of contact allergy to gold in this control group.

The high frequency of contact allergy to gold in patients with OLL found in the present study, suggests that dental gold can be one of several aetiological factors for developing or maintaining OLL. Caution is therefore recommended when considering restoring OLL patients with dental gold.

ACKNOWLEDGEMENTS

This study was funded by the National Board of Health and Welfare, Sweden, and The Swedish Dental Association.

The authors would like to thank Monica Andersson and Bodil Sjöström for skilful assistance with the patients and Per-Erik Isberg for statistical help.

REFERENCES

1. Björkner B, Bruze M, Möller H. High frequency of contact allergy to gold sodium thiosulfate. An indication of gold allergy? *Contact Dermatitis* 1994; 30: 144–151.
2. Möller H. Contact allergy to gold as a model for clinical-experimental research. *Contact Dermatitis* 2010; 62: 193–200.
3. Mallo Perez L, Diaz Donado C. Intraoral contact allergy to materials used in dental practice. A critical review. *Med Oral* 2003; 8: 334–347.
4. Karatsaidis A, Schreurs O, Helgeland K, Axell T, Schenck K. Erythematous and reticular forms of oral lichen planus and oral lichenoid reactions differ in pathological features related to disease activity. *J Oral Pathol Med* 2003; 32: 275–281.
5. Myers SL, Rhodus NL, Parsons HM, Hodges JS, Kaimal S. A retrospective survey of oral lichenoid lesions: revisiting the diagnostic process for oral lichen planus. *Oral Surg Oral Med Oral Pathol Oral Radiol Endod* 2002; 93: 676–681.
6. Scalf LA, Fowler JF, Jr, Morgan KW, Looney SW. Dental metal allergy in patients with oral, cutaneous, and genital lichenoid reactions. *Am J Contact Dermat* 2001; 12: 146–150.
7. Koch P, Bahmer FA. Oral lesions and symptoms related to metals used in dental restorations: a clinical, allergological, and histologic study. *J Am Acad Dermatol* 1999; 41: 422–430.
8. Laeijendecker R, Dekker SK, Burger PM, Mulder PG, Van Joost T, Neumann MH. Oral lichen planus and allergy to

- dental amalgam restorations. *Arch Dermatol* 2004; 140: 1434–1438.
9. Skoglund A. Value of epicutaneous patch testing in patients with oral, mucosal lesions of lichenoid character. *Scand J Dent Res* 1994; 102: 216–222.
 10. Bratel J, Hakeberg M, Jontell M. Effect of replacement of dental amalgam on oral lichenoid reactions. *J Dent* 1996; 24: 41–45.
 11. Dunsche A, Kastel I, Terheyden H, Springer IN, Christophers E, Brasch J. Oral lichenoid reactions associated with amalgam: improvement after amalgam removal. *Br J Dermatol* 2003; 148: 70–76.
 12. Bruze M, Hedman H, Björkner B, Möller H. The development and course of test reactions to gold sodium thiosulfate. *Contact Dermatitis* 1995; 33: 386–391.
 13. Fowler JJ. Selection of patch test materials for gold allergy. *Contact Dermatitis* 1987; 17: 23–25.
 14. Möller H, Larsson A, Björkner B, Bruze M. The histological and immunohistochemical pattern of positive patch test reactions to gold sodium thiosulfate. *Acta Derm Venereol* 1994; 74: 417–423.
 15. Swanbeck G, Dahlberg E. Cutaneous drug reactions. An attempt to quantitative estimation. *Arch Dermatol Res* 1992; 284: 215–218.
 16. Athavale PN, Shum KW, Yeoman CM, Gawkrödger DJ. Oral lichenoid lesions and contact allergy to dental mercury and gold. *Contact Dermatitis* 2003; 49: 264–265.
 17. Pratt MD, Belsito DV, DeLeo VA, Fowler JF, Jr, Fransway AF, Maibach HI, et al. North American Contact Dermatitis Group patch-test results, 2001–2002 study period. *Dermatitis* 2004; 15: 176–183.
 18. Bruze M, Edman B, Björkner B, Möller H. Clinical relevance of contact allergy to gold sodium thiosulfate. *J Am Acad Dermatol* 1994; 31: 579–583.
 19. Schaffran RM, Storrs FJ, Schalock P. Prevalence of gold sensitivity in asymptomatic individuals with gold dental restorations. *Am J Contact Dermat* 1999; 10: 201–206.
 20. Vamnes JS, Morken T, Helland S, Gjerdet NR. Dental gold alloys and contact hypersensitivity. *Contact Dermatitis* 2000; 42: 128–133.
 21. Ahlgren C, Ahnlide I, Björkner B, Bruze M, Liedholm R, Möller H, et al. Contact allergy to gold is correlated to dental gold. *Acta Derm Venereol* 2002; 82: 41–44.
 22. van der Meij EH, Schepman KP, van der Waal I. The possible premalignant character of oral lichen planus and oral lichenoid lesions: a prospective study. *Oral Surg Oral Med Oral Pathol Oral Radiol Endod* 2003; 96: 164–171.
 23. Wilkinson D, Fregert S, Magnusson B, Bandman H, Calnan C, Cronin E, et al. Terminology of contact dermatitis. *Acta Derm Venereol* 1970; 50: 287–292.
 24. Bruze M, Andersen KE. Gold – a controversial sensitizer. European Environmental and Contact Dermatitis Research Group. *Contact Dermatitis* 1999; 40: 295–299.
 25. Axéll T, Rundquist L. Oral lichen planus – a demographic study. *Community Dent Oral Epidemiol* 1987; 15: 52–56.
 26. Yiannias JA, el-Azhary RA, Hand JH, Pakzad SY, Rogers RS, 3rd. Relevant contact sensitivities in patients with the diagnosis of oral lichen planus. *J Am Acad Dermatol* 2000; 42: 177–182.
 27. Raap U, Stiesch M, Reh H, Kapp A, Werfel T. Investigation of contact allergy to dental metals in 206 patients. *Contact Dermatitis* 2009; 60: 339–343.
 28. Vamnes JS, Lygre GB, Gronningsaeter AG, Gjerdet NR. Four years of clinical experience with an adverse reaction unit for dental biomaterials. *Community Dent Oral Epidemiol* 2004; 32: 150–157.
 29. Martin MD, Broughton S, Drangsholt M. Oral lichen planus and dental materials: a case-control study. *Contact Dermatitis* 2003; 48: 331–336.
 30. Ekqvist S, Svedman C, Möller H, Kehler M, Pripp CM, Björk J, et al. High frequency of contact allergy to gold in patients with endovascular coronary stents. *Br J Dermatol* 2007; 157: 730–738.
 31. Hensten-Pettersen A. Casting alloys: side-effects. *Adv Dent Res* 1992; 6: 38–43.
 32. Drasch G, Muss C, Roeder G. Gold and palladium burden from dental restoration materials. *J Trace Elem Med Biol* 2000; 14: 71–75.
 33. Ahnlide I, Ahlgren C, Björkner B, Bruze M, Lundh T, Möller H, et al. Gold concentration in blood in relation to the number of gold restorations and contact allergy to gold. *Acta Odontol Scand* 2002; 60: 301–305.
 34. Ekqvist S, Svedman C, Lundh T, Möller H, Björk J, Bruze M. A correlation found between gold concentration in blood and patch test reactions in patients with coronary stents. *Contact Dermatitis* 2008; 59: 137–142.
 35. Ekqvist S, Lundh T, Svedman C, Björk J, Möller H, Nilsson LA, et al. Does gold concentration in the blood influence the result of patch testing to gold? *Br J Dermatol* 2009; 160: 1016–1021.
 36. Kay EA, Jayson MI. Risk factors that may influence development of side effects of gold sodium thiomalate. *Scand J Rheumatol* 1987; 16: 241–245.
 37. Graham GG, Haavisto TM, McNaught PJ, Browne CD, Champion GD. The effect of smoking on the distribution of gold in blood. *J Rheumatol* 1982; 9: 527–531.