



# LUND UNIVERSITY

## Measurement of Tumor Extent and Effects of Breast Compression in Digital Mammography and Breast Tomosynthesis

Förnvik, Daniel

2013

[Link to publication](#)

*Citation for published version (APA):*

Förnvik, D. (2013). *Measurement of Tumor Extent and Effects of Breast Compression in Digital Mammography and Breast Tomosynthesis*. [Doctoral Thesis (compilation), Medical Radiation Physics, Malmö]. Medical Radiation Physics, Lund University.

*Total number of authors:*

1

### General rights

Unless other specific re-use rights are stated the following general rights apply:

Copyright and moral rights for the publications made accessible in the public portal are retained by the authors and/or other copyright owners and it is a condition of accessing publications that users recognise and abide by the legal requirements associated with these rights.

- Users may download and print one copy of any publication from the public portal for the purpose of private study or research.
- You may not further distribute the material or use it for any profit-making activity or commercial gain
- You may freely distribute the URL identifying the publication in the public portal

Read more about Creative commons licenses: <https://creativecommons.org/licenses/>

### Take down policy

If you believe that this document breaches copyright please contact us providing details, and we will remove access to the work immediately and investigate your claim.

LUND UNIVERSITY

PO Box 117  
221 00 Lund  
+46 46-222 00 00

# Measurement of Tumor Extent and Effects of Breast Compression in Digital Mammography and Breast Tomosynthesis

**Daniel Förnvik**



**LUND**  
UNIVERSITY

DOCTORAL DISSERTATION

by due permission of the Faculty of Medicine, Lund University, Sweden.

To be defended in room 2005-2007, Inga Marie Nilssons gata 49, SUS Malmö,  
at 13.00, May 17<sup>th</sup>, 2013.

*Faculty opponent*

Assoc. Prof. Andrew D. A. Maidment, Dept. of Radiology, University of Pennsylvania

Organization LUND UNIVERSITY		Document name DOCTORAL DISSERTATION	
Medical Radiation Physics Department of Clinical Sciences, Malmö		Date of issue April 11 <sup>th</sup> , 2013	
Author(s) Daniel Förmvik		Sponsoring organization	
Title and subtitle Measurement of Tumor Extent and Effects of Breast Compression in Digital Mammography and Breast Tomosynthesis			
Abstract  Breast cancer is the most common form of cancer affecting women in the western countries. Today x-ray digital mammography (DM) of the breast is commonly used for early detection of breast cancer. However, the sensitivity of mammography is limited, mainly due to the fact that a 3D volume is projected down to a 2D image. This problem can be partially solved by a tomographic technique. Breast tomosynthesis (BT) reduces the detrimental effect of the projected anatomy.  Tumor size is an important predictor of prognosis and treatment effect. We hypothesized that the tumor outline would be better defined in BT and therefore tumor measurement in BT would be more accurate compared with DM. The results showed that breast tumor size measured on BT correlated better with the size measured by the pathologists on the surgical specimens compared with measurement on DM.  Breast compression is important in mammography both to improve image quality and to reduce the radiation dose to the breast, but it also has a negative consequence as some women refrain from mammography due to the pain associated with the examination. Since BT is a 3D technique, it was hypothesized that less breast compression force can be applied. The results indicated that less compression force is possible without significantly compromising the diagnostic quality of the image and that the patient comfort was improved.  An applied breast compression force as used in mammography results in a pressure distribution over the breast. The pressure distribution was assessed using thin pressure sensors attached to the compression plate. The results showed that the pressure distribution was heterogeneous in appearance and varied widely between different breasts. In almost half of the subjects most of the pressure was over the juxtathoracic part of the breast and the pectoral muscle with little or no pressure over the rest of the breast.  Another concern regarding breast compression is the question whether the resulting pressure might damage tumors, causing a shedding of malignant cells into the blood system. Peripheral venous blood samples were drawn before and after breast compression and analyzed for circulating tumor cells. The study found no elevated number of circulating cancer cells in peripheral blood after breast compression. Future analysis of samples from veins draining the breast are needed to study if circulating tumor cells are being trapped in the lung capillaries.			
Key words mammography, breast tomosynthesis, breast compression, breast cancer, pressure distribution, circulating tumor cells, cancer staging			
Classification system and/or index terms (if any)			
Supplementary bibliographical information		Language English	
ISSN and key title 1652-8220		ISBN 978-91-87449-28-4	
Recipient's notes		Number of pages 48	Price
		Security classification	

Signature


Date April 11<sup>th</sup>, 2013

# Measurement of Tumor Extent and Effects of Breast Compression in Digital Mammography and Breast Tomosynthesis

**Daniel Förnvik**

Medical Radiation Physics  
Department of Clinical Sciences, Malmö  
Faculty of Medicine, Lund University  
Skåne University Hospital  
2013



**LUND**  
UNIVERSITY

**Cover:** A 10 mm, grade 1, invasive lobular carcinoma visualized with digital mammography (top left), breast tomosynthesis (top right), ultrasonography (bottom left) and elasticity imaging (bottom right).

Thesis for the Degree of Doctor of Philosophy in Medical Science  
Lund University  
Faculty of Medicine Doctoral Dissertation Series 2013:58  
Medical Radiation Physics  
Department of Clinical Sciences, Malmö  
Skåne University Hospital  
SE-205 02 Malmö, Sweden

Copyright © Daniel Förnvik (pp 1-48)  
ISBN 978-91-87449-28-4  
ISSN 1652-8220

Printed in Sweden by Media-Tryck, Lund University  
Lund 2013



CLIMATE  
COMPENSATED  
PAPER



**REPA**<sup>®</sup>  
A part of FTI (the Packaging and  
Newspaper Collection Service)

*“It is nice to be important,  
but it is more important to be nice.”  
- Faster Harder Scooter*

# Abstract

Breast cancer is the most common form of cancer affecting women in the western countries. Today x-ray digital mammography (DM) of the breast is commonly used for early detection of breast cancer. However, the sensitivity of mammography is limited, mainly due to the fact that a 3D volume is projected down to a 2D image. This problem can be partially solved by a tomographic technique. Breast tomosynthesis (BT) reduces the detrimental effect of the projected anatomy.

Tumor size is an important predictor of prognosis and treatment effect. We hypothesized that the tumor outline would be better defined in BT and therefore tumor measurement in BT would be more accurate compared with DM. The results showed that breast tumor size measured on BT correlated better with the size measured by the pathologists on the surgical specimens compared with measurement on DM.

Breast compression is important in mammography both to improve image quality and to reduce the radiation dose to the breast, but it also has a negative consequence as some women refrain from mammography due to the pain associated with the examination. Since BT is a 3D technique, it was hypothesized that less breast compression force can be applied. The results indicated that less compression force is possible without significantly compromising the diagnostic quality of the image and that the patient comfort was improved.

An applied breast compression force as used in mammography results in a pressure distribution over the breast. The pressure distribution was assessed using thin pressure sensors attached to the compression plate. The results showed that the pressure distribution was heterogeneous in appearance and varied widely between different breasts. In almost half of the subjects most of the pressure was over the juxtathoracic part of the breast and the pectoral muscle with little or no pressure over the rest of the breast.

Another concern regarding breast compression is the question whether the resulting pressure might damage tumors, causing a shedding of malignant cells into the blood system. Peripheral venous blood samples were drawn before and after breast compression and analyzed for circulating tumor cells. The study found no elevated number of circulating cancer cells in peripheral blood after breast compression. Future analysis of samples from veins draining the breast are needed to study if circulating tumor cells are being trapped in the lung capillaries.

# Sammanfattning på svenska

Bröstcancer är den typ av cancer som drabbar flest kvinnor i Sverige. Årligen diagnostiseras drygt 7000 kvinnor med bröstcancer och ungefär 1400 dör av sin sjukdom. För att minska bröstcancerdödligheten rekommenderar Socialstyrelsen mammografiscreening där kvinnor över 40 år bjuds in för regelbundna kontroller. Dessa kontroller utförs med digital mammografi som innebär att man tar tvådimensionella röntgenbilder av bröstet. Det är välkänt att mammografi inte hittar alla brösttumörer. En eventuell tumör kan döljas av normal vävnad ovan och under tumören. Detta problem kan åtminstone delvis lösas med en snittbildsteknik. En sådan har utvecklats på senare år och kallas brösttomosyntes. I brösttomosyntes erhålls snittbilder av hela bröstet och således minskar problemet med att all bröstvävnad projiceras ned på en enda mammografibild. Brösttomosyntes har visat sig bättre på att hitta tumörer i studier, men ytterligare studier fördras för att bekräfta detta.

En viktig parameter för bedömning av prognos och behandling är tumörens storlek. I arbete **I** jämfördes mätningar av brösttumörers storlek gjorda med de olika avbildningsmetoderna brösttomosyntes, digital mammografi och ultraljud. Som storleksreferens användes patologens storleksmätning på det avlägsnade bröstpreparatet. Resultaten visar att storleksbestämningen med brösttomosyntes stämmer bättre överens med patologens mätning än digital mammografi. Således ger mätning på brösttomosyntes bättre underlag för prognosbedömning och behandlingsplanering.

Ett problem som gör att en grupp kvinnor avstår från regelbunden mammografiscreening är rädslan för smärta i samband med undersökningen. För att få en bra mammografibild med digital mammografi måste man anbringa en ganska kraftig kompression av bröstet. Eftersom brösttomosyntes är en tredimensionell undersökning av bröstet kan man tänka sig en reducerad bröstkompression och således en minskad smärtupplevelse. I arbete **II** togs tomosyntesbilder av samma bröst med både standard kompressionskraft och halverad kompressionskraft. Resultaten tyder på att en minskning av bröstkompression är möjlig med brösttomosyntes utan att bildkvaliteten försämras.

Idag förekommer ingen bra standard för hur mycket ett bröst ska komprimeras i samband med digital mammografi. I arbete **III** undersöktes hur kompressionskraften fördelas över bröstet, det vill säga hur tryckfördelningen är över bröstet. Detta undersöktes med hjälp av tunna trycksensorer placerade under kompressionsplattan.



Det visade sig att tryckfördelningen var heterogen och varierade mycket från bröst till bröst. Hos en grupp kvinnor låg det kraftigaste trycket över den bröstorgsnära delen medan huvuddelen av bröstet var otillräckligt komprimerat. En annan grupp uppvisade god tryckfördelning över bröstet. I denna grupp medförde ytterligare kompression endast ökad smärta. Arbetet aktualiserar behovet av en bättre kompressionsanordning som tar hänsyn till tryckfördelningen.

Ett avgörande steg i bröstcancers förlopp är uppkomsten av metastatisk sjukdom genom spridning av cancerceller till andra delar av kroppen. Det finns möjlighet att mäta mängden cirkulerande tumörceller i bröstcancerpatienters blod och studier har visat att denna metod har ett prognostiskt värde. I arbete **IV** undersöktes något som har diskuterats men inte studerats systematiskt hos människor, nämligen om bröstkompression i samband med mammografi skulle kunna leda till att tumörceller läcker ut i blodomloppet hos kvinnor med bröstcancer. Resultaten visade inte något ökat läckage av tumörceller till blod taget från blodåder på arm. En utvidgad studie planeras med cellräkning i blod taget från centrala blodådror till vilka bröstet dräneras för att utesluta möjligheten att avsaknaden i perifert blod orsakas av att cancercellerna fastnat i lungkapillärerna.

# Original papers

This thesis is based on the following papers, which will be referred to in the text by their Roman numerals.

- I.** *Breast tomosynthesis: Accuracy of tumor measurement compared with digital mammography and ultrasonography*  
Förnvik D, Zackrisson S, Ljungberg O, Svahn T, Timberg P, Tingberg A, Andersson I.  
Acta Radiol. 2010; 51(3): 240-7
- II.** *The effect of reduced breast compression in breast tomosynthesis: human observer study using clinical cases*  
Förnvik D, Andersson I, Svahn T, Timberg P, Zackrisson S, Tingberg A.  
Radiat Prot Dosimetry. 2010; 139(1-3): 118-23
- III.** *Breast compression in mammography: pressure distribution patterns*  
Dustler M, Andersson I, Brorson H, Fröjd P, Mattsson S, Tingberg A, Zackrisson S, Förnvik D.  
Acta Radiol. 2012; 53(9): 973-80
- IV.** *No evidence for shedding of circulating tumor cells into the peripheral venous blood as a result of mammographic breast compression*  
Förnvik D, Andersson I, Ehrnström R, Dustler M, Rydén L, Tingberg A, Zackrisson S, Aaltonen K.  
Breast Cancer Res. (submitted)

Published papers have been reproduced with kind permission of the following publishers:

The Royal Society of Medicine Press Ltd (Paper I and Paper III)  
Oxford University Press (Paper II)

## Preliminary reports

Preliminary reports have been presented at the following international meetings and conferences.

- i. *Breast tomosynthesis: A three-dimensional breast imaging technique*  
Förnvik D, Zackrisson S, Timberg P, Svahn T, Mattsson S, Tingberg A, Andersson I.  
Malmö Cancer Center Retreat, Torekov, Sweden, August 2008
- ii. *Complementary analysis of breast cancer using MRI and breast tomosynthesis*  
Förnvik D.  
Medicinska Riksstämman, Göteborg, Sweden, November 2008
- iii. *Breast tomosynthesis: Assessment of breast cancer size compared with digital mammography and ultrasonography*  
Förnvik D, Zackrisson S, Ljungberg O, Timberg P, Svahn T, Tingberg A, Andersson I.  
European Congress of Radiology, Vienna, Austria, March 2009  
Tomosynthesis Imaging Symposium, Durham, USA, April 2009
- iv. *The effect of reduced breast compression in breast tomosynthesis: an observer study using clinical cases*  
Förnvik D, Andersson I, Svahn T, Timberg P, Zackrisson S, Tingberg A.  
Third Malmö Conference on Medical Imaging, Malmö, Sweden, June 2009  
Nationellt Möte om Sjukhusfysik, Uddevalla, Sweden, September 2009  
European Congress of Radiology, Vienna, Austria, March 2010
- v. *Is it feasible to reduce breast compression in breast tomosynthesis?*  
Förnvik D, Timberg P, Andersson I, Svahn T, Zackrisson S, Tingberg A, Mattsson S.  
Malmö Cancer Center Retreat, Ven, Sweden, August 2010
- vi. *Can breast compression of malignant tumours in mammography result in metastasis?*  
Förnvik D, Dustler M, Andersson I, Tingberg A.  
3:e Nationella Mötet om Sjukhusfysik, Djurönäset, Sweden, November 2012

## Other related publications by the author

- *The diagnostic accuracy of dual-view digital mammography, single-view breast tomosynthesis and a dual-view combination of breast tomosynthesis and digital mammography in a free-response observer performance study*  
Svahn T, Andersson I, Chakraborty D, Svensson S, Ikeda D, Förnvik D, Mattsson S, Tingberg A, Zackrisson S.  
Radiat Prot Dosimetry. 2010; 139(1-3): 113-7
- *A human observer study for evaluation and optimization of reconstruction methods in breast tomosynthesis using clinical cases*  
Förnvik D, Jerebko A, Timberg P, Schasiepen I, Hofmann C, Zackrisson S, Andersson I, Mertelmeier T, Tingberg A.  
Proc SPIE 2011; 7961(79615G): 1-7
- *Breast cancer screening with tomosynthesis – initial experiences*  
Tingberg A, Förnvik D, Mattsson S, Svahn T, Timberg P, Zackrisson S.  
Radiat Prot Dosimetry. 2011; 147(1-2): 180-3
- *The effect of breast positioning on breast compression in mammography: a pressure distribution perspective*  
Dustler M, Andersson I, Förnvik D, Tingberg A.  
Proc SPIE 2012; 8313(83134M): 1-6
- *Investigation of viewing procedures for interpretation of breast tomosynthesis image volumes: a detection-task study with eye tracking*  
Timberg P, Lång K, Nyström M, Holmqvist K, Wagner P, Förnvik D, Tingberg A, Zackrisson S.  
Eur Radiol. 2013; 23(4): 997-1005
- *Pressure distribution in mammography: compression of breasts with malignant tumor masses*  
Förnvik D, Dustler M, Andersson I, Brorson H, Timberg P, Zackrisson S, Tingberg A.  
Proc SPIE 2013; 8668(8668E): 1-8
- *A study of the feasibility of using slabbing to reduce tomosynthesis review time*  
Dustler M, Andersson M, Förnvik D, Timberg P, Tingberg A.  
Proc SPIE 2013; 8673(86731L): 1-6

# Abbreviations

2D	two-dimensional
3D	three-dimensional
AEC	automatic exposure control
BT	breast tomosynthesis
CC	craniocaudal
CTC	circulating tumor cell
DCIS	ductal carcinoma <i>in situ</i>
DM	digital mammography
FSR	force sensing resistor
HER2	human epidermal growth factor receptor 2
IC	image criteria
ICS	image criteria score
IDC	invasive ductal carcinoma
ILC	invasive lobular carcinoma
LCIS	lobular carcinoma <i>in situ</i>
LM	lateromedial
MLO	mediolateral oblique
US	ultrasonography
VGA	visual grading analysis

# Contents

1 Introduction	13
1.1 Objectives .....	14
2 Scientific and technical background	15
2.1 Breast cancer .....	15
2.1.1 Morphological types of breast cancer .....	15
2.1.2 Staging and grading of breast cancer .....	16
2.1.3 Metastasis of breast cancer .....	17
2.2 Imaging modalities .....	18
2.2.1 Digital mammography (DM) .....	18
2.2.2 Breast tomosynthesis (BT) .....	20
2.2.3 Ultrasonography (US) .....	22
2.2.4 Elastic properties of breast tissue and imaging .....	23
2.3 Breast compression .....	25
2.3.1 Breast compression in digital mammography .....	25
2.3.2 Breast compression in breast tomosynthesis .....	25
2.3.3 Pressure distribution over the breast .....	26
2.4 Image quality .....	26
2.4.1 Fulfillment of image criteria (IC) .....	27
2.4.2 Visual grading analysis (VGA) .....	28
3 Summary of the papers	29
3.1 Paper I – Breast tomosynthesis: Accuracy of tumor measurement compared with digital mammography and ultrasonography .....	29
3.2 Paper II – The effect of reduced breast compression in breast tomosynthesis: human observer study using clinical cases .....	30
3.3 Paper III – Breast compression in mammography: pressure distribution patterns .....	31
3.4 Paper IV – No evidence for shedding of circulating tumor cells into the peripheral venous blood as a result of mammographic breast compression .....	33
4 Discussion and concluding remarks	35
4.1 Future aspects .....	39
5 Conclusions	41
Acknowledgements	43
References	45



# 1 Introduction

Breast cancer is the most common form of cancer affecting women in western countries. Population-based mammography screening programs have been introduced since reduced breast cancer mortality rates were shown in randomized controlled trials (Nyström et al., 2002; Marmot et al., 2012;). Still, the sensitivity of mammography has been reported to be as low as 70% (Pisano et al., 2005). The limited sensitivity is mainly due to dense breast tissue superimposed on lesions of interest and non-specific breast cancer growth patterns. This implies that there is still room for improvements in breast imaging. Breast tomosynthesis (BT) has been proposed to partially overcome the problem with tissue superimposition (Niklason et al., 1997). BT has been shown to increase the sensitivity of breast cancer detection compared to digital mammography (DM) in selected populations (Andersson et al., 2008; Gur et al., 2009; Svahn et al., 2012). If BT is to be implemented as a future screening modality further research is needed involving large population-based screening trials (Tingberg and Zackrisson, 2011). There is also a need to investigate its potential to demonstrate certain tumor features and to further optimize different image acquisition parameters.

A specific tumor feature is the size of the tumor, which is fundamental for the choice of treatment. The accuracy of BT in measuring tumor size has not until now been investigated.

Breast compression is an example of an image acquisition parameter that has not yet been investigated for BT in a clinical setting. Breast compression is important in mammography both to improve image quality and to reduce the radiation dose to the breast, but it also has a negative consequence as some women refrain from mammography due to the pain associated with the examination.

In general, breast compression has gained little attention in the literature (Poulos and McLean, 2004). The degree of breast compression is not standardized, to quote the European Commission<sup>1</sup> (1996), “Breast compression should be applied to a level which the patient can tolerate”. The lack of more precise recommendations leave room for large variation of how compression is actually performed, since the compression can also vary depending on the physical form of the breast, the compression plate used and the variability between radiographers (Mercer et al., 2013). Thus, there is a need to investigate parameters affecting breast compression.



Another concern regarding breast compression is the question whether the resulting pressure might damage tumors causing them to shed malignant cells into the blood system, and whether this in turn would affect the prognosis (Watmough et al., 1993). Studies have found that moderate pressure applied to tumors in small animals caused the number of cancer cells per ml blood to rise drastically or the incidence of distant metastases to increase compared to controls (Tyzzer, 1913; Romsdahl et al., 1965; Liotta et al., 1974). More recent publications have stressed the need for caution in cancer surgery, emphasizing the importance of minimizing tumor manipulation to avoid dissemination of malignant cells (Choy and McCulloch, 1996; Hayashi et al., 1999).

## 1.1 Objectives

The objectives of this thesis were:

- to assess the accuracy of breast tomosynthesis compared with digital mammography and ultrasonography for tumor size measurement (Paper **I**).
- to study the effect of reducing the compression force in breast tomosynthesis on the visualization of normal and pathological structures (Paper **II**).
- to measure the pressure distribution over the breast as a result of applied breast compression in mammography (Paper **III**).
- to study whether breast compression during mammography may result in tumor cell shedding to peripheral venous blood (Paper **IV**).

# 2 Scientific and technical background

## 2.1 Breast cancer

Breast cancer is the most common form of female cancer in the world (Ferlay et al., 2010) and also in Sweden, with around 7500 women diagnosed annually (Socialstyrelsen<sup>1</sup>). It is also the second most common cause of death among women aged 45-74 after death from cardiovascular diseases. Each year around 1400 deaths are caused by malignant breast tumors (Socialstyrelsen<sup>2</sup>).

Currently breast cancer screening programs based on mammography are used in Sweden as well as in many other countries. Until we have established reliable diagnostic methods at the cellular/subcellular level we are relying on breast cancer screening programs with mammography and subsequent surgery and/or hormone-, chemo- and radiation treatments.

### 2.1.1 Morphological types of breast cancer

Invasive ductal carcinoma (IDC) is the most common type of breast cancer and arises in the cells lining the ductal systems of the breast. The term invasive refers to the ability of the cancer to infiltrate nearby tissue and/or spread to other parts of the body. About 50-80% of all invasive breast cancers are IDCs and most of these are spiculated tumors or tumors with irregular borders (Tavassoli and Devilee, 2003). The spicules mainly represent a reactive fibrosis although the most proximal part usually contains cancer growth. This often makes exact tumor measurement difficult.

The second most common type of breast cancer is invasive lobular carcinoma (ILC), representing 5-15% of invasive breast tumors (Tavassoli and Devilee, 2003). Although ILC often presents as a spiculated tumor, a fair proportion has a more diffuse growth pattern, resulting in a more vague architectural distortion, which is often difficult to diagnose with current imaging techniques (Hilleren et al., 1991).

Less frequent histologic types are medullary and mucinous carcinoma which often form well circumscribed tumors, similar to benign tumors like cysts and fibroadenomas.

Additionally, breast cancer can also occur in a pre-invasive stage termed ductal carcinoma *in situ* (DCIS) and lobular carcinoma *in situ* (LCIS). DCIS is characterized by calcifications often well seen radiographically due to high density compared to normal breast tissue. LCIS is usually not associated with calcification and therefore not detectable mammographically.

Radiographically, breast cancers are often spiculated, i.e. a tumor bulk with more or less thick spicules extending outwards. However, breast cancer can also appear as well a more or less well-delineated tumor. Benign tumors are often well circumscribed, creating an overlap in the radiographic appearance between malignant and benign tumors.

## **2.1.2 Staging and grading of breast cancer**

Not only is breast cancer heterogeneous in its appearance but also in its biological behavior from slowly growing with low metastatic potential to rapidly growing with high probability of metastasis. Therefore, various predictors of prognosis and response to therapy are used.

The TNM-staging system is widely used, not only for breast cancer, but also for all types of cancer. T describes the maximum size of the primary tumor, N describes the status of the regional lymph nodes and M distant metastasis. Although size is important, the status of the axillary lymph nodes is the strongest prognostic factor. For example, if there is no node involvement the 10-year survival rate is around 80%, with a moderate lymph node involvement survival rates drop to 40-60% and if more than ten lymph nodes are positive the 10-year survival rate is only around 20% (Fisher et al., 1993). There is a correlation between tumor diameter and the number of positive lymph nodes (Engel et al., 2003).

In addition to TNM-classification, histopathological assessment of the grading of morphological features in breast cancer has been proven useful. Many studies have demonstrated a significant association between histological grade and survival in invasive breast cancer, thus considered a powerful prognostic factor (Elston and Ellis, 1991). Briefly, three tumor characteristics are evaluated; tubule formation as an expression of glandular differentiation, nuclear pleomorphism and mitotic counts. Each element is given a score of 1 to 3 and the score of all three components are added together to give the “grade”. The higher the grade, the worse the prognosis.

### *2.1.2.1 Other prognostic factors in clinical use*

In general, surgical and radiation treatments are similar for the different types of histological breast cancer. However, adjuvant drug treatments such as chemo- and/or hormone therapies and other medications can target a specific type of cancer depending on what kind of receptors are expressed. If the cancer cells of a breast

tumor have a significant number of receptors for either estrogen or progesterone, the cancer is considered hormone-receptor positive and likely to respond to endocrine therapies. Human epidermal growth factor receptor 2 (HER2) is a cell surface receptor overexpressed in about 15% of the invasive cancers. HER2 positive cancers tend to be more aggressive and have a higher risk of recurrence (Harris et al., 2007). A monoclonal antibody, Trastuzumab, which interferes with the HER2-receptor, has significantly improved the prognosis for women with tumors overexpressing this receptor (Romond et al., 2005).

Ki67 is an antigen present in all proliferating cells but not in resting cells. Ki67 is a prognostic marker (de Azambuja et al., 2007) and is recommended to be assessed routinely.

Several other potential molecular prognostic and treatment predictive factors are under intense investigation, but have not yet been introduced clinically (Aebi et al., 2011).


### **2.1.3 Metastasis of breast cancer**

The most important and detrimental step in the progression of breast cancer is the occurrence of distant metastatic disease through dissemination of cancer cells to other parts of the body. The primary tumor, with its uncontrolled proliferation, is only responsible for about 10% of deaths from all cancer types (Gupta and Massagué, 2006), but it is uncommon to die from the local tumor growth of a breast cancer. The metastases are formed by cancer cells that left the primary tumor mass and travelled through blood and lymphatic vessels to new sites, where they founded new colonies. Many critical steps of the metastatic cascade are unclear; including how malignant cells can give rise to overt metastasis in secondary organs. It is likely that cancer cells have spread throughout the body years before they are first detected (Dvorak, 1986). Breast cancer metastasizes to various organs, but bone, lung and liver are the most common (Lee, 1983).

#### *2.1.3.1 Circulating tumor cells*

Today, the traditional prognostic markers (stage and grade) are able to confidently predict the prognosis of approximately 30% of patients, who are most likely to have either a very favorable or a very poor outcome. For the remaining 70% of patients, of whom approximately 30% will still develop metastases, new prognostic markers are needed to help identify low-risk and high-risk groups for more effective decision on adjuvant treatment (Weigelt et al., 2005). One prognostic marker, that recently gained large attention, is the number of circulating tumor cells (CTC) per unit volume of blood (Figure 2.1). Cristofanilli et al. (2004) confirmed that the CTC count per unit of blood is an independent prognostic marker for progression-free survival and overall survival in metastatic breast cancer patients. Also, the CTC count in metastatic cancer

patients reflects the patient’s response to therapy (Hayes et al., 2006). The prognostic role of CTC in primary (non-metastatic) cancer patients has not been widely investigated, but a few studies have shown that the presence of CTCs can predict poor prognosis also in patients with primary breast cancer (Bidard et al., 2010).



**Figure 2.1** Example of an imaging analysis of a circulating tumor cell (CTC) using different fluorescence wavelengths/channels. CTCs are defined as nucleated cells (DAPI+) expressing cytokeratin 8, 18 and/or 19 (CK-PE+) and lacking the leukocyte antigen CD45 (CD45-APC-).

## 2.2 Imaging modalities

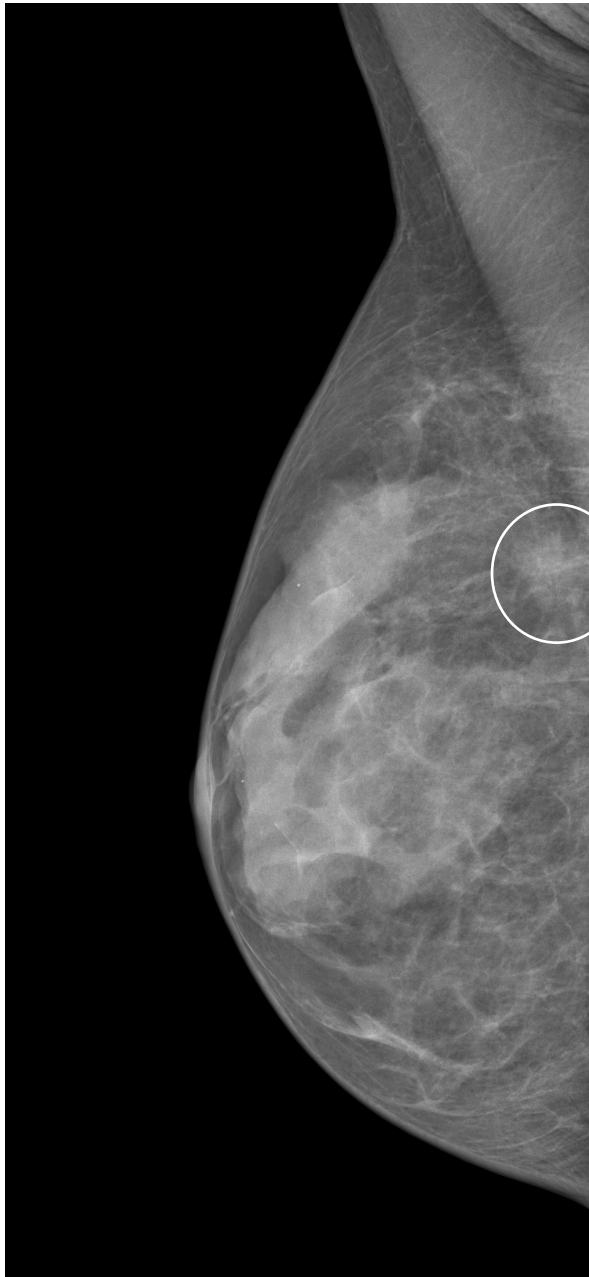
Figures 2.2, 2.4-2.6 show images acquired of the same breast containing a 10 mm, grade 1, invasive lobular carcinoma using the below mentioned different imaging techniques. Besides these imaging techniques, breast imaging can also be performed using scintigraphy, magnetic resonance, computed tomography, optical imaging, among others.

### 2.2.1 Digital mammography (DM)

DM is considered to be the “the gold standard” in breast imaging, and all new techniques are compared to it. DM utilizes the difference in x-ray attenuation between fatty, fibroglandular and tumor tissue. Hence, the beam quality is optimized to make use of these inherent attenuation differences, resulting in a visible contrast between the structures. The x-ray photons transmitted through the breast are then absorbed by an image detector and converted to digitized signal values that form the mammogram (Figure 2.2). Projections conventionally used in breast cancer screening with DM include craniocaudal (CC) and mediolateral oblique (MLO) views. In clinical investigations an additional lateromedial (LM) view is acquired. The average glandular dose at the mammography clinic, Skåne University Hospital, Malmö, for DM of a standard breast (European Commission<sup>2</sup>, 1996) is around 1 mGy per view.

DM has several favorable properties. The handling and archiving of mammograms is convenient, the throughput of patients is high and the reading time of the mammogram is short. Despite its advantages an important limitation is that the sensitivity of DM in

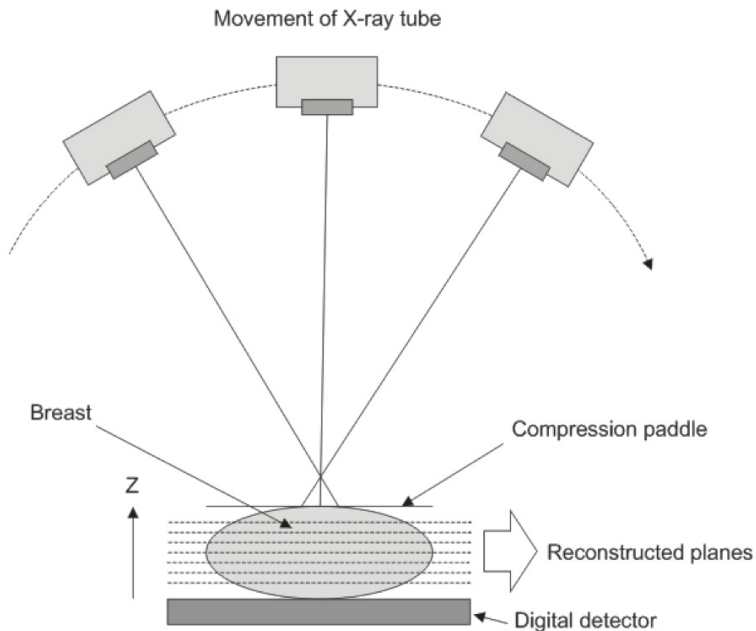
a screening setting is around 70-85% (Pisano et al., 2005). This is mainly due to dense breast tissue being superimposed on lesions of interest.



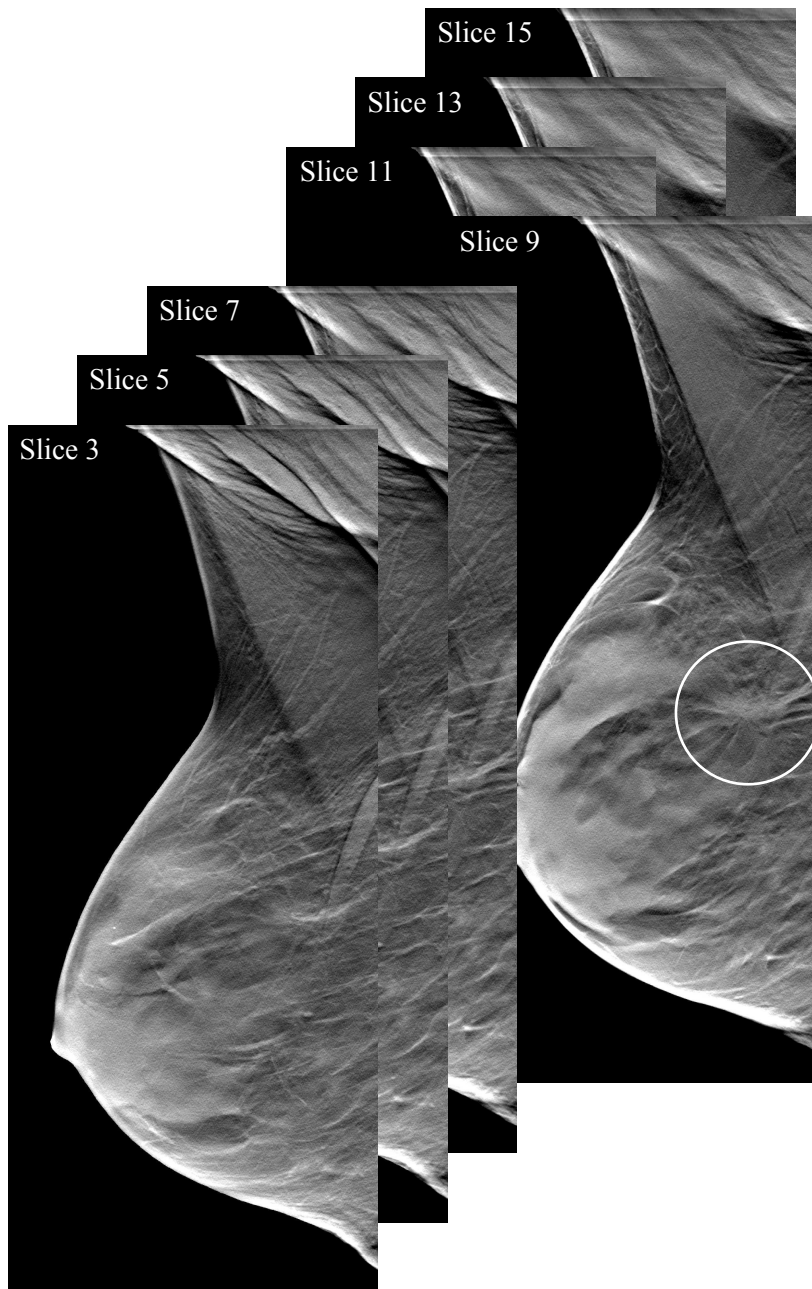
**Figure 2.2** Digital mammography acquired in the mediolateral oblique view. The breast tumor is barely visible.

## 2.2.2 Breast tomosynthesis (BT)

The introduction of large flat-panel detectors with high detective quantum efficiency and rapid read-out together with more powerful computers and reconstruction software in the last decade has made the development of BT possible (Dobbins and Godfrey, 2003). In BT multiple projection images are acquired over a limited angular range (Figure 2.3). In the works described in this thesis the BT unit was set to acquire 25 projection images evenly distributed over 50 degrees. Thin slices parallel to the detector are then mathematically reconstructed, building up the breast volume (Figure 2.4). Typically 40-60 millimeter-thin slices are reconstructed of an average breast, which can be viewed in a cine loop or as individual slices. For BT examinations, the typical tube loading is twice that of a DM projection view, resulting in approximately the same absorbed dose as for two-view mammography. The high spatial resolution of DM is retained in the X- and Y plane for the BT system and the resolution in the third dimension (Z-axis) is typically 1 mm. Since the angular range and number of projections are limited, the frequency component in the Z-dimension will be undersampled leading to artifacts in the reconstructed images (Mertelmeier et al., 2006). To suppress the artifacts resulting from filtered backprojection reconstruction, iterative reconstruction methods have been investigated (Förnvik et al., 2011).



**Figure 2.3** Schematic illustration of breast tomosynthesis. Multiple projection images are acquired during the x-ray tube movement. (only three projections and seven reconstructed planes are shown for simplicity)



**Figure 2.4** A breast tomosynthesis stack acquired in the mediolateral oblique view. The tumor appears in slice 9 and manifests as a spiculated tumor.



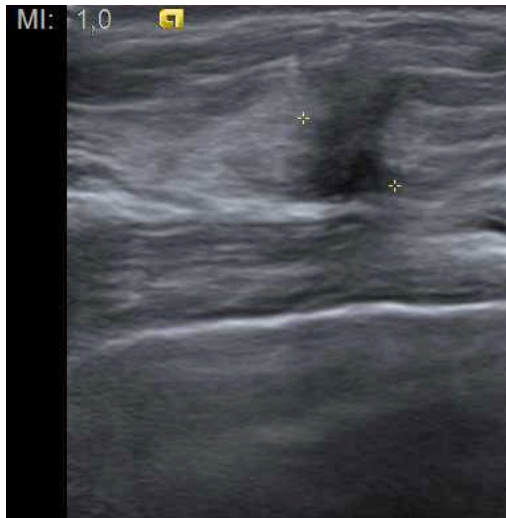The above-mentioned limitation of superimposed tissue in DM can thus be reduced with the use of BT, which has been shown to increase the sensitivity of breast cancer detection compared to DM in selected populations (Andersson et al., 2008; Gur et al., 2009; Svahn et al., 2012). Disadvantages with BT include lower throughput of patients and longer reading times, typically about twice that of DM in a screening setting. Faster computers and improved reading conditions, including reduction of the number of slices, can reduce these problems (Timberg et al., 2013; Dustler et al., 2013).

### **2.2.3 Ultrasonography (US)**

Breast ultrasonography (US) is an important complementary examination to mammography, especially in women with dense breasts (Crystal et al., 2003). The rationale for this is due to the physical difference in image generation between the two modalities. In US sound waves are generated by a hand-held transducer and are partially reflected from the interfaces of different tissue types. The reflected sound waves are transformed into electrical pulses, which are processed into a digital image (Figure 2.5). The acousto-mechanical properties of various breast tissue components are independent of their x-ray absorption properties, which leads to differing sonographic and mammographic tissue contrast. In addition, breast US produces cross-sectional images, enabling tissue visualization free from overprojection, thus rendering detailed contour analysis of lesions and accurate determination of tumor size (Teubner, 1997).

US is used in conjunction with DM in the clinical workup in order to further characterize masses (i.e. tumors and cysts) and to confirm/exclude the presence of a lesion suspected at mammography or clinical examination. Furthermore, US is often used for image guidance for fine needle aspirations and core biopsies of suspicious lesions.

A drawback with US is that it is time consuming, operator dependent (not easily reproducible) and the examination requires a radiologist with specialist training. Therefore it cannot be used as a screening modality. Nevertheless, automated procedures are being investigated (Kotsianos-Hermle et al., 2009).



**Figure 2.5** Ultrasonography image of the tumor that is seen as an irregularly marginated hypoechoic mass.

## 2.2.4 Elastic properties of breast tissue and imaging

A novel way of imaging the breast is through elasticity imaging. Elasticity imaging can be used to visualize internal structures by sensing the pattern of mechanical stresses on the surface of an organ. Organs that are sensitive to palpation for detection of disease, such as the breast, would be suitable for this method (Sarvazyan, 1998).

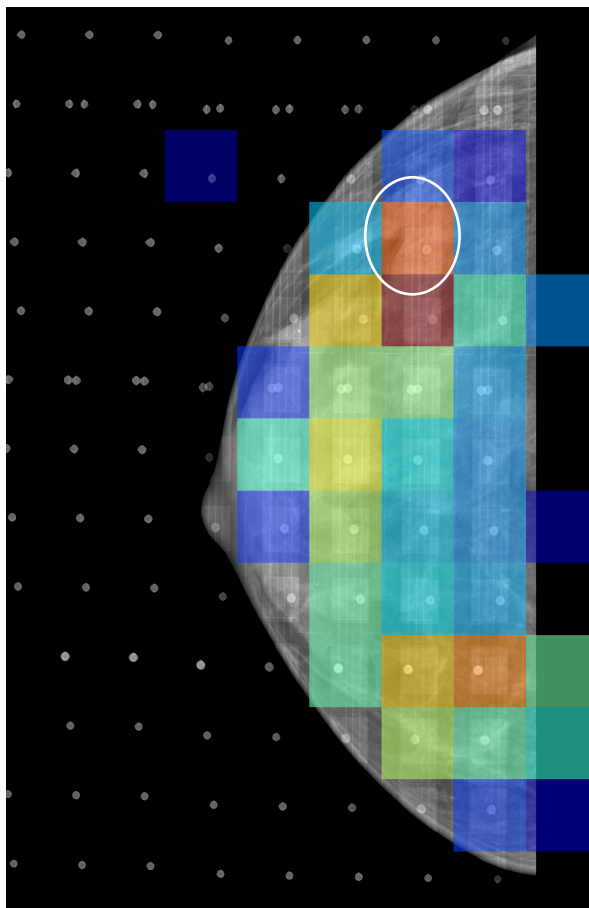
The contrast in elastic stiffness between normal and abnormal breast tissue has been recognized, although the data available is sparse and tends to be inconsistent and/or mostly acquired *ex vivo*. Nevertheless, breast tissue is nonlinearly elastic, showing an exponential decrease in the rate of thickness reduction as a result of increasing pressure. The relative change in stiffness with strain level also varies with different tissue types. Fat shows approximately linear behavior; its stiffness only changes by a factor of 3 from a 1% to 15% strain level, while cancerous tissue increases in stiffness more than 25 times for the same change in strain levels. At a particular strain level, the elastic modulus of fibroglandular tissue (dense tissue) is roughly 1 to 2 orders of magnitude stiffer than fat tissue; fibroadenoma is even stiffer, an additional 2-fold increase in stiffness compared to fibroglandular tissue; and malignant tumors are much stiffer exhibiting an additional 10-fold increase in stiffness compared to fibroglandular tissue (Krouskop et al., 1998; Wellman et al., 1999; Samani et al., 2007).

Based on relative stiffness, it should be possible to differentiate malignant structures from normal breast tissue from a pressure distribution measurement made at the

surface of a compressed breast. Furthermore, the tissue contrast is dependent on the compression level; the more compression applied the better the pressure contrast between different tissue types. An example of an elasticity image of the breast overlaid on a mammogram can be seen in Figure 2.6.

Related modalities such as ultrasound elastography and magnetic resonance elastography are not sufficiently accurate for diagnostic purposes due to limitations such as deformation range, resolution and tissue anisotropy (Wang, 2010).

Elasticity imaging has been applied in other regions of the body (i.e. measuring contact forces on skin) (Morin et al., 2001) but not in breast studies until recently (Förnvik et al., 2013). In order to obtain good elasticity images, sensitive pressure sensors are needed with high spatial resolution.



**Figure 2.6** An elasticity image overlaid on a digital mammography image acquired in the craniocaudal view. Pressure is shown on a scale from dark blue (lowest) to dark red (highest). The mean pressure over the tumor was higher compared to the mean pressure over the breast.

## 2.3 Breast compression

High patient acceptance of mammography and also high attendance in screening programs is important. One of the main problems with mammography is the pain caused by compressing the breast. This is of such a magnitude that some women refrain from the examination (Miller et al., 2008).

### 2.3.1 Breast compression in digital mammography

Compression of the breast during mammography is performed to improve image quality by increasing breast tissue separation and reducing scattered radiation, and to minimize the radiation dose to the breast, which is one of the most radiosensitive tissues of the female body. For these reasons, the breast should be compressed as much as reasonably possible to a level just below the patient's pain threshold or up to the maximum setting of the machine (generally 200 N) according to the European guidelines (European Commission<sup>1</sup>, 1996).

The amount of applied compression is currently solely based on applied force (N). Only a handful of studies have investigated breast compression in mammography. Poulos and McLean (2004) have questioned the use of applied force, instead recommending taking into account the actual degree by which breast thickness is reduced, so called compressibility.

In general, the more the breast volume is spread out in the 2D mammogram the easier image interpretation for the radiologist. Optimal compression also depends on the compression plate used and the positioning skill of the radiographer (Mercer, et al. 2013).

### 2.3.2 Breast compression in breast tomosynthesis

Since BT is a 3D technique, reduced compression could be beneficial due to better separation of the tissue structures in the depth direction. The reconstruction algorithm (filtered backprojection) used in BT effectively compensates for the scattered radiation that occurs in the individual projections. For this reason, the greater thickness of the irradiated tissue (due to lower compression) does not negatively affect the scatter radiation proportion in the resulting tomosynthesis image (Mertelmeier and Zhao, 2010).

Considering the absorbed dose to glandular tissue, lower compression does not necessarily mean higher doses. In a Monte Carlo study by Saunders et al. (2009), they found that for constant glandular dose a 12.5% breast compression reduction would

have minimal effect on radiologists' performance. Moreover, they found that for a fixed tube loading (as used in Paper I and Paper II) the radiation dose was actually reduced for the reduced compression as compared with full compression, owing to the dose distribution. Nowadays, most BT systems use automatic exposure control (AEC) that compensates for the loss in detector signal when lowering compression, consequently increasing the dose.

There are reasons for compressing the breast in BT. Firstly, the breast must be fixated to avoid motion blur. The scan time (tube movement) in BT can be up to 20 s potentially causing motion artifacts. Secondly, it has been observed on different occasions that it was not possible to generate a complete tomosynthesis 3D image of the entire breast in the reconstruction due to the geometry of the system; outermost projections do not completely cover the breast volume. However, using for instance a concave compression plate could solve this issue (Mertelmeier and Zhao, 2010).

### **2.3.3 Pressure distribution over the breast**

The pressure distribution over the breast as a result of applied compression force is heterogeneous (Paper III). When an even load is applied to the breast, the internal structures, with their inherent elastic modulus, will give rise to varying internal pressures that can be imaged with pressure sensors (elasticity imaging). Besides the usual breast thickness gradient decreasing from the chest wall to the nipple, other structures will affect the pressure distribution. The most prominent of these is the pectoral muscle, the inclusion of which is also an important image quality criterion (European Commission<sup>1</sup>, 1996). This muscle is rather stiff compared to surrounding tissue and becomes even stiffer if the woman being examined is tense, which also has effects on optimal breast compression. To the author's knowledge, no study has been published on the pressure distribution over the breast in mammography; more information will be given in Section 3.3.

## **2.4 Image quality**

Optimization of image quality is difficult as it is often task-specific. For instance in mammography, microcalcification detection greatly depends on the spatial resolution and the noise level of the system, whereas tumor mass detection is mainly limited by the image contrast of the system and the anatomical background in the image (Timberg, 2011).

Image quality can be evaluated using both objective methods such as determining the detective quantum efficiency (not described in this thesis), and subjective methods like

visual grading analysis (VGA) technique (Månsson, 2000). Methods belonging to the subjective branch use an observer as the final link of the imaging chain, and the task of the observer is to state whether certain criteria are fulfilled in the image or not. The criteria are often based on clinically relevant anatomical structures. Visual grading methods have been shown to agree both with methods based on receiver operating characteristic analysis (Tingberg et al., 2000), often referred to as “the gold standard” in evaluations of image quality, and with calculations of the physical image quality (Sandborg et al., 2001). The advantage of visual grading is the use of an observer, usually a radiologist dedicated to the field, grading the images. However, this is also the disadvantage of the method as bias could be introduced (hence the name “subjective”). A radiologist who has, in the last couple of years, been working with characteristic images from one system might systematically downgrade images taken with a new modality compared to the familiar ones.

Visual grading can be performed using several methods (Båth and Månsson, 2007). In Paper II image criteria (IC) and a two-step scale relative VGA were used.

### 2.4.1 Fulfillment of image criteria (IC)

In the IC method the observer has to state whether a certain criterion is fulfilled or not in the image. An image criteria score (ICS) is then calculated as the proportion of fulfilled criteria. The calculated mean ICS, that ranges from zero to unity, can then be compared for different systems. Table 2.1 gives examples of image quality criteria used in mammography (European Commission<sup>1</sup>, 1996). Revised image quality criteria of the European guidelines were used in Paper II (Hemdal et al., 2005; Grahn et al., 2005). The drawback with IC is that there is no soft transition from “not fulfilled” to “fulfilled”, which leads to difficulties for the observer when the reproduction of the anatomical structure is close to the decision threshold of the observer.

**Table 2.1** A selection of the criteria for the craniocaudal projection in European guidelines on quality criteria for diagnostic radiographic images.

<b>CC (CRANIO-CAUDAL) PROJECTION</b>	
<b>1.</b>	<b>DIAGNOSTIC REQUIREMENTS</b>
<b>1.1.</b>	<b>Image criteria related to positioning</b>
1.1.1.	Visually sharp reproduction of pectoral muscle at image margin
1.1.2.	Visually sharp reproduction of retrogladular fat tissue
1.1.5.	No skin folds
	<b>Image criteria related to exposure parameters</b>
1.1.8.	Reproduction of vascular structures seen through most dense parenchyma
1.1.9.	Visually sharp reproduction of all vessels and fibrous strands and pectoral muscle margin (absence of movement)
<b>1.2.</b>	<b>Important image details: micro-calcifications of 0.2 mm</b>

## **2.4.2 Visual grading analysis (VGA)**

VGA can be seen as an extension of IC with the addition of using a multistep scale. This gives the observer more freedom to state his/her opinion and overcomes the drawback with the either yes or no decision threshold in IC. The scale can be set arbitrarily and differs depending on if the VGA study is performed in an absolute or relative manner. In an absolute VGA the observer states his/her opinion about the visibility of a certain structure using an absolute scale typically consisting of three to five scale steps ranging from “bad/very bad” to “good/very good”. In a relative VGA the observer states his/her opinion about the visibility of a certain structure compared to a reference image using a relative scale typically consisting of five scale steps ranging from “much worse” to “much better” (Månsson, 2000). A disadvantage with VGA is that the scale steps used belong to an ordinal scale and often leads to incorrect use of statistical methods when analyzing the VGA data, however, an expanded VGA method has overcome this problem (Båth and Månsson, 2007).

# 3 Summary of the papers

## 3.1 Paper I – Breast tomosynthesis: Accuracy of tumor measurement compared with digital mammography and ultrasonography

The hypothesis behind this work was that tumor size measurement in DM is limited by superimposition of breast structures onto the 2D plane, potentially obscuring the tumor outline, and a 3D technique like BT, that reduces the disturbance effect of the projected anatomy, would provide a basis for a more accurate measurement of the tumor extent.

Seventy-three breast cancers imaged with DM, BT and US were measured by experienced radiologists without knowledge of the pathology results, which were used as reference. The longest axis of the breast tumor was measured with millimeter precision. Spicules of stellate lesions were not included, but rather the nucleus of the tumor. Of the 73 malignant breast tumors, 59% were IDCs, 19% were ILCs, 7% were DCIS, 1% LCIS and 14% were other types of invasive breast cancer.

Significantly more tumors could be measured on BT (86%) compared to DM (67%) ( $P < .05$ ). With DM the proportion of measurable tumors decreased significantly with increasing density of the breast parenchyma, with BT the same trend was observed but much less pronounced and with US there was a clear trend in the opposite direction (Table 3.1). Compared with pathology, tumor size was underestimated significantly ( $P < .05$ ) for all imaging modalities, although this was least apparent for BT. The correlation coefficient of BT, DM and US to pathologic size were 0.86, 0.71 and 0.85, respectively ( $P < .001$ ). The agreement between staging on imaging and pathology is seen in Table 3.2.

**Table 3.1** Percentage of measurable tumors in relation to breast density classification.

	BT (%)	DM (%)	US (%)	Total cases (n)
1) fatty parenchyma	91	87	77	22
2) intermediate parenchyma	84	59*	81	37
3) dense parenchyma	86	57	93	14

\*Statistical significance:  $P < .05$ , using  $\chi^2$  test for comparison of proportion to BT.



**Table 3.2** Agreement between T-staging on imaging and pathology of measurable tumors.

T stage	pT stage		Total staged correctly
	T1	T2	
BT ( <i>n</i> =63)	T1	48	3
	T2	2	10
DM ( <i>n</i> =49)	T1	36	6
	T2	4	2
US ( <i>n</i> =60)	T3	0	1
	T1	45	5
	T2	2	8

T1 includes tumors  $\leq 20$  mm in diameter; T2 includes tumors  $> 20$  mm and  $\leq 50$  mm; and T3 includes tumors  $> 50$  mm. pT refers to size at pathology. \*Statistical significance:  $P < .05$ , using  $\chi^2$  test for comparison of proportion to BT.

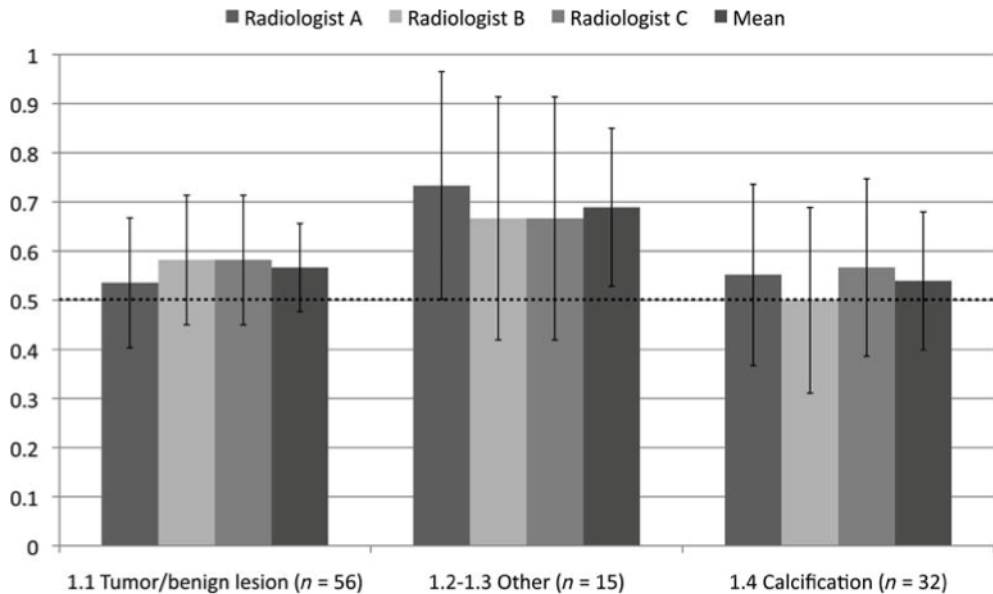
### 3.2 Paper II – The effect of reduced breast compression in breast tomosynthesis: human observer study using clinical cases

Due to the fact that BT is a 3D technique increased separation of the structures in the Z-direction would be an advantage. It was hypothesized that this could be accomplished by reducing the compression force compared to what is usually used in 2D mammography.

Forty-five women were examined with BT using full (i.e. the compression force used in DM) and half compression force. The BT examination was initiated by acquiring an image set under full compression of the breast, i.e. about the same used for the preceding DM examination, followed by another set under half compression without repositioning the breast. A total of 103 paired structure images were evaluated according to specified image quality criteria.

The reduced compression force resulted in a 5.8 mm average breast thickness increase. The half compression force images fulfilled (to the same extent as full compression images) the diagnostic requirements presented as revised image criteria for a breast radiograph to produce an image of standard quality. Figure 3.1 summarizes the scores of the three participating radiologists and their averages for structures of interest. Ideally, if no difference in image quality was found between full and half compression, the score would equal 0.5. If full compression was chosen as superior for all structures the score would equal 1, and if the opposite was true (half compression was chosen for all structures) the score would equal 0. Although there was a trend towards higher scores, all 95% confidence intervals, except the average of the criteria concerning glandular tissue and fibrous strands, included the value 0.5. All of the

examined women felt that half compression was more comfortable (83%) or equal to (17%) full compression.



**Figure 3.1** The proportion of the cases for which full compression level was rated superior per type of structure and radiologist and their mean. Equal proportions of full and half compression correspond to 0.5. Category labeled “Other” refers to image quality criteria of glandular tissue and fibrous strands.

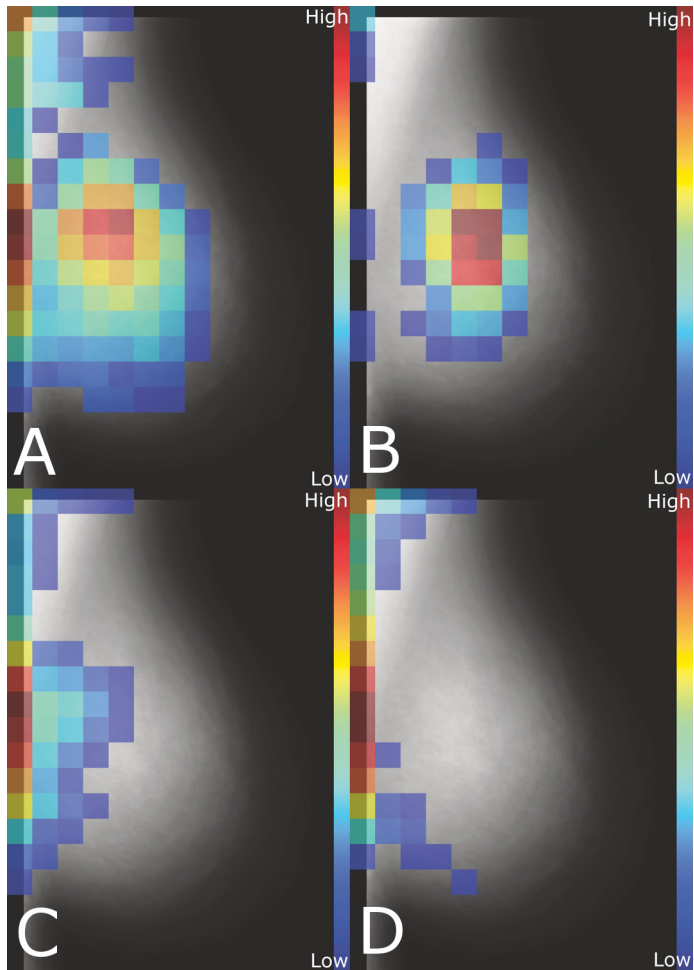
### 3.3 Paper III – Breast compression in mammography: pressure distribution patterns

This study was conducted in part to explain the findings in Paper II, but also to gain a general understanding of how the applied compression force is distributed over the breast.

One hundred and three women, without any biopsy-verified malignant tumors, were subjected to two breast compressions of the left breast using full compression force and approximately half compression force. The pressure distribution over the breast as a result of breast compression was obtained using force sensing resistor (FSR) sensors placed underneath the DM compression plate. Pressure data and DM screening mammograms were used to create composite images with pressure data displayed as a transparent color overlay. The subjects were asked to rate their experience of pain at full and reduced compression on a 10 cm visual analogue scale immediately following the different compressions.

The resulting pressure distribution was heterogeneous in appearance and varied widely between different breasts. Four pressure distribution patterns were identified (Figure 3.2). All measured pressure distributions could be classified as one, or a combination of two, of these patterns. In pattern A pressure was widespread over the breast. Pattern B was characterized by high pressure in the central part of the breast while pressure was low, or not present, elsewhere. Pattern C showed a concentration of high pressure in the juxtathoracic region (close to the chest wall), extending in a decreasing gradient towards the central part of the breast. Pattern D was characterized by very high pressure along a narrow zone at the juxtathoracic edge, extending along the pectoral muscle towards the armpit with little or no pressure over the breast. Two groups (43 breasts; C, D) showed pressure mainly over the juxtathoracic part of the breast and had significantly greater breast thickness ( $P = .003$ ) and lower mean pressure over dense tissue ( $P < .0001$ ) than those with more evenly distributed pressure. There was a significant difference in experienced pain between full and half compression ( $P < .05$ ). Multiple linear regression identified that pain was associated ( $P < .001$ ) with the independent variables breast area, mean pressure over dense tissue and breast thickness.

No correlation was found between compression force and breast thickness (full,  $P = .50$ ; half,  $P = .52$ ). There was, however, a strong negative correlation between measured force over the middle of the breast and breast thickness (full,  $P < .001$ ; half,  $P < .009$ ).



**Figure 3.2** Relative pressure distribution for the four pressure pattern groups (A-D). Each image group was created by combining all included pressure data sets and averaging in each pixel, excluding values less than 10% of the maximum after averaging. The mammographic background image was averaged from the mammograms of all 103 included subjects.

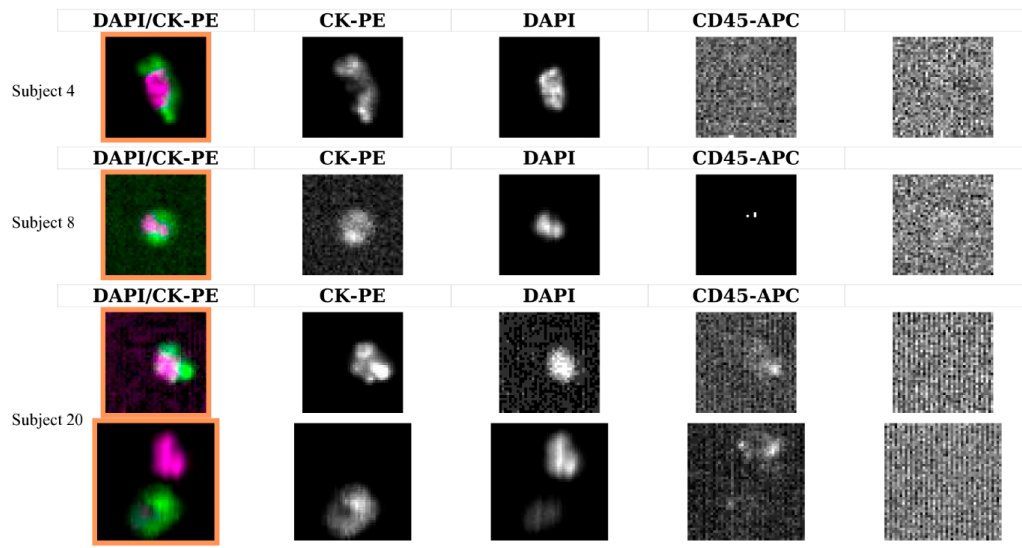
### 3.4 Paper IV – No evidence for shedding of circulating tumor cells into the peripheral venous blood as a result of mammographic breast compression

Some women experience breast compression as painful, and it has long been hypothesized that the force used for compressing the breast during mammography is

of such a magnitude that it might damage a tumor including its vascular structures and make it leak tumor cells into the blood and/or lymph system.

Twenty-four subjects with strong suspicion of breast malignancy had blood samples drawn before and after breast compression. To measure the pressure over the tumor FSR sensors were used. The blood samples were analyzed for CTCs using the CellSearch® system. Briefly, antibodies conjugated to ferro-fluid particles were used to magnetically isolate cells expressing the epithelial cell adhesion molecule. Unbound cells were removed and the enriched sample was fluorescently stained for nucleic acids (DAPI), cytokeratins (CK 8, 18 and 19) and the leukocyte antigen CD45. Two independent and accredited readers identified and counted the number of CTCs in computer-generated cellular images. Information on tumor histology, staging and prognostic factors was retrieved from pathology reports.

In 22 of the 24 subjects breast malignancies were confirmed at pathology. The average mean tumor pressure  $6.8 \pm 5.3$  kPa (range, 1.0-22.5 kPa) was significantly different from the average mean breast pressure  $3.4 \pm 1.6$  kPa (range, 1.5-7.1 kPa) ( $P < .001$ ). This confirms that there was increased pressure over the tumor. Four subjects (17%) were CTC positive before compression and two of these (8%) were also CTC positive after compression (Figure 3.3). A total of seven CTCs were isolated with a mean size of  $8 \times 6 \mu\text{m}$ . The small number of CTC positive subjects made it impossible to analyze any relationships between the presence of CTC and applied pressure or pathological factors.



**Figure 3.3** Example of CTCs from subjects with malignant disease in the study. Briefly, cells are fluorescently stained for nucleic acids (DAPI), cytokeratins (CK) and the leukocyte antigen CD45. Cells with a size of at least  $4 \mu\text{m}$  presenting the phenotype DAPI+/CK+CD45- are classified as CTCs.

# 4 Discussion and concluding remarks

The main finding in Paper I was that BT can more accurately determine tumor size and correlates better with pathology compared to DM. This is most likely due to the 3D presentation of the breast in BT images, which reduces the problem of superimposed tissue, since technical parameters such as beam quality and detector properties are similar for the two systems. For the same reason, more tumors could be measured with BT compared to DM. However, certain types of cancer remain hard to detect or measure on BT because of their growth pattern. This applies to tumors that infiltrate the breast tissue diffusely without forming evident tumor masses such as a certain proportion of ILC. These tumors may also be hard to detect or measure using US.

The tumor sizes assessed with the different modalities were compared with the histological sections. The size estimation on pathology may involve some uncertainties. The plane of slicing that was chosen may not have captured the maximum tumor extent, and, because of the slicing technique, it may be hard to measure the tumor extent in the orthogonal plane.

All modalities underestimated the tumor size significantly. The maximum tumor extent may not have been captured in the imaged plane on BT and DM, respectively. Another reason for underestimation of tumor size is that the approximation of the tumor outline in spiculated tumors might have been too conservative. The problem relates to the fact that it is not possible to determine how much of a spicule that is tumor growth and how much is reactive fibrosis. This is also apparent on US, when only the hypoechoic part of the lesion is included in the measurement and not the hyperechoic zone representing the spiculated periphery.

Table 3.1 shows the improved tumor visibility in dense breasts using BT compared to DM, illustrating the fact that the anatomic background is an important limiting factor in 2D mammography (Bochud et al., 1999). The table also shows that US is a good complement in dense breasts.

This is the first published study investigating the accuracy of tumor size measurement with BT correlated with pathology findings. A similar study was presented in 2010 at the European Congress of Radiology (Meacock et al., 2010), which found similar correlation coefficients between BT and DM, respectively, and pathology (BT: 0.83 vs. 0.86 in Paper I, DM: 0.78 vs. 0.71 in Paper I). In conclusion, the agreement

between staging on imaging and pathology was superior for BT compared to DM. This implies that BT provides more accurate information on prognosis and choice of treatment.

The results from Paper II suggests that BT may be performed with substantially less compression force compared with DM, despite the fact that the acquisition parameters, such as beam quality and tube loading (mAs), were not optimized for the half compression force images. This study was conducted on a prototype BT unit that lacked AEC and automatic selection of beam quality, which commercial units typically are equipped with.

Although the limited number of cases included in the study could be the reason for the lack of significant differences rather than a valid null hypothesis, the results indicate that any actual differences are probably so small that they would not have any substantial impact on the diagnostic performance. This reasoning is supported by taking into account the low inter-observer agreement between the three observers and that all but a very few structures were clearly visible on both full and half compression images. Furthermore, the deviation from 0.5 was smallest for the most clinically relevant structures such as masses and calcifications. Additionally, the majority of the breasts were examined in the MLO projection, which included the pectoral muscle, which is often the thickest part of the imaged volume. It is possible that the main part of the breast did not experience the same degree of thickness reduction, which in turn might have influenced the difference in image quality.

In some breasts the reduced compression was just enough to keep the breast in position and in some breasts the reduced compression did not affect the breast thickness, indicating that force is not a good indicator of adequate breast compression. Poulos et al. (2003) concluded that beyond a certain compression force level further compression only causes pain without producing any further decrease of breast thickness.

In this study the BT examination was performed by first acquiring an image set using full compression of the breast, followed by another set using half compression, without repositioning the breast. Using this practice, the examined woman could possibly be more relaxed after the initial compression, becoming less tense, compared to performing a second full or half compression. It is possible that this would affect the results in general and the pain results in favor of half compression.

This study is the first published study investigating reduced breast compression in BT using clinical cases. Saunders et al. (2009) investigated reduced breast compression for BT using a Monte Carlo program and a voxelized anthropomorphic breast phantom for two breast thicknesses (4 cm and 6 cm). They found that neither mass nor microcalcification conspicuity changed significantly with reduced compression similar to our thickness reduction (5 mm for 4 cm breast, 7.5 mm for 6 cm breast, 5.8 mm in Paper II), which is in accordance with our results.

In conclusion, breast compression reduction in BT is motivated by increased comfort, thereby in all likelihood increasing the number of women who would comply with the recommended mammographic screening protocols.

The pressure distribution over the breast as a result of applied breast compression was measured in Paper III. The main finding was that the pressure distribution was heterogeneous over the breast and varied greatly between breasts. This could to some extent explain the results found in Paper II of a non-significant difference in image quality between full and half compression possibly due to small thickness difference over the relevant breast area. Two of the pressure pattern groups showed pressure mainly over the juxtathoracic part of the breast and a compression reduction would have minimal impact over the rest of the breast. The breast thickness reduction between full and half compression was 1.8 mm compared to 5.8 mm in Paper II. As compression procedures are the same and compression forces were similar, the difference is likely due to the different compression plates used. In Paper II a more rigid BT compression plate was used that lacks the rounded edge and flexible fixtures of the conventional DM plate used in Paper III. Theoretically, a perfectly stiff plate would compress the breast to an even thickness and the pressure would be higher over stiff tissue compared to less stiff tissue. Using a soft compression plate, the plate would conform to the shape of the breast applying proportionally less pressure to stiff areas, thus creating a more even pressure distribution. The thickness read-out is influenced by the permissible tilt of the DM plate, as the anchoring of the plate is not fixed.

In conventional 2D mammography it is important to compress the breast to separate tissue components. One does not strive for a uniform compression of the breast as the areas of interest usually include dense parenchymal tissue surrounded by fat. In addition, less diagnostically relevant structures, such as the pectoral muscle, are firmer than the parenchyma, becoming more so when compressed, and will be subjected to proportionally higher pressure. In pressure groups C and D (Figure 3.2), the pectoral muscle and other structures in the chest wall acted as a support, preventing adequate compression of relevant tissues of the breast. For these groups increased compression force will mainly reduce the thickness of the pectoral muscle and the juxtathoracic area and the level of force applied will have little effect on the compression of the breast itself. Thus, further application of force will result in excess pain for a very minor decrease in breast thickness. On the contrary, the force was applied to the breast itself in pressure groups A and B, and half compression could be motivated for increase in patient comfort when taking into account the small thickness increase of 1.8 mm. This also suggests a need for a more refined compression device design, which can ascertain appropriate compression of the breast itself even in the presence of thick juxtathoracic structures.

The multiple linear regression model showed that a woman's experienced pain was related to breast area, mean pressure over dense tissue and breast thickness.



Interestingly it was not associated with other parameters such as force over the breast or maximum pressure. It seems reasonable to assume that women with a small breast area have increased experienced of pain, and that parenchyma is more tender than muscular or adipose tissue. How breast thickness is related to pain is less clear and it was also not significant in a univariate analysis.

A limitation of the study is that it depends on the performance of the sensor system. High-pressure areas at the sensors edge often exceeded the sensors' saturation limit. This could be avoided by setting a higher saturation limit, but that would negatively impact the sensors' ability to measure low pressure. Furthermore, the physical size of individual sensor elements introduce partial area effect, meaning for example that pressure structures smaller than an element will be interpreted as covering the whole element, or two elements if located on the edge between them. The pressure distribution results also depend on the thickness at different locations in the breast, which was assumed to be uniform under the compression plate. This is however not the case as it was noticed that the plate was bent to some small extent and was allowed to tilt a certain degree due to the design of the compression plate. Thus, it would have been useful to obtain a thickness map over the compressed breast.

To the author's knowledge, no study has investigated how the pressure is distributed over the breast as a result of applied compression *in vivo*. One study measured pressure in one single point *in vivo* but due to the experimental design gave no more information except for force measurement (Clark et al., 1990). Russell and Ziewacz (1995) measured pressure in a breast phantom made of vinyl-wrapped, unleavened-bread-dough. They found that pressure is higher over stiffer materials (mimicking breast tumors); however, phantom results can not be necessarily be extrapolated to a clinical situation.

In summary, it is not suitable to base breast compression on applied force, it is pressure caused by this force which leads to deformation of the breast. Inadequate compression of the breast is usually not due to lack of force but unsuitable pressure distribution.

Despite a substantial number of animal studies (Tyzzer, 1913; Romsdahl et al., 1965), studies of shedding during surgery (Choy and McCulloch, 1996; Hayashi et al., 1999) and letters of concern (Watmough and Quan, 1992; van Netten et al., 1999) regarding tumor cell shedding following manipulation of the primary tumor, no elevated CTC count in peripheral venous blood following breast compression was found in Paper IV. There are basically two possible explanations. First, the pressure over the malignant tumor was not enough to cause cell shedding to peripheral blood. This is opposed by the fact that cysts are occasionally ruptured after mammography (Pennes and Homer, 1987), though the characteristics of cysts differ from malignant masses. Second, there might in fact have been a release of tumor cells, but that these might have been trapped in the lung capillaries. The pathways of possible CTCs originating

from primary breast cancers are largely unknown. In order to reach the peripheral veins (from where the blood was drawn in this study) CTCs need to pass both the capillaries of the lungs and the capillary beds of the extremities without being trapped. It has been shown that the CTC count is higher in the central veins compared to the peripheral veins in primary colon cancer (Wind et al., 2009).

Additionally, the probability to find CTCs using the CellSearch<sup>®</sup> system is limited by a number of factors including the biokinetics of CTCs and the fact that only cells expressing the epithelial marker EpCam will be detected. However, the sampled volume is the main reason for not detecting CTCs (Coumans et al., 2012), which was the reason why two samples were drawn before and after compression, respectively.

In conclusion, this is the first study investigating this issue using clinical cases. Although a limited study sample, the results support the view that mammography is a safe procedure from the point of view of malignant cell shedding to peripheral blood.

## 4.1 Future aspects

BT has advantages over DM as shown in this thesis. Tumor size measured on BT images correlates better with pathology and less breast compression can be used compared to DM. However, to explore the true benefits of BT large-scale randomized screening studies are needed. Since 2010 such a study has been ongoing in Malmö. At this point, the results from that study are promising, indicating better sensitivity for BT compared to DM. It is yet too soon to tell if BT can replace DM in a screening situation, as some problems need to be addressed regarding such issues as workflow, reading time, and cost as well as possible impact on overdiagnosis.

The mammographic imaging systems have undergone remarkable improvements over the years but the compression device is basically the same since the introduction of mammography. Thus, there is a need for improvement of the compression device. Not only the physical design needs refinement but there is also a need for a physical parameter that could be determined for adequate breast compression. The use of force is not suitable; a parameter related to the deformation of the breast based on pressure distribution data would be more appropriate.

CTC is currently one of the most active areas of translational cancer research and will continue to be so over the next years. The thought of performing a “liquid biopsy” to obtain valuable prognostic information is attractive. As an extension of Paper **IV** we intend to draw blood from the superior vena cava in breast cancer patients, in addition to peripheral vein sampling, in order to assess the sieving of CTCs in the lung capillaries.



# 5 Conclusions

- The accuracy of tumor size measurement was superior for BT compared to DM, but not significantly different from US.
- BT may be performed with substantially less compression force compared to 2D mammography without significantly degrading the image quality from a clinical point of view.
- The distribution of pressure as a result of breast compression was heterogeneous and varied greatly between different breasts. The compression of the breast itself was frequently insufficient, the main pressure being absorbed by juxtathoracic structures.
- No evidence was found that breast compression in mammography causes dissemination of malignant cells to peripheral venous blood.



# Acknowledgements

I would like to express my sincere gratitude to Ingvar Andersson for sharing your knowledge and always finding the time to help me. I thank you from the bottom of my heart. Without you I would be doing physics ;)

I am very grateful to my supervisor Anders Tingberg for all the help during these years and for always cheering me up and putting me in a good mood. We have had some good times together around the world.

I am very grateful to my co-supervisors Sören Mattsson, for trusting in my abilities and giving me the opportunity to do research here, and Sophia Zackrisson, for being a good mentor and friend.

I would like to thank my friend and new co-supervisor Påntus Timberg. It has been so much fun to share a room with you all these years. You are a great musician and it has been a pleasure listening to your music.

I would like to thank: Thomas Mertelmeier and Anna Jerebko at Siemens AG for all of your help and support with the breast tomosynthesis projects. Marianne Löfgren, Cecilia Wattsgård, Annika Lindahl and Barbara Ziemiecka for being very research-friendly radiologists. The staff at Unilabs for being friendly and helping out with the projects, special thank to Maria Sesein and Eva Undrén. The Gothenburg group for a good collaboration over the years. My new collaboration partners at the Department of Oncology in Lund, special thanks to Kristina Aaltonen.

A special thank you to my friends, colleagues, PhD friends and co-workers: Mackan S, Christian B, Fredrik N, Pernilla P, Magnus D, Andreas W, Mats H, Calle S, Marie S, Therése G, Sofie C, Anna K, Martin A, Maria C, Ünal Ö, Mattias J, Simon K, Hanna H, Peder K, Karl Ö, Lars H, Jonas N, Hannie P, et al.; Bengt, Jonas, Sven B, Sven M, Gunnarsson, Mats N, Tommy K, Rääf, LEO, Kai, Sigrid, Peter, Veronika, Maja, David, Sacha, Elisa et al.; Sjukhusfysikermaffian (Jonathan, Emil, Johan, Lilldanne, Stoffe), Björn and Jenny, you have been the best possible friends during these years and I have been blessed with your daily presence.

Till min familj kochana mamusia Elżbieta, älskade pappa Guset och bästa syster Karolina: Jag är så tacksam för allt ni har gjort för mig och jag är stolt över er! Jag älskar er så oerhört mycket!



# References

- Aebi S, Davidson T, Gruber G, et al. (2011). Primary breast cancer: ESMO Clinical Practice Guidelines for diagnosis, treatment and follow-up. *Ann Oncol* 22: 12-24.
- Andersson I, Ikeda DM, Zackrisson S, et al. (2008). Breast tomosynthesis and digital mammography: a comparison of breast cancer visibility and BIRADS classification in a population of cancers with subtle mammographic findings. *Eur Radiol* 18: 2817-2825.
- de Azambuja E, Cardoso F, de Castro G Jr, et al. (2007). Ki-67 as prognostic marker in early breast cancer: a meta-analysis of published studies involving 12,155 patients. *Br J Cancer* 96: 1504-1513.
- Båth M, Månsson LG (2007). Visual grading characteristics (VGC) analysis: a non-parametric rank-invariant statistical method for image quality evaluation. *Br J Radiol* 80: 169-176.
- Bidard FC, Mathiot C, Delalogue S, et al. (2010). Single circulating tumor cell detection and overall survival in nonmetastatic breast cancer. *Ann Oncol* 21: 729-733.
- Bochud FO, Valley JF, Verdun FR, et al. (1999). Estimation of the noisy component of anatomical backgrounds. *Med Phys* 26: 1365-1370.
- Choy A, McCulloch P (1996). Induction of tumour cell shedding into effluent venous blood breast cancer surgery. *Br J Cancer* 73: 79-82.
- Clark DJ, Chambers IR, Faulkner K, et al. (1990). Pressure measurements during automatic breast compression in mammography. *J Biomed Eng* 12: 444-446.
- Coumans FA, Ligthart ST, Uhr JW, et al. (2012). Challenges in the enumeration and phenotyping of CTC. *Clin Cancer Res* 18: 5711-5718.
- Cristofanilli M, Budd GT, Ellis MJ, et al. (2004). Circulating tumor cells, disease progression, and survival in metastatic breast cancer. *N Engl J Med* 351: 781-791.
- Crystal P, Strano SD, Shcharynski S, et al. (2003). Using sonography to screen women with mammographically dense breasts. *AJR Am J Roentgenol* 181: 177-182.
- Dobbins JT 3rd, Godfrey DJ (2003). Digital x-ray tomosynthesis: current state of the art and clinical potential. *Phys Med Biol* 48: R65-106.
- Dustler M, Andersson M, Förnvik D, et al. (2013). A study of the feasibility of using slabbing to reduce tomosynthesis review time. *Proc SPIE* 8673: 86731L1-6.
- Dvorak HF (1986). Tumors: wounds that do not heal. Similarities between tumor stroma generation and wound healing. *N Engl J Med* 315: 1650-1659.
- Elston CW, Ellis IO (1991). Pathological prognostic factors in breast cancer. I. The value of histological grade in breast cancer: experience from a large study with long-term follow-up. *Histopathology* 19: 403-410.
- Engel J, Eckel R, Kerr J, et al. (2003). The process of metastatisation for breast cancer. *Eur J Cancer* 39: 1794-1806.



- European Commission<sup>1</sup> (1996). European guidelines on quality criteria for diagnostic radiographic images. Report EUR 16260 EN, Luxembourg.
- European Commission<sup>2</sup> (1996). European protocol on dosimetry in mammography. Publication EUR 16263 EN, Brussels, Belgium.
- Ferlay J, Shin HR, Bray F, et al. (2010). Estimates of worldwide burden of cancer in 2008: GLOBOCAN 2008. *Int J Cancer* 127: 2893-2917.
- Fisher ER, Anderson S, Redmond C, et al. (1993). Pathologic findings from the National Surgical Adjuvant Breast Project protocol B-06. 10-year pathologic and clinical prognostic discriminants. *Cancer* 71: 2507-2514.
- Förnvik D, Jerebko A, Timberg P, et al. (2011). A human observer study for evaluation and optimization of reconstruction methods in breast tomosynthesis using clinical cases. *Proc SPIE* 7961: 79615G1-7.
- Förnvik D, Dustler M, Andersson I, et al. (2013). Pressure distribution in mammography: compression of breasts with malignant tumor masses. *Proc SPIE* 8668: 86684E1-8.
- Grahn A, Hemdal B, Andersson I, et al. (2005). Clinical evaluation of a new set of image quality criteria for mammography. *Radiat Prot Dosimetry* 114: 389-394.
- Gupta GP, Massagué J (2006). Cancer metastasis: building a framework. *Cell* 127: 679-695.
- Gur D, Abrams GS, Chough DM, et al. (2009). Digital breast tomosynthesis: observer performance study. *AJR Am J Roentgenol* 193: 586-591.
- Harris L, Fritsche H, Mennel R, et al. (2007). American Society of Clinical Oncology 2007 update of recommendations for the use of tumor markers in breast cancer. *J Clin Oncol* 25: 5287-5312.
- Hayashi N, Egami H, Kai M, et al. (1999). No-touch isolation technique reduces intraoperative shedding of tumor cells into the portal vein during resection of colorectal cancer. *Surgery* 125: 369-374.
- Hayes DF, Cristofanilli M, Budd GT, et al. (2006). Circulating tumor cells at each follow-up time point during therapy of metastatic breast cancer patients predict progression-free and overall survival. *Clin Cancer Res* 12: 4218-4224.
- Hemdal B, Andersson I, Grahn A, et al. (2005). Can the average glandular dose in routine digital mammography screening be reduced? A pilot study using revised image quality criteria. *Radiat Prot Dosimetry* 114: 383-388.
- Hilleren DJ, Andersson IT, Lindholm K, et al. (1991). Invasive lobular carcinoma: mammographic findings in a 10-year experience. *Radiology* 178: 149-154.
- Kotsianos-Hermle D, Hiltawsky KM, Wirth S, et al. (2009). Analysis of 107 breast lesions with automated 3D ultrasound and comparison with mammography and manual ultrasound. *Eur J Radiol* 71: 109-115.
- Krouskop TA, Wheeler TM, Kallel F, et al. (1998). Elastic moduli of breast and prostate tissues under compression. *Ultrason Imaging* 20: 260-274.
- Lee YT (1983). Breast carcinoma: pattern of metastasis at autopsy. *J Surg Oncol* 23: 175-180.
- Liotta LA, Kleinerman J, Sidel GM (1974). Quantitative relationships of intravascular tumor cells, tumor vessels, and pulmonary metastases following tumor implantation. *Cancer Res* 34: 997-1004.

- Månsson LG (2000). Methods for the evaluation of image quality: a review. *Radiat Prot Dosimetry* 90: 89-99.
- Marmot MG, Altman DG, Cameron DA, et al. (2012). The benefits and harms of breast cancer screening: an independent review. *Lancet* 380: 1778-1786.
- Meacock LM, Mombelloni S, Iqbal A, et al. (2010). The accuracy of breast cancer size measurement: Digital breast tomosynthesis (DBT) vs 2D digital mammography (DM). European Collage of Radiology annual meeting, Vienna, Austria.
- Mercer CE, Hogg P, Lawson R, et al. (2013). Practitioner compression force variability in mammography: a preliminary study. *Br J Radiol* 86: 20110596.
- Mertelmeier T, Orman J, Haerer W, et al. (2006). Optimizing filtered backprojection reconstruction for a breast tomosynthesis prototype device. *Proc SPIE* 6142: 61420F1-12.
- Mertelmeier T, Zhao, W (2010). Mammography tomosynthesis apparatus with a compression plate having a recess therein. US Patent Patent no. US 7,742,558 B2.
- Miller D, Livingstone V, Herbison P (2008). Interventions for relieving the pain and discomfort of screening mammography. *Cochrane Database Syst Rev* 23: CD002942.
- Morin EL, Bryant JT, Reid SA, et al. (2001). Calibration issues of Tekscan systems for human pressure assessment. RTO meeting proceedings 56 – Soldier mobility: Innovations in load carriage system design and evaluation. Ottawa/Hull: St Joseph, Canada.
- van Netten JP, Cann SA, Glover DW (1999). Mammographic compression: a force to be reckoned with. *Br J Cancer* 81: 1426-1427.
- Niklason LT, Christian BT, Niklason LE, et al. (1997). Digital tomosynthesis in breast imaging. *Radiology* 205: 399-406.
- Nyström L, Andersson I, Bjurstram N, et al. (2002). Long-term effects of mammography screening: updated overview of the Swedish randomised trials. *Lancet* 359: 909-919.
- Pennes DR, Homer MJ (1987). Disappearing breast masses caused by compression during mammography. *Radiology* 165: 327-328.
- Pisano ED, Gatsonis C, Hendrick E, et al. (2005). Diagnostic performance of digital versus film mammography for breast-cancer screening. *N Engl J Med* 353: 1773-1783.
- Poulos A, McLean D, Rickard M, et al. (2003). Breast compression in mammography: how much is enough? *Australas Radiol* 47: 121-126.
- Poulos A, McLean D (2004). The application of breast compression in mammography: a new perspective. *Radiography* 10: 131-137.
- Romond EH, Perez EA, Bryant J, et al. (2005). Trastuzumab plus adjuvant chemotherapy for operable HER2-positive breast cancer. *N Engl J Med* 353: 1673-1684.
- Romsdahl MM, McGrath RG, Hoppe E, et al. (1965). Experimental model for the study of tumor cells in the blood. *Acta Cytol* 9: 141-145.
- Russell DG, Ziewacz JT (1995). Pressures in a simulated breast subjected to compression forces comparable to those of mammography. Work in progress. *Radiology* 194: 383-387.
- Samani A, Zubovits J, Plewes D (2007). Elastic moduli of normal and pathological human breast tissues: an inversion-technique-based investigation of 169 samples. *Phys Med Biol* 52: 1565-1576.

- Sandborg M, Tingberg A, Dance DR, et al. (2001). Demonstration of correlations between clinical and physical image quality measures in chest and lumbar spine screen-film radiography. *Br J Radiol* 74: 520-528.
- Sarvazyan A (1998). Mechanical imaging: a new technology for medical diagnostics. *Int J Med Inform* 49: 195-216.
- Saunders RS Jr, Samei E, Lo JY, et al. (2009). Can compression be reduced for breast tomosynthesis? Monte carlo study on mass and microcalcification conspicuity in tomosynthesis. *Radiology* 251: 673-682.
- Socialstyrelsen<sup>1</sup>. "Cancer Incidence in Sweden 2010". <http://www.socialstyrelsen.se/statistik>
- Socialstyrelsen<sup>2</sup>. "Cause of Death 2010". <http://www.socialstyrelsen.se/statistik>
- Svahn TM, Chakraborty DP, Ikeda D, et al. (2012). Breast tomosynthesis and digital mammography: a comparison of diagnostic accuracy. *Br J Radiol* 85: 1074-1082.
- Tavassoli FA, Devilee P (2003). World Health Organization classification of tumours. Pathology and genetics of tumours of the breast and female genital organs. IARC Press, Lyon, France.
- Teubner J (1997). Technique and results in radiologic diagnosis of breast diseases. *Echomammography*. Springer, Berlin, Germany.
- Timberg P (2011). Breast tomosynthesis. Aspects on detection and perception of simulated lesions. PhD Thesis Lund University, Sweden.
- Timberg P, Lång K, Nyström M, et al. (2013). Investigation of viewing procedures for interpretation of breast tomosynthesis image volumes: a detection-task study with eye tracking. *Eur Radiol* 23: 997-1005.
- Tingberg A, Herrmann C, Lanhede B, et al. (2000). Comparison of two methods for evaluation of the image quality of lumbar spine radiographs. *Radiat Prot Dosimetry* 90: 165-168.
- Tingberg A, Zackrisson S (2011). Digital mammography and tomosynthesis for breast cancer diagnosis. *Expert Opin Med Diagn* 5: 517-526.
- Tyzzar EE (1913). Factors in the production and growth of tumor metastases. *J Med Res* 28: 309-332.
- Wang Z (2010). Mechanical and optical methods for breast cancer imaging. PhD Thesis University of Iowa, USA.
- Watmough DJ, Quan KM (1992). X-ray mammography and breast compression. *Lancet* 340: 122.
- Watmough DJ, Quan KM, Aspden RM (1993). Breast compression: a preliminary study. *J Biomed Eng* 15: 121-126.
- Weigelt B, Peterse JL, van't Veer LJ (2005). Breast cancer metastasis: markers and models. *Nat Rev Cancer* 5: 591-602.
- Wellman PS, Howe RD, Dalton E, et al. (1999). Breast tissue stiffness in compression is correlated to histological diagnosis. PhD Thesis Harvard University, USA.
- Wind J, Tuynman JB, Tibbe AG, et al. (2009). Circulating tumour cells during laparoscopic and open surgery for primary colonic cancer in portal and peripheral blood. *Eur J Surg Oncol* 35: 942-950.





## Breast tomosynthesis: Accuracy of tumor measurement compared with digital mammography and ultrasonography

DANIEL FÖRNVIK<sup>1</sup>, SOPHIA ZACKRISSON<sup>2</sup>, OTTO LJUNGBERG<sup>3</sup>, TONY SVAHN<sup>1</sup>, PONTUS TIMBERG<sup>1</sup>, ANDERS TINGBERG<sup>1</sup> & INGVAR ANDERSSON<sup>2</sup>

<sup>1</sup>Department of Medical Radiation Physics, Lund University, Malmö University Hospital, Malmö, Sweden;

<sup>2</sup>Diagnostic Centre of Imaging and Functional Medicine, Malmö University Hospital, Malmö, Sweden;

<sup>3</sup>Department of Pathology, Malmö University Hospital, Malmö, Sweden

**Background:** Mammographic tumor size measurement can be difficult because breast structures are superimposed onto a two-dimensional (2D) plane, potentially obscuring the tumor outline. Breast tomosynthesis (BT) is a 3D X-ray imaging technique in which low-dose images are acquired over a limited angular range at a total dose comparable to digital mammography (DM). These low-dose images are used to mathematically reconstruct a 3D image volume of the breast, thus reducing the problem of superimposed tissue.

**Purpose:** To investigate whether breast cancer size can be more accurately assessed with breast tomosynthesis than with digital mammography and ultrasonography (US), by reducing the disturbance effect of the projected anatomy.

**Material and Methods:** A prototype BT system was used. The main inclusion criterion for BT examination was subtle but suspicious findings of breast cancer on 2D mammography. Sixty-two women with 73 breast cancers were included. BT, DM, and US sizes were measured independently by experienced radiologists without knowledge of the pathology results, which were used as reference.

**Results:** The tumor outline could be determined in significantly more cases with BT (63) and US (60) than DM (49). BT and US size correlated well with pathology ( $R=0.86$  and  $R=0.85$ , respectively), and significantly better than DM size ( $R=0.71$ ). Accordingly, staging was significantly more accurate with BT than with DM.

**Conclusion:** The study indicates that BT is superior to DM in the assessment of breast tumor size and stage.

**Key words:** Breast; cancer measurement; cancer staging; comparative studies

*Daniel Förnvik, Department of Medical Radiation Physics, Malmö University Hospital, SE-205 02 Malmö, Sweden (tel. +46 40 33 86 59, fax. +46 40 33 78 20, e-mail. daniel.fornvik@med.lu.se)*

*Submitted September 4, 2009; accepted for publication November 27, 2009*

Accurate size prediction of an invasive breast cancer is important in preoperative planning and as a prognostic indicator (1–4). With the increased use of breast-conserving surgery and neoadjuvant chemotherapy, the ability to correctly determine maximum tumor extent noninvasively is essential (5, 6). Although pathological measurement is regarded as the gold standard, important therapeutic decisions must be made on the basis of the tumor size assessed by imaging, as the pathological tumor staging is not yet available.

Preoperative tumor size is commonly measured on mammography and/or ultrasonography (US). The latter is widely available and is particularly valuable in patients with dense breasts, but is known to underestimate tumor size (7).

Mammographic tumor size measurement is not infrequently made difficult since breast structures are superimposed onto a two-dimensional (2D) plane, and this may obscure the tumor outline. In addition, mammographic estimates of tumor extent may be influenced by variations in the distance between the tumor and the film/detector, and compression of the breast during examination. Moreover, standard imaging projections do not always capture the maximum tumor extent. These problems may be compounded by certain tumor growth patterns. A tomographic technique such as breast tomosynthesis (BT) would overcome one of the major problems, i.e., reducing the obscuring effect of overlying and underlying breast tissues. Our hypothesis was that size measurements using BT may

be more accurate than using digital mammography (DM). This study was designed to evaluate the accuracy of size measurements in BT, DM, and US using pathological size as a gold standard.

## Material and Methods

### *Patient population*

Two groups of women were included: women recalled from screening with subtle findings suspicious for malignancy and women referred for clinical symptoms, with subtle or negative findings of malignancy on DM. The Regional Ethical Vetting Board at Lund University (Dnr 159/2006) approved the study, and all patients gave their informed consent.

A total of 74 patients with breast malignancies who underwent BT were included in the study and imaged within a period of 19 months (June 2006 to December 2007). All patients also underwent DM and US examinations followed by needle biopsy and surgery. Eight women were excluded since they underwent preoperative treatment with chemotherapy. Two women were excluded due to mAs values not complying with the study protocol. One woman was excluded due to distant metastasis. In one case, the tissue material was insufficient for accurate measurement on pathology, leaving 62 women with 73 malignant breast tumors for evaluation. The age of the patients averaged 60 years (range 42–79 years).

### *Image acquisition*

DM was performed using standard craniocaudal (CC) and mediolateral oblique (MLO) projections on dedicated digital units (Mammomat Novation; Siemens, Erlangen, Germany). BT was performed on a prototype unit adapted from the Mammomat Novation (Siemens, Erlangen, Germany) (8), and the examinations were carried out immediately following diagnostic DM/US examinations. In patients with suspicious findings on US only, BT was performed in the MLO view; otherwise, one of the two views in which the finding was least visible on DM was chosen for BT. This resulted in 6% CC and 94% MLO views of the total BT examinations. The principles have been described in more detail in an earlier study (9).

The BT prototype is based on a different amorphous selenium detector than the DM unit, optimized for very low exposures with rapid readout. It has a pixel size of  $85 \times 85 \mu\text{m}$  in full-resolution mode (DM:  $70 \times 70 \mu\text{m}$ ) (8). The BT images were acquired using the same tube voltage and the same anode/filter (W/Rh) combination as used for the DM images, determined by the automatic exposure control (AEC) of the DM unit. The entire BT scan, 25 projection images acquired over

an angular range of  $50^\circ$ , was performed using a tube loading twice that of a single DM image, resulting in approximately the same absorbed dose as a two-view mammography. One-millimeter-thick slices parallel to the detector plane were reconstructed using filtered backprojection (10).

US was performed on a dedicated unit (Acuson Sequoia; Siemens, Erlangen, Germany) by radiologists specialized in breast imaging. US measurements of the largest tumor extent were recorded on the static images on the diagnostic examination using built-in electronic calipers.

BT, DM, and US images were viewed on a Mammomareport workstation (Siemens, Erlangen, Germany) using two 5-megapixel flat-panel monitors (Dome C5i; Planar Systems Inc., Beaverton, Oreg., USA), calibrated according to the DICOM Grayscale Standard Display Function (11). The ambient light level was around 3 lux. During the size measurements, the ability to scroll, zoom, and alter the window level of the images was available.

### *Radiographic analysis*

One radiologist (S.Z.) measured the tumor size on BT and DM. Previous results were unknown to the observer, and the size measurements were done independently for each modality (BT and DM). Both DM views were displayed simultaneously, and the tumor size was measured on both using a calibrated built-in software tool (Synngo Mammomareport; Siemens, Erlangen, Germany). A second reading was performed (I.A.), but only to determine interobserver variation. The evaluation in this study was based on measurements of the first radiologist (S.Z.). The BT size measurement was performed in the slice with the largest tumor extension. The longest axis of a breast tumor was measured to the nearest millimeter using a distance measurement tool in the workstation software. Spicules of a stellate lesion were not included, but rather the nucleus of the tumor (12). In cases with suspicious calcifications only, the greatest extent of the microcalcifications was measured. Size measurements were only recorded for CC and MLO views; other views including magnification projections were excluded. Tumors were classified as not measurable in cases of architectural distortion without definable borders or in cases where the tumor was partially obscured by dense tissue.

Characteristics that hampered size determination were also noted, e.g., growth pattern of the tumor and breast density. Tumor type was classified as well-defined, diffuse borders, spiculated, or architectural distortion. Breast density was classified into three categories based on the American College of Radiology Breast Imaging Reporting and Data System (BI-RADS) (13), as follows: category 1 corresponding to BI-RADS 1 (fatty breast), category 2 corresponding to BI-RADS

2 and 3 (scattered fibroglandular densities or heterogeneously dense), and category 3 corresponding to BI-RADS 4 (dense breast tissue).

#### Pathologic analysis

The breast specimens were sent to the Department of Pathology where they were immediately examined by a pathologist specialized in breast pathology. The tumor, if any, was identified and cut sagittally into parallel slices, approximately 5 mm in thickness. The slice with the cut surface exhibiting the largest dimensions of the tumor was identified. By using a combination of palpation and inspection, the largest and the perpendicular diameters were measured to the nearest millimeter (14). The largest diameter was chosen as the tumor size.

Each slice of breast tissue was stretched over a paper towel, and the entire specimen was then immersed in 10% buffered formalin. After fixation for about 24 hours, blocks of tissue (approximately 4×6 cm in size) including the tumor and its surroundings were cut out from the tissue slices, dehydrated, and embedded in paraffin. Histological sections, approximately 4 µm in thickness, were cut from paraffin blocks, deparaffinized, and stained with hematoxylin-eosin. By using large-sized sections, the entire sagittal extension of most of the tumors (i.e., those less than 4×6 cm) could be included in one section. The largest dimension of the tumor exhibited in the histological section was identified and measured. In a minority of cases, the extensions of the tumor seen in the histological sections were found to be significantly greater than those that had been estimated on the gross specimens. This was usually the case when the tumor was less well delineated and its margins difficult to identify grossly, e.g., diffusely growing lobular carcinomas or spiculated carcinomas of tubular or ductal type. In such cases, the largest dimension of the tumor measured on the histological section was considered to constitute the tumor size, instead of the gross measure. In summary, tumor size

thus was considered equivalent to the largest sagittal extension regardless of whether this was derived from gross or histological measurements.

#### Statistical analysis

Scatter plots for each of the imaging measurements versus the pathology measurements and linear regression analysis were generated using the MedCalc program (version 9.6.4.0; MedCalc Software, Mariakerke, Belgium). Calculation of Pearson's *R* was done in order to compare different imaging measurement methods with the pathological size. Hypothesis tests for differences between correlations and proportions were done using paired *t* and  $\chi^2$  tests, respectively. The size differences in millimeters between imaging modality measurements and pathology measurements were plotted, following the approach of BLAND and ALTMAN (15). The measurements were considered concordant if they were within 2 mm. *P* values for comparative performance in size determination were calculated. Interobserver variations for BT and DM were compared using the McNemar test for discordant classifications and paired *t* test for size measurement comparison. Over- and underclassification of pathologic tumor staging (pTNM) based on clinical staging (TNM) size for the respective modalities was examined using the  $\chi^2$  test for comparison of proportions.

## Results

#### Types of tumor, visibility, and density

Of the 73 malignant breast tumors, 43 (59%) were invasive ductal cancers (IDC), 14 (19%) invasive lobular cancers (ILC), five (7%) tubular cancers, five (7%) ductal carcinoma in situ (DCIS), two (3%) intracystic papillary carcinoma, one (1%) IDC with DCIS, one (1%) mucinous carcinoma, one (1%) tubular cancer with DCIS, and one (1%) lobular carcinoma in situ (LCIS). The median pathologic tumor size was 15 mm (range 5–50 mm).

Table 1. Number of measurable tumors, by modality

	BT	DM (same view as BT)	DM (complementary view)	DM (two views)	US
Measurable	63	38*	39*	49*	60
Not measurable	5	11	10	6	3
Not visible	5	24*	22*	18*	10
Imaging error†	0	0	2	0	0
Total	73	73	73	73	73

BT: breast tomosynthesis; DM: digital mammography; US: ultrasound.

\*Statistical significance:  $P < 0.05$ , using  $\chi^2$  test for comparison of proportion to BT.

†Tumor was not captured in the image projection.



Significantly more tumors could be measured on BT (63, 86%) than on DM (49, 67%), whether we compared with one or two views, but only marginally more than on US (60, 82%) (Table 1, Fig. 1). Fewer tumors were not measurable on BT compared with the same DM view, although this difference was not statistically significant (Fig. 2). A significantly larger number of malignancies were not visible on DM compared with BT (24 and five, respectively). When combining the information from the two DM views, the number of measurable tumors increased to 49 and those not measurable and not visible decreased to six and 18, respectively. There was no significant difference in the estimation of the number of tumors classified as measurable by the initial and second observer for BT and DM (63 and 66 for BT, and 49 and 46 for DM, respectively) ( $P>0.05$ ).

In seven BT examinations, tumor size was measured on the basis of the extent of calcifications, compared with eight cases on DM. The remaining tumors were measured on the basis of the soft-tissue component.

BT was less sensitive to the density of the breast parenchyma compared with DM in terms of proportion of measurable tumors (Table 2). Accordingly, the greatest difference was seen in women with dense parenchyma, although statistical significance between BT and DM (2-views) was only observed for intermediate parenchyma and not for dense parenchyma, probably due to small sample size. US was slightly better than BT in dense breasts.

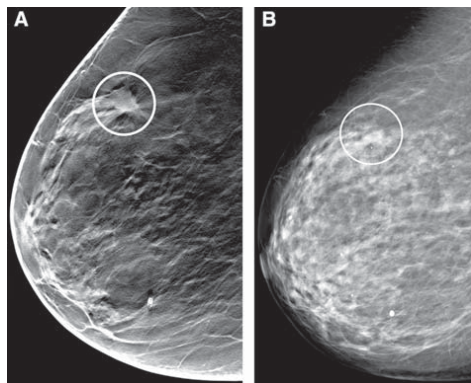


Fig. 1. A 67-year-old asymptomatic woman with a measurable tumor on breast tomosynthesis but not measurable on digital mammography. A. Tomosynthesis in the oblique view shows a well-defined spiculated tumor (circle) whose largest diameter was measured to be 12 mm. B. On the corresponding 2D view, an ill-defined area of increased density is seen (circle). On histopathology, a 15-mm invasive ductal carcinoma grade 3 was found.

#### Size agreement between respective imaging methods and pathology

BT had the highest proportion (62%) of concordant cases with pathology, although this was not statistically significant from DM and US (Table 3).

Fig. 3 shows the deviations in the size of the tumors determined with BT, DM, and US, respectively, compared with the size determined on pathology. Compared with pathology, tumor size was underestimated significantly ( $P<0.05$ ) for all imaging modalities, although this was least apparent for BT. Notable was that above a tumor size of around 20 mm, the deviation increased considerably for all imaging modalities. Of those above 20 mm, 38% (6/16) were growing multifocally or diffusely infiltrating and another 19% (3/16) represented tumors with extensive growth of DCIS, in some cases only partially calcified.

The correlation coefficients ( $R$ ) of BT, DM, and US to pathologic size were 0.86 (residual standard deviation (RSD) 4.1 mm), 0.71 (RSD 6.1 mm), and 0.85

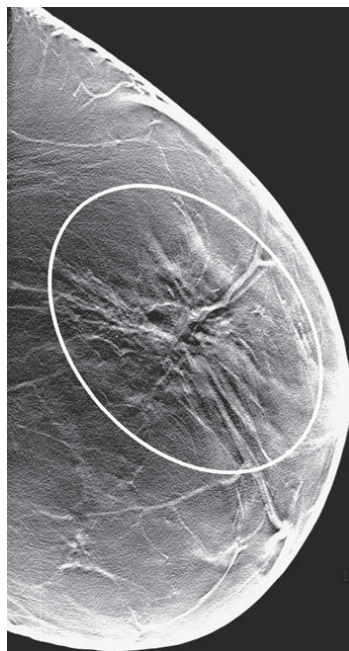


Fig. 2. A 49-year-old asymptomatic woman with a visible but not measurable tumor. Tomosynthesis (as well as 2D mammography) shows a large area of architectural distortion (circle) without a measurable tumor nucleus in the center. On histopathology, a 5-mm invasive ductal carcinoma grade 2 was found as well as a 22-mm ductal carcinoma in situ.

Table 2. Percentage of measurable tumors in relation to breast density classification

	Total <i>n</i>	BT %	DM (same view as BT) %	DM (complementary view) %	DM (two views) %	US %
1) fatty parenchyma	22	91	73	68	87	77
2) intermediate parenchyma	37	84	43*	54*	59*	81
3) dense parenchyma	14	86	43*	33†*	57	93

Abbreviations as in Table 1.

\*Statistical significance:  $P < 0.05$ , using  $\chi^2$  test for comparison of proportion to BT.

†Two breast cancers were not captured in the image projection and hence excluded.

(RSD 4.0 mm), respectively ( $P < 0.001$ ). The BT correlation coefficient was significantly higher compared with DM ( $P = 0.035$ ). US also had higher correlation coefficient compared with DM ( $P = 0.050$ ). In addition, a separate calculation of the correlation coefficient was done for tumors up to and including 20 mm. The correlation coefficients for BT ( $n = 50$ ), DM ( $n = 40$ ), and US ( $n = 47$ ) were 0.91 (RSD 2.1 mm), 0.74 (RSD 3.3 mm), and 0.83 (RSD 2.8 mm), respectively ( $P < 0.001$ ). There was no statistically significant difference in the size measurement of tumors by the initial and second observer for BT and DM ( $P > 0.05$ ).

Table 4 shows that 79% (58/73) were correctly staged on BT, compared with 52% (38/73) on DM ( $P = 0.0009$ ). US showed no major differences compared to BT ( $P > 0.05$ ).

## Discussion

Accurate measurement of tumor extent is important for tumor staging, which in turn is an important parameter for decisions on treatment. The main findings in this study were a better correlation between tumor size measured on BT and pathology compared with DM and pathology; furthermore, a significantly larger proportion of the tumors were measurable with BT. Accordingly, tumor staging was significantly more accurate on BT compared with DM.

The patient material was primarily selected for a feasibility study of tomosynthesis and has been described in more detail earlier (9). Basically, only cases that were difficult to interpret in 2D digital mammography were chosen for the study. BT was performed in the view where the cancer was least or not visible. In the majority of the cases, this was the oblique view. It can be argued that this principle of case selection could have introduced a bias in favor of BT. However, the aim of the study was to see whether the new technique could offer improved information compared with the existing standard digital mammography. The most expedient way to accomplish this goal in a limited series was to choose difficult cases. The impact of the superior accuracy of tumor measurement in BT in an unselected patient material or in a screening material remains to be demonstrated.

There are two important mechanisms explaining why a tumor is not seen or difficult to outline on 2D mammography: the anatomical noise (dense breast parenchyma) and the growth pattern of the tumor. For instance, some lobular invasive cancers grow in multiple small foci or even in single rows of cells, diffusely infiltrating the normal breast structures without forming an evident tumor on the mammogram. It appears from Fig. 3 that there was a better correlation between size measurements on imaging and pathology up to a tumor size of about 20 mm compared with larger tumors.

Table 3. Size agreement, by imaging modality and pathological size (*n*, (%))

	BT	DM (same view as BT)	DM (complementary view)	DM (two views)	US
Median size	13 mm	12 mm	12 mm	12 mm	12 mm
Range	3–44 mm	4–50 mm	5–54 mm	5–54 mm	5–38 mm
Overestimation	8 (13)	5 (13)	4 (10)	6 (12)	5 (8)
No size discrepancy	39 (62)	19 (50)	22 (56)	25 (51)	34 (57)
Underestimation	16 (25)	14 (37)	13 (33)	18 (37)	21 (35)
Total	63 (100)	38 (100)	39 (100)	49 (100)	60 (100)

Abbreviations as in Table 1.

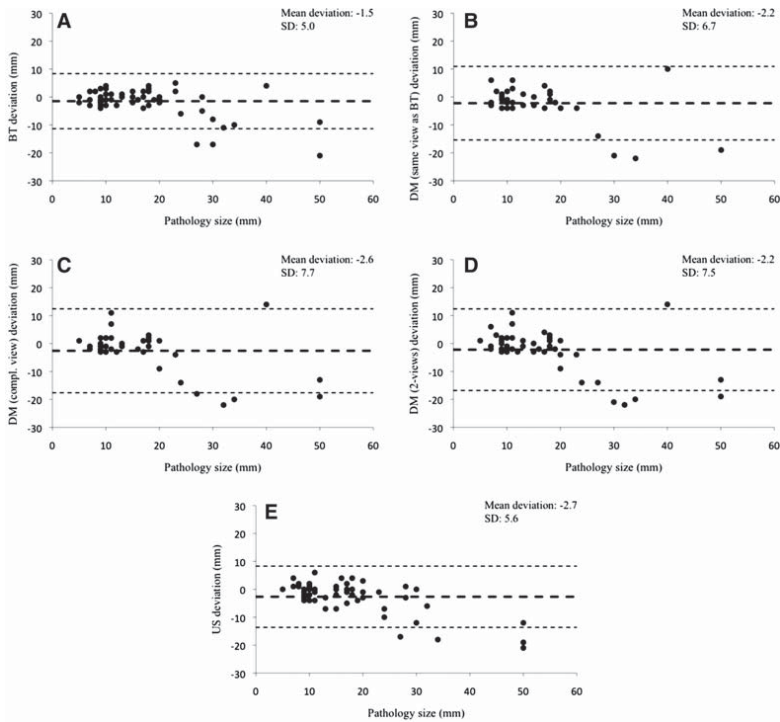


Fig. 3. Deviation of breast tomosynthesis (BT) measured breast cancer sizes ( $n=63$ ) (A), digital mammography (DM) (same view as BT) measured sizes ( $n=38$ ) (B), DM (complementary view) measured sizes ( $n=39$ ) (C), DM (two views) measured sizes ( $n=49$ ) (D), and ultrasonography (US) measured sizes ( $n=60$ ) (E) from pathology sizes. The mean of the deviation (thick dashed lines) and  $\pm 1.96$  SD limits (thin dashed lines) are illustrated on each graph.

The anatomical noise may be the main factor obscuring smaller tumors—a problem that is significantly reduced by tomosynthesis—while the growth pattern seems to be the main problem with the larger tumors—a problem that is only marginally reduced by BT. The problematic growth patterns included multifocal or diffusely infiltrating lobular invasive carcinoma, architectural distortion without evident tumor mass, and grade 3 tumors with nonspecific characteristics making them difficult to differentiate from normal glandular tissue. The larger tumors were usually palpable and chosen for BT due to an apparent discrepancy between the physical findings and the findings on DM.

A limitation of the current study was that only one breast was examined with BT; thus, nonspecific asymmetrical densities were not readily appreciated. Another source of major deviation was the presence of extensive calcification representing DCIS but also containing invasive components. The true extent of such calcifications may be difficult to assess on pathology. Due to their

small size and often scattered distribution they may not be captured by the thin histological sections used for microscopy. However, on BT and DM, the calcified component can be measured quite accurately and thus falsely recorded as overestimated on BT and DM. The solid components, which may represent invasive or noninvasive disease, were more easily identified and measured on US.

Pathologic tumor assessment of a resected breast tumor may involve another uncertainty. The plane of slicing that was chosen may not have captured the maximum tumor extent, and, because of the slicing technique, it may be hard to measure the tumor extent in the orthogonal plane.

Another explanation for underestimation of tumor size on BT and DM is that the approximation of the tumor outline in spiculated cancers was too conservative. Most previous studies of 2D mammography also showed an underestimation, which was also true for US (16–20). The problem relates to the fact that it is not

Table 4. Agreement between staging on imaging and pathology of measurable tumors

TNM stage	pTNM stage		Total staged correctly
	T1	T2	
BT (n=63)	T1	48	58/73 (79%)
	T2	2	
DM (n=49)	T1	36	38/73 (52%)*
	T2	4	
	T3	0	
US (n=60)	T1	45	53/73 (73%)
	T2	2	

Abbreviations as in Table 1.

T1 includes tumors  $\leq 20$  mm in diameter; T2 includes tumors  $>20$  mm and  $\leq 50$  mm; and T3 includes tumors  $>50$  mm.

\*Statistical significance:  $P < 0.05$ , using  $\chi^2$  test for comparison of proportion to BT.

possible to determine how much of a spicule is tumor growth and how much is reactive fibrosis. We measured the nucleus of a tumor, not including the spiculated extension. Most often on US, only the hypoechoic part of the lesion is included in the measurement and not the hyperechoic zone representing the spiculated periphery (21).

More cases of ILCs were detected and size measurement was more accurate with BT than on DM. This was evident for those tumors classified as not measurable on DM (Table 1), which were tumors that predominantly presented as an area architectural distortion, typical for ILCs, or are partly hidden by dense normal tissue. This is also apparent from Table 2, where it can be seen that a substantially larger percentage of cancers in women with dense breasts can be measured with BT compared to DM. Also, in no case could a tumor be measured on DM when it was not measurable on BT.

No study of the accuracy of BT in assessment of breast cancer size is known to the authors. Our DM and US correlation results are similar to those previously published (7, 16–20, 22, 23). Four out of six studies found ultrasonography to be a more reliable predictor than mammography. Our results indicate a slightly higher correlation between US and pathology compared to DM (two views) and pathology ( $P=0.050$ ). In addition, a greater proportion, although not statistically significant ( $P=0.057$ ), could be detected and measured with US compared to DM (two views).

That BT is better at predicting pathologic tumor size than DM is reasonable, as the anatomic background is an important limiting factor in 2D mammography (24). The disturbance effect of the anatomic background is substantially reduced in BT. Accordingly, correlation with pathology was higher with BT than with DM (two views) in the current study ( $P=0.035$ ).

In conclusion, our previous study indicated that BT might play an important role in the detection of breast cancer (9). The current study suggests that BT may also be superior to 2D mammography in the preoperative staging of breast cancer.

**Declaration of interest:** The authors report no conflicts of interest. The authors alone are responsible for the content and writing of the paper.

## References

- van Dongen JA, Bartelink H, Fentiman IS, Lerut T, Mignolet F, Olthuis G, et al. Factors influencing local relapse and survival and results of salvage treatment after breast-conserving therapy in operable breast cancer: EORTC trial 10801, breast conservation compared with mastectomy in TNM stage I and II breast cancer. *Eur J Cancer* 1992;28:801–5.
- Kinne DW. Staging and follow-up of breast cancer patients. *Cancer* 1991;67:1196–8.
- Carter CL, Allen C, Henson DE. Relation of tumor size, lymph node status, and survival in 24,740 breast cancer cases. *Cancer* 1989;63:181–7.
- Koscielny S, Tubiana M, Lê MG, Valleron AJ, Mouriessse H, Contesso G, et al. Breast cancer: relationship between the size of the primary tumour and the probability of metastatic dissemination. *Br J Cancer* 1984;49:709–15.
- Bonadonna G, Veronesi U, Brambilla C, Ferrari L, Luini A, Greco M, et al. Primary chemotherapy to avoid mastectomy in tumors with diameters of three centimeters or more. *J Natl Cancer Inst* 1990;82:1539–45.
- Jacquillat C, Weil M, Baillet F, Borel C, Auclerc G, de Maubanc MA, et al. Results of neoadjuvant chemotherapy and radiation therapy in the breast-conserving treatment of 250 patients with all stages of infiltrative breast cancer. *Cancer* 1990;66:119–29.
- Dummin LJ, Cox M, Plant L. Prediction of breast tumor size by mammography and sonography—a breast screen experience. *Breast* 2007;16:38–46.
- Bissonnette M, Hansroul M, Masson E, Savard S, Cadieux S, Warmoes P, et al. Digital breast tomosynthesis using an amorphous selenium flat panel detector. *Proc SPIE* 2005;5745:529–40.
- Andersson I, Ikeda DM, Zackrisson S, Ruschin M, Svahn T, Timberg P, et al. Breast tomosynthesis and digital mammography: a comparison of breast cancer visibility and BIRADS classification in a population of cancers with subtle mammographic findings. *Eur Radiol* 2008;18:2817–25.
- Mertelmeier T, Orman J, Haerer W, Dudam MK. Optimizing filtered backprojection reconstruction for a breast tomosynthesis device. *Proc SPIE* 2006;6142:131–42.
- NEMA standards publications PS 3.14. Digital imaging and communications in medicine (DICOM), part 14: grayscale standard display function. Washington, DC: National Electrical Manufacturers' Association; 1998.
- Flanagan FL, McDermott MB, Barton PT, Pilgram TK, Dehdashti F, Wick MR, et al. Invasive breast cancer: mammographic measurement. *Radiology* 1996;199:819–23.

13. American College of Radiology. Breast imaging reporting and data system (BI-RADS). 2nd edition. Reston, VA: American College of Radiology; 1995.
14. Elston CW, Ellis IO. Systemic pathology. In: Elston CW, Ellis IO, editors. The breast, 3rd edition, vol. 13. Edinburgh: Churchill Livingstone; 1998. p. 385–434.
15. Bland JM, Altman DG. Statistical methods for assessing agreement between two methods of clinical measurement. *Lancet* 1986;1:307–10.
16. Segara D, Krop IE, Garber JE, Winer E, Harris L, Bellon JR, et al. Does MRI predict pathologic tumor response in women with breast cancer undergoing preoperative chemotherapy? *J Surg Oncol* 2007;96:474–80.
17. Pritt B, Ashikaga T, Oppenheimer RG, Weaver DL. Influence of breast cancer histology on the relationship between ultrasound and pathology tumor size measurements. *Mod Pathol* 2004;17:905–10.
18. Bosch AM, Kessels AG, Beets GL, Rupa JD, Koster D, van Engelshoven JM, et al. Preoperative estimation of the pathological breast tumour size by physical examination, mammography and ultrasound: a prospective study on 105 invasive tumours. *Eur J Radiol* 2003;48:285–92.
19. Hieken TJ, Harrison J, Herreros J, Velasco JM. Correlating sonography, mammography, and pathology in the assessment of breast cancer size. *Am J Surg* 2001;182:351–4.
20. Pierie JPEN, Perre CI, Levert LM, de Hooge P. Clinical assessment, mammography and ultrasonography as methods of measuring the size of breast cancer: a comparison. *Breast* 1998;7:247–50.
21. Teuber J. Echomammography: technique and results. In: Friedrich M, Sickles EA, editors. Radiological diagnosis of breast diseases. Berlin: Springer-Verlag; 1997. p. 181–220.
22. Davis PL, Staiger MJ, Harris KB, Ganott MA, Klementaviciene J, McCarty KS Jr, et al. Breast cancer measurements with magnetic resonance imaging, ultrasonography, and mammography. *Breast Cancer Res Treat* 1996;37:1–9.
23. Fornage BD, Toubas O, Morel M. Clinical, mammographic, and sonographic determination of preoperative breast cancer size. *Cancer* 1987;60:765–71.
24. Bochud FO, Valley JF, Verdun FR, Hessler C, Schnyder P. Estimation of the noisy component of anatomical backgrounds. *Med Phys* 1999;26:1365–70.

# Paper II



## THE EFFECT OF REDUCED BREAST COMPRESSION IN BREAST TOMOSYNTHESIS: HUMAN OBSERVER STUDY USING CLINICAL CASES

D. Förnvik<sup>1,\*</sup>, I. Andersson<sup>2</sup>, T. Svahn<sup>1</sup>, P. Timberg<sup>1</sup>, S. Zackrisson<sup>2</sup> and A. Tingberg<sup>1</sup>

<sup>1</sup>Department of Medical Radiation Physics, Malmö University Hospital, SE-205 02, Malmö, Sweden

<sup>2</sup>Diagnostic Centre of Imaging and Functional Medicine, Malmö University Hospital, SE-205 02, Malmö, Sweden

\*Corresponding author: daniel.fornvik@med.lu.se

The aim of this study was to investigate whether the compression force used with conventional mammography can be reduced with breast tomosynthesis (BT), without adversely affecting the visualisation of normal and pathological structures. Forty-five women were examined with BT using full (same as for 2D mammography) and half compression force. Both examinations were performed with the same acquisition parameters. A total of 103 paired structure images were evaluated according to specified image quality criteria. Three experienced radiologists participated in the study. They had to make a forced choice, i.e. choose the image they felt best fulfilled the image quality criteria. The results showed no evident difference in the image quality, indicating that BT may be performed with substantially less compression force compared with 2D mammography. A majority of the examined women felt that half compression was more comfortable than full compression.

### INTRODUCTION

Compression of the breast is used during conventional mammography for several reasons: the required radiation dose and scatter will be lower improving the image quality and the structures of the breast will be better separated in the imaged 2D plane. For this reason, the breast is compressed as much as reasonably achievable to a level just below the patient's individual pain threshold or up to the maximum setting of the machine (generally 200 N). Since breast tomosynthesis (BT) is a 3D technique, reduced compression could be beneficial due to better separation of the tissue structures in the depth direction. Saunders *et al.*<sup>(1)</sup> recently investigated reduced breast compression for BT using a Monte Carlo program and a voxelised anthropomorphic breast phantom, concluding that for constant glandular dose a 12.5 % breast compression reduction would have minimal effect on radiologists' performance. Moreover, they found that for a fixed tube charge (as used in the present study) the radiation dose was actually reduced for the reduced compression as compared with the standard compression. A further advantage of reduced compression is improved patient acceptance of mammography and therefore higher attendance in screening programmes<sup>(2, 3)</sup>.

The purpose of this study was to investigate whether the compression force used with conventional mammography can be reduced for BT using clinical cases, without adversely affecting the visualisation of normal and pathological structures.

### MATERIALS AND METHODS

#### Patient population

Symptomatic women referred for mammography were invited to undergo BT examination. This resulted in 45 women (mean 65 y, range 49–84 y) examined with BT using full standard compression force (mean 113 N, range 60–170 N) as well as half compression force (mean 58 N, range 30–90 N). The Regional Ethical Review Board at Lund University (Dnr 319/2008) and the local Radiation Safety Committee approved the study. Informed consent was obtained and all examinations were voluntary.

#### Image acquisition

A BT prototype unit adapted from the Mammomat Novation<sup>DR</sup> (Siemens, Erlangen, Germany) was used<sup>(4)</sup>. Twenty-five projection images were acquired over an angular range of 40 degrees, using the same tube voltage and the same anode/filter (W/Rh) combination as used for the preceding digital mammography (DM) examination and as determined by the automatic exposure control device of the DM unit. The mean absorbed dose for DM of a standard breast<sup>(5)</sup> was 1.0 mGy. The tube loading used for each BT examination was twice that of a single DM image, resulting in approximately the same absorbed dose as a two-view mammography. The BT unit features a direct converter amorphous selenium flat panel detector and 1-mm thick slices parallel to the detector plane were reconstructed using filtered backprojection<sup>(6)</sup>. An 18 cm × 24 cm compression



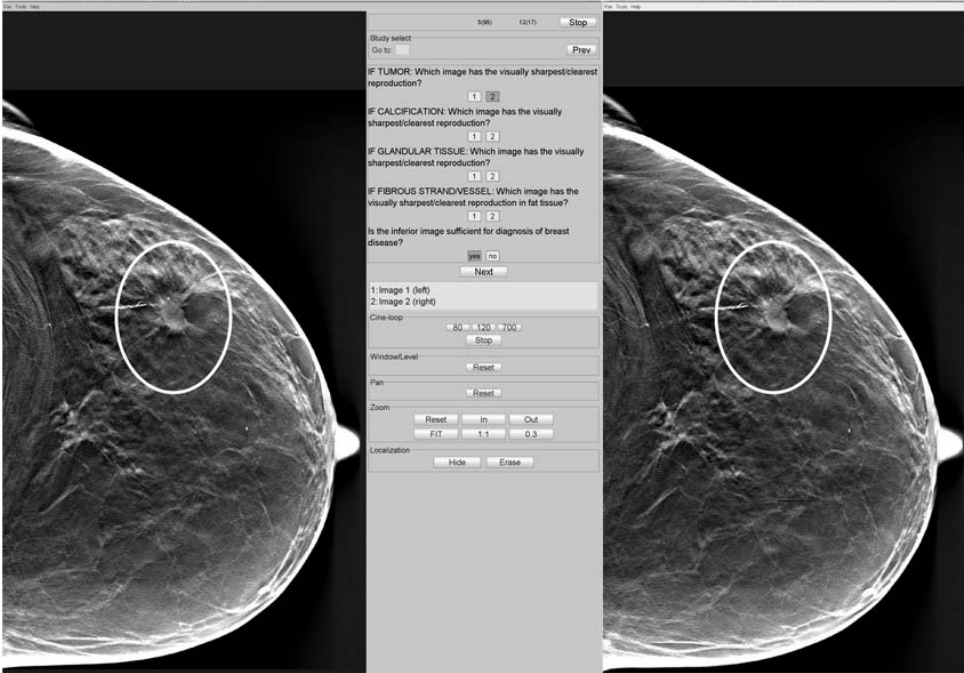


Figure 1. The graphical user interface, ViewDEX. Example of an image pair of a tumour obtained with half compression (left) and full compression (right).

paddle with a high edge and no flex was used throughout the study. The breast compression force and breast thickness were calibrated using ordinary routines and verified using an electronic precision scale (EKS, Wittisheim, France) and polymethylmethacrylate (PMMA) slabs of different thicknesses (force range 40–200 N, PMMA thickness range 19–86 mm, PMMA area 150 mm × 150 mm).

The BT examination was initiated by acquiring an image set under the standard compression of the breast, i.e. the same as used for the preceding conventional mammography examination, followed by another set under half compression without repositioning the breast. Except for the compression level, no other parameters (e.g. kVp, mA s) were altered between the two acquisitions. The compressed breast thickness was recorded. A questionnaire was used to investigate any difference (worse, equal, better) in compression discomfort between the two procedures.

#### Evaluation of clinical image quality

A total of 103 paired structures were extracted from the image sets generated from 46 breasts, averaging 2.2 structures per breast. All slices of a BT image set

containing the structure were selected as the structure volume. Based on the images' histogram of the structure region (the tomographic slice showing the structure in focus), suitable window/level settings were quantitatively adjusted using the ImageJ software<sup>(7)</sup> and used for all slices belonging to each structure volume. The paired structure volumes were displayed on a two five mega-pixel flat panel monitors (Dome C5i, Planar Systems Inc., Beaverton, Oreg., USA), calibrated according to the DICOM Grayscale Standard Display Function<sup>(8)</sup>. The ambient light level was around 3 lux. The structure volumes were displayed in random order, yielding approximately 50 % of the full compression structure volumes and 50 % of the half compression structure volumes on each screen. A graphical user interface, ViewDEX<sup>(9)</sup>, developed for observer performance studies, was used to display the paired structure volumes and to record the observer's response (Figure 1). Three radiologists specialised in mammography with at least 2-y experience in BT participated in the study. The structure volumes were evaluated using a forced choice method based on revised image quality criteria of the European Guidelines (Table 1)<sup>(10, 11)</sup>. The image quality

**Table 1.** The revised<sup>(10, 11)</sup> image quality criteria used in the present study.

1. Image criteria related to detector performance, exposure parameters and patient movement	
1.1. Tumour/benign lesion	Visually sharp/clear reproduction of tumour/benign lesion
1.2. Glandular tissue	Visually sharp/clear reproduction of glandular tissue
1.3. Fibrous strands	Visually sharp/clear reproduction of fibrous strands in fat tissue
1.4. Calcification	Visually sharp/clear reproduction of calcification
2. Overview judgement related to either screening or diagnostic procedures	
2.1. Is image quality sufficient for diagnosis of breast disease?	

criteria were shown and explained in the ViewDEX task panel together with score boxes. The radiologists had to score one of the paired structure volumes as superior before going to the next pair of structures. The structures were enclosed by circular regions of interest (initial and final slice) in the breast images and the radiologists were told to only rate the marked structures. There was an optional zoom and cine-loop function. No time limit was imposed on the observers' evaluation. In addition, an overview of image quality criterion (see 2.1 in Table 1) was evaluated for the inferior structure volume. The rationale behind this criterion was to rate the overall diagnostic quality of the image from a practical standpoint.

### Statistical analysis

The proportion of the cases for which full compression level was rated as superior was constructed for the different image quality criteria. The null hypothesis (NH) was defined as no statistically significant difference ( $\alpha = 0.05$ ) between 0.5 and the proportions. Ninety-five per cent confidence intervals (CI) were calculated for proportions according to the binomial distribution. Assuming that averages of proportions follow approximately a normal distribution, it was possible to construct 95 % CI of the averages by the use of variance for multiple variables including their covariance. An image criteria score (ICS) was calculated for the overview image quality criterion<sup>(12)</sup>. If an observer considered the criterion to be fulfilled, a score of 1 resulted, otherwise 0. The sum of scores was divided with the number of paired structure volumes that were evaluated. Inter-observer agreement was determined using Kappa statistics<sup>(13)</sup>. A Kappa score of  $<0.20$  is considered 'poor' strength of agreement,  $0.21-0.40$  is 'fair' strength of agreement,  $0.41-0.6$  is 'moderate' strength of agreement,  $0.61-0.80$  is 'good' strength of agreement and  $>0.80$  is 'very good' strength of agreement.

### RESULTS

The applied compression force and the resulting breast thickness are presented in Table 2. The reduced compression force resulted in a 5.8 mm

**Table 2.** Amount of applied compression force and resulting breast thickness as indicated by the BT unit.

	Mean	Range	Standard deviation
Compression force (N)			
Full	113	60-170	28
Half	58	30-90	14
Thickness (mm)			
Full	45.4	23-83	11.4
Half	51.3	28-92	11.7

average breast thickness increase as indicated by the BT unit. The reduced compression was usually just enough to keep the breast immobilised.

Figure 2 summarises the scores of the three radiologists and their averages for the different structures. Ideally, if no difference in the image quality were found between full and half compression, the bars would equal 0.5. If full compression were chosen as superior for all structures the bar would equal 1, and if the opposite were true (half compression was chosen for all structures) the bar would equal 0. All 95 % CIs, except the average of criteria 1.2-1.3, include the value 0.5, although there appears to be a tendency towards higher image quality for full compression for all types of structures. The reason for adding criteria 1.2 and 1.3 together was the small number of cases in these groups.

The results of the overview image quality criterion with absolute grading are presented in Table 3. No difference in the small proportion of cases resulting in images judged as providing non-sufficient quality for diagnosis of breast disease was observed between full and half compression. There was no information regarding whether the superior structure volume also failed to fulfill the criterion.

Inter-observer agreement results are presented in Table 4. The variation ranged between 'poor' and 'fair' strength of agreement, demonstrating that there was low correlation between the radiologists' scores; hence, randomness dominated the scoring.

All of the examined women felt that half compression was more comfortable (83 %) or equal to (17 %) standard compression.

THE EFFECT OF REDUCED BREAST COMPRESSION IN BREAST TOMOSYNTHESIS

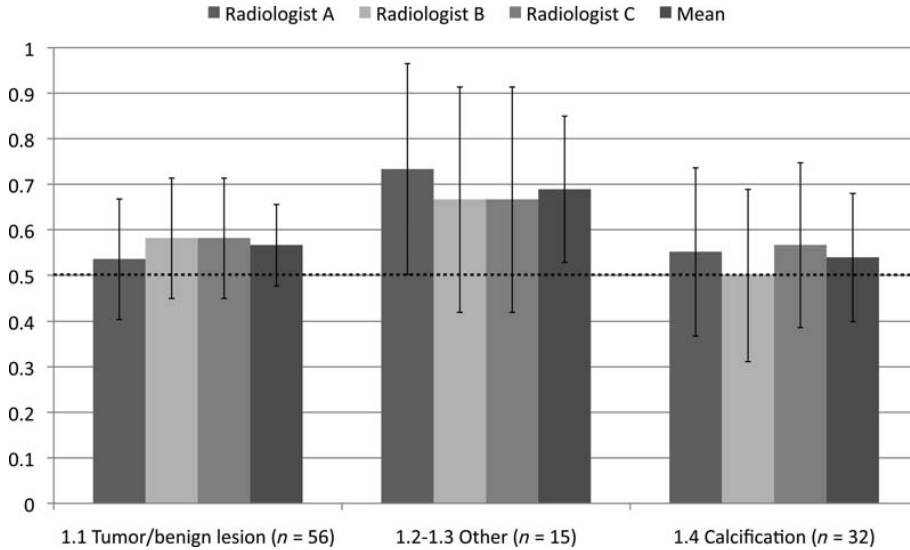


Figure 2. The proportion of the cases for which full compression level was rated as superior per type of structure and radiologist and their mean. Equal proportions of full and half compression correspond to 0.5. Category labelled ‘Other’ refer to image quality criteria 1.2 glandular tissue and 1.3 fibrous strands.

Table 3. ICS for the three observers and the number of inferior structure volumes that failed to meet the overview criterion 2.1.

	ICS (95 % CI)	Number of full compression that failed	Number of half compression that failed	Total
Radiologist A	0.92 (0.88–0.98)	4	4	8
Radiologist B	0.95 (0.91–0.99)	2	3	5
Radiologist C	0.93 (0.88–0.98)	4	3	7

DISCUSSION

One of the main problems with mammography is the pain caused by compressing the breast. This is of such a magnitude that some women refrain from the examination. In some studies it is concluded that beyond a certain compression force level further compression only causes pain without producing any further decrease of breast thickness<sup>(14, 15)</sup>. The results suggest that this problem can be substantially reduced with BT without significantly compromising the diagnostic quality of the image. This reasoning is supported by taking into account the increased patient comfort, the small difference in image quality between full and half compression and that the image acquisition was not optimised for the half compression. The lower compression (‘half compression’) that was used was usually just enough to keep the breast in position. A visual assessment of

Table 4. Inter-observer agreement between the radiologists.

Radiologists	Kappa value	Standard error
A–B	0.20	0.10
B–C	0.34	0.10
A–C	0.20	0.10

the paired structure volumes for adequate tissue inclusion showed no differences neither regarding tissue inclusion nor positioning.

No study of the effect of reduced breast compression in BT using clinical cases is known to the authors. The results are similar to those by Thilander Klang<sup>(14)</sup> for conventional 2D mammography. In a group of 108 women for whom the influence of breast compression force on image

quality and corresponding discomfort were studied, no significant difference was found in the image quality. On average the difference between the two compression forces was about 40 %. Eighty per cent of the women experienced improved comfort and 17 % experienced no difference with the lower compression force.

It is important that reduced breast compression does not result in an insufficient image quality for proper diagnostic interpretation. A human observer study evaluates the quality of the whole imaging chain and gives a measure of the clinical image quality. The European Commission has established guidelines on quality criteria for radiographic examinations to set the quality standard (not yet established for BT) and minimise reader subjectivity. An outcome of the Radiation Protection Programme of the Commission of the European Communities (CEC) trials in 1987 and 1991 was that these criteria could be used in a reproducible way and that they represented an improvement in the evaluation of image quality compared to pure subjective judgement<sup>(16, 17)</sup>. This was the main reason why the European Guidelines were used to investigate the image quality of full and half compression force images.

When conducting a human observer study based on visibility of anatomical structures usually a visual grading<sup>(18)</sup> technique is used. The set-up in this study was to compare the visibility of a defined structure in images obtained with full and half compression. The visibility of a structure is often graded on a five-level ordinal confidence scale: clearly inferior to (-2), slightly inferior to (-1), equal to (0), slightly better than (+1) and clearly better than (+2) the structure in the reference image. As a pilot study showed that the five-level scale was superfluous yielding mostly 'equal to (0)', the evaluation method was changed to a forced choice set-up. This particular problem has also been investigated by Gur *et al.*<sup>(19)</sup> showing that a forced choice method has higher ability to detect small differences in the perceived image quality than a five-level ordinal scale, given a side-by-side review.

Although the limited number of cases included in this study could be the reason for the lack of significant differences rather than a valid NH, the results indicate that any actual differences are probably so small that they would not have any substantial impact on the diagnostic performance. The half compression force images fulfilled the diagnostic requirements presented as image criteria for a breast radiograph to produce an image of standard quality. All, but a very few structures, were clearly visible on both full and half compression, meaning the image quality difference was never large enough to jeopardise the diagnostic evaluation. The low inter-observer agreement between the radiologists suggests

that the difference in image quality between full and half compression was small, yielding random scores.

The indicated compression force and thickness values were recorded in a fixed point in the compression paddle mount. The distribution of compression force and thickness over the rest of the breast was not known. The majority of the breasts were examined in the mediolateral oblique projection, which included the pectoral muscle, which is often the thickest part of the imaged volume. In this region, a slightly higher noise level was seen in the half compression images; however, this area is of minor importance from a diagnostic point of view. It is possible that the main part of the breast did not experience the same degree of reduction in thickness, which in turn might have influenced the difference in the image quality. It is planned to conduct a study in the near future that will investigate the compression force distribution over the breast.

Breast thickness is one of the most important parameters in the selection of an anode/filter and tube voltage combination. The tube voltage was not changed between the two compression acquisitions, thus much optimisation is possible to improve the image quality for the half compression images.

In conclusion, the results suggest that BT may be performed with substantially less compression force compared with 2D mammography without significantly compromising the diagnostic quality of the image.

## FUNDING

The author would like to thank Region Skåne (regionalt forskningsstöd), Stiftelsen för cancerforskning vid Onkologiska kliniken vid Universitetssjukhuset MAS, Allmänna Sjukhusets i Malmö stiftelse för bekämpande av cancer, and Siemens Healthcare for financial support.

## REFERENCES

1. Saunders, R. S. Jr., Samei, E., Lo, J. Y. and Baker, J. A. *Can compression be reduced for breast tomosynthesis? Monte carlo study on mass and microcalcification conspicuity in tomosynthesis.* *Radiology* **251**, 673–682 (2009).
2. Aro, A. R., de Koning, H. J., Absetz, P. and Schreck, M. *Psychosocial predictors of first attendance for organised mammography screening.* *J. Med. Screen.* **6**, 82–88 (1999).
3. Miller, D., Livingstone, V. and Herbison, P. *Interventions for relieving the pain and discomfort of screening mammography.* *Cochrane Database Syst. Rev.* CD002942 (2008).
4. Bissonnette, M. *et al.* *Digital breast tomosynthesis using an amorphous selenium flat panel detector.* *Proc. SPIE* **5745**, 529–540 (2005).

THE EFFECT OF REDUCED BREAST COMPRESSION IN BREAST TOMOSYNTHESIS

5. Zoetelief, J., Fitzgerald, M., Leitz, W. and Säbel, M. *European protocol on dosimetry in mammography*. Publication EUR 16263 EN (Brussels, Belgium: European Commission) (1996).
6. Mertelmeier, T., Orman, J., Haerer, W. and Dudam, M. K. *Optimizing filtered backprojection reconstruction for a breast tomosynthesis device*. Proc. SPIE **6142**, 131–142 (2006).
7. Rasband, W. S. *ImageJ*, U. S. National Institutes of Health (Bethesda, Maryland, USA). <http://rsb.info.nih.gov/ij/>, 1997–2009.
8. *NEMA Standards Publications PS 3.14. Digital Imaging and Communications in Medicine (DICOM), Part 14: Grayscale Standard Display Function*. National Electrical Manufacturers Association, 2101 L Street, NW, Washington, D.C., 20037 (1998).
9. Börjesson, S. *et al.* *A software tool for increased efficiency in observer performance studies in radiology*. Radiat. Prot. Dosim. **114**, 45–52 (2005).
10. Grahn, A. *et al.* *Clinical evaluation of a new set of image quality criteria for mammography*. Radiat. Prot. Dosim. **114**, 389–394 (2005).
11. Hemdal, B. *et al.* *Can the average glandular dose in routine digital mammography screening be reduced? A pilot study using revised image quality criteria*. Radiat. Prot. Dosim. **114**, 383–388 (2005).
12. Tingberg, A. *Quantifying the quality of medical X-ray images. An evaluation based on normal anatomy for lumbar spine and chest radiography*. Thesis, Lund University, Malmö (2000).
13. Altman, D. G. *Practical Statistics for Medical Research* (London: Chapman and Hall) (1991).
14. Thilander Klang, A. *Diagnostic quality and absorbed dose in mammography: Influence of X-ray spectra and breast anatomy*. Thesis, University of Göteborg, Göteborg (1997).
15. Poulos, A., McLean, D., Rickard, M. and Heard, R. *Breast compression in mammography: how much is enough?* Australas. Radiol. **47**, 121–126 (2003).
16. European Commission. *CEC quality criteria for diagnostic radiographic images and patient exposure trial*. EUR 12952, Brussels (1990).
17. European Commission. *European guidelines on quality criteria for diagnostic radiographic images*. EUR 16260, Brussels (1996).
18. Månsson, L. G. *Evaluation of radiographic procedures. Investigations related to chest imaging*. Thesis, University of Göteborg, Göteborg (1994).
19. Gur, D., Rubin, D. A., Kart, B. H., Peterson, A. M., Fuhrman, C. R., Rockette, H. E. and King, J. L. *Forced choice and ordinal discrete rating assessment of image quality: a comparison*. J. Digit. Imaging. **10**, 103–107 (1997).

# Paper III



## Breast compression in mammography: pressure distribution patterns

Magnus Dustler<sup>1</sup>, Ingvar Andersson<sup>2</sup>, Håkan Brorson<sup>3</sup>, Patrik Fröjd<sup>1</sup>, Sören Mattsson<sup>1</sup>, Anders Tingberg<sup>1</sup>, Sophia Zackrisson<sup>2</sup> and Daniel Föörnvik<sup>1</sup>

<sup>1</sup>Medical Radiation Physics; <sup>2</sup>Diagnostic Centre of Imaging and Functional Medicine; <sup>3</sup>Plastic and Reconstructive Surgery, Department of Clinical Sciences Malmö, Lund University, Skåne University Hospital, Malmö, Sweden  
Correspondence to: Magnus Dustler. Email: Magnus.Dustler@med.lu.se.

### Abstract

**Background:** Breast compression is important in mammography in order to improve image quality, better separate tissue components, and reduce absorbed dose to the breast. In this study we use a method to measure and visualize the distribution of pressure over a compressed breast in mammography.

**Purpose:** To measure and describe the pressure distribution over the breast as a result of applied breast compression in mammography.

**Material and Methods:** One hundred and three women aged 40.7–74.3 years (median, 48.9 years) invited for mammographic screening consented to take part in this study. They were subjected to two additional breast compressions of the left breast (standard force and approximately 50% reduction). Pressure images of the compressed breast were obtained using force sensing resistor (FSR) sensors placed underneath the compression plate. Subjects rated their experience of pain on a visual analogue scale (VAS).

**Results:** Four pressure patterns were identified, fitting 81 of the 103 breasts, which were grouped accordingly. The remaining 22 breasts were found to correspond to a combination of any two patterns. Two groups (43 breasts) showed pressure mainly over the juxtathoracic part of the breast, had significantly greater breast thickness ( $P = 0.003$ ) and had a lower mean pressure over dense tissue ( $P < 0.0001$ ) than those with more evenly distributed pressure. Reducing compression force increased average breast thickness by 1.8 mm ( $P < 0.0001$ ).

**Conclusion:** The distribution of pressure differed greatly between breasts. In a large proportion of breasts the compression plate did not provide optimal compression of the breast, the compression force being absorbed in juxtathoracic structures.

**Keywords:** Breast, mammography, adults, technology assessment

Submitted April 2, 2012; accepted for publication July 13, 2012

Mammography is the established gold standard in breast cancer screening (1, 2). Breast compression is used to immobilize the breast, separate superimposed tissue components, and reduce scattered radiation, both reducing radiation absorbed in glandular tissue and facilitating image interpretation (3). A negative aspect of compression is pain and, as a consequence, lower acceptance of clinical mammography and even more importantly lower attendance in screening programs (4, 5). The European Commission recommend that the breast is compressed using a level of force just below the subject's pain threshold or to the maximum setting of the machine, not to exceed 200 N (6). These common guidelines have been questioned for

not taking into account the actual degree by which breast thickness is reduced (7).

Breast tissue is non-linearly elastic, fibroglandular tissue more so than fat, showing an exponential decrease in the rate of thickness reduction as a result of increasing pressure (8). Föörnvik *et al.* (9) showed that reducing mean compression force in breast tomosynthesis (BT), using compression procedures no different from those in conventional mammography, from 113 N to 58 N increased mean thickness by 5.8 mm, from 45.4 mm to 51.3 mm. No significant reduction in clinical quality of the images was found. Similar results have been reported from screen film mammography where a change in compression force from



189 N to 116 N was investigated (10). No significant reduction of image quality was found despite a mean breast thickness increase of 3.6 mm.

To the authors' knowledge, no study has investigated how pressure (force per unit area,  $[N/m^2] = [Pa]$ ) is distributed over the breast as the result of applied compression force *in vivo*, though it has been investigated using phantoms (11). Software models simulating compression of the breast (12–15) have been described, but without data on pressure distribution. None of these are based on *in-vivo* mechanical tissue properties. Models based on MRI or CT data are further limited by describing one specific breast, which cannot represent the entire population (1). Pressure in a single point has been measured *in vivo* but due to experimental design gave no more information than force measurements (16). Measuring pressure distribution over the breast surface could provide a better understanding of internal pressure distribution. For the current study this was accomplished using thin, flexible I-Scan (Tekscan Inc., South Boston, MA, USA) force sensing resistor (FSR) pressure sensors.

We hypothesized that the pectoral muscle is firmer than breast tissue, and therefore would be subject to proportionally greater pressure, preventing optimal compression of the dense parenchyma that has the greatest potential for masking relevant lesions. The aim of this study was to describe the pressure distribution over the breast as a result of applied breast compression. We also examined compressed breast thickness and experienced pain and correlated these parameters with the pressure distribution.

## Material and Methods

### Subjects

Women undergoing mammographic screening at Skåne University Hospital, Malmö, Sweden who had already been selected to participate in a study of BT vs. digital mammography (DM) using the Siemens MAMMOMAT Inspiration BT system (Siemens Medical Systems, Erlangen, Germany), were asked for their consent to participate in this prospective study. A total of 131 subjects were included from October 18 to November 19, 2010. Fourteen did not wish to participate; three with breasts too large to fit under the medium size compression plate (model: 1014011, dimensions:  $28 \times 20 \times 0.16$  cm) were excluded, along with six with breast implants and five due to technical difficulties. This resulted in 103 (79%) subjects with a median age of 48.9 years (range, 40.7–74.3 years) being included (Fig. 1). The Regional Ethical Review Board at Lund University (Dnr 2010/559) approved the study. Informed consent was obtained and all examinations were voluntary.

### Study implementation

The women were subjected to two additional compressions without X-ray exposure: full standard compression force (mean,  $95.4 \pm 6.9$  [standard deviation] N; range, 77–112 N) as well as reduced (about half) compression force (mean,

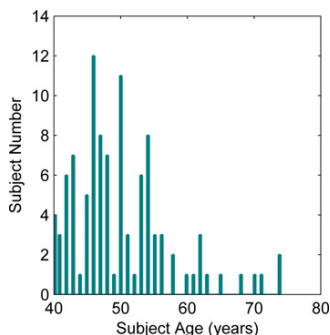


Fig. 1 Age distribution of study subjects

$54.3 \pm 6.4$  N; range, 34–67 N). Pressure distribution over the left breast, while compressed in the medio lateral oblique (MLO) projection ( $55^\circ$ ), was measured. The subjects were asked to rate their experience of pain (none to unbearable) at full and reduced compression on a 10 cm visual analogue scale (VAS) immediately following the different compressions (17).

### Pressure measurement system

Pressure distribution was measured using the I-Scan system with model 9801 sensors. Each sensor is 0.18 mm thick and has an active area of  $76 \times 203$  mm, divided into  $6 \times 16$  sensor elements (Fig. 2). The sensor sensitivity can be adjusted, though increased pressure resolution comes at the cost of a reduced saturation limit. The pressure resolution is 0.14 kPa at the manufacturer's recommended limit of 35 kPa. A consideration with such a system is 'partial area effect', meaning for example that pressure structures smaller than an element will be interpreted as covering




Fig. 2 Two FSR sensors fastened adjacent to one another underneath the compression plate, placed as close as possible to the cranial-juxtathoracic edge of the plate

the whole element, or two elements if located on the edge between them.

The performance of the I-Scan system has been verified in a number of publications (18–20). Morin *et al.* (21) calibrated and evaluated the system under conditions similar to those used in this study (i.e. measuring contact forces on skin) and found it to perform adequately. The sensors were calibrated and verified each day using a standard protocol. According to the user manual the calibration equipment had a full-scale gauge accuracy of 3% while the sensor had a non-linearity of <3%, repeatability of <3.5%, and full-scale hysteresis of <4.5% (22).

#### Pressure map acquisition

Two sensors were fastened underneath the compression plate as close as possible to its rounded cranial-juxtathoracic edge without bending them (as this affects output in an unpredictable manner (Fig. 2) (21)). The radiographer positioned and compressed the breast as for a routine mammogram (23). The output from the sensors was stored and compression force and breast thickness were recorded as indicated by the mammographic device (hereby referred to as applied force to differentiate it from the measured force acquired by the sensor system). The procedure was repeated using approximately half the previous force.

#### Pressure map analysis

Pressure data and DM screening mammograms were used to create composite images with pressure data displayed as a color overlay. Since the pressure images and mammograms were of different size and scale they were adjusted

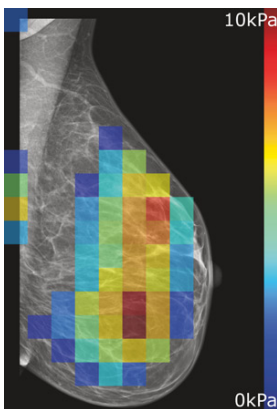


Fig. 3 An example of a composite X-ray/pressure breast image. Pressure information is displayed in transparent color on the mammogram. In this particular example a relatively large fraction of the compression force is distributed over the central parts of the breast. Pressure is also visible in the upper and middle left edges of the image. These three areas were pressurized in many breasts, though the relative force distribution between them varied. Due to the positioning of the sensors, pressure data could also be collected outside the X-ray image as shown along the left and upper edges

to match. To ensure a good match, both an X-ray image and a pressure image of the sensors (fastened in position beneath the compression plate) were acquired so that the sensors were visible in both images. These two images served as a template for subsequent composite images. Since the compression plate extended outside the active area of the detector, the image was enlarged with blank (shown as black) regions, extending 0.9 cm and 0.6 cm along its left and upper edges, respectively (Fig. 3).

To investigate the effect of breast anatomy on pressure distribution two methods were used: a subjective measure in which the location of dense (fibroglandular) tissue was determined and an objective three-region division of the breast; inner breast 0–25%, middle breast 26–67%, and outer breast 68–100%, respectively, of the distance between the juxtathoracic edge of the mammogram and the maximum anterior extent of the breast (Fig. 4). The cut-off levels were arbitrary, but easily reproducible. Breast area was defined from the X-ray image. Dense tissue area was defined as the area of sensor elements covering radiopaque structures in the X-ray image, decided in consensus by a radiologist and a medical physicist. Relative density was defined as the ratio between the dense tissue area and breast area.

#### Statistical analysis

Data were analyzed using MedCalc (version 9.6.4.0; MedCalc Software, Mariakierke, Belgium). Pearson's correlation coefficients were calculated to describe the strength

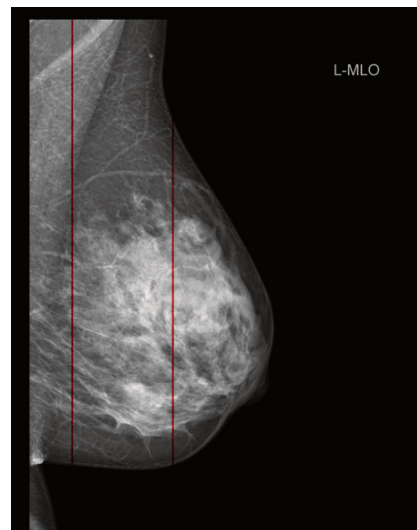


Fig. 4 Example of division of the breast into inner, middle, and outer regions. Regions are defined as fractions of the distance between the juxtathoracic edge of the mammogram and the maximum anterior extent of the breast, 0–25%, 26–67%, and 68–100%, respectively

**Table 1** Properties of 103 female breasts under full and reduced compression

Breast area (cm <sup>2</sup> )	196.3 ± 56.3 (99.6–322.9)	
Dense tissue area (cm <sup>2</sup> )	27.5 ± 20.9 (0–109.7)	
	Full compression	Reduced compression
Applied compression force (N)	95.4 ± 6.9 (77–112)	54.3 ± 6.3 (34–67)
Breast thickness (mm)	52.9 ± 13.7 (23–80)	54.7 ± 14.0 (23–86)
Force over the inner breast (N)	29.0 ± 16.8 (3.9–85.4)	24.7 ± 16.8 (2.4–88.2)
Force over the middle breast (N)	18.9 ± 14.5 (0.0–68.6)	12.5 ± 9.3 (0.3–44.9)
Force over the breast (N)	48.1 ± 19.4 (14.6–109.5)	37.3 ± 19.0 (4.6–107.1)
Mean pressure (kPa)	2.1 ± 1.0 (0.6–6.5)	1.6 ± 1.0 (0.2–6.1)
Pressurized area (cm <sup>2</sup> ) <sup>a</sup>	87.9 ± 26.1 (37.1–177.4)	82.2 ± 27.4 (25.8–195.2)
Mean pressure over pressurized area (kPa) <sup>a</sup>	5.6 ± 2.0 (2.1–11.5)	4.6 ± 2.2 (1.2–11.5)
Mean pressure over dense tissue (kPa)	2.4 ± 2.5 (0–10.5)	1.5 ± 1.5 (0–8.0)
Experienced pain <sup>†</sup>	34 (0.0–90.9)	17 (0.0–70.9)

<sup>a</sup>Pressurized area refers to the area of all sensors elements which gave a non-zero output

<sup>†</sup>Median values, 2.5% and 97.5% percentiles in parentheses

Unless otherwise noted, data are mean values ± 1 standard deviation, with ranges in parentheses

of relationship between parameters. The two-sided paired *t* test was used to analyze differences between full and reduced compression. To identify differences between pressure pattern groups, data from different pressure patterns were analyzed by one-way analysis of variance (ANOVA) or Kruskal-Wallis ANOVA for non-parametric data. Multivariate analysis using multiple linear regression with pain as dependent variable and age, breast area, dense tissue area, breast thickness, force over the inner breast, force over the middle breast, force over the breast, mean pressure, pressurized area, mean pressure over pressurized area, mean pressure over dense tissue, and maximum pressure as independent variables was performed. *P* values of <0.05 were considered statistically significant.

## Results

The forces derived from the pressure measurements, 48.1 ± 19.4 N and 37.3 ± 19.0 N at full and reduced compression, respectively, were significantly different from the forces recorded by the compression device, 95.4 ± 6.9 N (*P* < 0.0001) and 54.3 ± 6.4 N (*P* < 0.0001), and lacked significant correlation to them (full: *P* = 0.16; reduced: *P* = 0.61) (Table 1). There was a significant difference between full and reduced compression with regard to all parameters (outer breast was excluded from data analysis due to low overall or non-existent pressure). No correlation was found between measured compression force and breast thickness (full, *P* = 0.50; reduced, *P* = 0.52). There was, however, strong negative correlation between measured force over the middle breast and breast thickness (full, *P* < 0.001; reduced, *P* < 0.009). There was no correlation between age and breast thickness (full, *P* = 0.96; reduced, *P* = 0.80).

### Pain regression model

Experienced pain at full and reduced compression showed significant correlation (*P* < 0.0001), but there was no correlation between pain and breast thickness (full, *P* = 0.39; reduced, *P* = 0.19). Multiple linear regression identified that pain was associated (*P* < 0.001) with the independent variables breast area, mean pressure over dense tissue, and

**Table 2** Estimation of pain prediction model using multiple linear regression

	Coefficient	95% CI	<i>P</i> value
Constant	39.244	N/A	N/A
Breast area	-0.209	-0.334 to -0.078	0.0023
Breast thickness	0.630	0.053 to 1.208	0.035
Mean pressure over dense tissue	3.346	0.891 to 5.801	0.0088

breast thickness, the latter notably not showing any significant relation to pain in the univariate analysis, as noted above (Table 2). Force over the middle breast was excluded from the model as it showed strong correlation to mean pressure over dense tissue (full, *P* < 0.0001; reduced, *P* < 0.0001); this multicollinearity implied that both values could not be included simultaneously in the regression model.

### Pressure map analysis

From the composite images it was clear that pressure distribution varied widely between breasts. Only a minority of images showed relatively uniform pressure over the breast; the most frequent pattern was a number of high-pressure zones. Often, such a zone was seen in the juxtathoracic part of the breast, sometimes extending towards the armpit. Fig. 3 shows an example of a pressure distribution pattern.

Four pressure distribution patterns were identified. All compressions could be characterized as one, or a combination of two, of these patterns. Each pattern group is described below and shown in Fig. 5.

In group A pressure was widespread over the breast. The pressure was not uniformly distributed but most of the breast was subjected to some pressure.

Group B was characterized by high pressure in the central part of the breast while pressure was low, or not present, elsewhere. The location, size and shape of this area often, but not always, matched that of the radiologically dense tissue of the breast.

Group C showed a concentration of high pressure in the juxtathoracic region, extending in a decreasing gradient towards the central part of the breast.

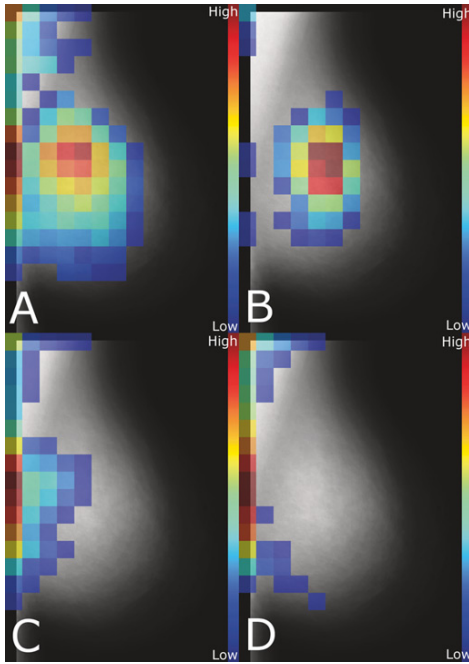


Fig. 5 Relative pressure distribution for the four pressure pattern groups (A–D). Each group image was created by combining all included pressure datasets and averaging in each pixel, excluding values less than 10% of the maximum after averaging. The mammographic background image was created from the mammograms of all 103 included subjects in the same way, apart from the 10% cut-off

Group D was characterized by very high pressure along a narrow zone at the juxtathoracic edge, extending along the pectoral muscle towards the armpit with little or no pressure over the breast.

Group U (ungrouped) included the remaining cases, all of which showed some combination of the above mentioned pressure patterns, most frequently a combination of group B and D.

Table 3 lists data from pressure measurements, properties determined from the mammograms, and various other parameters by pressure pattern group. Notably, there is no evidence of differences due to age ( $P = 0.68$ ). Subjects of group B experienced the highest level of pain, although not statistically significant ( $P = 0.094$ ). Compressed breast thickness was highest for group D ( $P = 0.003$ ).

## Discussion

The main purpose of breast compression is to separate structures in dense parenchymal tissues, through applying force to these areas. We hypothesized that less diagnostically relevant structures, such as the pectoral muscle, are firmer than

the parenchyma, becoming more so when compressed, and will be subjected to proportionally higher pressure. This effect is believed to become more pronounced as compression increases. The pectoral muscle and other structures at the chest wall would act as a support, preventing adequate compression of relevant tissues of the breast. We therefore hypothesized that a moderate reduction of the compression force would not significantly decrease pressure applied to breast tissue.

From the pressure images it is reasonable to conclude that two main factors influence pressure distribution; variations in thickness and stiffness across the breast: groups A and B showed pressure over the densest (and likely stiffest) part of the breast while groups C and D showed pressure over the thick juxtathoracic part and the pectoral muscle. It is possible that groups A and B represent subjects where the breast is thicker than the juxtathoracic structures. Thus our hypothesis applies primarily to groups C and D. Eklund *et al.* have reported that the pectoral muscle can limit the compression of anterior tissue if it is prominently included. They therefore recommended so-called displacement images, analogous to those required when a prosthesis is present (24, 25). We investigated this by calculating the area of the pectoral muscle included in the mammogram and found no significant difference between pressure pattern groups (ANOVA,  $P = 0.88$ ).

No correlation could be found between the compressed breast thickness and either the applied or measured force. The thickness difference between full and reduced compression was less than 2 mm on average. In groups A and B (where force is applied to the breast itself) this suggests that the breast is well compressed already at a relatively low applied level of force, with further force application resulting in a very small reduction in thickness at the cost of increased pain. This should also have a minimal impact on glandular dose (3). For groups C and D increased compression force will mainly reduce the thickness of the pectoral muscle and the juxtathoracic area and the level of force applied will have little effect on the compression of the breast itself. In both cases this might explain previous studies, which have found that there is no significant reduction in image quality due to reduced compression force (3, 9, 10). Essentially, our results might suggest that the reduced compression force (on average  $54.3 \pm 6.3$  N) is enough to adequately compress the breast and that further application of force will result in excess pain for a very minor decrease in thickness, provided that force is actually distributed to the breast itself. If not, the breast will not be adequately compressed even with standard compression force as juxtathoracic structures absorb the applied force (which is consistent with our hypothesis). Therefore it is our recommendation that pressure distribution, more so than force, should be taken into account when assessing the effects of breast compression. To verify this, a study of how image quality correlates to the pressure distribution would be of great interest.

It is not suitable to base compression on applied force, it is pressure caused by this force that leads to deformation of the breast. If breasts were homogenous in structure, pressure and thus compression would simply vary with

**Table 3 Breast properties measured by pressure pattern group. All data are taken at full compression if not otherwise stated and if applicable to the particular data-set**

	Group A	Group B	Group C	Group D	Group U	P value*
Subjects†	30 (29%)	8 (8%)	16 (16%)	27 (26%)	22 (21%)	-
Age (years)‡	47.5 (40.5-57.0)	52 (42-74)	46.5 (40-69.2)	48 (40.2-68.8)	50.5 (41-67.7)	0.68
Breast area (cm²)	191.5 ± 59.4 (109.6-321.8)	185.6 ± 37.3 (117.1-235.6)	174.7 ± 42.9 (109.1-247.7)	200.8 ± 55.6 (113.4-311.1)	217.1 ± 63.2 (99.6-322.9)	0.20
Dense tissue area (cm²)	28.4 ± 20.7 (1.6-85.5)	34.7 ± 17.9 (9.7-58.1)	17.0 ± 10.7 (0.0-37.1)	25.7 ± 13.8 (1.6-51.6)	33.1 ± 30.9 (1.6-109.7)	0.14
Relative density (%)	0.27 ± 0.14 (0.06-0.54)	0.25 ± 0.10 (0.03-0.37)	0.18 ± 0.10 (0.02-0.33)	0.20 ± 0.12 (0.02-0.43)	0.25 ± 0.15 (0.03-0.61)	0.11
Breast thickness (mm) (Full Compression)	46.0 ± 13.6 (23-72)	46.4 ± 11.0 (30-59)	56.9 ± 11.7 (40-77)	58.0 ± 12.8 (36-79)	55.4 ± 13.2 (34-80)	0.0030
Breast thickness (mm) (Reduced Compression)	47.6 ± 14.2 (23-76)	48.4 ± 11.6 (32-59)	59.6 ± 11.4 (42-82)	59.6 ± 12.8 (38-79)	57.2 ± 13.5 (35-86)	0.0027
Force over the inner breast (N)	23.3 ± 10.0 (4.0-40.0)	7.4 ± 3.1 (3.9-12.6)	34.5 ± 11.6 (12.6-59.0)	40.0 ± 18.8 (10.9-85.4)	26.9 ± 17.1 (10.1-74.7)	<0.0001
Force over the middle breast (N)	28.8 ± 14.0 (10.1-61.9)	36.4 ± 16.7 (11.0-68.6)	9.8 ± 6.3 (1.7-21.6)	8.3 ± 5.8 (0-25.4)	17.3 ± 9.5 (3.8-40.3)	<0.0001
Force over the breast (N)	53.4 ± 16.8 (21.5-96.9)	43.8 ± 16.0 (19.6-72.9)	44.5 ± 14.3 (23.2-71.2)	48.4 ± 22.4 (14.6-96.4)	44.7 ± 22.7 (19.4-109.5)	0.43
Mean pressure (kPa)	2.4 ± 1.1 (0.9-6.5)	1.9 ± 0.8 (1.0-3.8)	2.1 ± 0.8 (1.0-3.8)	2.0 ± 1.0 (0.7-4.1)	1.8 ± 0.9 (0.6-4.0)	0.18
Pressurized area (cm²)	104.3 ± 24.5 (68.1-177.4)	75.2 ± 16.9 (51.6-101.6)	79.4 ± 18.3 (43.5-108.1)	72.9 ± 21.9 (37.1-132.3)	94.6 ± 26.8 (51.6-158.5)	<0.0001
Mean pressure over dense tissue (kPa)	4.2 ± 2.4 (0.0-10.3)	5.4 ± 3.1 (0.0-10.5)	1.1 ± 1.2 (0.0-3.7)	7.2 ± 0.7 (0.0-2.7)	1.7 ± 1.9 (0.0-8.0)	<0.0001
Experienced pain‡ (Full Compression)	27 (0.5-86.3)	70.5 (21-91)	41 (0-97)	25 (0.4-75.8)	47 (0-97.5)	0.094
Experienced pain‡ (Half Compression)	15.5 (0.3-65.5)	33.5 (7-71)	27 (0-55)	12 (0.2-58.6)	19 (0.1-91)	0.22

†Probability of all groups being drawn from a sample population with equal mean/median

‡Numbers of subjects, with percentages in parentheses

§Median values, 2.5% and 97.5% percentiles in parentheses

¶Unless otherwise noted, data are mean values ± 1 standard deviation, with ranges in parentheses

the size of the breast. However, because the breast is in fact highly heterogeneous it would be impractical to base compression on size, as pressure will vary widely over the breast. The important consideration is how much the breast is actually compressed (so called compressibility) (7). Methods such as Siemens proprietary OPCOMP system take this into account by continuously monitoring the ratio between thickness reduction and applied force, halting further force application when the ratio drops below a threshold. The problem is that in many cases the applied force is concentrated over the pectoral muscle and the chest wall (Fig. 5). Consequently the force-thickness ratio drops as these structures are compressed and stiffen, causing the application of compression force to stop even if the breast is not adequately compressed, a situation noted by our study radiographer (21 years of experience) in mammography screening.

It would be reasonable to assume that the pressure distribution is affected by the density of the compressed breast, i.e. the stiffness of a dense breast would be closer to the stiffness of the juxtathoracic structures, which would result in a more homogenous distribution of pressure. There was a difference between the groups in relative density with group A being the densest and group C the least dense, though the differences were not significant ( $P = 0.11$ ). This may indicate that measures based on relative density, such as the widely used BIRADS (26) classification, may not be suitable to predict pressure distribution.

Compared to a previous study on BT (9) the difference between breast thickness for full and reduced compression is smaller in the current study, 1.8 mm compared to 5.8 mm. As compression procedures are the same and compression force was not substantially different, this difference must be attributed to the compression plate, the thickness readout or the force readout. Of these, only the plates are known to be different; this study employed conventional DM plates and the earlier one BT plates. The results of Thilander Klang (10), obtained as part of a general study on image quality, are not strictly comparable as both full and reduced compression forces were roughly twice as high, compression procedures may have been different and no data on compression plates was included. Still, the small difference of 3.6 mm in that work (10) might imply that the difference can be referred to the BT compression plate that lacks the rounded edge and flexible fixtures of the conventional plate used in this study. Using a rounded edge and flexible fastenings should both result in the inner (firmer) part of the breast being relatively less compressed and relatively greater compression applied to the outer (softer) parts, i.e. an inclined profile, introducing uncertainty in the interpretation of the thickness readout.

The multiple linear regression model showed that a woman's experienced pain was related to breast area, breast thickness, and mean pressure over dense tissue. Interestingly it was not associated with other parameters such as calculated force over the breast or maximum pressure. It seems reasonable to assume that parenchyma is more tender and sensitive to pressure than adipose tissue. Women with small breast area have increased experienced of pain, also commonly noticed in practice. How and

why breast thickness is related to experienced pain is less clear. One explanation might be that breast thickness is highest in group D, which has little pressure over the breast but more over the pectoral area. One could assume that compression of the pectoral area is less painful than compression of the breast.

As stated earlier the study is limited by the performance of the sensor system. High-pressure areas at the sensors edge often exceed the sensors' saturation limit. This could be avoided by setting a higher saturation limit, but that would negatively impact the sensors' ability to measure low pressure. Therefore sensitivity was prioritized, even when it resulted in saturated sensing elements and thus under-estimation of pressure (and calculated force, explaining the discrepancy between applied force and calculated force). A puzzling result, which can be seen in Table 1, is that the maximum measured force values, particularly at reduced compression, are higher than the maximum applied forces. An over-estimation of force greater than roughly 10% (that can be explained by element variability, hysteresis and calibration issues) is seen in a handful of cases, characterized by saturated elements along the chest wall. This is consistent with high pressure only being present in a narrow strip and force thus overestimated due to partial area effect. This is offset by under-estimation due to saturation, explaining why it is not as apparent at full compression where that effect becomes more pronounced.

Other limitations include that we used compression plates from only one manufacturer. We do not believe that the results would not apply to corresponding devices from other manufacturers, though this remains to be investigated in a future study. Furthermore, the tilt and lateral displacement of the compression plate and the magnification due to sensor positioning were not taken into account, though the effect is believed to be small compared to the sensors' spatial resolution. Additionally, the VAS scale is here treated as continuous data and compared between subjects, though this is not without precedent (27). Moreover, the age distribution of the subjects was not representative of the general population, with a substantial over-representation of women between age 40 and 55 years. There was however significant correlation between age and dense tissue area ( $P = 0.0026$ ). As groups A and B have the densest breasts and represent the most successful compressions, the problem of little or no pressure over the breast could be greater in the general population.

In conclusion, the results of the study suggest that currently used compression plates do not provide optimal compression of the breast for a substantial proportion of women, as little or no pressure is applied to the breast itself with standard compression force. This effect is not due to lack of force but unsuitable pressure distribution. When pressure is present over the breast itself, compression force could be reduced to increase comfort at the cost of a minor increase in breast thickness. This suggests a need for a more refined compression device design, which can ascertain appropriate compression of the breast itself even in the presence of thick juxtathoracic structures.

**Conflict of interest:** None.

#### ACKNOWLEDGEMENTS

The authors would like to express their gratitude to: Maria Seserin, Unilabs, Malmö, Sweden, for her efforts in patient handling; Professor Kjell Lindström, Department of Biomedical Engineering, Lund University, Skåne University Hospital, Malmö, Sweden, for his valuable comments regarding the sensor system; and Associate Professor Jonas Björk, Division of Occupational and Environmental Medicine, Lund, Sweden, for his efforts in processing statistical material. The authors would like to thank the Medical Faculty at Lund University, Region Skåne (regionalt forskningsstöd), Stiftelsen för cancerforskning vid Onkologiska kliniken vid Universitetssjukhuset MAS, Allmänna Sjukhusets i Malmö stiftelse för bekämpande av cancer, and Siemens AB, Healthcare Sector Sweden for financial support.

#### REFERENCES

- Nystrom L, Andersson I, Bjurstan N, *et al.* Long-term effects of mammography screening: updated overview of the Swedish randomised trials. *Lancet* 2002;**359**:909–19
- Tabar L, Yen MF, Vitak B, *et al.* Mammography service screening and mortality in breast cancer patients: 20-year follow-up before and after introduction of screening. *Lancet* 2003;**361**:1405–10
- Saunders RS Jr, Samei E. The effect of breast compression on mass conspicuity in digital mammography. *Med Phys* 2008;**35**:4464–73
- Aro AR, de Koning HJ, Absetz P, *et al.* Psychosocial predictors of first attendance for organised mammography screening. *J Med Screen* 1999;**6**:82–8
- Miller D, Livingstone V, Herbison P. Interventions for relieving the pain and discomfort of screening mammography. *Cochrane Database Syst Rev* 2008:CD002942
- Perry N, Broeders M, de Wolf C, *et al.* European guidelines for quality assurance in breast cancer screening and diagnosis. Fourth edition – summary document. *Ann Oncol* 2008;**19**:614–22
- Poulos A, McLean D. The application of breast compression in mammography: a new perspective. *Radiography* 2004;**10**:131–7
- Krouskop TA, Wheeler TM, Kallel F, *et al.* Elastic moduli of breast and prostate tissues under compression. *Ultrasound Imaging* 1998;**20**:260–74
- Fornvik D, Andersson I, Svahn T, *et al.* The effect of reduced breast compression in breast tomosynthesis: human observer study using clinical cases. *Radiat Prot Dosimetry* 2010;**139**:118–23
- Thilander Klang A. *Diagnostic Quality and Absorbed Dose in Mammography*. Gothenburg: University of Gothenburg; 1997
- Russell DG, Ziewacz JT. Pressures in a simulated breast subjected to compression forces comparable to those of mammography. *Work in Progress. Radiology* 1995;**194**:383–7
- Azar FS, Metaxas DN, Schnall MD. A deformable finite element model of the breast for predicting mechanical deformations under external perturbations. *Acad Radiol* 2001;**8**:965–75
- Zyganitidis C, Bliznakova K, Pallikarakis N. A novel simulation algorithm for soft tissue compression. *Med Biol Eng Comput* 2007;**45**:661–9
- Chung JH, Rajagopal V, Nielsen PM, *et al.* Modelling Mammographic Compression of the Breast. In: Metaxas DN, Axel L, Fichtinger G, *et al.*, eds. *MICCAI '08 Proceedings of the 11th International Conference on Medical Image Computing and Computer-Assisted Intervention, Part II*. Heidelberg: Springer-Verlag; 2008:758–6
- Chen B, Shorey J, Saunders RS Jr, *et al.* An anthropomorphic breast model for breast imaging simulation and optimization. *Acad Radiol* 2011;**18**:536–46
- Clark DJ, Chambers IR, Faulkner K, *et al.* Pressure measurements during automatic breast compression in mammography. *J Biomed Eng* 1990;**12**:444–6
- Revill SJ, Robinson JO, Rosen M, *et al.* The reliability of a linear analogue for evaluating pain. *Anaesthesia* 1976;**31**:1191–8

- 18 Luo ZP, Berglund LJ, An KN. Validation of F-Scan pressure sensor system: a technical note. *J Rehabil Res Dev* 1998; 35:186-91
- 19 Wilson DR, Eichler MJ, Hayes WC. Accuracy of the Iscan Pressure Measurement System. In: *RTO meeting proceedings 56 - Soldier Mobility: Innovations in Load Carriage System Design and Evaluation*. Ottawa/Hull: St Joseph, 2001:247-50
- 20 Bachus KN, DeMarco AL, Judd KT, et al. Measuring contact area, force, and pressure for bioengineering applications: using Fuji Film and TekScan systems. *Med Eng Phys* 2006;28:483-8
- 21 Morin EL, Bryant JT, Reid SA, et al. Calibration Issues of Tekscan Systems For Human Pressure Assessment. In: *RTO meeting proceedings 56 - Soldier Mobility: Innovations in Load Carriage System Design and Evaluation*. Ottawa/Hull: St Joseph, 2001:251-7
- 22 Tekscan. Pressure and Force Measurement Technology. See <http://www.tekscan.com/sensor-technology>
- 23 European Commission. *European guidelines on quality criteria for diagnostic radiographic images*. Brussels, 1996 EUR 16260
- 24 Eklund GW, Cardenosa G. The art of mammographic positioning. *Radiol Clin North Am* 1992;30:21-53
- 25 Eklund GW, Cardenosa G, Parsons W. Assessing adequacy of mammographic image quality. *Radiology* 1994;190:297-307
- 26 D'Orsi CJ, Mendelson EB, Ikeda DM, et al. *Breast Imaging Reporting and Data System: ACR BI-RADS - Breast Imaging Atlas*. Reston, VA: American College of Radiology, 2003
- 27 Dexter F, Chestnut DH. Analysis of Statistical Tests to Compare Visual Analog Scale Measurements among Groups. *Anesthesiology* 1995;82:896-902

## Paper IV





# No evidence for shedding of circulating tumor cells into the peripheral venous blood as a result of mammographic breast compression

Research article

Daniel Förnvik<sup>1,\*</sup>  
Ingvar Andersson<sup>2</sup>  
Roy Ehrnström<sup>3</sup>  
Magnus Dustler<sup>1</sup>  
Lisa Rydén<sup>4</sup>  
Anders Tingberg<sup>1</sup>  
Sophia Zackrisson<sup>2</sup>  
Kristina Aaltonen<sup>5</sup>

<sup>1</sup>Medical Radiation Physics  
Department of Clinical Sciences, Malmö, Lund University  
Skåne University Hospital Malmö  
SE-205 02 Malmö, Sweden

<sup>2</sup>Diagnostic Radiology  
Department of Clinical Sciences, Malmö, Lund University  
Skåne University Hospital Malmö  
SE-205 02 Malmö, Sweden

<sup>3</sup>University and Regional Laboratories Region Skåne  
Department of Pathology  
Skåne University Hospital Malmö  
SE-205 02 Malmö, Sweden

<sup>4</sup>Surgery  
Department of Clinical Sciences, Lund, Lund University  
Skåne University Hospital Lund  
SE-222 21 Lund, Sweden

<sup>5</sup>Oncology  
Department of Clinical Sciences, Lund, Lund University  
Skåne University Hospital Lund  
SE-222 21 Lund, Sweden

\*Corresponding author:  
[daniel.fornvik@med.lu.se](mailto:daniel.fornvik@med.lu.se)  
Phone: +46 40 33 86 59  
Fax: +46 40 96 31 85

# **No evidence for shedding of circulating tumor cells into the peripheral venous blood as a result of mammographic breast compression**

## **Abstract**

**Introduction:** The study aimed to investigate whether mammographic compression procedures might cause shedding of tumor cells into the circulatory system as reflected by circulating tumor cell (CTC) count in peripheral venous blood samples.

**Methods:** From March to October 2012, 24 subjects with strong suspicion of breast malignancy were included in the study. Peripheral blood samples were acquired before and after mammography. Enumeration of CTCs in the blood samples was performed using the CellSearch<sup>®</sup> system. The pressure distribution over the tumor-containing breast was measured using thin pressure sensors.

**Results:** Median age was 66.5 years (range, 51-87 years). In 22 of the 24 subjects breast cancer was subsequently confirmed. The difference between the average mean tumor pressure  $6.8 \pm 5.3$  kPa (range, 1.0-22.5 kPa) and the average mean breast pressure  $3.4 \pm 1.6$  kPa (range, 1.5-7.1 kPa) was statistically significant ( $P < 0.001$ ), confirming that there was increased pressure over the tumor. The median pathological tumor size was 19 mm (range, 9-30 mm). Four subjects (17%) were CTC positive before compression and two of these (8%) were also CTC positive after compression. A total of seven CTCs were isolated with a mean size of  $8 \times 6$   $\mu\text{m}$  (range of longest diameter, 5-12  $\mu\text{m}$ ).

**Conclusions:** We found no elevated CTC count in the peripheral blood after mammography, although a possible explanation is that the CTCs were trapped in the lung capillaries. The study supports the view that mammography is a safe procedure.

**Keywords:** circulating tumor cells, breast compression, breast cancer, mammography

## **Introduction**

Mammography is the golden standard imaging method of the breast. Compression of the breast during mammography is performed to improve image quality by increasing breast tissue separation and reducing scattered radiation, and to minimize the radiation dose to the breast, which is one of the most radiosensitive tissues of the female body. For these reasons, the breast is compressed as much as reasonably possible to a level just below the patient's pain threshold or up to the maximum setting of the machine (generally 200 N). It has long been discussed whether this applied pressure may damage a tumor resulting in shedding of malignant cells into the circulatory system and whether this in turn will affect the prognosis [1-3]. Several publications have stressed the need for caution in cancer surgery, emphasizing the importance of minimizing tumor manipulation to avoid dissemination of malignant cells [4-8]. Older studies have found that moderate pressure applied to tumors in small animals caused the number of cancer cells per ml blood to rise drastically or the incidence of distant metastases to increase compared to controls [9-12]. This is a relevant concern for mammography since the most important and detrimental step in the progression of breast cancer is the occurrence of metastatic disease through dissemination of cancer cells to other parts of the body.

Many critical steps of the metastatic cascade are unclear, including how malignant cells (possibly due to acquired features) can give rise to overt metastasis in secondary organs. One of the first steps in the metastatic process is the spread of tumor cells into the blood circulation. These circulating tumor cells (CTCs) have left the primary tumor and studies have confirmed that the CTC count per unit of blood is an independent prognostic marker for progression-free survival and overall survival in several types of cancer [13-15]. Also, the CTC count in peripheral blood of metastatic cancer patients during therapy directly reflects

the patient's response to therapy [16, 17]. The prognostic role of CTC in primary (non-metastatic) cancer has not been widely investigated [18], but a few studies have shown that the presence of CTCs can predict poor prognosis also in patients with primary breast cancer [15, 19, 20]. Furthermore, a prospective study by Lucci and colleagues [21] has shown that the presence of one or more CTCs predicted both early recurrence and decreased overall survival in 302 non-metastatic breast cancer patients independent of prognostic factors such as tumor size or grade. Franken et al. included 404 stage I-III patients and showed that the presence of CTCs ( $\geq 1/30$  ml) was associated with an increased risk for breast cancer related death [22]. Thus, the presence of CTCs seems to be an important prognostic factor also in women with primary breast cancer.

We hypothesized that damage to a tumor, caused by the pressure arising from compression of the breast, might release tumor cells into the blood stream. The main study aim was to investigate whether mammographic compression procedures might cause shedding of tumor cells as reflected by CTC count in peripheral blood samples taken before and after compression of the breast. To examine a possible correlation between the magnitude of the pressure and the CTC count, we measured the applied pressure to the tumor and the rest of the breast.

## **Materials and methods**

### *Study population*

Subjects were recruited among patients referred for clinical mammography as well as from the screening program. Patients from the clinical practice (below referred to as symptomatic women) were selected if information on clinical findings in the referral notes indicated a strong suspicion of malignancy. Subjects from the screening program were selected on the

basis of the screening mammogram showing a strong suspicion of malignancy requiring recall for further investigation. A total of 24 subjects were included from March to October 2012.

The workflow is illustrated in Figure 1.

The Regional Ethical Review Board at Lund University (Dnr 314/2011) approved the study.

Written informed consent was obtained from all included patients and all examinations were voluntary.

#### *Blood sampling and image acquisition*

All blood samples were drawn from either a cubital vein (97%) or a vein on the dorsal aspect of the hand (3%). The first blood sample was drawn immediately before the mammography examination, but in the symptomatic patients after an ultrasound examination using minimal pressure on the probe. The rationale of the ultrasound was to confirm the presence of a suspicious lesion (Figure 1). All subjects then underwent three projection views of the breast of interest: craniocaudal (CC), mediolateral oblique (MLO) and lateromedial (LM) using the Siemens MAMMOMAT Inspiration system (Siemens AG, Erlangen, Germany). In 22/24 (92%) of the subjects the pressure distribution was recorded in the CC projection image, in the remaining two of the subjects (8%) it was recorded in the MLO projection image. After completed mammography examination the second blood sample was drawn. This occurred on average 5.1 minutes (range, 2-14 minutes) after the pressure distribution was recorded.

#### *Pressure measurement system*

The pressure distribution over the compressed breast was measured using two thin, flexible I-Scan (TekScan Inc, South Boston, MA, USA) FSR (Force Sensing Resistor) pressure sensors (model 9801). Each sensor is 0.18 mm thick and has an active area of 76 mm x 203 mm,

divided into 6 x 16 sensor elements. The sensors were calibrated and verified before each subject measurement and the sensitivity was set according to previous experience [23]. The pressure resolution at this setting is roughly 0.14 kPa with a saturation limit between 30-35 kPa. The performance of the I-Scan system has been verified previously and evaluated under conditions similar to those used in this study [23-25].

#### *Pressure distribution acquisition*

Two sensors were fastened adjacent to one another underneath the compression paddle (model 1014011, dimensions: 28 x 20 x 0.16 cm) (Figure 2) for one of the projection images (see above) and then removed before the remaining images were acquired because the sensors are radiopaque (Figure 3). The pressure image was obtained using our routine technique in terms of positioning and compression force. The output from the sensors was stored and compression force and thickness was recorded as indicated by the mammographic device. Pressure data and the corresponding projection images were used to create composite images (Figure 3). The pressure column closest to the chest wall (the first 16 sensor elements) was excluded from the analysis as this column is usually outside the mammogram and characterized by high pressure values due to the inclusion of superficial parts of the chest wall [23]. A medical physicist (DF) together with an experienced radiologist (IA) decided in consensus which pressure elements covered the tumor areas.

#### *Enumeration and definition of circulating tumor cells*

Enumeration of CTCs in the blood circulation was performed with the Food and Drug Administration (FDA)-approved CellSearch<sup>®</sup> method (Veridex, Raritan, NJ, USA). Peripheral blood (7.5 ml) was drawn into CellSave Preservative Tubes (Veridex). Two samples were drawn before compression and two samples after compression to increase the likelihood of

detecting possible CTCs. Samples were maintained at room temperature and processed within 96 hours after blood collection. The methodology as well as the precision, accuracy and reproducibility of CTC measurements using the CellSearch<sup>®</sup> system have been previously described [26, 27]. Briefly, antibodies conjugated to ferro-fluid particles were used to magnetically isolate cells expressing the Epithelial Cell Adhesion Molecule (EpCam). Unbound cells were removed and the enriched sample was fluorescently stained for nucleic acids (DAPI), cytokeratins (CK 8, 18 and 19) and CD45. Cells with a size of at least 4 μm presenting the phenotype DAPI+/CK+/CD45- were classified as CTCs. All CTC evaluations were performed at the Department of Oncology (Clinical Sciences, Lund University, Sweden), by two accredited and independent scorers. In this study, the presence of one or more CTCs in any of the two pairs of samples (before and after) was considered CTC positive [15, 18, 22, 28, 29].

#### *Staging and pathology review*

Information on tumor histology, staging and prognostic factors was retrieved from pathology reports (Skåne University Hospital, Malmö, Sweden). All patients underwent primary surgery according to regional guidelines including mastectomy or breast-conserving surgery as well as sentinel node biopsy. In patients with metastatic sentinel node, axillary clearance was performed. The tumor size was given as the largest measured histological value of the x-, y- and z-axis of the tumor. Axillary node involvement was classified as positive in the presence of micro- and macrometastases, as negative in the presence of only isolated tumor cells or no node involvement or not applicable (N/A). All tumors were classified as well as graded according to the Nottingham (Elston/Ellis) grading system. Multifocal tumors were characterized by multiple foci of tumor cells found in the same breast quadrant with intervening ordinary stroma. Vascular invasion was determined by immunohistochemistry



(IHC) of CD34 and CD31 (BD Pharmingen) to detect blood vessels and podoplanin/D2-40 (Signet antibodies) to detect lymphatic vessels. Estrogen receptor (ER)- and progesterone receptor (PR)-positivity was evaluated by IHC with monoclonal antibodies (Ventana/Roche) with a cut-off for positivity set to >10%. Human epidermal growth factor receptor 2 (HER2) status was determined according to international standards [30]. Ki67 expression was measured with the antibody M1B1 (DAKO) and the cut-off for positivity was set to >20% positively stained tumor cells.

### *Statistical analysis*

The number of patients with positive CTCs was too small to perform any correlation tests or multivariate analysis. A paired t-test was used to determine if there was a statistically significant difference between the pressure exerted over the tumor and the surrounding breast parenchyma. A Mann-Whitney test was used to assess differences between symptomatic and asymptomatic subjects with regard to tumor characteristics. All analyses were performed using the SPSS software (version 20; SPSS Inc, Chicago, IL, USA) and *P*-values < 0.05 were considered statistically significant.

## **Results**

### *Pathology findings*

The median age of the subjects was 66.5 years (range, 51-87 years). Eleven (46%) of the subjects were symptomatic and 13 (54%) were asymptomatic. Of the 24 subjects, 15 (63%) had invasive ductal carcinomas (IDC), three (13%) had invasive lobular carcinomas (ILC), four (17%) had other types of carcinoma, one (4%) had non-Hodgkin's lymphoma and one (4%) had a benign cyst (Table 1). The median pathological tumor size was 19 mm (range, 9-30 mm). Twelve (55%) of the malignant breast tumors were histologic grade 1 or 2 and eight

(36%) were grade 3. Four (18%) were HER2 positive, six (27%) were ER-negative and eleven (50%) were PR-negative. One (5%) of the subjects showed vascular invasion and 13 (59%) had Ki67 > 20%. There were no apparent differences between tumor characteristics in symptomatic and asymptomatic women ( $P > 0.05$ ), but a trend for larger tumor sizes was seen in the symptomatic group ( $P = 0.10$ ).

### *Pressure*

The average applied compression force over the breast with pressure sensors attached was  $105.1 \pm 17.6$  N (range, 54-132 N). The average breast thickness in the same projection was  $45.1 \pm 12.2$  mm (range, 19-73 mm).

The average maximum tumor pressure was  $10.1 \pm 8.4$  kPa (range, 1.0-36.1 kPa) and the average mean tumor pressure was  $6.8 \pm 5.3$  kPa (range, 1.0-22.5 kPa). The difference between the average mean tumor pressure and the average mean breast pressure  $3.4 \pm 1.6$  kPa (range, 1.5-7.1 kPa) was statistically significant ( $P < 0.001$ ). Thus, the pressure was, on average, higher over the tumor compared to the rest of the breast and confirms that there is substantial pressure over the tumor. An example of a composite image with pressure data displayed as a color overlay is shown in Figure 3.

### *CTC evaluation*

Four subjects (17%) were CTC positive before compression and two of these (8%) were also CTC positive after compression. A total of seven CTCs were isolated with a mean size of  $8 \times 6$   $\mu\text{m}$  (range of longest diameter, 5-12  $\mu\text{m}$ ) (Figure 4). No relationships could be found between the presence of CTC and applied pressure or any pathological factors. An interesting

observation, however, is that the two patients with CTC positive results before and after compression had a tumor size above the median (25 and 30 mm, respectively) (Table 1).

## **Discussion**

This study aimed at investigating whether malignant tumor cells are shed and detectable in peripheral venous blood during mammographic compression. To the authors' knowledge, this is the first study investigating this issue. In this pilot study we found no evidence of tumor cell shedding to the peripheral blood, as opposed to a substantial number of animal studies [9-12], surgery shedding studies [4-8] and letters of concern [1-3] regarding tumor cell shedding following manipulation of the primary tumor. The presence of  $\geq 1$  CTC in 17% of our subjects is close to the span of other studies (using different volumes of blood) of primary breast cancer patients (19-31%) [15, 18, 20, 22, 31]. We could not find any relationship between the presence of CTCs and tumor characteristics (Table 1), which is consistent with other studies that have also found a lack of correlation between CTCs and histopathological factors [18, 29, 32]. We assumed that cancers with a medullary growth pattern including some grade 3 invasive ductal cancers which are often also well vascularized would be more prone to microruptures and shedding than cancers with productive fibrosis like many grade 1 and 2 ductal and lobular cancers. Our material might be too small to exclude such a possibility.

One (4%) of our CTC positive subjects had a benign cyst. The reported percentages of patients with benign disease that are CTC positive are between 8% [26] and 15% [22].

Whether or not CTCs in patients with benign disease are dangerous is currently unclear. It is possible that these cells are either non-malignant epithelial cells that have been stimulated to migration by inflammatory cytokines or actual malignant CTCs released from a pre-malignant lesion as discussed in benign colon disease [33].

We found that the pressure over the tumor was higher than over the rest of the breast, which is attributed to the difference in tissue elasticity between abnormal and normal tissue structures. The pressure over the tumor from manipulating the breast during positioning and subsequent compression is in general quite low. Clinical exams/palpation would result in pressures to the tumor exceeding those applied in the current study [34]. However, it is occasionally seen that a cyst disappears after mammography, supposedly due to rupture [35].

A few concerns regarding the probability to find CTCs in the present study should be addressed. First, CTC enumeration follows a Poisson distribution and is limited by the sampling error inherent to rare event detection and the fact that only ~ 0.15% (7.5 ml) of the total blood volume (5 l) is sampled [26]. In this study two samples were collected before and after compression (30 ml in total) for increased sensitivity. Second, despite its status as an FDA-approved method, one limitation of the CellSearch® system is that only CTCs expressing the epithelial marker EpCam will be detected. EpCam is likely to be (partly) downregulated during epithelial mesenchymal transition (EMT), which is the process when tumor cells leave the primary tumor to enter the blood stream [36]. An EpCam-based method could thus lack the possibility to identify the most stem-like and aggressive cancer cells in the blood circulation. Also, cells in the “normal-like” subgroup of breast cancer sometimes lack EpCam-expression [37] causing these cells to avoid detection in many enumeration methods used today. Third, there exist no reliable data regarding the CTC half-life in human subjects. Meng et al. estimate the half-life to be 1 to 2.4 hours [38]. The depletion kinetics of circulating prostate cancer cells were examined by Li et al. and they found that >70% of high-metastatic PC-3 cells and <30 % of low-metastatic LNCaP cells were depleted from the circulation after 1 hour following tail vein injection of BALB/c nude mice, respectively [39].

On the other hand Romsdahl et al. noticed a very fast depletion of CTCs with 93.6-99.6% percent reduction 4 minutes after tumor manipulation [10]. We collected our blood samples as fast as possible, on average 5.1 minutes after breast compression, limiting the possible half-life affect. But there is a risk that we missed the cell seeding by collecting the samples either within a too short or too long time frame. In general, the limited knowledge of the biology of CTCs and the process of metastasis is a limiting factor in detecting the total number of CTCs present in cancer patients.

One can speculate how a bolus of tumor cells to the blood would affect the patient prognosis. It is known that a decrease in the number of CTCs in metastatic breast cancer patients from unfavorable ( $\geq 5$  CTC/7.5 ml of blood) to favorable ( $<5$  CTC/7.5ml of blood) improves survival and could be used as a predictive factor of treatment response [13, 17]. However, only a fraction of the tumor cells that are shed into the bloodstream are believed to succeed in establishing secondary tumors [40]. There are also indications that trapped tumor cells in the lungs are destroyed due to mechanical aspects such as frictional and shearing forces [41]. Still, an increase of trapped malignant cells to the lungs would likely increase the risk of metastasis [11].

The pathways of possible CTCs originating from primary breast cancers are largely undetermined. In order to reach the peripheral veins (from where blood was drawn in this study) CTCs need to pass both the capillaries of the lungs and the capillary beds of the extremities without being trapped. This process is poorly understood, as the size of a CTC is often in the order of 5-12  $\mu\text{m}$  (and sometimes considerably larger) compared to the capillaries internal diameters of around 3-7  $\mu\text{m}$ . In addition, carcinoma cells are not especially deformable compared to erythrocytes, making CTCs ill suited for passage [42]. Possible

explanations of CTCs bypassing capillaries are that they become smaller by pinching off large amounts of cytoplasm, or that they travel through arterio-venous shunts [43]. Thus, we cannot exclude the dissemination of tumor cells as a result of applied breast compression; however, the cells might not reach the peripheral blood due to filtration in the capillary beds. For example, grade 3 tumors in general have larger, polymorphous cells and should thus have a greater tendency to be trapped in the lung capillaries. Animal studies indicate that the majority of cancer cells injected intravenously are arrested in the microvasculature of the lungs [42, 44, 45] and that the passage through small capillaries is also tumor dependent [46]. Furthermore, the CTC count has been shown to be higher in the central veins compared to the peripheral veins [47-49]. As an extension of the current study on the effect of breast compression we intend to draw blood from the superior vena cava in breast cancer patients, in addition to peripheral vein sampling, in order to assess the sieving of CTCs in the lung capillaries.

## **Conclusions**

This pilot study supports the view that mammography is a safe procedure from the point of view of malignant cell shedding to peripheral blood.

## **Abbreviations**

CC: craniocaudal; CTC: circulating tumor cell; EMT: epithelial mesenchymal transition; ER: estrogen receptor; FSR: force sensing resistor; HER2: human epidermal growth factor receptor 2; IDC: invasive ductal carcinoma; IHC: immunohistochemistry; ILC: invasive lobular carcinoma; LM: lateromedial; MLO: mediolateral oblique; PR: progesterone receptor;

## **Authors' contribution**

All authors (DF, IA, RE, MD, LR, AT, SZ and KA) made substantial contributions to conception and design, writing and critical review of the manuscript. In addition: IA conceived of the study. DF, IA and MD coordinated the data acquisition. IA, RE, LR and SZ participated in data interpretation. DF performed the statistical analysis. KA performed the blood sample analysis. AT and SZ were responsible for financial support. All authors read and approved the final manuscript.

### **Competing interests**

The authors declare that they have no competing interests.

### **Acknowledgements**

The authors would like to thank G. Dinnetz, E. Edvik and E. Undrén for logistics and blood sample collection; S. Baker and C. Welinder for processing blood samples. We also thank Gunnar Nilssons Cancerstiftelse, Magnus Bergvalls Stiftelse, Region Skåne (regional forskningsstöd) and Stiftelsen för cancerforskning vid Onkologiska kliniken vid Universitetssjukhuset MAS, for financial support.

## References

1. Watmough DJ, Quan KM: **X-ray mammography and breast compression.** *Lancet* 1992, **340**:122.
2. Watmough DJ, Quan KM, Aspden RM: **Breast compression: a preliminary study.** *J Biomed Eng* 1993, **15**:121-126.
3. van Netten JP, Cann SA, Glover DW: **Mammographic compression: a force to be reckoned with.** *Br J Cancer* 1999, **81**:1426-1427.
4. Choy A, McCulloch P: **Induction of tumour cell shedding into effluent venous blood breast cancer surgery.** *Br J Cancer* 1996, **73**:79-82.
5. Hayashi N, Egami H, Kai M, Kurusu Y, Takano S, Ogawa M: **No-touch isolation technique reduces intraoperative shedding of tumor cells into the portal vein during resection of colorectal cancer.** *Surgery* 1999, **125**:369-374.
6. Yamaguchi K, Takagi Y, Aoki S, Futamura M, Saji S: **Significant detection of circulating cancer cells in the blood by reverse transcriptase-polymerase chain reaction during colorectal cancer resection.** *Ann Surg* 2000, **232**:58-65.
7. Weitz J, Koch M, Kienle P, Schrödel A, Willeke F, Benner A, Lehnert T, Herfarth C, von Knebel Doeberitz M: **Detection of hematogenic tumor cell dissemination in patients undergoing resection of liver metastases of colorectal cancer.** *Ann Surg* 2000, **232**:66-72.



8. Uchikura K, Takao S, Nakajo A, Miyazono F, Nakashima S, Tokuda K, Matsumoto M, Shinchi H, Natsugoe S, Aikou T: **Intraoperative molecular detection of circulating tumor cells by reverse transcription-polymerase chain reaction in patients with biliary-pancreatic cancer is associated with hematogenous metastasis.** *Ann Surg Oncol* 2002, **9**:364-370.
9. Tyzzer EE: **Factors in the Production and Growth of tumor Metastases.** *J Med Res* 1913, **28**:309-332.
10. Romsdahl MM, McGrath RG, Hoppe E, McGrew EA: **Experimental model for the study of tumor cells in the blood.** *Acta Cytol* 1965, **9**:141-145.
11. Liotta LA, Kleinerman J, Saidel GM: **Quantitative relationships of intravascular tumor cells, tumor vessels, and pulmonary metastases following tumor implantation.** *Cancer Res* 1974, **34**:997-1004.
12. Nishizaki T, Matsumata T, Kanematsu T, Yasunaga C, Sugimachi K: **Surgical manipulation of VX2 carcinoma in the rabbit liver evokes enhancement of metastasis.** *J Surg Res* 1990, **49**:92-97.
13. Cristofanilli M, Budd GT, Ellis MJ, Stopeck A, Matera J, Miller MC, Reuben JM, Doyle GV, Allard WJ, Terstappen LW, Hayes DF: **Circulating tumor cells, disease progression, and survival in metastatic breast cancer.** *N Engl J Med* 2004, **351**:781-791.

14. de Bono JS, Scher HI, Montgomery RB, Parker C, Miller MC, Tissing H, Doyle GV, Terstappen LW, Pienta KJ, Raghavan D: **Circulating tumor cells predict survival benefit from treatment in metastatic castration-resistant prostate cancer.** *Clin Cancer Res* 2008, **14**:6302-6309.

15. Bidard FC, Mathiot C, Delaloge S, Brain E, Giachetti S, de Cremoux P, Marty M, Pierga JY: **Single circulating tumor cell detection and overall survival in nonmetastatic breast cancer.** *Ann Oncol* 2010, **21**:729-733.

16. Budd GT, Cristofanilli M, Ellis MJ, Stopeck A, Borden E, Miller MC, Matera J, Repollet M, Doyle GV, Terstappen LW, Hayes DF: **Circulating tumor cells versus imaging--predicting overall survival in metastatic breast cancer.** *Clin Cancer Res* 2006, **12**:6403-6409.

17. Hayes DF, Cristofanilli M, Budd GT, Ellis MJ, Stopeck A, Miller MC, Matera J, Allard WJ, Doyle GV, Terstappen LW: **Circulating tumor cells at each follow-up time point during therapy of metastatic breast cancer patients predict progression-free and overall survival.** *Clin Cancer Res* 2006, **12**:4218-4224.

18. Krishnamurthy S, Cristofanilli M, Singh B, Reuben J, Gao H, Cohen EN, Andreopoulou E, Hall CS, Lodhi A, Jackson S, Lucci A: **Detection of minimal residual disease in blood and bone marrow in early stage breast cancer.** *Cancer* 2010, **116**:3330-3337.

19. Stathopoulou A, Vlachonikolis I, Mavroudis D, Perraki M, Kouroussis Ch, Apostolaki S, Malamos N, Kakolyris S, Kotsakis A, Xenidis N, Reppa D, Georgoulas V: **Molecular**

**detection of cytokeratin-19-positive cells in the peripheral blood of patients with operable breast cancer: evaluation of their prognostic significance.** *J Clin Oncol* 2002, **20**:3404-3412.

20. Rack B, Schindlbeck C, Andergassen U, Lorenz R, Zwingers T, Schneeweiss A, Lichtenegger W, Beckmann MW, Sommer H, Pantel K, Friese K, Janni W: **Prognostic relevance of circulating tumor cells in the peripheral blood of primary breast cancer patients.** In *33rd Annual San Antonio Breast Cancer Symposium: 8-12 December 2010; San Antonio, USA*. abstr 503.

21. Lucci A, Hall CS, Lodhi AK, Bhattacharyya A, Anderson AE, Xiao L, Bedrosian I, Kuerer HM, Krishnamurthy S: **Circulating tumour cells in non-metastatic breast cancer: a prospective study.** *Lancet Oncol* 2012, **13**:688-695.

22. Franken B, de Groot MR, Mastboom WJ, Vermes I, van der Palen J, Tibbe AG, Terstappen LW: **Circulating tumor cells, disease recurrence and survival in newly diagnosed breast cancer.** *Breast Cancer Res* 2012, **14**:R133.

23. Dustler M, Andersson I, Brorson H, Fröjd P, Mattsson S, Tingberg A, Zackrisson S, Förnvik D: **Breast compression in mammography: pressure distribution patterns.** *Acta Radiol* 2012, **53**:973-980.

24. Luo ZP, Berglund LJ, An KN: **Validation of F-Scan pressure sensor system: a technical note.** *J Rehabil Res Dev* 1998, **35**:186-191.

25. Morin EL, Bryant JT, Reid SA, Whiteside RA: **Calibration issues of Tekscan systems for human pressure assessment.** In *RTO meeting proceedings 56 - Soldier Mobility: Innovations in Load Carriage System Design and Evaluation: May 2001; Ottawa/Hull: St Joseph, Canada.* 2001:251–257.
26. Allard WJ, Matera J, Miller MC, Repollet M, Connelly MC, Rao C, Tibbe AG, Uhr JW, Terstappen LW: **Tumor cells circulate in the peripheral blood of all major carcinomas but not in healthy subjects or patients with nonmalignant diseases.** *Clin Cancer Res* 2004, **10**:6897-6904.
27. Riethdorf S, Fritsche H, Müller V, Rau T, Schindlbeck C, Rack B, Janni W, Coith C, Beck K, Jänicke F, Jackson S, Gornet T, Cristofanilli M, Pantel K: **Detection of circulating tumor cells in peripheral blood of patients with metastatic breast cancer: a validation study of the CellSearch system.** *Clin Cancer Res* 2007, **13**:920-928.
28. Tibbe AG, Miller MC, Terstappen LW: **Statistical considerations for enumeration of circulating tumor cells.** *Cytometry A* 2007, **71**:154-162.
29. Pierga JY, Bidard FC, Mathiot C, Brain E, Delaloge S, Giachetti S, de Cremoux P, Salmon R, Vincent-Salomon A, Marty M: **Circulating tumor cell detection predicts early metastatic relapse after neoadjuvant chemotherapy in large operable and locally advanced breast cancer in a phase II randomized trial.** *Clin Cancer Res* 2008, **14**:7004-7010.

30. Wolff AC, Hammond ME, Schwartz JN, Hagerty KL, Allred DC, Cote RJ, Dowsett M, Fitzgibbons PL, Hanna WM, Langer A, McShane LM, Paik S, Pegram MD, Perez EA, Press MF, Rhodes A, Sturgeon C, Taube SE, Tubbs R, Vance GH, van de Vijver M, Wheeler TM, Hayes DF: **American Society of Clinical Oncology/College of American Pathologists guideline recommendations for human epidermal growth factor receptor 2 testing in breast cancer.** *J Clin Oncol* 2007, **25**:118-145.
31. Biggers B, Knox S, Grant M, Kuhn J, Nemunaitis J, Fisher T, Lamont J: **Circulating tumor cells in patients undergoing surgery for primary breast cancer: preliminary results of a pilot study.** *Ann Surg Oncol* 2009, **16**:969-971.
32. Riethdorf S, Müller V, Zhang L, Rau T, Loibl S, Komor M, Roller M, Huober J, Fehm T, Schrader I, Hilfrich J, Holms F, Tesch H, Eidtmann H, Untch M, von Minckwitz G, Pantel K: **Detection and HER2 expression of circulating tumor cells: prospective monitoring in breast cancer patients treated in the neoadjuvant GeparQuattro trial.** *Clin Cancer Res* 2010, **16**:2634-2645.
33. Pantel K, Denève E, Nocca D, Coffy A, Vendrell JP, Maudelonde T, Riethdorf S, Alix-Panabières C: **Circulating epithelial cells in patients with benign colon diseases.** *Clin Chem* 2012, **58**:936-940.
34. Kopans DB: **Physical trauma and breast cancer.** *Lancet* 1994, **343**:1364-1365.
35. Pennes DR, Homer MJ: **Disappearing breast masses caused by compression during mammography.** *Radiology* 1987, **165**:327-328.

36. Raimondi C, Gradilone A, Naso G, Vincenzi B, Petracca A, Nicolazzo C, Palazzo A, Saltarelli R, Spremberg F, Cortesi E, Gazzaniga P: **Epithelial-mesenchymal transition and stemness features in circulating tumor cells from breast cancer patients.** *Breast Cancer Res Treat* 2011, **130**:449-455.
37. Spizzo G, Went P, Dirnhofer S, Obrist P, Simon R, Spichtin H, Maurer R, Metzger U, von Castelberg B, Bart R, Stopatschinskaya S, Köchli OR, Haas P, Mross F, Zuber M, Dietrich H, Bischoff S, Mirlacher M, Sauter G, Gastl G: **High Ep-CAM expression is associated with poor prognosis in node-positive breast cancer.** *Breast Cancer Res Treat* 2004, **86**:207-213.
38. Meng S, Tripathy D, Frenkel EP, Shete S, Naftalis EZ, Huth JF, Beitsch PD, Leitch M, Hoover S, Euhus D, Haley B, Morrison L, Fleming TP, Herlyn D, Terstappen LW, Fehm T, Tucker TF, Lane N, Wang J, Uhr JW: **Circulating tumor cells in patients with breast cancer dormancy.** *Clin Cancer Res* 2004, **10**:8152-8162.
39. Li Y, Guo J, Wang C, Fan Z, Liu G, Wang C, Gu Z, Damm D, Mosig A, Wei X: **Circulation times of prostate cancer and hepatocellular carcinoma cells by in vivo flow cytometry.** *Cytometry A* 2011, **79**:848-854.
40. Weiss L: **Metastatic inefficiency.** *Adv Cancer Res* 1990, **54**:159-211.
41. Weiss L, Orr FW, Honn KV: **Interactions between cancer cells and the microvasculature: a rate-regulator for metastasis.** *Clin Exp Metastasis* 1989, **7**:127-167.

42. Weiss L, Orr FW, Honn KV: **Interactions of cancer cells with the microvasculature during metastasis.** *FASEB J* 1988, **2**:12-21.
43. Weinberg RA: **Moving out: invasion and metastasis.** In *The biology of cancer*. Edited by Weinberg RA. New York: Garland Science, Taylor & Francis Group; 2007:587-654.
44. Fidler IJ: **Metastasis: quantitative analysis of distribution and fate of tumor emboli labeled with 125 I-5-iodo-2'-deoxyuridine.** *J Natl Cancer Inst* 1970, **45**:773-782.
45. Mizuno N, Kato Y, Shirota K, Izumi Y, Irimura T, Harashima H, Kiwada H, Motoji N, Shigematsu A, Sugiyama Y: **Mechanism of initial distribution of blood-borne colon carcinoma cells in the liver.** *J Hepatol* 1998, **28**:878-885.
46. Zeidman I: **The fate of circulating tumors cells. I. Passage of cells through capillaries.** *Cancer Res* 1961, **21**:38-39.
47. Jiao LR, Apostolopoulos C, Jacob J, Szydlo R, Johnson N, Tsim N, Habib NA, Coombes RC, Stebbing J: **Unique localization of circulating tumor cells in patients with hepatic metastases.** *J Clin Oncol* 2009, **27**:6160-6165.
48. Wind J, Tuynman JB, Tibbe AG, Swennenhuis JF, Richel DJ, van Berge Henegouwen MI, Bemelman WA: **Circulating tumour cells during laparoscopic and open surgery for primary colonic cancer in portal and peripheral blood.** *Eur J Surg Oncol* 2009, **35**:942-950.

49. Peeters DJ, Van den Eynden GG, van Dam PJ, Prové A, Benoy IH, van Dam PA, Vermeulen PB, Pauwels P, Peeters M, Van Laere SJ, Dirix LY: **Circulating tumour cells in the central and the peripheral venous compartment in patients with metastatic breast cancer.** *Br J Cancer* 2011, **104**:1472-1477.



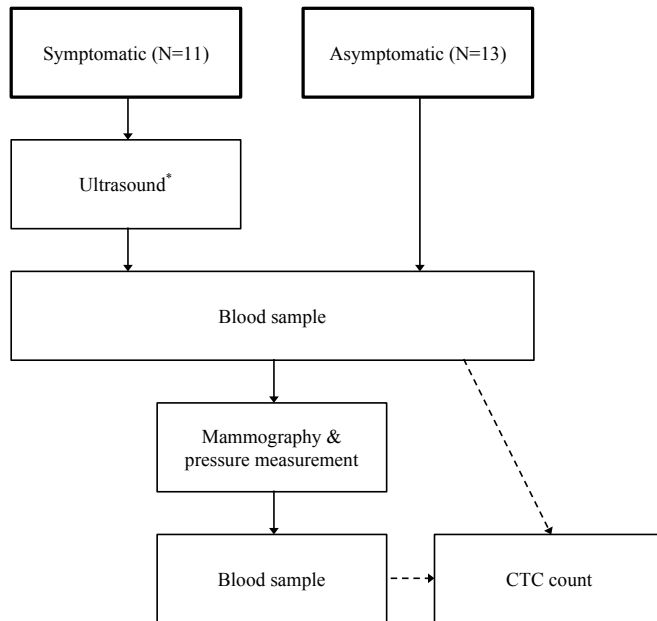
Table 1. Tumor characteristics and descriptive data of the 24 study subjects.

Subject	Age [years]	CTC before	CTC after	Maximum tumor pressure [kPa]	Tumor Size [mm]	Nodal status	Histology	Histological grade	Multifocal	Vascular invasion	ER	PR	HER2	Ki-67 [%]
1 (a)	66	0	0	13	21	-	IDC	3	+	-	+	+	-	50
2 (a)	70	0	0	7	13	-	IDC	3	-	-	-	-	-	70
3 (s)	85	0	0	9	NA	NA	Non- Hodgkin's lymphoma	NA	NA	NA	NA	NA	NA	NA
4 (a)	65	1	1	10	30	-	IDC	2	-	-	+	+	-	15
5 (a)	51	0	0	11	19	-	Medullary carcinoma	3	-	-	-	-	-	80
6 (a)	51	0	0	10	12	-	IDC	2	-	-	+	+	-	25
7 (s)	83	0	0	4	17	-	Intracystic papillary carcinoma	2	-	NA	+	+	-	NA
8 (a)	58	1	0	7	13	-	IDC	1	-	-	+	-	-	14
9 (a)	61	0	0	1	11	-	IDC	3	-	-	+	+	-	30
10 (s)	85	0	0	14	22	+	IDC	3	-	-	+	-	+	75
11 (a)	64	0	0	4	9	-	Metaplastic carcinoma	3	-	-	-	-	+	30
12 (s)	87	0	0	12	19	-	IDC	2	+	-	+	+	-	17
13 (s)	78	0	0	11	25	-	IDC	3	-	-	-	-	+	35
14 (s)	77	1	0	3	NA	NA	Benign cyst	NA	NA	NA	NA	NA	NA	NA
15 (a)	63	0	0	20	20	+	IDC	1	-	+	+	+	-	15
16 (s)	83	0	0	2	19	-	IDC	2	-	-	+	+	-	21
17 (s)	67	0	0	6	22	+	ILC	2	-	-	+	+	-	5
18 (s)	58	0	0	36	12	+	IDC	1	-	-	+	-	-	10
19 (a)	63	0	0	24	15	-	IDC	2	-	-	+	-	+	45
20 (s)	81	2	1	4	25	+	ILC	3	-	-	+	-	-	24
21 (a)	70	0	0	17	10	+	ILC	1	+	-	+	+	-	13
22 (s)	63	0	0	3	25	-	IDC	3	-	-	-	-	-	80
23 (a)	72	0	0	6	17	-	IDC	3	-	-	+	+	-	25
24 (a)	66	0	0	NA	30	+	Apocrine carcinoma	2	-	-	-	-	-	21

Abbreviations: a, asymptomatic; s, symptomatic; NA, not applicable; ER, estrogen receptor;

PR, progesterone receptor; HER2, human epidermal growth factor receptor 2; IDC, invasive

ductal carcinoma; ILC, invasive lobular carcinoma.



\*As a first step in the investigation the cancer suspicion was verified by an ultrasound examination of the tumor area applying as little pressure as possible.

Figure 1. Flowchart of the study.




Figure 2. Two FSR pressure sensors fastened underneath the compression paddle.

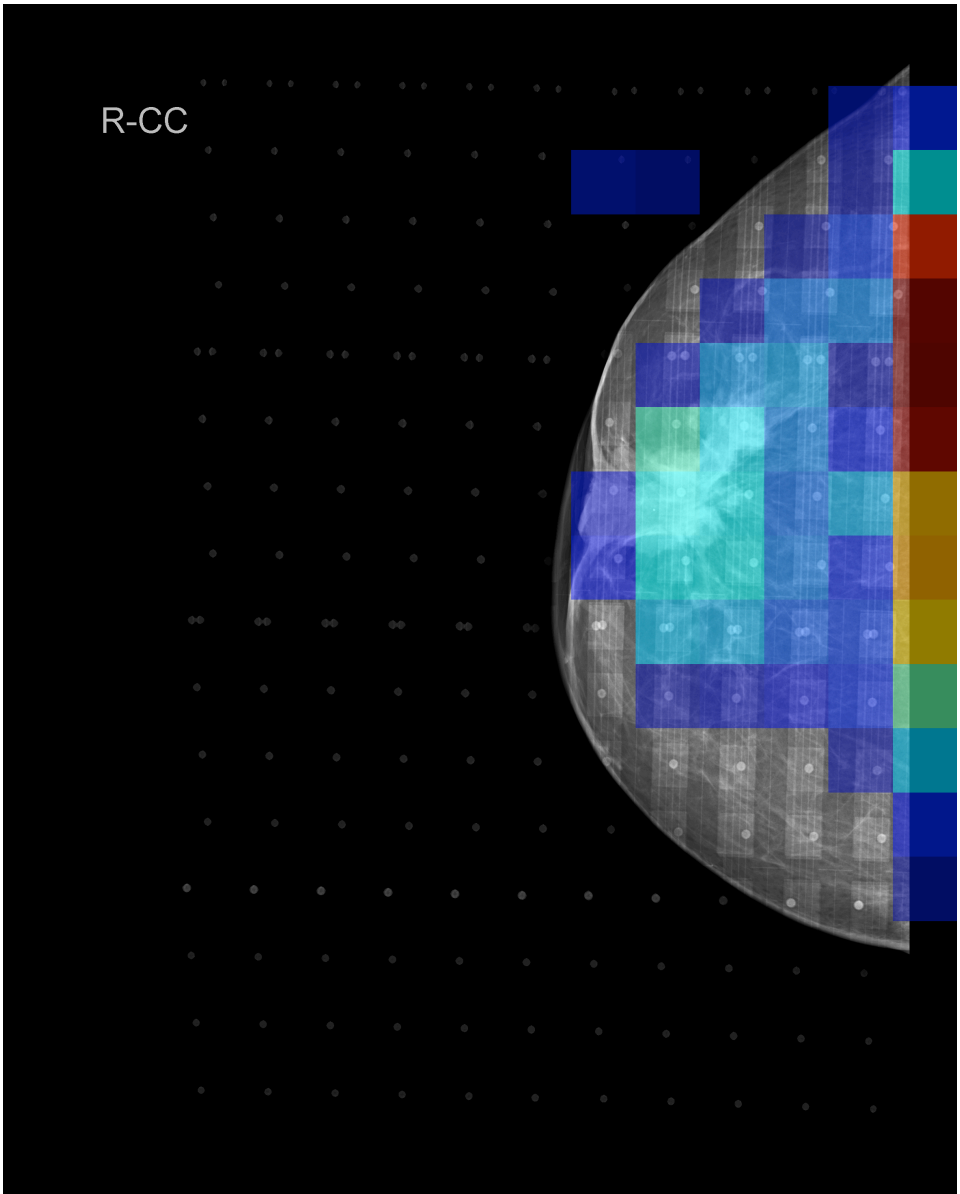


Figure 3. A 65 year-old woman (subject 4) with a 30 mm, grade 2, invasive ductal carcinoma. Note the spiculated tumor with retraction of the nipple-areolar complex. Pressure is shown on a scale from dark blue (lowest) to dark red (highest). The maximum tumor pressure was 10 kPa (mean tumor pressure, 8.9 kPa). This patient had 1 CTC before compression and 1 CTC after compression.

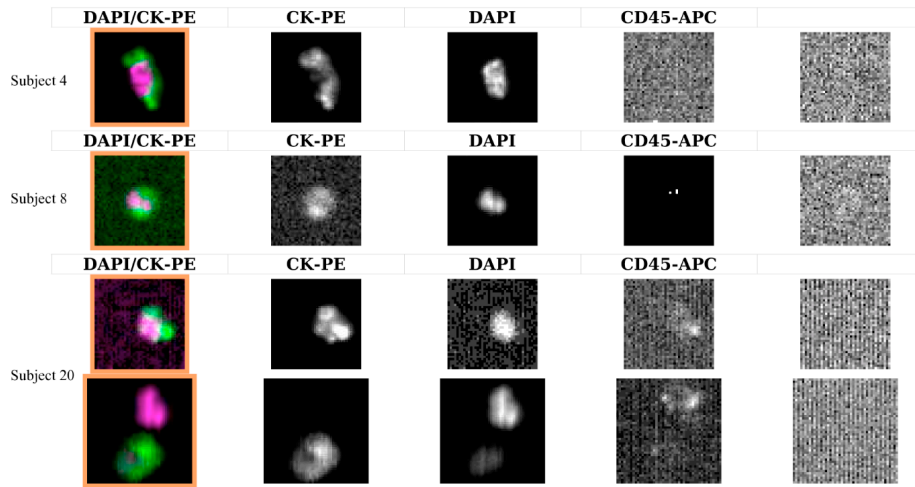


Figure 4. Example of CTCs from the subjects with malignant disease in the study. The analysis was performed with the CellSearch<sup>®</sup> system (Veridex) and cells positive for CK-PE/DAPI and negative for CD45-APC/control (right column) were considered CTCs.

