



LUND UNIVERSITY

Negative Pressure Wound Therapy - Mechanisms of Action and Protecting Exposed Blood Vessels in the Wound Bed

Anesäter, Erik

2015

[Link to publication](#)

Citation for published version (APA):

Anesäter, E. (2015). *Negative Pressure Wound Therapy - Mechanisms of Action and Protecting Exposed Blood Vessels in the Wound Bed*. [Doctoral Thesis (compilation), Thoracic Surgery]. Thoracic Surgery.

Total number of authors:

1

General rights

Unless other specific re-use rights are stated the following general rights apply:

Copyright and moral rights for the publications made accessible in the public portal are retained by the authors and/or other copyright owners and it is a condition of accessing publications that users recognise and abide by the legal requirements associated with these rights.

- Users may download and print one copy of any publication from the public portal for the purpose of private study or research.
- You may not further distribute the material or use it for any profit-making activity or commercial gain
- You may freely distribute the URL identifying the publication in the public portal

Read more about Creative commons licenses: <https://creativecommons.org/licenses/>

Take down policy

If you believe that this document breaches copyright please contact us providing details, and we will remove access to the work immediately and investigate your claim.

LUND UNIVERSITY

PO Box 117
221 00 Lund
+46 46-222 00 00

Negative Pressure Wound Therapy

Mechanisms of Action and Protecting Exposed Blood Vessels in the Wound Bed

Erik Anesäter, MD



LUND UNIVERSITY
Faculty of Medicine

DOCTORAL DISSERTATION

by due permission of the Faculty of Medicine, Lund University, Sweden.
To be defended 13.00 the 20th of March 2015, in Segerfalksalen at BMC
Lund.

Faculty opponent

Gunnar Kratz MD, PhD
Professor of Plastic Surgery, Linköping University, Sweden

Organization LUND UNIVERSITY. Department of clinical sciences, Lund. Faculty of Medicine.		Document name DOCTORAL DISSERTATION	
		Date of issue: 19/2 2015	
Title: Negative Pressure Wound Therapy - Mechanisms of action and Protecting Exposed Blood Vessels in the Wound Bed			
<p>Abstract: NPWT has recently been associated with severe complications and bleeding when used in wounds with exposed blood vessels. The aims of this work were to investigate the mechanisms of action of NPWT and to explore the possibility of using thin plastic discs to protect exposed blood vessels in the wound bed during NPWT.</p> <p>Three different kinds of wounds were created in pigs: 6 cm and 10 cm diameter circular defect wounds on the back and 6 cm incision wounds in the groin, exposing the femoral artery. Microvascular blood flow was studied with transcutaneous laser Doppler flowmetry (LDF), invasive LDF, and thermodiffusion. Femoral artery blood flow was studied with invasive LDF. Pressure in the wound edge tissue, in the wound cavity and periarterial pressure was measured with pressure transducers. Wound contraction and wound fluid removal were also studied.</p> <p>Tissue pressure 0.1 cm from the wound edge decreased while an increase was found further (0.5 cm) from the wound edge. Increased tissue pressure is believed to be the result of wound contraction and wound edge tissue deformation. The use of a small foam wound filler allowed significant wound contraction, which may result in considerable mechanical stress. In contrast, gauze or a large foam filler led to less wound contraction, which may be more appropriate when NPWT causes pain.</p> <p>Furthermore, NPWT induced a decrease in blood flow 0.5 cm, and an increase 2.5 cm from the wound edge, with a transition zone at 1 cm. This combination of hypo- and hyperperfusion may facilitate both oxygenation and stimulate angiogenesis. However, NPWT should be used with caution in tissues with compromised vascularity due to the risk of ischemia.</p> <p>Thin plastic discs of different designs were placed in the wound bed during NPWT. Femoral artery blood flow and wound bed tissue blood flow decreased when NPWT was applied, but was restored when a disc was inserted. The key mechanisms of NPWT – i.e., pressure transmission to the wound cavity, wound contraction, and wound fluid removal – were not impaired by the discs. Further development and studies on the possible protective effects of thin plastic discs used during NPWT are needed before these can be implemented in clinical practice.</p>			
Key words: Negative pressure wound therapy, wounds, complications, experimental surgery, blood flow			
Classification system and index terms (if any)		Language: English	
Supplementary bibliographical information		ISBN: 978-91-7619-103-3	
ISSN and key title: 1652-8220 Negative Pressure Wound Therapy - Mechanisms of Action and Protecting Exposed Blood Vessels in the Wound Bed		Number of pages: 100	
Recipient's notes		Security classification	Price

Signature  Date 9/2-15

Negative Pressure Wound Therapy

Mechanisms of Action and Protecting Exposed Blood Vessels in the Wound Bed

Erik Anesäter, MD



LUND UNIVERSITY
Faculty of Medicine

Clinical Sciences, Lund

Lund University

Sweden

2015

Copyright Erik Anesäter

Lund University, Faculty of Medicine, Doctoral Dissertation Series 2015:24

ISBN 978-91-7619-103-3

ISSN 1652-8220

Printed in Sweden by Media-Tryck, Lund University

Lund 2015



**CLIMATE
COMPENSATED
PAPER**



REPA[®]
A part of FTI (the Packaging and
Newspaper Collection Service)

If you can't explain it simply, you don't understand it well enough.

- Albert Einstein

Abstract

NPWT has recently been associated with severe complications and bleeding when used in wounds with exposed blood vessels. The aims of this work were to investigate the mechanisms of action of NPWT and to explore the possibility of using thin plastic discs to protect exposed blood vessels in the wound bed during NPWT.

Three different kinds of wounds were created in pigs: 6 cm and 10 cm diameter circular defect wounds on the back and 6 cm incision wounds in the groin, exposing the femoral artery. Microvascular blood flow was studied with transcutaneous laser Doppler flowmetry (LDF), invasive LDF, and thermodiffusion. Femoral artery blood flow was studied with invasive LDF. Pressure in the wound edge tissue, in the wound cavity and periarterial pressure was measured with pressure transducers. Wound contraction and wound fluid removal were also studied.

Tissue pressure 0.1 cm from the wound edge decreased while an increase was found further (0.5 cm) from the wound edge. Increased tissue pressure is believed to be the result of wound contraction and wound edge tissue deformation. The use of a small foam wound filler allowed significant wound contraction, which may result in considerable mechanical stress. In contrast, gauze or a large foam filler led to less wound contraction, which may be more appropriate when NPWT causes pain.

Furthermore, NPWT induced a decrease in blood flow 0.5 cm, and an increase 2.5 cm from the wound edge, with a transition zone at 1 cm. This combination of hypo- and hyperperfusion may facilitate both oxygenation and stimulate angiogenesis. However, NPWT should be used with caution in tissues with compromised vascularity due to the risk of ischemia.

Thin plastic discs of different designs were placed in the wound bed during NPWT. Femoral artery blood flow and wound bed tissue blood flow decreased when NPWT was applied, but was restored when a disc was inserted. The key mechanisms of NPWT – i.e., pressure transmission to the wound cavity, wound contraction, and wound fluid removal – were not impaired by the discs. Further development and studies on the possible protective effects of thin plastic discs used during NPWT are needed before these can be implemented in clinical practice.

Papers included in this thesis

This thesis is based on the following five papers, which will be referred to in the text by their Roman numerals. The papers are reproduced with the permission of the respective publisher.

- I. **Anesäter E**, Borgquist O, Hedström E, Waga J, Ingemansson R, & Malmsjö M. *The influence of different sizes and types of wound fillers on wound contraction and tissue pressure during negative pressure wound therapy*. International Wound Journal, 2011;8 (4):336-42
- II. Borgquist O, **Anesäter E**, Hedström E, Lee C K, Ingemansson R, & Malmsjö M. *Measurements of wound edge microvascular blood flow during negative pressure wound therapy using thermodiffusion and transcutaneous and invasive laser Doppler flowmetry*. Wound Repair and Regeneration, 2011;19 (6):727-33*
- III. **Anesäter E**, Borgquist O, Torbrand C, Roupé K M, Ingemansson R, Lindstedt S, & Malmsjö M. *A rigid disc for protection of exposed blood vessels during negative pressure wound therapy*. Surgical Innovation, 2013;20 (1):74-80
- IV. **Anesäter E**, Borgquist O, Torbrand C, Roupé K M, Ingemansson R, Lindstedt S, & Malmsjö M. *The use of a rigid disc to protect exposed structures in wounds treated with negative pressure wound therapy: Effects on wound bed pressure and microvascular blood flow*. Wound Repair and Regeneration, 2012;20 (4):611-6
- V. **Anesäter E**, Roupé K M, Robertsson P, Borgquist O, Torbrand C, Ingemansson R, Lindstedt S, & Malmsjö M. *The influence on wound contraction and fluid evacuation of a rigid disc inserted to protect exposed organs during negative pressure wound therapy*. International Wound Journal, 2011;8 (4):393-9

*Paper II was also included in Dr. Ola Borgquists' thesis, Lund 2013:39

Contents

Introduction	1
Chronic wounds	1
The normal healing of wounds	2
Conventional wound treatment	3
Negative pressure wound therapy	5
Historical aspects of vacuum therapy	6
Mechanisms of NPWT	8
Complications associated with NPWT	11
Thesis at a glance	15
Aims	17
Methods	19
Ethical considerations	19
Animal preparation	20
Wound preparation	20
The design of the protective discs	22
Wound contraction and wound fillers	25
Pressure measurements	26
Blood flow measurements	29
Laser Doppler flowmetry	30
Thermodiffusion	33
Wound edge microvascular blood flow	34
Blood flow in the femoral artery	35
Microvascular blood flow in the wound bed	36
Measurement of wound fluid removal	36
Statistical analysis	37

Results and Discussion	39
Different types and sizes of wound fillers	39
Wound contraction	39
Wound cavity and wound edge tissue pressure	41
Microvascular blood flow & different measurement techniques	45
Microvascular blood flow 0.5 cm from the wound edge	45
Microvascular blood flow 1.0 cm from the wound edge	46
Microvascular blood flow 2.5 cm from the wound edge	48
The possibility of using discs to protect exposed blood vessels	50
Periarterial and wound cavity pressure	51
Blood flow in the femoral artery	53
Microvascular blood flow in the wound bed	55
Wound contraction	57
Fluid evacuation from the wound cavity	59
Reflections on the design of the discs	60
Conclusions	63
Different types and sizes of wound fillers	63
Microvascular blood flow & different measurement techniques	64
The possibility of using discs to protect exposed blood vessels	64
Future research	67
Popular scientific summary in Swedish	69
Acknowledgements	73
References	75

Introduction

During the past decade, NPWT has revolutionized the management of wounds (1). The treatment entails the application of vacuum to a sealed, airtight wound and initiates a cascade of interrelated biological reactions that ultimately lead to enhanced wound healing. However, there has recently been an increase in the number of reports of bleeding and serious complications associated with the use of NPWT, and the importance of protecting the heart and other exposed organs is now being emphasized in the scientific literature. The aim of the work described in this thesis was to clarify the mechanisms of action of NPWT and to develop techniques that could be used to protect exposed blood vessels in the wound bed. The field of research is described below, followed by the aims, the methods, the results and conclusions, as agreed in our research group and with the permission of the respective publisher.

Chronic wounds

Non-healing chronic wounds are the cause of significant concern, and are estimated to account for 2-4% of all health care expenses in developed countries (2). Chronic wounds are not only a financial burden, but also a social problem, leading to reduced quality of life due to pain, depression, loss of income, and impaired mobility (3). The problem of complex non-healing wounds is expected to increase considerably in the future due to the ageing population, and the expected increase in diseases such as type II diabetes mellitus and obesity.

In addition to the increasing incidence of chronic wounds, the need for post-surgical wound care is also increasing (4), with surgical site infections expected to occur in 3-4% of all patients undergoing surgery in European hospitals. As

the population ages, a sharp increase can also be expected in the number of patients undergoing surgery (5).

The normal healing of wounds

Wound healing is an intricate process consisting of a series of events that overlap and are dependent on each another. The course of wound healing is traditionally divided into *three phases: the inflammatory phase*, occurring immediately after the injury, *the proliferative phase* and, finally, *the maturation phase* (6).

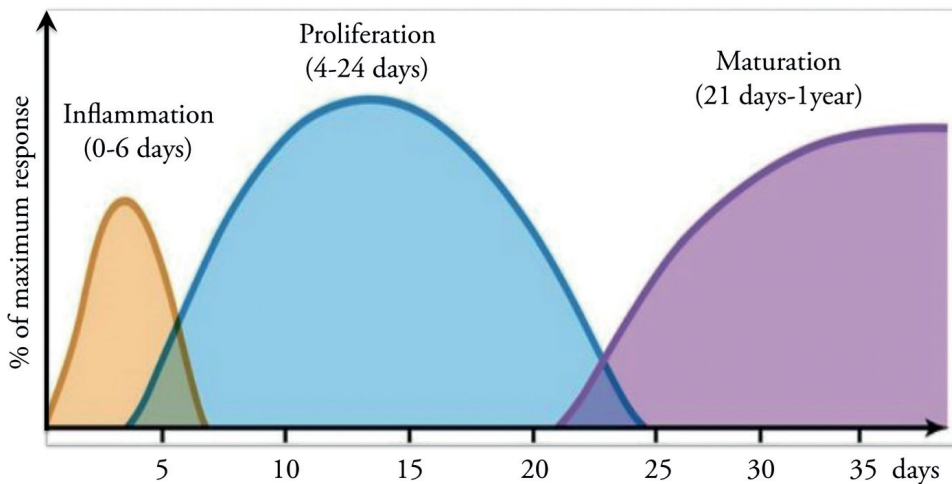


Figure 1. Illustration of the three phases of normal healing of an acute wound. Wound healing is initiated in the inflammatory phase (days 0-6), and is followed by the proliferative phase (days 4-24) and the maturation phase (day 21 up to 1 year). A chronic wound, however, remains in the inflammatory or the proliferative phase, and does not heal. Adopted from (6-8).

The inflammatory phase starts directly after the injury, and lasts for approximately 6 days. Immediately after the injury, platelets aggregate at the wound site and form a fibrin clot to stop bleeding. Once hemostasis is achieved, the blood vessels dilate and become more permeable causing an increase in exudate, which in turn facilitates the migration of inflammatory cells involved in the phagocytosis of bacteria and debris (6).

The proliferative phase follows the inflammatory phase, and typically lasts about 4 weeks (7). During this phase, vascular endothelial cells produce new blood vessels, a process referred to as angiogenesis (6). Fibroblasts produce collagen and fibronectin, creating a provisional extracellular matrix (6). Together with the newly formed blood vessels, the extracellular matrix forms granulation tissue. The proliferative phase also includes the formation of a new, thin epithelial cell layer, a process known as re-epithelialization, in which epithelial cells proliferate and bridge the wound. Re-epithelialization is accelerated if the environment around the wound is moist, as new epidermal cells travel faster across moist surfaces (9). Contraction of the wound, a very important part of wound healing in loose-skinned animals, also occurs in human wound healing. For example, on the back, neck and forearms, where the skin is not tightly bound to underlying structures, up to 80% of closure can be achieved by contraction. An undesirable effect of wound contraction is contracture, where the skin becomes too tight, reducing the range of motion. This may occur, for example, over joints (10).

Maturation or remodeling is the final phase. It starts once the wound has closed and can last for years (8). During the maturation phase, redundant cells are removed through apoptosis, and changes in the remaining tissue, through the remodeling of collagen, result in a scar that has similar properties to the parent tissue.

Wound healing is thus a dynamic and highly complex process involving a great diversity of cell types and soluble mediators. Acute wounds typically follow the phases described above. However, some wounds do not. They remain in the inflammatory or proliferative stage, leading to a chronic wound (11). Chronic wounds are normally defined as those persisting for more than 4 to 6 weeks, not showing the characteristics of normal wound healing (12). The majority of chronic wounds can be divided into four groups, namely: pressure ulcers, diabetic ulcers, arterial leg ulcers and venous leg ulcers (13, 14).

Conventional wound treatment

As each case is unique, the initial step in wound treatment is to assess the patient. For example, good glycemic control is important in diabetic patients, and those who smoke should be encouraged to give up the habit. If the patient

is suffering from edema, this should be adequately treated. Arterial blood circulation must also be assessed, and if found to be decreased, this must be addressed. Some patients may need to undergo revascularization surgery. Peripheral nerve function must also be investigated and if found to be reduced, as is common in diabetic patients, the use of offloading footwear should be considered (15). Typical considerations and strategies for the treatment of wounds have been described by a group wound care experts (Schultz et al.) (1, 16), and are described below.

The first step in treating a wound is wound cleaning and debridement, i.e., the removal of devitalized or non-functional tissue. The removal of necrotic, non-viable tissue has been shown to dramatically increase wound healing (17).

Managing inflammation and infection is the next step. Chronic wounds are characterized by elevated levels of proteases (matrix metalloproteinases, MMPs) and neutrophil elastase. This increased proteolytic activity is thought to disturb essential growth factors and growth-stimulating receptors, and destroy the underlying extracellular matrix (18, 19). Previous studies have also shown that the majority of wounds contain bacterial biofilms (20) that are difficult to treat if not debrided frequently, as they can return to their original status within 48-72 hours of the last debridement (21).

Furthermore, a moist environment is essential in wound healing, and the production of exudate is vital. However, if a wound produces too much exudate, the wound bed may become saturated, causing wound fluid to leak into the adjacent skin, leading to maceration of the tissue. Wound fluid stagnation may also trigger infection (22). Choosing the appropriate wound dressing material, and keeping the wound environment adequately moist are therefore of the utmost importance (23). There is a wide selection of wound dressing materials on the market, including gauze, films, hydrogels, hydro-colloids, foams, alginates, and antimicrobial-impregnated materials (24).

As described above, re-epithelialization is an important step towards wound healing. This can be hampered or prevented by a number of things. For example, it is believed that the native cells of chronic wounds have undergone changes that affect their ability to proliferate and move. Also, fibroblasts in diabetic ulcers seem to respond slowly to growth factor stimulation (25). Other factors believed to inhibit re-epithelialization include ischemia, as low oxygen levels reduce the ability of leukocytes to kill bacteria (16), infection, and the formation of callus at the wound margin (23).

During the last decade, new discoveries have been made, for example, the importance of biofilms in chronic wounds, and their management. New treatments have also been introduced, such as topical antimicrobial treatment. In the late 1990s another novel mode of treatment revolutionized chronic wound care, namely negative pressure wound therapy, NPWT (1).

Negative pressure wound therapy

Negative pressure wound therapy is sometimes also referred to as vacuum-assisted closure (V.A.C.) or topical negative pressure therapy (TNP), and has revolutionized the management of both acute and chronic wounds. The principle is quite simple: the wound is first filled with a porous material, usually gauze or polyurethane foam, to allow the pressure to be transmitted to and evenly distributed over the wound. A drainage tube is attached above the wound filler, and the wound is then sealed with an adhesive drape. The drainage tube is connected to a vacuum pump and a negative pressure is applied (26). The vacuum pump can be set to any pressure, but pressures commonly used clinically range from -80 to -125 mmHg (27). The pump can also be operated in different modes providing continuous, intermittent, or variable pressure reduction. Continuous mode throughout the whole treatment is the most frequently used mode clinically. In variable mode, the vacuum suction is varied, but never turned off completely; for example, it may range from -10 to -80 mmHg. In intermittent mode, the vacuum suction is turned on and off; for example: 5 minutes at -80 mmHg, and 2 minutes without suction.

NPWT generates a series of reactions in the wound and the surrounding tissue that ultimately lead to wound healing. Immediately after the vacuum pressure is applied the wound contracts, wound fluid is drained (28-30), and the wound bed is mechanically stimulated (31-33). NPWT also creates a moist wound environment (34), modifies blood flow in the wound area (29, 35-37) and triggers the formation of new blood vessels (38, 39). Furthermore, previous studies have shown that NPWT also reduces tissue edema (40) and stimulates the formation of granulation tissue (29).

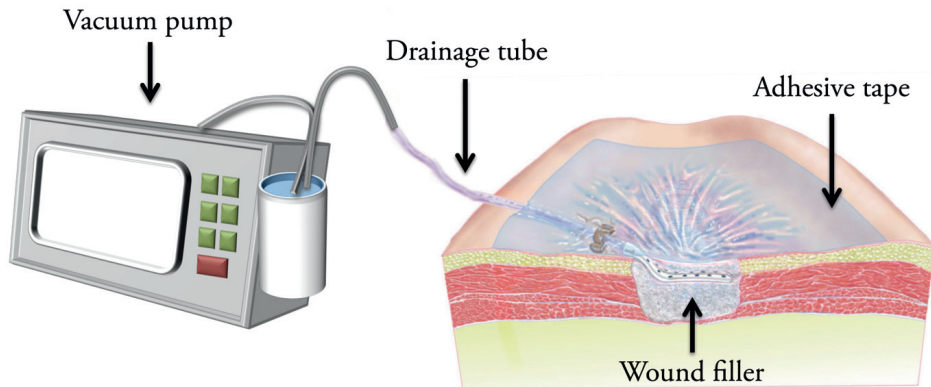


Figure 2. NPWT of a wound filled with gauze. The wound is sealed with an adhesive drape, and a drainage tube is connected to a vacuum pump. The pump can be set to various pressures, and different modes (e.g. continuous, intermittent, or variable).

Historical aspects of vacuum therapy

The use of vacuum suction in wound healing dates back thousands of years. For example, in the Roman era, deep wounds were treated by direct suction by mouth. This practice was later abandoned in favor of syringes as it was regarded as unhygienic (41). During the 19th century, heated glass cups were applied to the patient's skin. As the air cooled, a partial vacuum was created inside the glass cups, stimulating the circulation (41).




Figure 3. Heated glass cups (so-called Bier cups) were applied to the patient's skin, and as the air cooled, a partial vacuum was created. The method was used to stimulate local blood flow. This figure is reproduced with the permission of Prospera (Fort Worth, Texas, USA).

In recent times, Raffl used vacuum suction to accelerate wound healing after radical mastectomies in the early 1950s (42). In 1985, a Russian surgeon, Bagautdinov, described the use of vacuum suction to promote wound healing, at a hospital in Kazan, Russia (41). In 1989, Chariker et al. (43) reported the use of vacuum therapy in patients with incisional or cutaneous fistulae in abdominal wounds. Following this, in 1993, Fleischmann et al. used vacuum suction to promote healing in patients with open fractures (44).

However, NPWT was not widely adopted in wound care until the publication of the work of the plastic surgeon Morykwas and his colleague Argenta, a biomedical engineer, in 1997. They showed that NPWT could be used to reduce local edema and manage wound exudate in a porcine model (29). Together with a medical company, Kinetic Concepts Inc. (KCI), they developed the first commercially available system, namely the V.A.C.[®] Therapy System (KCI, San Antonio, TX, USA). Today, NPWT is used worldwide in a range of surgical disciplines.

It is estimated that around 300 million wounds are treated with NPWT annually (45), and numerous studies have demonstrated both the medical and

financial advantages of NPWT, for example, faster wound healing, earlier discharge from hospital, fewer readmissions and improved quality of life (46-50). Wounds suitable for NPWT are venous leg ulcers (50), diabetic foot ulcers (51, 52), vascular surgery wounds (53), skin grafts (54), decubitus ulcers (55), burns (56), wound dehiscence following abdominal (57) and thoracic surgery (58), and traumatic orthopedic (59) and surgical infections (60).

Mechanisms of NPWT

NPWT promotes wound healing through a series of mechanisms. The treatment has been shown to drain exudate (28-30), contract the wound edges (28-30, 61-64), decrease tissue edema (28, 29, 65) and mechanically stimulate the wound bed (31, 33). Furthermore, it promotes both the formation of new blood vessels and granulation tissue (29, 38, 39, 66, 67). NPWT also creates a moist wound healing environment (34) and alters the blood flow in and around the wound edges (29, 35-37). The fundamental effects of NPWT are presented in detail in the sections below.

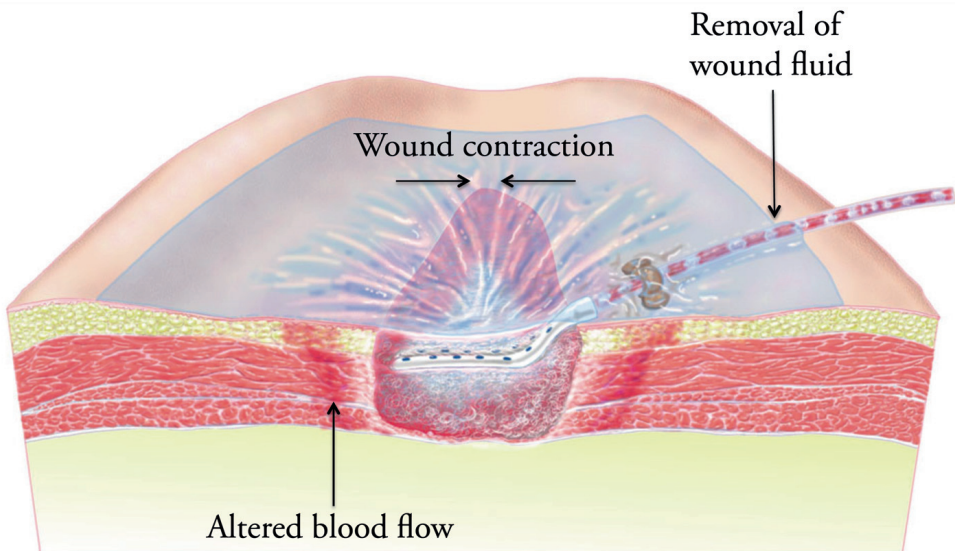


Figure 4. Cross-sectional view of a wound treated with gauze-based NPWT. The figure illustrates some of the fundamental effects of NPWT (i.e., wound contraction, wound fluid removal, and altered blood flow). Illustration by Bo Veisland, Lund, Sweden.

Mechanical forces of NPWT

It is known that cells require tension to divide and proliferate (68, 69), while cells that are not stretched undergo apoptosis (68, 70, 71). As NPWT is applied, the wound contracts creating *macrodeformation* of the wound. This is thought to be one of the fundamental effects of NPWT (72). During macrodeformation, shearing forces affect the cytoskeleton (73-75), initiating a signaling cascade that leads to increased production of granulation tissue and ultimately enhanced wound healing.

The mechanical forces produced during NPWT not only cause macrodeformation of the wound, but also *microdeformation*. As NPWT is applied, the wound bed is drawn up towards the wound filling material, whether it be foam or gauze, causing imprints of the material on the surface of the wound bed that can be seen in a microscope (76). These microscopic changes create tension on the cells, leading to a number of biochemical reactions and gene transcriptions (33, 39, 77-79). For example, mechanical tissue deformation stimulates the expression of angiogenic growth factors and receptors (i.e., vascular endothelial growth factor (VEGF), VEGF receptors and angiopoietin system receptors) (39, 78, 80-85). Furthermore, *in vitro* studies have shown that the stretching of endothelial cells stimulates blood vessel formation (86, 87). Mechanical stress also promotes the production of extracellular matrix components such as collagen, elastin, proteoglycans and glycosaminoglycans (78, 85, 88). A recent murine study also revealed a significant increase in dermal and epidermal nerve fiber densities in wounds treated with NPWT, indicating that vacuum treatment may promote nerve reproduction (89).

A previous study has indicated that the type of wound filler used may affect the degree of wound contraction. It was shown that foam produced greater wound contraction than gauze (90). Study I presented in this thesis was designed to evaluate the effects of different types and sizes of wound fillers on wound contraction.

The removal of wound fluid and reduction of edema

A moist environment is vital in wound healing (91-93) as it facilitates the re-epithelialization process. However, in an overly moist wound, wound exudate may cause infection (22) and maceration, leading to damage to the wound edge. Stagnant wound fluid may also increase the risk of abscesses. As mentioned above, the composition of wound exudate in chronic wounds differs

from that in acute wounds, leading to inhibited wound healing (18, 19). Several studies have shown that NPWT removes exudate (28-30).

NPWT is also believed to reduce post-inflammatory edema (94). Edema causes increased pressure on the wound tissue, which in turn compromises the microvascular blood flow, reducing the inflow of nutrition and oxygen. This in turn reduces resistance to infections and inhibits healing.

The effect on blood flow - a subject of much debate

It is well known that NPWT affects the periwound blood flow. The first to study this were Morykwas and Argenta (29) in a porcine model, who reported that the blood flow increased during NPWT. The effects of NPWT on blood flow have been studied intensively since its clinical introduction, although no consensus has been reached. Several studies have reported increased blood flow in the periwound tissue during NPWT (36, 37, 67, 95), while others have observed decreased blood flow (35-37). Study II was carried out to further investigate the effects of NPWT on periwound blood flow.

Formation of granulation tissue

Granulation tissue is a vascular connective tissue formed on the surface of a healing wound. The production of granulation tissue starts during the proliferative phase of wound healing, and the tissue is composed of newly formed capillaries and connective tissue. Several studies have shown that NPWT increases the production of granulation tissue, compared to conventional moist gauze therapy (29, 55, 96).

Does NPWT reduce bacterial count?

NPWT offers a closed system for wound healing, as the adhesive drape provides a barrier against secondary infection. However, it has not yet been established whether NPWT reduces the amount of bacteria in the wound. Initial studies by Morykwas et al. indicated that the bacterial load in the wound decreased during NPWT (29), and a subsequent study, also conducted by Morykwas, confirmed these results (30). However, other studies have shown increased numbers of bacteria during NPWT (97, 98). Another interesting finding is that NPWT may alter the composition of the bacterial flora, rather than reducing the bacterial load (99), for example, decreasing the amount of gram-negative bacilli while increasing the amount of *Staphylococcus aureus*. In conclusion it cannot with certainty, from the present literature, be deduced if NPWT reduces the

bacterial load in the wound or not, and further studies are required to elucidate this issue.

Complications associated with NPWT

The use of NPWT as a wound-healing tool expanded rapidly, but at the beginning of the 2000s reports of complications started to emerge. In 2003, Abu-Omar et al. described two cases of right ventricular rupture during NPWT of the sternum due to mediastinitis following coronary artery bypass grafting (CABG) (100). In 2006, Sartipy et al. reported five additional cases of right ventricular rupture following NPWT in patients treated for post-CABG mediastinitis, three of which died (101). The risk of right ventricular rupture and by-pass graft bleeding following NPWT of mediastinitis is currently estimated to be between 4 and 7% of all cases treated (101-111).

Severe bleeding of large blood vessels such as the aorta has also been reported in several patients receiving NPWT (108, 110). NPWT has shown good results in treating post-operative infections in peripheral vascular grafts (112), but here too, reports of bleeding have started to emerge. The incidence of NPWT-related bleeding in patients with exposed blood vessels or vascular grafts (such as femoral and femoral-popliteal grafts) in groin wounds was as high as 10% in some studies (113). Severe bleeding has also been reported in patients receiving NPWT for burn wounds (114).

Bleeding from a blood vessel arises from a perforation in the blood vessel wall. A contributing factor to such a perforation may be NPWT-related hypoperfusion of the blood vessel wall. Infected or burn-damaged vasculature is probably very sensitive to hypoperfusion, and NPWT is known to cause changes in perfusion. Applying NPWT to already sensitive structures may therefore cause ischemia, followed by necrosis, and ultimately rupture of the blood vessels. In addition to hypoperfusion, mechanical shearing forces, which are known to arise during NPWT, on the blood vessel wall may place extra strain on an already vulnerable structure, ultimately adding to the risk of rupture and severe bleeding.

The increasing number of reports of deaths and serious complications associated with NPWT led to two alerts being issued by the American Food and Drug Administration (FDA), in 2009 and 2011 (115, 116), stating that during a four-year period, NPWT had caused 174 injuries and 12 deaths, nine

of which (i.e., 75% of the deaths) were related to bleeding, in the U.S. alone. According to the FDA, bleeding of exposed blood vessel grafts during NPWT, due to for example graft-related infections, continues to be the most serious adverse event. These disturbing reports caused the FDA to state that NPWT is contraindicated (116) in certain types of wounds:

- in wounds with necrotic tissue with eschar
- in non-enteric and unexplored fistulas
- in wounds with malignancy present in the wound
- in wounds with exposed vasculature
- in wounds with exposed anastomotic sites
- in wounds with exposed nerves, and
- in wounds with exposed organs.

Despite this, off-label use (i.e., use outside the manufacturer's recommendations) has continued in some of these cases, as there are no alternatives that give comparable results. For example, Petzina et al. showed that mortality due to mediastinitis was reduced from 25% to 6% when using NPWT, compared to conventional treatment, even with the risk of right ventricular rupture (117). Good results have also been reported during NPWT of infected vascular grafts (112). As the number of complications arising from NPWT treatment has increased, the importance of protecting exposed organs (for example blood vessels) has been emphasized in the international scientific literature (107, 118-121).

The reason for right ventricular heart rupture and the bleeding complications following this were unknown until our research group identified the problem in 2009 (122). Pigs undergoing simulated heart surgery (i.e., sternotomy and pericardiectomy) were examined with magnetic resonance imaging (MRI), and it was found that the heart was drawn up towards the thoracic wall, causing the sharp sternal edges to be pressed into the anterior surface of the heart. In an attempt to prevent this, multiple layers of soft wound dressing were placed over the anterior surface of the heart. However, this did not prevent deformation and rupture of the right ventricle. Insertion of a rigid disc between the sharp edges of the sternum and the heart was shown to prevent deformation of the right ventricle. The development of a protective disc began, leading to the

HeartShield® device (122-124). This protective device has proven to be safe and efficacious in protecting the heart (125-127). Figure 5 below shows an illustration of a prototype of the protective device. Using rigid barrier discs to protect exposed organs during NPWT is covered by patents and patent applications. These are indirectly controlled by Sandra Lindstedt, Malin Malmsjö, and Richard Ingemansson.

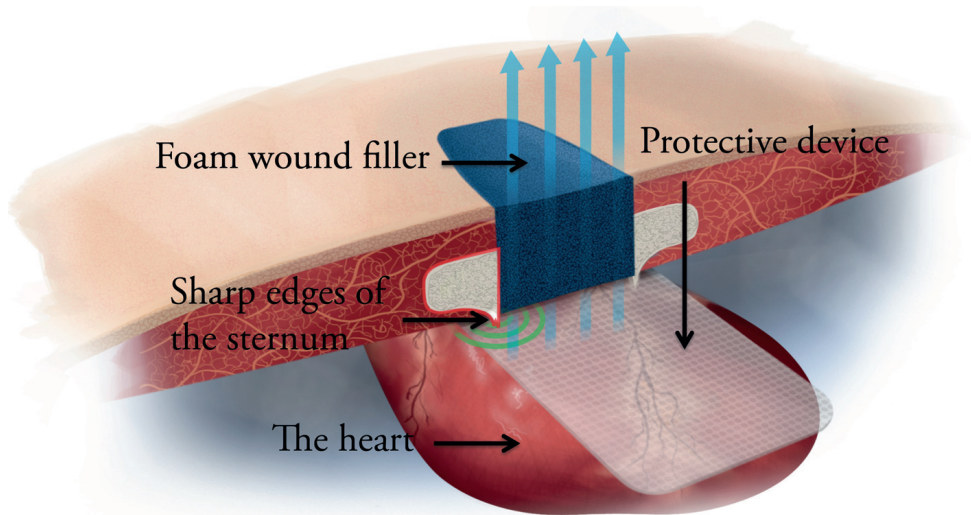


Figure 5. Cross section of a sternal wound illustrating how the heart can be protected from the mechanical effects of NPWT by a disc.

The application of NPWT to help heal vascular graft infections has shown good results (112), but there is still no device for protecting exposed blood vessels, for example, during NPWT of infected vascular grafts. Since a rigid disc inserted between the heart and the sternum could protect the heart, we hypothesized that a blood vessel could be protected in a similar way, by inserting a thin plastic disc between the blood vessel and the wound filling material.

Studies III, IV, and V were experimental studies carried out in different kinds of peripheral wounds, in a porcine model. The aim was to investigate the possibility of using thin plastic discs during NPWT to protect exposed blood vessels in the wound bed. Figure 6 below shows a schematic view of a peripheral wound prepared with a protective device shielding the blood vessels.

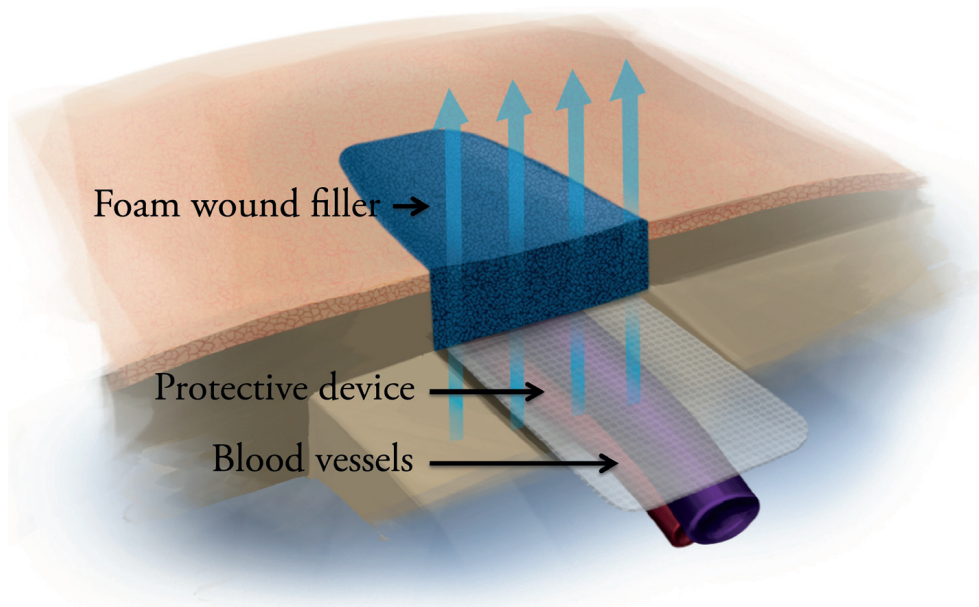


Figure 6. NPWT treatment of a peripheral wound with exposed blood vessels. A protective device has been inserted between the foam wound filler and the blood vessels.

Thesis at a glance

The studies described in this thesis are summarized in the table below. In all cases, peripheral wounds were studied in a porcine model. The same eight animals were used in Studies I and II, and another eight animals were used in Studies III, IV and V.

Study	Aim	Type of Wound	Methods
I	To study the effects of different types and sizes of wound fillers on wound contraction and wound edge tissue pressure during NPWT	Circular defect wound, 6 cm in diameter, back of the pig.	Vernier caliper, pressure transducers
II	To study the effects of NPWT on microvascular blood flow using different measurement techniques	Circular defect wound, 6 cm in diameter, back of the pig.	Transcutaneous laser Doppler flowmetry (LDF), invasive LDF, thermodiffusion
III	To study the effects of thin plastic discs on femoral periarterial pressure and blood flow in the femoral artery during NPWT	Incision wound, 6 cm in length, femoral artery exposed in the wound bed.	Invasive LDF with probe 457, pressure transducers
IV	To investigate the effects of thin plastic discs on wound cavity pressure and microvascular blood flow during NPWT	Circular defect wound, 6 cm in diameter, back of the pig.	Invasive LDF with probe 418-1, pressure transducers
V	To study the effects of thin plastic discs on wound contraction and wound fluid removal during NPWT	Circular defect wound, 10 cm in diameter, back of the pig.	Vernier caliper, electronic weighing scale

Aims

The principal aims of the work presented in this thesis were to investigate the mechanisms of action of NPWT and to explore the possibility of using thin plastic discs during NPWT to protect exposed blood vessels in the wound bed.

The specific aims were:

- to study the effects of different types and sizes of wound fillers on wound contraction and tissue pressure during NPWT,
- to investigate the impact of different measurement techniques, including transcutaneous laser Doppler flowmetry, invasive laser Doppler flowmetry, and thermodiffusion, on periwound blood flow during NPWT,
- to study the effects of thin plastic discs during NPWT, on femoral artery blood flow, femoral periarterial pressure, wound bed microvascular blood flow, pressure transmission to the wound cavity, wound contraction, and wound fluid removal.

Methods

Ethical considerations

The studies presented in this thesis were carried out on animals (i.e., porcine models). Our research group implements the tenet of the 3 R's, namely Replacement, Reduction and Refinement (Russell and Burch, 1959) (128).

The research described in this thesis could not be carried out using an *in vitro* model. A porcine model was therefore chosen, as the skin of the pig resembles that of a human being. Furthermore, we plan and combine our experiments in order to reduce the number of animals required. Each animal was used for different purposes; in these cases experimental studies were performed at three different wound locations (see Figure 7), in the same animal. Using a single animal for several purposes reduces the number of animals needed drastically, but must always be weighed against the possibility of interference between experiments. We cannot be certain, but we do not believe that using the same animal for different experiments has affected the results of these studies. However, it is important for the reader to know that the animals have been used for more than one purpose. Refining the experiments is a continuous process. The animals are fully anesthetized throughout the whole experiment. Heart rate, respiratory rate, breathing reflex, eye-lash reflex and muscular response (e.g. hoof-withdrawal reflex, jaw-tone) are continuously monitored to ensure that the level of anesthesia is adequate. The animals never regain consciousness after the experiments, but are euthanized by an intravenous bolus dose of potassium chloride.

Animal preparation

The experimental protocols used in these studies were approved by the Ethics Committee for Animal Research at Lund University, Sweden. All animals received humane care in compliance with the European Convention on Animal Care. A porcine model was used in these studies, as the properties of their skin are comparable to those of humans. Smaller animals such as rabbits, rats, and mice are often used in wound healing studies as they are less expensive, and easier to handle. However, the skin of smaller animals differs from human skin in several respects. For example, in these smaller animals primary healing occurs principally through wound contraction, whereas in both pigs and humans, wound healing occurs mainly through re-epithelialization. Furthermore, small animals have a thick layer of fur, and a thinner epidermis and dermis, while pigs have an epidermis and dermis of about the same thickness as humans. Moreover, porcine dermal collagen is similar to that in humans (129). Thus, the pig offers the best model of humans with regard to skin anatomy and physiology. However, it should be noted that the wounds studied here were clean, non-infected and uniform with regard to diameter and depth, which is seldom the case in clinical practice, where wounds, especially chronic ones, are rarely identical. The pigs were healthy, with a mean body weight of 70 kg. Wounds were made under general anesthesia, which was maintained throughout the experiments. At the end of each experiment a lethal dose of potassium chloride was administered intravenously.

Detailed descriptions of the animal preparation and the anesthesia can be found in the respective papers.

Wound preparation

The short-term effects of NPWT were studied in peripheral, surgically made wounds on the back of the pigs in Studies I, II, IV, and V, and in wounds in the groin of the pig (inguinal wounds) in Study III. The wounds were circular defect wounds with diameters ranging from 6 cm (Studies I, II, and IV) to 10 cm (Study V). In Study III, the wound was incisional and 6 cm long, leaving 6 cm of the femoral artery exposed for the study of the blood flow in this artery.

An overview of the locations of the different kinds of wounds is presented in Figure 7 below.

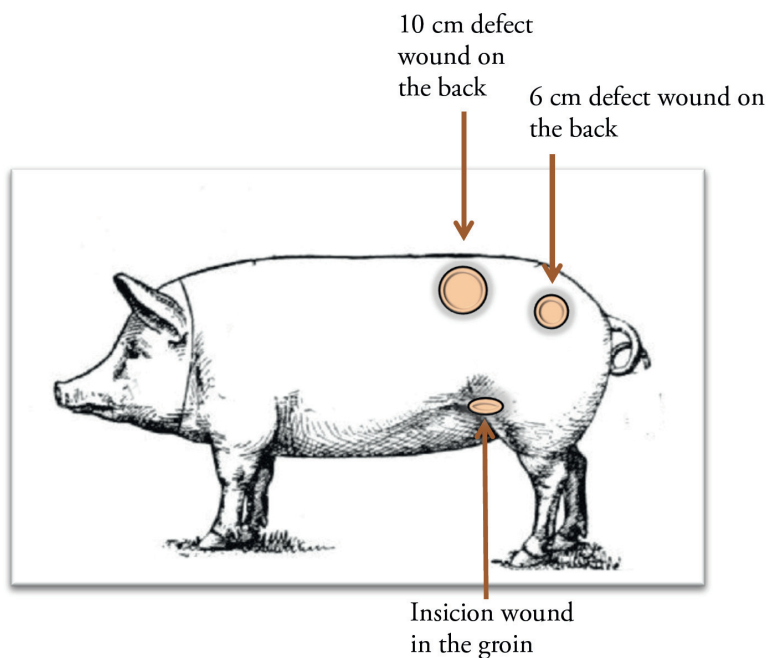


Figure 7. Illustration of all three different wound locations; a 6 cm long incision wound in the groin of the pig, and two circular defect wounds, 6 cm respectively 10 cm in diameter, on the back of the pig.

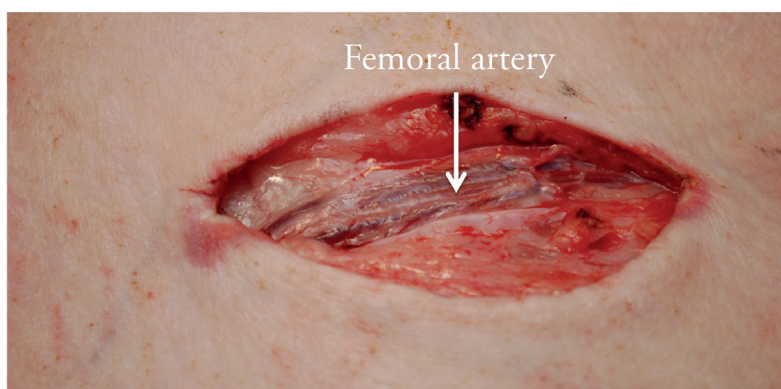


Figure 8. Incision wound in the groin of the pig (Study III). This picture shows how tissue has been dissected away, to expose the femoral artery.

The depth of the wounds also varied. In Study III the wound extended into the subcutaneous tissue (1 cm), while in Studies I, II, IV and V the wounds were somewhat deeper (3-4 cm), extending down into the muscle tissue.

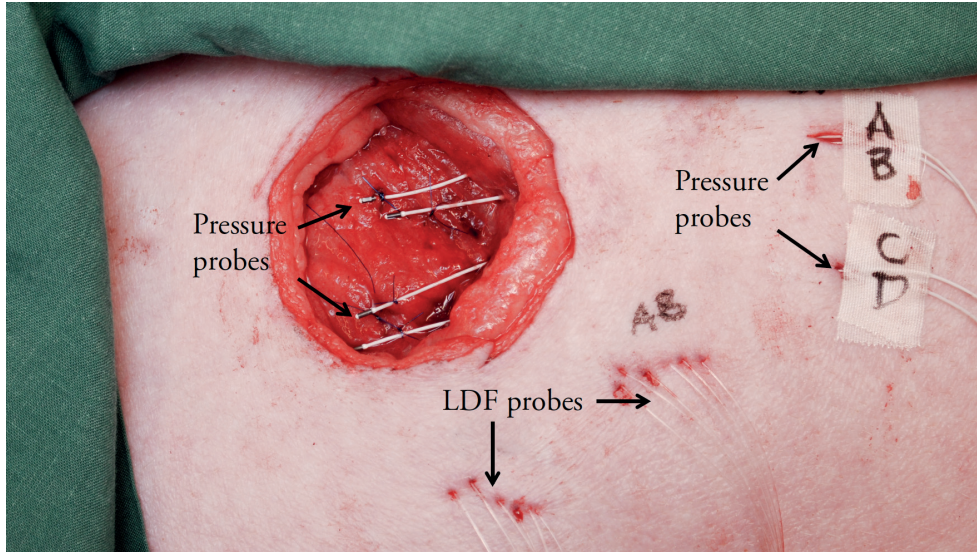


Figure 9. Representative example from Study IV showing a 6 cm in diameter circular defect wound located on the back of the pig.

The design of the protective discs

Thin plastic discs, intended to protect exposed blood vessels during NPWT, were evaluated in Studies III-V. These studies focused mainly on ensuring that the discs could be used safely, without compromising the mechanisms of action of NPWT, i.e. the effects on wound bed microvascular blood flow, pressure transmission to the wound cavity, wound contraction and wound fluid removal. The effects on blood flow in the femoral artery, and femoral periarterial pressure was also studied.

Discs of five different designs were used. All the discs were circular, with a diameter of either 6 cm (Study III and IV) or 10 cm (Study V) and when needed the discs were slightly adjusted to fit the wound (Study III). All discs had a thickness of 1 mm and were made of clear polyurethane (PU) plastic,

rigid enough to withstand the forces of the negative pressure. Some of the discs had 5 mm wide channels to accommodate exposed structures such as blood vessels, and some had 2 mm wide perforations distributed evenly over the surface of the discs with 5 mm intervals. In all cases, except in that referred to as the bare disc, a dressing of open-pore polyurethane foam covered the underside of the disc to facilitate pressure transmission and fluid evacuation. Also, a thin, perforated, soft non-adherent wound contact layer was inserted between the disc and the wound bed. The five principal kinds of discs and dressings are illustrated in Figure 11 on the next page.

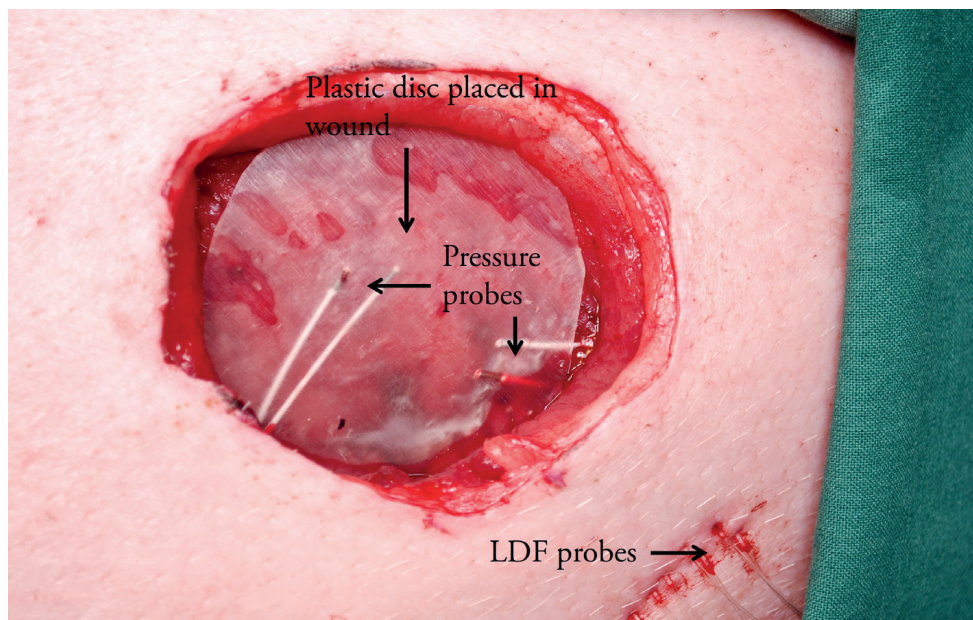


Figure 10. Representative image from Study IV showing a 6 cm in diameter, circular defect wound on the back of the pig, with a plastic disc (the “bare disc”) placed in the wound.

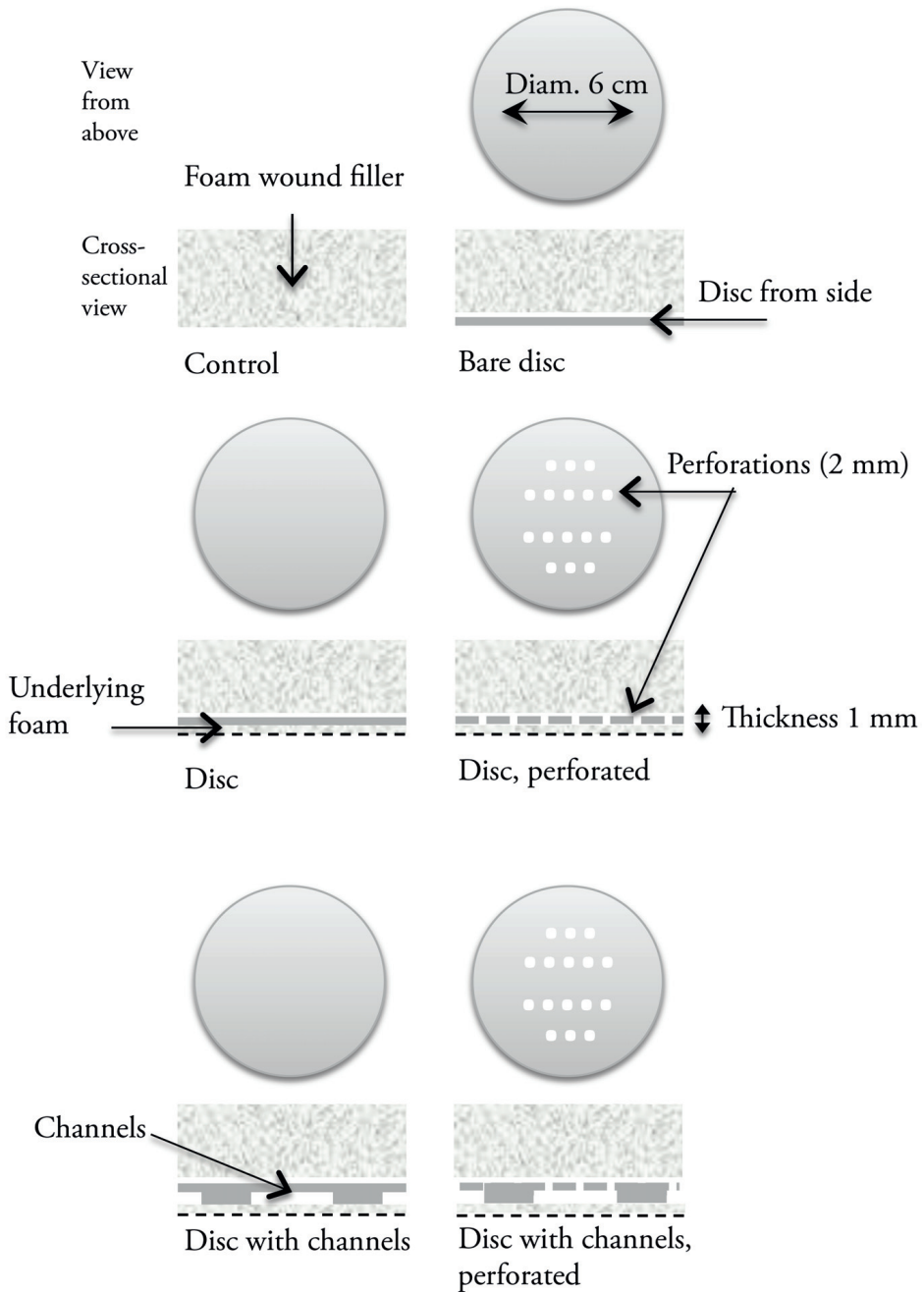


Figure 11. Schematic illustrations of the five various kinds of discs, from above, and cross-sectional views.

Wound contraction and wound fillers

Wound contraction during NPWT was measured in Studies I and V. Four marks were made around the edge of the wound, in orthogonal directions. The diameter of the wound was measured with a Vernier caliper as illustrated in Figure 12, and the mean value of the two diameters was calculated.

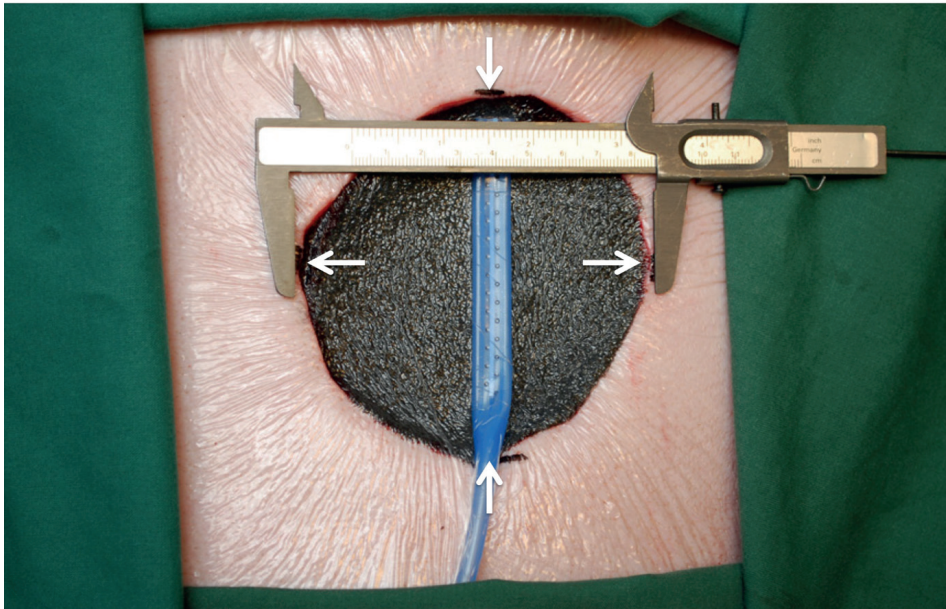


Figure 12. The diameter of the wound was measured with a Vernier caliper in two orthogonal directions (denoted by the white arrows). Permanent marks were made on the skin to allow measurements at the same position on every occasion.

Study I was designed to investigate the effects of different sizes and types of wound fillers on wound contraction and tissue pressure. Polyurethane (PU) foam and saline-soaked gauze of two different sizes, denoted small and large, were used. The small foam filler had a diameter of 50 mm, while the large foam filler was 70 mm in diameter. PU foam was used in Studies II-V. Two gauze sponges, each measuring 150 x 170 mm, together constituted the small gauze filler, and three gauze sponges constituted the large gauze filler. The diameters of the wound were measured before and after the application of negative pressures ranging from 0 mmHg to -160 mmHg at intervals of 20 mmHg.

Study V was designed to evaluate the effects of five different thin plastic discs described above. Wound contraction and wound fluid removal were investigated. The wound diameter was recorded for all five discs (i.e., all discs were tested individually), before and after the application of a negative pressure of -80 mmHg. The same wound but without a disc served as a control wound.

Pressure measurements

Wound cavity pressure, periarterial pressure (i.e., the pressure on top of the femoral artery) and wound edge tissue pressure was measured in Studies I, III, and IV. Two different techniques were used: a custom-built pressure gauge that relies on pressure transmission via a saline-filled catheter, and an intracranial tissue pressure (ICP) microsensor (Codman/Johnson and Johnson Professional Inc., Massachusetts, USA), in which pressure is measured with a miniature strain gauge.

Study I

In Study I negative pressures between -20 and -160 mmHg were applied to a peripheral porcine wound. Wound cavity pressure was measured underneath the wound filler using the saline-filled catheter. The tip of the catheter was sutured to the center of the wound cavity and the catheter was connected to the custom-built pressure gauge. This technique is not suitable for pressure measurements in tissue, as fluid may accumulate at the end of the probe. However, pressure measurements in the wound cavity pose no problems as the fluid is evacuated continuously by NPWT. Caution must yet be undertaken so that the fluid from the catheter is not completely evacuated by NPWT, by intermittently, between the measurement series, infusing saline.

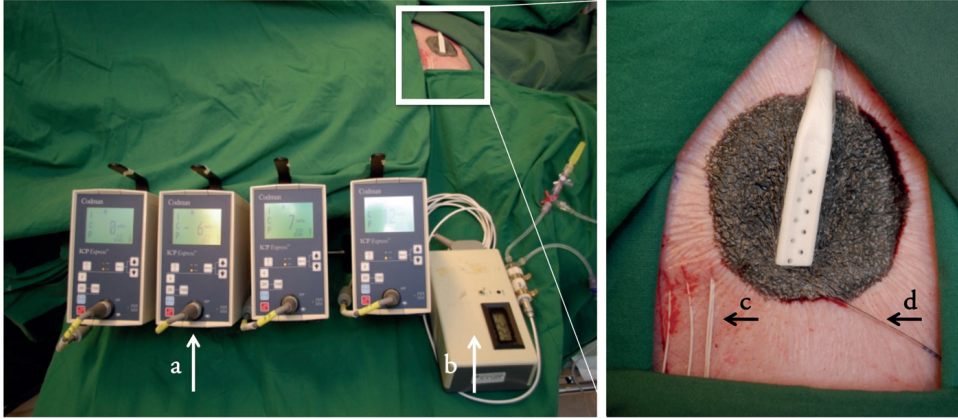


Figure 13. Equipment used for pressure measurement during NPWT in Study I. Four Codman ICP express monitors (a) and a custom-made pressure recorder (b), used to measure tissue pressure are shown on the left. The image on the right shows an enlargement of the peripheral wound filled with foam, during NPWT. ICP microsensors (c) and a saline filled catheter (d) were used to measure tissue pressure.

Wound edge tissue pressure was measured at distances of 0.1, 0.5, 1.0, and 2.0 cm from the wound edge (see Figure 14). The sensors were inserted into muscle tissue at a depth of 2 cm using an 18G Tuohy needle. The Codman ICP monitoring system was used to measure periwound tissue pressures as it can record high positive pressures. This system was not used to measure wound cavity pressure in Study I since it can only record negative pressures down to -99 mmHg, and negative pressures below -120 mmHg were applied in this study.

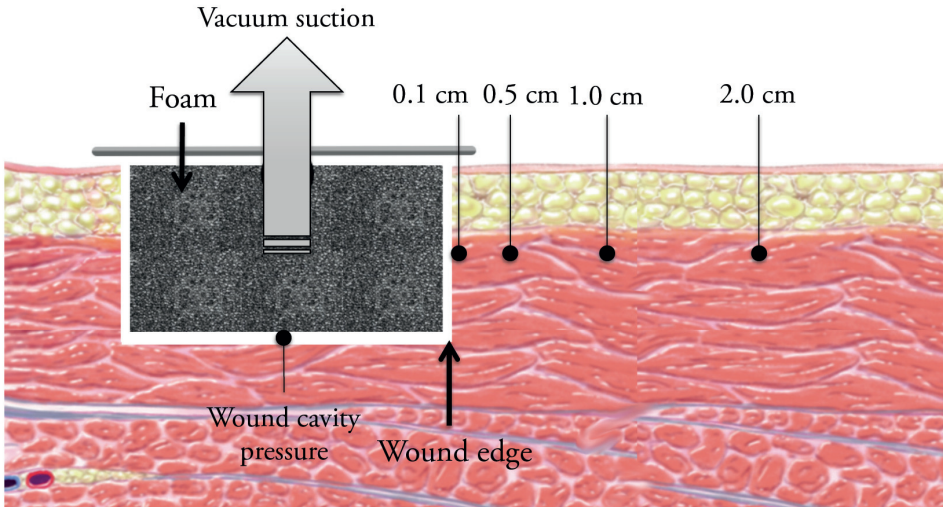


Figure 14. Position of the probes in Study 1, for the measurement of pressure in the wound cavity and tissue pressure 0.1, 0.5, 1.0, and 2.0 cm from the wound edge.

Study III

Study III was carried out to investigate the effects of the five different thin plastic discs on femoral periarterial pressure (pressure on top of the femoral artery) and blood flow in the femoral artery during NPWT. The experimental setup is shown in Figure 15. Incision wounds were created in the groin of the pigs. Two ICP microsensors were fixated with sutures on top of the femoral artery to record the periarterial pressure. The periarterial pressure and blood flow in the femoral artery were recorded before and after the application of continuous negative pressures of -80 and -120 mmHg using a custom-built vacuum source. A disc was placed over the artery, and the procedure was repeated. All five discs were tested individually.

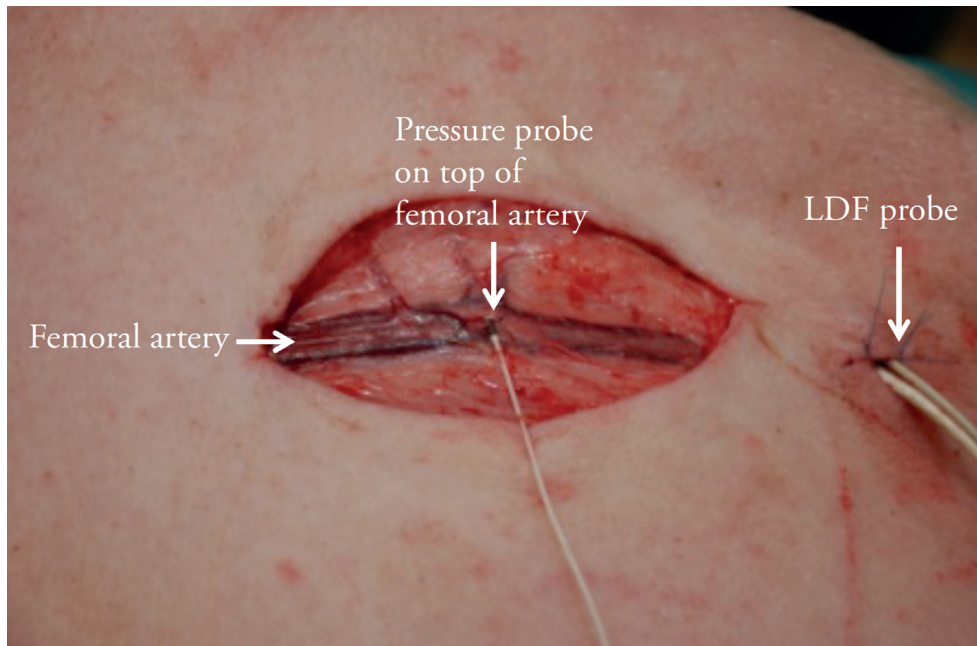


Figure 15. Position of the probes for the measurement of periarterial pressure in Study III. This picture also shows an LDF-probe, used to measure blood flow in the femoral artery.

Study IV

The thin plastic discs were further examined in Study IV, where wound cavity pressure and wound bed microvascular blood flow during NPWT were studied. The experimental setup is shown in Figure 21. Circular defect wounds, 6 cm in diameter, were created on the back of the pigs. Pressure was recorded using both ICP microsensors and the custom-built pressure gauge. Negative pressure (-80 mmHg) was applied using a custom-built vacuum source. The effects of all the disc designs were studied in each wound.

Blood flow measurements

Blood flow was investigated in Studies II, III, and IV. In Study II, microvascular blood flow in the wound edge tissue was studied using transcutaneous laser Doppler flowmetry (LDF), invasive LDF, and thermodiffusion. Blood flow in the femoral artery was investigated in Study III, using invasive LDF

(probe 457). In Study IV, wound bed microvascular blood flow was assessed using invasive LDF, with probe 418-1.

Laser Doppler flowmetry

Laser Doppler flowmetry (LDF), also known as laser Doppler velocimetry, is a technique frequently used to measure blood flow in flaps during plastic surgery procedures (130) and after skin burns to assess burn wound outcome (131). However, LDF does not measure blood flow directly, it is indirectly determined by recording the velocity and number of red blood cells. LDF can be utilized to measure blood flow invasively and non-invasively (transcutaneously).

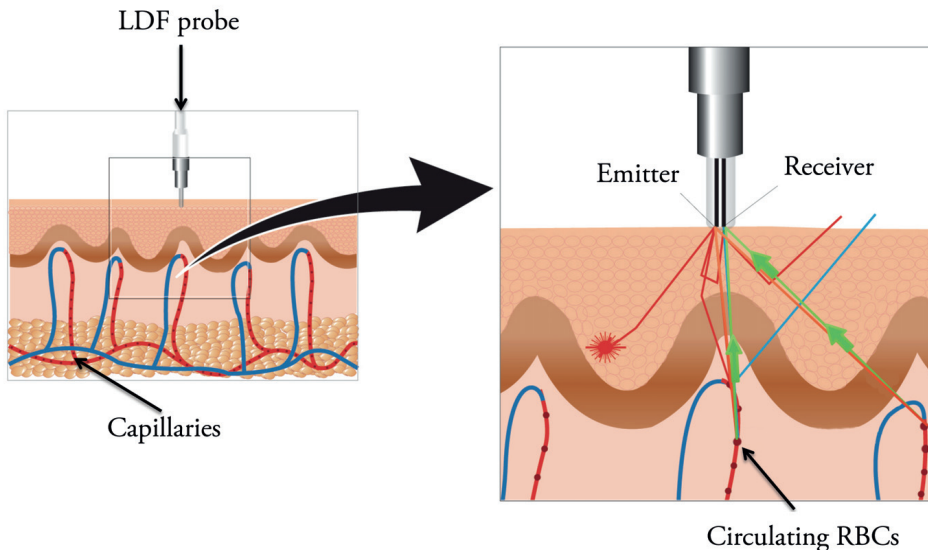


Figure 16. The basic principle of laser Doppler flowmetry (LDF). Laser light is emitted into the tissue (red beams). Most of the light is absorbed or reflected in the tissue (red and blue beams), but some of the light is reflected back to the LDF probe (green arrows). Light impinging on a moving object such as a red blood cell (RBC) undergoes a Doppler shift. The figure is used with permission from Perimed AB Sweden.

The invasive method entails the use of a fiberoptic probe that is inserted into the tissue where the blood flow is to be measured. The probe carries and emits a beam of laser light, which is scattered in the tissue. Red blood cells (RBCs)

passing by the probe reflect the laser light, which at the same time undergoes a change in wavelength. This change in wavelength is referred to as the Doppler shift. Light reflected from stationary objects remains unchanged. The amount and frequency distribution of the fluctuations in wavelength are directly related to the number and velocity of the RBCs (132). The data are collected by a fiberoptic cable, converted into an electric signal, and analyzed. The blood flow can then be determined from the product of the mean velocity and the mean concentration of the RBCs in the volume of tissue illuminated by the probe. However, the blood flow obtained in this way cannot be presented in absolute units, e.g. ml/min/100 g, but is given in arbitrary perfusion units. The same system (Perimed PeriFlux System 5000, Perimed, Stockholm, Sweden) was used in all studies (i.e., Studies II, III, and IV). This system allows real-time monitoring of the blood flow and the use of four LDF probes simultaneously.

Transcutaneous LDF measurements were performed in Study II using an O2C unit (LEA Medizintechnik, Giessen, Germany). This device allows non-invasive measurements of blood flow. Flat probes (LF-2, LEA Medizintechnik, Giessen, Germany) were placed on the skin surface and fixed with transparent adhesive film. The fundamental principle is essentially the same in both transcutaneous and invasive LDF (i.e., detecting a Doppler shift). The experimental setup is shown in Figure 17.

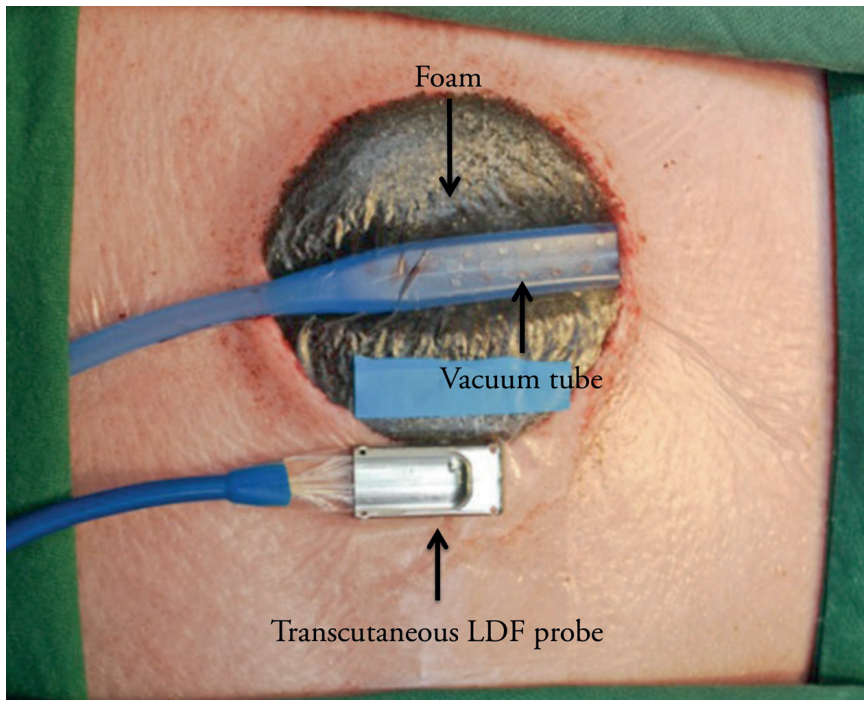


Figure 17. Photograph showing the setup used to measure transcutaneous blood flow in Study II.

Limitations of LDF

Although LDF is widely used to measure blood flow, its use has been criticized (133), as it is sensitive to all kinds of tissue movement. It is therefore vital to ensure that the LDF probes are properly anchored in the tissue, and to reduce involuntary movements. Furthermore, LDF uses a small sampling volume (about 1 mm^3) (134), which means that the technique only provides information on the blood flow in a very small region surrounding the probe. Thus, the blood flow in the surrounding tissue may be higher or lower than that in the volume being investigated due to variations in vascular density. It is therefore important to use more than one probe, and to supervise the real-time readings of the probes, to avoid non-physiological values. Where possible, it is also important to include other techniques for measuring blood flow, to confirm the LDF values. This was done in Study II, where both LDF and thermodiffusion were used to measure perfusion. Similar results were obtained with both techniques, which indicates that LDF can be used to measure the

blood flow in this setting. Good correlation has also been reported between these two techniques in a previous study (135).

Thermodiffusion

A third method of measuring blood flow, thermodiffusion, was investigated in Study II. Blood flow was measured using a Bowman Perfusion Monitor (Hemedex, Cambridge, MA, USA). Thermodiffusion is an invasive technique that entails the insertion of a probe into the tissue. A thermal transducer, called a thermistor, is mounted at the tip of the probe. The temperature of the transducer is 2 °C higher than the temperature of the surrounding tissue, and the thermistor consequently emits heat to the surrounding tissue. The power dissipated in the thermistor provides a measure of the ability of the tissue to remove heat, by both thermal conduction within the tissue and by thermal convection due to tissue blood flow. A passive proximal thermistor is used to monitor, and compensate for, temporal changes in baseline tissue temperature. Blood flow is expressed as ml/100 mg tissue/min in a small focal volume of tissue surrounding the distal tip of the probe.

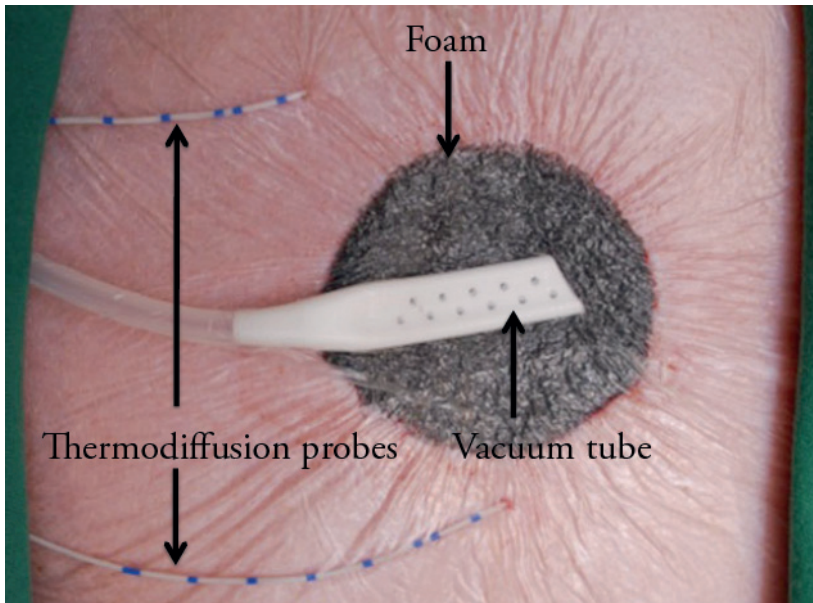


Figure 18. Two thermal diffusion probes were inserted into the muscle tissue, 0.5 and 2.5 cm from the wound edge (Study II).

In Study II a 19G QFlow 500 Thermal Diffusion Probe (Hemedex) was used. Probes were inserted using a 16G Secalon-T™ central venous catheter (BD Medical Surgical Systems, Stockholm, Sweden).

Limitations of thermodiffusion

The most evident drawback of the thermodiffusion technique is that, as in the case of LDF, the sampling volume is very small. However, when measuring microvascular blood flow, as was the case in Study II, this should not be a serious problem. Furthermore, the technique cannot be used if the animal or subject has a fever. This, however, was not a problem during Study II. The accuracy of the method can also be compromised if the thermodiffusion probe is placed near a large blood vessel (136). Once again, this was not a problem in Study II.

Wound edge microvascular blood flow

In Study II wound edge microvascular blood flow was measured using three different techniques: transcutaneous LDF, invasive LDF and thermodiffusion. Blood flow was measured at distances of 0.5, 1.0 (only LDF), and 2.5 cm from the wound edge. Probes were inserted to a depth of 2 cm in the muscle tissue for invasive LDF and thermodiffusion measurements. Transcutaneous LDF probes were placed on intact skin at the same distances from the wound edge. Blood flow was recorded before and after NPWT at different pressure levels (-20, -40, -80 and -125 mmHg).

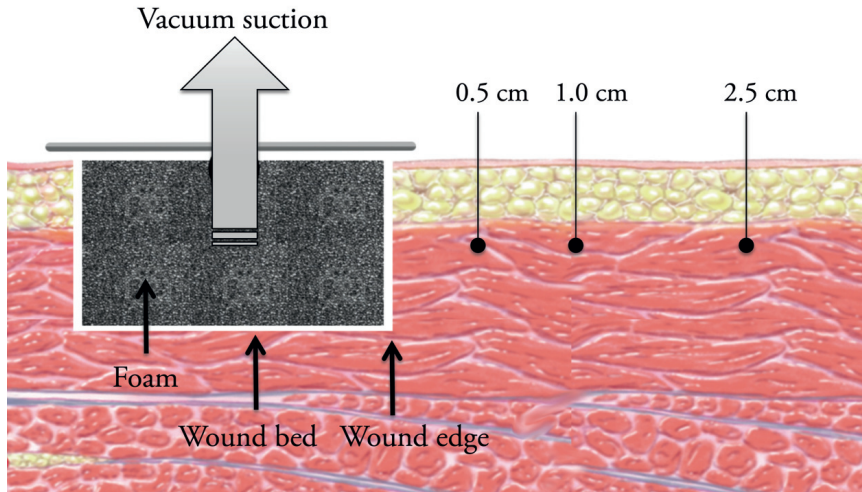


Figure 19. Probe positions for the measurement of microvascular blood flow 0.5, 1.0, and 2.5 cm from the wound edge in Study II.

Blood flow in the femoral artery

Study III was designed to investigate blood flow in a large peripheral artery, in this case, the femoral artery, during NPWT. The blood flow was recorded with invasive LDF, using Perimed probe 457 inserted through a small wound 2 cm distal to the groin wound, as shown in Figure 20.

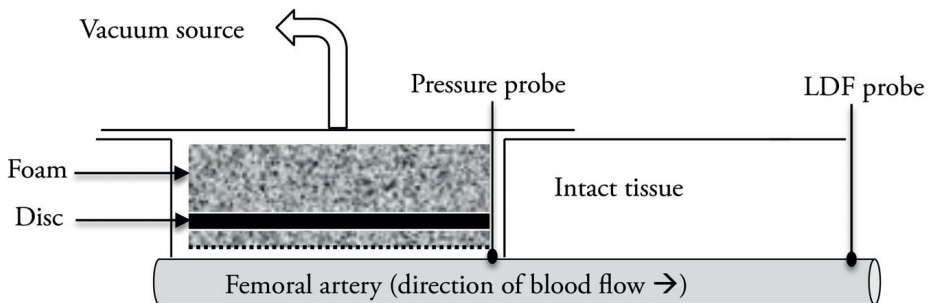


Figure 20: Experimental setup in Study III. Pressure probes were placed on top of the femoral artery to measure periarterial pressure. An LDF probe was placed 2 cm distal to the groin wound through a small incision wound.

Microvascular blood flow in the wound bed

In Study IV, microvascular wound bed blood flow was investigated during NPWT with and without each of the five plastic discs. Blood flow in the wound bed tissue was recorded with invasive LDF (probe 418-1) before and after the application of NPWT at -80 mmHg. The experimental setup is shown in Figure 21 below.

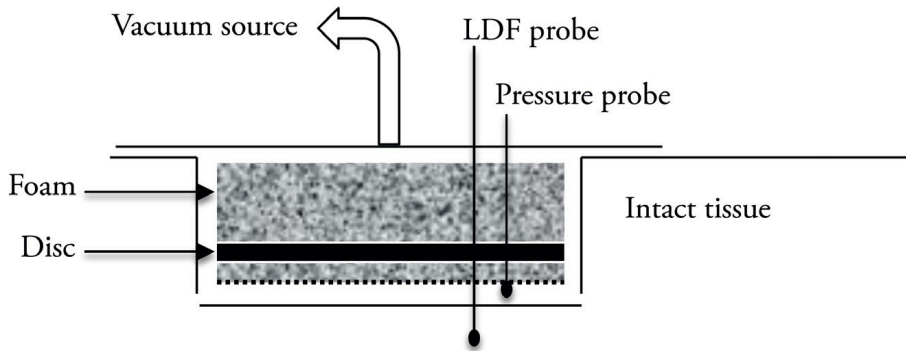


Figure 21. Experimental setup used in Study IV. LDF probes were inserted into muscular tissue in the wound bed. Wound cavity pressure was also measured.

Measurement of wound fluid removal

In Study V, fluid removal from the wound cavity was investigated during NPWT using each of the thin plastic discs described above. Physiological saline solution (100 ml) was infused into the sealed NPWT wound using a needle attached to a syringe. The needle was inserted through the skin, a few centimeters away from the wound edge, and entered the wound from the side, with the tip of the needle underneath both the NPWT dressing and the plastic disc. Negative pressure was then applied at -80 mmHg and maintained for the duration of the measurements. Fluid was evacuated into a canister placed on an electronic scale. The amount of fluid evacuated by NPWT was weighed every 5 seconds for 2 minutes (1 ml of saline solution was assumed to weigh 1 g). The same wound but with no disc served as a control.




Figure 22. Measurement of wound fluid removal during NPWT.

Statistical analysis

Calculations and statistical analysis were performed using GraphPad 5.0 software (San Diego, CA, USA).

In Studies I, II, IV, and V, statistical analysis was performed using the Mann-Whitney test when comparing two groups, and the Kruskal-Wallis test with Dunn's post-hoc test for multiple comparisons when comparing three groups or more.

In Study III, statistical analysis was performed using Student's t-test when comparing two groups, and ANOVA with Dunn's post-hoc test when comparing three groups or more. Grubb's test was used to identify outliers (6 outliers were found and excluded). Since it cannot be assumed that data obtained from experiments with only eight animals is normally distributed, in

retrospection, it would have been more appropriate to use a method of statistical analysis more suited for non-normally distributed data, for example, the Mann-Whitney or the Kruskal-Wallis test.

Mean values and the standard error of the mean (SEM) were used to describe the data in all studies. As the data in all the studies were assumed to be non-normally distributed, in retrospection, the most correct way of presenting the data would have been to give the median and the range. Data in newly conducted studies are presented as the median and range (or percentiles).

Values of $p < 0.05$ were assumed to indicate statistically significant differences.

Results and Discussion

Different types and sizes of wound fillers

Wound contraction

The results of Study I showed that the wound diameter decreased with increasing negative pressure. Wound contraction was greater when using a small foam filler than when using a large foam filler (5.8 ± 0.1 cm vs. 6.2 ± 0.2 cm in diameter, at -120 mmHg, $p = 0.033$). When using gauze, less wound contraction was observed, and no difference was seen between the two sizes of gauze filler (wound diameter 6.1 ± 0.2 cm for the small gauze filler and 6.1 ± 0.1 cm for the large gauze filler at -120 mmHg, $p > 0.30$).

A small foam filler thus resulted in greater wound contraction than a large foam filler during NPWT, while gauze resulted in intermediate wound contraction that was not affected by the size of the filler. A probable explanation of the difference between foam and gauze fillers is that foam is a more porous material, allowing greater volume reduction than gauze.

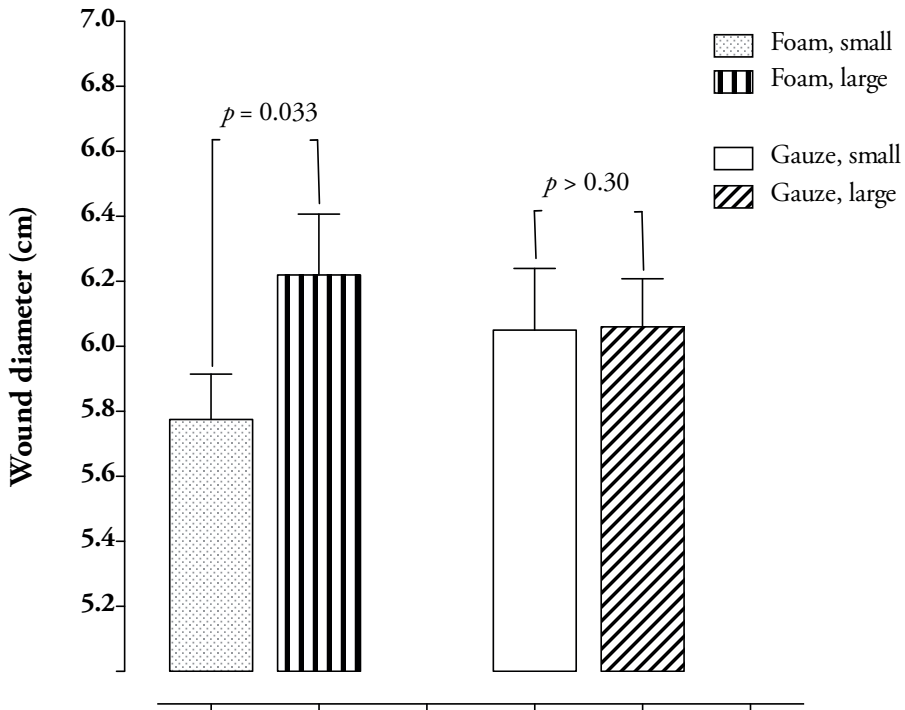


Figure 23. Wound diameter (mean values and SEM) during NPWT at -120 mmHg for foam and gauze wound fillers of different sizes (small and large).

It has been shown that mechanical wound contraction often causes pain to the patient (137). In the present study, high levels of negative pressure caused greater wound contraction, as did the small foam filler, while the large foam filler and gauze caused less wound contraction. It is therefore possible that patient pain could be reduced by using a larger foam filler or gauze, or by reducing the level of negative pressure.

Previous studies have shown that granulation tissue formation is enhanced in wounds subjected to greater wound contraction (138-140). Providing that the patient does not find the treatment painful, a small foam wound filler may therefore be suitable if the aim is to maximize granulation tissue formation.

Wound cavity and wound edge tissue pressure

Pressure transmission to the wound cavity was equally good with foam and gauze, for both sizes tested. For example, at an applied pressure of -120 mmHg, the pressure recorded when using the small foam filler was -105 ± 2 mmHg, compared to -103 ± 2 mmHg when using the large foam filler ($p > 0.30$). Wound cavity pressure did not reach the pressure set on the vacuum pump, probably due to some loss of negative pressure over the tube.

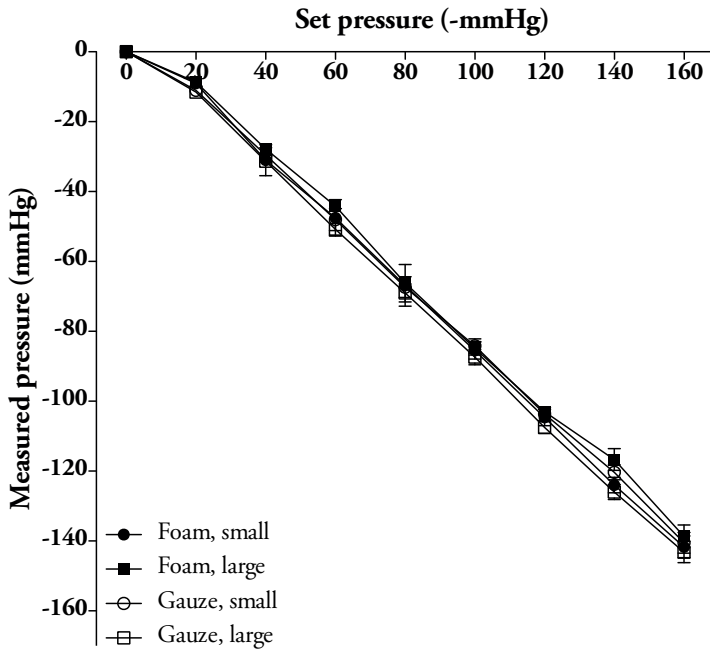


Figure 24. Wound cavity pressure (mean values \pm SEM) directly under the wound filler for both sizes of foam and gauze, during NPWT as a function of the vacuum pump pressure. No differences ($p > 0.30$) were seen between the different wound fillers.

Tissue pressure 0.1 cm from the wound edge decreased during NPWT (e.g. -35 ± 18 mmHg, at -120 mmHg, using the small gauze filler). The reduction in tissue pressure was not affected by the size of wound filler (e.g. -26 ± 14 mmHg for small foam and -37 ± 16 mmHg for large foam, at -120 mmHg, $p > 0.30$).

Tissue pressure 1.0 cm and 2.0 cm from the wound edge, was not affected by NPWT.

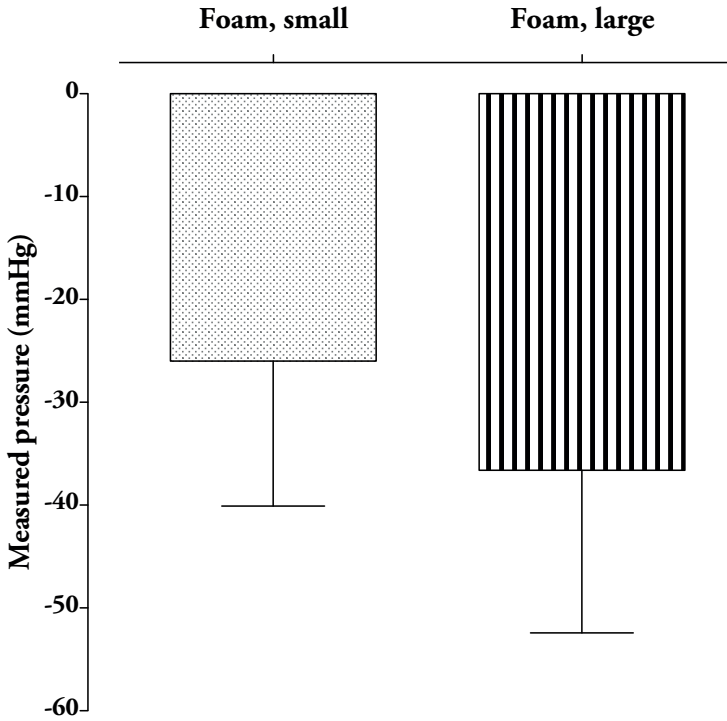


Figure 25. Tissue pressure (mean values and SEM) 0.1 cm from the wound edge, for both sizes of foam during NPWT at -120 mmHg, $p > 0.30$.

These findings are in line with those from a previous study on mice (141), and suggest that NPWT produces a hypobaric environment extending not only to the wound cavity but also to the superficial wound edge tissue. The subatmospheric tissue pressure, and the resulting pressure gradient over the wound edge may initiate the transport of interstitial fluid, reducing edema and facilitating the diffusion of oxygen and nutrients.

The tissue pressure 0.5 cm from the wound edge increased during NPWT (e.g. 7 ± 1 mmHg, at NPWT at -80 mmHg, using the small foam filler). Similar results have been reported by Kairinos et al. (142, 143), who found increased pressure in processed meat 1.0 cm from the wound edge, but not further away

(143). The pressure was higher with the small foam filler (9 ± 1 mmHg) than with the large foam filler (6 ± 1 mmHg) at -120 mmHg ($p = 0.034$).

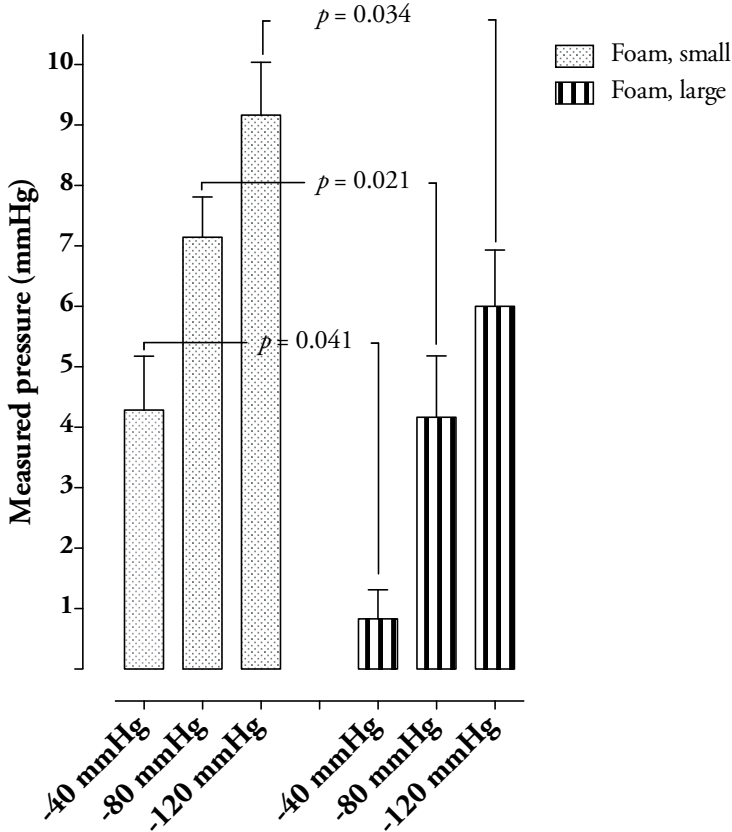


Figure 26. Tissue pressure (mean values and SEM) 0.5 cm from the wound edge, for both sizes of foam during NPWT at -40, -80, and -120 mmHg.

The mechanisms causing the tissue pressure to increase 0.5 cm from the wound edge are not fully understood. It may be that the negative pressure causes the wound to contract, resulting in compression of the wound edge tissue, which would in turn cause increased pressure in the tissue around the edge of the wound.

Study I revealed a difference in tissue pressure 0.5 cm from the wound edge when comparing small and large foam fillers, being higher for the small foam

filler. One reason for this could be that the small foam filler allowed greater contraction and thus a smaller wound diameter than the large foam filler. The adjacent tissue would therefore be subject to greater compression, causing higher tissue pressure. In contrast, the large foam filler, which poses a greater resistance to the wound edge wall, will result in less compression of the adjacent tissue, and therefore a lower pressure on the tissue.

In summary, Study I showed that NPWT causes wound contraction and changes in wound edge tissue pressure. In the wound cavity and in close proximity to the wound edge, i.e., 0.1 cm from the wound edge, tissue pressure decreased (i.e., subatmospheric pressure arose) during NPWT, whereas the tissue pressure 0.5 cm from the wound edge was seen to increase (i.e., positive pressure arose) during NPWT. Tissue pressure 1.0 cm and 2.0 cm from the wound edge was not affected by NPWT treatment.

Favorable effects may result from wound contraction and an increase in tissue pressure during NPWT. Previous studies have shown that wound contraction leads to mechanical stress around the wound edge, stimulating the expression of growth factors (e.g. VEGF and fibroblast growth factor-2), thus promoting granulation tissue formation and angiogenesis (73-75).

In a previous study by our research group, and in Study II presented below, it was shown that the blood flow 0.5 cm from the wound edge decreased during NPWT (138). Similar results were seen in another study by Kairinos et al. (35). A possible reason for this decrease in blood flow could be increased tissue pressure, causing mechanical compression of small blood vessels, ultimately causing a decrease in blood flow. In a previous study by Borquist et al., the decrease in blood flow could be controlled by changing the level of negative pressure applied (144). The choice of filler material, or the size of the filler, may offer other means of altering wound edge perfusion, however, this must be studied in greater detail before being implemented in clinical practice.

Microvascular blood flow & different measurement techniques

Study II was designed to investigate the effects of NPWT on wound edge microvascular blood flow in a porcine peripheral wound model. Circular defect wounds, 6 cm in diameter, on the back of the pigs were studied.

The effect of NPWT on wound edge microvascular blood flow has been the subject of much debate following reports of different results by different research groups (29, 35-37, 67). The reason for the difference in the findings has not yet been determined, however, one possible explanation could be that different techniques have been used to measure the blood flow. Laser Doppler flowmetry (LDF) has been used in most of the studies (29, 36, 67, 138, 145). In the present study the blood flow was measured using three different techniques: transcutaneous LDF (with a probe placed on the skin surface), invasive LDF (with probes inserted into the wound edge tissue), and thermodiffusion (with probes inserted into the wound edge tissue). Blood flow was recorded before and after NPWT was applied at different levels of negative pressure (-20, -40, -80, and -125 mmHg), and at different distances from the wound edge (0.5, 1.0, and 2.5 cm).

Microvascular blood flow 0.5 cm from the wound edge

When using invasive LDF and thermodiffusion the blood flow was seen to decrease 0.5 cm from the wound edge, typical values being $-45 \pm 7\%$ and $-12 \pm 35\%$ respectively, at -80 mmHg. Interestingly, at -20 mmHg, thermodiffusion showed an increase in blood flow ($10 \pm 18\%$). Transcutaneous LDF showed a tendency towards increased blood flow at all negative pressure levels, but the difference was small and not significant (typically $1 \pm 3\%$).

In summary, both invasive LDF and thermodiffusion showed decreased microvascular blood flow 0.5 cm from the wound edge. This is in line with our findings in previous studies (37, 138). The believed mechanism for the decrease in blood flow was briefly discussed on the previous page, and is thought to include increased tissue pressure in the wound edge. When the wound contracts, the tissue at the wound edge collapses towards the suction force and the tissue pressure around the rim of the wound edge increases (138), leading to

a reduction in blood flow as the blood vessels are compressed. In Study I, as well as in an earlier study by Kairinos et al. (143) it was shown that increased suction pressure caused gradually increased wound edge tissue pressure, which may explain the present finding, that blood flow changes with increasing negative pressure.

The hypoperfusion caused by NPWT may be either beneficial or disadvantageous, all depending on what type of wound one is intending to treat. It is well recognized that reduced blood flow stimulates angiogenesis and granulation tissue formation, which in turn facilitate the process of wound healing (28, 146). However, in tissues with already compromised perfusion, such as in arterial leg ulcers or in thin tissue grafts, the additional blood flow reduction may result in tissue ischemia with risk of development of necrosis. In clinical practice, NPWT is therefore used with great caution in tissues with compromised vascularity (35) and there are some that advise that NPWT is contraindicated if there is any doubt about the vascular status of the tissue (147, 148).

Microvascular blood flow 1.0 cm from the wound edge

Blood flow was measured 1.0 cm from the wound edge with invasive and transcutaneous LDF only. Thermodiffusion was not used as it was deemed too time-consuming to perform measurements at all three distances from the wound edge. Invasive LDF showed increased microvascular blood flow compared to baseline, at the lower levels of NPWT (0 to -40 mmHg) (e.g. $12 \pm 10\%$ at -40 mmHg), while at higher levels of negative pressure the blood flow decreased (e.g. $-30 \pm 8\%$ at -80 mmHg). Transcutaneous (non-invasive) LDF recordings showed a trend towards increased blood flow compared to baseline, regardless of the negative pressure applied.

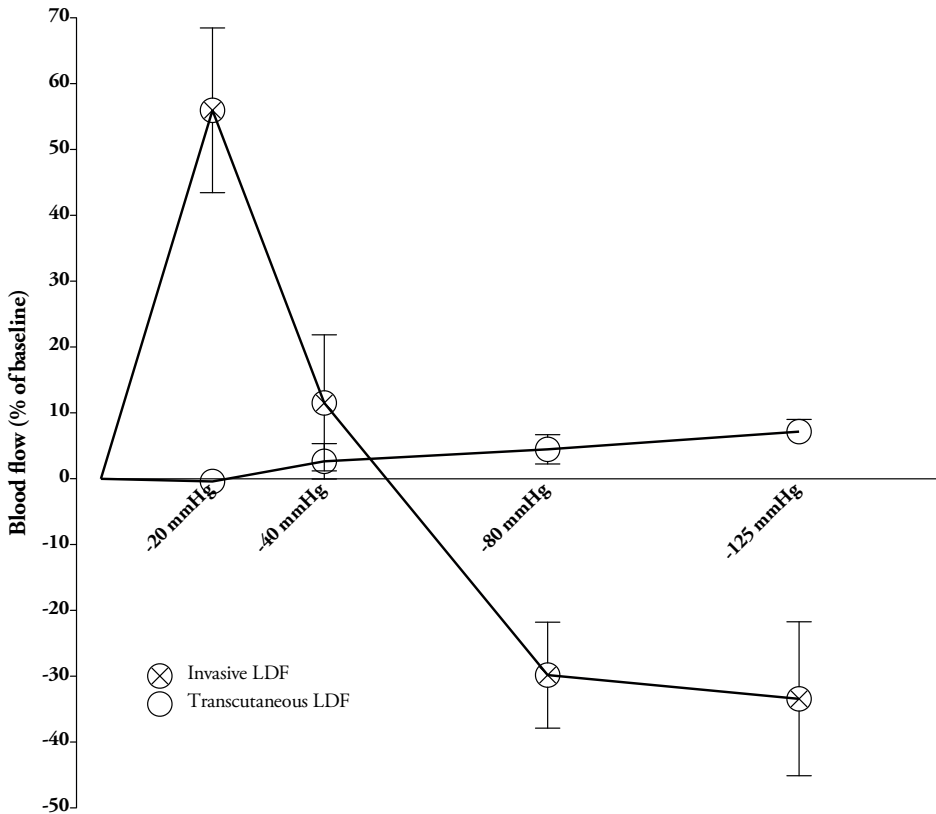


Figure 27. Blood flow as percent of baseline values (mean values and SEM) 1.0 cm from the wound edge during NPWT at four negative pressures.

Microvascular blood flow 1.0 cm from the wound edge was found to depend on the level of negative pressure applied. Decreased blood flow was seen at high levels of negative pressure, whereas low pressure levels led to increased blood flow. This may indicate a transition zone between hypoperfused tissue closer to the wound edge and hyperperfused tissue further from the wound.

A possible explanation of the discrepancy between the transcutaneous and the invasive LDF measurements could be that non-invasive LDF and invasive LDF record blood flow in different types of tissue, i.e., subcutaneous tissue in the transcutaneous technique, and muscle tissue in the invasive technique. It has been shown in previous studies that NPWT increases tissue pressure close to the wound edge, causing a decrease in blood flow (138, 143). As pig skin is quite

dense, it may resist compression, thus preserving the blood flow. Muscle tissue, however, is less dense and will be compressed to a greater extent, resulting in decreased blood flow during NPWT.

Microvascular blood flow 2.5 cm from the wound edge

Microvascular blood flow was measured 2.5 cm from the wound edge, using all three techniques, and was seen to increase regardless of the technique used. For example, at -80 mmHg, invasive LDF showed an increase in perfusion of $41 \pm 8\%$. Transcutaneous LDF showed a slight, but not significant increase of $7 \pm 3\%$, and thermodiffusion an increase of $31 \pm 20\%$.

Corresponding results have been reported in previous studies, for example, by Timmers et al. (67) using transcutaneous LDF, and by Wackenfors et al. (37) where invasive (intramuscular) LDF was used in porcine inguinal wounds. It is difficult to explain the mechanism behind this increase in blood flow. The results of Study I showed that the application of NPWT to a peripheral wound did not affect tissue pressure 1.0 cm or 2.0 cm from the wound edge. Similar results have been reported by Kairinos et al. (143). Changes in tissue pressure consequently cannot explain the increase in blood flow 2.5 cm from the wound edge. NPWT is known to cause wound contraction, as seen in Study I and in previous studies (31). It may be that the contraction of the wound creates a force on the adjacent tissue that opens up small arterioles and capillaries, ultimately causing an increase in blood flow. Previous experimental studies have shown that small arterioles and capillaries in the wound edge tissue are opened up upon the application of negative pressure (38).

The enhanced tissue perfusion following NPWT may have several beneficial effects as it helps keep the healing tissue well oxygenated. This supports the nutrient supply and helps with the removal of waste products from the healing wound (149). Poorly perfused tissue is also often hard to reach with antibiotics, hence an increased blood flow may facilitate the penetration of antibiotics to infected wounds.

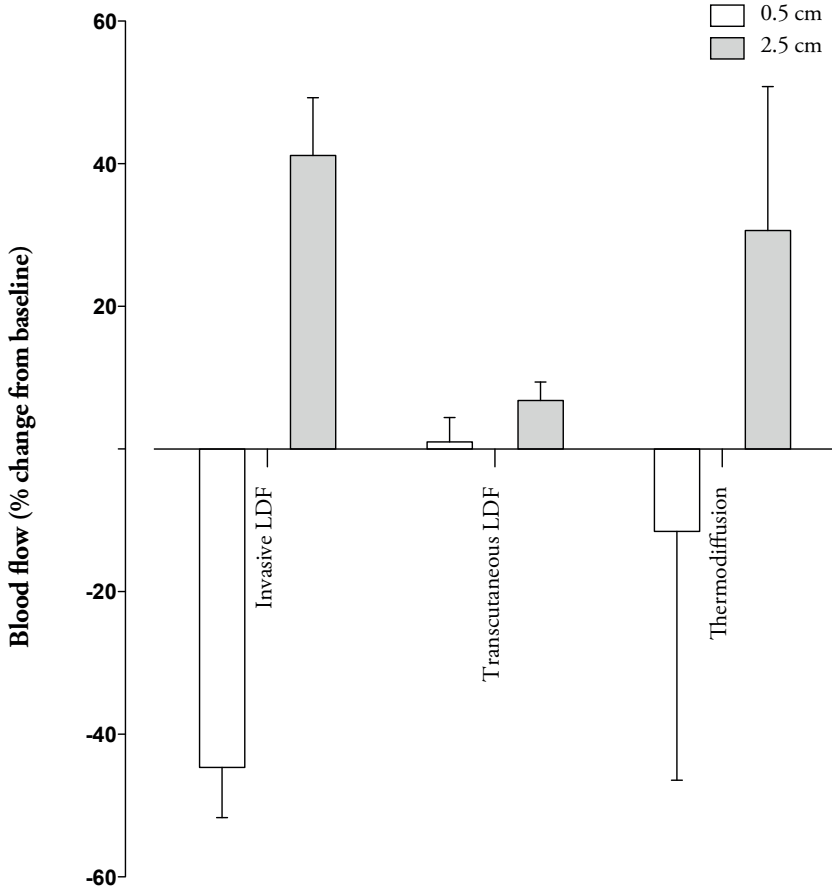


Figure 28. Blood flow as percent of baseline values (mean values and SEM) 0.5 cm and 2.5 cm from the wound edge, during NPWT at -80 mmHg.

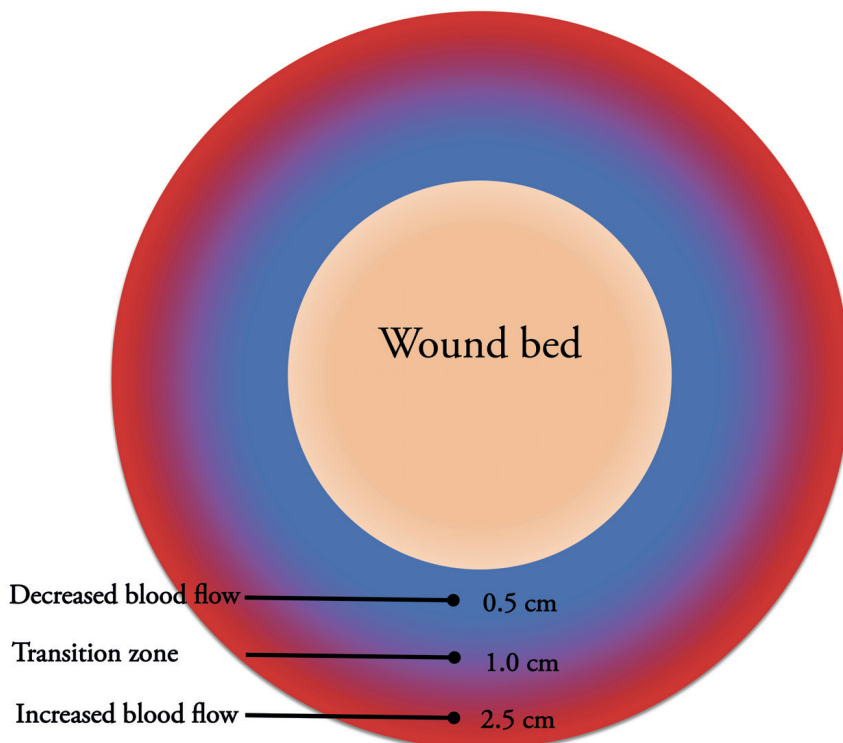


Figure 29. Changes seen in blood flow during NPWT. At a pressure of -80 mmHg the blood flow decreases 0.5 cm from the wound edge and increases 2.5 cm from the wound edge. A transition zone seems to exist about 1.0 cm from the wound edge.

The possibility of using discs to protect exposed blood vessels

Studies III-V were a series of experimental pilot studies in a porcine model performed to evaluate the effects of thin plastic discs, designed with the intention of protecting exposed blood vessels during NPWT. The main aims were to evaluate the effects of such devices, and to verify that the protective discs did not affect the fundamental mechanisms of NPWT. Blood flow in the femoral artery, wound bed microvascular blood flow, periarterial pressure and pressure transmission to the wound cavity were studied. Furthermore, wound contraction and wound fluid removal were evaluated.

Periarterial and wound cavity pressure

Pressure was measured under the discs in two different types of wounds (i.e., groin wounds exposing the femoral artery, and defect wounds on the back of the pigs), in two different studies, with similar results.

Femoral periarterial pressure (i.e., the pressure on top of the femoral artery in the groin of the pig) was measured in Study III (Figure 30) and wound cavity pressure was measured in Study IV (Figure 31). The delivery of an even pressure to the wound cavity is one of the fundamental effects of NPWT, and it is thus important to ensure that the insertion of the plastic disc does not impair this.

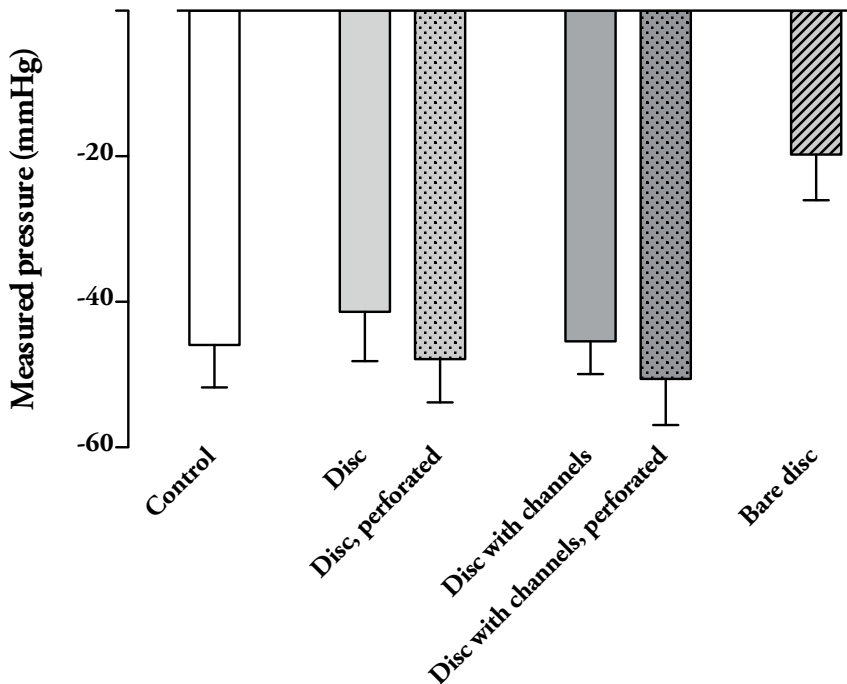


Figure 30. Periarterial pressure (mean values and SEM) during NPWT at -80 mmHg with different kinds of discs (Study III), $p > 0.30$ for all dressing-covered discs compared to control wounds.

The periarterial pressure recorded in Study III was similar in control wounds (filled with foam but no disc) and in wounds in which dressing-covered discs had been placed over the femoral artery. Typical values were -46 ± 6 mmHg for control wounds and -48 ± 6 mmHg for the dressing-covered, perforated disc, at -80 mmHg, $p > 0.30$.

The wound cavity pressure investigated in Study IV showed similar results to the periarterial pressure, i.e., no significant differences in wound cavity pressure when comparing dressing-covered discs and the control wound (filled with foam, but no disc). Typical values at -80 mmHg were -56 ± 6 mmHg in control wounds and -55 ± 6 mmHg in wounds with a dressing-covered perforated disc, $p > 0.30$.

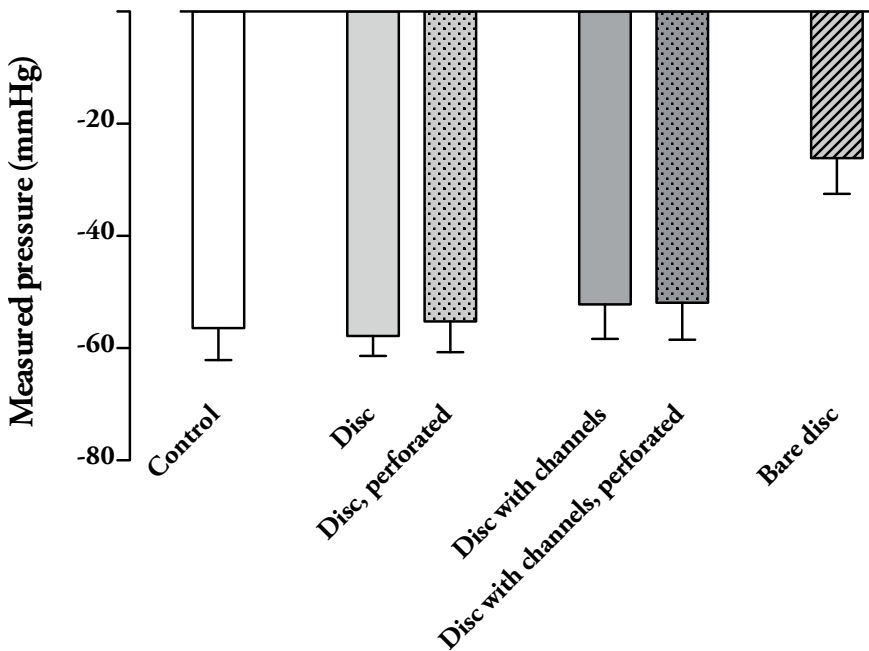


Figure 31. Wound cavity pressure (mean values and SEM) during NPWT at -80 mmHg (Study IV), $p > 0.30$ for all dressing-covered discs compared to control wounds.

Pressure transmission to the wound cavity was similar with all the dressing-covered discs studied. However, pressure transfer to the wound cavity was clearly compromised (-20 ± 6 mmHg when treated at -80 mmHg, $p = 0.013$, Study III) when using a disc without a wound dressing beneath it (i.e., the bare disc). The reason for this is most likely that the vacuum suction simply cannot find its way in under the bare disc and a form of closed space is created. Clinically, there is a considerable risk that this would lead to infection and impaired wound healing.

The wounds and the discs studied were approximately 6 cm in diameter. It cannot be assumed that the same results regarding pressure transmission to the wound cavity would be obtained if a larger rigid disc had been used, as would probably be the case in a larger wound.

Blood flow in the femoral artery

In Study III, blood flow in the femoral artery was measured in an incision wound in the groin of the pig. NPWT caused the blood flow in the artery to decrease. For example, when NPWT was applied at -80 mmHg, the blood flow was $8 \pm 4\%$ lower than the baseline value. When a thin plastic disc was inserted covering the femoral artery the blood flow was restored.

Hypoperfusion upon negative pressure application has been seen in previous studies (35-37, 138, 146), however the underlying mechanisms are not known. A possible explanation, however, may be that the vacuum pressure compresses the superficial tissue exposed in the wound. This may in turn lead to the constriction of the vasculature, either the microvasculature (35-37, 138, 146) or a larger artery (as in Study III). Compression of a large blood vessel may impair the blood flow to the blood vessel wall itself, via the vasa vasorum, causing local ischemia and tissue damage (i.e., damage to the blood vessel wall). It may also impair the blood flow to more distal tissues that are supplied by the artery. It may be speculated that the complications reported during NPWT (e.g. the rupturing of blood vessels and vascular grafts) (116) are caused by both hypoperfusion of the blood vessel wall (leading to ischemia and ultimately necrosis), and by tearing forces exerted by the vacuum pressure. Furthermore, anastomoses are known to be particularly sensitive to hypoperfusion, which may explain why treating these kinds of structures with NPWT may be especially problematic.

After recording the blood flow with no disc present, the femoral artery was covered with thin plastic discs of different designs and the blood flow was once again measured. After inserting the thin plastic disc, the blood flow increased as NPWT was applied (e.g. $8 \pm 4\%$ at -80 mmHg for a dressing-covered, perforated disc, $p = 0.025$). All discs had similar effects on blood flow ($p > 0.30$).

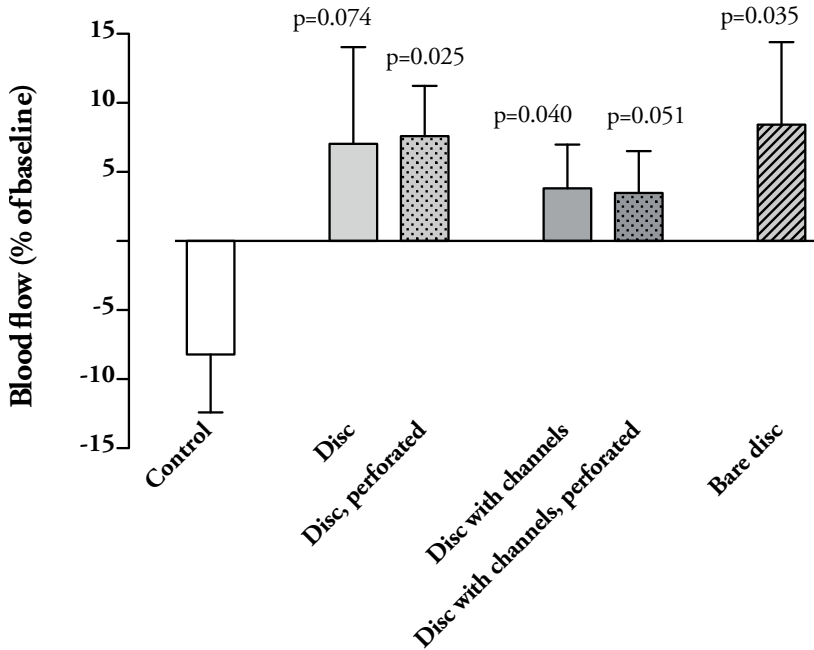


Figure 32. Changes in femoral artery blood flow studied in a 6 cm incision wound in the groin of the pig (mean values and SEM) as percent of baseline values, during NPWT at -80 mmHg (Study IV).

In Study III the effect of NPWT on a large artery (i.e., the femoral artery) was investigated. When the wound bed with the exposed artery was subjected to vacuum pressure, the blood flow in the artery decreased. When a thin disc was inserted between the wound bed and the foam filler the blood flow was restored. We have previously studied blood flow through large arteries and found that the blood flow through the mammary artery was not affected when NPWT was applied to a sternotomy wound (150). The results found in Study III thus differ from our earlier studies and the reason for discrepancy may very

well be that the mammary artery is imbedded in tissue and located more than 3 cm away from the wound subjected to negative pressure therapy. The femoral artery in Study III, on the other hand, was in immediate contact with the negative pressure. The results of Study I indicate that the compressive forces exerted by NPWT extend less than 1 cm into the wound bed tissue. From a clinical point of view, this means that delicate structures such as blood vessels probably only require protection during NPWT when they are directly exposed to NPWT, or located in close proximity to the wound bed. Thus, protective discs may not be needed in all wounds, and their use should be weighed against the positive effects of NPWT in accelerating wound healing. A plastic disc inserted between the wound filler and the wound bed may very well impair the microdeformative effects of NPWT on the wound bed, which in turn may slow down the formation of granulation tissue. The impact of a plastic disc on wound healing has not yet been studied, and it is anticipated that such a study would provide valuable information.

Microvascular blood flow in the wound bed

NPWT causes changes in microvascular perfusion. Areas of both hyper- and hypoperfusion were reported in Study II. It has long been debated whether the hypoperfusion seen during NPWT is favorable or not (35-37, 142, 143). It may be speculated that a decrease in blood flow triggers the release of wound-healing factors stimulating angiogenesis and granulation tissue formation. Also, compression of the wound edge wall may tamponade superficial postoperative bleeding (151). On the other hand, hypoperfusion may cause critical ischemia in poorly vascularized tissue, for example, in superficial skin flaps or diabetes wounds. Likewise, in wounds with exposed delicate structures such as blood vessels, hypoperfusion may cause ischemia and necrosis followed by rupture of the blood vessel wall.

In Study IV, wound bed microvascular blood flow was studied in a defect wound, 6 cm in diameter, on the back of the pig. When NPWT was applied at -80 mmHg, blood flow in the wound bed decreased by $49 \pm 7\%$ in control wounds. When a disc was inserted, the decrease in blood flow was less pronounced; for example, blood flow decreased by only $6 \pm 5\%$ when using a perforated disc (with underlying dressing), ($p = 0.006$ compared to control). The presence of the various dressing-covered discs (perforated and non-

perforated discs with and without channels) resulted in similar reductions in blood flow ($p > 0.30$). Three out of the five discs showed a significant difference compared to control wounds without discs. The results are presented in Figure 33.

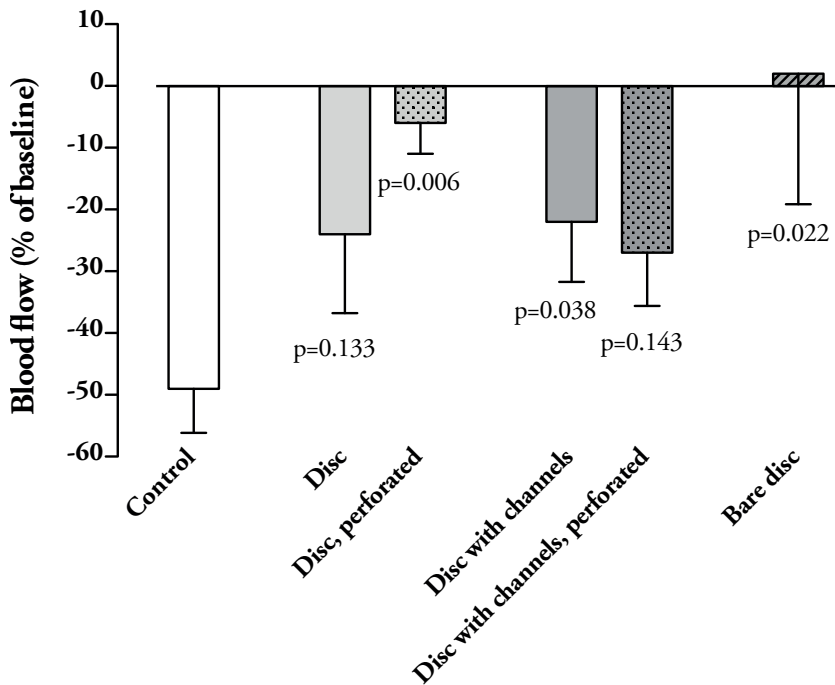


Figure 33. Changes in wound bed microvascular blood flow in a 6 cm defect wound on the back of the pig (mean values and SEM) as percent of baseline values, during NPWT at -80 mmHg (Study IV).

Three of the five discs provided alleviation of hypoperfusion, compared to the control wounds, while the other two discs only showed a tendency towards alleviation, compared to the control wounds. The underlying mechanisms for this difference cannot be concluded from Study IV. However, the difference may be due to the small number of measurements, and a larger sample size may shed light on this.

It is known that NPWT causes contraction and mechanical deformation of the wound bed tissue (31, 139). The mechanical tension on the wound bed may tear and damage exposed sensitive structures such as blood vessels. Study IV showed that the reduction in blood flow was less prominent in the presence of a protective plastic disc. This may be the result of the disc ameliorating the mechanical shearing forces exerted on the wound bed. The protective properties of these plastic discs must be studied further, but it may be speculated that they can protect sensitive structures such as blood vessels by reducing the mechanical forces exercised on an exposed blood vessel during NPWT. It must be borne in mind that the purely protective properties of these thin plastic discs were not investigated in Study IV.

Wound contraction

Study V was designed to investigate whether the use of a thin plastic disc impaired wound contraction or fluid evacuation during NPWT. Defect wounds, 10 cm in diameter, on the back of the pigs were studied. The wound diameter was measured in two orthogonal directions with a Vernier caliper, and the mean value was calculated. NPWT at 80 mmHg was applied. The degree of wound contraction was similar in control wounds and in wounds with a disc. For example, the wound diameter decreased to $91 \pm 1\%$ of the initial size when negative pressure was applied using only foam (control) and to $92 \pm 1\%$ in the presence of a disc (i.e., a dressing-covered, perforated disc). No statistical differences were seen between the various discs tested and the control wounds.

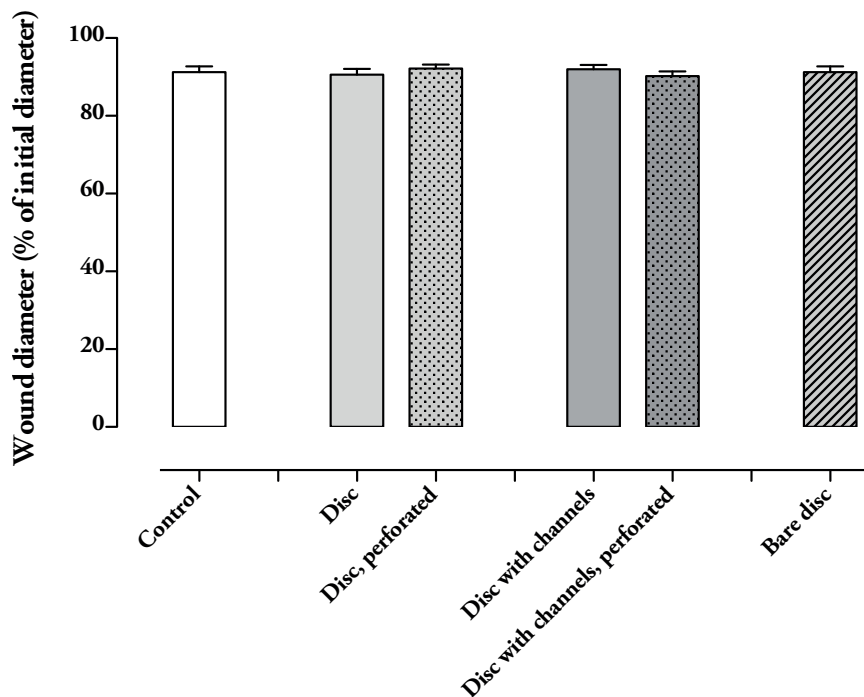


Figure 34. Wound diameter (mean values and SEM) as percent of the initial diameter, in a 10 cm defect wound on the back of the pig (mean values and SEM), during NPWT at -80 mmHg (Study V), $p > 0.30$.

In summary, the presence of a plastic disc did not impair wound contraction during NPWT. These findings are important since wound contraction is a key effect of NPWT (72), causing shearing forces that affect the cytoskeleton of the wound tissue cells (33). The exact mechanisms following this are not clear, but it is known that growth factor pathways are stimulated, that result in mitosis (152, 153) and production of new tissue (30). Wound contraction following NPWT is also essential in the management of open-abdomen wounds following, for example, trauma and abdominal infection (154), where it creates an opportunity for wound closure.

In Study V the changes in wound contraction were presented as percent of the initial wound surface area. The power of a statistical calculation based on a difference in wound surface area has been questioned. In this thesis, the results

are therefore presented as percent of the initial wound diameter. The results and the statistics in the original article (Study V) and in the present thesis are similar and the same conclusion can therefore be drawn.

Fluid evacuation from the wound cavity

In addition to examining wound contraction, the aim of Study V was also to evaluate fluid evacuation in the presence of a disc. Defect wounds, 10 cm in diameter, on the back of the pig were studied. The amount of fluid removed increased steadily during the first 30 seconds, and then levelled off. No differences were seen in the rate of wound fluid removal, or in the total volume of wound fluid removed, when comparing control wounds to wounds prepared with thin discs. For example, 73 ± 3 ml had been removed after 2 min of treatment when using only foam (control) and 71 ± 4 ml had been removed in the presence of a dressing-covered perforated disc.

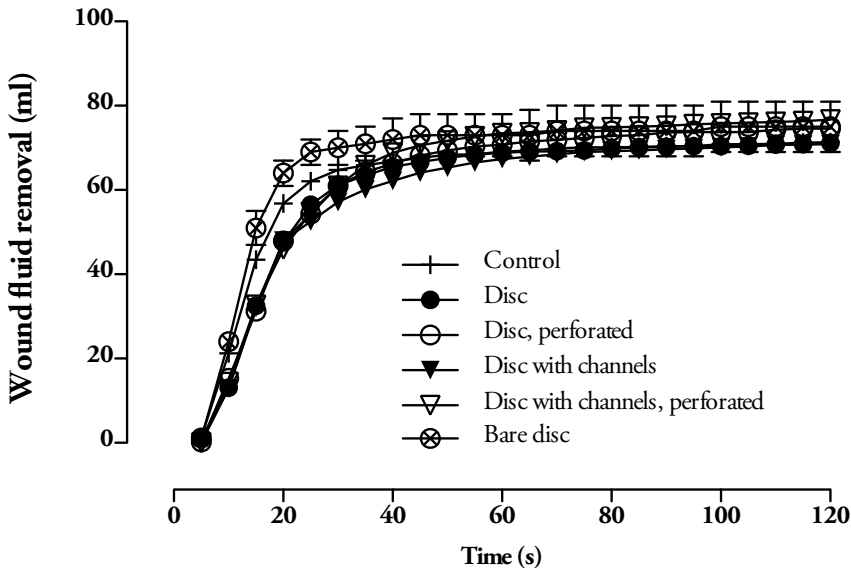


Figure 35. Wound fluid evacuation (mean values and SEM) during NPWT at -80 mmHg as a function of time (Study V).

The results showed that the presence of a thin plastic disc during NPWT did not impair wound fluid evacuation, which is important, since wound fluid

removal is thought to be one of the central features of NPWT, leading to enhanced wound healing. The importance of wound fluid removal has been pointed out in previous studies (28-30). Chronic wound fluid has been shown to inhibit cell proliferation (155, 156), and chronic inflammation is linked to a negative cycle in which inflammatory cells secrete cytokines, which in turn attract more inflammatory cells (19). At a molecular level, this causes an imbalance between the amount of proteases (e.g. MMP-3, MMP-9), protease inhibitors (e.g. TIMP-1), and pro-inflammatory cytokines (e.g. TNF- α , IL-1 β) (157-159). Stagnant wound fluid also increases the risk of abscesses.

Only short-term effects on wound fluid evacuation during NPWT were investigated. In such a wound model, the wound fluid has low viscosity and is easily removed by suction. Chronic wounds may be more prone to wound fluid stagnation since the wound fluid often becomes more viscous with time as the amount of fibrin increases and as platelets aggregate. Long-term studies into this are needed to investigate the effects of a protective disc on wound fluid removal in a chronic wound setting.

In summary, these first studies show no negative side effects when inserting a plastic disc into the wound during NPWT; pressure transmission was equally good with and without a disc, as were wound contraction and wound fluid removal. Femoral artery blood flow decreased when NPWT was applied, but was restored when a disc was inserted. Likewise, microvascular blood flow in the wound bed tissue decreased when NPWT was applied, but the reduction was less pronounced when a disc was inserted. However, the long-term protective properties of a plastic disc have not been studied, and neither has the effect of such a disc on long-term wound healing. These crucial issues must be studied further.

Reflections on the design of the discs

Discs of five different designs were evaluated in Studies III, IV, and V. With one exception, the undersides of the discs were covered with a thin layer of foam. Two of the discs had perforations. The reason for adding a thin layer of open-pore foam underneath the discs was that we believed that this would facilitate negative pressure transmission to the wound bed and the removal of wound fluid from beneath the disc. It was also hypothesized that providing the

discs with perforations might further promote pressure transmission and wound fluid removal.

These hypotheses were partly confirmed. Pressure transfer to the wound cavity was actually impaired when using a bare disc (i.e., without an underlying foam-dressing) (Studies III, and IV). Interestingly, the pressure in the wound cavity was of a similar magnitude regardless of whether the disc was perforated or not, suggesting that pressure transmission occurs in the dressing that covers the disc, as well as through the perforations of the disc. However, as Studies III, IV, and V were designed to evaluate the short-term effects of the plastic discs, it cannot be deduced whether the presence of a disc limits long-term wound healing. It is of great importance that pressure is mediated to the underside of the disc and distributed evenly over the whole wound cavity in order to facilitate wound fluid drainage, and to prevent the formation of dead space. Dead space may allow infection, resulting in the formation of abscesses and fistulae.

Interestingly, wound fluid removal did not differ when comparing a disc with a thin layer of foam underneath, to a disc without foam (Study V). Neither did the presence of perforations in the discs have any effect on wound fluid removal. This suggests that lateral fluid displacement takes place beneath the discs. However, the wounds were only 10 cm in diameter, and only the short-term effects were evaluated in these studies. It cannot, therefore, be deduced that the same results regarding pressure transmission to the wound bed and wound fluid evacuation would have been seen if the wounds had been larger, and larger discs had been used. Furthermore, long-term fluid evacuation and pressure transmission to the wound cavity were not examined. It may be that, as the size of the disc or the wound increases, perforations in the discs would become more important for adequate fluid removal, to minimize the risk of fluid stagnation beneath the discs. Non-perforated discs were included in these studies for scientific reasons only. For the reasons stated above, it is likely that only perforated discs will be used clinically in the future. Wound fluid stagnation may arise in the long-term clinical situation for several reasons, e.g. increased viscosity with time, coagulated blood, and the formation of adherences that hinder wound fluid removal. The removal of wound debris and exudate is of great importance, both in an infected wound and when there is a risk of an encapsulated infection.

Study V also showed that the presence of a protective disc did not impair wound contraction. The discs used were of the same size as the wound.

However, in a clinical situation it might suffice to place a disc only over structures needing protection. The effect of smaller discs has not been studied. It is likely that mechanical deformation of the wound bed will take place outside the area of the plastic disc, whereas the mechanical effect on wound bed that is covered by the disc will not be of the same magnitude. It is important to maintain the largest possible micro- and macrodeformation in order not to reduce the beneficial effects of NPWT.

NPWT is an excellent treatment option for certain complex wounds. However, treatment related side effects might put patients at substantial risk. This may in severe cases lead to serious harm and even death. In the challenge to try to find a solution to reduce these negative side effects we set out to develop a protective device used in conjunction with NPWT. However, when introducing a device in conjunction with an established method, for example NPWT, one has to make sure that the positive effects of the treatment remains and that the negative side effects are reduced. One also has to make sure that no new unforeseen side effects arise. Hence, before introducing a novel device into clinical practice, to improve an already existing therapy, substantial preclinical studies on animals have to be done. In this thesis we have tried to answer some of those questions but many questions do remain and we believe further research in this field is required.

Conclusions

Different types and sizes of wound fillers

NPWT created a hypobaric environment in the superficial wound edge tissue (0.1 cm from the wound edge), which may trigger the transport of interstitial fluid, helping the diffusion of oxygen and nutrients to the healing tissue. Further away from the wound edge (i.e., 0.5 cm from the wound edge) the pressure increased, an effect that may be the result of wound contraction and the resulting deformation of the wound edge during NPWT.

The use of a small foam wound filler caused considerable wound contraction, which may be beneficial when maximal mechanical stress and granulation tissue formation are desirable. In contrast, gauze or a large foam filler caused less wound contraction, which may be more suitable when NPWT causes discomfort to the patient.

It has been shown in the present work, and by others that NPWT elicits hypoperfusion in the wound edge tissue. This is presumably the result of the increased pressure on the tissue caused by NPWT. It is well known that these effects can be controlled by changing the level of negative pressure applied. Choosing the appropriate wound filler size and material may be another way of controlling wound edge tissue perfusion. Hypoperfusion may be beneficial in that it stimulates angiogenesis, needed for wound healing. However, in wounds with compromised perfusion there may be a risk of ischemia. Adjusting the therapy by decreasing the level of negative pressure or changing the type or size of the wound filler may be necessary. This must however be studied in greater detail before being implemented in clinical practice.

Microvascular blood flow & different measurement techniques

The effect of NPWT on microvascular blood flow in the wound edge tissue has been the subject of considerable debate. Different measurement techniques, including transcutaneous LDF, invasive LDF and thermodiffusion were used in this work in order to determine whether they detect different results. It was found that the blood flow decreased 0.5 cm from the wound edge during NPWT, when measured with the invasive techniques. This may be the result of the increased wound edge tissue pressure caused by NPWT. Further from the wound edge (i.e. 1.0 cm from the wound edge) blood flow was dependent on the level of negative pressure applied, i.e. a transition zone was seen. When using low pressure levels blood flow increased, while higher levels of negative pressure caused the blood flow to decrease. Microvascular blood flow increased 2.5 cm from the wound edge, regardless of the technique used. NPWT creates a pulling force on the tissue that may open up vascular beds and increase blood flow. The combination of hypo- and hyperperfusion stimulated by NPWT may be beneficial as hyperperfusion enhances oxygen and nutrient levels, while hypoperfusion stimulates angiogenesis. However, in a wound that is poorly vascularized there may be a risk of ischemia (as discussed earlier).

The possibility of using discs to protect exposed blood vessels

NPWT of wounds with exposed sensitive structures such as blood vessels, has caused serious complications and deaths during recent years. According to the FDA, bleeding from exposed blood vessels is the most serious adverse event during NPWT. In this work the possibility of using thin plastic discs to protect exposed blood vessels in the wound bed during NPWT was explored; specifically the effects on femoral artery blood flow and microvascular wound bed tissue blood flow, femoral periarterial pressure, pressure transmission to the wound cavity, wound contraction, and wound fluid removal.

Discs of different designs were placed on the wound bed underneath the foam, and the wound was treated with NPWT. Femoral artery blood flow decreased

when NPWT was applied, but was restored when a disc was inserted. Likewise, microvascular blood flow in the wound bed tissue decreased when NPWT was applied, but the reduction was less pronounced when a disc was inserted. The key mechanisms of NPWT; i.e. pressure transmission to the wound cavity, wound contraction, and wound fluid removal, were not impaired by the discs. It should be noted that the protective qualities of the plastic discs were not evaluated in this work. Neither have the long-term effects of discs on wound healing been studied. These issues should be studied in an animal model before human studies can be performed. However, we believe that the work presented in this thesis constitutes an important step towards a possible solution to the clinical problem of perforated blood vessels and bleeding during NPWT.

It is our hope that NPWT can be developed to become a safe therapy, with few complications. We believe that the therapy may be individualized in order to maximize the speed and quality of healing, while affording the patient greater comfort. The work described in this thesis is an attempt to explore some of these issues in an experimental wound model, in order to provide the basis for future development.

Future research

The results of Study I showed that NPWT could be affected by varying the type and size of wound filler; foam lead to greater wound contraction than gauze. However, these studies were carried out on animals, and human studies are required to substantiate these findings before clinical recommendations can be made. For example, a randomized control trial examining outcomes such as patient pain and time to full healing, with two arms, gauze treatment in one and foam treatment in the other, would be particularly interesting.

Study II showed that the blood flow *decreased* 0.5 cm from the wound edge, but *increased* 2.5 cm from the wound edge. This is in line with previous studies by our group. Since the publication of Study II further studies on wound edge perfusion have been published. Kairinos et al. found no evidence of increased blood flow 2.5 cm from the wound edge during NPWT (160), however, their study was based on measurements on intact skin, and not wounds. Furthermore, LDF has been criticized as a method of measuring blood flow during NPWT (133). In Study II, we used not only LDF but also thermodiffusion to measure blood flow, and the two techniques showed similar results. This strengthens our belief that LDF is a useful and reliable technique when evaluating blood flow during NPWT. Further studies using thermodiffusion to evaluate wound edge perfusion would, however, be very valuable.

Additionally, novel techniques are emerging for measurements of tissue perfusion, for example, photoacoustic imaging (PAI). This method entails the use of both lasers and ultrasound, and has been suggested to be a very promising instrument for measuring, among other things, perfusion (161). It has already been used to measure heart blood flow in zebrafish (162). PAI relies on the photoacoustic effect, first described by Graham Bell in the late 1800s. Emitted laser light is used to illuminate a sample. The absorbed light heats the sample, which causes thermal expansion and ultimately acoustic waves, which can be registered with ultrasound and converted into images, or used to

measure blood flow (163). PAI could thus provide another method of measuring blood flow during NPWT, in addition to thermodiffusion and LDF.

The results of Studies III-V suggest that a thin disc placed over the wound bed could be beneficial in protecting vital structures such as blood vessels from damage or rupture during NPWT. However, no long-term studies were carried out on wound healing or the actual protective effect of these discs. The next step is to investigate these matters further in animal models, for example, by studying the production of granulation tissue and the frequency of wound infections in the presence of a thin protective disc compared to control wounds and, of course, whether the disc can prevent the rupture of blood vessels. If such studies were to show good results, randomized, controlled studies could be performed in a human model to investigate whether the disc can protect blood vessels against complications such as perforation followed by severe bleeding.

Populärvetenskaplig sammanfattning

Popular scientific summary in Swedish

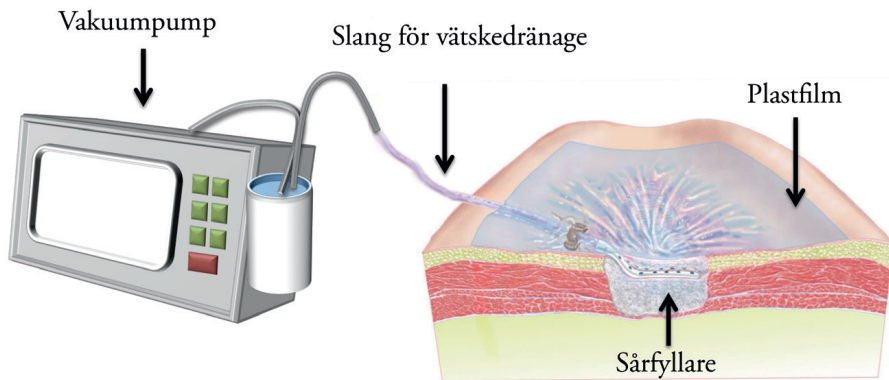
Undertrycksbehandling av sår, på engelska *negative pressure wound therapy* (förkortat NPWT) är en teknik som används vid behandling av svårläkta akuta och kroniska sår. Med hjälp av NPWT läker vissa typer av sår mycket snabbare än vid traditionell sårbehandling. I bildtexten på nästa sida ges en kort beskrivning av hur metoden fungerar. Tekniken utvecklades i slutet av 1990-talet och har sedan dess blivit mycket populär. NPWT bygger på att man via en vakuumpump skapar ett undertryck i sårhålan, som leder till en mängd vidare effekter, t.ex. dras såret samman, vilket skapar mekaniska drag- och tryck-effekter som aktiverar flera steg i sår-läkningsprocessen. Därtill transporterar NPWT bort överflödiga sårvätska (som visat sig innehålla substanser som hämmar sår-läkning) samt genererar förändringar i blodcirkulationen till sårområdet, som man bland annat tror gynnar nybildningen av blodkärl. Trots att metoden används flitigt har man inte helt klarlagt vad som händer i såret vid NPWT. Till exempel finns oenighet kring om blodflödet i sårområdet ökar eller minskar. Denna avhandling baseras på fem studier, som presenteras nedan.

Syftet med Studie I och II var att kartlägga vad som sker i såret och dess omgivande vävnad vid NPWT. Blodflöde, tryckförändringar och sårets kontraktion undersöktes. Vidare studerades om olika storlek och material på sår-fyllaren ger olika effekter på sårkontraktion och undertryck i såret. Förhoppningsvis kommer man i framtiden kunna individualisera behandlingstekniken för att passa patienter med olika typer av sår.

Studie I visade att NPWT gav upphov till ett kraftigt undertryck i sårhålan, som till viss del fortleddes även 1 mm ut i vävnaden. På 5 mm:s avstånd från sårets kant finns inte längre något undertryck, utan istället ett positivt vävnads-tryck. På 10 och 20 mm avstånd påverkades inte trycket av NPWT. Vidare sågs

att en liten mängd sårfillnadsmaterial av skum gav större sårkontraktion än en stor mängd. Vid användning av gasväv som sårfillnadsmaterial sågs måttlig sårkontraktion. Vissa patienter måste avbryta NPWT på grund av att behandlingen gör för ont. En möjlig orsak kan vara att sårkontraktionen blivit för kraftig. Skulle smärta uppstå kan man överväga att byta sårfillnadsmaterial till gasväv, som ju endast gav en måttlig kontraktion av såret, jämfört med svamp.

I Studie II sågs att blodflödet vid NPWT minskade 5 mm från sårhålets kant, medan det på 25 mm:s avstånd faktiskt ökade. Ett minskat blodflöde tror man ökar nybildningen av blodkärl vilket underlättar sårhäkning. Ett ökat blodflöde är också gynnsamt, då detta ger förbättrad syresättning i såret, samt ökar inflödet av näringsämnen.



På den högra bilden ses hud i genomsnitt med sår centralt. Såret är fyllt med s.k. sårfillnadsmaterial, antingen svamp eller gasväv (i detta fall gasväv), för att underlätta fortledningen av undertrycket till hela sårbotten. Ovanpå gasväven ligger en tunn slang, kopplad till en vakuumpump (vänster). Via slangen skapas ett sugtryck (undertryck) i såret. Såret är täckt med en tunn självhäftande plastfilm för att undertrycket ska behållas i såret. Plastfilmen motverkar också bakterieöverföring från intilliggande vävnad och skapar en lagom fuktig miljö vilket underlättar sårhäkning. Via slangen leds överbliven sårvätska från sårhålan till en uppsamlande behållare. På pumpen kan man ställa in önskat undertryck. Normalt sett brukar man använda -80 mmHg till -120 mmHg sugtryck.

I början av 2000-talet började rapporter om biverkningar från NPWT komma. 2011 presenterade Food and Drug Administration (Läkemedelsverkets amerikanska motsvarighet) en rapport där man beskrev 12 dödsfall och 174 skador till följd av NPWT, bara under 4 år och endast i USA. Bland annat har man sett att hjärtats högerkammare kan spricka med omedelbar död som följd

vid undertrycksbehandling av infektioner bröstben efter öppen hjärtkirurgi. Utöver detta har man också sett allvarliga blödningar vid behandling av sår där stora blodkärl ligger exponerade i sårbotten. Trots dessa risker fortsätter man behandla denna typ av sår på grund av i övrigt mycket goda behandlingsresultat, avsaknad av alternativa behandlingsstrategier och till viss del okunskap om effekterna av NPWT.

Vår forskningsgrupp var 2009 först i världen med att visa varför hjärtat riskerar att spricka vid NPWT av infekterade bröstbenssår efter öppen hjärtkirurgi. Genom försök på sövda grisar såg vi hur hjärtat sögs upp mot bröstbenets underdel och skavde mot de vassa kanter som bildats efter kirurgi. Vi försökte skydda hjärtat genom att lägga gasväv mellan hjärtat och bröstbenet, dock utan resultat. När vi istället placerade en tunn platta som skydd såg vi däremot att hjärtat inte längre tog skada. Denna skyddande platta har i senare studier visat sig förhindra skador på hjärtat. När vi såg hur hjärtat kunde skyddas av en tunn plastplatta fick vi idén att försöka ta fram en platta för skydd av exponerade blodkärl.

I Studie III, IV och V undersöktes möjligheten att, vid NPWT, skydda blodkärl som ligger exponerade i sårbotten, genom att täcka dessa med en skyddande platta. Fem olika tunna plastplattor togs fram och undersöktes i studierna. Vår hypotes var att dessa kunde motverka bristning och blödning i exponerade blodkärl i sår som behandlas med NPWT. Ett exempel på sår med utsatta kärl är ljumskår, där lårbensartären ligger mycket ytligt. Specifikt studerades effekten på blodflöde genom ett stort kärl (den ytliga lårbensartären) och i små kärl i omgivande vävnad, samt hur undertrycket fortplantade sig till sårhålan. Vidare studerades evakuering av sårvätska från sårhålan samt sårets kontraktion.

Vi såg att blodflödet i den ytliga lårbensartären minskade under NPWT av ett sår i ljumskan på grisen. När en täckande platta placerades ovan artären återställdes blodflödet. Samma effekt såg vi på blodflödet i sårbotten; blodflödet minskade vid undertrycksbehandling, men när vi placerade en täckande platta i såret så återställdes blodflödet delvis. Vi kunde också säkerställa att de grundläggande effekterna av NPWT inte försvagades vid användning av plattorna; undertrycket fortplantade sig till sårhålan, sårvätskan sögs bort från såret och såret drog ihop sig.

Acknowledgements

Utan Er hjälp hade detta inte varit möjligt. Jag vill därför tacka:

Sandra Lindstedt Ingemansson, huvudhandledare. Ett stort tack för ditt engagemang och din positivitet! Ditt stöd och din uppmuntran har varit fantastiskt!

Malin Malmsjö, bihandledare. Jag minns fortfarande när du bjöd mig på pizza (jag var fattig student på den tiden) på V.E.S.P.A i Lund, för att berätta om några försök du hade på gång. När jag gick därifrån var jag såld! Jag letade efter ett examensprojekt, det slutade med något helt annat nämligen detta. Din outtröttliga entusiasm, energi och glädje har varit av ovärderlig hjälp. Utan dina insatser hade denna avhandling aldrig skrivits. Tack Malin!

Christian Torbrand, bihandledare. För fenomenal stöttning och peppning under skrivandet av min avhandling och för härligt sällskap under många och långa grisförsök.

Rickard Ingemansson, för oerhört värdefullt stöd, särskilt inför halvtidskontroll!

Ola Borgquist, din skarpsynthet, förmåga att ifrågasätta och se nya infallsvinklar har förbättrat varje artikel vi skrivit tillsammans och du lärt mig hur en riktig vetenskapsman jobbar! Din (ofta bisarra) humor har förgyllt våra långa försöksdagar.

Markus Roupé, Erik Hedström för er värdefulla hjälp under försök och skrivande av ”platt-peken”.

Mina medförfattare **Julia Waga, Peter Robertsson** och **Charles K. Lee**.

Helen Sheppard för att din finslipning av språket gjort min avhandling många strån vassare.

Bo Veisland för otroliga illustrationer.

Nina. För att du den finaste människan som finns! För att du (och dina stenar) ger mig så mycket energi och glädje. Varje dag. Jag älskar dig.

Mamma **Eva** och pappa **Pälle**. För allt ni gjort och gör för mig. För att ni alltid finns där.

Mina syskon **Elin** och **Åsa**, för ert alltid lika underbara sällskap och era fantastiska familjer. Det är alltid en glädje att ses!

Till **mina vänner**, särskilt **Andreas** och **Martin** för er gästfrihet när jag gästade Lund och Malmö för forskningskurser. Jag kommer att sakna att sova på era golv! **Mattias**, för handfasta råd inför skrivandet av denna avhandling.

Slutligen vill jag tacka min nuvarande arbetsplats, **Hjärtkliniken Danderyds sjukhus**, särskilt **Viveka** och **Raffaele**, för att ni givit mig tid att skriva denna avhandling!

References

1. Leaper DJ, Schultz G, Carville K, Fletcher J, Swanson T, Drake R. Extending the TIME concept: what have we learned in the past 10 years? *Int Wound J*. 2012;9:1-19.
2. Gottrup F, Holstein P, Jorgensen B, Lohmann M, Karlsmar T. A new concept of a multidisciplinary wound healing center and a national expert function of wound healing. *Archives of surgery (Chicago, Ill : 1960)*. 2001;136(7):765-72.
3. Phillips T, Stanton B, Provan A, Lew R. A study of the impact of leg ulcers on quality of life: financial, social, and psychologic implications. *Journal of the American Academy of Dermatology*. 1994;31(1):49-53.
4. Sen CK, Gordillo GM, Roy S, Kirsner R, Lambert L, Hunt TK, et al. Human skin wounds: A major and snowballing threat to public health and the economy. *Wound repair and regeneration : official publication of the Wound Healing Society [and] the European Tissue Repair Society*. 2009;17(6):763-71.
5. Moro MLMD, Morsillo FMS, Tangenti MRN, Mongardi MRN, Pirazzini MCRN, Pietro Ragni MD, et al. Rates of Surgical-Site Infection: An International Comparison. *Infection Control and Hospital Epidemiology*. 2005;26(5):442-8.
6. Stadelmann WK, Digenis AG, Tobin GR. Physiology and healing dynamics of chronic cutaneous wounds. *Am J Surg*. 1998;176(2):26S-38S.
7. Hanson D, Langemo D, Thompson P, Anderson J, Hunter S. Understanding wound fluid and the phases of healing. *Adv Skin Wound Care*. 2005;18(7):360-2.
8. Johnstone CC, Farley A. The physiological basics of wound healing. *Nursing standard (Royal College of Nursing (Great Britain) : 1987)*. 2005;19(43):59-65.
9. Eaglstein WH. Moist wound healing with occlusive dressings: a clinical focus. *Dermatologic surgery : official publication for American Society for Dermatologic Surgery [et al]*. 2001;27(2):175-81.
10. Lorenz HP, Longaker M. Wounds: Biology, Pathology, and Management. In: Norton J, Barie P, Bollinger RR, Chang A, Lowry S, Mulvihill S, et al., editors. *Surgery*: Springer New York; 2008. p. 191-208.

11. Ennis WJ, Meneses P. Wound healing at the local level: the stunned wound. *Ostomy Wound Manage.* 2000;46(1):39S-48S.
12. Lazarus GS, Cooper DM, Knighton DR, Percoraro RE, Rodeheaver G, Robson MC. Definitions and guidelines for assessment of wounds and evaluation of healing. *Wound repair and regeneration : official publication of the Wound Healing Society [and] the European Tissue Repair Society.* 1994;2(3):165-70.
13. Mustoe T. Understanding chronic wounds: a unifying hypothesis on their pathogenesis and implications for therapy. *The American Journal of Surgery.* 2004;187(5):S65-S70.
14. Werdin F, Tennenhaus M, Schaller H-E, Rennekampff H-O. Evidence-based management strategies for treatment of chronic wounds. *Eplasty.* 2009;9.
15. Panuncialman J, Falanga V. The Science of Wound Bed Preparation. *Surgical Clinics of North America.* 2009;89(3):611-26.
16. Schultz GS, Sibbald RG, Falanga V, Ayello EA, Dowsett C, Harding K, et al. Wound bed preparation: a systematic approach to wound management. *Wound repair and regeneration : official publication of the Wound Healing Society [and] the European Tissue Repair Society.* 2003;11:1-28.
17. Steed DL, Donohoe D, Webster MW, Lindsley L. Effect of extensive debridement and treatment on the healing of diabetic foot ulcers. *Diabetic Ulcer Study Group. Journal of the American College of Surgeons.* 1996;183(1):61-4.
18. Trengove NJ, Stacey MC, MacAuley S, Bennett N, Gibson J, Burslem F, et al. Analysis of the acute and chronic wound environments: the role of proteases and their inhibitors. *Wound repair and regeneration : official publication of the Wound Healing Society [and] the European Tissue Repair Society.* 1999;7(6):442-52.
19. Mast BA, Schultz GS. Interactions of cytokines, growth factors, and proteases in acute and chronic wounds. *Wound repair and regeneration : official publication of the Wound Healing Society [and] the European Tissue Repair Society.* 1996;4(4):411-20.
20. James GA, Swogger E, Wolcott R, Pulcini E, Secor P, Sestrich J, et al. Biofilms in chronic wounds. *Wound repair and regeneration : official publication of the Wound Healing Society [and] the European Tissue Repair Society.* 2008;16(1):37-44.
21. Wolcott RD, Rumbaugh KP, James G, Schultz G, Phillips P, Yang Q, et al. Biofilm maturity studies indicate sharp debridement opens a time- dependent therapeutic window. *Journal of wound care.* 2010;19(8):320-8.

22. Gupta S, Bates-Jensen B, Gabriel A, Holloway A, Niezgoda J, Weir D. Differentiating negative pressure wound therapy devices: an illustrative case series. *Wounds*. 2007;19(1):1-9.
23. Dowsett C, Newton H. Wound bed preparation: TIME in practice. *WOUNDS UK*. 2005;1(3):58.
24. Broussard KC, Powers JG. Wound Dressings: Selecting the Most Appropriate Type. *American Journal of Clinical Dermatology*. 2013;14(6):449-59.
25. Loots MA, Lamme EN, Mekkes JR, Bos JD, Middelkoop E. Cultured fibroblasts from chronic diabetic wounds on the lower extremity (non-insulin-dependent diabetes mellitus) show disturbed proliferation. *Archives of dermatological research*. 1999;291(2-3):93-9.
26. Mendez-Eastman S. Guidelines for using negative pressure wound therapy. *Adv Skin Wound Care*. 2001;14(6):314-22.
27. Malmsjö M, Borgquist O. NPWT settings and dressing choices made easy. *Wounds International*. 2010;1(3):1-6.
28. Argenta LC, Morykwas MJ. Vacuum-assisted closure: a new method for wound control and treatment: clinical experience. *Ann Plast Surg*. 1997;38(6):563-77.
29. Morykwas MJ, Argenta LC, Shelton-Brown EI, McGuirt W. Vacuum-assisted closure: a new method for wound control and treatment: animal studies and basic foundation. *Ann Plast Surg*. 1997;38(6):553-62.
30. Morykwas MJ, Simpson J, Punger K, Argenta A, Kremers L, Argenta J. Vacuum-assisted closure: state of basic research and physiologic foundation. *Plast Reconstr Surg*. 2006;117(7 Suppl):121S-6S.
31. Malmsjö M, Ingemansson R, Martin R, Huddleston E. Negative-pressure wound therapy using gauze or open-cell polyurethane foam: similar early effects on pressure transduction and tissue contraction in an experimental porcine wound model. *Wound repair and regeneration : official publication of the Wound Healing Society [and] the European Tissue Repair Society*. 2009;17(2):200-5.
32. Borgquist O, Gustafsson L, Ingemansson R, Malmsjö M. Micro- and macromechanical effects on the wound bed of negative pressure wound therapy using gauze and foam. *Ann Plast Surg*. 2010;64(6):789-93.
33. Saxena V, Hwang CW, Huang S, Eichbaum Q, Ingber D, Orgill DP. Vacuum-assisted closure: microdeformations of wounds and cell proliferation. *Plast Reconstr Surg*. 2004;114(5):1086-96.
34. Banwell PE. Topical negative pressure therapy in wound care. *Journal of wound care*. 1999;8(2):79-84.

35. Kairinos N, Voogd AM, Botha PH, Kotze T, Kahn D, Hudson DA, et al. Negative-pressure wound therapy II: negative-pressure wound therapy and increased perfusion. Just an illusion? *Plast Reconstr Surg.* 2009;123(2):601-12.
36. Wackenfors A, Gustafsson R, Sjogren J, Algotsson L, Ingemansson R, Malmsjo M. Blood flow responses in the peristernal thoracic wall during vacuum-assisted closure therapy. *Ann Thorac Surg.* 2005;79(5):1724-30.
37. Wackenfors A, Sjogren J, Gustafsson R, Algotsson L, Ingemansson R, Malmsjo M. Effects of vacuum-assisted closure therapy on inguinal wound edge microvascular blood flow. *Wound repair and regeneration : official publication of the Wound Healing Society [and] the European Tissue Repair Society.* 2004;12(6):600-6.
38. Chen SZ, Li J, Li XY, Xu LS. Effects of vacuum-assisted closure on wound microcirculation: an experimental study. *Asian J Surg.* 2005;28(3):211-7.
39. Greene AK, Puder M, Roy R, Arsenault D, Kwei S, Moses MA, et al. Microdeformational wound therapy: effects on angiogenesis and matrix metalloproteinases in chronic wounds of 3 debilitated patients. *Ann Plast Surg.* 2006;56(4):418-22.
40. Lu X, Chen S, Li X, al. e. The experimental study of the effects of vacuum-assisted closure on edema and vessel permeability of the wound. *Chinese Journal of Clinical Rehabilitation.* 2003;7:1244-5.
41. Miller C. The History of Negative Pressure Wound Therapy (NPWT): From "Lip Service" to the Modern Vacuum System. *Journal of the American College of Clinical Wound Specialists.* 2012;4(3):61-2.
42. Raffl AB. The use of negative pressure under skin flaps after radical mastectomy. *Ann Surg.* 1952;136(6):1048.
43. Chariker M, Jeter K, Tintle T. Effective management of incisional and cutaneous fistulae with closed suction wound drainage. *Contemp Surg.* 1989;34:59-63.
44. Fleischmann W, Strecker W, Bombelli M, Kinzl L. [Vacuum sealing as treatment of soft tissue damage in open fractures]. *Unfallchirurg.* 1993;96(9):488-92.
45. Shweiki E, Gallagher KE. Negative pressure wound therapy in acute, contaminated wounds: documenting its safety and efficacy to support current global practice. *Int Wound J.* 2012;10(1):13-43.
46. Moues CM, van den Bemd GJ, Meerding WJ, Hovius SE. An economic evaluation of the use of TNP on full-thickness wounds. *Journal of wound care.* 2005;14(5):224-7.
47. Braakenburg A, Obdeijn MC, Feitz R, van Rooij IA, van Griethuysen AJ, Klinkenbijn JH. The clinical efficacy and cost effectiveness of the vacuum-assisted

- closure technique in the management of acute and chronic wounds: a randomized controlled trial. *Plast Reconstr Surg*. 2006;118(2):390-7.
48. Schwien T, Gilbert J, Lang C. Pressure ulcer prevalence and the role of negative pressure wound therapy in home health quality outcomes. *Ostomy Wound Manage*. 2005;51(9):47-60.
 49. Llanos S, Danilla S, Barraza C, Armijo E, Pineros JL, Quintas M, et al. Effectiveness of negative pressure closure in the integration of split thickness skin grafts: a randomized, double-masked, controlled trial. *Ann Surg*. 2006;244(5):700-5.
 50. Vuerstaek JD, Vainas T, Wuite J, Nelemans P, Neumann MH, Veraart JC. State-of-the-art treatment of chronic leg ulcers: A randomized controlled trial comparing vacuum-assisted closure (V.A.C.) with modern wound dressings. *Journal of Vascular Surgery*. 2006;44(5):1029-37.
 51. Armstrong DG, Lavery LA. Negative pressure wound therapy after partial diabetic foot amputation: a multicentre, randomised controlled trial. *Lancet*. 2005;366(9498):1704-10.
 52. Zhang J, Hu ZC, Chen D, Guo D, Zhu JY, Tang B. Effectiveness and safety of negative-pressure wound therapy for diabetic foot ulcers: a meta-analysis. *Plast Reconstr Surg*. 2014;134(1):141-51.
 53. Ross RE, Aflaki P, Gendics C, Lantis Ii JC. Complex lower extremity wounds treated with skin grafts and NPWT: a retrospective review. *Journal of wound care*. 2011;20(10):490, 2-5.
 54. Scherer LA, Shiver S, Chang M, Meredith JW, Owings JT. The vacuum assisted closure device: a method of securing skin grafts and improving graft survival. *Archives of surgery (Chicago, Ill : 1960)*. 2002;137(8):930-3.
 55. Joseph E, Hamori C, Bergman S, Roaf E, Swann N. A new prospective randomized trial of Vacuum assisted closure versus standard therapy of chronic nonhealing wounds. *Wounds* 2000;12:60-7.
 56. Kamolz LP, Andel H, Haslik W, Winter W, Meissl G, Frey M. Use of subatmospheric pressure therapy to prevent burn wound progression in human: first experiences. *Burns*. 2004;30(3):253-8.
 57. Wild T, Stortecy S, Stremitzer S, Lechner P, Humpel G, Glaser K, et al. [Abdominal dressing -- a new standard in therapy of the open abdomen following secondary peritonitis?]. *Zentralbl Chir*. 2006;131 Suppl 1:S111-4.
 58. Sjogren J, Gustafsson R, Nilsson J, Malmsjo M, Ingemansson R. Clinical outcome after poststernotomy mediastinitis: vacuum-assisted closure versus conventional treatment. *Ann Thorac Surg*. 2005;79(6):2049-55.

59. Bollero D, Carnino R, Risso D, Gangemi EN, Stella M. Acute complex traumas of the lower limbs: a modern reconstructive approach with negative pressure therapy. *Wound repair and regeneration : official publication of the Wound Healing Society [and] the European Tissue Repair Society.* 2007;15(4):589-94.
60. Ozturk E, Ozguc H, Yilmazlar T. The use of vacuum assisted closure therapy in the management of Fournier's gangrene. *Am J Surg.* 2009;197(5):660-5.
61. Eginton MT, Brown KR, Seabrook GR, Towne JB, Cambria RA. A prospective randomized evaluation of negative-pressure wound dressings for diabetic foot wounds. *Ann Vasc Surg.* 2003;17(6):645-9.
62. Joseph E, Hamori CA, Bergman S, Roaf E, Swann NF, Anastasi GW. A prospective randomized trial of vacuum-assisted closure versus standard therapy of chronic nonhealing wounds. *Wounds.* 2000;12(3):60-7.
63. Morykwas MJ, Faler BJ, Pearce DJ, Argenta LC. Effects of varying levels of subatmospheric pressure on the rate of granulation tissue formation in experimental wounds in swine. *Ann Plast Surg.* 2001;47(5):547-51.
64. Moues CM, van den Bemd GJ, Heule F, Hovius SE. Comparing conventional gauze therapy to vacuum-assisted closure wound therapy: a prospective randomised trial. *Journal of plastic, reconstructive & aesthetic surgery : JPRAS.* 2007;60(6):672-81.
65. Stannard JP, Robinson JT, Anderson ER, McGwin G, Jr., Volgas DA, Alonso JE. Negative pressure wound therapy to treat hematomas and surgical incisions following high-energy trauma. *J Trauma.* 2006;60(6):1301-6.
66. Ichioka S, Shibata M, Kosaki K, Sato Y, Harii K, Kamiya A. Effects of shear stress on wound-healing angiogenesis in the rabbit ear chamber. *J Surg Res.* 1997;72(1):29-35.
67. Timmers MS, Le Cessie S, Banwell P, Jukema GN. The effects of varying degrees of pressure delivered by negative-pressure wound therapy on skin perfusion. *Ann Plast Surg.* 2005;55(6):665-71.
68. Huang S, Chen CS, Ingber DE. Control of cyclin D1, p27(Kip1), and cell cycle progression in human capillary endothelial cells by cell shape and cytoskeletal tension. *Mol Biol Cell.* 1998;9(11):3179-93.
69. Huang S, Ingber DE. Shape-dependent control of cell growth, differentiation, and apoptosis: switching between attractors in cell regulatory networks. *Exp Cell Res.* 2000;261(1):91-103.
70. Chen CS, Mrksich M, Huang S, Whitesides GM, Ingber DE. Geometric control of cell life and death. *Science.* 1997;276(5317):1425-8.

71. Chen CS, Mrksich M, Huang S, Whitesides GM, Ingber DE. Micropatterned surfaces for control of cell shape, position, and function. *Biotechnol Prog.* 1998;14(3):356-63.
72. Orgill DP, Manders EK, Sumpio BE, Lee RC, Attinger CE, Gurtner GC, et al. The mechanisms of action of vacuum assisted closure: more to learn. *Surgery.* 2009;146(1):40-51.
73. Quinn TP, Schlueter M, Soifer SJ, Gutierrez JA. Cyclic mechanical stretch induces VEGF and FGF-2 expression in pulmonary vascular smooth muscle cells. *Am J Physiol Lung Cell Mol Physiol.* 2002;282(5):L897-903.
74. Rivilis I, Milkiewicz M, Boyd P, Goldstein J, Brown MD, Egginton S, et al. Differential involvement of MMP-2 and VEGF during muscle stretch- versus shear stress-induced angiogenesis. *Am J Physiol Heart Circ Physiol.* 2002;283(4):H1430-8.
75. Urschel JD, Scott PG, Williams HT. The effect of mechanical stress on soft and hard tissue repair; a review. *Br J Plast Surg.* 1988;41(2):182-6.
76. Bassetto F, Lancerotto L, Salmaso R, Pandis L, Pajardi G, Schiavon M, et al. Histological evolution of chronic wounds under negative pressure therapy. *Journal of plastic, reconstructive & aesthetic surgery : JPRAS.* 2011;65(1):91-9.
77. Wilkes R, Zhao Y, Kieswetter K, Haridas B. Effects of dressing type on 3D tissue microdeformations during negative pressure wound therapy: a computational study. *J Biomech Eng.* 2009;131(3):031012.
78. McNulty A, Spranger I, Courage J, Green J, Wilkes R, Rycerz A. The consistent delivery of negative pressure to wounds using reticulated open cell foam and regulated pressure feedback. *Wounds.* 2010;22(5):114-20.
79. Wilkes R, Zhao Y, Cunningham K, Kieswetter K, Haridas B. 3D strain measurement in soft tissue: demonstration of a novel inverse finite element model algorithm on MicroCT images of a tissue phantom exposed to negative pressure wound therapy. *J Mech Behav Biomed Mater.* 2009;2(3):272-87.
80. Li J, Hampton T, Morgan JP, Simons M. Stretch-induced VEGF expression in the heart. *J Clin Invest.* 1997;100(1):18-24.
81. Seko Y, Takahashi N, Shibuya M, Yazaki Y. Pulsatile stretch stimulates vascular endothelial growth factor (VEGF) secretion by cultured rat cardiac myocytes. *Biochem Biophys Res Commun.* 1999;254(2):462-5.
82. Chang H, Wang BW, Kuan P, Shyu KG. Cyclical mechanical stretch enhances angiopoietin-2 and Tie2 receptor expression in cultured human umbilical vein endothelial cells. *Clin Sci (Lond).* 2003;104(4):421-8.

83. Cloutier M, Maltais F, Piedboeuf B. Increased distension stimulates distal capillary growth as well as expression of specific angiogenesis genes in fetal mouse lungs. *Exp Lung Res.* 2008;34(3):101-13.
84. Labler L, Rancan M, Mica L, Harter L, Mihic-Probst D, Keel M. Vacuum-assisted closure therapy increases local interleukin-8 and vascular endothelial growth factor levels in traumatic wounds. *J Trauma.* 2009;66(3):749-57.
85. Shiu YT, Weiss JA, Hoying JB, Iwamoto MN, Joung IS, Quam CT. The role of mechanical stresses in angiogenesis. *Crit Rev Biomed Eng.* 2005;33(5):431-510.
86. Ingber DE, Prusty D, Sun Z, Betensky H, Wang N. Cell shape, cytoskeletal mechanics, and cell cycle control in angiogenesis. *J Biomech.* 1995;28(12):1471-84.
87. Von Offenberg Sweeney N, Cummins PM, Cotter EJ, Fitzpatrick PA, Birney YA, Redmond EM, et al. Cyclic strain-mediated regulation of vascular endothelial cell migration and tube formation. *Biochem Biophys Res Commun.* 2005;329(2):573-82.
88. Folkman J, Moscona A. Role of cell shape in growth control. *Nature.* 1978;273(5661):345-9.
89. Younan G, Ogawa R, Ramirez M, Helm D, Dastouri P, Orgill DP. Analysis of nerve and neuropeptide patterns in vacuum-assisted closure-treated diabetic murine wounds. *Plast Reconstr Surg.* 2010;126(1):87-96.
90. Malmsjo M, Ingemansson R, Lindstedt S, Gustafsson L. Comparison of bacteria and fungus-binding mesh, foam and gauze as fillers in negative pressure wound therapy - pressure transduction, wound edge contraction, microvascular blood flow and fluid retention. *Int Wound J.* 2012;10(5):597-605.
91. Okan D, Woo K, Ayello EA, Sibbald G. The role of moisture balance in wound healing. *Adv Skin Wound Care.* 2007;20(1):39-53.
92. Bishop SM, Walker M, Rogers AA, Chen WY. Importance of moisture balance at the wound-dressing interface. *Journal of wound care.* 2003;12(4):125-8.
93. Kerstein MD. Moist wound healing: the clinical perspective. *Ostomy Wound Manage.* 1995;41(7A Suppl):37S-44S.
94. Eisenhardt SU, Schmidt Y, Thiele JR, Iblher N, Penna V, Torio-Padron N, et al. Negative pressure wound therapy reduces the ischaemia/reperfusion-associated inflammatory response in free muscle flaps. *Journal of plastic, reconstructive & aesthetic surgery : JPRAS.* 2012;65(5):640-9.
95. Ichioka S, Watanabe H, Sekiya N, Shibata M, Nakatsuka T. A technique to visualize wound bed microcirculation and the acute effect of negative pressure. *Wound repair and regeneration : official publication of the Wound Healing Society [and] the European Tissue Repair Society.* 2008;16(3):460-5.

96. Genecov DG, Schneider AM, Morykwas MJ, Parker D, White WL, Argenta LC. A controlled subatmospheric pressure dressing increases the rate of skin graft donor site reepithelialization. *Ann Plast Surg.* 1998;40(3):219-25.
97. Khashram M, Huggan P, Ikram R, Chambers S, Roake JA, Lewis DR. Effect of TNP on the microbiology of venous leg ulcers: a pilot study. *Journal of wound care.* 2009;18(4):164-7.
98. Weed T, Ratliff C, Drake DB. Quantifying bacterial bioburden during negative pressure wound therapy: does the wound VAC enhance bacterial clearance? *Ann Plast Surg.* 2004;52(3):276-9.
99. Moues CM, Vos MC, van den Bemd GJ, Stijnen T, Hovius SE. Bacterial load in relation to vacuum-assisted closure wound therapy: a prospective randomized trial. *Wound repair and regeneration : official publication of the Wound Healing Society [and] the European Tissue Repair Society.* 2004;12(1):11-7.
100. Abu-Omar Y, Naik MJ, Catarino PA, Ratnatunga C. Right ventricular rupture during use of high-pressure suction drainage in the management of poststernotomy mediastinitis. *Ann Thorac Surg.* 2003;76(3):974.
101. Sartipy U, Lockowandt U, Gabel J, Jideus L, Dellgren G. Cardiac rupture during vacuum-assisted closure therapy. *Ann Thorac Surg.* 2006;82(3):1110-1.
102. Bapat V, El-Muttardi N, Young C, Venn G, Roxburgh J. Experience with Vacuum-assisted closure of sternal wound infections following cardiac surgery and evaluation of chronic complications associated with its use. *J Card Surg.* 2008;23(3):227-33.
103. Ennker IC, Malkoc A, Pietrowski D, Vogt PM, Ennker J, Albert A. The concept of negative pressure wound therapy (NPWT) after poststernotomy mediastinitis-- a single center experience with 54 patients. *Journal of cardiothoracic surgery.* 2009;4:5.
104. Khoyneshad A, Abbas G, Palazzo RS, Graver LM. Spontaneous right ventricular disruption following treatment of sternal infection. *J Card Surg.* 2004;19(1):74-8.
105. Abu-Omar Y, Naik MJ, Catarino PA, Ratnatunga C. Right ventricular rupture during use of high-pressure suction drainage in the management of poststernotomy mediastinitis. *Ann Thorac Surg.* 2003;76(3):974.
106. Yellin A, Refaely Y, Paley M, Simansky D. Major bleeding complicating deep sternal infection after cardiac surgery. *The Journal of thoracic and cardiovascular surgery.* 2003;125(3):554-8.
107. Petzina R, Malmso M, Stamm C, Hetzer R. Major complications during negative pressure wound therapy in poststernotomy mediastinitis after cardiac surgery. *The Journal of thoracic and cardiovascular surgery.* 2010;140(5):1133-6.

108. Caianiello G, Petraio A, Ursomando F, Pepino P, Cotrufo M, De Feo M, et al. Aortic erosion during negative pressure therapy in a pediatric heart transplant recipient. *Ann Thorac Surg*. 2011;92(5):1879-80.
109. Sjogren J, Gustafsson R, Nilsson J, Lindstedt S, Nozohoor S, Ingemansson R. Negative-pressure wound therapy following cardiac surgery: bleeding complications and 30-day mortality in 176 patients with deep sternal wound infection. *Interactive cardiovascular and thoracic surgery*. 2011;12(2):117-20.
110. Grauhan O, Navarsadyan A, Hussmann J, Hetzer R. Infectious erosion of aorta ascendens during vacuum-assisted therapy of mediastinitis. *Interactive cardiovascular and thoracic surgery*. 2010;11(4):493-4.
111. Carnero-Alcazar M, Silva Guisasola JA, Rodriguez Hernandez JE. Right ventricle bleeding secondary to vacuum assisted therapy? *Interactive cardiovascular and thoracic surgery*. 2010;10(3):472.
112. Sumpio BE, Allie DE, Horvath KA, Marston WA, Meites HL, Mills JL, et al. Role of negative pressure wound therapy in treating peripheral vascular graft infections. *Vascular*. 2008;16(4):194-200.
113. Cheng HT, Hsu YC, Wu CI. Efficacy and safety of negative pressure wound therapy for Szilagyi grade III peripheral vascular graft infection. *Interactive cardiovascular and thoracic surgery*. 2014;(Epub).
114. Ren H, Li Y. Severe complications after negative pressure wound therapy in burned wounds: two case reports. *Therapeutics and clinical risk management*. 2014;10:513-6.
115. FDA, Communication S. UPDATE on Serious Complications Associated with Negative Pressure Wound Therapy Systems. 2011;February 24.
116. FDA PPHN. Serious Complications Associated with Negative Pressure Wound Therapy Systems. 2009 November 13.
117. Petzina R, Hoffmann J, Navasardyan A, Malmsjo M, Stamm C, Unbehaun A, et al. Negative pressure wound therapy for post-sternotomy mediastinitis reduces mortality rate and sternal re-infection rate compared to conventional treatment. *European journal of cardio-thoracic surgery : official journal of the European Association for Cardio-thoracic Surgery*. 2010;38(1):110-3.
118. Gustafsson RI, Sjogren J, Ingemansson R. Deep sternal wound infection: a sternal-sparing technique with vacuum-assisted closure therapy. *Ann Thorac Surg*. 2003;76(6):2048-53.
119. Hersh RE, Jack JM, Dahman MI, Morgan RF, Drake DB. The vacuum-assisted closure device as a bridge to sternal wound closure. *Ann Plast Surg*. 2001;46(3):250-4.

120. Malmsjo M, Ingemansson R, Sjogren J. Mechanisms governing the effects of vacuum-assisted closure in cardiac surgery. *Plast Reconstr Surg.* 2007;120(5):1266-75.
121. Sjogren J, Malmsjo M, Gustafsson R, Ingemansson R. Poststernotomy mediastinitis: a review of conventional surgical treatments, vacuum-assisted closure therapy and presentation of the Lund University Hospital mediastinitis algorithm. *European journal of cardio-thoracic surgery : official journal of the European Association for Cardio-thoracic Surgery.* 2006;30(6):898-905.
122. Malmsjo M, Petzina R, Ugander M, Engblom H, Torbrand C, Mokhtari A, et al. Preventing heart injury during negative pressure wound therapy in cardiac surgery: assessment using real-time magnetic resonance imaging. *The Journal of thoracic and cardiovascular surgery.* 2009;138(3):712-7.
123. Lindstedt S, Ingemansson R, Malmsjo M. A rigid barrier between the heart and sternum protects the heart and lungs against rupture during negative pressure wound therapy. *Journal of cardiothoracic surgery.* 2011;6:90.
124. Ingemansson R, Malmsjo M, Lindstedt S. A protective device for negative-pressure therapy in patients with mediastinitis. *Ann Thorac Surg.* 2013;95(1):362-4.
125. Ingemansson R, Malmsjo M, Lindstedt S. The Duration of Negative Pressure Wound Therapy Can Be Reduced Using the HeartShield Device in Patients With Deep Sternal Wound Infection. *Eplasty.* 2014;14:e16.
126. Ingemansson R, Malmsjo M, Lindstedt S. The HeartShield device reduces the risk for right ventricular damage in patients with deep sternal wound infection. *Innovations (Philadelphia, Pa).* 2014;9(2):137-41.
127. Lindstedt S, Malmsjo M, Ingemansson R. C-reactive protein and leucocyte counts drop faster using the HeartShield(R) device in patients with DSWI. *Int Wound J.* 2013. (E-pub).
128. Russell WMS, Burch RL, Hume CW. *The principles of humane experimental technique* 1959.
129. Sullivan TP, Eaglstein WH, Davis SC, Mertz P. The pig as a model for human wound healing. *Wound repair and regeneration : official publication of the Wound Healing Society [and] the European Tissue Repair Society.* 2001;9(2):66-76.
130. Zografos GC, Martis K, Morris DL. Laser Doppler flowmetry in evaluation of cutaneous wound blood flow using various suturing techniques. *Ann Surg.* 1992;215(3):266-8.
131. Jaskille AD, Ramella-Roman JC, Shupp JW, Jordan MH, Jeng JC. Critical review of burn depth assessment techniques: part II. Review of laser doppler technology.

- Journal of burn care & research : official publication of the American Burn Association. 2010;31(1):151-7.
132. Leahy MJ, Mul FFMD, Nilsson GE, Maniewski R. Principles and practice of the laser-Doppler perfusion technique. *Technol Health Care*. 1999;7(2-3):143-62.
 133. Kairinos N, McKune A, Solomons M, Hudson DA, Kahn D. The flaws of laser Doppler in negative-pressure wound therapy research. *Wound repair and regeneration : official publication of the Wound Healing Society [and] the European Tissue Repair Society*. 2014;22(3):424-9.
 134. Allen J, Howell K. Microvascular imaging: techniques and opportunities for clinical physiological measurements. *Physiological measurement*. 2014;35(7):R91.
 135. Raamat R, Jagomagi K, Kingisepp P. Simultaneous recording of fingertip skin blood flow changes by multiprobe laser Doppler flowmetry and frequency-corrected thermal clearance. *Microvascular research*. 2002;64(2):214-9.
 136. Miller C, Armonda R. Monitoring of Cerebral Blood Flow and Ischemia in the Critically Ill. *Neurocritical care*. 2014.
 137. Smith APS WK, Frykberg RG, DeLeon J. Negative pressure wound therapy. In: Krasner DL, ed. *Chronic Wound Care: The Essentials: HMP Communications*; 2014.
 138. Borgquist O, Ingemansson R, Malmsjo M. Wound edge microvascular blood flow during negative-pressure wound therapy: examining the effects of pressures from -10 to -175 mmHg. *Plast Reconstr Surg*. 2009;125(2):502-9.
 139. Borgquist O, Ingemansson R, Malmsjo M. The influence of low and high pressure levels during negative-pressure wound therapy on wound contraction and fluid evacuation. *Plast Reconstr Surg*. 2011;127(2):551-9.
 140. Borgquist O, Gustafsson L, Ingemansson R, Malmsjo M. Tissue Ingrowth Into Foam but Not Into Gauze During Negative Pressure Wound Therapy. *Wounds*. 2009;21(11):302-9.
 141. Murphey GC, Macias BR, Hargens AR. Depth of penetration of negative pressure wound therapy into underlying tissues. *Wound repair and regeneration : official publication of the Wound Healing Society [and] the European Tissue Repair Society*. 2009;17(1):113-7.
 142. Kairinos N, Solomons M, Hudson DA. Negative-pressure wound therapy I: the paradox of negative-pressure wound therapy. *Plast Reconstr Surg*. 2009;123(2):589-98.
 143. Kairinos N, Solomons M, Hudson DA. The paradox of negative pressure wound therapy - in vitro studies. *Journal of plastic, reconstructive & aesthetic surgery : JPRAS*. 2008;63(1):174-9.

144. Borgquist O, Ingemansson R, Malmsjo M. The effect of intermittent and variable negative pressure wound therapy on wound edge microvascular blood flow. *Ostomy Wound Manage.* 2010;56(3):60-7.
145. Wackenfors A, Sjogren J, Algotsson L, Gustafsson R, Ingemansson R, Malmsjo M. The effect of vacuum-assisted closure therapy on the pig femoral artery vasomotor responses. *Wound repair and regeneration : official publication of the Wound Healing Society [and] the European Tissue Repair Society.* 2004;12(2):244-51.
146. Petzina R, Gustafsson L, Mokhtari A, Ingemansson R, Malmsjo M. Effect of vacuum-assisted closure on blood flow in the peristernal thoracic wall after internal mammary artery harvesting. *European journal of cardio-thoracic surgery : official journal of the European Association for Cardio-thoracic Surgery.* 2006;30(1):85-9.
147. Venturi ML, Attinger CE, Mesbahi AN, Hess CL, Graw KS. Mechanisms and clinical applications of the vacuum-assisted closure (VAC) Device: a review. *Am J Clin Dermatol.* 2005;6(3):185-94.
148. Attinger CE, Janis JE, Steinberg J, Schwartz J, Al-Attar A, Couch K. Clinical approach to wounds: debridement and wound bed preparation including the use of dressings and wound-healing adjuvants. *Plast Reconstr Surg.* 2006;117(7 Suppl):72S-109S.
149. Jonsson K, Jensen JA, Goodson WHI, Scheuenstuhl H, West J, Hopf HW, et al. Tissue oxygenation, anemia, and perfusion in relation to wound healing in surgical patients. *Ann Surg.* 1991;214(5):605-13.
150. Petzina R, Ugander M, Gustafsson L, Engblom H, Hetzer R, Arheden H, et al. Topical negative pressure therapy of a sternotomy wound increases sternal fluid content but does not affect internal thoracic artery blood flow: assessment using magnetic resonance imaging. *The Journal of thoracic and cardiovascular surgery.* 2008;135(5):1007-13.
151. Sjögren J, Gustafsson R, Koul B, Ingemansson R. Selective mediastinal tamponade to control coagulopathic bleeding. *Ann Thorac Surg.* 2003;75(4):1311-3.
152. Austad ED, Thomas SB, Pasyk K. Tissue expansion: dividend or loan? *Plast Reconstr Surg.* 1986;78(1):63-7.
153. Olenius M, Dalsgaard CJ, Wickman M. Mitotic activity in expanded human skin. *Plast Reconstr Surg.* 1993;91(2):213-6.
154. Quyn AJ, Johnston C, Hall D, Chambers A, Arapova N, Ogston S, et al. The open abdomen and temporary abdominal closure systems--historical evolution and systematic review. *Colorectal disease : the official journal of the Association of Coloproctology of Great Britain and Ireland.* 2012;14(8):e429-38.

155. Bucalo B, Eaglstein WH, Falanga V. Inhibition of cell proliferation by chronic wound fluid. *Wound repair and regeneration : official publication of the Wound Healing Society [and] the European Tissue Repair Society.* 1993;1(3):181-6.
156. Grinnell F, Zhu M. Identification of neutrophil elastase as the proteinase in burn wound fluid responsible for degradation of fibronectin. *J Invest Dermatol.* 1994;103(2):155-61.
157. Wysocki AB, Staiano-Coico L, Grinnell F. Wound fluid from chronic leg ulcers contains elevated levels of metalloproteinases MMP-2 and MMP-9. *J Invest Dermatol.* 1993;101(1):64-8.
158. Chen SM, Ward SI, Olutoye OO, Diegelmann RF, Kelman Cohen I. Ability of chronic wound fluids to degrade peptide growth factors is associated with increased levels of elastase activity and diminished levels of proteinase inhibitors. *Wound repair and regeneration : official publication of the Wound Healing Society [and] the European Tissue Repair Society.* 1997;5(1):23-32.
159. Ladwig GP, Robson MC, Liu R, Kuhn MA, Muir DF, Schultz GS. Ratios of activated matrix metalloproteinase-9 to tissue inhibitor of matrix metalloproteinase-1 in wound fluids are inversely correlated with healing of pressure ulcers. *Wound repair and regeneration : official publication of the Wound Healing Society [and] the European Tissue Repair Society.* 2002;10(1):26-37.
160. Kairinos N, Holmes WJ, Solomons M, Hudson DA, Kahn D. Does a zone of increased perfusion exist around negative-pressure dressings? *Plast Reconstr Surg.* 2013;132(4):978-87.
161. Hu S, Wang LV. Photoacoustic imaging and characterization of the microvasculature. *Journal of biomedical optics.* 2010;15(1):011101.
162. Park J, Cummins TM, Harrison M, Lee J, Zhou Q, Lien CL, et al. High frequency photoacoustic imaging for in vivo visualizing blood flow of zebrafish heart. *Optics express.* 2013;21(12):14636-42.
163. Zackrisson S, van de Ven SM, Gambhir SS. Light in and sound out: emerging translational strategies for photoacoustic imaging. *Cancer research.* 2014;74(4):979-1004.

Paper I

The influence of different sizes and types of wound fillers on wound contraction and tissue pressure during negative pressure wound therapy

Erik Anesäter, Ola Borgquist, Erik Hedström, Julia Waga, Richard Ingemansson, Malin Malmjö

Key Points

- the aim of this study was to examine the effect of the type (foam or gauze) and size (small or large) of wound filler for NPWT on wound contraction and tissue pressure

Anesäter E, Borgquist O, Hedström E, Waga J, Ingemansson R, Malmjö M. The influence of different sizes and types of wound fillers on wound contraction and tissue pressure during negative pressure wound therapy. *Int Wound J* 2011; 8:336–342

ABSTRACT

Negative pressure wound therapy (NPWT) contracts the wound and alters the pressure in the tissue of the wound edge, which accelerates wound healing. The aim of this study was to examine the effect of the type (foam or gauze) and size (small or large) of wound filler for NPWT on wound contraction and tissue pressure. Negative pressures between -20 and -160 mmHg were applied to a peripheral porcine wound ($n = 8$). The pressure in the wound edge tissue was measured at distances of 0.1, 0.5, 1.0 and 2.0 cm from the wound edge and the wound diameter was determined. At 0.1 cm from the wound edge, the tissue pressure decreased when NPWT was applied, whereas at 0.5 cm it increased. Tissue pressure was not affected at 1.0 or 2.0 cm from the wound edge. The tissue pressure, at 0.5 cm from the wound edge, was greater when using a small foam than when using a large foam. Wound contraction was greater when using a small foam than when using a large foam during NPWT. Gauze resulted in an intermediate wound contraction that was not affected by the size of the gauze filler. The use of a small foam to fill the wound causes considerable wound contraction and may thus be used when maximal mechanical stress and granulation tissue formation are desirable. Gauze or large amounts of foam result in less wound contraction which may be beneficial, for example when NPWT causes pain to the patient.

Key words: Experimental surgery • Negative pressure wound therapy • Tissue pressure • Wound contraction • Wound healing

Authors: E Anesäter, MD, Department of Ophthalmology, Lund University and Skåne University Hospital, Lund, Sweden; O Borgquist, MD, Departments of Ophthalmology and Anesthesiology & Intensive Care, Lund University and Skåne University Hospital, Lund, Sweden; E Hedström, MD, PhD, Department of Clinical Physiology, Lund University and Skåne University Hospital, Lund, Sweden; J Waga, Department of Ophthalmology, Lund University and Skåne University Hospital, Lund, Sweden; R Ingemansson, MD, PhD, Department of Cardiothoracic Surgery, Lund University and Skåne University Hospital, Lund, Sweden; M Malmjö, MD, PhD, Department of Ophthalmology, Lund University and Skåne University Hospital, Lund, Sweden

Address for correspondence: Dr M Malmjö, MD, PhD, BMC A13, SE-221 84 Lund, Sweden

E-mail: malin.malmjo@med.lu.se

INTRODUCTION

Negative pressure wound therapy (NPWT) has remarkable effects on the healing of chronic and difficult wounds (1,2). The technique entails the application of negative pressure to a sealed, airtight wound. One of the fundamental effects of negative pressure on the wound bed is believed to be the induction of mechanical deformation of the tissue (3,4) as the wound contracts when negative pressure is applied (3). During this contraction, the wound edge tissue is drawn towards the vacuum, resulting in tissue compression and increased pressure on the wound edge (5,6). In a previous study, using processed meat, it was shown that the tissue pressure increased 1 cm from the vacuum source, while at deeper locations, it was not affected (5). These findings were later verified in human subjects (7).

Compression of superficial tissue and an increase in tissue pressure have been suggested to decrease blood perfusion in the wound edge (8–10). Decreased blood flow may be one of the beneficial effects of NPWT, as factors released in response to hypoperfusion are strong stimulators of angiogenesis and granulation tissue formation. Another beneficial effect of the pressure on the wound wall may be to tamponade superficial bleeding during surgical procedures (11). However, in poorly vascularised tissue, there may be risk of ischaemia (12). In these cases, the level of negative pressure may need to be reduced to alleviate the pressure in the tissue, thereby reducing the degree of hypoperfusion (13). No study has yet been performed to examine whether tissue pressure can be affected by changing the type or size of wound filler used for NPWT.

Previous studies on tissue pressure during NPWT have been performed *in vitro*, using processed meat (5), and *in vivo* on human subjects (7), but only at limited positions around the wound edge. The aims of this study were to examine wound contraction and tissue pressure upon NPWT using different levels of negative pressure (ranging from –20 to –160 mmHg). Different types (foam or gauze) and sizes (small or large) of wound fillers were applied *in vivo* to a porcine peripheral wound and the pressure in the wound edge tissue was measured at distances of 0.1, 0.5, 1.0 and 2.0 cm from the wound edge and the wound diameter was determined.

MATERIALS AND METHODS

Animals

Eight healthy domestic pigs of both sexes, with a mean body weight of 70 kg, were fasted overnight with free access to water. The experimental protocol for this study was approved by the Ethics Committee for Animal Research at Lund University, Sweden. All animals received humane care in compliance with the European Convention on Animal Care.

Anaesthesia and surgical procedure

An intramuscular injection of xylazine (Rompun® vet. 20 mg/ml; Bayer AG, Leverkusen, Germany; 2 mg/kg) mixed with ketamine (Ketaminol® vet. 100 mg/ml; Farmaceutici Gellini S.p.A, Aprilia, Italy; 20 mg/kg) was used for premedication. Anaesthesia was then induced with intravenous sodium thiopental (Pentothal®; Abbot Scandinavia, Stockholm, Sweden; 8 mg/kg) and maintained with a continuous infusion of fentanyl (3.5 µg/kg/hour) in Ringer's acetate in combination with intermittent bolus doses of sodium thiopental. The animals were orally intubated with cuffed endotracheal tubes. Mechanical ventilation was established with a Siemens-Elema ventilator (Siemens-Elema AB, Solna, Sweden) in the volume-controlled mode (65% nitrous oxide and 35% oxygen). Ventilatory settings were identical for all animals (respiratory rate, 15 breaths/minute; minute ventilation, 12 l/minute). A positive end-expiratory pressure of 5 cm H₂O was applied. A Foley catheter was inserted into the urinary bladder through a suprapubic cystostomy. After the experiments were finished, a lethal dose of potassium chloride was administered intravenously for euthanasia.

Wounds and treatment

Circular wounds, 6 cm in diameter, extending into the subcutaneous tissue, were created on the pig's back, 10 cm from the spine, towards the back leg. One wound was created on each pig for the performance of the experiments. Either AMD gauze (Kendall Healthcare, Mansfield, MA) or open pore structure polyurethane foam (VAC® black GranuFoam®, KCI, San Antonio, TX) was used as wound filler. The gauze was soaked in saline. The wound was sealed with transparent

Key Points

- previous studies on tissue pressure during NPWT have been performed *in vitro*, using processed meat, and *in vivo* on human subjects, but only at limited positions around the wound edge
- the aims of this study were to examine wound contraction and tissue pressure upon NPWT using different levels of negative pressure (ranging from –20 to –160 mmHg)
- eight healthy domestic pigs of both sexes, with a mean body weight of 70 kg, were fasted overnight with free access to water
- circular wounds, 6 cm in diameter, extending into the subcutaneous tissue, were created on the pig's back

adhesive drape. A drain was connected to the vacuum source. Negative pressures between -20 and -160 mmHg were applied at 20 mmHg increments.

The effects of two different sizes of wound fillers were investigated. The foam pieces were circular and cut to a diameter of 50 or 70 mm (referred to as the 'small' and 'large' foam fillers, respectively). Two gauze sponges (each 150×170 mm) together constituted the 'small' gauze filler, and three gauze sponges constituted the 'large' gauze filler.

Pressure measurements

The negative pressure on the wound bed, underneath the wound filler, was measured using a saline-filled pressure catheter. The tip of the catheter was sutured to the centre of the bottom of the wound (Figure 1). The pressure catheter was connected to a custom-built pressure gauge that relies on pressure transduction via a fluid-filled catheter. Owing to fluid accumulation at the end of the probe, this technique is not suitable for pressure measurements in the tissue as fluid may accumulate there. However, pressure measurements in the wound bed poses no problem as the fluid is evacuated continuously by the NPWT.

Intracranial tissue pressure microsensors (Codman/Johnson and Johnson Professional Inc., Raynham, Massachusetts, US) were used to measure the pressure in the tissue. These were inserted into the tissue, using an 18G Tuohy needle, at distances of 0.1 , 0.5 , 1.0 and 2.0 cm from the wound edge (Figure 1).

The Codman ICP monitoring system was used to measure tissue pressures as it can record high positive pressures. This system was not used for measuring wound bed pressure as it only records negative pressures down to -99 mmHg. The resulting pressure was recorded after having stabilised at a constant level, which typically occurred within 2 minutes after application of NPWT.

Measurement of wound contraction

Four marks were made on the edge of the wound. The vertical and horizontal diameters of the wound were measured before and after the application of negative pressure. The horizontal diameter was here measured in parallel with the pig's spine and the vertical diameter was measured 90° from this. The mean of the two diameters measured (the horizontal and the vertical) was calculated.

Calculations and statistics

Eight pigs were used for this study. In cases where adverse events and experimental conditions inhibited the continuation of the experiments, the number had to be reduced. Calculations and statistics were performed using GraphPad 5.0 software. The sequence of applying the different NPWT modalities was varied between the experiments using a Latin square design. Statistical analysis was performed using the Mann-Whitney test. Significance was defined as $P < 0.05$. The P -values in the interval 0.001 – 0.300 have been written out, while outside this interval the expressions ' $P < 0.001$ ' and ' $P > 0.30$ ' have




Figure 1. Left: the four Codman ICP express pressure monitors used to measure the tissue pressure around the wound edge and the custom-built pressure gauge used to measure the pressure in the wound bed. Right: the porcine wound filled with foam showing the tissue pressure sensors (left arrow) 0.1 , 0.5 , 1.0 and 2.0 cm from the wound edge, and the pressure sensor sutured to the wound bed (right arrow). The drain is seen in the centre of the wound filler.

been used. Results are presented as the mean \pm the standard error of the mean and median (range).

RESULTS

Wound contraction

The mean wound diameter was initially 6.1 ± 0.2 cm (median 5.9 cm, range 5.4–6.7 cm). NPWT was applied and the wound diameter was reduced with increasing levels of negative pressure. Wound contraction was greater when using a small piece of foam [the mean wound diameter was 5.8 ± 0.1 cm, (median 5.7 cm, range 5.1–6.5 cm) at -120 mmHg] compared with when using a large piece of foam [the mean wound diameter was 6.2 ± 0.2 cm, (median 6.1 cm, range 5.6–7.6 cm) at -120 mmHg, $P = 0.033$]. Gauze resulted in an intermediate wound contraction that was not affected by the size of the gauze filler [the mean wound diameter was 6.1 ± 0.2 cm (median 5.9 cm, range 5.4–7.5 cm) for the small gauze filler and 6.1 ± 0.1 cm (median 5.9 cm, range 5.6–7.2 cm) for the large gauze filler at -120 mmHg, $P > 0.30$]. See Figure 2 for detailed results.

Pressure on the wound bed

Pressure transduction to the wound bed is equally good between the foam sizes tested. For example, at an applied pressure

of -120 mmHg, the mean pressure recorded when using the small foam filler was -105 ± 2 mmHg (median -105 mmHg, range -110 to -99 mmHg) compared with -103 ± 2 mmHg (median -103 , range -108 to -98 mmHg) when using the large foam filler ($P > 0.30$). The results were similar for gauze, for example when using the small gauze filler, the mean pressure was -104 ± 2 mmHg (median -104 mmHg, range -110 to -97 mmHg) compared with -108 ± 2 mmHg (median -108 , range -112 to -101 mmHg) when using the large gauze filler ($P > 0.30$). See Figure 3 for detailed results.

Pressure in the wound edge tissue

The tissue pressure was measured at different distances from the wound edge. At 0.1 cm from the wound edge, the tissue pressure decreased during NPWT, regardless the type of wound filler [e.g. -26 ± 14 mmHg (median -17 , range -91 to -3 mmHg), at -120 mmHg, using the small foam filler]. At 0.5 cm from the wound edge, the tissue pressure increased during NPWT, regardless the type of wound filler [e.g. 9 ± 1 mmHg (median 9, range 7–13 mmHg), at -120 mmHg, using the small foam filler]. At 1.0 cm and 2.0 cm from the wound edge, the tissue pressure was not affected by NPWT, regardless the type of wound filler ($P > 0.30$). See Figure 4 for detailed results.

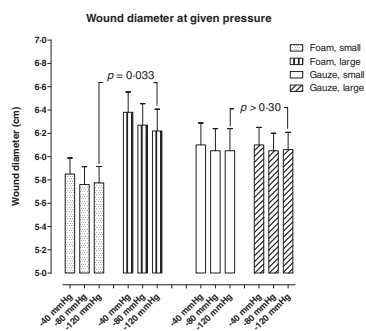


Figure 2. Wound diameter upon application of Negative pressure wound therapy using gauze and foam of different sizes (small or large). The diameter was measured in the horizontal and the vertical plane, as described in the Methods, and the mean values for each wound were calculated. Results are shown as mean \pm standard error of the mean (SEM) of six experiments.

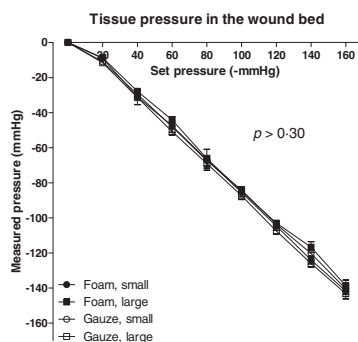


Figure 3. Wound bed pressures during Negative pressure wound therapy in wounds filled with foam or gauze of different sizes (small or large). Results are shown as mean \pm standard error of the mean (SEM) of six experiments. Note that both sizes of foam and gauze offer similar pressure transduction to the wound bed.

Key Points

- this study showed that a small foam, under negative pressure, resulted in a greater wound contraction than a large foam
- gauze resulted in an intermediate wound contraction that was not affected by the size of the gauze filler
- at a distance of 0.1 cm from the wound edge, the tissue pressure decreased gradually with increasing suction pressure
- this finding suggests that NPWT induces a hypobaric environment not only in the wound bed but also in the superficial wound edge tissue
- at 0.5 cm from the wound edge, the tissue pressure increased gradually with the applied negative pressure
- the reason for the increase in pressure 0.5 cm from the wound edge is not fully understood
- it is believed that the negative pressure contracts the wound resulting in wound edge tissue compression, which causes increased tissue pressure around the edge of the wound
- one possible explanation for this is that a small foam filler results in a smaller wound diameter than a large foam filler
- the increase in tissue pressure may result in decreased blood flow
- it is well known that reduced blood flow stimulates angiogenesis and granulation tissue formation, which facilitates the process of wound healing
- furthermore, compression of the wound edge tissue may be beneficial during surgical procedures as it has been shown to tamponade superficial bleeding and may reduce wound edge oedema
- the wound is more contracted during NPWT treatment at a high level of negative pressure or when using a small foam
- conversely, the wound is less contracted during NPWT treatment at a low level of negative pressure or when using gauze or a large foam filler

Tissue pressure at 0.5 cm from the wound edge

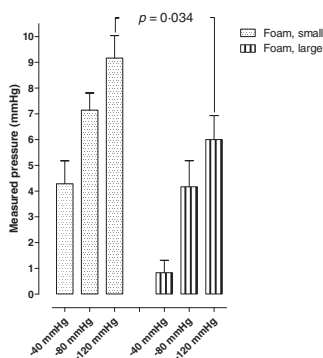


Figure 4. Tissue pressure measured 0.5 cm from the wound edge during Negative pressure wound therapy (NPWT) at -40 , -80 and -120 mmHg, respectively in wounds filled with foam of different sizes (small or large). Results are shown as means of eight experiments. Note that the tissue pressure is positive at this distance from the wound edge. This is presumably the result of the compressive forces generated by NPWT.

The decrease in tissue pressure 0.1 cm from the wound edge was not affected by the size of wound filler [e.g. -26 ± 14 mmHg (median -17 , range -91 to -3 mmHg), for small foam and -37 ± 16 mmHg (median -26 , range -99 to -13 mmHg), for large foam, at -120 mmHg, $P > 0.30$]. However, the tissue pressure 0.5 cm from the wound edge was higher for a small foam than for a large foam [e.g. 9 ± 1 mmHg (median 9, range 7–13 mmHg), for the small and 6 ± 1 for large foam (median 6, range 3–9 mmHg), at -120 mmHg, $P = 0.034$, Figure 4].

DISCUSSION

This study showed that a small foam, under negative pressure, resulted in a greater wound contraction than a large foam. Gauze resulted in an intermediate wound contraction that was not affected by the size of the gauze filler. The reason for the difference in properties between foam and gauze may be that the porous structure of foam allows greater volume reduction under pressure.

At a distance of 0.1 cm from the wound edge, the tissue pressure decreased gradually with increasing suction pressure. These observations are in line with results from a previous

study in mice (14). This finding suggests that NPWT induces a hypobaric environment not only in the wound bed but also in the superficial wound edge tissue. Subatmospheric tissue pressure and a pressure gradient over the wound edge may initiate a transport of interstitial fluid, which may facilitate the diffusion of oxygen and nutrients.

At 0.5 cm from the wound edge, the tissue pressure increased gradually with the applied negative pressure. Similar results have been reported in recent studies by Kairinos *et al.* (5,7), where there was increased pressure in processed meat 1.0 cm from the wound edge, while the pressure was not affected at deeper locations (5). The reason for the increase in pressure 0.5 cm from the wound edge is not fully understood. It is believed that the negative pressure contracts the wound resulting in wound edge tissue compression, which causes increased tissue pressure around the edge of the wound (5).

The tissue pressure (at 0.5 cm from the wound edge) was dependent on the size of the foam filler, being higher for the small foam filler and lower for the large foam filler. One possible explanation for this is that a small foam filler results in a smaller wound diameter than a large foam filler. The negative pressure thus causes greater compression of the tissue when using a small foam filler, than when using a large one. Conversely, the large foam filler offers greater resistance against the wound edge wall, which prevents the tissue from being compressed.

The increase in tissue pressure may result in decreased blood flow (12). We have previously showed that the blood flow 0.5 cm from the wound edge decreased during NPWT (9). It is well known that reduced blood flow stimulates angiogenesis and granulation tissue formation, which facilitates the process of wound healing (15,16). Furthermore, compression of the wound edge tissue may be beneficial during surgical procedures as it has been shown to tamponade superficial bleeding (11), and may reduce wound edge oedema. However, in poorly vascularised tissue, compression and decreased blood perfusion may cause ischaemia (12,13).

The wound is more contracted during NPWT treatment at a high level of negative pressure or when using a small foam. Conversely, the wound is less contracted during NPWT

treatment at a low level of negative pressure or when using gauze or a large foam filler. The biological effects in the wound edge may thus be adjusted by changing the conditions under which NPWT is applied. We know that mechanical wound contraction often causes pain to the patient (17). It is possible that this can be managed by reducing the level of negative pressure, or by using gauze or a large foam filler. In contrast, if the aim is to maximise granulation tissue formation, a high level of negative pressure (4,9,18) or a small foam filler may be used.

It is indeed interesting that wound contraction differs between different sizes and types of wound filler and it is most probable that this relates to healing during NPWT. In a previous study, it could be shown that wound contraction is greater when using foam than when using gauze in sternotomy wounds (19). Mechanical effects on the wound edge resulting from NPWT are believed to be one of the fundamental mechanisms by which NPWT promotes healing. Wound contraction creates deformational forces at the wound-foam interface (20), which is thought to initiate a series of inter-related biological effects including the promotion of wound edge microvascular blood flow, the removal of bacteria and the stimulation of granulation tissue formation (21). Different amounts of wound contraction, offered by different types of wound fillers, may be desirable for different types of wounds. The advantage of greater wound contraction, such as that achieved with foam, may be massive stimulation of granulation tissue and, thus, faster healing. Large wound contraction may also be preferable in wounds dependent on reverse tissue expansion for secondary wound closure, for example for upper and lower limb compartment syndrome. However, when NPWT is applied to a wound that cannot be closed (e.g. because of an enlarged heart), a lower degree of wound contraction, such as that obtained with gauze, may be preferable. Also, a lower degree of wound contraction may result in a lower risk of the underlying organs becoming wedged between the sternal edges: This may reduce the risk of damage to the heart and lungs. Furthermore, patient's pain may be reduced by minimising the mechanical effects on the wound edge.

The choice of conditions for NPWT may be of even greater importance when treating

poorly vascularised tissue, such as in diabetic patients with arteriosclerosis, or in patients with general arteriosclerosis. NPWT elicits hypoperfusion in the wound edge as a result of increased tissue pressure. We know that these effects can be governed by altering the level of negative pressure applied (13). The choice of filler material, or the size of the filler, may offer other means of governing wound edge perfusion, however, this needs to be studied in greater detail.

In conclusion, NPWT contracts the wound and alters the tissue pressure which may accelerate wound healing. NPWT creates a hypobaric environment in the superficial wound edge tissue (0.1 cm from the wound edge), which may cause the transport of interstitial fluid, facilitating the diffusion of oxygen and nutrients. Deeper in the wound edge (0.5 cm), tissue pressure increases that may be a result of wound contraction and wound edge tissue deformation. The use of a small foam to fill the wound causes considerable wound contraction and may thus be used when maximal mechanical stress and granulation tissue formation are desirable. Conversely, gauze or large amounts of foam result in less wound contraction which may be beneficial when NPWT causes pain to the patient.

REFERENCES

- 1 Morykwas MJ, Simpson J, Punger K, Argenta A, Kremers L, Argenta J. Vacuum-assisted closure: state of basic research and physiologic foundation. *Plast Reconstr Surg* 2006;117:121S-6S.
- 2 Banwell PE, Teot L. Topical negative pressure (TNP): the evolution of a novel wound therapy. *J Wound Care* 2003;12:22-8.
- 3 Malmjsjo M, Ingemansson R, Martin R, Huddleston E. Negative-pressure wound therapy using gauze or open-cell polyurethane foam: similar early effects on pressure transduction and tissue contraction in an experimental porcine wound model. *Wound Repair Regen* 2009;17:200-5.
- 4 Borgquist O, Ingemansson R, Malmjsjo M. The influence of low and high pressure levels during negative-pressure wound therapy on wound contraction and fluid evacuation. *Plast Reconstr Surg* 2011;127:551-9.
- 5 Kairinos N, Solomons M, Hudson DA. The paradox of negative pressure wound therapy - in vitro studies. *J Plast Reconstr Aesthet Surg* 2010;63: 174-9.
- 6 Willy C, Gerngross H. Scientific background of the vacuum closure - an abstract. *Zentralbl Chir* 2004;129 Suppl 1:56.

- 7 Kairinos N, Solomons M, Hudson DA. Negative-pressure wound therapy I: the paradox of negative-pressure wound therapy. *Plast Reconstr Surg* 2009;123:589–98; discussion 599–600.
- 8 Wackenfors A, Gustafsson R, Sjogren J, Algotsson L, Ingemansson R, Malmso M. Blood flow responses in the peristernal thoracic wall during vacuum-assisted closure therapy. *Ann Thorac Surg* 2005;79:1724–30; discussion 1730–1.
- 9 Borgquist O, Ingemansson R, Malmso M. Wound edge microvascular blood flow during negative-pressure wound therapy: examining the effects of pressures from –10 to –175 mmHg. *Plast Reconstr Surg* 125:502–9.
- 10 Wackenfors A, Sjogren J, Gustafsson R, Algotsson L, Ingemansson R, Malmso M. Effects of vacuum-assisted closure therapy on inguinal wound edge microvascular blood flow. *Wound Repair Regen* 2004;12(6):600–6.
- 11 Sjögren J, Gustafsson R, Koul B, Ingemansson R. Selective mediastinal tamponade to control coagulopathic bleeding. *Ann Thorac Surg* 2003;75:1311–3.
- 12 Kairinos N, Voogd AM, Botha PH, Kotze T, Kahn D, Hudson DA, Solomons M. Negative-pressure wound therapy II: negative-pressure wound therapy and increased perfusion. Just an illusion? *Plast Reconstr Surg* 2009;123:601–12.
- 13 Borgquist O, Ingemansson R, Malmso M. The effect of intermittent and variable negative pressure wound therapy on wound edge microvascular blood flow. *Ostomy Wound Manage* 56(3): 60–7.
- 14 Murphey GC, Macias BR, Hargens AR. Depth of penetration of negative pressure wound therapy into underlying tissues. *Wound Repair Regen* 2009;17:113–7.
- 15 Petzina R, Gustafsson L, Mokhtari A, Ingemansson R, Malmso M. Effect of vacuum-assisted closure on blood flow in the peristernal thoracic wall after internal mammary artery harvesting. *Eur J Cardiothorac Surg* 2006;30:85–9.
- 16 Argenta LC, Morykwas MJ. Vacuum-assisted closure: a new method for wound control and treatment: clinical experience. *Ann Plast Surg* 1997;38:563–76; discussion 577.
- 17 Krasner DL. Managing wound pain in patients with vacuum-assisted closure devices. *Ostomy Wound Manage* 2002;48:38–43.
- 18 Borgquist O, Gustafsson L, Ingemansson R, Malmso M. Tissue ingrowth into foam but not into gauze during negative pressure wound therapy. *Wounds* 2009;21:302–9.
- 19 Malmjö M, Lindstedt S, Ingemansson R. Effects of foam or gauze on sternum wound contraction, distension and heart and lung damage during negative-pressure wound therapy of porcine sternotomy wounds. *Interact Cardiovasc Thorac Surg* 2011;12:349–54.
- 20 Malmjö M, Borgquist O. NPWT settings and dressing choices made easy. *Wounds International* 2010;1.
- 21 Malmso M, Ingemansson R, Sjogren J. Mechanisms governing the effects of vacuum-assisted closure in cardiac surgery. *Plast Reconstr Surg* 2007;120:1266–75.

Paper II



Measurements of wound edge microvascular blood flow during negative pressure wound therapy using thermodiffusion and transcutaneous and invasive laser Doppler velocimetry

Ola Borgquist, MD¹; Erik Anesäter, MD²; Erik Hedström, MD, PhD³; Charles K. Lee, MD⁴; Richard Ingemansson, MD, PhD⁵; Malin Malmström, MD, PhD²

1. Department of Anesthesiology and Intensive Care and Department of Ophthalmology, Lund University and Skåne University Hospital, Lund, Sweden
2. Department of Ophthalmology, Lund University and Skåne University Hospital, Lund, Sweden
3. Department of Clinical Physiology, Lund University and Skåne University Hospital, Lund, Sweden
4. Division of Plastic & Reconstructive Surgery, University of California, San Francisco (UCSF), San Francisco, California
5. Department of Cardiothoracic Surgery, Lund University and Skåne University Hospital, Lund, Sweden

Reprint requests:

Associate Professor M. Malmström, BMC
A13, SE-221 84 Lund, Sweden.
Tel: +46 733 565650;
Fax: +46 46 222 0616;
Email: malin.malmstrom@med.lu.se

Manuscript received: May 1, 2011
Accepted in final form: September 8, 2011

DOI:10.1111/j.1524-475X.2011.00741.x

ABSTRACT

The effects of negative pressure wound therapy (NPWT) on wound edge microvascular blood flow are not clear. The aim of the present study was therefore to further elucidate the effects of NPWT on periwound blood flow in a porcine peripheral wound model using different blood flow measurement techniques. NPWT at -20 , -40 , -80 , and -125 mmHg was applied to a peripheral porcine wound ($n = 8$). Thermodiffusion, transcutaneous, and invasive laser Doppler velocimetry were used to measure the blood perfusion 0.5, 1.0, and 2.5 cm from the wound edge. Thermodiffusion (an invasive measurement technique) generally showed a decrease in perfusion close to the wound edge (0.5 cm), and an increase further from the edge (2.5 cm). Invasive laser Doppler velocimetry showed a similar response pattern, with a decrease in blood flow 0.5 cm from the wound edge and an increase further away. However, 1.0 cm from the wound edge blood flow decreased with high pressure levels and increased with low pressure levels. A different response pattern was seen with transcutaneous laser Doppler velocimetry, showing an increase in blood flow regardless of the distance from the wound edge (0.5, 1.0, and 2.5 cm). During NPWT, both increases and decreases in blood flow can be seen in the periwound tissue depending on the distance from the wound edge and the pressure level. The pattern of response depends partly on the measurement technique used. The combination of hypoperfusion and hyperperfusion caused by NPWT may accelerate wound healing.

Blood flow changes around the wound edges are believed to be among the mechanisms by which negative pressure wound therapy (NPWT) accelerates wound healing.¹⁻⁵ However, the effect of NPWT on wound edge microvascular blood flow has been the subject of much debate following reports of different results by different research groups.¹⁻⁵ Invasive laser Doppler velocimetry has been used to show that the microvascular blood flow in wounds on the back of pigs increased four times above the baseline value when a negative pressure of -125 mmHg was applied, whereas blood flow was inhibited at -400 mmHg and greater negative pressures.² We have previously studied blood flow at different distances from the wound edge (0.5 to 5 cm), in both subcutaneous and muscular tissue,^{3,6,7} and at different levels of negative pressure (-10 to -200 mmHg)⁶ in a porcine peripheral wound model, using invasive laser Doppler velocimetry. Blood flow unequivocally increased 2.5 cm from the wound edge upon negative pressure application,⁶ while it decreased 0.5 cm from the wound edge.^{3,4,6} The change in blood flow was found to increase gradually with increasing level of negative pressure, and was

maximal at approximately -80 mmHg.⁶ Timmers et al. measured the blood flow in healthy intact forearm skin during NPWT using transcutaneous laser Doppler velocimetry, and found only increases in blood flow for pressures between -100 and -500 mmHg.³ Conversely, Kairinos et al. found only decreases in perfusion when studying blood flow in human tissue using radioisotope perfusion imaging.¹ There is therefore no consensus on the effect of NPWT on the periwound blood flow.

It has never been shown whether the increases or decreases in blood flow in the wound edge during NPWT are beneficial for wound healing. It may be speculated that increases in blood flow are important to ensure adequate oxygenation and nutrient supply and removal of waste products from the healing wound. Hypoperfusion is known to stimulate angiogenesis and granulation tissue formation, but at the same time, it is important not to render the wound too hypoperfused, thereby causing ischemia.

Knowledge of the exact effects on periwound blood flow attained with a certain negative pressure level can be of help

when tailoring the therapy to the specific needs for a certain wound. It may sometimes be necessary to reduce the negative pressure level to minimize pain and the risk of ischemia, keeping in mind that it also is important to maintain some of the blood flow effects of the therapy.

Thermodiffusion is a blood flow measurement technique that has not previously been used in conjunction with NPWT, but it has been experimentally and clinically evaluated for quantification of microcirculation in various organs,⁸⁻¹¹ and there is significant correlation to results obtained by other techniques in different experimental and clinical settings.^{8,11}

The present study was designed to investigate the effects of NPWT on periwound blood flow in a porcine peripheral wound model, using both invasive (invasive laser Doppler velocimetry and thermodiffusion) and noninvasive (transcutaneous laser Doppler velocimetry) techniques for measurements. Blood flow was recorded before and after NPWT was applied at different levels of negative pressure (-20, -40, -80, and -125 mmHg) and at different distances from the wound edge (0.5, 1.0, and 2.5 cm).

MATERIALS AND METHODS

Animals

Healthy domestic pigs of both sexes, with a mean body weight of 70 kg, were used in the study. All the animals were fasted overnight with free access to water. The experimental protocol for this study was approved by the Ethics Committee for Animal Research, Lund University, Sweden. All animals received humane care in compliance with the European Convention on Animal Care.

Anesthesia

An intramuscular injection of xylazine (Rompun® vet. 20 mg/mL, Bayer AG, Leverkusen, Germany; 2 mg/kg) mixed with ketamine (Ketaminol® vet. 100 mg/mL, Farmaceutici Gellini S.p.A., Aprilia, Italy; 20 mg/kg) was used for premedication. Intravenous catheters were inserted into the auricular veins of both ears. Anesthesia was then induced with intravenous sodium thiopental (Pentothal®, Abbott Scandinavia, Stockholm, Sweden; ~10 mg/kg) and maintained with a continuous infusion of fentanyl (Leptanal®, Lilly, France; 3.5 µg/kg/hour) in Ringer's acetate or buffered 2.5% glucose (250–500 mL/hour) in combination with sodium thiopental (400–600 mg/hour) delivered via an infusion pump (Compact Perfusor, Braun, Melsungen, Germany). After orotracheal intubation using a 7.5-mm diameter cuffed endotracheal tube, the pig was connected to a rebreathing circuit (Servo 900C; Siemens-Elementa AB, Solna, Sweden) and its lungs were ventilated mechanically in the volume-controlled mode (65% N₂O, 35% O₂). Ventilatory settings were identical for all animals (respiratory rate, 15 breaths/minute; minute ventilation, 10 L/minute). A positive end-expiratory pressure of 5 cmH₂O was applied. A Foley catheter was inserted into the urinary bladder through a suprapubic cystostomy. The animals remained anesthetized during the entire experiment. After the experiments, a lethal dose of potassium chloride was administered intravenously.

Wound treatment

The animals were placed in the lateral position, and wounds (6 cm in diameter) penetrating into the muscle were created on the paravertebral area of the back. Open-pore polyurethane foam was placed in the wound cavities and trimmed to a size slightly larger than the wound in order to allow volume reduction during vacuum application. The wounds were sealed with a transparent adhesive drape. A drain connected the foam with a vacuum source that was set to deliver negative pressures of -20, -40, -80, or -125 mmHg. These pressure levels were selected as they have been shown to have low (-20 mmHg), half of the maximal (-40 mmHg), and maximal (-80 mmHg) effects on blood flow in a previous study.⁶ The highest pressure level, -125 mmHg, was chosen because it is a commonly used pressure level in the clinical setting.¹² After preparation of the wounds with NPWT dressings (at atmospheric pressure), the blood flow in the wound edges was allowed to stabilize for 1 hour.

Blood flow measurements using thermodiffusion (an invasive technique)

The Bowman Perfusion Monitor (Hemedex, Cambridge, MA) is based on the principle of thermodiffusion. A thermal transducer is mounted at the tip of a flexible 19G QFlow 500 Thermal Diffusion Probe. The transducer is heated to a temperature 2 °C above that of the surrounding tissue. The power dissipated in the thermistor provides a measure of the ability of the tissue to carry away the heat by both thermal conduction within the tissue and by thermal convection due to tissue blood flow. A passive, proximal thermistor is used to monitor, and compensate for, temporal changes in tissue baseline temperature. Perfusion is measured as mL/100 mg tissue/minute in a small, focal volume of tissue surrounding the distal tip of the probe.

Two thermal diffusion probes were inserted into the muscle tissue 0.5 and 2.5 cm from the wound edge, using a 16G Secalon-T™ central venous catheter (BD Medical Surgical Systems, Stockholm, Sweden). Blood perfusion was recorded before and after the application of negative pressure (-20, -40, -80, or -125 mmHg). Between each negative pressure application, there was a 15-minute interval to allow for stabilization of the blood flow to the baseline value. The experimental setup is shown in Figure 1.

Invasive laser Doppler velocimetry

Laser Doppler velocimetry allows the microvascular blood flow to be measured continuously. Two four-channel Perimed PF5010 Laser Doppler Perfusion Monitor units (Perimed, Stockholm, Sweden) were used. The filament probes were inserted into the muscle tissue 0.5, 1.0, and 2.5 cm from the wound edge. Laser Doppler recordings were performed before and after the application of negative pressures. Between each negative pressure application, there was a 15-minute interval to allow for stabilization of the blood flow to the baseline value. The results are shown on the monitor as arbitrary perfusion units, and are presented here as a percent of the baseline values (i.e., before the application of negative pressure).

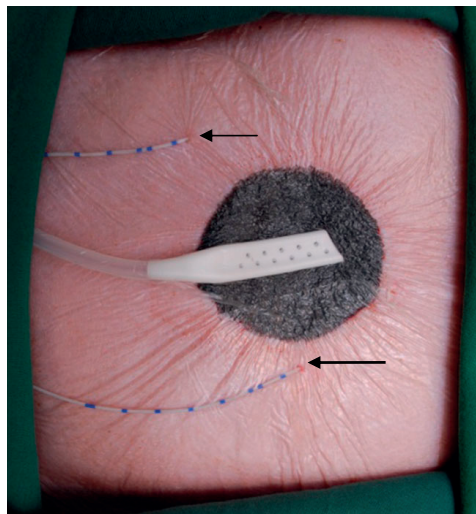


Figure 1. Photograph of the experimental setup for blood flow measurements using thermodiffusion with the Bowman Perfusion Monitor. A wound was created on the back of a pig. Two probes for blood flow measurements were inserted intramuscularly 0.5 cm (arrow) and 2.5 cm (arrowhead) from the wound edge. The wound was then sealed for negative pressure wound therapy.

Transcutaneous laser Doppler velocimetry

The O2C unit (LEA Medizintechnik, Giessen, Germany) transmits both continuous laser light and white light to the tissue where it is scattered and collected at the skin surface. The collected light is split into its spectral components by a charge-coupled device, and is converted into an electrical signal. The laser Doppler shift is detected, and the product of moving erythrocytes and the velocity of each erythrocyte are used to calculate the relative blood flow. White light is used for the detection of oxygen saturation and relative amount of hemoglobin. Blood flow and relative amount of hemoglobin were obtained in terms of arbitrary units, whereas oxygen saturation is expressed in percent.

Flat measurement probes (LF-2, LEA Medizintechnik) were placed on the skin surface 0.5, 1.0, and 2.5 cm from the wound edge, and held in place by a transparent adhesive film. Measurements were performed before and after each negative pressure (-20 , -40 , -80 , or -125 mmHg) was applied. Fifteen minutes was allowed for baseline stabilization between each pressure setting. The experimental setup is shown in Figure 2.

Limitations

Both oxygen saturation and the relative amount of hemoglobin were measured using the O2C unit. However, great variations and inconsistency in the results between the different

recordings made the measurements unreliable. These measurements were therefore not included in the analysis.

Calculations and statistics

Calculations and statistical analysis were performed using GraphPad 5.0 software (San Diego, CA). Blood flow results are presented as the percent change upon negative pressure application compared to the baseline values. Results are presented as the mean \pm the standard error of the mean. Statistical analysis was performed using the Mann–Whitney test when comparing two groups, and the Kruskal–Wallis test with Dunn's test for multiple comparisons when comparing three groups or more. Significance was defined as $p < 0.05$.

RESULTS

All differences referred to in the text were statistically significant.

Blood flow measured using thermodiffusion (an invasive technique)

Close to the wound edge (0.5 cm from the wound edge), increased perfusion ($10 \pm 18\%$) was recorded at a low level of negative pressure (-20 mmHg), while decreased perfusion (e.g., $-12 \pm 35\%$ at -80 mmHg) was found at higher levels of negative pressure (-40 , -80 , and -125 mmHg). Further from

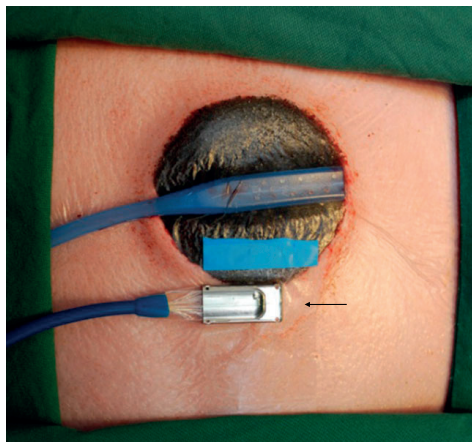


Figure 2. Photograph of the experimental setup for blood flow measurements using transcutaneous laser Doppler velocimetry with the O2C device. A wound was created on the back of a pig and the wound was then sealed for negative pressure wound therapy. The probe (arrow) was placed 0.5, 1.0, or 2.5 cm from the wound edge. In this photograph, the sensing part of the probe is placed 0.5 cm from the wound edge.

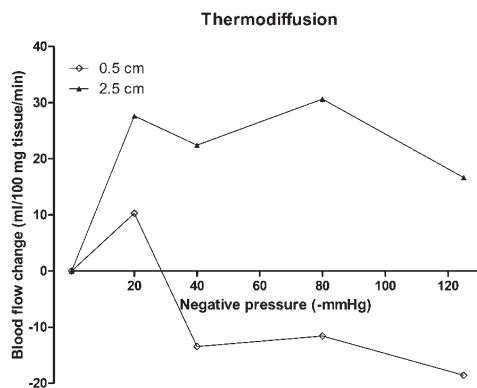


Figure 3. Wound edge microvascular blood flow measured invasively using thermodiffusion, 0.5 and 2.5 cm from the wound edge. Recordings were performed before and after negative pressure wound therapy was applied, and the change in blood flow compared to the baseline level was calculated. Results are expressed as mean values.

the wound edge (2.5 cm), blood perfusion was seen to increase at all levels of negative pressure investigated (e.g., $31 \pm 20\%$ for -80 mmHg). See Figure 3 for detailed results.

Blood flow measured using invasive laser Doppler velocimetry

Close to the wound edge (0.5 cm), a decrease in the microvascular blood flow was recorded at all negative pressure levels studied (e.g., $-45 \pm 7\%$ at -80 mmHg). One centimeter from the wound edge, the measured blood flow increased at low levels of negative pressure (e.g., $12 \pm 10\%$ at -40 mmHg), and then decreased at higher levels of negative pressure (e.g., $-30 \pm 8\%$ at -80 mmHg). Further from the wound edge (2.5 cm), the perfusion increased for all negative pressures studied (e.g., $41 \pm 8\%$ for -80 mmHg). See Figure 4 for detailed results.

Blood flow measured using transcutaneous laser Doppler velocimetry

When laser Doppler measurements were performed transcutaneously, using skin probes, blood flow was found to increase gradually with increasing levels of negative pressure at all distances from the wound edge. Typical values were $1 \pm 3\%$ when measured 0.5 cm from the wound edge, $4 \pm 2\%$ when measured 1.0 cm from the wound edge, and $7 \pm 3\%$ when measured 2.5 cm from the wound edge, at -80 mmHg (Figure 5).

DISCUSSION

In the present study, the effects of NPWT on the periwound microvascular blood flow were determined in detail in a

porcine model. Thermodiffusion was used for continuous, real-time quantitative flow measurements. To our knowledge, this technique has never before been used to study the effects of NPWT on blood flow. In addition, transcutaneous and invasive laser Doppler velocimetry were performed. Results using these two measurement techniques have varied considerably in previous studies.²⁻⁷ This is the first time transcutaneous and invasive laser Doppler velocimetry have been used in parallel in the same experimental setup to evaluate the cause of the variability in a controlled way.

Blood flow effects 2.5 cm from the wound edge

All the techniques used in this study demonstrated that blood flow increased 2.5 cm from the wound edge when NPWT was applied. This is in line with previous work by Timmers et al., who used transcutaneous laser Doppler velocimetry to measure blood flow in healthy intact forearm skin,⁵ and by Wackenfors et al., where invasive (intramuscular) laser

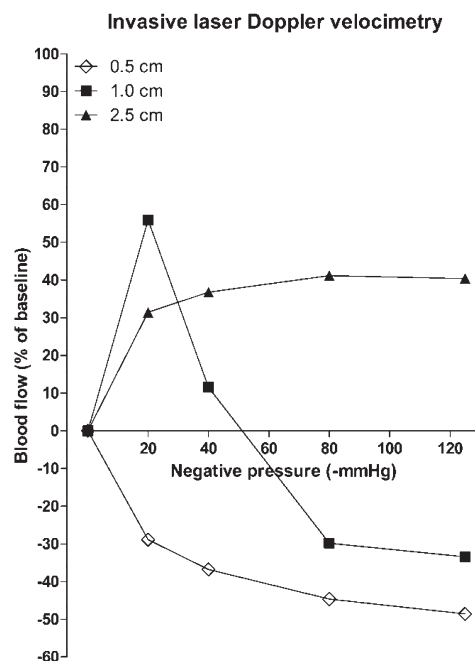


Figure 4. Wound edge microvascular blood flow measured using invasive laser Doppler velocimetry, with probes placed in muscle tissue 0.5, 1.0, and 2.5 cm from the wound edge. Recordings were performed before and after negative pressure wound therapy was applied, and the percent change in blood flow was calculated. Results are expressed as mean values.

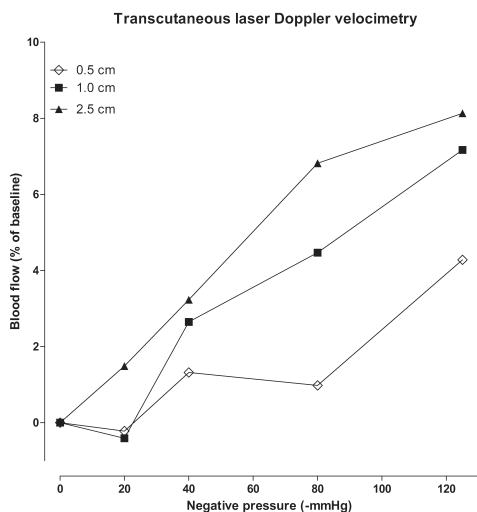


Figure 5. Wound edge microvascular blood flow measured using transcutaneous laser Doppler velocimetry, with a probe placed on the skin surface 0.5, 1.0, and 2.5 cm from the wound edge. Recordings were performed before and after negative pressure wound therapy was applied, and the percent change in blood flow was calculated. Results are expressed as mean values.

Doppler velocimetry was used in porcine inguinal wounds. The mechanism by which blood flow is increased 2.5 cm from the wound edge after the application of NPWT is difficult to explain. Kairinos et al. showed that the pressure on the tissue 2 cm from the wound edge was the same as atmospheric pressure, and, thus, a change in tissue pressure is not a plausible explanation of the present blood flow findings.¹³ NPWT has mechanical effects causing wound contraction.¹⁴ When applied to a wound cavity, NPWT may create a force on the tissue that can open up small arterioles and capillaries, leading to increased blood flow.^{15,16} Indeed, previous experimental studies have shown that small arterioles and capillaries in the wound edge tissue open up upon the application of negative pressure.^{15,16}

Blood flow effects 0.5 cm from the wound edge

Blood flow decreased 0.5 cm from the wound edge during NPWT when measured by invasive laser Doppler velocimetry. We have found similar results in our previous studies where we used the same measurement technique in porcine peripheral wound models.^{4,6} Thermofusion measurements (also an invasive technique) performed in the same experimental setup confirmed the decrease in blood flow in tissue close to the wound edge during NPWT. However, when blood flow was measured by noninvasive laser Doppler velocimetry at a similar distance using transcutaneously placed probes, the

blood flow appeared to increase when NPWT was applied. The latter finding is in accordance with the results of a study by Timmers et al., who observed an increase in blood flow when making transcutaneous laser Doppler velocimetry recordings in the forearm of healthy volunteers.⁵

Differences in results obtained with the invasive and transcutaneous laser Doppler measurement techniques 0.5 cm from the wound edge

The reason for the disparity between invasive and transcutaneous laser Doppler measurements can only be speculated upon, but it may be due to the fact that these techniques measure blood flow in different tissue types (i.e., the dermis in the case of the transcutaneous technique, and inside muscle tissue in the case of the invasive technique). The effects of NPWT on blood flow in the tissue close to the wound edge are the result of tissue compression and a resulting increase in tissue pressure.^{6,13} Dense tissue, such as pig skin, will resist compression, and there may be no decrease in blood flow there, while muscle tissue is less dense and will be compressed to a greater extent, resulting in decreased blood flow during NPWT. Another explanation of the differences between the invasive and transcutaneous measurements may be that laser Doppler velocimetry has a small sampling area and, for the transcutaneous technique, the laser light must travel through the epidermis before reaching the microcirculation, while probes inserted into the tissue will be in direct contact with the microvasculature of the tissue.

Transcutaneous measurement has been the method of choice in clinical practice due to the non-invasiveness of the technique. Such measurements may not accurately reflect the blood flow effects of NPWT on the wound edge as the present study showed only increases in blood flow with this technique, whereas invasive measurements showed both increases and decreases in blood flow. However, it cannot be concluded from this study whether increases or decreases in blood flow are beneficial for wound healing. It may be speculated that increases in blood flow are important to ensure adequate oxygenation and nutrient supply and removal of waste products from the healing wound. Hypoperfusion is known to stimulate angiogenesis and granulation tissue formation, but at the same time, it is important not to render the wound too hypoperfused, thereby causing ischemia.

Blood flow effects 1.0 cm from the wound edge (the transition zone)

In this study, the effect on blood flow 1.0 cm from the wound edge appeared to depend both on the level of negative pressure applied and on the measurement technique used. With an invasive laser Doppler measurement technique, high levels of negative pressure resulted in decreased blood flow, while low pressure levels led to increased blood flow. There may thus be a transition zone between the hypoperfused tissue closer to the wound and the hyperperfused tissue further from the wound. Thus, the response of the blood flow in muscle tissue when negative pressure is applied is dependent on the level of negative pressure, and may result in an increase or a decrease in perfusion (Figure 6).

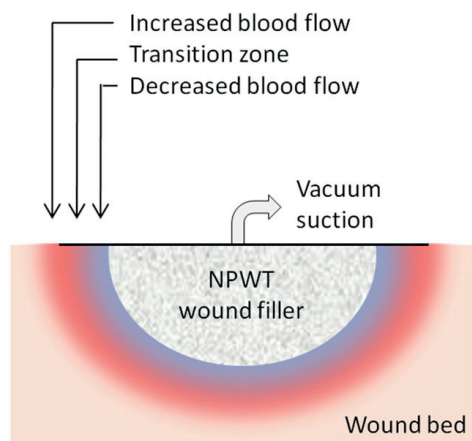


Figure 6. Schematic illustration of the effect of negative pressure wound therapy (NPWT) on periwound blood flow. In general, close to the wound edge, blood flow decreases (blue), while further from the wound edge, blood flow increases (red). Between these locations, there may be a transition zone where the blood flow may increase or decrease depending on the negative pressure level.

Transcutaneous laser Doppler measurements resulted in increased dermal blood flow for all negative pressure levels greater than -20 mmHg.

The negative pressure level

The most commonly used pressure level in everyday wound care is -125 mmHg, based on a limited, pioneering study on pigs carried out in 1997.² However, we now know from more recent and detailed animal studies that the maximal biological effects on the wound edges, in terms of wound contraction,¹⁷ regional blood flow,⁶ and the formation of granulation tissue,¹⁸ are obtained already at -80 mmHg. Clinical studies have also shown that negative pressure levels of less than -125 mmHg result in excellent wound healing,¹⁹ and in a series of clinical cases, it was found that wound healing was similar when using -125 and -75 mmHg.²⁰ The results of the present study confirm that -80 mmHg has maximal effects on blood flow. If the patient is experiencing pain, or if the tissue is poorly vascularized (e.g., in diabetic foot ulcers and thin skin transplants), it may be necessary to reduce the negative pressure level to minimize pain and the risk of ischemia.^{1,13,21} The findings of the present study confirm that a negative pressure of -40 mmHg reduces the blood flow changes significantly, and may thus be a good choice for NPWT of poorly perfused tissues. We know from previous studies that NPWT has wound-healing effects at this level of negative pressure.^{6,22} Biological effects of NPWT are seen already at a negative pressure level of -20 mmHg, but this is probably the lowest pressure that can be used for NPWT.⁶ In the present study, a

pressure level of -20 mmHg resulted in an increase in blood perfusion at both 0.5 and 2.5 cm from the wound edge as measured by thermodiffusion, and may thus be an interesting pressure for treating poorly perfused wounds.

Limitations

The reason for the differences in the findings of previous blood flow studies could not be determined, but it may depend on the technique used to measure perfusion. Laser Doppler velocimetry has been used in most of the studies.^{2,3,5-7} Several factors may influence the outcome when measuring the periwound blood flow, e.g., movement artifacts, the location of the measurement relative to the wound edge, the tissue type, the geometry of the wound, the wound filler size or type, and the negative pressure level.

To conclude, thermodiffusion and transcutaneous and invasive laser Doppler velocimetry have been used to determine blood perfusion in the immediate periwound area during NPWT. The results confirm previous findings that blood flow is increased 2.5 cm from the wound edge for pressures between -20 and -125 mmHg. In tissue 0.5 cm from the wound edge, blood flow is seen to decrease when measured with invasive techniques. When probes are placed transcutaneously, the blood flow is found to increase. This may be due to the differences in tissue structure.

ACKNOWLEDGMENTS

We thank Julia Waga for her invaluable assistance with the experimental work. This study was supported by the Swedish Medical Research Council, Lund University Faculty of Medicine, the Swedish Government Grant for Clinical Research, Lund University Hospital Research Grants, the Swedish Medical Association, the Royal Physiographic Society in Lund, the Åke Wiberg Foundation, the Anders Otto Swärd Foundation/Ulrika Eklund Foundation, the Magn Bergvall Foundation, the Crafoord Foundation, the Anna-Lisa and Sven-Erik Nilsson Foundation, the Jeansson Foundation, the Swedish Heart-Lung Foundation, Anna and Edvin Berger's Foundation, the Märta Lundqvist Foundation, and the Lars Hierta Memorial Foundation. Marcom Medical ApS, Denmark, kindly supplied the O2C unit.

REFERENCES

1. Kairinos N, Voogd AM, Botha PH, Kotze T, Kahn D, Hudson DA, Solomons M. Negative-pressure wound therapy II: negative-pressure wound therapy and increased perfusion. Just an illusion? *Plast Reconstr Surg* 2009; 123: 601–12.
2. Morykwas MJ, Argenta LC, Shelton-Brown EI, McGuirt W. Vacuum-assisted closure: a new method for wound control and treatment: animal studies and basic foundation. *Ann Plast Surg* 1997; 38: 553–62.
3. Wackenfors A, Gustafsson R, Sjogren J, Sjogren J, Algotsson L, Ingemansson R, Malmjö M. Blood flow responses in the peristernal thoracic wall during vacuum-assisted closure therapy. *Ann Thorac Surg* 2005; 79: 1724–30; discussion 1730–1.
4. Wackenfors A, Sjogren J, Gustafsson R, Algotsson L, Ingemansson R, Malmjö M. Effects of vacuum-assisted closure therapy on inguinal wound edge microvascular blood flow. *Wound Rep Regen* 2004; 12: 600–6.

5. Timmers MS, Le Cessie S, Banwell P, Jukema GN. The effects of varying degrees of pressure delivered by negative-pressure wound therapy on skin perfusion. *Ann Plast Surg* 2005; 55: 665–71.
6. Borgquist O, Ingemansson R, Malmjsjo M. Wound edge microvascular blood flow during negative-pressure wound therapy: examining the effects of pressures from –10 to –175 mmHg. *Plast Reconstr Surg* 2010; 125: 502–9.
7. Wackenfors A, Sjogren J, Algotsson L, Gustafsson R, Ingemansson R, Malmjsjo M. The effect of vacuum-assisted closure therapy on the pig femoral artery vasomotor responses. *Wound Rep Regen* 2004; 12: 244–51.
8. Klar E, Kraus T, Bleyl J, Newman WH, Bowman HF, Hofmann WJ, Kummer R, Bredt M, Herfarth C. Thermodiffusion for continuous quantification of hepatic microcirculation—validation and potential in liver transplantation. *Microvasc Res* 1999; 58: 156–66.
9. Horn P, Vajkoczy P, Thomé C, Muench E, Schilling L, Schmiedek P. Xenon-induced flow activation in patients with cerebral insult who undergo xenon-enhanced CT blood flow studies. *AJNR Am J Neuroradiol* 2001; 22: 1543–9.
10. Angelescu M, Bredt M, Kraus T, Weber C, Wiesel M, Klar E. Perioperative monitoring of the cortical microcirculation in clinical renal transplantation by thermodiffusion. *Transplant Proc* 1997; 29: 2790–2.
11. Vajkoczy P, Roth H, Horn P, Lucke T, Thomé C, Hubner U, Martin GT, Zapletal C, Klar E, Schilling L, Schmiedek P. Continuous monitoring of regional cerebral blood flow: experimental and clinical validation of a novel thermal diffusion microprobe. *J Neurosurg* 2000; 93: 265–74.
12. Argenta LC, Morykwas MJ, Marks MW, DeFranzo AJ, Molnar JA, David LR. Vacuum-assisted closure: state of clinic art. *Plast Reconstr Surg* 2006; 117 (Suppl. 7): 127S–42S.
13. Kairinos N, Solomons M, Hudson DA. The paradox of negative pressure wound therapy—in vitro studies. *J Plast Reconstr Aesthet Surg* 2010; 63: 174–9.
14. Malmjsjo M, Ingemansson R, Martin R, Huddleston E. Negative-pressure wound therapy using gauze or open-cell polyurethane foam: similar early effects on pressure transduction and tissue contraction in an experimental porcine wound model. *Wound Rep Regen* 2009; 17: 200–5.
15. Chen SZ, Li J, Li XY, Xu LS. Effects of vacuum-assisted closure on wound microcirculation: an experimental study. *Asian J Surg* 2005; 28: 211–7.
16. Ichioka S, Watanabe H, Sekiya N, Shibata M, Nakatsuka T. A technique to visualize wound bed microcirculation and the acute effect of negative pressure. *Wound Rep Regen* 2008; 16: 460–5.
17. Borgquist O, Ingemansson R, Malmjsjo M. The influence of low and high pressure levels during negative-pressure wound therapy on wound contraction and fluid evacuation. *Plast Reconstr Surg* 2011; 127: 551–9.
18. Borgquist O, Gustafsson L, Ingemansson R, Malmjsjo M. Tissue ingrowth into foam but not into gauze during negative pressure wound therapy. *Wounds* 2009; 21: 302–9.
19. Nease C. Using low pressure, negative pressure wound therapy for wound preparation and the management of split-thickness skin grafts in three patients with complex wounds. *Ostomy Wound Manage* 2009; 55: 32–42.
20. McCord SS, Naik-Mathuria BJ, Murphy KM, McLane KM, Gay AN, Bob Basu C, Downey CR, Hollier LH, Olutoye OO. Negative pressure therapy is effective to manage a variety of wounds in infants and children. *Wound Rep Regen* 2007; 15: 296–301.
21. Kairinos N, Solomons M, Hudson DA. Negative-pressure wound therapy I: the paradox of negative-pressure wound therapy. *Plast Reconstr Surg* 2009; 123: 589–98; discussion 599–600.
22. Isago T, Nozaki M, Kikuchi Y, Honda T, Nakazawa H. Effects of different negative pressures on reduction of wounds in negative pressure dressings. *J Dermatol* 2003; 30: 596–601.

Paper III

A Rigid Disc for Protection of Exposed Blood Vessels During Negative Pressure Wound Therapy

Surgical Innovation
20(1) 74–80
© The Author(s) 2013
Reprints and permission:
sagepub.com/journalsPermissions.nav
DOI: 10.1177/1553350612444169
<http://sri.sagepub.com>


Erik Anesäter, MD¹, Ola Borgquist, MD¹, Christian Torbrand, MD¹,
K. Markus Roupé, MSc, PhD¹, Richard Ingemansson, MD, PhD¹,
Sandra Lindstedt, MD, PhD¹, and Malin Malmjö, MD, PhD¹

Abstract

Background. There are increasing reports of serious complications and deaths associated with negative pressure wound therapy (NPWT). Bleeding may occur when NPWT is applied to a wound with exposed blood vessels. Inserting a rigid disc in the wound may protect these structures. The authors examined the effects of rigid discs on wound bed tissue pressure and blood flow through a large blood vessel in the wound bed during NPWT. **Methods.** Wounds were created over the femoral artery in the groin of 8 pigs. Rigid discs were inserted. Wound bed pressures and arterial blood flow were measured during NPWT. **Results.** Pressure transduction to the wound bed was similar for control wounds and wounds with discs. Blood flow through the femoral artery decreased in control wounds. When a disc was inserted, the blood flow was restored. **Conclusions.** NPWT causes hypoperfusion in the wound bed tissue, presumably as a result of mechanical deformation. The insertion of a rigid barrier alleviates this effect and restores blood flow.

Keywords

experimental surgery, wound healing, negative pressure wound therapy, microvascular blood flow

Introduction

There are increasing numbers of reports on deaths and serious complications associated with the use of negative pressure wound therapy (NPWT).^{1–4} Bleeding is one of the more serious complications, occurring in patients with exposed blood vessels or vascular grafts (such as femoral and femoral-popliteal grafts), in sternal and groin wounds, and during the removal of dressings adhered to or embedded in the wound bed tissue.⁵ The application of negative pressure treatment to nerves and blood vessels is currently contraindicated because of the risk of damage. These tissues are, however, often subject to NPWT because of the lack of effective alternative treatments. In November 2009, the Federal Drug Administration filed an alert where bleeding was classified as the most serious complication to NPWT, having been reported in 6 death and 17 injury reports.⁵ The importance of protecting exposed organs and sensitive tissue has also been emphasized in the international scientific literature.^{4,6–9}

Heart rupture, bypass graft bleeding, and death are the most devastating complications for patients treated with NPWT for mediastinitis after cardiac surgery, the incidence

being 4% to 7%.^{4,6–9} We have previously described the reason for heart rupture during NPWT in pigs using magnetic resonance imaging.¹⁰ The heart was shown to be drawn up toward the thoracic wall, the right ventricle bulged into the space between the sternal edges, and the sharp edges of the sternum protruded into the anterior surface of the heart. These events were not prevented by the insertion of soft, nonadhesive, wound-contact layers, but the insertion of a rigid disc between the anterior part of the heart and the inside of the thoracic wall was successful in providing protection.¹⁰ Heart and lung ruptures, similar to those seen in patients, were observed in this experimental setup without the rigid discs, whereas no damage to heart or lungs was seen when rigid discs were used.¹¹

NPWT is also known to cause the rupture of blood vessels, leading to hemorrhage in peripheral wounds. The cause may be the negative pressure–induced mechanical

¹Lund University and Skåne University Hospital, Lund, Sweden

Corresponding Author:

Malin Malmjö, Department of Ophthalmology, Lund University and Skåne University Hospital, BMC A13, SE-221 84 Lund, Sweden
Email: malin.malmjoe@med.lu.se

deformation and a hypoperfusion of exposed, delicate structures resulting in damage to and tears in the blood vessels walls. NPWT is known to mechanically deform the wound edges^{12,13} and alter microvascular blood flow around the wound.¹⁴⁻¹⁸

The aim of the present study was to examine the effects on pressure transduction to the wound bed and blood flow through a large blood vessel during continuous NPWT with rigid discs of different designs inserted between the wound filler and the wound bed. We hypothesized that the placement of a rigid disc, able to withstand the forces of negative pressure, over an artery that is exposed in the wound bed could offer protection from hypoperfusion.

Materials and Methods

Animals

Eight healthy domestic pigs of both sexes, with a mean body weight of 70 kg, were used in the study. The animals were fasted overnight with free access to water. The experimental protocol for this study was approved by the Ethics Committee for Animal Research, Lund University, Sweden. All animals received humane care in compliance with the European Convention on Animal Care.

Anesthesia

An intramuscular injection of xylazine (Rompun vet 20 mg/mL; Bayer AG, Leverkusen, Germany; 2 mg/kg) mixed with ketamine (Ketaminol vet 100 mg/mL; Farnaceutici Gellini SpA, Aprilia, Italy; 20 mg/kg) was used for pre-medication. Intravenous catheters were inserted into the auricular veins of both ears. Anesthesia was then induced with intravenous sodium thiopental (Pentothal; Abbott Scandinavia, Stockholm, Sweden; 10-12 mg/kg) and maintained with a continuous infusion of fentanyl (Leptanal; Lilly, France; -3.5 µg/kg/h) in Ringer's acetate or buffered 2.5% glucose (250-500 mL/h), in combination with sodium thiopental (-400 mg/h), delivered via an infusion pump (Compact Perfusor, Braun, Melsungen, Germany). After orotracheal intubation using a 7.0 mm diameter cuffed endotracheal tube, the pig was connected to a rebreathing circuit (Servo 900C; Siemens-Elema AB, Solna, Sweden) and its lungs ventilated mechanically in the volume-controlled mode (65% N₂O, 35% O₂). Ventilatory settings were identical for all animals (respiratory rate = 15 breaths/min; minute ventilation = 10 L/min). A positive end-expiratory pressure of 5 cm H₂O was applied. A Foley catheter was inserted into the urinary bladder through a suprapubic cystostomy. The animals remained anesthetized during the entire experiment, which lasted for approximately 8 hours. On completion of the experiment, a lethal dose of potassium chloride was administered intravenously.

Wound Treatment

A 6-cm long wound was created over the femoral artery in the pig's groin. The exposed artery was approximately 6 cm in length. Tissue was removed to simulate a true open wound. Two intracranial tissue pressure micro-sensors (Codman ICP monitoring system, Johnson & Johnson Professional Inc-Codman, Henrico, VA) were sutured to the bottom of the wound, beside the artery, for recording of the pressure on the wound bed. The wound was sealed for NPWT using open-pore polyurethane foam. A laser Doppler probe (Probe 457, Perimed, Stockholm, Sweden) was inserted through a 2-cm incision, 5 cm distal to the NPWT-treated wound, to measure the distal blood flow in the femoral artery using a Perimed PF5010 LDPM unit (Perimed). After preparation of the wound, the blood flow was allowed to stabilize at atmospheric pressure for 1 hour. Wound bed pressure and femoral artery blood flow were recorded before and after the application of continuous negative pressure at -80 and -120 mm Hg using a custom-built vacuum source. The pressures used were consistent with clinical practice. The blood flow was recorded as arbitrary perfusion units (PU) and is presented here as percent of baseline values (before the application of negative pressure). Blood flow was recorded in probes showing a baseline blood flow between 0 and 300 PU. Values above 300 PU were excluded as they exceed normal physical blood flow, hence they were considered artificial. Blood flow was measured before and after the placement of a disc. The immediate effects of negative pressure were studied. The experimental setup is shown in Figure 1A and B.

The effects on blood flow through the femoral artery and pressure transduction to the wound bed after insertion of different rigid discs between the wound bed and the foam wound filler were investigated. The blood flow through the femoral artery was studied in the same wound, with and without a disc. Every wound thereby served as its own control.

The discs were 6 cm in diameter, millimeter-thin, made of plastic, and rigid enough to withstand the forces of the negative pressure. The discs were not commercially available. The discs were created with or without channels (to accommodate exposed sensitive structures such as blood vessels and nerves), perforations and a thin layer of open-pore structure black polyurethane foam covered the underside of the discs (to facilitate pressure transduction and fluid evacuation). The various combinations of discs and dressings are shown in Figure 2.

Calculations and Statistics

Calculations and statistical analysis were performed using GraphPad 5.0 software (San Diego, CA). Results

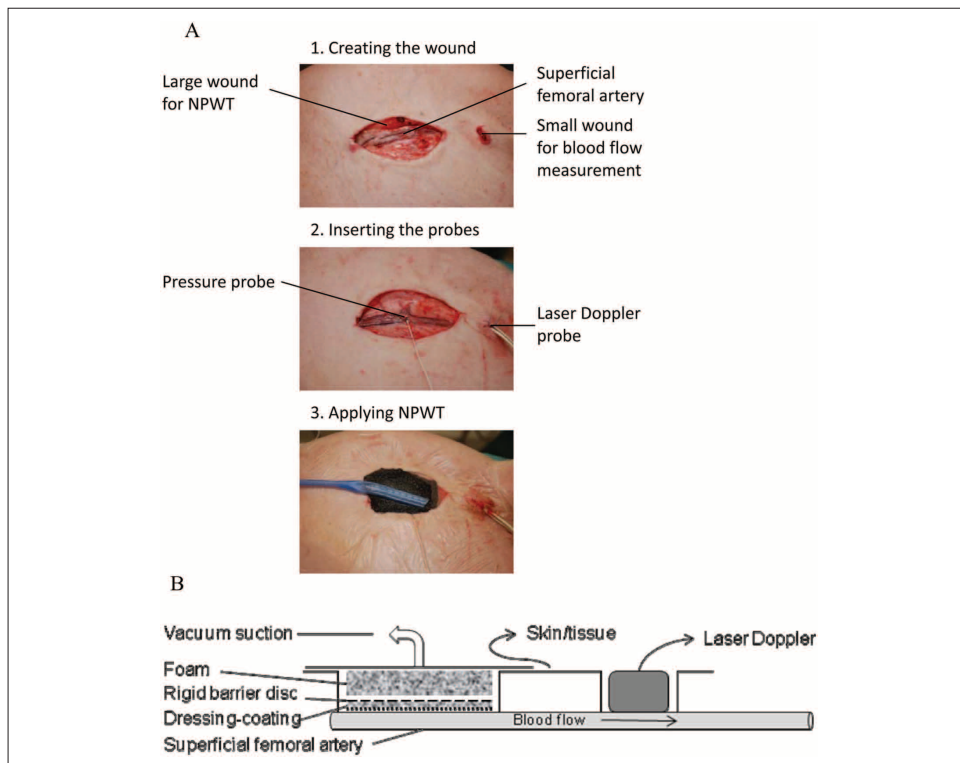


Figure 1. (A) Photographs and (B) schematic illustration of the experimental setup for measuring wound bed pressure and femoral artery blood flow

Two pressure sensors were sutured to the bottom of the wound. A laser Doppler probe was inserted through a 2-cm incision, 5 cm distal to the wound, to measure the blood flow in the femoral artery. The wound was treated with NPWT in the absence (control) or presence of rigid barrier discs of different designs. Wound bed pressure and distal blood flow was measured before and after application of NPWT at -80 or -120 mm Hg.

are presented as the mean of 8 measurements \pm the standard error of the mean. Statistical analysis was performed using Student's *t* test when comparing 2 groups and ANOVA with Dunn's test for multiple comparisons when comparing 3 groups or more. Grubb's test was used to identify outliers (6 outliers were found and excluded). Significance was defined as $P < .05$.

Results

Pressure on the Wound Bed

The wound bed pressure was similar in control wounds (filled with foam only) and wounds in which dressing-covered discs had been placed over the wound bed. Typical

values were -46 ± 6 mm Hg for control wounds and -48 ± 6 mm Hg for a dressing-covered, perforated disc, when -80 mm Hg was applied, $P > .30$ (Figure 3). Pressure transduction to the wound bed was similar for all the dressing-covered discs studied, that is, perforated and non-perforated discs, with and without channels (Figure 3, $P > .30$). However, the pressure transfer to the wound bed was impaired (-20 ± 6 mm Hg when treated at -80 mm Hg, $P = .011$) when using a bare disc (ie, without a dressing).

Blood Flow in the Femoral Artery

Similar decreases in blood flow were seen in the femoral artery, 5 cm distal to the control wound when continuous NPWT was applied at -80 and -120 mm Hg ($-8 \pm 4\%$




Figure 2. Schematic illustration of the dressings and discs used in the experimental setup. The upper illustration shows the surface of the disc from above, and the lower illustration shows a cross section of the foam wound filler and the underlying disc.

at -80 mm Hg and $-8 \pm 4\%$ at -120 mm Hg, $P > .30$). After the insertion of a protective disc, the blood flow increased as NPWT was applied (eg, $8 \pm 4\%$ at -80 mm Hg for a dressing-covered, perforated disc, $P = .016$). All discs had similar effects on blood flow ($P > .30$). See Figure 4 for detailed results.

Discussion

When NPWT is applied to a wound with exposed blood vessels or vascular grafts there is risk of damage to or rupture of these delicate structures, probably because of the mechanical deformation and/or hypoperfusion of the structures induced by NPWT. We placed rigid discs over the wound bed to minimize the mechanical deformation of the wound bed tissue and exposed structures, in this case the femoral artery. Our results show that negative pressure is distributed evenly over the wound surface when the underside of the disc is covered by a porous dressing. Furthermore, all discs had similar positive effects on blood flow.

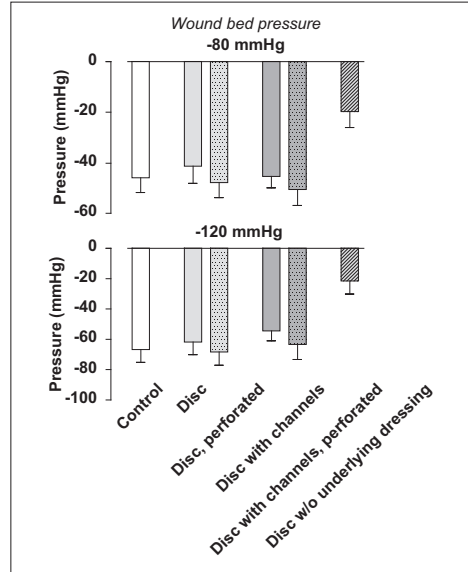


Figure 3. Wound bed pressure during NPWT at -80 and -120 mm Hg. Measurements were performed in the presence of foam only (control) and under various kinds of discs. Results are means \pm SEM of 8 experiments. Note that the wound bed pressure was similar in the control wound and in those with dressing-covered discs, but significantly less under the bare disc.

Pressure Delivery to the Wound Bed

The undersides of the discs were covered with a thin layer of open-pore foam, and then a perforated, soft, nonadherent wound contact layer was added in most of the cases. A contact layer allows the negative pressure to be distributed evenly over the wound surface; it also aids in removal of wound fluid from beneath the disc. The pressure transduction to the wound bed using dressing-covered discs was similar to that in the control wound without a disc. However, the pressure transfer to the wound bed was impaired when using a bare disc (ie, without a dressing), which most probably is because of the fact that there is no open structure wound dressing to allow the pressure to be distributed into the space underneath the disc.

Interestingly, the pressure on the wound bed was of a similar magnitude regardless of whether the rigid disc was perforated or not, suggesting that pressure transduction occurs in the dressing that covers the disc as well as through the perforations of the disc. The wounds in the present study were 6 cm in diameter, and it cannot

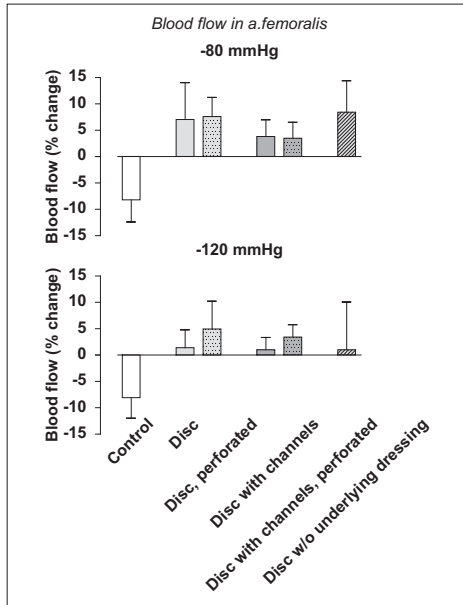


Figure 4. Change in blood flow in the femoral artery when NPWT was applied at -80 and -120 mm Hg. Measurements were performed in the presence of foam only (control) and under various kinds of discs. Results are expressed as the percent change compared with the baseline before the application of negative pressure and are mean \pm SEM of 8 experiments.

be deduced whether the same results regarding pressure transduction to the wound bed would have been obtained if larger rigid discs had been used. Presumably, as the size of the disc increases the importance of having perforations in the disc would also increase, to allow pressure transmission to, and fluid removal from, the wound bed.

It cannot be deduced from the present study whether the presence of a rigid barrier disc may limit the wound healing at the wound bed because of the formation of residual dead space and fistulae. We believe that it is of the utmost importance that pressure is transduced to the underside of the disc and distributed evenly over the wound bed in order to facilitate drainage of effluents and thereby hinder the formation of residual dead space, which may be a source of infection and fistulae formation. To maximize the pressure distribution over the wound bed it is our strong belief that the disc should be perforated and also covered with an open structure dressing that has the properties of distributing negative pressure to all parts of the wound.

Blood Flow in the Femoral Artery

Blood flow through the femoral artery decreased when NPWT was applied to the control wounds. This finding is in line with previous reports where the perfusion of the superficial wound bed tissue decreases during NPWT.^{14,16-19} The reason for the decrease in blood flow may be the compression of superficial tissue or structures that are exposed in the wound, leading to the collapse of the vasculature, being either the microvasculature^{14,16-19} or a larger artery (as in the present study). Compression of a large blood vessel may reduce the blood flow to the blood vessel wall itself, via vasa vasorum, and reduce the blood flow to more distal tissues that are supplied by the artery.

Thus, the damage to blood vessels or vascular grafts reported during NPWT⁵ may be caused both by hypoperfusion of the blood vessel wall (leading to necrosis) and by tearing forces exerted by the negative pressure. Anastomoses are known to be extra sensitive to hypoperfusion and tearing, and NPWT may cause graft failure with ensuing bleeding complications. Hypoperfusion and mechanical forces may also cause complications in wounds with other exposed delicate structures, such as nerves.

In the present study we inserted a rigid disc between the wound bed and the foam filler, which facilitated blood flow through the artery. The disc was rigid to provide a mechanical barrier to hinder the compression force that arises when the wound filler is pushed against the wound bed by the negative pressure. We have previously demonstrated that a rigid barrier protects against mechanical deformation of other cardiovascular structures during NPWT. In sternotomy wounds, the heart is sucked up toward the sharp edges of the split sternum and deformed by these wound edges when negative pressure is applied. Placement of a rigid barrier underneath these edges hinders this mechanical deformation of the heart.¹⁰

We have previously studied blood flow through large arteries and found that the blood flow through the mammary artery was not altered when applying NPWT to a sternotomy wound.²⁰ The reason for the difference between the findings in the present study and those in our previous study is probably that the mammary artery is embedded in tissue, and it is more than 3 cm away from the wound subjected to negative pressure therapy, while the artery in the present study was in direct contact with the dressings to which negative pressure was applied. It has been shown that the compressive forces exerted by NPWT extend less than 2 cm into the wound bed tissue.¹⁵ From a clinical point of view, this means that sensitive structures only require protection during NPWT when they are located in close proximity to the wound bed. In clinical practice, protective discs may not be necessary in all wounds, and their use should be weighed against the positive effects of NPWT in accelerating wound healing.

The presence of a disc probably prevents the micromechanical effects of the NPWT on the wound bed, which in turn might slow the speed of granulation tissue formation.

Limitations

It should be noted that the aim of the present study was to examine the effects on blood flow through a large blood vessel during NPWT and see the effects of the presence of a rigid disc. The effect of a rigid disc on wound healing can therefore not be deduced from the present study. A future study for monitoring granulation tissue formation would be valuable. Another limitation of the study is the short time frame of monitoring the blood flow and the wound bed. The risk of potential problems, such as pressure erosion from the contact between the wound bed, the blood vessel, and a rigid disc, has not been evaluated here.

Conclusions and Clinical Implications

Blood flow through a large artery exposed in a wound bed decreases when NPWT is applied. The placement of a rigid disc over the blood vessel restores blood flow, presumably by alleviating the compressive forces exerted by the negative pressure. A rigid disc placed over the wound bed may be beneficial to protect vital structures, such as blood vessels, vascular grafts, or nerves, from damage or rupture during NPWT.

Authors' Note

Authors Erik Anesäter and Ola Borgquist contributed equally to the study.

Declaration of Conflicting Interests

The authors declared no potential conflicts of interest with respect to the research, authorship, and/or publication of this article.

Funding

The authors disclosed receipt of the following financial support for the research, authorship, and/or publication of this article: This study was supported by the Swedish Medical Research Council, Lund University Faculty of Medicine, the Swedish Government Grant for Clinical Research, Lund University Hospital Research Grants, the Swedish Medical Association, the Royal Physiographic Society in Lund, the Åke Wiberg Foundation, the Anders Otto Swärd Foundation/Ulrika Eklund Foundation, the Magn Bergvall Foundation, the Crafoord Foundation, the Anna-Lisa and Sven-Erik Nilsson Foundation, the Jeansson Foundation, the Swedish Heart-Lung Foundation, Anna and Edvin Berger's Foundation, the Märta Lundqvist Foundation, and the Lars Hierta Memorial Foundation.

References

1. Bapat V, El-Muttardi N, Young C, Venn G, Roxburgh J. Experience with vacuum-assisted closure of sternal wound infections following cardiac surgery and evaluation of chronic complications associated with its use. *J Card Surg.* 2008;23:227-233.
2. Ennker IC, Malkoc A, Pietrowski D, Vogt PM, Ennker J, Albert A. The concept of negative pressure wound therapy (NPWT) after poststernotomy mediastinitis—a single center experience with 54 patients. *J Cardiothorac Surg.* 2009;4:5.
3. Sartipy U, Lockowandt U, Gabel J, Jidéus L, Dellgren G. Cardiac rupture during vacuum-assisted closure therapy. *Ann Thorac Surg.* 2006;82:1110-1111.
4. Petzina R, Malmjö M, Stamm C, Hetzer R. Major complications during negative pressure wound therapy in poststernotomy mediastinitis following cardiac surgery. *J Thorac Cardiovasc Surg.* 2010;140:1133-1136.
5. U.S. Food and Drug Administration. FDA preliminary public health notification: serious complications associated with negative pressure wound therapy systems. <http://www.fda.gov/MedicalDevices/Safety/AlertsandNotices/PublicHealthNotifications/ucm190658.htm>. Published November 13, 2009. Accessed March 23, 2012.
6. Gustafsson RI, Sjogren J, Ingemansson R. Deep sternal wound infection: a sternal-sparing technique with vacuum-assisted closure therapy. *Ann Thorac Surg.* 2003;76:2048-2053.
7. Hersh RE, Jack JM, Dahman MI, Morgan RF, Drake DB. The vacuum-assisted closure device as a bridge to sternal wound closure. *Ann Plast Surg.* 2001;46:250-254.
8. Malmjö M, Ingemansson R, Sjogren J. Mechanisms governing the effects of vacuum-assisted closure in cardiac surgery. *Plast Reconstr Surg.* 2007;120:1266-1275.
9. Sjogren J, Malmjö M, Gustafsson R, Ingemansson R. Poststernotomy mediastinitis: a review of conventional surgical treatments, vacuum-assisted closure therapy and presentation of the Lund University Hospital mediastinitis algorithm. *Eur J Cardiothorac Surg.* 2006;30:898-905.
10. Malmjö M, Petzina R, Ugander M, et al. Preventing heart injury during negative pressure wound therapy in cardiac surgery: assessment using real-time magnetic resonance imaging. *J Thorac Cardiovasc Surg.* 2009;138:712-717.
11. Malmjö M, Ingemansson R. Preventing injury to vital organs during negative pressure wound therapy. Paper presented at: John A. Boswick, MD, Burn and Wound Care Symposium; February 22-26, 2010; Maui, HI.
12. Borgquist O, Ingemansson R, Malmjö M. The influence of low and high pressure levels during negative-pressure wound therapy on wound contraction and fluid evacuation. *Plast Reconstr Surg.* 2011;127:551-559.
13. Malmjö M, Ingemansson R, Martin R, Huddleston E. Negative-pressure wound therapy using gauze or open-cell polyurethane foam: similar early effects on pressure

- transduction and tissue contraction in an experimental porcine wound model. *Wound Repair Regen.* 2009;17:200-205.
14. Borgquist O, Ingemansson R, Malmsjö M. Wound edge microvascular blood flow during negative-pressure wound therapy: examining the effects of pressures from -10 to -175 mm Hg. *Plast Reconstr Surg.* 2010;125:502-509.
 15. Kairinos N, Solomons M, Hudson DA. The paradox of negative pressure wound therapy—in vitro studies. *J Plast Reconstr Aesthet Surg.* 2010;63:174-179.
 16. Kairinos N, Solomons M, Hudson DA. Negative-pressure wound therapy I: the paradox of negative-pressure wound therapy. *Plast Reconstr Surg.* 2009;123:589-598.
 17. Wackenfors A, Gustafsson R, Sjögren J, Algotsson L, Ingemansson R, Malmsjö M. Blood flow responses in the peristernal thoracic wall during vacuum-assisted closure therapy. *Ann Thorac Surg.* 2005;79:1724-1730.
 18. Wackenfors A, Sjögren J, Gustafsson R, Algotsson L, Ingemansson R, Malmsjö M. Effects of vacuum-assisted closure therapy on inguinal wound edge microvascular blood flow. *Wound Repair Regen.* 2004;12:600-606.
 19. Kairinos N, Voogd AM, Botha PH, et al. Negative-pressure wound therapy II: negative-pressure wound therapy and increased perfusion. Just an illusion? *Plast Reconstr Surg.* 2009;123:601-612.
 20. Petzina R, Ugander M, Gustafsson L, et al. Topical negative pressure therapy of a sternotomy wound increases sternal fluid content but does not affect internal thoracic artery blood flow: assessment using magnetic resonance imaging. *J Thorac Cardiovasc Surg.* 2008;135:1007-1013.

Paper IV



The use of a rigid disc to protect exposed structures in wounds treated with negative pressure wound therapy: Effects on wound bed pressure and microvascular blood flow

Erik Anesäter, MD¹; Ola Borgquist, MD^{1,2}; Christian Torbrand, MD^{1,3}; K. Markus Roupé, MSc, PhD¹; Richard Ingemansson, MD, PhD⁴; Sandra Lindstedt, MD, PhD⁴; Malin Malmjö, MD, PhD¹

1. Department of Ophthalmology, Lund University and Skåne University Hospital, Lund, Sweden
2. Department of Anesthesiology, Lund University and Skåne University Hospital, Lund, Sweden
3. Department of Urology, Lund University and Skåne University Hospital, Lund, Sweden, and
4. Department of Cardiothoracic Surgery, Lund University and Skåne University Hospital, Lund, Sweden

Reprint requests:

Professor M. Malmjö, BMC A13, SE-221 84 Lund, Sweden.
Tel: +46 733 565650;
Email: malin.malmj@med.lu.se

Manuscript received: August 26, 2011
Accepted in final form: March 31, 2012

DOI:10.1111/j.1524-475X.2012.00801.x

ABSTRACT

There are increasing reports of deaths and serious complications associated with the use of negative pressure wound therapy (NPWT). Bleeding may occur in patients when NPWT is applied to a wound with exposed blood vessels or vascular grafts, possibly due to mechanical deformation and hypoperfusion of the vessel walls. Recent evidence suggests that using a rigid barrier disc to protect underlying tissue can prevent this mechanical deformation. The aim of this study was to examine the effect of rigid discs on the tissue exposed to negative pressure with regard to tissue pressure and microvascular blood flow. Peripheral wounds were created on the backs of eight pigs. The pressure and microvascular blood flow in the wound bed were measured when NPWT was applied. The wound was filled with foam, and rigid discs of different designs were inserted between the wound bed and the foam. The discs were created with or without channels (to accommodate exposed sensitive structures such as blood vessels and nerves), perforations, or a porous dressing that covered the underside of the discs (to facilitate pressure transduction and fluid evacuation). When comparing the results for pressure transduction to the wound bed, no significant differences were found using different discs covered with dressing, whereas pressure transduction was lower with bare discs. Microvascular blood flow in the wound bed decreased by $49 \pm 7\%$ when NPWT was applied to control wounds. The reduction in blood flow was less in the presence of a protective disc (e.g., $-6 \pm 5\%$ for a dressing-covered, perforated disc, $p = 0.006$). In conclusion, NPWT causes hypoperfusion of superficial tissue in the wound bed. The insertion of a rigid barrier counteracts this effect. The placement of a rigid disc over exposed blood vessels or nerves may protect these structures from rupture and damage.

INTRODUCTION

There are increasing numbers of reports of deaths and serious complications associated with the use of negative pressure wound therapy (NPWT).¹⁻³ Bleeding is the most serious complication, mainly occurring in patients with exposed blood vessels or vascular grafts (such as femoral and femoral-popliteal grafts), in sternal and groin wounds, in patients receiving anticoagulant therapy, and during the removal of dressings adhered to or imbedded in the tissue.⁴ The application of negative pressure treatment to exposed nerves and blood vessels is currently contraindicated because of the risk of damage. These tissues are, however, often subject to negative pressure due to the lack of alternative, effective treatments. In November 2009, the Food and Drug Administration filed an alert on serious complications associated with NPWT

systems,⁴ and the importance of protecting exposed organs and sensitive tissue has also been emphasized in the international scientific literature.⁵⁻⁸

Heart rupture, bypass graft bleeding, and death are devastating complications of NPWT, the incidence being 4-7% for patients treated with NPWT for mediastinitis after cardiac surgery.⁵⁻⁹ We have previously used magnetic resonance imaging in pigs to describe the reason for heart rupture during NPWT.¹⁰ The heart was shown to be sucked up toward the thoracic wall and when the right ventricle bulged into the space between the sharp sternal edges, these protruded into the anterior surface of the heart causing rupture.¹⁰ These events were not prevented by the insertion of soft, nonadhesive wound contact layers, whereas the insertion of a rigid disc between the anterior part of the heart and the inside of the thoracic wall was successful in offering protection.¹⁰⁻¹²

Yet another theory regarding the mechanisms responsible for heart rupture in conjunction with NPWT is that adhesions between the thin-walled right ventricle and the sternum are exposed to shearing forces when NPWT is applied.¹³ However, this problem can be remedied by freeing the sternal edges from adhesions that have been formed following surgery. Furthermore, a rigid disc has also been successful in preventing lung rupture.¹²

NPWT is also known to cause rupture of blood vessels and subsequent bleeding complications in peripheral wounds. The reason for this may be the negative pressure-induced mechanical deformation and hypoperfusion that result in damage and tears of the blood vessel walls. NPWT mechanically deforms the wound edges^{14,15} and alters microvascular blood flow around the wound.^{16–20} We hypothesized that the placement of a rigid disc that is able to withstand the forces of negative pressure over the wound bed could reduce blood flow changes and mechanical deformation, thereby protecting blood vessels and nerves that are exposed during NPWT. The aim of the present study was thus to examine the effect of NPWT on wound bed pressure and microvascular blood flow when rigid barrier discs of different designs were inserted over the wound bed (under the foam wound filler).

MATERIALS AND METHODS

Animals

Eight healthy domestic pigs of both sexes, with a mean body weight of 70 kg, were used in the study. All of the animals were fasted overnight with free access to water. The experimental protocol for this study was approved by the Ethics Committee for Animal Research, Lund University, Sweden. All animals received humane care in compliance with the European Convention on Animal Care.

Anesthesia

An intramuscular injection of xylazine (Rompun® vet. 20 mg/mL; Bayer AG, Leverkusen, Germany; 2 mg/kg) mixed with ketamine (Ketaminol® vet. 100 mg/mL; Farmaceutici Gellini SpA, Aprilia, Italy; 20 mg/kg) was used for premedication. Intravenous catheters were inserted into the auricular veins of both ears. Anesthesia was then induced with intravenous sodium thiopental (Pentothal®; Abbott Scandinavia, Stockholm, Sweden; 10–12 mg/kg) and maintained with a continuous infusion of fentanyl (Leptanal®; Lilly, Suresnes, France; ~3.5 µg/kg/hour) in Ringer's acetate or buffered 2.5% glucose (250–500 mL/hour) in combination with sodium thiopental (~400 mg/hour), delivered via an infusion pump (Compact Perfusor; Braun, Melsungen, Germany). After orotracheal intubation using a 7.0-mm-diameter cuffed endotracheal tube, the pig was connected to a rebreathing circuit (Servo 900C; Siemens-Elema AB, Solna, Sweden), and its lungs ventilated mechanically in the volume-controlled mode (65% N₂O, 35% O₂). Ventilatory settings were identical for all animals (respiratory rate, 15 breaths/minute; minute ventilation, 10 L/minute). A positive end-expiratory pressure of 5 cmH₂O was applied. A Foley catheter was inserted into the urinary bladder through a suprapubic cystostomy. The animals remained anesthetized during the entire experiment.

Upon completion of the experiment, a lethal dose of potassium chloride was administered intravenously.

Wound treatment

The animals were placed in the prone position. Six circular wounds, 6 cm in diameter and extending into muscle tissue, were created on each pig's back. Open-pore polyurethane foam was used as wound filler. A drain was connected to the vacuum source. The wound was then sealed with a transparent adhesive drape. After preparation of the wounds with NPWT dressings, the blood flow at the wound edges was allowed to stabilize for 1 hour. Negative pressure (~80 mmHg) was then applied using a custom-built vacuum source.

The effects of inserting different rigid discs between the wound bed and the foam wound filler were investigated. The barrier discs were circular in shape, 6 cm in diameter and 1 mm thin. They were made of clear polyurethane plastic and rigid enough to withstand the forces of the negative pressure. The discs were created with or without 5-mm-wide channels (to accommodate exposed sensitive structures such as blood vessels and nerves), perforations (pore size 2 mm), or a porous dressing that covered the underside of the discs (to facilitate pressure transduction and fluid evacuation). The perforations were distributed evenly across the surface of the discs with 5-mm intervals. All of the disc designs were used in each individual wound. The various combinations of discs and dressings are shown in Figure 1.

Wound bed pressure

The negative pressure on the wound bed, underneath the wound filler, was measured using two different techniques: four saline-filled pressure catheters connected to a custom-built pressure gauge and four intracranial tissue pressure microsensors (Codman ICP monitoring system; Codman/Johnson and Johnson Professional Inc., Raynham, MA). The saline-filled pressure catheter with the custom-built pressure gauge showed similar results as the intracranial tissue pressure microsensors. The tips of two saline-filled pressure catheters and two intracranial tissue pressure microsensors were sutured to the bottom of the wound at a position that allowed measurement of the pressure under a channel when using discs with channels, while the other catheters were sutured between the channels. The pressure, expressed as the mean value of the data from all of the eight probes, was recorded before and after the application of negative pressure.

Microvascular blood flow

Microvascular blood flow was measured by laser Doppler velocimetry, which allows the blood flow to be measured continuously. A four-channel Perimed PF5010 LDPM unit (Perimed, Stockholm, Sweden) was used. Four laser Doppler filament probes (Probe 418-1; Perimed) were inserted 0.5 cm into the superficial wound bed tissue, a position where blood flow is well known to be reduced by NPWT.^{19,21,22} When using discs with channels, the probes were placed at a position that allowed measurement of the blood flow directly under the channel. Laser Doppler recordings are continuous. To minimize the risk of measuring artifacts, the positions of the laser

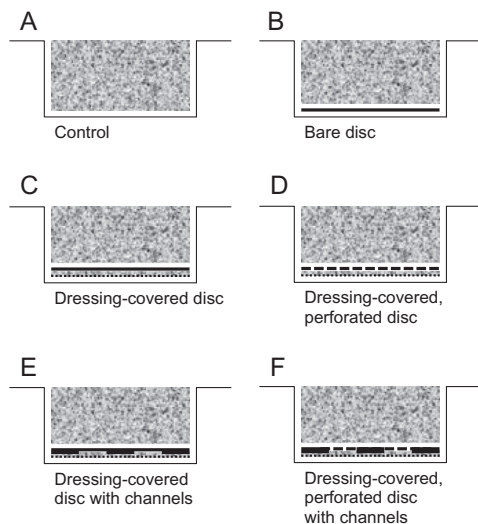


Figure 1. Schematic illustration showing a cross section of a wound filled with (A) only foam (control), (B) a bare disc (not covered with dressing), (C) a dressing-covered disc, (D) a dressing-covered, perforated disc, (E) a dressing-covered disc with channels, and (F) a dressing-covered, perforated disc with channels.

Doppler probes were adjusted after the application of negative pressure until they represented an area of hypoperfusion. Blood perfusion values were measured after reaching steady state, which normally occurred after 1 minute. Laser Doppler recordings were then performed before and after the application of -80 mmHg. The results are recorded as arbitrary perfusion units (PU) and are presented here as a percentage of the baseline values (before application of negative pressure), calculated as means of the four measurements that were made in every wound.

Limitations

In the present study, the short-term effects on wound bed pressure and microvascular blood flow during NPWT with a rigid barrier were examined. In this acute wound model, the wound fluid is of low viscosity and easily removable by suction. A chronic wound is probably more prone to wound fluid stagnation because wound fluid becomes more viscous with time, blood coagulates, and adherences that hinder wound fluid removal may be formed. The use of a perforated disc may therefore be of special importance in the clinical setting.

We only used discs with the exact same size as the wound. However, in clinical practice, the rigid barrier only needs to be placed over sensitive tissue structures. It cannot be deduced from the present study how a disc only the half or the fifth of the size of the wound bed will perform. It is probable that

mechanical deformation of the wound bed will only take place where there is not a rigid disc. It is important to maintain the largest possible macrodeformation in order not to interfere with the beneficial treatment effects, but still protect exposed vessels and nerves. Hopefully, this can be achieved with a relatively small disc that covers only the fragile structures and their close surroundings.

We believe that the material in the closest proximity to the wound bed should consist of either foam or gauze, as these materials have shown to enhance the formation of granulation tissue in several studies. We also believe that a layer of either foam or gauze is important to facilitate transportation of fluid from underneath the disc and out of the wound cavity.

However, the exclusion of non-dressing-covered discs supplied with perforations or channels limits our ability to draw any greater conclusions regarding the possible differences between dressing-covered and non-dressing-covered discs. This would require further studies.

Laser Doppler velocimetry was used for perfusion measurements. This methodology has been subject to much debate. Indeed, it is sensitive for all kinds of movement and has a small sampling area, and therefore the small volume of tissue investigated may have a blood flow higher or lower than the immediate surrounding area owing to variation in vascular density. However, the advantage of continuous measurements makes it a valuable tool. It lacks the drawbacks of alternative methods, such as the need for a direct line of sight and low resolution. Thus, the overwhelming majority of research conducted on perfusion changes due to NPWT have used laser Doppler. It is imaginable that the rigid disc affects the laser Doppler readings, but because it is possible to monitor the blood flow changes on-screen any interference may easily be detected.

It should be noted that until further studies on humans have been performed, use of the discs in the clinical setting cannot be encouraged.

Calculations and statistics

Calculations and statistical analysis were performed using GraphPad 5.0 software (San Diego, CA). Blood flow results are presented as the percent change upon negative pressure application, compared to the baseline values. Results are presented as mean of eight experiments \pm the standard error of the mean. Statistical analysis was performed using the Mann-Whitney test when comparing two groups, and the Kruskal-Wallis test with Dunn's test for multiple comparisons when comparing three groups or more. $p < 0.05$ was considered statistically significant.

RESULTS

Pressure on the wound bed

We found no significant difference in wound bed pressure when comparing dressing-covered discs with control wound (filled only with foam).

Typical values were -56 ± 6 mmHg in control wounds and -55 ± 6 mmHg for dressing-covered, perforated discs, $p > 0.30$ (Figure 2). Pressure transduction to the wound bed was similar for all dressing-covered discs studied, i.e., both

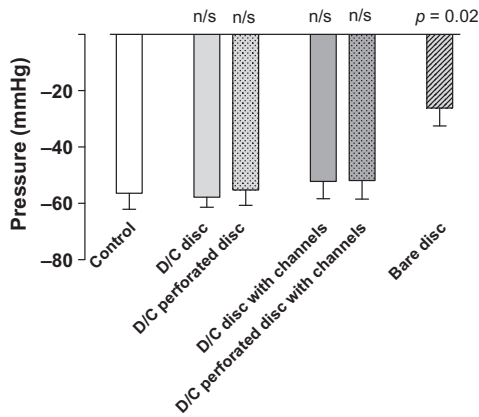


Figure 2. Wound bed pressure during negative pressure wound therapy at -80 mmHg measured using intracranial tissue pressure microsensors sutured to the bottom of the wound. Measurements were performed in the presence of foam only (control), and under the various kinds of discs (D/C indicates that the disc was covered with dressing). The bars illustrate means \pm standard error of the mean ($n = 8$). Note that the only significant change in pressure transfer is from the “bare disc.” The wound bed pressure was similar in the control wound and those with dressing-covered discs. n/s, not significant.

perforated and nonperforated discs, with and without channels (Figure 2; $p > 0.30$). Furthermore, for the discs with channels, the pressure was similar under and between the channels. When using a rigid disc without dressing, the pressure transfer to the wound bed was impaired (-26 ± 6 mmHg, $p = 0.013$ compared with control).

Wound bed microvascular blood flow

When NPWT was applied, blood flow in the wound bed decreased by $49 \pm 7\%$ in control wounds. When a disc was inserted, the decrease in blood flow was less pronounced, which is shown in Figure 3. The presence of the various dressing-covered discs (perforated and nonperforated discs with and without channels) resulted in similar reductions in blood flow ($p > 0.30$), whereas results for the bare disc deviated showing both hyper- and hypoperfusion ($2 \pm 21\%$, $p = 0.022$ compared with control).

DISCUSSION

When NPWT is applied to a wound with exposed blood vessels or vascular grafts, there is a risk of damage to these delicate structures. This is probably due to the mechanical deformation and/or hypoperfusion induced by NPWT, but it could also be due to infection or inflammation induced by the interface material. The insertion of a rigid barrier has been

proposed as a protective measure against mechanical deformation. In the present study, we examined the effect of NPWT on wound bed pressure and microvascular blood flow when different types of rigid barrier discs had been inserted between the wound bed and the wound filler.

Pressure delivery to the wound bed

The rigid discs were covered on the underside, with a thin layer of open-pore foam and a perforated, soft, nonadherent wound contact layer. The reason for this covering was to allow the negative pressure to be distributed evenly over the wound surface and to allow the removal of wound fluid from under the disc. Our results show that this dressing covering on the underside of the disc allowed pressure transfer to the wound bed that was not significantly different compared with the control wound, where only a foam wound filler was used.

The wounds in the present study were 6 cm in diameter. It cannot be deduced whether the same results regarding pressure transduction to the wound bed would be obtained if a larger rigid disc would be used (as would probably be the case for a larger wound).

Microvascular blood flow in the wound bed

For several years, there have been discussions regarding if the decrease in blood flow during NPWT is desirable or not.^{18–20,22,23} On the one hand, a decrease in blood flow may

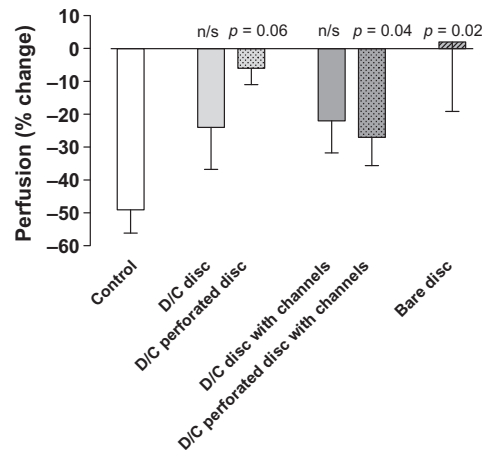


Figure 3. Microvascular blood flow in the superficial tissue of the wound bed, upon the application of negative pressure wound therapy at -80 mmHg. Measurements were performed in the presence of foam only (control), and under the various kinds of discs (D/C indicates that the disc was covered with dressing). Results are expressed as the percent change compared to the baseline, and the bars represent means \pm standard error of the mean ($n = 8$). n/s, not significant.

be desirable as wound healing factors released in response to hypoperfusion are strong stimulators of angiogenesis and granulation tissue formation. Also, compression of the wound wall may tamponade superficial bleeding during surgical procedures.²⁴ On the other hand, in poorly vascularized wounds (e.g., superficial flaps or wounds in diabetics), hypoperfusion may cause critical ischemia. Similarly, in wounds with exposed delicate structures, such as blood vessels or nerves, hypoperfusion may cause necrosis, rupture of blood vessels, or the failure of graft anastomosis with ensuing bleeding complications. In the present study, we show that the insertion of a rigid disc between the wound bed and the foam wound filler reduces the hypoperfusion caused by NPWT, thereby facilitating blood flow. This may offer means of protecting delicate structures from hypoperfusion and ischemia when exposed in a wound requiring NPWT.

NPWT causes contraction and mechanical deformation of the wound bed tissue.^{14,15} Macromechanical effects (such as wound contraction) are typically distinguished from micro-mechanical effects (which are due to the interaction of tissue and dressing at a microscopic level).²⁵ The mechanical stress on the wound bed may cause tears and damage to any exposed sensitive structure, such as blood vessels or nerves. In the present study, we found that the blood flow reduction was less pronounced when a rigid disc protected the wound bed. This may be the result of mechanical shearing forces on the wound bed being protected.

The hypoperfusion effect by the rigid discs was not affected by the presence of perforations. The mechanism underlying a reduction in hypoperfusion without a reduction in pressure cannot be deduced from the present study and can only be speculated upon. The mechanism by which NPWT decreases blood flow in superficial tissue has recently been pinpointed. The tissue pressure, 1 cm from the wound edge, has been shown to increase upon application of negative pressure,^{22,23} the reason being that the wound filler is pushed into the tissue by the negative pressure. This "pushing" effect is probably not affected by the disc having perforations or not.

The impact of the disc design

Presumably, as the size of the disc increases, the importance of perforations in the disc in allowing pressure transmission to, and fluid removal from, the wound bed increases. Furthermore, in a clinical situation, there may be wound fluid stagnation in a wound for several reasons, e.g., increased viscosity with time, coagulated blood, and the formation of adherences that hinder wound fluid removal. The removal of wound debris and exudate is of great importance both in an infected wound and when there is a risk for creation of an encapsulated infection. The discs used in the present study were rather small. Larger discs probably need perforations for adequate fluid removal, thus minimizing the risk of fluid stagnation beneath the discs. Nonperforated discs were included in the study for scientific reasons only. For the reasons stated, we believe that only perforated discs will be used clinically in the future (although this is solely speculative).

The tissue surrounding an NPWT-treated wound affects the mechanical effects of the therapy. Dense tissue, such as piskin, will resist compression. Muscle tissue, on the other hand, is less dense and will be compressed to a greater extent. No data exist regarding the correlation between tissue type and the magnitude of micro- and macrodeformation, but it

seems reasonable that the tissue type may affect the wound-healing outcome.

Likewise, the mechanical forces are different in a soft peripheral wound compared with that in a sternotomy wound. In a study by Malmjö et al.,¹⁰ four layers of paraffin gauze failed to prevent the deformation of the heart upon application of NPWT, whereas a rigid disc prevented shape changes in the heart and maintained separation between the heart and the sharp sternal edges. This has implications for the therapy, and it may be speculated if gauze alone may be sufficient for protection in smaller wounds.

Limitations of the Study

Two out of four dressing-covered discs created an alleviation of the hypoperfusion compared with control wound. However, when examining the effect of the dressing-covered disc with channels and perforations, as well as the dressing-covered disc without perforations, there was no significant difference compared with control. The reason for this cannot be deduced from the present study. It may be a result of the difference in disc design, where the channels and/or perforations affect the pressure transduction, which then also affects the blood flow in the wound bed.

Another explanation for the nonsignificant results is that it may be a type 2 error and larger sample size may be one way to explore this possibility.

Conclusions and clinical implications

A rigid barrier may be a beneficial protective measure in wounds with exposed structures (blood vessels, vascular grafts, nerves, etc.) that are at risk for damage when NPWT is applied. We show that the placement of a rigid disc over the wound bed counteracts hypoperfusion in the superficial wound bed tissue, perhaps as a result of the prevention of mechanical stress and deformation of the wound bed. The risk of ischemia is thereby reduced. In clinical practice, it should only be necessary to place a rigid barrier over structures needing protection. Protective discs may not be necessary in all wounds, and it should be remembered that the biological effects of NPWT, which are beneficial in accelerating wound healing, are altered in the presence of a rigid disc.

ACKNOWLEDGMENTS

This study was supported by the Swedish Medical Research Council, Lund University Faculty of Medicine, the Swedish Government Grant for Clinical Research, Lund University Hospital Research Grants, the Swedish Medical Association, the Royal Physiographic Society in Lund, the Åke Wiberg Foundation, the Anders Otto Swärd Foundation/Ulrika Eklund Foundation, the Magn Bergvall Foundation, the Crafoord Foundation, the Anna-Lisa and Sven-Erik Nilsson Foundation, the Jeansson Foundation, the Swedish Heart-Lung Foundation, Anna and Edvin Berger's Foundation, the Märta Lundqvist Foundation, and the Lars Hierta Memorial Foundation.

The authors declare no conflicts of interest.

REFERENCES

1. Bapat V, El-Muttardi N, Young C, Venn G, Roxburgh J. Experience with vacuum-assisted closure of sternal wound infections

- following cardiac surgery and evaluation of chronic complications associated with its use. *J Card Surg* 2008; 23: 227–33.
2. Ennker IC, Malkoc A, Pietrowski D, Vogt PM, Ennker J, Albert A. The concept of negative pressure wound therapy (NPWT) after poststernotomy mediastinitis—a single center experience with 54 patients. *J Cardiothorac Surg* 2009; 4: 5–12.
 3. Sartipy U, Lockowandt U, Gabel J, Jidéus L, Dellgren G. Cardiac rupture during vacuum-assisted closure therapy. *Ann Thorac Surg* 2006; 82: 1110–11.
 4. Shuren JE. *FDA preliminary public health notification: serious complications associated with negative pressure wound therapy systems*. November 13 ed: Food and Drug Administration, 2009.
 5. Gustafsson RI, Sjögren J, Ingemansson R. Deep sternal wound infection: a sternal-sparing technique with vacuum-assisted closure therapy. *Ann Thorac Surg* 2003; 76: 2048–53; discussion 2053.
 6. Hersh RE, Jack JM, Dahman MI, Morgan RF, Drake DB. The vacuum-assisted closure device as a bridge to sternal wound closure. *Ann Plast Surg* 2001; 46: 250–4.
 7. Malmström M, Ingemansson R, Sjögren J. Mechanisms governing the effects of vacuum-assisted closure in cardiac surgery. *Plast Reconstr Surg* 2007; 120: 1266–75.
 8. Sjögren J, Malmström M, Gustafsson R, Ingemansson R. Poststernotomy mediastinitis: a review of conventional surgical treatments, vacuum-assisted closure therapy and presentation of the Lund University Hospital mediastinitis algorithm. *Eur J Cardiothorac Surg* 2006; 30: 898–905.
 9. Petzina R, Malmström M, Stamm C, Hetzer R. Major complications during negative pressure wound therapy in poststernotomy mediastinitis following cardiac surgery. *J Thorac Cardiovasc Surg* 2010; 140: 1133–6.
 10. Malmström M, Petzina R, Ugander M, Engblom H, Torbrand C, Mokhtari A, Hetzer R, Arheden H, Ingemansson R. Preventing heart injury during negative pressure wound therapy in cardiac surgery: assessment using real-time magnetic resonance imaging. *J Thorac Cardiovasc Surg* 2009; 138: 712–17.
 11. *A novel rigid barrier device for protection of the heart and lungs during NPWT: preclinical studies in pigs and proof of concept in humans*. Symposium on Advanced Wound Care 2012, Atlanta, GA, April 19–22.
 12. Lindstedt S, Ingemansson R, Malmström M. A rigid barrier between the heart and sternum protects the heart and lungs against rupture during negative pressure wound therapy. *J Cardiothorac Surg* 2011; 6: 90–4.
 13. Khojenezhad A, Abbas G, Palazzo RS, Graver LM. Spontaneous right ventricular disruption following treatment of sternal infection. *J Card Surg* 2004; 19: 74–8.
 14. Borgquist O, Ingemansson R, Malmström M. The influence of low and high pressure levels during negative pressure wound therapy on wound contraction and fluid evacuation. *Plast Reconstr Surg* 2010; 127: 551–9.
 15. Malmström M, Ingemansson R, Martin R, Huddleston E. Negative-pressure wound therapy using gauze or open-cell polyurethane foam: similar early effects on pressure transduction and tissue contraction in an experimental porcine wound model. *Wound Rep Reg* 2009; 17: 200–5.
 16. Borgquist O, Ingemansson R, Malmström M. Wound edge microvascular blood flow during negative-pressure wound therapy: examining the effects of pressures from –10 to –175 mmHg. *Plast Reconstr Surg* 2010; 125: 502–9.
 17. Kairinos N, Solomons M, Hudson DA. The paradox of negative pressure wound therapy—in vitro studies. *J Plast Reconstr Aesthet Surg* 2010; 63: 174–9.
 18. Kairinos N, Solomons M, Hudson DA. Negative-pressure wound therapy I: the paradox of negative-pressure wound therapy. *Plast Reconstr Surg* 2009; 123: 589–98; discussion 599–600.
 19. Wackenfors A, Gustafsson R, Sjögren J, Algotsson L, Ingemansson R, Malmström M. Blood flow responses in the peristernal thoracic wall during vacuum-assisted closure therapy. *Ann Thorac Surg* 2005; 79: 1724–30; discussion 1730–1.
 20. Wackenfors A, Sjögren J, Gustafsson R, Algotsson L, Ingemansson R, Malmström M. Effects of vacuum-assisted closure therapy on inguinal wound edge microvascular blood flow. *Wound Rep Reg* 2004; 12: 600–6.
 21. Wackenfors A, Sjögren J, Algotsson L, Gustafsson R, Ingemansson R, Malmström M. The effect of vacuum-assisted closure therapy on the pig femoral artery vasomotor responses. *Wound Rep Reg* 2004; 12: 244–51.
 22. Kairinos N, Voogd AM, Botha PH, Kotze T, Kahn D, Hudson DA, Solomons M. Negative-pressure wound therapy II: negative-pressure wound therapy and increased perfusion. Just an illusion? *Plast Reconstr Surg* 2009; 123: 601–12.
 23. Kairinos N, Solomons M, Hudson DA. The paradox of negative pressure wound therapy—in vitro studies. *J Plast Reconstr Aesthet Surg* 2008; 63: 174–9.
 24. Sjögren J, Gustafsson R, Koul B, Ingemansson R. Selective mediastinal tamponade to control coagulopathic bleeding. *Ann Thorac Surg* 2003; 75: 1311–13.
 25. Morykwas MJ, Simpson J, Punger K, Argenta A, Kremers L, Argenta J. Vacuum-assisted closure: state of basic research and physiologic foundation. *Plast Reconstr Surg* 2006; 117 (7 Suppl.): 121S–6S.

Paper V

The influence on wound contraction and fluid evacuation of a rigid disc inserted to protect exposed organs during negative pressure wound therapy

Erik Anesäter, Markus Roupé, Peter Robertsson, Ola Borgquist, Christian Torbrand, Richard Ingemansson, Sandra Lindstedt, Malin Malmjö

Anesäter E, Roupé M, Robertsson P, Borgquist O, Torbrand C, Ingemansson R, Lindstedt S, Malmjö M. The influence on wound contraction and fluid evacuation of a rigid disc inserted to protect exposed organs during negative pressure wound therapy. *Int Wound J* 2011; 8:393–399

ABSTRACT

The use of a rigid disc as a barrier between the wound bed and the wound filler during negative pressure wound therapy (NPWT) has been suggested to prevent damage to exposed organs. However, it is important to determine that the effects of NPWT, such as wound contraction and fluid removal, are maintained during treatment despite the use of a barrier. This study was performed to examine the effect of NPWT on wound contraction and fluid evacuation in the presence of a rigid disc. Peripheral wounds were created on the backs of eight pigs. The wounds were filled with foam, and rigid discs of different designs were inserted between the wound bed and the foam. Wound contraction and fluid evacuation were measured after application of continuous NPWT at -80 mmHg. Wound contraction was similar in the presence and the absence of a rigid disc ($84 \pm 4\%$ and $83 \pm 3\%$, respectively, compared with baseline). Furthermore, the rigid disc did not affect wound fluid removal compared with ordinary NPWT (e.g. after 120 seconds, 71 ± 4 ml was removed in the presence and 73 ± 3 ml was removed in the absence of a disc). This study shows that a rigid barrier may be placed under the wound filler to protect exposed structures during NPWT without affecting wound contraction and fluid removal, which are two crucial features of NPWT.

Key words: Fluid removal • Negative pressure wound therapy • Protective disc • Wound contraction • Wound healing

Authors: E Anesäter, MD, Department of Ophthalmology, Lund University and Skåne University Hospital, Lund, Sweden; M Roupé, MSc, PhD, Department of Ophthalmology, Lund University, Lund, Sweden; P Robertsson, BSN, Department of Ophthalmology, Lund University, Lund, Sweden; O Borgquist, MD, Department of Anesthesiology and Intensive Care, Lund University and Skåne University Hospital, Lund, Sweden, Department of Ophthalmology, Lund University and Skåne University Hospital, Lund, Sweden; C Torbrand, MD, Department of Ophthalmology, Lund University and Skåne University Hospital, Lund, Sweden, Department of Cardiothoracic Surgery, Lund University and Skåne University Hospital, Lund, Sweden; R Ingemansson, MD, PhD, Department of Cardiothoracic Surgery, Lund University and Skåne University Hospital, Lund, Sweden; S Lindstedt, MD, PhD, Department of Cardiothoracic Surgery, Lund University and Skåne University Hospital, Lund, Sweden; M Malmjö, MD, PhD, Department of Ophthalmology, Lund University and Skåne University Hospital, Lund, Sweden

Address for correspondence: Associate Professor M Malmjö, MD, PhD, BMC A13, SE-221 84 Lund, Sweden

E-mail: malin.malmjso@med.lu.se

Key Points

- as wound contraction and fluid removal are crucial attributes of NPWT in accelerating wound healing, this study was performed to investigate if these features are affected by the presence of a rigid barrier inserted to protect underlying tissue
- eight healthy domestic pigs of both sexes, with a mean body weight of 70 kg, were used in the study
- in addition, to investigate if pressure transduction and fluid evacuation in the wounds could be facilitated, perforations in the discs or a porous dressing that covered the underside of the discs were also tested

INTRODUCTION

One of the mechanisms by which negative pressure wound therapy (NPWT) is believed to promote wound healing is by inducing mechanical deformation of the wound edge tissue (1–3). The mechanical effects exerted by NPWT on the wound bed are thought to result in shearing forces at the wound–dressing interface that affect the cytoskeleton (4) and initiate a cascade of biological effects, including stimulation of angiogenesis, changes in blood flow to the wound margins (5,6), promotion of granulation tissue formation and wound healing (2). Indeed, it has been shown that early changes in the size of a wound are correlated to the rate of healing (7).

The removal of exudate is also thought to promote wound healing during NPWT (1–3). The exudate in a chronic wound may impede the wound healing process as it contains elevated levels of inflammatory cytokines and proteolytic enzymes (8). NPWT allows continuous removal of wound fluid, thus preventing the accumulation of inhibitory factors (9) and exerting a positive influence on the healing process.

There are increasing numbers of reports on deaths and serious complications associated with the use of NPWT (10–12). Bleeding is one of the serious complications that may arise, occurring in patients with exposed blood vessels or vascular grafts (such as femoral and femoral–popliteal grafts), as well as in sternal and groin wounds (13,14). The application of negative pressure to nerves and blood vessels is currently contraindicated because of the risk of damage. These tissues are, however, often exposed to NPWT because of the lack of other effective treatments. In November 2009, the Federal Drug Administration filed an alert concerning this issue (13), and the importance of protecting exposed organs and sensitive tissues has also been emphasised in the international scientific literature (15–18). The insertion of a rigid barrier over organs and other sensitive structures exposed to NPWT has been suggested as a protective measure (14,19).

As wound contraction and fluid removal are crucial attributes of NPWT in accelerating wound healing, this study was performed to investigate if these features are affected by the presence of a rigid barrier inserted to protect underlying tissue.

MATERIALS AND METHODS

Animals

Eight healthy domestic pigs of both sexes, with a mean body weight of 70 kg, were used in the study. The animals were fasted overnight with free access to water. The experimental protocol for this study was approved by the Ethics Committee for Animal Research, Lund University, Sweden. All animals received humane care in compliance with the European Convention on Animal Care. Anaesthesia was administered as described previously (20).

Wound treatment

Circular wounds, 10 cm in diameter and 4 cm deep (below the level of the skin, extending into subcutaneous tissue), were created on the pig's back. Open-pore polyurethane foam (VAC[®] black GranuFoam[®], KCI, San Antonio, TX) was used as wound filler. The effects on fluid removal and wound contraction when inserting rigid discs of different types between the wound bed and the wound filler were investigated. The discs were 6 cm in diameter, millimeter-thin, made of plastic and rigid enough to withstand the forces of the negative pressure. To test if the discs could accommodate exposed sensitive structures (such as blood vessels and nerves), discs with or without channels (i.e. grooves in the disc) were used. In addition, to investigate if pressure transduction and fluid evacuation in the wounds could be facilitated, perforations in the discs or a porous dressing that covered the underside of the discs were also tested.

After placing a disc and the foam in the wound, the wound was sealed with a transparent, adhesive drape. A flat Jackson-Pratt drain was connected to the vacuum source and continuous NPWT at –80 mmHg was applied.

Wound contraction and fluid removal

Distances between wound edges were measured in two orthogonal directions and the wound surface area was calculated. Measurements were performed before and after the application of NPWT at –80 mmHg. The degree of wound contraction is expressed as a percentage of the original area, before pressure application.

Physiological saline solution (100 ml) was infused through the NPWT dressing-sealed wound using a needle attached to a syringe.

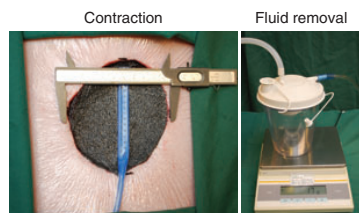


Figure 1. Photos of the experimental setup used to measure wound contraction (left) and fluid removal (right). The distance between the wound edges was measured in two orthogonal directions, and the wound surface area was calculated before and after the application of negative pressure. Contraction is expressed as a percentage of the initial wound surface area. In the fluid removal experiments, 100 ml saline was infused under the negative pressure wound therapy (NPWT) dressing using a needle attached to a syringe. Negative pressure was then applied, and the amount of fluid evacuated into a canister was weighed every 5 seconds for 2 minutes.

The needle was inserted through the skin a few centimetres away from the wound edge and entered the wound from the side, with the tip placed underneath both the NPWT dressing and the rigid disc. Negative pressure at -80 mmHg was then applied and maintained for the whole duration of the measurements. Fluid was evacuated into a canister placed on a scale. The amount of fluid evacuated by NPWT was weighed every 5 seconds for the next 2 minutes. The experimental setup is depicted in Figure 1 and has been described previously (20).

Calculations and statistics

Calculations were performed using GraphPad 5.0 software (San Diego, CA). Statistical analysis was performed using the Mann-Whitney test when comparing two groups and the Kruskal-Wallis test with Dunn's post-test for multiple comparisons when comparing three groups or more. Significance was defined as $P < 0.05$. All differences referred to in the text are statistically significant. Results are presented as means of eight experiments \pm the standard error of the mean (SEM).

RESULTS

Wound contraction

The degree of wound contraction was similar with and without the rigid discs. For example, the wound surface area decreased to $83 \pm 3\%$

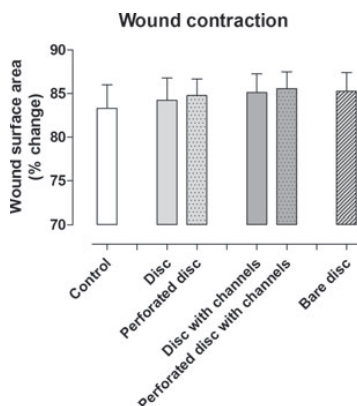


Figure 2. Wound contraction during negative pressure wound therapy (NPWT) at -80 mmHg in a porcine peripheral wound model. Measurements were performed in the presence of foam only (control), and with various kinds of protective discs, as described in the text. The change in wound surface area is expressed as a percentage of the initial area (mean \pm SEM of eight experiments).

of the initial size when negative pressure was applied using only foam (control) and to $84 \pm 4\%$ in the presence of a disc (in this case a dressing-covered, perforated disc, $P = \text{n.s.}$). No difference was seen between the various discs tested. See Figure 2 for detailed results.

Fluid drainage

The fluid that had been injected in the wound was evacuated upon the application of negative pressure. The amount of fluid that was removed increased gradually during the first 30 seconds and then levelled off. Both the rate of fluid removal and the total volume of fluid removed were similar in the absence and presence of the rigid discs. For example, 73 ± 3 ml had been removed after 2 minutes of treatment when using only foam (control) and 71 ± 4 ml had been removed in the presence of the disc (in this case a dressing-covered, perforated disc, $P = \text{n.s.}$). There was no difference between the various discs tested. See Figure 3 for detailed results.

DISCUSSION

The use of a rigid barrier between the wound bed and the NPWT wound filler has been suggested as a protective measure to reduce

Key Points

- the degree of wound contraction, that is, macro-deformation, was not affected by the presence of a protective disc
- this is an important finding as wound contraction is believed to be a fundamental effect of NPWT
- growth factor pathways are stimulated, which results in mitosis and the production of new tissue
- It was found that the rate of fluid removal and the total volume removed after 2 minutes were similar regardless if a rigid barrier disc was present or not
- it is obvious that some wound fluid will remain in the wound regardless of the treatment
- the rate of wound fluid removal is of importance as the removal of wound exudate is believed to be a main feature of NPWT, helping to accelerate wound healing

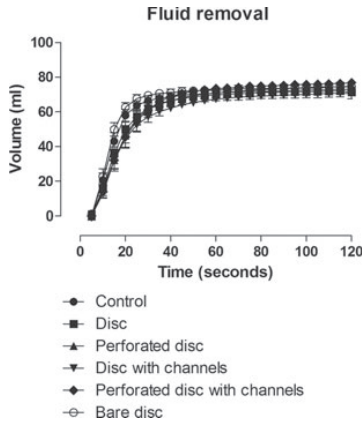


Figure 3. Wound fluid removal during negative pressure wound therapy (NPWT). Measurements were performed in the presence of foam only (control), and with various kinds of protective discs, as described in the text. 100 ml saline was infused into the wound. A continuous negative pressure of -80 mmHg was then applied and the amount of fluid evacuated into the canister was measured using a scale. The results are presented as mean values \pm SEM of eight experiments.

the risk of damage to exposed structures in the wound bed because of mechanical shearing forces. Wound contraction and fluid removal are crucial attributes of NPWT, leading to the acceleration of wound healing, and this study was performed to examine the effect on these mechanisms in the presence of a rigid disc.

Mechanical effects of NPWT

It is widely believed that one of the fundamental effects of negative pressure delivery to the wound bed is the induction of mechanical deformation of the tissue. Macromechanical effects, such as wound contraction, are typically distinguished from micromechanical effects which are due to the interaction of tissue and dressing at a microscopic level (7). These actions are thought to result in a cascade of inter-related biological effects, including the promotion of periwound blood flow, removal of bacteria, and stimulation of granulation tissue formation, as originally defined in the works of Evans and Land (5) and Greene *et al.* (6) and reviewed in the study of Lavery *et al.* (7). The degree of wound contraction, that is, macro-deformation, was not affected by the

presence of a protective disc. This is an important finding as wound contraction is believed to be a fundamental effect of NPWT (21–23). This mechanical effect is believed to result in shearing forces at the wound–dressing interface that affect the cytoskeleton (4) and initiate a signalling cascade that ultimately leads to granulation tissue formation and wound healing. The cellular and molecular events that take place are not known in detail, but they are probably initiated by cell deformation and then result in changes in ion concentration and the permeability of ion channels, the release of second messengers, the stimulation of molecular pathways and changes in gene expression (24). Growth factor pathways are stimulated, which results in mitosis (25,26) and the production of new tissue (3).

Fluid removal

The reduction in wound fluid volume during NPWT in the presence of a rigid disc was also studied. Fluid was injected in the wound and the rate of removal upon application of negative pressure was examined. It was found that the rate of fluid removal and the total volume removed after 2 minutes were similar regardless if a rigid barrier disc was present or not. Likewise, pressure measurements performed in another study showed that the wound bed pressure was similar in control wounds (filled only with foam) and wounds in which discs had been placed over the wound bed (data not shown). All the infused fluid could not be removed from the wound, regardless of the disc type used. It is obvious that some wound fluid will remain in the wound regardless of the treatment. The rate of wound fluid removal is of importance as the removal of wound exudate is believed to be a main feature of NPWT, helping to accelerate wound healing. The importance of wound fluid removal has been emphasised in previous studies (1–3). Removal of exudate during NPWT greatly reduces the amount of non bound soluble factors (3). Chronic wound fluid is known to inhibit cell proliferation (27,28), and chronic inflammation is associated with a vicious cycle in which inflammatory cells secrete cytokines, which in turn attract more inflammatory cells (29). At the molecular level, this has been shown to be associated with an imbalance between the concentration of proteases (e.g. MMP-3,

MMP-9), protease inhibitors (e.g. TIMP-1) and pro-inflammatory cytokines (e.g. TNF- α , IL-1 β) (30–32). Scherer *et al.* (21) reported that pro-MMP levels were reduced during NPWT, as well as during a 10-day follow-up period. The level of pro-MMP-9 (and active MMP-9) has been shown to be an accurate prognostic indicator of subsequent healing when measured in venous ulcers (33).

The impact of the disc design

The reason for using perforated discs was to facilitate the removal of wound fluid and debris from underneath the disc. The non perforated discs were included in the study to examine if lateral fluid displacement takes place beneath the discs. In a clinical situation, there may be wound fluid stagnation in a wound for several reasons, for example, increased viscosity with time, coagulated blood, and the formation of adhesions that hinder wound fluid removal. The removal of wound debris and exudate is of great importance, both in an infected wound and when there is a risk for creation of an encapsulated infection. As discussed previously, the amount of wound fluid that was removed was similar regardless if the disc was perforated or not. However, the discs used in this study were rather small. Larger discs probably need perforations for adequate fluid removal, thus minimising the risk of fluid stagnation beneath the discs. We believe that only perforated discs will be used clinically in the future.

Clinical implications

The use of a protective disc can prevent complications such as tissue damage and vessel rupture. This study shows that the use of such a disc has no effect on wound contraction or the removal of exudate, both central features to wound healing during NPWT. For the clinician it is important to remember that when a disc is used to cover an exposed structure, such as a blood vessel, part of the wound will be in direct contact with the wound filler (as in ordinary NPWT) and part of the wound bed will be in contact only with the protective disc. The structure and properties of the material in direct contact with the wound bed determine the effects of NPWT on new tissue formation. The disc has a smooth structure, and we expect to see granulation tissue formation that is

similar to that in a wound bed covered with a non adherent wound contact layer (34,35), that is, less granulation tissue than in a wound bed that has been in direct contact with the wound filler (36). It is therefore important to use protective discs only when indicated, that is, when there is a need to protect exposed structures. It is also important to cover only the structures in need of protection, allowing as much of the wound bed as possible to be in contact with the filler.

Limitations

The risk that the introduction of a rigid biomaterial into a wound may create problems must be taken into account and minimised. Creating the rigid disc with flexible edges is one way to reduce the risk for visceral rupture. The use of a perforated disc, which allows fluid removal, is one way to minimise the risk for fluid stagnation and infection. In this study, the short-term effects on wound contraction and fluid evacuation during NPWT with a rigid barrier were examined. In this acute wound model, the wound fluid is of low viscosity and easily removable by suction. A chronic wound is probably more prone to wound fluid stagnation as wound fluid becomes more viscous with time, blood coagulates and adhesions that hinder wound fluid removal may be formed. The use of a perforated disc may therefore be of special importance in the clinical setting. An advantage with having perforations of the disc is to allow the transfer of negative pressure through the disc instead of around the edges of the disc, which otherwise may be a point of shear. Another limitation of the study is that the experiments did not test the device on top of major structures, that is, vessels. This is currently being examined in a preclinical study (not published).

Conclusions

There is a risk for damage of delicate structures, such as exposed blood vessels and vascular grafts, when NPWT is applied to a wound. The placement of a rigid disc over the wound bed offers protection. This study shows that both wound contraction and fluid removal are maintained in the presence of a rigid disc during NPWT, and thus these wound-healing features of NPWT are not affected by the presence of a protective disc.

Key Points

- the reason for using perforated discs was to facilitate the removal of wound fluid and debris from underneath the disc
- the use of a protective disc can prevent complications such as tissue damage and vessel rupture
- this study shows that the use of such a disc has no effect on wound contraction or the removal of exudate, both central features to wound healing during NPWT
- it is important to cover only the structures in need of protection, allowing as much of the wound bed as possible to be in contact with the filler
- this study shows that both wound contraction and fluid removal are maintained in the presence of a rigid disc during NPWT, and thus these wound healing features of NPWT are not affected by the presence of a protective disc

REFERENCES

- Argenta LC, Morykwas MJ. Vacuum-assisted closure: a new method for wound control and treatment: clinical experience. *Ann Plast Surg* 1997;38:563–76, discussion 577.
- Morykwas MJ, Argenta LC, Shelton-Brown EI, McGuirt W. Vacuum-assisted closure: a new method for wound control and treatment: animal studies and basic foundation. *Ann Plast Surg* 1997;38:553–62.
- Morykwas MJ, Simpson J, Pungler K, Argenta A, Kremers L, Argenta J. Vacuum-assisted closure: state of basic research and physiologic foundation. *Plast Reconstr Surg* 2006;117(7 Suppl):121S–6S.
- Saxena V, Hwang CW, Huang S, Eichbaum Q, Ingber D, Orgill DP. Vacuum-assisted closure: microdeformations of wounds and cell proliferation. *Plast Reconstr Surg* 2004;114:1086–96, discussion 1097–8.
- Evans D, Land L. Topical negative pressure for treating chronic wounds: a systematic review. *Br J Plast Surg* 2001;54:238–42.
- Greene AK, Puder M, Roy R, Arsenaault D, Kwei S, Moses MA, Orgill DP. Microdeformational wound therapy: effects on angiogenesis and matrix metalloproteinases in chronic wounds of 3 debilitated patients. *Ann Plastic Surg* 2006;56:418–22.
- Lavery LA, Barnes SA, Keith MS, Seaman JW, Armstrong DG. Prediction of healing for post-operative diabetic foot wounds based on early wound area progression. *Diabetes Care* 2008;31:26–9.
- Schultz GS, Sibbald RG, Falanga V, Ayello EA, Dowsett C, Harding K, Romanelli M, Stacey MC, Téot L, Vanscheidt W. Wound bed preparation: a systematic approach to wound management. *Wound Repair Regen* 2003;11 Suppl 1:S1–S28.
- Mouës CM, Van Toorenbergen AW, Heule F, Hop WC, Hovius SE. The role of topical negative pressure in wound repair: expression of biochemical markers in wound fluid during wound healing. *Wound Repair Regen* 2008;16:488–94.
- Bapat V, El-Muttardi N, Young C, Venn G, Roxburgh J. Experience with vacuum-assisted closure of sternal wound infections following cardiac surgery and evaluation of chronic complications associated with its use. *J Card Surg* 2008;23:227–33.
- Ennker IC, Malkoc A, Pietrowski D, Vogt PM, Ennker J, Albert A. The concept of negative pressure wound therapy (NPWT) after post-sternotomy mediastinitis – a single center experience with 54 patients. *J Cardiothorac Surg* 2009;4:5.
- Sartipy U, Lockowandt U, Gäbel J, Jideus L, Dellgren G. Cardiac rupture during vacuum-assisted closure therapy. *Ann Thorac Surg* 2006;82:1110–1.
- Sullivan N, Snyder DL, Tipton K, Uhl S, Schoelle KM. Negative pressure wound therapy devices. Technology assessment report. Rockville, MD: Agency for Healthcare Research and Quality, 2009.
- Petzina R, Malmjsjo M, Stamm C, Hetzer R. Major complications during negative pressure wound therapy in poststernotomy mediastinitis after cardiac surgery. *J Thorac Cardiovasc Surg* 2010;140:1133–6.
- Gustafsson RI, Sjogren J, Ingemansson R. Deep sternal wound infection: a sternal-sparing technique with vacuum-assisted closure therapy. *Ann Thorac Surg* 2003;76:2048–53, discussion 2053.
- Hersh RE, Jack JM, Dahman MI, Morgan RF, Drake DB. The vacuum-assisted closure device as a bridge to sternal wound closure. *Ann Plast Surg* 2001;46:250–4.
- Malmjsjo M, Ingemansson R, Sjogren J. Mechanisms governing the effects of vacuum-assisted closure in cardiac surgery. *Plast Reconstr Surg* 2007;120:1266–75.
- Sjogren J, Malmjsjo M, Gustafsson R, Ingemansson R. Poststernotomy mediastinitis: a review of conventional surgical treatments, vacuum-assisted closure therapy and presentation of the Lund University Hospital mediastinitis algorithm. *Eur J Cardiothorac Surg* 2006;30:898–905.
- Malmjsjo M, Petzina R, Ugander M, Engblom H, Torbrand C, Mokhtari A, Hetzer R, Arheden H, Ingemansson R. Preventing heart injury during negative pressure wound therapy in cardiac surgery: assessment using real-time magnetic resonance imaging. *J Thorac Cardiovasc Surg* 2009;138:712–7.
- Borgquist O, Ingemansson R, Malmjsjo M. The influence of low and high pressure levels during negative pressure wound therapy on wound contraction and fluid evacuation. *Plast Reconstr Surg*. In press.
- Chen SZ, Li J, Li XY, Xu LS. Effects of vacuum-assisted closure on wound microcirculation: an experimental study. *Asian J Surg* 2005;28:211–7.
- Etöz AÖY, Özcan M. The use of negative pressure wound therapy on diabetic foot ulcers: a preliminary controlled trial. *Wounds* 2004;16:264–9.
- Campbell PE, Smith GS, Smith JM. Retrospective clinical evaluation of gauze-based negative pressure wound therapy. *Int Wound J* 2008;5:280–6.
- Silver FH, Siperko LM. Mechanosensing and mechanochemical transduction: how is mechanical energy sensed and converted into chemical energy in an extracellular matrix? *Crit Rev Biomed Eng* 2003;31:255–331.
- Austad ED, Thomas SB, Pasyk K. Tissue expansion: dividend or loan? *Plast Reconstr Surg* 1986;78:63–7.
- Olenius M, Dalsgaard CJ, Wickman M. Mitotic activity in expanded human skin. *Plast Reconstr Surg* 1993;91:213–6.
- Bucalo B, Eglstein WH, Falanga V. Inhibition of cell proliferation by chronic wound fluid. *Wound Repair Regen* 1993;1:181–6.
- Grinnell F, Zhu M. Identification of neutrophil elastase as the proteinase in burn wound fluid responsible for degradation of fibronectin. *J Invest Dermatol* 1994;103:155–61.
- Mast BA, Schultz GS. Interactions of cytokines, growth factors, and proteases in acute and

- chronic wounds. *Wound Repair Regen* 1996;4: 411–20.
- 30 Wysocki AB, Staiano-Coico L, Grinnell F. Wound fluid from chronic leg ulcers contains elevated levels of metalloproteinases MMP-2 and MMP-9. *J Invest Dermatol* 1993;101:64–8.
- 31 Yager DR, Chen SM, Ward S, Olutoye OO, Diegelmann RF, Cohen IK. Ability of chronic wound fluids to degrade peptide growth factors is associated with increased levels of elastase activity and diminished levels of proteinase inhibitors. *Wound Repair Regen* 1997;5:23–32.
- 32 Ladwig GP, Robson MC, Liu R, Kuhn MA, Muir DF, Schultz GS. Ratios of activated matrix metalloproteinase-9 to tissue inhibitor of matrix metalloproteinase-1 in wound fluids are inversely correlated with healing of pressure ulcers. *Wound Repair Regen* 2002;10:26–37.
- 33 Tarlton JF, Bailey AJ, Crawford E, Jones D, Moore K, Harding KD. Prognostic value of markers of collagen remodeling in venous ulcers. *Wound Repair Regen* 1999;7:347–55.
- 34 Blakely M, Weir D. The innovative use of Safetac soft silicone in conjunction with negative pressure wound therapy: three case studies. Poster at SAWC 2007.
- 35 Dunbar A, Bowers DM, Holderness H Jr. Silicone net dressing as an adjunct with negative pressure wound therapy. *Ostomy Wound Manage* 2005;51(11A Suppl):21–2.
- 36 Malmso M, Ingemansson R. Similar biological effects of green and black polyurethane foam in negative pressure wound therapy: green foam facilitates monitoring of wound status, bleeding and exudate. 20th Conference of the European Wound Management Association; 2010 May 26–28; Geneva, Switzerland.

