



LUND UNIVERSITY

Electrophysiology - when nothing is seen

Hugosson, Therése

2018

Document Version:

Publisher's PDF, also known as Version of record

[Link to publication](#)

Citation for published version (APA):

Hugosson, T. (2018). *Electrophysiology - when nothing is seen*. [Doctoral Thesis (compilation), Department of Clinical Sciences, Lund]. Lund University: Faculty of Medicine.

Total number of authors:

1

General rights

Unless other specific re-use rights are stated the following general rights apply:

Copyright and moral rights for the publications made accessible in the public portal are retained by the authors and/or other copyright owners and it is a condition of accessing publications that users recognise and abide by the legal requirements associated with these rights.

- Users may download and print one copy of any publication from the public portal for the purpose of private study or research.
- You may not further distribute the material or use it for any profit-making activity or commercial gain
- You may freely distribute the URL identifying the publication in the public portal

Read more about Creative commons licenses: <https://creativecommons.org/licenses/>

Take down policy

If you believe that this document breaches copyright please contact us providing details, and we will remove access to the work immediately and investigate your claim.

LUND UNIVERSITY

PO Box 117
221 00 Lund
+46 46-222 00 00

Electrophysiology

- when nothing is seen

Therése Hugosson

MD

Ophthalmology, Department of Clinical Sciences, Lund
Faculty of Medicine, Lund University



LUND UNIVERSITY

Faculty of Medicine

Doctoral dissertation

by due permission of the Faculty of Medicine, Lund University, Sweden.

To be defended the 1st of June 2018 at 1:00 p.m.,
in Room I-1345, BMC, Sölvegatan 19, Lund.

Faculty opponent:

Professor Andrew Webster
Institute of Ophthalmology, University College London
Moorfields Eye Hospital, London
United Kingdom

Organization Faculty of Medicine LUND UNIVERSITY	Document name DOCTORAL DISSERTATION	
	Date of issue June 1, 2018	
Author(s) Therése Hugosson	Sponsoring organization	
Title and subtitle Electrophysiology - when nothing is seen		
<p>Abstract</p> <p>Sometimes patients report reduced vision, but, for the ophthalmologist, there is nothing to see that can explain the symptoms. In most cases, the appearance and structure go hand in hand with the function, but sometimes the fundus appearance is normal in spite of retinal dysfunction. Electrophysiology is then important for an objective assessment of the retinal function and for the correct diagnosis. In this thesis, a number of diseases with different pathogeneses is revealed, and underlying mechanisms are newly identified and explained for the first time.</p> <p>In the first study, patients from two families presented an early macular dysfunction, preceding any signs of abnormalities in fundus appearance. The diagnosis spinocerebellar ataxia type 7, a rare autosomal dominant neurodegenerative disorder, was revealed and confirmed.</p> <p>In another study, a large six-generation Scandinavian family afflicted with a slow progressing retinopathy was analysed. In some of the family members, the retinal appearance was almost normal, and electrophysiology revealed a late-onset retinitis pigmentosa. A disease-causing mutation, c.449G→A (p.S150N), was identified in exon 6 of the <i>KLHL7</i> gene. Thus, a novel autosomal dominant retinitis pigmentosa gene was identified. Subsequently, another two potentially disease-causing mutations, c.458C→T (p.A153V) and c.457G→A (p.A153T), were observed in six independent families with autosomal dominant retinitis pigmentosa.</p> <p>The first described electrophysiological long-term follow-up (17 years) of patients with a mutation in the newly identified <i>KLHL7</i> gene verified a phenotype of slowly progressive retinal degeneration, in some family members with late onset.</p> <p>In the last study, a previously healthy teenage girl with rapidly progressive visual loss bilaterally was examined because of "unexplained visual loss", in spite of comprehensive investigations. However, electrophysiology verified extensive retinal dysfunction and led to the diagnoses osteosarcoma and cancer associated retinopathy with AIPL1 as the specific retinal autoantigen.</p> <p>Electrophysiology is therefore important "when nothing is seen" for neither the patient nor the ophthalmologist to understand the symptoms of the patient, reveal the correct diagnosis and hopefully to treat and/or ease the condition.</p>		
Key words Electrophysiology, visual loss, spinocerebellar ataxia, KLHL7, cancer associated retinopathy		
Classification system and/or index terms (if any)		
Supplementary bibliographical information		Language English
ISSN and key title 1652-8220		ISBN 978-91-7619-633-5
Recipient's notes	Number of pages	Price
	Security classification	

I, the undersigned, being the copyright owner of the abstract of the above-mentioned dissertation, hereby grant to all reference sources permission to publish and disseminate the abstract of the above-mentioned dissertation.

Signature _____ Date April 23, 2018

To the Patients

Cover illustration: Multifocal electroretinography

© Therése Hugosson

Ophthalmology

Department of Clinical Sciences, Lund

Faculty of Medicine, Lund University, Sweden

ISBN 978-91-7619-633-5

ISSN 1652-8220

Printed by Media-Tryck, Lund University, Lund, Sweden, 2018.

CONTENTS

ABSTRACT	7
SVENSK SAMMANFATTNING.....	9
LIST OF PAPERS.....	11
ABBREVIATIONS.....	13
INTRODUCTION.....	15
Retina	
Electrophysiology	
Optical coherence tomography	
Unexplained visual loss	
AIMS OF THE STUDY.....	25
METHODS.....	27
Ophthalmological examinations	
Electrophysiological examinations	
Optical coherence tomography	
Genetic analyses	
Immunological and other techniques	
RESULTS.....	33
Spinocerebellar ataxia type 7 (Paper I)	
Retinitis pigmentosa (Paper II)	
Retinitis pigmentosa (Paper III)	
Cancer associated retinopathy (Paper IV)	
DISCUSSION	39
Spinocerebellar ataxia type 7	
Retinitis pigmentosa	
Cancer associated retinopathy	
CONCLUSIONS	49

ACKNOWLEDGEMENTS	51
REFERENCES	55
APPENDICES	
Paper I	
Paper II	
Paper III	
Paper IV	

ABSTRACT

Sometimes patients report reduced vision, but, for the ophthalmologist, there is nothing to see that can explain the symptoms. In most cases, the appearance and structure go hand in hand with the function, but sometimes the fundus appearance is normal in spite of retinal dysfunction. Electrophysiology is then important for an objective assessment of the retinal function and for the correct diagnosis. In this thesis, a number of diseases with different pathogeneses is revealed, and underlying mechanisms are newly identified and explained for the first time.

In the first study, patients from two families presented an early macular dysfunction, preceding any signs of abnormalities in fundus appearance. The diagnosis spinocerebellar ataxia type 7, a rare autosomal dominant neurodegenerative disorder, was revealed and confirmed.

In another study, a large six-generation Scandinavian family afflicted with a slow progressing retinopathy was analysed. In some of the family members, the retinal appearance was almost normal, and electrophysiology revealed a late-onset retinitis pigmentosa. A disease-causing mutation, c.449G→A (p.S150N), was identified in exon 6 of the *KLHL7* gene. Thus, a novel autosomal dominant retinitis pigmentosa gene was identified. Subsequently, another two potentially disease-causing mutations, c.458C→T (p.A153V) and c.457G→A (p.A153T), were observed in six independent families with autosomal dominant retinitis pigmentosa.

The first described electrophysiological long-term follow-up (17 years) of patients with a mutation in the newly identified *KLHL7* gene verified a phenotype of slowly progressive retinal degeneration, in some family members with late onset.

In the last study, a previously healthy teenage girl with rapidly progressive visual loss bilaterally was examined because of "unexplained visual loss", in spite of comprehensive investigations. However, electrophysiology verified extensive retinal dysfunction and led to the diagnoses osteosarcoma and cancer associated retinopathy with *AIP1* as the specific retinal autoantigen.

Electrophysiology is therefore important "when nothing is seen" for neither the patient nor the ophthalmologist to understand the symptoms of the patient, reveal the correct diagnosis and hopefully to treat and/or ease the condition.

SVENSK SAMMANFATTNING

När man som patient uppsöker ögonläkare på grund av försämrad syn kan det vara synskärpan, synfältet, mörkerseendet eller dylikt som påverkats. Ögonläkaren gör en rutinundersökning och i de flesta fall kan diagnos ställas men i vissa fall går det inte att finna någon förklaring till besvären. Det kan bero på att förändringarna är diskreta eller i tidigt stadiet men ibland är det en funktionell synnedsättning med psykologisk förklaring. Dock är det av yttersta vikt att utesluta annan orsak till synbesvären och därför remittera till olika röntgenundersökningar och/eller till specialläkare vid andra kliniker för utvidgade utredningar. Vissa mer specialiserade undersökningar kan även göras inom ögonsjukvården, tex elektrofysiologi för att studera näthinnans funktion, ty även om näthinnan ser normal ut kan funktionen vara påverkad.

I studie I undersöktes patienter från två familjer på grund av gradvis försämring av synskärpan på båda ögonen. Ett par av patienterna hade genomgått omfattande utredningar utan att något avvikande hade noterats och hos en av patienterna misstänktes psykologisk förklaring. Elektrofysiologi utfördes och påvisade nedsatt funktion i gula fläcken, dvs centrala delen av näthinnan, trots att näthinnan såg normal ut. Diagnosen spinocerebellär ataxi typ 7 kunde därefter konstateras, dvs en ovanlig genetisk neurodegenerativ sjukdom, vilket bekräftades med gentest.

I studie II studerades en stor Skandinavisk familj, inkluderande sex generationer, med långsamt utvecklande näthinnesjukdom. Hos några

familjemedlemmar såg näthinnan nästan normal ut men med elektrofysiologi noterades retinitis pigmentosa, dvs en ärftlig sjukdom som långsamt leder till blindhet på grund av avvikelser i näthinnans fotoreceptorer (celler). Vidare analyser fann genförändringar i genen *KLHL7*, dvs en helt nyupptäckt gen som förklaring till retinitis pigmentosa med dominant ärftlighetsmönster.

I studie III undersöktes en annan Skandinavisk familj som också visade sig ha en genförändring i den nyupptäckta *KLHL7* genen. Även här noterades att hos några av familjemedlemmarna hade näthinnan normalt eller nästan normalt utseende. Elektrofysiologisk långtids uppföljning (upp till 17 år), den först beskrivna vid denna nyupptäckta genförändring, påvisade en långsamt fortskridande näthinnesjukdom med sen debut hos några familjemedlemmar.

I studie IV utreddes en tidigare frisk 14 årig tjej på grund av snabb oförklarlig synnedsättning på båda ögonen. Omfattande utredningar hade gjorts vid flera olika kliniker men inget avvikande hade konstaterats. Elektrofysiologi påvisade dock uttalat nedsatt näthinnefunktion på båda ögonen. Men varför? Vidare riktade analyser initierades med bland annat blodprover och röntgenundersökningar. Det visade sig att flickan hade ett osteosarkom, dvs skelett cancer i ett ben. Kroppens eget försvar mot denna cancer, dvs antikroppar, korsreagerade mot ämnet AIPL1 i näthinnan, vilket förklarade synnedsättningen, dvs cancer associerad retinopati. Detta lär vara det först beskrivna fallet av cancer associerad retinopati vid osteosarkom.

I denna avhandling belyses hur viktig elektrofysiologi är för att vid oklar synnedsättning ställa korrekt ögon diagnos och i vissa fall även leda fram till annan diagnos, såsom tex neurologisk sjukdom och cancer. När diagnosen är fastställd kan även bakomliggande orsaker studeras och i denna avhandling har nyupptäckta mekanismer identifierats.

LIST OF PAPERS

This thesis is based on the following papers, which will be referred to in the text by their Roman numerals.

- I. Macular dysfunction and morphology in spinocerebellar ataxia type 7 (SCA 7).
Hugosson T, Gränse L, Ponjavic V, Andréasson S.
Ophthalmic Genet. 2009 Mar;30(1):1-6.

- II. Mutations in a BTB-Kelch protein, *KLHL7*, cause autosomal-dominant retinitis pigmentosa.
Friedman JS, Ray JW, Waseem N, Johnson K, Brooks MJ, **Hugosson T**, Breuer D, Branham KE, Krauth DS, Bowne SJ, Sullivan LS, Ponjavic V, Gränse L, Khanna R, Trager EH, Gieser LM, Highbanks-Wheaton D, Cojocaru RI, Ghiasvand NM, Chakarova CF, Abrahamson M, Göring HH, Webster AR, Birch DG, Abecasis GR, Fann Y, Bhattacharya SS, Daiger SP, Heckenlively JR, Andréasson S, Swaroop A.
Am J Hum Genet. 2009 Jun;84(6):792-800.

- III. Phenotype associated with mutation in the recently identified autosomal dominant retinitis pigmentosa *KLHL7* gene.
Hugosson T, Friedman JS, Ponjavic V, Abrahamson M, Swaroop A, Andréasson S.
Arch Ophthalmol. 2010 Jun;128(6):772-8.

- IV. Aryl Hydrocarbon Receptor-Interacting Protein-Like 1 in Cancer-Associated Retinopathy.
Dalin F, Adamus G, Yang S, Landgren E, Palle J, Hallgren Å, Frost BM, **Hugosson T**, Landegren N, Eriksson D, Andréasson S, Tabbara KF, Kämpe O, Alimohammadi M.
Ophthalmology. 2016 Jun;123(6):1401-4.

Published papers are reprints with permission from the publishers.

ABBREVIATIONS

AAbs	Autoantibodies
adRP	Autosomal dominant retinitis pigmentosa
AIPL1	Aryl-hydrocarbon-receptor-interacting protein-like 1
ATXN7	Ataxin 7
BTB	Bric-a-brac, tramtrack and broad complex
CAG	Cytosine–adenine–guanine
CAR	Cancer associated retinopathy
CNS	Central nervous system
CRX	Cone-rod homeobox
CT	Computed tomography
DNA	Deoxyribonucleic acid
E3	Ubiquitin ligase
ERG	Electroretinography
GCL	Ganglion cell layer
GFP	Green fluorescent protein
INL	Inner nuclear layer
IPL	Inner plexiform layer
IR	Infrared
ISCEV	International Society for Clinical Electrophysiology of Vision
KLHL7	Kelch Like Family Member 7
LCA	Leber’s congenital amaurosis
LGN	Lateral geniculate nucleus
mfERG	Multifocal electroretinography
MIM	Mendelian Inheritance in Man
MRI	Magnetic resonance imaging
NFL	Nerve fiber layer
OCT	Optical coherence tomography
od	Oculus dexter (right eye)
ONL	Outer nuclear layer
OPL	Outer plexiform layer

os	Oculus sinister (left eye)
OS	Outer segment (of the photoreceptor)
PCR	Polymerase chain reaction
RNA	Ribonucleic acid
RPE	Retinal pigment epithelium
RT-PCR	Reverse transcriptase PCR
SCA 7	Spinocerebellar ataxia type 7
SD	Spectral-domain
SNP	Single nucleotide polymorphism
STAGA	SPT3-TAF9-ADA-GCN5 acetyltransferase
TD	Time-domain
V1	Visual area 1
VA	Visual acuity
VEP	Visual evoked potentials

INTRODUCTION

Sometimes patients report that they "can't see". It might be a loss of visual acuity (VA), visual field or any other visual parameter that brings the patients an experience of reduced vision. When the ophthalmologist looks into the eye, it might appear fine by ophthalmoscopy with a normal or almost normal fundus appearance, i.e. there is nothing to see that can explain the symptoms described by the patient. The patient will then be further examined by the ophthalmologist and sometimes also referred to other clinics. In spite of extensive investigations using, for example, analyses of blood and cerebrospinal fluid, magnetic resonance imaging (MRI) and computed tomography (CT) of the brain, sometimes, there is nothing abnormal to reveal that can explain the symptoms, and, as a result, the patients are reported to have "unexplained visual loss" or functional visual loss, i.e. psychological.

However, in these patients, electrophysiology may verify a retinal dysfunction, and the symptoms of the patients can be explained and understood. To further diagnose and clarify the pathogenesis of the retinal dysfunction in every individual patient, targeted analyses and examinations can then be added.

In this thesis entitled "Electrophysiology - when nothing is seen", the studies elucidate the use of electrophysiology in some diseases with different pathogeneses "when nothing is seen" neither by the patient nor the ophthalmologist.

Retina

The retina is a light-sensitive tissue lining the inner surface of the human eye (Figure 1). Actually, the retina and the optic nerve originate as outgrowths from the developing brain, i.e. the retina is considered part of the central nervous system (CNS). The blood to the retina is supplied by the ophthalmic artery which bifurcates into two distinct vascular networks - the choroidal network (supplies the choroid and the outer retina) and the retinal network (supplies the inner retina) (Oyster 1999).

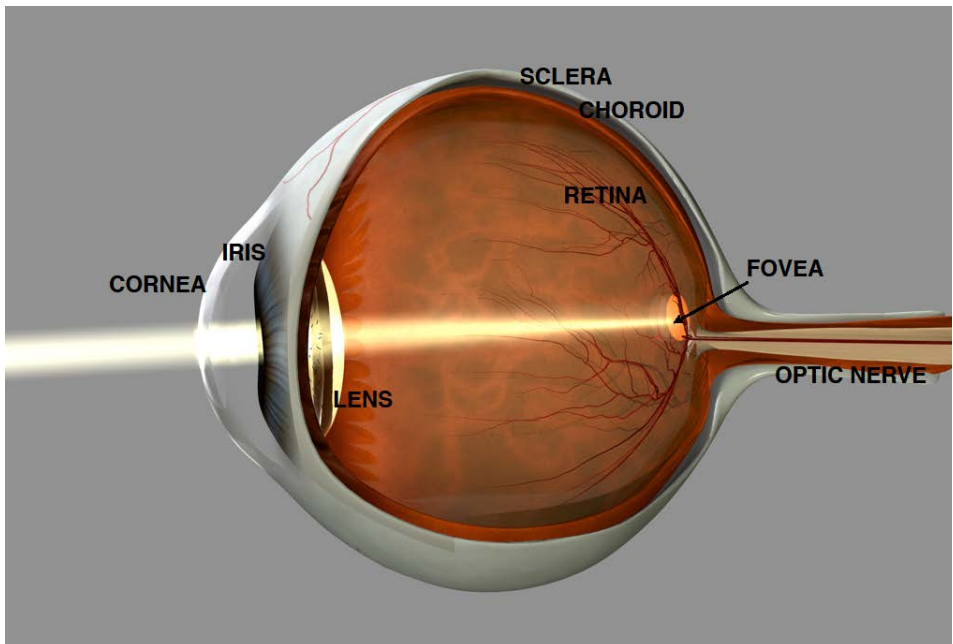


Figure 1. Anatomy of the human eye. (Copyright Professor Fredrik Ghosh)

The retina, which in section is approximately 0.5 mm thick, is composed of several layers of neurons interconnected by synapses (Figure 2). The cells that absorb light are called photoreceptors and are of two types, the rods and the cones, which are sensitive to different wavelengths of light. The rods

contain a visual pigment called rhodopsin, which responds to dim light and is important for night vision (scotopic vision). The cones respond to bright light and mediate colour vision and daylight vision (photopic vision). The cones express visual pigments with different absorption maxima and are hence divided into three subgroups: short (blue), medium (green) and long (red) wavelength sensitive cones (Österberg 1935, Kolb et al 1995).

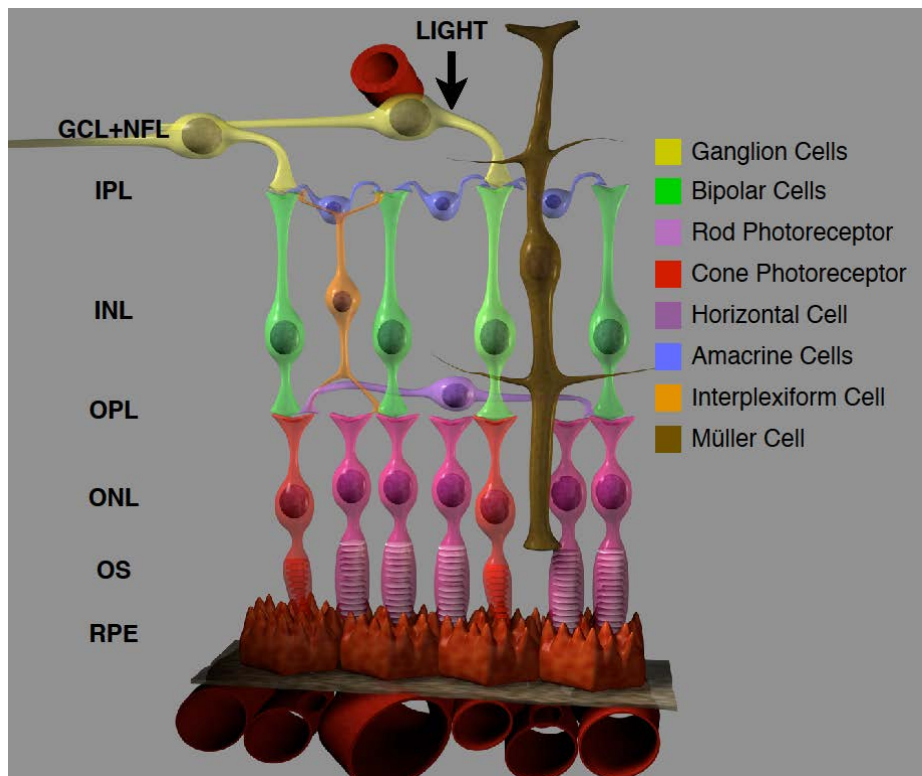


Figure 2. Simplified schematic illustration of the cellular organization of the retina. Retinal pigment epithelium (RPE), outer segments (OS), outer nuclear layer (ONL), outer plexiform layer (OPL), inner nuclear layer (INL), inner plexiform layer (IPL), ganglion cell layer (GCL) and nerve fiber layer (NFL). (Copyright Professor Fredrik Ghosh)

The entire human retina contains approximately 5 million cones and 92 million rods (Curcio et al 1990). The optic disc or optic nerve head (called "the blind spot") lacks photoreceptors and is the way out for axons of ganglion

cells leaving the eye. The fovea, located in the centre of the macula, is a small pit composed of closely packed cones and is responsible for our sharp central vision, which is important for tasks such as reading. Approximately half of the nerve fibers in the optic nerve transfer information from the fovea while the remaining half carry information from the rest of the retina.

Light entering the eye is absorbed by the retina, and the visual pigment in the photoreceptors is then activated, initiating a cascade of chemical reactions, called the phototransduction cascade. The neural signals from the photoreceptors are processed by other retinal cells, and the output signal is conducted as action potentials in the retinal ganglion cells, the axons of which form the optic nerve. The signal is further transmitted through the optic chiasm to the lateral geniculate nucleus (LGN), and the output radiates to the brain, primarily to the primary visual cortex (V1), in order to create an interpreted image (Oyster 1999).

Electrophysiology

Electrophysiological examinations of patients with retinal diseases were introduced in clinical departments in the late 1940s. Holmgren, Granit and Karpe, Swedish pioneers, conducted many of the observations and analyses that serve as basis for understanding the electroretinography (ERG) today (Holmgren 1865, Granit 1933, Karpe 1948). Over the years, ERG recording techniques have become progressively more sophisticated in the clinical setting. Since the introduction of the full-field ERG, other diagnostic tests have been invented, and the most recent advance in ERG technology is multifocal electroretinography (mfERG) developed by Sutter in the early 1990s (Sutter et al 1992, Bearse et al 1996). The primary objective of the

ERG examination is to assess the function of the retina, which is particularly valuable in cases in which the retina appears normal.

Full-field electroretinography

Full-field ERG is a method for objective assessment of the total retinal function. The dark-adapted patient with dilated pupils gazes into a Ganzfeld hemispheric dome, from which light stimuli and background illumination are presented homogeneously to the entire retina. The examination measures the electrical activity generated by the retinal cells in response to a light stimulus. The electrical response is a result of a retinal potential generated by light-induced changes in the flux of transretinal ions, primarily Na^+ and K^+ . Usually, full-field ERG is performed using electrodes embedded in a corneal contact lens, which measures a summation of retinal electrical activity at the corneal surface. The response is then analysed by electronic and computer analysing systems (Creel 2005).

By using different flash stimulus strength measured in candela-seconds per meter squared ($\text{cd}\cdot\text{s}/\text{m}^2$), inter-stimulus rate measured in hertz (Hz), recording bandpass (Hz) and adaptive state of the retina (dark adapted or light adapted), responses from different cells in the retina will be obtained (Figure 3). The result of stimulation of the dark-adapted eye with dim blue light mainly reflects the rod function. When the strength of the stimulus is increased, combined rod and cone system responses will be obtained. To evaluate the isolated cone response, 30 Hz flicker is used, as rods do not respond at this rate.

According to the International Society for Clinical Electrophysiology of Vision (ISCEV), the amplitude of the response, i.e. from trough to peak of a

typical wave, is measured in microvolts (μV), and the implicit time, i.e. the time interval from the stimulus to the peak of the wave, is measured in milliseconds (ms) (Marmor et al 2004, McCulloch et al 2015).

The full-field ERG response is comprised of different components, often referred to as the cornea negative a-wave and the cornea positive b-wave. The origin of the different components is complex (Brown 1968). Simplified, the a-wave is believed to originate from the photoreceptors, and the b-wave reflects, predominantly, the activity of bipolar cells and Müller cells (Newman et al 1984). However, the bipolar cells depend on the photoreceptors for neural signal propagation, and, thereby, the b-wave indirectly reflects photoreceptor activity as well.

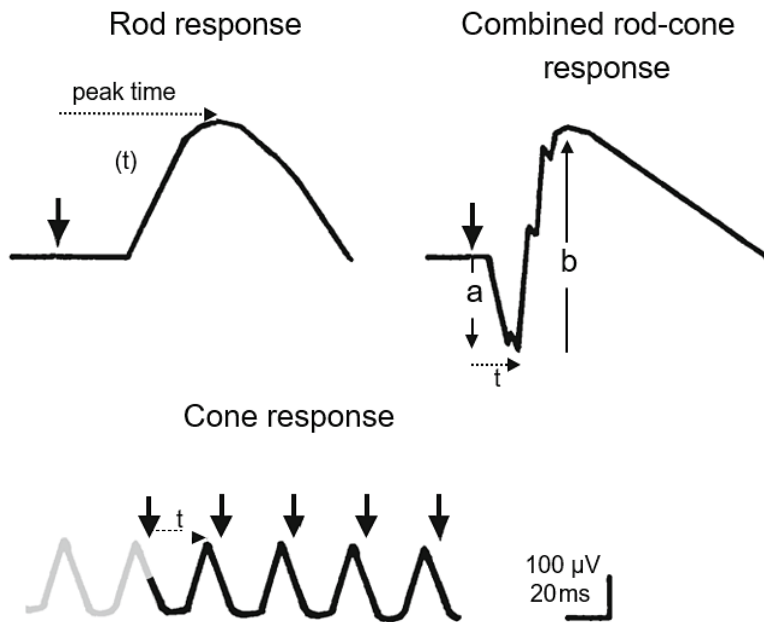


Figure 3. Three full-field electroretinography responses. Bold arrows indicate the stimulus flash, solid arrows illustrate the a- and b-wave amplitudes and dotted arrows mark the implicit time or peak time (t). (Adapted from ISCEV Standard for full-field clinical electroretinography (2015 update), McCulloch et al 2015)

Multifocal electroretinography

MfERG is a method of simultaneously recording local electrophysiological responses from different regions of the central retina under light adapted conditions. The nature of the stimulus and the form of analysis differ from full-field ERG.

In mfERG the retina is stimulated with an array of hexagonal elements, each element follows a pseudo-random m-sequence to control the change between the light and dark stages of each stimulus hexagon (Figure 4). In routine clinical examinations, the array contains either 61 or 103 hexagons within a field diameter of 40-50 degrees. The hexagons are scaled in size to produce responses of approximately equal amplitude in the healthy retina. Although these mfERG signals are referred to as responses, they are not direct electrical potentials as in full-field ERG but rather a mathematical extraction of the signal.

The patient should be in ordinary room illumination before testing, and the examination is performed in moderate room light. Preparation of the patient includes dilating the pupils, inserting a recording electrode that contacts the cornea and monitoring of fixation and refraction for optimal acuity at the viewing distance. Monocular stimulation is then performed with the hexagonal stimulus array displayed on a monitor. Powerful computers and analysis software allow appropriate band-pass filtering and spatial averaging to remove extraneous electrical noise and to smooth waveforms.

The standard mfERG response, the first-order kernel, has an initial negative deflection (N1), followed by a positive peak (P1) and a second negative deflection (N2). The cellular origin of the peaks is not confirmed, but there is evidence that N1 includes the same contributions as the a-wave of the light

adapted full-field ERG and that P1 and N2 include contributions from the cells contributing to the light adapted b-wave. The standard measurement of the mfERG response is the amplitude and implicit time of P1 in accordance with ISCEV (Hood et al 2008, Hood et al 2012).

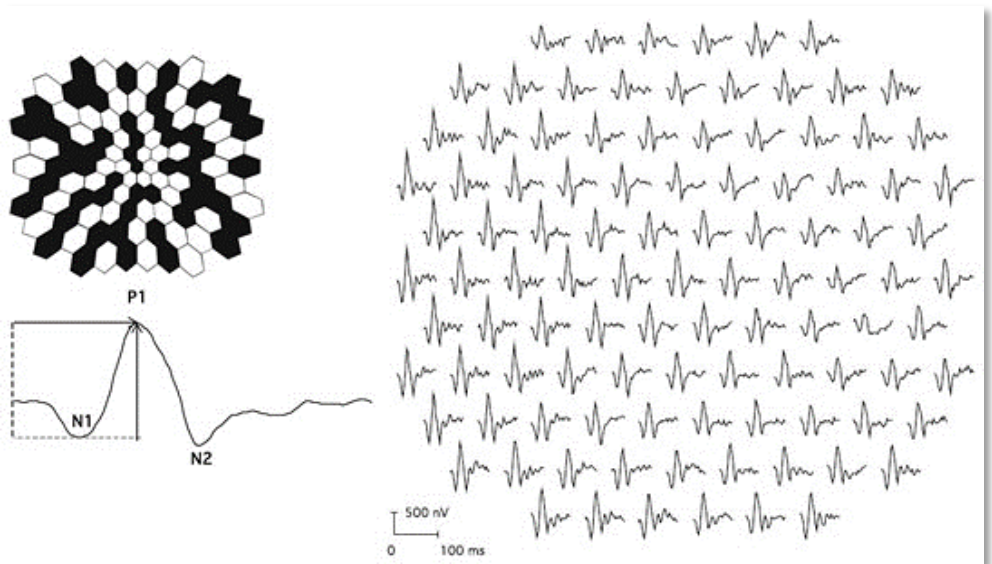


Figure 4. In the upper left hexagonal stimulus array with 103 elements scaled with eccentricity. Below a multifocal electroretinography response. Vertical arrow illustrates the amplitude and the horizontal arrow marks the implicit time of the positive peak. To the right trace array with 103 elements (right eye, field view). (Adapted from *ISCEV Standard for clinical multifocal electroretinography (mfERG) (2011 edition)*, Hood et al 2012)

To interpret mfERG, the trace array, with a response correlating to every hexagonal element, is the basic form of display. Sometimes, a 3-D plot is added to illustrate the overall signal strength per unit area of retina. Another way to display the results is to group responses from the trace array, for example, in successive rings from centre to periphery. In general, an abnormal mfERG result indicates that the cones and/or bipolar cell layers are dysfunctional and, in contrast to full-field ERG, also indicates the precise distribution of the retinal dysfunction.

Optical coherence tomography

Optical coherence tomography (OCT) was introduced in the early 1990s (Huang et al 1991). It is a non-invasive noncontact diagnostic imaging technique that renders a high-resolution cross sectional or three-dimensional view of the retina. Detailed images of the retinal layers are obtained, allowing analysis of structural changes within the retina (Hee et al 1995).

The mechanism is analogous to ultrasonic pulse-echo imaging but uses near-infrared light instead of sound waves. The OCT images are obtained by the measurement of magnitude and echo time delay of back scattered light from an optical beam across the retina. However, due to the high velocity of light direct detection of light echoes is not possible. Therefore measurements are done correlating sample reflections from a reference mirror using a Michelson interferometer. This set-up is referred to as the time-domain (TD) OCT. A reflectivity profile, i.e. A-scan, is generated containing information about the location of structures and the spatial dimensions. By combining a series of A-scans a cross-sectional tomographic B-scan is obtained (Podoleanu 2012, Murthy et al 2016).

A new generation of OCT technology called spectral-domain (SD) OCT has evolved within the past decade. In SD-OCT, an interferometer with a stationary reference arm is used to detect light echoes by measuring the interference signal as a function of wavelength. Thereby the SD-OCT allows high speed scanning with scan rates 50-100 times faster than conventional TD-OCT, as well as advantages in signal-to-noise ratio and improved resolution of the B-scan images. The advances in OCT technology have made it possible to study structural changes and fine lesions in the individual retinal layers more precisely and in less time (Murthy et al 2016).

Unexplained visual loss

One of the most challenging differential diagnostic problems faced by ophthalmologists is visual loss which cannot be explained by obvious abnormalities of the eye. An initial approach to a patient with "unexplained visual loss" is to assess the location of the problem: 1) refractive/media, 2) retina/choroid, 3) optic nerve/visual pathways or 4) nonorganic, i.e. psychological.

The investigation includes a clinical ophthalmological examination with VA, visual field test, colour vision test, swinging flashlight test, slit-lamp microscopy, ophthalmoscopy, OCT, colour fundus photography, fluorescein angiography, indocyanine green angiography, fundus autofluorescence and at a department for electrophysiology full-field ERG, mfERG and visual evoked potentials (VEP). Furthermore, the investigation may also include radiology with MRI and CT of the brain, and in some selected cases more specialized examinations with genetic analyses (for example linkage analysis, mutation screen, next generation sequencing, whole exome sequencing and whole genome sequencing) as well as different immunological techniques. In this thesis, the above mentioned ancillary tests have been performed selectively for the patients in the different studies. During the last years, though, ophthalmic practice has been revolutionized by multimodal retinal imaging techniques such as SD-OCT, OCT angiography and microperimetry.

In this thesis, the importance of electrophysiology is elucidated, especially in cases with "unexplained visual loss", to assess the retinal function and reveal the correct ophthalmological diagnosis, and in some cases even a systemic disorder, which will be further described in the Discussion of this thesis.

AIMS OF THE STUDY

Sometimes, patients report reduced vision but routine ophthalmological examinations do not show any abnormalities that can explain the symptoms. The general aim of this study is to use electrophysiology "when nothing is seen" to reveal the correct diagnosis and, furthermore, to identify as well as explain the underlying disease mechanisms.

Specific aims

Paper I

To reveal the diagnosis by using electrophysiology in patients, from two families, with bilateral loss of VA and normal ophthalmoscopic fundus appearance.

Paper II

To identify the responsible gene and gene mutation(s) in a six-generation Scandinavian family with slow progressing retinopathy and in some family members almost normal retinal appearance.

Paper III

To describe the phenotype with long-term follow-up by using electrophysiology in patients with mutation in the recently identified autosomal dominant retinitis pigmentosa gene *KLHL7* and sometimes almost normal fundus appearance.

Paper IV

To reveal the clinical diagnosis by using electrophysiology in "unexplained visual loss" and further to explore the underlying disease mechanism(s).

METHODS

Ophthalmological examinations

Ophthalmological examinations included best corrected VA, slit-lamp microscopy, ophthalmoscopy and fundus photography. Goldmann perimetry was performed using the standardized targets I4e and V4e and, in Paper I, even the targets O3/O4. Farnsworth's colour vision test was examined in Paper I. Schirmer's test was done in Paper III (Uchida et al 2005).

Electrophysiological examinations

Full-field electroretinography

Full-field ERG was recorded in a Nicolet analysis system (Nicolet Biomedical Instruments, Madison, WI, USA), after the pupils were dilated with topical cyclopentolate 1% and metaoxedrine 10% and the patients were dark adapted for 40 minutes. After topical anaesthesia of the eye, a Burian Allen bipolar contact lens (Hansen Labs, Coralville, Iowa) was applied on the cornea and a ground electrode on the forehead. Responses were obtained with a wide band filter (-3 dB at 1 Hz and 500 Hz) stimulating with brief (30 μ s) single full-field flashes of dim blue light (Wratten filters 47, 47A and 47B) and white light (0.81 cd-s/m² and 3.93 cd-s/m²). Cone responses were obtained with 30 Hz flickering white light (0.81 cd-s/m²) averaged from 20 sweeps (Marmor et al 2004).

If responses measuring less than 10 μV were recorded with single white flashes, recordings were also obtained with computer averaging (30 flashes), a bipolar artefact rejecter and a line frequency notch filter (50 Hz). To obtain small cone responses, stimulation then included 200 sweeps of 30 Hz flickering white light (0.81 $\text{cd}\cdot\text{s}/\text{m}^2$) (Andréasson et al 1988).

Multifocal electroretinography

MfERG was recorded using a visual evoked response imaging system (VERIS 4; EDI, San Mateo, California, USA). The stimulus matrix consisted of 103 hexagonal elements displayed on a screen in the infrared (IR) camera. The sizes of the hexagons were scaled with eccentricity to elicit approximately equal amplitude responses at all locations. At a viewing distance of 5 cm, the radius of the stimulus array subtended approximately 20–25 degrees. The luminance of each hexagon was independently alternated between black (3.5 cd/m^2) and white (138.0 cd/m^2) according to a pseudorandom binary m-sequence at 75 Hz.

After dilatation of the pupils and application of topical anaesthesia as described above, a Burian Allen bipolar lens with IR light was applied on the ocular surface and a ground electrode on the forehead. Recordings were monocular, and the fixation was controlled using the IR camera and illumination with IR light from the recording electrode, with visualization of the hexagonal elements over the retina. The first order kernel P1 amplitudes and implicit times in ring areas 1–6 were calculated according to the guidelines for basic mfERG (Hood et al 2008). Responses from ring areas 1 and 2 were averaged, noted Ring (1+2).

Optical coherence tomography

TD-OCT was performed using the Zeiss OCT-3 (Stratus OCT 4.0.1, Zeiss Humphrey Instruments, Dublin, CA, USA). The Stratus OCT projects a near-infrared light beam (820 nm) onto the retina and delineates intraretinal, cross-sectional anatomy with axial resolution of ≤ 10 μm and transverse resolution of 20 μm . Single line scans of 5 mm and macular thickness maps of scan length 6 mm centred over the fovea were obtained. Retinal thickness was calculated by automated measurement (Hee et al 1995).

Genetic analyses

In Paper I blood samples were drawn and subsequently further genetic analyses were performed at the Department of Medical Biosciences, Unit of Medical and Clinical Genetics, University Hospital of Umeå, Sweden. Deoxyribonucleic acid (DNA) was analysed with polymerase chain reaction (PCR) for cytosine–adenine–guanine (CAG) trinucleotide expansion repeats in the *SCA 7* gene.

In Paper II all genetic analyses were performed at the Neurobiology-Neurodegeneration & Repair Laboratory, National Eye Institute, National Institutes of Health, USA. A whole-genome scan of DNA samples from 23 individuals of Scandinavian autosomal dominant retinitis pigmentosa (adRP) Family 72 were hybridized to Affymetrix SNP Nsp 250K array according to the manufacturer's recommendations (Affymetrix, Santa Clara, CA, USA). Subsequently, multipoint linkage analysis was performed on the genotyping data via Merlin (Abecasis et al 2002, Ruschendorf et al 2005). Furthermore, a mutation screen was carried out on *Kelch Like Family Member 7 (KLHL7)*

in patients and controls collected from North America (Michigan and Texas cohorts), Scandinavia and the United Kingdom (Friedman et al 2006). PCR amplified DNA was sequenced using ABI 3130xl Genetic Analyzer (Applied BioSystems, Foster City, CA).

In Paper III, blood samples were obtained, and DNA was analysed. *KLHL7* exons 1 through 12 were sequenced at the Neurobiology-Neurodegeneration & Repair Laboratory, National Eye Institute, National Institutes of Health, USA, as described in Paper II.

Immunological and other techniques

In Paper II, the immunological methods were carried out at the Neurobiology-Neurodegeneration & Repair Laboratory, National Eye Institute, National Institutes of Health, USA. Ribonucleic acid (RNA) samples from mouse tissues and flow sorted green fluorescent protein (GFP) tagged photoreceptors were used for cDNA synthesis by reverse transcriptase PCR (RT-PCR), followed by quantitative PCR. Immunoblot analysis of *KLHL7* in mouse retina was carried out with the use of a mouse α -*KLHL7* polyclonal antibody (Abnova, Walnut, USA). Immunohistochemical characterization of *KLHL7* protein in mouse retina was performed with α -*KLHL7* antibody. Immunocytochemistry was done, using GFP-tagged photoreceptors dissociated from *Nrl*-GFP mouse retina and α -*KLHL7* antibody (Akimoto et al 2006).

In Paper IV, the following immunological techniques were performed at the Department of Medicine, Karolinska University Hospital, Stockholm, Sweden:

Immunostaining

A porcine eye was cryosectioned in 6 μm thick sections, fixed in ice-cold acetone for 2 minutes and stained with haematoxylin-eosin. Sera from the patient with suspected paraneoplastic retinopathy, another patient with isolated retinitis and healthy blood donors were used as primary antibodies, each in four different dilutions: 1:50, 1:100, 1:200 and 1:400. The sections were incubated over night at 4°C. Antibody binding was detected using a fluorescein isothiocyanate conjugated goat anti-human IgG (Jackson Immuno Research Laboratories).

Radioimmunoprecipitation

A full-length clone of *aryl-hydrocarbon-receptor-interacting protein-like 1* (*AIPL1*) (SC321437, OriGene) was used for in vitro transcription and translation to generate 35S-radiolabeled recombinant protein antigen using the TNT system (Promega). The radio-immunoprecipitation assay was used to screen a cohort of 100 patients with cancer associated retinopathy (CAR) or autoimmune retinopathy and 73 healthy blood donors, using radioactively labeled AIPL1.

Proteome microarray

A human proteome microarray (HuProt) (CDI Laboratories, Baltimore, MD) including 19 394 proteins, covering approximately 80% of the protein coding genes, was screened with serum from the patient. The array was subsequently scanned using a GenePix 4000B microarray scanner.

RESULTS

The studies in this thesis elucidate electrophysiology "when nothing is seen". Different diseases with various pathogenesis are presented: in Paper I, spinocerebellar ataxia type 7 (SCA 7), a neurological and ophthalmological genetic disease; in Paper II and III, adRP, an ophthalmological disease caused by mutation in the newly identified *KLHL7* gene; in Paper IV, CAR with osteosarcoma and ophthalmological complications caused by retinal autoantibodies.

Spinocerebellar ataxia type 7 (Paper I)

All patients in Families I and II reported a bilateral gradual loss of VA. Besides very discreet pigmentation in the maculae of the oldest patient, all patients had a normal ophthalmoscopic fundus appearance. In all patients, minor central scotomas were noted bilaterally with Goldmann perimetry. Farnsworth's colour vision test in all the patients indicated colour vision defects without any obviously preferred axes discrimination. In the oldest patient, OCT demonstrated minor changes of reduced retinal thickness in the foveal and parafoveal areas. The patients were extensively examined because of "unexplained visual loss".

Electrophysiology was then performed, and retinal dysfunction was verified. Full-field ERG demonstrated slightly reduced 30-Hz flicker cone amplitudes in Family I. Additionally, in the oldest patient, the 30-Hz flicker cone implicit

time was distinctly prolonged bilaterally. In all patients, mfERG presented markedly reduced amplitudes bilaterally and mainly corresponding to the foveal area. In the two youngest patients, the amplitudes in the outer ring areas were better preserved than in the oldest patient. In the patient with the shortest duration of symptoms, the implicit time of the mfERG was within normal limits. The oldest patient, who had the most advanced symptoms, had a distinctly prolonged implicit time, exceeding +2 standard deviations for all ring areas. In conclusion, mfERG indicated predominantly central involvement, especially in the early disease stages, which, in pace with disease progression, extended from the centre to the more peripheral areas.

To further diagnose, blood samples were sent for genetic analyses, and molecular analysis demonstrated an abnormally expanded CAG repeat within the *SCA 7* gene (38–49 repeats) present in one allele in all the patients, thus confirming the diagnosis *SCA 7*.

Retinitis pigmentosa (Paper II)

A large six-generation Scandinavian family (Family 72) afflicted with a slow progressing retinopathy was studied (Andreasson 1991). In some of the family members, the retinal appearance was almost normal or demonstrated only very discreet degenerative changes, and full-field ERG presented a late-onset RP with mild and slower than usual progression of disease.

A whole-genome scan of 23 individuals in Family 72 was performed, and linkage analysis revealed a new adRP locus (called RP42) to chromosome 7p15. Subsequently, within this newly identified region, a potentially disease-causing c.449G/A, p.S150N (serine 150-to-asparagine) mutation in exon 6 of

the *KLHL7* gene was discovered. The *KLHL7* gene was then screened for possible mutations in 502 adRP probands from Europe and North America. Another independent putative mutation, c.458C/T, p.A153V (alanine 153-to-valine), was observed in three families, including the Scandinavian Family 101. A third independent and potentially disease-causing change at residue c.457G/A, encoding a p.A153T (alanine 153-to-threonine) alteration, was also uncovered. All these three missense mutations reported in six independent adRP families are present in exon 6 of *KLHL7* and were not observed in 470 controls from North America, Scandinavia or the United Kingdom. Concerning prevalence it was estimated that *KLHL7* is responsible for 1%–2% of adRP.

Immunoblot analysis revealed that *KLHL7* encodes a 75 kDa protein. RT-PCR and immunocytochemistry validated the expression of *KLHL7* in rod photoreceptors. The two isoforms of *KLHL7* contain Bric-a-brac, Tramtrack and Broad Complex (BTB), BACK and Kelch functional domains, suggesting that *KLHL7* is a BTB-Kelch protein. All three *KLHL7* mutations (S150N, A153V and A153T) are within the conserved BACK domain (Stogios et al 2004). Homology modeling suggested that mutant amino acid side chains can potentially fill the space (i.e. cleft) between the two helices, thereby affecting the ubiquitination complexes (Vriend 1990).

Retinitis pigmentosa (Paper III)

Eleven patients from Family 101 were selected from the Swedish RP register (Figure 5). Four of the patients had been examined earlier and were given re-examination with clinical follow-up ranging up to 17 years.

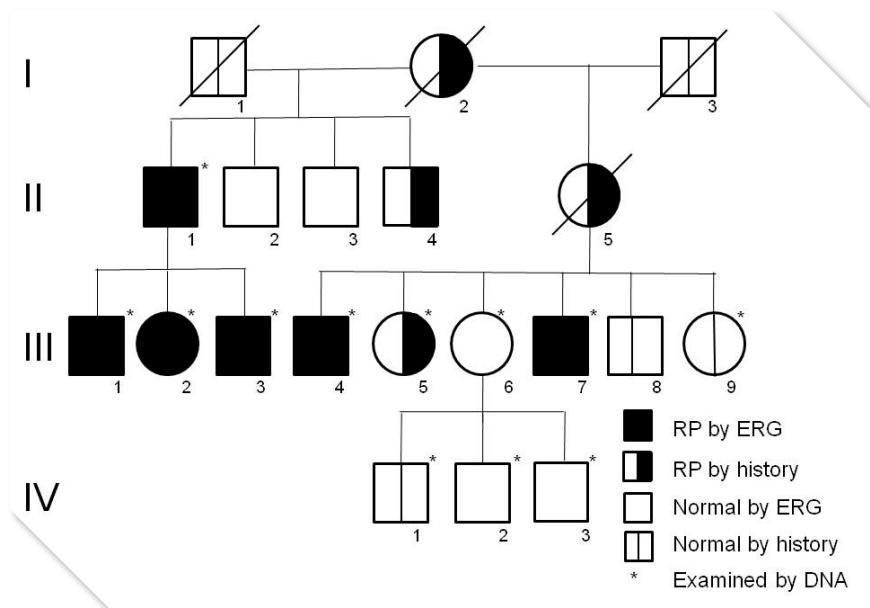


Figure 5. Autosomal dominant retinitis pigmentosa (RP) caused by *KLHL7* mutation in Family 101 from the Swedish RP register. ERG indicates electroretinography. (Adapted from Paper III)

In most examined family members, the fundus showed normal appearance or minor abnormalities. However, with disease progression scattered bone corpuscular pigment and other characteristic RP degenerations were seen. Full-field ERG demonstrated varying degree of reduced cone and rod function, but rod responses were preserved in some patients late in life. Follow-up (17 years) demonstrated slowly progressive retinal degeneration. In one 17-year-old family member, cone and rod function was initially normal, but RP was confirmed by electrophysiology 17 years later. MfERG then showed well-preserved amplitudes corresponding to the foveal area but affected amplitudes and prolonged implicit times in the outer ring areas. In conclusion, long-term follow-up verified a phenotype with a varying degree of retinal photoreceptor dysfunction and, in some family members, with late onset and slowly progressive.

Blood samples were sent for genetic analyses and, in 7 family members, a heterozygous exon 6 change (c.458C/T) was revealed in the *KLHL7* gene as described in Paper II. Accordingly, patients with normal fundus appearance and normal ERG findings early in life can harbour an autosomal dominant form of RP.

Cancer associated retinopathy (Paper IV)

The patient, a previously healthy 14-year-old girl, was referred to our Department because of "unexplained visual loss". At ophthalmological examination, her VA was oculus dexter (od) 0,4, oculus sinister (os) 1,0. Two months later, her VA was od hand motion, os 0,2 and eventually only light perception bilaterally. Examinations by a pediatrician and a pediatric neurologist and the results from MRI of the brain and analyses of blood and cerebrospinal fluid did not reveal any pathology. Steroids, general as well as local treatment, were tried without any improvement in VA.

Ophthalmoscopic fundus appearance showed significantly narrowed blood vessels. Goldmann perimetry od was not possible due to VA, but os presented a small area of remaining visual field in the inferior temporal quadrant. OCT presented normal foveal structure. Thus, "unexplained visual loss". Electrophysiology was then performed, and retinal dysfunction was verified. Full-field ERG with white light amplitudes resulted in od 8 μ V, os 26 μ V, and with 30 Hz flickering no significant amplitudes were obtained. MfERG od and os presented no significant responses.

To further diagnose, blood samples were sent to Ocular Immunology Laboratory, OHSU, USA, and, there, Western Blot tests were positive for

anti-retinal autoantibodies (AAbs) against 33-kilodalton (kDa), 46-kDa (α -enolase) and 90-kDa proteins but negative for anti-recoverin AAbs. CAR was then suspected, and the patient was therefore examined by x-ray, which was normal. However, MRI revealed an edematous tumor in the right calcaneus. Biopsy of calcaneus and cytological examination revealed a small cell tumor classified as osteosarcoma.

For further understanding of the retinopathy, human retinal tissue was immunostained with serum from the patient and revealed a strong staining in the synaptic region of the photoreceptor cells with an overlap of anti-AIPL1 antibody staining. To identify candidate retinal autoantigen(s), a human proteome microarray was immunoscreened with serum from the patient, and a strong signal was identified as AIPL1. Further, using radioactively labeled AIPL1 in a radio-immunoprecipitation assay, AAbs against AIPL1 were revealed to be present in our patient but absent in healthy blood donors and other patients with CAR/autoimmune retinopathy. It was concluded that AIPL1 was the specific retinal autoantigen for this girl with osteosarcoma and CAR.

DISCUSSION

Sometimes, patients present with complaints of visual loss in which the medical history and ophthalmological examination fail to provide a ready diagnosis. The patients may have subtle, early stage undiagnosed ocular disease as the cause of their visual complaint, but, sometimes, the visual loss in these patients has a psychosocial basis. These patients with "unexplained visual loss" are commonly referred to a neuro-ophthalmologist, since, if there is no visible pathology, an underlying neurological cause for their visual loss has to be excluded. Moreover, OCT may reveal structural macular abnormalities. However, to evaluate retinal function electrophysiology is the ideal approach. Since the visual symptoms may precede the diagnosis of a systemic disorder, as described in Papers I and IV, these patients are really challenging for the clinician.

In this thesis, the studies elucidate "when nothing is seen" for neither the patient nor the ophthalmologist. Due to electrophysiology with full-field ERG and mfERG, it was possible to obtain diagnoses and explain the symptoms of the patients. Thereby, psychosocial basis for the visual loss, which was suspected in Papers I and IV, could be ruled out.

Spinocerebellar ataxia type 7

SCA 7 (MIM: 164500) is a rare autosomal dominant neurodegenerative disorder characterized by progressive neurological manifestations, including cerebellar ataxia and progressive retinal dystrophy with central visual loss. Eventually the patients may develop more extensive neurological deficits, including difficulties with manual dexterity and speech, dysarthria, dysphagia and eye movement abnormalities that can progress to frank ophthalmoplegia (Garden et al 2008, Klockgether 2008, Gupta et al 2008, Tsivgoulis et al 2008). While the estimated worldwide prevalence of SCA 7 is less than 1/100 000, higher prevalence is described in Scandinavia (Jonasson et al 2000).

SCA 7 is caused by a heterozygous expanded CAG trinucleotide repeat in the *ataxin 7 (ATXN7)* gene (MIM: 607640), also known as the *SCA 7* gene, on chromosome 3p14, encoding a polyglutamine tract in the protein ataxin-7. The onset of SCA 7 ranges from infancy to the sixth decade with a correlation between the number of CAG repeats and disease severity - the longer the CAG repeat, the earlier age of onset and the more severe disease (Johansson et al 1998). As in other trinucleotide repeat disorders, such as Huntington's disease, genetic anticipation, defined as increasing disease severity in successive generations of an affected kindred, has been observed, particularly during paternal transmission (David et al 1997, Stoyas et al 2018). On mutated alleles, CAG repeat size is highly variable, and alleles with > 36 CAG repeats are considered fully penetrant (David et al 1997, Rüb et al 2008).

Ataxin-7 is predominantly nuclear, but shuttles between the nucleus and cytoplasm. One function of ataxin-7 is its role as a core component of a transcription co-activator complex called STAGA (SPT3-TAF9-ADA-GCN5

acetyltransferase) (Garden et al 2008). Ataxin-7 also associates with microtubules and stabilizes the cytoskeletal network (Nakamura et al 2012). Normal ataxin-7 is widely expressed in brain, retina and peripheral tissues, including striated muscle, testis and thyroid gland (Cancel et al 2000). One hypothesis is that pathology is caused by polyglutamine expansion in ataxin-7 which confers toxic properties and leads to selective neuronal degeneration in the cerebellum, the brain stem and the retina (Guyenet et al 2015, Karam et al 2018).

The findings in Paper I indicate that the visual disturbance in patients with SCA 7 is associated with early macular dysfunction, preceding any signs of abnormalities in fundus appearance. Lately, normal fundus examination in SCA 7 has also been described by other authors (Horton et al 2013, Mahale et al 2017). According to the electrophysiological outcome in Paper I, the primary dysfunction involves the cones in the foveal region. However, in an older patient, cone dysfunction throughout the retina was verified. Since full-field ERG demonstrated normal rod responses in all patients, our results might be in accordance with the studies of SCA 7 which have revealed marked cone dysfunction throughout the retina prior to any rod abnormality (Abe et al 2000, Lin et al 2008). This widespread loss of cone function ahead of rod function implies the retinal degeneration in SCA 7 to be classified as a cone-rod dystrophy (Yagasaki et al 1989, La Spada et al 2001, Aleman et al 2002, Ben-Arie-Weintrob et al 2005).

Ataxin-7 has been described to mediate a direct interaction of STAGA with CRX (cone-rod homeobox) (Palhan et al 2005). CRX, a nuclear transcription factor, is predominantly expressed in retinal photoreceptors and controls the expression level of numerous photoreceptor specific genes, including rhodopsin and the colour opsins. Mutations in the *CRX* gene (MIM: 602225)

cause autosomal dominant cone-rod dystrophy type II and Leber's congenital amaurosis (LCA), the LCA phenotype is then described as early cone rod degeneration and therefore possibly comparable to SCA 7 associated retinal dysfunction, primarily affecting the cone function (Swaroop et al 1999). It is thus suggested that CRX transcription interference accounts for the retinal degeneration in SCA 7 (Freund et al 1997, La Spada et al 2001).

Retinitis pigmentosa

RP (MIM: 268000) refers to a heterogeneous group of inherited ocular diseases that result in progressive retinal degeneration with an estimated prevalence of 1/ 4 000, thus placing RP as the leading cause of inherited blindness (Verbakel et al 2018). Symptoms include photophobia, decreased night vision (nyctalopia), loss of the midperipheral visual field and, as the disease progresses, loss of far peripheral visual field, increase of tunnel vision and, eventually, loss of central vision as well (Hartong et al 2006). The symptoms are caused by the initial degeneration of rod photoreceptors and, later, cone photoreceptor decline with reduced VA and colour vision. The progression of disease symptoms occurs bilaterally in an approximately symmetrical manner.

At ophthalmological examination RP is characterized by decreased VA, constricted visual fields, dyschromatopsia and the classic fundus appearance with dark pigmentary clumps in the midperiphery and perivenous areas ("bone spicules"), attenuated retinal vessels, cystoid macular edema and waxy optic disc pallor (Hajali et al 2008, Verbakel et al 2018). RP is sometimes associated with posterior subcapsular cataract, high myopia, astigmatism, keratoconus and mild hearing loss. Early-onset RP occurs within the first few

years of life and is typically associated with syndromic disease forms while late-onset RP emerges from early to mid-adulthood (Sieving et al 1995, Soumplis et al 2013, Arno et al 2017). According to Hartong et al (2006), 50-60% of RP is inherited autosomal recessive, 30-40% of RP is inherited autosomal dominant and 5-15% is inherited as an X-linked trait.

To date, mutations in at least 60 genes may cause RP, and, of these, 22 genes have been associated with autosomal dominant forms of RP (see RetNet website, Dryja et al 1990, Dryja et al 1991, Sullivan et al 2006, Daiger et al 2007, Sullivan et al 2013). The adRP genes encode proteins involved in diverse biological functions. However, most genetic defects in adRP genes specifically lead to photoreceptor degeneration (Sancho-Pelluz et al 2008). Although multiple causes of photoreceptor dysfunction have been proposed the biochemical mechanism(s) of most forms of adRP still remain to be elucidated.

Paper II describes the mapping of a novel adRP locus (RP42, [MIM: 612943]) by whole-genome scan of a large six-generation Scandinavian family and the identification of three disease-causing mutations in the *KLHL7* gene (MIM: 611119). The first clinical characterization of the adRP phenotype linked to mutation in the *KLHL7* gene is described in Paper III. Follow-up, with time ranging up to 17 years, revealed slowly progressive retinal degeneration and, in some family members, late onset and preserved rod function until late in life, which differs from the classic form of adRP with early and often rapid decline of rod function. Note, in Paper III, normal fundus appearance was observed in early stages of adRP, such as in one 34-year-old patient.

Subsequently, Wen et al in 2011 characterized the phenotype in patients with adRP caused by all the three disease-causing *KLHL7* mutations identified in

Paper II. Their results confirmed the findings of Paper III, i.e. late onset, slow progression, and, in addition, they noted strong retention of foveal function and bilateral concentric constriction of the visual fields with far periphery sparing. In 2016, Angius et al described two children with early onset RP (before 6 years of age) carrying bi-allelic *KLHL7* mutations located close to or within the Kelch domain. Consequently, in contrast to the three mutations identified in Paper II which are clustered in the BACK domain. Angius et al concluded that *KLHL7* mutations could thus show greater severity in recessive than in dominant cases. The retinal phenotype in their study was evaluated with eye examination, fundus photography and sweep VEP to estimate the VA, but, unfortunately, ERG was not obtained due to noncooperation of the probands.

KLHL7 is widely expressed in human tissues, including rod photoreceptors, and the physiologic function of the protein is not yet well understood. Based on the presence of BTB and Kelch domains, in Paper II this protein was hypothesized to stabilize the formation of Cullin ubiquitin ligating enzyme (E3) ligase complexes in the retina (Sumara et al 2008). Hence, mutations in the BACK domain of *KLHL7* affect the ability to act as an intermediary or chaperone between E3 ligase and its substrate. Failure to do so could result in accumulation of the substrate(s) or aggregates, leading to cellular toxicity within the photoreceptors and retinal degeneration (Rubinsztein 2006, Tai et al 2008). In 2011, Kigoshi et al supported this hypothesis by presenting *KLHL7* as the substrate recognition subunit of the Cullin 3-based ubiquitin ligase complex and showed that the adRP causative p.A153V mutation inhibits the ligase activity.

At present, there is no cure for RP, but the efficacy and safety of various prospective treatments are currently being evaluated. Studies have

demonstrated that proper vitamin A supplementation can delay rod photoreceptor degeneration and postpone blindness in some patients in certain stages of the disease (Berson et al 1993, Berson et al 2007). The Argus retinal prosthesis became the first approved treatment for RP in 2011 and is currently available in some countries, including Germany (Stingl et al 2013). The goal of gene therapy studies is to virally supplement retinal cells expressing mutant genes associated with the RP phenotype with healthy forms of the gene, thus allowing the repair and proper functioning of retinal photoreceptor cells. Clinical trials have been done investigating the insertion of the healthy *RPE65* gene (MIM: 180069) in patients expressing the LCA retinal phenotype (Bainbridge et al 2008, Maguire et al 2009, Bainbridge et al 2015). Possible treatments remain in the research and clinical trial stages, and future treatments may involve gene therapy, artificial retinal implants, stem cells, nutritional supplements, retinal transplants, and/or drug therapies.

Cancer associated retinopathy

CAR, first described by Sawyer et al in 1976, is an uncommon paraneoplastic retinal disorder that often leads to blindness in association with various systemic cancers, most commonly small cell lung carcinoma, breast cancer and gynaecologic cancer (Adamus 2015). In many cases, visual loss from CAR precedes the diagnosis of cancer (Heckenlively et al 2008, Adamus 2009).

Patients with CAR usually present with a progressive loss of vision over a few weeks to months and often bilaterally but may be asymmetric. At the initial consultation with an ophthalmologist, the medical history shows no obvious cause for the disorder. At examination, reduced VA and visual field

defects are noticed, but fundus appearance and fluorescein angiography are usually normal. CAR is therefore really challenging for the clinician, and the patients are often diagnosed with "unexplained visual loss" as described in Paper IV. However, full-field ERG almost always demonstrates abnormal findings with reduction of both rod and cone responses, which was the case in Paper IV. Selective cone dysfunction has also been described though (Scholl et al 2000, Weleber et al 2005, Khan et al 2006). Since the visual symptoms may precede the diagnosis of cancer, and since there is no specific diagnostic tool, it is very difficult to reveal the diagnosis CAR. However, during the last years the number of individuals with suspected CAR has been continuously increasing, owing to growing awareness amongst physicians and improved diagnostic tools and criteria (Adamus 2015).

It has been observed that some proteins that are normally restricted to retina, an immune-privileged site, are also ectopically expressed in some type of cancers. The pathogenesis of CAR is believed to be a cross-reactivity of the immune system against tumours and normal tissues, thus with an abnormal response of the immune system against normal tissues either by the production of AAbs or auto-reactive T cells (Backes et al 2011, Miska et al 2012). These AAbs are believed to suppress the growth of the malignancy (Albert et al 2004), but the AAbs may also impact the retina by inducing apoptosis of photoreceptor cells, which leads to retinal degeneration (Adamus et al 1997, Adamus et al 1998, Adamus et al 2004). It has been observed that patients with CAR possess different AAbs that react with specific retinal proteins, including for example recoverin (23 kDa) and α -enolase (46 kDa) (Adamus et al 2004). However, positive titer of AAbs alone does not give the diagnosis of CAR since AAbs can be found in the normal population and in patients with non-paraneoplastic autoimmune retinopathy.

Antiretinal antibody tests are now commercially available. Still though, there may be many more antibodies against different retinal proteins that have not yet been identified (Bredholt et al 2006). Paper IV reports on the identification of AIPL1 as a novel retinal autoantigen in a patient with osteosarcoma and CAR. AIPL1, encoded by the *AIPL1* gene (MIM: 604392), is a protein that is highly expressed in retina and specifically localized within the photoreceptors (Akey et al 2002). It has been suggested that AIPL1 plays a role in photoreceptor development (van der Spuy et al 2003) and may be important in protein trafficking, folding and stabilization (Ramamurthy et al 2003, Hidalgo-de-Quintana et al 2008, Majumder et al 2013).

Interestingly, mutations in the *AIPL1* gene have previously been reported to cause the devastating blinding disease LCA (MIM: 604393) and account for approximately 5-10% of all LCA cases (Sohocki et al 2000). LCA is a severe congenital or early onset inherited retinal dystrophy that classically presents with flat ERGs and minimal, if any, vision beyond infancy (Cremers et al 2002). To note, in patients with *AIPL1* mutations, the fundus appearance can appear normal early in the disease (Dharmaraj et al 2004, Pennesi et al 2011, Tan et al 2012) similar to the CAR patient in Paper IV. The identification of AIPL1 as a novel CAR autoantigen thereby introduces CAR as an acquired autoimmune phenocopy of the inherited disorder LCA (Ludwig 2013).

Long term immunosuppression is the main therapy for CAR (Ferreira et al 2009). The treatment may provide mild to moderate transient VA and visual field improvement, but overall there is no significant long-lasting improvement. The visual prognosis remains poor, ranging from progressive visual loss to blindness. Sadly, treatment of the cancer usually does not lead to improvement of the vision.

The teenage girl described in Paper IV underwent amputation of her right leg due to the osteosarcoma. Osteosarcoma is a bone malignancy, most prevalent in teenagers and young adults. The vast majority are aggressive with an elevated tendency for metastatic spread to the lungs. The survival rates five years after diagnosis are estimated to be 60-70% for patients with non-metastatic disease but only 10-30% for patients with metastatic disease at initial diagnosis (Harris et al 1998). Today, more than eight years after the patient described in Paper IV underwent amputation, she is still blind in both eyes. Happily, she has given birth to twins, lives her life with a positive attitude and is dedicated to the work to prevent cancer.

To my knowledge, this is the first described case with osteosarcoma in CAR. The importance of comprehensive tests for AAbs is highlighted in order to reveal the cancer diagnosis and also to explain the visual symptoms, enabling earlier treatment.

CONCLUSIONS

In most cases, retinal appearance and structure go hand in hand with retinal function. However, in some cases, the fundus appearance is normal in spite of retinal dysfunction. For an objective assessment of the retinal function, electrophysiology is therefore important "when nothing is seen" and is central to understanding the symptoms described by the patient, revealing the correct diagnosis and, hopefully, to treating and/or easing the condition. In this thesis, various diseases with different pathogeneses have been revealed, and underlying mechanisms have been newly identified.

Specific conclusions

Paper I

The patients presented an early macular dysfunction, preceding any signs of abnormalities in fundus appearance and were diagnosed with genetically confirmed SCA 7. The electrophysiological findings were consistent with cone-rod dystrophy.

Paper II

In a six-generation Scandinavian family a disease-causing mutation, c.449G→A (p.S150N), was identified in exon 6 of the *KLHL7* gene. Thus, a

newly identified adRP gene. Mutation screening of *KLHL7* revealed three different missense mutations in six independent families.

Paper III

The first described clinical examination of patients with adRP caused by mutation in the recently identified *KLHL7* gene. Long-term follow-up verified a phenotype with slowly progressive retinal degeneration and in some family members with late onset.

Paper IV

"Unexplained visual loss" was reported but electrophysiology verified extensive retinal dysfunction. Subsequent tests revealed osteosarcoma and CAR, with identification of AIPL1 as the novel retinal autoantigen. To my knowledge not earlier described.

ACKNOWLEDGEMENTS

I would like to express my sincere gratitude to all who have helped me on the way towards this achievement. Especially I want to mention and thank:

Associate Professor Ulrica Englund Johansson, my supervisor, for your wide ranging knowledge, great ambition, empathy and true goodwill.

My co-supervisor Patrik Schatz, MD, PhD, for your depth of knowledge, analytical ability, kindness and impressive availability.

Assistant Senior Lecturer Maria Swanberg, my co-supervisor, for interesting contributions, fruitful remarks and introducing me to genetics.

Professor Sten Andréasson for guiding me to the wonderful specialty Ophthalmology already in 1996 – I have never regretted my choice.

Satpal Ahuja, MVSc, PhD, FNAVS (India), for considerate, encouraging discussions and interesting contributions. Thanks for your dedication in supporting me to write this thesis.

Boel Nilsson, Ing-Marie Holst and Susanne Boystrom, research nurses at the Department of Ophthalmology in Lund, for skillful technical assistance, teamwork and enthusiasm.

Professor Fredrik Ghosh for your cool, enjoyable and positive attitude as well as for excellent illustrations.

Researchers, colleagues and friends at BMC B11 for stimulating discussions in a warm, tolerant and positive atmosphere.

All the patients involved for participation, cooperation and patience.

Professor Eberhart Zrenner, for giving me a guest researcher fellowship at the Division of Experimental Ophthalmology at the University Eye Hospital in Tübingen, Germany. I had a great time during your excellent leadership!

Professor Andre Messias for your kindness and outstanding intelligence, teaching me electrophysiology and statistics in Tübingen.

Assistant Professor James Friedman and Professor Anand Swaroop, National Institutes of Health (NIH), United States, for extremely educational and very interesting cooperation with Papers II and III.

Frida Dalin, PhD, and Mohammad Alimohammadi, MD, PhD, for cooperation and strenuous work with Paper IV.

Lolita Jönsson, Head of Ophthalmology clinic in Kristianstad, for giving me the opportunity to write my thesis. You let me progress, take up and try to meet new challenges and allow me to grow.

Professor Karin Jirström for your empathy, believe in me, extraordinary courage and fair-minded attitude.

My mentor Magnus Hägerdal, MD, PhD, for listening, coaching and giving the best advices with your analytical ability, excellent leadership, empathy and true goodwill.

My dear friends and advisors Kajsa Wettrell, MD, PhD, and Göran Wettrell, MD, PhD, for all the innumerable discussions about work and life. You went by car all the way to Tübingen to visit me and bring Swedish food, books and music. Thanks for everything!

Professor Håkan Hydén for believing in me, being there for me (“Lill-Therése”) with your professional attitude and empathy at a time when I really needed you.

Marika Lindvall, MD. You are my star, my golden star.

Charlotta Böiers, MD, PhD, and Mattias Holmer, PhD, for being true friends for better for worse encouraging me with cheer.

Noah and Theo for your youthful energy and quick bright responses.

Theodor - my wonderful brother and closest friend. You are ALWAYS there for me - listening, supporting, finding possibilities and giving good advices. Always with your warm heart and calm attitude. You are great!

My mother and father for always being there (whatever, whenever, wherever) - loving, supporting, encouraging and believing in me. You are incredible!

Olof – last but certainly not least – the man in my life. MY WARM THANKS for love, support, patience, energy, happiness,

The work in this thesis was supported by ALF Funds, the Faculty of Medicine, Lund University, the Swedish Medical Research Council, the Foundation Fighting Blindness, Owings Mills, Maryland, the Swedish Association of the Visually Impaired, the National Eye Institute, National Institutes of Health, Harold F. Falls and Paul R. Lichter Professorships, Research to Prevent Blindness, the Elmer and Sylvia Sramek Foundation, the European Union (GENORET), the British Retinitis Pigmentosa Society, the NIHR Biomedical Research Centre for Ophthalmology, the Torsten and Ragnar Söderberg Foundation, the Novo Nordisk Foundation, Bagsværd and the Swedish Research Council, Stockholm.

REFERENCES

- Abe T, Tsuda T, Yoshida M, et al. Macular degeneration associated with aberrant expansion of trinucleotide repeat of the SCA7 gene in 2 Japanese families. *Arch Ophthalmol*. 2000;118(10): 1415–1421.
- Abecasis GR, Cherny SS, Cookson WO, Cardon LR. Merlin—rapid analysis of dense genetic maps using sparse gene flow trees. *Nat Genet*. 2002;30: 97–101.
- Adamus G, Machnicki M, Elerding H, Sugden B, Blocker YS, Fox DA. Antibodies to recoverin induce apoptosis of photoreceptor and bipolar cells in vivo. *J Autoimmun*. 1998;11: 523-533.
- Adamus G, Machnicki M, Seigel GM. Apoptotic retinal cell death induced by autoantibodies of cancer associated retinopathy. *Invest Ophthalmol Vis Sci*. 1997;38: 283-291.
- Adamus G, Ren G, Weleber RG. Autoantibodies against retinal proteins in paraneoplastic and autoimmune retinopathy. *BMC Ophthalmol*. 2004;4:5.
- Adamus G. Autoantibody targets and their cancer relationship in the pathogenicity of paraneoplastic retinopathy. *Autoimmun Rev*. 2009;8(5): 410-414.
- Adamus G. Latest updates on antiretinal autoantibodies associated with vision loss and breast cancer. *Invest Ophthalmol Vis Sci*. 2015;56(3): 1680-1688.
- Akey DT, Zhu X, Dyer M, et al. The inherited blindness associated protein AIPL1 interacts with the cell cycle regulator protein NUB1. *Hum Mol Genet*. 2002;11(22): 2723-2733.
- Akimoto M, Cheng H, Zhu D, et al. Targeting of GFP to newborn rods by Nrl promoter and temporal expression profiling of flow-sorted photoreceptors. *Proc Natl Acad Sci U S A*. 2006;103: 3890–3895.
- Albert ML, Darnell RB. Paraneoplastic neurological degenerations: keys to tumour immunity. *Nat Rev Cancer* 2004;4: 36–44.
- Aleman TS, Cideciyan AV, Volpe NJ, et al. Spinocerebellar ataxia type 7 (SCA7) shows a cone-rod dystrophy phenotype. *Exp Eye Res*. 2002;74(6): 737–745.
- Andréasson S, Sandberg MA, Berson EL. Narrow-band filtering for monitoring low-amplitude cone electroretinograms in retinitis pigmentosa. *Am J Ophthalmol*. 1988;105(5): 500-503.
- Andréasson S. Electroretinographic studies of families with dominant retinitis pigmentosa. *Acta Ophthalmol*. 1991;69: 162–168.

- Angius A, Uva P, Buers I, et al. Bi-allelic Mutations in *KLHL7* Cause a Crisponi/CISS1-like Phenotype Associated with Early-Onset Retinitis Pigmentosa. *Am J Hum Genet.* 2016;99(1): 236-245.
- Arno G, Carss KJ, Hull S, et al. Biallelic Mutation of *ARHGEF18*, Involved in the Determination of Epithelial Apicobasal Polarity, Causes Adult-Onset Retinal Degeneration. *Am J Hum Genet.* 2017;100(2): 334-342.
- Backes C, Ludwig N, Leidinger P, et al. Immunogenicity of autoantigens. *BMC Genomics* 2011;12: 340.
- Bainbridge JW, Mehat MS, Sundaram V, et al. Long-term effect of gene therapy on Leber's congenital amaurosis. *N Engl J Med.* 2015;372(20): 1887-1897.
- Bainbridge JW, Smith AJ, Barker SS, et al. Effect of Gene Therapy on Visual Function in Leber's Congenital Amaurosis. *N Engl J Med* 2008;358 (21): 2231–2239.
- Bearse MA, Sutter EE. Imaging localized retinal dysfunction with the multifocal electroretinogram. *J Opt Soc Am Assoc.* 1996;13: 634–640.
- Ben-Arie-Weintrob Y, Berson EL, Dryja TP. Histopathologic genotypic correlations in retinitis pigmentosa and allied diseases. *Ophthalmic Genet.* 2005;26(2): 91–100.
- Berson EL, Rosner B, Sandberg MA, et al. A Randomized Trial of Vitamin A and Vitamin E Supplementation for Retinitis Pigmentosa. *Arch Ophthalmol.* 1993;111: 761-772.
- Berson EL. Long-term visual prognoses in patients with retinitis pigmentosa: The Ludwig von Sallmann lecture. *Exp Eye Res.* 2007;85(1): 7–14.
- Bredholt G, Storstein A, Haugen M, et al. Detection of autoantibodies to the BTB-kelch protein *KLHL7* in cancer sera. *Scand J Immunol.* 2006;64: 325–335.
- Brown KT. The electroretinogram: its components and their origins. *Vision Res.* 1968;8(6): 633-677.
- Cancel G, Duyckaerts C, Holmberg M, et al. Distribution of ataxin-7 in normal human brain and retina. *Brain* 2000;12: 2519-2530.
- Creel DJ. Clinical Electrophysiology. Webvision: The Organization of the Retina and Visual System. 2005;Last Update: July 2, 2007.
- Cremers FP, van den Hurk JA, den Hollander AI. Molecular genetics of Leber congenital amaurosis. *Hum Mol Genet.* 2002;11(10): 1169-1176.
- Curcio CA, Sloan KR, Kalina RE, Hendrickson AE. Human photoreceptor topography. *J Comp Neurol.* 1990;292(4): 497-523.
- Daiger SP, Bowne SJ, Sullivan LS. Perspective on genes and mutations causing retinitis pigmentosa. *Arch Ophthalmol.* 2007;125(2):151-158.
- David G, Abbas N, Stevanin G, et al. Cloning of the *SCA7* gene reveals a highly unstable CAG repeat expansion. *Nat Genet.* 1997;17(1):65–70.
- Dharmaraj S, Leroy BP, Sohocki MM, et al. The phenotype of Leber congenital amaurosis in patients with *AIPL1* mutations. *Arch Ophthalmol.* 2004;122(7): 1029-1037.

- Dryja TP, Hahn LB, Cowley GS, McGee TL, Berson EL. Mutation spectrum of the rhodopsin gene among patients with autosomal dominant retinitis pigmentosa. *Proc Natl Acad Sci U S A*. 1991;88(20): 9370-9374.
- Dryja TP, McGee TL, Reichel E, et al. A point mutation of the rhodopsin gene in one form of retinitis pigmentosa. *Nature* 1990;343: 364–366.
- Ferreya HA, Jayasundera T, Khan NW, He S, Lu Y, Heckenlively JR. Management of autoimmune retinopathies with immunosuppression. *Arch Ophthalmol*. 2009;127(4): 390-397.
- Freund CL, Gregory-Evans CY, Furukawa T, et al. Cone-rod dystrophy due to mutations in a novel photoreceptor-specific homeobox gene (CRX) essential for maintenance of the photoreceptor. *Cell* 1997;14;91(4): 543–553.
- Friedman JS, Chang B, Kannabiran C, et al. Premature truncation of a novel protein, RD3, exhibiting subnuclear localization is associated with retinal degeneration. *Am J Hum Genet*. 2006;79: 1059–1070.
- Garden GA, La Spada AR. Molecular pathogenesis and cellular pathology of spinocerebellar ataxia type 7 neurodegeneration. *Cerebellum* 2008;12.
- Granit R. The components of the retinal action potential in mammals and their relation to the discharge in the optic nerve. *J Physiol*. 1933;77: 207–239.
- Gupta SN, Marks HG. Spinocerebellar ataxia type 7 mimicking Kearns-Sayre syndrome: A clinical diagnosis is desirable. *J Neurol Sci*. 2008;15;264(1–2): 173–176.
- Guyenet SJ, Mookerjee SS, Lin A, et al. Proteolytic cleavage of ataxin-7 promotes SCA7 retinal degeneration and neurological dysfunction. *Hum Mol Genet*. 2015;24(14): 3908-3917.
- Hajali M, Fishman GA, Anderson RJ. The prevalence of cystoid macular oedema in retinitis pigmentosa patients determined by optical coherence tomography. *Br J Ophthalmol*. 2008;92(8): 1065-1068.
- Harris MB, Gieser P, Goorin AM, et al. Treatment of metastatic osteosarcoma at diagnosis: a Pediatric Oncology Group Study. *J Clin Oncol*. 1998;16(11): 3641-3648.
- Hartong DT, Berson EL, Dryja TP. Retinitis pigmentosa. *Lancet* 2006;368: 1795–1809.
- Heckenlively JR, Ferreyra HA. Autoimmune retinopathy: a review and summary. *Semin Immunopathol*. 2008;30(2): 127-134.
- Hee MR, Izatt JA, Swanson EA, et al. Optical coherence tomography of the human retina. *Arch Ophthalmol*. 1995;113(3): 325-332.
- Hidalgo-de-Quintana J, Evans RJ, Cheetham ME, van der Spuy J. The Leber congenital amaurosis protein AIPL1 functions as part of a chaperone heterocomplex. *Invest Ophthalmol Vis Sci*. 2008;49: 2878–2887.
- Holmgren F. En metod att objektivera effekten av ljusintyck på retina. *Upsala Lakfor*. 1865;1: 177–191.

- Hood DC, Bach M, Brigell M, et al. ISCEV guidelines for clinical multifocal electroretinography (2007 edition). *Doc Ophthalmol.* 2008;116(1): 1-11.
- Hood DC, Bach M, Brigell M, et al. ISCEV standard for clinical multifocal electroretinography (mfERG) (2011 edition). *Doc Ophthalmol.* 2012;124(1): 1-13.
- Horton LC, Frosch MP, Vangel MG, Weigel-DiFranco C, Berson EL, Schmahmann JD. Spinocerebellar ataxia type 7: clinical course, phenotype-genotype correlations, and neuropathology. *Cerebellum* 2013;12(2): 176-193.
- Huang D, Swanson EA, Lin CP, et al. Optical coherence tomography. *Science* 1991;254(5035): 1178-1181.
- Johansson J, Forsgren L, Sandgren O, et al. Expanded CAG repeats in Swedish spinocerebellar ataxia type 7 (SCA7) patients: Effect of CAG repeat length on the clinical manifestation. *Hum Mol Genet.* 1998;7(2): 171–176.
- Jonasson J, Juvonen V, Sistonen P, et al. Evidence for a common spinocerebellar ataxia type 7 (SCA7) founder mutation in Scandinavia. *Europ J Hum Genet.* 2000;8: 918-922.
- Karam A, Trottier Y. Molecular Mechanisms and Therapeutic Strategies in Spinocerebellar Ataxia Type 7. *Adv Exp Med Biol.* 2018;1049: 197-218.
- Karpe G. Apparatus and method for clinical recording of the electroretinogram. *Doc Ophthalmol.* 1948;2(1): 268-276.
- Khan N, Huang JJ, Foster CS. Cancer associated retinopathy (CAR): An autoimmune-mediated paraneoplastic syndrome. *Semin Ophthalmol.* 2006;21(3): 135-141.
- Kigoshi Y, Tsuruta F, Chiba T. Ubiquitin ligase activity of Cul3-KLHL7 protein is attenuated by autosomal dominant retinitis pigmentosa causative mutation. *J Biol Chem.* 2011;286(38): 33613-33621.
- Klockgether T. The clinical diagnosis of autosomal dominant spinocerebellar ataxias. *Cerebellum* 2008;12.
- Kolb H, Fernandez E, Nelson R, editors. *Webvision: The Organization of the Retina and Visual System.* Salt Lake City (UT): University of Utah Health Sciences Center; 1995-. <http://webvision.med.utah.edu/>.
- La Spada AR, Fu YH, Sopher BL, et al. Polyglutamine-expanded ataxin-7 antagonizes CRX function and induces cone-rod dystrophy in a mouse model of SCA7. *Neuron* 2001;31(6): 913–927.
- Lin Y, Zheng JY, Jin YH, Xie YC, Jin ZB. Trinucleotide expansions in the SCA7 gene in a large family with spinocerebellar ataxia and craniocervical dystonia. *Neurosci Lett.* 2008;434(2): 230–233.
- Ludwig RJ. Clinical presentation, pathogenesis, diagnosis, and treatment of epidermolysis bullosa acquisita. *ISRN Dermatol.* 2013;2013: 812029.
- Maguire AM, High KA, Auricchio A, et al. Age-dependent effects of RPE65 gene therapy for Lebers congenital amaurosis: a phase 1 dose-escalation trial. *Lancet* 2009;374(9701): 1597–1605.

- Mahale RR, Mehta A, Miryala A, Srinivasa R. Spinocerebellar ataxia type 7 sans retinal degeneration: A phenotypic variability. *Ann Indian Acad Neurol.* 2017;20: 438-439.
- Majumder A, Gopalakrishna KN, Cheguru P, Gakhar L, Artemyev NO. Interaction of aryl hydrocarbon receptor-interacting protein-like 1 with the farnesyl moiety. *J Biol Chem.* 2013;288(29): 21320-21328.
- Marmor MF, Holder GE, Seeliger MW, Yamamoto S. Standard for clinical electroretinography (2004 update). *Doc Ophthalmol.* 2004;108: 107–114.
- McCulloch DL, Marmor MF, Brigell MG, et al. ISCEV Standard for full-field clinical electroretinography (2015 update). *Doc Ophthalmol.* 2015;130(1): 1-12.
- Miska J, Bas E, Devarajan P, Chen Z. Autoimmunity-mediated antitumor immunity: tumor as an immunoprivileged self. *Eur J Immunol.* 2012;42: 2584–2596.
- Murthy RK, Haji S, Sambhav K, Grover S, Chalam KV. Clinical applications of spectral domain optical coherence tomography in retinal diseases. *Biomed J.* 2016;39(2): 107-120.
- Nakamura Y, Tagawa K, Oka T, et al. Ataxin-7 associates with microtubules and stabilizes the cytoskeletal network. *Hum Mol Genet.* 2012;21: 1099-1110.
- Newman EA, Odette LL. Model of electroretinogram b-wave generation: a test of the K+ hypothesis. *J Neurophysiol.* 1984;51(1): 164-182.
- Oyster CW. *The Human Eye: Structure and Function.* Sinauer Associates 1999.
- Palhan VB, Chen S, Peng GH, et al. Polyglutamine-expanded ataxin-7 inhibits STAGA histone acetyltransferase activity to produce retinal degeneration. *Proc Natl Acad Sci U S A.* 2005;102(24): 8472-8477.
- Pennesi ME, Stover NB, Stone EM, Chiang PW, Weleber RG. Residual electroretinograms in young Leber congenital amaurosis patients with mutations of AIPL1. *Invest Ophthalmol Vis Sci.* 2011;52(11): 8166-8173.
- Podoleanu AG. Optical coherence tomography. *J Microsc.* 2012;247(3): 209-219.
- Ramamurthy V, Roberts M, van den Akker F, Niemi G, Reh TA, Hurley JB. AIPL1, a protein implicated in Leber's congenital amaurosis, interacts with and aids in processing of farnesylated proteins. *Proc Natl Acad Sci U S A.* 2003;100: 12630–12635.
- RetNet: Retinal Information Network. <http://www.sph.uth.tmc.edu/Retnet/>.
- Rüb U, Brunt ER, Seidel K, et al. Spinocerebellar ataxia type 7 (SCA7): widespread brain damage in an adult-onset patient with progressive visual impairments in comparison with an adult-onset patient without visual impairments. *Neuropathol Appl Neurobiol.* 2008;34(2): 155–168.
- Rubinsztein DC. The roles of intracellular protein degradation pathways in neurodegeneration. *Nature* 2006;443: 780–786.
- Ruschendorf F, Nurnberg P. ALOHOMORA: A tool for linkage analysis using 10K SNP array data. *Bioinformatics* 2005;21: 2123–2125.

- Sancho-Pelluz J, Arango-Gonzalez B, Kustermann S, et al. Photoreceptor cell death mechanisms in inherited retinal degeneration. *Mol Neurobiol.* 2008;38: 253–269.
- Sawyer RA, Selhorst JB, Zimmerman LE, Hoyt WF. Blindness caused by photoreceptor degeneration as a remote effect of cancer. *Am J Ophthalmol.* 1976;81(5): 606-613.
- Scholl HP, Zrenner E. Electrophysiology in the investigation of acquired retinal disorders. *Surv Ophthalmol.* 2000;45(1): 29-47.
- Sieving PA, Richards JE, Naarendorp F, Bingham EL, Scott K, Alpern M. Darklight: model for nightblindness from the human rhodopsin Gly-90→Asp mutation. *Proc Natl Acad Sci U S A.* 1995;92(3): 880-884.
- Sohocki MM, Perrault I, Leroy BP, et al. Prevalence of AIPL1 mutations in inherited retinal degenerative disease. *Mol Genet Metab.* 2000;70(2): 142-150.
- Soumpelis V, Sergouniotis PI, Robson AG, et al. Phenotypic findings in C1QTNF5 retinopathy (late-onset retinal degeneration). *Acta Ophthalmol.* 2013;91(3): e191-195.
- Stingl K, Bartz-Schmidt KU, Besch D, et al. Artificial vision with wirelessly powered subretinal electronic implant alpha-IMS. *Proc Biol Sci.* 2013;280(1757): 20130077.
- Stogios PJ, Prive GG. The BACK domain in BTB-kelch proteins. *Trends Biochem Sci.* 2004;29: 634–637.
- Stoyas CA, La Spada AR. The CAG-polyglutamine repeat diseases: a clinical, molecular, genetic, and pathophysiologic nosology. *Handb Clin Neurol.* 2018;147: 143-170.
- Sullivan LS, Bowne SJ, Birch DG, et al. Prevalence of disease causing mutations in families with autosomal dominant retinitis pigmentosa: A screen of known genes in 200 families. *Invest Ophthalmol Vis Sci.* 2006;47: 3052–3064.
- Sullivan LS, Bowne SJ, Reeves MJ, et al. Prevalence of mutations in eyeGENE probands with a diagnosis of autosomal dominant retinitis pigmentosa. *Invest Ophthalmol Vis Sci.* 2013;54(9): 6255-6261.
- Sumara I, Maerki S, Peter M. E3 ubiquitin ligases and mitosis: Embracing the complexity. *Trends Cell Biol.* 2008;18: 84–94.
- Sutter EE, Tran D. The field topography of ERG components in man. I. The photopic luminance response. *Vision Res.* 1992;32: 433–446.
- Swaroop A, Wang QL, Wu W, et al. Leber congenital amaurosis caused by a homozygous mutation (R90W) in the homeodomain of the retinal transcription factor CRX: direct evidence for the involvement of CRX in the development of photoreceptor function. *Hum Mol Genet.* 1999;8(2): 299–305.
- Tai HC, Schuman EM. Ubiquitin, the proteasome and protein degradation in neuronal function and dysfunction. *Nature reviews* 2008;9: 826–838.

- Tan MH, Mackay DS, Cowing J, et al. Leber congenital amaurosis associated with AIPL1: challenges in ascribing disease causation, clinical findings, and implications for gene therapy. *PLoS One* 2012;7(3): e32330.
- Tsivgoulis G, Vassilopoulou S, Rallis K, Markomichelakis N, Spengos K. Spinocerebellar ataxia type 7 presenting as Stargardt's disease. *J Neurol.* 2008;255(3): 456–458.
- Uchida K, Akita Y, Matsuo K, et al. Identification of specific autoantigens in Sjögren's syndrome by SEREX. *Immunology* 2005;116(1): 53-63.
- van der Spuy J, Kim JH, Yu YS, et al. The expression of the Leber congenital amaurosis protein AIPL1 coincides with rod and cone photoreceptor development. *Invest Ophthalmol Vis Sci.* 2003;44: 5396–5403.
- Verbakel SK, van Huet RAC, Boon CJF, et al. Non-syndromic retinitis pigmentosa. *Prog Retin Eye Res.* 2018;In press.
- Vriend G. WHAT IF: A molecular modeling and drug design program. *J Mol Graph.* 1990;8(1): 52–56, 29.
- Weleber RG, Watzke RC, Shults WT, et al. Clinical and electrophysiologic characterization of paraneoplastic and autoimmune retinopathies associated with antienolase antibodies. *Am J Ophthalmol.* 2005;139(5): 780-794.
- Wen Y, Locke KG, Klein M, et al. Phenotypic characterization of 3 families with autosomal dominant retinitis pigmentosa due to mutations in KLHL7. *Arch Ophthalmol.* 2011;129(11): 1475-1482.
- Yagasaki K, Jacobson SG. Cone-rod dystrophy. Phenotypic diversity by retinal function testing. *Arch Ophthalmol.* 1989;107(5): 701–708.
- Österberg G. Topography of the layer of rods and cones in the human retina. *Acta Ophthalmol.* 1935;S6: 1-103.