



LUND UNIVERSITY

Clinical Aspects on Chimney Stent Graft Technique in Endovascular Repair of the Aorta.

BinJabr, Adel

DOI:

[10.1177/1526602814564384](https://doi.org/10.1177/1526602814564384)

2015

[Link to publication](#)

Citation for published version (APA):

BinJabr, A. (2015). *Clinical Aspects on Chimney Stent Graft Technique in Endovascular Repair of the Aorta*. [Doctoral Thesis (compilation), Vascular Diseases - Clinical Research]. Vascular Diseases, Lund University. <https://doi.org/10.1177/1526602814564384>

Total number of authors:

1

General rights

Unless other specific re-use rights are stated the following general rights apply:

Copyright and moral rights for the publications made accessible in the public portal are retained by the authors and/or other copyright owners and it is a condition of accessing publications that users recognise and abide by the legal requirements associated with these rights.

- Users may download and print one copy of any publication from the public portal for the purpose of private study or research.
- You may not further distribute the material or use it for any profit-making activity or commercial gain
- You may freely distribute the URL identifying the publication in the public portal

Read more about Creative commons licenses: <https://creativecommons.org/licenses/>

Take down policy

If you believe that this document breaches copyright please contact us providing details, and we will remove access to the work immediately and investigate your claim.

LUND UNIVERSITY

PO Box 117
221 00 Lund
+46 46-222 00 00

Clinical Aspects on Chimney Stent Graft Technique in Endovascular Repair of the Aorta.

Adel Bin Jabr



LUND UNIVERSITY
Faculty of Medicine

DOCTORAL DISSERTATION

by due permission of the Faculty of medicine, Lund University, Sweden.

To be defended at Skåne University Hospital. Date 2015-02-27 and time 08:00.

Faculty opponent

Professor E. Sebastian Debus

Organization LUND UNIVERSITY, Departement of Clinical Sciences, Malmö, Vascular Center, Skåne University Hospital, Lund University, Sweden	Document name	
	Date of issue 2014-12-28	
	Sponsoring organization	
Author(s) Adel Bin Jabr		
Title and subtitle Clinical Aspects on Chimney Graft Technique in Endovascular Repair of the aorta.		
<p>Introduction: Open repair of the aorta carries a high risk for morbidity and mortality especially in the elderly population and in patients unfit for major surgery. Endovascular aortic repair is safe, durable and effective when there is adequate proximal and distal sealing zone for the aortic stent graft. Fenestrated and branched stent grafts have made the repair possible for complex but elective cases that do not have an adequate sealing zone. Urgent complex cases and patients with midaortic occlusive diseases do not have any therapeutic alternative if they are not fit for open repair. Chimney graft technique fills this gap and allows the sealing zones for aortic stent graft to be extended as required.</p> <p>The aim of the present thesis is to study the applicability, safety and durability of CG technique in urgent cases with complex lesions in the thoracic and abdominal aorta including the midaortic occlusive diseases.</p> <p>Patients and Methods: All patients who received CG were treated urgently or semi-urgently. The majority of the treated aortic lesions were aneurysms, dissections, pseudoaneurysms, infection, and accidental overstented vital aortic side branches. The median age of all patients was 75 years (IQR, 69-78), of them 32% were female except for the first study where all ten patients were female with midaortic occlusive diseases. The second study evaluated the mid to long-term efficacy and durability of the CG technique in 29 patients with urgent and complex lesions of the thoracic aorta. The third study examined the long-term results of CG in preserving the visceral flow of 51 patients with urgent complex aortic lesions. The fourth study evaluated the CTA images of 206 patients with ruptured abdominal aortic aneurysm. The study measured the applicability of CG in patients for whom standard EVAR was contraindicated because of a short aneurysmal neck.</p> <p>Results: The results showed that CG is applicable and safe for midaortic occlusive diseases with high technical success and patency rate without major adverse effect. The treated patients with thoracic aortic lesions had 14% 30-day mortality, 21% type I endoleak, 7% CG-related mortality, 98% secondary patency and 68% of the aortic lesions shrank significantly. Visceral CG had a 10% 30-day mortality, 6% CG-related mortality, 12% type I endoleak, 93% secondary patency and 63% of the aortic lesions shrank significantly. Twenty-two patients had one renal artery sacrificed, 57% of these required permanent renal dialysis. The fourth study proved that CG technique increased the overall suitability for endovascular repair from 34% to 40-46%.</p> <p>Conclusions: Chimney graft seems effective and safe for treating midaortic occlusive diseases in patients unfit for open surgery. The early and mid to long-term results of the CG technique for urgent and complex lesions of the thoracic and abdominal aorta in high-risk patients are promising with a low early mortality, acceptable rate of type I endoleaks and long durability of the CGs, which may justify a broader applicability of this technique. Most endoleaks could be sealed endovascularly. However, sacrificing a kidney in such elderly population was associated with permanent dialysis in 55% of patients and should be avoided whenever possible. CGs in one or both renal arteries may increase overall suitability of rAAA for EVAR by 6-12%.</p>		
Key words: Chimney stent graft, snorkel technique, endovascular aortic repair, thoracic endovascular aortic repair, endoleak, patency, rupture, urgent, stent graft, aorta, computed tomography, ultrasound, stenosis, EVAR, TEVAR.		
Classification system and/or index terms (if any)		
Supplementary bibliographical information		Language English
ISSN 1652-8220		ISBN978-91-7619-106-4
Recipient's notes	Number of pages	Price
	Security classification	

Signature Adel Bin Jabr _____

Date 2014-12-28 _____

Clinical Aspects on Chimney Stent Graft Technique in Endovascular Repair of the Aorta.

Adel Bin Jabr



LUND UNIVERSITY
Faculty of Medicine

© Adel Bin Jabr MD

Vascular Center, Skåne University Hospital-Malmö.
Faculty of Medicine
ISBN 978-91-7619-106-4
ISSN 1652-8220

Printed in Sweden by Media-Tryck, Lund University
Lund 2015



KLIMATKOMPENSERAT
PAPPER



*To my family,
that suffered my absence during a tough period. I was away
from them, however; they were always with me in my heart. I
specially dedicate this work to my children, mother and father,
who died while waiting eagerly for my graduation. I am sorry
for the out of hand delay.*

Contents

Contents	6
List of papers	8
Abbreviations	9
Introduction	11
Anatomy of the aorta	11
Common pathologies of the aorta	11
Historical aspects on the aorta and vascular system	12
The history of endovascular stent graft techniques	18
Modern results of standard EVAR	19
Modern results of fenestrated and branched EVAR	21
Chimney stent grafts	24
Chimney graft technique	25
The principle of chimney graft technique	27
Modern results of chimney stent grafts	30
Aim of thesis	34
Specific aims	34
Patients and Methods	35
Patients	35
Paper I	36
Paper II	36
Paper III	37
Paper IV	37
Ethics	38
Statistics	38
Results	39
Paper I	39
Paper II	39
Paper III	40
Paper IV	44
Discussion	46
Limitations of the studies	54
Conclusions	55
Future considerations	56

Popul�rvetenskaplig sammanfattning p� svenska	57
Inledning/introduktion	57
Patienter och metoder	58
Resultat	58
ملخص الأَطروحة بالعربية	59
مقدمة	59
المرضى والطرق	60
النتائج	60
الاستنتاجات	61
Acknowledgements	62
References	63

List of papers

The present thesis is based on the following papers, which will be referred to in the text by their Roman numerals

- I. Chimney grafts preserve visceral flow and allow safe stenting of juxtarenal aortic occlusion.**
Bin Jabr A, Sonesson B, Lindblad B, Dias N, Resch T, Malina M.
J Vasc Surg. 2013;57:399-405.
- II. Efficacy and Durability of Chimney Graft Technique in Urgent and Complex Thoracic Endovascular Aortic Repair.**

Bin Jabr A, Lindblad B, Dias N, Resch T, Malina M. Submitted to J Vasc Surg. In press.
- III. Long-Term Results of Chimney Graft Technique for Preservation of Visceral Arteries in Urgent Endovascular Repair of Complex Aortic Lesions.**

Bin Jabr A, Lindblad B, Kristmundsson T, Dias N, Resch T, Malina M. In manuscript.
- IV. The impact of renal chimney grafts on anatomic suitability for endovascular repair in ruptured abdominal aortic aneurysm.**

Dias N, Bin Jabr A, Sveinsson M, Björnses K, Malina M, Kristmundsson T.
J Endovasc Ther. In press.

Reprints were made with permission from the respective publishers.

Abbreviations

AAA	Abdominal aortic aneurysm
ASA	American society of anesthesiologists
bEVAR	Branched endovascular aneurysm repair
BT	Brachiocephalic trunk
bTEVAR	Branched thoracic endovascular aneurysm repair
CG	Chimney graft
CHD	Congestive heart disease
CI	Confidence interval
CLF	Center line flow
CT	Celiac trunk
CTA	Computed tomography angiography
EL-I	Type I endoleak
EVAR	Endovascular aneurysm repair
fEVAR	Fenestrated endovascular aneurysm repair
FU	Follow up
IFU	Instruction for use
IQR	Interquartile range
HT	Hypertension
LCCA	Left common carotid artery
LRA	Left renal artery
LSA	Left subclavian artery
MOF	Multiple organ failure
MRA	Magnetic resonance angiography

OR	Open repair
rAAA	Ruptured abdominal aortic aneurysm
CRF	Chronic renal failure
RRA	Right renal artery
SD	Standard deviation
SG	Stent graft
SMA	Superior mesentric artery
TAAA	Thoracoabdominal aortic aneurysm
TEVAR	Thoracic endovascular aneurysm repair

Introduction

Anatomy of the aorta

The aorta is the main and largest artery of the human body, a lifeline that transports oxygen, nutrients, essential metabolites, immunity and waste products to all parts of the body. It starts from the left ventricle of the heart and soon gives three main arch branches to supply the brain and arms. Then it descends alongside the vertebra throughout the body giving off branches that supply all the thoracic and abdominal viscera, until it bifurcates just before entering the pelvis into the two common iliac arteries, which supply the pelvic organs and the lower extremities.

The aortic wall is formed of three layers; the intima (inner layer), media (thick middle layer, which provides the tensile strength by sheets of intertwining elastic tissue arranged in a spiral array) and the adventitia (the outermost layer).

Common pathologies of the aorta

Atherosclerosis is the most common pathology of the vascular system including the aorta. It is a chronic and most often asymptomatic disease with multifactorial etiology (Hansson 2005). The distal part of the aorta is commonly affected which may sometimes result in symptomatic occlusion or stenosis (Figure 1).

There are several definitions of an aortic aneurysm. Commonly, an aortic aneurysm is defined as a dilation of the aortic wall to more than 1.5 times its normal size (Johnston et al. 1991) or as an outer abdominal aortic diameter over 3 cm in males (Hirsch et al. 2006). The etiology is multifactorial (Pearce & Shively 2006) and results in weakness and widening of the aortic wall. Aneurysm may occasionally cause pain, which is a sign of impending rupture. Unless treated immediately rupture may result in shock and death. Generally, aneurysms less than five cm in diameter have a low risk of rupture and do not need to be treated.

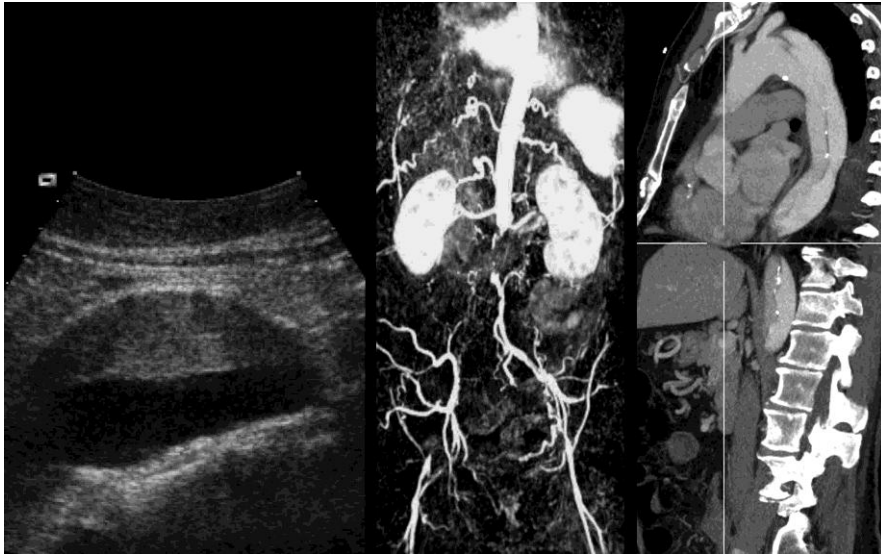


Figure 1

There are several non-invasive imaging techniques to visualise the aorta: ultrasound of an abdominal aortic aneurysm (**left**) and CTA of patient with left iliac occlusion (**center**), MRA of patient with aortic dissection (**right**),.

Acute aortic dissection (Figure 1) and ruptured aortic aneurysms are the most common life-threatening disorders affecting the aorta (Hagan et al. 2000, Patel et al. 2014). Aortic dissection starts with an intimal tear usually in the thoracic part of the aorta. The tear in the intima involves also part of the media, makes the blood pressure split the aortic wall, separating the intima/media from the media/adventitia, and creates a false lumen. This may obliterate both aortic side branches and the true aortic lumen, which in turn may cause a characteristic severe chest or abdominal pain with or without other associated ischemic symptoms. Even with optimal treatment, aortic dissection with end-organ ischemia, heart failure or rupture of the aorta can lead to death.

Historical aspects on the aorta and vascular system

The basis for today's modern vascular surgery rests on achievements and developments that came from the past.

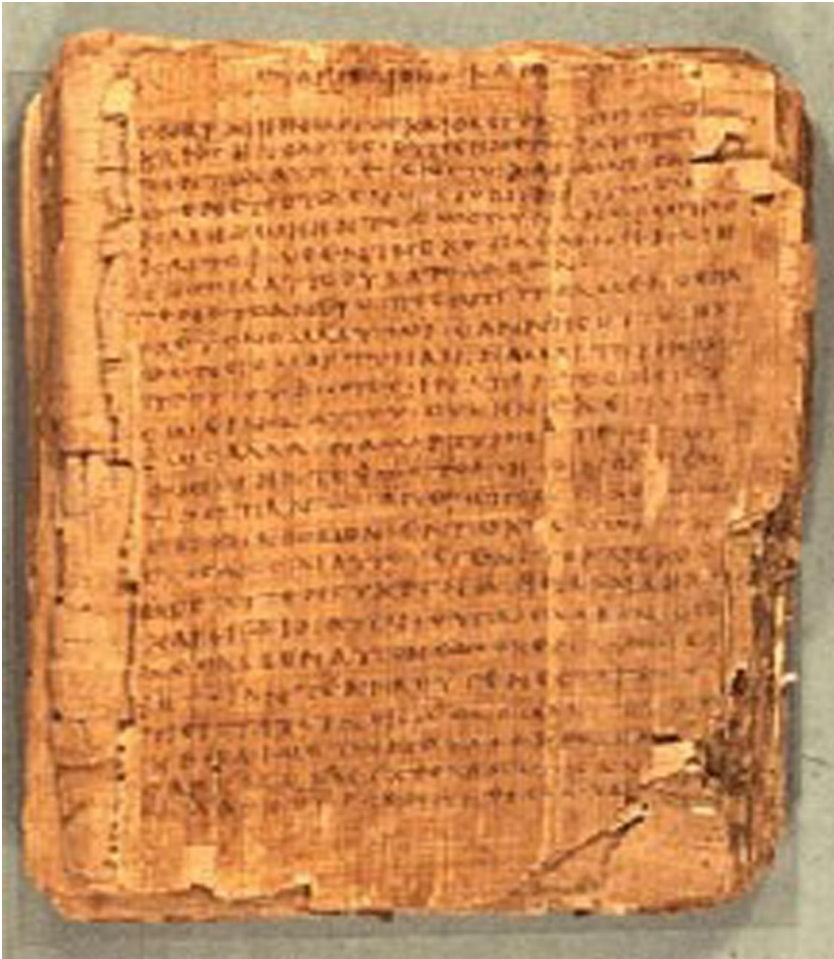

Figure 2

The Ebers Papyrus (c. 1550 BC) from Ancient Egypt was found between the legs of a mummy in the Assasif district of the Theban necropolis in Egypt. It is kept at the library of the University of Leipzig, in Germany.

The first description of the heart, aorta, and arterial aneurysm was found in the earliest (1550 BC) medical writing of Ebers Papyrus (Ebers 1875), which was copied from earlier texts (Figure 2). The writer described the treatment of aneurysms by knife and fire to stop the bleeding. This would suggest that they were talking about peripheral aneurysms (Barker 1992).

The first documented atherosclerosis and arterial calcification has been found in Egyptian mummies (2000 BC), where it was relatively common (Slaney 1990), however it was not mentioned in the Greek or Roman ancient literature.

The misnomer "aorta" is derived from the Greek words ἀορτή - aortē, and from αἰεῖρω – aeirō, which means "I lift, raise". The name reflects the understanding of the ancient Greeks after they observed in cadavers that the aorta was empty of blood. They thought its main function was to suspend the heart and pass air into the lungs (Kuntz & Kuntz, 2008). Hippocrates (460-370 BCE) and his pupil Aristoteles (384-322 BCE) used the term aorta to describe the mounting part for the heart and lungs (Lascaratós et al. 1988).

Aneurysms were also described by the Rome gladiator physician, Galen (130-199 AD), as a dilatation of arteries. These were probably posttraumatic pseudoaneurysms. Antyllus a pupil to Galen reported on treating these peripheral aneurysms with proximal and distal ligation of the artery without excising the sack because it seems that they had problems with hemostasis; their ligatures may have slipped off during arterial stump retraction causing fatal bleeding. Although his works have been destroyed, his ideas are recorded in the writings of Oribasius (400 AD) (Lascaratós et al. 1988).

Abu al-Qasim al-Zahrawi (in west known as Abulcasis) (936-1013 AD), was born and lived in al-Zahra town, six miles northwest of Córdoba, Andalusia. He described different hemostatic methods including the cautery and how to ligate blood vessels almost 600 years before Ambroise Paré (Pearn 2012). He also explained the hereditary nature of hemophilia and described the procedure for treating testicular varicose veins (Abulcasis 1973). Al-Zahrawi was also the first to use catgut in surgery and to illustrate various cannulae (Hamarech 1984).

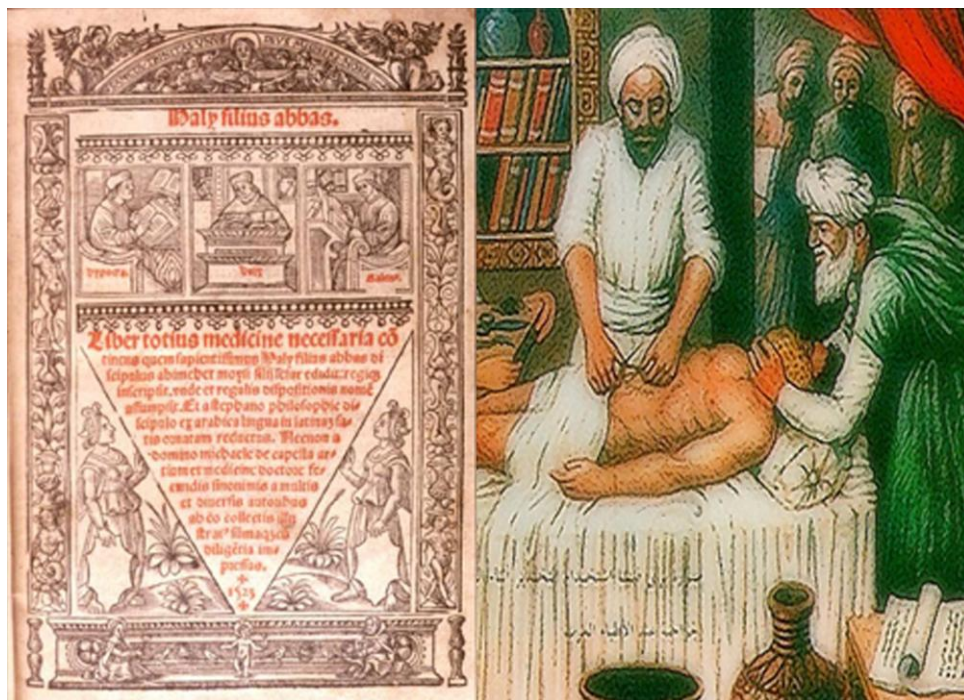

Figure 3

A latine translation of the medical textbook " Kitab al-Maliki or Complete Book of the Medical Art" of Ali Bin Abbas Al-Ahwazi". The right picture shows Ali Bin Abbas Al-Ahwazi performing an abdominal operation.

Ali Bin Abbas Al-Ahwazi (known in the west as Haly Abbas) (930- 994 AD) was born in Al-Ahwaz, lived and died in Baghdad. He was the first to describe surgical treatment for tumors of the vessels “aneurysms” (Figure 3). He also described the different types of arterial pulses and the inference of each including its relationship to the functionality condition of the heart. The first known description of capillary circulation was also part of his work (Aciduman et al. 2010). He developed catheters for the first time and invented the concept of using them to overcome internal obstructions or stenosis, where they were used first for urinary retention and dysuria (Figure 4).




Figure 4
Page from a 1531 Latin translation by Peter Argellata of El Zahrawi's treatise on surgical and medical instruments.

Alaa-al-din Ibn al-Nafis (1210-1288) was born in Damascus and died in Egypt. He was the first physician to describe the pulmonary and coronary circulation, four centuries before the descriptions of William Harvey (England, 1578-1657) (Abdel-Halim 2008). Ibn al-Nafis created a scientific evidenced based concept in medicine with a disciplined approach. He emphasized the joint relationship between anatomy and physiology. He was clear in condemning several of the common medical understandings of his time. For instance, he rectified the by Galen and Avicenna old description of heart anatomy and its function (Iskander 1967, Abdel-Halim 2008). He also described the arterial supply of the heart muscles by the coronary arteries (Figure 5) 300 years before the description of Realdo Colombo (Italy, 1516-1559).

Matheus Purmann (1649-1711) (Lüben-Germany) operated in 1680 an antecubital aneurysm, and he ligated the artery above and below the aneurysm and removed the sac (Barker 1992). The ligation technique was soon disseminated, and is described in the Swedish literature of Olof af Acrel (1717-1806) in his “Chirurgiske händelser” (Acrel 1965).

The development in Europe brings us to the English surgeon John Hunter (1728-1793), who studied among others the development of collateral circulation when a main artery was occluded. His method of treating aneurysms was based on this observation. In 1785, he ligated the superficial femoral artery high up in the Hunter's canal to treat a popliteal aneurysm. The patient did well; the aneurysm shrunk to a hard knot, and the limb survived (Perry 1993). The ligation method remained the only option until endoaneurysmorrhaphy of a large traumatic brachial artery aneurysm was performed by Rudolph Matas (USA) (1860-1957) in May, 1888 (Matas 1888).




Figure 5

The opening page of one of Ibn al-Nafis's medical works. This is probably a copy made in India during the 17th or 18th century.

After John Hunter, sir Astley Cooper (1768-1841) made the famous operation of tying the abdominal aorta for a leaking iliac aneurysm in 1817 (Crone 1957). The right leg remained viable; however, the left leg became very ischemic, and the patient died two days after the procedure (Brock 1952).

The French surgeon Rene Leriche (1879-1955) published in 1923 his observations on obliteration of the terminal aorta and stated that the ideal treatment would be resection of the area and reestablishment of flow with a vascular prosthesis. In 1940, he described in detail “Leriche syndrome” that now bears his name (Leriche & Morel 1948). He recommended a resection of the terminal aorta and common iliac arteries together with bilateral lumbar sympathectomy through a retroperitoneal approach.

At the beginning of the 20th century (1902), Alexis Carrel (USA) received the Nobel Prize for demonstrating a suture technique for arterial anastomosis (Edward & Edward 1974).

The Portuguese surgeon Cid Dos Santos performed the first thromboendarterectomy in 1947, and a few years later, it was accepted as a treatment for aortoiliac atherosclerotic obstructions (Dos Santos 1947). Thromboendarterectomy allowed treatment of localized aortoiliac occlusive disease (Wylie 1952).

The modern open aortic repair started in the 1950s (De Bakey 1979). In 1952 reported the French surgeon Charles Dubost for the first time a successful open AAA repair with homograft replacement (Dubost et al. 1952). Soon polyester Dacron grafts became available and showed good results (DeBakey et al. 1957). During the next 40 years, open repair with Dacron was the standard therapy for aortic aneurysmal lesions. Thereafter ePTFE-grafts emerged. Occlusive disease was treated with graft by-pass.

However, aortic repair is major surgery with significant trauma to the patients, longer hospital stays (1-2 weeks), longer recovery period (4-12 weeks) and it carries a high risk for morbidity and mortality. Taking into consideration, that aortic aneurysm opt to affect elderly people, who normally have low physiological capacity and often other associated comorbidities, all of which increases their risk to not sustain such major surgery.

The history of endovascular stent graft techniques

The endovascular stent-graft era started in 1986 when Nicholas Volodos, (Kharkov, Soviet Union) established the first endovascular therapy by using an aortic SG (Volodos et al. 1986). In 1987, he performed the first thoracic aortic

stent graft (TEVAR) (Volodos et al. 1988). However, the dramatic shift in the management of aortic aneurysms and other aortic pathology from open repair to endovascular handling occurred after the widely disseminated report of Juan Parodi (Brasil) in 1991 (Parodi et al. 1991). Endovascular therapy is a minimally invasive aortic repair based on stents and graft material inserted and placed by catheters and guide wires from the peripheral arteries (the femoral and brachial) with less trauma, shorter hospital stay (2-3 days), and rapid recovery (1-2 weeks).

The first implanted SGs were homemade devices and served to establish the feasibility of the technique (Volodos et al. 1986, Parodi et al. 1991, Volodos et al. 1991). Bifurcated and modular aortic SG was pioneered and first employed by Timothy Chuter (USA) (Chuter et al. 1993).

The first commercially made SGs were not without problems (Van Marrewijk et al. 2005, Mestres et al. 2010). Newer grafts with both proximal and distal anchoring (Yusuf et al. 1994, Ivancev et al. 1997) and between that, a supporting stent skeleton (Lawrence-Brown et al. 1998) began to show acceptable results. While the initial single center results were excellent (Greenberg et al. 2001, Resch et al. 2003), two British and one Dutch multi-center randomized trials demonstrated only moderate advantage of endovascular treatment. (Prinssen et al. 2004, Greenhalgh et al. 2004, Evar I trial 2005, Evar II trial 2005) Today further development of the endovascular technique has made it possible to treat the majority of aortic aneurysms with SGs.

Modern results of standard EVAR

EVAR soon became a good alternative to open surgery with a continuously increasing preference for this technique (Sethi et al. 2013, Fitridge et al. in press). In many countries, more than 60% of elective aneurysm repair is made endovascularly. Procedure-related mortality is lower with EVAR (1.4% for EVAR and 4.2% for open repair) but late all-cause mortality seems very similar between the groups (at 4 years; 15.8% for EVAR-group versus 17% for open-group) (Paravastu et al. 2014). Of course, this is dependent on the selection of cases offered EVAR- or open treatment. Since the multicenter studies were made, more severe comorbidities in patients are accepted for EVAR-treatment. Additional adjuncts include percutaneous access, low-profile grafts, branched SGs aso. (Jackson et al. 2014, von Meijenfeldt et al. 2014). Simultaneously, the endovascular skills and logistics have been improved in most centers. Results also depend on the anatomic feasibility and different indications and treatment traditions vary between the regions (Fitridge et al. in press). One drawback of EVAR has been the increased rate of reinterventions (18.9% versus 9.3%). This is

of concern although the majority of the reinterventions are relatively simple percutaneous procedures (Quadra et al. 2013). Another question has been emerged on how often and how long follow-up is required (Paravastu et al. 2014).




Figure 6

Two standard infrarenal bifurcated aorto-iliac stentgrafts. Both carry a bare metal top stent for cross renal fixation. The modular nature of these devices is illustrated in the left image where the iliac limb is to be inserted into the bifurcated body. The right image shows the flexibility of the devices and also the catheter that was used to deploy it.

Since the first report on treating ruptured abdominal aortic aneurysm in 1994 (Yusuf et al. 1994), giant steps have been taken to implement the endovascular treatment for rAAA. For ruptured cases, the following requirements have been crucial: preoperative anatomic delineation by CTA, emergent access to a skilled endovascular team, the availability of off-the-shelf SGs that covers most situations, and an adequately equipped operation room. This is not built or gained very easy. Single and multicenter studies have reported on improved survival for rAAA treated with EVAR with 30-day mortality between 21-27% (Holst et al. 2009, Veith et al. 2009, Badger et al. 2014, van Beek et al. 2014). However failed to demonstrate a difference in 30-day mortality between the EVAR and open surgical groups, despite of the 760 patients included (Badger et al. 2014). This may reflect an immature endovascular organisation rather than a true lack of benefit. A major concern was the skills that should be equal at each center in handling cases both open and endovascularly. That is normally not possible. The endovascular skills and logistics were simpler in many centers during the early days of the endovascular era while now some centers perform relatively few open aortic repairs. That is to say, that reviews and meta-analyses in this area are more difficult to interpret since open operative skills may differ from endovascular skills

and conclusions should be made cautiously. In an analysis of Medicare data of 11,000 rAAA-patients of whom 1,126 had EVAR and 9,872 had open surgery, 30-day mortality was 34% versus 48% between EVAR and open repair (Edwards et al 2014). Interestingly the proportion of EVAR-treated ruptured cases increased from 8% to 31% between 2001-2008 (Edwards et al. 2014).

The success story of endovascular therapy relies on the ability of the SG device (Figure 6) to exclude the target aortic segment, which is dependent on securing optimal proximal and distal sealing zones. Improved endovascular skills and a desire to be able to handle a larger proportion of cases with AAA with more demanding anatomic morphology have led to the development of fenestrated and branched SGs.

Modern results of fenestrated and branched EVAR

The more challenging anatomy particularly the short, conical or angulated neck necessitates the development of advanced endovascular SGs. Therefore, both fenestrated and branched SGs were developed to overcome this limitation. In contrast to the fenestrated SG (Figure 7), a branched SG can be utilized even when the visceral artery originates from unhealthy or dilated part of the aorta where there is no apposition between the SG and the native aortic wall. Both techniques were developed during the same timeframe, where in 1996, Park and associates reported the first two patients treated with fenestrated devices for juxta-renal aortic aneurysms. (Park et al. 1996) Subsequently Anderson and co-workers presented the successful first clinical experience with fenestrated graft in treating 13 patients with juxtarenal and pararenal aortic aneurysms (Andersson et al. 2001).

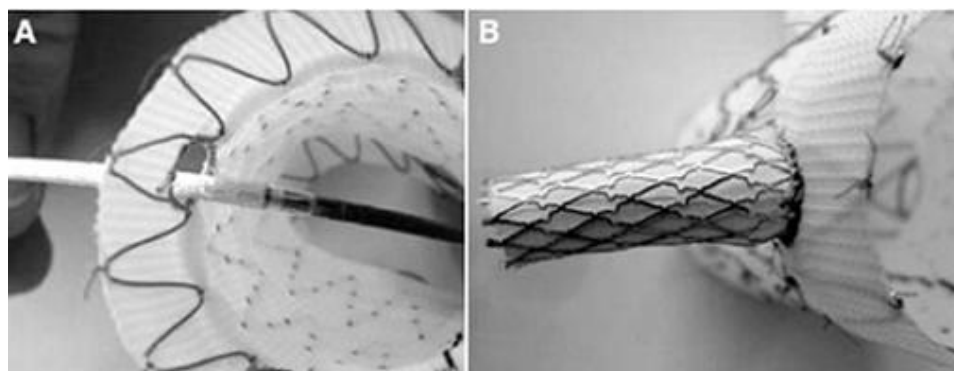


Figure 7

The principle of a fenestrated SG: A covered stent, mounted on a balloon catheter, has been passed through the fenestration of an aortic SG (left) and is subsequently deployed by inflating the balloon (right).

One draw-back with fenestrated SGs were that the orifices of the fenestrations need to be placed very accurately over the orifices of side branches that are to be revascularized (Figure 8). That demanded more endovascular skills and the side branches were not always possible to catheterize from the fenestrations. The fenestration technique was soon adopted by several centers (Kristmundsson et al. 2009, 2013, Oderich et al. 2014, Grimme et al. 2014) showing fully acceptable results. In the summarizing table below (Table I), the increasing experience is showing promising results, and this new technique has mainly replaced open surgery for juxta-renal aneurysms.

The technical success, to be able to catheterize target vessels for fenestrations has been almost 100%, but in the follow-up stenosis (6-12%) and occlusion of renal arteries are reported to occur in 2-6% of cases (Di et al. 2013). Initially, the drawback with fenestrated SGs was considered to be a high risk of endoleaks type I but this has not been the main complication seen. In most series, it has been reported that the need for many unplanned adjunctive intraoperative procedures to achieve an optimal outcome is common but also access related complications. The technique has also expanded to thoracic cases (Mc Williams et al. 2004, Yuri et al. 2013). Small series of using this technique in thoracic aorta allows preserving aortic branch flow to vital side branches.

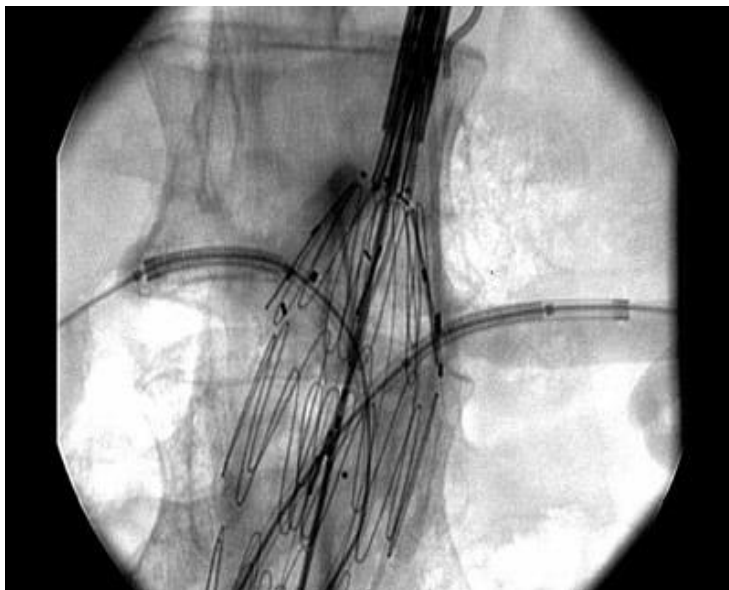

Figure 8

An intraoperative angiography of fenestrated SG demonstrating the relationship between the main aortic SG and the bilateral renal arms. Renal SGs are yet not deployed and the most proximal aortic part not fully deployed.

Table 1

Initial outcome of fenestrated SGs for juxtarenal aneurysms

Author	No. of pat.	EL-I (%)	30-day mortality (%)
Anderson et al. 2001	13	0	0
O'Neil et al. 2006	119	5.9	0.8
Semmens et al. 2006	58	6.9	3.4
Scurr et al. 2008	45	0	2.2
Kristmundsson et al. 2009	54	5.6	3.7
Greenberg et al. 2009	30	13	0
Amiot et al. 2010	134	2	2
Verhoeven et al. 2010	100	2	1
Kienz et al 2010	61	6.6	0
Manning et al. 2011	20	0	10
GLOBALSTAR 2012	318	4.4	3.5
Kristmundsson et al. 2013	100	0	1
Tsillamparis et al. 2013	264	0	0.8
Cochennec et al 2014	89	0	6.7
Oderich et al. 2014	67	1.4	1.5
Hertault et al. 2014	288	0	2.4
Grimme et al. 2014	138	4.3	1.4

Branched SGs were also developed and many prototypes tested both experimentally and in clinical cases (Inoue et al. 1999, Chuter et al. 2005, Andersen et al. 2005). The main advantage of branched SGs is that they can be used in aneurysmatic parts of the aorta where there is no apposition between the main SG and the native aortic wall. A disadvantage is that the operation time is longer (Manning et al. 2011, Silveira et al. 2012). There are by now multiple reports of successful implementation of branched SG in treating among others, hypogastric, pararenal, juxtarenal, para-anastomotic, thoracoabdominal, and aortic arch aneurysms (Greenberg et al. 2006, Muhs et al. 2006, Dias et al. 2008, Kasirajan 2011). All these series are limited but show that endovascular treatment with branched SG has lower 30-day mortality than the corresponding open surgical repairs while the need for reintervention is at an acceptable level.

Chimney stent grafts




Figure 9

There are four main types of stents applied as CGs: The rigid balloon expandable bare and covered stents (left) and the flexible selfexpanding bare and covered stents (right). Jostents, a Wallstent and a Fluency covered stent are shown.

Chimney graft technique

The nomenclature of this technique has varied overtime and various terms have been used. The “snorkel”, top-stent (Larzon et al. 2008), parallel grafts or as the majority called it a “chimney graft” (Figure 9) is required for two main reasons. The fenestrated and branched SGs have so far been unsuccessful to become universally applicable because they require a long manufacturing time (1-2 months) and remain costly (Dias et al. 2008). Urgent cases cannot await such long time. Therefore, urgent cases with a hostile neck that are not fit for OR may have no other therapeutic alternative.

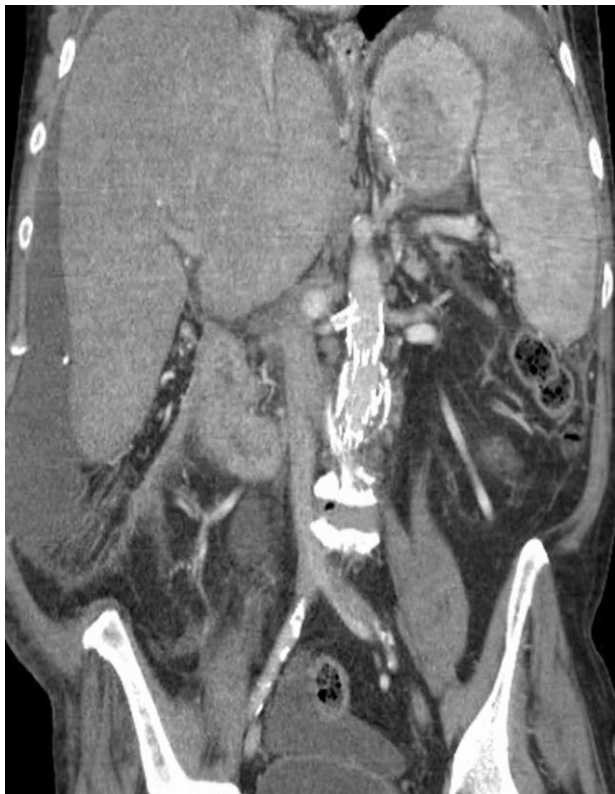

Figure 10

One of the first performed CG cases, which was made in 1999 as a bailout procedure to rescue an accidentally overstented renal artery by L Lönn and M Malina. This is the CT image at 14 years follow-up. Patent CG and excluded AAA are noted.

To our best knowledge, the first CG was applied in 1999 to rescue an overstented renal artery in a patient treated by Lars Lönn and Martin Malina (Figure 10). Greenberg and coworkers were the first to publish a CG procedure that was performed in 2001. Thereafter, they conceptualized this technique with EVAR as a therapeutic option for AAA (Greenberg et al. 2003). By implanting a CG parallel to the main aortic SG, side branches could be preserved both in the abdominal and thoracic aorta (Greenberg et al. 2003). It was soon also used intentionally in emergent cases as a primary solution (Malina et al. 2008). Thereafter many groups expanded the application of CG technique beyond juxtarenal aneurysms to suprarenal, thoracoabdominal, and aortic arch aneurysms. The technique has been successfully implemented to manage several different aortic lesions for instance aortic dissection, rupture, occlusive disease, aortic fistulas and reinterventions for complications of previous open and endovascular aortic interventions and infections.

The CG technique extended the applicability of endovascular repair in the emergent cases, and rapidly became a reasonably good alternative to open surgery (Kolvenbach et al 2011).

Some centers use the CG technique as the treatment of choice also for elective cases (Lachat et al. 2013). Maybe the most important factor for this was that CGs were readily available on the shelf and affordable while the manufacturing time and cost of fenestrated and branched SGs could be prohibitive (Banno et al 2014, Guo et al in press). A complementary technique of inverted CGs allowing retrograde flow up to side branches were used – the periscope technique was first reported for visceral arteries during repair of a ruptured TAAA (Lachat et al. 2010)

The sandwich technique (Figure 11) where CGs are placed in between two layers of aortic SG to allow the CGs to revascularize side branches even in an aneurysmatic part of the aorta was used first for revascularization of the internal iliac artery (Lobato et al. 2011) and later for revascularization of the visceral and renal arteries (Lobato & Camacho-Lobato 2012).

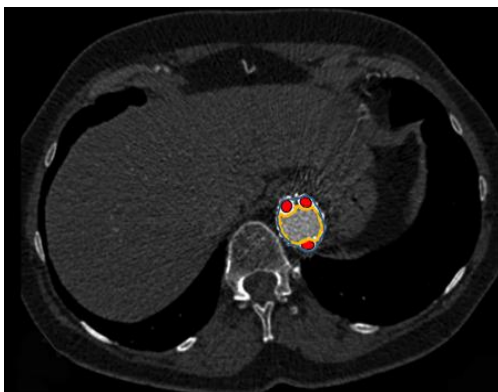


Figure 11

Aortic aneurysms that involve the visceral portion of the aorta can be managed with the sandwich technique, where CGs (marked red) pass between the proximal and distal (marked orange) aortic SGs to the visceral arteries.

The principle of chimney graft technique

Whether in the abdomen or in the thorax, for aneurysm, dissection, transection or occlusive disease the principle of CG technique is almost the same. Chimney graft is deployed into a vital aortic side branch alongside and parallel to the main aortic SG in order to extend the sealing zone and maintain blood flow to the aortic side branches (Figure 12-14).

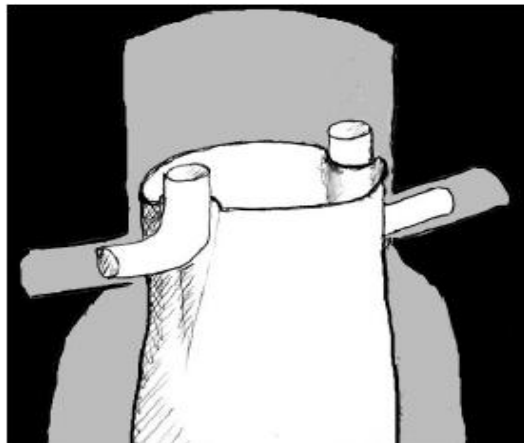


Figure 12

An often used illustration of the chimney graft technique demonstrates the relationship between chimney graft, main aortic SG and the aorta. Courtesy of M Malina.

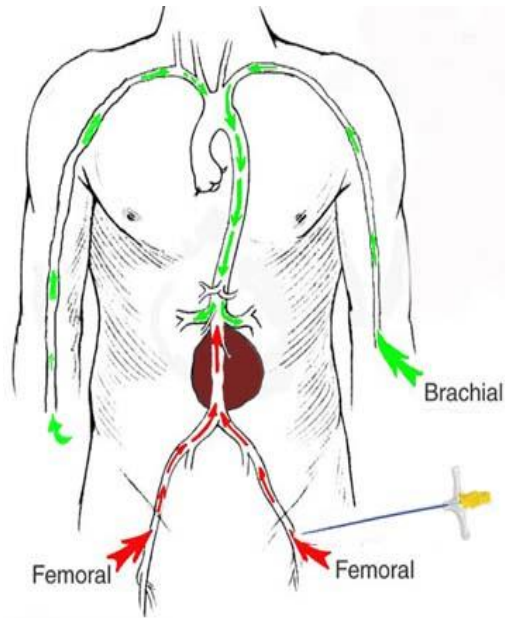


Figure 13

The procedure requires multiple access ports, one for each chimney graft and for the aortic SG. The visceral chimneys are classically introduced via the brachial approach while the main aortic SG is passed through the femoral ports. For arch branches, a right carotid approach may be preferred for chimney graft insertion. The chimney graft can also be inserted to the visceral branches through a femoral approach through the so called “lift technique” (Lachat et al. 2010, 2013).

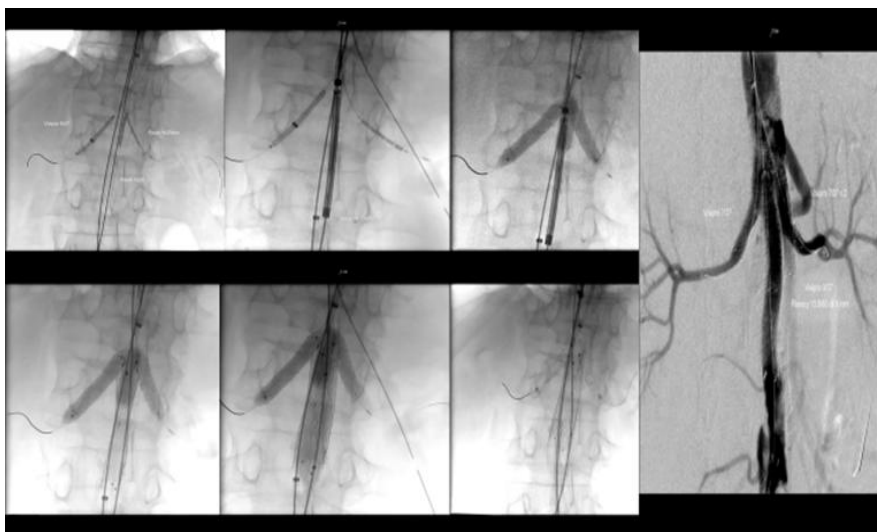


Figure 14

The sequential steps of chimney graft insertion – here exemplified in a patient treated for aortic occlusive disease:

- 1- Non-deployed CGs are inserted first.
- 2- Then, the main aortic SG is inserted and kept non-deployed.
- 3- Balloons are inflated inside all CGs to keep them expanded and obstructed. This would protect the visceral organs from possible embolization by any dislodged material, while deploying and inflating the main aortic SG.
- 4- Main aortic SG is deployed and inflated with balloon.
- 5- Then the balloon of the main aortic SG is deflated allowing the blood to flow downstream (flushing any debris out distally in case of occlusive disease).
- 6- The balloons of CGs are then deflated allowing revascularization of the visceral organs.
- 7- Completion angiography demonstrates patency of all stented vessels

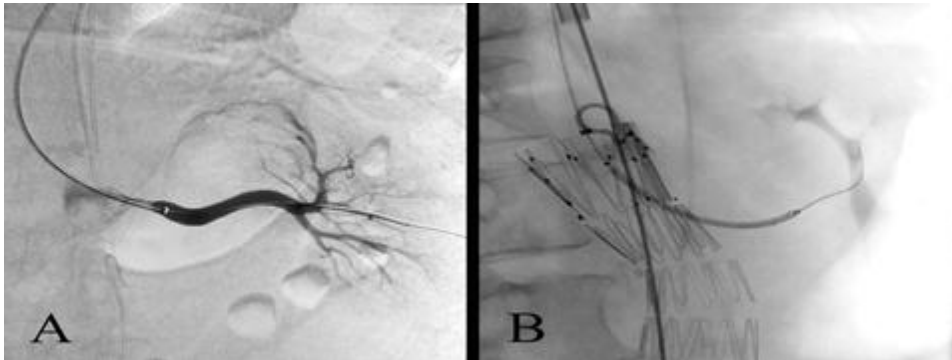


Figure 15 Small improvements that make the stents more suitable for the CG technique:

A. A 6F introducer sheath is parked in the renal artery for insertion of a CG from a brachial approach prior to deployment of the aortic SG. Even this 6F sheath proved difficult to introduce into the renal artery unless the stiff guide wire was passed dangerously far into the kidney for stability.

B. A 58 mm long covered stent is parked in the kidney to be deployed after the release of the aortic SG. Until recently, only 22mm long covered stents with a 6F profile were available and longer stents required larger sheaths that are more difficult to pass into the renal arteries.

A major problem for the visceral CGs has been the fact that most covered stents (Figure 9) require 7 F sheaths or larger. Such large sheaths are difficult to introduce in the visceral arteries from a brachial approach. This is particularly true for the renal arteries. The recent development of low profile covered stents now makes it possible to insert even long covered stents through 6 F sheaths (Figure 15). This facilitate the use of CGs and is likely to expand the applicability of this technique.

Modern results of chimney stent grafts

Chimney grafts were initially used as a rescue technique and adopted by some centers especially for emergent cases both in the abdominal and thoracic aorta with promising results. Still a major concern has been proximal endoleak type I (Rutherford 2004). However, to have a solution or rescue on the “shelf” for maintaining blood flow to vital side branches and repair for endovascular treatment in an emergent situation even in cases with complex morphology is necessary for endovascular development. While it does seem justifiable to treat urgent cases with CGs, the majority of published cases were elective patients, and in many instances treatment selection has been based on economic factors and not on the best available treatment as a guideline (Table II, III).

Table II

Early outcomes from studies on visceral chimney grafts.

Authors	No. patients	No. CGs	Elective/urgent repair	Early patency No.(%)	EL-I No.(%)	30-day M No
Larzon et al. 2008	13	14	7 /6	14 (100)	1 (8)	0
Ohrlander et al. 2008	6	11	1/5	11 (100)	1 (17)	0
Hiramoto et al. 2009	8	8	8/0	8 (100)	1 (13)	0
Allaqaband et al. 2010	2	2	2/0	2 (100)	0 (0)	0
D'Utra et al. 2010	1	1	1/ 0	1 (100)	1 (100)	0
Donas et al. 2010	72	127	72/0	127 (100)	6 (8)	0
Kolvenbach et al. 2010	5	17	0/5	5(100)	1 (20)	0
Bruen et al. 2011	21	37	21/0	36 (97)	1 (5)	1
Coscas et al. 2011	16	26	16/0	25 (96)	2 (13)	2
Pecoraro et al. 2011	3	8	0/3	7 (88)	1 (33)	1
Ricci et al. 2011	1	2	1/ 0	2 (100)	0 (0)	0
Brechtel et al. 2012	1	4	0/1	4 (100)	1 (100)	0
Lee et al. 2012	28	56	28/0	55 (98)	2 (7)	2
Moulakakis et al. 2012	3	4	2/1	4 (100)	1 (33)	0
Tan et al. 2012	1	2	0/1	2 (100)	0 (0)	0
Zhang et al. 2012	31	45	45/0	45 (100)	5 (16)	0
Fukui et al 2013	13	18	12/1	18 (100)	0 (0)	0
Lachat et al. 2013	77	169	68/9	165 (98)	19 (25)	2
Lee et al. 2013	1	2	1/0	2 (100)	0 (0)	0
Schiro et al. 2013	9	9	0/9	9 (100)	2 (22)	0
Tolenaar et al. 2013	13	22	11/2	21 (95)	1 (8)	0
Varu et al. 2013	4	6	6/0	6 (100)	1 (17)	0
Banno et al. 2014	38	60	32/6	59 (98)	2 (5)	3
Ducasse et al. 2014	22	22	22/0	22 (100)	1 (5)	1
Marino et al. 2014	1	3	0/1	3 (100)	1 (100)	0
Massmann et al 2014	2	2	2/0	2 (100)	0 (0)	0
Rouer et al. 2014	1	1	1/0	1 (100)	0 (0)	0
Guo et al. In press	42	56	42/0	42 (100)	8 (19)	0
Overall	407	734	357/50		59	12

Table III

Early outcomes from studies on thoracic chimney grafts.

Authors	No. patients	No. CGs	Elective/urgent repair	Early patency No.(%)	EL-I No.(%)	30-day M No
Hiramoto et al.2006	1	1	1/0	1 (100)	0 (0)	0
Baldwin et al. 2008	7	7	4/3	7 (100)	1 (14)	2
Larzon et al.2008	10	10	2/8	10 (100)	0 (0)	0
Ohrlander et al.2008	4	4	0/4	4 (100)	1 (25)	1
Sugiura et al. 2009	11	11	0/11	11 (100)	2 (18)	0
Lachat et al.2010	1	4	0/1	4 (100)	1 (100)	1
Rancic et al.2010	2	4	0/2	4 (100)	1 (50)	1
Dias et al.2011	4	4	0/4	4 (100)	0 (0)	1
Gehringhoff et al. 2011	9	9	0/9	9 (100)	1 (11)	0
Pecoraro et al. 2011	6	16	0/6	16 (100)	1 (17)	0
Schlosser et al.2011	1	2	0/1	2 (100)	1 (100)	0
Richardson et al. 2011	1	1	0/1	1 (100)	0 (0)	0
Ketelsen et al. 2011	1	1	0/1	1 (100)	0 (0)	0
Shu et al. 2011	8	8	8/0	8 (100)	0 (0)	0
Yoshida et al. 2011	2	6	2/0	6 (100)	0 (0)	0
Joseph et al. 2012	1	1	1/0	1 (100)	0 (0)	0
Mitshouka et al. 2012	1	1	1/0	1 (100)	0 (0)	0
Shu et al. 2012	32	34	28/4	34 (100)	0 (0)	0
Brunkwall et al. 2013	6	12	6/0	12 (100)	2 (33)	1
Fukui et al. 2013	9	15	9/0	15 (100)	4 (44)	0
Samura et al. 2013	2	4	2/0	4 (100)	0 (0)	0
Zhou et al. 2013	1	2	1/0	2 (100)	0 (0)	0
Mangialardi et al. 2014	26	28	19/7	28 (100)	6 (23)	1
Xue et al. 2014	59	62	42/17	61 (98)	5 (8)	0
Overall	205	246	126/79		26	8

M, mortality.

The beneficial effect of this new technique has been documented in reviews (Katsagyris et al. 2013, Wilson et al. 2013) but long-term data, especially regarding emergent cases has been limited. Mortality from the procedure even if it requires more access sites and longer procedural time for repair has been favorable (Lachat et al. 2013). It has also been shown that major access complications are more common than the anticipated type I endoleaks. The results depend on what

type of aortic pathology and what aortic arch side branches have been treated (Katsagyriset al. 2013, Wilson et al. 2013). Another limitation is that multicenter randomized studies of convincing size comparing this technique with other treatment possibilities do not seem feasible.

It has been discussed if endoleak type I can be minimized by a certain length of the overlapping zone from the CG-graft (Criado et al. 2013 Lachat et al. 2010, 2013). The gutters alongside the CG-s could be a potential source for type I endoleak. However the length of that overlap possible to achieve is mainly due to anatomical factors. From the litterature no major conclusive view on the length of overlapping required for abdominal and/or thoracic pathology exists.

The published cases of thoracic pathologies combined with CG-grafts are definitively more complex (Wilson et al. 2013). Nevertheless, the results are promising but maybe the hemodynamic forces are even more overwhelming in the arch of aorta even if not proven (Katsagyris et al. 2013, Wilson et al. 2013). The risk of type III endoleak in CG-graft cases especially if thoracic side branches has been revascularized is also recognized (Criado et al. 2013).

In improvement of this technique as it seems from the literature further validation of the usefulness of this CG-graft technique is needed. However, the main indication for this technique that is accepted is emergent cases or cases where the manufacturing time for a fenestrated or branched SG cannot be waited for. In our center emergency cases has been a large part of our indication for having the consideration of a CG combined with abdominal or thoracic aortic repair.

Another problem seen in this category of patients are the substantial risk of developing renal insufficiency or even the requirement of hemodialysis. In the recent reviews, the risk of chronic renal impairment is reported to be around 10 % and the need for chronic hemodialysis around 2% (Katsagyris et al. 2013).

Aim of thesis

The general aim of the present thesis was to study different aspects of the CG technique that would demonstrate the feasibility of CGs in treating complex aortic lesions at the arch, descending thoracic and abdominal aorta. The thesis explores also the contribution of this technique in expanding the endovascular therapy in replacement to open surgery.

The applicability, efficacy, complication rate and mid- to long-term durability of the CGs has been studied with the consideration of the possibility to routinely adopt and/or expand the applicability of this technique.

Specific aims

- I. To test the novel application of CG technique in treating midaortic occlusive diseases (Paper I).
- II. To evaluate the mid to long-term efficacy and durability of CGs used with TEVAR for urgent lesions of the thoracic aorta (Paper II).
- III. To analyze the long-term results of CGs in visceral arteries of the abdominal aorta (Paper III).
- IV. To analyze how CGs may potentially expand the applicability of EVAR for rAAA (Paper IV).

Patients and Methods

Detailed methodology of each study is present in the respective paper. The following will provide a short summary of patients and methods in general. In the context of the present thesis the term and abbreviation “Chimney graft, CG”, denotes to both chimney stent and chimney stent graft.

Patients

All studies reflect a single center experience where all patients were treated in the vascular center of Skåne University hospital-Malmö, Lund University, Malmö, Sweden. They were operated between November 2004 and June 2013. All cases were urgent or semi-urgent and with complex lesions. Ten patients (Jan 2006 - Jan 2011) received CGs for midaortic occlusive disease (paper I), 29 patients (Nov 2004 - Oct 2012) received CGs for proximal aortic lesions (paper II), 51 patients (June 2006 - Oct 2012) received CGs for visceral branches (paper III) and 206 patients had a ruptured AAA (Jan 2006 - June 2013)(paper IV).

Patients presented with diversity of complex aortic lesions. It was often difficult to categorize them; however, it was more difficult to have them in one group. Each of them was almost unique with different pathology and different data/circumstances. It was difficult to have the thoracic and abdominal (visceral) group together in one group because each has different characteristics with different circumstances and CG behaves differently in each group. Patients were regrouped for several times until we were satisfied with the current groups.

All patients with midaortic occlusive disease formed a special entity (paper I), and patients with mid- to long-term review are classified into thoracic group by whom the lesion affects the thoracic aorta (paper II) and abdominal group (paper III) for whom CG was implanted into the visceral branches. Seven patients were shared between papers II and III, because they underwent TEVAR with visceral CGs for lesions that involved both the thoracic and abdominal aorta. The fourth group composed of good quality CTAs of 206 patients with ruptured AAA that were treated at Skåne university hospital-Malmö between January 2006 and June 2013 (paper IV).

Patients who were proposed for and operated with the CG technique were deemed unfit for OR, fEVAR, and bEVAR. They mostly had complex aortic lesion that required emergent/urgent handling with distorted anatomy and associated comorbidities. The median age of patients operated with CG technique was 75 years (IQR, 69-78).

Patients had preoperative CTA and normally a FU CTA yearly. Patients with impaired renal function receive either limited volumes of diluted contrast or intraoperatively CO₂ contrast. In the worst scenarios with severe renal impairment, they were followed up with ultrasonography and the routine clinical investigation.

Paper I

Ten female patients with a median age of 70 years, presented with visceral and /or lower limb ischemia due to severe midaortic stenosis or occlusion. All patients required urgent or semi-urgent management, however all were considered high-risk candidates for open repair.

Patients underwent preoperative assessment and were classified according to the scale of the American Society for Anesthesiologists (ASA). All were considered class III, because they suffered lower limb and/or visceral ischemia associated with other comorbidities such as hypertension and diabetes mellitus. Their survival without intervention was questionable/pure.

Paper II

Twenty-nine patients (20 male) with a median age of 73 years (IQR, 63-74 years) presented with aortic lesions at the arch (n=9), descending (n=10) or thoracoabdominal aorta (n=10). They were treated with CG technique and TEVAR. No patients were lost to follow-up. Twenty-two of them required urgent (within 24 hours) intervention. Most thoracic aortic lesions were ruptured (n=14, 48%) or symptomatic. They included aneurysms (n=11), complicated dissections (n=9), pseudoaneurysms (n=5), accidental overstenting of LCCA (n=2), iatrogenic aorto-esophageal fistula (n=1) and traumatic transection (n=1). The median FU and IQR for the entire cohort was 2 years (0.6-3.8 years), 2.5 years (1-4 years) for patients surviving the procedure and 3.5 years (1.9-6.4 years) for those who were still alive.

Chimney graft technique was used in urgent cases with complex thoracic aortic morphology that were associated with deficient sealing zone (n=27), or after

accidental overstenting of a vital aortic side branch (n=2). No patient was a candidate for OR, fEVAR or bTEVAR.

Placing CGs in the precerebral vessels is principally different from the visceral arteries by gaining access from the periphery. Hypothetically, peripheral access to the visceral arteries is also possible in selected cases e.g. renal arteries and SMA.

Paper III

Retrospective analysis of prospectively collected data was made for fifty-one patients with visceral CG (16 female, 35 males) with a median age of 77 years (IQR, 72-81). Patients presented with mainly abdominal aortic lesions (EVAR=43, TEVAR=8) necessitating urgent (n=31, 61%) and or semi-urgent (n=20, 39%) endovascular aortic repair and visceral CG technique.

The median follow-up (FU) was 2.3 years (IQR, .8-5 years). Median FU of 30-day survivors was 3 years (IQR, 1- 5 years) and median FU of those 22 patients who remained alive at the end of the study period was 4.8 years (IQR, 3 – 6 years).

The indications for intervention were 37 aneurysms, 5 accidental overstenting, 4 pseudoaneurysms, 4 restenting and 1 dissection. Of the aneurysms, 19 were ruptured at the time of presentation. Median aneurysm diameter was 75 mm (IQR, 63 - 90 mm).

The diversity of the included patients in each group (thoracic and abdominal) made further grouping and subclassification difficult. Further analyses were of interest, for instance the shortest stents overlapping that would secure sealing, the course and direction of CG that would prevent EL-I, the outcome of different types and sizes of utilized CGs. Such analyses were not possible because of the limited number of our patients.

The impact of major associated comorbidities are seen in the high rate of deaths among the patients. This is in contrast to most other reports on CGs but reflects our long FU period and also the selection of patients that is dominated by emergent/urgent cases where other techniques really has not been an option.

Paper IV

A good quality CTAs (n=206) of 248 patients with ruptured AAA that were treated at the vascular center of Skåne university hospital between January 2006 and June 2013, were analyzed. A centerline-of-flow (CLF) 3D reconstruction was generated with a workstation (AquariusWS; Terarecon, San Francisco, CA, USA), and the aneurysmal neck, distances between the vessels, neck diameter, aortic

diameter at the SMA level, iliac attachment sites, suprarenal angle (α) and infrarenal angle (β) were measured and used for the assessment. Based on the instruction of the intention for use (IFU) for commercially available SG devices an assessment of the suitability for standard EVAR was made compared to the extended suitability when using CG technique with EVAR for those patients who have a short aneurysmal neck as the only contraindication to the standard EVAR. The sealing zone was extended by placing a unilateral CG to the most distal renal artery or bilateral renal CGs. Acceptable sealing zone with a CG was defined as being ≥ 15 mm in length, not compromising the SMA takeoff and with a maximal aortic diameter of 30mm. A CG was not considered an option when supra- or infrarenal angulations were outside of the IFU recommendations. Aneurysm classification was made according to the reporting standards for endovascular aortic aneurysm repair (Chaikof et al. 2002).

Ethics

The Ethical advisory board approved the study and informed consent was obtained from all patients. No human identity or privacy is involved and the treatment provided to this cohort of patients was the standard care of our department.

Statistics

Data is in paper I-III presented as numbers, percentages, medians and range or interquartile range (IQR). Kaplan-Meier estimate was used to construct outcome curves. In paper IV data was presented in mean \pm standard deviation (SD). The length, diameter and angulation measurements were tested by one-way analysis of variance. Chi-square test compared the percentages and a P value < 0.05 was considered significant. IBM SPSS program version 20 (IBM Corporation, Armonk, New York, USA) was used for these analyses.

Results

Paper I

Technical success was achieved in 100%. This study focuses mainly on the technical feasibility and safety of this new indication for CG. All the aortic occlusions could be crossed, SGs deployed without adverse complications and all the stenosed or occluded visceral arteries could be cannulated. This required multiple adjunctive maneuvers such as the use of buddy wires, body floss wires and others. All stents remained patent during the study period. One patient died on the ninth postoperative day of uncompensated heart failure.

Paper II

The median hospital stay was 7 days (4-17). All-cause mortality was 52% (15/29), of them two deaths were CG-related that occurred after eleven months. The 30-day mortality was 14% (n=4), all were emergent cases. The median FU time was 2 years (.6-3.8 years) and the primary technical success, according to the reporting standards for thoracic endovascular aortic repair (Fillinger et al. 2010), was obtained in 86% (25/29) of the patients. All primary and secondary (early and late) EL-I (21%, 6/29) occurred in supraaortic branches, where primary EL-I (10%, n=3) required prompt reintervention within days, 2/3 secondary EL-I required delayed reinterventions after 4-16 months observation and the third was sealed spontaneously. CG-related reinterventions were required in seven patients (24%). The secondary patency rate of the CGs was 98 (40/41). The aneurysm sac shrank in 17/25 (68%). Sacrificing celiac trunk and LSA were generally well tolerated without serious complication (Table IV).

Table IV

Early and mid to long-term results of chimney grafts with thoracic endovascular aortic repair in 29 patients.

Abdominal CG	Early Primary (≤30 day)	Late Secondary (>30 day)	Total
Median FU (year, IQR)	2.5 (1-4)	3.5 (1.9-6.4)	2 (.6-3.8)
All-cause mortality	14% (4)	38% (11)	52% (15/29)
Procedure-related mortality	14% (4)	7% (2)	21% (6)
30-days mortality	14% (4)	----	14% (4)
CG-related mortality	----	7% (n=2)	7% (n=2)
Type I EL	10% (n=3)	10% (n=3)	21% (6/29)
CG-related reinterventions	17% (n=5)	7% (n=2)	24% (7/29)
CG patency	95% (39/41)	98% (40/41)	98% (40/41)
Shrinkage of aneurysm sac	----	----	68% (17)
Favorable outcome	----	----	66% (19/29)

Paper III

Seventy-three CGs were implanted into the visceral branches of the abdominal aorta in 51 patients. The CGs were constructed of 113 stents and SGs.

The median hospitalization time was 9 days (IQR, 5-15) and the median follow-up (FU) was 2.3 years (IQR, 0.8 – 5 years). The median FU of those 22 patients who remained alive at the end of the study period was 4.8 years (IQR, 3 – 6 years) (Table V).

Thirty-day mortality was 10% (5/51), all of them were procedure related and urgently handled cases. Six percent (n=3) of the deaths were considered CG-related, and 16% (n=8) were procedure related. All-cause mortality was 57% (n=29).

The median length of CGs was 48 mm (IQR, 30 – 93 mm) with a median stent diameter of 7 mm (IQR, 6 – 8 mm). Patients with long thoracoabdominal pathology (n=8) were treated with the so-called sandwich technique (Figure 11) (n=5) and periscope SG (n=5).

The primary assisted and secondary technical success rate was 82% (42/51) and 90% (46/51) respectively. The primary assisted patency was 96% (70/73). Thirty-one visceral branches were consciously sacrificed for technical reasons, of them

30 patients required an extension of the sealing zone. Two patients had two visceral branches sacrificed (celiac trunk and right renal artery), and a third patient with a sacrificed celiac trunk but one of his renal CG was permanently crushed postoperatively. The three patients suffered CG- related complications and respectively died nine months, eleven months and 10 days postoperatively.

Primary EL-I occurred in five patients (10%) (Table VI). All primary EL-I seemed to be originated from the left renal artery. Two patients were successfully restented, one was successfully embolized and one is still under conservative management for the sixth postoperative year. There was no secondary endoleaks but a single recurrent EL-I, which had relatively short CGs (22-38 mm) with balloon expandable SGs. The aneurysm sac shrank in 63% (29/46) (Figure 16) of the 30-days survivors, increased in 13% (6/46) and remained unchanged in 15 % (7/46). Chimney graft-related reintervention was required in 8 patients (16%), four within 30 days. The long-term primary and assisted primary CG-patency was 89% (65/73) and 92% (67/73), respectively.

Among the 30-days survivors, serum creatinine was significantly ($\geq 20\%$) increased in 26/46 (57%) (Figure 16). Of these 17 (65%) patients had a sacrificed kidney by two of them the renal artery was postoperatively unintentionally occluded or crushed. Twelve/46 (26%) patient developed chronic renal failure that ultimately required permanent hemodialysis. Eleven/12 (92%) of them had a lost kidney, among them eight kidneys were intentionally intraoperatively sacrificed (Table V). The median age of patients with a sacrificed kidney was 80 (74-82) years, of them 15 had a ruptured aneurysm. The total implanted renal CGs in the 30-day survivors were 50 (right renal artery=29 and left renal artery=21), and the sacrificed renal arteries were 17 (right=six and left=11) (Table V). Four patients were preoperatively known of having renal impairment; two of them underwent renal sacrifice and three required permanent renal dialysis (Table V).

Tabel V

Long-term results of visceral CGs with urgent endovascular aortic repair of complex lesions in 51 patients.

Abdominal CG	Early Primary (≤ 30 day)	Late Secondary (>30 day)	Total
Median FU (year, IQR)		4.8 years (IQR, 3–6)	2.3 (0-7.5)
All-cause mortality	10% (5)	47% (24)	57%
Procedure-related mortality	10% (5)	6% (3)	16 %
30-days mortality	10% (5)	n.a.	10%
CG- related mortality	0	6% (3)	6%
Type I EL	10% (5)	2% (1) recurrent	12%
CG-related reinterventions	8% (4)	8% (4)	16%

CG patency	89% (65/73)	93% (68/73)	93%
Renal impairment	n.a.	57% (26/46)	57%
Permanent dialysis	n.a.	26% (12/46)	26%
Shrinkage of aneurysm sac	n.a.	63% (29/46)	63%

Kaplan Meier outcome functions of both thoracic and visceral CGs showed a higher rate of EL-I compared to CG occlusion (Figure 17).

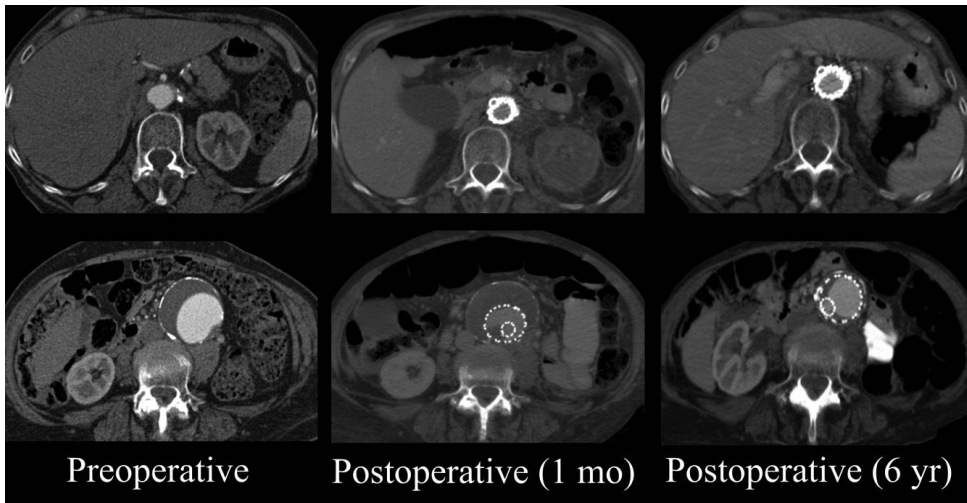


Figure 17

Computed tomography angiography of an 84 years old female patient, who presented with symptomatic abdominal aortic aneurysm with sharply angulated neck. Semi-urgent endovascular aneurysm repair with chimney graft to right renal artery was performed. Left renal artery was sacrificed. The pictures show preoperative, two-months and six years postoperative results, where chimney graft remained patent and aneurysm shrank significantly. She is still doing fine in her 8th postoperative year. She developed chronic renal failure, however, without requiring dialysis.

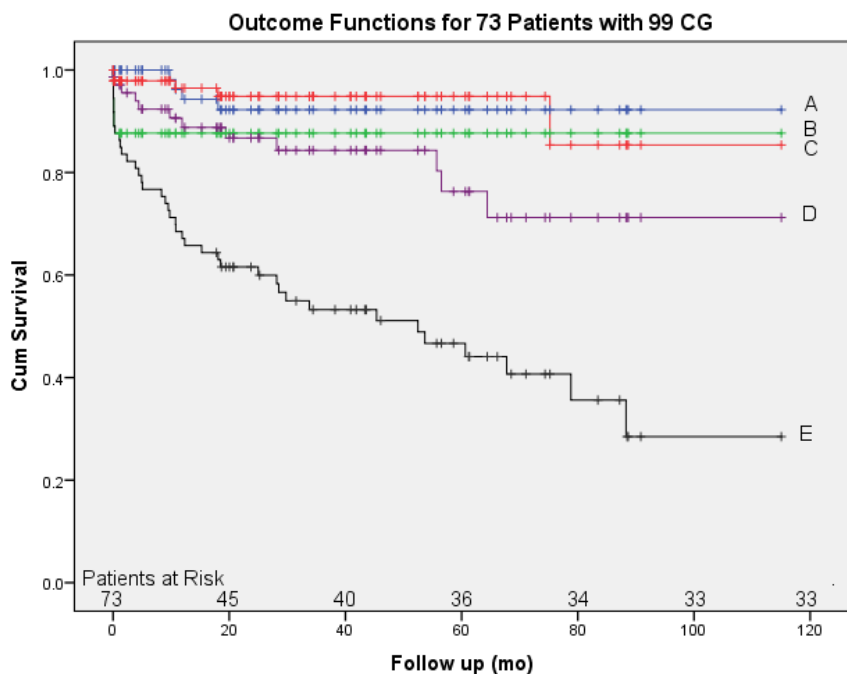


Figure 17
Kaplan-Meier outcome curves of 73 patients who were treated with 99 CGs and endovascular aortic repair (EVAR and TEVAR) for urgent complex aortic lesions. The curves are presenting the freedom from A= chimney related mortality, B= 30-day mortality, C= CG occlusions, D= EL-I and E= all-cause mortality.

Table VI
A chimney branch-related outcome for 73 patients with different complex aortic lesions who were urgently treated with 99 CG technique and TEVAR or EVAR.

CG Location	BT	LCCA	LSA	CT	SMA	RRA	LRA	Total
No	7	13	4	1	19	31	24	99
CG Occlusion	0	0	0	0	2	1	4	7(7%)
Primary EL-I	3	0	0	0	0	1	5	9 (9%)
Secondary EL-I	1	2	0	0	0	0	0	3 (3%)
Sacrificed branches	0	0	10	11	0	9	13	43 (59%)
Bleeding	0	0	0	0	2	0	1	3 (3%)

BT, brachiocephalic trunk; *CT*, celiac trunk; *LCCA*, left common carotid artery; *LRA*, left renal artery; *RRA*, right renal artery; *SMA*, superior mesenteric artery.

Paper IV

Of the included patients, 85% were men with a mean age of 75 ± 7.8 years (women 76 ± 7.5 years). Sixty-three percent (130/206) of the rAAA were infrarenal, 32% (66/206) juxtarenal (no healthy aorta between aneurysm and renal arteries) and 5% (10/206) suprarenal (splanchnic and/or renal arterial involvement). Women had smaller AAA diameters upon rupture with larger suprarenal angulation and smaller iliac access. Standard-EVAR suitability was 34% (70/206) (Figure 18) (male 37%, female 16%, $p < 0.01$), with 32 different combinations of exclusion criteria within the cohort. Sixty-five percent ($n=89$) of unsuitable patients had aneurysm neck < 15 mm and short neck was the only exclusion criteria in 24% ($n=33$) (Figure 18). In short neck aneurysms where no other exclusion criteria was present, a proximal sealing zone > 15 mm could be achieved with one or two renal CGs in 36% ($n=12$) and 76% ($n=25$), increasing overall suitability to 40% and 46% respectively.

Other anatomical factors such as large neck diameter, severe neck angulation or access related issues (often in combination with short necks) accounted for the remaining exclusion criteria. In 45% of patients, exclusion criteria was solely based on short necks (24%), or access related issues (9%), or combination of these (12%).

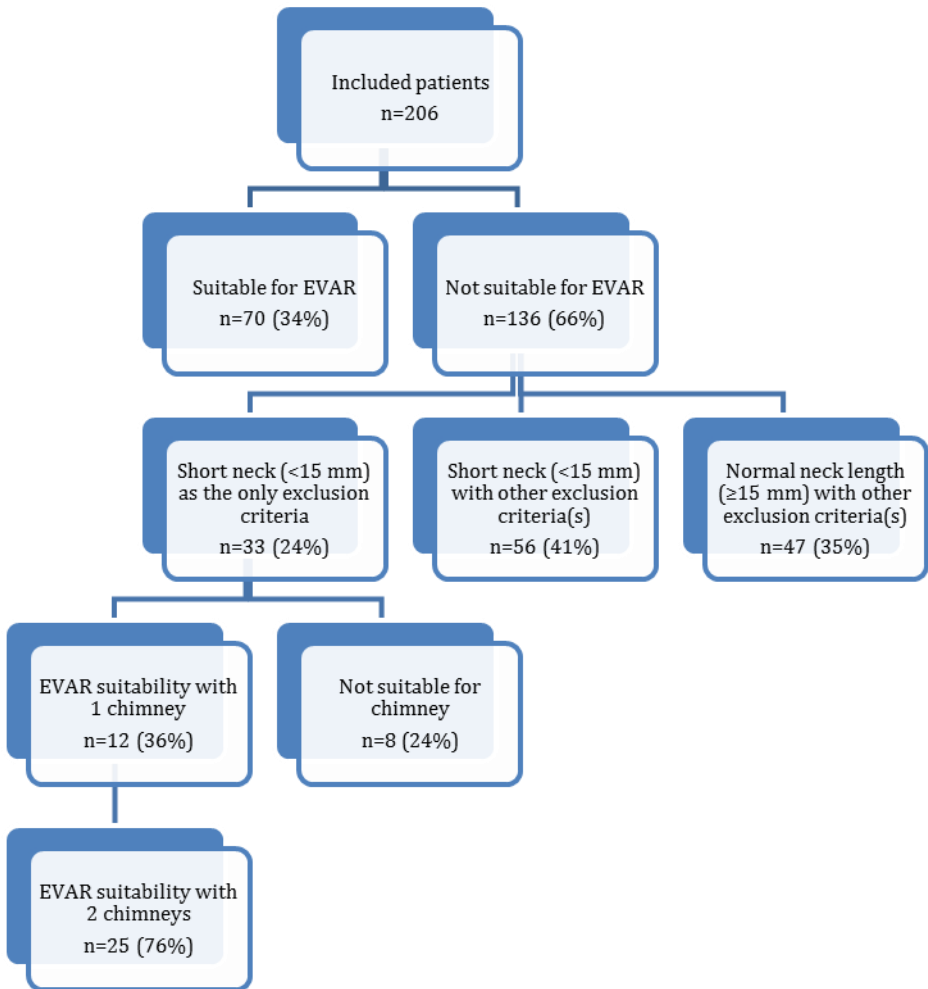


Figure 18
Flowchart demonstrating the overall anatomical suitability of rAAA for EVAR. It also shows the contribution of one and two renal CG/s in increasing the rAAA-suitability for EVAR.

Discussion

The first application of CG technique that we are aware of was in 1999 (Figure 10) (Lönn and Malina, oral communication) as a bailout procedure to rescue an accidentally overstented renal artery during EVAR, the first published report mentioning this technique was in 2003 (Greenberg et al. 2003). In memory of dr. Greenberg, we acknowledge his contribution to the dissemination of his technique although he himself was never fully convinced of its efficacy. It was theoretically hard to believe that a small SG would endure the high forces of aortic pressure and function durably without major complication or adverse effect. There was a concern that the implanted CG would disturb the conformability of the main SG and the laminar blood flow, form a nidus for new thromboembolic or obstructive events and create gutters alongside the main SG, which may lead to EL-I and eventually rupture. However, the outcome turned out to be better than expected and encouraged several specialized centers to adopt this technique and expand its application to involve the juxtarenal, suprarenal and the thoracic aorta including the arch (Larzon et al. 2005, 2008, Ohrlander et al 2008, Lachat et al. 2010). Physicians simply could not resist the temptation to further expand this new technique in treating not only aneurysms but also aortic occlusive diseases, dissections, ruptures, infections, fistulas, traumatic transections and difficult complications of previous open as well as endovascular aortic repair (Lachat et al. 2013).

The possibility to handle emergent cases and the use of CG as a rescue possibility made this technique useful when other advanced technique failed, such as the branched SG, fEVAR or in-situ fenestration failed, however, as seen from our summary and reviews by others (Katsagiris et al. 2013, Wilson et al. 2013) a large proportion of CG-cases are elective cases where other treatment options also were at hand.

The most recognized shortcoming of the CG technique was EL-I, which may have discouraged a wider implementation and limited the interest in developing it further (Moulakakis et al. 2013). Twelve years have elapsed since the introduction of the CG technique and up to date there has been little further development of the CG devices (Stewart et al. 2014). The development so far was by physicians who extended the used off-the-shelf SGs in various ways such as the periscope and sandwich-technique (Lachat et al. 2010, Lobato & Camacho-Lobato 2011).

Commercially, there is a greater benefit from developing the most complex devices such as branched and fenestrated SGs, while the beauty of the CGs is that they are simple and readily available. Still, dedicated CGs need to be developed and may incorporate a thrombogenic coating of the external surface or covered CGs that are more flexible with a lower profile. Some of these improvements are happening and only longer covered stents that can be passed through 6 F sheaths are available.

Even in the absence of dedicated devices, the applicability and indications for the CG technique are expanding (Figure 19) and it is often used for the extremely difficult and urgent cases or when other advanced alternatives, including OR, either fails or is deemed too risky (Criado 2007, Schiro et al. 2013). In many countries, the cost of fEVAR or bEVAR has been prohibitive, which made the CG technique the only possible therapeutic option for many patients (Zhang et al. 2012, Guo et al. in press). Below are two examples of CGs used as bailout after the failure of other techniques (fEVAR and in-situ-fenestration) (Figure 19, 20).

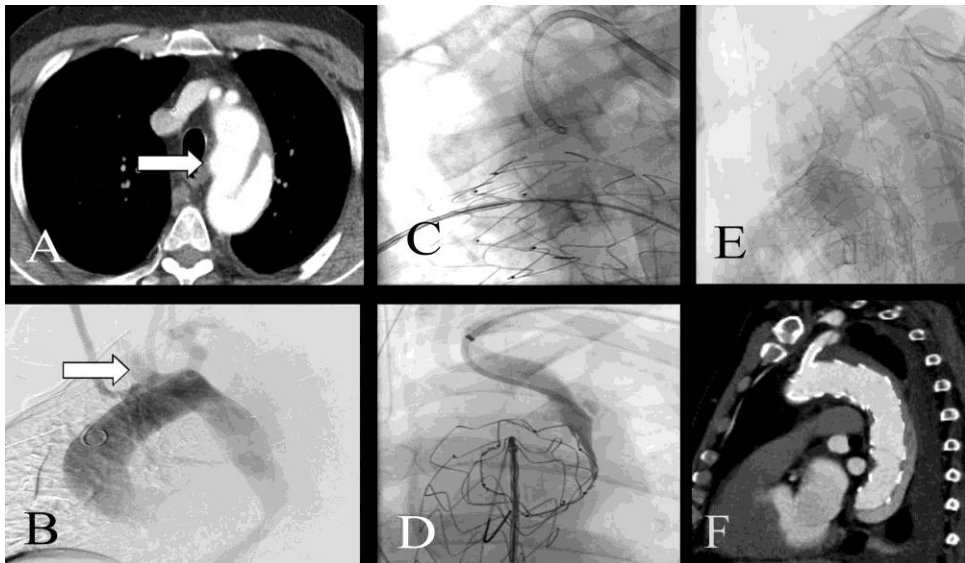


Figure 19

Sixty-nine years old male patient with arteria lusoria (arrows) presented acutely with symptomatic aortic dissection type B (A) that extended distally to the external iliac arteries. Patient underwent TEVAR (B) with attempted in-situ fenestration to LSA, however this failed because the angulation was not suitable (C and D). CG-placement (E) rescued the situation and CG was successfully inserted into the LSA (F).

The studies in the present thesis demonstrated different clinical aspects of the CG technique including its applicability, efficiency, durability, deficiencies and its

contribution to expanding the indication for endovascular therapy for urgent, complex aortic lesions. Among these, we were the first to describe/report its novel and safe applicability in treating juxtarenal occlusion of the aorta (paper I).

Paper I studied the applicability of CG technique in treating midaortic (juxtarenal) occlusion in urgent patients who were deemed unfit for major thoracoabdominal surgery. Manipulating a stenosed or occluded juxtarenal aorta and deploying a SG in the stenosed juxtarenal level carries a significant risk of dislodgement of emboli that can occlude the adjacent visceral vessels or may result in serious distal embolization (Mangialardi et al. 2014).

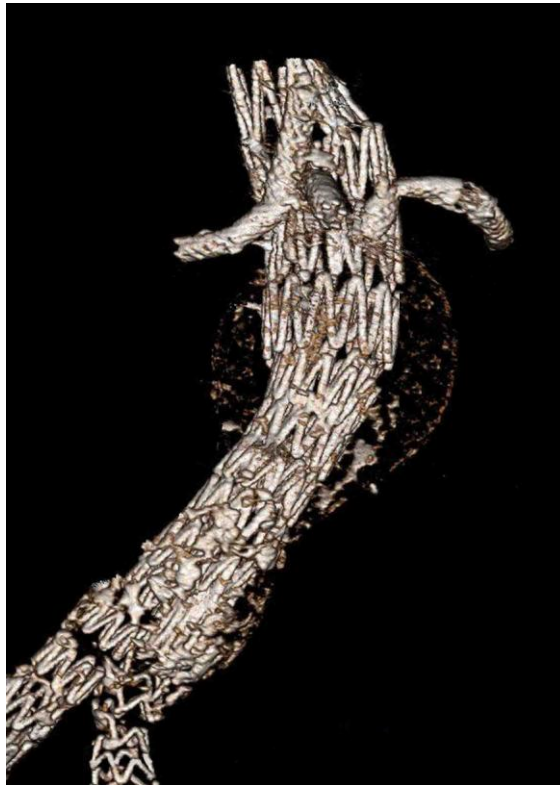

Figure 20

Fenestrated SG failed to stent the right renal artery, and then rescue-CG was possible to implant instead and maintain flow to the kidney.

The CG technique was proposed to these patients because they were considered high-risk for OR and consequently had no alternative therapy. All procedures were technically and clinically successful. Mangialardi and coworkers have reported beneficial results maybe with a more pronounced risk of peripheral embolization

(Mangialardi et al. in press). We realize that a firm conclusion cannot be built on our limited number of patients (n=10), however, the midterm results were convincing without major complication or CG-related death and all stents remained patent during the midterm FU period. In addition, the renal function improved in the three patients with a preoperative chronic renal impairment. These results seem promising and may allow a wider implementation of this technique for such group of patients. In occlusive disease of the aorta, endoleak is a rare complication of CG technique, however in non-occlusive disease it was the most intimidating complication.

Another finding is that our 10 treated patients all were females. "Coral reef syndrome" as well as juxtarenal aortic occlusion has been seen more often in females (Hultgren et al. 2005, 2013). We can only speculate on why this gender difference is noted since more distal aorto-iliac occlusive disease has more equal distribution between the genders.

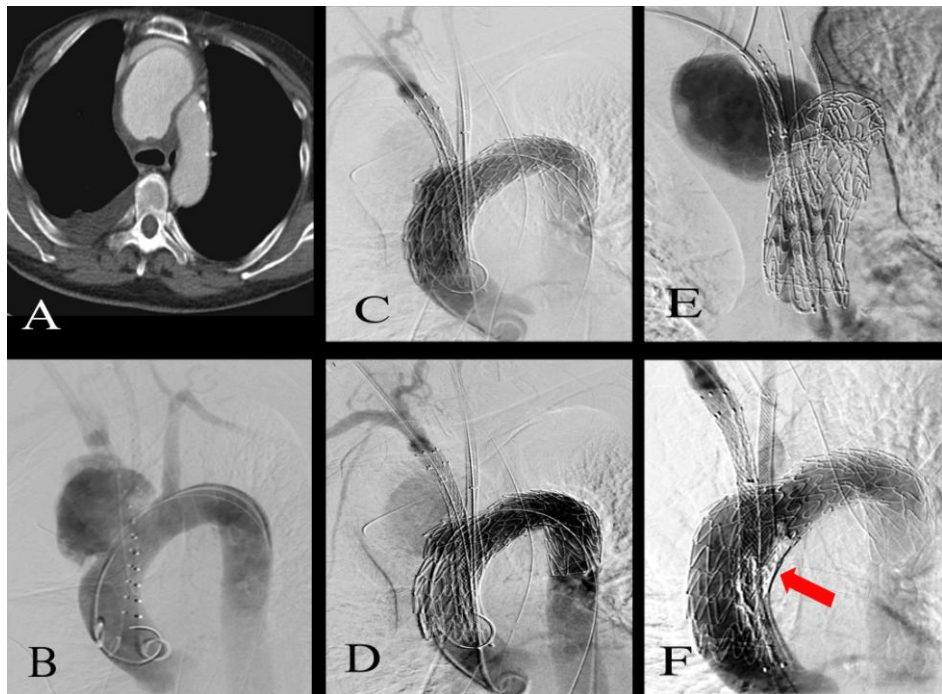


Figure 21

Case illustrating the complexity of the patients, potential drawbacks of the chimney technique and the lack of alternatives:

Patient with septicemia who developed a symptomatic mycotic pseudoaneurysm at the arch of the aorta and BT. The mycotic aneurysm expanded 1 cm in three days (**A**, **B**). The patient also had generalized colonic cancer and was deemed inoperable. She underwent semi-urgent TEVAR with chimneys to BT and LCCA (**C**), however, a minor EL-I was noted (**D**). Postoperatively, there was

further growth of the pseudoaneurysm and high-flow EL-I (*E*) which was treated with thrombin- and Onyx injection (arrow) (*F*). Almost no EL-flow was seen after this. The patient improved, infectious signs normalized but recurrent symptoms and increased EL-I eventually led to open arch reconstruction. She died 4 months later from her malignancy.

Paper II evaluated the mid to long-term outcome of CGs in high-risk patients with urgent complex non-occlusive diseases of the thoracic aorta (Figure 21). The results (Paper II) demonstrated an unexpectedly good efficiency and durability of CGs with 21% EL-I, 98% secondary patency, 24% CG-related reintervention, 7% CG-related mortality and 52% all-cause mortality. The EL-I was mostly manageable, which is in agreement with the findings of others (Mangialardi et al. 2014, Xue et al. in press), and in our series the brachiocephalic trunk was the major source with 67% (4/6) of all EL-Is. (Table VI) It seems that the brachiocephalic trunk is not only a risk for EL-I but also for other CG-related complications including mortality. This may be caused by the fact that the brachiocephalic trunk is a large vessel that creates larger gutters but also by a more extensive arch disease. Only one of the seven patients with a stented brachiocephalic trunk remains alive. This finding concurs with other reports (Hogendoorn et al. 2013).

The patency of all CGs were excellent (98%) in comparison to the other advanced fenestrated and branched SGs (97%) or even to OR (97%) (Ouzounian et al. 2014).

The overall survival of our patients may seem disappointing but compares favorably with other reports on urgent handling of thoracic aortic disease (Carpenter et al. 2014)

Patients in paper III received visceral CGs for mainly urgent, complex aortic lesions. Among them was the most frequent complication not EL-I but chronic renal impairment (57%), which was not so dramatically reflected in other studies (12%, 12%, 0%) (Katsargyris et al. 2013, Moulakakis et al. 2012, Lachat et al. 2013). It is unclear why other studies report less renal impairment among their patients. The higher age, urgency and lesion complexity of our patients may not suffice to fully explain this difference. There may also be differences in the definition of permanent chronic renal impairment. An asymptomatic stent-kink, renal artery thrombosis or stenosis may not be observed and lead to unilateral renal ischemia and atrophy, despite of routine urine analysis or renal function test and with today normally used imaging techniques (Pfister et al. 2010). Then, an important question is still open, namely if renal impairment could be prevented during such interventions? We don't have a definitive answer for this question. However based on our finding, all patients who ultimately required permanent dialysis (n=16) had by one way or another lost a kidney. Twelve patients had an intentionally sacrificed kidney. One patient had previous nephrectomy due to

cancer, one had a crushed renal CG, and two patients had a critical renal artery stenosis. Such strong association emphasize the importance of preserving both kidneys in such procedures in an elderly population. In order to achieve this goal, it seems particularly important to avoid sacrificing a kidney unless it is unavoidable.

If renal sacrifice cannot be avoided, the less functioning kidney should be selected if possible. Stringent postoperative renal FU is clearly important. Liberal use of anticoagulation may prevent chronic thromboembolisms and late trash of the kidneys.

The frequency of type I endoleaks have as reported in the summary and reviews been surprisingly low (Katsagyris et al. 2013, Wilson et al. 2013). Few developed during FU as also noted in this series. Maybe the risk is higher in thoracic CG-repair especially for late endoleak type I but still the low number of reported cases and the short FU-times do not allow firm conclusions to be made (Paper II, III, Lachat et al 2013). It is also shown both in our series and reviews that the majority of endoleaks type I can be treated successfully with endovascular technique more often in the visceral CGs compared to the thoracic CGs (paper II, III, Xue et al 2014, Guo et al. in press, Lachat et al. 2013).

Another concern regarding CG repair was to have two graft fabrics lying parallel to each other in a pulsatile environment without fabric tears and late endoleaks type III. We did not find such outcome among our patients. Only few such cases have been reported and in many of them, it seems more to be due to separation of component rather than tears in the fabric (Lachat et al. 2013). Another cause of concern has been migration of the grafts. The CG lying on the outside of an aortic SG, could potentially reduce the proximal fixation and increase the risk of migration of the SGs.

We observed one thoracic patient with this EL-I from a CG in the brachiocephalic trunk that was caused by distal migration of the main aortic SG (Paper II). This has also so far only been reported in a few instances, mostly in thoracic cases (Larzon et al. 2008).

We observed relatively different results of CGs used in the thoracic aorta versus the abdominal aorta. EL-I was more frequent in CGs of the supra-aortic branches (21%) compared to those of the visceral aortic branches (12%), whereas CG occlusions are more common in the visceral branches. This observation is also reflected when comparing the different Kaplan-Meier curves (Papers I and II), however the total survival function of both thoracic and visceral CGs (Figure 16) indicated that EL-I still is more frequent than CG occlusion. A possible explanation for this difference could be that the thoracic CGs are shorter in length, larger in diameter and surrounded by the strong continuous movements of the

heart and lungs. The alignment and angulation of the aortic branches are also different and may contribute to the problems, especially the secondary EL-I (10% vs. 0%). The reasons may also have beneficial effects such as a slightly increased secondary CG patency among thoracic CGs (98%) compared to the visceral CGs (93%). Overall, the 30-day mortality (14% vs. 10%) and the CG related reinterventions (24% vs. 16%) seem somewhat increased among the thoracic group of patients. The early required reinterventions were 71%, (5/7) for the thoracic group, and 50% (4/8) for the abdominal group. The later CG related reintervention are increased among the visceral group because infection and bleeding were more frequent among them (Figure 22). Of all reinterventions, the complementary open surgical procedures were more required for the thoracic group of patients (57%, 4/7 vs. 25%, 2/8). This may also reflect an increased technical demand for inserting supraaortic CGs; hence, it is associated with frequent complications in the early postoperative period.

The CG-related mortality, all-cause mortality, a favorable outcome and shrinkage rate of the aneurysmal neck are almost similar between the thoracic and abdominal

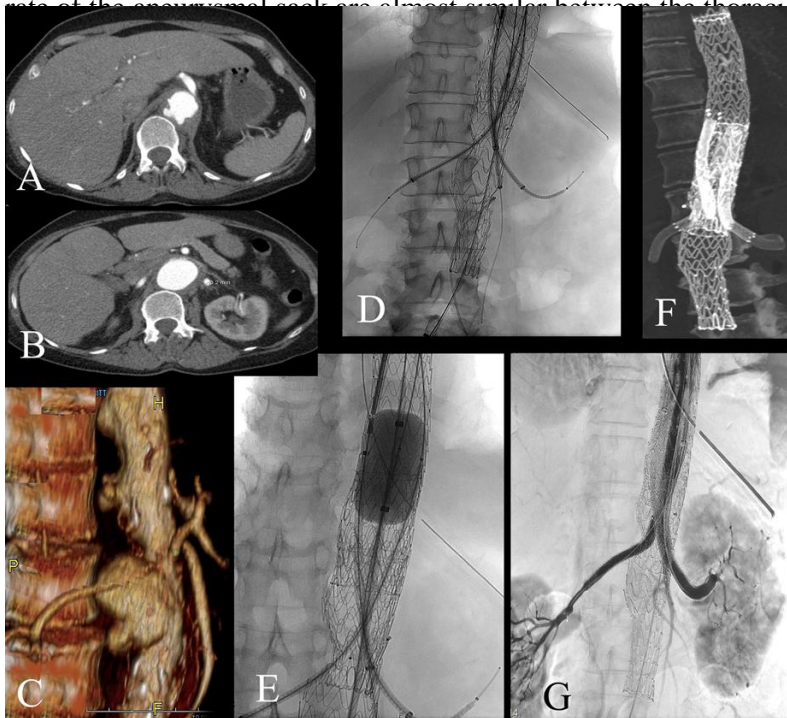


Figure 22
63 year old woman with pneumococcal pneumonia with sepsis and abscess formation that became multifocal despite of drainage and antibiotics.

She developed symptomatic mycotic pseudoaneurysms in the thoracic and visceral part of aorta and aorta enlarged rapidly.

She was treated endovascularly with CGs with sandwich technique to SMA, RRA and LRA and Cel Tr was embolized.

Postoperatively acalculous cholecystitis but no other procedure related complication. In FU the several mycotic aneurysms obliterated totally, no infectious sign and at 4year control patent CGs and no other complications found.

The need for CG technique may vary according to the pathology and aortic morphology, where it still constitute the only definitive therapeutic option for midaortic occlusive diseases in elderly patient with severe comorbidities, it is not superior to the fenestrated or branched SG in a suitably elective cases (Wilson et al. 2013). Open repair is still the standard treatment for many aortic pathologies in many centers.

Additional statistical analysis was initially aimed to unmask the relationship between the various types, diameters, and lengths of the utilized SGs and the outcome of aortic repair. Spearman correlation test has indeed shown several positive relationships, however a more advanced meaningful statistical analysis was prohibited by the overwhelming diversity and complexity of the cases combined with the limited number of patients. In the absence of solid conclusions, we refrained from these data.

The fourth study demonstrated that CG technique could increase the anatomic suitability of rAAA for EVAR. With each renal CG, there is 6% increased suitability of ruptured aortic aneurysms for the endovascular repair. The study demonstrated that the number of patients that could be treated endovascularly according to the instructions for use (IFU) is lower than anticipated. If one extends the use outside the IFU-criteria, a larger proportion of patients is possible to handle endovascularly (Larzon and Skog 2014).

In our series, six cases had aortic or graft infections with severe comorbidities that made them unfit for open surgery. They had no other option than endovascular treatment. Often it is claimed that it can be used as a bridge to a later staged surgery with the aim of eradicating the infection. Only one of our patients had a secondary procedure done.

Limitations of the studies

Chimney graft technique is relatively a new technique that is yet not widely nor routinely implemented in all centers. For this reason, the related data and studies are limited.

The uniqueness and complexity of each patient made it difficult for us to categorize and group them properly.

It is difficult to obtain longer FU period with larger group of patients because of the advanced age of our patients with the associated sever comorbidities that dramatically decreases the life expectancy of our patients, who usually die due to other causes.

If one exclude deaths, the FU time is 9.4 years and 7.5 years in papers II and III respectively.

Conclusions

Chimney graft technique demonstrated clinically acceptable results in treating both occlusive and non-occlusive diseases of the aorta in almost all parts of the aorta.

It showed good early, mid and long-term results that are comparable to open surgery, fenestrated or branched SG in the arch descending, thoracoabdominal and abdominal aortic lesions. It can routinely be advocated for urgent, complex cases with severe comorbidities and for some elective cases.

Chronic renal impairment is an obvious risk in cases where renal artery needs to be sacrificed. This fact should be considered preoperatively and during the follow-up period.

Future considerations

Chimney graft technique has the potential for further improvement. It deserves more resources for the development of its components.

Improving the performance of CG may entitle for instance the adding of a thrombogenic coating at the middle thirds of the CG, and upper part of the main aortic SG, which may theoretically reduce the risk of EL-I. Ellipse or oval shaped CGs may theoretically enhance the seal of the para-chimney gutters.

Maybe the future has “in-built” channels on the outside of the main aortic SG giving the main graft a more circular form and without the irregular “indentations” that the usual CGs makes. This may optimize the proximal seal and avoid gutters from parallel grafts. Such channels may, however, make catheterization of vital side branches even more cumbersome. However, they might also improve outcome of CGs to BT that seems to be today the CGs with the highest risk for complications.

With the increasing number of patients also reported results for the elective use of CGs are acceptable with a not so high frequency of EL-I. A concern may be late EL-III and we need further and longer FU for analyzing such problems. That CGs has much less documentation than fenestrated SGs for elective treatment is important and still the role of CGs is mainly for treating emergent cases or where manufacturing customized SGs cannot be afforded.

For all endovascular therapy, access-related complications are the most frequent complications seen. More focus on how to improve the technique for a safer access and secured closure of access sites is important. Developing even lower profiles of CGs and main aortic SGs is also crucial.

Populärvetenskaplig sammanfattning på svenska

Inledning/introduktion

Öppen rekonstruktion av aorta innebär en påtaglig risk för postoperativa komplikationer och dödlighet, särskilt i den äldre befolkningen och i dem som är mindre lämpliga för en sådan stor operation. Endovaskulär aorta kirurgi förefaller säker, hållbar och effektiv när det finns tillräcklig proximal och distal tätningsszon för en stentgraft. Fenestratede och grenade stentgrafter har gjort det möjligt för att erbjuda endovaskulär kirurgi även till dem som inte har en tillräcklig tätningsszon. Men dessa special-kärlproteser är inte rutinmässigt tillgängliga, behöver måttanpassas och är tidskrävande att tillverka (4-6 veckor). De akuta komplicerade fallen och patienter med oklusiv aortasjukdom har inga andra behandlingsalternativ om de inte lämpar sig för öppen kirurgi. Chimney grafter (skorsten proteser) (CG) teknik fyller denna lucka och gör endovaskulär behandling för denna patientgrupp möjlig. En skorstensgraft är en liten kärlprotes som lägges parallellt med den aortala stentgraften och går till en sidogren som behöver bevaras. Skorstensgrafter bevarar blodflödet till viktiga sidogrenar (t.ex. hjärna, tarm, njurar) och utvidgar tätningssonen för aortala stentgrafter. Syftet med denna avhandling är att studera kliniska aspekter av denna teknik, inklusive tillämpning, säkerhet och långsiktig hållbarhet.

Avhandlingen innehåller följande fyra studier:

1. Skorstensgrafter bevarar blodflödet till njur- och tarmkärl och möjliggör säker stentning av aortaokklusion i buken. (10 kvinnliga patienter)
2. Effekt och hållbarhet av skorstensgrafter vid brådskande och komplexa aorta sjukdomar i bröstkorget. (29 patienter)
3. Långtidsresultat av skorstensgrafter för bevarande av njur- och tarmkärl vid brådskande rekonstruktion av bukaorta. (51 patienter)
4. Effekterna av skorstensgraft till njurarna på anatomisk tillämplighet av endovaskulär behandling vid brustet bukaortaaneurysm. (206 patienter)

Patienter och metoder

Alla patienter som fick en skorsten graft i denna studie ansågs mycket riskfyllda för öppen aortakirurgi. Samtliga fall behandlades akut eller brådskande. Majoriteten av de behandlade tillstånden var aortala aneurysm, dissektioner, pseudoaneurysm, infektioner, felaktig överstenting av en vital aortagren och svåra komplikationer av föregående öppen eller endovaskulär aortakirurgi. Patienternas median ålder var 75 (47-87) år och 32% var kvinnor. De tio patienterna med ocklusiv sjukdom var dock samtliga kvinnor.

Resultat

Skorstensgraft vid behandling av ocklusiv aortasjukdom är en helt ny tillämpning av denna teknik som förefaller säker och effektiv. Inga graft- eller kärlocklusionen sågs och för flera en förbättrad njurfunktion. De patienter som fick skorstensgraft för aortasjukdom i bröstkorgen hade 14% 30-dagars mortalitet, 7% skorstensrelaterad dödlighet, 21% typ I endoläckage, 98% sekundär öppetstående, och 68% av de aortala aneurysmen krympte i storlek. Den tredje studien innefattande patienter med skorstensgraft till njur- och tarmkäril och visade en 10% 30-dagars mortalitet, 6% skorstensrelaterad dödlighet, 93% långsiktig öppetstående och 12% typ I endoläckage. Trettioen större aortala grenar offrades varav 22 var njurartärer. 55% av de patienter som förlorade en njure blev permanent dialyskrävande. Den fjärde studien visade att skorstensgraft kan öka den totala lämpligheten av brustna bukaortaaneurysm för endovaskulär behandling från standardbehandling 34% till utnyttjande av skorsten graft till 40-46%.
Slutsatser

Oklusiv sjukdom kan komma att behandlas endovaskulärt tack vare skorstensgraft. Skorstensgraft förefaller även tillämpliga vid behandling av akut komplex aortal sjukdom både i bröstkorg och buk. I motsats till tidigare rapporter förefaller endoläckage inte vara en starkt begränsande komplikation för denna teknik och de flesta endoläckage kunde tätas endovaskulärt. Patienter där en njure offrades behövde dock permanent dialys i 57% av fallen. Skorstensgraft i en eller till båda njurartärerna kan öka den totala tillämpligheten av brustna bukaortaaneurysm för endovaskulär behandling med 12%.

Sammanfattningsvis förefaller skorstensgraft vara lovande vid brådskande komplexa aortasjukdomar i en högriskpopulation. Resultaten motiverar en fortsatt användning och utveckling av denna teknik.

ملخص الأطروحة بالعربية

مقدمة

العمليات الجراحية المفتوحة للشريان الأبهر (الأورطي) تحمل مخاطر عالية للمراضة والوفيات وخاصة عند كبار السن وعند المرضى الغير مؤهلين صحياً لعمليات جراحية كبرى كهذه. تعتبر عمليات علاج الأبهر بالقساطر (العمليات المغلقة) آمنة وفعالة ولها ديمومة جيدة عندما تتوفر منطقة عزل/ختم كافية عند الجزئيان العلوي والسفلي لدعامة (الانبوب المدعوم بهيكل من البلاستيك والمزروع داخل الشريان لتوصيل الدم) الأبهر الرئيسية. الدعامة المتطورة كالدعامة ذات النوافذ والدعامة ذات الفروع تمكنت من علاج الحالات المعقدة الاختيارية (الباردة) لأمراض الأبهر التي لا توجد فيها أماكن/مناطق عزل كافية لدعامة الأبهر الرئيسية. ومع ذلك، فإن هذه الدعامة لا تتوفر بشكل روتيني وتلقائي في غرف العمليات لأنها تصمم بشكل شخصي حسب مقاسات كل مريض على حدة ويستغرق تصنيع كل منها 4-8 أسابيع وبالتالي فإن الحالات الحرجة لا تستطيع الانتظار طول هذه الفترة ولن تستفيد من هذه الدعامة المتخصصة. أي انه لا توجد أي سبل أو خيارات علاجية لدى الحالات المعقدة الطارئة وحالات انسداد منتصف الأبهر (Midaortic or Juxtarenal aortic occlusion) الغير مؤهلين للعمليات الكبرى المفتوحة. تقنية دعامة الإمداد الدموي المزروعة (Chimney stent graft) أتت حديثاً لتسد هذه الفجوة وتمكّن عمليات قساطر الأوعية الدموية من علاج هذه الفئة من المرضى. دعامة الإمداد الدموي المزروعة تؤمن وتحافظ على تدفق الدم إلى الأعضاء الهامة المتفرعة شرايينها من الأبهر وفي نفس الوقت تمكّن الجراح من الحصول على منطقة عزل/ختم كافية للدعامة الرئيسية للأبهر بحيث يضمن ثباتها في موقعها المزروعة فيه مع الحيلولة دون التسريب الجانبي للدم.

الهدف من الأطروحة الحالية هو دراسة الجوانب السريرية لهذه التقنية الحديثة بما في ذلك إمكانية تطبيقها عملياً ومدى سلامتها على المريض وكيفية خدمتها داخل الجسم على المدى الطويل. كما تدرس الأطروحة إمكانية هذه التقنية ومساهماتها في توسيع دواعي التدخل العلاجي بقساطر الأوعية الدموية لعلاج الحالات الصعبة الطارئة سواء كانت في منطقة الصدر أم في البطن وعلاج حالات انسداد منتصف الأبهر وكذلك المضاعفات المستعصية الناتجة من عمليات سابقة في الأبهر بتقنيات أخرى سواء كانت مفتوحة أم مغلقة. تتضمن الأطروحة الدراسات الأربع التالية

1 - دعامة الإمداد الدموي المزروعة تحافظ على التروية الدموية لأعضاء البطن وتسمح بزراعة آمنة لدعامة الأبهر كعلاج لحالات انسداد منتصف الأبهر. (عشرة مرضى من النساء)

2 - فعالية وديمومة دعامة الإمداد الدموي المزروعة مع العمليات المغلقة لقساطر الأوعية الدموية

للأبهر في منطقة الصدر لعلاج الحالات المعقدة الطارئة. (29 مريضاً)

3 - النتائج طويلة المدى لتقنية دعامة الإمداد الدموي المزروعة لتأمين التروية الدموية لأعضاء البطن أثناء العلاج المغلق بقسطر الاوعية الدموية للحالات المعقدة الطارئة للأبهر في منطقة البطن. (51 مريضاً)

4 - تأثير دعامة الإمداد الدموي المزروعة على الملاءمة/التوافق التشريحية للعمليات المغلقة لقسطر الاوعية الدموية في حالات تمزق تمدد الأبهر البطني (ruptured abdominal aortic aneurysm). (206 مريضاً)

المرضى والطرق

جميع امراض هذه المجموعة ممن حصلوا على دعامة الإمداد المزروعة كانوا غير مؤهلين لعمليات كبرى مفتوحة وكانت حالاتهم طارئة استدعت معالجتهم على وجه السرعة. وشملت آفات الأبهر التي تمت معالجتها بهذه التقنية التمدد المرضي للأبهر (Aneurysm)، تسلخ الأبهر (Dissection)، التمدد الكاذب للأبهر (pseudoaneurysms)، والعدوى، اغلاق عرضي (overstented) لفروع حيوية للأبهر ومضاعفات مستعصية لعمليات سابقة في الأبهر سواء كانت مفتوحة أو مغلقة. بلغ متوسط عمر جميع المرضى 75 (47-87) سنة، منهم 32٪ من الإناث.

النتائج

كان الاستخدام الاستثنائي لهذه التقنية في علاج مجموعة محدودة من حالات انسداد منتصف الأبهر آمنة وفعالة ولم تظهر لها آثار سلبية تستدعي القلق. تكلفت جميع العمليات بالنجاح التقني وظلت جميع الدعامات مفتوحة أثناء فترة المتابعة التي تجاوزت الست سنوات عند بعض الامراض بل وتحسنت وظائف الكلى لدى من كانوا يعانون من قصور في وظائفها من قبل اجراء العملية. تضمنت نتائج علاج المرضى الذين عانوا من اعتلال الأبهر الصدري (29 مريض) الاتي: وفيات اول ثلاثين يوم بعد العملية 14٪، الوفيات ذات الصلة بدعامة الإمداد المزروعة 7٪، تسريب من النوع الأول (type I endoleak) 21٪، استمرار نفاذية (عمل) الدعامات 98٪، وانكسرت 68٪ من حالات التوسع المرضي للأبهر.

في الدراسة الثالثة بينت النتائج طويلة الأمد لدعامات الشرايين الرئيسية لأعضاء البطن (51 مريض) ان نسبة وفيات الثلاثين يوم قد بلغت 10٪ و6٪ نسبة الوفيات التي ترجع أسبابها الى الدعامة المزروعة واستمرت نسبة نفاذية الدعامات على المدى الطويل 93٪ بينما بلغت نسبة التسريب من النوع الأول 12٪. تم الاستغناء عمدا (لأسباب تقنية) عن 31 شريان بطني منهم 22 شريان كلوي احتاج 55٪ منهم الى غسيل دوري دائم للكلى. وأظهرت الدراسة الرابعة أن تقنية دعامة الإمداد المزروعة قد تزيد من ملاءمة حالات تمزق التوسع المرضي للأبهر البطني لعمليات قسطر الاوعية الدموية المغلقة من 36٪ إلى 40-46٪.

الاستنتاجات

أظهرت النتائج ان الاستخدام الاستثنائي لدعامة الامداد الدموي المزروعة في علاج حالات انسداد منتصف الابهر آمنة وفعالة. كما أظهرت دعامة الامداد الدموي المزروعة فاعلية وديمومة في علاج الأفات الأخرى الطارئة للأبهر الصدري والبطني لدى المرضى الغير مؤهلين لعمليات كبرى مفتوحة. وعلى عكس ما قد زعم في تقارير سابقة لا يبدو أن التسريب وليكان الدم يشكل مشكلة كبيرة لهذه التقنية، بل ان التدخل المغلق لقساطر الاوعية الدموية قادر على علاج اغلب حالات التسريب. ولكن التضحية بكلية لأمرض مسنين كهؤلاء يصاحبه نسبة خطورة عالية (55%) لفشل كلوي يحتاج الى غسيل دائم للكلى ولهذا يجب الحفاظ على كلا الكليتين قدر المستطاع. زراعة دعامة الامداد الدموي في أحد أو كلا الشرايين الكلوية قد تزيد من ملائمة حالات تمزق الابهر المتمدد للعلاج بواسطة قساطر الاوعية الدموية المغلقة بنسبة 12% كما ان هذه النسبة قد تزيد الى 60% إذا ما تم التغلب على مشاكل الوصول واختراق الشرايين.

وعموما، يبدو ان تقنية دعامة الامداد الدموي المزروعة ناجحة سريريا ولها نتائج واعدة في علاج الحالات الطارئة للأمراض الغير قادرين على اجتياز عمليات كبرى مفتوحة. هذا يبرر تطبيق أوسع لهذه التقنية ويدعو الى مزيد من الاهتمام لتطويرها.

Acknowledgements

This work has been accomplished with the support of several co-workers. While writing this in a hurry, I may forget mentioning dear names; therefore, I deeply apologize well in advance for such unfortunate. I would particularly like to thank:

The Erasmus Mundus window 7 (later called 8) team for the scholarship, and the successful leadership of Petter Pilsjö.

My main supervisor, associate professor Martin Malina, for the tough time, sincere advices and countless home-invitations. I certainly have learned a lot from him.

My main co-supervisor, associate professor Bengt Lindblad, for the time, knowledge and support that was given despite his retirement.

The co-supervisors associate professor Tim Resch and associate professor Anders Gottsäter for the cooperative responses to my questions.

A clean, justice, honesty, strong and supportive are titles that describes Ulrikke Voss, Aleksandra Popovic, professor Stefan Hansson, Claes Moreau and Anna Arstam, who during the difficult time was like a light in the darkness and the open door when all were closed. Thank you is a little to describe my feeling. These people reflect a bright face of Sweden that I like to keep in my memory.

There are people who were so human, cooperative and helpful. I mean dr. Leena Lehti, professor Inga Odenholt, Margareta Marvsten, Marie Ahlgren, Kjerstin Ädel, Alfonso letelier. Thank you.

Finally yet importantly, I thank my friends and family for their supportive attitude and warm feeling.

References

- Abbdel-Halim RE. Contributions of Ibn Al-Nafis (1210–1288 AD) to the progress of medicine and urology. A study and translations from his medical works. *Saudi Med J*. 2008;29:13-22.
- Aciduman A Arda B, Kahya E, Belen D. The royal book by Haly Abbas from the 10th century: one of the earliest illustrations of the surgical approach to skull fractures. *Neurosurgery*. 2010;67:1466-75.
- Acrel, Olof af. *Chirurgiska händelser, anmärkte och samlade uti Kongl. Lazarettet och annorstädes, med ansefliga tilökningar och bifogade afritningar, andra gången till trycket befordrade*. 2 ed. H. Fougst, Stockholm., 1775. 3rd ed. Stureförlaget, Stockholm, 1965.
- Albucasis A. *On surgery and instruments*. English translation and commentary by Spink M S and Lewis G L; The Wellcome Institute, London, 1973.
- Allaqaband S, Jan MF, Bajwa T. ‘The chimney graft’ – a simple technique for endovascular repair of complex juxtarenal abdominal aortic aneurysms in no-option patients. *Catheter Cardiovasc Interv*. 2010;75:1111–5.
- Amiot S, Haulon S, Becquemin J-P, Magnan PE, Lermusiaux P, Goueffic Y, Jean-Baptiste E, Cochenec F, Favre JP; Association Universitaire de Recherche en Chirurgie Vasculaire. Fenestrated endovascular grafting: the French multicentre experience. *Eur J Vasc Endovasc Surg*. 2010;39:537-44.
- Anderson JL, Adam DJ, Berce M, Hartley DE. Repair of thoracoabdominal aortic aneurysms with fenestrated and branched endovascular stent grafts. *J Vasc Surg*. 2005;42(4):600-7.
- Anderson JL, Berce M, Hartley DE. Endoluminal aortic grafting with renal and superior mesenteric artery incorporation by graft fenestration. *J Endovasc Ther*. 2001;8:3-15.
- Badger S, Bedenis R, Blair PH, Ellis P, Kee F, Harkin DW. Endovascular treatment for ruptured abdominal aortic aneurysm. *Cochrane Database Syst Rev*. 2014;7:CD005261.
- Baldwin ZK, Chuter TA, Hiramoto JS, Reilly LM, Schneider DB. Double-barrel technique for preservation of aortic arch branches during thoracic endovascular aortic repair. *Ann Vasc Surg*. 2008;22(6):703-9.
- Banno H, Frédéric Cochenec F, Jean Marzelle ,Becquemin J-P. Comparison of fenestrated endovascular aneurysm repair and chimney graft techniques for pararenal aortic aneurysm. *J Vasc Surg*. 2014;60:31-9.
- Barker WF. *Clio. The arteries*. R G Landers, Austin, 1992:2-502.

- British Society for Endovascular Therapy and the Global Collaborators on Advanced Stent- Graft Techniques for Aneurysm Repair (GLOBALSTAR) Registry. Early results of fenestrated endovascular repair of juxtarenal aortic aneurysms in the United Kingdom. *Circulation*. 2012;125:2707-15.
- Brechtel K, Ketelsen D, Endisch A, Heller S, Heuschmid M, Stock UA, Kalender G. Endovascular repair of acute symptomatic pararenal aortic aneurysm with three chimney and one periscope graft for complete visceral artery revascularization. *Cardiovasc Intervent Radiol*. 2012;35:413-7.
- Brock RC. The life and work of Astley Cooper. Livingstone, Edinburgh.1952:1-174.
- Bruen KJ, Feezor RJ, Daniels MJ, Beck AW, Lee WA. Endovascular chimney technique versus open repair of juxtarenal and suprarenal aneurysms. *J Vasc Surg*. 2011;53:895-904.
- Carpenter SW, Kodolitsch YV, Debus ES, Wipper S, Tsilimparis N, Larena-Avellaneda A, Diener H, Kölbel T. Acute aortic syndromes: definition, prognosis and treatment options. *J Cardiovasc Surg (Torino)*. 2014;55(2 Suppl 1):133-44.
- Chaikof EL, Blankensteijn JD, Harris PL, White GH, Zarins CK, Bernhard VM, Matsumura JS, May J, Veith FJ, Fillinger MF, Rutherford RB, Kent KC; Ad Hoc Committee for Standardized Reporting Practices in Vascular Surgery of The Society for Vascular Surgery/American Association for Vascular Surgery. Reporting standards for endovascular aortic aneurysm repair. *J Vasc Surg*. 2002;35:1048-60.
- Chuter TA. Branched stent-grafts for endovascular repair of aortic and iliac aneurysms. *Tech Vasc Interv Radiol*. 2005;8(1):56-60.
- Chuter TA, Green RM, Ouriel K, Fiore WM, DeWeese JA. Transfemoral endovascular aortic graft placement. *J Vasc Surg*. 1993;18(2):185-95.
- Cochennec F, Kobeiter H, Gohel MS, Majewski M, Marzelle J, Desgranges P, Allaire E, Becquemin JP, Coscas R, Kobeiter H, Desgranges P, Becquemin JP. Impact of intraoperative adverse events during branched and fenestrated aortic stent grafting on postoperative outcome. *J Vasc Surg*. 2014;60(3):571-8.
- Coscas R, Kobeiter H, Desgranges P, Becquemin JP. Technical aspects, current indications, and results of chimney grafts for juxtarenal aortic aneurysms. *J Vasc Surg*. 2011;53:1520-7.
- Creech O. Endoaneurysmorrhaphy. Treatment of aortic aneurysm. *Ann Surg*. 1966;164:935-46.
- Criado FJ. A percutaneous technique for preservation of arch branch patency during thoracic endovascular aortic repair (TEVAR): retrograde catheterization and stenting. *J Endovasc Ther*. 2007;14(1):54-8.
- Criado FJ, Duson S. Parallel grafts in perspective: definitions and a new classification. *Vasc Dis Manag*. 2013;10(1):16-9.
- Crowe SJ. Halsted of Johns Hopkins: The man and his men. In: *Surgery: Basic science and clinical evidence, Volume 1*. Ed. JA Norton, Springer, Springfield, 1957:210-218.
- DeBakey ME. The development of vascular surgery. *Am J Surg*. 1979;137(6):697-738.
- De Bakey ME, Cooley DA, Creech O Jr. Aneurysm of the aorta treated by resection; analysis of three hundred thirteen cases. *J Am Med Assoc*. 1957;163(16):1439-43.

- Dias NV, Resch TA, Sonesson B, Ivancev K, Malina M. EVAR of aortoiliac aneurysms with branched stent-grafts. *Eur J Vasc Endovasc Surg.* 2008;35(6):677-84.
- Dias NV, Resch T, Sonesson B, Malina M. Single superior mesenteric artery periscope grafts to facilitate urgent endovascular repair of acute thoracoabdominal aortic pathology. *J Endovasc Ther.* 2011;18(5):656-60.
- Di X, Ye W, Liu Cw, Jiang J, Han W, Liu B. Fenestrated endovascular repair for pararenal abdominal aortic aneurysms: a systematic review and meta-analysis. *Ann Vasc Surg.* 2013;27(8):1190-200.
- Donas KP, Torsello G, Austermann M, Schwindt A, Troisi N, Pitoulias GA. Use of abdominal chimney grafts is feasible and safe: short-term results. *J Endovasc Ther.* 2010;17:589-93.
- Dos Santos JC. Sur la désobstruction des thromboses artérielle anciennes. *Mem acad chir.* 1947;3:409-12.
- D'Utra G, O'Brien N, Maioli F, Perot C, Bianchini A, Maurel B, Guillou M, D'Elia P, Azzaoui R, Haulon S. Challenging treatment of a secondary endoleak in a fenestrated endograft. *J Endovasc Ther.* 2010;17:458-61.
- Dubost C, Allary M, Oeconomos N. Resection of an aneurysm of the abdominal aorta: reestablishment of the continuity by a preserved human arterial graft, with result after five months. *AMA Arch Surg.* 1952;64:405-8.
- Ducasse E, Lepidi S, Brochier C, Deglise S, Berard X, Alberti D, Midy D. The "open" chimney graft technique for juxtarenal aortic aneurysms with discrepant renal arteries. *Eur J Vasc Endovasc Surg.* 2014;47(2):124-30.
- Ebers G. Papyrus Ebers: Das hermetische Buch über die Arzneimitel der alten Ägypter in hieratischer Schrift. Leipzig, 1875.
- Edward ES, Edward PD. Alexis Carrel, visionary surgeon. Thomas, Springfield, 1974.
- Edwards ST, Schermerhorn ML, O'Malley AJ, Bensley RP, Hurks R, Cotterill P, Landon BE. Comparative effectiveness of endovascular versus open repair of ruptured abdominal aortic aneurysm in the Medicare population. *J Vasc Surg.* 2014;59(3):575-82.
- EVAR trial participants. Endovascular aneurysm repair versus open repair in patients with abdominal aortic aneurysm (EVAR trial 1): randomised controlled trial. *Lancet.* 2005;365(9478):2179-86.
- EVAR trial participants. Endovascular aneurysm repair and outcome in patients unfit for open repair of abdominal aortic aneurysm (EVAR trial 2): randomized controlled trial. *Lancet.* 2005;365(9478):2187-92.
- Fillinger MF, Greenberg RK, McKinsey JF, Chaikof EL. Reporting standards for thoracic endovascular aortic repair (TEVAR). *J Vasc Surg.* 2010;52:1022-33.
- Fitridge RA, Boulton M, Mackillop C, De Loryn T, Barnes M, Cowled P, Thompson MM, Holt PJ, Karthikesalingam A, Sayers RD, Choke E, Boyle JR, Forbes TL, Novick TV. International Trends in Patient Selection for Elective Endovascular Aneurysm Repair: Sicker Patients with Safer Anatomy Leading to Improved 1-Year Survival. *Ann Vasc Surg.* In press.

- Fukui D, Wada Y, Komatsu K, Fujii T, Ohashi N, Terasaki T, Seto T, Takano T, Amano J. Innovative application of available stent grafts in Japan in aortic aneurysm treatment-significance of innovative debranching and chimney method and coil embolization procedure. *Ann Vasc Dis.* 2013;6(3):601-11.
- Gehringhoff B, Torsello G, Pitoulias GA, Austermann M, Donas KP. Use of chimney grafts in aortic arch pathologies involving the supra-aortic branches. *J Endovasc Ther.* 2011;18(5):650-5.
- Greenberg RK, Clair D, Srivastava S, Bhandari G, Turc A, Hampton J, Popa M, Green R, Ouriel K. Should patients with challenging anatomy be offered endovascular aneurysm repair? *J Vasc Surg.* 2003;38(5):990-6.
- Greenberg RK, Lawrence-Brown M, Bhandari G, Hartley D, Stelter W, Umscheid T, Chuter T, Ivancev K, Green R, Hopkinson B, Semmens J, Ouriel K. An update of the Zenith endovascular graft for abdominal aortic aneurysms: initial implantation and mid-term follow-up data. *J Vasc Surg.* 2001;33(2 Suppl):S157-64.
- Greenberg RK, Sternbergh WC 3rd, Makaroun M, Ohki T, Chuter T, Bharadwaj P, Saunders A; Fenestrated Investigator. Intermediate results of a United States multicenter trial of fenestrated endograft repair for juxtarenal abdominal aortic aneurysms. *J Vasc Surg.* 2009;50:730-7.
- Greenberg RK, West K, Pfaff K, Foster J, Skender D, Haulon S, Sereika J, Geiger L, Lyden SP, Clair D, Svensson L, Lytle B. Beyond the aortic bifurcation: branched endovascular grafts for thoracoabdominal and aortoiliac aneurysms. *J Vasc Surg.* 2006;43(5):879-86.
- Greenhalgh RM, Brown LC, Kwong GP, Powell JT, Thompson SG; EVAR trial participants. Comparison of endovascular aneurysm repair with open repair in patients with abdominal aortic aneurysm (EVAR trial 1), 30-day operative mortality results: randomised controlled trial. *Lancet.* 2004;364(9437):843-8.
- Grimme FA, Zeebregts CJ, Verhoeven EL, Bekkema F, Reijnen MM, Tielliu IF. Visceral stent patency in fenestrated stent grafting for abdominal aortic aneurysm repair. *J Vasc Surg.* 2014;59(2):298-306.
- Guo W, Xiaohui M, Zhongzhou H, Xiaoping L, Xin J, Jiang X, HongPeng Z, Lijun WW; Zhang Jia, Zhang MinHong Z, Du Xin D. Endovascular repair with chimney technique for juxtarenal aortic aneurysm. *Eur J Vasc Endovasc Surg.* In press.
- Hagan PG, Nienaber CA, Isselbacher EM, Bruckman D, Karavite DJ, Russman PL, Evangelista A, Fattori R, Suzuki T, Oh JK, Moore AG, Malouf JF, Pape LA, Gaca C, Sechtem U, Lenferink S, Deutsch HJ, Diedrichs H, Marcos y Robles J, Llovet A, Gilon D, Das SK, Armstrong WF, Deeb GM, Eagle KA. International Registry of Acute Aortic Dissection (IRAD): new insights from an old disease. *JAMA.* 2000;283:897-903.
- Hamareh S K in *The Genius of Arab Civilisation* Ed. J R Hayes; 2nd edition, Eurabia, Ltd; London; 1983:198-200.
- Hansson GK. Inflammation, atherosclerosis, and coronary artery disease. *N Engl J Med.* 2005;352:1685-95.

- Hertault A, Sobocinski J, Kristmundsson T, Maurel B, Dias NV, Azzaoui R, Sonesson B, Resch T, Haulon S. Results of F-EVAR in octogenarians. *Ann Vasc Surg.* 2014;28(6):1396-401.
- Hiramoto JS, Chang CK, Reilly LM, Schneider DB, Rapp JH, Chuter TA. Outcome of renal stenting for renal artery coverage during endovascular aortic aneurysm repair. *J Vasc Surg.* 2009;49:1100-6.
- Hirsch AT, Haskal ZJ, Hertzner NR, Bakal CW, Creager MA, Halperin JL, Hiratzka LF, Murphy WR, Olin JW, Puschett JB, Rosenfield KA, Sacks D, Stanley JC, Taylor LM Jr, White CJ, White J, White RA, Antman EM, Smith SC Jr, Adams CD, Anderson JL, Faxon DP, Fuster V, Gibbons RJ, Hunt SA, Jacobs AK, Nishimura R, Ornato JP, Page RL, Riegel B; American Association for Vascular Surgery/Society for Vascular Surgery; Society for Cardiovascular Angiography and Interventions; Society for Vascular Medicine and Biology; Society of Interventional Radiology; ACC/AHA Task Force on Practice Guidelines. ACC/AHA Guidelines for the Management of Patients with Peripheral Arterial Disease (lower extremity, renal, mesenteric, and abdominal aortic): a collaborative report from the American Associations for Vascular Surgery/Society for Vascular Surgery, Society for Cardiovascular Angiography and Interventions, Society for Vascular Medicine and Biology, Society of Interventional Radiology, and the ACC/AHA Task Force on Practice Guidelines (writing committee to develop guidelines for the management of patients with peripheral arterial disease)--summary of recommendations. *J Vasc Interv Radiol.* 2006;17(9):1383-97.
- Hogendoorn W, Schlösser FJ, Moll FL, Sumpio BE, Muhs BE. Thoracic endovascular aortic repair with the chimney graft technique. *J Vasc Surg.* 2013;58(2):502-11.
- Holst J, Resch T, Ivancev K, Björse K, Dias N, Lindblad B, Mathiessen S, Sonesson B, Malina M. Early and intermediate outcome of emergency endovascular aneurysm repair of ruptured infrarenal aortic aneurysm: a single-centre experience of 90 consecutive patients. *Eur J Vasc Endovasc Surg.* 2009;37(4):413-9.
- Hultgren R. Abdominal aortic aneurysms--gender aspects on prevalence, treatment, and concurrent aneurysms. *Thorac Cardiovasc Surg.* 2013;61(1):15-21.
- Hultgren R, Olofsson P, Wahlberg E. Gender differences in patients treated for critical limb ischemia. *Eur J Vasc Endovasc Surg.* 2005;29(3):295-300.
- Inoue K, Hosokawa H, Iwase T, Sato M, Yoshida Y, Ueno K, Tsubokawa A, Tanaka T, Tamaki S, Suzuki T. Aortic arch reconstruction by transluminally placed endovascular branched stent graft. *Circulation.* 1999;100(19 Suppl):II316-21.
- Iskander AZ (Ed): A catalogue of arabic manuscripts on medicine and science in the Wellcome Historical Medical Library. London, The Wellcome Historical Medical Library Series, 1967.
- Ivancev K, Malina M, Lindblad B, Chuter TA, Brunkwall J, Lindh M, Nyman U, Risberg B. Abdominal aortic aneurysms: experience with the Ivancev-Malmö endovascular system for aortomoniliac stent-grafts. *J Endovasc Surg.* 1997;4(3):242-51.

- Jackson A, Yeoh SE, Clarke M. Totally percutaneous versus standard femoral artery access for elective bifurcated abdominal endovascular aneurysm repair. *Cochrane Database Syst Rev.* 2014;2:CD010185.
- Johnston KW, Rutherford RB, Tilson MD, Shah DM, Hollier L, Stanley JC. Suggested standards for reporting on arterial aneurysms. Subcommittee on Reporting Standards for Arterial Aneurysms, Ad Hoc Committee on Reporting Standards, Society for Vascular Surgery and North American Chapter, International Society for Cardiovascular Surgery. *J Vasc Surg.* 1991;13(3):452-8.
- Joseph G, Janakiraman E, Subban V, Jamesraj J, Mullasari AS. Concurrent endovascular repair of extensive thoracic aortic and infra-renal aorto-iliac aneurysms. *Heart Lung Circ.* 2012;21(12):803-5.
- Kasirajan K. Branched grafts for thoracoabdominal aneurysms: off-label use of FDA-approved devices. *J Endovasc Ther.* 2011;18(4):471-6.
- Katsargyris A, Oikonomou K, Klonaris C, Töpel I, Verhoeven EL. Comparison of outcomes with open, fenestrated, and chimney graft repair of juxtarenal aneurysms: are we ready for a paradigm shift? *J Endovasc Ther.* 2013;20(2):159-69.
- Kienz P, Austermann M, Tessarek J, Torsello G. [Treatment of complex aortic aneurysms with fenestrated endografts—first results]. *Zentralbl Chir.* 2010;135(5):427-32.
- Kolvenbach RR, Karmeli R, Pinter LS, Zhu Y, Lin F, Wassiljew S, Meyer-Gaessner M. Endovascular management of ascending aortic pathology. *J Vasc Surg.* 2011;53(5):1431-7.
- Kolvenbach RR, Yoshida R, Pinter L, Zhu Y, Lin F. Urgent endovascular treatment of thoraco-abdominal aneurysms using a sandwich technique and chimney grafts--a technical description. *Eur J Vasc Endovasc Surg.* 2011;41(1):54-60.
- Kristmundsson T, Sonesson B, Dias N, Malina M, Resch T. Association between the SVS/AAVS anatomical severity grading score and operative outcomes in fenestrated endovascular repair of juxtarenal aortic aneurysm. *J Endovasc Ther.* 2013;20(3):356-65.
- Kristmundsson T, Sonesson B, Dias N, Törnqvist P, Malina M, Resch T. Outcomes of fenestrated endovascular repair of juxtarenal aortic aneurysm. *J Vasc Surg.* 2014;59(1):115-20.
- Kristmundsson T, Sonesson B, Malina M, Björse K, Dias N, Resch T. Fenestrated endovascular repair for juxtarenal aortic pathology. *J Vasc Surg.* 2009;49(3):568-74.
- Kuntz E, Kuntz H-D. *Hepatology.* Springer-Verlag, Berlin, 2008.
- Lachat M, Bisdas T, Rancic Z, Torsello G, Mayer D, Gil-Sales J, Pecoraro F, Donas KP. Chimney endografting for pararenal aortic pathologies using transfemoral access and the lift technique. *J Endovasc Ther.* 2013;20(4):492-7.
- Lachat M, Frauenfelder T, Mayer D, Pfiffner R, Veith FJ, Rancic Z, Pfammatter T. Complete endovascular renal and visceral artery revascularization and exclusion of a ruptured type IV thoracoabdominal aortic aneurysm. *J Endovasc Ther.* 2010;17(2):216-20.
- Lachat M, Veith FJ, Pfammatter T, Glenck M, Bettex D, Mayer D, Rancic Z, Gloekler S, Pecoraro F. Chimney and periscope grafts observed over 2 years after their use to

- revascularize 169 renovisceral branches in 77 patients with complex aortic aneurysms. *J Endovasc Ther.* 2013;20(5):597-605.
- Larzon T, Eliasson K, Gruber G. Top-fenestrating technique in stentgrafting of aortic diseases with mid-term follow-up. *J Cardiovasc Surg (Torino).* 2008;49(3):317-22.
- Larzon T, Gruber G, Friberg O, Geijer H, Norgren L. Experiences of intentional carotid stenting in endovascular repair of aortic arch aneurysms—two case reports. *Eur J Vasc Endovasc Surg.* 2005;30(2):147-51.
- Larzon T, Skoog P. One hundred percent of ruptured aortic abdominal aneurysms can be treated endovascularly if adjunct techniques are used such as chimneys, periscopes and embolization. *J Cardiovasc Surg (Torino).* 2014;55(2):169-78.
- Lascartos J, Liapis C, Ionidos C. Surgery of aneurysms in Byzantine times (324-1453 A.D.). *Eur J Vasc Endovasc Surg.* 1998;15:110-4.
- Lawrence-Brown M, Sieunarine K, Hartley D, van Schie G, Goodman MA, Prendergast FJ. The Perth HLB bifurcated endoluminal graft: a review of the experience and intermediate results. *Cardiovasc Surg.* 1998;6(3):220-5.
- Lee JT, Greenberg JI, Dalman RL. Early experience with the snorkel technique for juxtarenal aneurysms. *J Vasc Surg.* 2012;55:935-46.
- Lee S, Ko YG, Choi D, Lee DY. A case of abdominal aortic aneurysm with short angulated proximal neck treated with the chimney graft technique. *Korean Circ J.* 2013;43(6):416-21.
- Leriche R, Morel A. The syndrome of thrombotic obliteration of the aortic bifurcation. *Ann Surg.* 1948;127:193-206.
- Lobato AC. Sandwich technique for aortoiliac aneurysms extending to the internal iliac artery or isolated common/internal iliac artery aneurysms: a new endovascular approach to preserve pelvic circulation. *J Endovasc Ther.* 2011;18(1):106-11.
- Lobato AC, Camacho-Lobato L. The sandwich technique to treat complex aortoiliac or isolated iliac aneurysms: results of midterm follow-up. *J Vasc Surg.* 2013;57(2):26S-34S.
- Lobato AC, Camacho-Lobato L. Endovascular treatment of complex aortic aneurysms using the sandwich technique. *J Endovasc Ther.* 2012;19(6):691-706.
- Malina M, Resch T, Sonesson B. EVAR and complex anatomy: an update on fenestrated and branched stent grafts. *Scand J Surg.* 2008;97(2):195-204.
- Manning BJ, Agu O, Richards T, Ivancev K, Harris PL. Early outcome following endovascular repair of pararenal aortic aneurysms: triple- versus double- or single-fenestrated stent-grafts. *J Endovasc Ther.* 2011;18(1):98-105.
- Manning BJ, Agu O, Richards T, Ivancev K, Harris PL. Temporary axillobifemoral bypass as an adjunct to endovascular aneurysm repair using fenestrated stent grafts. *J Vasc Surg.* 2011;53(3):867-9.
- Mangialardi N, Serrao E, Kasemi H, Alberti V, Fazzini S, Ronchey S. Chimney technique for aortic arch pathologies: an 11-year single-center experience. *J Endovasc Ther.* 2014;21(2):312-23.

- Mangialardi N, Ronchey S, Serrao E, Fazzini S, Alberti V, Orrico M, Kasemi H. Endovascular management of total juxtarenal aortic occlusive disease in high-risk patients: technical considerations and clinical outcome. *J Cardiovasc Surg (Torino)*. In press.
- Marino M, Kasemi H, Di Angelo CL, Fadda GF. Ruptured Thoracoabdominal Aneurysm Treatment with modified chimney stent graft. *Ann Thorac Surg*. 2014;98(2):e37-40.
- Massmann A, Serracino-Inglott F, Buecker A. Endovascular aortic repair with the chimney technique using the ultra low-profile Ovation stent-graft for juxtarenal aneurysms having small iliac access vessels. *Cardiovasc Intervent Radiol*. 2014;37(2):488-92.
- Matas R. Traumatic aneurysm of the left brachial artery. Incision and arterial excision of the sac-recovery. *Med News NY*. 1888;53:462-6.
- McWilliams RG, Murphy M, Hartley D, Lawrence-Brown MM, Harris PL. In situ stent-graft fenestration to preserve the left subclavian artery. *J Endovasc Ther*. 2004;11(2):170-4.
- Muhs BE, Verhoeven EL, Zeebregts CJ, Tielliu IF, Prins TR, Verhagen HJ, van den Dungen JJ. Mid-term results of endovascular aneurysm repair with branched and fenestrated endografts. *J Vasc Surg*. 2006;44(1):9-15.
- Mitsuoka H, Shintani T, Saito T, Norimatsu T, Higashi S. Preservation of aortic arch branches using chimney and sandwich stent grafts. *Ann Vasc Dis*. 2012;5(1):73-7
- Mestres G, Zarka ZA, García-Madrid C, Riambau V. Early abdominal aortic endografts: a decade follow-up results. *Eur J Vasc Endovasc Surg*. 2010;40(6):722-8.
- Moulakakis KG, Mylonas SN, Avgerinos E, Papapetrou A, Kakisis JD, Brountzos EN, Liapis CD. The chimney graft technique for preserving visceral vessels during endovascular treatment of aortic pathologies. *J Vasc Surg*. 2012 ;55(5):1497-503.
- Oderich GS, Greenberg RK, Farber M, Lyden S, Sanchez L, Fairman R, Jia F, Bhadraraj P; Zenith Fenestrated Study Investigators. Results of the United States multicenter prospective study evaluating the Zenith fenestrated endovascular graft for treatment of juxtarenal abdominal aortic aneurysms. *J Vasc Surg*. 2014;60(6):1420-8.
- Ohrlander T, Sonesson B, Ivancev K, Resch T, Dias N, Malina M. The chimney graft: a technique for preserving or rescuing aortic branch vessels in stent-graft sealing zones. *J Endovasc Ther*. 2008;15:427-32.
- O'Neill S, Greenberg RK, Haddad F, Resch T, Sereika J, Katz E. Prospective analysis of fenestrated endovascular grafting: intermediate-term outcomes. *Eur J Vasc Endovasc Surg*. 2006;32:115-23.
- Ouzounian M, LeMaire SA, Coselli JS. Open aortic arch repair: state-of-the-art and future perspectives. *Semin Thorac Cardiovasc Surg*. 2013;25(2):107-15.
- Paravastu SC, Jayarajasingam R, Cottam R, Palfreyman SJ, Michaels JA, Thomas SM. Endovascular repair of abdominal aortic aneurysm. *Cochrane Database Syst Rev*. 2014;1:CD004178.
- Park JH, Chung JW, Choo IW, Kim SJ, Lee JY, Han MC. Fenestrated stent-grafts for preserving the visceral arterial branches in the treatment of abdominal aortic aneurysms: preliminary experience. *J Vasc Interv Radiol*. 1996;7:819-23.

- Parodi JC, Palmaz JC, Barone HD. Transfemoral intraluminal graft implantation for abdominal aortic aneurysms. *Ann Vasc Surg.* 1991;5(6):491-9.
- Patel AY, Eagle KA, Vaishnava P. Acute type B aortic dissection: insights from the International Registry of Acute Aortic Dissection. *Ann Cardiothorac Surg.* 2014;3(4):368-74.
- Pearce WH, Shively VP. Abdominal aortic aneurysm as a complex multifactorial disease: interactions of polymorphisms of inflammatory genes, features of autoimmunity, and current status of MMPs. *Ann N Y Acad Sci.* 2006;1085:117-32.
- Pearn J. Gunpowder, the Prince of Wales's feathers and the origins of modern military surgery. *ANZ J Surg.* 2012;82(4):240-4.
- Pecoraro F, Pfammatter T, Mayer D, Frauenfelder T, Papadimitrou D, Hechelhammer L, Veith FJ, Lachat M, Rancic Z. Multiple periscope and chimney grafts to treat ruptured thoracoabdominal and pararenal aortic aneurysms. *J Endovasc Ther.* 2011;18:642-9.
- Perry MO. John Hunter-triumph and tragedy. *J Vasc Surg.* 1993;17:7-14.
- Pfister K, Krammer S, Janotta M, Jung EM, Kasprzak P. Ultrasound for surveillance after endovascular repair of abdominal aortic aneurysm--simple and safe? *Zentralbl Chir.* 2010;135(5):409-15.
- Prinssen M, Verhoeven EL, Buth J, Cuypers PW, van Sambeek MR, Balm R, Buskens E, Grobbee DE, Blankensteijn JD; Dutch Randomized Endovascular Aneurysm Management (DREAM) Trial Group. A randomized trial comparing conventional and endovascular repair of abdominal aortic aneurysms. *N Engl J Med.* 2004;351(16):1607-18.
- Qadura M, Pervaiz F, Harlock JA, Al-Azzoni A, Farrokhyar F, Kahnamoui K, Szalay DA, Rapanos T. Mortality and reintervention following elective abdominal aortic aneurysm repair. *J Vasc Surg.* 2013;57(6):1676-83.
- Rancic Z, Pfammatter T, Lachat M, Hechelhammer L, Frauenfelder T, Veith FJ Criado FJ, Mayer D. Periscope graft to extend distal landing zone in ruptured thoracoabdominal aneurysms with short distal necks. *J Vasc Surg* 2010; 51:1293-6.
- Resch T, Malina M, Lindblad B, Ivancev K. The impact of stent-graft development on outcome of AAA repair--a 7-year experience. *Eur J Vasc Endovasc Surg.* 2001;22(1):57-61.
- Richardson S, Popori RK, Pichel AC, Farquharson F, Serracino-Inglott F. A ruptured thoracoabdominal aortic aneurysm managed endovascularly using the telescoping chimney technique. *Ann Vasc Surg* 2011; 25: 384.e1-e4.
- Ricci C, Ceccherini C, Leonini S, Vigni F, Cini M, Neri E, Tommasino G, Tucci E, Benvenuti A, Sassi C. Double renal chimney graft using only femoral approach. *J Cardiovasc Surg (Torino).* 2011; 52: 93-97.
- Rouer M, El Batti S, Julia P, de Blic R, Fabiani JN, Alsac JM. Chimney **stent graft** for endovascular sealing of a pararenal aortic aneurysm. *Ann Vasc Surg.* 2014;28(8):1936.e15-8.
- Rutherford RB. Structural failures in abdominal aortic aneurysm stentgrafts: Threat to durability and challenge to technology. *Semin Vasc Surg.* 2004 Dec;17(4):294-7.

- Samura M, Zempo N, Ikeda Y, Hidaka M, Kaneda Y, Suzuki K, Tsuboi H, Hamano K. Endovascular repair of distal arch aneurysm with double-chimney technique. *Ann Thorac Surg.* 2013;95(5):1778-80.
- Schiro A, Antoniou GA, Ormesher D, Pichel AC, Farquharson F, Serracino-Inglott F. The chimney technique in endovascular aortic aneurysm repair: late ruptures after successful single renal chimney stent grafts. *Ann Vasc Surg.* 2013;27(7):835-43.
- Schlosser FJ, Aruny JE, Freiburg CB, Mojibian HR, Sumpio BE, Muhs BE. The chimney procedure is an emergently available endovascular solution for visceral aortic aneurysm rupture. *J Vasc Surg* 2011;53:1386-90.
- Scurr JR, Brennan JA, Gilling-Smith GL, Harris PL, Vallabhaneni SR, McWilliams RG. Fenestrated endovascular repair for juxtarenal aortic aneurysm. *Br J Surg.* 2008;95(3):326-32.
- Semmens JB, Lawrence-Brown MM, Hartley DE, Allen YB, Green R, Nadkarni S. Outcomes of fenestrated endografts in the treatment of abdominal aortic aneurysm in Western Australia (1997–2004). *J Endovasc Ther.* 2006;13(3):320-9.
- Sethi RK, Henry AJ, Hevelone ND, Lipsitz SR, Belkin M, Nguyen LL. Impact of hospital market competition on endovascular aneurysm repair adoption and outcomes. *J Vasc Surg.* 2013;58(3):596-606.
- Shahverdyan R, Gawenda M, Brunkwall J. Triple-barrel graft as a novel strategy to preserve supra-aortic branches in arch-TEVAR procedures: clinical study and systematic review. *Ann Vasc Surg.* 2013;27(7):835-43.
- Shu C, Wang T, Li M, Li X, Li QM, Fang K. [Endovascular aortic repair plus chimney technique in the treatment of Stanford type B aortic dissection involving aortic arch]. *Zhonghua Yi Xue Za Zhi.* 2012;92(47):3320-3.
- Shu C, Luo MY, Li QM, Li M, Wang T, He H. Early results of left carotid chimney technique in endovascular repair of acute non-a-non-B aortic dissections. *J Endovasc Ther.* 2011;18(4):477-84.
- Silveira PG, Galego GN, Bortoluzzi CT, Franklin RN. RE: Branched grafts for thoracoabdominal aneurysms: Off-label use of FDA-approved devices. *J Endovasc Ther.* 2012;19(1):130.
- Slaney, G. A history of aneurysm surgery. in: *The cause and management of aneurysms.* Eds. RM Greenhalgh, JA Mannick, JT Powell. WB Saunders, London; 1990:1-18.
- Stewart B, Khanduri P, McCord C, Ohene-Yeboah M, Uranues S, Vega Rivera F, Mock C. Global disease burden of conditions requiring emergency surgery. *Br J Surg.* 2014;101(1):e9-22.
- Sugiura K, Sonesson B, Akesson M, Björnses K, Holst J, Malina M. The applicability of chimney grafts in the aortic arch. *J Cardiovasc Surg (Torino).* 2009;50(4):475-81.
- Tan GW, Wong D, Punamiya S, Tan BP, Vu C, Ang B, Foo D, Chia KH. Aortoenteric fistula treated with endovascular aortic stent-graft and bilateral chimney stent-grafts to renal arteries. *Ann Vasc Surg.* 2012;26:422.e13–e16.
- Tolenaar JL, Zandvoort HJ, Moll FL, van Herwaarden JA. Technical considerations and results of chimney grafts for the treatment of juxtarenal aneurysms. *J Vasc Surg.* 2013;58(3):607-15.

- Tsilimparis N1, Perez S, Dayama A, Ricotta JJ 2nd. Endovascular repair with fenestrated-branched stent grafts improves 30-day outcomes for complex aortic aneurysms compared with open repair. *Ann Vasc Surg.* 2013;27(3):267-73.
- Tsilimparis N, Perez S, Dayama A, Ricotta JJ 2nd, Van Marrewijk CJ, Leurs LJ, Vallabhaneni SR, Harris PL, Buth J, Laheij RJ; EUROSTAR collaborators. Risk-adjusted outcome analysis of endovascular abdominal aortic aneurysm repair in a large population: how do stent-grafts compare? *J Endovasc Ther.* 2005;12(4):417-29.
- Van Beek SC, Conijn AP, Koelemay MJ, Balm R. Endovascular Aneurysm Repair Versus Open Repair for Patients with a Ruptured Abdominal Aortic Aneurysm: A Systematic Review and Meta-analysis of Short-term Survival. *Eur J Vasc Endovasc Surg.* 2014;47(6):593-602.
- Varu VN, Tran K, Chandra V, Lee GK, Dalman RK, Lee JT. Midterm Changes in Renal Function Following Snorkel Repair of Juxtarenal Aneurysms. *J Vasc Surg.* 2013;58(2):555.
- Van Beek SC, Conijn AP, Koelemay MJ, Balm R. Editor's Choice - Endovascular aneurysm repair versus open repair for patients with a ruptured abdominal aortic aneurysm: a systematic review and meta-analysis of short-term survival. *Eur J Vasc Endovasc Surg.* 2014;47(6):593-602.
- Van Marrewijk CJ, Leurs LJ, Vallabhaneni SR, Harris PL, Buth J, Laheij RJ; EUROSTAR collaborators. Risk-adjusted outcome analysis of endovascular abdominal aortic aneurysm repair in a large population: how do stent-grafts compare? *J Endovasc Ther.* 2005;12(4):417-29.
- Veith FJ, Lachat M, Mayer D, Malina M, Holst J, Mehta M, Verhoeven EL, Larzon T, Gennai S, Coppi G, Lipsitz EC, Gargiulo NJ, van der Vliet JA, Blankensteijn J, Buth J, Lee WA, Biasi G, Deleo G, Kasirajan K, Moore R, Soong CV, Cayne NS, Farber MA, Raithel D, Greenberg RK, van Sambeek MR, Brunkwall JS, Rockman CB, Hinchliffe RJ; RAAA Investigators. Collected world and single center experience with endovascular treatment of ruptured abdominal aortic aneurysms. *Ann Surg.* 2009;250(5):818-24.
- Verhoeven EL, Vourliotakis G, Bos WT, Tielliu IF, Zeebregts CJ, Prins TR, Bracale UM, van den Dungen JJ. Fenestrated stent grafting for short-necked and juxtarenal abdominal aortic aneurysm: an 8-year single-centre experience. *Eur J Vasc Endovasc Surg.* 2010;39(5):529-36.
- Volodos NL, Shekhanin VE, Karpovich IP, Troian VI, Gur'ev IA. A self-fixing synthetic blood vessel endoprosthesis. *Vestn Khir Im I I Grek.* 1986;137(11):123-5.
- Volodos NL, Karpovich IP, Shekhanin VE, Troian VI, Iakovenko LF. A case of distant transfemoral endoprosthesis of the thoracic artery using a self-fixing synthetic prosthesis in traumatic aneurysm. *Grudn Khir.* 1988 Nov-Dec;(6):84-6.
- Volodos NL, Karpovich IP, Troyan VI, Kalashnikova YuV, Shekhanin VE, Ternyuk NE, Neoneta AS, Ustinov NI, Yakovenko LF. Clinical experience of the use of self-fixing synthetic prostheses for remote endoprosthetics of the thoracic and the abdominal aorta and iliac arteries through the femoral artery and as intraoperative endoprosthesis for aorta reconstruction. *Vasa.* 1991;33(Suppl):93-5.

- Von Meijenfeldt GC, Ultee KH, Eefting D, Hoeks SE, Ten Raa S, Rouwet EV. Differences in mortality, risk factors, and complications after open and endovascular repair of ruptured abdominal aortic aneurysms. *Eur J Vasc Endovasc Surg.* 2014;47(5):479-86.
- Wilson A, Zhou S, Bachoo P, Tambyraja AL. Systematic review of chimney and periscope grafts for endovascular aneurysm repair. *Br J Surg.* 2013;100(12):1557-64.
- Wylie EJ. Thromboendarterectomy for arteriosclerotic thrombosis of major arteries. *Surgery.* 1952;32(2):275-92.
- Zhang T, Jia X, Liu J, Jia SH, Guo W. [Approach and efficacy of endovascular repair for abdominal aortic aneurysm with hostile proximal landing zone]. *Zhonghua Yi Xue Za Zhi.* 2012;92(47):3329-32.
- Zhou W, Zhou W, Qiu J. Endovascular repair of an aortic arch pseudoaneurysm with double chimney stent grafts: a case report. *J Cardiothorac Surg.* 2013;8:80-7..
- Yuri K, Yokoi Y, Yamaguchi A, Hori D, Adachi K, Adachi H. Usefulness of fenestrated stent grafts for thoracic aortic aneurysms. *Eur J Cardiothorac Surg.* 2013;44(4):760-766.
- Yoshida RA, Kolvenbach R, Yoshida WB, Wassijew S, Schwierz E, Lin F. Total Endovascular Debranching of the Aortic Arch. *Eur J Vasc Endovasc Surg.* 2011;42(5):627-30.
- Yusuf SW, Whitaker SC, Chuter TA, Wenham PW, Hopkinson BR. Emergency endovascular repair of leaking aortic aneurysm. *Lancet.* 1994;344(8937):1645.
- Xue Y, Sun L, Zheng J, Huang X, Guo X, Li T, Huang L. The chimney technique for preserving the left subclavian artery in thoracic endovascular aortic repair. *Eur J Cardiothorac Surg.* 2014 In press.